



Case

1

Acro Dental Clinic
Director
Oh, Sang-Yoon

Implant position: #24

Age:32, Sex:M

Nonsubmerged GBR Using Customized 3D Titanium Membrane (SMARTmembrane)

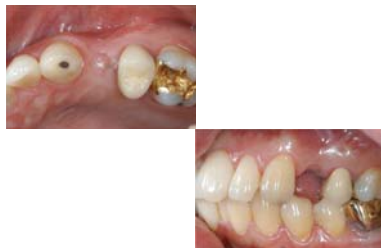

Fig. 1. A Preoperative intraoral view (postext. 4ms). Horizontal deficiency at labial side (#24).

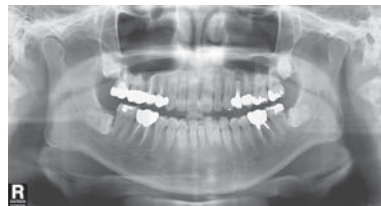

Fig. 2. Initial panorama.

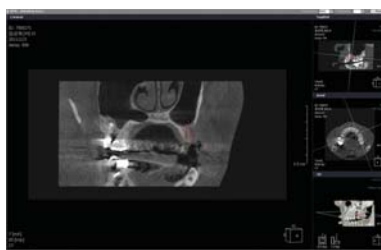


Fig. 3-4. Preop CT (#24). Severe Labial bone resorption.

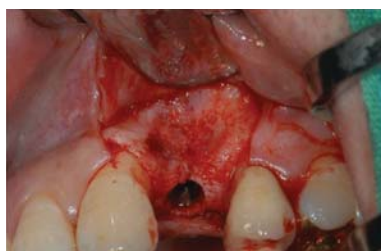

Fig. 5-6. Implantation (TS III SA) & sinus lifting. Labial bone deficiency.

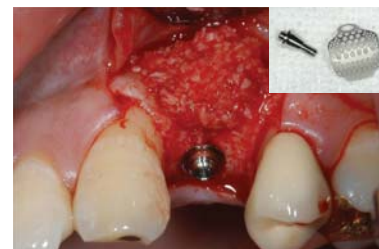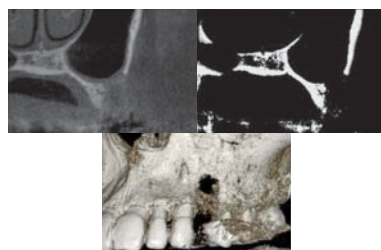


Fig. 7. Bone Graft for labial augmentation.

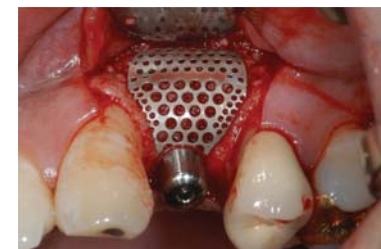

Fig. 8. Osstem SMARTmembrane (Type I).

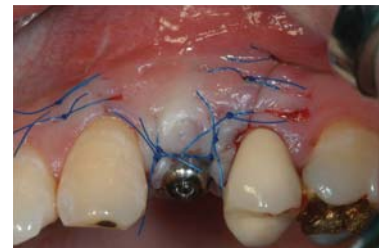

Fig. 9. Nonsubmerged GBR using healing abutment.

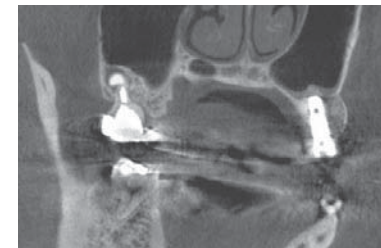

Fig. 10. Postop CT (#24). Labial augmentation using bone graft & SMARTmembrane.

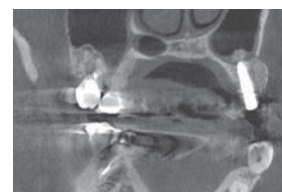
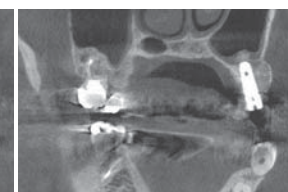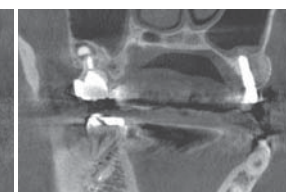


Fig. 11-13. 2ms later postop. CT (#24).
* Coronal section at mesial side.



* Coronal section at center area.



* Coronal section at distal side.

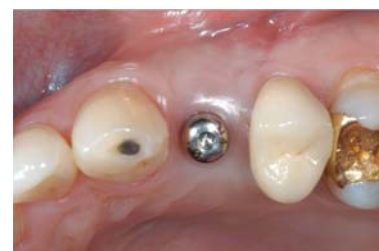

Fig. 14. 2ms later. Good nonsubmerged healing of GBR.

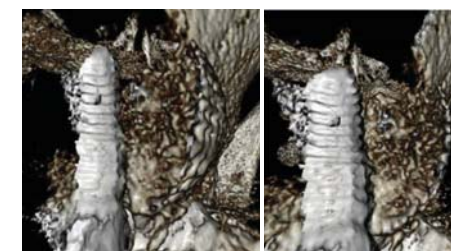


Fig. 15-16. 2ms later 3D CT (#24). Incredible space maintenance. No loss of graft material in the SMARTmembrane.

<http://Shetak.com>

Smart Membrane (TSIII SA) SA



Case

2

Apsun Dental Clinic
Director
Cho, Yong-Seok

Implant position: #14

Age:59, Sex:F

GBR on Premolar Defect Using the SMARTmembrane

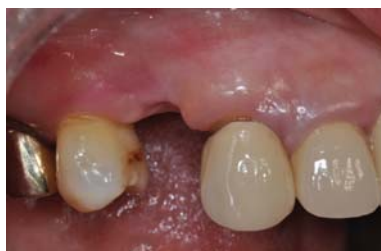

Fig. 1-2. 59 years old female visited to place an implant at upper right 1st premolar missing site. She received implant 7 years ago and it was retrieved 7 months ago due to the mobility of the implant which involved in severe peri-implantitis. Soft tissue was well healed but it showed insufficient tissue volume.

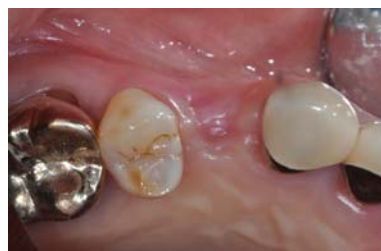

Fig. 3. Panoramic view shows relatively radiolucent image of premolar missing site.

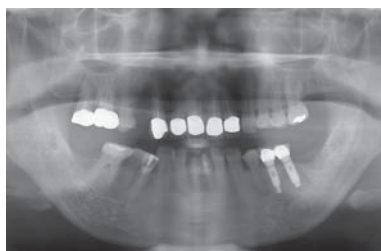

Fig. 4. Bone was exposed after mucoperiosteal flap elevation. Bone healing was very poor even 7 months after the fixture removal.

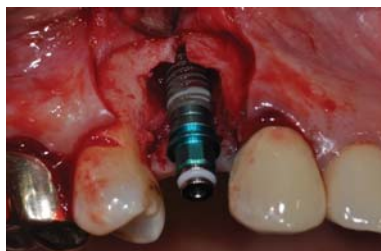

Fig. 5. After site preparation TSIII SA ϕ 4.0x11.5mm fixture was installed.

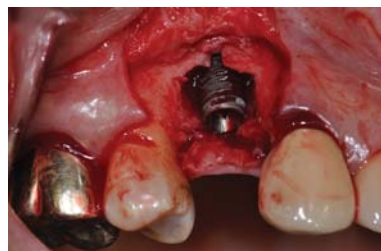

Fig. 6. Bone defect around the fixture was carefully examined to select a SMARTmembrane. Buccal and proximal and slight palatal bone defects were observed.



Fig. 7-8. Height of 1.0mm was selected and connected on the fixture.




Fig. 9. A Type 3 SMARTmembrane was selected.

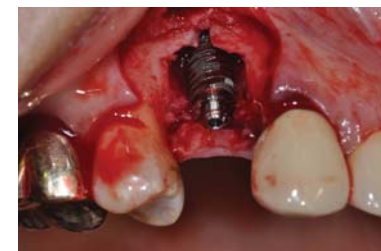

Fig. 10. An allogenic bone substitute (SureOss 0.25cc) was grafted to fill the bone defects.

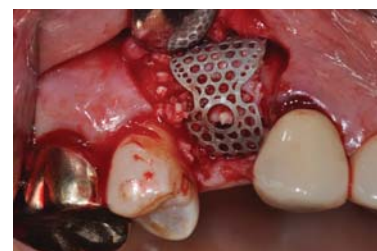

Fig. 11-12. The SMARTmembrane was fixed on the height using a healing abutment. The SMARTmembrane was directly applied without modification.

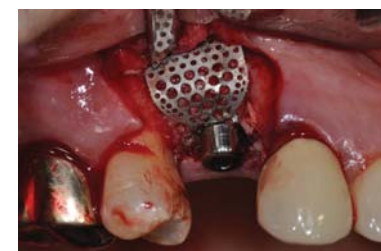


Fig. 13. Flap was closed with 5-0 nylon.

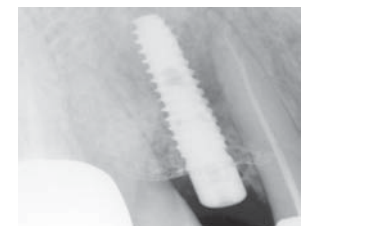

Fig. 14. POP Standard X-ray shows well adapted SMARTmembrane over the fixture and height.

<http://Shjetak.com>

Smart Membrane (TSIII SA)



Case

3

Yena Dental Clinic
Director
Yang, Choon-Mo

Implant position: #31, #42

Age:75, Sex:M

Immediate Implant Placement and Immediate Loading with Simultaneous Guided Bone Regeneration

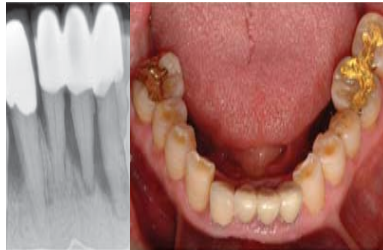

Fig. 1. A 75 year old male with failing fixed bridge at sites #32 to #42 due to advanced periodontal pathology.

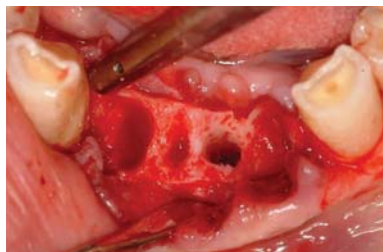

Fig. 3. Final osteotomy in sites #31 and #42.

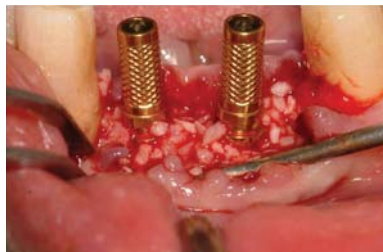

Fig. 5. Temporary abutments attached to the implants and mixture of particulated autogenous bone and FDA(OsteOs) placed into defective socket. Barrier membrane was not used.

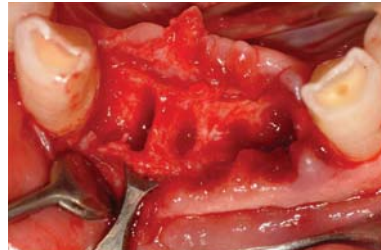


Fig. 2. Following the extraction, sharp and irregular bony spines were trimmed by chisel and collected for bone grafting.

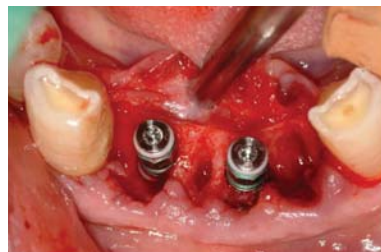

Fig. 4. Osstem TSIII SA implants placed at site #31 with insertion torque of 37Ncm and #42 with 27Ncm.

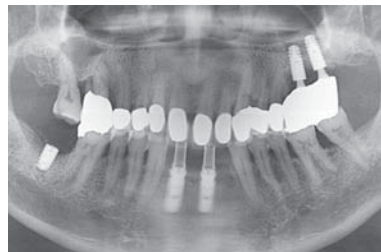


Fig. 6. Post-operative panoramic view before making provisional restoration.

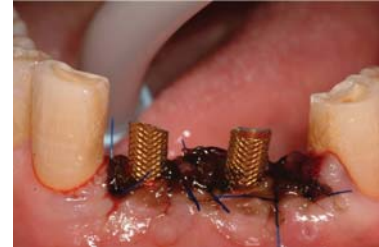

Fig. 7. Gingival protecting gel with nanoemulsion ingredients (NBF).

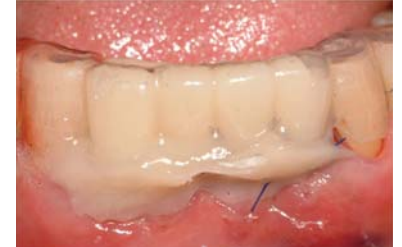

Fig. 8. Chair-side provisional restoration was made by relining the prefabricated omni-vec shell with autopolymerizing resin (Bis-Acrylic Protemp).

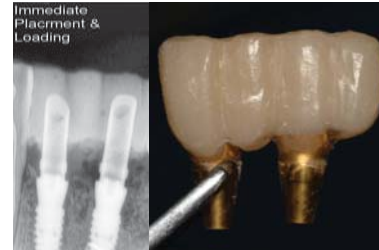


Fig. 9. Immediate post-operative periapical radiograph and retrievable screw-retained provisional restoration.

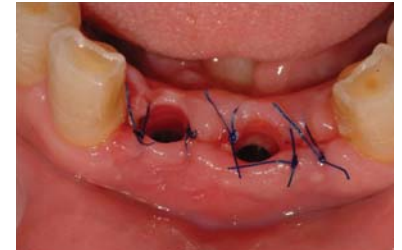

Fig. 10. Soft tissue healing at 2 weeks after surgery.

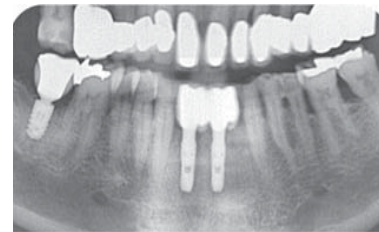

Fig. 11. 6 months after immediate loading.

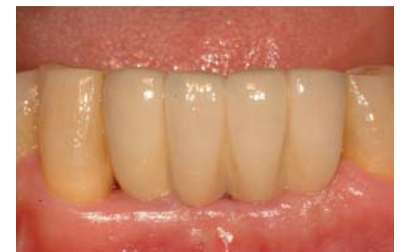

Fig. 12. Definite fixed partial denture at 1 year of immediate loading.

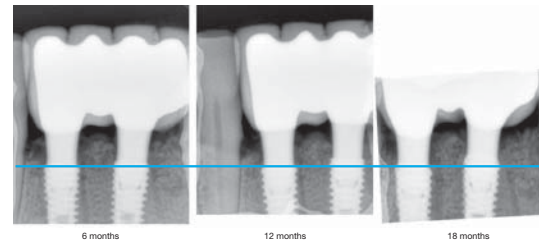


Fig. 13. Periapical radiograph at various remodeling period.

<http://Shattak.com>

TSIII SA System



Case

4

All Dental Clinic
Director
Oh, Young-Hak

Implant position: #37

Age: 49, Sex: F

TSIII SA Immediate Implant Installation

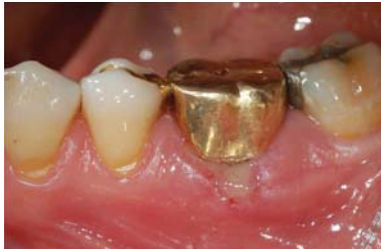

Fig. 1~2. Pre-operative photo and radiograph of extraction (Root bifurcation lesion owing to improper post surgery).

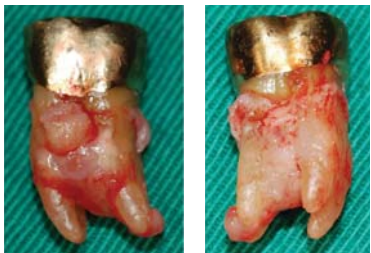
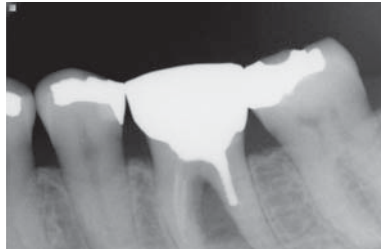


Fig. 3. Hyperparakeratosis acanthosis, with mild epithelial dysplasia.

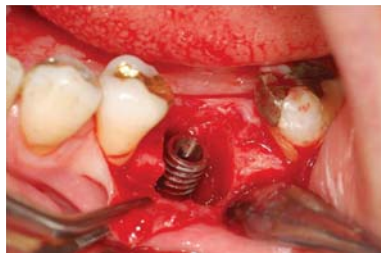

Fig. 4. Bone graft(MBCP) with immediate implantation.

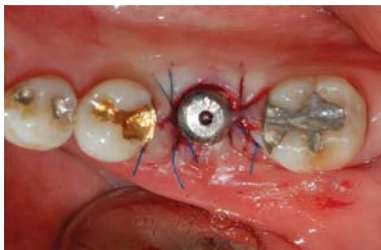

Fig. 5. One stage surgery
(TSIII SA ϕ 5.0*10mm, MBCP 0.5g).

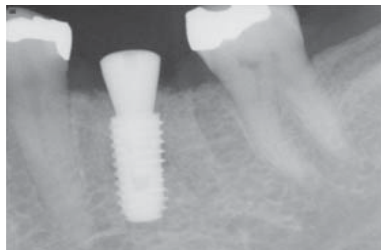


Fig. 6. Periapical radiograph after implantation (Good initial stability).

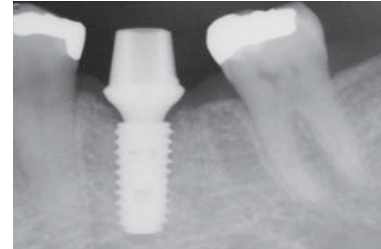


Fig. 7~8. 2 months after implant placement, transfer abutment(temporary) was connected and repeatedly tightened to 30Ncm. The cusp angle formed was low so that the shape and the form of the temporary protheses are less exposed to masticatory pressure.

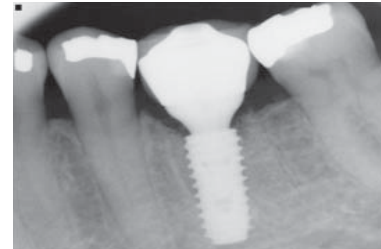
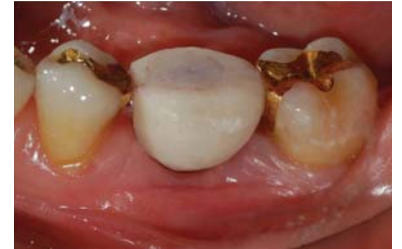

Fig. 9~10. Final prosthesis setting at 3 months after implant placement.

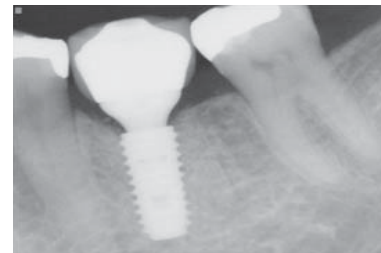
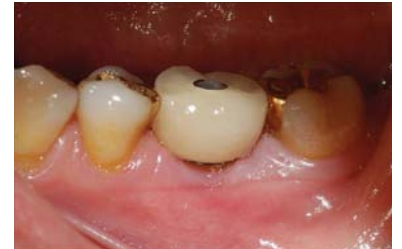
Fig. 11~12. 9 months after implant placement. Well-matured soft tissues are shown.

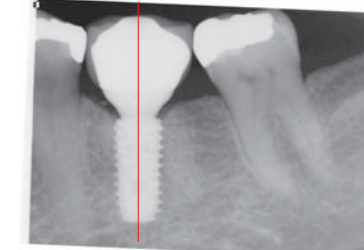
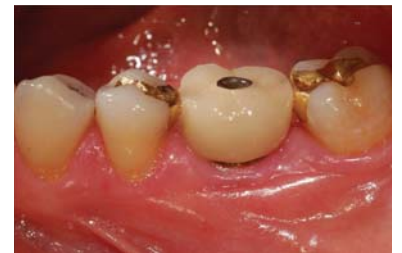

Fig. 13. Periapical radiograph at 18 months after implant placement.
We accomplished functional need and stable bone response around implants. The results were clinically satisfactory.

<http://Shetak.com>

Case

5

Seoul Dental Clinic
Director
Lee, Dae-Hee

Implant position: Multi.

Age: 32, Sex: F

Delayed Implantation of TSIII SA after Ridge Augmentation

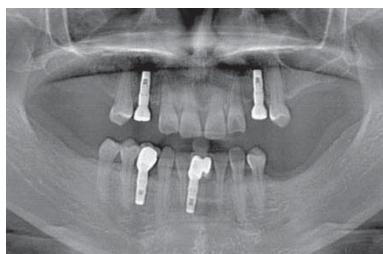


Fig. 1. This case was a referred case for severe atrophy of molar region and bone graft on the existing implant site.

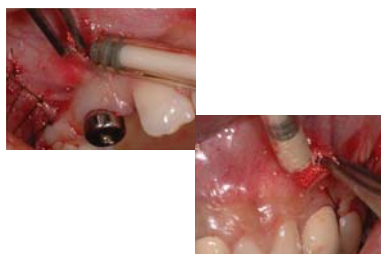


Fig. 2. Previous fixtures were given the GBR through the vertical incision only.

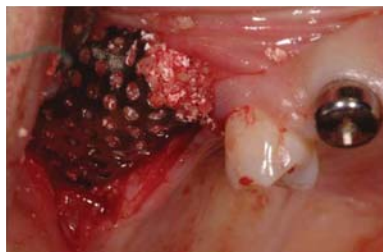

Fig. 3. Vertical & horizontal ridge augmentation was performed in right upper side using titanium mesh.

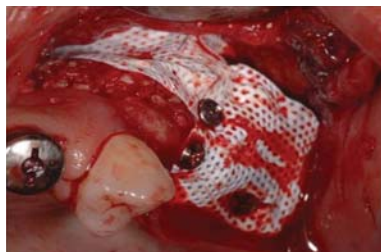


Fig. 4. In left upper area, sinus graft and ridge augmentation was done and flap was secured with the aid of buccal fat pad.

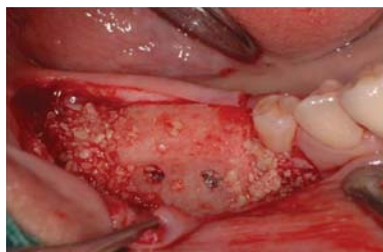

Fig. 5-6. Lower area shows the ridge augmentation with allogenic block bone which area was covered with Ossix membrane.

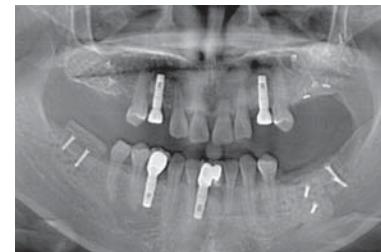
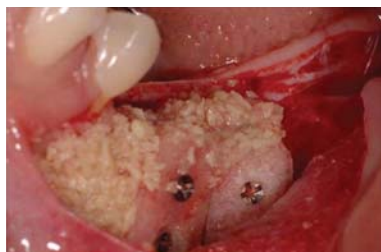
Fig. 7. This panoramic view shows the ridge augmented appearance.

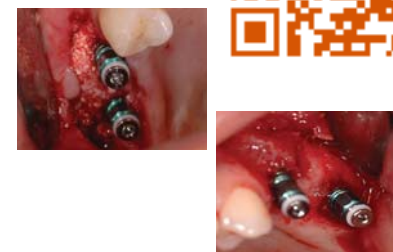

Fig. 8. Titanium mesh was removed after 5 months and four TSIII SA fixtures were installed in upper area.

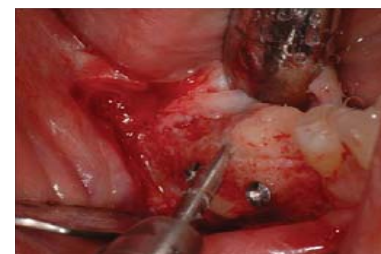

Fig. 9-10. Allogenic bone were combined well with host bone with a minor resorption. Excessive vertical bone was cut to the desirable amount.

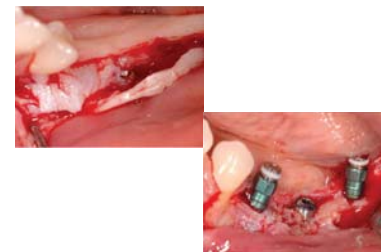
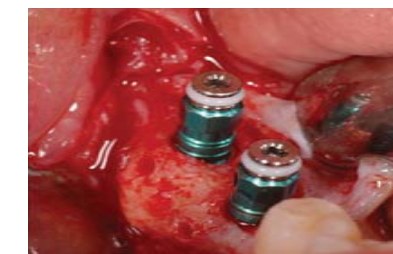

Fig. 11-12. Lt. side also showed the desirable amount of new bone at that time. All the fixtures were submerged in this surgery. 2nd surgery was prepared with APF & FGG in upper side and punch technique in lower side after 2 months.

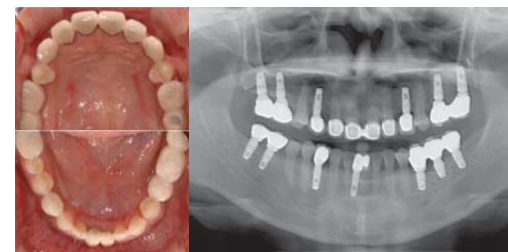
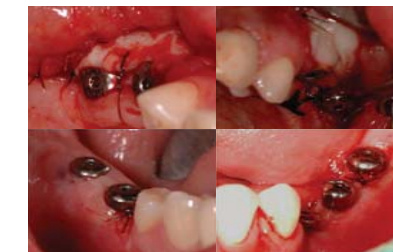


Fig. 13. The final restorations were engaged after passing through the periods of provisional restoration.



http://Shetak.com

TSIII SA System



Case

6

A' dent Dental Clinic
Director
Cho, Hyun-Ki

Implant position: Multi.

Age: 64, Sex: F

Milling CAD/CAM Titanium Abutment for Implant Prosthesis - Clinical Result

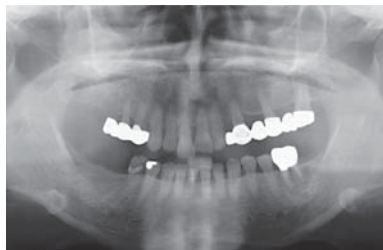

Fig. 1~2. #16, 17, 46, 47 TSIII SA Implant placement. One-stage method (2010. 5. 31).

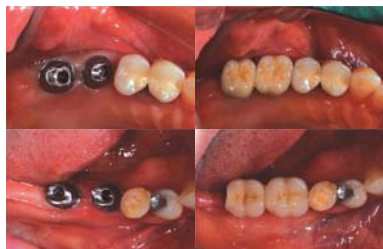
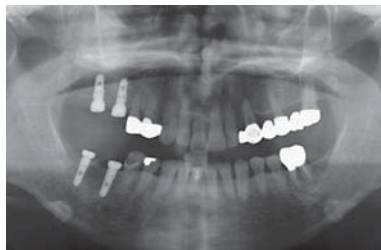
Fig. 3~8. #16, 17, 46, 47 final crown with custom abutment (2010. 8. 18).

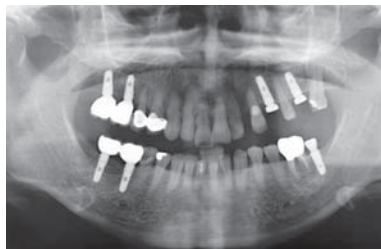
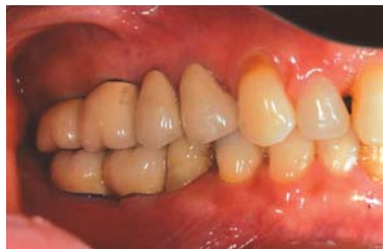
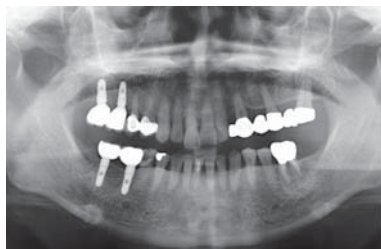Fig. 9. #23-27 crown and bridge removal.
#24, 26, 37 implant placement one-stage method
(2010. 8. 31).

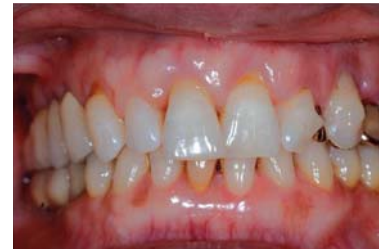

Fig. 10. #23 mesial space, #11 labial position.
Start of orthodontics treatment for labioversion and space recovery
(2010. 9. 8).

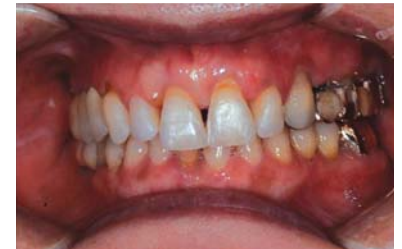

Fig. 11. #11 finish of orthodontics treatment (2010. 12. 7).

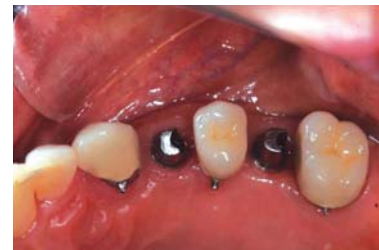

Fig. 12~13. #24, 26 final crown with transfer abutment (2010. 12. 22).

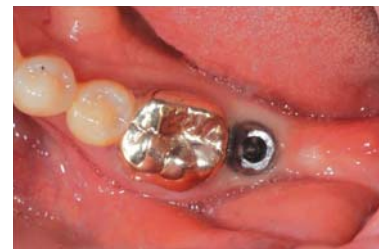
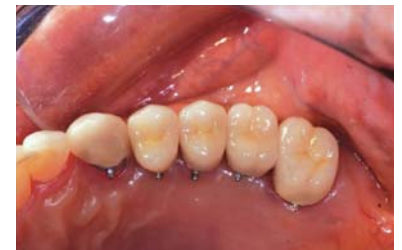
Fig. 14~15. #37 final crown with transfer abutment (2010. 12. 22).

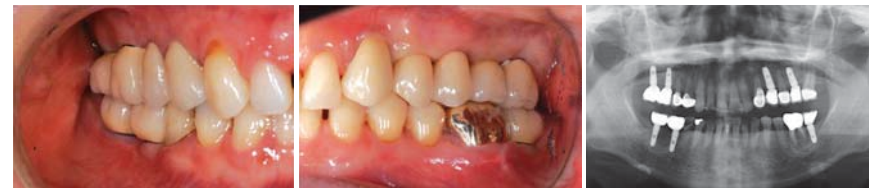
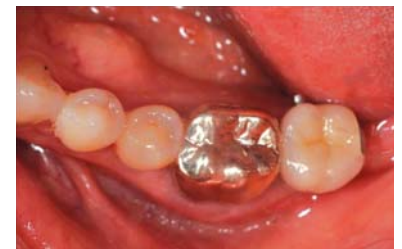
Fig. 16~18. Final prosthesis (2010. 12. 22).

<http://Shetaktak.com>

CAD/CAM Abutment - CustomFit (TSIII SA)



Case

7

Namsang Dental Clinic
Director
Kim Ki-Seong

Implant position: #36, #37

Age: 49, Sex: M

Maximizing Esthetic and Functional Outcomes through the Evolution in Implant Abutment Design: Osstem CAD/CAM “CustomFit” Abutment

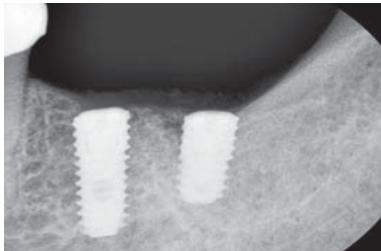


Fig. 1. Placed #36, #37 TSIII SA implants.

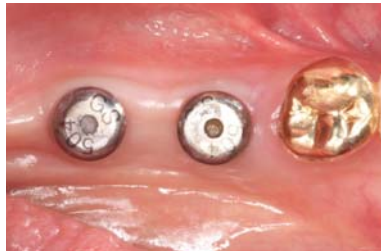

Fig. 2. Setting the healing abutment.

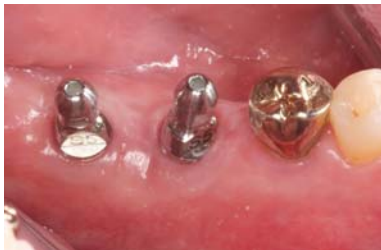

Fig. 3. Taking fixture-level impression.

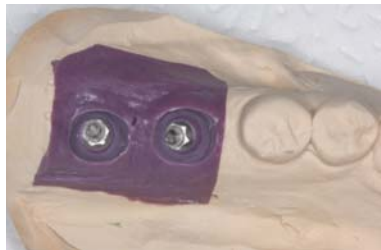

Fig. 4. Checking the working model.




Fig. 5-7. 3D interactive abutment design confirmation.

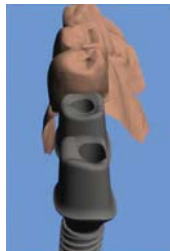


Fig. 8-9. Cast-gold and milling abutment limitations were overcome with CustomFit abutment for Osstem implants to which CAD/CAM technology were applied. They were regarded as a good alternative to aesthetic and functional implant restoration.

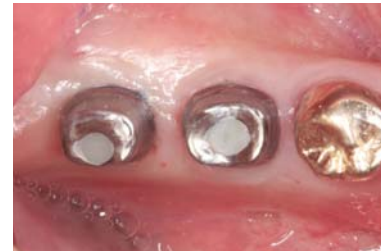

Fig. 10-11. Abutment positioning. The abutment screw is retightened at least twice at 30Ncm with 10 minutes interval. The abutment margin is exposed using the retraction cord if necessary, and then abutment level impression is made.

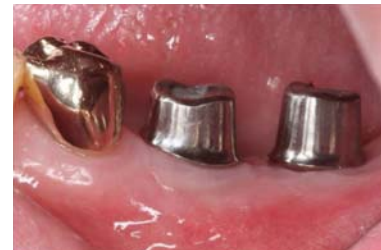

Fig. 12-13. Removing the provisional restoration for final restoration delivery.

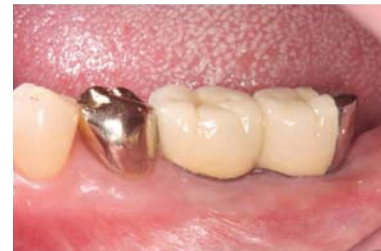
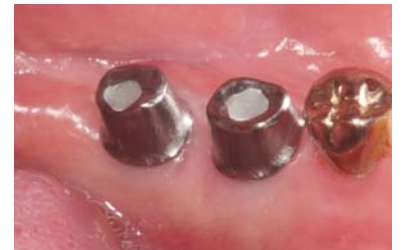
Fig. 14. Cementation with temporary cement.

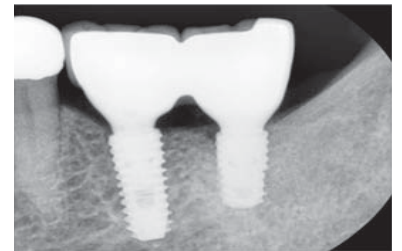

Fig. 15. Periapical radiograph for checking the residual excess cement.

<http://ShyEtak.com>

CAD/CAM Abutment - CustomFit (TSIII SA)



Case

8

Yena Dental Clinic
Director
Yang, Choon-Mo

Implant position: #35, #36, #37

Age: 70, Sex: F

CAD/CAM Guided Flapless Implant Surgery and Immediate Loading Utilizing OsstemGuide

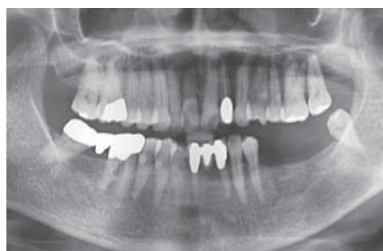


Fig. 1. A 70 year old female patient. 3 month healing after extraction of #35 tooth due to root decay.

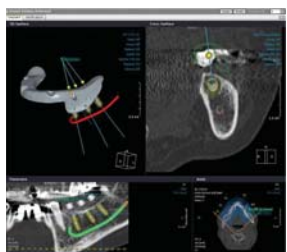

Fig. 3. 3D planning for OsstemGuide.

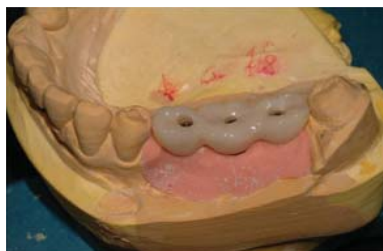

Fig. 5. Prefabrication of provisional restoration before implant surgery.

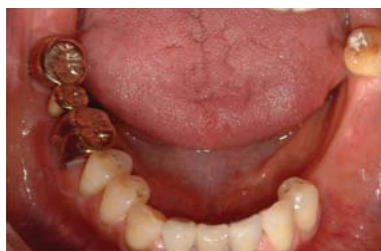

Fig. 2. Minimal attached gingiva was observed and considerable horizontal alveolar bone resorption was estimated in lower left quadrant.

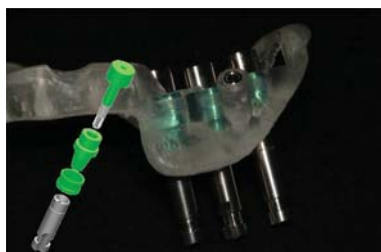

Fig. 4. Implant replica placed into the sleeves of surgical guide for making working cast.

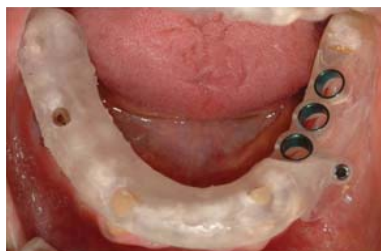

Fig. 6. Anchored surgical guide in the mouth for flapless implant placement.

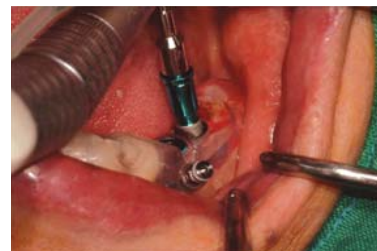

Fig. 7. Implants were placed into the computer-planned sites through sleeves of OsstemGuide.

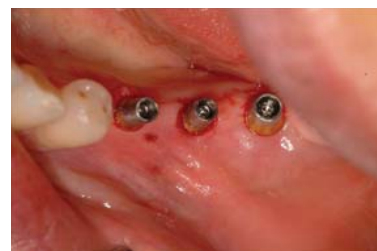

Fig. 9. Temporary abutments attached to the implants. Ready to load immediately.

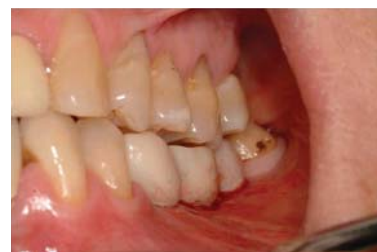

Fig. 11. Minimally invasive surgery and immediate loading by prefabricated provisional prosthesis.

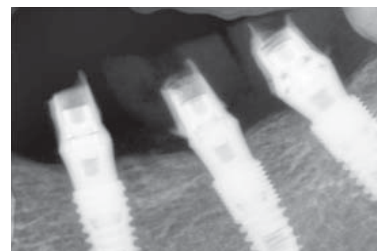


Fig. 13. Immediate provisional resin restoration at the day of surgery.

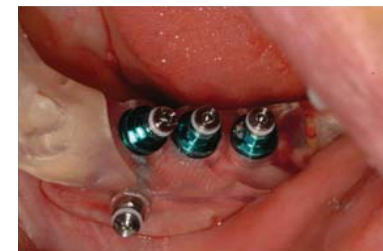

Fig. 8. Implants in ideal position and with optimized angulation.

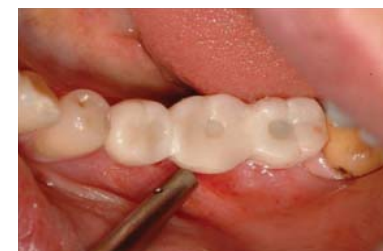

Fig. 10. Immediately loaded screw-retained provisional prosthesis.

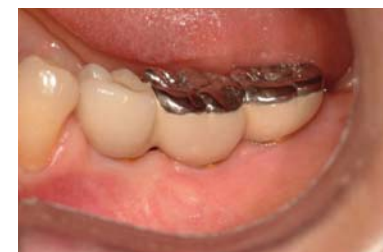

Fig. 12. Definite prosthesis delivered after 5 months of loading by provisional restoration.

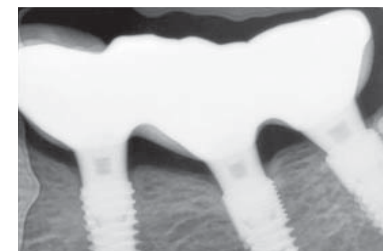


Fig. 14. Definite prosthesis after 1 and half year of loading. Note increased bone remodeling around implant fixtures.

<http://Shvetak.com>

Osstem Guide (TSIII SA)



Case

9

All Dental Clinic
Director
Oh, Young-Hak

Implant position: #16

Age: 62, Sex: M

Wide Diameter Implant Installation with Sinus Graft

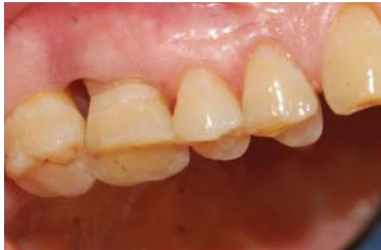

Fig. 1. The patient visited the clinic chiefly complaining of mastication troubles with food packing problem.

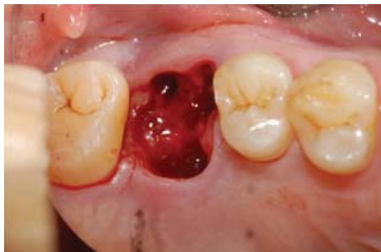

Fig. 3. After the extraction.

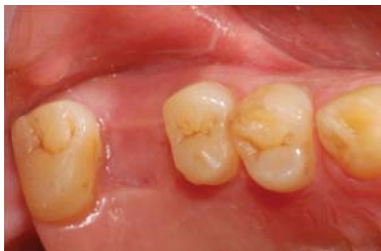

Fig. 5. Photographs of the intra-oral cavity after 3 months of the extraction. Well-matured soft tissues are shown.

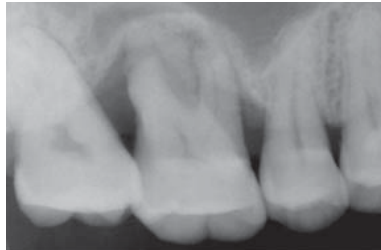


Fig. 2. Pre-operative radiograph of extraction.

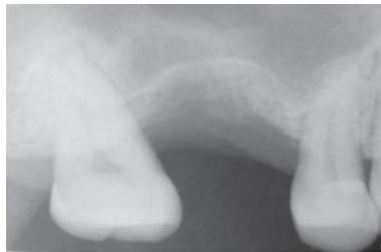


Fig. 4. Periapical radiograph after 3 months of the extraction.

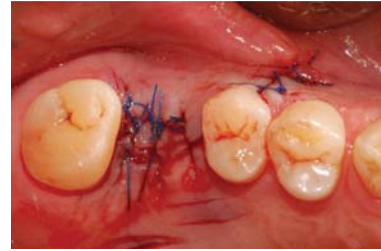


Fig. 6. Wide implant implantation with sinus graft & GBR (MBCP, Tutoplast & CYTOPLAST).

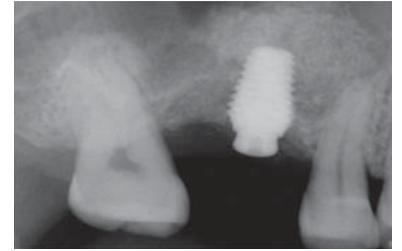


Fig. 7. 2.5 months after implant placement.

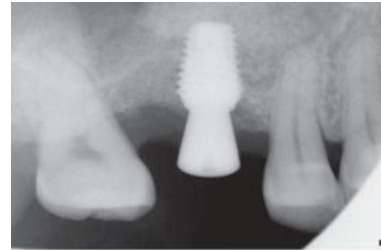


Fig. 8. 4 months after 2nd surgery.

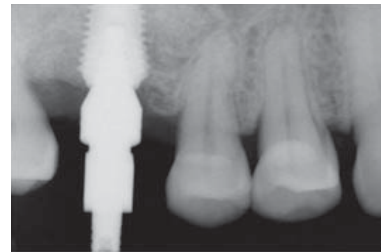


Fig. 9-10. Impression and final prosthesis setting at 6 months after implant placement.

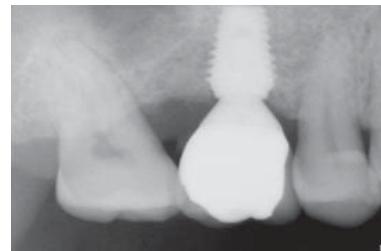
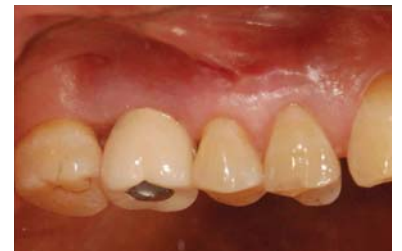

Fig. 11-12. Periapical radiograph at 7 months after implant placement. Well-matured soft tissues are shown.



<http://ShyEtak.com>

TSIII SA UltraWide System



Case

10

Acro Dental Clinic
Director
Oh, Sang-Yoon

Implant position: #47

Age: 28, Sex: F

My Favorite Immediate Implantation Technique Using Osstem Implant TSIV SA

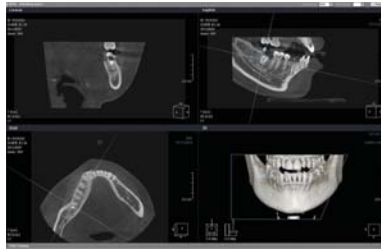

Fig. 1. A preop. X-ray (CT Coronal section View).

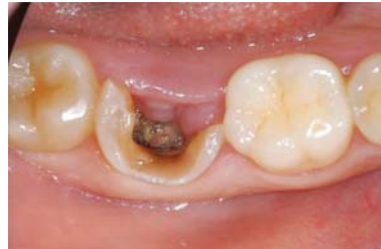

Fig. 2. Preoperative intraoral view (#47).

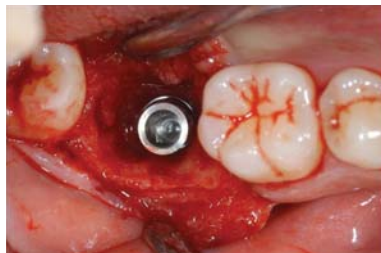

Fig. 3-4. Immediate implantation (TSIV ø 5.0 x 11.5mm).
TSIV SA design advantages are as follows. ① Easy to initial stabilization by abrupt tapered design.
② Excellent self tapping capacity by deep & sharp cutting edge. ③ Minimum trauma to the lingual concavity & inferior alveolar canal by pointed apex design.

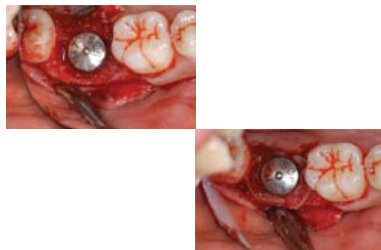


Fig. 5. Bone graft & healing abutment connection.
PRF for Surgical isolation.

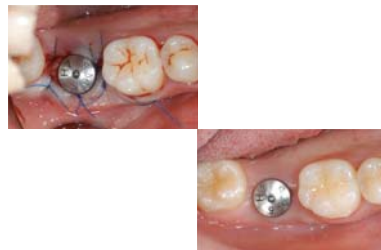

Fig. 6. Circular approximation.
Good healing ; Fast biological secondary stability by TS SA surface.

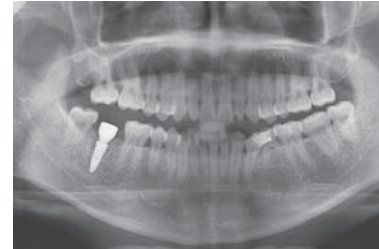

Fig. 7. Postoperative panoramic view.

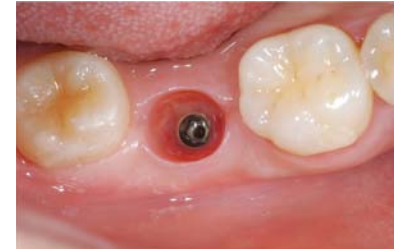

Fig. 8. 4 months later.
Tissue molding by healing abutment.

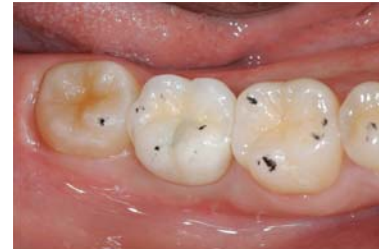

Fig. 9. Final prosthesis.
Harmonious gingival line & profile.

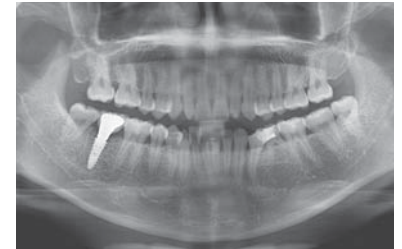


Fig. 10. Panoramic view after final prosthesis.

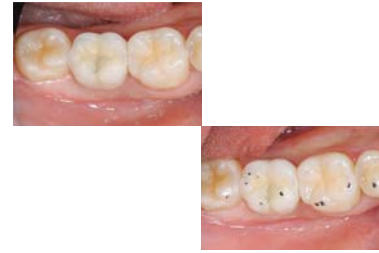

Fig. 11. 6 months later.
Maintain occlusal stability by no sinkdown.

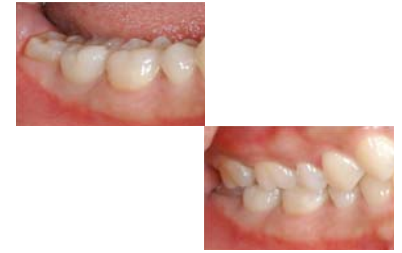

Fig. 12. 6 months later.
Natural gingival line & profile.

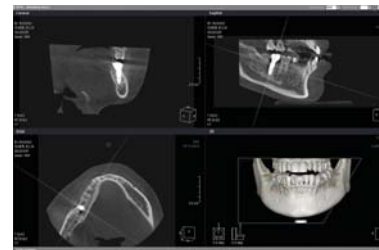
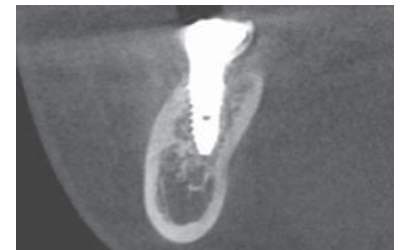

Fig. 13-14. 6 months later follow up CT (Coronal section view).



<http://Shetak.com>

TSIV SA System



Case

11

Apsun Dental Clinic
Director
Cho, Yong-Seok

Implant position: #11, #21

Age: 51, Sex: M

Immediate Implant Placement of TSIV SA Fixtures after Extraction of Both Maxillary Central Incisors

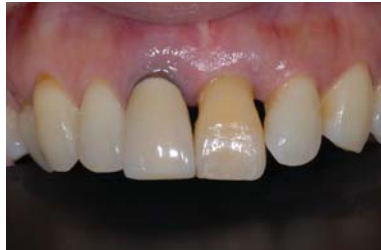

Fig. 1. 51 years old female visited my clinic for the mobility and esthetic problem of both maxillary central incisors.

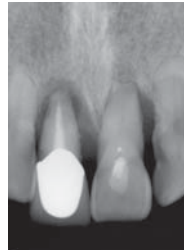

Fig. 2. In Standard X-ray view, both teeth received endodontic treatment before and involved in periodontitis with severe bone destruction. Immediate implantation after extraction of the both teeth was planned.

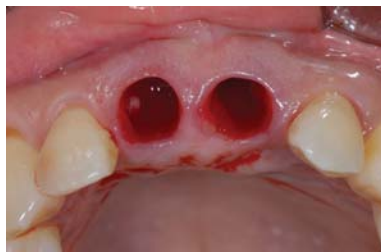

Fig. 3-4. After extraction of the teeth throughout curettage was performed. Loss of the labial bone plate was observed.

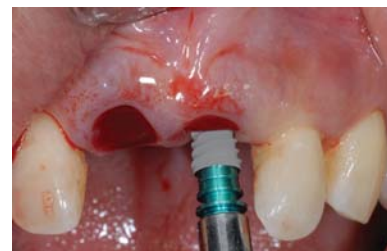
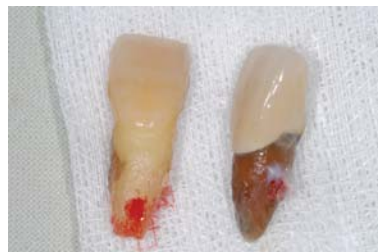
Fig. 5-6. After drilling at palatal side of the extraction sockets TSIV SA \varnothing 4.5x11.5mm were installed. Initial torque was over 40Ncm and ISQ value was 73/74 each.

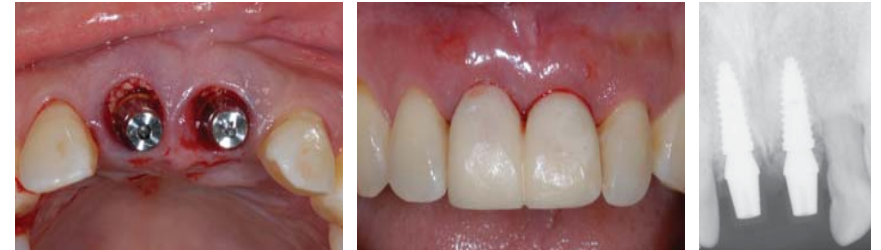
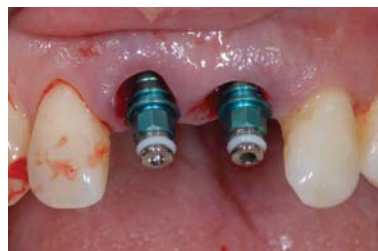
Fig. 7-9. Non functional immediate restoration was tried. Rigid abutments are connected on the fixtures with 30Ncm and allogenic bone graft material (SureOss 0.2cc+0.2cc) was grafts on labial bone defect. Temporary bridge was fabricated and delivered with out of occlusion. POP Standard X-ray shows well positioned TSIV SA fixtures.

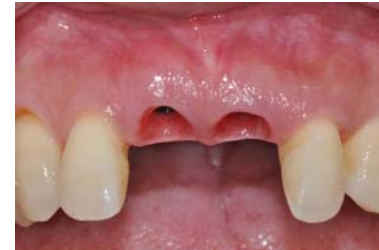

Fig. 10-11. 5 months after temporization patient visited with good gingival health condition. After impression taking cementation type crowns are fabricated over customized abutments.

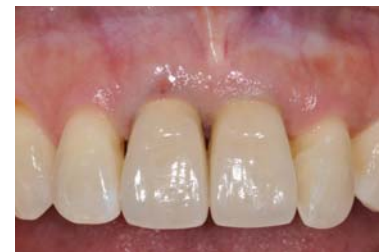
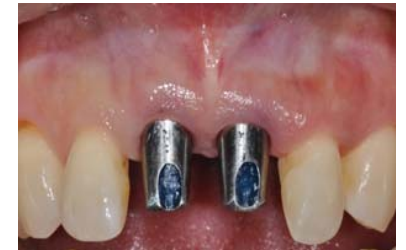
Fig. 12-13. Both crowns are delivered using a temporary cement. They showed harmonized crown and soft tissue.

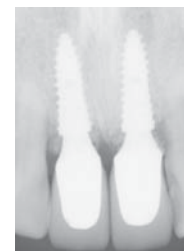
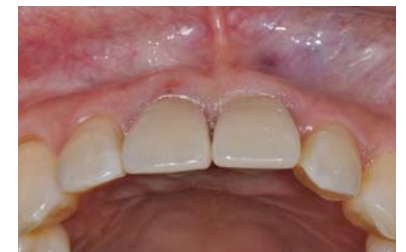

Fig. 14. Final Standard X-ray shows good osseointegration of the fixtures. However coronal bone remodeling is not finished yet.

Osstem
Clinical
Cases



Case

12

Yena Dental Clinic
Director
Yang, Choon-Mo

Implant position: #35, #37

Age: 41, Sex: M

Non Submerged Placement of Osstem TSII SA Implant

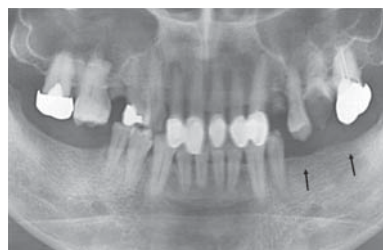

Fig. 1. A 41 year old male patient. Panoramic view prior to implant therapy in the lower left quadrant. Upper left premolar and molar teeth were extruded because of being free from occlusion for a long time.

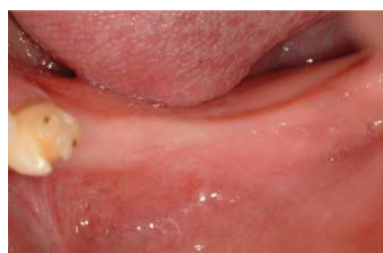

Fig. 3. View of surgical site. Minimal attached gingiva was observed in the molar region.

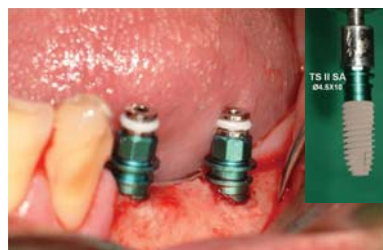


Fig. 5. Implant insertion. Miso-distal and bucco-lingual angulation of each fixture (TSII SA 4.5X10mm) was evaluated.

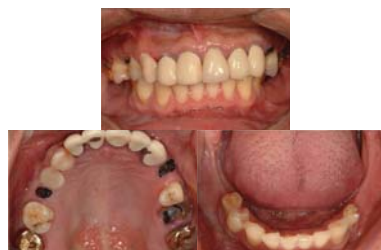

Fig. 2. Oral view of soft and hard tissue before treatment.

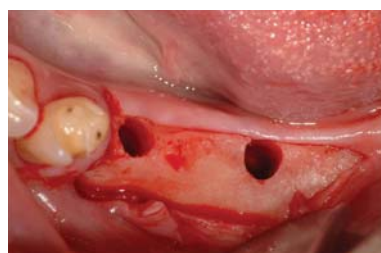


Fig. 4. Finished osteotomy. The bone density was evaluated as normal.

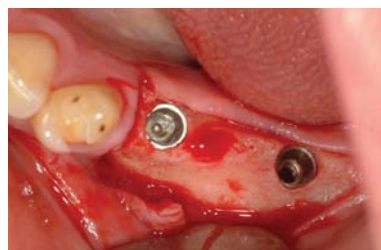

Fig. 6. Platform of each implant was located subcrestally.

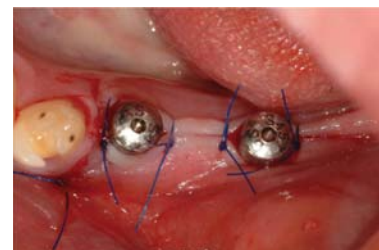


Fig. 7. The insertion-torque was 22Ncm to the site #35 and 18Ncm to the site #37 fixture by machine. The transmucosal healing abutments were connected.




Fig. 9. Intra-oral periapical radiograph after implant placement.

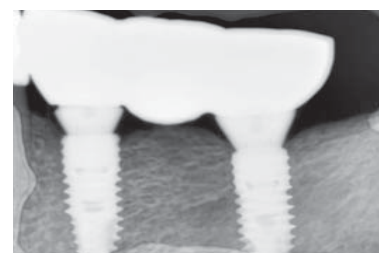


Fig. 11-12. Cement-retained fixed partial denture was delivered at 10 weeks after implantation.




Fig. 13. Follow-up radiograph at 3 months after functional loading.

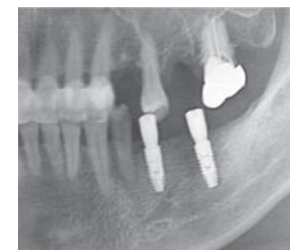


Fig. 8. Panoramic view of post-operative result.

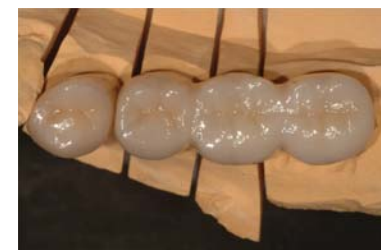
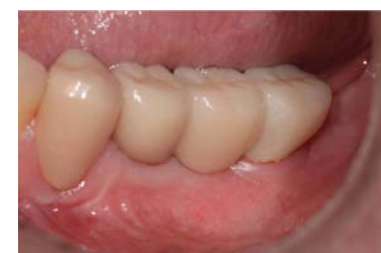
Fig. 10. All-zirconia bridge (Prettau zirconia of zirkonzahn) supported by two implants.



<http://Shetak.com>

Osstem
Clinical
Cases



Case

13

Namsang Dental Clinic

Director
Kim Ki-Seong

Implant position: Multi.

Age: 53, Sex: M

A Clinical Case of Osstem Implant Placement with Maxillary Sinus Augmentation by Lateral Window Technique

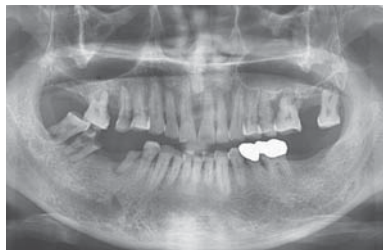

Fig. 1. Multiple teeth with deep caries and severe periodontitis were extracted.

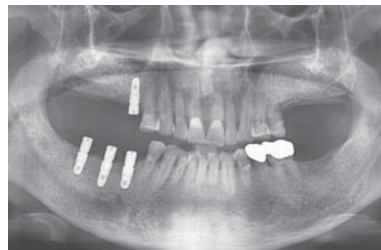

Fig. 2. SSII SA fixtures were placed in #15, #45, #46, #47 missing area. Maxillary Sinus Graft procedure in Rt. & Lt. sides was done with lateral window technique.

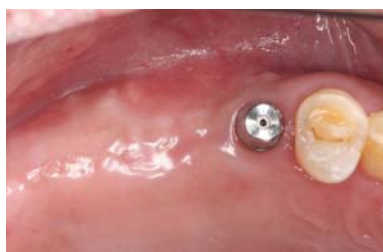

Fig. 3-4. At four months after sinus graft procedure, SSII SA fixtures were planned to be placed in #16 and #17 missing area.

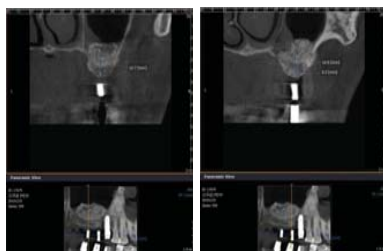
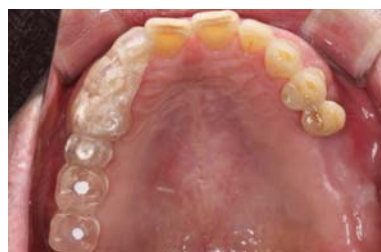

Fig. 5. Sufficient bone volume was acquired in both sides of sinus cavity.

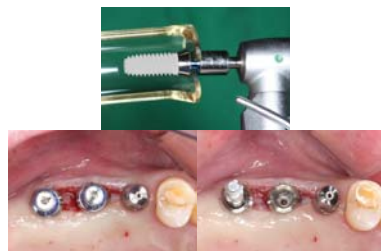


Fig. 6. SSII SA fixtures were placed with minimal flap incision.

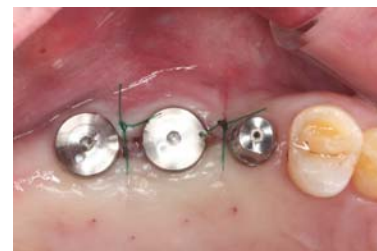

Fig. 7-8. Flap was sutured. Well-positioned SSII SA fixtures were shown in radiographic finding.

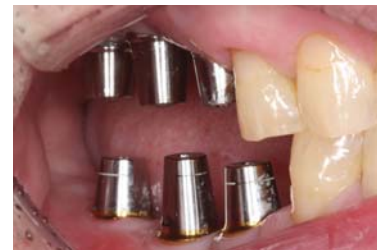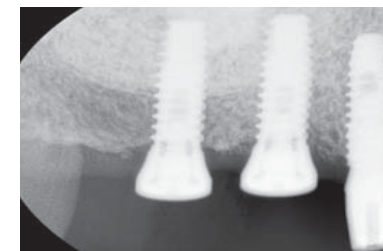


Fig. 9-10. Excellent solid abutments were connected with repeated 30Ncm tightening and an abutment level impression was made by using impression copings.

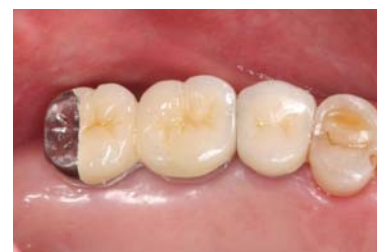
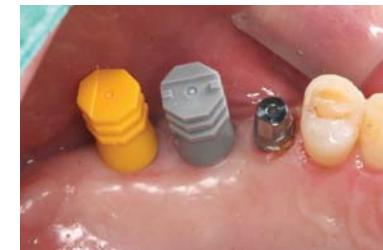
Fig. 11-12. Final treatment outcome at 8 months after the final crown placement.

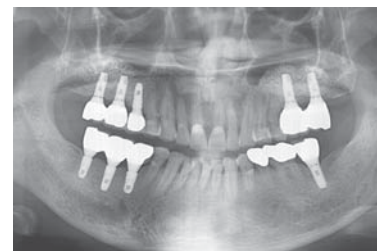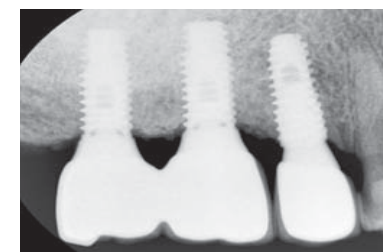


Fig. 13. Panoramic view at 12 months after the final crown placement. Bone level around placed SA fixtures was maintained stably.

<http://Shvetak.com>

SSII SA System



Case

14

Seoul National University
Bundang Hospital
Professor
Kim, Young-Kyun

Implant position: #26, #27

Age: 46, Sex: F

Immediate Loading Using TSIII HA Implants in Maxillary Posterior Area

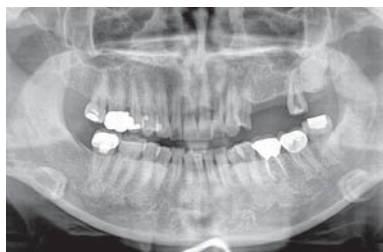

Fig. 1. Initial panoramic radiograph of 46-year old female patient. Left maxillary 2nd premolar and 1st molar were lost.

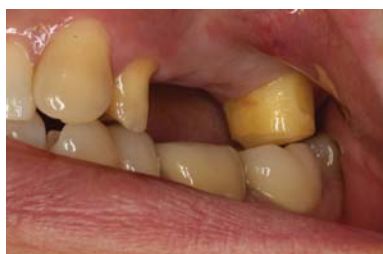

Fig. 3. Preoperative intraoral buccal view.

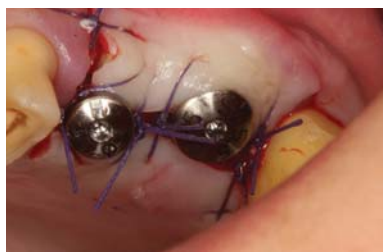

Fig. 5. Postoperative intraoral occlusal view.

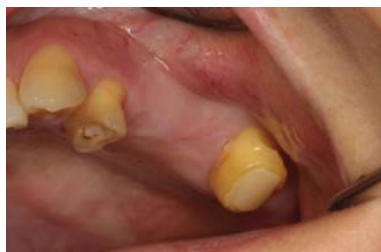

Fig. 2. Preoperative intraoral occlusal view.

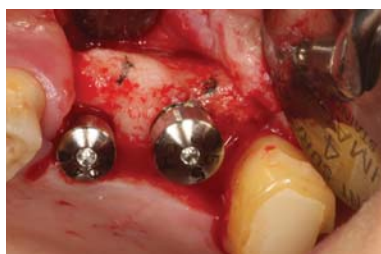

Fig. 4. Two Osstem TSIII HA implants(#25:4.5D/10L, #26:5D/10L) were installed.

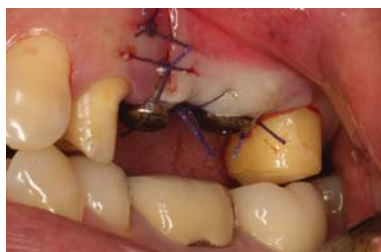

Fig. 6. Postoperative intraoral buccal view.

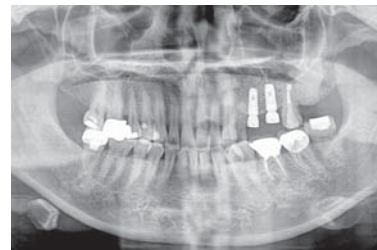


Fig. 7. Postoperative panoramic radiograph.

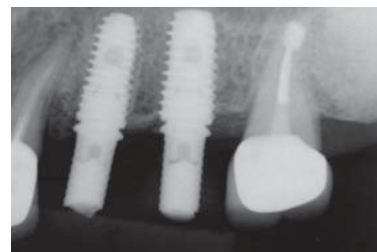


Fig. 9. Periapical radiograph 3 months after immediate loading.

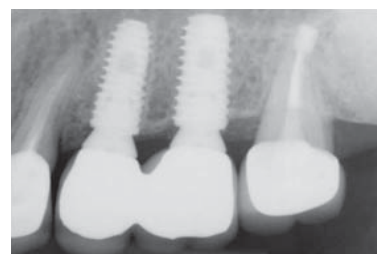


Fig. 11. Periapical radiograph 9 months after immediate loading.

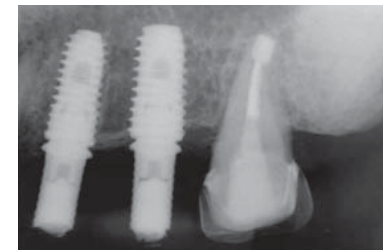


Fig. 8. Periapical radiograph 10 days after implant placement. Immediate loading was performed.

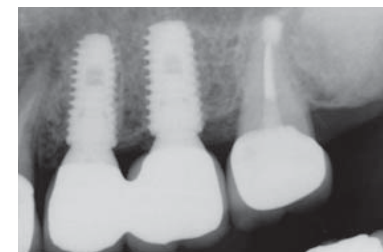

Fig. 10. Periapical radiograph 6 months after immediate loading. Final prosthesis was delivered.

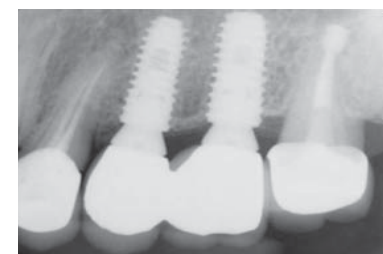


Fig. 12. Periapical radiograph 12 months after immediate loading. Crestal bone level was stable.

<http://Shetak.com>

Osstem
Clinical
Cases



Case

15

Apsun Dental Clinic
Director
Cho, Yong-Seok

Implant position: #26, #27

Age: 64, Sex: F

Sinus Lift Using the CAS kit and Implantation of the TSIII HA Fixtures at Lt Maxillary Molars

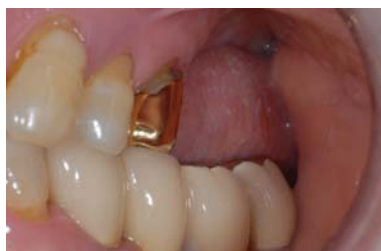

Fig. 1. 64 years old female visited my clinic to receive implants. She extracted #27 3 months ago for the mobility of the tooth after bridge cutting. Excessive occlusal clearance due to vertical bone loss was observed.

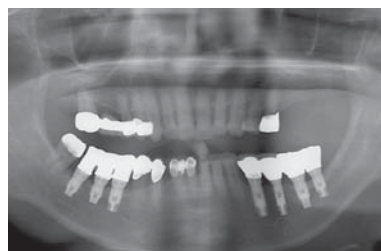


Fig. 2. In Panoramic view, residual alveolar bone heights of #26, 27 are not clear and bone density seems very poor.

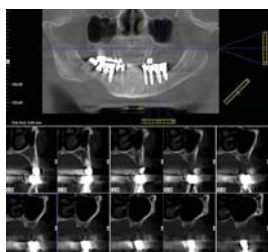


Fig. 3. In Conebeam CT view, it is difficult to measure the remaining bone height because of unclear alveolar bone crest. The sinus shows in healthy condition.

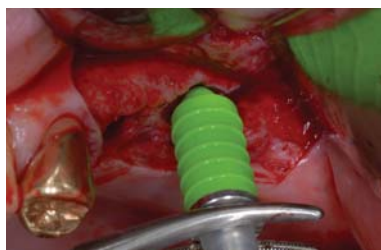

Fig. 5. The remaining bone height of #26 was sufficient and #27 was not. Sinus lift procedure was performed at #27 site using the CAS kit. Hydraulic membrane lifting procedure was done after penetration of the sinus floor.

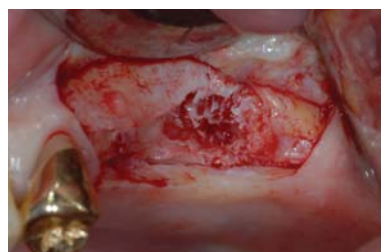

Fig. 4. Bone exposed after elevation of the mucoperiosteal flap. Bone healing of #27 site which involved in periodontitis looks very poor even 3 months after extraction.

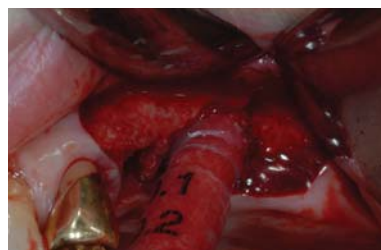

Fig. 6. Allogenic bone substitute (SureOss 0.5cc) was grafted.

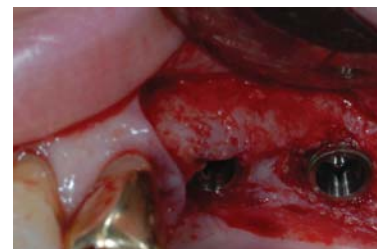

Fig. 7. After bone graft TSIII HA 4.5x10.0mm fixtures were installed. Because of poor bone quality insertion torques were under 10Ncm, and ISO value was measured as 56/58 and 48/55 each.

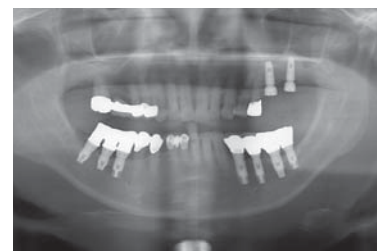

Fig. 9. POP Panoramic view shows well positioned #26i, 27i. Well defined dome shaped bone grafting is seen at the apex of #27i.

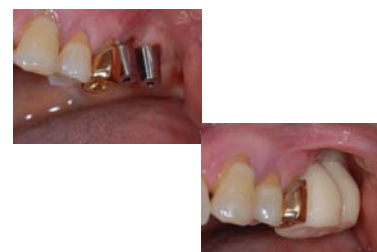

Fig. 11-12. The rigid abutments are connected 6 months after operation and the temporary bridge was delivered.

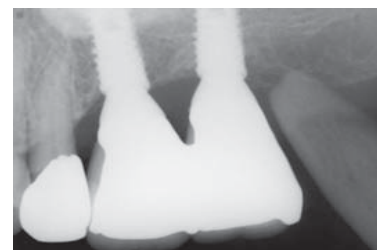


Fig. 14. Standard X-ray view after cementation of the final bridge.

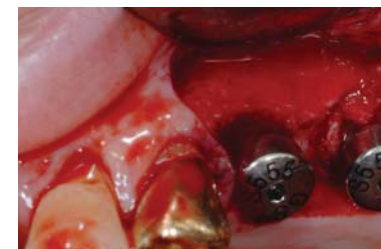

Fig. 8. After minor autogenic bone graft around #27i bone defect 1-stage surgery was done by connecting healing abutments.

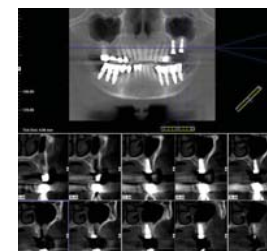


Fig. 10. POP CT shows successful sinus bone grafting of #27i using the CAS kit without membrane perforation.

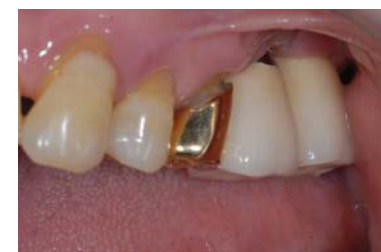

Fig. 13. Final restoration was delivered 7 months after operation.

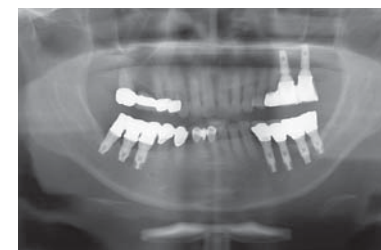

Fig. 15. The Panoramic view shows sinus floor remodeling of the #27i.

<http://Shetak.com>

CAS KIT (TS III HA)



Case

16

Seoul Dental Clinic
Director
Lee, Dae-Hee

Implant position: #26

Age: 66, Sex: M

Use of GSIII short implant instead of sinus surgery

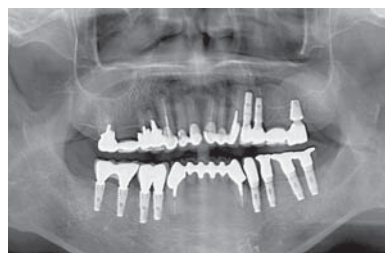

Fig. 1~2. This patient had suffered from cerebral stroke and its complications. His chief complaint was food packing under the pontic side of left upper implant-supported bridge area.

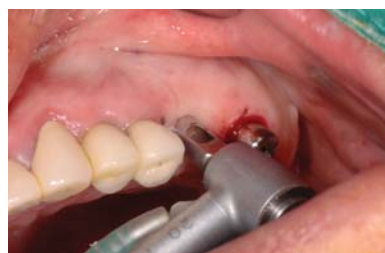

Fig. 3. Flapless surgery was done for the patient's convenience.

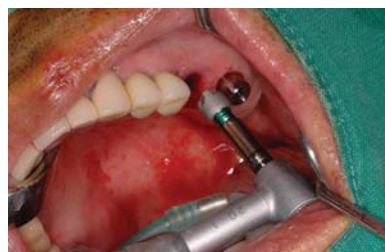

Fig. 5. 6mm short GS III fixture was installed.

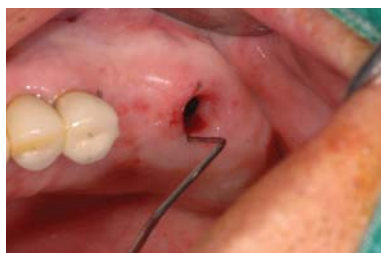

Fig. 4. CAS drill of Osstem was used to shaving the sinus floor for bi-cortical engagement of fixture.

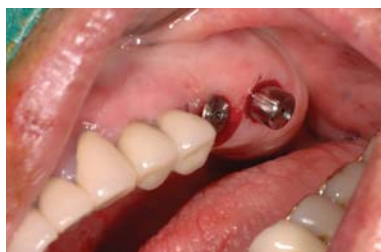

Fig. 6. Healing abutment was fastened and suture was not practiced.

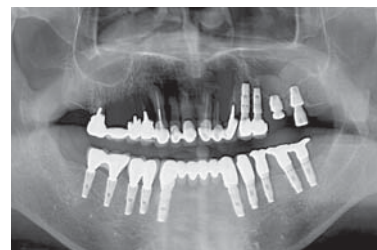

Fig. 7. Fixture was successfully engaged not to touch the thickened sinus membrane.

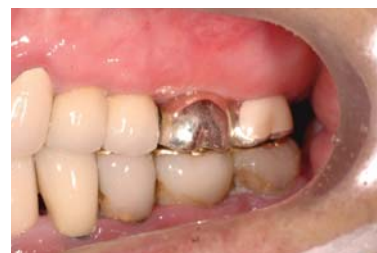

Fig. 9. Gold bridgework was delivered. Plaque control was poor due to the hemiparalysis of right side from stroke.

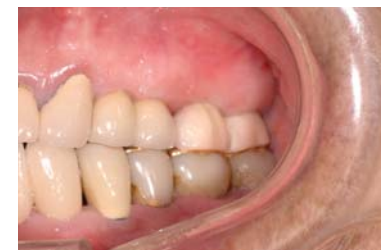

Fig. 8. After the period of provisional restoration.

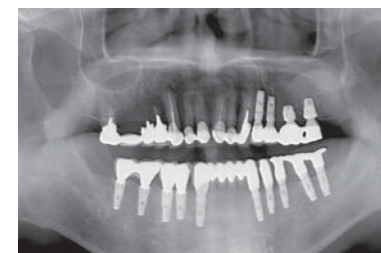

Fig. 10. This picture shows the final appearance after bridgework.

<http://Shetaktak.com>

Osstem
Clinical
Cases

Case

17

Seoul National University
Bundang Hospital
Professor
Kim, Young-Kyun

Implant position: #32, #42

Age: 72, Sex: M

Overdenture Treatment Using Two MS Port Implants in the Severely Atrophic Mandible

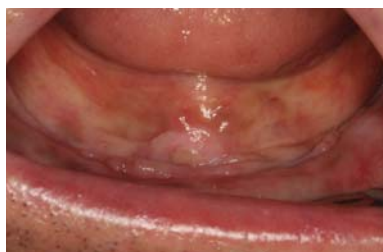

Fig. 1. Preoperative intraoral view of 72-year old male patient. Ulcerative lesion is observed in the mouth floor.



Fig. 3. MS port implant fixture (2.5mm in diameter, 8.5mm in length).

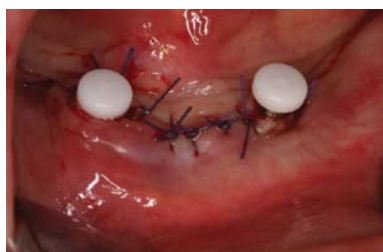

Fig. 5. Cap was mounted and wound was closed.

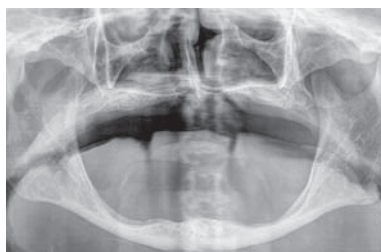

Fig. 2. Preoperative panoramic radiograph. Severe mandibular bony atrophy is shown and mental foramen is close to the alveolar crest.

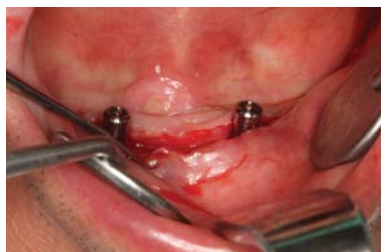

Fig. 4. Two MS port implants were installed using minimal invasive surgical approach.

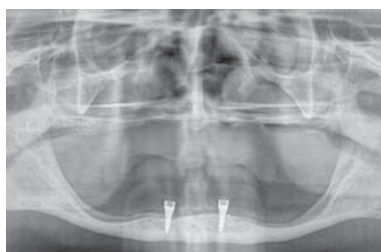


Fig. 6. Panoramic view of post-operative result.

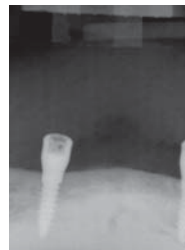

Fig. 7. Periapical radiograph 2 weeks after implant placement (#42 area).

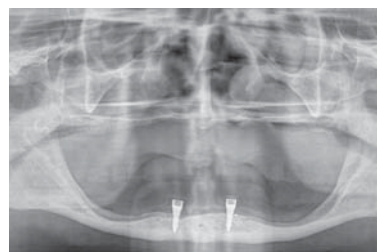


Fig. 9. Panoramic radiograph 2 months after implant placement.

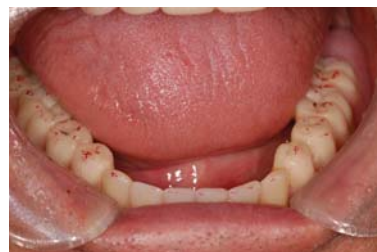

Fig. 11. Overdenture was placed.

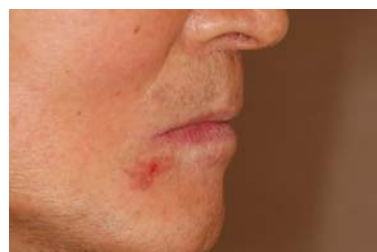

Fig. 13. Lateral facial photograph after overdenture placement.



Fig. 8. Periapical radiograph 2 weeks after implant placement (#32 area).

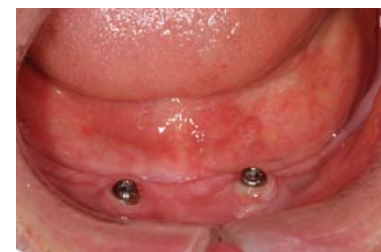

Fig. 10. Intraoral photograph 2 months after overdenture delivery.

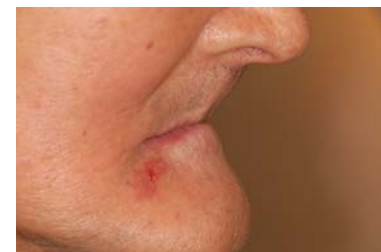

Fig. 12. Lateral facial photograph before overdenture placement.



<http://Shetaktak.com>

Osstem
Clinical
Cases



Osstem Clinical Cases

<http://Shetarak.com>