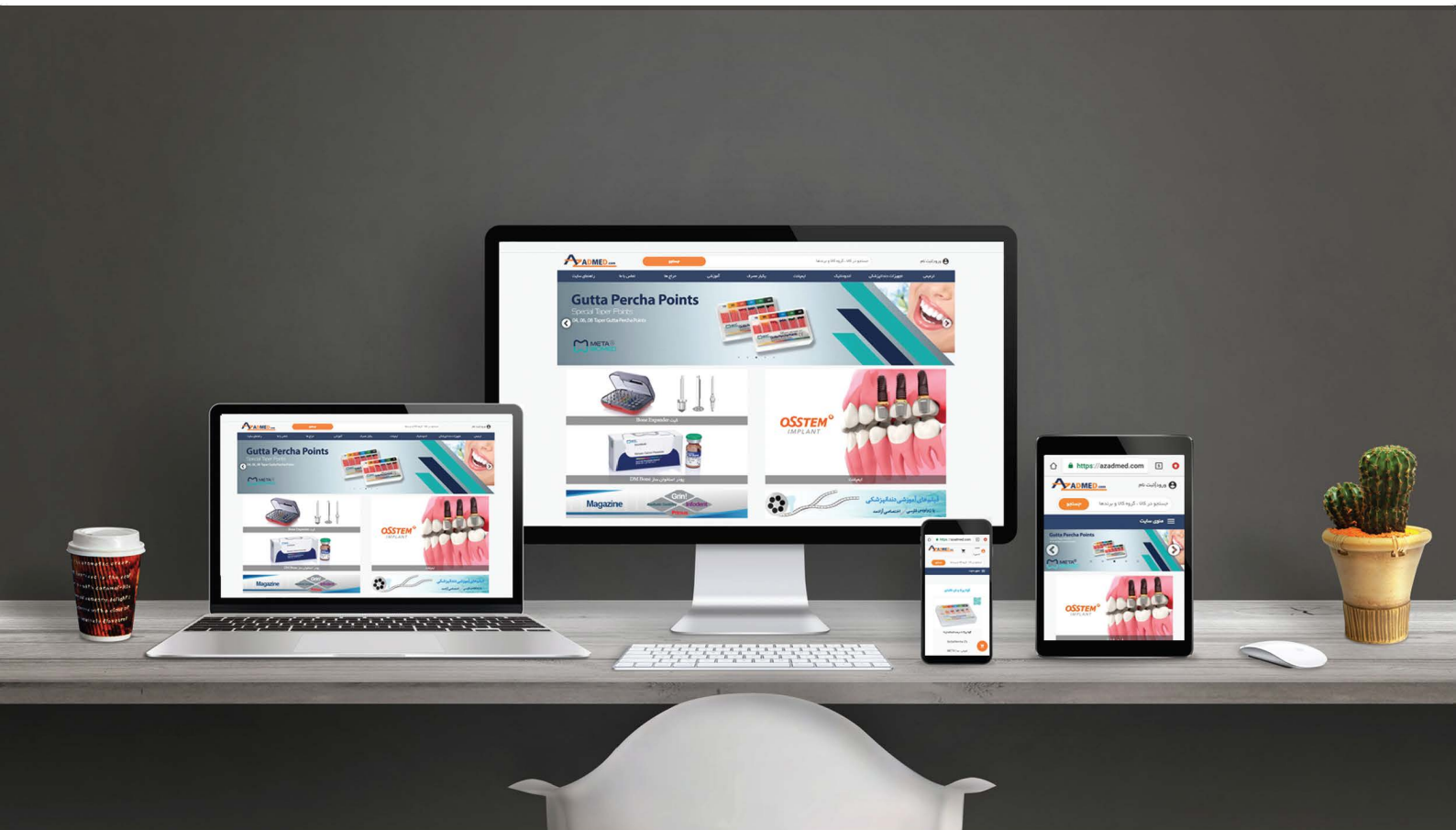




آزاد تجارت پارس  
AZAD TEJARAT PARS.LTD


**AZADMED.com**



[www.azadmed.com](http://www.azadmed.com)



 azaadtejaratpars

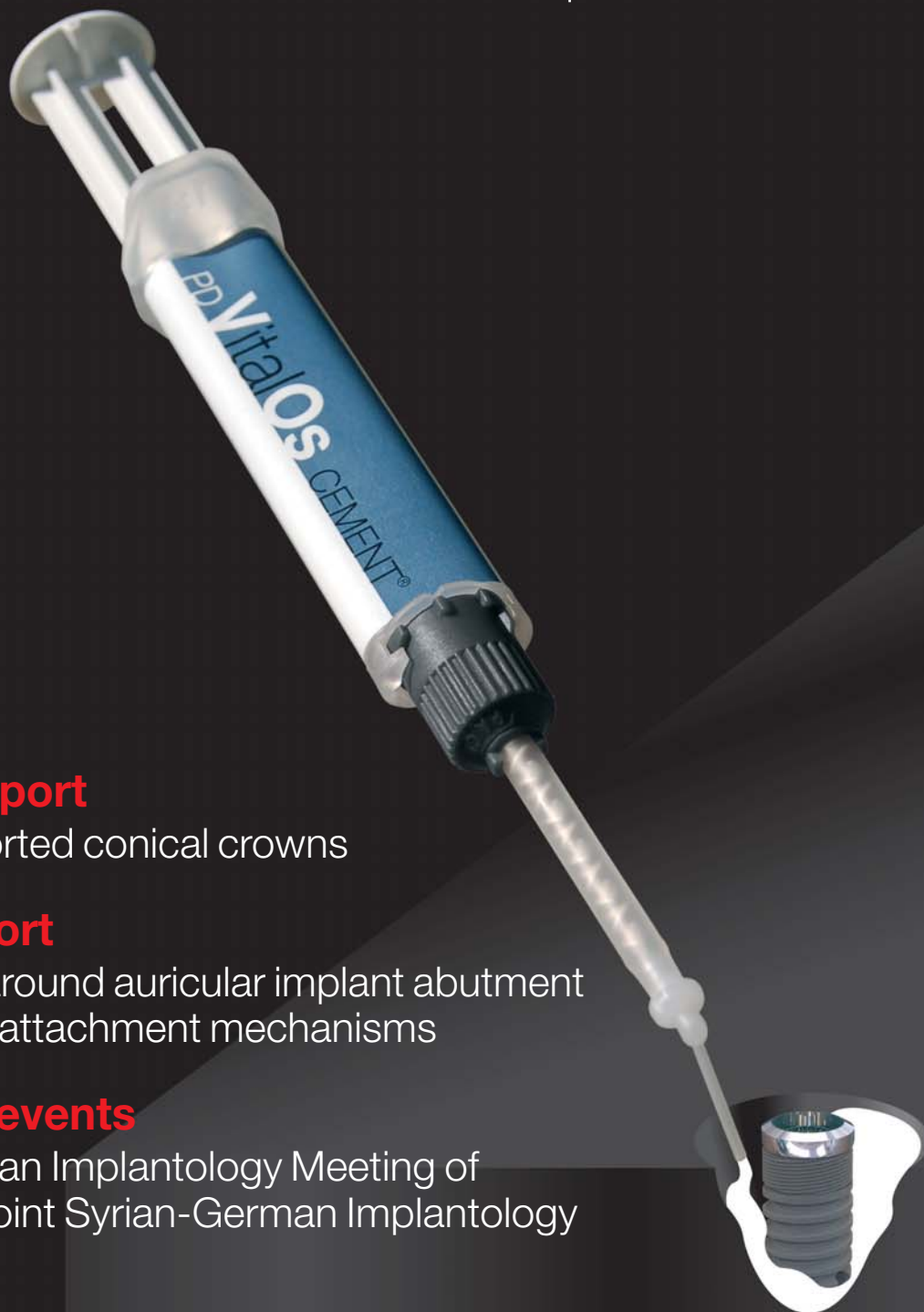 @azadmed2

 88 98 80 63 - 6

# implants

international magazine of oral implantology

1 2009



## **\_implants report**

Implant-supported conical crowns

## **\_clinical report**

Skin reaction around auricular implant abutment using different attachment mechanisms

## **\_worldwide events**

5<sup>th</sup> Arab-German Implantology Meeting of DGZI and 1<sup>st</sup> Joint Syrian-German Implantology Meeting

**ADMED**  
com



**CAMLOG  
AT THE IDS:  
HALL 11.3,  
BOOTH  
NO. A10-B19**

**NEW IMPLANTS, NEW ABUTMENTS**  
**LIBERTY OF CHOICE**  
**NATURALLY FROM CAMLOG**

Reliable implants, patented Tube-in-Tube™ connection, and from now on as an option: platform switching. Camlog offers more. More information: [www.camlog.com](http://www.camlog.com)

a perfect fit®

**camlog**



Dr Rainer Valentin  
Board member  
German Association for  
Dental Implantology (DGZI)

## The aging patient – the “young elderly”

Dear colleagues,

the average life expectancy of newborn boys is 76,89 years, and for newborn girls even 82,25 years. Aside from the fact that nature does not seem to treat men and women quite equally, the dentist can clearly derive the following: Dental medicine and dental implantology especially for senior citizens will become more important in the future. Nowadays older people are much more active than one could have imagined thirty or fifty years ago. The desire to look young and the youthful attitude towards life is growing increasingly in the so called “young elderly”, which naturally means a great challenge for us implantologists. It is self-evident that this is particularly the case in implantology. The German Association of Dental Implantology (DGZI) has already reacted and has included a special course for “Gerostomatology/Implantology for older patients and prosthodontics” in its curriculum. In cooperation with Bonn University we have developed a module for you, which provides the participants with profound knowledge about the demographical development and the current state-of-the-art of science concerning gerostomatology in Germany. Thus, you gain an opportunity to be well prepared for these patients.

The participants of this seminar will be informed in detail about the following:

- Anatomical and physiological changes in patients.
- How should a dental office look in general, in order to suit the requirements of older patients?
- What has to be considered in view of the intake of medication or dental anaesthesia?
- How can the implantologist proceed best regarding indication, planning of the treatment and prosthetic therapy?
- You can gather more detailed information about our current curriculum at one of the most important international dental fairs, the IDS in Cologne, where as a matter of course DGZI is represented.

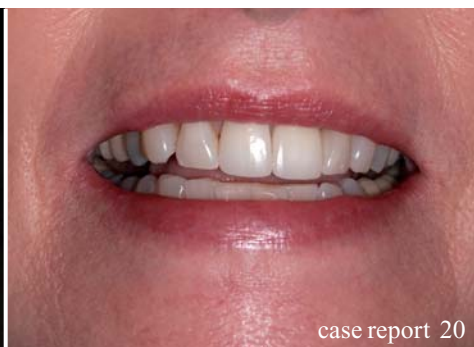I am looking forward to welcoming you there personally.

Best regards

Dr Rainer Valentin  
Board member  
German Association of Dental Implantology (DGZI)



implants report 6



case report 20



social news 41

| editorial

- 03 The aging patient – the “**young elderly**”  
\_ Rainer Valentin

| report

- \_ implants report
- 06 **Implant-supported conical crowns**  
**Historical development and review of innovative systems**  
\_ Rolf Vollmer, Martina Vollmer, Mazen Tamimi, Rainer Valentin, Germany
- \_ case report
- 12 **3-D Planning, Navigation, and additional Questions concerning practical Dentistry**  
\_ Friedhelm Heinemann, Torsten Mundt, Manuel Pfeifer, Werner Götz, Christoph Bourauel, Reiner Biffar, Germany
- \_ case report
- 20 **Extraction and Immediate Implant Placement Using a Combined Hard and Soft Tissue Augmentation and Provisionalization Technique**  
\_ Suheil M. Boutros, USA
- \_ user report
- 24 **Use of Bone Regeneration Cement for Bone Grafting in Atrophic Areas—Clinical, Radiographic and Histological Analysis**  
\_ Sérgio Alexandre Gehrke, Bruno König Júnior, Nara Maria Beck Martins, Brazil
- \_ clinical report
- 32 **Skin reaction around auricular implant abutment using different attachment mechanisms**  
\_ Walid Sadig, Ziad Salameh, Saudi Arabia

| events

- \_ worldwide events
- 36 **First International Dental Symposium** Cairo, 15–17 January 2009  
\_ Rolf Vollmer, Germany
- \_ worldwide events
- 40 **5<sup>th</sup> Arab-German Implantology Meeting of DGZI and 1<sup>st</sup> Joint Syrian-German Implantology Meeting**
- \_ implant events
- 41 **Selected Events 2008/2009**

| news

- \_ social news
- 42 **DGZI Vice President Dr Hille** newly elected speaker of the Consensus Conference
- \_ social news
- 42 **Unanimous approval of the Managing Board and the future DGZI strategy at DGZI General Meeting!**
- \_ social news
- 43 **Congratulations and Happy Birthday** to all DGZI-members around the world
- \_ manufacturer news
- 44 **Manufacturer News**

| about publisher

- 50 Imprint

Cover image courtesy by Produits Dentaires


# NobelReplace™

The world's most used implant system.\*

Internal tri-channel connection for accurate and secure prosthetic restorations

TiUnite® surface and Groovy™ to enhance osseointegration

Implant design that replicates the shape of natural tooth roots



Color-coded system for accurate and fast component identification and ease of use

Color-coding: step-by-step drilling protocol for predictable surgical procedures

**VISIT US AT IDS®**

Date: Mar 24 – 28, 2009  
Place: Cologne, Germany  
Convention Center  
Booth: Hall 4.1 #A90/A91  
More Details at  
[www.ids-cologne.de](http://www.ids-cologne.de)

\* Source: Millennium Research Group

Versatility, ease-of-use and predictability have made NobelReplace™ Tapered the most widely used implant design in the world.\* NobelReplace™ Tapered is a general use, two-piece implant system that performs both in soft and hard bone, one- and two-stage surgical procedures, while consistently delivering optimal initial stability. NobelReplace™ Tapered is a system

that grows to meet the surgical and restorative needs of clinicians and their patients – from single-tooth restorations to more advanced multi-unit solutions. Whether clinicians are just starting or are experienced implant users, they will benefit from a system that is unique in flexibility and breadth of application.

Nobel Biocare is the world leader in innovative evidence-based dental solutions.


For more information, visit our website.

[www.nobelbiocare.com/nobelreplace](http://www.nobelbiocare.com/nobelreplace)

# Implant-supported conical crowns

Historical development and review of innovative systems

author\_ Rolf Vollmer, Martina Vollmer, Mazen Tamimi, Rainer Valentin, Germany



Using conical crowns on antirotational implant connections historically required the expensive fabrication of customized primary and secondary crowns. The Kobold system is a double-crown system using prefabricated components. It is suitable for immediate restoration using a splinted superstructure as well as for simple conical crown restorations on two or more implants or for extending existing restorations on natural abutments.

Dentures supported by implants that are splinted with a bar were described by P. D. Ledermann as early as in 1979. This concept was adopted by many dentists and remains a viable and proven option up today. Long-term studies have confirmed the efficacy and function of this splinting/connecting technique both for immediate and for delayed restoration cases. Conical crowns have come a long way since their beginnings in the 1970s. Used as prefabricated implant-supported components, they still offer many benefits. From a

hygienic point of view, however, these designs present with obvious deficiencies. So-called microgaps can be a significant problem with individually cast frameworks, some of which require a tertiary structure to eliminate divergences (Fig. 1).

## Telescopic or conical crowns as connective elements

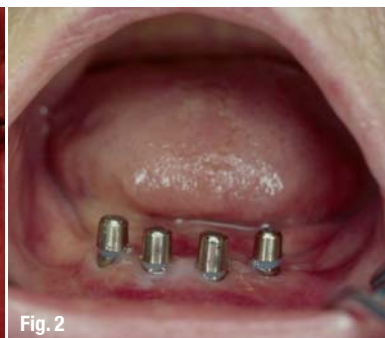Telescope or conical crowns as connection elements for natural abutments have been recognized

**Fig. 1** Bar construction in a immediate postoperative view. Clearly discernible marginal gap.

**Fig. 2** Customized conical crowns on IMZ implants, 1984.

**Fig. 3** Control radiograph of the IMZ conical crowns.

**Fig. 4** Negatively tapered coping for milling a custom primary crown.

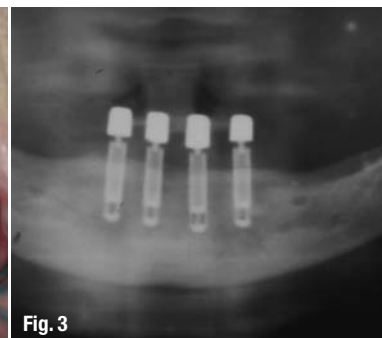
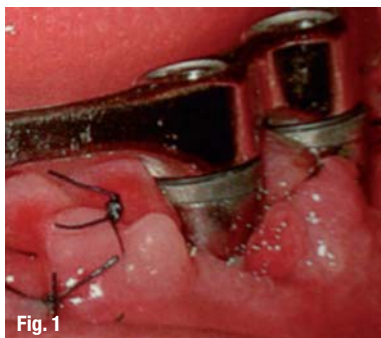
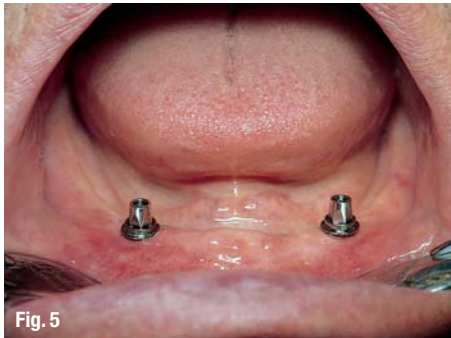



Fig. 5

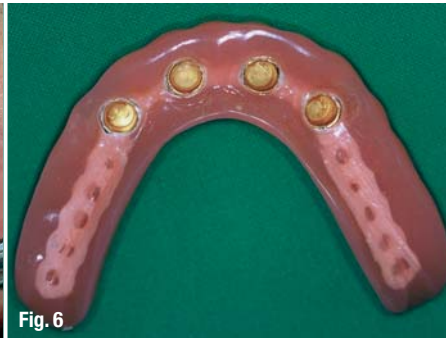

Fig. 6

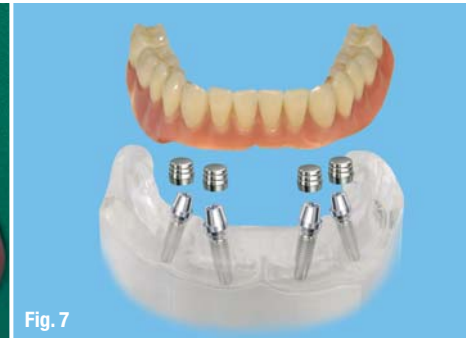

Fig. 7

and very successful for several decades now. They also offer excellent hygiene. In 1968, Dr Karlheinz Körber filed a patent application for the fabrication of conical crowns and their use. The patent application for the parallelometer used for this procedure today was submitted by Körber—now a university professor—in 1971. Conical crowns have become increasingly popular in oral implantology. Individually milled crowns were first used by Dr Nikola Laux (Hamburg, Germany) in 1984, on the IMZ implant system (Figs. 2 and 3); a patent application followed in 1988. Laux was one of the pioneers of the double-crown technique on implants. The first conical crowns were casted and milled individually. However, any proven contemporary technology should strive to develop automated fabrication methods. A first step in this direction were prefabricated negatively tapered copings, including copings made from titanium alloys, that were subsequently milled (Fig. 4), so that the primary copings no longer had to be casted individually. In 1989, the first manufacturer began to produce completely prefabricated conical crowns according to the Laux system (Fig. 5). But it was not until the 1990s, when various types of internal connectors made implant-abutment connections more reliable, that the first publications on individually milled telescope or conical crowns appeared in print. The use of laboratory fabricated telescope or conical crowns on implants gradually became a standard procedure as an alternative to bar-supported restorations. The electroforming technique and tension-free adhesive connections between abutments (passive fit) in high quality laboratory made restorations have brought great im-

provements (Fig. 6), regardless of whether the restorations are supported by natural teeth or by implants. A passive fit is an indispensable precondition for implant-supported restorations and a guarantee for the long-term success of implants.

### Requirements of telescope or conical crowns

Telescopes require perfect parallelism or a well defined slight conicity of the primary copings. This can only be achieved with custom components or customized prefabricated components. Conical crowns with a cone angle of 4° allow for axial divergence between adjacent implants of up to 8°. But considering the anatomical shape of the jaws, especially the maxilla, it is almost impossible to place anterior implants in a direction that they do not exceed this axial divergence. Simple prefabricated systems that do not compensate axial divergences are unlikely to gain widespread acceptance. The problem of angle compensation has to be solved in the simplest possible manner. Any manipulation in the laboratory constitutes a compromise that defeats the purpose of working with prefabricated components. Laser welding, luting or adjusting of primary copings should be a thing of the past. Angle compensation should be fully automatic, so that errors do not occur in the first place. Once a connective element for removable restorations achieves this goal, it will hardly be possible to improve it. Conical crowns offer secure anchorage and provide mutual stabilization against transverse forces. They allow the fabrication of removable bridges and skeleton

**Fig. 5\_** Prefabricated conical crowns according to Dr. Nikola Laux on Paraplast implants.

**Fig. 6\_** Electroformed crowns, adhesively integrated into a full denture as secondary crowns.

**Fig. 7\_** Smiling Cone system compensating for axial diversions.

**Fig. 8\_** Pressing both parts together creates a ball joint that responds to implant divergences.

**Fig. 9\_** The ball joint in the Kobold secondary crown has a self-cleaning effect.

**Fig. 10\_** Tooth 13 had to be extracted in the mandible. Five implants were inserted and loaded immediately.

**Fig. 11\_** The implants in site.

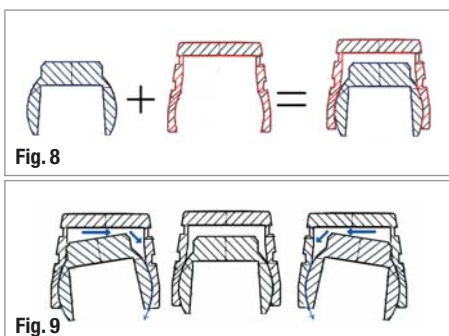


Fig. 8

Fig. 9

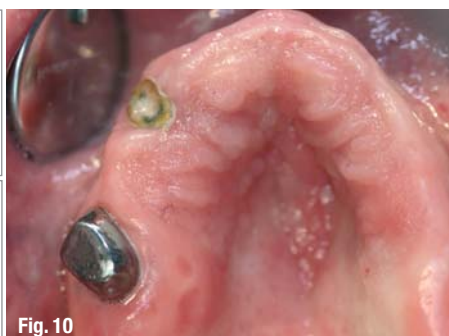

Fig. 10

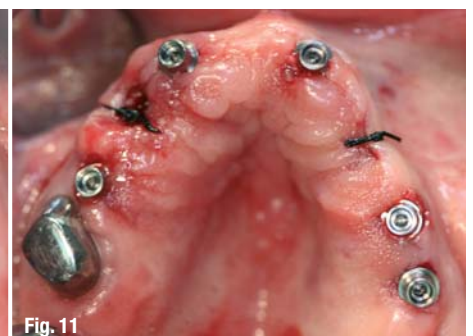

Fig. 11



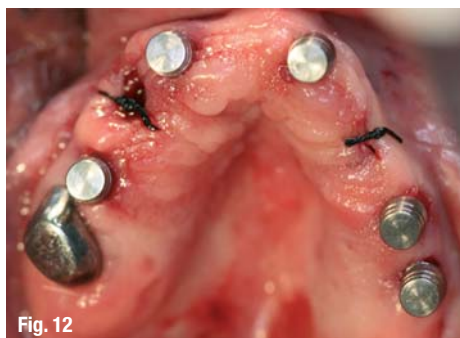

Fig. 12

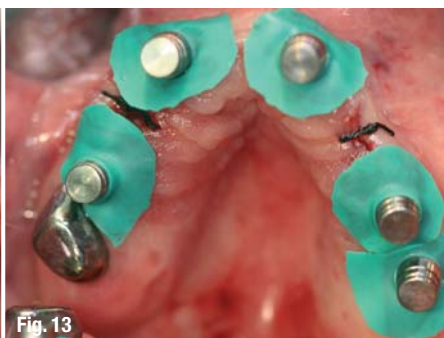


Fig. 13

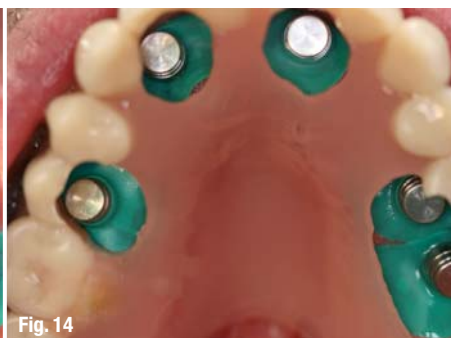

Fig. 14

**Fig. 12\_** The primary crowns for the Kobold conical crowns connected to the implant.

**Fig. 13\_** The secondary crowns are inserted with positive pressure to actuate the friction.

**Fig. 14\_** A piece of rubber dam is pulled over the secondary crowns to prevent resin from flowing into undercuts when integrating the secondary crowns.

dentures that are just as comfortable to wear as fixed prosthetic dentures. Attachments that use rubber rings are subject to greater wear and tear and are unable to distribute transverse forces evenly to the implants. Fabricating maxillary dentures without a palatal bar or removable bridges is a challenge therefore, and the inherent problems cannot be solved by modified ball attachments with rubber rings or by magnetic attachments. While these will keep a denture in its approximate position in the mouth, masticatory forces are transmitted in a relatively uncontrolled manner.

### Prefabricated conical crowns

This Syncone concept for the Ankylos system was original presented in 2001. It was the first prefabricated abutment with a tertiary component that compensated axial divergences. Here, the concept of the wobble cone was applied to a conical axisymmetric implant-abutment connection. However, these conical crowns must be aligned without the help of an antirotational mechanism and require highly precise and time-consuming procedures including the use of suitable paralleling gauges. An imprecise alignment may result in jamming on insertion or removal of the restoration. This may result in eccentric strain, especially in cases of immediate restoration that may contribute to osseointegration failure. For this reason, the Syncone system (Morse taper connection) cannot be used for implants with an antirotational mechanism such as a hex connector. Hex connectors can only be adjusted in 60° increments and do not permit any finer adjustments.

**Fig. 15\_** Completed restoration and a happy patient.

**Fig. 16\_** Secondary crowns in site.

**Fig. 17\_** Grinded denture.

In 2005, Bredent introduced its Smiling Cone, the first conical crown to permit actual divergences of up to 20° which can be used on different implant systems (Fig. 7).

### The Kobold conical crown system

The Kobold conical crown system is a new system presented by Dr. Robert Laux the developer of the Smiling Cone. It, too, permits angle compensation, but follows a different concept. While the Smiling Cone works across two different angle regions, the Kobold system achieves angle compensation by way of a ball joint inside the secondary crown that self-adjusts while inserting or removing the denture (Fig. 8).

The Kobold conical crown provides the desired angle compensation automatically by allowing the secondary crown to function as a ball joint. When a divergence manifests itself on denture insertion, the internal ball moves in the correct position and allows the restoration to be inserted (Fig. 9). Kobold conical crowns can be used with different implant systems, and additional implant systems are in the process of including Kobold crowns in their product range. Kobold conical crowns offer prosthetic options previously available only with the Syncone or the Smiling Cone. Depending on the indication, Kobold conical crowns show resilience when two implants are used. Secondary splinting becomes effective when using more than two implants. The Kobold conical crown makes collaboration with the dental laboratory more efficient. The lab does not have to switch to ball attachments or magnets if the

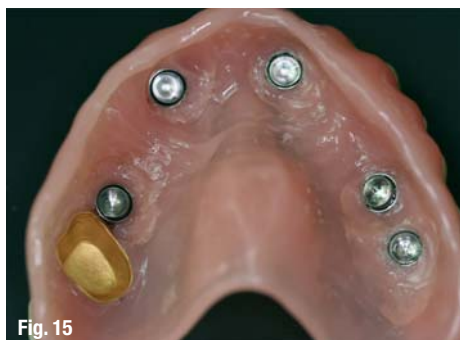

Fig. 15

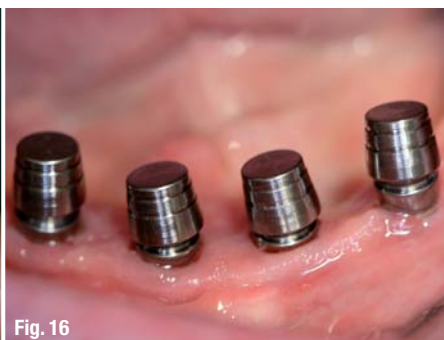

Fig. 16

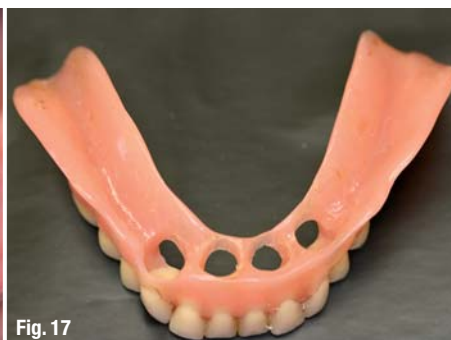

Fig. 17

BEGO is an official  
co-partner of the German  
Olympic teams for  
**Vancouver 2010**  
**London 2012**

GO FOR GOLD.



Bionic Engineering Design transfer of optimal living  
nature solutions to technical products

BEGO Semados®  
Mini-Implant

BEGO Semados®  
S-Implant

BEGO Semados®  
RI-Implant

## BIONIC ENGINEERING DESIGNED IMPLANTS

### Are You Interested?

Call your nearest BEGO Implant  
Systems Distributor  
or BEGO Implant Systems  
in Bremen, Germany

[www.bego-implantology.com](http://www.bego-implantology.com)

BEGO Semados® patented Implants embody:

- Indication-optimised contour design
- Function-optimised and bacterial-tight implant-abutment-connection
- High purity and ultra-homogenous TIPure<sup>Plus</sup>-surface
- Polished rim for an inflammation-free gingiva-attachment
- 100 % German design – 100 % German manufacturing
- Value for money

BEGO Semados® implants = stress reduction in the implants and the  
crestal bone for long-lasting clinical success!

**BEGO**   
Partners in Progress

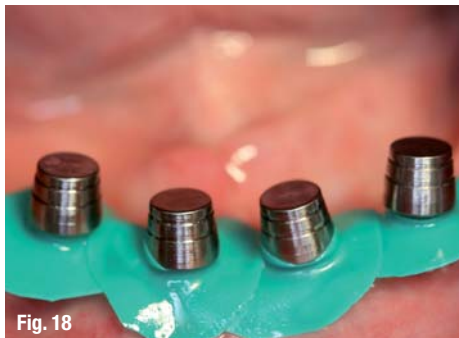

Fig. 18

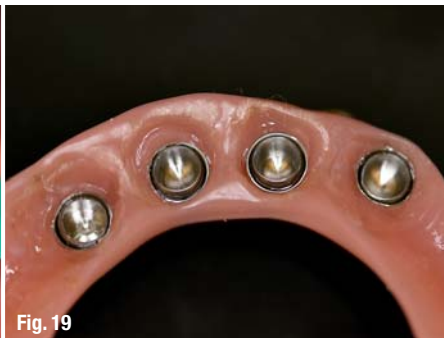

Fig. 19

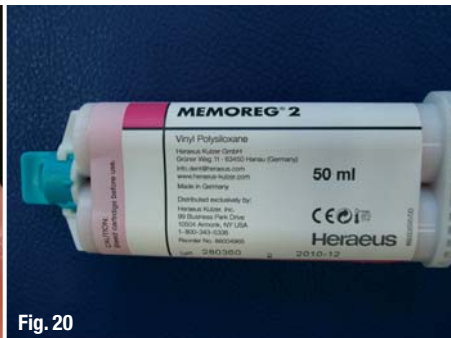

Fig. 20

**Fig. 18\_** Secondary crowns and rubber dam.

**Fig. 19\_** Completed denture.

**Fig. 20\_** Vinyl polysiloxane bite registration material.

dentist wants to use prefabricated parts. The Kobold system is a double-crown system using prefabricated components. It is suitable for immediate restoration using a splinted superstructure as well as for simple conical crown restorations on two implants or for extending existing restorations on dental implants or on natural teeth. For combination dentures, natural teeth can be restored with custom telescope or conical crowns, while implants receive prefabricated crowns. It is particularly easy to integrate one or several implants with conical crowns in an existing restoration already using telescopes or conical crowns.

The advantages of this kind of prefabricated conical crown (Kobold system) are many:

- \_ Defined adhesion of approximate 8 N after a 25 N load.
- \_ The mobile ball joint secondary crown provides angle compensation for divergent implants.
- \_ The prefabricated conical crowns exhibit only minimal wears and offer functional friction for a period of many years.
- \_ Conical crowns can be easily cleaned thanks to secondary splinting.
- \_ The cost of a prefabricated conical crown is considerably lower than that of a custom double crown.
- \_ The abutments are self-cleaning.
- \_ The primary copings are easy to clean.
- \_ The CAD/CAM production process results in very narrow so-called microgaps.
- \_ Only a single metal (titanium) is used.
- \_ Collaboration with the laboratory is easy and efficient.

**Fig. 21\_** Securing the secondary crowns and relining impression.

**Fig. 22\_** Implant analogues in the secondary crowns.

**Fig. 23\_** Cast fabrication.

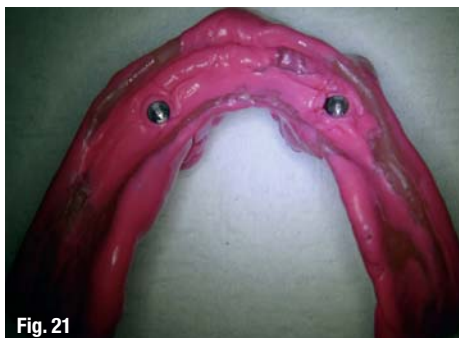

Fig. 21

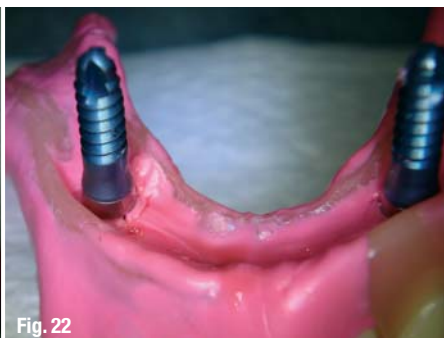

Fig. 22



Fig. 23

### \_Clinical procedure in the maxilla

The procedure is easily applicable to the maxilla. Multiple maxillary implants are nearly impossible to place with exactly parallel axes. However, the Kobold crown easily compensates any divergences. We recommend inserting at least six implants in the maxilla. More implants can of course be provided if the quality of the bone is soft like D3 or D4 bone acc. to the categories of C.E. Misch or if the length of the implants is not sufficient. Reducing the number of implants below six is generally not recommended, as this will compromise long-term stability. Figures 10 to 15 illustrate a patient case in which a 73-year-old patient received five implants that were restored immediately.

### \_Clinical procedure in the mandible

#### Direct procedure

Figures 16 to 19 illustrate a patient case in which a patient received four implants in the mandible, to be restored later. Following a healing period of three months, four Kobold conical crowns were fixed. To polymerize the secondary crowns into the existing complete denture, the copings were finger-pressed onto the primary crowns (Fig. 16).

The complete denture was grinded to eliminate any contact with the secondary crowns in order to obtain a passive fit (Fig. 17), which was double checked with a silicone impression. It is recommended to pull a piece of perforated rubber dam over the secondary crowns (Fig. 18) to prevent resin from flowing into undercuts when gluing the sec-

ondary crowns. Excess resin might prevent the removal of the denture, jeopardizing the entire idea of a removable restoration. The relief areas should be so extensive and generous that no premature contact occurs between the denture of the secondary crowns that might jeopardize the passive fit of the denture and provoke failure especially in cases with immediate loading. The secondary crowns are integrated into the denture and the denture is finished and polished (Fig. 19). That result would take several weeks to achieve at the same quality level with custom components. If, despite all precautions, premature contacts do occur, the secondary crowns can be tilted slightly to one side to permit passive integration anyway. Once the secondary crowns have been attached with self-curing resin as described, the denture is sent to the laboratory for finishing. The patient is already satisfied at this stage because the adhesive connection of the secondary components already creates the typical "fixed-restoration" feeling.

#### Indirect procedure

If the dentist prefers the so-called indirect procedure performed in the dental laboratory, this preference can also be easily accommodated. Following connection of the primary components, the secondary components are placed over them intra-oral, and the existing or new denture is relieved as described above. The denture is lined with a polyether or vinyl polysiloxane material (Fig. 20), and a fixating and relining impression is taken concurrently (Fig. 21).

To fabricate the cast, two primary parts mounted on implant analogues are inserted into the secondary components embedded in the impression (Fig. 22). The dental technician fabricates a master cast and relines and secures the secondary components (Fig. 23).

It is important to preserve the mobility of the joint inside the secondary component by blocking out this area with modelling wax. The indirect procedure deemphasizes the chair side aspect of the procedure while offering the same precision of fit – provided the impressions are accurate. The choice of procedure is entirely up to the dentist.

#### Immediate restoration and loading

In immediate loading cases it is important to ensure that the patients themselves do not remove their restorations during the first few weeks. They are removed only at the dental office at five to seven day interval. At these appointments, patients will rinse with chlorhexidine digluconate. The denture is cleaned and reinserted by the dentist. It is particularly important to follow this procedure in the maxilla to avoid improper loading of the implants during the initial phase. Of course, patients must be in-

structed to avoid biting off bigger bits of food with their front teeth during the first few weeks to guard the implants against excessive chewing loads. When these instructions are followed and the bone supply is adequate for implants of 12 mm or more in length, the experience of several dentists with the procedure is good up to now. Needless to say, it should be used only for selected patients. The dentist must decide whether to incur the increased risk of immediate restoration/immediate loading based on the merits of the individual case. Patients in any case should participate in the decision-making process, and the decision must be documented comprehensively. The safest way is still to allow a certain healing period after implant insertion, which should not present a major obstacle in patients that had been edentulous for many years. The risk of failure after appropriate healing is very low. A skeleton denture without palatal bar can be provided after three months in the mandible or four to five months in the maxilla.

#### \_Summary

Using conical crowns on antirotational implant connections historically required the expensive fabrication of custom primary and secondary crowns. The systems available today have their limitations in terms of handling or implants-superstructure stability. The double-crown-technique has been used for implants for more than twenty years. Yet it is only now that fully prefabricated systems are beginning to make inroads into the implant market. The Kobold system is such a double-crown system that uses prefabricated components. It is suitable both for immediate restoration by a splinted superstructure and for simple conical crown restorations on two implants or for extending existing restorations on natural abutments. In summary, the Kobold system is a reliable, simple and cost-efficient way to provide high quality prosthetic dentures. Kobold conical crowns offer prosthetic options previously available only with the Syncone or the Smiling Cone.

#### \_Contact

implants

##### Dr Rolf Vollmer

57537 Wissen, Germany  
E-mail: info.vollmer@t-online.de

##### Dr Rainer Valentin

Deutzer Freiheit 95–97  
50679 Cologne, Germany  
E-mail: dr.rainer.valentin@netcologne.de

# 3-D Planning, Navigation, and additional Questions concerning practical Dentistry

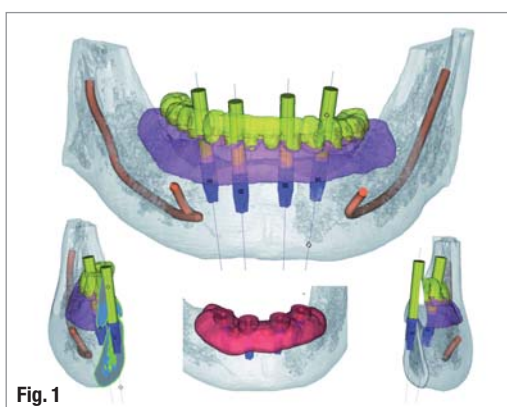
**authors** Friedhelm Heinemann<sup>1+2</sup>, Torsten Mundt<sup>2</sup>, Manuel Pfeifer<sup>3</sup>, Werner Götz<sup>4</sup>, Christoph Bouraue<sup>5</sup>, Reiner Biffar<sup>2</sup>, Germany

It is the aim of this paper to reveal those patient cases where implantological prosthetic treatment with three-dimensional imaging by means of digital volume tomography (DVT) or computer tomography (CT) should be applied in order to analyze and eliminate errors. It is made clear that the increasing population with implants also requires an exact determination of the implant localization and diagnostic imaging of long term integrated implants.

**\_Not only do 3-D illustration** facilities contribute to the increase of indications and thus to a rise in restorations with implants, but a major need for three-dimensional imaging for control and complication management purposes is also given. The fast-paced development of computer techniques, hard and software, storage media, the compatibility of programmable devices with sensors and optics, can also be applied in many fields of dentistry. In the past years, technical, and especially computer-supported methods for dental diagnosis and therapy have been refined significantly. Innovations in digital technologies show promising and

interesting improvements in regard to their application. Anyway, a pragmatic, time-saving and user-oriented application of particular programs is of great importance. This in fact is the real improvement of the current development. The chance of cooperation also offers adequate possibilities to integrate this technique into general dental offices without major investments. At the same time, modern data transfer and multiple means of communication improve time management as well. The indication for the use of DVT or CT has to be checked separately for every single case. This holds true for all medical therapies, and it guarantees a better realization of therapy in view of individual needs. It has to be evaluated if the enhanced complexity and the resulting higher costs will be refunded by official and private health insurance companies. It is of great significance, how three-dimensional planning with appropriate methods and materials can be put into practice. Crucial and pathbreaking improvements can be shown here.

**Fig. 1** Virtual planning with SimPlant®, Materialise Dental GmbH, Oberpfaffenhofen, Germany.



## \_Imaging techniques

In 1917 the Austrian mathematician Johan Radon developed a mathematical method by means of which one could calculate the projection image of an

<sup>1</sup> Praxis für moderne Zahnheilkunde (Dental Office for Modern Dentistry), Im Hainsfeld 29, 51597 Morsbach

<sup>2</sup> Ernst-Moritz-Arndt-Universität Greifswald, Poliklinik für Zahnärztliche Prothetik, Alterszahnheilkunde und medizinische Werkstoffkunde, (Ernst-Moritz-Arndt University of Greifswald, Department of Prosthodontics, Gerodontology and Biomaterials), Rotgerberstr. 8, 17475 Greifswald

<sup>3</sup> Rechtsanwälte Ehle & Schiller (Lawyers Ehle & Schiller), Mehlemer Straße 13, 50968 Cologne

<sup>4</sup> Friedrich-Wilhelms-Universität Bonn, Zentrum für Zahn-, Mund- und Kieferheilkunde, Poliklinik für Kieferorthopädie, Oralbiologische Grundlagenforschung (University of Bonn, Clinic for Dentistry, Dept. of Orthodontics, Oral Biology Research Laboratory), Welschnonnenstr. 17, 53111 Bonn

<sup>5</sup> Friedrich-Wilhelms-Universität Bonn, Stiftungsprofessur für Oralmedizinische Technologie (University of Bonn, Endowed Chair of Oral Technology), Welschnonnenstr. 17, 53111 Bonn

X-ray that had been weakened by materia. This was a purely mathematical gain of insight and far away from any applicability. However, radon transformation is nowadays the basis for the calculation of non-destructive spatial images of an intact object and all its inner structures. From 1975 on, CT technology found its way into medical diagnostics. All body tissues weaken the penetrating X-rays differently. The technician Godfrey Hounsfield defined an attenuation value for objects, the so called Hounsfield unit (HU) was named after him.

The various values are: for air 1,000 HU, adipose tissue from 200 to 50 HU, and water 0 HU. Bone values start with 300 HU to 2,000 HU (teeth), metall around 3,000 HU. By using gray-scale value filters for special HU values, body tissues can be segmented and shown separately from any other tissue structures. CBDVT is the abbreviation for a cone beam digital volume tomograph. This apparatus is a new development for reconstruction purposes, which has only become possible thanks to high performance computer systems and the latest mathematical algorithms. This image taking method works as follows: An X-ray source formed like a "cudgel" or pyramide X-ray with an opposing detector unit circles around the patient. Thus, approximately 300 X-ray images can be taken from different positions. The X-ray tubes can be compared with an orthopantomogram (OPG) or they may even be identically equal. Only the exposure time (due to the necessary high number of projections) and the anode current (in order to achieve a good penetration) are elevated. A difference has to be made between pulsed and non-pulsed radiation methods. A non-pulsed tube continuously emits rays, which on the one hand facilitates the steering of the device, but on the other hand implies a higher X-ray dose for the patient.

The pulsed tube only emits X-rays, when definitely taking an X-ray image. Thereby an unnecessary exposure to X-rays can be avoided, which is favorable for patients in regard to the total exposure to radiation. It has to be noted that in the moment of power-up some X-ray tubes also emit low voltage X-ray radiation (between 20 kV and 50 kV), which has a higher biological damaging effect.

Some DVT manufacturers have already solved this problem. The detector unit transforms the X-ray projection information into an image data file, which will be saved temporarily on a reconstruction computer. There are two kinds of technologies for detector units: 1.) Image amplifiers function with a special electron tube. By means of a scintillator layer X-ray radiation is transformed into visible light, reinforced by the tube, and then digitalized by a camera chip. Image amplifiers are a bit more sensitive to X-rays than surface detectors, their purchase is cheaper for manufacturers, but there are some im-

portant disadvantages that have to be mentioned. Image geometry displays heavy distortions in the bordering area, which have to be mathematically corrected, and which limit the use of the whole detector surface. During the course of time the image quality decreases significantly, which makes repeated recalibration necessary, and finally requires an exchange of the image amplifier. Meanwhile this method has become obsolete. 2.) The impinged X-ray radiation of semi-conductor surface detectors will be digitalized directly without any geometrical distortions. The (still) high purchase price for flat panel detectors (FPD) is to the disfavor of DVT manufacturers. Thanks to this recent DVT technology the mechanical effort and the size of the devices can be kept on a very low level. Besides, it can be adapted to the appearance of the usual panoramic radiography. Furthermore, cone beam methods minimize the development of scattering artifacts (e.g. on crowns), which poses a big problem for normal CT images of the cranial region. For practical issues, it should be mentioned that those DVT devices applied in dentistry have been reduced to an exclusive use for the cranial region. Therefore, dentists are allowed to operate such devices, whereas CTs can only be operated by radiologists. The discussion about advantages and disadvantages of both device groups is factual, though sometimes a bit polemic. It is undisputed that CTs compared to DVTs have a lower sensitivity to movement but are more prone to scattering artifacts. Various DVT devices require different positioning of the patients during image taking, e.g. reclined, seated or standing up.

Since movement artifacts are illustrated much more dramatically on DVT images, imaging is principally better in a reclined position, though due to this position patients may suffer from deglutition reflexes provoked by saliva. Devices designed for image taking of patients in seated or standing up positions are convincing, because of the minimal required space. The discussion about the exposure to radiation of the various devices and techniques has to be judged differentially. The comparability of the present studies is often not given, because of different evaluations of biological effects on human organs. There is no doubt about that DVTs have lower radiation than CTs, though there are great differences among DVT devices. The new CT generation enables a significant reduction of exposure to radiation by applying so called low dose protocols. On the whole, the exposure to radiation is low in all modern devices, but its radiation dose still multiply surpasses that of OPGs. An important criterium in regard to exposure to radiation is the avoidance of repeated image taking. Above all, the necessary image quality and processability depend on the specialized staff, the maintenance of the devices and the competence of the device operator.

## Three-dimensional planning and navigation

Adequate software should provide illustration facilities into the three main scanning directions (axial, coronal, sagittal) so they are readable for the user. Most programs solve this by parallel projection on the monitor of a panorama analog image, a jaw cross section and a transversal section. Normally a three-dimensional image of the jaw can also be visualized. However, this is a rather close to reality animation and not an exact realistic image. By moving the cursor, a change of the cutting level can be obtained in all images, so that anatomical anomalies can be pursued into every cutting direction. In addition to this optimized image the program also includes auxiliary means and tools, which make the work easier and give practical help to users. Apart from simple facilities used for the measurement of length, angle and density there are imaging programs, which show the course of the mandibular nerve canal, and the insertion of planning axes and of implant forms from different manufacturers and their product line. The first planning system on this basis, which implied much of the corresponding pioneering, was developed by SimPlant®-System (nowadays the Belgian company Materialise Dental). It was introduced in Germany in the early nineties, and sponsored by the German Association of Dental Implantology. In the last few years, many innovations have been made to improve this development. A wax-up of the prosthetic planning or a duplication of the existing prosthesis can be transferred to a so-called scan prosthesis composed of X-ray opaque substitution teeth. The virtual positioning of the implants into the jaw bone will be carried out in compliance with the location of the X-ray opaque substitution teeth. Afterwards this virtual planning will be digitally transferred and a drilling guide will be produced. Based directly on the 3-D-data of CT or DVT a drill guide, which can be mucosa-, tooth- or even bone-supported, will be calculated and finally materialized with a laser beam, which solidifies a liquid UV-curable resin.

With this in mind, 30 years ago German implantology pioneers have started working "minimally invasive" and "atraumatically" on single-phase implants. However, they had to rely on palpation, expe-

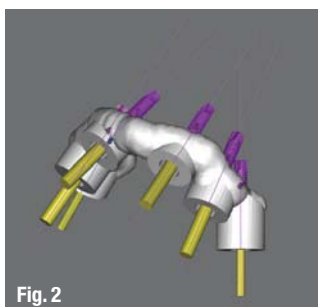
rience and intraoperative control when positioning their implants. From the forensic point of view this way of proceeding is considered to be obsolete. In case of failure the documentation of the way of proceeding will be required, and checked in terms of safety. Hence, a respective three-dimensional image of the jaw situation is necessary for a minimally invasive implantation. On its basis implantology possibilities will be checked, then the planning can be done, and finally the positioning of the implant can be determined. New and precise navigation systems, which are routinely used especially in neurosurgery, where they are of vital importance for the patients, have also found their way into dentistry.

In the last few years navigation techniques have been improved, in order to adapt them to the requirements for application in dentistry. Navigation systems have also become available for dental implantology purposes, due to the development of specialized software and instruments. By means of this direct navigation, previously combined DVT or CT data will be combined and visualized on a monitor, and reference points for the localization of the jaw and the driver tip will be optically recorded. The current drill position will be displayed in color. It can be controlled by the program based planning. On the contrary to the already described way of proceeding in regard to drilling jigs, the system, however, has to be ready to use in the dentist's office during the operation. A comparable exactness cannot be achieved in "free-hand style" without navigation. Schermeier et al. (2002) concluded in their study that skilled surgeons could not achieve aberrations below 2–3 mm, whereas the maximal failure using navigation was detected between 0.6 and 0.8 mm.

## Hazard to anatomical structures

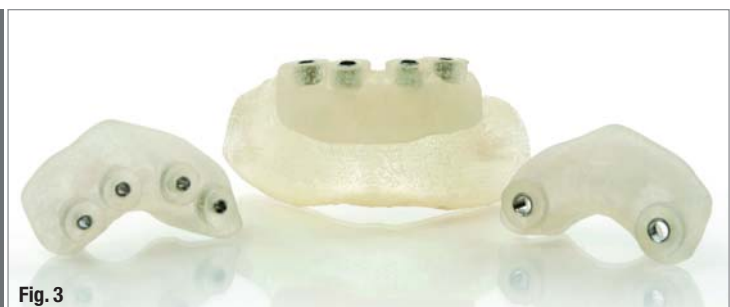Though thanks to "backward planning" in modern implantology, anatomical risks can be avoided by preimplantological augmentative and other surgical methods, anatomical knowledge still plays an important role in regard to successful implantations. Within therapy planning, the three-dimensional image taking with CT and DTV techniques provides an exact and distortion-free image of important anatomical structures, both in bones and soft tissues (Lenglinger et al.

**Fig. 2** Virtual bone-supported SurgiGuide® drill guide, as calculated by the SimPlant®-Software, Materialise Dental GmbH, Oberpfaffenhofen, Germany.



**Fig. 2**

**Fig. 3** Bone-supported SurgiGuide® drill guides with ascending diameters on stereolithographic bone model, Materialise Dental GmbH, Oberpfaffenhofen, Germany.



**Fig. 3**

# WHATEVER **YOUR PATIENTS** NEED

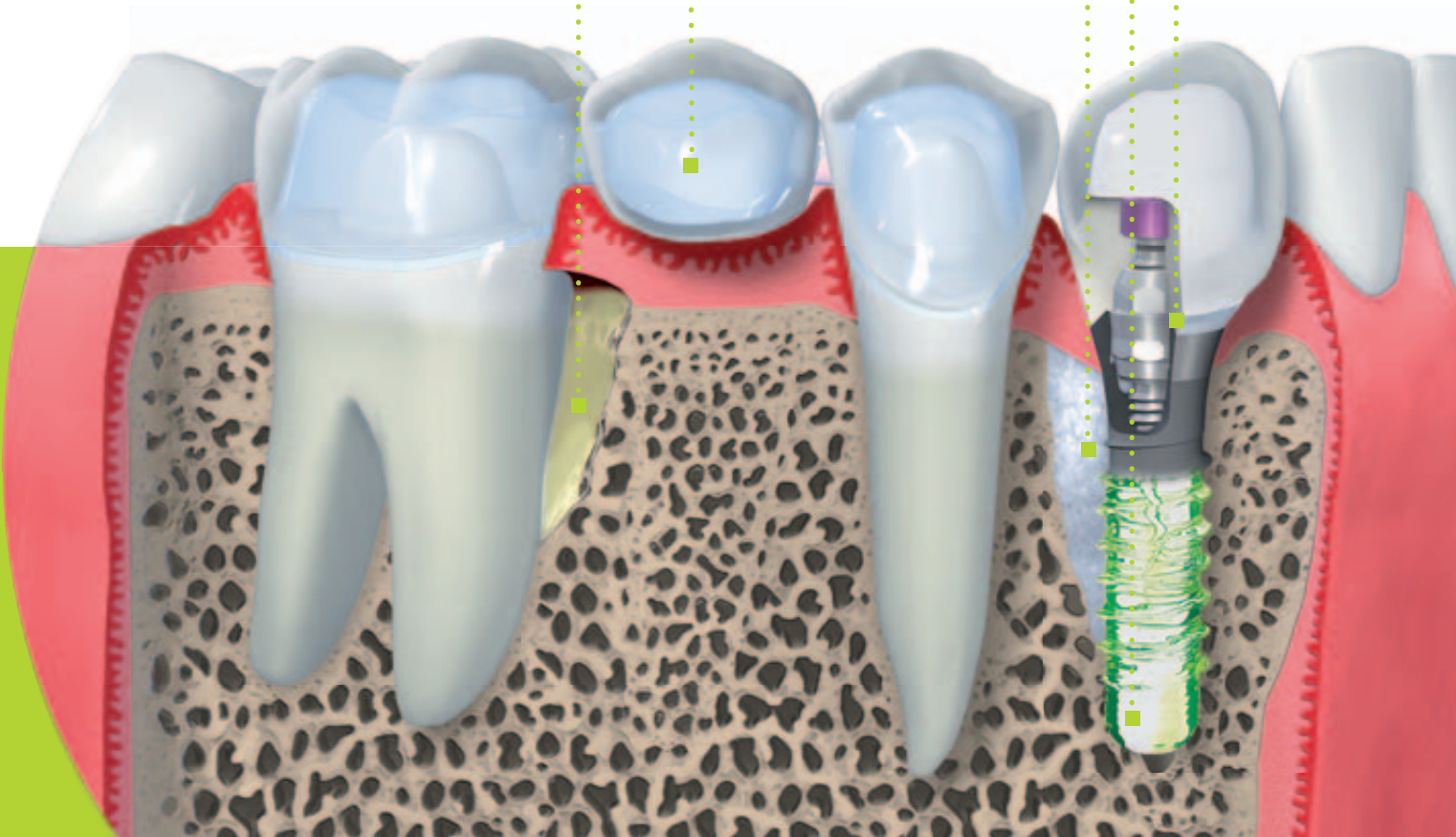
Straumann® CAD/CAM solutions

Straumann® Emdogain

Straumann® Dental Implant System

Straumann® SLActive

Straumann® BoneCeramic



## **SURGICAL, RESTORATIVE, AND REGENERATIVE SOLUTIONS BY STRAUMANN**

Whatever treatment is needed, Straumann offers the right solution to achieve optimal results. Straumann is dedicated to high quality products designed to meet biological principles. Our wide range of innovative products includes surgical, restorative and regenerative solutions as well as the latest in CAD/CAM technology.

COMMITTED TO  
**SIMPLY DOING MORE**  
FOR DENTAL PROFESSIONALS



1999, İplikçioğlu et al. 2002, Rubio Serrano et al. 2008). Thus, possible anatomical "snares" can easily be detected. However, one has to re-evaluate the anatomical situation from the perspective of the conventional two-dimensional radiological method compared to the three-dimensional method. This significantly simplifies the transmission of computer-supported implant planning to the operative site (Rupprecht 2007).

A multicentric retrospective study of 1,202 placed implants proved that thanks to navigated implantology none of the endangered anatomical structures was damaged (Bier et al. 2006). Three-dimensional representation facilitates the demonstration of anatomical structures before an autologous bone extraction, e.g. of the lower jaw (Aalam and Nowzari 2007) or the detection of pathological alterations (İplikçioğlu et al. 2002) in general. Due to tooth loss, there are numerous anatomical problems zones, which can mainly be found in heavily atrophied jaws (Gruber et al. 1993, Pietrokovski et al. 2007). A quantitative "bone mapping" of the different jaw regions, carried out in order to evaluate the existing bony structures and dimensions (Juodzbaly and Raustia 2004), as well as the detection of bone densities and qualities (Gomes de Oliveira et al. 2008) is facilitated by computer-supported diagnosis and the imaging of the different anatomical cutting levels (sagittal, coronal, axial). Zones of interest in oral implantology are in the upper jaw the maxillary sinus, especially its floor region, the floor of the nasal cavity, in the lower jaw the course of the mandibular nerve canal, the mental nerve at the mental foramen, and the structures belonging to the lingual side of the bone (Gruber 1993, van der Zypen 1994, Lenglinger et al. 1999, Sharawy and Misch 1999, Machado et al. 2001). There are abounding variations and risks e.g. the maxillary sinus septa (Kim et al. 2006), position and course of the foramina, the neurovascular bundle at the lingual side of the mandible, and in the anterior palatal region of the maxilla (Jacobs et al. 2007), a mylohyoid ridge, which can reach the height of the resorbed alveolar ridge at the atrophic posterior mandible. Undercut bone areas (Gruber 1993) or anatomical variations of the mental foramen (position, number, size etc., see Greenstein and Tarnow 2006). It is well known that conventional radiological methods do not always display the mandibular nerve canal reliably, which is of great importance for implantological purposes (Kieser et al. 2005). During the course of planning, many navigation programs offer nerve canal detections with a determined collision warning. It is important to verify the real size and the marking in order to also document irregular courses or doublings like they can be found in dentate and especially in toothless patients (Sharawy and Misch 1999). Also the course

and the extension of the intra-osseous anterior loop of the mental nerve ("mentalis-siphon", "anterior loop"), which can vary between 1 to 7 cm (Machado et al. 2001) can hardly be detected in an OPG (dental panoramic radiograph). 3-D planning also enables the detection of probable deviations, e.g. towards inferior, seen from the course of the loop from mesial buccal cranial, and then distal buccal (Hu et al. 2007, Uchida et al. 2007). As shown in the following case studies, 3-D planning also is of advantage for the localization of retained teeth or of inserted implants, and the relation between implants and neighboring natural teeth concerning implant restoration in partially dentate patients.

### Costs

Though implant navigation provides considerable diagnostic and operative advantages, dentists and patients are consistently concerned about the costs. Implant navigation is always coupled with additional expenses. In the past, official and private health insurances considered these costs as "luxury treatment" and thus as non-refundable. This may change. According to an adjudgment of the Local Court Dortmund (verdict dated September 21, 2008, file number: 421 C 9664/07) the costs for implantation navigation have been admitted for the first time by a private health insurance company. It remains to be seen, how health insurance companies will orient themselves by this adjudgment, or if other courts will follow the legal concept of the Local Court Dortmund. The Local Court Dortmund considered the implantation navigation in a concrete sense to be a "medically necessary treatment" according to the conditions of private health companies. After asking for an expert opinion, the court was convinced that the implantation would have been too risky without the supporting navigation technique, due to the very complicated anatomical anomalies of the patient, who filed this suit.

The patient's jaw showed considerable anatomical anomalies. The alveolar process in both inferior posterior tooth regions of the patient showed a knife-edged jaw ridge. This was heavily translocated lingually and the alveolar process was considerably atrophied at this level. The lingual wall of the mandibular margin below the mylohyoid ridge proceeded strongly angled, so the risk of perforating the lingual cortical plate when drilling the implant bone supporting area was given. Therefore, a drilling direction had to be chosen, which was different from the natural tooth longitudinal axis, especially when drilling in the posterior lower jaw area. The implant axis was heavily inclined to lingual. Without implantation navigation there would have been considerable risks of damaging nerves

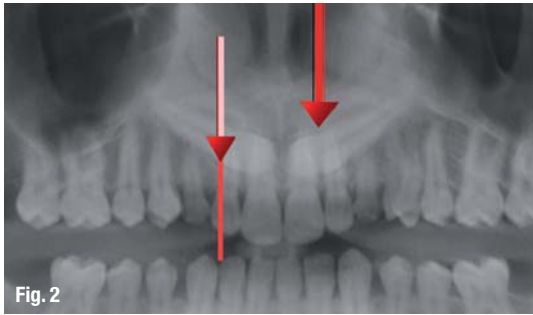


Fig. 2

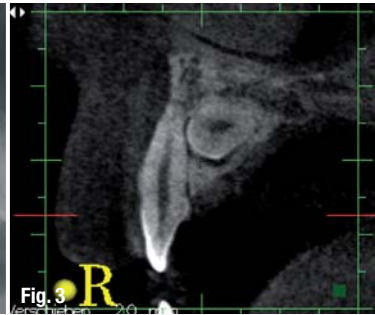

Fig. 3

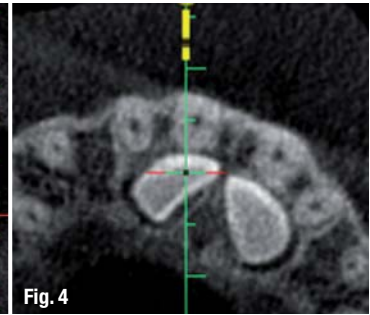


Fig. 4

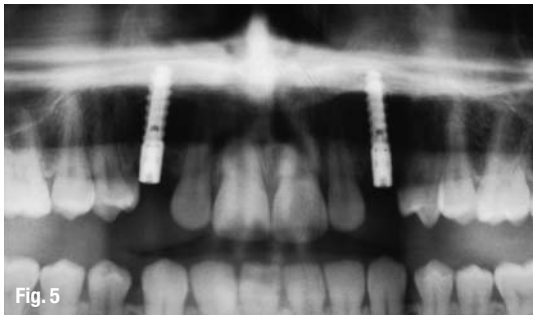

Fig. 5

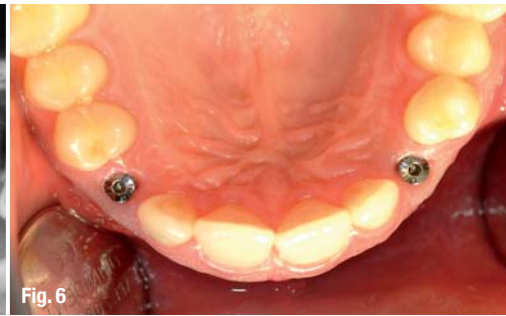

Fig. 6

**Case 1**

**Fig. 2\_** Panoramic display of retained canine teeth in the upper jaw.

**Fig. 3\_** The narrow spatial position in relation to the incisors indicates the subsequent operative procedure.

**Fig. 4\_** Also the transversal section illustrates the complicated retention form.

**Fig. 5\_** Panoramic display after implantation as immediate implantation after extraction of deciduous canine teeth.

**Fig. 6\_** Clinical appearance four weeks after the implantation and extraction of the deciduous teeth.

and muscles, and of perforating the lingual cortical plate. The verdict of the Local Court Dortmund has two consequences for the practical work of implantologists. On the one hand, every patient should be checked thoroughly in order to see, if there are any clinical or "conservative" radiological findings, which may indicate significant anatomical anomalies. This would justify the necessity to apply implantation navigation. The consequence of the case decided upon by the Local Court Dortmund would be e.g. if a dentist does not make use of implantation navigation he might be charged for a medical error, and thus becomes liable. On the other hand it has to be checked before carrying out implantation navigation, if in case of existing anatomical anomalies, this treatment will be refundable. According to the verdict of the Local Court Dortmund, this would be the case if implantation navigation is estimated to be medically necessary. In case of existing anatomical anomalies it is recommendable to clarify the reimbursement of costs beforehand with the patient's health insurance company. In view of a possible intended reimbursement, all clinical findings, which favor implantation navigation, should be meticulously documented for each case.

**Indications and case studies**

**Case study 1:**

A 22 year old male patient presented himself with two persisting and meanwhile loose deciduous teeth. The dental panoramic radiograph showed that the remaining teeth were retained and ectopic. The dentist, who had treated the patient before, had recommended to leave the retained canine teeth like they are in order not to risk any damages that might be caused by an operation. Since the deciduous teeth started loosening we had to elaborate on a new concept. In addition, the patient wanted an implant restoration for his neighboring teeth, but this could not be done since the retained teeth were still existent. After thoroughly informing the patient he decided upon having a 3-D image taken in order to exactly determine the position of the remaining canine teeth, and to be able to judge the possibilities to integrate them or to find an alternative treatment. The image revealed that due to the form of retention an orthodontic treatment would be very time-consuming and expensive. The retained teeth had no direct contact to the roots of the other remaining teeth. The decided operative extraction could be carried out in a very precise way, thanks to the three-

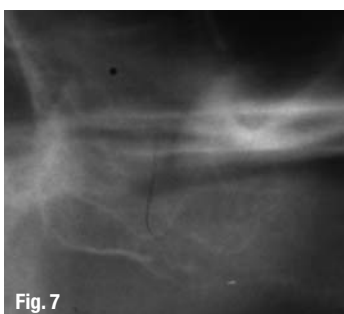


Fig. 7

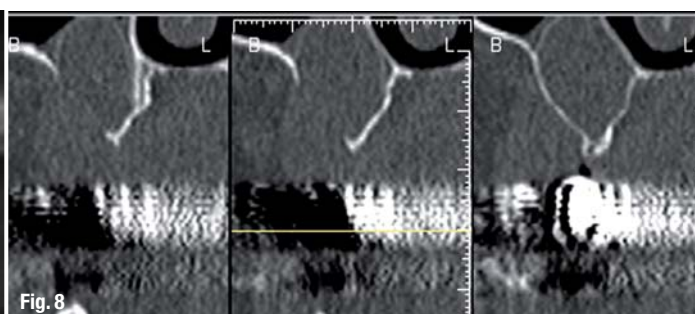


Fig. 8

**Case 2**

**Fig. 7\_** Panoramic display of the right upper jaw. Thereupon the evaluation of the sinus floor was planned.

**Fig. 8\_** The cross section of the three-dimensional image shows the bony defect and an opacification of the maxillary sinus.

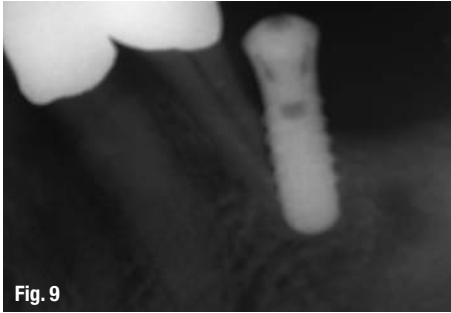


Fig. 9

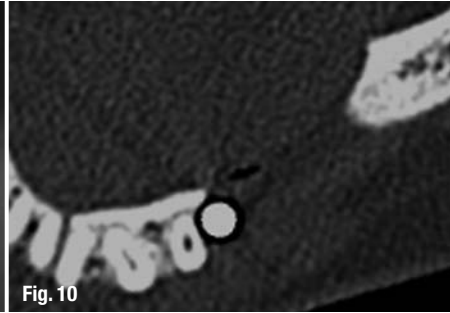


Fig. 10

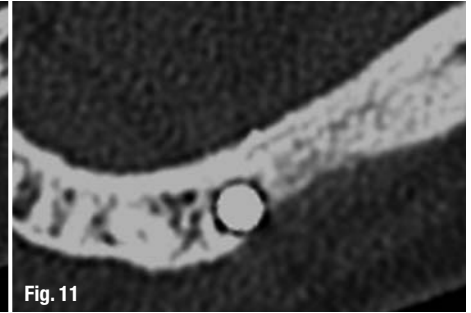


Fig. 11

**Case 3**

**Fig. 9\_** The contact between implant and tooth cannot clearly be proven due to the two-dimensional X-ray image. Root and implant apex may lie one behind the other.

**Fig. 10\_** In the medial transversal section implant and root still lie next to each other.

**Fig. 11\_** The contact and damage can be clearly seen at the implant's apex. A large part of the root has been cut off beyond the pulp cavity.

**Fig. 12\_** The extracted tooth provides the ultimate proof.

**Fig. 13\_** The removed implant can be exactly repositioned.

dimensional image. Due to the great loss of tissue we waited four months until we placed the implant. On the occasion of the extraction of the deciduous canine teeth we carried out an immediate implantation.

**Case study 2**

The upper and lower jaw of a 49 year old female patient had to be restored with implants. Since a sinus lift was necessary for the upper jaw anyway, there was no need for another X-ray image. Due to the low bone volume in the lower jaw it was agreed with the patient to have a three dimensional image taken. Also, the radiologist could nearly display the complete upper jaw and thus enabled the evaluation of the maxillary sinuses. The evaluation showed a missing bony floor in the maxillary sinus in the area of the posterior teeth of the right upper jaw, which could therefore be considered for the operative procedure. The patient could not give any anamnestic information about this. The bone loss might result from an earlier extraction of a molar.

**Case study 3**

A 51 year old female patient presented herself with a letter of referral for restoration of the unilateral free-end situation in the left lower jaw. Some time ago an implant 34 had been angularly inserted directly behind tooth 33. In order to avoid nerve damages an insertion was carried out angularly to the mesial direction, without previous three-dimensional planning. The dental panoramic radiograph suggested a lesion of tooth 33, for the tooth did not show any sensitivity reactions, no percussion pain and no apical alterations. This could not have been shown so clearly in a two-dimensional image. All the same, the implant apex (could also have been located directly behind the

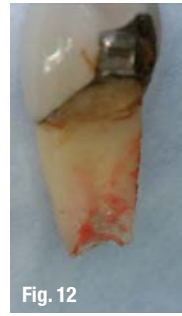

Fig. 12

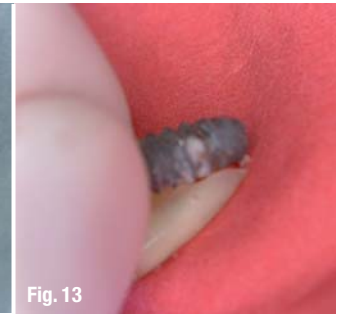


Fig. 13

root apex. Since the patient required further treatment and more certainty in regard to diagnosis, a 3-D image was taken, which proved a root apex lesion of tooth 33. Thus, tooth and implant were removed and a new restoration had to be planned.

**Case study 4**

About 25 years ago a ceramic anchor implant was placed in the left lower jaw of the today 67 year old female patient and the free-end situation was restored with a composite bridge. The prosthesis was no longer preservable, the implant was heavily loosened and surrounded by soft tissue, which could clearly be seen in the dental panoramic radiograph. The inferior posterior course of the anchor implant was directly above the mandibular nerve canal. At first, a three-dimensional image was taken for a better diagnosis, since the implant had to be removed in any case. The image displayed that the periimplant soft tissue in the anterior area was separated from the root canal course. In the mesial and posterior areas the soft tissues could not be separated from the inferior alveolar nerve. The anchor implant could be carefully removed intraoperatively. It was then tried to totally remove the granulation tissue from the defected area under magnifying glass control, which did not work out, due to con-

**Case 4**

**Fig. 14\_** The ceramic anchor implant is completely surrounded by soft tissue.

**Fig. 15\_** The inferior alveolar nerve can allusively be seen on the right, next to the soft tissue. It proceeds through the soft tissue of the posterior implant region.

**Case 5**

**Fig. 16\_** A significantly reduced area of 45° inclination can be seen under the mylohyoid line.

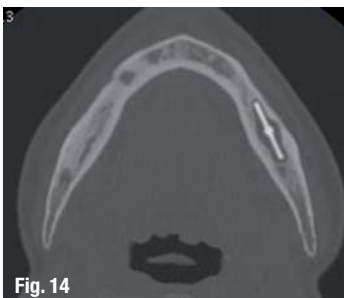

Fig. 14

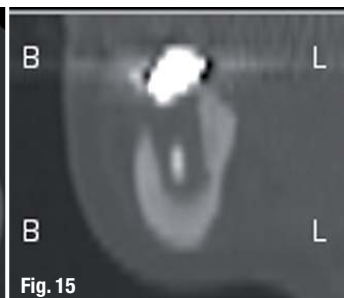


Fig. 15




Fig. 16

# Fast and Safe Bone Regeneration

Visit us: IDS 2009  
Hall 10.2 / Booth No. N-047

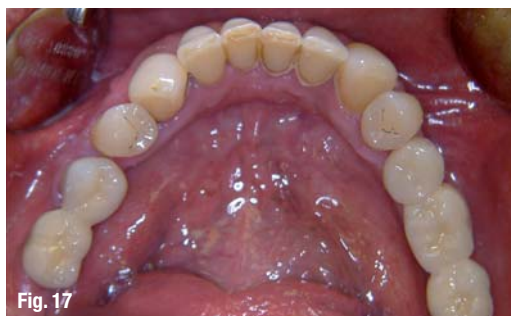

Fig. 17

Fig. 17\_ Clinical appearance of the final dental restoration.

crescences on the floor of the bony defect. In order not to damage the nerve, and considering the anatomical facts, the granulation tissue of the mesially defected area was removed, and mesially and distally clearly separated from the remaining soft tissues on the bottom of the defect. The extracted tissue was histologically examined. The patient was informed that radiological control examinations of the remaining defect should be carried out regularly.

## Case study 5

Implantation planning for the posterior teeth area of a heavily degenerated jaw. The 44 year old male patient required a restoration of the free-end situation with implants on both sides. Due to the clinical diagnosis, which had revealed heavily degenerated areas, a three-dimensional image had to be taken. Degenerated areas of almost 45° were displayed. However, the dimension of the jaw bone was sufficient for implant placement and restoration with angled abutments. An implant angle of 25° was sufficient. In exact compliance with the planning, the implantation was carried out with navigation support using a corresponding template.

## Acknowledgements

Our special thanks in regard to practical training with the planning systems go to the companies Baumgartner and Rath GmbH, Munich, C. Hafner GmbH & Co. KG, Pforzheim, and Materialise Dental GmbH, Oberpfaffenhofen, Germany. We also want to thank the companies Dental Ästhetik Vosteen, Morsbach, and Zahntechnik Erdmann GmbH, Heiligenhaus for the manufacturing of the splints used for implant planning, and their dental technician work.

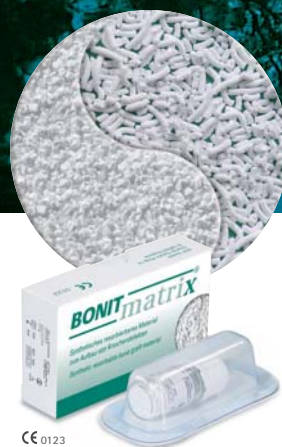*The reference list can be requested from the editorial office.*

**\_contact**

**implants**

**Dr Friedhelm Heinemann**

Im Hainsfeld 29, 51597 Morsbach, Germany  
E-mail: friedhelmheinemann@web.de



CE 0123



CE 1023

## Fast Bone regeneration with BONITmatrix®

BONITmatrix® is a proven bone graft material with considerable advantages for surgeons and patients.

- Excellent biocompatibility due to nanostructuring
- Integration into the natural bone remodelling
- Completely synthetic material assures high safety

Granulate and Package sizes:

0,6 x 4,0 mm	0,25 g
0,6 x 4,0 mm	0,50 g
0,6 x 4,0 mm	1,00 g
0,6 x 0,3 mm	0,25 g

## Safe Barrier with Hypro-Sorb® F to prevent ingrowth of Soft Tissue

Bioresorbable Bilayer-Collagen membrane for Guided Bone- and Tissue Regeneration (GBR/GTR).

- Good biocompatibility
- Optimal handling characteristics due to high tensile strength
- Complete resorption after approx. 6 months

Membrane sizes:

15 x 20 mm
20 x 30 mm
30 x 40 mm

**DOT GmbH**  
Charles-Darwin-Ring 1a  
D-18059 Rostock  
Germany  
Tel: +49 (0)381-4 03 35-0  
Fax: +49 (0)381-4 03 35-99  
sales@dot-coating.de  
www.dot-coating.de

DOT is a leading supplier of innovative solutions for dental and orthopedic implants

**DOT**  
medical implant solutions

# Extraction and Immediate Implant Placement Using a Combined Hard and Soft Tissue Augmentation and Provisionalization Technique

author\_ Suheil M. Boutros, USA

## Abstract

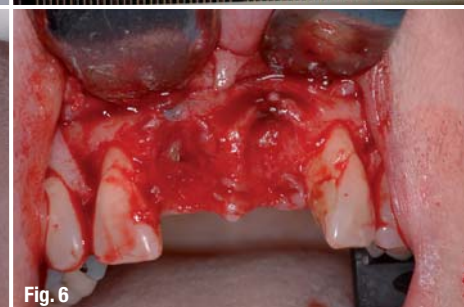
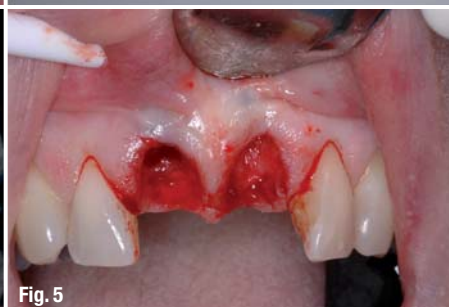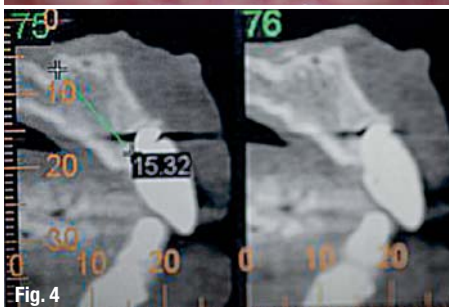
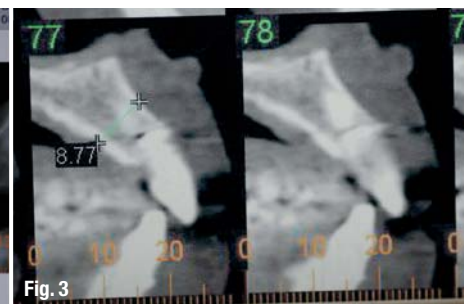
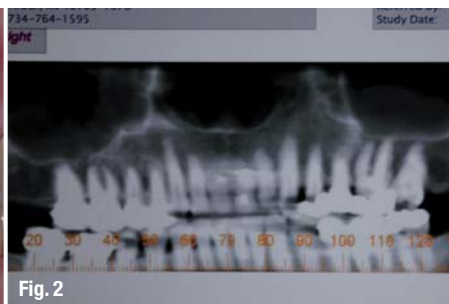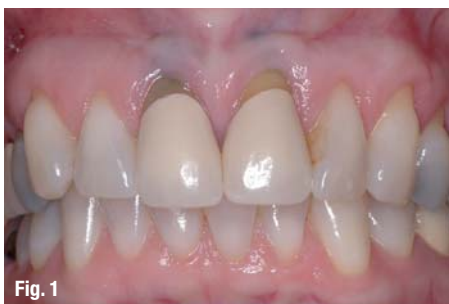Provisionalization of Endosseous implants at the time of placement has become more prominent in the field of dental implantology over the past several years, especially in the esthetic zone. The advantages of this modality of treatment include immediate tooth replacement, containment for bone grafting, soft tissue augmentation, formation and maintenance of esthetic soft tissue contours, minimizing the number of surgical procedures, the treatment time and an improved sense of the patient's perception of the implant treatment process. Although the survival rate for this technique is high and predictable, post treatment gingival recession and bone resorption in the aesthetic zone are potential limitations. This case report presents a surgical technique for the preservation and augmentation of anterior aesthetics that combines minimally invasive extraction, im-

mediate implant placement, a combined soft and hard tissue augmentation and immediate non-functional loading and the use of an implant system that allows platform switching to preserve the buccal bone.

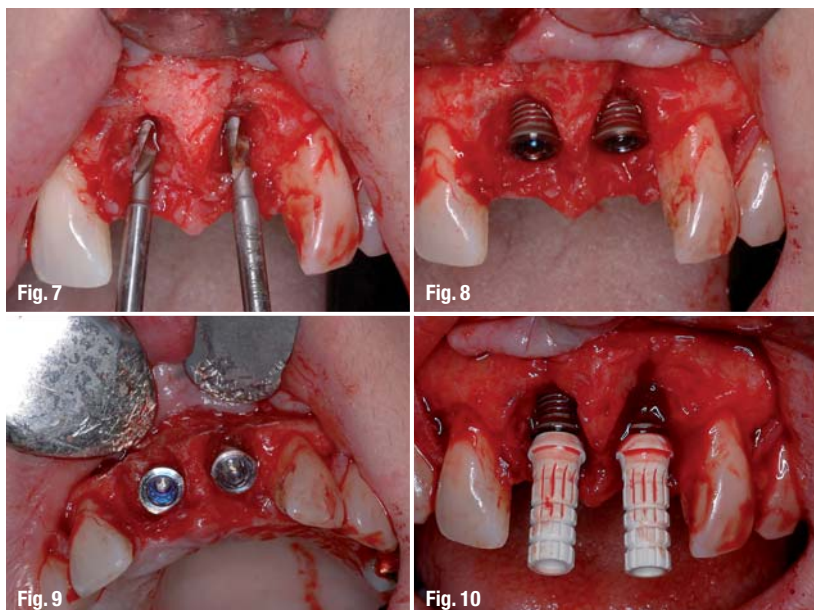
## Case Presentation

A 49-year old non-smoking female patient in good health with no contraindications to treatment presented with questionable maxillary right and left central incisors 15 years following traumatic injury that resulted in root canal therapy post and crown. Several apicoectomy surgeries were performed scarring from surgery was evident. Both incisors had mobility range of 2 to 3 (Fig. 1).

Clinical and radiographic examinations revealed no signs of infection and there were root fractures on both teeth, and they were given a hopeless prognosis.



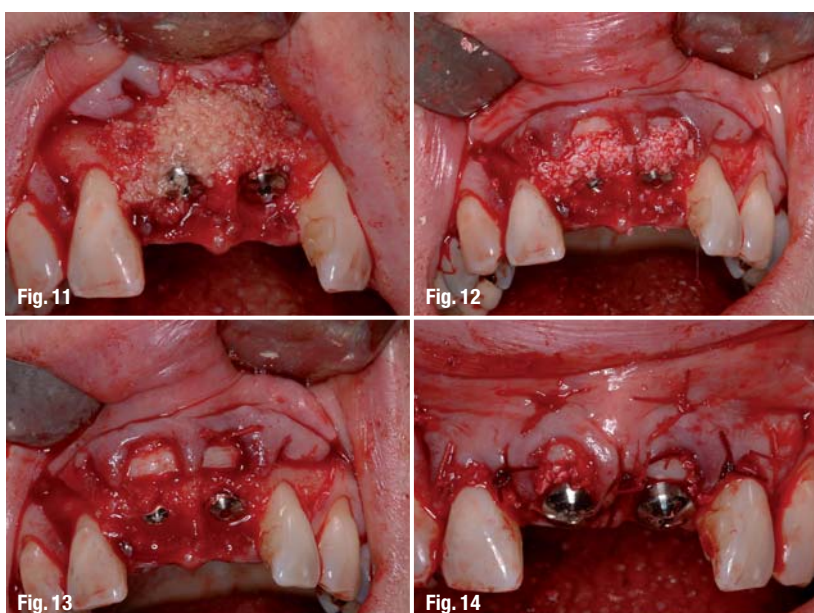
Premium  
quality at friendly  
prices



**Fig. 1\_** Preoperative appearance of right and left maxillary central incisors. **Fig. 2\_** Preoperative Cone Beam CT-SCAN. **Fig. 3\_** 8.77 mm the width of the alveolar bone in the region of the maxillary right incisor. **Fig. 4\_** 15.32 mm the height of the alveolar bone in the region of the maxillary left incisor. **Fig. 5\_** Flapless extraction. **Fig. 6\_** Flap reflection to determine the interproximal bone height. **Fig. 7\_** Twist drills were used as guides. **Fig. 8\_** Coronal-apical position of the fixtures. **Fig. 9\_** Buccal-palatal position of the fixtures. **Fig. 10\_** Temporary cylinders. **Fig. 11\_** Mineralized freeze-dried bone. **Fig. 12\_** Xenograft bovine bone as a second layer. **Fig. 13\_** A connective tissue graft sutured. **Fig. 14\_** Flap sutured around the healing abutments.

#### Pretreatment Planning

The implant team conducted a complete medical and dental evaluation. Diagnostic casts were obtained. Evaluation of the surgical site involved a diagnostic wax-up of the hard and soft tissue and the laboratory technician converted it to surgical guide/restorative template. In addition to the periapical radiographs, a cone beam CT-SCAN was obtained to determine the amount of alveolar bone present apical to the root tips of the maxillary incisors (Fig. 2, 3, 4). Treatment options were given and informed consent was signed.



perfect aesthetics  
internal hex  
accelerated treatment

Xigñ®

Allfit®

The Allfit® Xigñ® implant system is designed for enossal dental implantations.

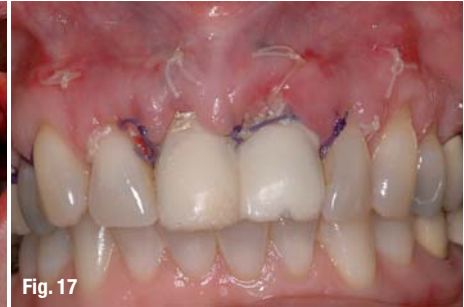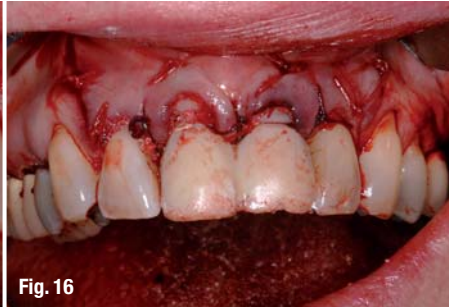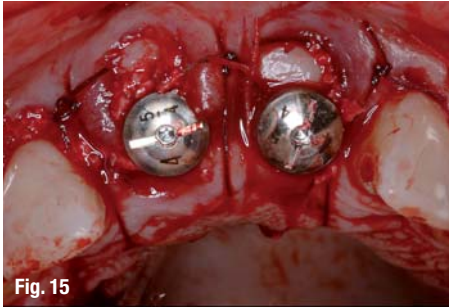
The Xigñ® implant system is suitable for single-step and dual-step implant protocols.

It is made of Grade 4 pure titanium.

Xigñ® implants are abraded with aluminium oxide and hot-etched and have an osmotically active nanocoating. All accessory parts are colour-coded.

**IHDE DENTAL**   
the implant.comany

Dr. Ihde Dental GmbH  
Erfurter Str. 19 · D-85386 Eching/Munich, Germany  
Telephone: (49) 89 319 761-0 · Fax (49) 89 319 761-33  
e-mail: info@ihde-dental.de · www.implant.com



**Fig. 15\_** Buccal palatal view of flap.

**Fig. 16\_** Provisional crowns out of occlusion.

**Fig. 17\_** Ten days post surgery.

**Fig. 18\_** The second temporary crowns.

**Fig. 19\_** The final restorations two years post placement.

**Fig. 20\_** Final radiograph two years post placement.

**Fig. 21\_** The final restorations.

**Surgical Phase**

Following the administration of intra-venous sedation (Midazolam 8 mg, Fentanyl 100 microgram, and 8 mg of Dexamethasone) the local anesthetic was administered (lidocaine with epinephrine 1:100,000), atraumatic teeth extractions with periostomes was performed without flap reflection to preserve the interproximal papillae and the buccal plate of bone (Fig. 5). A full thickness flap was reflected (Fig. 6).

The sockets were debrided using hand and rotary instruments. Using copious irrigation, preparation of the osteotomies began using a 2mm twist drill (Fig. 7).

Preparation of the osteotomies continued with a 3 mm drills and the implants were placed according to the manufacture's protocol (4/5/4 x13 mm, Certain Prevail, Biomet 3i, Palm Beach, Florida). The implants were 3 mm below the adjacent teeth CEJ (Fig. 8). The buccal-lingual position was more in a palatal position (Fig. 9).

**Provisionalization**

Certain Non-hexed PreFormance temporary cylinders were used (Fig. 10). These abutments fulfilled the requirements for platform switching.

**Bone and Soft Tissue Grafting**

A combination of mineralized freeze dried bone allograft (MFDBA) and xenograft bovine bone were used (Fig. 11). A subepithelial connective tissue graft was harvested from the right palatal area of the first and second bicuspid and was sutured using 4-0Vicryl suture to allow the soft tissue augmentation (Fig. 13). The pedicle flap was coronally advanced and was sutured around the healing abutments while the temporary crowns were finished by the restoring dentist (Fig. 14, 15). The provisional crowns were fab-

ricated in the office laboratory. The healing abutments were removed and the temporary crowns were seated. The occlusion was checked to eliminate any premature contacts (Fig. 16).

The patient was provided with appropriate post operative instructions and returned in 10 days for a follow-up visit (Fig. 17).

**Restorative Phase**

Twelve weeks post extractions and implants placement and provisionalization, the temporary crowns were changed to different temporary crowns to improve the soft tissue healing (Fig. 18). Six weeks later, the patient was seen by her restorative dentist for the final fixtures level impressions and the fabrication of the final restorations. Prefabricated Gingi-Hue abutments were used with the platform switching concept.

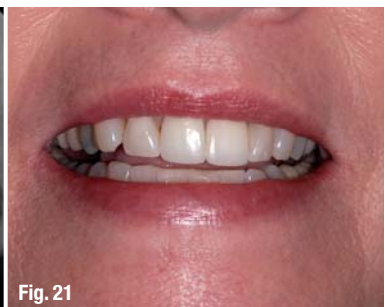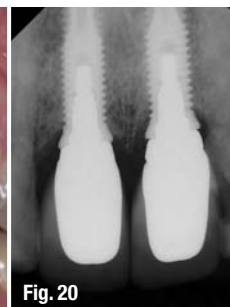
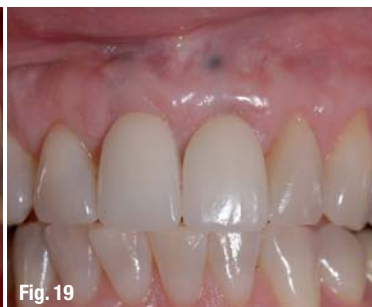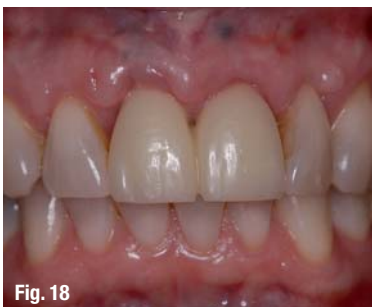The final porcelain fused to metal crowns were cemented on the abutments using permanent cement. The patient seen for follow-up visits (Fig. 19). The buccal gingival height remained stable two years after the placement of the final restoration. Periapical radiograph were taken after two years and confirmed the stability of the bone level around the implants (Fig. 20).

**Conclusion**

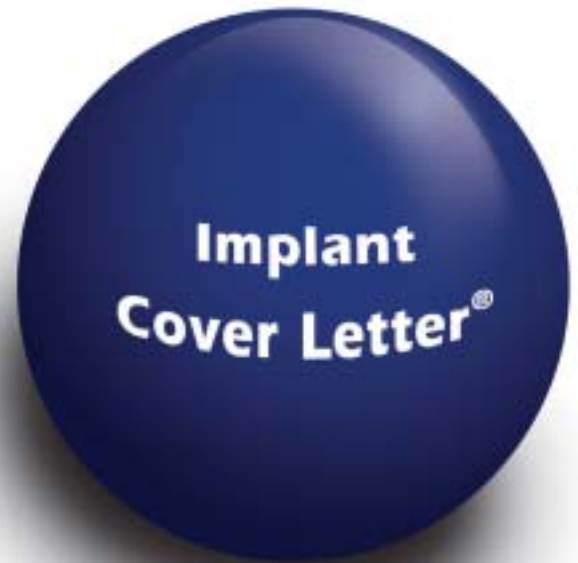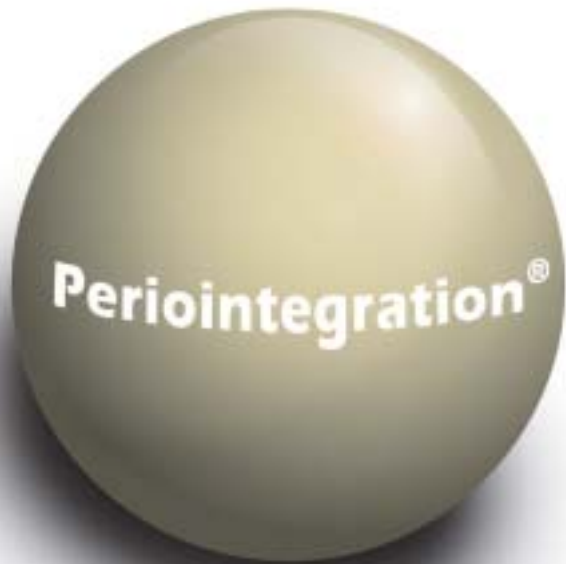This case report describes a technique to preserve and augment anterior aesthetics by combining atraumatic teeth extraction, hard and soft tissue augmentation, immediate provisionalization and using the platform switching concept to preserve the buccal plate. The gingival tissue surrounding the implants has remained stable with no recession two years following final crowns placement (Fig. 21).

**\_contact implants**

**Suheil M. Boutros, DDS, MS**  
 Assistant Prof, Department of Periodontics  
 University of Michigan  
 Periodontal Specialists of Grand Blanc  
 8185 Holly Road, Suite 19  
 Grand Blanc, MI 48439, USA  
 Phone: +1-810-695-6444  
 E-mail: sboutros@umich.edu



# information & concept



“....significantly better....”

**Hall 4.1**  
**Stand A-021**

The unique zirconium nitride implant-abutment-coating ZircoSeal® developed by the well-known Fraunhofer Institut and Clinical House Europe reduces the plaque adhesion and increases the biocompatibility of the surface characteristics and gingiva fibroblasts connection after biofilm removal in a highly significant way (Periointegration®). Active prevention of plaque-induced peri-implantitis and stimulation of Periointegration® can be expected.

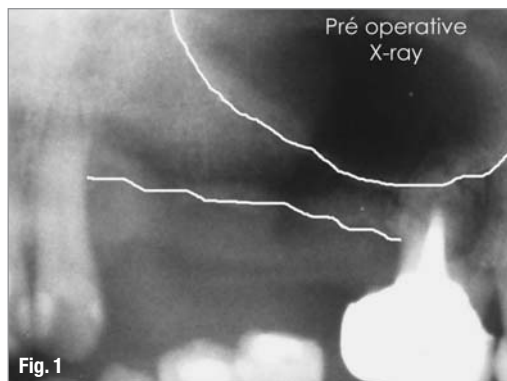
This new implant technology for long-term sustainability is created by the Stiftung Mensch und Medizin and covered by Germany's oldest insurance company GOTHAER with the first “10 year full-coverage-warranty-program” including a fixed compensation of surgical-, prosthetics cost and components in case of implant loss.





# Use of Bone Regeneration Cement for Bone Grafting in Atrophic Areas—Clinical, Radiographic and Histological Analysis

**authors\_** Sérgio Alexandre Gehrke\*, Bruno König Júnior\*\*, Nara Maria Beck Martins\*\*\*, \*Lachem, Universidade Federal de Santa Maria, Brazil, \*\* ICB, Universidade de São Paulo, Brazil, \*\*\* Dpt. of Pathology, Universidade Federal de Santa Maria, Brazil



## \_Abstract

The reconstruction of edentulous jaws aims first at augmenting the ridge width by gaining volume, and then at promoting growth of healthy and functional bone, able to support the prosthetic implant restoration over many years. The bone atrophy following tooth loss is due to a lack of mechanical stimulation and is emphasized by the pressure applied by the prosthesis and—in the posterior region—by the progressive pneumatization of the maxillary sinuses. The challenge of bone augmentation materials is to promote sufficient bone capital allowing adequate placement of implants. Nowadays, thanks to the recent breakthrough in understanding of cell metabolism, there is a great

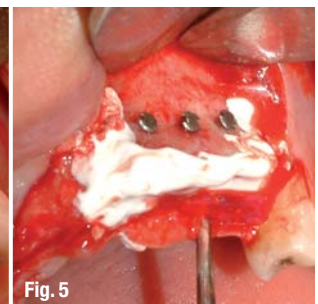
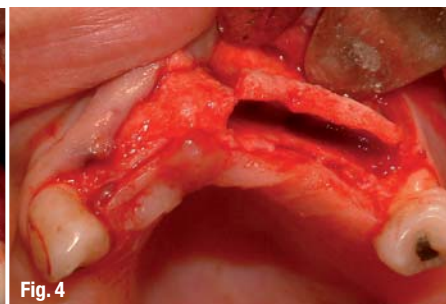
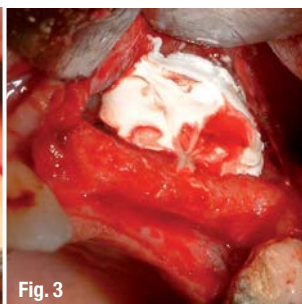
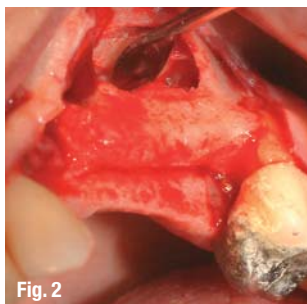
trend to develop synthetic materials for this purpose, in order to decrease the surgical trauma and the number of interventions. This is reflected by the number of products available on the market.

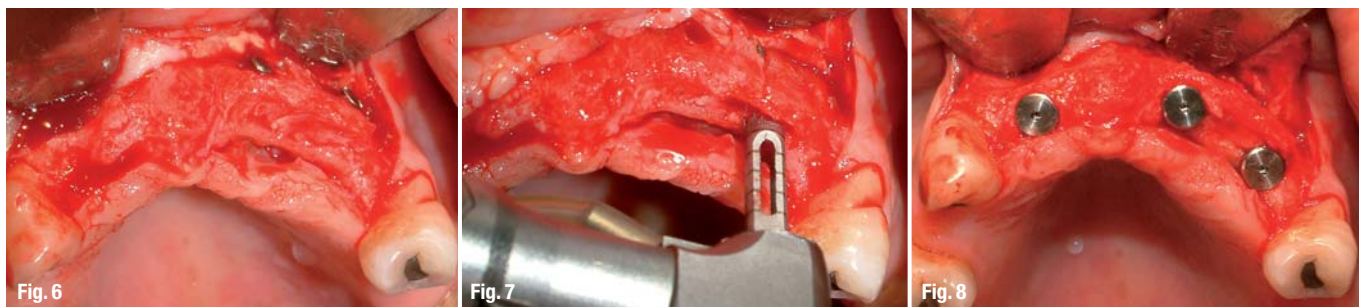
PD VitalOs Cement is a relatively new synthetic bone substitute that has been extensively studied in animal models. Although its use in clinical practice has shown positive results already, the histological data still needs to be developed and studied in details. The objective of this study is to evaluate the performance of PD VitalOs Cement for the osseous regeneration of atrophic areas to allow subsequent placement of dental implants. Performance is assessed through clinical and radiological follow-up as well as histological examination to evaluate the osteogenic potential of the material in six patients. The selected indications for this study are the sinus floor elevation and the horizontal ridge augmentation, two procedures performed in two steps, allowing collection of cores when installing the implants.

## \_Introduction and literature review

Successful augmentation of ridge margins is achieved when two requirements are fulfilled: on the one hand healthy and functional bone able to support implant-supported prosthetic restorations in function over years and on the other hand,

**Fig. 1\_** Pre-operative radiograph.  
**Figs. 2, 3\_** Preparation of the site and installation of the cement in the sinus.  
**Figs. 4 – 6\_** Illustration of the horizontal ridge augmentation technique.





**Figs. 7–9** Collection of cores for the histological examination.

the gain of a sufficient bone volume to preserve esthetics. The main reason for using bone substitute materials is to allow tissue regeneration through viable, healthy and mature bone in areas where implantation is planned. Various degrees of atrophy are encountered in the maxilla and mandible of patients. They vary with the etiology of teeth loss, such as periodontal disease, systemic health problems, anatomy, trauma, agenesis, among other factors. This atrophy for lack of stimulation of the bone after tooth loss is even enhanced by the pressure applied by the edges of the prosthesis and, more posteriorly, by the progressive pneumatization of the maxillary sinuses. Initially, the alveolar process loses width without height loss. This phenomenon starts buccally and progresses towards the lingual or palatal direction. It takes place relatively quickly, especially in the anterior region of the maxilla, so that the implants of usual diameter cannot be placed due to the insufficient width for the preparation of the bone bed. The severe bone loss results in a lack of support for the soft gum tissues as well as for the upper lip and facial soft tissue, leading to unsatisfactory esthetic results.

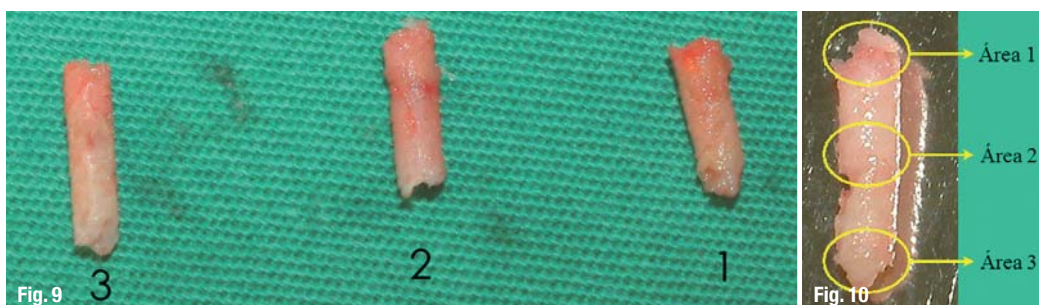
It is important to keep in mind that following tooth loss, the process of bone loss can be lessened or even prevented by the installation of implants as soon as possible, before progressive atrophy starts. Masticatory loads transmitted through the implants to the alveolar maxillary sockets stimulate the bone and therefore contribute to diminishing or even avoiding the progressive bone atrophy. Nevertheless, when these conditions are not achieved it becomes necessary to recover the lost bone anatomy through various techniques and materials. The actual trend is to perform surgeries as little invasive as possible and with a high predictability.

The need for correction of bone defects has led to the development of synthetic materials reproducing biological properties required for bone grafting. Autologous graft is generally considered the most suitable material to correct such defects. However, use of autologous bone is not always an option when the defect size is too large or when patient discomfort would be too important or when his recovery would take too long.<sup>1-6</sup>

The ideal synthetic bone substitute should be biocompatible, gradually resorbed and eventually replaced by the host tissue (osteoconductive or osteoinductive properties)<sup>7-11</sup> Beside these biological properties and availability, the stabilization of the implantation site is an interesting feature in various operative situations.<sup>12</sup> Given that few techniques and materials present all these requisites, the dental surgeon needs to have choice criteria to choose the adequate technique and material for different situations.

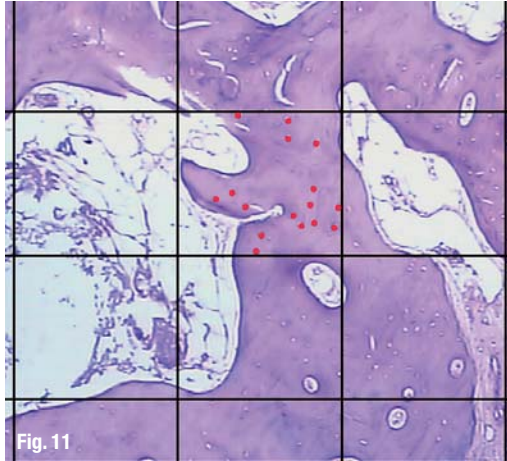
The use of biomaterials in clinical dentistry is gaining increasing importance in light of the various possibilities of application and ease of use they offer. The use of alloplastic bone substitutes is indicated to restore the function and morphology of areas that have suffered surgical interventions, to increase the volume of atrophied alveolar ridges, or to treat lesions caused by periapical diseases, periodontal bone defects, bone loss associated or not to implants, etc.<sup>13-18</sup>

Calcium-based substitute materials have been widely studied over the last twenty years, mainly due to the relative ease of production and the possibility to produce large quantities. Among these, cements were also developed to facilitate the installation of such materials in bone defects. The use of a cement as bone substitute offers in-



**Fig. 10** Division of the cores into three analysis areas.

**Fig. 11** Illustration of the histological analysis for counting the number of osteocytes per mm<sup>2</sup>.



interesting features, like the setting reaction leading to stabilization of the treated site or the ease of placement. However, there are some clinical requisites that must be fulfilled, like easy handling of the product, adequate setting time, sufficient mechanical strength between placement and complete resorption, neutral pH (6.5–8.5) during and after setting to prevent any cytotoxic effect, and good adherence to bone tissue.

Bone cements offer a very interesting alternative to granular bone substitutes. The first difference to granules is that they harden in situ and are therefore mechanically stable in their environment. This means that they can be used without membrane to hold them in place, like it is done with granular products to avoid their secondary migration. The other reason why a membrane is not necessary is related to the inner structure of a cement. The porosity of the material is too narrow to allow cells, blood vessels and soft tissues to penetrate the cement. Bone regeneration takes place at the bone-cement interface, which moves over time towards the heart of the material.<sup>19, 20</sup> The fact that the surgery is then performed without handling a membrane lowers the overall cost and the per-operative time.

The present study aims at evaluating clinically, radiographically and histologically the performance of an injectable calcium phosphate cement (PD VitalOs Cement) used to fill bone defects in patients requiring subsequent implant installation.

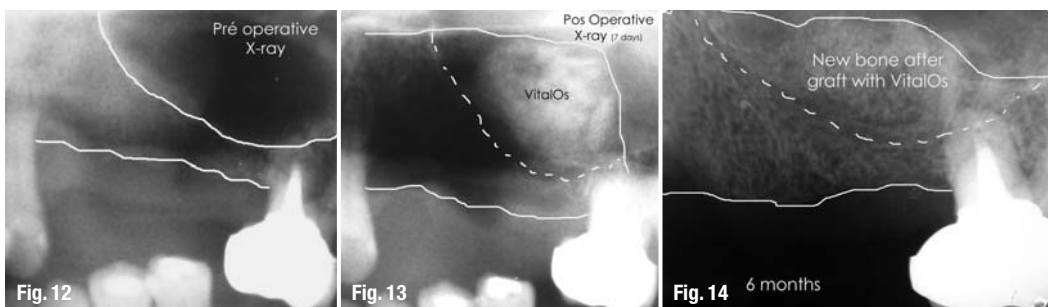
## Materials and Methods

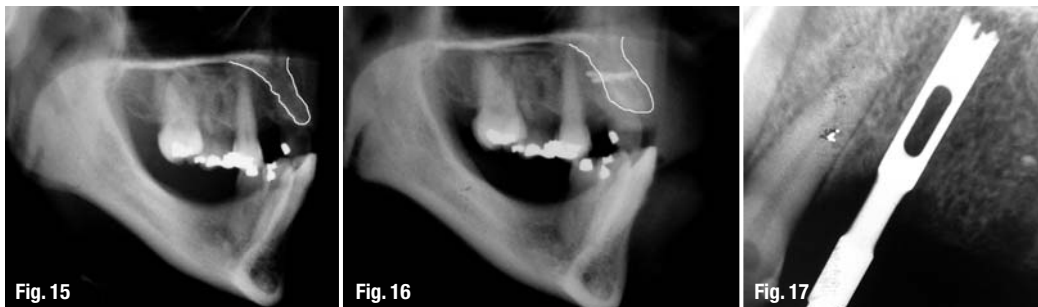Six patients of the Bioface Institute were selected for the study, three requiring sinus floor augmentation (without concomitant placement of implants—two-stage procedure) (group 1) and three requiring maxillary buccal augmentation through ridge distraction (group 2). The selected patients had all a good general health, without major disease history or contra-indication for the proposed reconstructive surgery. They all agreed in written with the proposed treatment guidelines, and received pre- and post-operative antibiotics and anti-inflammatory treatment.

In patients of the group 1 (G1) maxillary sinuses were filled with the cement (Figs. 1–3). The treated sites presented conditions where simultaneous implantation was not possible. The intervention was performed through opening of a lateral window. When lifting the sinus membrane, attention was paid to uncover the lateral bone wall of the nasal cavity. The filling of the sinus was performed by injecting the cement while holding the membrane lifted with an instrument. It is very important to ensure a good anchoring of the cement against the bone wall of the nasal cavity since the latter provides the osteogenic cells for the replacement of the cement by new bone. To achieve this it is necessary to control the bleeding in the sinus. Stability of the cement in the site is effective once it is anchored to the inner side of the sinus (nasal cavity) and its outer part (the inner side of the ridge around the lateral window) (Figs. 1–3). After 6 months, every implantation site was drilled with a trephine bur (external diameter 3 mm) in order to get cores for histological examination.

The patients in group 2 (G2) required bone volume augmentation in the anterior maxilla. The technique chosen was a horizontal ridge augmentation allowing in the same time the correction of the lip position. The empty spaces created by the distraction were in average 4 mm wide and were filled with the cement, starting from the bottom, up to the level of the ridge. The implants were placed four months later. The implantation sites were drilled with a trephine bur to collect cores for histological examination.

**Figs. 12–14** Radiographic sequence showing the evolution of the augmentation material in the sinus (pre-op, post-op, 6 months follow-up).





**Figs. 15, 16\_** Lateral radiographs, pre-operative and after 4 months. **Figs. 17, 18\_** Radiograph showing collection of a core in native bone and corresponding histological section of this area with 10x magnification (HE).

In both groups, samples of native bone (NB) were obtained by drilling in neighboring implantation sites where no augmentation was previously performed (Figs. 4–9).

G1 patients were controlled by conventional panoramic radiographs at one week and six months post-operatively. G2 patients were additionally followed up with profile radiographs one week and four months after surgery.

The cores were dehydrated, embedded in paraffin, then cut into sections. The latter were stained with the Hematoxylin and Eosin (HE) and the Masson's trichrome (TM) methods.<sup>21</sup>

All observations were made with a light microscope Nikon E200 coupled to a camera. The comparison between native bone and augmented areas was made by analyzing quantitatively the number of osteocytes per square mm. The measurements were performed at three levels of the cores (areas 1 to 3, external to apical parts), as shown in Figs. 10 and 11. The analysis was made on images with a 10x magnification. The results are presented in Table 1, in the form of mean values from the data of three patients, for each core area considered. The data was analyzed with the variance analysis test (Anova two way, with software GraphPad Prism® 4.0,  $p < 0.05$ ).

Area	Native bone	G 1	G 2
1	7.33	19.33	14.33
2	6.33	14.66	19
3	8.66	16.66	17.66

**Table 1\_** Mean number of osteocytes per mm<sup>2</sup> in each area.

A descriptive and semi-quantitative analysis was performed, considering the following factors involved in bone healing: cortical repair, collagen fibers, inflammatory infiltrate and new bone formation (Tables 2 and 3). The notation system used was the following: Collagen fibers, inflammatory infiltrate and new bone formation: 0 = absent, 1 = light, 2 = moderate, 3 = large presence. Cortical repair: 0 = absent, 1 = irregular union of margins, 2 = covering around 50% of the core width, 3 = width larger than 50% of the core width. The data presented in Tables 2 and 3 are mean values of the three core areas.

The sections were analyzed by a single examiner with experience in analysis of bone tissue histological sections.

Patient	Cortical repair	Collagen fibers	Inflammatory infiltrate	New bone formation
I	2	2	1	3
II	3	2	1	3
III	2	1	0	3

**Table 2\_** Semi-quantitative analysis, G1.

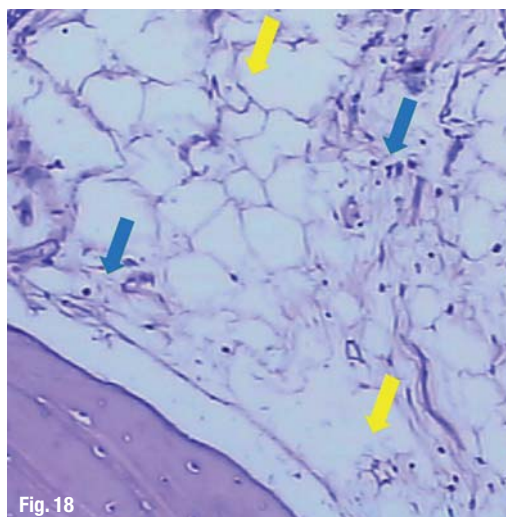
Patient	Cortical repair	Collagen fibers	Inflammatory infiltrate	New bone formation
I	3	1	0	3
II	3	1	0	3
III	3	2	1	3

**Table 3\_** Semi-quantitative analysis, G2.

## Results

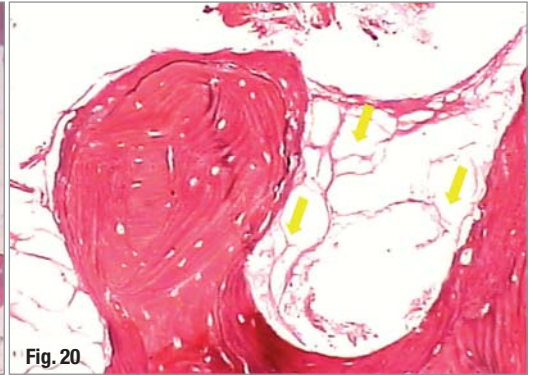
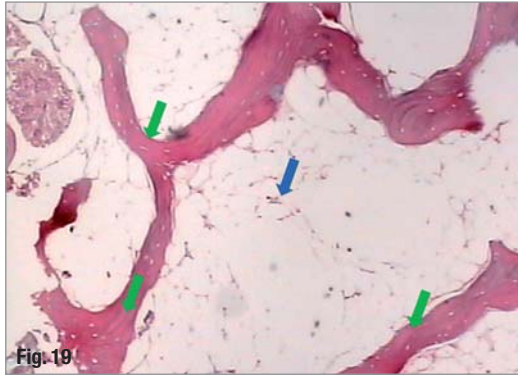
### Clinical

No complication of any type was reported among the six patients involved in the study in the course of the whole treatment: no per-operative complication (two surgeries per patient) and no post-operative complication (post-operative study



**Fig. 18**

**Figs. 19, 20\_** Histology of native bone with 10x and 40x magnification (TM).



time: six months for G1 patients, four months for G2 patients).

Upon suture removal, the healing process was uneventful, similar to cases usually treated with autologous bone. The installation of well osseointegrated implants was possible in the second surgical procedure and the implant-supported prostheses have all been placed successfully.

The bone tissue in the implantation sites had always a firm consistency, similar to normal type II bone tissue, with a good resistance to the drilling performed with rotary instruments. This allowed placement of implants with good primary stability.

**Radiographs**

Thanks to its radiopacity, the cement was easily located on the post-op radiographs taken at one week, especially in the G1 cases (Fig. 13). This allowed to distinguish clearly on the subsequent radiographs the resorption of the cement and the formation of new bone. After six months the presence of new bone can be clearly evidenced in the sinuses (Figs. 12–14). In the G2 the volume gained 4 months after the augmentation procedure can also be clearly evidenced on the radiographs (Figs. 15 and 16). This allowed adequate installation of implants, facilitating the final esthetic result.

**Histologies**

The number of osteocytes per square mm was found to be statistically different between NB (native bone) and G1 and G2 (Anova analysis,  $p < 0.05$ ), the

augmented groups showing more osteocytes than in native bone (Table 1). No statistical difference was evidenced between the two augmented groups (G1 and G2).

The semi-quantitative analysis of the cores showed similar results in group 1 and 2.

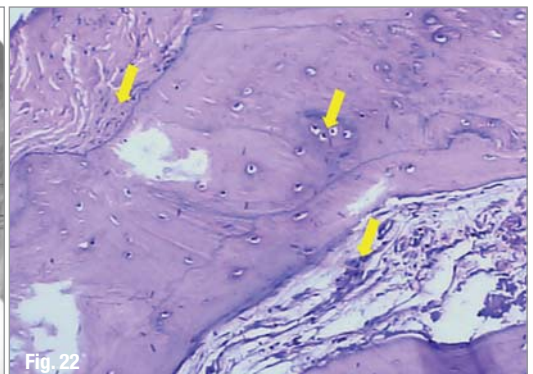
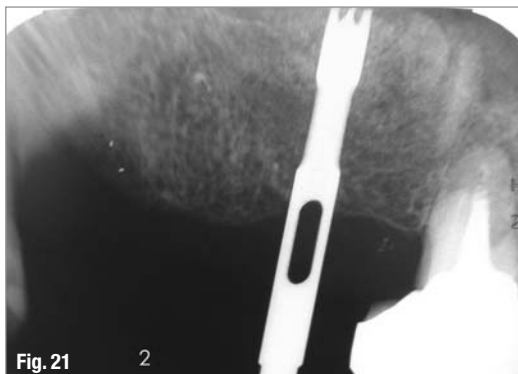
**Native bone**

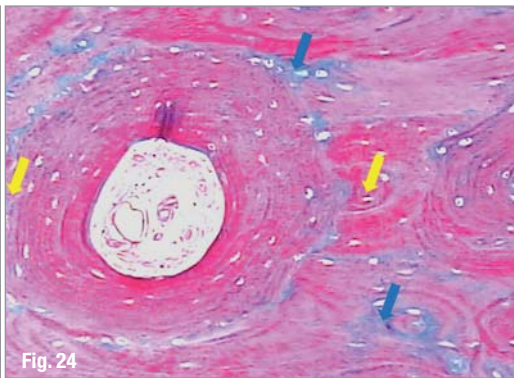
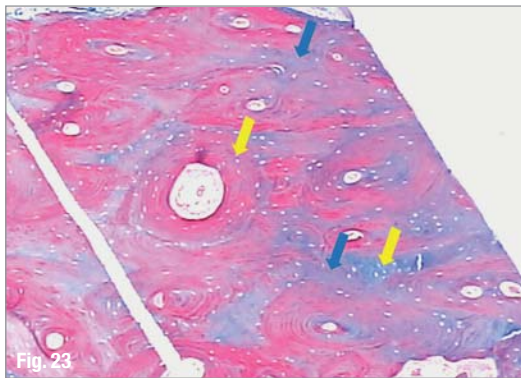
The histological analysis of the cores taken in native bone shows a trabecular structure typical of cancellous bone, like narrow trabeculae (green arrows) with lines of incremental growth and presence of many viable cells (osteocytes—blue arrows) in all patients under evaluation. The medullary spaces had a normal aspect, without inflammatory infiltrate, with blood vessels free of congestion and cells resembling adipocytes (bone marrow fat—yellow arrow), as shown in Figs. 17–20.

**Areas augmented with bone regeneration cement**

The histologies gathered from sinuses augmented with the cement (G1) show new bone formation, although the quantity and density of the trabeculae is inferior to those found in those of G2. The spaces where calcification was not complete show a large quantity of blood vessels and collagen fibers with intensive cellular activity (yellow arrows). Some areas presented a conjunctive tissue, rich in collagen fibers and with only few cells. In none of the sections studied was there any remnant of unresorbed cement to be seen (Figs. 21–25). In the areas augmented with the

**Figs. 21, 22\_** Radiograph showing the collection of a core (G1), and resulting histology (10x – HE).





**Figs. 23–25**\_ Histological section from G1, magnified 4, 10 and 40x (TM).

cement in the G2 group (ridge distraction) intensive new bone formation can be seen, with a trabecular density higher than in the native bone (green arrows). The trabeculae are made of viable cells (osteocytes, blue arrows), as well as several incremental growth lines, with newly formed bone observed in the form of lamellar bone in these areas. The non-calcified spaces augmented with the cement show the presence of collagen fibers with intensive cellular activity (yellow arrow). The presence of dilated blood vessels was noted, indicating intensive vascularization in the new bone formation areas (Figs. 26 – 30). Like in the histo-

logical sections of G1, none of the G2 sections showed any cement remnant.

### Discussion

The atrophic areas augmented with the cement healed uneventfully and no per- or post-operative complication occurred in any of the two bone augmentation procedures performed in this study. Implant placement surgeries were also performed without any complication and all patients could eventually have their implant-supported prostheses in-

www.AICimplant.com

# AIC World Meeting

2009 THAILAND

---

**OSSTEM IMPLANT,**  
The most dynamic evolution in the world!

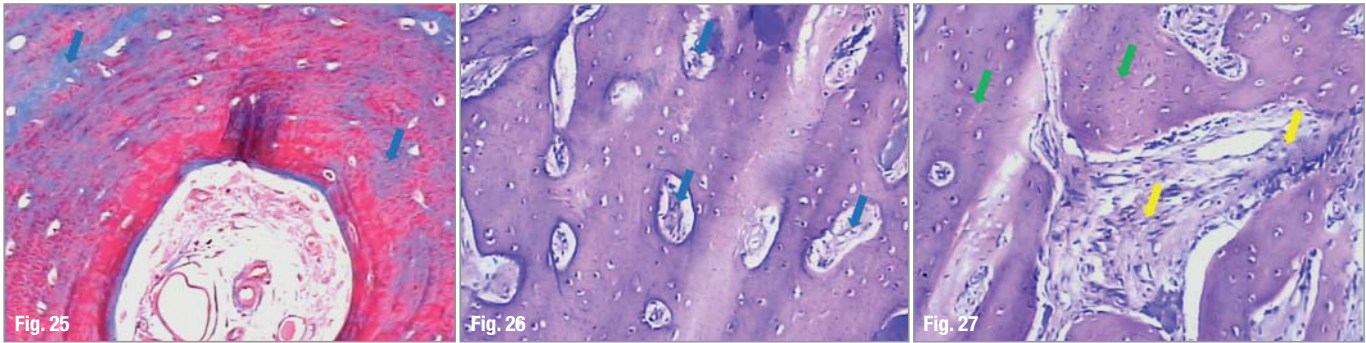
2nd~3rd, May 2009  
**CENTARA GRAND HOTEL**  
in Bangkok, Thailand

Besuchen Sie OSSTEM; IDS Köln  
Hall 4.1 A008,A010,A019,C019

## PROGRAM

3rd, May 2009

Session	Speaker	Subject	Moderator	
<b>Opening</b>	09:30~10:00(30")	<b>Opening</b>		
<b>Session 1</b>	10:00~10:45(45")	Dr. Suh, Bong-hyeun	Early/immediate loading in surgically compromised patient	Dr. How Kim Chuan
	10:50~11:35(45")	Dr. Rajapsa Panichuttra	Esthetics CAD-CAM Abutments	Dr. Marius Mitrenca
	11:35~12:00(25")	<b>Q &amp; A</b>		
<b>Lunch</b>	12:00~13:00(60")	<b>Lunch</b>		
<b>Session 2</b>	13:00~13:50(50")	Dr. Cho, Yong-seok	Advantages of OSSTEM GS Implant System	Dr. Yen-Ching Chang
	13:55~14:40(45")	Dr. Jun, In-sung	Why we have to go to a sinus lifting with simultaneous implantation rather than delayed implantation	Dr. Zhou Lei
	14:40~14:55(15")	<b>Q &amp; A</b>		
<b>Break</b>	14:55~15:15(20")	<b>Break</b>		
<b>Session 3</b>	15:15~16:00(45")	Dr. Christopher Sim	An Assessment of the Clinical Performance of GSII Implant System	Dr. Ajit Shetty
	16:05~16:50(45")	Dr. Sung, Moo-gyung	Comprehensive approach in poor bone quality	Dr. Albert Lee
	16:55~17:30(35")	Dr. Cho, Yong-seok	Advantages of OSSTEM GS Implant System	Dr. Yen-Ching Chang
	17:30~18:00(30")	<b>Q &amp; A</b>		
<b>Closing</b>	18:00	<b>Closing</b>		



**Figs. 26, 27**\_ Histological sections from G2, magnified 10 and 40x (HE).

stalled as planned. The cement was easy to locate on all post-operative radiographs, especially in the sinus, and the healing process could be stated and followed through all follow-up times. The histological analysis of the sections allowed good interpretation of the results. The drilling during implant placement surgery found an osseous tissue of firm consistency, with good resistance to drilling with rotary instruments. This allowed implant installation with primary stability. Histologically, new bone formation could be clearly shown and explains the very favorable clinical conditions encountered upon placement of the implants. The sections showed the presence of viable bone tissue in the augmented areas (Figs. 22–30). Inside the trabeculae, signs of viable cells were found within the cellular spaces (Figs. 23 and 29).

Another interesting finding was the presence of incremental growth lines clearly seen in the bone trabeculae (Figs. 23 and 24). This was the evidence suggesting that an active bone remodeling process is taking place (Figs. 23–26). We also note the discrete to moderate presence of inflammatory mononuclear infiltrate in the medullary spaces (Figs. 22–25), a characteristic frequently encountered in medullary spaces, probably associated with the ongoing local bone healing process. At small magnifications, a larger bone density was observed in the augmented areas compared to the native bone areas (Figs. 17, 21 and 26).<sup>22, 23</sup> All these findings lead us to conclude that the processes of bone neof ormation and remodeling were ongoing in the grafted areas. The good osteoconductive properties of the injectable cement allow deposition of newly

formed bone of good quality to support implants. We find three very valuable reasons for using the injectable PD VitalOs Cement: First, the time saved by not having to get autologous bone from a donor site, and the ease of handling that shortens the surgical procedures. Second, its excellent osteoconductive properties allowing deposition of newly formed bone at the bone-cement interface, and finally, the adequately slow resorption rate that avoids the loss of volume of the injected cement. These features are great advantages comparing to autologous bone. The spongy particulated autologous bone, known to be quickly remodeled, leads to considerable early loss of volume of the augmented areas.<sup>16, 17</sup>

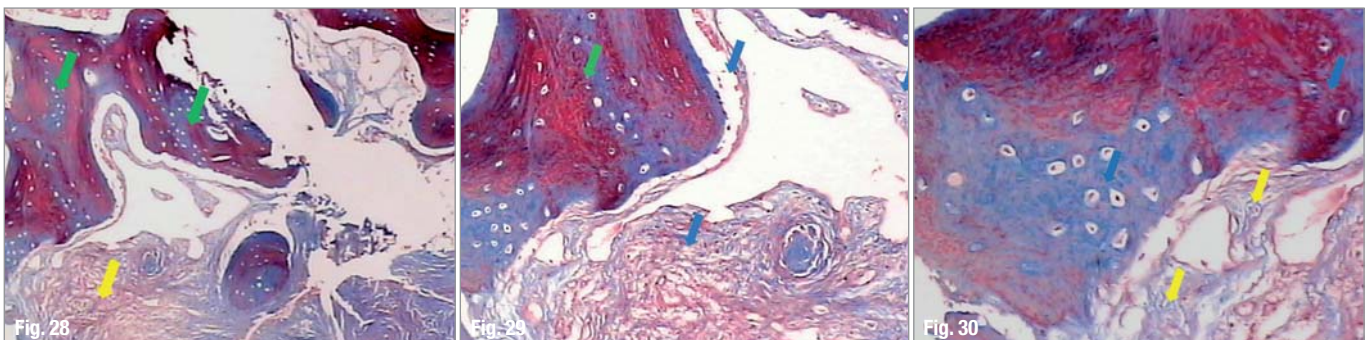
The three-dimensional microstructure of the material (porosity, surface area of particles, cohesion of particles and surface roughness) is certainly a key factor to the successful use of the product in vivo. The other key factor to success is the surgical procedure itself, which must follow a precise protocol, including important steps like careful drying of the site to ensure primary stability of the cement.

### Conclusions

PD VitalOs Cement was used very efficiently as a bone grafting material. The histological sections of the areas augmented with the cement have shown the ability of the product to favour predictably osteogenesis, resulting in a firm osseous tissue once the cement is completely resorbed. In addition to these biological features, the product proved to be very easy to handle, reducing the trans-operative time and the trauma to the patient.

<b>_contact</b>	<b>implants</b>
<p><b>Dr Sérgio Alexandre Gehrke</b>                  BioFace Institut                  Dr. Bozano, 571                  Santa Maria – RS, Brazil                  E-mail:                  Sergio.gehrke@terra.com.br</p>	

**Figs. 28–30**\_ Histological section from G2, magnified 4, 10 and 40x (TM).



# The leading light

Surgical instruments with self-generating LED



Operate by daylight quality light – and with a self-contained light source. The new W&H surgical instruments with LED produce a pure white light autonomously and are therefore compatible with all motors with ISO coupling. This is through the integrated generator, which supplies energy to the LEDs in the SI-11 LED G and WI-75 LED G handpieces. You will be amazed by how much you can see at a brightness of up to 31,000 Lux.

For more information please ask your local dental dealer.

[wh.com](http://wh.com)



# Skin reaction around **auricular implant abutment** using different attachment mechanisms

author\_ Walid Sadig, Ziad Salameh, Saudi Arabia

## \_Introduction

With the advent of osseointegration in dental rehabilitation and recent advances in surgical and laboratory techniques, it has been possible to transfer and extend the osseointegration principle to facial rehabilitation.<sup>1</sup> Retention, stability and aesthetics have been significantly improved with the use of endosseous implants, contributing to natural appearing prostheses.

Facial prostheses in the past have been retained primarily by skin adhesives,<sup>1,2</sup> to improve retention and stability, such techniques had several disadvantages including damage to the customized surface of the prosthesis when removing glue from the skin surface; contact dermatitis as a result of long-time use and progressive discoloration and breakdown of the elastomeric maxillofacial restorative material.<sup>2</sup> Major advantages of implant-retained facial replacement, include ease of placement, predictable retention, improved esthetics, and increased life span of the prosthesis.<sup>3</sup> Several studies reported high functioning success rate for auricular prostheses,<sup>4,5,6</sup> however this treatment modality is not without complications. Adverse skin reactions are the most common well documented complication with craniofacial osseointegration.<sup>7,8</sup> 48 per cent of patients who had implant retained auricular prostheses developed soft tissue infections at some stage during the follow-up period.

Craniofacial implants maybe connected to the prosthesis with attachment devices of various designs and retention levels. Magnet or bar-and-clip retention are the two primary forms of retention used separately or combined in the auricular region. The use of single standing magnet attachments clinically seemingly reduced the number of inflammatory skin reactions.<sup>10</sup>

A photoelastic study of the auricular-temporal region of a human skull, found that the Locator attachment correlated with higher retention values as well as with higher peri-implant stress compared to the Hader bar-and-clip attachment design.<sup>11</sup> Non-submerged single stage implants are well established treatment modality in oral implantology because of the many advantages it include.<sup>12</sup> It seems such implant design is not utilized extraorally to retain a facial replacement. The purpose of this clinical report was to describe the placement of non-submerged single stage implants to retain auricular prostheses. Management of adverse skin reaction was evaluated also through this report by utilizing three types of attachment mechanisms.

## \_Patient report

A 43-year-old woman who sustained traumatic loss of the scalp and left ear when she was 35-year-old in a motor vehicle accident, presented to our clinic. The affected area was grafted with a

**Fig. 1** \_ Two non submerged implants at the time of the surgery.

**Fig. 2** \_ Two implants were used 10 mm apart and at 12 mm from the external auditory canal.

**Fig. 3** \_ A 5 mm healing cover was then placed into the internal thread of the implant fixture.

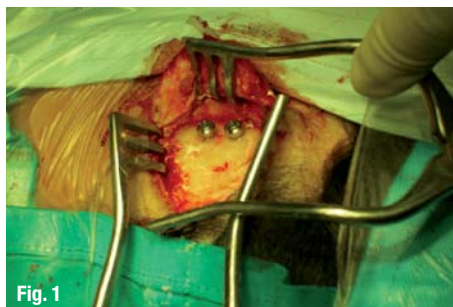

Fig. 1

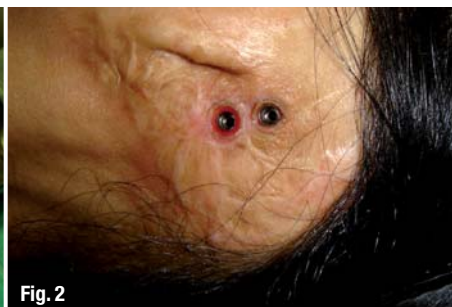

Fig. 2

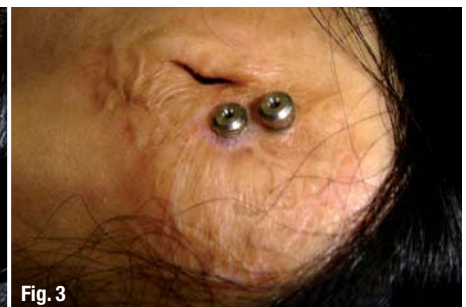

Fig. 3

split thickness graft harvested from the elna. The patient always refused the option of adhesive-retained auricular prostheses, but she accepted the option of implant-retained auricular prostheses after being aware of its benefits.

Treatment planning included consultations with otolaryngologist, plastic surgeons and radiologist. To avoid perforation of the inner cortical margin of the neurocranium, standard radiographic images were combined with a CT scan that allows preoperative determination of temporal bone thickness and proper positioning of the implants in relation to prosthesis location.<sup>8,13</sup>

Two implants were used 10 mm apart and at 12 mm from the external auditory canal, and were sufficient for adequate retention 14 (Fig. 1 and Fig. 2). A surgical template was used to obtain accurate implant placement.

At the surgery day the planned implant sites were marked with surgical ink. An incision was made and the bone surface exposed by elevating the skin and periosteum. Using a depth limiting drill the predetermined depth of 5 mm was prepared using twist drills up to size 3.5 mm diameter. The osteotomy sites were then threaded with a titanium screw tap. Using a ratchet, two tapered implant fixtures of 4.1 mm diameter and 5 mm in length with 1.8 mm non submerged neck (Industrie Biomediche E Farmaceutiche®, di Muollo Ferdinando, Italy) were inserted into the threaded holes. A 5 mm healing cover was then placed into the internal thread of the implant fixture (Fig. 3).

Thinning of the subcutaneous tissue was performed to minimize the thickness of the skin graft also to prevent free skin movement around the implant healing abutments. The skin flap was then punched over the implant head using a 4 mm diameter disposable punch before replacement and suturing so a multilayered closure of the wound is affected. Subsequently a pressure bandage has been applied for the first four days to prevent a postoperative hematoma. Postoperative radiographic examinations were performed to control the implant position and sutures were removed after ten days.

The implant fixtures were allowed to integrate with the bone for two months. No intra operative

or post operative complication was encountered and since a non submerged implant was used, a second surgery was not needed.

During the healing period the patient was instructed to maintain cleanliness around the healing abutments by asking a family member to remove any dry tissue crust with small brush and whip the area with moistened towel soaked in diluted iodine solution. Care was taken to inspect the abutments and surrounding tissue for cleanliness and evidence of any infection. Crusting and epithelial debris around the base of the abutment was removed with a probe.

#### Fabrication of the superstructure

After the healing period, the fabrication of the auricular prostheses started by taking a fixture level impression to fabricate a Hader bar splint (Fig. 4). Adjustments were made to ensure passivity of fit, so as not to place any undue stress on the implants. Rider clips are then positioned onto the bar to ensure adequate retention. The undercuts of the bar were blocked out using wax. Self-curing acrylic resin was then poured using standard orthodontic techniques to cover the bar clips, and area of required base. The prosthesis was then sculpted (Fig. 5) upon the base plate acrylic resin and model and then tried onto the patient by following standard evaluation guidelines.

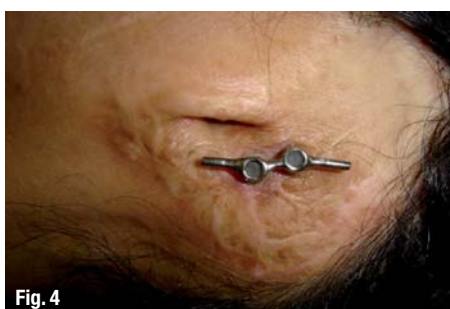The advantage of the implants is that final sculpting can be performed on the patient. The bar splint and prosthesis were placed back on the model and invested as usual.

After wax elimination and in order to enhance bonding with the silicon, the outer surface of the base was perforated with small round bur before cleaning with acetone and a layer of primer is applied and allowed to dry thoroughly. Normal procedure of color matching and curing was then performed. The silicon was allowed to cure under the bench press for two hours. Upon completion of the prosthesis it was tried on the patient and clip adjustments performed (Fig. 6). The patient was then instructed on how to place and remove the prosthesis. After two weeks of wearing the bar retained prostheses, the patient complained from pain and tenderness; clinical examination revealed heavy

**Fig. 4** A Hader bar joining the implant fixtures.

**Fig. 5** Auricle prostheses sculpted before patient's trial.

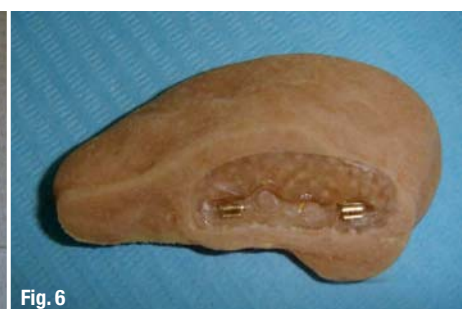**Fig. 6** Prostheses finished and ready to be placed.



**Fig. 4**



**Fig. 5**



**Fig. 6**

sebaceous crusting with evidence of exudates oozing from the peri-implant epithelial tissue surrounding the head of the lower fixture. When the bar was removed no granulation tissue was noted, the implants were immobile, and the skin showed slight mobility with raised contour of 5 mm thickness. The upper fixture was not affected by the infection and the skin thickness was 3 mm as it was before. Skin culture grew *Staphylococcus aureus*  $\beta$ -hemolytic *Streptococcus* which is considered not normal skin flora. To manage the infection the area around the healing abutment was wrapped with strips of gauze, saturated with 1 per cent triamcinolone and 0.5 per cent bacitracin (Aureomycin, Wyeth, Madison, NJ, USA). When no improvement was noticed within 72 hours, the patient was given Ciprofloxacin 250 mg two tablets twice daily for ten days (Ciprobay 250, Bayer AG, Germany). The bactericidal effect of the systemic antibiotic used with this patient was very successful. After the infection has resolved, the bar retained prostheses was redelivered to the patient. Unfortunately after one month of wearing the ear prosthesis, patient reported reinfection of the same area.

Since no adverse skin reaction was noticed whenever a healing abutment of 5 mm in height was used, a decision was made to replace the Hader bar connector by a magnetic attachment system with individual keeper over each implant. Rigid flat type magnetic keeper of 4 mm in height was secured to the implants Magfit™ IP IFN 40 (Aichi Steel Co. Ltd., Nagoya, Japan).

Since the height of the keeper of the magnetic attachment was almost at the skin level, one week later tissue over growth by secondary epithelialization was noted over the lower magnetic keeper.

A thickness reduction of the skin surrounding the emerging magnet keeper was attempted at chair side under local anesthetic solution using a diode laser beam. Ten days later skin re-growth again over the lower keeper and the patient complained from poor retention of the prosthesis when compared to the Hader bar connector. Consequent to this and because of the claimed health hazards of using magnets in the head neck area, a decision was made to use a Locator attach-

ment. The locators connector has a skirt around the denture components that easily locates the permanent mating component on the implant (Fig. 7 and Fig. 8). The self-aligning feature of the locator aids the patient in a similar manner as a guide plane for the removable overdenture (Fig. 9). The patient can easy align and seat the prosthesis. The locators have extra advantages in complex cases as they can compensate for severe angle misalignment and a divergence up to 40 degrees between the implant and the connector system.<sup>12</sup>

## Discussion

Craniofacial osseointegration care is a stepwise, protocol-driven process involving multiple disciplines. The interdisciplinary consultation is the starting point for the process of treatment. The prosthodontist is responsible for the diagnosis and treatment planning, recording of tissue surfaces as they relate to implants, design of retention, design and assessment of fit of superstructures, and long-term maintenance. Hader bar is the most common bar used, offering the advantages of a better retention and resistance against horizontal force<sup>16</sup> while disadvantages are that it needs more space to place and is easier to break down. Due to the location of the site of the ear prosthesis most clinicians prefer to use a combination of a bar splint utilizing rider clip and magnetic retention.<sup>17</sup> This is to ensure absolute margin integrity during soft tissue movement caused by the proximity of the temporomandibular joint.

Clinical experience suggests that magnet attachment is indicated where low dislodging forces are anticipated, when the patient has poor dexterity, or where a special need for independent abutments exists.<sup>17</sup> In addition, magnets facilitate improved access around the abutments for the cleaning and easier concealment of the retention system within the normal contour of the prostheses.<sup>18</sup> The locator connector poses similar advantages as the magnets with additional features such as higher retention, different retention levels, and available in different cuff length.

The main advantages of the non-submerged one stage implant is the fact that the location of

Fig. 7\_ Locators attachment on the implants.

Fig. 8\_ Locators attachment in the fitting surface of the prosthesis.

Fig. 9\_ The final prosthesis.

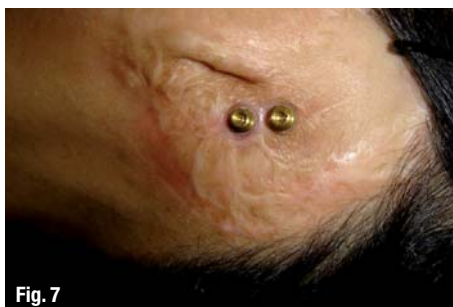

Fig. 7

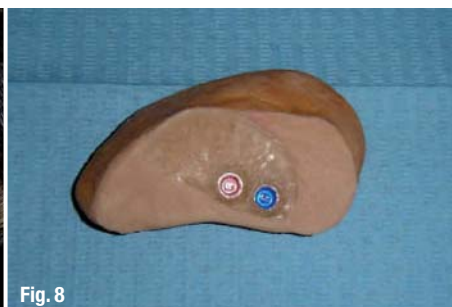

Fig. 8

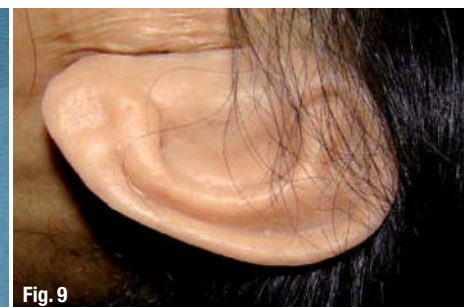

Fig. 9

the connection between the implant and the superstructure is typically above the bone level by 2 mm with no microgap which allow biological collar of connective tissue interface, therefore better peri-implant seal can be maintained.<sup>12</sup> Whereas with the conventional flanged extra oral implant in swine showed that junctional epithelium diminishes to a one-cell-thick layer as it approaches the flange of the titanium implant, this mono layer of cell create the biological barrier against bacterial contamination.<sup>19</sup>

#### Possible reasons for infection and infection control

Loosening of retaining screws of the bar may occur for several reasons; misfit of the bar superstructure to the implant will lead to screw loosening hence, greater movement of the bar abutment resulting in shear forces that disrupt the epithelial abutment interface. This disruption then serves as a pathway by which bacteria can cause infection. As there is essentially no completely passive (perfect) fit of the bar superstructure 20, independent abutments attachment system should be the first option with craniofacial implants, especially when increased thickness of the peri-implant abutment tissues is encountered. Retrospective analysis of adverse soft tissue reactions showed that peri-implant soft tissue problems tended to occur during the first two years after implant exposure.<sup>20</sup> The skin is not intended to have a persistent interruption of its integrity as a result of the presence of the penetrating alloplastic material, so time is needed for peri-abutment skin and the local immune system to adapt and to cope with this unnatural condition.

In the initial stages of endosseous-retained prosthetic rehabilitation, patients need time to appreciate the new commitments required for the success of such treatment. In the first year after implants placement, clinical and radiographic examinations were conducted monthly and after prosthetic reconstruction it was performed every six months.

The assessed clinical outcome parameters include health of the peri-implant tissue, implant hygiene, and mobility of implants.

#### Conclusion

In contrast with a conventional craniofacial prosthesis, an implant-retained auricular prosthesis often is not experienced as a prominent foreign object and can improve the quality of life. Utilization of non-submerged one stage implant in the craniofacial region is considered viable option as it is intraorally. Although adequate patient hygiene is a must, this clinical report indicates that type and fit of the attachment, to create an intimate seal around the peri-implant epithelial tissue is crucial to maintaining healthy tissues in the peri-implant abutment site.

*The literature list can be requested from the editorial office.*

#### contact

#### implants

##### Prof. Dr Walid Sadig

Department of Prosthetic Dental Sciences  
College of Dentistry, King Saud University  
60169 Riyadh 11545, Saudi Arabia  
Phone: +966-1-4677325  
Fax: +966-1-4678548  
E-mail: walidsadig@yahoo.com

# sticky granules

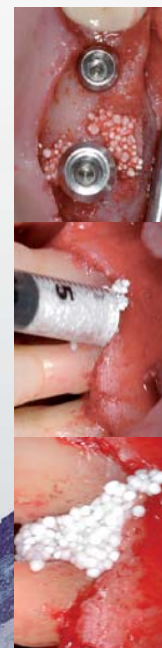
# bionic

**easy-graft™** 

injectable  
in situ hardening  
100% synthetic bonegraft

The  $\beta$ -TCP composite for all indications

easy-graft™



„the swiss rock...“

**DS**  
**DENTAL**

Degradable Solutions AG  
Wagistrasse 23 · CH-8952 Schlieren  
phone: +41 (0)43 433 62 60  
fax: +41 (0)43 433 62 61  
dental@degradable.ch · www.degradable.ch

# First International Dental Symposium Cairo, 15–17 January 2009

author\_ Rolf Vollmer, Germany

**Under the Patronage** of His Excellency Lt. General Ahmed Shafik, Minister of Civil Aviation, and Prof. Dr Hosam Kamel, Cairo University President, the Faculty of Oral and Dental Medicine (Cairo University) together with EgyptAir Hospital in cooperation with the Continuing Dental Education Center was honored to present their First International Dental Symposium. The Dean of the Faculty of Oral and Dental Medicine, Prof. Dr Ahmed Noor Habib, Chairman of Honor Prof. Dr Khaled Abo El Fadl, General Secretary Prof. Dr Amr Abdel Azim, and Executive Secretary Dr Ahmed Taha Mokhtar, prepared an excellent organized meeting with international standards. International speakers coming from Saudi Arabia, USA, Jordan, Lebanon, Germany, UAE and Libya as well as local (Egypt) speakers presented the state-of-the-art in dentistry. The theme of the symposium was the role of different dental subspecialties in aesthetic dentistry to achieve



a beautiful smile. The different topics of the lectures gave an overview how to achieve this serious goal.

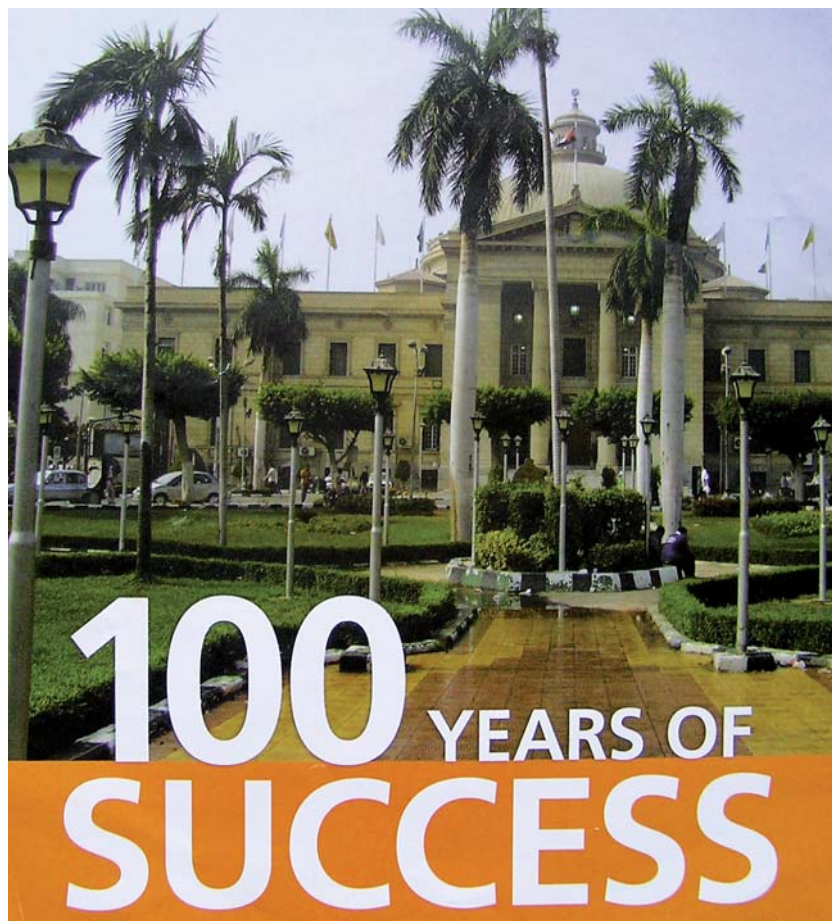
Lectures about one important dental subspecialty the field of implant dentistry covered a big part of the meeting emphasizing the importance of teamwork between the surgeon and the prosthodontist.

DGZI (German Association of Dental Implantology) was represented by distinguished speakers like Prof. Dr Werner Götz (University of Bonn, Department of Oral Biology), Dr Rolf Vollmer and Dr Mazen Tamimi as DGZI representatives.

Prof. Götz reported about demographic changes which will lead to an increasing number of older patients in the next 20 years also in the Middle East. These patients are scheduled to be an important group of dental customers for the future. An optimal dental treatment including dental implantology should be provided for the so called "young old people" taking into account for the therapy the pathological and orofacial changes.

Dr Stephen Wheeler USA, Board member of DGZI affiliated Academy of Osseointegration—AO, showed catastrophic failure and loading protocols and agreed with statements of Dr Vollmer concerning caution in immediate loading especially in cases of poor bone quality. Dr M. Tamimi discussed different treatment options in the severely atrophied mandible.

Prof. Dr Nabil Barakat, Lebanon, demonstrated the interdisciplinary benefits of orthodontics and osseointegration. Dr Nadim Abu Jawdeh, Lebanon, was engaged with "The Smile Dynamics in Esthetic Dentistry". Prof. Dr Ahmed Noor Habib, Dean of the Faculty of Oral and Dental Medicine, informed about precise impression techniques and final restoration. Prof. Dr Abdel Salam Askary, Text book author, gave the au-

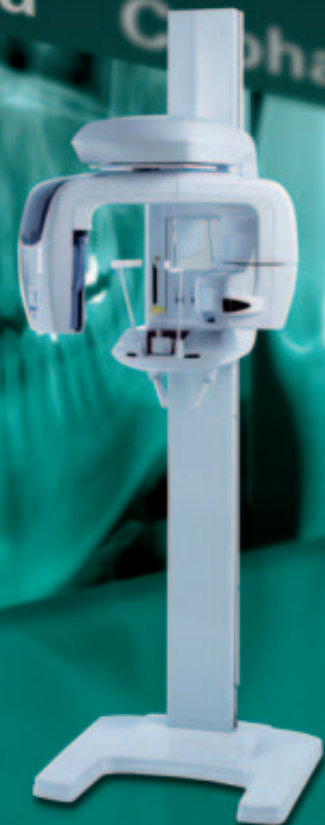
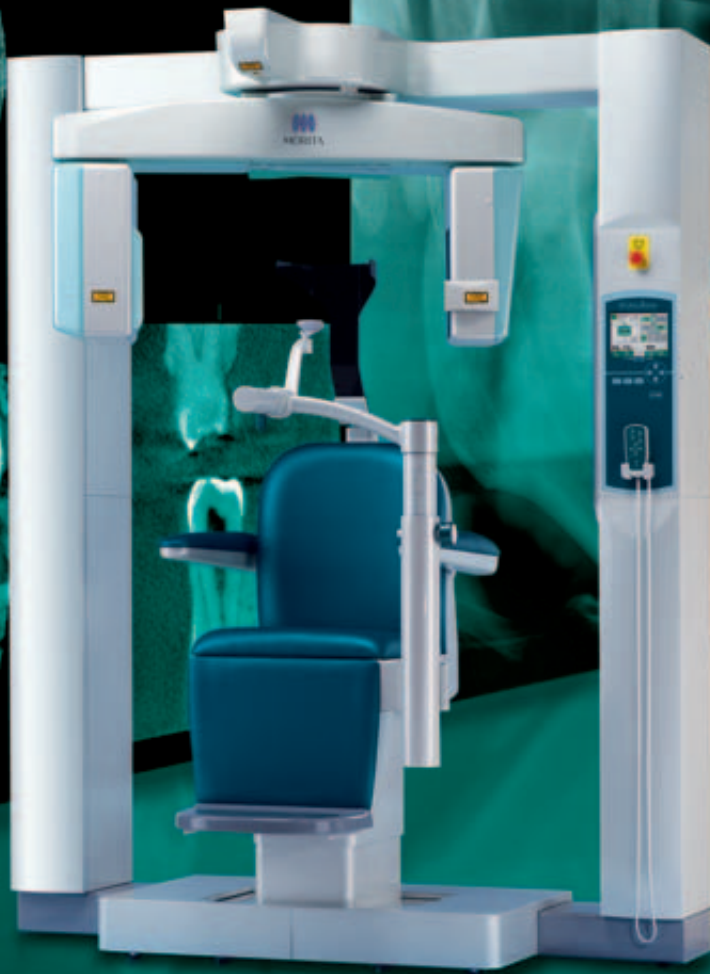
3D

Panorama

Veraviewepocs 2D/3D

3D Accutomo 170



Now: the NEW  
Veraviewepocs 3De  
for the entry into  
digital 3D X-rays


## The Number One in Every Class

 J.MORITA MFG.CORP.

Whether your interest is digital panoramic, cephalometric or 3D imaging – at J. Morita you always get the best device for the most precise diagnoses. As a pioneer in volume tomography we are familiar with the high requirements of diagnosticians. Our wide variety of devices and choice of combinations provide you with the sharpest imaging of details down to 80 µm.

From the first step, upgradable 2D devices, to the basic version Veraviewepocs 3De and the high-quality X-Ray CT unit 3D Accutomo 170, one thing always remains unchanged: You obtain the highest imaging quality from the lowest effective radiation dose and the shortest scan times. Nothing is more elementary than the correct diagnosis.


Trust the number one in the class! We would be happy to advise you. Phone +49 (6074) 836-0 or visit our website at [www.jmoritaeurope.com](http://www.jmoritaeurope.com)



**Volume Size**  
40 mm x 40 mm  
60 mm x 60 mm  
80 mm x 80 mm  
100 mm x 100 mm  
170 mm x 120 mm

Thinking ahead. Focused on life.

  
**MORITA**



dience detailed information about the indications for flapless surgery. Diagnosis and treatment to achieve the aesthetic smile was the topic of Prof. Rami Samir Guiha. The impressive lecture demonstrated the relationship between three primary components: the teeth, the lip and the gingival tissues.

The Director of Continuing Education, Prof. Dr Amr Abdel Azim, and the Dean of the Faculty of Oral and Dental Medicine, Cairo University, Prof. Dr Ahmed Noor Habib, talked about their mission for an excellent Post Graduate Dental Practice Training at Cairo University under the motto: Learn more, improve your skills, and be a step ahead!

The goal of the Continuing Dental Education and Training Centre (CDEC) is to provide general dentists with an opportunity to learn new concepts in the fast changing world of dentistry. The mission in continuing dental education is to engage in those educational activities that facilitate the maintenance and upgrading of the skills, knowledge, technology and competence of the practicing dentist or dental professional related to optimal dental health care delivery.

- \_ Assess the learning needs of general dentists.
- \_ Improve the knowledge and clinical skills of dental professionals.
- \_ Introduce dental professional to new ideas and techniques as they become available to enhance the

care delivered by the dental professional by promoting excellence and consistency in education.

\_ Design continuing dental education activities using modern educational methods, technology and media to accomplish objectives of the educational activity.

\_ Periodically assess the continuing education needs of general dentists through surveys to develop and deliver the courses that are based on the established objectives and identified needs.

\_ Plan and produce continuing dental education activities that are cost-effective.

\_ Collaboration with other organizations like German Association of Dental Implantology (DGZI) to increase the availability and accessibility of continuing dental education to general dentists.

\_ Operate the continuing dental education activities within an organizational framework to optimize administrative effectiveness and develop a comprehensive marketing and programming strategy.

During the meeting the DGZI representatives expressed their admiration for the well organized meeting and their hope for future mutual joint meetings and activities together with Cairo University, which just celebrated its centennial and 75 years anniversary of the Dental Faculty.



PIEZON-MASTER-SURGERY.COM

**EMS**<sup>+</sup>  
ELECTRO MEDICAL SYSTEMS

PIEZON MASTER SURGERY® –  
DIE WELT DER ZAHN-,  
MUND- UND KIEFERCHIRURGIE  
FEIERT EINEN NEUEN HELDEN

**REVOLUTION  
IM OP**

**INNOVATIV** in Technologie, einfache Bedienung, alle Applikationen, exklusive Instrumente, beste Resultate, grosse Erfahrung – die Original Methode Piezon jetzt auch in der Parodontalchirurgie, der Implantologie, der Oral- und Maxilla-chirurgie.

Piezon Master  
Surgery



**EINZIGARTIG** in der Welt der Chirurgie – das 3-Touch-Panel zur intuitiven Bedienung.

**EXKLUSIV** abgestimmt auf das neue piezokeramische Chirurgiehandstück – die neuen Swiss Instruments Surgery.

**REVOLUTIONÄR** bis ins Detail – wer den Piezon Master Surgery erlebt hat, fragt: Warum nicht gleich so?



Mehr Information  
unter [www.piezon-master-surgery.com](http://www.piezon-master-surgery.com)



# 5<sup>th</sup> Arab-German Implantology Meeting of DGZI and 1<sup>st</sup> Joint Syrian-German Implantology Meeting



## The Syrian Dental Association (established in 1975)

- \_ Dr Safah Al Buni is the president of the Syrian Dental Association.
- \_ 16,000 dentists are the members of the Syrian Dental Association.
- \_ 14,000 dentists are practicing dentistry in Syria in their own private clinics.
- \_ 2,200 dentists are the specialists of all of dentistry fields in Syria.
- \_ 9 scientific societies established for all the dentistry specialties.
- \_ 4 governmental Dental colleges for dentistry in Syria and 4 Private Dental colleges for dentistry in Syria.

Implantology is growing up in Syria; as many of the Syrian dentists are joining the Implantology courses and educational programs particularly the German Board of Oral Implantology 'GBOI' in all over the world; that's why we are expecting a big number of attendance for our congress.

## Languages

Arabic is the official and most widely spoken language. Kurdish is widely spoken in the Kurdish regions of Syria. Many educated Syrians also speak English and French. Armenian and Turkmen are spoken among the Armenian and Turkmen minorities. Aramaic, the lingua franca of the region before the advent of Islam and Arabic, is spoken among certain ethnic groups.

The unique location between, Asia, Africa and Europe gave the Syrian lands a strategic importance, where as being in at the crossroads between the Caspian Sea, the Black Sea, the Indian Ocean, and the Nile made it one of the most important trade and caravan routes and it became a melting-pot of ideas, beliefs and talents.

Syria is often described as the largest small country in the world because of its wealth of ancient civilizations. Modern man is indebted to this land for much of his thought and learning. Therefore it is properly said that every cultured man belongs to two nations—his own and Syria.

Come and join our conference with an outstanding program of speakers.

Dr Mazen Tamimi  
President of DGZI—International Section

## Dear colleagues,

after the success of the 4<sup>th</sup> Arab-German Implantology Meeting during the last 4 years in Dubai, I would like to invite you to come to Damascus, Syria, from 8–10 April 2009. The meeting will take place in the Ebla Cham Palace Hotel and it will be the 1<sup>st</sup> Joint Syrian-German Implantology Meeting and the 5<sup>th</sup> Arab-German Implantology Meeting of DGZI.

## Syria

Syria officially the Syrian Arab Republic, is an Arab country in Southwest Asia, bordering Lebanon and the Mediterranean Sea to the west, Jordan to the south, Iraq to the east, and Turkey to the north. The modern state of Syria was formerly a French mandate and attained independence in 1946, but can trace its roots to the Eblan civilization in the third millennium BC. Its capital city, Damascus, was the seat of the Umayyad Empire and a provincial capital of the Mamluk Empire. Syria gained independence in April 1946 officially a Republic.

## Etymology

The name Syria derives from the ancient Greek name for Syrians, *Syrioi*, which the Greeks applied without distinction to various Assyrian people. Modern scholarship confirms the Greek word traces back to the cognate, *Assyria*, ultimately derived from the Akkadian *Aššur*. You will be here history's voice can be heard, where the soil holds the imprints of the world's oldest civilizations, some dating back the fourth millennium BC. The names of sites evoke the story of mankind at its beginnings: Mari, Ebla, Ugarit, Amrit, Apamea, Doura-Europos, Palmyra, Bosra, Damascus, Aleppo, Hama, Latakia.

## contact implants

### **Dr Mazen Tamimi**

President of DGZI-  
International Section

Phone:

+962-6-5533160 or

+962-6-5513770

Mobile:

+962-07-95513313

Fax:

+962-6-5532515

E-mail: drtamimi@

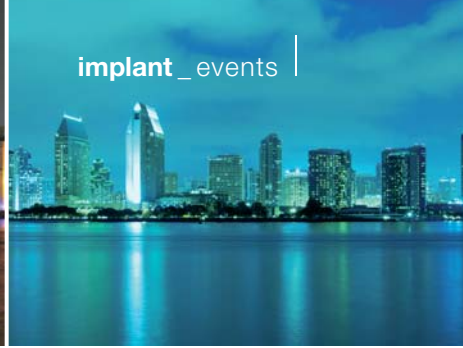dgzi-international.com

Web: www.dgzi-

international.com

www.drtamimi.com

Amman – Jordan



# Selected Events 2009

## MARCH 2009

March 10–12

*UAE International Dental Conference  
& Arab Dental Exhibitions*

Dubai, UAE

E-mail: [office@dgzi-info.de](mailto:office@dgzi-info.de)

March 24–28

*33<sup>rd</sup> IDS – International Dental Show*

Cologne, Germany

Web: [www.aeedc.com](http://www.aeedc.com)

Web: [www.koelnmesse.de](http://www.koelnmesse.de)

## APRIL 2009

April 8–10

*5<sup>th</sup> Arab–German Implantology Meeting of DGZI  
& 1<sup>st</sup> Joint Syrian–German Implantology Meeting*

Damascus, Syria

E-mail: [alkubaissy@hotmail.com](mailto:alkubaissy@hotmail.com) (for Syria)

E-mail: [drtamimi@dgzi-international.com](mailto:drtamimi@dgzi-international.com)  
(for other countries)

Web: [www.dgzi-international.com](http://www.dgzi-international.com)

Web: [www.drtamimi.com](http://www.drtamimi.com)

## MAY 2009

May 7–11

*31<sup>st</sup> APDC—Asia Pacific Dental Congress*

Hong Kong, China

Web: [www.apdc2009.org](http://www.apdc2009.org)

## JUNE 2009

June 25–27

*8<sup>th</sup> SimPlant Academy World Conference*

Monterey, Canada

Web: [www.simplantacademy.org](http://www.simplantacademy.org)

## SEPTEMBER 2009

September 2–5

*FDI Singapore*

Singapore

Web: [www.fdiworlddental.org](http://www.fdiworlddental.org)

## OCTOBER 2009

October 9–10

*39<sup>th</sup> International Congress of DGZI*

Munich, Germany

Phone: +49-3 41/4 84 74-3 08

Fax: +49-3 41/4 84 74-2 90

Web: [www.event-dgzi.de](http://www.event-dgzi.de)

## NOVEMBER 2009

November 4–7

*AOS 7<sup>th</sup> Biennial Conference*

Queensland, Australia

Phone: +617 3858 55 25

Web: [www.aosconference.com.au](http://www.aosconference.com.au)

November 27  
– December 2

*GNYDM Greater New York Dental Meeting*

New York, USA

Web: [www.gnydm.com](http://www.gnydm.com)



## DGZI Vice President Dr Hille newly elected speaker of the Consensus Conference

DGZI Vice President Dr Roland Hille, was elected as the new speaker at the Consensus Conference Implantology, during the December 3, 2008 meeting. For this reason, for the first time, DGZI took over the leadership of a board, which is supported by most of the professional and specialist associations in implantology. He takes over the office from Dr Dr Wolfgang Jakobs, Speicher, Germany, who distinguishedly lead the Consensus Conference Implantology during his in-

cumbency. The members of the Consensus Conference, in existence for approximately 20 years, are: DGZI, DGI, BDO, DGMKG and BDZI/EDI. The Consensus Conference is a meeting place for opinion-forming and quality management in implantology. In the past, German implantology standards were sustainably influenced thanks to consistent certification guidelines that mainly focus on implantology, the determination of the types of indication, and consistent referee guidelines.

## Unanimous approval of the Managing Board and the future DGZI strategy at DGZI General Meeting!

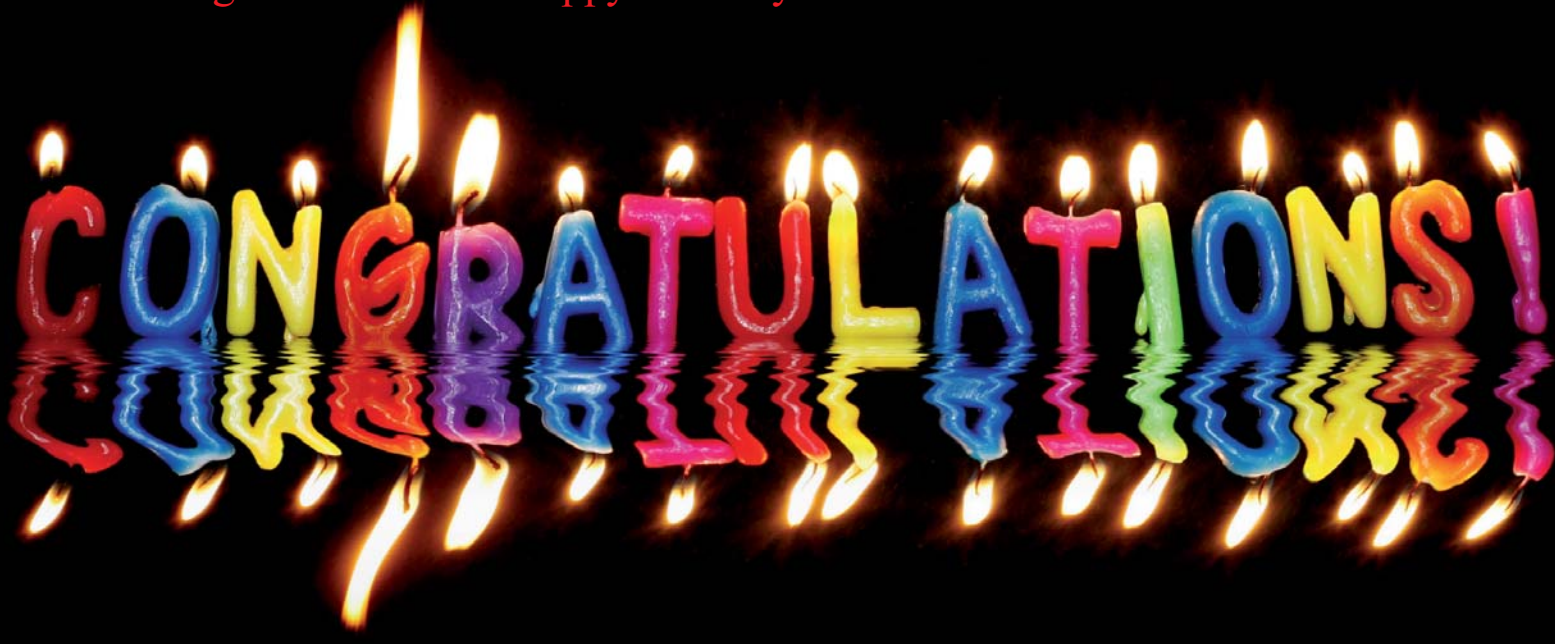

On the occasion of the annual DGZI General Meeting on November 15, 2008, at the Radisson Hotel in Cologne, the confidence in the Managing Board was reconfirmed unanimously. The members present showed great interest in each board member's report on work concerning the association. The main emphasis of our last year's work was placed especially on the success of the complex education and training programs in dental implantology, the active cooperation within the Implantology Consensus Conference, information for patients and corresponding public information campaigns. In his report, DGZI's President Dr Friedhelm Heinemann pointed out the extraordinary successes of DGZI during the reference period and the excellent cooperation among the members of the board. The division of work and collective action were and still are at the fore of DGZI management work. According to Dr Heinemann this is the reason why one should vote again for a continuous cooperation of all Managing Board members. This would guarantee continuity and quality in the management of the oldest scientific association for dental implantology in Europe. Special attention is directed to the strategy for the education and training of colleagues working in the field of dental implantology. DGZI is the first association that presents the newly configured "DGZI Curriculum for Implantology" featuring numerous innovations. For the first time dentists have the chance to complete single specialized modules in addition to the already estab-

lished topics in order to achieve an even more profound specialization in dental implantology. Full consent was also given to last year's budgeting and the future budget planning. DGZI treasurer Dr Rolf Vollmer reported on the excellent financial situation. Thus, DGZI is in the position to meet its statutory purposes fully. The second Vice President Dr Roland Hille gave an account about the work within the Consensus Conference and public relations. DGZI still plays an important role within the renowned associations that take an active part in the Consensus Conference. Especially in politically uncertain times, members expect an active exertion of influence by the major implantology associations, and information about the future orientation for dental offices. Extensive public relations with reports and interviews in the media, and a successful radio campaign were the cornerstones for last year's information for patients. According to Dr Hille this way should be continued consistently, since public relations belong to the main DGZI tasks. On time for the turn of the year, DGZI will provide, amongst other things, an "Patients Implantology Guidebook" for all members. This guideline, which will be available for patients at the dentist's waiting room, will inform thoroughly about dental implantology. The DGZI General Assembly unanimously approved the Managing Board members Dr Rolf Vollmer/Wissen as 1<sup>st</sup> Vice President and Treasurer, Dr Roland Hille/Viersen as 2<sup>nd</sup> Vice President, and as the Head of the Division for Organization Dr Rainer Valentin/Cologne.

Dr Georg Bach/Freiburg i. Breisgau, Dr Dr Wolfgang Hörster/Cologne and Dr Detlef Bruhn/Berlin were voted assessors. In his first statement DGZI President Dr Heinemann appreciated this clear vote and is looking forward to continuing this successful cooperation with his re-elected Managing Board colleagues and all members taking an active part in DGZI.

**Congratulations and Happy Birthday** to all DGZI-members around the world



## JANUARY 2009

### 70<sup>th</sup> Birthday

Dr Reinhard Keller (26.01.)

### 65<sup>th</sup> Birthday

Dr Günter Kudernatsch (01.01.)  
Dr Carsten Taaks (03.01.)

### 60<sup>th</sup> Birthday

Dr Peter Urbanowicz (01.01.)  
Dr Novel Urrutia (04.01.)

Dr Günter Leyk, M.Sc. (21.01.)  
Dr Gerd Laufenberg (28.01.)

### 55<sup>th</sup> Birthday

ZÄ Steffi Vogler (01.01.)  
Dr Christopher Auty (21.01.)

### 50<sup>th</sup> Birthday

Annegret Litwin (08.01.)  
Anke Zeidler (12.01.)

Dr Thomas Jäger (16.01.)  
Dr Uwe Engelsmann (18.01.)  
Dr Virginia Hönig (19.01.)  
Dr Rolf Mäder (29.01.)  
Dr Günther Schlimbach (29.01.)

### 45<sup>th</sup> Birthday

Dr Wolf-Christian Hampe (01.01.)  
Dr Totanje Moneir (12.01.)  
Dr Abd El Salam El Askary (14.01.)

Christiane Schaper (16.01.)  
Dr Hans Schröder, M.Sc. (21.01.)  
Dr Michael Hintz (24.01.)

### 40<sup>th</sup> Birthday

ZA Peter Ruegenberg (07.01.)  
Dr Noboru Obata (26.01.)

## FEBRUARY 2009

### 70<sup>th</sup> Birthday

ZA Heinz Adam (07.02.)

### 65<sup>th</sup> Birthday

Dr Marija Calic (16.02.)  
Dr Frithjof Scholz (17.02.)  
Dr Horst Wiehl (28.02.)  
Dr Armin Friedmann (29.02.)

### 60<sup>th</sup> Birthday

Dr Stefan Krauß (08.02.)  
Dr Helmut Wild (12.02.)

Dr Gabriele Locke (13.02.)  
Dr Günter Schmid (18.02.)  
Dr Thomas Luyken (19.02.)

### 55<sup>th</sup> Birthday

Dr Axel Sommermeier (03.02.)  
Dr Michael Leible (25.02.)  
Dr Georg Havelland (27.02.)

### 50<sup>th</sup> Birthday

Dr Thomas Bork (13.02.)  
Dr Al-Rez Omran (13.02.)

ZA Uwe Simon (16.02.)  
Dr Rüdiger Carlberg (18.02.)  
Dr Tibor Stein (23.02.)  
Dr Gunter Hagemann (24.02.)  
Dr Peter Kalitzki (26.02.)

### 45<sup>th</sup> Birthday

Dr Ralf E. Klaus (01.02.)  
ZA Markus Christian Schmitt (11.02.)  
Dr Erik Baldauf (15.02.)  
Dr Adnan Kotesch (18.02.)  
Dr Bernd Leppert (21.02.)

Dr Robert Eisenburger (26.02.)  
Dr Alexander Eberlein (27.02.)

### 40<sup>th</sup> Birthday

Dr Volker Böll (04.02.)  
Dr Stefan Maubach (08.02.)  
Dr Hawari Samer (15.02.)  
ZÄ Dorota Rabschewski (16.02.)  
ZA Frank Huttanus (26.02.)

## MARCH 2009

### 65<sup>th</sup> Birthday

Dr Hartmut Bongartz (30.03.)

### 60<sup>th</sup> Birthday

Dr Barbara Matthaes (03.03.)  
Isolde Moser (07.03.)  
Dr Konrad Kiesewetter (09.03.)  
Dr Hans Kolbinger (12.03.)  
Dr Johannes Heil (26.03.)  
Dr Martin Allgöwer (31.03.)

### 55<sup>th</sup> Birthday

Dr Rudolf Hochederer (05.03.)  
Dr Ferdinand Lochner (10.03.)  
Dr Günther Stern (13.03.)  
ZA Leon Horrichs (20.03.)

### 50<sup>th</sup> Birthday

Dr Adolf Friedrich Rinne (04.03.)  
Dr Felix Sippel (06.03.)  
Dr Edelt Peters (06.03.)  
Dr Gerald Marterer (13.03.)  
Dr Hans Jürgen Müller (14.03.)

Eike Erdmann (16.03.)  
Dr Peter Fischer (20.03.)  
Dr Toussaint Eijck (24.03.)

### 45<sup>th</sup> Birthday

Dr Galit Cohen (04.03.)  
Dr Falk Walpuski (09.03.)  
Dr M. Faisal Als Bee (15.03.)  
ZTM Frank Schröder (16.03.)  
ZTM Stefan Leisner (23.03.)  
Dr Klaus Zieglgänsberger (24.03.)

### 40<sup>th</sup> Birthday

Dr Jan Martin Ebling (02.03.)  
Dr Alass Ahmad (07.03.)  
Dr Ralf Lauenstein (14.03.)  
Daas Abedul Rahman (22.03.)  
Dr Mihai Rominu (24.03.)  
Dr Erik Vetter (26.03.)  
Dr Mahmoud Warrak (28.03.)

# Manufacturer News

Oemus Media

## NEW! Laser—international magazine of laser dentistry

Starting on the IDS International Dental Show in March the first issue of the International Laser Magazine will be published by Oemus Media AG. In cooperation with the World Federation of Laser Dentistry (WFLD), the magazine was made for commissioning the international know-how-transfer in laser dentistry. Like to the IMPLANTS, the international magazine of oral implantology, which is published very successful since more than 10 years, readers get a periodic update by user-oriented case reports, scientific studies and manufacturer news from the all over the world of laser dentistry. Reports about international congresses, meetings and international activities of the World Federation of Laser Dentistry will have an important significance in this regard. LASER—international magazine of laser dentistry will be published four times a year in English language.



**Oemus Media AG**


Holbeinstraße 29  
04229 Leipzig, Germany  
E-mail: kontakt@oemus-media.de  
Web: www.oemus.com  
Booth at IDS: Hall 4.1, E060-F069

EMS

## Precise and gentle: Bone sections using ultrasound

Piezon Master Surgery by EMS means that the Piezon method is now available in dental, oral and maxillofacial surgery. The method is based on piezoceramic ultrasound waves which produce high-frequency, linear oscillations forwards and back. According to EMS, these vibrations increase the precision and security of surgical applications. The ultrasound operation enables a micrometric section cut in an area of 60 to 200 micrometers with only a slight loss in bone mass. The ultrasound ray only selectively cuts hard tissue; soft tissue remains untouched. The high-frequency vibrations with permanent cooling also mean that there is little blood in the operating area and thermal alterations are avoided. Piezon Master Surgery can be used in parodontal, oral and maxillary surgery as well as in implantology. Specific indications are osteotomy and osteoplastics, extraction, apical root resection, cystectomy, extraction of bone blocks, sinus lift, nerve transposition, jaw ridge division and extraction of autologous bones. According to the manufacturer's details op-

eration using the touch board is easy and hygienic. By moving your fingers over the notches of the operating elements, the power as well as the flow rate of the isotonic solution can be regulated. The LED reacts to the moving fingers by emitting a quiet signal, even if a hand is in a glove or if an additional protective film is used. For reasons of hygiene, corners, joints and chinks have been avoided in the design. Piezon Master Surgery is offered as a basic system with five instruments for use in implantation preparation. The development of the exclusive Swiss Instruments Surgery is based on the experience of 25 years' continual research and covers various applications, according to EMS. The user has optional systems for tooth extraction, retrograde root channel preparation and procedures on bones at his disposal. All systems contain autoclavable Combitorques and a Steribox.



**EMS Electro Medical Systems GmbH**

Schatzbogen 86  
81829 München, Germany  
E-mail: info@ems-dent.de  
www.ems-dent.de  
Booth at IDS: Hall 10.2, L010-M019

Dr. Ihde Dental

## A new implant presented by Dr. Ihde Dental

Offering premium quality at attractive prices—that is the corporate mission of Dr. Ihde Dental. Of course this mission also applies to the new Hexacone implant, which has been designed specifically with

platform switching in mind. The Hexacone bone-level implant is a self-tapping implant that provides a high level of primary intraosseous stability, with improved bone healing thanks to a special concavity integrated into the design. The implant features a microthreaded neck, ensuring excellent bone apposition. To prevent trauma to anatomical structures such as the maxillary sinus floor or the mandibular nerve, the implant was designed

with a rounded apical end. Like the other Dr. Ihde Dental implant lines, the Hexacone implants are coated with an osmoactive surface.



**Dr. Ihde Dental GmbH**

Erfurter Straße 19  
85386 Eching, Germany  
E-mail: info@ihde.com  
Web: www.implant.com  
Booth at IDS: Hall 10.2, O031



OSSTEM

**“GSIII implant”—“Excellent initial fixation, convenient operation”**

Since beginning of 2008, OSSTEM IMPLANT showed a new product called “GSIII implant”. As the latest product in the GS System line, the “GSIII implant” has earned raves for its excellent fixation following implant placement. For patients with alveolar bone that is not hard enough, the time it took for bone and implant to adhere following implant placement was somewhat long. “GSIII implant” is expected to reduce the time it takes for the implant to be fixed on the bone after placement considering the excellent initial fixation. This in turn will result in considerably shorter treatment time, which is clear advantage. In addition,



a huge increase in demand is expected from dentists who perform the operation because the new product has many advantages such as convenience in controlling the implant placement depth, convenience in performing the operation, excellent placement touch, and convenience in changing the placement direction. Since the target market does not overlap with the market for the company’s existing products, this product is expected to aid in the market’s growth and make a significant contribution that will enable the OSSTEM implant system to gain advantage along with the existing products in competition with other implants.

**OSSTEM Germany GmbH**

Mergenthaler Allee 25D, 65760 Eschborn, Germany  
E-mail: info\_de@osstem.com, Web: www.osstem.com  
Booth at IDS: Hall 4.1, A008, A010, A019, C019

DOT

**Fast and Safe Bone Regeneration**

BONITmatrix is a proven synthetic bone graft material with considerable advantages for surgeons and patients. The material shows an excellent biocompatibility due to nanostructured calcium phosphates which are embedded in a bioactive Silicadioxide-Xerogel matrix. BONITmatrix® is integrated into the nat-

ural bone remodelling process and therefore completely resorbed. Furthermore the material accelerates bone regeneration, shows a very good osseointegration and can reduce the healing time. HyproSorb® F is a bioresorbable bilayer Collagen membrane for Guided Bone and Tissue Regeneration (GBR/GTR). The membrane acts for approx. 6 months as a safe barrier to prevent ingrowth of soft tissue before it will be



resorbed. Furthermore the membrane shows good biocompatibility as well as optimal handling properties due to high tensile strength.

**DOT GmbH**

Charles-Darwin-Ring 1a  
18059 Rostock, Germany  
E-mail: info@dot-coating.de  
Web: www.dot-coating.de  
Booth at IDS: Hall 10.2, N047

AD

**OMNIA**  
Disposable Medical Devices

OMNIA S.p.A.  
Via F. Delvevo, 190 - 43036 Fidenza (PR) Italy  
Tel. +39 0524 527453 - Fax +39 0524 525230  
www.omniasrl.com

W&H

**W&H surgical instruments with LED and generator**

Excellent lighting conditions facilitate perfect treatment results. That is why W&H has developed a new generation of surgical instruments that enable you to operate with daylight quality light and with light sources that are self-sufficient. The perfect white LED light is completely self-generated. This is down to the integrated generator that supplies energy to the light-emitting diodes. En clair: Independent of the operation unit—with or without light—the new surgical instruments with integrated generator allow operations with best possible LED illumination. Another impressive addition to the W&H product range—surgical instruments that provide daylight-quality light in the treatment area, independent of the respective drive system. Both the SI-11 LED G straight handpiece and the WI-75 LED G contra-angle handpiece are compatible with any motor with ISO coupling. As soon as the straight or contra-an-

gle handpiece is operated, the generator independently produces electricity for the LEDs. An additional, separate electricity supply is not necessary. Light emitting diodes are based on semiconductor connections that convert electricity directly into light. This results in robust light sources that barely heat up, that are shock-resistant and that do not emit any harmful IR or UVA rays. Furthermore, LEDs have a much higher durability than conventional light sources. Due to the colour temperature, the LED light colour corresponds to neutral white light. This light creates a sharp visual contrast, which gives significant support to the user’s vision and means that their own eyesight is not damaged. Both instruments have a tried and tested construction and are thermoisinfectable and sterilizable at 135 °C.

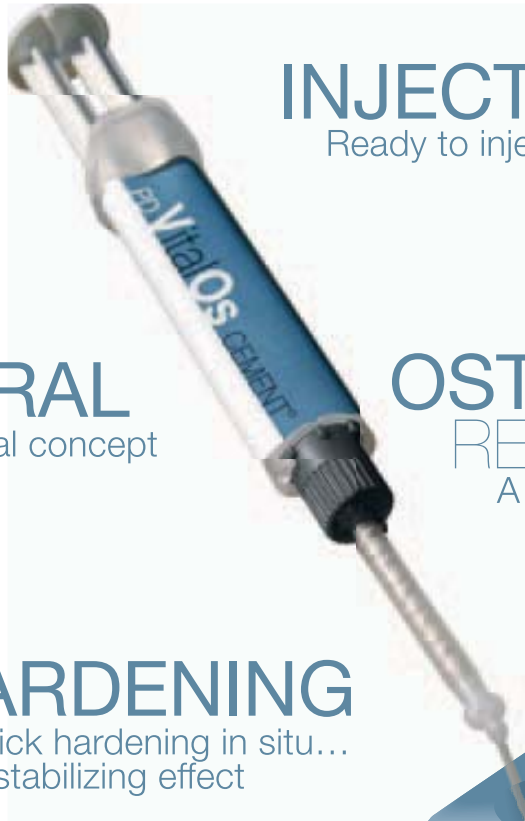

**W&H Deutschland GmbH**

Raiffeisenstraße 4  
83410 Laufen, Germany  
E-mail: office.de@wh.com  
Web: www.wh.com  
Booth at IDS: Hall 10.1, C010-D011

# PD VitalOs CEMENT®

The bone regeneration cement



## INJECTABLE

Ready to inject without premixing

## MINERAL

All-mineral concept

## OSTEOCONDUCTIVE RESORBABLE

A truly resorbable Calcium Phosphate cement

## HARDENING

Quick hardening in situ...  
stabilizing effect



1

stage

**Facilitates one-stage surgery**

**Optimized flow**

complete and tight filling

**Stabilizing effect**

strong adhesion to implant

**Solid interphase**

cement

2-in-1

**Filler and barrier**

bone substitute / membrane in one

**Cost effective**

no membrane required

Ready  
to use

**Time saving**

no premixing required

**Simplicity**

directly injectable

**Safe**

reduced risk of  
contamination

Visit us: IDS 2009  
Hall 10.1 Booth A N°: 068

[www.vitalos.com](http://www.vitalos.com)

Produits Dentaires SA / Switzerland



Sybron Implant Solutions

**Now also available:  
Cytoplast Membranes  
titanium reinforced or  
resorbable**

For the application of membranes, the reliability and predictability are major preconditions. The proven membrane Cytoplast Non Resorb of Sybron Implant Solutions, Bremen, has guaranteed both facts for more than 10 years. Sybron Implants now introduces two new membranes. The Cytoplast TI 250 membrane is a non-resorbable and titanium reinforced membrane available in three dimensions. The reinforcement with titanium grade 1 increases the stability of this membrane and allows space preservation for an augmentation. Indents within the surface of the membrane provide a structure which enlarges the available area for cell



adhesion to 250%. A microporosity of less than 0.3 micron prevents an infiltration of bacteria as well as cells so that the membrane can remain exposed. In addition, the new resorbable membrane Cytoplast RTM has been included in the sales program. This membrane of highly purified (type 1) bovine achilles tendon allows a tissue integration into the outer layer thanks to the multiple layer structure, thus preventing a direct migration of bacteria and epithelial cells. The unique fiber alignment supports

the tensile strength. The membrane is cell-occlusive and of optimal flexibility and enables an easy handling. Each side of the membrane can be placed on the defect. With the relatively long resorption time of 26–38 weeks the membrane is suitable for the use in periodontal defects, sinus lift osteotomy and augmentation of soft tissue. Aside from these outstanding product qualities, the Cytoplast membranes feature a very favourable cost-performance ratio.

With the purchase of 4 boxes, another box will be delivered free of charge. Case documentations and a step-by-step instruction are available at

**Sybron Implant Solutions GmbH**

Julius-Bamberger-Straße 8a  
28279 Bremen, Germany  
E-mail: info@sybronimplants.de  
Web: www.sybronimplants.de  
Booth at IDS: 10.1, H028

CAMLOG

**CAMLOG under new leadership—  
Dr Michael Peetz appointed as  
CEO**



After five years of successfully heading the CAMLOG Group, Jürg Eichenberger stepped down as Chief Executive Officer of CAMLOG Biotechnologies AG, Basel/ Switzerland, at the end of last year. He maintains his function as Chairman of the Board of Directors of CAMLOG Holding AG. In the years from 2003 to 2008, decisively shaped by Jürg Eichenberger, the international CAMLOG Group has continuously developed above market average. As of January 2009, Dr Michael Peetz has been appointed

new CEO of CAMLOG Biotechnologies AG. He is exceptionally experienced and qualified to succeed Jürg Eichenberger. From 1990 to 2008, Dr Peetz held important executive positions with Geistlich Pharma AG, Wolhusen/Switzerland. As a Managing Director, Chief Operating Officer, and member of the Executive Board, he led Geistlich Biomaterials into the position of the world-wide leading provider of Regenerative Products and turned this division into a profitable and internationally significant business unit. Dr Peetz is also founder and a member of the Board of Directors of the OSTEOLGY FOUNDATION and a member of its Scientific and Education Committees. He was the initiator of a series of world-wide recognized OSTEOLGY congresses with more than 2,500 participants.

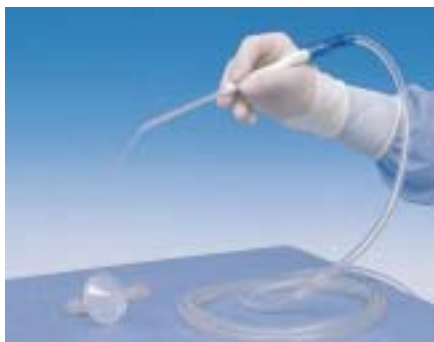**CAMLOG Biotechnologies AG**

Margarethenstrasse 38  
CH-4053 Basel, Switzerland  
E-mail: info@camlog.com  
Web: www.camlog.com  
Booth at IDS: Hall 11.3, A010, B019

Omnia

**Surgical aspirator  
tubing with bone-  
collector fittings**

The aspiration system devices are widely used products in odontoiatric clinics during the different medical procedures. Their aim is the aspiration of blood and liquid secretions produced in the oral cave during the oral surgery or during routine procedures and conservative treatments. The surgical aspiration system manufactured by OMNIA is designed to be used in the most different medical disciplines and especially in oral surgery. The special ergonomic shape of the cannula makes aspiration



operations simple and accurate, even in presence of draft material. The lightweight medical grade PVC pipe assures mobility and comfort during long surgical operations. The surgical aspirator can be

fitted with Osteotrap bone filter. The purpose of the filter itself is to collect autologous removed bone usually lost during the creation of the implantal area through the filtration of what has been aspirated. This allows to collect a quantity of material equal to the volume of the implant itself. Osteotrap is a high quality medical device designed to be used during oral surgery, implantology and maxillo facial surgery.

**Omnia S.p.A**

Via F. Delnevo 190  
43036 Fidenza (PR), Italy  
E-Mail: info@omniasrl.com  
Web: www.omniasrl.com  
Booth at IDS: 4.1, D090-E091



Sybron Implant Solutions

**Now also available:  
Cytoplast Membranes  
titanium reinforced or  
resorbable**

For the application of membranes, the reliability and predictability are major preconditions. The proven membrane Cytoplast Non Resorb of Sybron Implant Solutions, Bremen, has guaranteed both facts for more than 10 years. Sybron Implants now introduces two new membranes. The Cytoplast TI 250 membrane is a non-resorbable and titanium reinforced membrane available in three dimensions. The reinforcement with titanium grade 1 increases the stability of this membrane and allows space preservation for an augmentation. Indents within the surface of the membrane provide a structure which enlarges the available area for cell



adhesion to 250%. A microporosity of less than 0.3 micron prevents an infiltration of bacteria as well as cells so that the membrane can remain exposed. In addition, the new resorbable membrane Cytoplast RTM has been included in the sales program. This membrane of highly purified (type 1) bovine achilles tendon allows a tissue integration into the outer layer thanks to the multiple layer structure, thus preventing a direct migration of bacteria and epithelial cells. The unique fiber alignment supports

the tensile strength. The membrane is cell-occlusive and of optimal flexibility and enables an easy handling. Each side of the membrane can be placed on the defect. With the relatively long resorption time of 26–38 weeks the membrane is suitable for the use in periodontal defects, sinus lift osteotomy and augmentation of soft tissue. Aside from these outstanding product qualities, the Cytoplast membranes feature a very favourable cost-performance ratio.

With the purchase of 4 boxes, another box will be delivered free of charge. Case documentations and a step-by-step instruction are available at

**Sybron Implant Solutions GmbH**

Julius-Bamberger-Straße 8a  
28279 Bremen, Germany  
E-mail: info@sybronimplants.de  
Web: www.sybronimplants.de  
Booth at IDS: 10.1, H028

CAMLOG

**CAMLOG under new leadership—  
Dr Michael Peetz appointed as  
CEO**



After five years of successfully heading the CAMLOG Group, Jürg Eichenberger stepped down as Chief Executive Officer of CAMLOG Biotechnologies AG, Basel/ Switzerland, at the end of last year. He maintains his function as Chairman of the Board of Directors of CAMLOG Holding AG. In the years from 2003 to 2008, decisively shaped by Jürg Eichenberger, the international CAMLOG Group has continuously developed above market average. As of January 2009, Dr Michael Peetz has been appointed

new CEO of CAMLOG Biotechnologies AG. He is exceptionally experienced and qualified to succeed Jürg Eichenberger. From 1990 to 2008, Dr Peetz held important executive positions with Geistlich Pharma AG, Wolhusen/Switzerland. As a Managing Director, Chief Operating Officer, and member of the Executive Board, he led Geistlich Biomaterials into the position of the world-wide leading provider of Regenerative Products and turned this division into a profitable and internationally significant business unit. Dr Peetz is also founder and a member of the Board of Directors of the OSTEOLGY FOUNDATION and a member of its Scientific and Education Committees. He was the initiator of a series of world-wide recognized OSTEOLGY congresses with more than 2,500 participants.

**CAMLOG Biotechnologies AG**

Margarethenstrasse 38  
CH-4053 Basel, Switzerland  
E-mail: info@camlog.com  
Web: www.camlog.com  
Booth at IDS: Hall 11.3, A010, B019

Omnia

**Surgical aspirator  
tubing with bone-  
collector fittings**

The aspiration system devices are widely used products in odontoiatric clinics during the different medical procedures. Their aim is the aspiration of blood and liquid secretions produced in the oral cave during the oral surgery or during routine procedures and conservative treatments. The surgical aspiration system manufactured by OMNIA is designed to be used in the most different medical disciplines and especially in oral surgery. The special ergonomic shape of the cannula makes aspiration



operations simple and accurate, even in presence of draft material. The lightweight medical grade PVC pipe assures mobility and comfort during long surgical operations. The surgical aspirator can be

fitted with Osteotrap bone filter. The purpose of the filter itself is to collect autologous removed bone usually lost during the creation of the implantal area through the filtration of what has been aspirated. This allows to collect a quantity of material equal to the volume of the implant itself. Osteotrap is a high quality medical device designed to be used during oral surgery, implantology and maxillo facial surgery.

**Omnia S.p.A**

Via F. Delnevo 190  
43036 Fidenza (PR), Italy  
E-Mail: info@omniasrl.com  
Web: www.omniasrl.com  
Booth at IDS: 4.1, D090-E091

# innovation & warranty



“....more patients....”

**Hall 4.1**  
**Stand A-021**

Professional medical communication supports the patient's decision-making process by providing him with valid information about the advantages of precautionary options like Periointegration® in dental implant treatment.

As trust and reliability are the key aspects for the investment in oral health and require a high degree of care and knowledge transfer in patient language MHC-Medical HighCare Communications® supports dentists in their professional patient approach.

The combination of a high-tech product innovation like the ZircoSeal® abutment surface and the maximum safety given by the ImplantCoverletter® provides dentists and their patients with a successful treatment concept. The FullcoverageImplant is the right choice where quality, innovation, safety and communication are concerned.



CLINICAL HOUSE DENTAL GmbH  
Am Bergbaumuseum 31 • 44791 Bochum  
Tel.: +49 234 90 10 260 • Fax: +49 234 90 10 262  
[www.periointegration.de](http://www.periointegration.de)



MedicalHighcare  
Communications

MedicalHighcare Communications GmbH  
Am Bergbaumuseum 31 • 44791 Bochum  
Tel.: +49 234 97 47 6027 • Fax: +49 234 97 47 6030  
[www.mhc-communications.de](http://www.mhc-communications.de)

# implants

international magazine of oral implantology



<b>Publisher</b>	Torsten R. Oemus	oemus@oemus-media.de
<b>CEO</b>	Ingolf Döbbecke Jürgen Isbaner Lutz V. Hiller	doebbecke@oemus-media.de isbaner@oemus-media.de hiller@oemus-media.de
<b>Chief Editorial Manager</b>	Dr. Torsten Hartmann (V. i. S. d. P.)	hartmann@dentalnet.de
<b>Editorial Council</b>	Dr. Friedhelm Heinemann Dr. Roland Hille Dr. Winand Olivier Prof. Dr. Dr. Kurt Vinzenz Dr. Torsten Hartmann Dr. Suheil Boutros	friedhelmheinemann@web.de dr-hille@t-online.de dr.olivier@t-online.de kurt.vinzenz@aon.at hartmann@dentalnet.de SMBoutros@aol.com
<b>Editorial Office</b>	Kristin Urban Katja Kupfer	k.urban@oemus-media.de kupfer@oemus-media.de
<b>Executive Producer</b>	Gernot Meyer	meyer@oemus-media.de
<b>Art Director</b>	Dipl.-Des. Jasmin Hilmer	hilmer@oemus-media.de
<b>Customer Service</b>	Marius Mezger	m.mezger@oemus-media.de
<b>Published by</b>	Oemus Media AG Holbeinstraße 29 04229 Leipzig, Germany Phone: +49-3 41/4 84 74-0 Fax: +49-3 41/4 84 74-2 90 E-mail: kontakt@oemus-media.de	

**implants** international magazine of oral implantology is published in cooperation with the German Association of Dental Implantology (DGZI).

**DGZI President** Dr. Friedhelm Heinemann  
DGZI Central Office  
Feldstraße 80, 40479 Düsseldorf, Germany  
Phone: +49-2 11/1 69 70-77  
Fax: +49-2 11/1 69 70-66  
E-mail: office@dgzi-info.de

[www.dgzi.de](http://www.dgzi.de)  
[www.oemus.com](http://www.oemus.com)

## implant\_Copyright Regulations

*\_the international magazine of oral implantology* is published by Oemus Media AG and will appear in 2009 with one issue every quarter. The magazine and all articles and illustrations therein are protected by copyright. Any utilization without the prior consent of editor and publisher is inadmissible and liable to prosecution. This applies in particular to duplicate copies, translations, microfilms, and storage and processing in electronic systems. Reproductions, including extracts, may only be made with the permission of the publisher. Given no statement to the contrary, any submissions to the editorial department are understood to be in agreement with a full or partial publishing of said submission. The editorial department reserves the right to check all submitted articles for formal errors and factual authority, and to make amendments if necessary. No responsibility shall be taken for unsolicited books and manuscripts. Articles bearing symbols other than that of the editorial department, or which are distinguished by the name of the author, represent the opinion of the afore-mentioned, and do not have to comply with the views of Oemus Media AG. Responsibility for such articles shall be borne by the author. Responsibility for advertisements and other specially labeled items shall not be borne by the editorial department. Likewise, no responsibility shall be assumed for information published about associations, companies and commercial markets. All cases of consequential liability arising from inaccurate or faulty representation are excluded. General terms and conditions apply, legal venue is Leipzig, Germany.



IDS March 24–28, 2009  
Cologne, Germany

You will find us:  
Hall 4.1. Stand F 66

One Of The Leading  
Societies In Implantology  
Welcomes You.

Meet people from all over the world!

Join the leading fair in dentistry!

Come to the IDS 2009 and visit us!



For more information please contact us: DGZI Central Office  
Feldstraße 80, 40479 Düsseldorf  
Phone: +49-2 11/1 69 70-77, Fax: +49-2 11/1 69 70-66  
E-Mail: [office@dgzi-info.de](mailto:office@dgzi-info.de), [www.dgzi.de](http://www.dgzi.de)



**DGZI**  
Deutsche Gesellschaft für  
Zahnärztliche Implantologie e.V.



**Sybron  
Implant Solutions**  
SYBRON DENTAL SPECIALTIES

# EXTRAORDINARY

Introducing a new implant from one of the most respected names in dentistry - *Sybron*. Our new Sybron**PRO™ XRT** incorporates an extraordinary array of features proven to address immediate stability, preservation of crestal bone<sup>2</sup>, and long-term aesthetics.

Call us today to experience the EXTRAORDINARY for yourself!

**IDS<sup>®</sup>**  
**2009**

Visit us at the IDS in  
Cologne: Hall 10.1,  
aisle H, booth 028

<sup>1</sup>Surgical and Mechanical Techniques to Increase Stability of Dental Implants. Kharouf, Zeineb; Oh, Hyeong Cheol; Saito, Hanae; Cardaropoli, Giuseppe; Bral, Michael; Cho, Sang-Choon; Froum, Stuart; Tarnow, Dennis. Ashman Department of Periodontology and Implant Dentistry, New York University. Research presented at the AO Boston 2008.

<sup>2</sup>Implant Design and Its Effect on Preservation of Crestal Bone Levels. Jang, Bong-Joon; Pena, Maria Luisa; Kim, Mean Ji; Eskow, Robert; Elian, Nicolas; Cho, Sang-Choon; Froum, Stuart; Tarnow, Dennis. Ashman Department of Periodontology and Implant Dentistry, New York University. Research presented at the AO Boston 2008.

**Sybron – Celebrating over 100 years of dental excellence**


Europe  
Sybron Implant Solutions GmbH  
Julius-Bamberger-Str. 8a  
28279 Bremen, Germany  
T 49.421.43939.0  
info@sybronimplants.de

United Kingdom  
4 Flag Business Road  
Vicarage Farm Road  
Peterborough, PE1 5TX, UK  
T 008000 841 2131

France  
16 Rue du Sergent Bobillot  
93100 Montreuil, France  
T 33.149.88.60.85

Australia  
# 10, 112-118 Talavera Rd  
North Ryde, NSW 2113  
T 61.2.8870.3099

HEADQUARTERS  
USA  
1717 West Collins Avenue  
Orange, California 92867  
T 714.516.7800



[www.sybronimplants.com](http://www.sybronimplants.com)

**ADMED**  
.com

**OSSTEM**<sup>®</sup>  
**IMPLANT**

**This is  
the First**

# TS III CA

**SUPER HYDROPHILIC SURFACE**



Tel: +98 21 88 98 80 63 - 6  
[www.azadmed.com](http://www.azadmed.com)

Fax: +98 21 88 98 75 72  
[www.osstem.ir](http://www.osstem.ir)