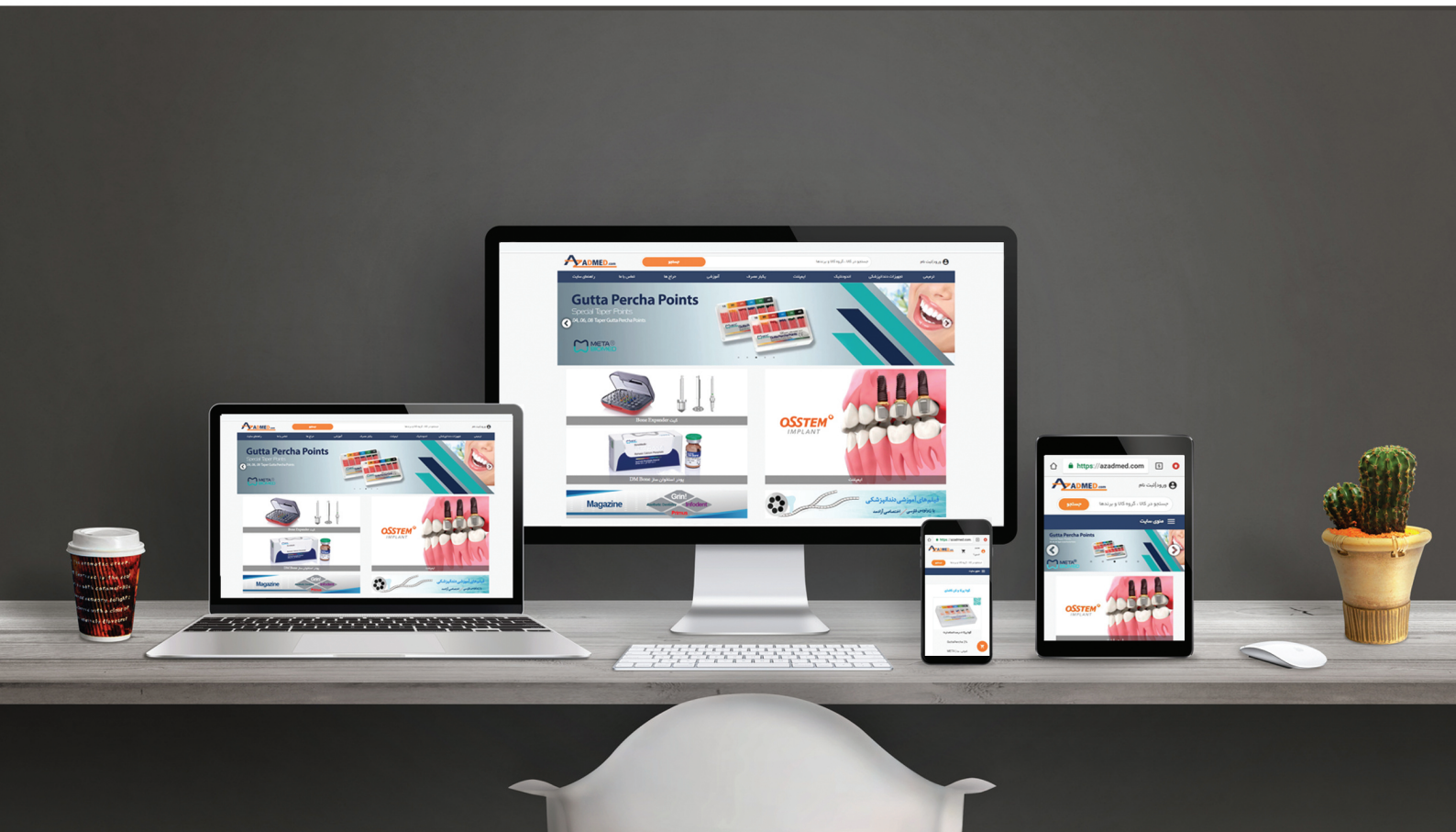




آزاد تجارت پارس  
AZAD TEJARAT PARS.LTD

**AZADMED.com**



[www.azadmed.com](http://www.azadmed.com)



 azaadtejaratpars

 @azadmed2

 88 98 80 63 - 6

# implants

international magazine of oral implantology

2<sup>2009</sup>



**Scientific study**

Soft Tissue Integration in the Neck Area of Titanium Implants—An Animal Trial

**IDS review**

IDS for implantologists—Interview with Dr Rolf Vollmer

**worldwide events**

24<sup>th</sup> Annual Meeting of the Academy of Osseointegration




**DGZI**  
Deutsche Gesellschaft für  
Zahnärztliche Implantologie e.V.



# Now even more innovative.

Easy-to-dismantle surgical instruments with LED and generator



**Easy to dismantle. Easy to assemble.** As simple as they are efficient: both the S-11 LED G and the WS-75 LED G can be completely dismantled. And, of course, they can be put back together again. Quick, simple and risk-free: meaning that you too are able to eliminate any risks and work in truly optimum hygienic conditions. Get the new standard for yourself: perfect light, global compatibility, precision, ergonomics – and complete safety.

For more information please ask your local dental dealer.

[wh.com](http://wh.com)



# In the main interest: the new modular post- graduate education concept of the DGZI



Dr Friedhelm Heinemann  
President of DGZI

Dear colleagues,

once again IDS 2009 has proved to be the mega event of the international dental world. The increasing number of exhibitors and visitors showed that the upward trend of the past years could be maintained. This signal was and is still of great importance, especially with regard to the tense situation in the market, and the worldwide stagnating or even declining sales figures. This shows, that dentistry and especially implantology may confront this crisis with new ideas, technological innovation and the courage to try out new approaches. IDS's main issues were, on the one hand digital dentistry, ranging from diagnosis, planning and navigation to CAD/CAM-made dental prostheses, and of course, as in the past years, implantology on the other hand. The line of products is increasingly difficult to overview. Apart from those manufacturers already established in Germany, there is an increasing number of Asian system suppliers entering the lucrative German market. Considering the increasing exchangeability of the products, the main focus now also lies on all kinds of services offered for implants. It was the second time that the expert association DGZI was represented with its own stand at IDS. The decision to form part of IDS paid off again. Throughout the event, DGZI's board members and the Düsseldorf office staff had plenty to do in order to cope with the visitors' enormous need for information at the fair. The primary topic of interest was the postgraduate education program offered by our expert association. Especially the new modular concept of the DGZI curriculum, which provides the participants with many different possibilities, as there are e.g. the contents of the curricula concerning personal interest, and specific requirements that can be tailored to a participant's own practice, attracted much attention. With this practice-oriented concept the DGZI does not only take into account the persistent trend of specialization, but also the different requirements for main issues concerning the practice itself. In addition to master studies, DGZI has developed a systematic module curriculum based on five compulsory modules, e.g. concerning implant prosthetics and hard and soft tissue management. All participants no matter if you are an implantology expert or beginner will be updated with regard to scientific basics and practice-oriented techniques. Afterwards, the participants can select from more than ten modules, and choose three main topics according to their special interests. Topics that can be chosen are e.g. gerostomatology, laser in implantology, piezo-based surgery, and also sedation techniques. The new curriculum additionally ensures efficiency by avoiding any overlapping with previous curricula contents. It is also possible to book single modules separately, i.e. independent of participating in the whole curriculum. This is a further step to improve the education in dental implantology.

With kind regards,

Yours

A handwritten signature in black ink, appearing to read 'Dr. F. Heinemann', with a long, sweeping underline.

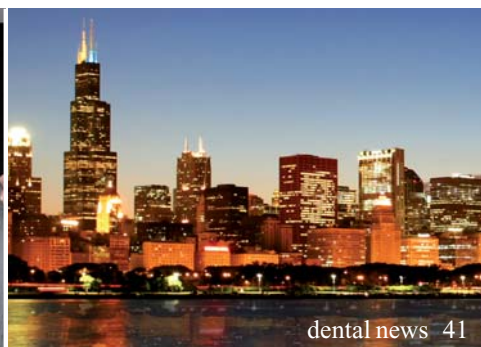Dr Friedhelm Heinemann  
President of DGZI



clinical report 6



worldwide events 36



dental news 41

| editorial

- 03 In the main interest: **the new modular postgraduate education concept** of the DGZI  
\_Friedhelm Heinemann

| report

- \_ clinical report
- 06 **Geriatric medicine gives new impetus to implantology**—From anatomical and biological basics to dental practice  
\_Werner Götz, Rolf Vollmer and Friedhelm Heinemann, Germany
- \_ scientific study
- 14 **Soft Tissue Integration in the Neck Area of Titanium Implants**— an Animal Trial  
\_S. Allegrini Jr, M.R.F. Allegrini, M. Yoshimoto, B. König Jr, R. Mai; J. Fanghänel, T. Gedrang, Germany and Brazil
- \_ clinical report
- 24 **Maxillary sinus floor augmentation using a nano-crystalline hydroxyapatite silica gel. A prospective study—Histological results after 3 months of healing**  
\_Luigi Canullo, DDS; Iole Vozza, DDS; Dr Fabrizio Caricato; PhD Claudia Dellavia, DDS, PhD, Germany and Italy
- \_ scientific article
- 28 **Integration of diode laser surface decontamination in periimplantitis therapy**—a twelve year review of a fit for practice concept  
\_Georg Bach, Germany

| events

- \_ worldwide events
- 34 **Consensus Conference Implantology**

\_ worldwide events

- 36 **IDS flourishes despite economic trouble**  
\_Daniel Zimmermann, Germany

\_ IDS review

- 37 **IDS for implantologists— Interview with Dr Rolf Vollmer**

\_ worldwide events

- 38 **24<sup>th</sup> Annual Meeting of the Academy of Osseointegration (AO)**  
\_Rolf Vollmer and Rainer Valentin, Germany

\_ worldwide events

- 40 **AOS 7<sup>th</sup> Biennial Conference**

\_ implant events

- 41 **Selected Events 2009/2010**

| news

\_ dental news

- 42 **Midwinter Meeting Weathers Economic Storm**—Attendance down 9 % from 2008 meeting but 82 % of exhibitors report generating new business at show

\_ social news

- 43 **Congratulations and Happy Birthday to all DGZI-members around the world**

\_ manufacturer news

- 44 **Manufacturer News**


| about publisher

- 50 **Imprint**

Cover image courtesy by: DENTSPLY Friadent GmbH

# NobelActive™

Taking a new direction in implants.



Dual-function prosthetic connection

Built-in Platform Shifting™

Bone-condensing property

High initial stability, even in compromised bone situations

Adjustable implant orientation for optimal final placement

10 YEARS WITH  
TIUNITE® SURFACE  
New data confirm  
long-term stability.

NobelActive equally satisfies surgical and restorative clinical goals. NobelActive thread design progressively condenses bone with each turn during insertion, which is designed to enhance initial stability. The sharp apex and cutting blades allow surgical clinicians to adjust implant orientation for optimal positioning of the

prosthetic connection. Restorative clinicians benefit by a versatile and secure internal conical prosthetic connection with built-in Platform Shifting upon which they can produce excellent esthetic results. Based on customer feedback and market demands for NobelActive, the product assortment has been expanded – dental profession-

als will now enjoy even greater flexibility in prosthetic and implant selection. Nobel Biocare is the world leader in innovative evidence-based dental solutions. For more information, visit our website.

[www.nobelbiocare.com/nobelactive](http://www.nobelbiocare.com/nobelactive)

# Geriatric medicine gives **new impetus** to implantology

From anatomical and biological basics to dental practice

authors\_ Werner Götz, Rolf Vollmer and Friedhelm Heinemann, Germany



Fig. 6

**Fig. 6\_** Leonardo da Vinci: Head study of an old and a young man from the beginning of the 16<sup>th</sup> century. A typical toothless face of an aged man (left).

**\_The increase in life expectancy** and the drop in the birth rate are the main causes for demographic aging, especially in the industrial nations. In about 20 years nearly 40% of the German population will be older than 60 years. This signifies that gerostomatology will become increasingly important for practical dental medicine. Therefore, the knowledge of changes inside the oral cavity due to aging, and age correlated oral diseases are becoming more important. Whereas age-related facial phenomena have always been a reason for medical indication in plastic and esthetic facial surgery, the increasing number of senior citizens, who ask for an overall therapeutical concept for "dentofacial rejuvenation" requires an interdisciplinary view regarding the aging processes in face and oral cavity.

Dental implantologists are particularly in demand when it comes to interdisciplinary cooperation. It does not make any sense to perform a facelifting procedure, and postpone the restoration of teeth and the reconstruction of the stomatognathic system. On the contrary, first the oral cavity should be restored, and the function and esthetic of teeth should be recovered with fixed or removable dental prostheses. The

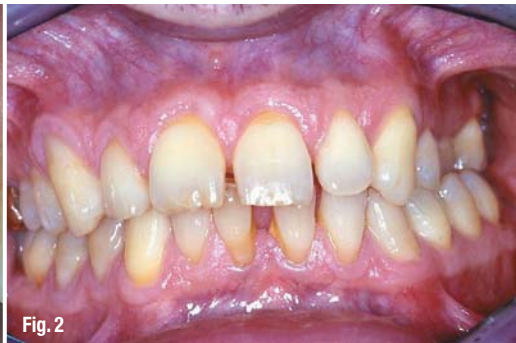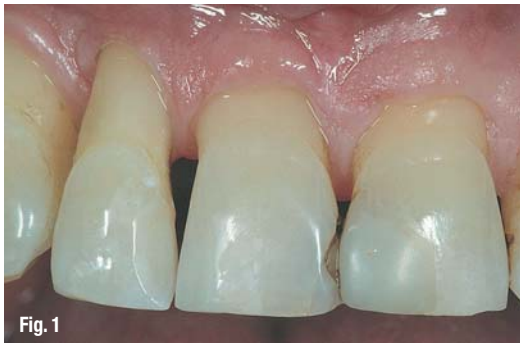restoration should be carried out from the inside, working outwards.

## **\_The biology of aging**

Aging stands for the irreversible change of an organism, which is characterized by an accumulation of tissue and cell damage that leads to a progressing decrease in organ functions. There is a higher risk of disease and death, and the adaptability of the body regarding external and internal stress is reduced. So far, none of the 300 existing age-related theories can explain the phenomenon of aging adequately. Especially theories treating changes due to aging, which are based on cellular and molecular biological, and genetic levels are favored. Until now, clearly defined "age genes" that might cause aging have not been found in the human genome.

In human history aging has nearly always been equated with disease. Modern gerontology clearly distinguishes between the so called physiological (primary) age-related changes and geriatric diseases. Physiological aging, which is characterized by physiological regressive processes, and which stands for normal aging, differs from so called unimpaired aging, where even normal physiological losses are low. Among those people over 60, there is an increasing number of "healthy" aging persons, who state that they are subjectively feeling healthy. The causes for unimpaired aging are not only due to genetic disposition, but they also strongly depend on exogenic factors such as (healthy) lifestyle, mental vigour, and the socioeconomic status. In the future, these "young elderly" will increasingly be eager for qualitatively high standard restoration and "anti-aging" methods.

Secondary aging means that in addition to physiological changes due to aging, geriatric diseases appear. These diseases are correlated with aging and/or there is a higher risk of illness at a greater age. Among them are e.g. cardiovascular diseases, metabolic diseases such as diabetes melitus, degenerative diseases of the locomotor system or psychic diseases. Age-related oral diseases are e.g. xerostomia (dryness of the



**Fig. 1** 69-year-old patient: Anterior teeth of the upper jaw with age-related changes, e.g. recessions, yellow stains, enamel cracks in one tooth.

**Fig. 2** 65-year-old patient: Complete and almost caries-free dentition with age-related changes e.g. minor recessions, enamel cracks.

mouth), root caries and malignant oral tumors, and their premalignant lesions. It is disputed if parodontopathies, especially recessions and inflammatory changes, are correlated with age.

Typical age-related physiological organ changes do not only effect oral health in a wider sense, but also one has to consider holistic aspects when treating and advising senior citizens. Decreasing neuromuscular abilities due to increasing loss of bone and muscle volume, and the reduced nerve conduction speed may have an effect for example on handling dental prostheses. Also a reduced immunological competence regarding oral microflora, deafness and defective vision on compliance due to age, functional losses concerning the gastrointestinal tract, especially its motility, and eating behaviour affect oral health. Reduced functions of organs and metabolism lead to changed pharmacodynamics and kinetics in age, which have to be considered in dentistry when medicating antibiotics or in case of local anesthesia.

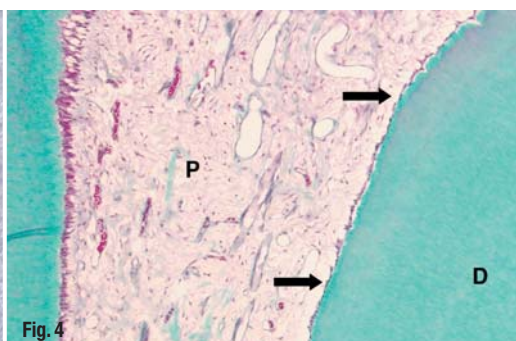
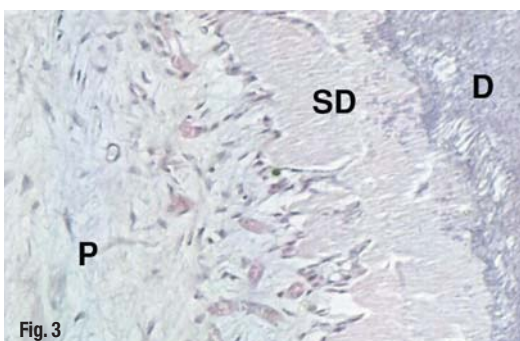
### Dental and oral age-related changes

The differential diagnostical distinction of pathological oral changes in older patients implies the natural knowledge about physiological changes. It must be critically remarked that due to the lack of clinical and scientific studies, our knowledge about age-related oral changes is still quite incomplete. Individual variabilities in the aging of each person should also be considered. When looking at the whole natural dentition, shortenings of the dental arches are a typical age-related dental evidence as a result of lifelong mesial movement. It is important for restorative and

esthetic dentistry that a yellow staining appears on the teeth of older people (Figs. 1, 2), in case that the teeth are not already covered with exogenically caused pigmentation (e.g. in smokers). Especially in the region of the anterior teeth other phenomena are of great importance, e.g. loss of incisal edge contours, loss of marginal ridges or contouring of dental crown surfaces (Figs. 1, 2). Losses of hard substance in terms of abrasion, attrition etc. are no longer considered to be typical age-related phenomena in industrial countries, because in comparison with former times, the composition of food has changed significantly.

With increasing age dental enamel suffers from progressive embrittlement and hardening due to dehydration and compression of crystal structures, which clinically often appear in the form of enamel cracks (Figs. 1, 2).

The loss of organic components and the progressing hypermineralization imply dentin sclerosis. The age-related alterations of both hard substances lead to changes of the material characteristics which have to be considered for filling therapies, etching or in case of application of adhesive systems. The pulp cavity decreases due to the accumulation of secondary dentin (Fig. 3). The pulp tissue itself is subject to different age-related changes: The connective tissue becomes fibrotic, calcifications appear, odontoblasts degenerate and die off, nerves and blood vessels also degenerate (Fig. 4). Thus, the hemodynamics of the old pulp, the sensitivity, and the sense of pain are reduced. This might signify that the reaction time for cold pulp testing has to be longer than in younger patients. However, vitality and function of the pulpa can be retained to a very great age.

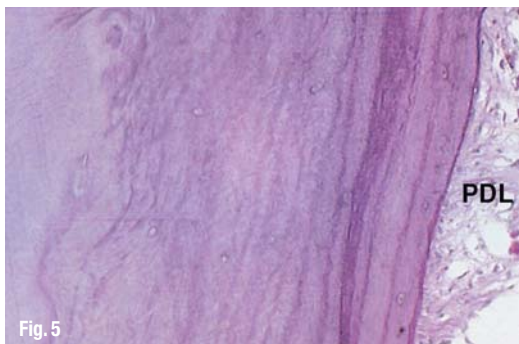


**Fig. 3** Premolar of a 66-year-old patient (histological specimen): Apposition of secondary dentin (SD), P = pulpa, D = dentin.

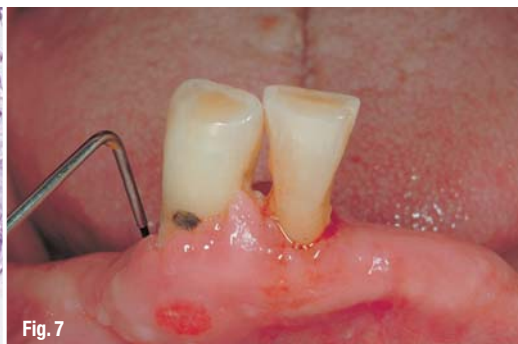**Fig. 4** Molar of a 70-year-old patient: Histological specimen of the pulpa (P) with fibrosis, loss of odontoblasts (arrows), D = dentin.



**Fig. 5** Molar of a 68-year-old patient: Histological specimen with hypercementosis: Annual ring-like apposition of cementum, PDL = periodontal ligament



**Fig. 7** 77-year-old female patient: Residual dentition in the lower jaw, distal development of alveolar ridge atrophy and formation of the alveolar crest mucosa.



An age-related narrowing of the periodontal cleft can be explained with a longlife apposition of root cementum (Fig. 5), which in extreme cases can even lead to hypercementoses. Although in older patients the gingival stippling dwindles macroscopically, the gingiva only suffers minor changes. It is probable that the continuous humidification with saliva and its multiple anabolic factors have a positive effect. There is a controversial discussion whether it comes to apical migration of the junctional epithelium (passive eruption, Fig. 1, 2) in dentally fit older people with normal gingiva. These regressive changes are probably due to continuous, lifelong, and mostly subclinical phases of inflammatory changes with loss of attachment.

The question if there is a higher risk for gingivitis and periodontitis with growing age, cannot be answered precisely. It is known that within general gerontological immune changes also the lymphocytic defense may be affected. Even host reactions e.g. on lipopolysaccharides (LPS) are retarded in old age. The plaque of older people contains more immune factors e.g. IgA.

The only comprehensive clinical study regarding the state of the oral mucosa of older patients came to the conclusion that there were no structural and functional differences compared with the oral mucosa of young patients, provided that there were no local or systemic diseases present. In contrast to the facial skin (see below) the oral mucosa is not influenced by photoaging. Oral perceptions e.g. touch, temperature or pain are not or only slightly affected in old age. On a case-by-case basis the state of the oral mucosa strongly depends on individual and regional differences. Histological studies of epithelia of older people showed atrophies and hyperkeratoses as well. The dentist bears high responsibility in view of early detection of age correlated pathological changes of the oral mucosa, and especially with regard to malignant tumors, and premalignant lesions e.g. leukoplakia.

### Saliva, mastication and deglutition in old age

It was long believed that saliva secretion, taste, mastication, and deglutition were reduced in older people with full dentition. There has been a change of

thinking thanks to numerous clinical and physiological studies that have been carried out during the last few years.

Though on the occasion of autopsies, considerable pathological changes of the oral salivary glands could be found even in generally healthy older people, studies showed that there was only a minor reduction of salivation rates. There were hardly any differences in quantity and composition of saliva compared with younger people. A change of salivary secretion e.g. a reduction (hyposialy) has to be considered to be pathological even in old age. The main reason for xerostomia (dryness of the mouth), which is caused by a reduced amount of saliva, is due to the intake of medication. More than 30% of the people older than 65 years suffer from this. Xerostomia is a frequent side effect of many pharmacological substances.

A good blood supply protects the tongue from heavy regressive changes in old age. Although taste buds diminish with increasing age, the taste hardly diminishes, contrary to the olfactory sense. There are no current studies that prove a significant difference in the perception of taste qualities in older people. Disorders in the perception of taste almost always have pathological causes.

Within the framework of muscular degeneration processes during physiological aging, the muscles of mastication, tongue and fauces also suffer from atrophies coupled with a loss of strength and tone. These changes are even more pronounced in toothless elderly people. However, current studies show a good functional preservation of mastication properties. Even toothless people or long-term denture wearers often still have functional reserve capacities. Minor losses can be found in older test persons especially with regard to oral motor abilities, so that the oral phase of the swallowing process may take longer. Considerable dysphagia (impaired deglutition) in older people is often symptomatic for a general disease e.g. diabetes, neurological diseases or tumors of the upper intestinal tract.

### Edentulism and the aged face

In former times there was no clear distinction between age and disease, aging was put on the same

BEGO is an official  
co-partner of the German  
Olympic teams for  
**Vancouver 2010**  
**London 2012**

GO FOR GOLD.



Bionic Engineering Design transfer of optimal living  
nature solutions to technical products

BEGO Semados®  
Mini-Implant

BEGO Semados®  
S-Implant

BEGO Semados®  
RI-Implant

## BIONIC ENGINEERING DESIGNED IMPLANTS

### Are You Interested?

Call your nearest BEGO Implant  
Systems Distributor  
or BEGO Implant Systems  
in Bremen, Germany

[www.bego-implantology.com](http://www.bego-implantology.com)

BEGO Semados® patented Implants embody:

- Indication-optimised contour design
- Function-optimised and bacterial-tight implant-abutment-connection
- High purity and ultra-homogenous TIPure<sup>Plus</sup>-surface
- Polished rim for an inflammation-free gingiva-attachment
- 100 % German design – 100 % German manufacturing
- Value for money

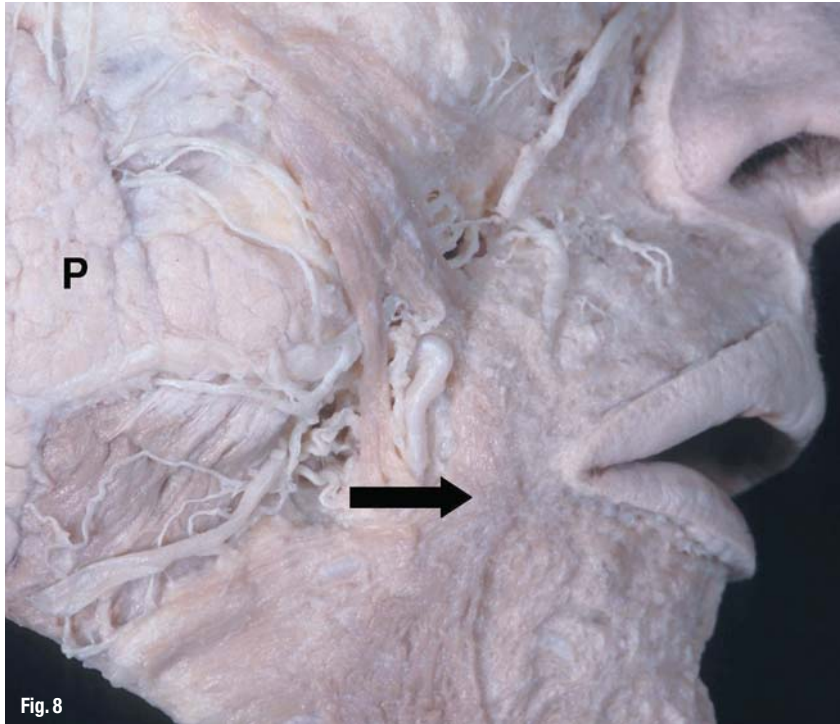
BEGO Semados® implants = stress reduction in the implants and the  
crestal bone for long-lasting clinical success!

**BEGO**   
Partners in Progress

www.adwork.de

[www.bego-implantology.com](http://www.bego-implantology.com)

 **ADMED**.com



**Fig. 8** Anatomical specimen of the superficial lateral face region, arrow: Modiolus, P = Parotis.

level with loss of teeth. Historical illustrations mostly show old people, with a typical aged face, which is a consequence of edentulism (Fig. 6). In industrial countries at least, improved dental restoration and successful prophylaxis have made it possible that an increasing number of senior citizens retain a complete and caries-free natural dentition until a very great age (Fig. 2). Therefore, an increasing loss of teeth is not necessarily attributed to age.

However, the effects of demographic aging will be so eminent that one cannot expect a decline in edentulism in the German population until 2020.

According to DMS IV (Deutsche Mundgesundheitsstudie IV, German Oral Health Study) of 2006, 23% of the people between 65 and 74 years of age were affected. Field studies showed that independent of the age, the main causes for loss of teeth are still caries and periodontopathies. Current studies even suggest that edentulism may be a risk factor for cardiovascular diseases, chronic infections, malignoma of the upper intestinal tract and perhaps also for senile dementia.

The typical age-related changes of the edentulous jaw, which lead to alveolar ridge atrophy in form of disease disuse atrophy by developing a jaw ridge, are of special interest for prosthetics and implantology (Fig. 7). Long-term sequelae can be seen in the architecture of the jaw and facial bones: Shortening of dental arches, divergences of dental arches, anterior rotation, and the formation of prognathic relation ("witch chin"), reduction of anterior face height and vertical dimension of occlusion etc. (Figs. 6, 8). The insertions of the masticatory muscles shift, and a flattening of the vestibule, and

a probable mouth floor elevation may be the consequence. The so called alveolar ridge skin mucosa derives from the dentate parts of the gingiva, and appears as a firm, fixed or mobile, unfixed mucosa (Fig. 7).

### The face in old age

The ever visible face often plays a more important esthetical and thus psychological role for elderly people than teeth and oral cavity, which cannot be seen with the closed oral rim. Apart from the bony (osseous) basis, the soft tissue parts (jaw and mimic muscles, subcutaneous adipose tissue, skin) are very important for the aging process. There are many factors e.g. gender, nutritional status, individual disposition for general diseases that influence these processes. Some exogenic factors e.g. smoking, alcohol, and solar radiation have negative effects. The loss of teeth and the resulting changes of the osseous relations and the atrophy of facial bones intensify the aging appearance of the facial soft parts and present the image of the aged face (Fig. 6, 8).

The loss of osseous and dental support due to edentulism and the age-related loss of the muscular tone lead to a so called perioral collapse. The modiolus, a nodular ligament bundling the mimic muscles of the lower and middle face (Fig. 9) shifts to caudal. The consequences are lip inversion and the decrease of the vertical dimensions of the upper lip. Additional age-correlated lip changes such as a general reduction of the lip volume together with the loss of the lip vermilion, or the fading of the lip vermilion due to decreased vascularization, the flattening of philtrum and cupid's bow, or hanging labial angles have quite a negative influence on the appearance of the lower face (Fig. 10). The decreasing elasticity of the upper lip of elderly people with full or partial dentition implicates that the lower anterior teeth become more visible when opening the mouth. Numerous fine wrinkles spreading radially from the lips are common in elderly smokers. Angular cheilitis is quite often found in senior citizens with lip changes.

### Implantological restoration for aging patients

The demographic development, and the loss of teeth at a greater age increase the need for implantological restorations in elderly patients. On the one hand patients do not want to accept removable prostheses, and on the other hand due to a late loss of teeth, adaption to a full prosthesis is often impossible. Even patients who had worn a full prosthesis for a long time, often require implant supported, fixed or removable prostheses, especially af-



NEW IMPLANTS, NEW ABUTMENTS  
**LIBERTY OF CHOICE**  
NATURALLY FROM **CAMLOG**

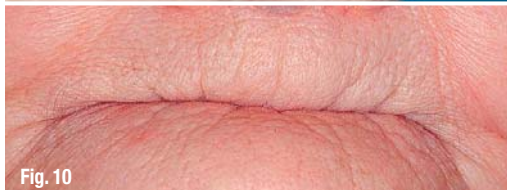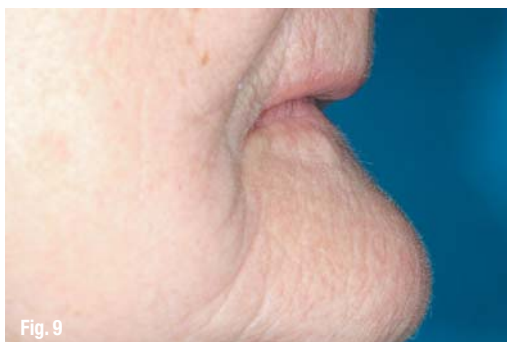
Reliable implants, patented Tube-in-Tube™ connection, and from now on as an option: platform switching. Camlog offers more. More information: [www.camlog.com](http://www.camlog.com)

a perfect fit®

**camlog**

**Fig. 9** 75-year-old female patient: Profile of the lower face: "Witch chin".

**Fig. 10** 81-year-old female patient: Appearance of the lips in edentulism.



ter their full prosthesis has become insufficient due to anatomical changes or physiological aging. The psychological effect is also important. The full prosthesis, which many people know from their parents and grandparents, is negatively associated with age. Therefore, many "young elderly" favor implant restorations.

There are no medical and scientific reasons for an age limit with regard to dental implants. Clinical studies of recent years have shown that neither age, nor most of the age-related diseases, bear any risk factors for implant prognosis. This is also the case for parameters such as the stability of the implant or periimplant resorptions. In addition to the medical history (anamnesis), a corresponding frequency of certain diseases and multimorbidity, some facts have to be taken into account: With regard to older patients one has to look at the generally reduced blood flow (circulation) and the changes in the gingival region. Peculiarities within the operative site must also be considered.

The lower jaw bone of young patients is internally and externally supplied with blood. In elderly patients the blood vessels of the bone atrophy, so that the blood circulation can mostly be guaranteed by the periosteum. Thus, the jaw bone should only minimally be deperiosteated during surgery. Given the ideal case and manageable conditions, even a stamping technique may be possible. Of course prosthetics also have to be adapted to the conditions of elderly people. In general one has to count on limited fine motor skills, which are often due to health impairments e.g. stroke aftermaths. In those cases it is convenient to refrain from complicated bolt constructions and favor e.g. telescope or conical telescope crowns, which can easily be removed and cleaned. Concerning the increasing number of elderly people with implants, one has to keep in mind, if or to what extent the risk of periimplantitis for this group of patients will play an important role in the

future. The age-related changed immunology may have a negative influence on this.

Meanwhile expert associations have realized that gerostomatology or geriatric implantology will become more important in the near future. Accordingly the German Association for Dental Implantology (DGZI) has developed a special study group modul for geriatric implantology.

### **\_Conclusions for everyday practice**

Dentistry is becoming more important, especially for senior citizens and as a consequence there is an increasing demand for dental implants. With respect to general anamnesis and determined age-specific changes, the aging patient can be treated well and adequately, also allowing for his or her fine motor skills. We even talk about the "young elderly", who want to retain their lifestyle without being bothered by removable and loose dental prostheses. Gerostomatology and especially geriatric implantology will become more important in the future, since edentulism will considerably decrease in younger people in the coming years.

### **References**

This publication is a reviewed, updated and especially dedicated to implantologists version of the following article by the first-mentioned author:

Götz, W.: Gesicht und Mundhöhle im Alter. *Face* (1/2007), pp. 8–14

A reference list is available on request from the first mentioned author.

### **\_Figure sources**

We want to express our special thanks to the following persons for providing the figures for the present paper: Prof Dr H Stark (Bonn University, Dept. of Prosthodontics: 1, 2, 7, 8, 10; Prof Dr H-M Schmidt (Bonn University, Dept. of Anatomy): 9.

|   |                 |
|---|-----------------|
| <b>_contact</b>   | <b>implants</b> |
| <p><b>Prof Dr med Werner Götz</b><br/>                 Rheinische Friedrich-Wilhelms-University Bonn<br/>                 Dental Clinic<br/>                 Department of Orthodontics<br/>                 Oralbiological Research Laboratory<br/>                 Welschnonnenstr. 17<br/>                 53111 Bonn, Germany<br/>                 Phone: +49-2 28/28 72 21 16<br/>                 Fax: +49-2 28/28 72 25 88<br/>                 E-mail: wgoetz@uni-bonn.de</p> |                 |

WHATEVER  
**YOUR PATIENTS**  
NEED

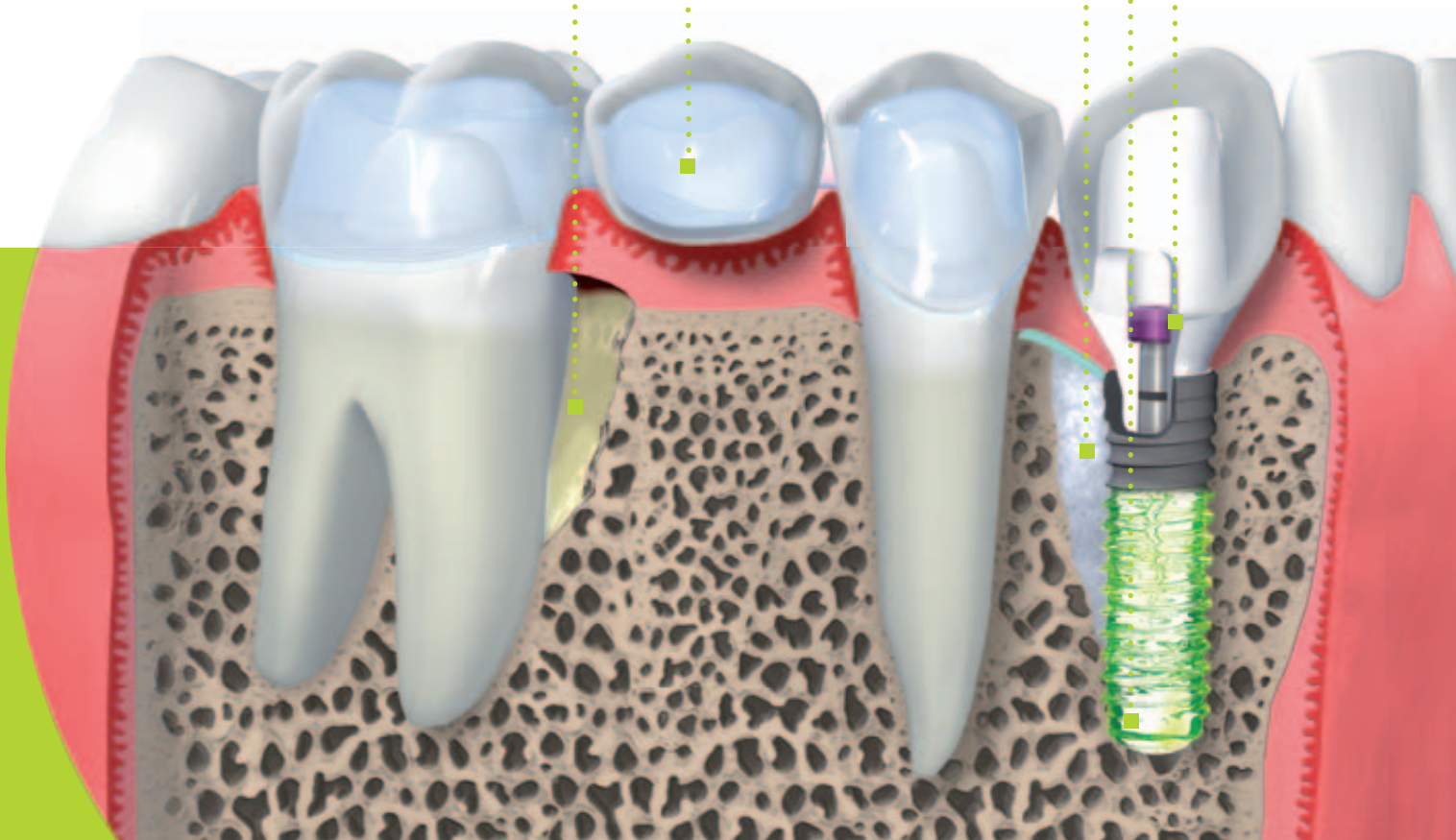
Straumann® CAD/CAM Solutions

Straumann® Emdogain

Straumann® Dental Implant System

Straumann® SLActive

Straumann® BoneCeramic



**SURGICAL, RESTORATIVE, AND REGENERATIVE SOLUTIONS BY STRAUMANN**

Whatever treatment is needed, Straumann offers the right solution to achieve optimal results. Straumann is dedicated to high quality products designed to meet biological principles. Our wide range of innovative products includes surgical, restorative and regenerative solutions as well as the latest in CAD/CAM technology.

COMMITTED TO  
**SIMPLY DOING MORE**  
FOR DENTAL PROFESSIONALS

# Soft Tissue Integration in the Neck Area of Titanium Implants— an Animal Trial

**authors\_** S. Allegrini Jr<sup>a,c</sup>, M.R.F. Allegrini<sup>b</sup>, M. Yoshimoto<sup>c</sup>, B. König Jr<sup>d</sup>, R. Mai<sup>a</sup>, J. Fanghänel<sup>a</sup>, T. Gedrange<sup>a</sup>

<sup>a</sup> Department of Orthodontics, Preventive and Pediatric Dentistry, Ernst-Moritz-Arndt University Greifswald, Germany

<sup>b</sup> Department of Periodontology, Odontologic Center of Militar Policy, São Paulo, Brazil

<sup>c</sup> Department of Oral and Maxillofacial Surgery, Camilo Castelo Branco University, São Paulo, Brazil

<sup>d</sup> Department of Anatomy, Institute of Biomedical Science, University of São Paulo, São Paulo, Brazil

First published in: *Journal of Physiology and Pharmacology*, 11/2008, 59 Suppl 5: 117–32.

## Summary

Dental implant materials are required to enable good apposition of bone and soft tissues. They must show sufficient resistance to chemical, physical and biological stress in the oral cavity to achieve good long-term outcomes. A critical issue is the apposition of the soft tissues, as they have provided a quasi-physiological closure of oral cavity. The present experiment was performed to study the peri-implant tissue response to non-submerged (1-stage) implant installation procedures. Two different implants types (Nobel Biocare, NobelReplace® Tapered Groovy 4.3 x 10 mm and Replace® Select Tapered TiU RP 4.3 x 10 mm) were inserted into the right and left sides of 8 domestic pigs (*Sus scrofa domestica*) mandibles, between canines and premolars and immediately provided with a ceramic crown. Primary implant stability was determined using resonance frequency analysis. Soft tissue parameters were assessed: sulcus depth (SDI) and junctional epithelium (JE). Following 70 days of healing, jaw sections were processed for

histology and histomorphometric examination. Undecalcified histological sections demonstrated osseointegration with direct bone contact. The soft tissue parameters revealed no significant differences between the two implant types. The peri-implant soft tissues appear to behave similarly in both implant types.

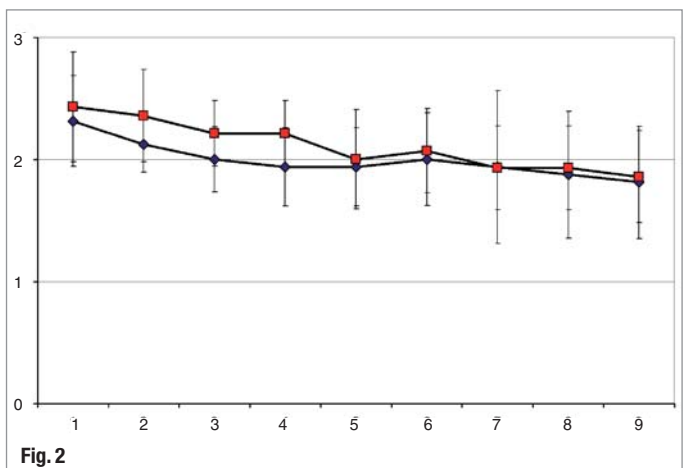
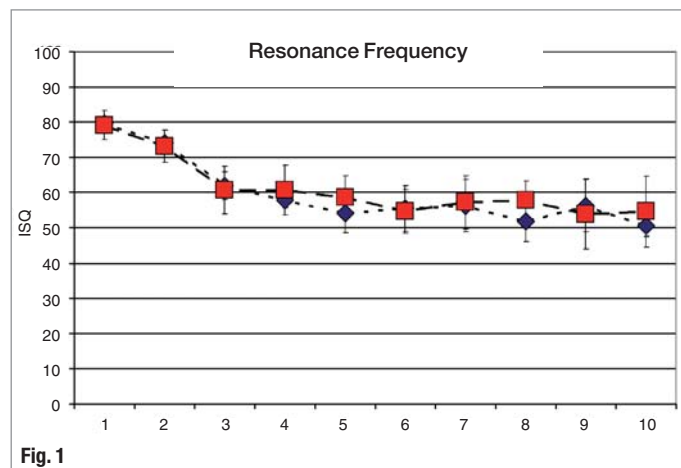
## Introduction

The periodontal tissues have the important function of gingival protection that means to provide a seal against the contaminated environment of the oral cavity. The soft tissue barrier around implants closely resembles that one around the teeth.<sup>1</sup> The marginal soft tissue integration plays a fundamental role in establishing an effective seal between the oral environment and the endosseous part of a titanium implant. Generally, the peri-implant mucosa is recognized as a scar tissue, exhibiting an impaired resistance to bacterial colonization.<sup>2</sup>

In attempts to enhance esthetics and to facilitate technical processing, other materials besides tita-

**Fig. 1\_** Results of Resonance Frequency analysis (t-test). Red color = NobelReplace® Tapered Groovy and blue color = Replace® Select Tapered TiU. The implant stability quotient (ISQ) results show the stability in scale from 0 to 100 Hz.

**Fig. 2\_** Results of SDI measurement analysis (t-test) in millimeters. Red color = NobelReplace® Tapered Groovy and blue color = Replace® Select Tapered Ti.

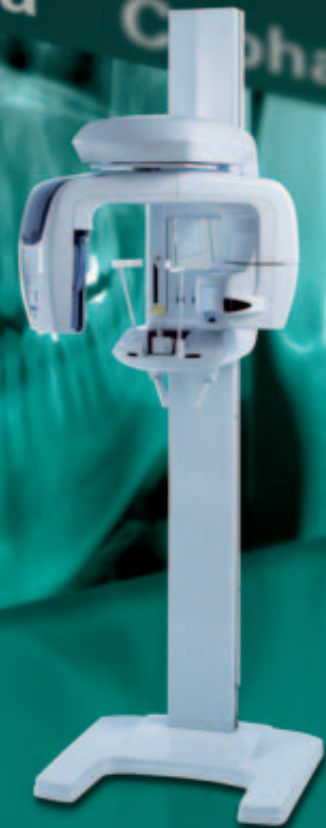
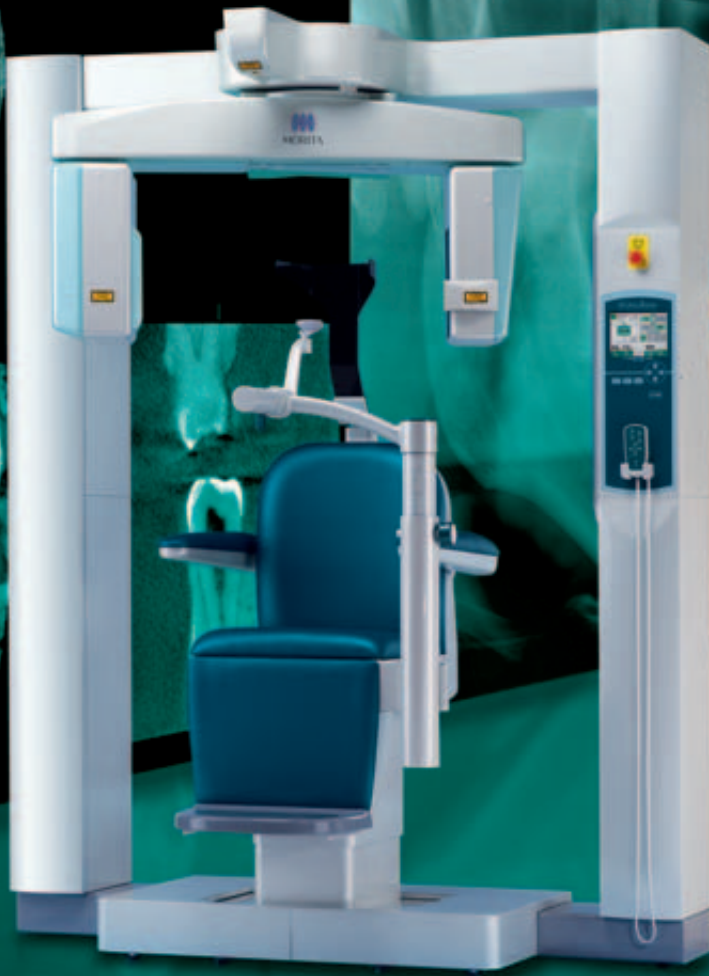
3D

Panorama

Veraviewepocs 2D/3D

3D Accutomo 170



Now: the NEW  
Veraviewepocs 3De  
for the entry into  
digital 3D X-rays


## The Number One in Every Class

 J.MORITA MFG.CORP.

Whether your interest is digital panoramic, cephalometric or 3D imaging – at J. Morita you always get the best device for the most precise diagnoses. As a pioneer in volume tomography we are familiar with the high requirements of diagnosticians. Our wide variety of devices and choice of combinations provide you with the sharpest imaging of details down to 80 µm.

From the first step, upgradable 2D devices, to the basic version Veraviewepocs 3De and the high-quality X-Ray CT unit 3D Accutomo 170, one thing always remains unchanged: You obtain the highest imaging quality from the lowest effective radiation dose and the shortest scan times. Nothing is more elementary than the correct diagnosis.

Trust the number one in the class! We would be happy to advise you. Phone +49 (6074) 836-0 or visit our website at [www.jmoritaeurope.com](http://www.jmoritaeurope.com)



**Volume Size**  
40 mm x 40 mm  
60 mm x 60 mm  
80 mm x 80 mm  
100 mm x 100 mm  
170 mm x 120 mm

Thinking ahead. Focused on life.

  
**MORITA**



nium have been used in the marginal, transmucosal part of the implant. A good long-term prognosis of implant therapy is related to sustained osseointegration and a proper mucosal/implant barrier protecting the bone tissue against factors released from the oral environment.<sup>3,4,5</sup> A carefully insertion technique and sufficient stability of the implants are essential factors to correct healing of the soft tissues. An insufficient primary stability causes bad healing and the premature loss of the implant.

The gingival and the periimplant mucosa are covered by a keratinized oral epithelium, which is continuous with the JE with a length 2 mm and a connective tissue (CT) zone with a height 1 to 2 mm.<sup>6,7,8</sup>

The JE of the periimplant mucosa is attached to the implant surface via hemidesmosomes and basal lamina<sup>9</sup>. In case of cementum layer absence most fibers in the CT run in a parallel direction to the implant surface,<sup>1,6</sup> as well as in the coronal-apical direction or circumferentially oriented.<sup>2</sup> Owing to the absence of the extrinsic fiber cementum on the implant surface, no fiber attachment at implants is possible.

Smooth surface has been shown to guarantee decent soft tissue attachment on material surface. Such fibers appear to be more prominent on microtextured compared to smooth transmucosal surfaces.<sup>2</sup> The thickness of the CT depends on the implant material and the stage of healing.<sup>9,10,11</sup> Although a direct connective tissue contact (CTC) was observed commonly for machined, roughly sandblasted, and plasma-sprayed implant surfaces, the collagen fibers don't show any signs of perpendicular insertion to the respective surfaces.<sup>1,6,8</sup>

However, as previous studies have also demonstrated, the surface texture significantly influences fibroblast and epithelial cell attachment, it was suggested that a certain roughness surface is needed for an optimal soft tissue sealing.<sup>12</sup>

Proper dimension and function of the soft tissue seal around dental implants is considered to be a pre-

requisite for achieving long term stable peri-implant conditions.<sup>6</sup> Accordingly extensive research has been performed to investigate the biological soft tissue seal at different types, materials and roughness of dental implants.<sup>6,8,13</sup> The biocompatibility of the material used in the transmucosal part of the implant may therefore be a factor of importance for treatment success. Therefore, the aim of the present study is to investigate the soft tissue integration of non-submerged titanium implants types in pig models.

### Material and Methods

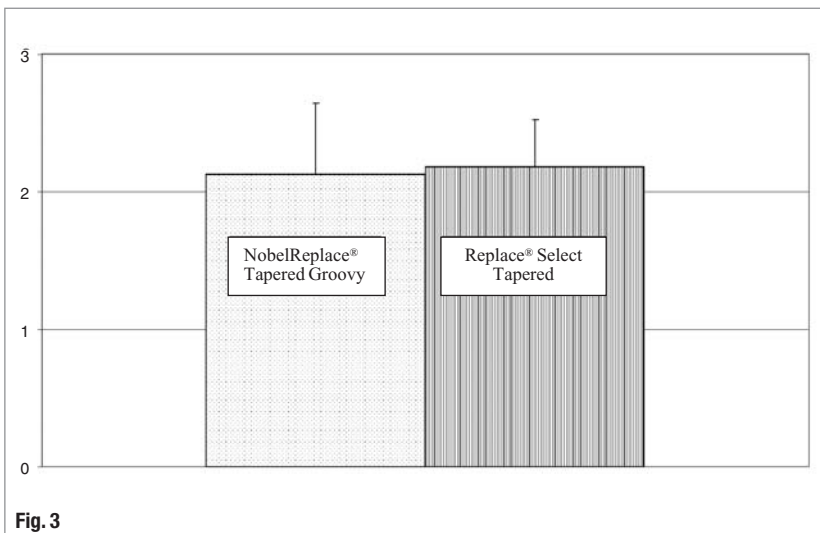
In this study two different NobelBiocare implants types (NobelReplace<sup>®</sup> Tapered Groovy 4.3 x 10 mm and Replace<sup>®</sup> Select Tapered TiU RP 4.3 x 10 mm) were inserted respectively into the right and left mandibles of pigs (*Sus scrofa domestica*) according to a uniform protocol. Eight animals from 15 to 16 months old and average weight of 80 kg were used.

The protocol of this study was approved by the Ethical Committee for Animal Research LVL MV/TSD/7221.3-1.1-037/05. Mandibular premolars P2-P4 were extracted bilaterally. After 3 months of healing, the screws titanium implants were fixed between the canines and molars (a total of two implants per animal). All implants were inserted by a standard surgical technique of implant system. The implants shoulders were at the ridge crest level after placement. In one of the eight animals used in this research the implant Replace<sup>®</sup> Select Tapered TiU was not installed due to preexistence local gingival inflammation.

All implants were carried out by one person to reduce the application fault. The implants were immediately provided with a ceramic crown (Ceramic Coping Easy Abutment<sup>™</sup>, Nobel Biocare, Germany). Then the Resonance Frequency Analysis (RFA) of each implant was measured to analyze and evaluate the implant-bone stability. The Implant Stability Quotient (ISQ) values were measured by Osstell<sup>™</sup> (Integration Diagnostics, Göteborgsvägen, Sweden). The analysis results show the stability in scale from 0 to 100 Hz. The RFA is based on abutment of implant to evaluate the clinical implications. This method is used for evaluating healing and quantitative measurement of the osseointegration.

The surgical procedures were accomplished in the animals under general anesthesia (i.v. injection into v. auricularis caudalis) of ketamine hydrochloride 150-200 mg (Ketamin, Belapharm, Vercha, Germany), droperidole 4.0-7.0 mg (Droleptan, Janssen Pharmaceutical, Oxon, UK) and Faustan 4.0 mg (Temmler Pharma, Marburg, Germany). In addition, approximately 1-2 ml of 2% Xylocaine<sup>®</sup>/Epinephrine 1:50.000 was injected at the surgical site to reduce bleeding. No plaque control program was used in this study. To assess the repair process and bone remodeling,

**Fig. 3** Representative histomorphometry (t-test) of gingival SDI results to the implants NobelReplace<sup>®</sup> Tapered Groovy (2.13 mm) and Replace<sup>®</sup> Select Tapered TiU (2.179 mm) obtained by light microscopy.



# Bienvenido a Barcelona!

1st European Implant Direct Congress

October 23rd - 25th 2009

Send us your best cases and  
**Win trip to  
Barcelona!**

**Challenging  
Conventional  
Thinking in  
Implant  
Dentistry**

## Program Preview

**Congress at COEC** ([www.coec.cat](http://www.coec.cat))  
leading dental training center

### Live surgeries

Dr. Pedro Peña (Spain)  
Dr. Marius Steigmann (Germany)

## Congress Speakers

Dr. Gerald Niznick (USA)  
Prof. Dr. Xavier Aragones (Spain)  
Dr. Ioannis Vergoullis (Greece)  
Dr. Alexis Stamou (Greece)  
Dr. Fernando D'Avenia (Italy)  
Dr. Pedro Peña (Spain)  
Prof. Dr. Jürgen Becker (Germany)  
Dr. Frederic Hermann (Switzerland)  
Dr. Jarek Pospiech (Poland)  
Dr. Domenico Sfondrini (Italy)  
Dr. Marius Steigmann (Germany)  
Dr. Pedro Guitian (Spain)  
Dr. Waldemar Festenburg (Austria)  
Dr. Jan-Willem Vaartjes (Netherlands)

### Entertaining social and cultural program

Relax and enjoy the Olympic harbour  
or explore Barcelona by bicycle

### Top participation options

4\*\*\*\* Package 335 Euro per person\*

5\*\*\*\* Package 435 Euro per person\*

\*includes accommodation from the 23rd to  
the 25th October 2009, reception, entry to the  
congress, evening program



**Register today!**

[www.implantdirect.eu](http://www.implantdirect.eu)

Tollfree Infoline 00800 4030 4030


[barcelona@implantdirect.eu](mailto:barcelona@implantdirect.eu)



**Implant  
Direct™**

simply smarter.

**Fig. 4** General view of undecalcified implant neck region (NobelReplace® Tapered Groovy) and bone/gingiva structure. Morphological condition was observed with aldehyde–fuchsin–Masson–Goldner staining. Destructive changes of the peri-implant bone were not found. Histologically, peri-implant gingiva showed similar structure to that of the gingiva around natural teeth.



during the healing period, intravenous fluorochrome substances injections were used. Intravital fluorochrome staining was performed on days 14 (2% tetracycline, 10 mg/kg bodyweight (yellow)), and 28 (1% calcein, 5 mg/kg (light green)). 56 (6% xylenol, 1.5 mg/kg (orange)).

Two soft tissue parameters were assessed: sulcus depth (SDI) and junctional epithelium (JE). Periodontal probe was realized with a periodontal millimetric metallic instrument, calibrated in 0.5 mm (PCPUNC-156, HU–Friedy®). Standard t-test was used to calculate the significance of data differences ( $p \leq 0.05$ ) in the SDI and primary stability of the implants. In order to achieve minimum error in measurement, probe was carried out twice in all SDI by the same operator and the average was used in the test.

After 70 days postoperatively, the animals were killed with an intracardiac injection of a high dose (5 mg/kg) of pentobarbital natrium (Eutha 77, Essex-Pharma, München, Germany). The implants/bone complex blocks were removed, fixed in formalin 4% and embedding with Technovit 9100 New® (Kulzer & Co, Wehrheim, Germany). The histological preparations were processed in agreement with the technique established by Donath.<sup>14</sup>

## Results

The results of Resonance Frequency showed no differences in stability (primary and in the end of investigation) between both kinds of implants. The standard and adequate primary stability of the implants obtained after surgical installation allowed an equilibrated healing of soft tissues. Since the first to the last week soft tissue parameters were assessed. All investigated implants showed clinically a light inflammable mucous hypertrophy and low plaque accumulation.

The data in Fig. 1 represented in numbers the weekly application of Resonance Frequency in the NobelReplace® Tapered Groovy and Replace® Select Tapered TiU implants until the animals sacrifice. The implant stability quotient (ISQ) results are showed in scale from 0 to 100 Hz. The distribution of ISQ index showed the primary stability to the both implants in the day of insertion (average 80 Hz). In the following

three weeks it was observed a decline of ISQ index to 60 Hz. From this point on the ISQ index presented variations otherwise they were kept between 50 and 60 Hz until the end of the 70 days experiment. The implants comparison did not present a significant difference ( $p \leq 0.05$ ). The different morphology and neck superficial texture between the two implants tested did not interfere in the results of this analysis.

The data obtained from 1<sup>st</sup> to 9<sup>th</sup> week probing of the SDI are showed in Fig.2. The SDI of gingival in the mandibles of pigs remained in the average of 1.5 and 2.5mm to the both implants. Although there was a small difference in the first 3 post-operative weeks, probably due to the tissue cicatrisation process, the final resultant remained slightly below 2 mm. The TiU superficial treatment until the top of NobelReplace® Tapered Groovy implant did not present significant statistic differences when compared to the one without treatment, during gingival sulcus measurement. The numeric result of the weekly gingival evaluation of each installed implant was submitted to t-test analysis. The results demonstrated medium values from 2.4 mm until 1.8 mm, however without statistics difference  $\leq 0.05$ .

During the 70 days after implantation, no gingival resection was observed. Between vestibular gingival sulcus and width of inserted gingival nothing was observed. The cervical section of the implant showed sufficient esthetic solution under point of view of biological functions.


The histomorphometry of gingival SDI was also obtained through images using a Universalmikroskop Axioplan Zeiss (Oberkochen, Germany) connected to a high-resolution video camera Colorview II SIS (Olympus Europa GmbH, Hamburg, Germany) and one SIS, Software Image analysis 3.1 (Soft Imaging System GmbH, Münster, Germany), for each implant inserted. The numeric results of gingival SDI under t-test of the studied implants showed no significant differences on its final average data. The results represented in the graphic (Fig. 3) showed under this analysis, a numeric balance comparing the two implants necks.

## Histological findings Figures 4–9

The histological evaluation of the implant-soft tissue interface exhibited no morphologic and substantial differences between the two implant types. Histomorphometry was possible in all specimen (Figs. 4, 5, 6).

The bone markers under fluorescence microscopy showed intense bone deposition and well organized lamellar formation (Fig. 7).

Longitudinal section in polarized light of implant with TiU surface showed functionally oriented collagen fibrils in SDI (Fig. 8). Thick horizontal and vertical collagen fibers were found. The vertical fibers were



running from the periosteum and the alveolar crest towards the oral epithelium (Fig. 8)

Collagen fibers bundles were noted following parallel to the crown in vertical plane (white arrows). Close to the abutment surface, collagen fibers changed their direction into a oblique orientation to the bone crest (yellow arrows). In all specimens the mucosa was covered by keratinized oral epithelium that was continuous with the parakeratinized sulcular epithelium that lined the lateral surface of the periimplant SDI (Fig. 9). The sulcular epithelium was continuous providing an epithelial union between the implant and surrounding periimplant mucosa. The different implants did not demonstrate bone crest lost on the neck level (Fig. 9). The morphological characteristic of bone tissue observed in the two different surfaces neck did not allow the penetration of the tip of periodontal probe beyond this level.

## Discussion

One of the primordial factors to long time osseointegration implants success is the health maintenance of surrounding tissues. This study was originally designed to compare the structure of peri-implants tissues between surface-treated and non-treated neck implants. The mechanism for the termination of the epithelial migration along the surface of dental implants is not yet known. It may be argued, therefore, that differences may occur in the soft tissue attachment to implant transgingival or abutments designed with smooth or rough surfaces. The ceramic material used in the abutment portion of the implant was of decisive importance for the epithelial-connective tissue attachment in this study. Studies *in vitro* and *in vivo*<sup>15, 16, 17</sup> showing that the orientation and proliferation of epithelial and CT cells on titanium surfaces are influenced by the topography of the material surface. According to recent research, the adherence and spreading of epithelial cells on metallic surfaces, such as titanium and gold alloy, are good, especially if the surface is smooth.<sup>6</sup> As a consequence of the fact that rough surfaces accumulate and retain more plaque than smooth surfaces, nowadays, most implant systems use a highly polished titanium in the transmucosal part.<sup>18</sup> A polished implant collar may

provoke crestal bone loss associated with "non-load" factor, but, similarly to microgap, bone loss can be avoided by leaving smooth implant neck above the bone level.<sup>19, 20</sup> According a study from Buser et al.<sup>2</sup> the authors speculated that plasma spray titanium surface promote a better attachment of CT fibers.

The sulcular epithelium must remain stretchable to compensate the movements of soft tissue. It is a strategically important interface to seal the underlying tissues and is the most important tissue for peripheral defense against the repeated or continual bacterial challenge. In the study of Schupbach and Glauser<sup>21</sup>, the autor concluded that the junctional epithelium (JE) serves as a seal to restore mucosal continuity and to form a compartment for peripheral defense.

JE and CTC are important parameters in providing information about the location of the apical extension of JE cells, the crestal bone height and extent of bone-implant contact. Some authors suggest that certain height of periimplant mucose is needed to allow appropriate conjunctive and epithelium insertion. If this soft tissue dimension is not adequate bone resorption can occur to ensure the "biological width".<sup>6</sup> The average of bone loss to osseointegrated implants reaches less that 1.5 mm in the first year, continuing < 0.2 mm in the following three and five years.<sup>19</sup>

The periimplant health monitoring and maintenance are extremely dependent on trusty diagnostic tests. Therefore, it is indispensable the use of clinical diagnostic parameters that correctly identify inflammatory alteration, even in its initial level. As periodontal and periimplant tissues are apparently similar, there is a tendency to use periodontal parameters to evaluate clinical state of the implant surrounding tissues. According Lang et al.<sup>22</sup>, probing consists a good indicator to evaluate healthy or unhealthy status of periimplant tissues.

The use of Osstell® permits the non-invasive measurement of quality of implantation. Furthermore, it is possible to measure the increase or decrease in implant stiffness through initial assessment of stability (made immediately after placement), and thus to monitor the healing process. The implant stability is subdivided into primary (immediately after implantation) and secondary (heal up) stability. The

**Fig. 5** Photomicrography under light microscopy. Aldehyde-fuchsin-Masson-Goldner staining. Bone levels with bone to implant contact. The sample demonstrated a similar distance from the bone to implant like in healthy tooth. Morphological condition was observed with aldehyde-fuchsin-Masson-Goldner staining.

**Fig. 6** Photomicrography under light microscopy. Region of implant neck Replace® Select Tapered with mineralized new bone formation. Starting point of sulcus depth measurement. White line shows the beginning of gingival anchorage to implant. Morphological condition was observed with aldehyde-fuchsin-Masson-Goldner staining.

**Fig. 7** Photomicrography under fluorescence microscopy. Intense contact areas of new bone with implant surface. Tetracycline – yellow, Calcein – green, Xylenol – orange, Bar – 300 µm.

in cooperation with

**Gothaer/AMG**

Stiftung **Mensch & Medizin**<sup>®</sup>

**Free of cost!**

## Fullcoverageservice

### 7 reasons for the license concept of Fullcoverageimplant

- ✓ scientifically documented Periointegration<sup>®</sup>
- ✓ first business formula for success in implantology
- ✓ 10 years of recall motivation for patients
- ✓ 10-year guarantee secured by Gothaer/AMG
- ✓ 200 euro\* fixed cost allowance for prosthetics
- ✓ surgical cost reimbursement\*
- ✓ Germany-wide presence in the media

\*according to General Terms and Conditions

**Information on Fullcoverageimplant**

Yes, please send me information on a license partnership.  
Please fax coupon to (0)234 9010262. Or post to Clinical House Dental,  
Am Bergbaumuseum 31, 44791 Bochum.

Name: \_\_\_\_\_

Address: \_\_\_\_\_

Phone: \_\_\_\_\_

Email: \_\_\_\_\_

www.Stiftung-Mensch-und-Medizin.de  
www.vollkaskoimplantat.de



**New!**

- 3.5 mm implant diameter
- extended guarantee 200.00 euro\* fixed cost allowance for prosthetics
- Germany-wide media presence for license partners



**Now!**

# Periointegration®

...instead of periimplantitis

In cooperation with Fraunhofer Institut and renowned universities, intensive basic research has been conducted in the field of modern mechanically resistant coating. For the first time ever, a technology transfer from aerospace technology permits the coating of titanium surfaces with zirconium nitride and zirconium oxide.

Recent scientific findings in the field of surface technology have shown that zirconium nitride significantly reduces the colonization of periodontal-pathogen germs on the biofilm and considerably favors the formation of a dentogingival seal. (Größner-Schreiber et al. 2006).



## Fullcoverageimplant®

...we know what to do

The comprehensively insured implant is the first business concept for success for implantology combining technology, guarantee and media coverage in a Germany-wide recognisable media concept. Inform yourself on the advantages for your practice and the access conditions for license partners.

**Phone: +49 (0) 234 90 10 260**

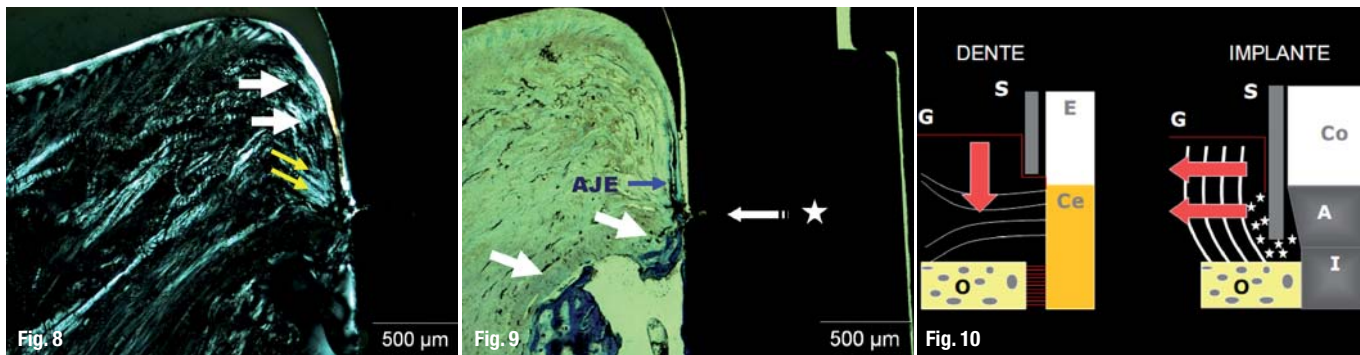
**info@vollkaskoimplantat.de**

**www.vollkaskoimplantat.de**

Clinical House Dental GmbH

Am Bergbaumuseum · 44791 Bochum/Germany

Phone +49 (0)234 90 10 260 · Fax +49 (0)234 90 10 262



**Fig. 8\_** Photomicrography under polarized microscopy. Parallel collagen fibers between the implant surface in JE (white arrows). Oblique fibers in direction to bone crest (yellow arrows). Bar – 500 µm.

**Fig. 9\_** Photomicrography under light microscopy. Bone crestal level (white arrows). AJE covered to parakeratinized tissue (blue arrow). Region between implant neck and abutment (star). Toluidine blue. Bar – 500 µm.

**Fig. 10\_** Periodontal probe effect in teeth (left side) and in implant region (right side). On the left side of diagram, the metallic probe do not penetrate into JE because of the perpendicular fibers towards to cement. On the right side, besides penetrating into JE, the metallic probe keeps away periimplant mucose to lateral direction. (G) gingival; (O) alveolar bone; (S) periodontal probe; (Co) protetic crown; (E) enamel; (A) abutment; (Ce) cementum; (I) titanium implant. Source: Lindhe.<sup>22</sup>

primary stability is largely a mechanical parameter. Two parameters are particularly useful when evaluating implant stability. The first one is the location in the bone. The second one is the stiffness of the implant in the surrounding tissue. The stiffness can be viewed in three ways: first of all the stiffness of the implant components themselves. Here the geometry and material composition for implants play the important part. In a second view is the stiffness of the implant/bone interface (bond between the surface of the implant and the surrounding bone) and in the third view is the stiffness of the bone itself (determined by the trabecular/cortical bone ratio and the importance of length and type of used implants and the preparation technique depending on the bone quality and quantity.<sup>23</sup> The used of t-test on histomorphometry of the implant/bone samples permitted better quantification of primary stability after the surgical procedure than resonance frequency.

The results of this research demonstrate accentuate decline of ISQ index during the post-operative first 3 weeks. Implants installed in dense bone tissue show decreasing stability during osteointegration process. This reduce in anchorage may correspond to the remodel phase of necrotic tissue, followed by a bone apposition phase. According to Ueda et al.<sup>24</sup>, a high compression of bone tissue can cause cellular death (necrosis), leading to bone cortical resorption. Other authors showed direct correlation between high stress regions and bone reabsorption process Huiskes and Nunamaker.<sup>25</sup> When a local crestal bone resorption occurs, it is expected a reduce in AFR values in the subsequent weeks.

Moreover, it was observed in this study a relative equilibrium in AFR index after the 3<sup>rd</sup> week. After a long term, the implants reach stabile values non depending the bone density presented at the act of installation. The absence of loading over implants may have determined a stable phase between bone resorption and deposition performed by osteoclasts and osteoblasts during remodeling process; and in sequence the equilibrium in AFR index after the 3<sup>rd</sup> week post-operative.

Gingival evaluation in the present study was done by manual instruments and histological parameter. Probing procedures are frequently used for

periimplants disease diagnostics, so that special attention must be given to periimplantar probing depth (PPd) that is considered a crucial parameter to determine tissue conditions surrounding implants. Such conditions may influence the exam exactness.

Some scientific studies relate that perimplant mucose resistance may be lower due to the configuration and orientation of tissue fibers that surround implants.<sup>26</sup> The collagen fibers of conjunctive tissue are paralely arranged to the implant surface<sup>1, 8</sup> differing of the situation founded in teeth (Fig.10) where there are various fibers groups running from cement to conjunctive tissue and alveolar bone.<sup>26</sup> The periodontal probe tends to penetrate near to bone crest, apically to the JE in titanium implants.<sup>6, 8</sup>

Ericsson and Lindhe<sup>27</sup> observed that probing resistance offered by dental gingive is bigger than that offered by periimplant mucose. Berglundh et al.<sup>8</sup>, related that at both tooth and implant sites, the apical cells of the epithelium terminated approximately 1.0 mm to 1.5 mm coronal to the alveolar bone crest. Christensen et al.<sup>14</sup> found depth probing in the average of 2.18 mm to 2.28 in implants and 1.65 to 1.82 in teeth. In a recent comparative review about biologic width around teeth and implant, the authors found values nearly by 1.5 mm.<sup>26</sup> It is evident that the periimplant seal around implants tends to be longer than around teeth.<sup>26</sup> The findings in this research showed gingival SDI and JE varying from 1.8 mm to 2.4 mm for both implant types. These results are very similar to those found by Christensen et al.<sup>28</sup> Other study about unloaded implants showed values of 0.49 mm for SDI and 1,16 mm for JE after three months.<sup>1</sup> In a comparative research about different implants surfaces, the authors found that length of the JE was higher on machined (mean 2.9 mm) than on the acid-etched (mean 1.4 mm) and oxidized surface (mean 1.6 mm).<sup>29</sup> The authors supposed that the smooth surface may allow more pronounced epithelial downgrowth as was reported for rough surfaces. Nevertheless, the results of the present research did not demonstrate significant difference in the two implant necks. The probably stability of the alveolar bone crest observed in this work can be a difference mark towards the Glauser's work.<sup>29</sup> The penetration of the probe apparently deflects the

# Fast and Safe Bone Regeneration

soft tissue from the implant surface and the tip of the probe reaches the JE apically. The present study showed in both surfaces that the most fibers at the interface run in a direction more or less parallel to the implant surface. This result is in accordance with the literature.<sup>1,6,21</sup>

It was observed a small alteration of soft tissue with easy inflammable mucous hypertrophy. The existence of peri-mucositis was not confirmed through pathological test, but clinical examination. According to Lang et al.<sup>22</sup> the density of periimplant tissues in vivo influences in the probe penetration. In the presence of inflammatory tissue, the probe penetrated next to the crestal bone going through CT. However, in healthy tissue or with mucositis identified the supra crestal level. It was presented in this study that clinical healthy periimplant tissues showed a more rigid attachment and offered more resistance against probe penetration when compared with periimplantitis area. This way, probing means a reliable clinical procedure to monitor peri-implant tissues fast reading and repeatable.<sup>22</sup> Nevertheless, Smith and Zarb<sup>30</sup> relate that PPD is not a good predictor to periimplant bone alterations.

According Hermann et al.<sup>31</sup> dynamic changes were shown to occur within the components (SDI, JE and CTC) that constitute this stable structure, and their dimensions were found to be dependent on the presence/absence of microgap (interface) between the implant and abutment, and the location of the microgap (interface) in relation to the bone crest. A firm attachment of the mucosa to a tooth or an implant is a pre-requisite for peripheral defense and hemidesmosomes have a definite role in providing this attachment.

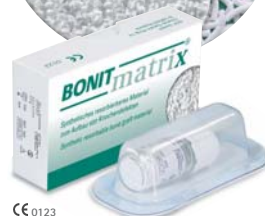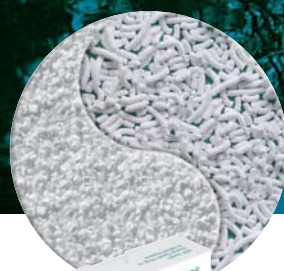
## Conclusion

The soft tissue parameters revealed no significant differences between the two implant types. The peri-implant soft tissues appear to behave similarly in both implant types. The kind of implantation and implant design play a decisive role for good primary stability. The aesthetic demands are of particular importance for the patients. However, these results need to be verified also in loaded conditions in clinical setting.

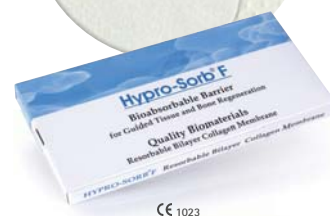*The Literature list can be requested from the editorial office.*

## Acknowledgements

The research was partly funded by a fellowship from the Alexander von Humboldt Foundation (BRA/1115625) and Nobel Biocare. The copyright permission was given from the Editorial Office of the Journal of Physiology and Pharmacology because we considered that work really interesting to our readers specializing in implantology area.



CE 0123



CE 1023

### Fast Bone regeneration with BONITmatrix®

BONITmatrix® is a proven bone graft material with considerable advantages for surgeons and patients.

- Excellent biocompatibility due to nanostructuring
- Integration into the natural bone remodelling
- Completely synthetic material assures high safety

Granulate and Package sizes:

|              |        |
|--------------|--------|
| 0,6 x 4,0 mm | 0,25 g |
| 0,6 x 4,0 mm | 0,50 g |
| 0,6 x 4,0 mm | 1,00 g |
| 0,6 x 0,3 mm | 0,25 g |

### Safe Barrier with Hypro-Sorb® F to prevent ingrowth of Soft Tissue

Bioresorbable Bilayer-Collagen membrane for Guided Bone- and Tissue Regeneration (GBR/GTR).

- Good biocompatibility
- Optimal handling characteristics due to high tensile strength
- Complete resorption after approx. 6 months

Membrane sizes:

|            |
|------------|
| 15 x 20 mm |
| 20 x 30 mm |
| 30 x 40 mm |

DOT GmbH  
Charles-Darwin-Ring 1a  
D-18059 Rostock  
Germany  
Tel: +49 (0)381-4 03 35-0  
Fax: +49 (0)381-4 03 35-99  
sales@dot-coating.de  
www.dot-coating.de

DOT is a leading supplier of innovative solutions for dental and orthopedic implants

**DOT**  
medical implant solutions



# Maxillary sinus floor augmentation using a nano-crystalline hydroxyapatite silica gel

A prospective study—Histological results after 3 months of healing

**authors** Luigi Canullo, DDS<sup>a</sup>; Iole Vozza, DDS<sup>b</sup>; Dr Fabrizio Caricato<sup>c</sup>; PhD Claudia Dellavia, DDS, PhD<sup>d</sup>

<sup>a</sup> University of Bonn, Germany.

<sup>b</sup> Assistant Professor, Department of Prosthodontics, University of Rome, Rome, Italy.

<sup>c</sup> Private Practice, Rome, Italy.

<sup>d</sup> Assistant Professor, Department of Human Morphology, University of Milan, Milan, Italy.

**Clinically, posterior maxilla** often represents a hardly suitable zone for implant placement due to insufficient available bone. Sinus floor elevation was developed to increase needed vertical height to overcome this problem (Wallace & Froum 2003, Del Fabbro et al 2004). Variable augmentation materials and techniques using various bone grafts and bone substitutes were frequently used to enable placement of posterior maxillary dental implants (Maiorana et al. 2000, Karabuda et al. 2001, Cammack et al. 2005).

A newly developed bone grafting substitute consisted of nanocrystalline hydroxyapatite (HA) and nanostructured silica (SiO<sub>2</sub>) (Nanobone, Artoss, Rostock, Germany) is now available for clinical application. It was described to be osteoconductive and biodegradable in a comparable manner to natural bone remodeling process (Henkel et al. 2004). Furthermore, clinical investigation demonstrated that Nanobone has osteoconductive and biomimetic properties and is integrated into the host physiological bone turnover at a very early stage (Gotz et al 2008). Canullo & Dellavia (2009), in a recent clinical

trial, showed that grafting of maxillary sinus floor using a nano-structured hydroxyapatite silica gel as bone filler is a reliable procedure in critical anatomical conditions after early healing period.

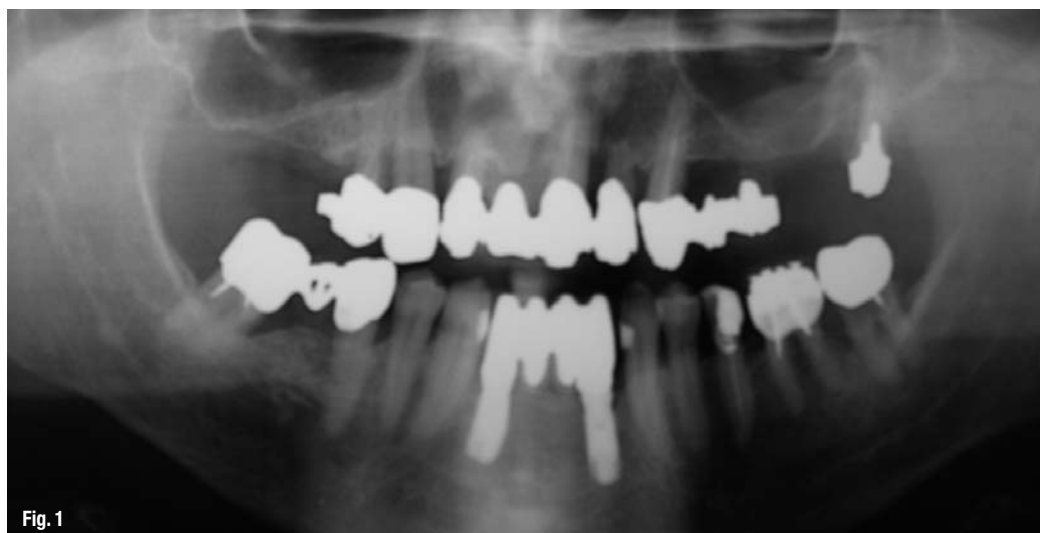
The aim of this prospective study was to evaluate tissue composition of augmented maxillary sinus floor 3 months after using of a nano-crystalline hydroxyapatite bone substitute. Histological analysis and bone-to-implant contact (BIC) assessment between the grafting material and inserted mini-implant were achieved.

## Materials and methods

### Patient selection

All procedures and materials in the present prospective study were approved by the local ethical committee, and all patients provided informed consent. Five patients (2 men and 3 women) in need for fixed implant-supported prosthesis in the posterior maxillae were consecutively recruited for the present study. The patients were in good general

Fig. 1 Preoperative panoramic exam.

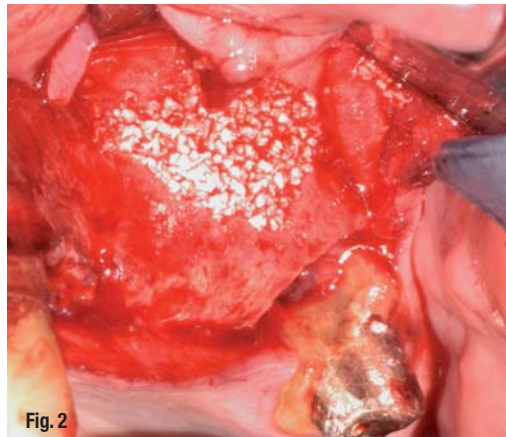


health and had a median age of 54 years that ranged from 43 to 72 years. All patients underwent comprehensive dental care and were instructed to maintain a high level of oral hygiene. In the present study, inclusion criteria that had to be fulfilled by all patients are listed in Table 1. Preoperatively, computerized tomography and digital panoramic examinations were acquired for antral anatomy evaluation (Fig. 1).

### Surgical procedure

Patients received 875 mg of amoxicillin/clavulanic acid (1 capsule/12h) one day before the surgery and for six days. After local anesthesia, crestal incision was made at the implant site and sulcular at the adjacent teeth if present. Subsequently, a vertical releasing incision was done at the distally and the muco-periosteal flap was raised. A rectangular or oval-shaped osteotomy was then prepared on the lateral aspect of the alveolar ridge under copious normal saline irrigation. The resulted detached "window" was elevated medially and apically while simultaneously reflecting the sinus membrane.

After adequate reflection, the sinus membrane was inspected for tears and Nanobone mixed with



**Fig. 2** Sinus lift grafted using nano-cristalline hydroxyapatite silica gel (Nanobone®); buccal view.

antibiotic solution (Lincocin 600 mg, Pharmacia Italia S.p.a., Milano, Italy) was placed incrementally at the superior aspect of the sinus and against the medial aspect of the grafted compartment created in the sinus cavity, according to Donath & Breuner (1982). The graft material was meticulously condensed at each stage (Fig. 2). A mini screw for osteosynthesis of 1.2 mm diameter and 13 mm in length (Sweden & Martina, Padua, Italy) was then positioned to maintain the space opened. This implant in fact kept the internally rotated sinus bone door con-

AD

## Magnification from Carl Zeiss - Your Company to grow with.

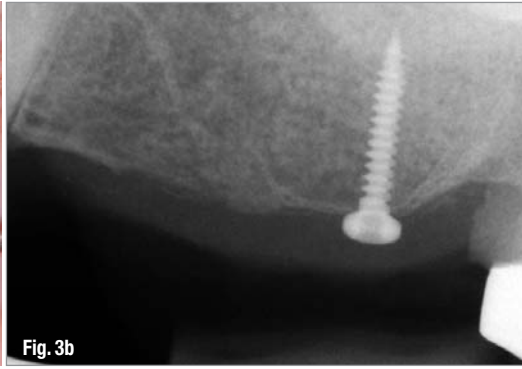
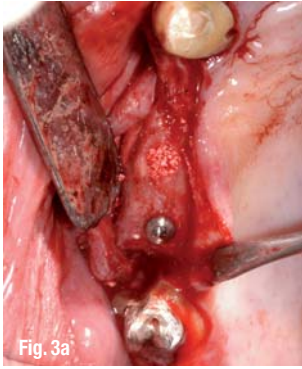
**OPMI® pico**  
Manual Dental Microscope

**OPMI® PROergo**  
Motorized Dental Microscope

**EyeMag®**  
Medical Loupes

*"The Dental Microscope has revolutionized endodontic therapy in an extremely short time."  
Dr. Peter Velvart, Zürich*

*"You can only treat what you see."  
Prof. Dr. Syngcuk Kim, University of Pennsylvania*



**Fig. 3a** Micro-screw inserted at the end of sinus lifting procedure (clinical occlusal view).

**Fig. 3b** Micro-screw kept the internally rotated sinus bone door constantly apart from sinus floor, contrasting eventual increased pressure in the operated sinus.

stantly apart from sinus floor, contrasting eventual increased pressure in the operated sinus (Fig. 3a and 3b). Single interrupted sutures were finally used for flap adaptation. Surgical procedure was applied unilaterally for each patient of this study.

The surface of used mini screw was treated first by cleaning process that was carried out using a solution of isopropyl alcohol and metilbutil-ethers. Then, sandblasting was performed with zirconium microspheres that sized 120 microns at 5 atms while applying a rotation impulse of 120° each 5 seconds. Sand was constantly set with a patented fluid vibrating process to control humidity (ZirTi Surface, Sweden & Martina).

**Second surgery and prosthetic restoration**

After a 3 month healing period (Fig 4a and 4b), a bioptical core containing the mini-implant was retrieved using a 3 mm trephine bur. In the same surgical step, implants were inserted. After 3 months of submerged healing, implants were restored.

**Histological assessments**

Samples were immediately immersed in buffered 4%-paraformaldehyde fixative solution with a pH of 7.7 for 5 days. The bone specimens were processed and undecalcified for histological analysis according to previous protocol.<sup>11</sup> Sliced longitudinal sections were then stained with toluidine blue/pyronine G and observed using a light microscope (Nikon Eclipse E600, Nikon, Tokyo, Japan) equipped with a calibrated digital camera (DXM1200, Nikon). At 40x microscopic magni-

fication, using a standard point-counting technique with a 100 test points grid, histomorphometric measurements of the tissue fractions occupied by, Nanobone, regenerated bone, and bone marrow were performed. Additionally, BIC was computed as the percentage ratio between the implant length distances in direct contact with newly mineralized bone and the implant total length.

**\_Results**

After 3 months of healing, varying amounts of newly formed bone were found through the specimens (Fig. 5). From the histomorphometric analysis, Nanobone residuals accounted for 47.35 % ± 5.20 % of the extracted bone volume, marrow spaces presented 19.30 % ± 3.20 % and bone occupied 33.35 % ± 4.1 % (new bone: 22.23 % ± 4.10%, and native bone: 11.12 % ± 4.20%). Well-mineralized regenerated bone with lamellar parallel-fibred structure and Haversian systems surrounded the residual Nanobone particles. Mean BIC was 17.75 % ± 2.9 %. No connective tissue was observed at the implant boundary surface (Fig. 6).

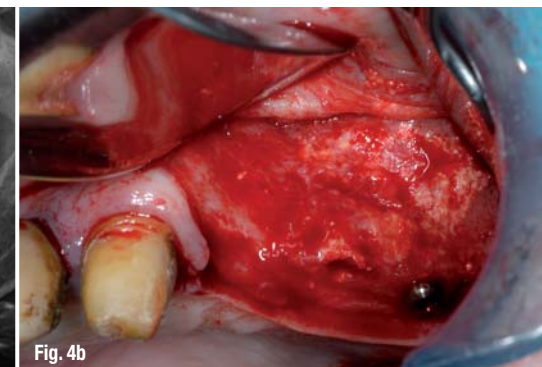
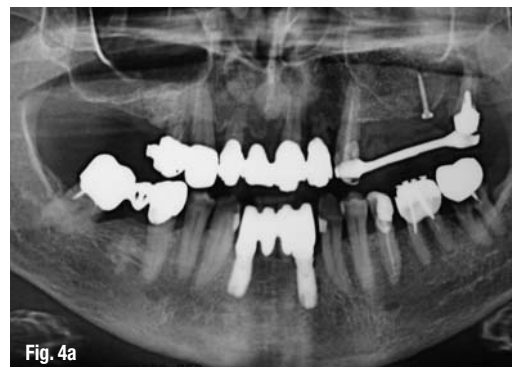**\_Discussion**

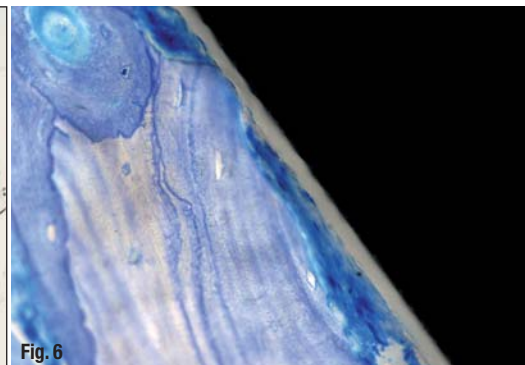
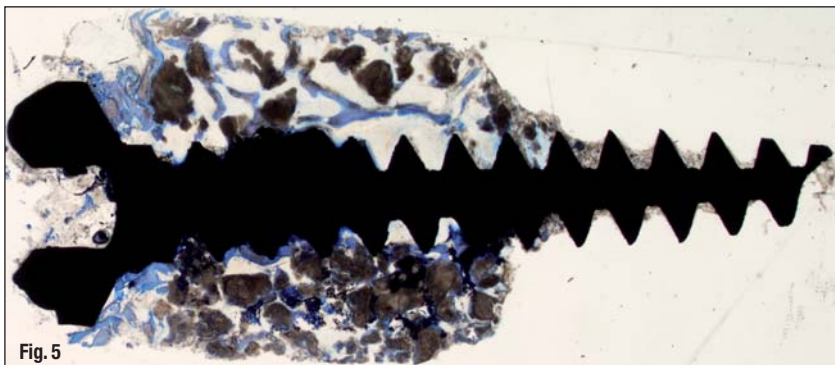
The result of this study indicated that Nanobone could be suitable for maxillary sinus floor augmentation as it proved osteogenic behavior, i.e. bone regeneration, at very early healing stage in critical vertical bone height conditions. This was demonstrated by histological and histomorphometric analyses carried out in the present study, in addition to immunohistochemical, SEM, and energy-dispersive X-ray analyses performed in other basic studies.<sup>4, 10, 11</sup>

According to Wallace Froum (2003) and Del Fabbro et al. (2004), 6 to 9 months were considered the optimal period for bone graft healing as the osteogenetic process was considered completed thereafter. However, the present investigation results showed that Nanobone presented a fast turnover compared to other biomaterials (Valentini et al. 2000, Tarnow et al. 2000). This might be correlated to the SiO<sub>2</sub> gel matrix of the material that is degraded and substituted by an or-

**Fig. 4a** Panoramic X-ray of the patient in Figure 1 after 3 months of augmentation.

**Fig. 4b** Clinically, buccal window appears filled of bone-like material.





ganic matrix and to the hydroxyapatite nanoporosity which would allow bone matrix proteins to adhere and promote differentiation of osteoblast precursor cells.<sup>4, 10, 11</sup>

As Literature<sup>6, 8, 18</sup> indicates that in case of severely resorbed maxilla required healing time should be between 6 to 12 months, demonstrated early healing and bone regeneration using Nanobone should encourage longer follow-up and further animal and clinical investigations concerning early implant loading.

Regarding the used mini-implant surface (ZirTi Surface, Sweden Et Martina) used in this study, the resulted mean BIC of 17.75 % was comparable to those in a canine model by Conner et al. In that study, mean BIC values were reported as 16.24 % for acid etched surfaces and 25.08 % for TPS after a 4-month healing period. Another animal study (Palma et al. 2006) reported mean BIC values of 14.3 to 17.6 % for turned implants and 37.3 to 44.7 % for oxidized implants after a 6-month healing period. Although it is hard to compare animal to clinical studies, the BIC values reported in the present and the quantity of new bone found at 3 months of healing could clinically assess the potential of this grafting biomaterial even in very early stages of bone maturation.

According to Literature (Becker et al. 1995, Buser et al. 1996, Tarnow et al. 2000, Wallace Et Froum 2003), the use of collagen barrier membrane to enhance bone regeneration in maxillary sinus augmentation to prevent soft tissues invasion was highly recommended. However in the present investigation, the absence of barrier membrane application to occlude buccal bone wall did not influence healing as histological outcomes of bone formation and absence of connective tissue were observed at the mini-implant boundaries (Fig. 6).

Finally, presented preliminary results encourage further research on this biomaterial in augmenting critical vertical bone conditions and immediate or early implant loading for a longer follow-up period and wider patient size.

### Conclusion

Within the limits of this clinical prospective study, it can be concluded that nano-crystalline hydroxya-

patite bone substitute showed good histological outcomes for augmenting maxillary sinus floor in critical bone volume conditions. Furthermore, the absence of covering membrane and 3-month healing period could clinically demonstrate the potential of this grafting biomaterial. In such a critical condition the use of a rough-surfaced mini-implant showed BIC values supposed to be effective also in case of functional loading.

*Acknowledgements:* The authors highly appreciated the skills and commitment of Dr Audrenn Gautier

*A literature list can be requested from the editorial office.*

**Fig. 5** Specimen stained with toluidine blue/pyronine G. Overview of the mini-implant positioned in sinus lift grafted with Nanobone. Total Magnification: 10x.

**Fig. 6** Specimen stained with toluidine blue/pyronine G. Regenerated bone (B) incorporating a Nanobone fragment (N) and a newly formed osteon in contact with the implant surface (I). Total Magnification: 200x.

### Table 1 Subject and study site inclusion and exclusion criteria

#### Subject inclusion criteria:

- \_ Need for fixed implant-supported prosthesis in the posterior maxillae
- \_ Age > 18 years
- \_ No relevant Medical conditions
- \_ Non-smoking or smoking ≤ 10 cigarettes/day (all pipe or cigar smokers were excluded)
- \_ Full Mouth Plaque Score and Full Mouth Bleeding Score ≤ 25 %

#### Study site inclusion criteria

- \_ Presence of native bone height of 1–3 mm in the sinus zone

#### Specific subject and site exclusion criteria:

- \_ Schneiderian membrane acute infections or chronic sinusitis
- \_ Allergies involving respiratory system
- \_ Patients with a history of Bisphosphonate therap

### \_contact

### implants

#### Luigi Canullo, DDS

Via Nizza, 46  
00198 Rome, Italy  
Phone: +39-06/8411980  
E-mail: luigicanullo@yahoo.com

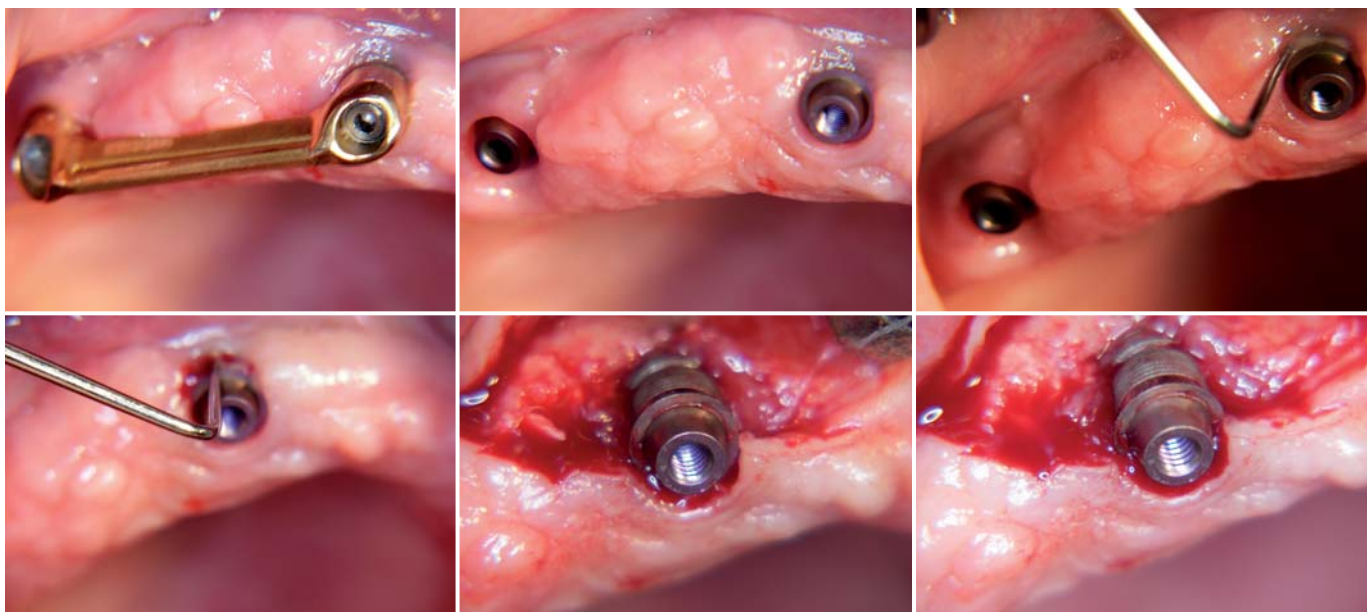
# Integration of diode laser surface decontamination in periimplantitis therapy—a twelve year review of a fit for practice concept

author\_ Georg Bach, Germany

**Manifestation of periimplantitis**  
 On probing, secretion is released at the mesial implant, though the clinical appearance is inconspicuous and further probing leads to a substantial bleeding. After mobilization of the soft tissues, the typical crater-shaped periimplant bone defect becomes visible.

After many years of great euphoria, a certain disillusion has spread in implantology, which is especially due to the reason that implants with corresponding suprastructures do not last forever, like it has often been pointed out. Anyway, complications cannot totally be excluded. Professor Herbert Deppe, Chair for the Dental Surgery and Implantology Department of Munich University, has recently reported on the fact that approximately an eighth of incorporated implants show periimplantary lesions after about 10 years. In the beginning, the main fear was that enossal implants had to face early complications. Nowadays, this is no more the case since sophisticated surgery techniques and improved implant surfaces have reduced these risks. One still has to worry about long-term sequelae shown in artificial abutments caused by periimplantary lesions af-

ter some years of strain. However, periimplantitis is mainly induced by bad oral hygiene and/or the inability to carry out mouth care (e.g. in old patients), and it is not associated to a certain type of implant (system-independent). Numerous therapy approaches have been made to preserve artificial abutments suffering from periimplantitis. A four phase treatment model is usually applied (hygienization phase, surgical resective phase, reconstructive and augmentative phase, recall phase). This model has considerably been enhanced by the launch of diode or injection lasers, which have later been complemented by CO<sub>2</sub>- and Er:YAG-, and Er,Cr:YSGG-laser respectively. Since the mid-nineties, diode lasers belong to the established wavelengths used in dentistry. Today, diode lasers with short pulse technique are predominant,



In Kooperation mit  
**Gothaer/AMG**

Stiftung Mensch & Medizin®

Foto: corbiss

**Neu!**

- 3,5 mm Implantatdurchmesser
- Garantieverlängerung 200,00 Euro\* Festkostenzuschuss zur Prothetik
- deutschlandweite Medienpräsenz für Lizenzpartner



**Jetzt!**

# Periointegration® ...statt Periimplantitis

Aktuelle wissenschaftliche Studien belegen, dass nach 9-14 Jahren ohne systematisch unterstützende Behandlung Implantate von Periimplantitis bedroht sind (Roos-Jansäcker et al. 2006, Paper II). Gefragt sind daher periointegrative Implantate.

Periointegration bedeutet die langfristige und entzündungsfreie Erhaltung von unterstützendem Knochen mit einer dicht anliegenden Weichgewebssmanschette um das Implantat.

In Zusammenarbeit mit der Academy of Periointegration, ein Zusammenschluss führender Vertreter aus Forschung, Lehre und Praxis, ist es Clinical House Europe GmbH gelungen, sieben Designkriterien in eine neuartige ultradichte, periointegrative Implantatkonstruktion umzusetzen.

In Kooperation mit dem Fraunhofer Institut und namhaften deutschen Universitäten wurde eine intensive Grundlagenforschung im Bereich moderner Hartstoffschichten betrieben. Ein Technologietransfer aus der Luft- und Raumfahrttechnik ermöglicht erstmalig die Beschichtung von Titanoberflächen mit Zirkoniumnitrid und Zirkoniumoxid.

Die aktuellen wissenschaftlichen Ergebnisse auf dem Gebiet der Oberflächentechnologie zeigen, dass Zirkoniumnitrid ein Anhaften des Biofilms mit paradontopathogenen Keimen erheblich verringert und die Anlagerung der Gingiva zu einem dichtanliegenden Saumepithel maßgeblich fördert. (Größner-Schreiber et al. 2006).

## **Vollkaskoimplantat®** ...wir tun was

Das Vollkaskoimplantat ist das erste Business Erfolgskonzept für die Implantologie, welches Technologie, Garantieabsicherung und Medialeistung zu einem bundesweit erkennbaren Markenkonzept verbindet. Informieren sie sich über die Vorteile für ihre Praxis und die Zugangsvoraussetzungen für Lizenzpartner.

**Tel: +49 (0) 234 90 10 260**  
**info@vollkaskoimplantat.de**  
**www.vollkaskoimplantat.de**

Clinical House Dental GmbH  
Am Bergbaumuseum · 44791 Bochum  
Tel. +49 (0)234 90 10 260 · Fax +49 (0)234 90 10 262

### **Gratis!** **Vollkaskoservice**

- 7 Gründe für das Lizenzkonzept Vollkaskoimplantat:**
- ✓ wissenschaftlich dokumentierte Periointegration®
  - ✓ erstes Business-Erfolgsrezept für die Implantologie
  - ✓ 10 Jahre Recall-Motivation für Patienten
  - ✓ Gothaer/AMG abgesicherte 10 Jahres Garantie\*
  - ✓ Festkostenzuschuss Prothetik von 200 Euro\*
  - ✓ Chirurgische Kostenerstattung\*
  - ✓ deutschlandweite Medien-Präsenz

**Vollkasko Infogutschein**  
Ja, bitte senden Sie mir Informationen zum Thema Lizenzpartnerschaft zu.  
Abschnitt bitte faxen an 0234 901 0262. Oder per Post an Clinical House Dental,  
Am Bergbaumuseum 31, 44791 Bochum.

Name \_\_\_\_\_  
Anschrift: \_\_\_\_\_  
Tel: \_\_\_\_\_  
Email: \_\_\_\_\_

[www.Stiftung-Mensch-und-Medizin.de](http://www.Stiftung-Mensch-und-Medizin.de)  
[www.vollkaskoimplantat.de](http://www.vollkaskoimplantat.de)

\*gemäß AGB's

though it all started out with the cw mode. High performance diode lasers emit monochromatic, coherent light of wavelength 810 nm, which is especially well absorbed by dark surfaces. Thanks to these physical conditions, the injection laser (= diode laser) is perfectly suitable for incisions applied in standard dental surgery, as well as for the resection of benign tumors in the oral cavity, the uncovering of implants and for application in mucogingival surgery. The good cutting properties of diode lasers are due to the extraordinary absorption of laser light by the hemoglobin located inside the tissue. Additional to soft tissue surgery, the diode laser is also used for decontamination of surfaces covered with microbes (on implants and teeth). It could be demonstrated that especially the Gram-negative, anaerobe microbiological spectrum was properly damaged by laser light (Bach und Krekeler (1995;2000)). In compliance with reasonable performance and time parameters, which have been confirmed sustainably by clinical long term studies (Moritz (1996), Gutknecht (1997), Bach et. al. (1995, 1996, 1998, 2000, 2001)), a thermic or morphological damage of the implant surface and the surrounding bone tissue can definitively be excluded (Bach and Schmelzeisen (2002)). It was the aim of the present study to demonstrate and evaluate a treatment model for periimplantitis therapy, which shows sustainable results and which is absolutely suitable for practice. There is no doubt that the conventional methods for periimplantitis treatment, which have often been described in literature, permit adequate surface cleaning and thus also the reduction of pathogenic microorganisms on the implant surfaces. Nevertheless, the complete removal of relevant bacteria cannot be ensured. Moreover, the conventional removal of biofilms has only little influence on those bacteria infiltrating the soft tissue. The integration of diode laser light in periimplantitis therapy must be seen as a new approach.

**\_Material and method**

Ten patients (with n = 17 implants) have been treated and examined for a period of more than 12 years (since May 2007). In spring 1995, all of them suffered from periimplantitis on their artificial titanium abutments.

**\_Pathogenesis of periimplantitis**

Periimplantitis therapy represents a border area between implantology and parodontology. The causes for parodontitis and periimplantitis are bacterial infections, in particular they are biofilm based infectious diseases. Gram-negative and anaerobe microbes are mainly responsible for the destruction of the parodontal and periimplantary supporting tissue. As a rule, one of the following microbes

causes parodontopathy in case of one of both biofilm based infectious diseases:

- \_ *Actinobacillus actinomycetemcomitans*
- \_ *Prevotella intermedia* and
- \_ *Porphyromonas gingivalis*

Whereas periimplantitis is mainly caused by the following microbes:

- \_ *Fusobacteria*
- \_ *Prevotella intermedia* and
- \_ *Porphyromonas gingivalis*

The principal object of periimplantitis therapy carried out in our dental clinic was to remove the biofilm and hence the removal of the mentioned pathogenic microorganisms.

**\_ Patients treated**

For detailed data, age and sex of the patients, please see Figs. 1 and 2. It should be mentioned that an accumulation of the disease's first incidence is registered in the middle years (age: 30 to 50 years) in both groups. Sex-specific differences could not be ascertained.

| Age         | Number of patients |
|-------------|--------------------|
| 20–30 years | 1                  |
| 30–40 years | 3                  |
| 40–50 years | 3                  |
| 50–60 years | 2                  |
| 60–70 years |                    |

**Fig. 1\_** Age pattern of the examined and treated patients in 1995.

| Sex    | Number of patients |
|--------|--------------------|
| Female | 5                  |
| Male   | 5                  |

**Fig. 2\_** Evaluation according to the sex of the examined and treated patients.

**\_Inclusion and exclusion criteria**

All patients involved had to meet strict inclusion criteria as there were:

- \_ Clinically visible inflammatory signs like BOP (bleeding on probing) and high probing depths
- \_ Radiovisible periimplantary bone lesions ("crater")

Exclusion criteria were:

- a) Severe primary diseases
- b) Nicotine or alcohol abuse
- c) Lack of compliance

Due to the strict inclusion and exclusion criteria only a limited number of people could be admitted for this study.

**\_Treatment procedure**

Equal treatment procedures for all periimplantitis patients:

# 39<sup>TH</sup> INTERNATIONAL ANNUAL CONGRESS OF THE DGZI

Complications, Risks and Failures in the Oral Implantology

October 9–10, 2009, in Munich  
Hilton Munich Park

## SPECIAL PODIUM

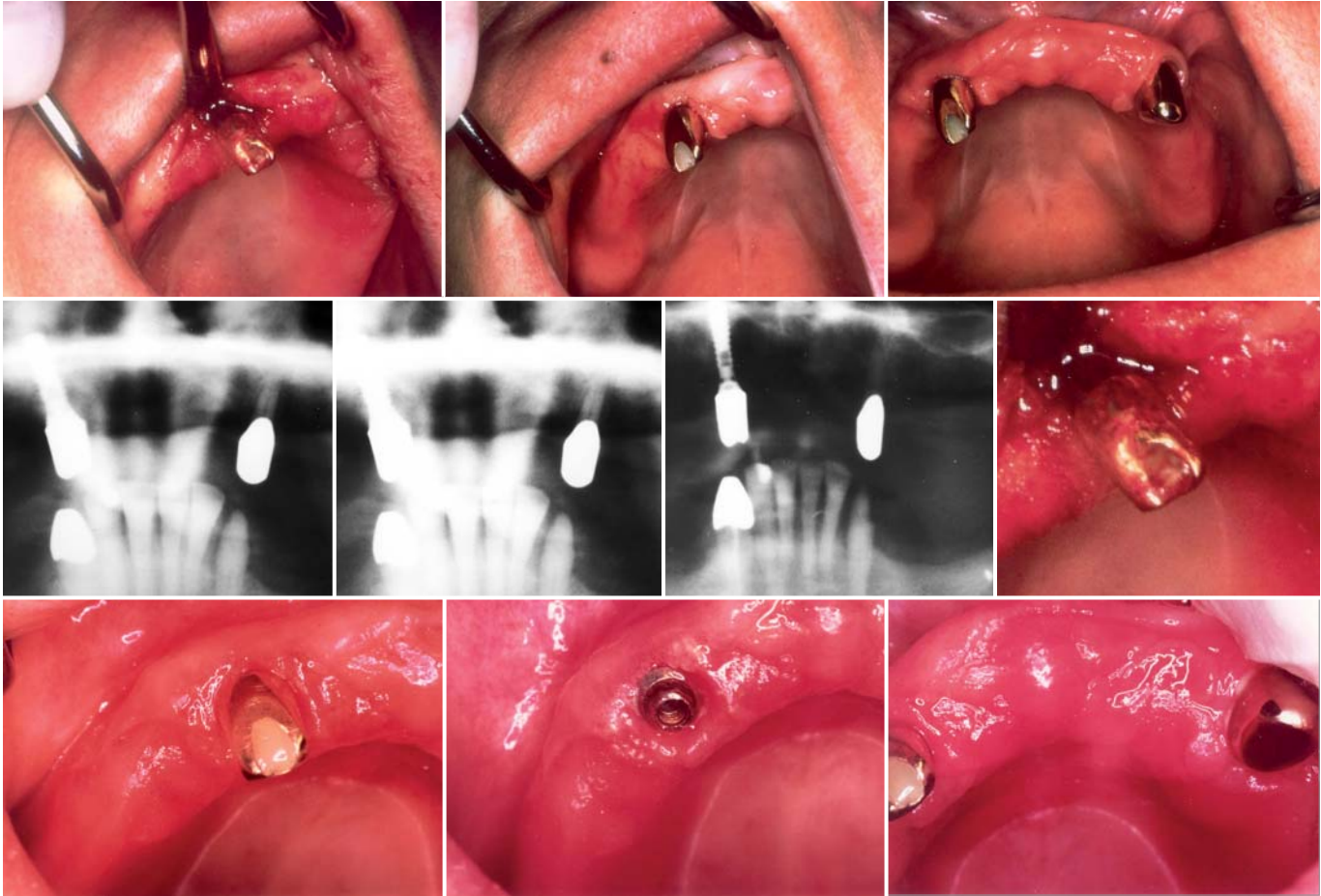
„Periimplantitis –  
a challenge of  
the future“ with  
talk of experts



Allianz Arena

Information:  
Phone: +49-3 41/4 84 74-3 08  
Fax: +49-3 41/4 84 74-2 90  
[event@oemus-media.de](mailto:event@oemus-media.de)  
[www.dgzi.de](http://www.dgzi.de)  
[www.event-dgzi.de](http://www.event-dgzi.de)





**Periimplantitis therapy:**

You can see the first patient, who had undergone periimplantitis treatment, by means of diode laser decontamination, according to our model.

November 1994: Manifestation of periimplantitis at implant regio 13. The panoramic tomography (detail) shows a significant bone loss at the artificial abutment. After mobilization of the soft tissue the situation of the defect becomes clearly visible.

January 2008: The prosthesis made in 1990, is still in the same position. The situation of the treated regio 13 implant does not show any irritations with and without suprastructure.

There is no evidence of probing depth. The panoramic tomography shows a stable bone situation. Besides the reconstructed defect of regio 13, only the root filling of 43 protrudes. This is the only difference compared to the tomography taken in 1995.

**1. Initial therapy:**

- \_ Motivation and instruction of patients
- \_ Cleaning and polishing
- \_ Application of disinfecting agents

**2. Resective phase:**

- \_ Forming of a mucoperiosteal flap
- \_ Removal of granulation tissue
- \_ Decontamination by means of diode laser light ( $p = 1.0$  watt,  $t_{max} = 20$  sec.)
- \_ Apical shifting of soft tissues

**3. Reconstructive phase:**

- \_ If necessary, bone augmentation
- \_ Where applicable, mucogingival corrections

**4. Recall phase:**

- \_ After four weeks, six months, one year and then annual evaluations of clinical findings, taking of X-rays (PSA), decontamination of eventually exposed areas by means of diode laser light.

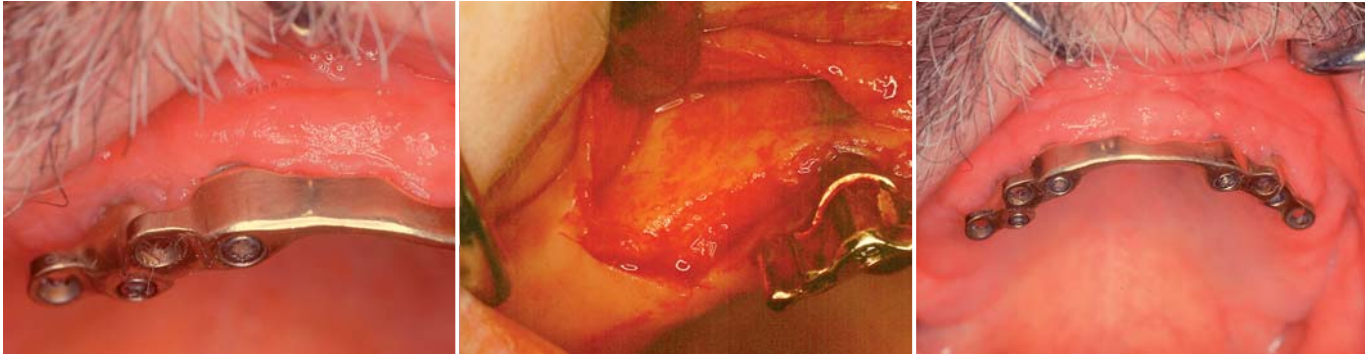
**\_Image processing methods**

As a rule orthopantomograms (panoramic tomography) and additionally dental films in parallel technique were chosen as an adequate image processing method. In some cases of exacerbated in-

flammations A/B scan ultrasonic methods were applied. A preoperative orthopantomogram and the dental film status (dental shots of the respective areas) were taken. A postoperative orthopantomogram was directly taken after surgery. A panoramic tomography was taken one year later and then every two years. The advantage of the orthopantomogram is its panoramic-like view of all teeth, the osseous limbus alveolaris and important neighboring anatomical structures. The dental film in parallel technique allows statements concerning progredience, stagnation of loss of hard- and soft tissue, and it shows the course of the limbus alveolaris in a reproducible way.

**\_Microbiological diagnosis**

Time schedule: Preoperative, four weeks postoperative, one year postoperative and in a five to ten-year postoperative interval germs were eliminated from the effected areas. We did not apply the classical microbiological examination technique (isolation of microbes—cultivation – pure cultures – microscopic samples – gas chromatography – antibiotic sensitivity testing—and biochemical identification, the so called "bunte Reihen"). We used DNA-RNA hybridization probes instead. The advantage of these hybridization probes is that no living



**Saving of a prosthesis by treating periimplantitis of a strategically important implant in the upper jaw.**

March 1995: Just one year after the incorporation of a very sophisticated and for the patient nearly too expensive implant-supported prosthesis in the upper jaw, the manifestation of periimplantitis was detected in the first quadrant. After mobilization of the soft tissue (below) the defect situation becomes clearly visible. Four months after the surgical resective phase there were no clinical signs of irritation.

November 2007: The prosthesis is still in its intraoral place. Meanwhile, the patient has reached the age of 63 years. The situation of the treated implant regio 13 (total suprastructure) does not show any clinical signs of irritation in toto and in the former surgical area. There is no probing depth.

material of the areas probed is needed for cultivation purposes, which minimized the work in the dental clinic (without direct access to an Institute of Microbiology). Additionally, the results were much faster on hand as is the case with classical microbiological examinations. The disadvantage of this rapid test is its high price. Furthermore, only special marker microbes can be detected and not all pocket microorganisms can be determined. The germ extraction site had to be dried carefully with a cotton swab, the paper tip was placed, and after a waiting time of 10 seconds put into a sterile storage vessel and sent to the manufacturing company for microbiological diagnosis. The company is in charge of microbiological diagnosis and evaluation of the so called microbe marker values. The classification of marked microbes was: less than 0.1 % = negative; 0.1-0.99 % = low; 1.0-9.9 % = middle, more than 10 % = high.

**\_Laser light decontamination**

Decontamination formed an essential part of the whole therapy. It was carried out by means of diode laser light with 1 watt performance and 20 seconds of application time per implant under fiber contact. A special program (I = implantology-parodontology) was at our disposal, which was used together with the corresponding device (Oralia 01 IST). Performance and time limitation (1.0 watt, 20 seconds) were already fixed parameters of this program. When observing these parameters (time limitation and limitation of performance) it can be guaranteed that the disease causing microbes will be damaged sufficiently and thus, pulpa, periimplantary and periodontal tissue structures will not suffer any thermic damages (Bach and Krekeler (1995)).

**\_Results**

Alltogether 10 patients could be examined and checked up during the whole 12 years. In 1994/1995 the "Diode Laser Basic Study" of the Department of Periodontal Surgery of the Dental Clinic in Freiburg/Germany included 50 periimplantitis patients. Due to moving, change of dentist, dead of pa-

tients and other unknown reasons the number of patients was reduced to 10, who are still patients of my dental clinic.

**a) Microbiological results**

For microbiological results please see Fig. 3. It must especially be emphasized that Porphyromonas gingivalis could nearly be completely eliminated during the whole examination period, and a significant reduction of other anaerobe, Gram-negative bacteria could be achieved. We could obtain similar results for Porphyromonas gingivalis and Fusobacteria except for two cases of low concentration and one of middle concentration, these bacteria could be limited to the lower level of detection in other patients, whereas other relevant marker microbes could be considerably repressed.

**b) Recurrence**

One of the following results was considered to be a case of recurrence:

- \_ Occurrence of probing depths of more than 4 mm
- \_ Loss of implant
- \_ Recurrence of an inflammation
- \_ Excessive soft tissue inflammation with pocket activity

After 12 years the quota of recurrence was 23% in the periimplantitis group (4 implants). It is stated in international literature that the five year observation period recurrence rate is 30 %.

**c) Losses after 140 months**

Within the examination period of 12 years we suffered the following losses: two of 17 implants (12 %).

**d) Radiological results**

On the occasion of the one year check up, a reconstruction of the once crater-shaped defect could be found at the first thread and implant cervix respectively in all 17 implants. After five years this was the case in twelve implants, after ten years in ten implants and in nine implants, when the last X-ray control was carried out. In two implants a successive loss of the bony supporting tissue forced us to remove the artificial abutment in one case af-

# Consensus Conference Implantology

Starting from the beginning of the year 2009 DGZI presides over the Consensus Conference. Dr med dent Roland Hille currently is its President. This is a good opportunity to talk to Dr Hille, Board member of the German Association of Dental Implantology (DGZI) and get more information about the aims and tasks of this union.



## Dr Hille, can you tell us, what stands behind the Consensus Conference Implantology?

**Dr Hille:** The Consensus Conference Implantology is a cooperation of two scientific specialist non profit associations (DGI, DGZI), two professional associations (BDIZ, BDO), and an organization that is both a professional and a scientific specialist association (DGMKG, German Association of Oral and Maxillofacial Surgery).

The members of the KK (CC, Consensus Conference) are:

- \_ The Professional Association of Oral Surgeons (BDO)
- \_ The European Association of Dental Implantologists (BDIZ/EDI)
- \_ German Association of Oral and Maxillofacial Surgery (DGMKG)
- \_ German Association of Implantology (DGI)
- \_ German Association of Dental Implantology (DGZI)

The Working Group for Maxillofacial Surgery is an associated member of the Consensus Conference Implantology without any right to vote.

## Are there regular meetings of the Consensus Conference?

**Dr Hille:** Every member sends two participants to the Consensus Conference Implantology. As a rule, there are four annual meetings of the Consensus Conference Implantology.

## What are the tasks of the Consensus Conference?

**Dr Hille:** The Consensus Conference was brought into being with the aim to create a neutral meeting place for opinion-forming, implementing the specialization for implantology. Of top priority are quality management in implantology, consistent definitions of medical standards, congruent determination of professional training contents, and their mutual recognition, and equal evaluation, always referring to this professional field.

## Does the Consensus Conference influence the postgraduate education programs?

**Dr Hille:** During the joint meeting of the different associations (Consensus Conference) on May 2<sup>nd</sup>,

1998, a resolution was passed which says that the scientific associations DGI and DGZI will implement a structured curriculum (Curriculum implantology) in the field of oral implantology. DGZI and DGI mutually and completely approved their structured curriculum (curricula). In the same meeting it was also agreed upon to develop consistent criteria for curricula and examinations.

Together with the BDIZ/EDI the DGMKG and the BDO took over the professional conduct-related task to achieve that the successfully acquired qualifications focussing on the special field of oral implantology issued by the scientific associations to be approved by the German Dental Associations and the federal chamber of dentistry. Meanwhile also the points rating system for continuing medical education (CME) is approved and accepted by the German Dental Associations and the federal chamber of dentistry in a unique form. More information can be found in the table on the opposite side.

## What was and is the aim of the Consensus Conference concerning dental education?

**Dr Hille:** It was the aim of the Consensus Conference to set up uniform federal criteria for professional training in dental implantology. Apart from the other associations participating in the Consensus Conference, the scientific associations have developed their own Implantology Curriculum. Another effort of the Consensus Conference was to standardize these curricula according to the main features of scientific criteria.

## Can you give us an idea about the advantages the colleagues have after passing the education program?

**Dr Hille:** Postgraduate structural curricula modules which are successfully passed can be fully approved for a Master of Science study program. In cooperation with the Danube State University Krems in Austria the DGZI conducts a Master of Science study program for oral implantology. The curricula programs are accepted mutual unanimously by the scientific specialist non profit associations (DGI, DGZI) and integrated in the study programs of the participating universities. DGI e.g., in cooperation with



Steinbeis College Berlin, an officially recognized private college, offers also a two year Master of Science study program in oral implantology as well as other regional universities such as Westfälische University Münster.

But the Consensus Conference neither dictates the contents of the curricula, nor is this intended. The scientific associations (DGZI, DGI) update the contents continuously according to new concepts and treatment options.

DGZI conducts also a qualification test for the specialization "Specialist Implantology DGZI". This qualification test is approved as advanced training according to the certification rules of the Consensus Conference and focuses on more clinical and practical training.

Let me last but not least mention that DGZI also is

conducting the so called German Board examination as an international qualification test which is also based on the successfully passed curricula.

**If our colleagues have more questions about these very interesting subjects, what is the contact address of the Consensus Conference?**

**Dr Hille:** The Consensus Conference office's address is

Königsallee 49c

41747 Viersen, Germany

Phone: +49-21 62/1 23 79

Fax: +49-21 62/35 58 07

E-mail: dr-hille@t-online.de

**Dr Hille, thanks a lot for these valuable information.**

## **\_ Consensus Conference Implantologie at a glance**

**implants**

The Consensus Conference Implantology is a cooperation of two professional associations (BDIZ, BDO), two scientific specialist non profit associations (DGI, DGZI), and an organization that is both a professional and a scientific specialist association (DGMKG, German Association of Oral and Maxillofacial Surgery).

### **Members:**

\_ The Professional Association of Oral Surgeons e.V. (BDO)

\_ The European Association of Dental Implantologists e.V. (BDIZ EDI)

\_ German Association of Oral and Maxillofacial Surgery (DGMKG)

\_ German Association of Implantology (DGI)

\_ German Association of Dental Implantology (DGZI)

The Working Group for Maxillofacial Surgery is an associated member of the Consensus Conference Implantology without the right to vote.

Administration: DGZI.

President: Dr med dent Roland Hille

Annual Meetings: 4

Participants per member: 2

Office's Address: Königsallee 49c, 41747 Viersen, Phone: +49-21 62/1 23 79, Fax: +49-21 62/35 58 07, E-mail: dr-hille@t-online.de

### **Tasks**

\_ The Consensus Conference was brought into being with the aim to create a neutral

meeting place for opinion-forming, implementing the specialization for implantology. Of top priority are quality management in implantology, consistent definitions of medical standards, congruent determination of professional training contents, and their mutual recognition, and equal evaluation, always referring to this professional field.

\_ During the joint meeting of the different associations (Consensus Conference) on May 2<sup>nd</sup>, 1998, a resolution was passed which says that the scientific associations DGI and DGZI will implement a structured curriculum (Curriculum implantology) in the field of oral implantology. DGZI and DGI mutually and completely approved their structured curriculum (curricula). Together with the BDIZ/EDI the DGMKG and the BDO took over the professional conduct-related task to achieve that the successfully acquired qualifications focussing on the special field of oral implantology issued by the scientific associations is approved by the German Dental Associations. In the same meeting it was also agreed upon to develop consistent criteria for curricula and examinations.

\_ It is the aim of the Consensus Conference to set up uniform federal criteria for professional training in dental implantology. Apart from the other associations participating in the Consensus Conference, the scientific associations have developed their own Implantology Curriculum. Another effort of the Consensus Conference

was to standardize these curricula according to the main features of scientific criteria.

\_ Postgraduate structural curricula modules successfully passed can be fully approved for the Master of Science studies. Since 2005 DGI, in cooperation with Steinbeis College Berlin, an officially recognized private college, has offered a two year Master of Science study program in oral implantology.

In cooperation with the Danube State University Krems in Austria the DGZI conducts a Master of Science study program for oral implantology. Other regional universities such as Westfälische University Münster also offer Master of Science study programs in the field of oral implantology.

\_ The Consensus Conference neither dictates the contents of the curricula, nor is this intended. The scientific associations update the contents continuously.

\_ DGZI conducts a qualification test for the specialization "Specialist Implantology DGZI". This qualification test is approved as advanced training according to the certification rules of the Consensus Conference.

\_ The same applies to the implantology curriculum offered by DGI in cooperation with the Academy Practice and Science (APW) of the DGZMK (German Association of Dental and Maxillofacial Medicine)

\_ DGMKG offers a corresponding curriculum in the field of oral and maxillofacial surgery.

# IDS flourishes despite economic trouble

author\_ Daniel Zimmermann, Germany



The world's largest dental show has defied the economic gloom. According to a preliminary report released by the organiser Koelnmesse at the end of March, the number of visitors this year increased by 6.9 per cent to over 100,000. The number of exhibitors also rose by 4.5 per cent to 1,820. International companies held a 65 per cent share, an increase of 10 per cent compared with the previous show in 2007.

The results confirm a slight decline in the German domestic market, which is significant for the local dental industry. Sales have dropped by 2.6 per cent to € 1.58 billion compared with 2007; this is attributed mainly to financial constraints in the dental and dental technology sectors in the last quarter of 2008. Although dental physicians are the group of medical specialists who are the most willing to invest in the establishment of clinics, according to the latest results of the Institute of German Dental Physicians (IDZ), the overall investment trend has fallen significantly.

However, a survey conducted by the Association of German Dental Manufacturers (VDDI) found that export business expectations for 2009 are positive overall in spite of varying business development in individual regions. VDDI Chairman, Dr Martin Rickert said that 83 per cent of the member companies surveyed expect a rise in, or at least consistent, overseas sales for 2009. The export quota of the companies traditionally operating as 'global players' is 57 per cent.

"It is good news that in spite of the turbulence in the financial market, the dental industry and the health economy can, overall, sustain as solid markets," Dr Rickert said during a press conference in Cologne. "IDS has confirmed its status as the international leading trade show in dentistry. We are certain that the show's outcome will give positive signals for the global dental market and international health markets as well," he added.



# IDS for implantologists—

## Interview with Dr Rolf Vollmer

Innovations are exciting—Professional training (curricula) is indispensable. IDS—The International Dental Show—took place in Cologne from March 24 to 28, 2009. This year's worldwide biggest fair of dental industry focussed on innovations, also with regard to implantology.

**Dr Vollmer, you are Vice President of Germany's most traditional implantological expert association. Where do we stand today, and what are we awaiting in the coming years?**

The general trend, though I do not agree with it in every respect, is certainly focussed on new surfaces, faster healing processes, and faster patient care. In the next two to five years, progress is probable in the field of biological surfaces. I can also imagine that there will be further developments with regard to bone substitutes, because the "philosopher's stone" has not yet been found. There have been many alleged trends, which sometimes implied high prime costs for users and which later came to nothing. As expected, apart from a number of innovations not really extensive news could be presented.

### **Which basic problems remain unsolved?**

Positive and significant are the solutions to complex technical tasks. Just think about the imaging techniques – e.g. digital X-ray sensors, storage phosphor plate techniques, or filters for special implantological image evaluation, or of the biological parts of the membranes, bone substitutes, growth factors. That is pure innovation. Surprisingly there are some relatively simple problems which have not yet been addressed. It is praiseworthy that in recent years one thing was established as standard. There is often a micro thread in the neck area of the implant which passes over to a macro thread apically. But metric and inch measurements still exist. Not every implant system is stringently compatible with another system. This implies higher dental tool costs for users. It is also more complicated if patients move to live elsewhere, and have to find another implantologist for their treatment. One should at least agree upon uniform sizes for the screws and threads used, perhaps two or three sizes with corresponding screw-wrenches. This would certainly simplify the daily work of implantologists.

### **Why does DGZI exhibit at such a fair?**

That is a good question! We already participated in 2007, and we could deliver a positive summary, though our presentation at the dental show in 2007



mainly focussed on image building. Awaiting the worldwide economic crisis, we also had to think about whether it would be worth the effort and the costs involved, and form part of the fair as an exhibitor. To be honest, I was not sure of that.

### **And what about the result?**

That is more than just impressive. Köln Messe (Cologne Fair) announced a growth rate of 6.9% concerning the number of visitors. More than 106,000 interested dentists, dental technicians, dental assistants and students visited the IDS 2009. Considering our comparatively small booth, we can certainly say that the IDS 2009 was absolutely successful, for we could count 685 qualified contacts altogether. I think that apart from the large number of German visitors, the internationality of the visitors to the fair was indeed remarkable. To sum up, I can say that the IDS 2009 has considerably exceeded all expectations of our association.

### **What about the talks at the fair? What were they about?**

As I have already mentioned at the beginning of our interview, professional training (curricula) is indispensable. Especially at the IDS we noticed an increased demand for implantological curricula and specialist training in Germany and abroad. We are very pleased to see that there was an obvious demand for quality and continuity. Since internationality is traditionally highly rated in our society, it pleases me the most that many foreign members took the chance of the fair in order to get in contact with us, and visit their DGZI.

# 24<sup>th</sup> Annual Meeting of the Academy of Osseointegration (AO)

authors\_ Rolf Vollmer and Rainer Valentin, Germany

**The 24<sup>th</sup> Annual Meeting** of the Academy of Osseointegration (AO) was held at the San Diego Convention Center from February 26–28, 2009. Slogan of this meeting was "A New Wave in Implant Therapy". AO is one of the international partner organizations, a so called affiliate association of DGZI (German Association of Dental Implantology). AO is a purely scientific association, similar to the DGZI, with more than 6,500 members worldwide, who have specialized in dental implantology. Top experts from all over the world presented their scientific studies in the form of expert lectures and workshops. In his welcoming speech Steven G. Lewis DMD, the current President of the Academy of Osseointegration, introduced the meeting program and welcomed the colleagues from all over the world. He specially thanked DGZI, which was represented by Dr Rolf Vollmer, Dr Rainer Valentin and DGZI's international representative Dr Mazen Tamimi. They were also accompanied by a small group of interested colleagues.

Steven G. Lewis pointed out: This year we selected the topic: "A New Wave in Implant Therapy."

The mission of the academy is "to advance oral health and well being by disseminating state-of-the-art and clinical and scientific knowledge of implant dentistry and tissue engineering and by defining expertise in the field of implant dentistry."

The president thanked his program directors for doing such an excellent job. Furthermore, he expressed his thanks to the sponsors who made this congress feasible for a magnitude of approximately 3,000 participants.

**Furthermore Steven G. Lewis remarked about the educational objectives:**

The goal of this year's Annual Meeting is to provide attendees with the most current educational experience in implant dentistry. The overall objective is to explore technological breakthroughs in implant dentistry and their impact on clinical practice. Tech-





nology and new techniques must always maintain a balance with science based therapy.

Our aim is to provide a comprehensive program including current innovations in restorative and surgical techniques; the team approach; practice management; improved diagnostics with computed tomography (CT); digital volumetric tomography (DVT) and photography; and current concepts from some of the most well-known presenters around the world.

The ultimate goal is to provide relevant, predictable techniques to integrate into clinical practice that will improve patient care.

**Target Audience**

The program is targeted toward everyone who has an interest in implant therapy. This includes: students in training programs, dentists with limited implant experience and specialists with extensive training in implant dentistry. Auxiliary staff, including hygien-

ists, assistants and laboratory personnel will also benefit from this meeting.

|  |                          |
|--|--------------------------|
| <a href="#">_information</a>   | <a href="#">implants</a> |
| <p><b>Affiliate Groups</b></p> <p>The Academy of Osseointegration strives to create the most scientifically and clinically advanced meeting in osseointegration on a yearly basis. We welcome you to attend this meeting and are certain that you will enjoy it. In addition to the annual session of the AO, we also suggest that you consider attending the meetings of our friends in other groups dedicated to osseointegration throughout the world. Four of those groups, the ABROSS in Brazil, ADI in the UK, AOS in Australia, and DGZI in Germany can be accessed by clicking on their logos below.</p> |                          |





# AOS 7<sup>th</sup> Biennial Conference



On behalf of the Australasian Osseointegration Society, I am honored and privileged to invite you to the AOS 7<sup>th</sup> Biennial Conference to be held at the Gold Coast, Queensland, from 4–7 November 2009.

The conference is dedicated to 'Staying Between the Flags', with the aim of fostering safe clinical practice by promoting understanding of the benefits and limitations of various clinical techniques. The scientific program will be designed to address practical and highly relevant issues that concern clinicians. We have invited outstanding speakers who are certain to contribute to an exciting three days, providing an authoritative and reliable scientific and clinical basis for the treatment of patients, as well as addressing exciting new innovations and research. As always, we are delighted to collaborate with our industry sponsors who are an essential component of the success of this conference. The Gold Coast is renowned for its sunny subtropical climate, popular surfing beaches, active nightlife and wide variety of tourist attractions. It is a fantastic venue all year round, but especially at the beginning of the summer when this event is to be held. Take a few extra days in conjunction with the conference and experience this wonderful location. On behalf of the organising committee, I hope that you will join us for what I am sure will prove to be an attractive, stimulating and interesting program.

Yours sincerely  
Saso Ivanovski  
AOS 2009 Chairman

## Host Organisation: Australasian Osseointegration Society

The Society brings together people at the forefront of implant dentistry in Australasia. Members include dentists, dental technicians, hygienists, industry rep-

representatives and allied health personnel with the common aim of improving the standards and outcomes of implant dentistry by sharing and discussing information in an open learning environment.

## Social Program Highlights

### Welcome cocktail reception

Join us on top of the world at the highest point above the Gold Coast for an unforgettable welcome to AOS09 on Wednesday 4 November 2009. Travel to the very top of the world's tallest residential tower Q1, rising 230 meter into the sky, in one of the world's fastest elevators. With floor to ceiling glass windows, you'll experience spectacular 360 degree views from the surf to the hinterland and beyond whilst enjoying drinks and canapés. This will be a unique Gold Coast experience that shouldn't be missed!

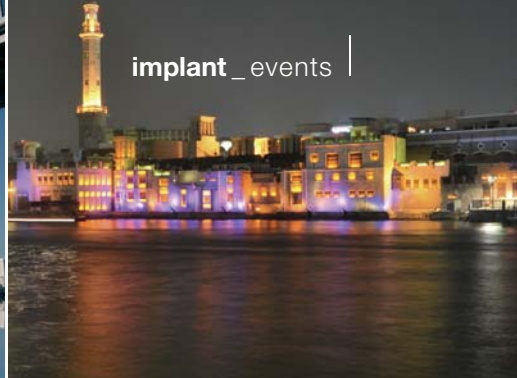### Conference dinner

Sponsored by Astra Tech, the conference dinner will also be a highlight of the social program. To be held on Friday 6 November 2009 at the Gold Coast Convention and Exhibition Centre, the dinner will provide a great opportunity to enjoy a relaxing evening with colleagues and industry associates.

Further details regarding all social functions, including any applicable costs to attend, will be included in the registration brochure which will be available in 2009. Register your interest to receive a brochure at [www.aosconference.com.au](http://www.aosconference.com.au).

### Confirmed Speakers

Professor Jan Lindhe/Sweden  
Dr Michael Norton/USA  
Professor Urs Belser/Switzerland  
Dr Ueli Grunder/Switzerland  
Dr Joseph Kann/USA



# Selected Events 2009/2010

## JUNE 2009

June 4-6

*EUROPERIO*

Stockholm, Sweden

Web: [www.europerio6.net](http://www.europerio6.net)

June 5-7

*2<sup>nd</sup> International Congress of Cosmetic Dentistry*

Salerno, Italy

Web: [www.cosmeticmeetingsalerno.com](http://www.cosmeticmeetingsalerno.com)

June 25-27

*8<sup>th</sup> SimPlant Academy World Conference*

Monterey, Canada

Web: [www.simplantacademy.org](http://www.simplantacademy.org)

## SEPTEMBER 2009

September 2-5

*FDI Singapore*

Singapore

Web: [www.fdiworlddental.org](http://www.fdiworlddental.org)

## OCTOBER 2009

October 9-10

*39<sup>th</sup> International Congress of DGZI*

Munich, Germany

Phone: +49-3 41/4 84 74-3 08

Fax: +49-3 41/4 84 74-2 90

Web: [www.event-dgzi.de](http://www.event-dgzi.de)

October 11-15

*58<sup>th</sup> Annual Meeting of AAID*

New Orleans, Louisiana,  
USA

Web: [aaaid.com](http://aaaid.com)

October 23-25

*1<sup>st</sup> European Implant Direct Congress*

Barcelona, Spain

Web: [www.implantdirect.eu](http://www.implantdirect.eu)

## NOVEMBER 2009

November 4-7

*AOS 7<sup>th</sup> Biennial Conference*

Queensland, Australia

Phone: +617 3858 55 25

Web: [www.aosconference.com.au](http://www.aosconference.com.au)

November 27  
- December 2

*GNYDM Greater New York Dental Meeting*

New York, USA

Web: [www.gnydm.com](http://www.gnydm.com)

## MARCH 2010

March 2-4

*Biannual WFLD World Congress in Conjunction  
with UAE International Dental Conference &  
Arab Dental Exhibition*

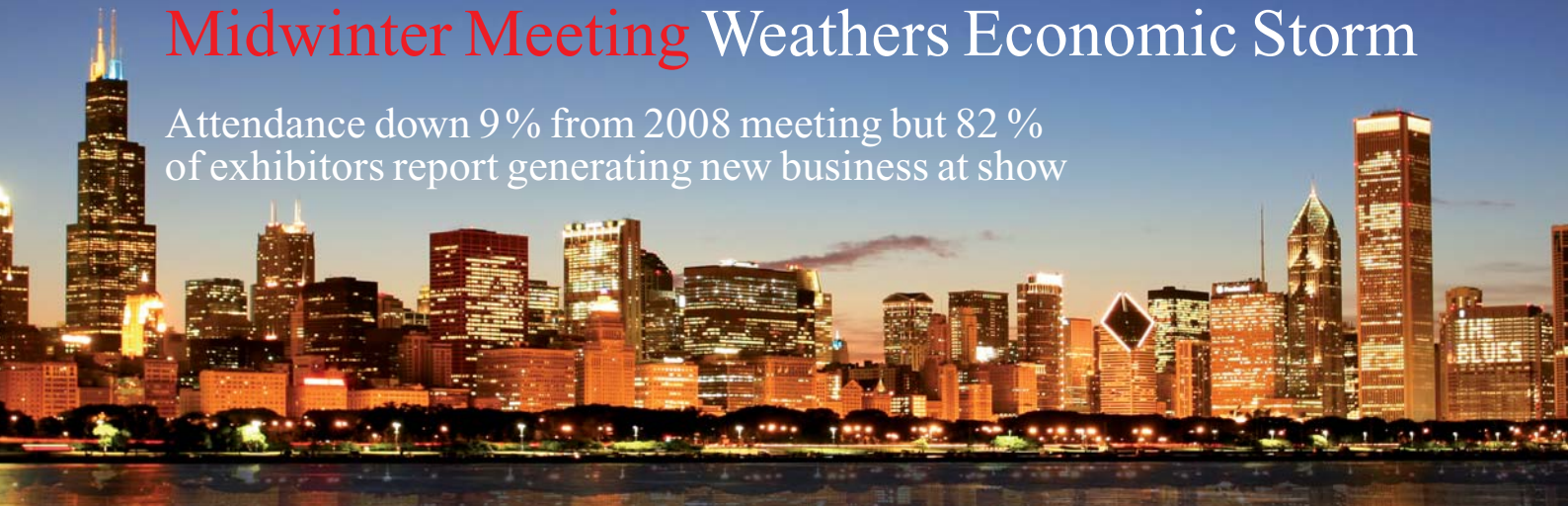Dubai, UAE

Web: [www.aedc.com](http://www.aedc.com)



# Midwinter Meeting Weathers Economic Storm

Attendance down 9% from 2008 meeting but 82% of exhibitors report generating new business at show



The Midwinter Meeting, the Chicago Dental Society's annual dental conference and tradeshow, consistently ranks amongst the country's top conventions, even earning the distinction as one of the top four medical tradeshow in the US last year, according to Expo magazine.

Held February 26 to March 1, this year's meeting once again attracted dental professionals from around the world, including nearly 7,000 dentists. Total attendance for the meeting was 31,333, representing a nine per cent drop over the 2008 figures, which were an all-time high in the meeting's 144-year history. "I think we all went into this meeting holding our breath a little," Dr. David Kumamoto, CDS president, said. "But the feedback from exhibitors and the number of sold-out courses reveal just how strong our meeting is." Nearly one-quarter of the conference's 240+ courses were sold out, and the vast majority of courses were near capacity.

The exhibit floor, which showcased 570 companies, was completely sold out months in advance. The Midwinter Meeting was recently chosen as offering the best cost-to-value benefit of any dental tradeshow in the US, according to 66 per cent of exhibitors responding to a post-show survey.

According to the survey of exhibitors:

- 82 per cent said they generated new business at show
- 32 per cent said the Midwinter Meeting was as good as other meetings they had attended in the last twelve months; 45 per cent said it was better
- 90 per cent said they plan to exhibit at the 2010 meeting; ten per cent were not yet sure
- 73 per cent said that they will continue with the same booth size; ten per cent said they would enlarge their booth space at 2010

While attendance in general declined by nine percent, a review of the attendance figures shows that the number of dentists attending decreased

only by seven per cent and dental hygienists by eight per cent. Below are the attendance numbers for select categories. 2008 figures are listed in parentheses for comparison: Dentists 6,983 (7,515), Dental hygienists 3,883 (4,216), Dental assistants 3,161 (3,699), Dental office personnel 2,248 (2,642), Dental technicians 369 (464), Dental students 675 (820), Dental hygiene or dental assistant students 1,603 (1,398), Dental trade 871 (1,262), Exhibitor attendees 9,061 (9,991).

The category showing the steepest decline was dental trade, which includes dental product manufacturers and distributors. This 30% drop was not unexpected, however, as attendance among this group usually falls during years in which the biennial International Dental Show in Cologne, Germany, is held. International attendance was 1,457. Although this represented a 26% drop from 2008, it was keeping with a decade-long trend in which international attendances waxes and wanes based on when the IDS is held.

The top five countries most represented at the meeting were: Canada 411, United Kingdom 241, Mexico 143, Germany 66, Japan 60.

In comparison, the top five states most represented at the meeting were: Illinois 12,047, Wisconsin 1,987, Indiana 1,749, Michigan 1,691, Ohio 561.

In 2010, the Chicago Dental Society will be moving to the west building at McCormick Place and shortening its meeting to three days. Exhibits and courses will open on Thursday morning and close on Saturday evening. With the new facility in the west building, CDS will also be able to house all courses and exhibits in one building. "These changes will make the meeting even more cost-effective and convenient for our attendees and exhibitors," Randall Grove, executive director of the Chicago Dental Society said. The society's new plans have already earned kudos from the Dental Trade Alliance, which called CDS "one of the most forward-thinking [show organizers]".

**Congratulations and Happy Birthday** to all DGZI-members around the world



## APRIL 2009

### 65<sup>th</sup> Birthday

ZA Hinrich Fischer (02.04.)  
ZTM Karsten Steinhage (20.04.)

### 60<sup>th</sup> Birthday

Dr Mohamad Mansour (15.04.)  
Dr Jürgen Bowien (18.04.)  
ZA Hans-Joachim Pein (20.04.)  
Dr Michael Hager (24.04.)  
Dr Angelina Protsch von Zieten (25.04.)

### 55<sup>th</sup> Birthday

Dr Walter Königer (01.04.)  
Dr Karl-Heinz Heuckmann (03.04.)

Dr Jörn Köpcke (10.04.)  
Dr Johannes Wurm (11.04.)  
Dr Ulrich Kachane (13.04.)  
Dr Rüdiger Hoffknecht (15.04.)  
ZA Beate Jaeger (19.04.)  
Dr Bernd Hetheier (21.04.)  
Dr Walter Swetly (25.04.)

### 50<sup>th</sup> Birthday

Dr Abdulhija Ahmad (01.04.)  
Dr Emad Salloun (17.04.)  
Dr Anneke Thalenhorst-Hüneke (23.04.)  
Dr Rainer Miazgowski (25.04.)  
Dr Joachim Kanzow (26.04.)

Jürgen Isbaner (27.04.)  
Dr Albert Deininger (29.04.)

### 45<sup>th</sup> Birthday

ZTM Falko Köpke (01.04.)  
ZA Sergej Horst (03.04.)  
Dr Pierre Bayssari (04.04.)  
Dr Rudolf Hefe (05.04.)  
Dr Regine Dressler (06.04.)  
Dr Klaus-Peter Elsmann (06.04.)  
Dr Stephan Girthofer (08.04.)  
Dr Helmut Baader (10.04.)  
Dr Magdy Mohamed Haitham (12.04.)  
Raafat Raad (15.04.)

Dr Thomas Böll (15.04.)  
Kersten Sander (18.04.)  
Dr Jens Pönisch (20.04.)  
Dr Steffen Hammer (28.04.)

### 40<sup>th</sup> Birthday

Dr Robert Folosea (02.04.)  
Dr Siegfried Hoelzer (07.04.)  
Dr Thorsten Hems (10.04.)  
Dr Robert Laux (13.04.)  
Dirk Aichinger (16.04.)  
ZA Axel Fay (18.04.)  
Dr Jochen Alexander Conradt (26.04.)  
Dr Ahmad Aba El-Lahif (26.04.)

## MAY 2009

### 70<sup>th</sup> Birthday

Dr Gert Plankensteiner (19.05.)  
Dr Nicolas Abou Tara (31.05.)

### 65<sup>th</sup> Birthday

Dr Günter Fröhlich (16.05.)

### 60<sup>th</sup> Birthday

Dr Marek Fischel (03.05.)  
Dr Aurel Netzer (09.05.)  
Dr Ayad M.A. Ismail (13.05.)  
Dr Karl-Heinz Brietze (13.05.)  
Dr Klaus Brandner (15.05.)

Dr Günther Dippmann (17.05.)  
Dr Rolf Scheulen (27.05.)  
Dr Attila Miklos (31.05.)

### 55<sup>th</sup> Birthday

Dr Najib Farhat (01.05.)  
Dr Michael Frey (02.05.)  
Dr Gregory Ribitzky (08.05.)  
Dr Chkera Assem (14.05.)

### 50<sup>th</sup> Birthday

Dr Urs Kühne (05.05.)  
Dr Jürgen Kleinwechter (08.05.)

ZA Falk Oberbrinkmann (09.05.)  
Dr Martin Helmut Wilhelm Steinbauer (09.05.)  
Dr Meir Potok (10.05.)  
Dr Patricia Klein (20.05.)  
ZTM Alexander Sirker (20.05.)  
Dr Ulrich Axmann (23.05.)  
Dr Ulf-Ingo Westphal (28.05.)

### 45<sup>th</sup> Birthday

Dr Joerg Grimmeisen (02.05.)  
Dr Michael Rathmann (05.05.)  
Dr Oliver Wellmann (05.05.)

Dr Markus Klaus (12.05.)  
Dr Torsten Glas (14.05.)  
Dr Michael Bruckschlegel (17.05.)  
Dr Oliver Otto (22.05.)  
Alireza Sina (25.05.)

### 40<sup>th</sup> Birthday

ZA Laszlo Pakozdy (03.05.)  
Dr Kannot Samer (12.05.)  
Stefan Mac Bretschneider (16.05.)

## JUNE 2009

### 65<sup>th</sup> Birthday

Dr Hans Jürgen Ritter (06.06.)  
Dr Bernd Triemer (06.06.)  
Dr Baruch Lurje (06.06.)

### 60<sup>th</sup> Birthday

Dr Peter J. Preusse (03.06.)  
ZA Thomas Zwietasch (24.06.)  
Dr Karl-Josef Besch (28.06.)  
Dr Burghard Hahn (29.06.)

### 55<sup>th</sup> Birthday

Dr Norbert Grittern (04.06.)  
Dr Detlev Jürgensen (09.06.)

Dr Frank Rupprich (09.06.)  
Winfried Zeppenfeld (09.06.)  
Dr Norbert Engel (16.06.)  
Dr Hans Thumeyer (17.06.)  
Dr Josef Vizkelety (24.06.)  
Dr Mohamad Hitham Al-Khiami (25.06.)

### 50<sup>th</sup> Birthday

Dr Klaus Philipp Berdel (04.06.)  
Dr Alois Müller (08.06.)  
Sabine Winnige-Rosenkranz (14.06.)  
Dipl.-Stom. Roman Stutzki (15.06.)  
Dr Jürgen Wedler (16.06.)  
Dr Karsten Kotthaus (18.06.)

Dipl.-Stom. Peter Herrnberger (23.06.)  
Dr Olaf Schön (27.06.)

### 45<sup>th</sup> Birthday

Dr Rainer Michael Braun (01.06.)  
Sabine Zude (17.06.)  
Dr Karl Heinz Sill (20.06.)  
Dr Thomas Schulz (21.06.)  
Dr Wolfgang Landefeld (29.06.)

### 40<sup>th</sup> Birthday

ZA Stefan Friedrich (02.06.)  
Dr Lutz Tiller (09.06.)  
Dr Ralf Falkenberg (09.06.)

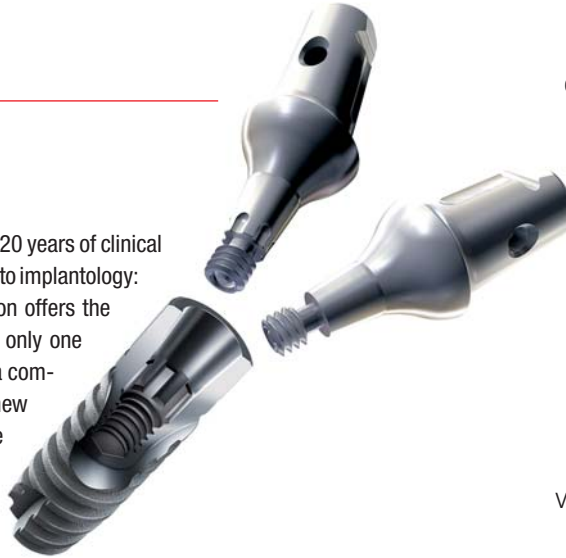
Dr Hakan Bilhan (10.06.)  
Michael Kissal (11.06.)  
ZTM Andreas Krimmel (11.06.)  
Dr Jürgen Kaul (20.06.)

# Manufacturer News

DENTSPLY Friadent

## ANKYLOS C/X— The New Generation

All the advantages of an implant system backed by 20 years of clinical success combined with an innovation that is unique to implantology: this is ANKYLOS C/X. The new ANKYLOS generation offers the option of indexed and non-indexed prosthetics in only one implant and also has newly designed prosthetics, a completed redesigned placement procedure, and a new package design. ANKYLOS C/X leaves it up to the dentist to decide whether to use the index to assist with positioning if that makes the prosthetic



delivery easier. Or use the tapered connection geometry without index if this is required by the prosthetic design. The abutment remains rotation-locked in both cases with the full-surface keyed and locked taper, and the combination options remain open: every abutment fits into every implant.

**DENTSPLY Friadent GmbH**

Steinzeugstraße 50

68229 Mannheim, Germany

E-mail: [info@friadent.de](mailto:info@friadent.de)

Web: [www.dentsply-friadent.com](http://www.dentsply-friadent.com)

W&H

## W&H steps on it: Extension of plant and new international plants

W&H, leader in the field of LED technology, proves to be more than optimistic contrary to all economic forecasts, and for a good reason: Products like the new LED instruments with generator or the new ozone generator Prozone once again emphasize the innovative power of the company and the claim

it lays to offering cross-application complete solutions. In order to be able to manufacture the growing product portfolio in the usual quality and with the well-tryed sell & call system, investments in the extension of the parent company in Bürmoos were made in the past two years: now a total of 25,000 square metres is at the disposal of the W&H Group in Austria alone. For the send-off of the largest construction investment of the company, the ground was broken on 20 March 2007—exactly at the beginning of the last IDS. The existing plant II at the town entrance of Bürmoos near Salzburg was reconstructed over a period of almost two years—and extended by 8,700 square metres. Management,

sales, marketing and representative units of the company such as training and conference rooms or the new showroom have been housed in the building since the end of 2008. In the first place, however, the area provides space for 1,500 square metres used for metal cutting and 500 square metres of additional assembly space where mainly equipment and instruments for dental restoration and prosthetics as well as prophylaxis and parodontology are produced.

“The extension of the plant is extremely important for our company because the newly obtained space capacities enable us to satisfy the demand for our high-quality technological products in a quick and flexible manner in the future too. This ensures efficient production in the medium term and the long term as well”, as DI Peter Malata, management of W&H, underlines this. With W&H Switzerland and W&H Sterilization, the new building in Bürmoos is the third construction project of the W&H Group that was completed between 2007 and 2009. At the same time, W&H Impex moved to a new location in Canada. And in the middle of April 2009, DMKA Singapore will also get off to a new start: the W&H service station for the Asia Pacific region will offer W&H technical premium service, which is to say a number of services on the highest level.



**W&H Deutschland GmbH**

Raiffeisenstraße 4

83410 Laufen, Germany

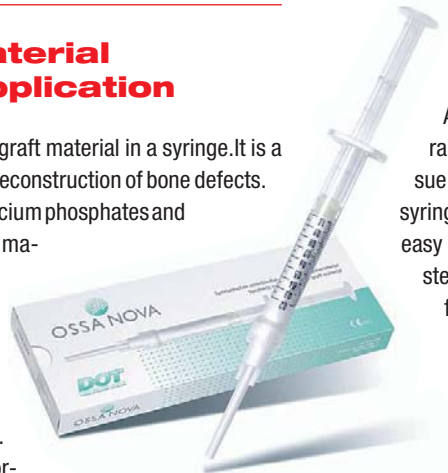
E-mail: [office.de@wh.com](mailto:office.de@wh.com)

Web: [www.wh.com](http://www.wh.com)

DOT

## Pasty Bone Graft Material for Easy and Safe Application

OSSA NOVA is a pasty, ready for use, bone graft material in a syringe. It is a new synthetic bone graft substitute for the reconstruction of bone defects. It consists of a mixture of nanocrystalline calcium phosphates and a biological active Silica dioxide matrix. The material is manufactured in a low temperature process without sintering which in turn leads to a high inner surface and a high porosity of the particles. OSSA NOVA furthermore shows a good capillarity for the deep diffusion of biological fluids (e. g. blood) combined with an adsorption of important growth factors present in blood. OSSA NOVA



represents a pasty injectable bone graft substitute-ready for use. The pasty consistence enables a close contact to defect borders with a formed closed application and leads to an optimal defect alignment.

After application OSSA NOVA will be integrated into the natural remodelling process and will be replaced by new bone tissue. OSSA NOVA can be applied directly into the defect using the syringe without any premixing, thus resulting in a more safe and easy application. The material is supplied in single syringes, sterilised by gamma irradiation. OSSA NOVA is available in the following package sizes: 0,25 ml/0,5 ml/1,0 ml with 1 and 2 syringes /package.

**DOT GmbH**

Charles-Darwin-Ring 1a  
18059 Rostock, Germany  
E-mail: sales@dot-coating.de  
Web: www.dot-coating.de

Nobel Biocare

## Nobel Biocare now on iTunes U

Nobel Biocare announced it is making free training and educational material available to dentists, dental specialists, students and patients on its new site found on iTunes U on the iTunes Store. Nobel Biocare is the first med-tech company to have its own presence on iTunes U. T&E (Training & Education) is one of Nobel Biocare's main strengths. One of the key trends in education on which Nobel Biocare wants to continue to build its reputation is the rapid development of e-learning. Found in the "Beyond Campus" section of iTunes U, Nobel Biocare's Training & Education program will provide easy, state-of-the-art on-demand e-learning. Beginning today, users can search and download training and education material directly from the site, and then experience it on their Mac or PC, or sync with iPod or iPhone to learn anywhere, anytime.

Today, Nobel Biocare already maintains T&E partnership agreements with twenty-four leading dental universities worldwide through its University Partner Program, a peer-to-peer collaboration that assists academic dental insti-

tutions to integrate the latest Crown, Bridge, and Implant coursework into their undergraduate programs. The Program provides academic institutions with the latest science-based treatment expertise, clinical competency development, high-tech educational tools, and support with implant restorations and CAD/CAM dentistry concepts.

Domenico Scala, CEO Nobel Biocare: "Nobel Biocare on iTunes U demonstrates our commitment to sharing our broad experience in T&E with the next generation of dental professionals. iTunes U provides an innovative way for us to engage millions of students and dental professionals with state-of-the-art dental education."

iTunes U is a dedicated area within the iTunes Store (www.itunes.com) featuring free educational content such as course lectures, language lessons, lab demonstrations and more. iTunes software, a free download, is required.

**Nobel Biocare AB**

Box 5190, 40226 Gothenburg, Sweden  
E-mail: info@nobelbiocare.com  
Web: www.nobelbiocare.com

Implant Direct

## Implant Direct launches compatible implant line with Straumann Dental Implant System\*

After the successful start of the European business with its own Spectra system and compatible implant lines with Nobel Biocare and Zimmer Dental, Implant Direct is expanding its product portfolio with implants and prosthetic parts that are compatible with Straumann, starting September 2008.

The SwissPlant® implant is both, surgically and prosthetically compatible with Straumann Standard/Standard Plus implants. This gives Straumann users the advantage of inserting SwissPlant implants without purchasing another surgical kit. The SwissPlant implants come with endosteal diameters of 4.1 mm and 4.8 mm, and with implant lengths of 6, 8, 10, 12, 14 mm, all with the characteristic blasted, micro-rough surface of Implant Direct. The prosthetic platform in-



cludes the traditional internal octagon of Straumann's implant-prosthetic connection. The implant has been improved to include mini-threads in the upper implant body reducing tensions in crestal bone, as well as double lead threads in the apical area. Due to the micro-rough surface of the implant neck it can be used for one-stage or two-stage procedures, providing a maximum of treatment flexibility.

\*registered trademark of Institut Straumann AG

**Implant Direct Europe**

Förrlibuckstrasse 150  
8005 Zürich, Switzerland  
E-mail: info-eu@implantdirect.com  
Web: www.implantdirect.eu

Sybron Implant Solutions

**Innovations for SybronPRO Series**

The SybronPRO series dental implant system was developed by Dr. Nick Elian and his team at New York University School of Dentistry. The system was introduced in North America in March of 2008 following two years of development and clinical investigation at NYU. Launch in Europe was in summer 2008. The goal was to develop an implant system that incorporated many of the design features currently available across many implant platforms, combining them into a single "best of breed" design. The investigators evaluated different implant systems, looking for features that contributed to hard and soft tissue preservation & long term success.

The SybronPRO system is the first to combine one-stage and two-stage implant designs, utilizing the same surgical instrumentation. Further, both implant designs share the same proven prosthetic connection, maximizing simplicity while minimizing component inventory.



**XRT with Narrow Neck**

The SybronPRO series XRT for an implantation at bone level, will additionally be available as narrow neck variation with two new platforms (3.5 and 4.1 mm). These implants with a narrow neck have an internal hex connection and will be ready for delivery as of the second quarter 2009. They offer a broad indication spectrum with the diameters of 3.3 mm, 4.1 mm and 4.8 mm and different lengths of 9, 11, 13 and 15 mm.

**Improved Surgical Instruments**

We are continuously looking for new ways of improving the handling of our instruments. The evaluation of customer information resulted in changes of our surgical drills and the depth gauge. We have

added gold-colored drills (instead of black) to our product line, and we have provided the drills with clearly visible depth markings. These improvements have been implemented in the meantime with the Lindemann drills,

the profiler drills and the depth gauge.

A brief instruction for insertion of the implants (illustrated) and the radiographic overlay (with overview on the implant size range) are now available for the surgical planning.

As a special offer, the SybronPRO implants XRT (for insertion of bone level) and TL (for insertion on tissue level) can be ordered at an absolutely favourable action price with a saving of up to 40% per implant plus free-of-charge surgical and prosthetic tray and healing abutments.

**Sybron Implant Solutions GmbH**

Julius-Bamberger-Straße 8a  
28279 Bremen, Germany  
E-mail: info@sybronimplants.de  
Web: www.sybronimplants.de

AD

Since our beginnings, we have always been focused on quality and innovation toward the battle against cross-contamination and infections.

In the last 20 years, we have ensured safety and protection to you and your patients, with advanced and reliable products. Tools that represent the ideal solution for who is operating in dentistry, implantology/oral surgery and general surgery.

With Omnia sure to be safe.

Surgical Line Safety Line MAXI®

**OMNIA®**  
Disposable Medical Devices

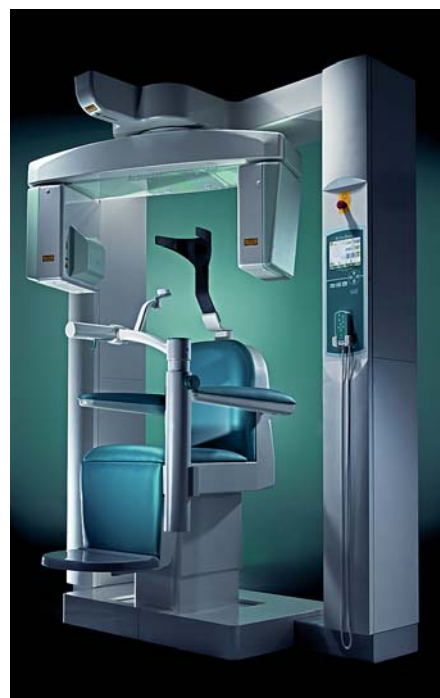OMNIA S.p.A.  
Via F. Delnevo, 190 - 43036 Fidenza (PR) Italy  
Tel. +39 0524 527453 - Fax +39 0524 525230  
www.omniasrl.com

J. Morita

**3D Accuitomo broads its range: the 170 version now provides four new image formats**

New intermediate formats permit the ambitious diagnostician to make use of a total of nine imaging formats. J. Morita have now broadened the capability of the 3D Accuitomo by adding another four image sizes. Visitors to the IDS could see for themselves the image quality across the whole range from ø 40 x H 40 to ø 170 x H 120 mm. Even the sceptics would be convinced by the resolution realized by the Voxel size of 80 µm in the largest format. The large field of view (FOV) is suitable for the precise diagnosis of the whole head region. Enhanced image dynamics enable greater precision in the visualization of hard and soft tissue. The built-in flat panel detector (FPD) technology provides a 14-bit greyscale and creates a balanced distribution of the contrasts.

Accuitomo is a name associated with many different applications, for example in implant therapy, for examinations of apical lesions, images of jaw joint, impactions, endodontics, restorative dentistry and surgery. The manufacturer says the exposure dose for the patients remains low for all the image formats.



3D Accuitomo 170: High resolution from ø 40 x H 40 mm to ø 170 x H 120 mm.

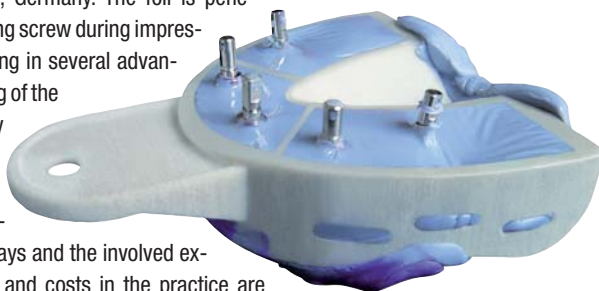**J. Morita Europe GmbH**

Justus-von-Liebig-Straße 27a  
63128 Dietzenbach, Germany  
E-mail: Info@JMoritaEurope.com  
Web: www.JMoritaEurope.com

Hager & Werken

## New Foil Tray for Precise Implant Impression in one Sitting

The new impression tray Miratray-Implant is a patented plastic foil tray allowing a highly precise implant impression in one sitting. The tray bottom consists of a thin, transparent foil that is firmly fixed to the tray frame by a special adhesive. This foil technology was developed by the team of Prof Dr Spiekermann and Dr Haselhuhn of the University Aachen, Germany. The foil is penetrated by the locking screw during impression taking resulting in several advantages: Firstly, fitting of the corresponding tray size is done with view, furthermore, the individual fitting of the trays and the involved expenditure of time and costs in the practice are avoided. Finally decisive is the fact that the laboratory costs for the individual unique tray are avoided and the sitting for situation impression taking becomes redundant. So, the Miratray-Implant impression tray, available in six standard sizes, combines the advantages of an individual tray regarding precision with the low costs of a serial production tray. More information under [www.hagerwerken.de](http://www.hagerwerken.de)



### Hager & Werken GmbH & Co. KG

Postfach 10 06 54  
47006 Duisburg, Germany  
E-mail: [info@hagerwerken.de](mailto:info@hagerwerken.de)  
Web: [www.hagerwerken.de](http://www.hagerwerken.de)

BEGO Implant Systems

## New implant abutment solutions— optimally designed for creating stable soft tissue structures

The BEGO Aesthetic Line was developed for dentists and dental technicians who want to take advantage of anatomically preformed abutments. "Surgically and prosthetically optimum" —these were the requirements while developing the new BEGO Aesthetic Line. In the medium-term, this new line of abutments, available in titanium and BEGO Wirobond® MI, will replace the entire range of BEGO Titanium and Wirobond® MI Abutments (anatomical, conical, parallel, angulated). For operators, this new abutment line creates the space needed for non-irritating soft tissue apposition, stabilises the soft tissue and helps prevent soft tissue recession. These new abutments also optimise the effort required for customising by dental technicians. Optimum aesthetics can be achieved in just a few steps.



### BEGO Implant Systems GmbH & Co. KG

Technologiepark Universität  
Wilhelm-Herbst Straße 1  
28359 Bremen, Germany  
E-mail: [wachendorf@bego.com](mailto:wachendorf@bego.com)  
Web: [www.bego-implantology.com](http://www.bego-implantology.com)

Premium  
quality at friendly  
prices



perfect aesthetics  
internal hex  
accelerated treatment

Xign®

Allfit®

The Allfit® Xign® implant system is designed for enossal dental implantations. The Xign® implant system is suitable for single-step and dual-step implant protocols. It is made of Grade 4 pure titanium. Xign® implants are abraded with aluminium oxide and hot-etched and have an osmotically active nanocoating. All accessory parts are colour-coded.

**IHDE DENTAL**   
the implant.company

Dr. Ihde Dental GmbH  
Erfurter Str. 19 · D-85386 Eching/Munich, Germany  
Telephone: (49) 89 319 761-0 · Fax (49) 89 319 761-33  
e-mail: [info@ihde-dental.de](mailto:info@ihde-dental.de) · [www.implant.com](http://www.implant.com)



NSK

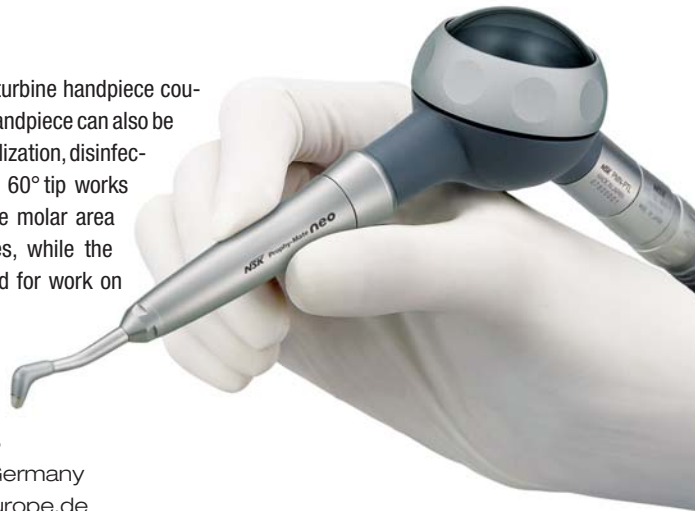
## Air Powered Tooth Polishing System

Prophy-Mate neo unites form and functionality for easier use. Excellent weight balance and a lightweight, compact powder chamber make Prophy-Mate neo comfortable to hold, while the original NSK handpiece connection swivels 360° even under strong air pressure. Selectable 60° and 80° tips maximize the cleaning ability. With powerful NSK original twin nozzles, cleaning time is greatly shortened thus reducing treatment time. Designed for one-touch attachment directly to NSK couplings

and major brands' air turbine handpiece couplings. The tips of the handpiece can also be easily removed for sterilization, disinfection and cleaning. The 60° tip works particularly well for the molar area and occluding surfaces, while the 80° tip is ideally suited for work on anterior teeth.

### NSK Europe GmbH

Elly-Beinhorn-Str. 8  
65760 Eschborn, Germany  
E-mail: info@nsk-europe.de  
Web: www.nsk-europe.de



CAMLOG

## New CAMLOG SCREW-LINE Implants with optional Platform Switching



CAMLOG SCREW-LINE implants have been a success story since market introduction in 2002. Thanks to the inner and outer geometric configurations, they have stood the hardest possible performance and reliability tests, i.e., their day-to-day use in clinic and dental practice. Based on this, CAMLOG introduced further improvements in SCREW-LINE implants at the IDS in March 2009: fine adjustment of the apical area by rounding plus slight thread reduction. These advances result in an even gentler and more tissue-conservative implant insertion. Additionally, the conical neck area has been drawn up higher toward the implant shoulder thus enlarging the contact zone between implant surface and bone in SCREW-LINE implants Promote®.

The new SCREW-LINE implants also offer the option of platform switching. Users now have the alternative of either following the accustomed protocol using standard abutments or deciding on platform switching. If indicated, this choice can even be taken after implantation.

### CAMLOG Biotechnologies AG

Margarethenstrasse 38  
4053 Basel, Switzerland  
E-mail: info@camlog.com  
Web: www.camlog.com

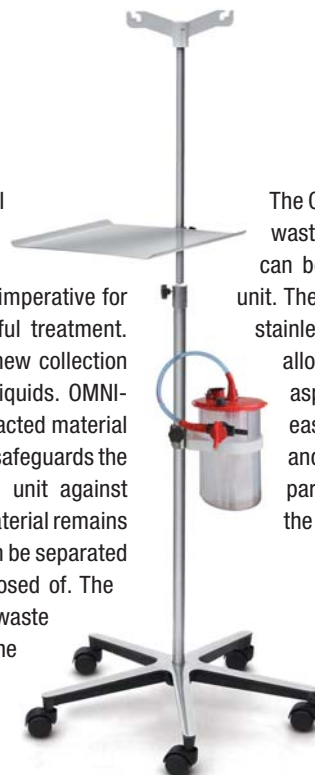OMNIA

## Collection system for organic waste liquids during surgical aspiration

The concept is very simple. Thanks to sheer gravity, extracted material is retained in the suction collection bag contained in the canister. Due to the created vacuum, liquids and particles of tissue from the treatment site are extracted and channelled into the collection bag. Blood, saliva and saline solution as well as particles of bone and surrounding tissue may cause blockages in your suction system. The suction system of your dental unit is in constant

use throughout oral surgical and implantological interventions.

Its failure-free operation is imperative for uninterrupted and successful treatment. This is guaranteed by the new collection system for organic waste liquids. OMNI-VAC system retains the extracted material and, in doing so, effectively safeguards the pump filter of your dental unit against blockages. The extracted material remains in the collection bag that can be separated from the canister and disposed of. The collection bag for organic waste liquids is disposable, while the Canister (1.5 Lt.) is autoclavable at 134 °C.



The OMNIA Collection system for organic waste liquids during surgical aspiration can be connected directly to the dental unit. The support for OMNI-VAC is made in stainless steel with wheeled basement. It allows the positioning of the OMNI-VAC aspiration system with the possibility of easily moving it in the surgery room, and it is possible to put 2 containers in parallel connection. It is possible to use the tray to support the Physiodispenser.

### Omnia S.p.A

Via F. Delnevo 190  
43036 Fidenza (PR), Italy  
E-mail: info@omniasrl.com  
Web: www.omniasrl.com



Carl Zeiss

## Visualization Solutions for Dentistry

### EyeMag® Medical Loupes—Seeing is Believing

The growing demands currently being placed on precision and quality are making loupes an indispensable tool in many fields of medicine. The outstanding features of EyeMag® medical loupes from Carl Zeiss are excellent imaging quality and superb wearing comfort. The brilliant, stereoscopic image helps to better differentiate between the smallest structures and increases the quality of your work.

### Dental Microscopes from Carl Zeiss—Take the quality of your work to a new level

Thanks to brilliant optics, precise and high-contrast, natural images, dental microscopes from Carl Zeiss allow the visualization of even the finest tooth and tissue structures.

### OPMI® pico—Brilliant optics and unique ease of use

The OPMI® pico dental microscope offers outstanding performance, a compact design and is easy to use. Thanks to unique front-to-back and lateral travel, OPMI® pico with MORA interface offers even more mobility and flexibility. A comfortable head and body posture is guaranteed as the OPMI® pico MORA interface can be positioned in any direction required by the dentist.

### OPMI® PROergo®—For a new dimension in vision

OPMI® PROergo® combines brilliant optical quality with operating comfort to deliver a uniquely designed product. The outstanding features of the fully mo-



torized dental microscope are its superb ease of use for relaxed and upright work in every treatment position. OPMI® PROergo® can be positioned continuously and precisely at the press of a button and offers the dentist a large number of functions for a new dimension in visual convenience.

All dental microscopes from Carl Zeiss offer the dentist various options to demonstrate his or her work to patients using images and videos or in lectures. In this way the dentist's work can be documented and visualized with excellent and impressive quality.

### Carl Zeiss Surgical GmbH

Carl-Zeiss-Straße 22

73447 Oberkochen, Germany

E-mail: [surgical@meditec.zeiss.com](mailto:surgical@meditec.zeiss.com)

Web: [www.meditec.zeiss.com/dentistry](http://www.meditec.zeiss.com/dentistry)

AD



Mark your diary now!

EXPRESSION OF INTEREST

[www.aosconference.com.au](http://www.aosconference.com.au)

AUSTRALASIAN  
OSSEointegration  
SOCIETY 7<sup>TH</sup> BIENNIAL  
CONFERENCE

4 - 7 NOVEMBER 09

GOLD COAST CONVENTION AND  
EXHIBITION CENTRE

GOLD COAST, QUEENSLAND  
AUSTRALIA

### CONFIRMED SPEAKERS INCLUDE

- **Professor Jan Lindhe**, University of Gothenburg, Sweden
- **Dr Michael Norton**, Private Practice, UK and Marquette University, USA
- **Professor Urs Belser**, University of Geneva, Switzerland
- **Dr Ueli Grunder**, University of Zurich, Switzerland
- **Dr Joseph Kan**, Loma Linda University, USA

To register your interest in attending the AOS09 Conference and to be placed on the mailing list to receive further information as it becomes available, register your details online at [www.aosconference.com.au](http://www.aosconference.com.au) or email your full contact details to [info@aosconference.com.au](mailto:info@aosconference.com.au).

### AOS09 CONFERENCE MANAGERS

c/ Event Planners Australia  
PO Box 1517  
Eagle Farm QLD 4009  
AUSTRALIA

T: +61 7 3858 5525

F: +61 7 3858 5499

E: [info@aosconference.com.au](mailto:info@aosconference.com.au)

W: [www.aosconference.com.au](http://www.aosconference.com.au)

Titanium sponsor



Platinum sponsors



Gold sponsor



Silver sponsor




[www.aosconference.com.au](http://www.aosconference.com.au)

Surf and learn at the Gold Coast in November 2009 – the perfect location!

# implants

international magazine of oral implantology



|                                |   |  |
|--------------------------------|---|--|
| <b>Publisher</b>               | Torsten R. Oemus  | oemus@oemus-media.de   |
| <b>Chief Executive</b>         | Jürgen Isbaner  | isbaner@oemus-media.de   |
| <b>Chief Editorial Manager</b> | Dr. Torsten Hartmann (V. i. S. d. P.)   | hartmann@dentalnet.de  |
| <b>Editorial Council</b>       | Dr. Friedhelm Heinemann<br>Dr. Roland Hille<br>Dr. Winand Olivier<br>Prof. Dr. Dr. Kurt Vinzenz<br>Dr. Torsten Hartmann<br>Dr. Suheil Boutros             | friedhelmheinemann@web.de<br>dr-hille@t-online.de<br>dr.olivier@t-online.de<br>kurt.vinzenz@aon.at<br>hartmann@dentalnet.de<br>SMBoutros@aol.com |
| <b>Editorial Office</b>        | Kristin Urban<br>Katja Kupfer   | k.urban@oemus-media.de<br>kupfer@oemus-media.de  |
| <b>Executive Producer</b>      | Gernot Meyer  | meyer@oemus-media.de   |
| <b>Art Director</b>            | Dipl.-Des. Jasmin Hilmer  | hilmer@oemus-media.de  |
| <b>Customer Service</b>        | Marius Mezger   | m.mezger@oemus-media.de  |
| <b>Published by</b>            | Oemus Media AG<br>Holbeinstraße 29<br>04229 Leipzig, Germany<br>Phone: +49-3 41/4 84 74-0<br>Fax: +49-3 41/4 84 74-2 90<br>E-mail: kontakt@oemus-media.de |  |

**implants** international magazine of oral implantology is published in cooperation with the German Association of Dental Implantology (DGZI).

**DGZI President** Dr. Friedhelm Heinemann  
DGZI Central Office  
Feldstraße 80, 40479 Düsseldorf, Germany  
Phone: +49-2 11/1 69 70-77  
Fax: +49-2 11/1 69 70-66  
E-mail: office@dgzi-info.de

[www.dgzi.de](http://www.dgzi.de)  
[www.oemus.com](http://www.oemus.com)

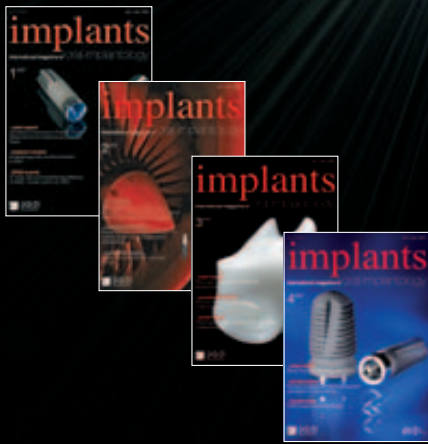## implant\_Copyright Regulations

*the international magazine of oral implantology* is published by Oemus Media AG and will appear in 2009 with one issue every quarter. The magazine and all articles and illustrations therein are protected by copyright. Any utilization without the prior consent of editor and publisher is inadmissible and liable to prosecution. This applies in particular to duplicate copies, translations, microfilms, and storage and processing in electronic systems.

Reproductions, including extracts, may only be made with the permission of the publisher. Given no statement to the contrary, any submissions to the editorial department are understood to be in agreement with a full or partial publishing of said submission. The editorial department reserves the right to check all submitted articles for formal errors and factual authority, and to make amendments if necessary. No responsibility shall be taken for unsolicited books and manuscripts. Articles bearing symbols other than that of the editorial department, or which are distinguished by the name of the author, represent the opinion of the afore-mentioned, and do not have to comply with the views of Oemus Media AG. Responsibility for such articles shall be borne by the author. Responsibility for advertisements and other specially labeled items shall not be borne by the editorial department. Likewise, no responsibility shall be assumed for information published about associations, companies and commercial markets. All cases of consequential liability arising from inaccurate or faulty representation are excluded. General terms and conditions apply, legal venue is Leipzig, Germany.

# implants

International magazine of oral implantology



for specialists around  
**the world**

Hereby I wish to subscribe to **implants** (4 issues per year)

44 €\* for German Customers | 46 €\* for Customers outside Germany

\*all prices include shipping and handling costs

#### PERSONAL DETAILS/SHIPPING ADDRESS

Name

Position/Dept.

Company

Address

Country/ZIP

Telephone

Facsimile

E-mail

Date/Signature

Your personal data will be recorded and retained by Oemus Media AG, Holbeinstraße 29, 04229 Leipzig, Germany. Your personal data is used for internal purposes only. The subscription will be renewed automatically every year until it is cancelled six weeks in advance before renewal date.

IM 2/09

#### PAYMENT OPTIONS

Credit Card:  VISA

MasterCard

Card Number

Expiry date

Name (as it appears on the card)

KPN/CW2/CVC2 No.

3-4 digits in the signature area on the back of the credit card

OEMUS MEDIA AG

Holbeinstraße 29

04229 Leipzig, Germany

Tel.: +49-3 41/4 84 74-2 01

Fax: +49-3 41/4 84 74-2 90

www.oemus.com

grasse@oemus-media.de



# EXTRAORDINARY

Introducing a new implant from one of the most respected names in dentistry - *Sybron*.  
Our new Sybron**PRO™XRT** incorporates an extraordinary array of features  
proven to address immediate stability, preservation of crestal bone<sup>2</sup>,  
and long-term aesthetics.

Call us today to experience the EXTRAORDINARY for yourself!

<sup>1</sup>Surgical and Mechanical Techniques to Increase Stability of Dental Implants. Kharouf, Zeineb; Oh, Hyeong Cheol; Saito, Hanae; Cardaropoli, Giuseppe; Bral, Michael; Cho, Sang-Choon; Froum, Stuart; Tarnow, Dennis. Ashman Department of Periodontology and Implant Dentistry, New York University. Research presented at the AO Boston 2008.

<sup>2</sup>Implant Design and Its Effect on Preservation of Crestal Bone Levels. Jang, Bong-Joon; Pena, Maria Luisa; Kim, Mean Ji; Eskow, Robert; Elian, Nicolas; Cho, Sang-Choon; Froum, Stuart; Tarnow, Dennis. Ashman Department of Periodontology and Implant Dentistry, New York University. Research presented at the AO Boston 2008.

**Sybron – Celebrating over 100 years of dental excellence**

Europe  
Sybron Implant Solutions GmbH  
Julius-Bamberger-Str. 8a  
28279 Bremen, Germany  
T 49.421.43939.0  
info@sybronimplants.de

United Kingdom  
4 Flag Business Road  
Vicarage Farm Road  
Peterborough, PE1 5TX, UK  
T 008000 841 2131

France  
16 Rue du Sergent Bobillot  
93100 Montreuil, France  
T 33.149.88.60.85

Australia  
# 10, 112-118 Talavera Rd  
North Ryde, NSW 2113  
T 61.2.8870.3099

**HEADQUARTERS**  
USA  
1717 West Collins Avenue  
Orange, California 92867  
T 714.516.7800



[www.sybronimplants.com](http://www.sybronimplants.com)

**Endo e Class**  
سیستم هوشمند اندوروتاری  
۱۵ حافظه، انیوتن ترک (user friendly)

**KI20**  
موتور جراحی ایمپلنت  
قدرتمندترین موتور جراحی ایمپلنت دنیا  
با ترک ۹۰ نیوتن

**ENDO SMART**  
سیستم هوشمند  
اندو روتاری

**IROOT S**  
اپکس لوکیتور  
نسل پنجم با دقت ۹۸/۸  
با نرم افزاز ویژه

**Rootor**  
اپکس لوکیتور

**Cybrid**  
لایت کیور  
با قدرت فوق العاده ۲۷۰۰ وات

**META BIOMED**

**Endo pex**  
آبچوراتور (گان + هیت کریر)

سیستم تزریق گرم گوتا پرکا و فیلینگ ورتیکال با تراکم عمودی ساده و آسان با نتیجه متفاوت



**E&QMASTER**  
آبچوراتور (گان + هیت کریر)



**GENESYS**  
آبچوراتور (گان + هیت کریر)