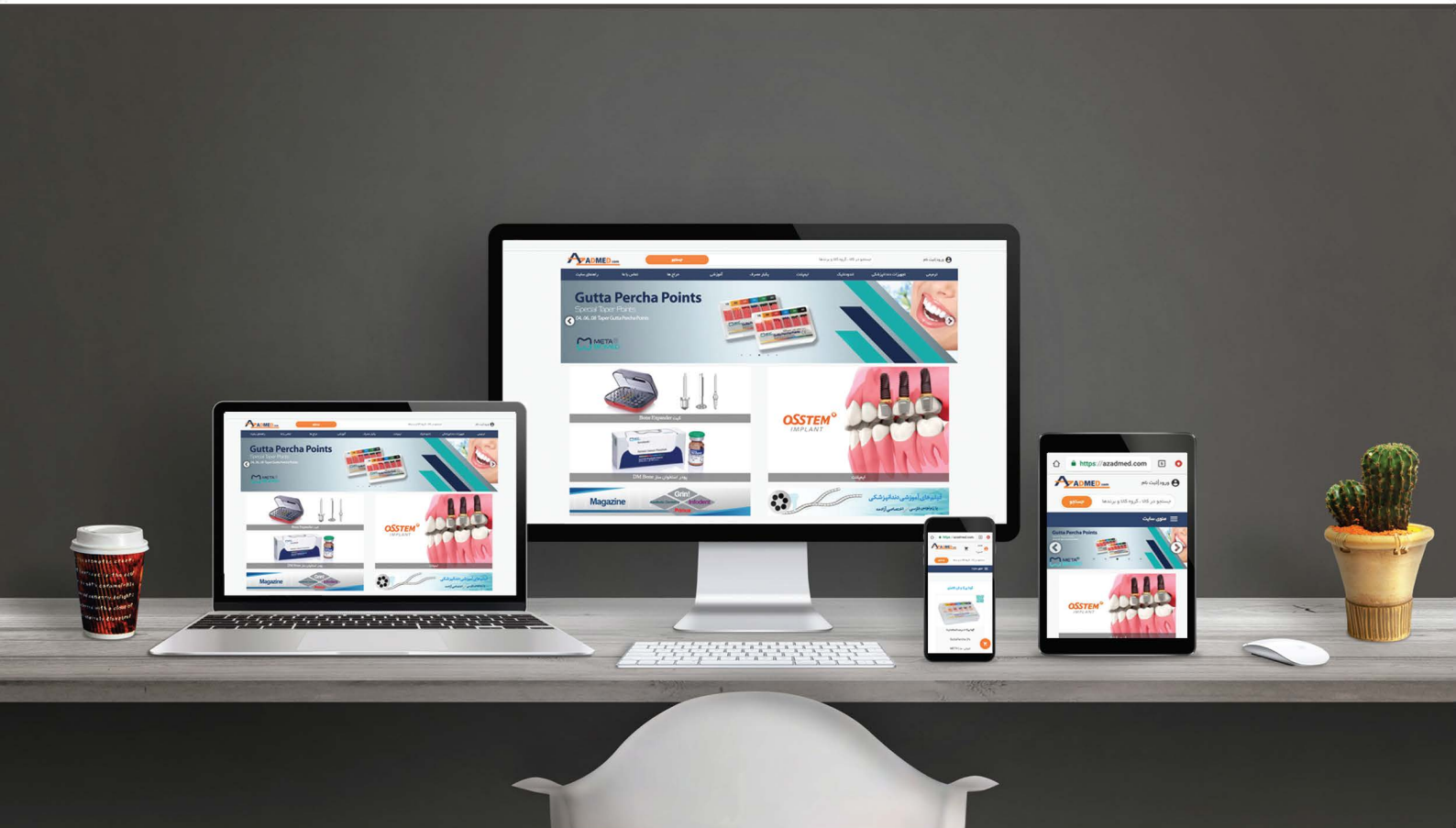




آزاد تجارت پارس
AZAD TEJARAT PARS.LTD

AZADMED.com



www.azadmed.com



 azaadtejaratpars

 @azadmed2

 88 98 80 63 - 6

implants

international magazine of oral implantology

2²⁰¹¹

ADMED
ADMED.com

| **special**

Back to the egg:
An evidence-based endo-implant
algorithm (Part II)

| **clinical technique**

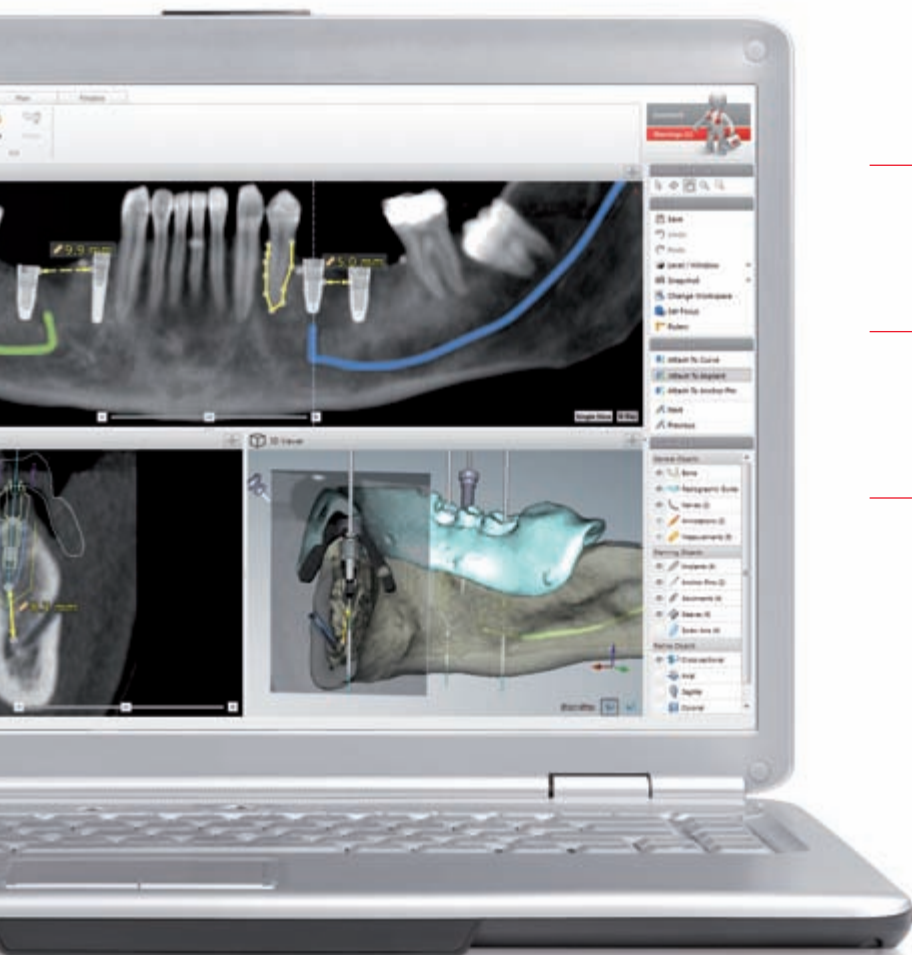
A simplified method for the removal
of cemented implant prosthetics

| **meetings**

DGZI's 41st International Annual Congress
celebrated in autumn in Cologne

0277113

Take diagnostics and planning to the next level.



Maximize treatment safety and predictability.

Enhance quality and efficiency through digital diagnostics.

Enjoy planning flexibility for optimized function and esthetics.



It's called NobelClinician Software. You can diagnose and plan treatments with a new level of predictability and safety. Enhance your diagnostics with combined 2D and 3D views and optimize implant placement based on patient anatomy and prosthetic needs. Using NobelClinician Software, you can collaborate with your treatment partners through the integrated NobelConnect functionality and present treatment

options to your patients. In addition, you have the option to complete the digital path with the proven guided surgery concept NobelGuide. When you partner with Nobel Biocare, a pioneer in digital dentistry, you benefit from proven technology that ensures superior function and natural-looking esthetics. **Their smile, your skill, our solutions.**

nobelbiocare.com/digital



The key to success

The **IDS in Cologne**, the world's largest dental show, has again closed its doors. With over 2,000 exhibitors from 59 countries it was once more a superlative exhibition. The variety of cultures, different therapeutic approaches, and numerous innovations on display absolutely overwhelmed visitors.

For oral implantology, the digitalization of treatments came to the fore, as this technology will certainly be a very exciting topic in future and will no doubt result in a great deal of information for the field. Due to 3-D diagnostics, computer-aided planning, navigation, and digital impression-taking of CAD/CAM manufactured prosthetics, there seems to be no limit to the increased use of technology in our practices, and in view of our changing job descriptions.

Patients agree with the increased use of technology in their treatment, for it reflects their own day-to-day life experiences. It is our duty as responsible dentists to balance therapies which are scientifically proven to a certain degree of accuracy with any error sources and inadequacies to which we may justifiably expose our patients.

These technical capabilities open up a wide range of dental treatments for dentists and patients as well. It is now up to us to integrate medically sensible and scientifically approved innovations into our everyday work.

Technological development continues to progress, but without an appropriate scientifically-based education (i.e. curriculum, sitting in on classes, and supervision) implantology still cannot be carried out successfully for the benefit of our patients. The key to success is to combine the knowledge base of implantology (including all physiological and biological aspects) with a highly qualified surgical and prosthetic procedure. Digitalization is one means of measuring success. The better the dentist's basic education, the more he will be able to improve the results of his treatment by means of digitalization.

On the occasion of its 41th International Annual Congress, which will take place in Cologne from September 30 until October 1, 2011, DGZI will once again interest you with its congress topic of "Implantology—requirements, possibilities and expectations" and its excellent expert contributions regarding current issues. Allow yourself to be entertained by our podium discussion on the topic "Digital implantology—What should and what must be done?" Here, well-qualified experts will highlight contrasting positions and offer recommendations for your future work, as DGZI remains committed to science as well as success in practice.

I look forward to welcoming you in Cologne and am eager to exchange ideas with you all.

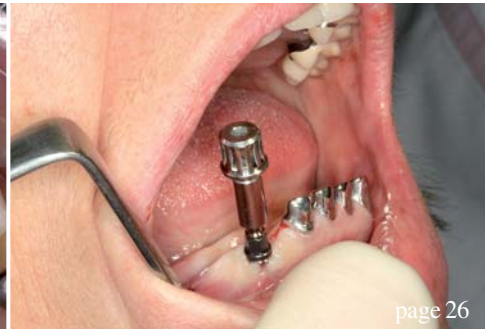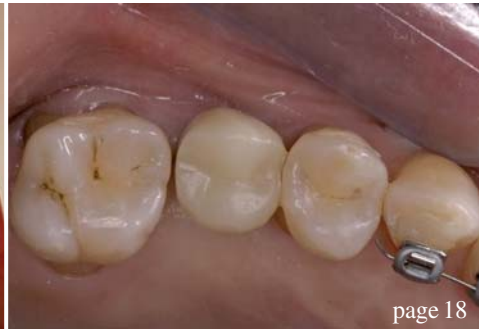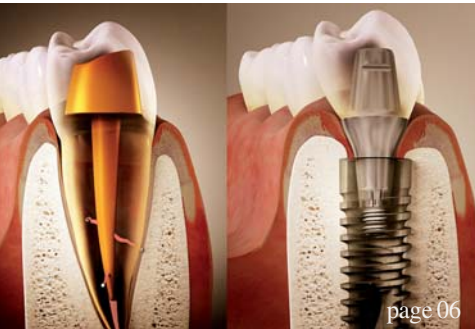Kindly Yours,



Dr med dent Roland Hille



Dr med dent Roland Hille



| **editorial**

03 **The key to success**
| Dr med dent Roland Hille

| **special**

06 **Back to the egg:**
An evidence-based **endo-implant algorithm** (Part II)
| Dr Kenneth Serota

18 **The surgically accelerated orthodontics** in
multidisciplinary implant treatment
| Federico Brugnami *et al.*

| **clinical technique**

20 **The maintenance of crestal bone**
around dental implants
| Dr Mohammed A. Alshehri

26 **Implant-prosthetic troubleshooting**
| Dr Georg Bach *et al.*

32 **A simplified method** for the removal
of cemented implant prosthetics
| Dr Scott Davis

| **user report**

36 **Augmentation**—one important basis in
implant treatment concept
| Prof Dr med Frank Liebaug *et al.*

| **meetings**

40 **Biggest IDS** ever
42 **DGZI's 41st International Annual Congress**
celebrated in autumn in Cologne
| Eva Kretzschmann

| **news**

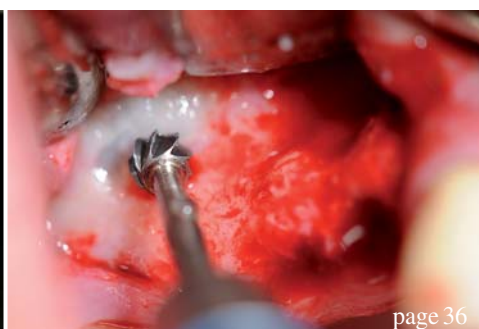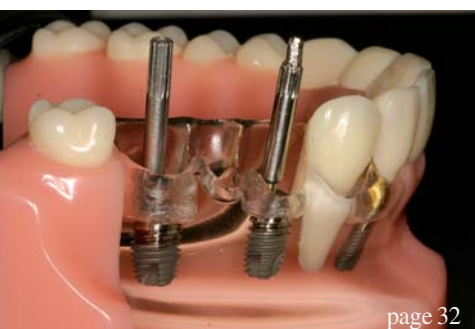46 **Manufacturer News**

| **about the publisher**

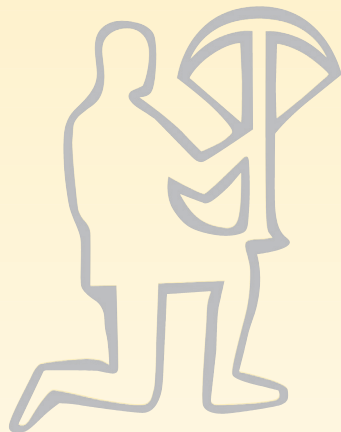

50 | imprint







Cover image courtesy of Neoss GmbH,
www.neossimplant.com



IMPLA™ Implants - simply safe



IMPLA™ Dual Surface

- ideal for compact bone
- optimised for gingiva-level insertion

IMPLA™ Micro Retention

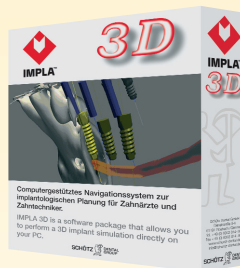
- optimised for soft bone and sinus elevation
- ideal for primary stability

IMPLA™ Mini Implant


- ball or conical attachment
- minimally invasive
- easy to insert

IMPLA™ Cylindrical

- no additional thread cutting necessary
- integrated platform switching



IMPLA™ 3D
Navigation



IMPLA™ surgery box
The all-round box

For more information visit our homepage
www.schuetz-dental.com
or request our catalog!



Back to the egg: An evidence-based endo-implant algorithm (Part II)

Author_ Dr Kenneth Serota, USA

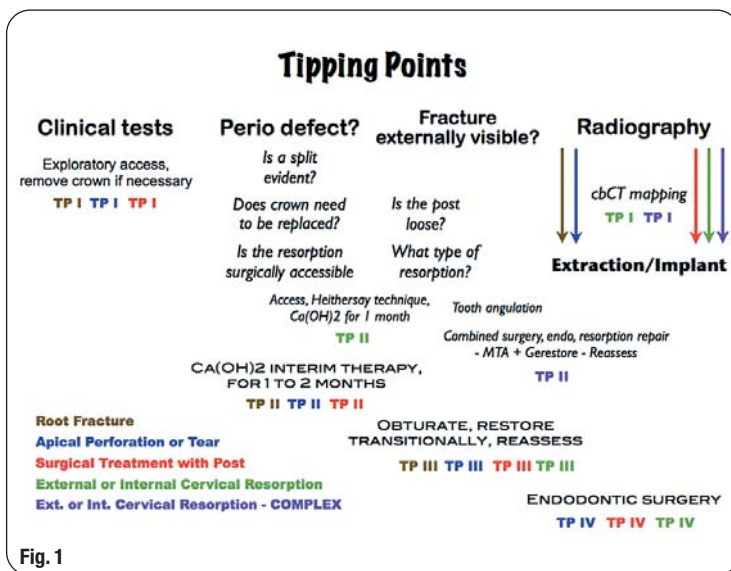


Fig. 1 The term *tipping point* refers to the moment of critical mass, the threshold, the boiling point. The colour sequence highlights the diagnostic steps to be followed in each tipping-point algorithm for the listed pathological states.

The laws of nature are but the mathematical thoughts of God.

—Euclid of Alexandria

_Four thousand years ago, a number of Babylonian legal decisions were compiled in what came to be known as the *Code of Hammurabi*. The decision with reference to the construction of dwellings and the responsibility for their safety begins: If a builder engineers a house for a man and does not make it firm, and the structure collapses and causes the death of the owner, the builder shall be put to death. We are all builders or engineers of sorts; we calculate the path of our arms and legs with the computer of our brain and we catch baseballs and footballs with greater dependability than the most advanced weapons system intercepts missiles. In our professional lives, however, in contradistinction to the paradigm of evidence-based dentistry, our efforts as builders often rely solely upon personal experience, intuitive cognition and anecdotal accounts of successful strategies.

Table I As reported by Chugal *et al.*, the most significant vector relevant to post-op healing is the presence and magnitude of pre-op apical periodontitis.¹⁷

The challenges posed by implant-driven treatment planning mandate vigilance of the interaction between those involved in research and development, manufacturing and distribution and the leaders of ideologically diverse disciplines. Temporal shifts and trends in the service mix are part of the evolution of the art and science of dentistry; to some degree, the implant-driven vector has captured the hearts and minds of those who seek to nullify preservation of natural tooth structure in the oral ecosystem and deify ortho-biological replacement. The corporate entities from which we derive our tools too often fail to distinguish the point at which science ends and policy begins.

By positioning advocates and acolytes at the vanguard of their marketing campaigns, they effect change; however, their support for education is directed towards dissemination of product, not the fundamentals and rudiments of biological imperatives. Prospective large cohort clinical trials with clearly defined criteria for survival, with and without intervention, quality of life information and economic outcomes are essential to comparing alternative foundational treatments. These studies will require expertise, time and financial support from the various stakeholders, professional and corporate alike.¹

The authority of those who teach is often an obstacle to those who want to learn.

—Marcus Tullius Cicero

| Size in mm | Success in % |
|------------|--------------|
| 0 | 87.6 |
| 1-5 | 65.7 |
| >5 | 56.2 |

CHEAPLY IMPLANTS BETTER IMPLANTS AS IHDE DENTAL



SAY IT TO ALL!

www.banal-implants.de

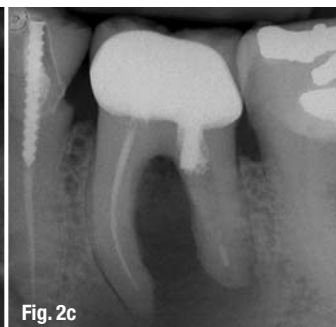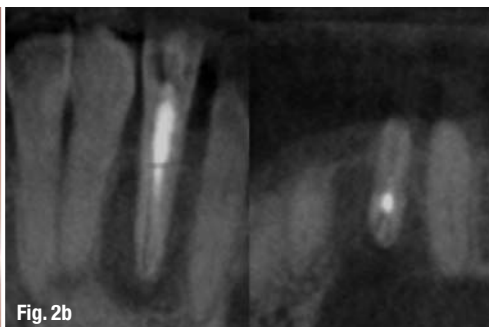
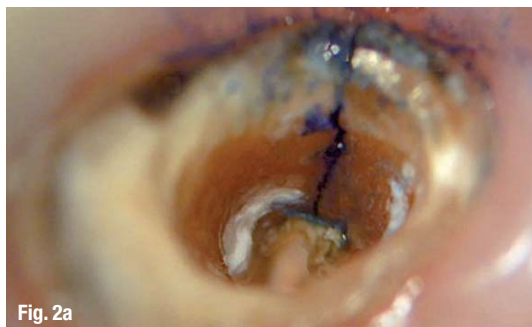


Fig. 2a The use of dyes, colouring agents and micro-etching is invaluable in visualising a suspected crack in tooth structure. Cohen *et al.* found that when premolars were used as bridge abutments, a surprising number of these abutments sustained a VRF.⁶¹

Fig. 2b The dental literature reports a statistically higher level of accuracy using CBCT (cone-beam computed tomography) scans for detecting VRF than with the use of peri-apical radiography alone.

Fig. 2c The multivariate nature of the endo-implant algorithm mandates the use of CBCT to detect and evaluate the degree of peri-apical pathosis. Analysis of the size, extent, nature and position of peri-apical and resorptive lesions in three dimensions is essential for the optimal level of standard of care in diagnosis.

The prosthodontic pundits maintain that the spiralling costs of saving endodontically **retreated** teeth, for which extraction may well prove to be the common endpoint, bring into question whether such teeth should be sacrificed early. Ruskin *et al.* concluded that implants have greater success than endodontic therapy, are more predictable, and cost less when one considers the 'inevitable' failure of initial root-canal treatment, retreatment and peri-apical surgery.² Is it responsible therapeutics or irresponsible expediency that justifies the removal and restoration of such teeth from the outset with an implant-supported restoration? Can one ethically argue that extraction is warranted because the financial cost of orthodontic extrusion/soft-tissue surgery, endodontic retreatment and post/core/crown fabrication is greater than extraction with an implant-buttressed restoration, and in all likelihood, more predictable?³

Jokstad *et al.*⁴ identified over 220 implant brands in the dental marketplace. With variability in surface, shape, length, width and form, there are potentially more than 2000 implants for any given treatment situation. A systematic review by Berglundh *et al.*⁵ assessed the reporting of biological and technical complications in prospective implant studies. Their findings indicated that while implant survival and loss were reported in all studies, biological difficulties, such as sensory disturbance, soft-tissue complications, peri-implantitis/mucositis and crestal bone loss, were considered in only 40 to 60% of studies. Technical complications such as component/connection and superstructure failure were addressed in only 60 to 80% of the studies. Are we as a profession standing idly by and watching marketing pressures force treatment decisions to be made empirically, with untested materials and techniques? There is an unsettling similarity between these events and the early days of implant development.⁶

The endodontic pundits argue that major studies published to date suggest there is no difference in long-term prognosis between single-tooth implants and restored root-canal treated teeth. In fact, regardless of the similarity of treatment outcomes, the preponderance of post-treatment complications favours

endodontic therapy. Therefore, the decision to treat a tooth endodontically or to place a single-tooth implant should be based on criteria such as restorability of the tooth, quality and quantity of bone, aesthetic demands, cost-benefit ratio, systemic factors, potential for adverse effects and patient preferences.⁷⁻¹¹ A review of endodontic treatment outcomes by Friedman and Mor¹² used radiographic absence of disease and clinical absence of signs and symptoms as the defining parameters for success. They suggested that the chance of having a tooth extracted after failure from initial endodontic treatment, retreatment and apical surgery collectively would be roughly one in 500 cases.

The dialogue comparing endodontic treatment to implant therapy jarringly overlooks the crucial fact that it is often the calibre of the restoration and its prognosis, and not the endodontic prognosis *per se*, that is the determinant of the treatment outcome. The primary biological mandate of any dental procedure is the retention of the orofacial ecosystem in a disease-free state. Surgical and non-surgical endodontic therapies have historically been key modalities in the attainment of this foundational goal. Friedman noted that "the patient weighing one 'success' rate against the other may erroneously assume their definitions to be comparable and select the treatment alternative that appears to be offering the better chance of 'success.'"¹³ The conundrum with which researchers and clinicians alike wrestle increasingly includes the non-science of emotion as well.

This publication will address non-surgical and/or surgical resolution of failing primary endodontic treatment outcomes and the historical and ongoing efforts of the dental industry to engineer the biomimetic replacement of natural teeth successfully and replicate the structural predicates that comprise the substitution algorithm of bone, soft tissue and tooth. There are many levels to the accrual of 'best evidence dentistry'. The purpose of this paper is to ensure that all variables in the treatment planning equation of foundational dentistry are understood and given equal weight in the decision-making process for comprehensive care.

Whenever possible, the treatment choice should be an attempt to salvage a tooth using a multidisciplinary team approach, putting aside preconceived notions and biases. Finances should not dictate the advice proffered. Furthermore, it is advisable to forego being clinically 'conservative'. Treatment should not be initiated in the absence of a critical evaluation of the potential for all contributing factors to equate to a positive outcome. When needed, care must be taken to carry out every diagnostic procedure available, even those of a more invasive nature (Fig. 1). Before arriving at a definitive diagnosis and treatment plan, the clinician should obtain consent from the patient to remove any restoration in order to analyse the residual tooth structure and assess the potential to carry out reliably predictable treatment. The patient must understand in detail, the feasibility of and margin for success of each treatment option presented.¹⁴

There are few studies in the endodontic literature analysing the reasons for extraction of endodontically treated teeth. Root-filled teeth are invariably prone to extraction due to non-restorable carious destruction and fracture of unprotected cusps. Tamse *et al.* found that mandibular first molars were extracted with greater frequency than maxillary first molars; the most significant causal difference was the incidence of vertical root fracture (VRF—1.8% maxillary molar, 9.8% mandibular molar).¹⁵ Teeth **not** crowned after obturation are lost with six times the frequency of those restored with full coverage restorations.¹⁶

Procedural failure, iatrogenic perforation or stripping, idiopathic resorption, trauma and periodontal disease all contribute to a lesser degree. The major biological factor that influences endodontic treatment outcome failure with the possibility of extraction appears to be the extent of microbiological insult to the pulp and peri-apical tissue, as reflected by the peri-apical diagnosis and the magnitude of peri-apical pathosis (Table I and Figs. 2a–c).¹⁷

Dentine is the most abundant mineralised tissue in the human tooth. In spite of this importance, over half a century of research has failed to provide consistent values of dentine's mechanical properties. In clinical dentistry, knowledge of these properties is pivotal to any number of variables, ranging from innovations in preparation design to the choice of bonding materials and methods. The Young's modulus (the measure of the stiffness of an isotropic elastic material) and the shear modulus (modulus of rigidity) are diminished by viscoelastic behaviour (time-dependent stress relaxation) at strain rates of physiological (functional) relevance. The reported tensile strength data suggests that failure initiates at flaws. These flaws may be intrinsic, perhaps regions of altered mineralisation, or extrinsic, caused by cavity or post-channel preparation, wear, or damage. There have been few studies of fracture toughness or fatigue.¹⁸ Finally, little is known about the biomechanical properties of altered forms of dentine subsequent to decay, the influence of irrigants and chemicals, and the choice of curing techniques used for bonded restorations.¹⁹

Studies suggest that there are at least two forms of transparent or sclerotic dentine: a form associated with caries and a form associated with age-related changes in the root. The impact upon tooth strength as a function of these altered forms of dentine is not well understood. The long-term predictability of residual coronal tooth structure to function in a manner commensurate with the demands of the orofacial ecosystem may need to be reassessed in light of observations that sclerotic dentine, unlike normal dentine, does not exhibit yielding before failure and that the fatigue lifetime is deleteriously affected at high stress levels.²⁰ Mechanisms for energy dissipation and crack growth resistance present in young dentine are not present in old dentine. Restorative methods and techniques, particularly regarding ferrule creation for endodontically treated teeth, may need to be amplified to address the fact that fatigue crack growth resistance of dentine decreases with age (Fig. 3).²¹

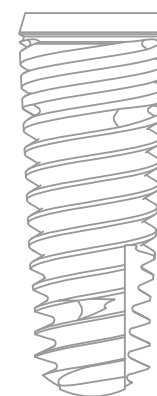
TRI

dental implants

TRI®

Performance Concept

The Swiss implant provider TRI Dental Implants presents its patented TRI® implant concept with three essential success factors - released after test market with 5000 implants.



1. TRI® -Friction

Secure frictional implant-abutment connection

Elimination of micro movements

Seal effect for platform switching

2. TRI® -BoneAdapt

Step-design for ideal bone adaptation

Progressive cutting design

Protected cortical design

3. TRI® -Grip

Increased primary stability

Enhanced control during placement

Superior guidance and direction

Available implant lines:

TRI-Vent^o (€ 115): Ø 3.75/4.1/4.7mm

compatible to Tapered Screw-Vent (Zimmer Dental)**

TRI-Log^o (€ 115): Ø 3.8/4.1/4.7mm

prosthetically compatible to K-Serie (Camlog)**

Test our free introductory implant set.
Each additional implant incl abutment 150 Euro*.

*Offer only includes titanium abutments
**Registered trademarks of Zimmer Dental and Camlog AG.

Through Research Innovative
www.tri-implants.com
Free Infoline: 00800 3313 3313

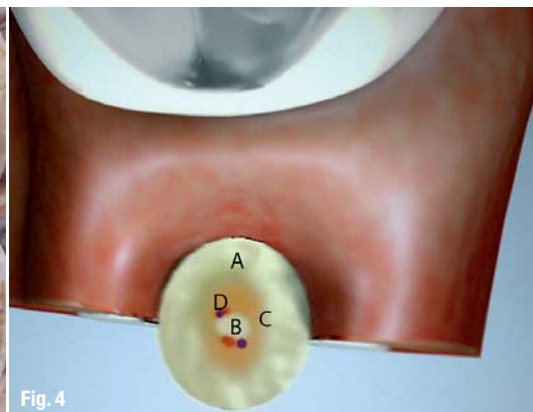
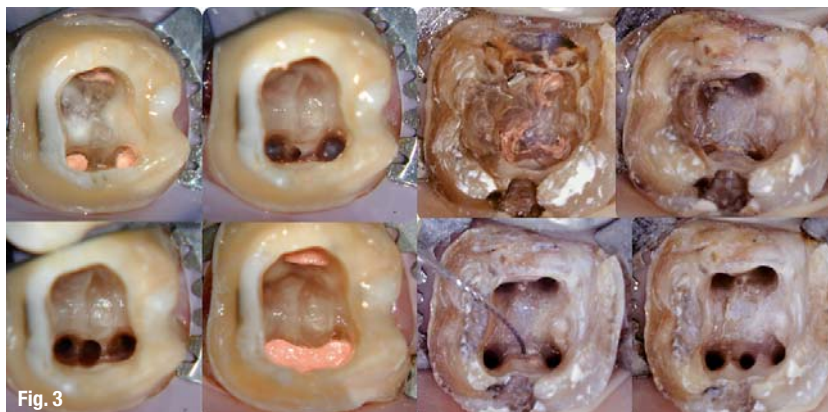

Fig. 3 Two different retreated teeth; two different potential treatment outcomes. The root-canal system of both teeth has been re-engineered in its anatomic entirety; however, the treatment outcome after restoration for both is unlikely to be the same. Regenerative technologies incorporating mesenchymal stem cells derived from dental tissues may one day obviate the concern.

Fig. 4 Less porous, less hydrated and highly mineralised outer dentine (a); pulp canal space (b); more porous, more hydrated and less mineralised inner dentine (c); water in the dentinal tubules and pulp space is held in a confined environment under hydrostatic pressure (d).

Understanding the mechanical properties of teeth is essential in order to address the most common clinical problem affecting all endodontically treated teeth, fracturing, which in spite of even minimal loss of tooth structure may be severe enough to necessitate removal.²²⁻²⁴ The hypothesis that dentine brittleness increases with diminished moisture content has been debunked; conserving bulk dentine is the *sine qua non* of fracture prevention. Kuttler *et al.* reported that dentine thickness correlates inversely to post-space diameter in the distal roots of mandibular molars.²⁵ A size #4 Gates-Glidden drill caused strip perforations in 7.3% of canals studied. The authors recommend that Gates-Glidden drills no larger than a size #3 be used. After endodontic treatment, dentine thickness on the furcation side was less than 1 mm in 82% of the distal roots studied (Fig. 4). There are primary causes that predispose teeth to fracturing and secondary causes that predispose teeth to fracturing after a period of time (Fig. 5). Endodontics is a component of an interdisciplinary process and a chain is only as strong as its weakest link. Subsequent to any endodontic procedure, intensity of stress concentration and tensile stresses within an endodontically treated tooth will depend upon:

- 1) the material properties of the crown, post, and core material chosen;
- 2) the shape of the post;
- 3) the adhesive strength at the crown-tooth, core-tooth, core-post, and post-tooth interfaces;
- 4) the magnitude and direction of occlusal loads;
- 5) the amount of available tooth structure; and
- 6) the anatomy of the tooth.

Fig. 5 Primary causes of fracture include excessive structure loss, loss of free unbound water from the root-canal lumen and dentinal tubules, age-induced changes in the dentine and restorations and restorative procedures. Secondary causes of fracture include the effects of endodontic irrigants and medicaments on dentine, the effects of bacterial interaction with dentine substrate and bio-corrosion of metallic post-cores.

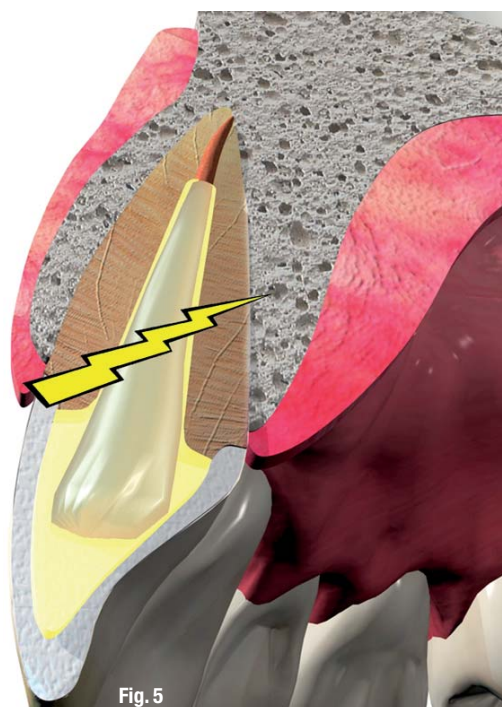
Any combination of vectored stress concentration and high tensile stresses will predispose these teeth to fracturing without an adequately engineered restorative design.

Re-engineering

Re-engineering negative treatment outcomes is a significant part of the contemporary endodontic

oeuvre. The presence of apical periodontitis may affect the outcome of initial endodontic treatment;²⁶ however, there is general consensus that apical periodontitis is the most important variable that influences a positive outcome with non-surgical and surgical retreatment.²⁷⁻²⁹ Positive treatment outcomes may be more likely in certain teeth with a combination of both procedures, rather than with one or the other alone (Fig. 6).

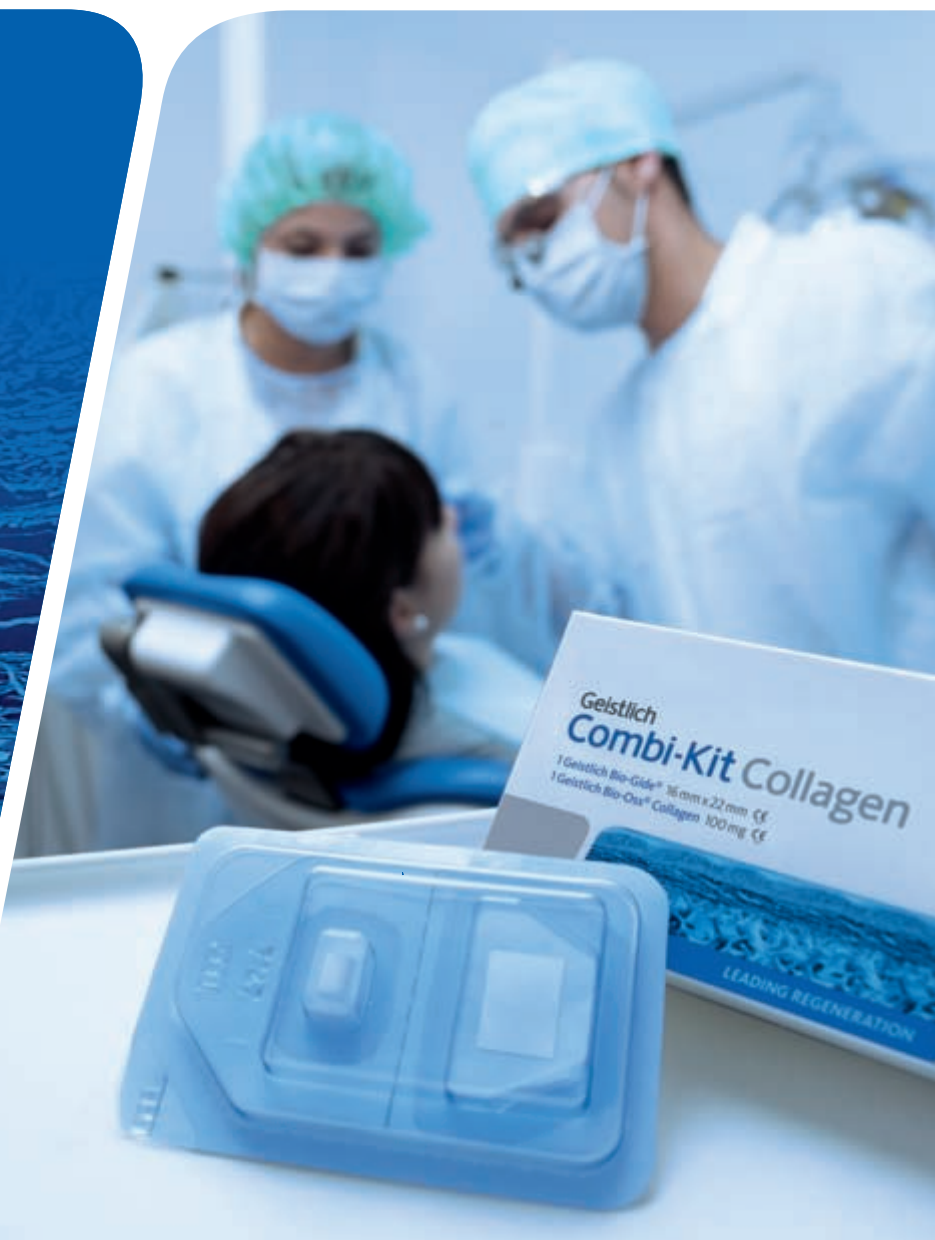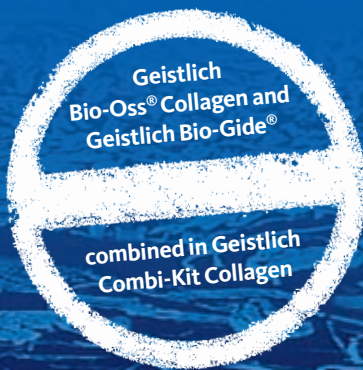The premise that non-surgical retreatment improves the outcome of peri-apical surgery has been supported by both historical and current studies.³⁰⁻³² Apical surgical 'correction' of intra-canal infections may isolate, but not eliminate, the residual microflora of the root-canal space. It should therefore be limited to situations in which non-surgical retreatment is judged impractical. With the range of sophisticated equipment and material in the conventional endodontic armamentarium, this is a remote consideration at best. When the aetiology is



Geistlich Combi-Kit Collagen

The kit for success.

Geistlich Combi-Kit Collagen –
the combination for Ridge Preservation
and minor augmentations.



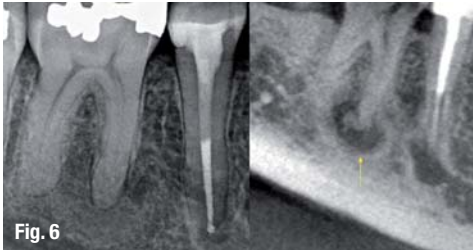


Fig. 6

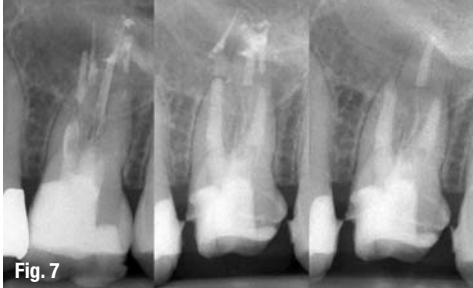

Fig. 7

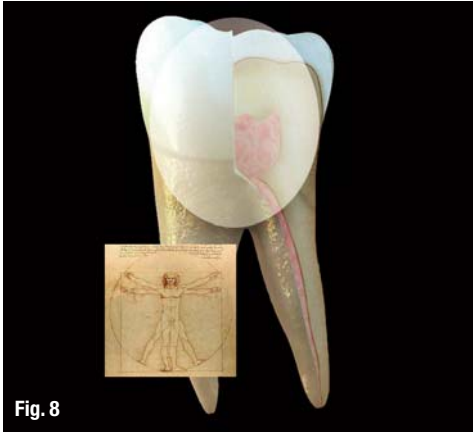


Fig. 8

Fig. 6 Flat field peri-apical radiograph (left); small focal field CBCT (right; Kodak 90003D, Kodak Dental Systems). The differential in visualisation of peri-apical pathology from a 3-D to a 2-D image is as much as 2:1.⁶²

Fig. 7 The initial endodontic treatment procedure was inadequate and failing. Re-engineering (inclusive of interim calcium hydroxide therapy) ensured optimal eradication of microflora from the root-canal space, and the obturation produced definitive closure of the apical termini. Surgery was performed to redress persistent symptoms.

Fig. 8 The strength of the egg-like coronal structure of a tooth can support substantial occlusal stress and force; however, disrupting the integrity of the 'dome' or roof of the pulp chamber with an access preparation will invariably lead to a statistically significant degree of fracturing after endodontic therapy.¹⁶

independent of the root-canal system, surgery is the most beneficial treatment.³³ Non-surgical retreatment may still be indicated in these cases, especially when intra-canal infection cannot be ruled out. Time constraints or financial pressures should never be a factor in making surgery the first treatment choice (Fig. 7).

There are a myriad of variables associated with non-surgical retreatment, and treatment outcome studies in endodontics have been egregiously abused by those wishing to diminish the value of re-engineering natural teeth. Many studies have categorised teeth with caries, fractures, periodontal involvement and poor coronal restorations as negative endodontic outcomes.^{34,35}

Prior procedural errors,³⁶ occlusal considerations,³⁷ material choice for the restoration³⁸ and design of the full coverage component all suggest that success is a function of comprehensive

treatment planning as much as technical expertise. Evidence-based or controlled best evidence studies should conclude that these are non-endodontic causes of failure and that the success of endodontic treatment itself is high and predictable.

Kvist and Reit³⁹ have shown that while surgical cases demonstrated higher healing rates than non-surgical retreatment cases initially, four years after treatment there was no difference between the two modalities, owing to 'late' surgical failure. The failure rate for surgical therapy appears to be analogous to the failure rate for retreatment as a function of the size of the lesion treated.⁴⁰ Levels of apical resection⁴¹ and the type of root-end filling material make a difference to surgical treatment outcome success;⁴² however, the dentine-bonded composite technique and the use of compomer materials has not been widely reported on. As these techniques dome the resected root face, sealing off the cut tubules, they may prove to be the most effective retrograde surgical protocols of all. The literature is unclear concerning peri-apical **re-surgery**.

Gagliani *et al.*⁴³ compared peri-apical surgery and re-surgery over a five-year follow-up period.

Using magnification and microsurgical root-end preparations, the positive outcome for primary surgery was 86% and 59% for re-surgery. While others have shown positive outcomes for re-surgery, the decision remains highly case specific. In spite of our best efforts, negative endodontic treatment outcomes occur and ortho-biological replacement of teeth and their surrounding anchoring structures is an integral part of contemporary foundational treatment planning.

A recent article by Assuncao *et al.*⁴⁴ describes engineering methods used in dentistry to evaluate the biomechanical behaviour of osseointegrated implants. Photoelasticity is used for determining stress-concentration factors in irregular geometries. The application of strain-gauge methodology to dental implants provides both *in vitro* and *in vivo* measurement strains under static and dynamic loads. Finite element analysis can simulate stress using a **computer-generated model** to calculate stress, strain, and displacement. An analysis of the impact of mechanical/technical risk factors on implant-supported reconstructions is beyond the scope of this publication; however, the replacement of lost teeth by implants should, without exemption, provide a feeling of *restitutio ad integrum*. The means by which the restoration of the original condition at the crown-root interface is idealised is detailed in this article.

The structure and composition of teeth is perfectly adapted to the functional demands of the mouth, and are superior in comparison to any artificial material. So first of all, do no harm.

—Anonymous

Back to the egg

An increased uniform amount of coronal dentine significantly amplifies the fracture resistance of endodontically treated teeth regardless of the post system used or the choice of material for the full coverage restoration.⁴⁵ A recent article by Coppede *et al.* demonstrated that friction-locking mechanics and the solid design of internal conical abutments provided greater resistance to deformation and fracture under oblique compressive loading when compared to internal hex abutments.⁴⁶ These two 'seemingly' disparate observations define the inherent continuum between natural tooth engineering and the principles of engineering necessary to ortho-biologically replicating the native state.

The use of a ferrule or collet and a bonded or intimately fitted post-core to restore function and form to an endodontically treated tooth is analo-

5th^{AD}

Swiss Bio- material Days

June 24–25, 2011, Lucerne

Prevention versus augmentation

Scientific chair: Prof. Dr. W. Lückerath

Registration: www.ds dental.ch

gous to the use of a long, tapered friction-fit interface with a retaining screw (Morse taper) to secure an abutment to a fixture. In both cases, the role of contact pressure between mating surfaces in generating frictional resistance provides a locked connection. This has been shown to effect long-term stability of crestal bone support for the overlying gingival tissues and maintain a healthy protective and aesthetic periodontal attachment apparatus.⁴⁷

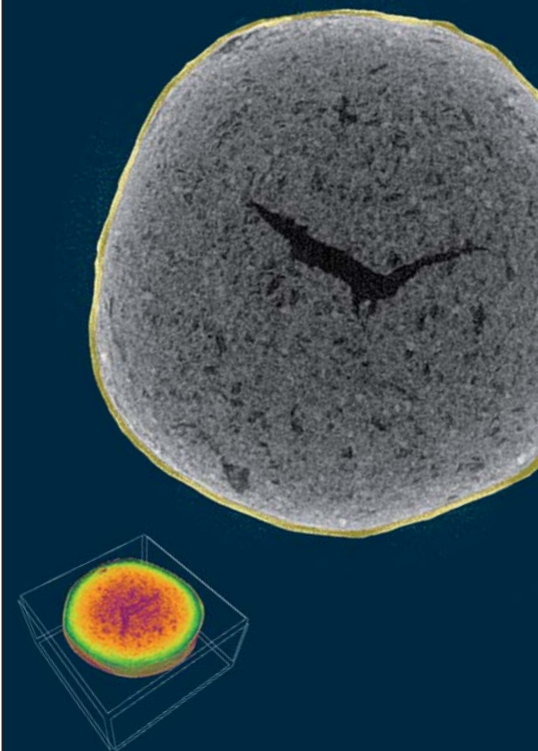
The Roman architect Vitruvius' (Marcus Vitruvius Pollio) description of the perfect human form in geometrical terms was a source of inspiration for Leonardo da Vinci, who successfully illustrated the proportions outlined in Vitruvius' work *De Architectura*. The result, the Vitruvian man, is one of the most recognised drawings in the world and is accepted as the standard of human physical beauty. Vitruvius theorised that the essential symmetry of the human body with arms and legs extended should fit into the perfect geometric forms: the circle and the square. Da Vinci recognised that the circle and the square are only tangent at one place, the base. Observe the insert in Figure 8. The stabilising platform for the human form outlined begins at that tangent; the intersection is graphically analogous to the structural configuration of platform switching.

The relative simplicity of this construct reinforces the obvious. When we compare design in living things to the artificial designs they inspire, a striking parallel emerges. Almost all the products of man's technology are no more than imitations of those in nature and usually, they fail to match the superior design in living things. Consider the engineering perfection that is the egg. Its strength lies in its oblate spheroid shape. A blow to the side of an egg from a sharp object places pressure along the thin shell and breaks it easily. However; if the egg is squeezed directly on its poles, the vectored pressure is compressed along the surface structure, not across the shell; the egg cannot be broken without extraordinary force. However, if a pinhole is created in one of the poles disrupting the integrity of the structure, the pressure will readily break the egg, commensurate with a sharp blow to the side.

In geometry, an oval is a curve that resembles an egg or an ellipse. Architects and engineers have used smooth ovate curves to support the weight of structures over an open space literally since the second millennium BC. These arches, vaults and domes can be seen in buildings and bridges all over the world; the most pervasive example is the keystone arch used by the Romans for aqueducts and mills.

An arch directs pressure along its form so that it compresses the building material from which it is constructed. Even a concrete block is readily broken if one hits it on the side with a sledge. But under compression forces from above, the block is incredibly strong and unyielding. Many will remember the weight-bearing tripod experiments from grade school in which an egg acts as one of three supporting legs of a square section of wood that bears books as the load. The structure could support over sixty books, almost twenty pounds (9 kilograms), before breaking the supporting egg. One need only look at the root trunk and coronal tooth structure of a multi-rooted teeth and it becomes apparent that strength of the tooth form is dependent upon an arch form for its integrity (Figs. 8 & 9).

Is it possible for this natural feat of engineering to be biomimetically replicated to the design parameters of osseointegrated implants? There are a number of paradigms that continue to fuel debate in the dental clinical and scientific communities that pertain to the optimal engineering predicates for implant design. These include smooth versus rough surfaces, submerged versus non-submerged installation techniques, mixed tooth-implant versus solely implant-supported reconstructions, Morse taper abutment fixation versus a butt-joint interface, and titanium abutments versus aesthetic abutments in clinical situations in which aesthetics are of primary concern.



Speakers:

Prof. Dr. Wilfried Engelke, Göttingen
Prof. Dr. Walter Lückerath, Bonn
Prof. Dr. Else Marie Pinholt, Copenhagen
Prof. Dr. Dr. Rudolf Reich, Bonn
Dr. Georg Bach, Freiburg im Breisgau
Dr. Peter Fairbairn BDS, London
Dr. Dr. Karl-Heinz Heuckmann, Chieming
Dr. Stefan Neumeyer, Eschlkam
Dr. Detlef Klotz, Duisburg
Dr. Kurt Ruffieux, Zürich
Dr. Jens Schug, Zürich
PD. Dr. Patrick Schmidlin, Zürich
Dr. Dr. Angelo Trödhan, Wien
Dr. Mario Kirste, Frankfurt
Dr. Gerhard Werling, Bellheim

Fig. 9 An arch eliminates tensile stresses in spanning an open space, as all forces are resolved into compressive stresses. It requires all of its elements to hold it together, thus making it self-supporting. The incorporation of platform switching into the design of an implant abutment simulates three oblate spheroid shapes—one vertical, two horizontal. The objective is to ensure that axially vectored compressive stresses are contained within an idealised shape that is structurally enhanced by the use of a precise friction-fit connection.

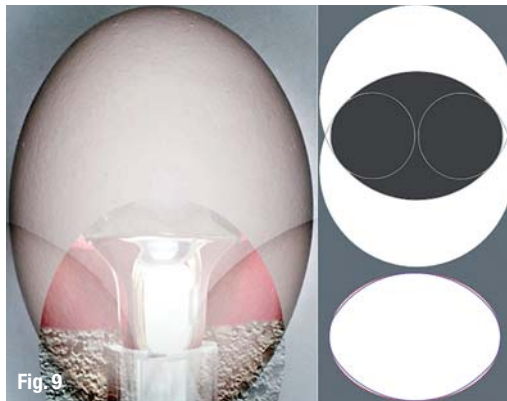


Fig. 10a Foundational dentistry mandates that the impact of an ortho-biological replacement unit be commensurate with the biological objectives and functional requirements of the natural tooth.

Fig. 10b As the number of implant-supported single-tooth replacements increases, implant-abutment connection design should ensure that occlusal table replication displays equivalency in both dimension and cuspal inclination with the surrounding natural dentition.

The cone-screw abutment has been shown to diminish micro-movement by reducing the burden of component loosening and fracture. This enables the identification of the effects of the parameters such as friction, geometric properties of the screw, the taper angle and the elastic properties of the materials on the mechanics of the system. In particular, a relation between the tightening torque and the screw pre-tension is identified. It was shown that the loosening torque is smaller than the tightening torque for typical values of the parameters. Most of the tightening load is carried by the tapered section of the abutment, and in certain combinations of the parameters the pre-tension in the screw may be reduced to zero. This tapered abutment connection provides high resist-

ance to bending and rotational torque during clinical function, which significantly reduces the possibilities of screw fracture or loosening.

_Biomechanics

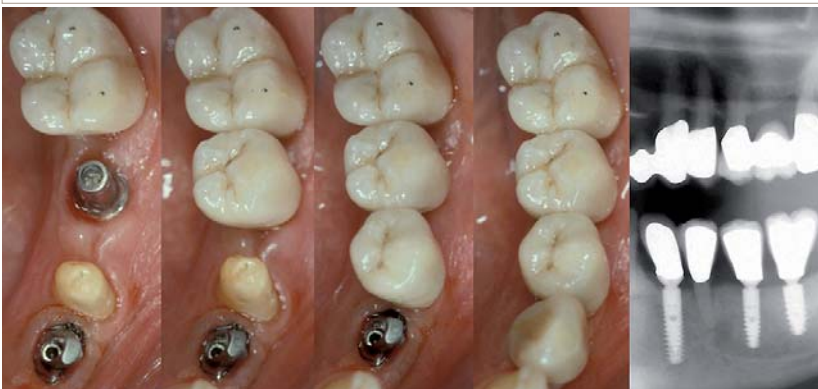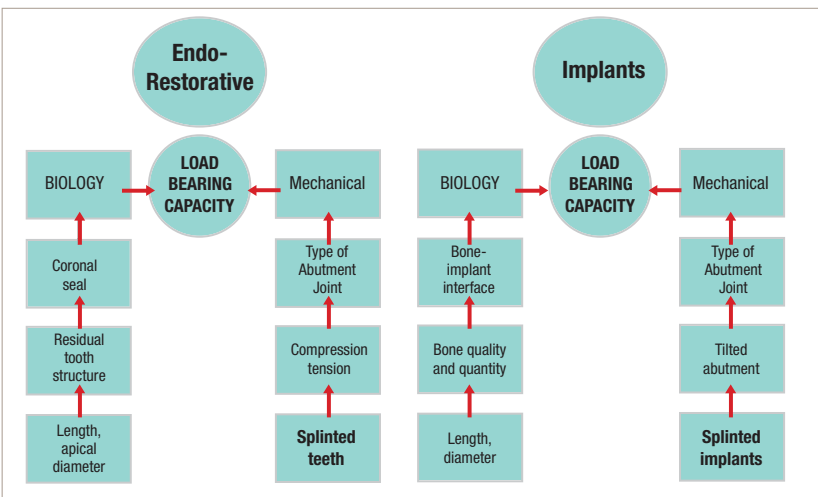
The seed of a tree has the nature of a branch or twig or bud. It is a part of the tree, but if separated and set in the earth to be better nourished, the embryo or young tree contained in it takes root and grows into a new tree.

—Isaac Newton

Pressure on the cervical cortical plate, micro-movement of the fixture–abutment interface (FAI), and microflora leakage and colonisation at and within the FAI are some of the pathological vectors associated with osseous remodelling, both crestal and peripheral to dental implants.⁴⁸ Occlusal considerations engineered into fixture design should enable optimum load distribution for permanent load stability during functional loading, reduce functional stress transfer to the interfacial tissues, and enhance the biological reaction of interfacial tissues to occlusally generated stress transfer conditions.⁴⁹ Future modifications to implant biomechanics should focus on designs wherein the osseous trabecular framework that retains the fixture will adapt to the amount and direction of applied mechanical forces, cope with off-axis loading, compensate for differences in occlusal plane to implant height ratios, as well as adjust to mandibular flexion and torsion.⁵⁰ In this new era of implant-driven treatment planning, fixtures should be engineered to support single crowns with cantilevers instead of implant–implant or implant–teeth connections for a span of any degree. These engineering design iterations will minimise high-stress torque load at the implant–abutment interface and obviate areas with degrees of bone insufficiency. The goal should be to biomimetically replicate the natural state to the greatest degree with regard to load bearing capacity (Figs. 10a & b).

Stable crestal bone levels are the yardstick by which treatment success and health are measured in the orofacial ecosystem, whether success and health relate to natural tooth retention or restorative and/or replacement rehabilitation. It is therefore surprising that the treatment outcome standards for osseointegration accept crestal bone remodelling and resorption of up to 1.5 to 2 mm in the first year following fixture placement and prosthetic insertion.⁵¹

The concept of *biological width* outlines the *minimum* soft-tissue dimension that is physiologically necessary to protect and separate the osseous crest from a healthy gingival margin surrounding teeth



IDENTICAL
IMPLANT SHAPE



TUBE-IN-TUBE™
CONNECTION



CONICAL
CONNECTION

CAMLOG IS NOW
TWICE AS GOOD

New, conical, and of CAMLOG quality: The CONELOG® Implant System. First-class Tube-in-Tube™ or conical implant-abutment connection – now all from one source.

For more information: www.camlog.com

a perfect fit™

camlog

Fig. 11a The composition of biological width around implants: sulcus depth (SD), distance from peri-implant mucosal margin (PM) to the most coronal point of junctional epithelium (cJE); junctional epithelium (JE), distance from cJE to most apical point of the junctional epithelium (aJE); connective tissue zone (CT), distance from aJE to the first bone to implant contact (BC).⁶³

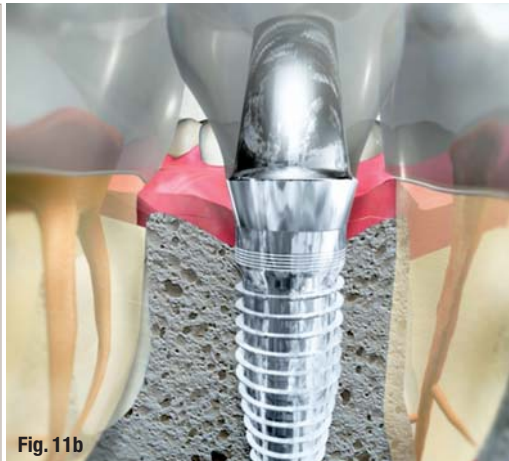
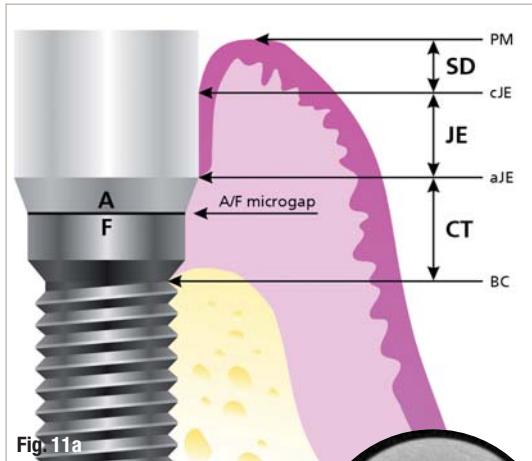
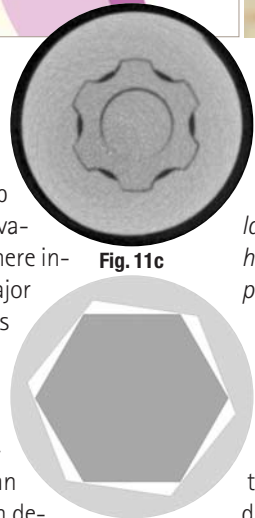


Fig. 11b When a matching implant-abutment diameter is used, the inflammatory cell infiltrate is located at the outer edge of the implant-abutment junction close to crestal bone; this close proximity may explain in part, the biological and radiographical observations of crestal bone loss or saucerisation around restored implants. This is not peri-implantitis or mucositis; however, any area of bacterial accumulation and stasis, inaccessible to normal hygiene protocols, is a risk factor for exacerbation.

and the peri-implant environment. A bacteria-proof seal, the lack of micro-movement associated with a friction grip interface and a minimally invasive second-stage surgery (where indicated) without any major trauma to the periosteal tissues are also important factors in preventing crestal bone loss. The literature suggests that the stability of the implant-abutment interface may have an important initial role to play in determining crestal bone levels.⁵² Tarnow's seminal study on crestal bone height support for the interdental papillae clearly demonstrated the influence of the bony crest on the presence or absence of papillae between implants and adjacent teeth.⁵³ Twenty years later, logic dictates that anticipated early crestal bone loss and diminished, albeit continual, loss in successive years of function ought to have been engineered out of the substitution algorithm for peri-implant tissues.⁵⁴



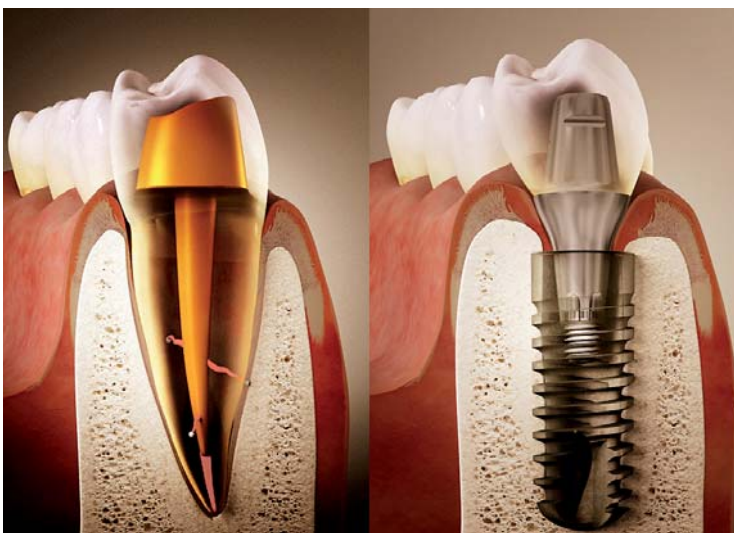**Platform switching:
By default or by design**

There is no logical way to the discovery of elemental laws. There is only the way of intuition, which is helped by a feeling for the order lying behind the appearance.

—Albert Einstein

Platform switching theorises that by using an abutment diameter of a lesser dimension than the periphery of the implant fixture, horizontal relocation of the implant-abutment connection will reduce remodelling and resorption of crestal bone after insertion and loading. The concept implies that peri-implant hard tissue stability will engender soft tissue and papilla preservation. Maeda *et al.* reported that stress levels in the cervical bone area peripheral to a fixture were greatly reduced when a narrow diameter abutment was connected, in comparison to a size commensurate with the fixture diameter.⁵⁵ The authors concluded that the biomechanical advantage of shifting stress concentrations away from the cervical area will diminish their impact on the biological dimension of hard and soft tissue extending apically from the FAI (Figs. 11a–c). The inherent disadvantage is that this shifts stress to the abutment screw with the potential for loosening or fracture.

Ericsson *et al.*⁵⁶ detected neutrophilic infiltrate in the connective tissue zone at the implant-abutment interface. The facility by which platform switching/shifting reduces bone loss around implants has been investigated by Lazzara *et al.*⁵⁷ The authors hypothesised that if the abutment diameter matches that of the implant, the inflammatory cell infiltrate will be formed in the connective tissue at the micro-gap created at the FAI. If an abutment of narrower diameter is connected to a wider neck implant, the FAI is shifted away from the outer edge of the implant, thus distancing inflammatory cell infiltrate away from bone. Hypothetically, less crestal bone loss is



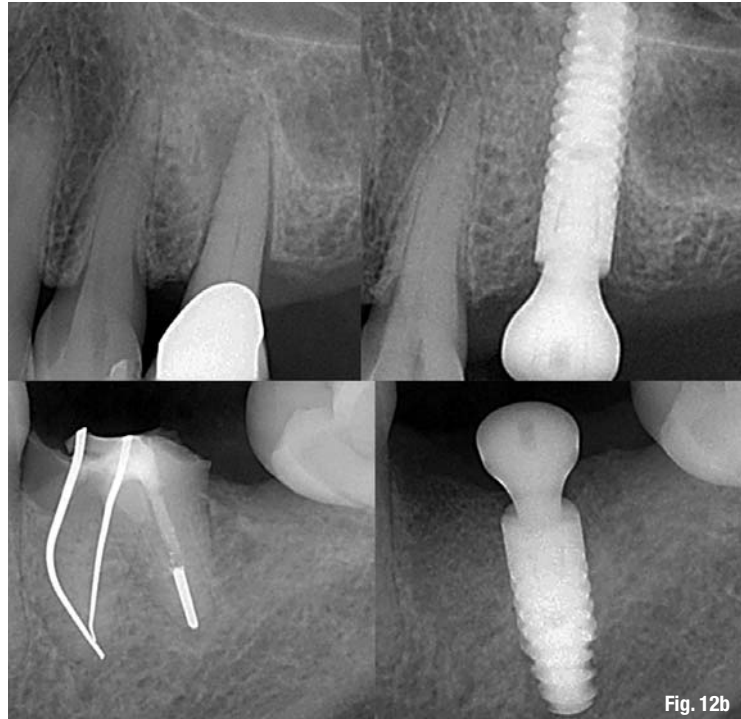
expected and an increased implant-abutment disparity allows more stable peri-implant soft-tissue integration.

Baggi *et al.* conducted a finite element analysis experiment to define stress distribution and magnitude in the crestal area around three commercially available implants: ITI Straumann (Straumann), Nobel Biocare (Nobel Biocare) and Ankylos C/X (DENTSPLY Friadent).⁵⁸ Numerical models of maxillary and mandibular molar bone segments were generated from computed tomography images and local stress vectors were introduced to allow for the assessment of bone overload risk. Different crestal bone geometries were also modelled. Type II bone quality was approximated and complete osseointegration was assumed. It was concluded that the Ankylos C/X implant based on its platform switched and sub-crestally positioned design demonstrated better stress-based performance and lower risk of bone overload than the other implant systems evaluated.

Platform switching with a stable implant-abutment connection is increasingly accepted essential implant design features required to reduce or eliminate early crestal bone loss. A bacteria-proof seal, a lack of micro-movement due to a long friction grip tapered channel, and minimally invasive second-stage surgery without any major trauma for the periosteal tissues are also important factors in preventing cervical bone loss. A preconfigured platform-switched design has a significant impact on the implant treatment in aesthetic areas, as not only is the tissue biotype preserved, but it has also been shown to be enhanced by osseous generation over the collar of the fixture (Figs. 12a & b).^{59,60}

The endo-implant algorithm parallels the question: Which came first, the chicken or the egg as an example of circular cause and consequence. It could be reformulated as follows: Which came first, X that cannot arise without Y, or Y that cannot arise without X? An equivalent situation arises in engineering and science known as *circular reference*, in which the parameter is required to calculate that parameter itself. This is the essence of foundational dentistry. If nature creates the ideal, are we as clinicians not responsible for replicating the ideal, should adverse conditions irrevocably alter nature and necessitate its elimination?

Nature wisely created a structure that could harmoniously interpolate hard and soft tissue, act as the portal of nutrition and communication for the body, and be the gatekeeper on guard and in function throughout our lifetime. Our role is to ensure that we re-engineer nature; we must adhere to its rules, its



logic and fundamentals. This is not an easy task, as filtering out the best range of evidence from a wide range of sources, presenting clear, comprehensive analyses and incorporating patient experience is a Herculean task. In many ways, this is analogous to *Alice's Adventures in Wonderland*, as so much of what we do grows curiously and curiously as each new innovation demands that we go through the looking glass and determine what Alice found there.

"There's no use trying," said Alice. "One can't believe impossible things." "I daresay you haven't had much practice," said the Queen. "When I was your age, I always did it for half an hour a day. Why, sometimes I've believed as many as six impossible things before breakfast."

—Lewis Carroll

Editorial note: A complete list of references is available from the publisher.

Fig. 11c_The Morse taper connection of the Ankylos C/X (internal index) fixture distributes oblique and horizontally applied forces over a large area of the matrix joining surface inside the implant. The connection is therefore only loaded in the vertical direction. The cross-section shows no gap between the abutment taper and the implant which avoids micro-loosening. This is in contrast to systems with internal hex connections (clearance fit) that demonstrate micro-motion and 'rotational slop', making them prone to inflammatory reactions at the implant-abutment connection due to micro-leakage.

Fig. 12a_The platform-switched design negates micro-motion and resultant crestal bone resorption. The goal of ortho-biological replacement is the idealised replication of the natural state.

Fig. 12b_The expectation of a precise cone fixture-abutment connection is that the crestal bone will overgrow the fixture platform and remain in that position regardless of whether the implant was placed in a grafted site or immediately placed in an extraction site. Die-back or saucerisation is not a consideration.

_contact

implants

Dr Kenneth Serota

4310 Sherwoodtowne Blvd.
Suite 300
Mississauga, Ontario
L4Z 4C4
Canada

kendo@endosolns.com
www.endosolns.com | www.rxroots.com |
www.ankylosworld.com

The surgically accelerated orthodontics in multidisciplinary implant treatment

Authors Federico Brugnamì & Alfonso Caiazzo, Italy

Abstract

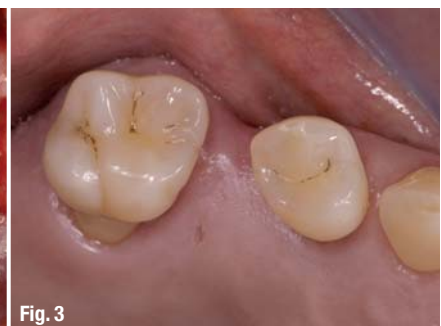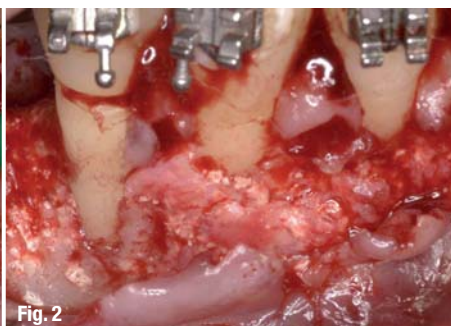
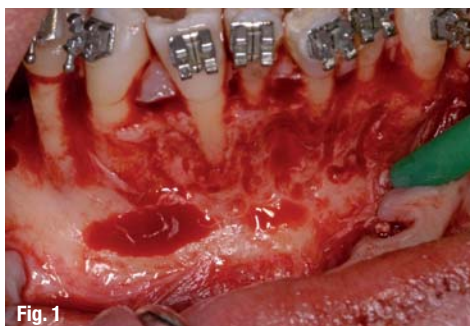
Multidisciplinary treatment requires excellent communication and coordination amongst clinicians in a variety of fields. Although this can be difficult to achieve at first, interdisciplinary collaboration may result in efficient treatment that patients appreciate and benefit from. When appropriately coordinated, the job of each specialist can facilitate the work of the other team members. For example, orthodontists can be of considerable assistance in periodontal and prosthetic treatment. Dental alignment of the arches can facilitate periodontist's and prosthodontist's objectives. This is done, for example, by aligning the natural dentition, making possible a path of insertion for a prosthesis, or establishing a physiological alveolar crestal topography to facilitate periodontal surgery. Orthodontic tooth movement can then be of substantial benefit for the patient. Many adults seeking routine restorative dentistry have misaligned teeth, which compromises either the final restorative outcome or the ability to clean the natural dentition. Orthodontic appliances have become smaller, less noticeable and easier to maintain during therapy. Invisible or lingual appliances further improve the rate of acceptance by adult patients. Many adults can now have their teeth aligned to improve their

chewing function and their smiles with reduced aesthetic effect during therapy. In addition, implants have become a major part of the treatment plan for adults with missing teeth. If adjacent teeth have drifted into the edentulous area, orthodontics may be beneficial for providing adequate space for implant placement and restoration. One of the major problems in acceptance of orthodontic treatment by adults is the length of treatment. For this reason, periodontists and oral surgeons may be helpful to the orthodontist, as they can facilitate the orthodontist's work and thereby reduce treatment time. Endosseous implants can be used to enhance anchorage and increase movement control of orthodontically moved teeth. Furthermore, the alveolar architecture can be reshaped with periodontally accelerated osteogenic orthodontic augmentation (PAOO) surgery to produce the regional acceleratory phenomenon (RAP),^{1,2} which results in a vast increase in osteoblast and osteoclast activity. The biological result of this is osteopenia (decrease of bone mineralisation without loss of volume). The clinical result is softer bone, which may allow faster movement of teeth.^{3,4} In multidisciplinary treatment of adult patients, malocclusion may be associated with tooth loss, bone resorption and a consequent need for implants and/or periodontal treatment and bone augmentation. In these cases

Fig. 1 A very resorbed ridge in the edentulous area was evident together with bone dehiscence on teeth 31, 42, 44. A regeneration with xenogeneic bone of bovine origine (Endobone, Biomet 3i, USA) and a resorbable membrane (Osseoguard, Biomet 3i, USA) was performed.

Fig. 2 Six months after surgery one osteointegrated implant (Biomet 3i, USA) in the augmented area was placed. A regeneration of the bony fenestration on tooth 42 was also evident, while the control 44 remained unchanged.

Fig. 3 Appropriate implant placement requires orthodontic movement.



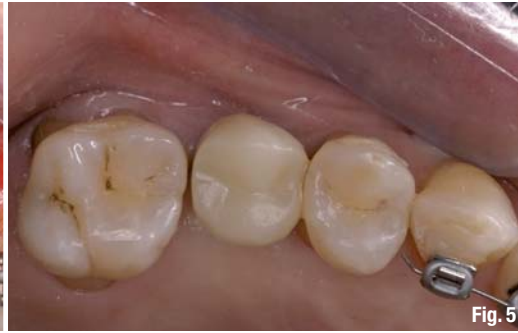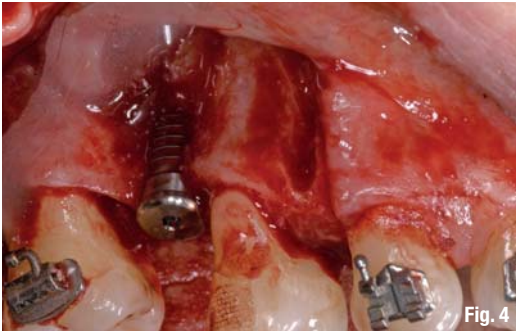


Fig. 4 At the time of implant placement a corticotomy was performed to accelerate the orthodontic movement and facilitate the implant restoration. Regeneration with a first layer of autologous graft collected during site preparation, covered with xenograft and a resorbable membrane (Endobone and Osseoguard, Biomet 3i, Palm Beach Gardens, USA) was performed simultaneously to the placement.

Fig. 5 Provisional restoration in place.

especially, efficient interdisciplinary collaboration may result in a great benefit for the patients.⁵⁻¹²

Periodontally accelerated orthodontic movement, as described by Wilcko, appears particularly feasible in those multidisciplinary cases for which treatment planning requires orthodontic movement and oral or periodontal surgery. In these cases, corticotomy can be combined with wisdom tooth extraction and/or a regenerative technique, such as guided bone regeneration (GBR), in order to avoid multiple surgeries. Recently some orthodontic therapies, especially the so-called low-friction therapies, have demonstrated clinically and radiographically that it is possible to expand dental arches without interfering with periodontal health, by augmenting the alveolar bones. Melsen *et al.*¹³ confirmed what was previously suggested, that the tooth will move with the bone and not in bone, especially when light orthodontic forces are applied. Dehiscence and fenestration, which are difficult to diagnose preoperatively, may represent a limitation of this technique. Since the tooth will move with the periodontium, in cases in which the periodontium is not present, we might create recession and attachment loss.¹⁴ A recent study on modern American skulls found that a dehiscence was present in 40.4% of the skulls, and a fenestration was present in 61.6% of skulls.¹⁵ If this data is translated in clinical treatment, it may mean that potentially at least 50% of orthodontic patients undergoing expanding movement could be at risk of gingival recession and periodontal damage. It would be advisable, then, to introduce routine 3-D X-rays into the pre-operative work-up (i.e. cone beam). The cone-beam examination, with a reduced dose of radiation compared with the fan beam (CT scan) and better definition,¹⁶ could be used routinely in those patients with a thin, scalloped periodontium, where the risk of post-operative recessions is higher. The PAOO technique has been found not only to be predictable in solving dehiscence and fenestration above the roots,¹⁷ but also to produce a noticeable change in the cephalometric analysis of points A and B.¹⁷ With the PAOO technique, the patient needs to be seen routinely for changing the wires,

as the teeth movements are much faster than in regular orthodontic treatment. The use of segmental corticotomy (applied only to the teeth that have to move more than the others) can dramatically change the relationship amongst groups of teeth.¹⁸ This has to be kept in mind, since it may require changes in distributing the anchorage by the orthodontist. The teeth in the area of surgery will be moving much faster than the other teeth.

Conclusions

When the treatment plan requires orthodontic movement and oral or periodontal surgery, corticotomy can be combined with a wisdom tooth extraction and/or a regenerative technique, such as GBR, in order to avoid multiple surgeries and to optimise the final outcome for the patient. Another indication is for instances in which the risk of creating root dehiscence in patients with thin periodontium is very high even with slow orthodontic movement and light forces applied. Root recession can be present even without clinical manifestation of gingival recession. An efficient multidisciplinary approach to a complex case may result in a faster and better treatment. The PAOO technique can be used for faster dental movement, to treat and prevent periodontal problems and to regenerate ridge defects, allowing implant placement.

Editorial note: A list of references is available from the publisher.

contact

implants

Federico Brugnami, DDS

Piazza dei prati degli Strozzi 21
00195 Roma, Italy
Tel.: +39 06 39730191
Fax: +39 06 39730195

fbrugnami@gmail.com

Alfonso Caiazzo, DDS

Private Practice, Salerno, Italy

The maintenance of **crestal bone** around dental implants

Author_Dr Mohammed A. Alshehri, Saudi Arabia

_Introduction

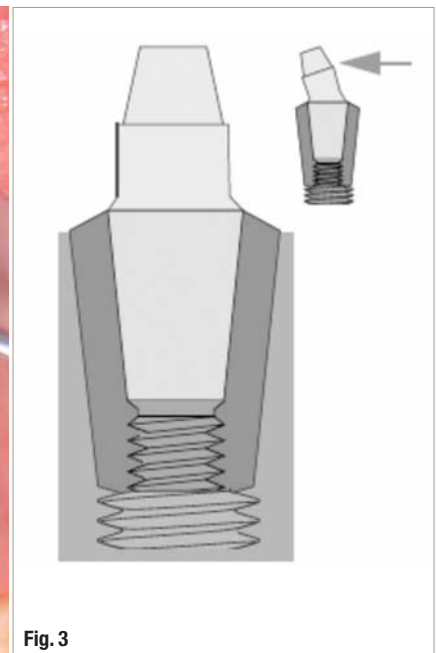
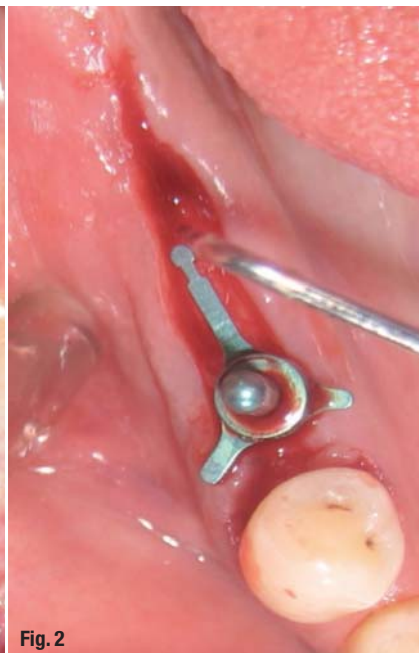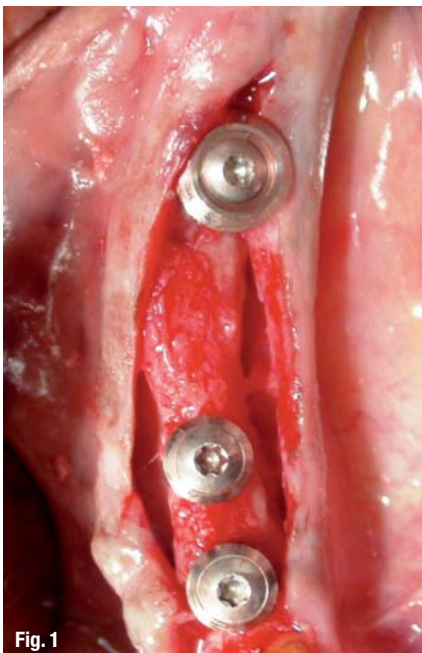
The longevity of dental implants is highly dependent on integration between implant components and oral tissues, including hard and soft tissues. Studies have shown that submerged titanium implants had 0.9 to 1.6 mm marginal bone loss from the first thread by the end of the first year in function, while only 0.05 to 0.13 mm bone loss occurred after the first year.¹⁻³

The first report in the literature to quantify early crestal bone loss was a 15-year retrospective study that evaluated implants placed in edentulous jaws.¹ In this study, Adell *et al.* reported an average of 1.2 mm marginal bone loss from the first thread

during healing and the first year after loading. In contrast with the bone loss during the first year, there was an average of only 0.1 mm bone lost annually thereafter.

Based on the findings on submerged implants, Albrektsson *et al.* and Smith and Zarb proposed criteria for implant success, including a vertical bone loss of less than 0.2 mm annually following the implant's first year of function.^{4,5}

Non-submerged implants have also demonstrated early crestal bone loss, with greater bone loss in the maxilla than in the mandible, ranging from 0.6 to 1.1 mm, at the first year of function.⁶⁻⁸



_Surgical trauma

Heat generated at the time of drilling, elevation of the periosteal flap and excessive pressure at the crestal region during implant placement may contribute to implant bone loss during the healing period.

Heat generation and excessive pressure

Eriksson and Albrektsson reported that the critical temperature for implant site preparation was 47°C for one minute or 40°C for seven minutes.⁹ Matthews and Hirsch demonstrated that temperature elevation was influenced more by the force applied than drill speed.¹⁰ When both drill speed and applied force were increased, no significant increase in temperature was observed owing to efficient cutting.^{10, 11}

Sharawy *et al.* compared the heat generated by the drills of four different implant systems run at speeds of 1,225, 1,667 and 2,500 rpm.¹² All of the drill systems were able to prepare an 8 mm site without the temperature rising by more than 4°C (to 41°C). For all drill systems, the 1,225 rpm drill speed required a 30 to 40% longer drilling time when compared with 2,500 rpm and a 20 to 40% reduction in the time required for bone temperature to normalise. With greater depth of preparation and insufficient time between drill changes, a

detrimental temperature rise to 47°C or greater may be reached. The authors recommend that surgeons interrupt the drilling cycle every five to ten seconds to allow irrigant time to cool the osteotomy.

Periosteal flap

The periosteal elevation has been suggested as one of the possible contributing factors to crestal implant bone loss. Wilderman *et al.* reported that the mean horizontal bone loss after osseous surgery with periosteal elevation is approximately 0.8 mm, and the reparative potential is highly dependent upon the amount of cancellous bone (not cortical bone) underneath the cortical bone.¹³ The bone loss at stage II implant surgery in successfully osseointegrated implants is generally vertical and noted only around the implant characterised by saucerisation, not the surrounding bone even though during surgery all the bone was exposed. Therefore, this hypothesis is not generally supported.

_Occlusal overload

Research has indicated that occlusal overload often resulted in marginal bone loss or de-osseointegration of successfully osseointegrated implants.^{1, 3, 14-20} The crestal bone around dental im-

Table I Comparison between tooth and implant.

| | Tooth | Implant |
|---|--|--|
| Connection | Periodontal ligament (PDL) | Osseointegration (Brånemark <i>et al.</i> , 1977), functional ankylosis (Schroeder <i>et al.</i> , 1976) |
| Proprioception | Peridontal mechanoreceptors | Osseoperception |
| Tactile sensitivity (Mericske-Stern <i>et al.</i> , 1995) | High | Low |
| Axial mobility (Sekine <i>et al.</i> , 1986; Schulte, 1995) | 25–100 µm | 3–5 µm |
| Movement phases (Sekine <i>et al.</i> , 1986) | Two phases Primary: non-linear and complex Secondary: linear and elastic | One phase Linear and elastic |
| Movement patterns (Schulte, 1995) | Primary: immediate movement Secondary: gradual movement | Gradual movement |
| Fulcrum to lateral force | Apical third of root (Parfitt, 1960) | Crestal bone (Sekine <i>et al.</i> , 1986) |
| Load-bearing characteristics | Shock absorbing function Stress distribution | Stress concentration at crestal bone (Sekine <i>et al.</i> , 1986) |
| Signs of overloading | PDL thickening, mobility, wear facets, fremitus, pain | Screw loosening or fracture, abutment or prosthesis fracture, bone loss, implant fracture (Zarb & Schmitt, 1990) |

Table I

plants could be a fulcrum for lever action when a bending moment is applied, suggesting that implants could be more susceptible to crestal bone loss by mechanical force.

Factors associated with increased bending overload in dental implants:

- _ Prostheses supported by one or two implants in the posterior region (Rangert *et al.* 1995);
- _ Straight alignment of implants;
- _ Significant deviation of the implant axis from the line of action;
- _ High crown/implant ratio;
- _ Excessive cantilever length (>15 mm in the mandible, Shackleton *et al.* 1994; >10–12 mm in the maxilla, Rangert *et al.* 1989; Taylor 1991);
- _ Discrepancy in dimensions between the occlusal table and implant head;
- _ Para-functional habits, heavy bite force and excessive premature contacts (>180 µm in monkey studies, Miyata *et al.* 2000; >100 µm in human studies, Falk *et al.* 1990);
- _ Steep cusp inclination;
- _ Poor bone density/quality; and
- _ Inadequate number of implants.

The cortical bone is known to be least resistant to shear force, which is significantly increased by bending overload. The greatest bone loss was seen on the tension side.²⁹ According to Von Recum, when two materials of different moduli of elasticity are placed together with no intervening material and one is loaded, a stress contour increase is observed where the two materials first come into contact.³⁰ Photoelastic and 3-D finite element analysis studies demonstrated V- or U-shaped stress patterns with greater magnitude near the point of the first contact between implant and the photoelastic block, which is similar to the early crestal bone loss phenomenon.³¹

Misch claimed that the stresses at the crestal bone may cause microfracture or overload, resulting in early crestal bone loss during the first year of function, and the change in bone strength from loading and mineralisation after one year alters the stress-strain relationship and reduces the risk of microfracture during the following years.³² Wiskott and Belser described a lack of osseointegration attributed to increased pressure on the osseous bed during implant placement, establishment of a physiological biological width, stress shielding and lack of adequate biomechanical integration between the load-bearing implant surface and the surrounding bone.³³ They focused on the significance of the relationship between stress and bone homeostasis.

Based on a study by Frost,³⁴ five types of strain levels interrelated with different load levels in the bone were described:

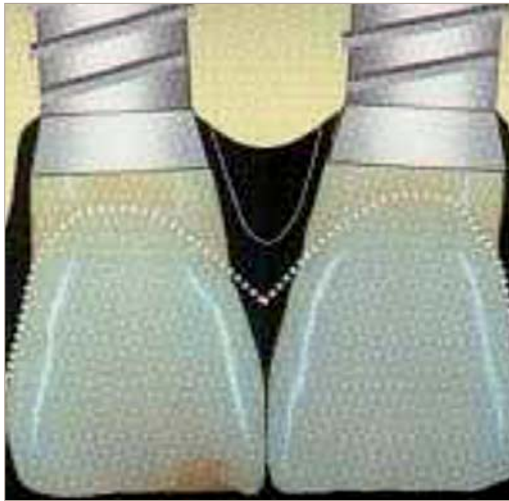- 1) Disuse, bone resorption;
- 2) Physiological load, bone homeostasis;
- 3) Mild overload, bone mass increase;
- 4) Pathological overload, irreversible bone damage; and
- 5) Fracture.

The concept of "microfracture" was proposed by Roberts *et al.*, who concluded that crestal regions around dental implants are high-stress-bearing areas.³⁵ They explained that if the crestal region is overloaded during bone remodelling, "cervical cratering" is created around dental implants. The study recommended axially directed occlusion and progressive loading to prevent microfracture during the bone-remodelling periods.

Progressive loading on dental implants during healing stages was first described by Misch in the 1980s to decrease early implant bone loss and early

Table II _ Studies regarding the biologic width around natural teeth or dental implants.

| | Dental Implants | | | | |
|-----------------------------------|---|--|-------------------------------------|---------------------------------------|---|
| | Natural teeth | | Non-submerged | Submerged | |
| | Gargiulo <i>et al.</i> ⁵⁷ 30 human skulls | Vacek <i>et al.</i> ⁵⁸ 10 human skulls | Cochran <i>et al.</i> ⁶⁸ | Berglundh <i>et al.</i> ⁵³ | Abrahamsson <i>et al.</i> ⁷¹ |
| Sulcus depth (SD) | 0.69 mm | 1.34 mm | 0.16 mm | 2.14 mm | 2.14 mm |
| Junctional epithelium (JE) | 0.97 mm | 1.14 mm | 1.88 mm | | |
| Connective tissue attachment (CT) | 1.07 mm | 0.77 mm | 1.05 mm | 1.66 mm | 1.28 mm |
| Biologic width | 2.04 mm | 1.91 mm | 3.08 mm | 3.80 mm | 3.42 mm |
| | (JE + CT) | (JE + CT) | (SD + JE + CT) | (SD + JE + CT) | (SD + JE + CT) |



implant failure. Based on the concept, progressive loading needs to be employed to allow the bone to form, remodel and mature to resist stress without detrimental bone loss by staging application of diet, occlusal contacts, prosthesis design and occlusal materials.³⁶ Appleton *et al.* reported a decrease in crestal bone loss in progressively loaded implants, compared with implants without progressive loading, within a similar healing and loading period. In addition,

digital radiographs indicated an increase in bone density in the crestal 40% of the implant in the progressive loaded crowns.³⁷ Greater crestal bone loss observed at the first year of function compared with following years can be explained by a reduced occlusal overload or increased resistance to occlusal overload after the first year of function including a functional adaptation of the oral musculature, wear of the prosthesis material, and/or an increase in bone density after a certain time period.

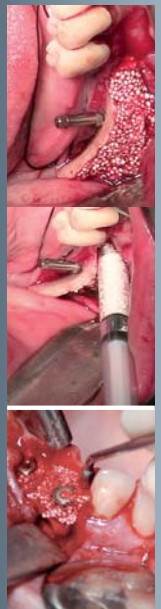Peri-implantitis

Peri-implantitis is one of the two main causative factors of implant failure in later stages. A correlation between plaque accumulation and progressive bone loss around implants has been reported in experimental studies and clinical studies. Tonetti and Schmid reported that peri-implant mucositis is a reversible inflammatory lesion confined to peri-implant mucosal tissues without bone loss. Peri-implantitis however begins with bone loss around dental implants.¹⁸

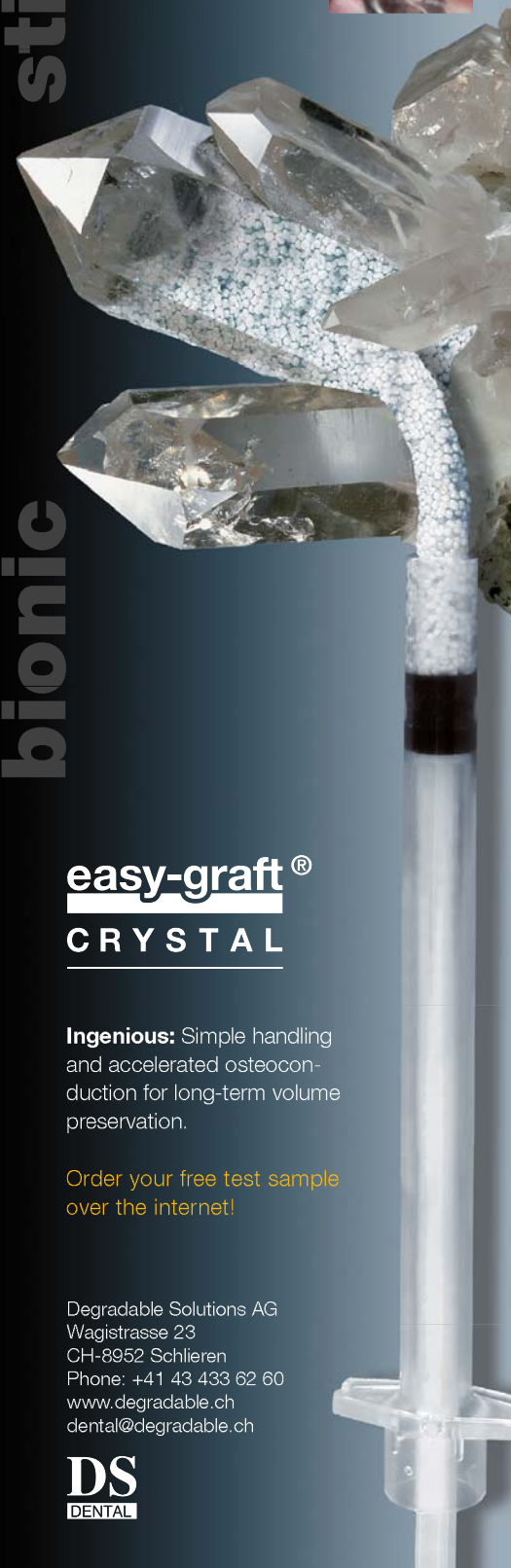Clinical features of peri-implantitis were described by Mombelli as including radiographic evidence of vertical destruction of the crestal bone, formation of a peri-implant pocket in association with radiographic bone loss, bleeding after gentle probing, possibly with suppuration, mucosal swelling, redness and no pain typically.³⁸ In an experimental study evaluating the pattern of ligature-induced breakdown of peri-implant and periodontal tissues in beagle dogs, significantly greater tissue destruction was demonstrated clinically, radiographically, and histomorphometrically at implant areas than at tooth sites. It was also found that significantly fewer vascular structures existed at implant sites compared with periodontal tissues.

The difference in collagen fibre direction (parallel to the implant surface and perpendicular to tooth surface) and amount of vascular structure may explain the faster pattern of tissue destruction in peri-implant tissues than periodontal tissues. Literature has shown that peri-implantitis is similar in nature to periodontitis in that the microbiota of peri-implantitis resemble the microbiota of periodontitis; however, there has been no evidence that peri-implantitis induces crestal bone loss during healing and in the first year of function at a faster rate than following years.

Early crestal bone loss may result in an environment favourable for anaerobic bacterial growth, thus possibly contributing to more bone destruction in following years. In the majority of implants however the bone loss is dramatically reduced after the first year of prosthesis loading. Therefore, peri-implantitis as the main causative factor for early implant bone loss may not be justified.



sticky granules
bionic



easy-graft®
CRYSTAL

Ingenious: Simple handling and accelerated osteoconduction for long-term volume preservation.

Order your free test sample over the internet!

Degradable Solutions AG
Wagistrasse 23
CH-8952 Schlieren
Phone: +41 43 433 62 60
www.degradable.ch
dental@degradable.ch

DS
DENTAL

_Micro-gap and the platform-switching concept

Many implant systems have an abutments used with conventional implant types that are flush with the implant shoulder in the contact zone. This results in the formation of microcracks between the implant and the abutment. Numerous studies have shown that bacterial contamination of the gap between the implant and the abutment adversely affects the stability of the peri-implant tissue. If above-average axial forces are exerted on the implant, a pumping effect may ensue (depending on the positive internal/external connection at the interface), which may then result in a flow of bacteria from the gap, causing the formation of inflammatory connective tissue in the region of the implant neck.³⁹⁻⁴¹

Berglundh and Lindhe evaluated the micro-gap of the Brånemark two-stage implant and found that inflamed connective tissue existed 0.5 mm above and below the abutment-implant connection, which resulted in 0.5 mm bone loss within two weeks after the abutment had been connected to the implant.⁴² Ericsson et al. coined the term distance-sleeve-associated infiltrated connective tissue to describe this phenomenon. They interpreted this to be a biological protective mechanism against the bacteria residing in the microcrack, explaining the plaque-independent bone loss of approximately 1 mm during the first year. This bone loss may result in a reduction of the marginal bone level in both the vertical and the horizontal dimensions.⁴³

If the microcrack is located close to the bone, the creation of the biological width will occur at the expense of the bone. The platform-switching effect was first observed in the mid-1980s. At the time, larger-diameter implants were often restored with narrower abutments (Ankylos, DENTSPLY Friadent; AstraZeneca; Bicon), as congruent abutments were often still unavailable. As it later turned out, this was a remarkable coincidence.⁴⁴ The platform-switching concept requires that this micro-gap be placed away from the implant shoulder and closer toward the axis in order to increase the distance of this micro-gap from the bone as a protective measure.

_Biological width

The clinical term biological width denotes the dimensions of periodontal and peri-implant soft-tissue structures such as the gingival sulcus, the junctional epithelium, and the supra-crestal connective tissues.⁴⁵ According to measurements conducted by Gargiulo *et al.*, the average biological width (from the base of the sulcus to the alveolar bone margin) is 2.04 mm, of which 0.97 mm is epithelial attachment

and 1.07 mm is connective tissue attachment.⁴⁶ These dimensions, however, are in no way static but subject to interindividual variation (from tooth to tooth and from patient to patient) and will also vary according to gingival type and implant concepts.

Numerous studies have shown that bone resorption around the implant neck does not start until the implant is uncovered and exposed to the oral cavity. This invariably leads to bacterial contamination of the gap between the implant and the superstructure.⁴⁷⁻⁵⁰ Bone remodelling will progress until the biological width has been created and stabilised. This width progresses not only apically along the vertical axis (Fig. 1), but also 1 to 1.5 mm horizontally, according to studies conducted by Tarnow *et al.* This is the reason for maintaining a minimum distance of 3 mm between two implants and platform switching in the aesthetic reconstruction zone in order to obtain intact papillae and stable inter-implant bone.⁵¹⁻⁵³

_Summary

Maintenance of crestal bone around dental implants is one of the critical factors that affect its longevity and aesthetic soft-tissue architecture. Preservation of such bone is a multifactorial process; as summarised in this article some other factors related to crestal bone loss have been investigated. These includes bone volume, bone quality, soft-tissue biotype, condition of the adjacent teeth, implant design, implant dimensions, abutment design, augmentation procedures, implant insertion depth, time of loading, time of restoration, frequency of prosthetic secondary-component replacement, suturing techniques and patient compliance.

Proper tissue maintenance and care, regular hygienic evaluations and patient education on proper methods for home care are vital. Continued evaluation via probing, radiographic assessment and oral examination will allow the clinician to ensure long-term maintenance and overall treatment success.

Editorial note: A list of references is available from the publisher.

_contact

implants

Dr Mohammed A. Alshehri

Consultant Restorative and Implant Dentistry at the Riyadh Military Hospital, Department of Dentistry
P.O. Box 225763
Riyadh 11324, Saudi Arabia

dr_mzs@hotmail.com



SIMPLY BETTER

STRAUMANN® SLActive

Straumann® SLActive – The next generation in surface technology

- Higher security and faster osseointegration for every indication
- Reduced healing times from 6–8 weeks down to 3–4 weeks
- Increased treatment predictability in critical protocols

www.straumann.com



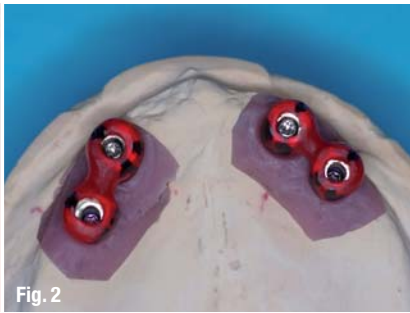
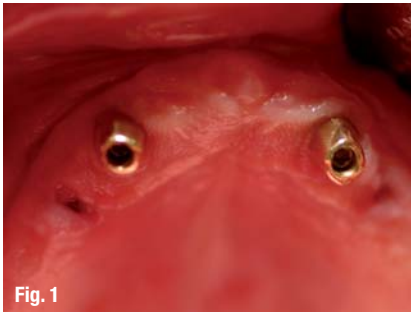Based on the following studies: preclinical: Buser et al. (2004), Schwarz et al. (2006/2007) clinical: Zöllner et al. (2007), Oates et al. (2007) internal data on file

COMMITTED TO
SIMPLY DOING MORE
FOR DENTAL PROFESSIONALS

Implant-prosthetic troubleshooting

When dental technicians and dentists break into a sweat!

Authors_Dr Georg Bach & Christian Müller, Germany



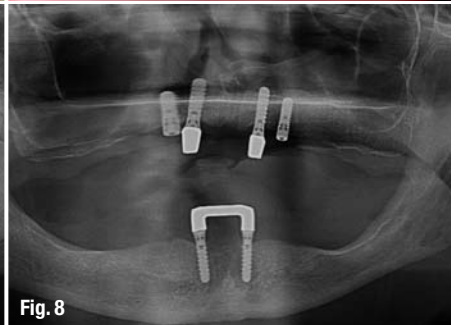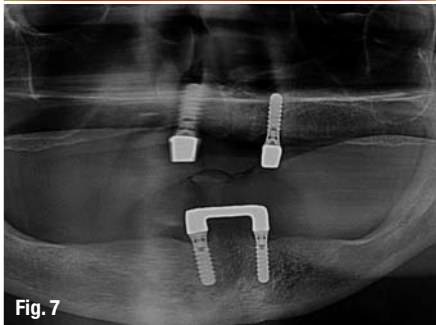
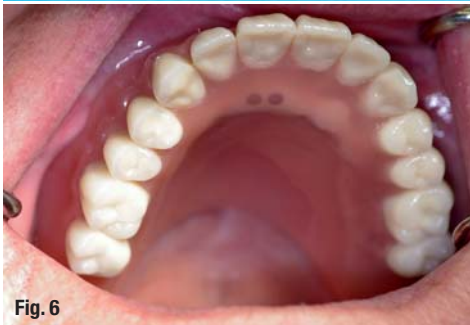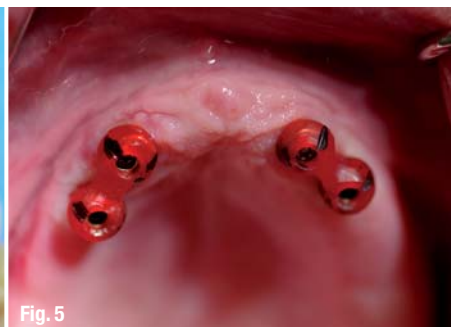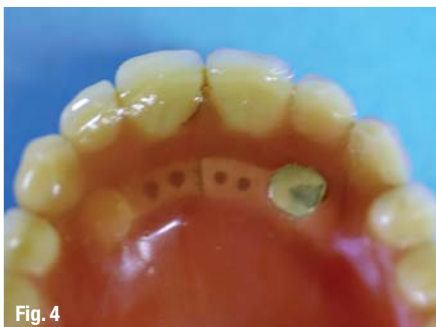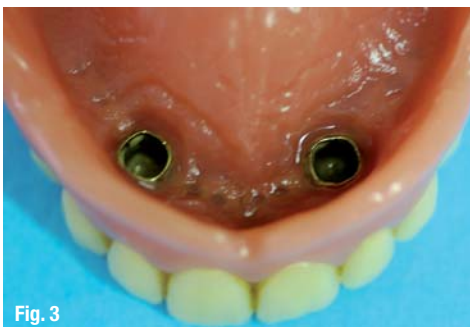Unidentified jaw misalignment
Figs. 1–4 The former prosthesis (with two maxillary implants); note the discrepancy between the translucent templates and the axis of the plastic front teeth.

_Implant-prosthetic troubleshooting usually starts at an advanced stage of the implant-prosthetic treatment, i.e. when implants have already been inserted, and the next step is the insertion of prostheses on the artificial abutment teeth. This point in time is extremely un-

favourable for several reasons, one being that—owing to the already completed surgical phase—there is no opportunity for intervention and modification of the implant placement, and the other reason being that the patient feels he or she is on the verge of a successfully completed treatment and does not realise that difficulties may now arise, which in extreme cases could result in failure of the entire treatment. This development usually ends in mutual accusations and forensic disputes.

_"Incorruptible"—The dental master model

In a worst-case scenario, it will not become apparent that the inserted implants cannot be



treated dentally, or only with extreme difficulty, owing to unfavourable placement in the jawbone until the dental master model has been created by the dental technician after casting or after the check-bite at the very latest.

"Plaster is incorruptible!". This conclusion, attributed to Freiburg dental surgeon Prof Eschler, was deliberately kept trivial; however, it is simply and utterly true. The dental master model shows the realities concerning placement of the implant, its axis, also with regard to abutment teeth, and the transition to the gingiva.

Exemplary patient cases

Our report will demonstrate, based on a few exemplary patient cases, the solution possibilities, but also the limits of implant-prosthetic troubleshooting—especially in terms of achieving a sustainable result for patient, dentist and dental technician.

Unidentified jaw misalignment (Figs. 1–8)

The problem

Two years ago, a male patient (in his mid-70s) had received two implants in the maxilla, followed by treatment with telescopes and a partial prosthesis. The patient stated that "the work did not agree with him right from the start".

Aside from functional problems, he disliked the fact that the maxillary front teeth were not visible even when he opened his mouth half-way.

Just by looking at the maxillary prosthesis it was easy to notice the metal portions of the prosthesis, which were placed extremely palatally, showing through. An examination of the oral cavity revealed a considerable discrepancy between the implant placement and the axis of the plastic front teeth!

Our solution

A wax-up marked the beginning of the actual treatment. It was modified until the patient was satisfied with the placement of his teeth and his subsequent appearance. Based on the results of this treatment planning, we were able to determine which position and alignment would be required for two additional implants (distally of the existing ones).

This in turn resulted in the creation of a drilling template, which was used during the insertion of the two additional artificial abutment teeth. After osseointegration of these two implants in regions #14 and 24, the new partial prosthesis (now supported by four implants (two existing and two new ones) was produced and integrated step by step.

Aside from cases like the one mentioned above, which are usually the result of design errors and/or design flaws, there is additional, yet different implant-prosthetic troubleshooting—covering primarily implant fractures or failure of individual implants within an extensive supra-structure. This considerably smaller part of implant-prosthetic problem areas, as compared with the group of design errors mentioned above,

Figs. 5 & 6 After interdisciplinary planning between dental technician and dentist, two additional distally located implants were inserted; the four artificial abutment teeth each received a telescopic crown. We used individual insertion keys to facilitate incorporation of the telescopes.

Fig. 7 Initial X-ray image (panoramic tomography) with two implants (treated with telescopes) in the maxilla.

Fig. 8 Condition after the increase of abutment teeth in the maxilla, each inserted distally of the previous implants.

Loss of implant due to peri-implantitis

Fig. 9 The mesial abutment tooth of a bridge entirely supported by implants in the left maxilla was lost. After healing of the soft tissue, a further implant was inserted in a position as close as possible to the former implant position. The illustration shows the dental master model with the customised abutment.

Fig. 10 The former bridge structure was used as a customised "spoon" for the newly added implant so that a customised abutment could be created for the additional implant to be mounted distally (note the loss of vertical distance) for use in the existing restoration.

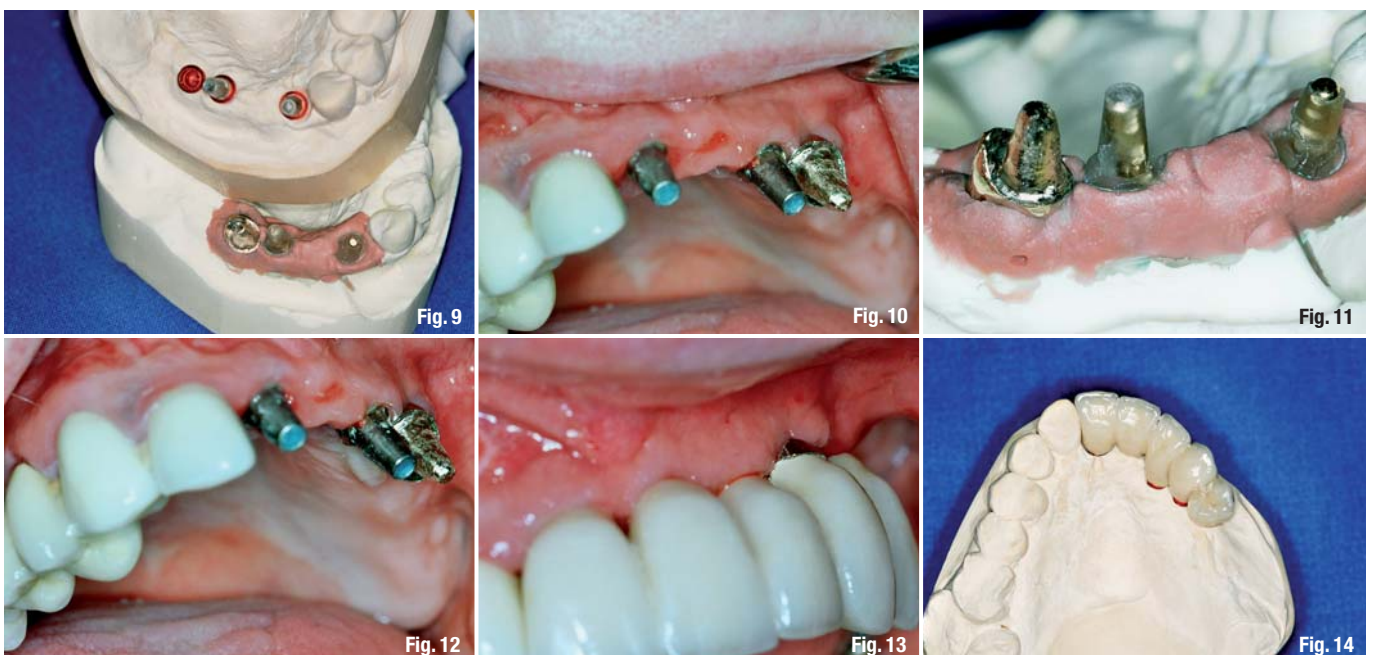

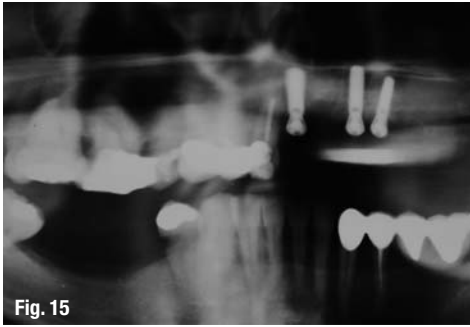


Fig. 15

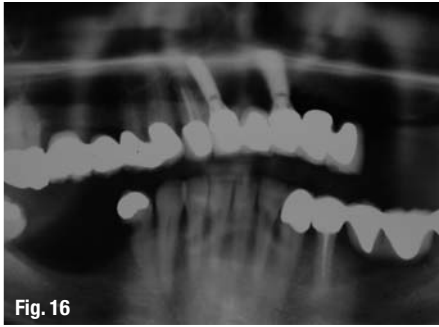


Fig. 16

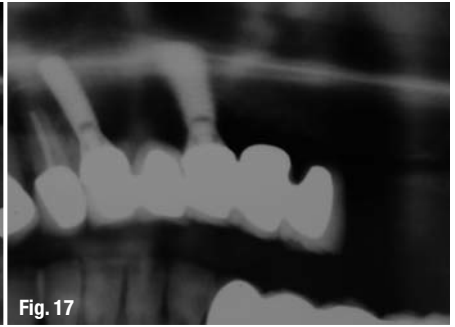

Fig. 17

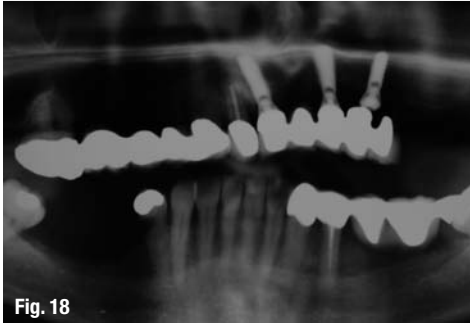


Fig. 18

Fig. 11_ Customised abutment tooth as a terminal abutment.

Fig. 12_ Patient's oral condition.

Figs. 13 & 14_ We were able to preserve the bridge in the left maxilla.

Fig. 15_ Three implants had originally been inserted to treat anodontia in the second quadrant.

Figs. 16 & 17_ The distal implant was lost; the detailed view shows the non-functional crown #25.

Fig. 18_ Condition after re-implantation distally of the implant localization.

Implant fracture

Fig. 19_ The distal (diameter-reduced) implant of a bridge supported entirely by fractured implants.

Fig. 20_ An additional implant was inserted distally after removal of the fragment that had remained in the bone. After integration of the implant, a new bridge supported entirely by implants was created, while incorporating the former implant.

will be covered and evaluated in this article. The purpose of this is to demonstrate solutions so that the patients affected receive a modified solution in order to preserve the existing and very expensive work.

_Loss of implant due to peri-implantitis
(Figs. 9–18)

A bridge structure in the second quadrant had been in place without any problems in a 50-year-old female patient for 10 years. Therefore, she only came to recall and follow-up examinations sporadically. The problem-free period ended abruptly when swelling and bite pain occurred in the left half of the maxilla. A panoramic tomography revealed radiological indications of a profound osseous defect around the mesial implant, which had to be removed on the same day. The issue then was the entire supra-structure. The patient insisted that this structure be preserved owing to the financial cost of having a new structure created after re-implantation.

Our solution

A new implant was inserted after the soft tissue and bone had healed in the area where the lost implant had previously been in place. The bridge structure that had been temporarily affixed on the remaining implant was used as guidance for incorporation of a replacement implant and then removed for the actual implant procedure.

After osseointegration of the artificial abutment tooth, we inserted a plastic abutment and made a casting of the integrated bridge structure with polyether casting material. This customised abutment was transformed into metal and the bridge structure finally cemented in place after a trial insertion.

_Implant fracture (Figs. 19 & 20)

Diameter-reduced implants can often be implanted even in a reduced osseous bed and aid in the avoidance of augmentations. However, when introduced into the market, diameter-reduced implants were frequently used for other indications as well; some authors even recommended using them as standard implants. Stress phenomena caused a considerable number of implant fractures, resulting in markedly restricted indications for diameter-reduced implants.

The case presented here reflects the typical progress of this early phase. A purely implant-supported (two abutments) extension bridge was incorporated into the fourth quadrant. A diameter-reduced implant was used in spite of an orovestibular bone dimension that would have been sufficient for supporting a standard implant. The result was that the distal implant fractured after eight years.

Our solution

In one surgical session, we removed both the implant fragment remaining in the bone by way of an osteotomy and placed a further distal im-

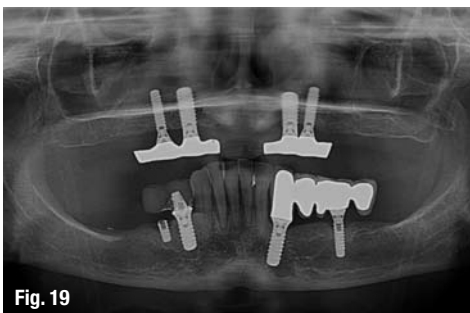

Fig. 19

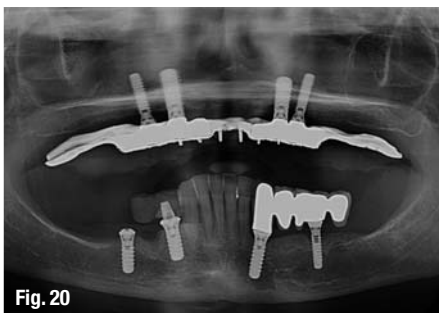

Fig. 20

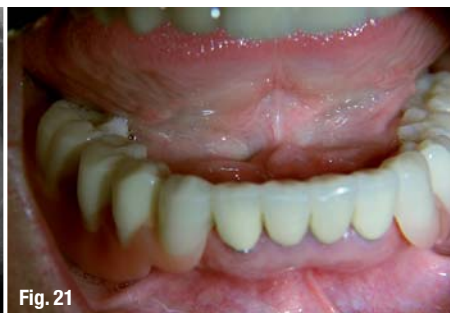

Fig. 21

ADVANCED TISSUE-MANAGEMENT

The easy way to aesthetics.

PARASORB Sombrero®

RESODONT®

PARASORB® HD Cone

GENTA-COLL® HD Cone



RESODONT®

- ▶ naturally cross-linked, with no chemical additives
- ▶ quick and easy to cut to size and apply, both sides can be used
- ▶ rapid integration in the surrounding tissue
- ▶ highest degree of product safety and excellent biocompatibility

PARASORB Sombrero®

- ▶ to cover and simultaneously fill the alveolus (socket preservation)
- ▶ offers a defined regeneration matrix
- ▶ formation of a stable bony implant bed after a relatively short time
- ▶ improved long-term aesthetic and functional results particularly in the anterior region

PARASORB® HD Cone GENTA-COLL® HD Cone

- ▶ rapid and safe haemostasis
- ▶ reduction of alveolar ridge atrophy
- ▶ optionally comes with antibiotic protection for high-risk patients (e.g. diabetics, smokers, immune-suppressed patients)

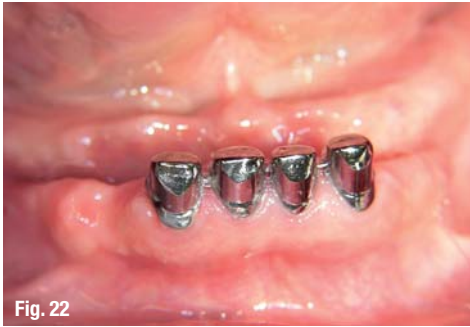

Fig. 22

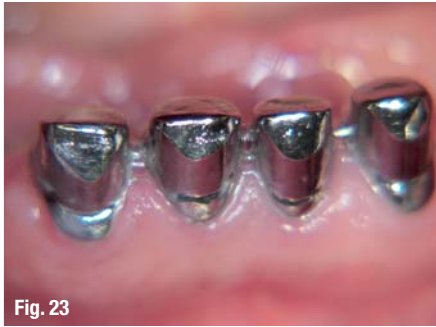

Fig. 23

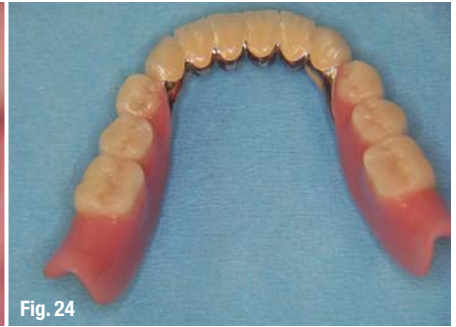

Fig. 24

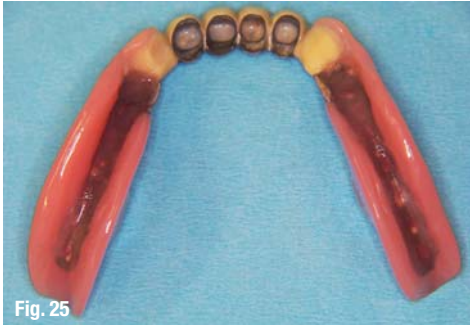

Fig. 25

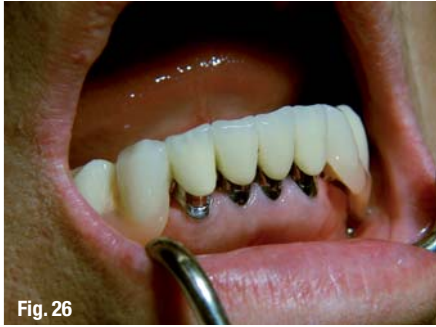

Fig. 26

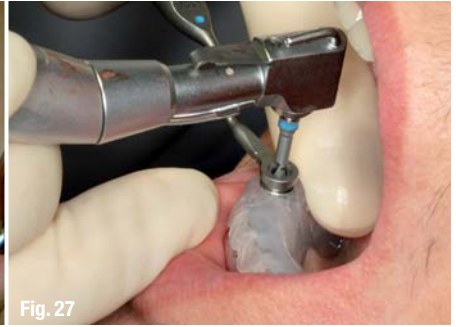

Fig. 27

The unsuccessful conventional solution

Figs. 21–25 Owing to the loss of prospective abutment teeth #43 and 33 during the prosthetic treatment phase, the remaining front teeth #42, 41, 31 and 32 received telescopic crowns.

Fig. 26 The partial prosthesis showed insufficient mounting.

Figs. 27–29 With the aid of 3-D imaging and planning, four implants were inserted in regions #46, 43, 33 and 36—without any augmentative treatment.

Fig. 30 After osseointegration of the artificial abutment teeth, two side-tooth bridges entirely supported by implants and four individual crowns were integrated with the remaining mandibular teeth.

plant. After its osseointegration, we incorporated a completely new bridge using the existing mesial implant.

The results achieved here can help us learn from design errors and select a different approach for future cases, so that we can also treat patients who have had failure of a comprehensive prosthetic restoration. Our last case will illustrate this situation.

The unsuccessful conventional treatment versus the successful, well-planned implantological procedure (Figs. 21–34)

Finally, we would like to present an unusual case: an unsuccessful conventional treatment that was replaced with implantological treatment carried out in close collaboration between the dentist and dental technician. The patient had experienced considerable complications during prosthetic treatment (the goal being a telescopic partial prosthesis supported by teeth

#43 and 33, while preserving the front teeth #42 to 32, which had been caries-free and without fillings until then, and replacement of teeth #47 to 44 and 34 to 37). First, tooth #33 fractured and had to be extracted, in spite of the fact that preparation and casting had already been done. Treatment was replanned after this event, and teeth #42, 41, 31 and 32 were also prepared (the goal being telescopic crowns). Shortly before implementation, tooth #43 also had to be extracted. The patient was unable to give the exact reasons for this. This left her with four teeth—#42, 41, 31 and 32—which all had telescopic crowns.

Anchoring of the partial prosthesis was poor; the patient was able to loosen it with minimal tongue-applied pressure. The pronounced tendency of the prosthesis saddles to cave in also resulted in complications in the form of multiple recurrent pressure sores. The patient was referred to us at this point. The reason for this according to her dentist was that implants, which the patient had inquired about, could be inserted

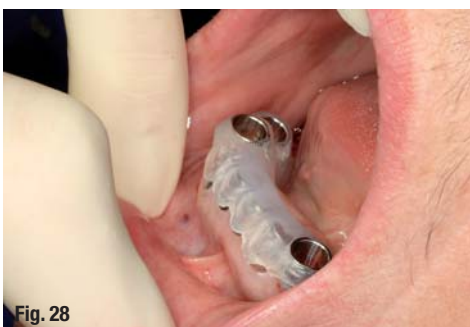

Fig. 28

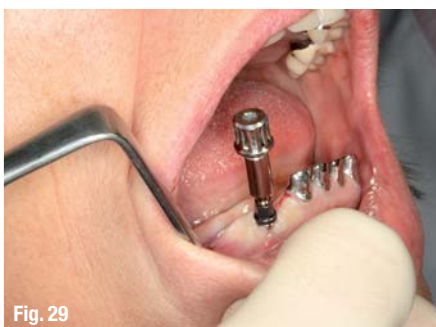

Fig. 29

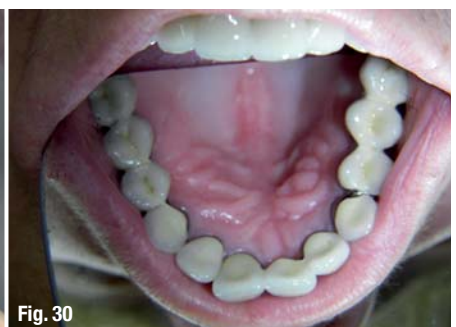

Fig. 30

neither in the extended front-tooth area nor in the side-tooth area owing to the narrow and atrophied alveolar ridge.

Our solution

It was true that the alveolar ridge on both sides, starting with the cuspid region and extending to the area where the molars had been previously, was fairly pointed, and the course of the osseous limbus alveolaris displayed a pro-

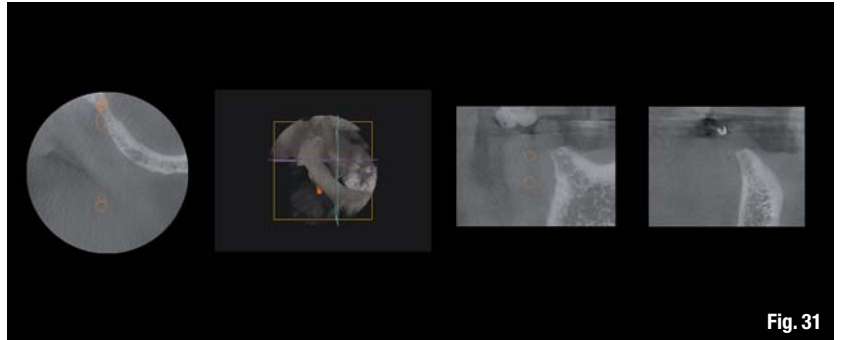


Fig. 31

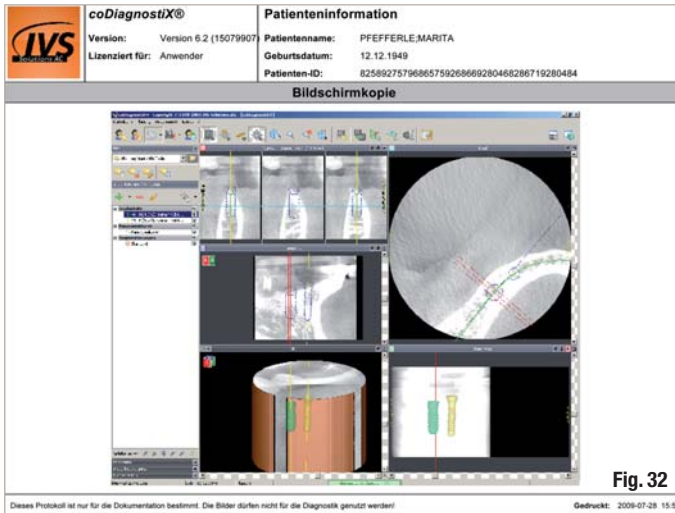


Fig. 32

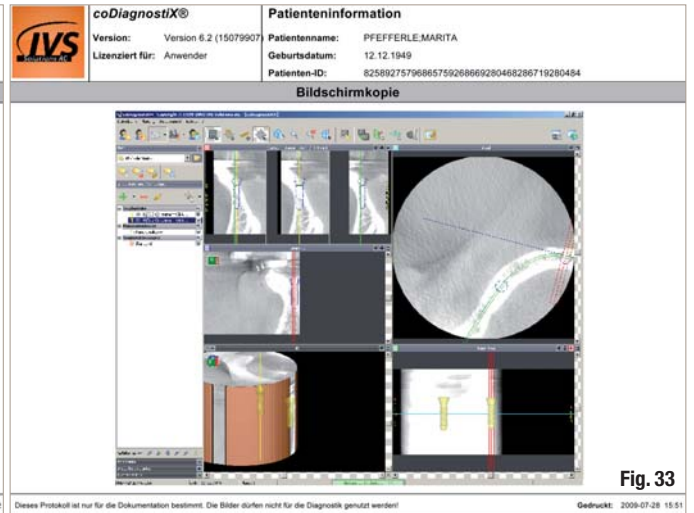


Fig. 33

nounced sagging distally of the previous premolar zone.

The patient thus showed considerable osseous deficits in both the oro-vestibular and horizontal dimension. In order to assess the basic possibilities of oral implants, we decided to perform 3-D imaging, which proved extremely helpful in this complex patient case. After illustration of the osseous situation, there were indications that implantation would be possible without carrying out augmentation procedures. We then prepared a virtual implant plan, the results of which led us to prepare a drilling template.

The remaining front teeth proved very helpful as a place for securely anchoring the template. By opting for a shortened row of teeth with one implant each in the region of the former six-year molars and an additional artificial abutment in each of the former cuspid areas, we were able to keep the dimensions of the template relatively small.

The insertion of four implants in the regions of teeth #46, 43, 33 and 36 and their osseointegration were followed by treatment with the suprastructures, which consisted of two bridges in regions #46 to 43 and 33 to 36, entirely supported by implants, and four individual crowns on the

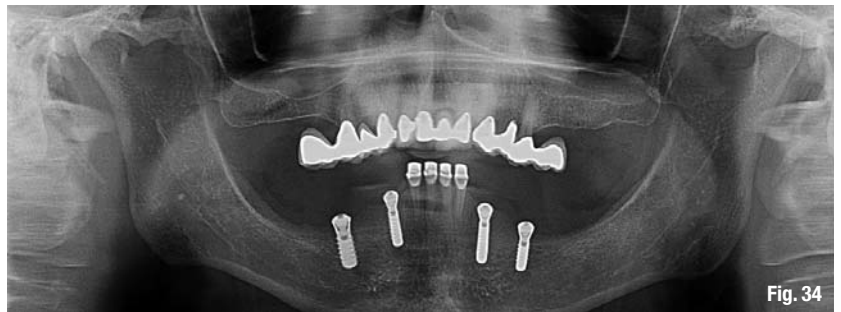

Fig. 34

front teeth. The restorations were temporarily affixed for six months and then cemented in place.

| | |
|---|-----------------|
| _contact | implants |
| <p>Dr Georg Bach Oral surgery specialist Rathausgasse 36 79098 Freiburg/Breisgau, Germany doc.bach@t-online.de</p> <p>ZTM Christian Müller Master dental technician Dental Technik Müller Carl-Kistner-Straße 21 79115 Freiburg/Breisgau, Germany CHMUE10@aol.com</p> | |

Figs. 31–33_Three-dimensional diagnosis and planning (see dental pins) of the third and fourth quadrant. **Fig. 34**_Orthopantomogram after incorporation of four implants, three of which were diameter-reduced Roxolid (Straumann) implants.

A simplified method for the removal of cemented implant prosthetics

Author_Dr Scott Davis, Australia

There are times when it becomes necessary to remove the cemented prosthetic restoration from one or more implants and the prosthesis is not amenable to conventional crown and bridge removal devices. In order to remove these prostheses, we need to gain access to the abutment screws by drilling through the crown or bridge. The challenge is to create the smallest possible access hole and to do this with a minimum of clinical time and effort. This article will describe a simple method for constructing and using a device to guide the creation of appropriate access holes in the implant prosthesis. I was lucky enough not to have a patient with a loose or damaged bridge to use for this presentation, so I used a patient education model to provide the images to facilitate the description of the technique (Figs. 1a & b). Figure 2 shows the location of the implants.

Constructing the device

The master cast that was used for the construction of the implant prosthesis is the central element for this

technique (Fig. 3). Long screws from impression copings (Fig. 4) or long laboratory screws are inserted into the implant analogues (Figs. 5a & b). The cast is blocked out with periphery wax to act as a formwork for the construction of the device (Figs. 6a–c). The wax should extend for at least one tooth on either side of the prosthesis. If no tooth is present distal to the prosthesis, then additional teeth are covered anteriorly to maximise stability of the device. The wax should also block out the full dimensions of the prosthesis. I like to construct the mesial aspect of the device to be sufficiently wide and robust for a finger or thumb to be readily placed on this area for stabilising the device during preparation of the access holes. The model and the screws are lubricated with either petrolatum or a water-based lubricant. Auto-polymerising or light-curing resin is adapted to the cast to cover the adjacent occlusal surfaces and encompass the screws in the implant analogues (Figs. 7a–c). I prefer to use GC pattern resin and in the later stage of polymerisation, I remove the screws before they potentially become locked in the resin. Once the mate-

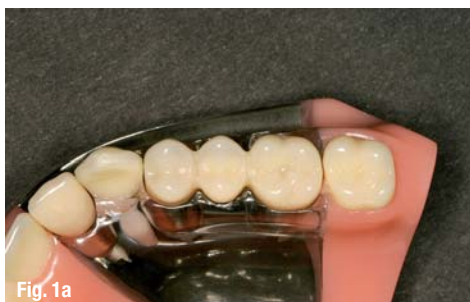

Fig. 1a

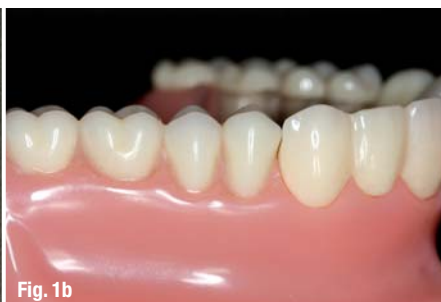

Fig. 1b

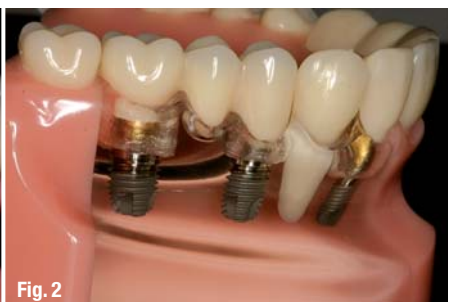

Fig. 2

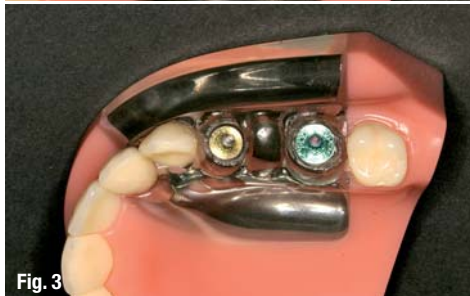

Fig. 3



Fig. 4

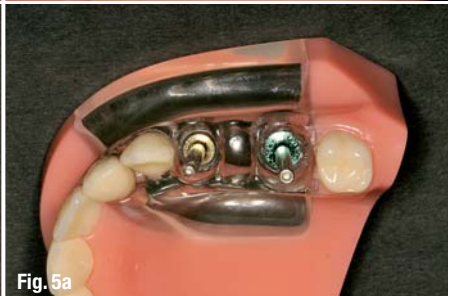

Fig. 5a

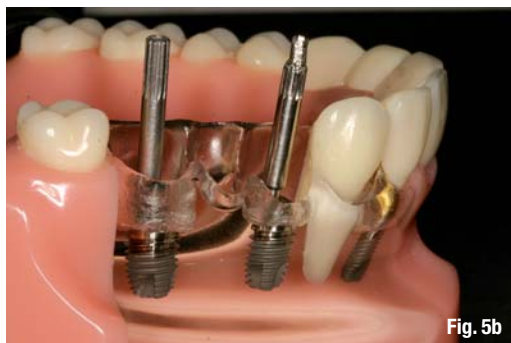

Fig. 5b

rial sets, it is trimmed and polished (Figs. 8a & b) then checked for stability on the model. Additional material can be added if required. If a stone model of the prosthesis is available, it is convenient to confirm the stability of the device and to assess that there is no contact between the prosthesis and the device (Fig. 9). The intaglio surface is adjusted as required to ensure appropriate adaptation.

In the clinic

The chairside process is simplified by the use of this acrylic resin guiding device that provides a visual aid for the appropriate position for drilling the access holes. Ideally, porcelain should be removed using a diamond high-speed bur with copious irrigation. I prefer to use a round diamond bur for this purpose, as it is less likely to cause porcelain chipping. If the prosthesis is metal ceramic, the metal substructure is first penetrated with a small round carbide bur. Subsequently, a metal-cutting tungsten carbide bur is used to widen the access as required. Figure 10 shows a screwdriver passing through the guide into the abutment screw. Figures 11a and b show the precision of the preparation without over-preparation. Once the access hole has been debrided of obturating materials, an appropriate screwdriver is inserted. In order to prevent ceramic delamination, it is important to ensure the driver is not contacting any porcelain before significant torque is applied. I initially insert the driver and inspect for lack of contact with the porcelain. Following, I apply light hand torque to the driver in order to determine that it is fully seated before a second inspection to ensure no porcelain contact. Finally, the screw and the prosthesis are removed.

Discussion

Drilling free hand into the prosthesis with no guide can result in oversized access holes and wasted chairside time. The primary goal of the method described here is to maximise laboratory procedures in order to reduce chairside time. The method also minimises the size of the access holes, which reduces damage to the prosthesis. Delegation of the construction of the device to a technical assistant can further reduce cost, for both the patient and us. Thereby, a task to which we look forward

41ST

INTERNATIONAL ANNUAL CONGRESS OF THE DGZI

Implantology – Claims, possibilities and expectations



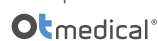
FAX +49-3 41/4 84 74-3 90

Please send me further information on the
41ST INTERNATIONAL ANNUAL CONGRESS OF THE DGZI
September 30–October 1, 2011, Cologne, Germany

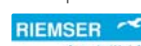
Office Stamp

IM 2/11

Gold Sponsor:



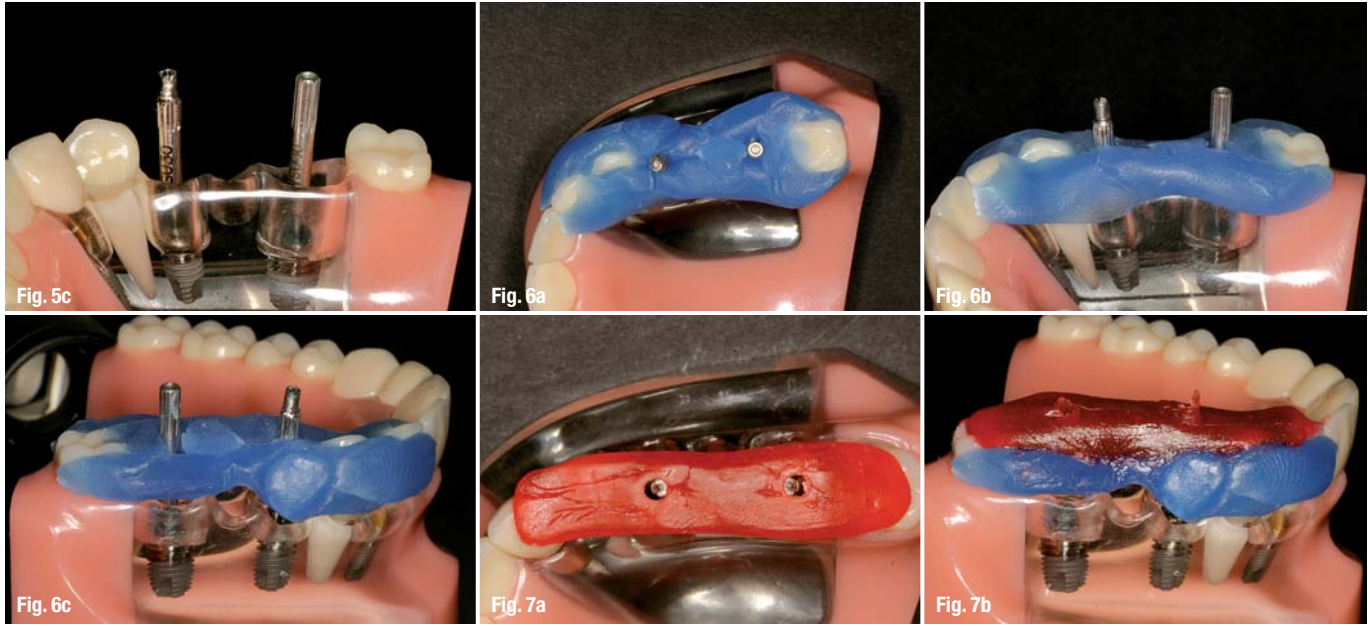
Silver Sponsor:



Bronze Sponsor:



Call for papers for download on www.dgzi.de



with trepidation can be reduced to a minor inconvenience. By minimising the diameter of the access holes, we increase the probability that the prosthesis can be returned to the patient after dealing with the reason for removal. Once the prosthesis has been removed from the mouth, there are two options. Firstly, we could consider the abutment/prosthesis as a single item. After inspection and cleaning, the prosthesis can be replaced. Had the abutment screw become loose, then the grain structure of the screw may have become elongated and the screw should be replaced.

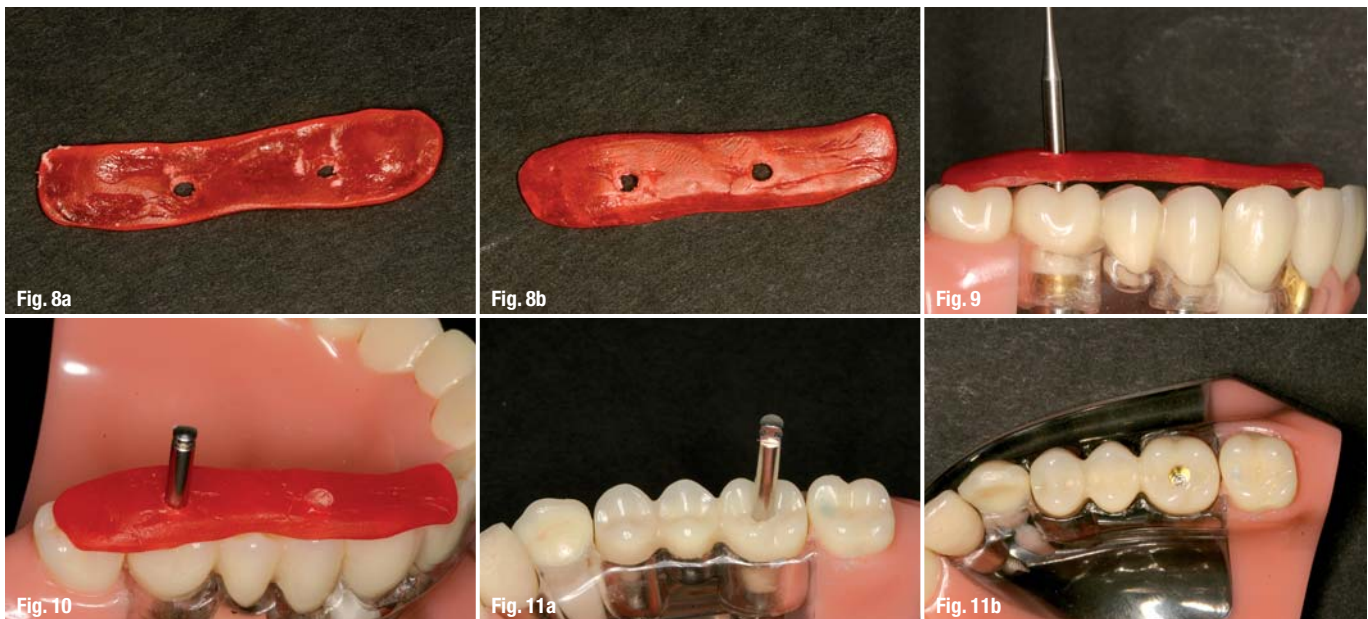
The second option is separating the abutment from the crown or bridge. When they cannot be separated by mechanical means, they can be separated by gentle heating in a furnace. Slowly heat to less than 200°C for

five minutes, then the abutment and prosthesis should separate very easily. Allow to cool to room temperature slowly, then inspect porcelain for defects before returning to the patient.

_about the author

implants

Dr Scott Davis graduated from the University of Sydney in 1984 with a Bachelor of Dental Science degree and completed his Master of Dental Science degree in Prosthodontics in 1993 at the University of Western Australia. He worked as a senior lecturer in Restorative Dentistry. Since 1997, he has worked in a private specialist practice. Dr Davis can be contacted at scott@davisdental.com.au.



SAVE CELLS

NEW EMS SWISS INSTRUMENTS SURGERY – SAVING TISSUE WITH NEW INNOVATIONS IN IMPLANT DENTISTRY

The inventor of the Original Piezon Method has won another battle against the destruction of tissue when dental implants are performed. The magic word is dual cooling – instrument cooling from the inside and outside together with simultaneous debris evacuation and efficient surgical preparations in the maxilla.

COOLING HEALS

A unique spiral design and internal irrigation prevent the instrument's temperature from rising during the surgical procedure. These features combine effectively to promote excellent regeneration of the bone tissue.

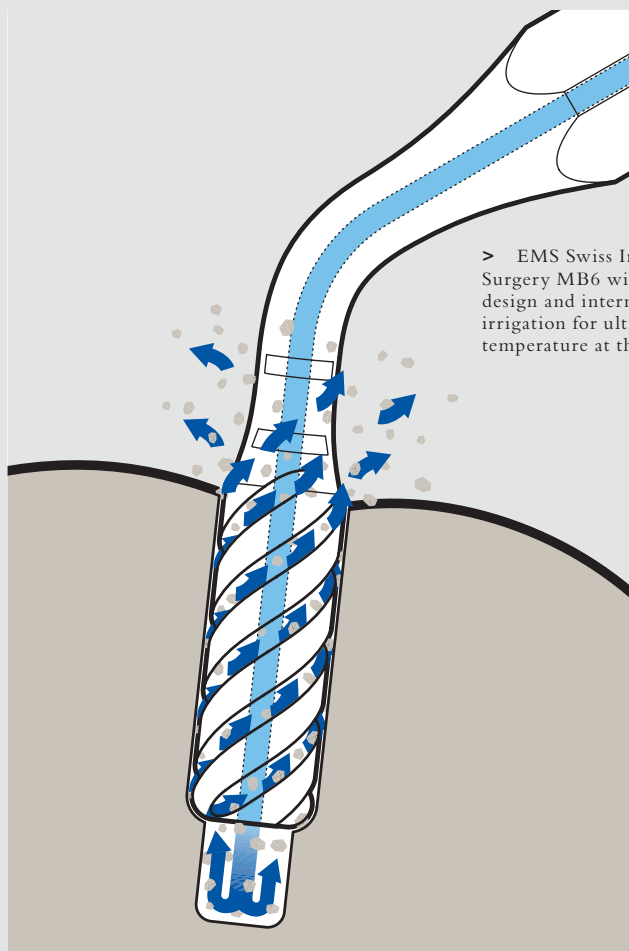
EMS Swiss Instruments Surgery MB4, MB5 and MB6 are diamond-coated cylindrical instruments for secondary surgical preparation (MB4, MB5) and final osteotomy (MB6). A spiral design combined with innovative dual cooling makes these instruments unique in implant dentistry.

CONTROL SAVES

Effective instrument control fosters atraumatic implant preparation and minimizes any potential damage to the bone tissue.

PRECISION REASSURES

Selective cutting represents virtually no risk of damage to soft tissue



> EMS Swiss Instrument Surgery MB6 with unique spiral design and internal instrument irrigation for ultralow temperature at the operative site

(membranes, nerves, blood vessels, etc.). An optimum view of the operative site and minimal bleeding thanks to cavitation (hemostatic effect!) further enhance efficacy.

The new EMS Swiss Instruments Surgery stand for unequalled Swiss precision and innovation for the

benefit of dental practitioners and patients alike – the very philosophy embraced by EMS.

For more information >
www.ems-swissquality.com



Augmentation— one important basis in implant treatment concept

Authors_ Prof Dr med Frank Liebaug, Dr med dent Ning Wu, Germany

_In recent years new issues have arisen in the field of implant dentistry. The 1980s was the decade of osseointegration; the 1990s, the era of guided bone regeneration. Recently, the focus has mainly been on the improvement of dental aesthetics and methods of improving the aesthetic and functional results, the load-carrying capacity and the simplification of surgical techniques. These aspects should not be considered separately from each other, as they overlap.

In 1980, Philip Boyne first described procedures for sinus floor augmentation. Since then more than 1,000 scientific articles on sinus floor augmentation have been published.

Today, the use of osseointegrated dental implants is an effective and reliable method for long-term treatment of patients with partial and total tooth loss. The success rate and predictability of implant treatment depends on several factors but are generally high. The goal is to make this rehabilitative process accessible to as many patients as possible, even those with poor bone quality and/or low bone mass. Until now, an insufficient amount of bone and poor bone quality have been unfavourable or even a contra-indication for implant treatment. Because of poor bone quality and often-progressive bone re-

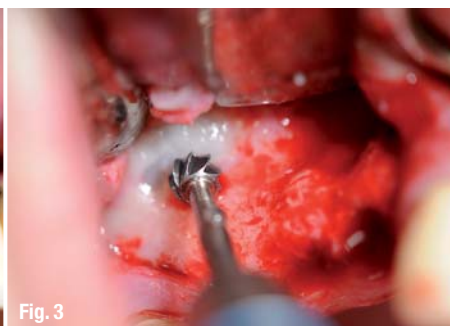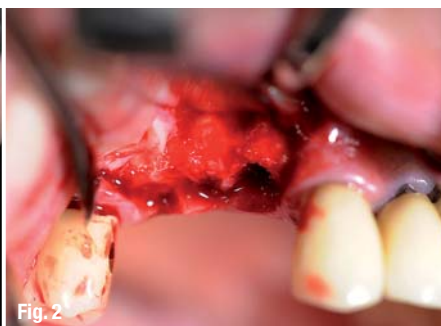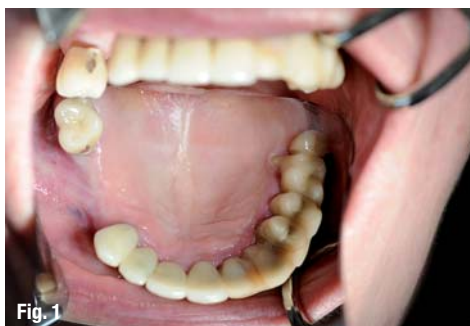sorption after tooth loss, the posterior maxilla especially is a high-risk area for the placement of dental implant restorations. If atrophic maxillary bone or a large maxillary sinus is present, the implant treatment is more difficult. A solution in such cases is the use of shorter implants. However, certain clinical conditions must be met so that an unfavourable relationship between the implant and the restoration length (implant-crown ratio) does not lead to biomechanical problems, improper loading or premature implant loss. In such cases, the implant treatment must be planned carefully and additional surgical procedures before dental prosthetics, such as a bone graft in the maxillary sinus, are often required to compensate for inadequate bone. In this way, optimal conditions for the insertion of implants in the posterior portions of the alveolar process of the maxilla are created.

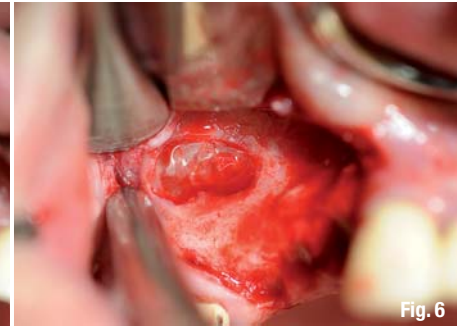
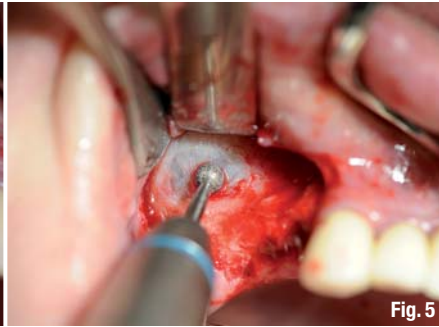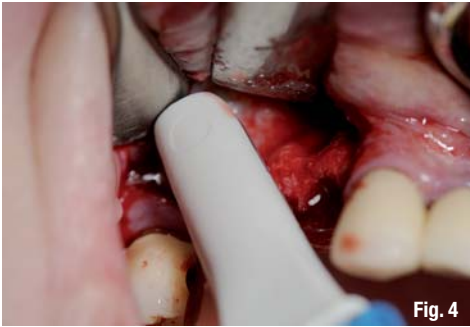In the past, dentists and maxillofacial surgeons avoided complex procedures that required access to the maxillary sinus through the oral cavity, provided such were not necessary. As early as 1984, Brånemark demonstrated with clinical and experimental data that the apical end of an osseointegrated implant can be placed in the maxillary sinus without adversely affecting the health of the sinus area if the Schneiderian membrane remains intact.

Fig. 1_ Situation before operation, vestibule area is relatively broad, flat ridge regions # 14 to 16, 6 weeks after extraction of tooth #14.

Fig. 2_ Surgical site after surgical flap preparation shows fully ossified alveolus of tooth #14, 6 weeks after extraction.

Fig. 3_ Pre-preparation of the bone window in region #16 with large Rosecutter to mark the finish line under continuous cooling.





Today, it is common knowledge that the long-term success of dental implants depends on the degree of osseointegration. This, in turn, is dependent on the primary stability, on the one hand, which is determined by the density of cortical bone and the bone quality, and on the secondary stability, on the other hand. The latter results from the progressive deposition of bone along the implant surface. Although an implant that is inserted into bone with reduced height and width and that extends from one end into the sinus cavity shows a good primary stability with a sufficient solid cortex, its anchor remains limited. Thus, osseointegration of the entire implant surface, which is critical to the long-term success, cannot be achieved. If a progressive loss of crestal bone takes place over time, the implant stability is further affected.

Therefore, in the posterolateral maxillary it is often necessary to perform a sinus floor augmentation if there is poor bone quality and insufficient alveolar process height. A sinus floor augmentation and significant pneumatization of the maxillary sinus are indicated in order to be able to use sufficiently long implants to guarantee the anchor in a region of high functional load.

In 1980, Boyne and James wrote the first publication on the treatment of patients with endosseous implants in combination with sinus floor elevation. Access to the maxillary sinus was by means of the intra-oral antrostomy and the preparation of a "bone window". This was then carefully advanced into the cavity and drawn. Therefore,

a partial detachment of the Schneiderian membrane from the sinus floor was needed. Subsequently, a bone graft was placed under the membrane and the opening was obturated again. Generally, the bone from the patients themselves was used as the graft. In a second step, several months after the sinus floor elevation, blade implants were successfully implanted. The prosthetic reconstructions existed in fixed or removable dentures, which were placed in the edentulous sections of the posterior maxilla.

Soon thereafter, Tatum *et al.* worked on this surgical technique intensively, seeking to improve the results by means of modified procedures. Tatum Sun took on a key role in the development of the procedure for sinus floor elevation using an autogenous bone graft from the iliac crest for the preparation of the implant insertion (Tatum 1977, 1986). Progress in the field of biomaterials and refined techniques and protocols for the rehabilitation of tooth loss by osseointegrated implants have increased the success rate and the predictability of implant treatment.

Xenogeneic grafts

To spare patients an additional removal of autologous bone in other areas of the spine or of the iliac crest, bone substitute materials (xenogeneic grafts) are used increasingly today. Xenogeneic grafts are now mostly deproteinized (inorganic) bovine bone specimens. These grafts are used either alone or are mixed and used as part of a mixed transplant with

Fig. 4 Extraction of the patient's own (autologous) bone chips by Safescraper.
Fig. 5 Careful dissection of the Schneiderian membrane by the use of a diamond bur.
Fig. 6 Illustration of the intact Schneiderian membrane in region #16.

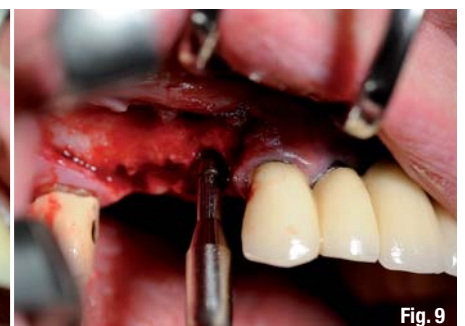
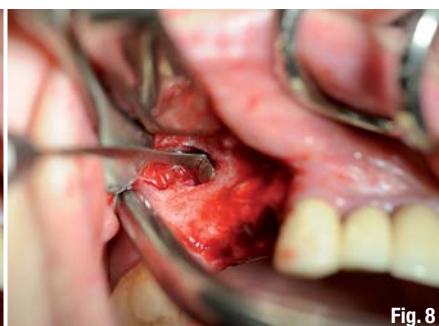
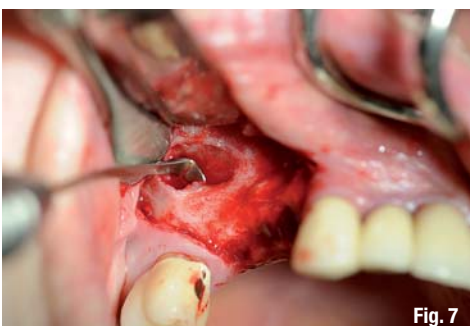Fig. 7 Carefully solution of the Schneiderian membrane from lateral to caudal.
Fig. 8 Lifting and moving of the Schneiderian membrane.
Fig. 9 Preparation of the implant cavity after pilot hole with bone-condensing instruments.

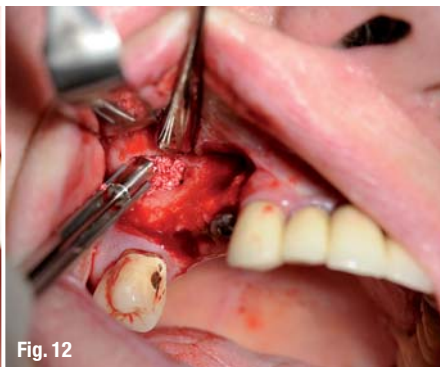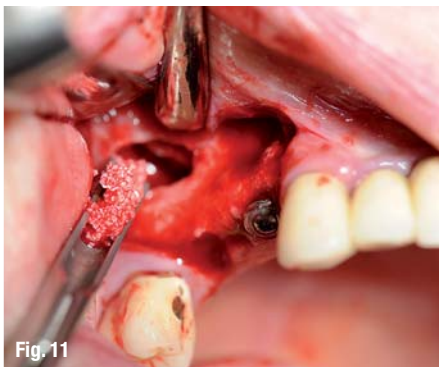

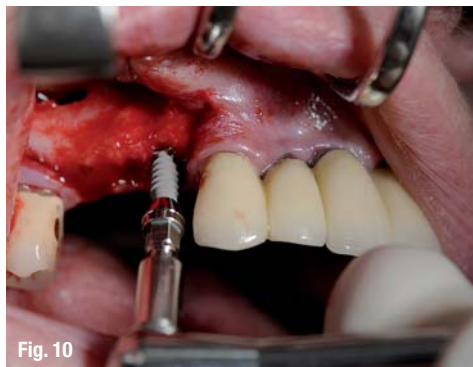
Fig. 10 Insertion of the implant in region #14.

Fig. 11 After stabilisation of the Schneiderian membrane, the Bio-Gide membrane is raised by the introduction of Bio-Oss granules (Geistlich), blood from the operation area and mixed with autologous bone chips of the patient.

Fig. 12 Another gentle introduction of the augmentation in the Bio-Gide membrane before insertion of the dental implant in region #16.

autologous transplant patients and bone defect of the patient's blood.

The implant survival rate with the use of xenogeneic grafts is statistically equivalent to the use of particulated autogenous bone grafts. Del Fabbro *et al.* conducted studies on various bone replacement materials in 2004. Aghaloo and Moy 2007 found a survival rate of 88% in pure autologous transplants, 92% in mixed grafts with autologous bone, 81% in pure alloplastic grafts, 93.3% in pure allogeneic grafts and 95.6% in pure xenogeneic grafts was found. These figures are encouraging for dentists and indicate a positive long-term prognosis for implant treatment in the distal maxilla. However, in aesthetically challenging zones, an implant insertion without augmentation procedures is almost impossible to achieve, for only connective soft tissue aided by bone or graft material can contribute to aesthetically satisfying results.

Placement of grafts and implants

The graft material should be inserted starting from the areas that are the most difficult to reach and contact with the bone walls must be ensured to improve the healing of bone. If the sinus membrane (Schneiderian membrane) is very thin, it should be protected and stabilised with a collagen membrane. The recesses are first filled anteriorly and posteriorly, and thereafter the area of the medial sinus wall was filled too. The graft should not raise the membrane further and must not be compressed too much, as then vascularisation particularly with biomaterial will be hampered. The implants are then successively inserted into the prepared implant cavities. This achieves compaction of the loose cancellous tissue of the maxillary bone after the actual pilot hole with poor bone quality is achieved by means of bone-condensing instruments. This is also a useful and effective way to improve primary stability. After the insertion of the implants from the lateral side, the graft material is placed on the implants, all intermediate space and cavities are filled and the bone window is covered with a small collagen mem-

brane. The size of the collagen membrane should correspond to the existing bone window. The attachment can take place without the use of pins or absorbable sutures under the mucoperiosteal flap.

New studies have shown that there are no differences between the results with the use of collagen-membranes and those with membranes made of expanded polytetrafluoroethylene (ePTFE, GORE-TEX; Wallace *et al.* 2005). Since collagen-membranes stick, they can be installed without screws or pins and, because of their absorbability, they do not have to be removed in a later procedure.

Suturing and wound care

For the final wound care, the defect is covered passively with the lobes. For this purpose, releasing incisions in the periosteal area are necessary. This method, however, is usually only necessary with simultaneous maxillary bone augmentation (for widening) because pure sinus floor augmentation does not change the ridge contour. The thread thickness can be specified from 4.0 to 6.0 mm with non-absorbable monofilament.

Summary

It is generally in the interest of the patient to weigh the benefits of pure autologous grafts or some combination of autologous bone and the incorporation of synthetic bone materials and/or xenogeneic bone substitute materials. The use of foreign material leads to conservation of the patient's own bone and avoids a second opening at a donor site, which creates an additional wound.

In principle, in treatment planning and advising patients must respect the patient's desire that all surgical procedures proceed as smoothly, efficiently and, ultimately, as successfully as possible. It is through the combination of autologous bone grafts and foreign material, depending on the case and necessary use of membranes, that the long-term success of implant treatments is predictable. Oper-

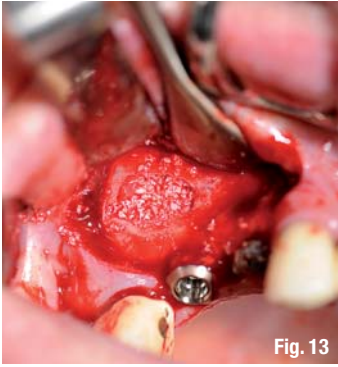

Fig. 13

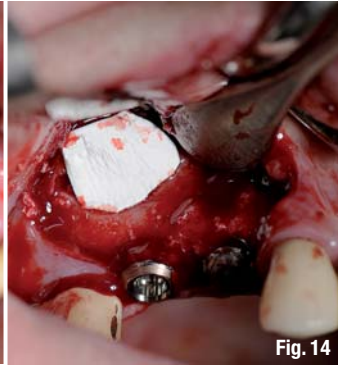

Fig. 14

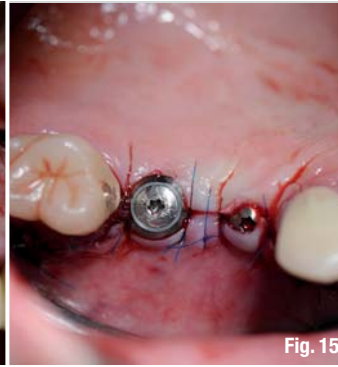


Fig. 15

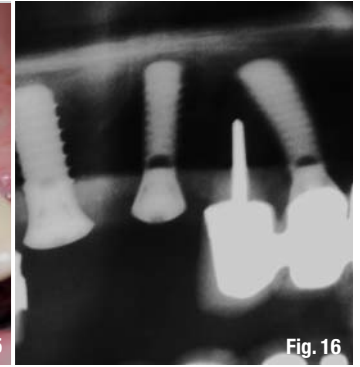


Fig. 16

ators should always be open to learning new methods, but must do so with their responsibility to their patients in mind.

The demands of today's patients are constantly growing and so the management of hard and soft tissues is of crucial importance for dental implantology. The current augmentation procedure provides a well-supported and physiologically shaped gingiva in the adjacent implant shoulder and super-structure area and thus provides an indispensable basis for aesthetic long-term success. Knowledge and mastery of augmentation is essential for ensuring long-term success and makes the

use of endosseous implants possible in the first place.

_contact

implants

Prof (Univ. Shandong) Dr med Frank Liebaug
 Arzbergstraße 30
 98587 Steinbach-Hallenberg, Germany
 Tel.: +49 36847 31788
 frankliebaug@hotmail.com

Fig. 13 After the insertion of the dental implant, loose filling with augmentation of the lateral side takes place.

Fig. 14 Coverage of the facial bone defects with residual Bio-Gide membrane.

Fig. 15 State after wound closure and preparation of trans-mucosal healing of ITI-implants (Straumann Dental Implants).

Fig. 16 X-ray after external sinus lift shows no displacement of the augmentation material in the maxillary sinus.

AD

implants

international magazine of oral implantology



You can also subscribe via www.oemus.com/abo

 **Subscribe now!**

I would like to subscribe to **implants** for € 44 including shipping and VAT for German customers, € 46 including shipping and VAT for customers outside of Germany, unless a written cancellation is sent within 14 days of the receipt of the trial subscription. The subscription will be renewed automatically every year until a written cancellation is sent to OEMUS MEDIA AG, Holbeinstr. 29, 04229 Leipzig, Germany, six weeks prior to the renewal date.

Reply via Fax +49 341 48474-290 to OEMUS MEDIA AG or per E-mail to grasse@oemus-media.de

Last Name, First Name

Company

Street

ZIP/City/Country

E-mail Signature

Notice of revocation: I am able to revoke the subscription within 14 days after my order by sending a written cancellation to OEMUS MEDIA AG, Holbeinstr. 29, 04229 Leipzig, Germany.

IM 2/11



Biggest IDS ever

The upbeat mood at IDS 2011 was especially due to the large number of visitors. Accordingly, the trade fair's halls were very busy and the exhibitors' stands were extremely well visited. Exhibitors confirmed that representatives of all important professions—ranging from dental practices and dental labs to the dental trade, plus the higher education sector—visited their stands. Exhibitors were particularly pleased with the large number of international visitors to the trade fair. This year there was a strong increase in visitors not only from Latin America and South America, Australia, the United States and Canada, but also from Italy, France, the Netherlands, Spain, the United Kingdom, Switzerland, Russia, Ukraine, Turkey, Israel, China and India. IDS was also a huge financial success for many exhibitors. Countless orders were placed, both domestically and internationally, and so numerous companies were able to boast a long list of orders. Of equal if not greater importance to many exhibitors were the opportunities to establish and maintain contacts, generate customer loyalty, win new customers and open up new foreign markets. All of these goals were also reached at the 34th International Dental Show. Last but not least, the exhibitors expressed great satisfaction with the visitors' high decision-making authority. This finding is confirmed by the initial results of an independent visitor survey, as 85 per cent of all trade visitors are involved in purchasing decisions at their company. "We've succeeded in making the International Dental Show even more attractive, both domestically and internationally. The

strong increase in international participants especially shows that IDS is the world's leading dental trade show," says Dr Martin Rickert, Chairman of the Association of German Dental Manufacturers (VDDI). "What's more, participants were able to forge high-quality business contacts, both between industry and trade professionals as well as between the industry, dentists and dental technicians. Thus the trade fair once again signalled better times ahead and generated momentum that will help the dental sector stay on course for a successful business year."

Enormous interest in innovation

The specialist trade and users were especially interested in the innovative new products and technologies on display. According to Dr Martin Rickert (VDDI), the trade fair demonstrated that digital processes and technologies are becoming increasingly popular since they facilitate even more efficient and higher quality treatments. Hence a major focus of IDS 2011 was on products and systems that offer users and patients improvements in preventative care, diagnostics and dental treatment. These include expanded ultrasound systems that enable painless professional preventative care, digital intraoral scanners, improved root canal treatment methods, new dental filling materials, aesthetic dental crowns and bridges that look especially natural, and improved digital X-ray diagnostics that are especially useful in the area of implantology.



35th IDS
12–16 March 2013



Simply Smarter Prosthetic Solutions



15° & 30° Angled Abutments - 85 Euro

Abutment in 5 Collar Heights - 85 Euro



Zirconia Abutment on Anodized Titanium Bases - 95 Euro

Anodized Titanium Bases for Custom Zirconia Abutments - 45 Euro

GPS™ Overdenture Attachment System

- Straight & Angled abutments
- Platform compatible with Locator® attachments
- All-in-One Package incl. Anodizes stainless Steel Housing with 4.5lbs, Retentive Cap & Transfer

Zirconia Abutments on Titanium Bases

- Gold anodized to maintain the natural tooth color the zirconia
- Abutments with contoured margins are provided in 0°, 8° & 15° with 1 & 2mm collar heights

Joining our full line of industry-compatible prosthetics



ScrewPlant®
Internal Hex
with External Bevel - ID Proprietary



RePlant®
Internal Tri-Lobe
Compatible with NobelReplace™



SwishPlant™
Internal Octagon
Compatible with Straumann Tissue Level



Legacy™
Internal Hex
Compatible with Zimmer, BioHorizons, MIS®



Laboratory Abutment Straight Snap-On Straight Contoured 15° Angled Contoured Gold/Plastic Zirconia/Ti Abutment Angled Zirconia/Ti Abutment Plastic Temporary Abutment Ball Attachment GPS™ Attachment Angled GPS™ Attachment Multiple-Unit w/Cap & Transfer Straight Angled

Find the industry-compatible prosthetics that fit your practice.

Implant Direct Sybron sets new standards with high-quality implants with low prices and value added All-in-One™ Packaging for only 115 Euro per implant, including the corresponding prosthetic components. Besides the unique Spectra System, we offer compatible implant systems to Nobel Biocare™, Straumann and Zimmer® Dental. Make a decision today and choose a path of smart solutions and considerably more profit.

Tollfree Infoline: 00800 4030 4030
www.implantdirect.eu
Europe's No.1 Online Provider for Dental Implants



DGZI's 41st International Annual Congress celebrated in autumn in Cologne

Author_ Eva Kretzschmann, Germany

_A few months ago the German Association of Dental Implantology (DGZI) celebrated its 40th Anniversary Congress with great success in Berlin. At the moment, preparations are underway for DGZI's 41st International Annual Congress which is planned to take place in the cathedral city of Cologne from September 30 until October 1.

Over 500 participants, more than 70 speakers, and a highly satisfied expert association account for the success of last years DGZI's 40th International Annual Congress.

At the moment, preparations are being made for this years International Annual Congress which is planned to take place in the Maritim Hotel in Cologne from September 30 until October 1. Our current priority is to gather speakers and topics which will make this DGZI event at least as challenging as last year s congress. According to information given by DGZI President and Congress President Prof Dr Dr Frank Palm, the congress, under the direction of DGZI scientific chairman Dr Roland

Hille, will focus on the topic of "Implantology—Requirements, Possibilities and Expectations". DGZI has invited renowned national and international speakers to participate in the conference with the aim of achieving a global exchange of experiences. The topic of this years traditional panel discussion held on the second day of the congress will be "Digital Implantology—What Should and What Must Be Done?". It will offer an ideal opportunity to analyze critically implantological issues and to profit from the speakers' wealth of experience.

_From theory to practice

Numerous workshops and hands-on courses will offer opportunities for practical application right at the beginning of the congress. The participants will be able to get acquainted with current developments regarding implants, bone substitutes and membranes, as well as advancements in diagnosis, navigation and CAD/CAM technologies. Our previous experience has indicated that there is an increasing demand for information about new



products, materials and technologies, especially in light of this year's IDS (International Dental Show). The exchange of experiences amongst colleagues, often coupled with helpful advice, is highly important. Thanks to numerous exhibitors, participants can come into direct contact with the industry, and thus obtain information on products and applications on the spot. In addition to the program for dentists, a complete program for implantological assistance is also offered. The main topics for the assistance program are tooth decay and periodon-

titis prophylaxis, surgery assistance, communication with patients and hygiene in the dental practice.

Conclusion: On September 30 and October 1 a variety of information regarding implantology will be offered at DGZI's 41st International Annual Congress in Cologne.

Call for papers: Available to download at www.dgzi.de



Great interest in regenerative dentistry at **Osteology** in Cannes



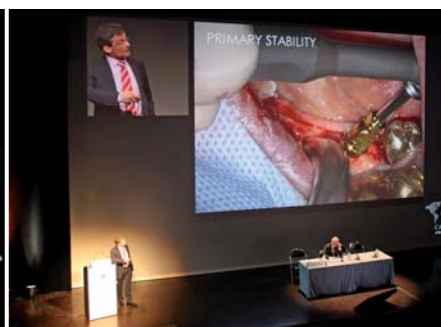With 3,000 people, an impressive number of participants is attending the International Osteology Symposium in Cannes to learn about the latest news and developments in regenerative therapies.

How can practitioners achieve clinical excellence in bone and soft tissue regeneration? How can they handle risks and complications in daily practice? With a total of 85 speakers and moderators, 24 workshops, 145 posters and an interactive clinical forum with SMS voting, the Osteology Symposium presents both the latest scientific results and practical guidelines and tips for daily practice to the 3,000 participants in Cannes. The symposium programme embraces a broad

selection of indications in implantology and periodontology. Internationally acknowledged speakers discuss whether new findings cast doubt on well-established treatment concepts, and which new therapies and products may be reliably used in daily practice in the future.

Clinical excellence in bone regeneration

Bone regeneration is a well-established procedure in implantology and is applied by an increasing number of practitioners. At the same time the expectations of patients are growing, and the pressure for cost reduction is increasing. Osteology in Cannes





gives answers to questions as to which of the current clinical concepts are suitable for daily practice and make it possible to achieve clinical excellence in bone regeneration.

Key topics at the symposium are surgical techniques in soft and hard tissue regeneration, the use of biomaterials optimizing aesthetic outcomes and evidence based treatment concepts to identify risk factors to avoid complications. Other important topics are peri-implantitis, the handling of complex cases, state-of-the-art ridge preservation and sinus grafting procedures as well as the presentation of outstanding Osteology granted projects in the Osteology Research Session.

Predictability in soft tissue regeneration

Soft tissue management has become a key issue in regenerative dentistry over past years. Surgical techniques such as specific flap preparations, microsurgery or the use of soft tissue grafts are currently used to optimise aesthetic results. But new developments have also delivered promising results and gained a great deal of interest.

At Osteology in Cannes, key topics in implantology are the handling of aesthetic challenges, complications and inadequate tissue contours, the potential and limits of soft tissue grafts, as well as the use of biomaterials to augment keratinised mucosa. Important periodontal topics include measures to enhance aesthetic outcomes, root coverage procedures, identification of risk factors in recession treatment as well as the use of new soft tissue substitutes.

Linking Science with Practice

Evidence based science and practice-oriented education in regenerative therapies are the primary tasks of the Osteology Foundation. With its 3,000 participants in Cannes, the Foundation has increased the number of participants by about 20% compared to the last international Symposium in Monaco in 2007. Since the start of the Osteology congress series in 2003, a total of 15,000 people have visited national and international Osteology symposia. These numbers reflect the growing interest in regenerative dentistry, but also the success of the symposium concept: Osteology symposia offer a high level of continuing education combined with exceptional congress venues.



| | |
|---|----------|
| _contact | implants |
| Osteology Foundation | |
| Landenbergstrasse 35 6002 Lucerne, Switzerland | |
| info@osteology.org www.osteology-cannes.org | |

AD

laser

international magazine of laser dentistry



One issue free of charge!

Subscribe now!

You can also subscribe via www.oemus.com/abo

I hereby agree to receive a free trial subscription of **laser international magazine of laser dentistry** (4 issues per year). I would like to subscribe to **laser** for € 44 including shipping and VAT for German customers, € 46 including shipping and VAT for customers outside Germany, unless a written cancellation is sent within 14 days of the receipt of the trial subscription. The subscription will be renewed automatically every year until a written cancellation is sent to OEMUS MEDIA AG, Holbeinstr. 29, 04229 Leipzig, Germany, six weeks prior to the renewal date.

Reply per Fax +49 341 48474-290 to OEMUS MEDIA AG or per E-mail to grasse@oemus-media.de

Last Name, First Name

Street

ZIP/City/ Country

E-mail

Notice of revocation: I am able to revoke the subscription within 14 days after my order by sending a written cancellation to OEMUS MEDIA AG, Holbeinstr. 29, 04229 Leipzig, Germany.

Signature OEMUS MEDIA AG Holbeinstr. 29, 04229 Leipzig, Germany
 Tel.: +49 341 48474-0, Fax: +49 341 48474-290
 IM 2/11 E-Mail: grasse@oemus-media.de

Manufacturer News

CAMLOG

Twice as good

User-friendly products, first-class services, partner-oriented customer relationships, a fair price-benefit ratio, and the convincing long-term results of the CAMLOG® Implant System have made CAMLOG one of the leading providers in the field of implant dentistry. For implantologist teams preferring conical implant-abutment connections, CAMLOG is now expanding its range of products and hosting the market launch* of its CONELOG® Implant System at the IDS 2011.

One unique feature is that CAMLOG® implants and CONELOG® implants have the same outer geometry (SCREW-LINE implants) and can be inserted using one and the same surgery set. This offers a high degree of flexibility in surgical practice and makes handling of the instruments simpler. The CAMLOG®/CONELOG® SCREW-LINE surgery set contains new drills without internal cooling, in a design with four cutting edges offering an outstanding cutting performance.

CONELOG® SCREW-LINE implants have a self-locking internal taper (7.5°) and the popular CAMLOG indexing with three grooves in the implant



and the matching cams on the abutment. This makes for user-friendly handling and a high accuracy of fit for the system parts. In the CONELOG® Implant System, the taper is used only with the abutments thus height displacement in impression-taking is excluded. A clever release tool makes loosening the abutment an easy task.

CONELOG® SCREW-LINE implants are available with diameters of 3.3 mm, 3.8 mm, 4.3 mm, and

5.0 mm. A 7 mm short implant is available for diameters 3.8 mm, 4.3 mm, and 5.0 mm. The implant lengths 9 mm, 11 mm, 13 mm, and 16 mm are available for all implant diameters. CAMLOG® SCREW-LINE implants and CONELOG® SCREW-LINE implants differ in terms of the geometries of their connections, but there is no difference in price between the two types of implants. CAMLOG sees this as a question of philosophy: the user's personal experience determines the preference for a parallel-wall or conical connection design. The CAMLOG® Implant System will continue to undergo development in the future, too.

The CONELOG® Implant System allows proponents of conical implant-abutment connections to enjoy the same first-class services from CAMLOG.

**The CONELOG® Implant System has been launched in Germany at the IDS. Launches in other countries will follow. Please, contact your local CAMLOG distributor.*

CAMLOG Biotechnologies AG

Margarethenstrasse 38
4053 Basel, Switzerland

info@camlog.com
www.camlog.com

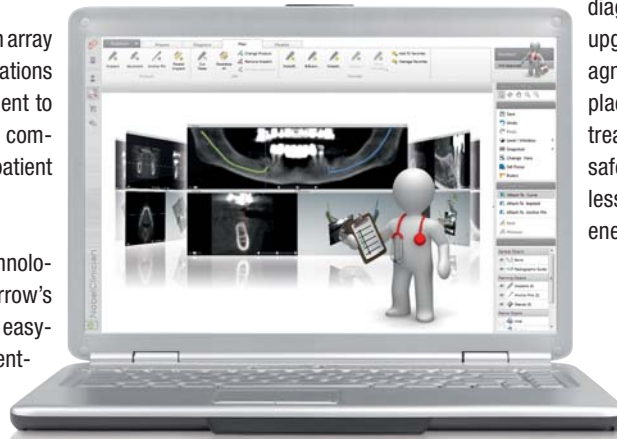Nobel Biocare

Digital Dentistry— Feel the pulse of tomorrow's dentistry, today

At the 34th IDS, Nobel Biocare introduced an array of products, technology and service innovations that underscore the company's commitment to offering innovative solutions to the dental community, with a focus on clinical needs and patient requirements.

Nobel Biocare offers the latest digital technologies to bring dental professionals tomorrow's dentistry, today—through innovative and easy-to-use solutions that help to address patient-specific needs and support effective patient treatment. Nobel Biocare's Digital Dentistry includes digital diagnostics

and treatment planning, guided implant surgery and CAD/CAM dental prosthetics. Together, they enhance clinicians' skills, improve patient care and deliver long-lasting results. As a pioneer in digital dentistry, Nobel Biocare supports dental professionals with a more efficient, predictable,



Treatment planning with the new NobelClinician software.

profitable and flexible solution. The treatment concept NobelGuide with the software NobelClinician offers oral surgeons superior treatment safety and predictability, full flexibility in planning cases, as well as optimized biomechanics, functionality and esthetic outcomes thanks to enhanced treatment diagnostics, planning and guided surgery. The upgraded NobelGuide concept utilizes 3-D diagnostics, 3-D planning and guided implant placement to ensure a predictable, positive treatment outcome. NobelGuide facilitates safe, minimally invasive surgery that results in less patient pain, reduced swelling and shortened healing times.

Nobel Biocare USA, LLC

22715 Savi Ranch Parkway,
Yorba Linda, CA 92887, USA

info.usa@nobelbiocare.com
www.nobelbiocare.com

Straumann

Dental Wings, 3M ESPE and Straumann to establish open standard software

Dental Wings, 3M ESPE and Straumann are joining forces to create an open standard software platform for use across a range of dental applications.

Digital technologies are becoming increasingly widespread in dentistry and cover a broad spectrum of applications—from general practice-management to treatment planning, imaging, guided surgery, digital impression-taking, right through to computer-aided prosthetic design and manufacture. The need for standardization is acute as the number of different systems and software platforms has risen considerably. Creating a standard will reduce the confusion caused by incompatible systems and will drive growth in digital den-



Joining forces: Larry Lair, President & General Manager of 3M ESPE (left); Naoum Araj, President of Dental Wings (center); Beat Spalinger, President & CEO of Straumann (right).

tistry. The initiative is expected to offer enhanced flexibility, simplicity, and convenience for users, while saving time, costs and investment risk.

3M ESPE and Straumann have agreed to adopt Dental Wings' software platform DWOS as the core operating software in their CAD/CAM solutions.

Dental Wings has established itself as a leading dental software developer. 3M ESPE and Straumann add strong expertise and leadership in their fields.

Both 3M ESPE and Straumann will continue to build their own specific applications on top of the core software, adding value for their customers. Other companies are encouraged to join the collaboration.

Institut Straumann AG
Peter Merian-Weg 12
4052 Basel, Switzerland

info@straumann.com
www.straumann.com



BEGO Implant Systems

The new surgical tray—Focused on the essentials

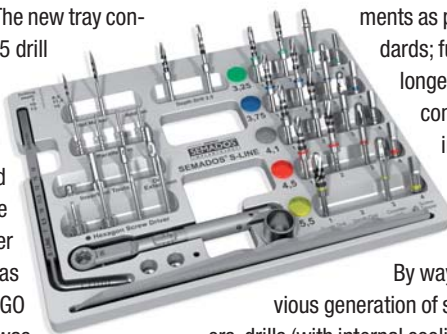
BEGO Implant Systems is delighted to be able to present the new BEGO S-Line TrayPlus with the appropriately redesigned drills. The new tray contains everything except the 5.5 drill module, which can be ordered separately as required.

The long-awaited optimised surgical tray is not only more clearly organised but also easier to use. The size of the tray has been adapted to match the BEGO Mini/OsseoPlus tray. This was achieved in part by separating the drill stops. In addition to the space saved, we have also made it easier to remove the tray from its container, thus facilitating greater ease of use in a practice or clinic setting.

The drills have undergone a complete redesign—the cutting geometry has been optimised for noticeably smoother and safer working when preparing the implant bed. Moreover, extremely clear depth markings in the form of block laser marks and addi-

tional grooves help to accurately gauge drilling depth. The paralleling posts and depth gauge have been modified in line with the new drill geometry – for optimum implant bed preparation.

We have removed the internal cooling feature from the new drills for hygiene reasons. This was the ideal way to meet hygiene chain requirements as prescribed by QA standards; furthermore, there is no longer any need for time-consuming cleaning of the internal cooling channel using cleaning reamers.



By way of transition, the previous generation of surgical trays, containers, drills (with internal cooling) and other BEGO S-Line instruments will still be available for purchase until the end of 2011.

BEGO Implant Systems GmbH & Co. KG

Technologiepark Universität
Wilhelm-Herbst-Str. 1
28359 Bremen, Germany

info@bego-implantology.com
www.bego-implantology.com

AD



Since our beginnings, we have always been focused on quality and innovation toward the battle against cross - contamination and infections.

In the last 20 years, we have ensured safety and protection to you and your patients, with advanced and reliable products. Tools that represent the ideal solution for who is operating in dentistry, implantology/oral surgery and general surgery.

With Omnia sure to be safe.



OMNIA S.p.A.
Via F. Delnevo, 190 - 43036 Fidenza (PR) Italy
Tel. +39 0524 527453 - Fax +39 0524 525230
VAT: IT 0171 1860344 - R.E.A. PR 173685
Company capital € 200.000,00
www.omniaspa.eu

Schütz Dental

IMPLA™—a professional implant system does not have to be complicated!

The precursor of today's IMPLA™ implants can pride itself with a documented history dating back to 1958.

Our IMPLA™ research and development team is composed of in-house engineers as well as external professional users such as implantologists, oral surgeons and dentists. Over the years, the goal of this team has always been to create an implant system that leaves nothing to be desired for beginners as well as for advanced implantologists. The system features all necessary tools and accessories, from a well-appointed surgery box all the way to platform switching, to make implantation as easy and as safe as possible for all parties concerned.

The IMPLA™ family, produced completely in Germany with highest quality standards, has grown significantly over the years. One traditional part of the family is the classic IMPLA™ Dual Surface implant, a conical screw implant with a passive thread and a polished implant shoulder. A newer member of the family is IMPLA™ Micro Retention with its special primary stability. This implant is especially suited for very soft bone. A micro thread at the implant neck gives this implant the little bit of extra stability necessary for implantation in combination with a sinus lift.

IMPLA™ Cylindrical is the all-rounder and suitable for nearly every indication. Its self-cutting thread offers the necessary flexibility required by beginners as well as advanced users. Integrated platform switching reduces the marginal bone loss to a minimum. All IMPLA™ implants have a high-purity surface which is obtained with a special surface treatment procedure and a specific acid formulation. This method creates an ideal surface roughness superior to that of many other implants available in the market. Furthermore, IMPLA™ implants



are manufactured with a highly precise internal hexagon which ensures an accurate fit between implant and abutment.

Brand new and available since the beginning of 2011 is our latest development, the new onestage Mini Implant, supplied with a conical or a ball-abutment.

Just imagine that you would not even have to decide between those many options beforehand! The IMPLA™ surgical box contains all tools necessary to insert each of these different implants, leaving you with the flexibility to decide which implant you prefer as each case presents itself. In addition, with the computer navigation system IMPLA™ 3D for precise planning and template-guided implantation, IMPLA™ offers you a great tool for virtual planning using a three-dimensional bone model.

Join one of our many international courses and trainings. From placing your first implant on to more complicated methods such as sinus lift and bone spreading —we are certain that we will find the right course for you!

Schütz Dental GmbH

Dieselstr. 5–6
61191 Rosbach, Germany

export@schuetz-dental.de
www.schuetz-dental.com

Omnia

An essential equipment for your surgical/piezoelectric unit

While creating the implant site, a proper irrigation is essential for the necessary bone integration of the implant and consequently, for a successful operation.

For this reason, it is very important that the surgical bur is properly cooled. An adequate, but not excessive flow of coolant liquid can be guaranteed only by an irrigation system which has been developed for a specific drilling unit. OMNIA provides a wide range of Hose set which fit to most surgical and piezoelectric units in the market. All our Hose sets are provided with perforator, roller to adjust the flow, connectors and pump section in medical grade silicon. Omnia mechanical irrigation systems offer following options:

- a) single internal irrigation
- b) single external irrigation
- c) double internal and external irrigation thanks to the Y-joints, which are included within the hose set.

Furthermore all our Hose set are provided with following components:

- d) the above mentioned Y-joints for the double internal and external irrigation



- e) the S shaped clips for the connection of the irrigation hose with the cord of the micro motor
- f) The cord holder hooks for the connection of the irrigation hose with the cord of the physiodispenser.

OMNIA S.p.A.

Via F. Delnevo 190
43036 Fidenza (PR), Italy

info@omniaspa.eu
www.omniaspa.eu

TRI Dental Implants

TRI Dental Implants launches novel TRI® Performance Concept

During the IDS Cologne 2011 and Osteology Cannes 2011, the Swiss implant manufacturer TRI® Dental Implants presented its innovative TRI® Performance Concept that has been developed in co-operation with leading clinicians including Dr. Marius Steigmann and previously has been tested in a test markets with 5000 implants.

Das TRI® Performance Concept consists of three essential success factors:

_TRI®-Friction: The frictional implant-abutment connection guarantees maximum abutment stability and eliminates the risk of a microgap in the platform switching concept.

_TRI®-BoneAdapt: TRI's implant body step-design has been developed to facilitate the best performing bone adaptation in the respective bone areas, respecting the sensitive corticalis as well as guaranteeing bone compression in the spongiosa region.

_TRI®-Grip: The apical part of this implant allows for a maximum of initial stability as well as guidance for all indications, but specifically immediate placement.

The TRI® Performance Concept has been integrated in the TRI®-Vent Implant line (compatibility to TaperedScrew-Vent/Zimmer Dental) and the TRI®-Log Implant line (compatibility to K-Series of Cam-



log). Prosthetically, all components have been developed to respect a continuous soft tissue management and feature one singular prosthetic platform for better usage of platform switching with wider diameters. All implants are offered for the introductory

price, but can also be purchased for the package price including a free-of-choice titanium abutment. For further information and introductory offers, please offer the toll free hotline 00800 331 333 13 or visit our website on www.tri-implants.com

TRI Dental Implants Int. AG

Zugerstrasse 77
6340 Baar, Switzerland

info@tri-implants.com
www.tri-implants.com

Dentaurum Implants

tioLogic® Zenotec abutments CAD/CAM system

The prosthetic product portfolio of the tioLogic® implant system has been extended to include an additional abutment series for the CAD/CAM fabrication technique. These new abutments open up new options for dental laboratories to fabricate high-quality aesthetic restorations, which are also highly cost-effective. The tio-



Logic® titanium bases from Dentaurum Implants GmbH provide the optimal base for the Zenotec CAD/CAM system from Wieland Dental Technik to ensure accurate, quick fabrication of patient-specific, aesthetic implant restorations. The tioLogic®

Zenotec titanium bases and matching dummy abutments are available from Wieland Dental Technik in all 3 prosthetic abutment series (S-M-L) of the tioLogic® implant system.

The collaboration between Dentaurum Implants and Wieland Dental Technik enables users to take

advantage of the quality and know-how "Made in Germany" from experts with many years of experience.

This guarantees a high degree of precision as well as tested and documented safety by independent institutes and facilities, as is customary for the system solutions of the two companies.

Dentaurum Implants GmbH


Turnstr. 31
75228 Ispringen, Germany

info@dentaurum-implants.de
www.dentaurum-implants.de

Implant Direct

GPS™ Abutment - new in the product line of Implant Direct Sybron

Implant Direct Sybron Europe presents the newest addition to its product portfolio. The GoDirect Prosthetic System (GPS™) is a complete overdenture attachment system with Straight & Angled Abutments that provide a retentive platform compatible with LOCATOR® attachments. The abutments are available in a wide range of options, depending on the implant line. They offer five collar heights for four different connections: industry-standard internal hex, tri-lobe, octagon and their proprietary internal hex with an external bevel. Accommodating up to 90° relative



divergence, GPS allows placement of multiple inclined implants which is especially useful in the maxilla to avoid the sinus. Furthermore, GPS features replacement male caps with a full range of different retention forces from 1.0 to 4.5lbs. The All-in-One Package includes GPS™ abutment, transfer, comfort cap, metal housing with nylon liner, replacement male cap, black processing male and silicon block-out spacer.

Orders can be placed over the Tollfree Infoline 00800 4030 4030 or the online shop.

Implant Direct Sybron Europe

Hardturmstrasse 161
8005 Zürich, Switzerland

info@implantdirect.eu
www.implantdirect.eu

implants
international magazine of oral implantology



Publisher

Torsten R. Oemus
oemus@oemus-media.de

CEO

Ingolf Döbbbecke
doebbecke@oemus-media.de

Members of the Board

Jürgen Isbaner
isbaner@oemus-media.de

Lutz V. Hiller

hiller@oemus-media.de

Chief Editorial Manager

Dr Torsten Hartmann (V. i. S. d. P.)
hartmann@dentalnet.de

Editorial Council

Prof Dr Dr Frank Palm
frank.palm@klinikum-konstanz.de

Dr Roland Hille

dr-hille@t-online.de

Prof Dr Dr Kurt Vinzenz

kurt.vinzenz@aon.at

Dr Torsten Hartmann

hartmann@dentalnet.de

Dr Suheil Boutros

SMBoutros@aol.com

Editorial Office

Kristin Urban

k.urban@oemus-media.de

Eva Kretschmann

e.kretschmann@oemus-media.de

Executive Producer

Gernot Meyer
meyer@oemus-media.de

Designer

Sarah Fuhrmann
s.fuhrmann@oemus-media.de

Customer Service

Marius Mezger
m.mezger@oemus-media.de

Published by

Oemus Media AG
Holbeinstraße 29
04229 Leipzig, Germany
Tel.: +49 341 48474-0
Fax: +49 341 48474-290
kontakt@oemus-media.de

Printed by

Messedruck Leipzig GmbH
An der Hebemärchte 6
04316 Leipzig, Germany

implants

international magazine of oral implantology

is published in cooperation with the German Association of Dental Implantology (DGZI).

DGZI President

Prof Dr Dr Frank Palm
DGZI Central Office
Feldstraße 80, 40479 Düsseldorf, Germany
Tel.: +49 211 16970-77
Fax: +49 211 16970-66
office@dgzi-info.de

www.dgzi.de
www.oemus.com

Copyright Regulations

_implants international magazine of oral implantology is published by Oemus Media AG and will appear in 2011 with one issue every quarter. The magazine and all articles and illustrations therein are protected by copyright. Any utilization without the prior consent of editor and publisher is inadmissible and liable to prosecution. This applies in particular to duplicate copies, translations, microfilms, and storage and processing in electronic systems.

Reproductions, including extracts, may only be made with the permission of the publisher. Given no statement to the contrary, any submissions to the editorial department are understood to be in agreement with a full or partial publishing of said submission. The editorial department reserves the right to check all submitted articles for formal errors and factual authority, and to make amendments if necessary. No responsibility shall be taken for unsolicited books and manuscripts. Articles bearing symbols other than that of the editorial department, or which are distinguished by the name of the author, represent the opinion of the afore-mentioned, and do not have to comply with the views of Oemus Media AG. Responsibility for such articles shall be borne by the author. Responsibility for advertisements and other specially labeled items shall not be borne by the editorial department. Likewise, no responsibility shall be assumed for information published about associations, companies and commercial markets. All cases of consequential liability arising from inaccurate or faulty representation are excluded. General terms and conditions apply, legal venue is Leipzig, Germany.

41ST

INTERNATIONAL ANNUAL CONGRESS OF THE DGZI

Implantology – Claims, possibilities and expectations

Chairman: Prof. Dr. Dr. Frank Palm
Scientific Administration: Dr. Roland Hille



September 30–Oktober 1, 2011
Cologne, Germany

Speakers (among others)

Prof. Dr. Dr. Frank Palm/DE
Prof. Dr. Norbert Gutknecht/DE
Prof. Dr. Bernd Wöstmann/DE
Prof. Dr. Peter Rammelsberger/DE
Prof. Dr. Dieter Wember-Matthes/DE
Prof. Dr. Mauro Marincola/IT
Dr. Michael Sachs/DE
Dr. Hans-Joachim Nickenig/DE
Dr. Wolfgang Dinkelacker/DE
Dr. Armin Nedjat/DE
Drs. Guido-Jan Kisters/DE
Enrico Steger/IT

Gold Sponsor:



Silver Sponsor:



Bronze Sponsor:



FAX +49-3 41/4 84 74-3 90

Please send me further information on the
41ST INTERNATIONAL ANNUAL CONGRESS OF THE DGZI
September 30–October 1, 2011, Cologne, Germany

Call for papers for download on www.dgzi.de

Office Stamp

IM 2/11

Official care provider
to the German Olympic teams
since 2002

GO FOR GOLD.



Bionic Engineering Design transfer of
optimal living nature solutions
to technical products

BEGO Semados®
Mini-Implant

BEGO Semados®
S-Implant

BEGO Semados®
RI-Implant

BIONIC ENGINEERING DESIGNED IMPLANTS

BEGO Semados® patented Implants embody:

- Indication-optimised contour design
- Function-optimised implant-abutment-connection
- High purity and ultra-homogenous-surface
- Polished rim for an inflammation-free gingiva-attachment
- 100 % German design – 100 % German manufacturing
- Value for money

Are You Interested?

info@bego-implantology.com

www.adwork.de

BEGO 
Partners in Progress

www.bego-implantology.com

ADMED
com

• Base it

بیس و لاینر (دایکال نوری)



- حاوی کلیسم هیدروکساید آپاتیت (دارای خاصیت رادیواپسیتی)
- شیرینکیچ پائین ، چسبندگی بالا و استحکام در برابر پوسیدگی
- دارای مقاومت بیشتر از گلاس آینومر
- ایجاد بهترین عایق • ۴ سرنگ ۲ گرمی
- قابلیت ایجاد دنتین ثانویه با آزاد کردن یون های کلیسم هیدروکسی و فسفات

You're
the Artist

SPIDENT
MADE IN KOREA

• Es Flow

نانو کامپوزیت فلو



- مناسب برای ترمیم حفره های کلاس ۱ تا ۳ و کلاس عمیقی
- قابل استفاده در ارتودنسی
- دارای مقاومت و پولیش پذیری بالا
- با خاصیت افت پلیمریزاسیون اندک و ضریب ارتجاعی مشابه عاج دندان
- فلو پذیری مناسب
- ۲ سرنگ ۲ گرمی

Web: www.befrest.com

Email: info@azadmed.com

Tel: +98 21 88 98 80 63 - 6 Fax: +98 21 88 98 75 72

تهران، خیابان فاطمی، خیابان کاج جنوبی، ساختمان آوا، شماره ۳۴
Add: Ava Building, No 34, Kaj St, Fatemi Ave, tehran, Iran