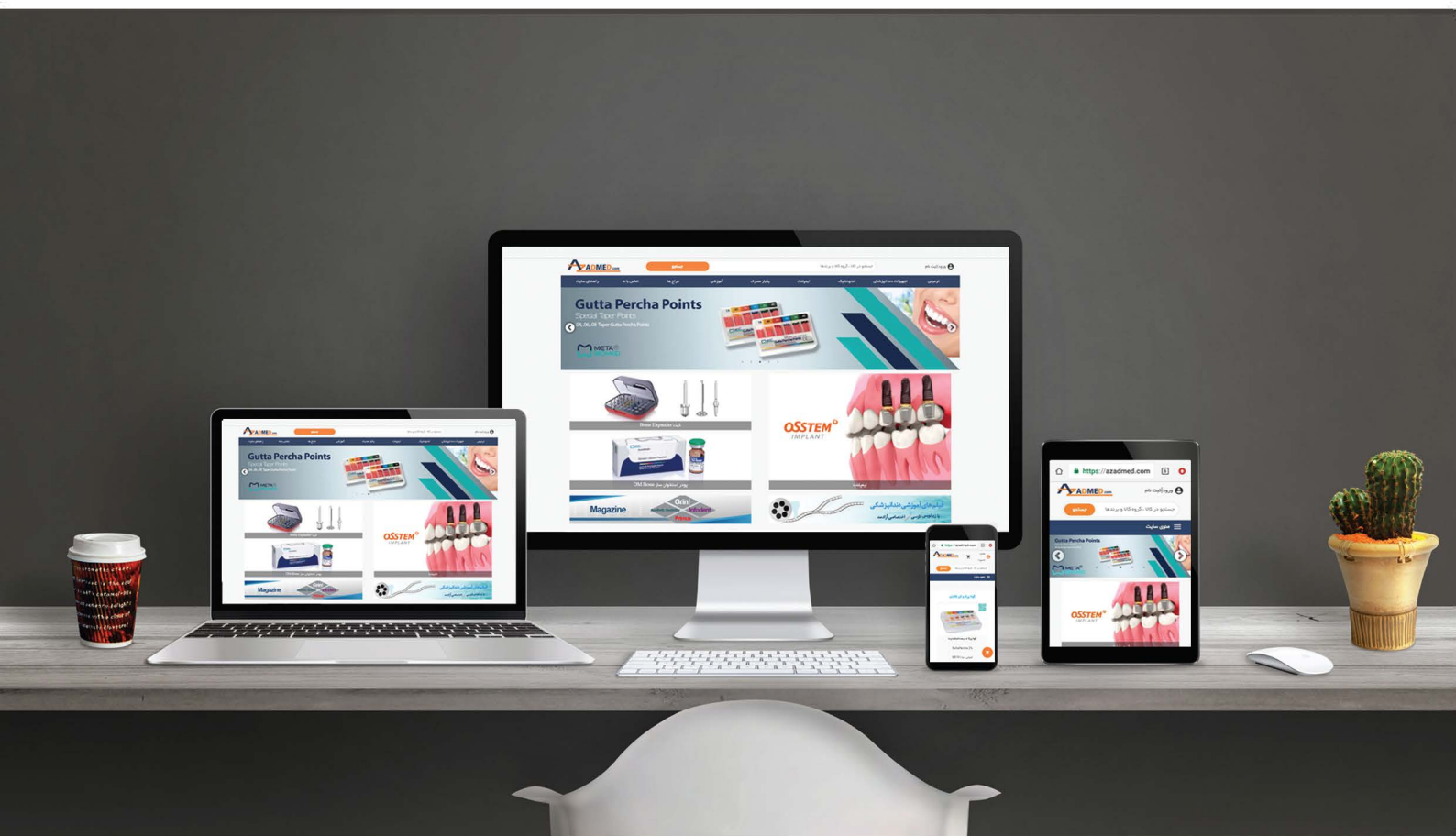




AZADMED.com



www.azadmed.com



 [azaadtejaratpars](https://www.instagram.com/azaadtejaratpars)

 [@azadmed2](https://www.telegram.com/@azadmed2)

 88 98 80 63 - 6

implants

international magazine of oral implantology

2²⁰¹³



| **Research**

Ridge augmentation for an atrophied posterior mandible

| **Overview**

Advantages of 3-D planning for implants

| **Case report**

Implant-supported rehabilitation after radiation therapy

0277173

The Original leads
to the top.

2012

1996

Long-term
results of
12-14 years¹

Geistlich Bio-Gide® –
The Original

¹ Jung RE et al., Clin. Oral Implants Res. 2012; Jun 15 (Epub ahead of print)



Practice-oriented implantology



Dr Rolf Vollmer

_IDS 2013 has both met and exceeded any expectations implantologists could foster towards the world's leading international dental exhibition. With more than 15 million implants already inserted in Germany alone and over 800,000 implantations every year, implantology is a regular focal point at IDS and many implantologists are among the visitors.

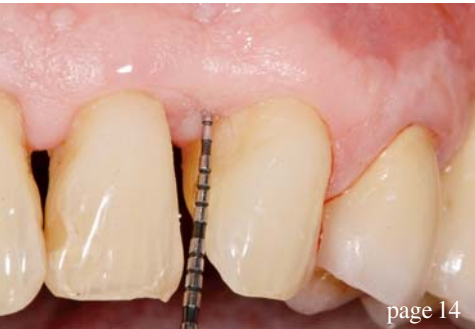As the oldest European society for implantology, DGZI (German Society of Oral Implantology) took its responsibility as an internationally active organisation for dental implantologists seriously and was present with its own booth. Specialists from around the world were welcome to learn more about the DGZI training programs and DGZI membership. The DGZI booth was also a meeting point for regular members both nationally and internationally. The DGZI executive board, among them DGZI President Prof. Dr Dr Frank Palm, Dr Roland Hille and Dr Rainer Valentin, were available for any requests throughout IDS, providing aspiring and long-term members, co-operation partners as well as the media with information on future events and activities of DGZI.

One of the central topics was of course the 43rd DGZI International Congress from 3 to 5 October 2013 in Berlin. "Practice-Oriented Implantology" will be this year's headline of the traditional DGZI meeting led by Congress President Prof. Dr Dr Frank Palm and Scientific Director Dr Roland Hille. The DGZI International Congress has established itself as a meeting point for novice as well as highly experienced clinicians, presenting the latest scientific insights and evidence-based clinical observations on the current developments in this special field.

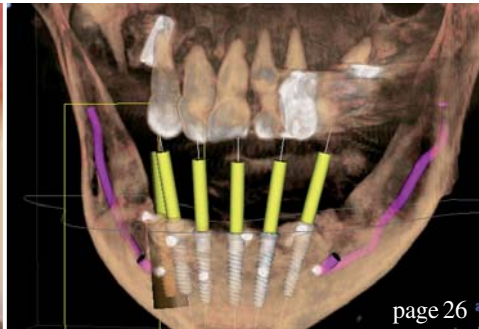
With this in mind, the DGZI executive board is happy to have promoted implantology successfully at IDS and strives to reflect DGZI's activities and international orientation again in this issue of *implants—international magazine of oral implantology*. Therefore, we hope you will enjoy reading the specialist articles on the following pages and will be glad to welcome specialists in implantology again in Berlin this fall!

Yours,

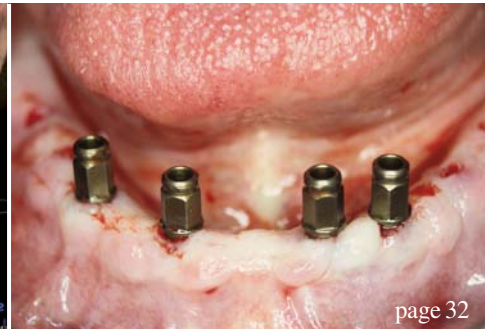Dr Rolf Vollmer



page 14



page 26



page 32

| editorial

- 03 **Practice-oriented implantology**
| Dr Rolf Vollmer

| research

- 06 **Ridge augmentation for an atrophied posterior mandible—Part II**
| Dr Omar Soliman *et al.*

- 14 **Periodontal tissue repair in the aesthetic zone**
| Giulio Rasperini *et al.*

| overview

- 18 **Bisphosphonate therapy and osteonecrosis of the jaw**
| Johannes D. Bähr *et al.*
- 26 **Advantages of 3-D planning for implants**
| Dr A. Grandoch *et al.*

| case report

- 32 **Implant-supported rehabilitation after radiation therapy**
| Dr Umut Baysal *et al.*

| industry report

- 36 **The finesse of the pink and the power of IPS e.max**
| Rafael Santrich *et al.*

| news

- 42 **Manufacturer News**
- 49 **News**

| meetings

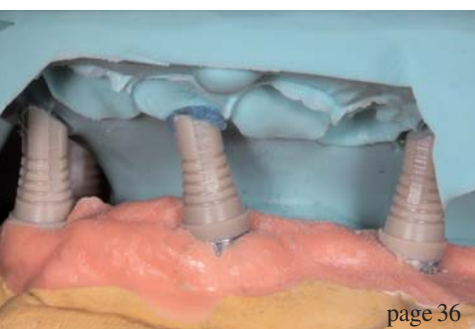- 45 **IDS 2013 sets new records**
| Koelnmesse GmbH
- 46 **IDS Statements**
- 48 **Osteology celebrates its 10th anniversary!**

| about the publisher

- 50 | imprint



Cover image courtesy of Degradable Solutions AG, www.easy-graft.com



page 36



page 45



page 46

Legacy™ System



100% Compatible with Zimmer® Dental



Reality Check
Zimmer Customers



Legacy™3 Implant

All-in-One Packaging includes implant, abutment, transfer, cover screw & healing collar €145

Legacy™ Implant System Advantages:

Industry-Compatible Internal Hex

Prosthetic compatibility with Zimmer Dental Screw-Vent®, BioHorizons® & MIS implants

Surgical Compatibility with Tapered Screw-Vent®

No need to change surgical protocol or tools

Three Implant Designs & Packaging Options

Allows for selection based on price, packaging or thread design

Legacy1: €115 includes cover screw, healing collar & plastic carrier

Legacy2: €130 includes cover screw, healing collar & temporary abutment/transfer

Legacy3: €145 includes cover screw, healing collar & preparable abutment/transfer

Micro-Threads

Reduce crestal stress for improved initial stability

Widest Range of Dimensional Options

The entire Legacy system includes seven implant diameters

(3.2, 3.7, 4.2, 4.7, 5.2, 5.7, 7.0mm) & six implant lengths (6, 8, 10, 11.5, 13, 16mm)



Laboratory Abutment	Straight Snap-On	Straight Contoured	15° Angled Contoured	Gold/Plastic	Zirconia/Ti Abutment	Plastic Temporary Abutment	Ball Attachment	GPS™ Attachment	Angled GPS™ Attachment	Multiple-Unit w/Cap & Transfer Straight	Multiple-Unit w/Cap & Transfer Angled
€60	€75	€75	€75	€90	€90	€30	€68	€90	€90	€75	€90

Legacy™1

Standard "V" Threads
Matches Screw-Vent®

Legacy™2

Spiral Threads
for Increased Stability

Legacy™3

Buttress Threads
for Increased Surface



Ridge augmentation for an atrophied posterior mandible—Part II

NanoBone block **versus** allograft bone block

Authors Dr Omar Soliman, Prof. Dr Mohamed Nassar, Ass. Prof. Dr Mahmoud Shakal & Ass. Prof. Dr Eman Mohy El-din Megahed, Egypt

_Introduction

The aim of the present study was to compare the clinical outcome and radiographic bone changes in augmented ridges utilising a synthetic NanoBone block versus an allograft bone block, and to investigate histologically the success of a synthetic NanoBone block versus an allograft bone block for ridge augmentation.

In the previous issue of implants: international magazine of oral implantology, the authors gave a detailed introduction to their topic and explained the materials

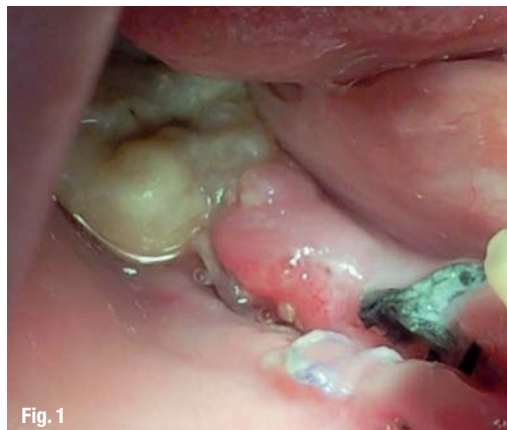

Fig. 1

- Fig. 1_Incision line opening in group A.
- Fig. 2_Partial graft exposure in group A.
- Fig. 3_Screw exposure.
- Fig. 4_Screw loss in group A.
- Fig. 5_Complete graft exposure in group A.
- Fig. 6_Inflammation in group A.
- Fig. 7_Inflammation in group A.

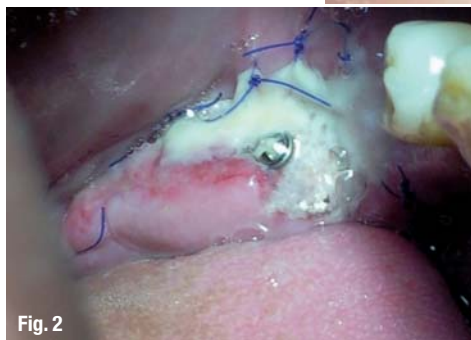

Fig. 2

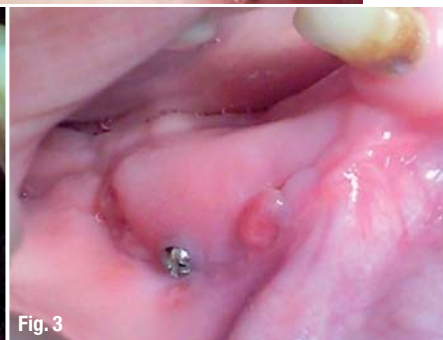

Fig. 3

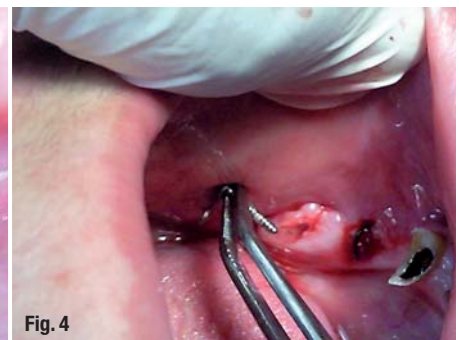

Fig. 4

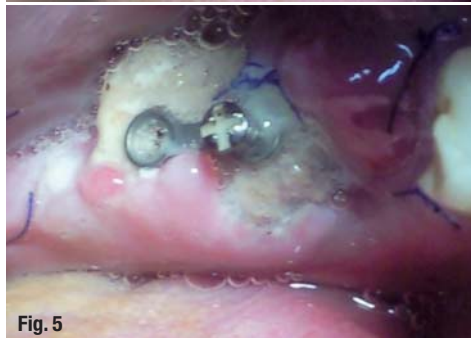

Fig. 5

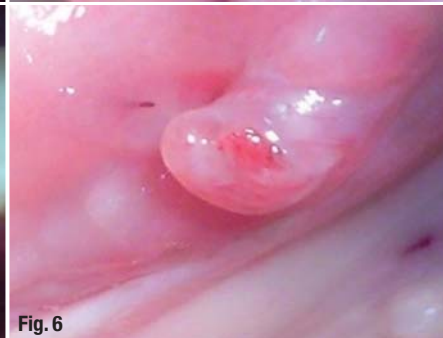

Fig. 6

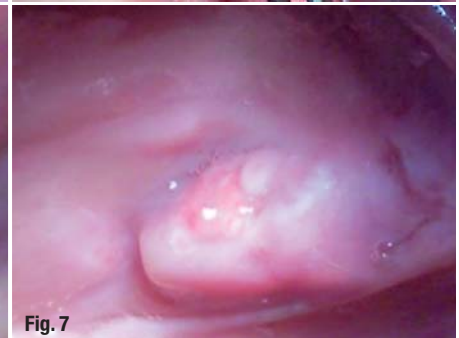
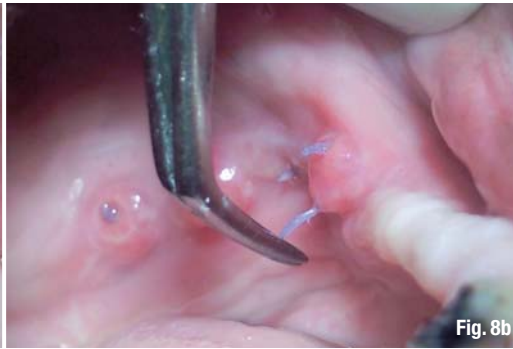
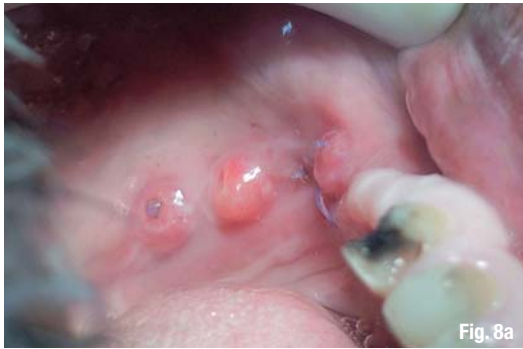Fig. 7



Figs. 8a & b_Inflammation in group B.

and methods used in their study. In this issue, their report is completed by the results of their investigations and an extensive discussion.

Results

Clinical results and complications

- Group A: During intra-operative procedures, NanoBone augmentation was associated with fracture of the NanoBone block during augmentation in one case because it was fragile and fractured easily. In the post-operative period, soft-tissue complications such as the incision line opening (one case, Fig. 1), a small perforation of the mucosa over the grafted bone (two cases, Fig. 7), and graft infection (one case, Fig. 6) occurred. In addition to partial graft exposure (Fig. 2), screw exposure (Fig. 3) and screw loss (Fig. 4), one block graft was completely exposed (30 days after surgery) and lost (Fig. 5). Treatment was initiated as soon as possible. Necrotic soft tissue was removed, and the NanoBone block was leveled with the soft tissue using a high-speed bur. The area was immediately and thoroughly irrigated with chlorhexidine. Patients were prescribed an additional week of oral antibiotics and instructed to apply chlorhexidine gel over the affected area twice a day, as well as to refrain from chewing on the grafted site until mucosal healing was complete.

- Group B: No intra-operative complications were present during the allograft augmentation. In addition, no post-operative complications were present after the ridge augmentation or at the time of the implant surgery, except for one case of infection (Figs. 8a & b).

- Both groups: The regenerated ridges healed uneventfully and no evidence of serious adverse local reactions, that is, foreign-body reaction, pain, dysaesthesia, inflammation was observed in any patient throughout the study.

Bone-gain clinical measurements

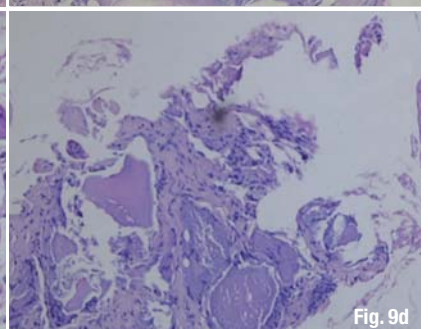
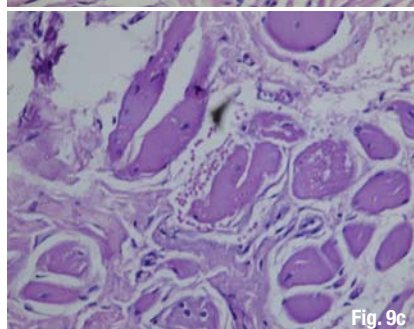
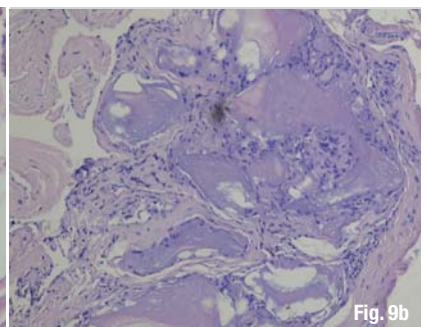
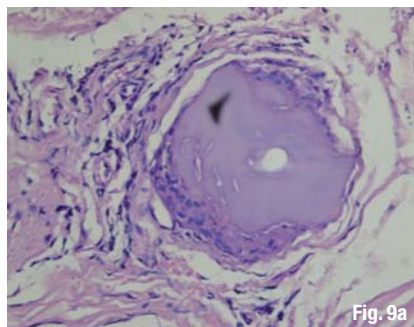
Analytical data regarding the increase in alveolar bone height and width was obtained before and after ridge augmentation and at the time of implant place-

ment. The mean and standard deviation of the augmentation volume obtained were calculated (Table 1 & Fig. 12).

In group A, the amount of bone height gained was 2.25 ± 1.31 mm ($P < 0.001$) and bone-width gain was 2.3 ± 1.49 mm ($P < 0.002$), while the amount of bone height gained was 0.75 ± 0.97 mm ($P < 0.001$) and bone-width gain was 0.45 ± 0.55 mm ($P < 0.002$) in group B. In group A, the amount of bone-height loss was 2.75 ± 1.31 mm ($P < 0.024$) and bone-width loss was 2.9 ± 1.88 mm ($P < 0.037$), while the amount of bone-height loss was 4.05 ± 1.01 mm ($P < 0.024$) and bone-width loss was 4.4 ± 0.93 mm ($P < 0.037$) in group B.

CBCTEvaluation (Figs. 10a, b & d)

It was surprising that Nanobone density was greater in group A after grafting. This was because of the presence of mineral in NanoBone, which acts as a scaffold, degrading progressively and being replaced by new bone. The new bone is premature with a low mineral density and is therefore not radiopaque after six months.



Figs. 9a-d_Histological evaluation.

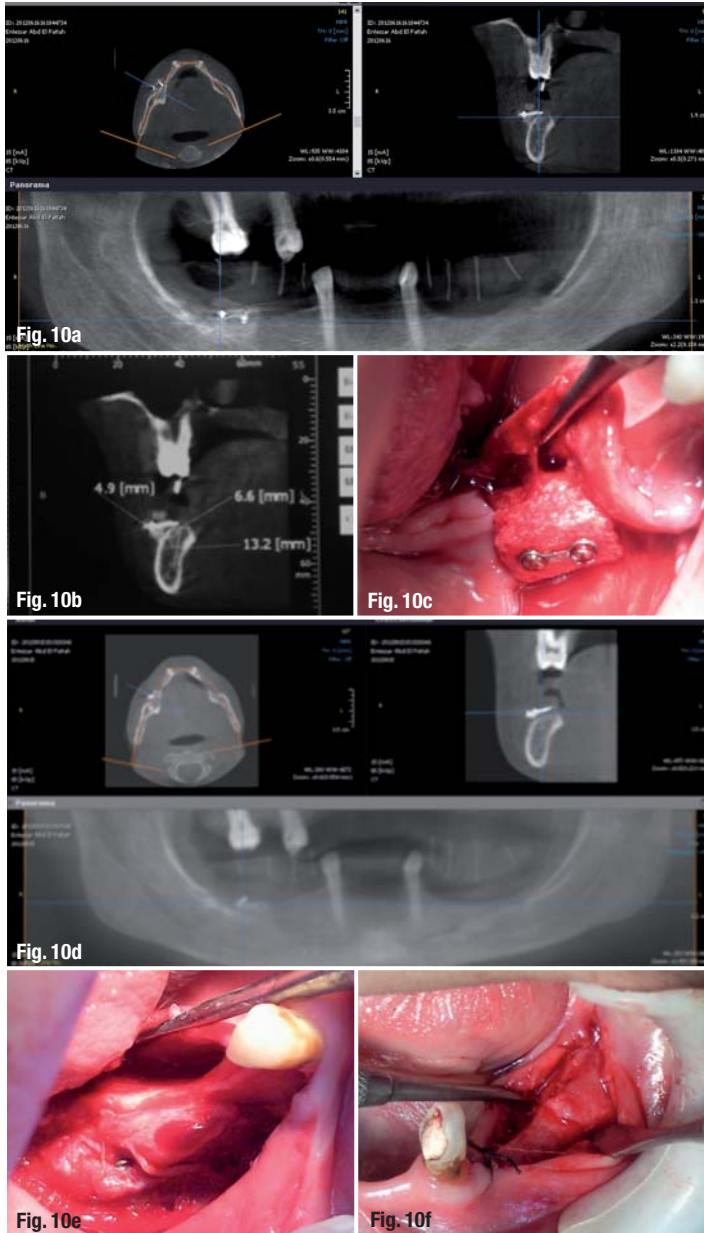


Fig. 10a_ CBCT immediately after ridge augmentation (Nanobone on the right side and Fisiograft on the left side)

Fig. 10b_ measurements of CBCT immediately after Nanobone ridge augmentation.

Fig. 10c_ Clinical view of Nanobone block fixation during augmentation procedures.

Fig. 10d_ CBCT six months after ridge augmentation (Nanobone in Rt side and Fisiograft in Lt side; NB. Nanobone graft not appears radiopaque in CBCT cross section).

Fig. 10e_ Clinical view of Nanobone graft six months after augmentation (at the time of implant placement).

Fig. 10f_ Clinical view of Fisiograft six months after augmentation (at the time of implant placement).

By comparing CBCT scans before and six months after the augmentation procedures (Figs. 10 a, b & d), it was found that CBCT is not a suitable means of evaluation for ridge augmentation with either NanoBone or allograft bone blocks.

Histological results

Histological evaluation showed rapid incorporation of the NanoBone block graft at six months, as ev-

idenced by newly formed bone containing viable osteocytes.

_Discussion

Reconstruction of the posterior mandible is challenging since deficiency in bone and mucosa is required due to the deformity.²⁷ Unlike the maxillary sinuses, the alveolar ridge does not provide a natural cavity to contain particulate grafting material.²⁸ Therefore, the graft must have sufficient strength and rigidity to attach to the recipient site and 3-D stability to withstand muscular forces.²⁹ The availability of autogenous bone block grafts from intra-oral sites is often a limitation in treatment possibilities.³⁰ Among the alternatives to autogenous bone blocks are the synthetic NanoBone and allograft bone blocks. Studies have reported that allograft fresh-frozen bone may provide results equivalent to those achieved with autogenous bone grafts.³⁰⁻³³ Currently, however, only insufficient evidence is available regarding treatment efficacy of allograft bone blocks, for example volumetric changes and remodelling/incorporation within the host bone, and the long-term survival rates of subsequently inserted implants,³⁰ and few studies have been conducted on the innovative NanoBone block.²³ The success of grafting procedures highly depends on primary soft-tissue closure, which warrants healing by primary intention and entails only marginal soft-tissue collagen formation and remodelling. In addition, it reduces postoperative discomfort and provides a significant step in predictable bone regeneration. Incision line opening is the most frequent postoperative complication in the initial healing phase of intraoral bone grafting.³⁴ It results in contamination or loss of the graft as well as a delay or abolition of the vascularisation and may halt bone growth.³⁵ The high frequency of incision line opening in bone block grafting is caused by the strain on the overlying tissue, which must cover larger quantities of bone. Furthermore, the local growth factor of the soft tissue is low under the reflected flaps which are positioned over a graft material or barrier membrane and not on the host bone.³⁶ In the present study, we used Kazanjian's vestibuloplasty instead of a crestal flap. Whether to make crestal or vestibular incisions during bone-block augmentation depends on the following factors. Vestibular incisions may be more advantageous than crestal incision because of better protection of the underlying grafted bone.²² They are also claimed to increase the blood supply to the lingual flap from the floor of the mouth. In addition, the lingual flap is not completely dissected from the inner aspect of the mandible and helps maintain the vestibule. This decreases muscle tension, preventing movement on both sides of the wound, which prevents wound dehiscence and incision line opening.



I AM A FAN

like most of my colleagues.

Dr. Leyli Behfar | Specialist in Oral Surgery

CAMLOG is my first choice when it comes to dental implants. With their high-precision implant systems, I find an answer for every indication. Implantations can be performed easily, efficiently and with excellent quality standards. CAMLOG is an inspiring partner in many ways – and that is getting around. www.camlog.com

a perfect fit™

camlog

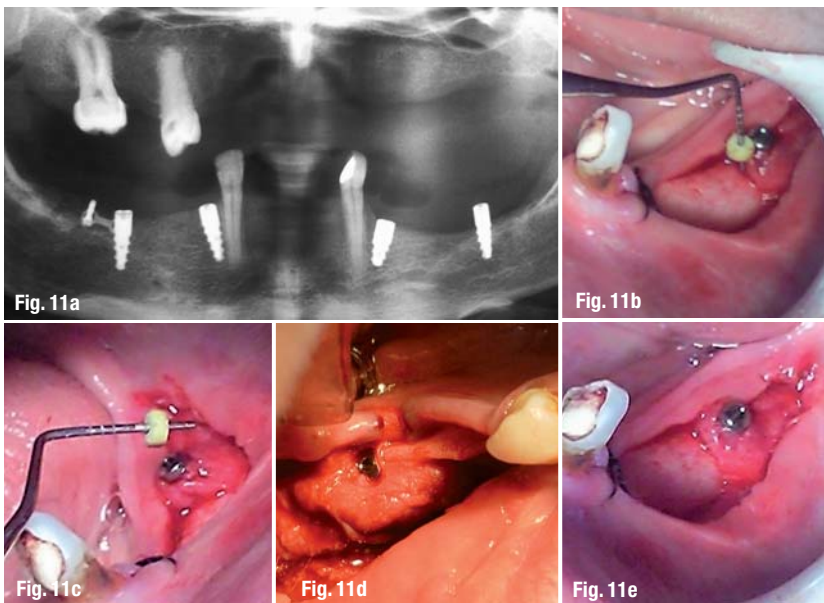
	Alveolar height measurements (mm)					Alveolar width measurements (mm)				
	BA	AA	BIP	BG	BL	BA	AA	BIP	BG	BL
Nanobone block group	13.1 +2.8	8.2 +2.7	10.45 +2.7	2.25 +1.31	2.75 +1.31	3.8 +0.85	9.7 +1.13	6 +1.71	2.3 +1.49	2.9 +1.88
Allograft bone block group	14.9 +2.9	9.9 +2.9	10.7 +2.8	0.75 +0.97	4.05 +1.01	4.60 +0.77	9.50 +0.94	5.05 +1.1	0.45 +0.55	4.4 +0.93
t. test	1.40	1.38	0.196	2.890	2.047	2.19	0.429	1.44	3.67	2.025
p. value	0.177	0.184	0.846	0.001	0.024	0.042	0.635	0.165	0.002	0.037

Table 1 Comparison of bone gain in groups A and B (BA: before augmentation; AA: after augmentation; BIP: before implants placement; BG: bone gain; BL: bone loss).

This is a frequent complication after crestal incision, especially in the mandible, owing to muscle tension, which may compromise the prognosis of the underlying grafted bone. It was clear from our results that the clinical complications, either during the procedures or during the healing period, were greater in group A than those observed in group B. We assume that this complication arose because NanoBone blocks have sufficient strength and rigidity to attach to the recipient site. Furthermore, NanoBone has 3-D stability and maintains its strength with little or no resorption when properly used. This results in an increase in tension on the overlying mucosa. In comparison, allograft bone blocks are resorbed rapidly, which decreases the tension on the overlying mucosa. This finding is consistent with that of Spin-Neto et al.,³⁷ who state that a loss of about one-third of the grafted block volume with allografts should be expected. They therefore recommend that this finding be kept in mind during treatment planning involving alveolar ridge augmentation with allografts, since it indicates the need for allograft bone blocks of larger dimensions to compensate for their considerable re-

sorption. The majority of adverse events occurred as a result of improper contouring or inappropriate closure techniques, which resulted in secondary soft-tissue dehiscence and infection. Clinical training is therefore strongly recommended for clinicians unfamiliar with NanoBone. The clinical complications observed in group A can be reduced by proper flap design and careful follow-up treatment during the healing period. It is worth noting that protecting the bone block from maxillary tooth pressure either by tooth grinding or by constructing an upper denture to maintain centric occlusion can prevent the bone block from fracture and the overlying mucosa from tearing. Another important result is that NanoBone exposed during the healing period was placed vertically to increase the alveolar ridge height. This finding is consistent with Barone et al.,³⁸ who postulate in their study that horizontal ridge augmentation has a more predictable outcome than vertical ridge augmentation. The observed difference in resorption between the two groups may be due to the different architecture of the NanoBone and the allograft bone blocks. It has previously been demonstrated that different graft architectures have a direct influence on the dynamics of bone remodelling.³⁹ The greater resorption of the allograft bone blocks can also be explained by inadequate revascularisation, less bone in-growth inside the grafted block and/or a smaller number of cells involved in the remodelling process of this type of bone graft.⁴⁰⁻⁴² NanoBone is a synthetic HA with nano-pores manufactured in a sol-gel process in the presence of SiO₂, so that it is degraded completely by osteoclastic activity. At the same time, the osteoblasts form autogenous bone and NanoBone is substituted by bone. In the present study, bone-width gain was measured both clinically and using CBCT. It was found that clinical measurement was an effective method to determine bone gain. This finding is consistent with that of Cheng Chen et al.²⁴ The results of the present study demonstrated that NanoBone blocks provided a statistically significant increase in bone gain after the grafting procedure, while the bone gain with allograft bone

Fig. 11a Panoramic X-ray after Tiologic implant placement, in Nanobone graft (right side) and in Fisiograft (left side). NB. Fisiograft does not appear radiopaque.
Figs. 11b & c Measurement of the Fisiograft height, invisible in X-ray.
Fig. 11d Tiologic implant in Nanobone graft (right side).
Fig. 11e Tiologic implant in Fisiograft (left side).



CONFIDENCE IN LIMITED SPACE

STRAUMANN® NARROW NECK CrossFit®

The Straumann Soft Tissue Level solution to address space limitations

- Confidence when placing small diameter implants
- Wide range of treatment options
- Simplicity in daily use



reddot design award
winner 2012



More information on www.straumann.com

COMMITTED TO
SIMPLY DOING MORE
FOR DENTAL PROFESSIONALS

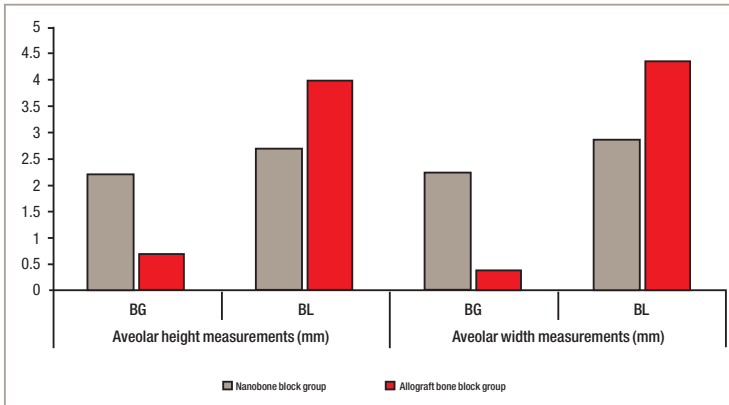
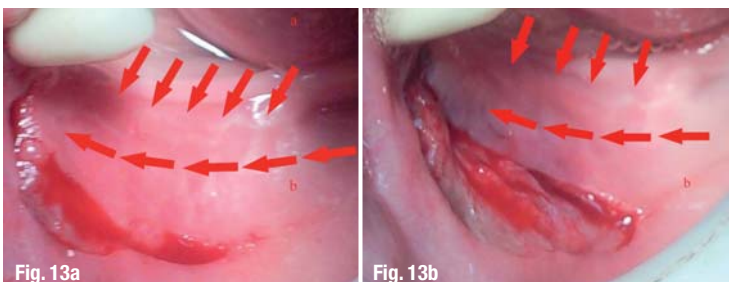


Fig. 12 Comparison of bone gain and loss between Nanobone and Fisiograft groups.

blocks was not statistically significant. Ehrhart et al.⁴³ and Grauer et al.⁴⁴ postulate that CBCT may be an effective tool for evaluating the treatment outcome after graft procedures or for long-term monitoring. This is not consistent with our finding that the newly formed bone does not appear in CBCT as radiopaque. Bone substitutes can form a scaffold which allows their colonisation by bone-promoting cells and their replacement by newly formed bone, thus becoming space maintainers in the process.⁴⁵ It is interesting to note that this newly formed bone is premature bone and that the resolution of the CBCT scan did not allow the newly formed bone to appear as radiopaque because of its low density. This finding is consistent with our histological results, which found that the newly formed bone has an organised matrix surrounded by an immature bone matrix or osteoid.

After six months, the radiolucency of the NanoBone blocks was evidence that the NanoBone had degraded completely. This is consistent with the finding by Gotz et al.,⁴⁶ who postulate that nanocrystalline HA has osteoconductive and biomimetic properties and is integrated into the host's physiological bone turnover at a very early stage. It is also consistent with the findings by Canullo et al.,¹⁹ who stated that newly formed bone, although in limited quantities, was already found at three months of healing and new trabecular bone was found at six months of healing.²⁰ Conversely, allograft bone did not appear as radiopaque after the augmentation or after six months owing to its composition, so we were unable to determine whether it had degraded completely.

Figs. 13a & b Blood flow from posterior area to the flap.



Evaluation of the final treatment was not a part of the present study, but implants were placed in the planned positions and were osseointegrated successfully in eight NanoBone blocks. In addition, implants could not be placed in six patients in groups due to insufficient bone gain. The most important concerns after a bone-block augmentation procedure are the assessment and comparison of the clinical success of the dental implants, which are inserted in the augmented localised atrophied ridges after one year, and determining whether these procedures can prevent resorption of the graft owing to masticatory forces.

Conclusion

The use of a NanoBone block resulted in a significant increase in ridge width, facilitating implant placement (Figs. 11a–e) in areas previously judged to be too narrow. The allograft bone block was well tolerated and was associated with a low complication frequency, but was not suitable for ridge augmentation in the posterior mandible. CBCT was not suitable to assess and evaluate bone gain after ridge augmentation by neither Nanobone block nor Fisiograft bone block.

Recommendation

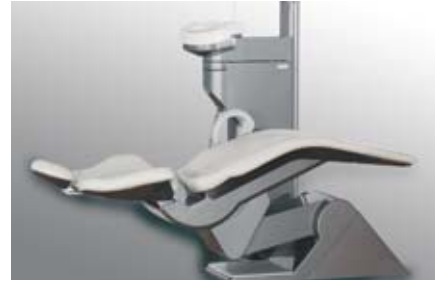Kazanjian vestibuloplasty should be modified by performing only vestibular and mesial vertical incision and not performing distal vertical incision, because distal vertical incision prevents blood flow from posterior area to the flap (Figs. 13a & b). By doing that, blood flow to flap will be from lingual side (a) supplied by the sublingual artery and posterior area (b) supplied by the facial artery and muscular branches of the maxillary artery.

_contact	implants
<p>Dr Omar Soliman PhD candidate Perioimplant dentistry Tel.: +20 1009634358, +20 1201005457 Omar.Soliman77@yahoo.com</p> <p>Prof. Dr Dr Mohamed Nassar Professor of Perioimplant dentistry Faculty of Dentistry, Tanta University, Egypt. Tel.: +20 1121522221 Prof_Nassar@yahoo.com</p>	

_RITTER IMPLANTS SYSTEM
_Quality. Flexibility. Innovation.



Founded in 1887 by the German Frank Ritter in New York, Ritter is one of the oldest prestige brands of finest dental equipment worldwide. Due to innovative ideas and a great entrepreneurial spirit, Ritter produced the first dental units already more than 125 years ago.



Today Ritter products are more than ever an essential element in dental practices worldwide. Users appreciate the Ritter product range for the high-quality aspects and the reliability - Made in Germany. Due to their functionality and user orientated construction, Ritter dental units contribute constantly to an optimized workflow of today's modern dental practices.

seo-Integration is guaranteed. Clever and easy handling is provided by self-tapping threads and a coloured system of drills and implants according to their diameters.



All Ritter Implants and Accessories are made by high modern CNC manufacturing machines. A combination of advanced machining and hand-finishing create the most accurate tools possible for the marking of ceramic drills.

In the course of the last years, Ritter has started to write a new success story with the launch of an innovative, state of the art implant system. The Ritter Implant Ivory Line provides Two Piece Implants (Implant plus separate Abutment) as the QSI Spiral Implant and TFI Twin Fissure Implant as well as One Piece Implants (Implant and Abutment already connected) called Mono Compress Implant MCI. The system contains logically reduced and clearly arranged components of tools and abutments with the best features for all clinical cases. Due to the super Nano-Surface, a quick and reliable Os-

The Ritter brand stands for high quality, state of the art technology and innovative products Made in Germany. The credo is to always provide customers and clients with the best services and prices combined with the most comprehensive dental solutions in the market.

More information:
www.ritterimplants.com

NEW
...ask for your special start offer:
Set price, incl. Implants, Analogs, Transfers
Abutments, Healing Caps and Starter Tool Kit!



FAX VOUCHER

YES, I want to save my benefit !
Please contact us as soon as possible.
I confirm with my address and signature / stamp



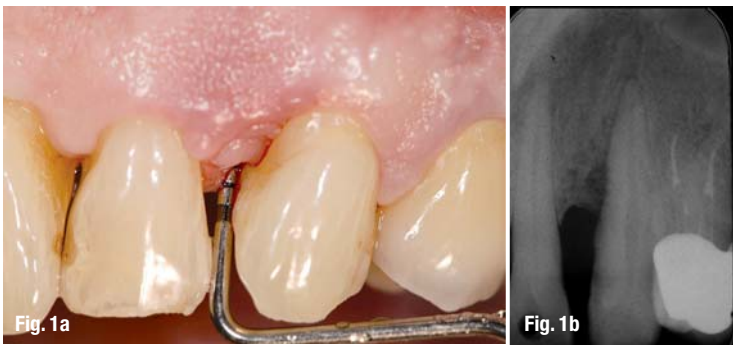
%

Number of Sets (max. 10)	<input type="text"/>	NAME	<input type="text"/>		
STREET	<input type="text"/>		VAT-NO.	<input type="text"/>	
CITY / ZIP	<input type="text"/>		COUNTRY	<input type="text"/>	
FON	<input type="text"/>		EMAIL	<input type="text"/>	
DATE	<input type="text"/>		SIGNATURE	<input type="text"/>	



Periodontal tissue repair in the aesthetic zone

Authors_Giulio Rasperini & Giorgio Pagni, Italy



lored to even have a positive effect on REC. These approaches are different when compared to traditional guided tissue regeneration (GTR) techniques used for root coverage purposes; instead they help reducing REC by reestablishing a positive periodontal architecture via regeneration and improving the support for soft tissues during wound healing.

_Indication

Traditionally, periodontal therapy is aimed at reducing PPD and improving CAL by eliminating bacterial deposits and factors predisposing to bacterial accumulations. Osseous resection is often required or suggested when a negative osseous architecture is present. Apically positioned flaps or repositioned flaps with removal of the secondary flaps are often used. This therapeutic approach is very predictable and allows maintaining the patients' dentition in the long term even in complex cases. Unfortunately, however, it can only worsen gingival recession and patients treated with traditional periodontal therapy often complain of un-aesthetic outcomes of the surgery and root hypersensitivity. Moreover, when deep infrabony defects are present, the practitioner is put on the hotspot of having to choose the lesser of two evils: either sacrifice a large amount of the supporting bone of the neighboring dentition or sacrifice the tooth with the deep bony lesion. PR is particularly indicated in such cases.

_Techniques

With most PR treatments, including the use of Enamel Matrix Derivative (EMD), bone grafts, Guided Tissue Regeneration (GTR) or combinations of the above, regeneration of bone, cementum and a functionally oriented periodontal ligament can be

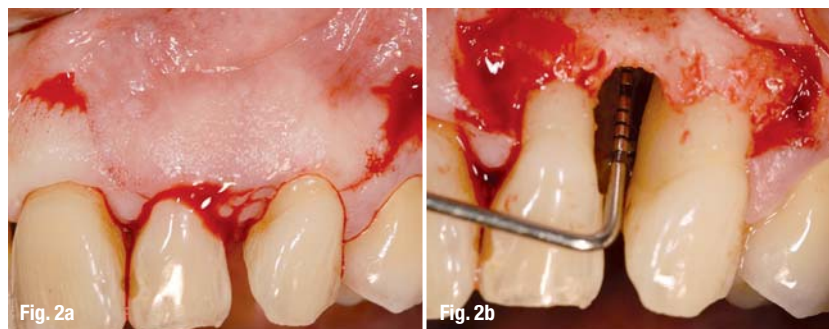
_Introduction

Periodontal regeneration (PR) has provided the practitioner with a more conservative therapeutic strategy for the treatment of infrabony periodontal defects. In fact, PR not only helps reducing periodontal pocket depth (PPD), but it also allows to gain clinical attachment level (CAL) with minimal negative effects on gingival recession (REC), which is particularly important when treating aesthetic areas.

In this paper, we will evaluate different approaches for periodontal regenerative therapy in the aesthetic area and we will suggest how regenerative treatment of infrabony defects may be tai-

Figs. 1a-b_ Pocket depth of 13 mm mesially to tooth #23. The tooth is stable and the periapical radiography shows angular bone loss with the formation of an infrabony defect.

Figs. 2a-b_ The presence of the papilla with no pocket depth between the lateral and the central incisor and between the canine and the first premolar suggest to place vertical relising incision at the base of those papilla and prererve the papilla over the infrabony defect with a buccal incision. The flap is then elevated full-thickness and the defect debrided and misured.



achieved in the infrabony defect with little increase of gingival recession.

More recently, minimally invasive approaches have been suggested. The Single Flap Approach (SFA) is the elevation of a single flap (either buccal or lingual), keeping intact the tissues on the other flap. The Minimally Invasive Surgical Technique (MIST) is an adaptation of the papilla preservation techniques with the intent to limit flap elevation and mesiodistal extension of the flap. With these approaches, the outcomes in terms of REC worsening were more encouraging and reduced the loss of soft tissue to almost nothing.

Finally, Coronally Advanced Flaps (CAF) in combination with regenerative approaches have been introduced with the intent of stabilising the soft tissue and providing a more stable wound for regeneration to occur. With this approach, a decrease in REC can be achieved, thus not only addressing the loss of attachment but also improving the aesthetic appearance of the area.

The Soft Tissue Wall technique is recommended for the treatment of infrabony defects in the aesthetic area, when one of the involved teeth has also

experienced an apical migration of the free gingival margin.

Soft Tissue Wall technique

In this approach, a horizontal incision is made at the base of the interdental papillae and extended to one tooth mesially and distally from the infrabony defect. A full-thickness trapezoidal flap (with the wider base apically positioned) is then elevated. The remaining facial portion of the anatomic papillae is preserved and de-epithelialised in order to create connective tissue beds to which the flap can be secured at the time of suturing. The papilla over the infrabony defect is dissected at its base and the entire interproximal supracrestal soft tissue is elevated in order to gain proper access to the defect.

After flap elevation, the granulation tissue is removed from the defects by means of metal curettes, followed by scaling and root planning using metal curettes and power-driven instrumentation.

Sharp and blunt dissection into the vestibular lining mucosa is performed to eliminate muscle tension and permit coronal displacement of the flap. Flap mobilisation is considered adequate

AD

5,0 x 6,0mm

6,0 x 8,0mm

5,0 x 6,0mm

5,0 x 5,0mm

4,5 x 6,0mm

5,0 x 6,0mm

6,0 x 5,7mm

6,0 x 5,7mm

5,0 x 5,0mm

14 JAHRE

6,0 x 5,7mm

4,5 x 6,0mm

5,0 x 5,0mm

4,5 x 6,0mm

5,0 x 6,0mm

6,0 x 5,7mm

14 JAHRE

6,0 x 5,7mm

28 YEARS OF CLINICAL USE SINCE 1985

SHORTEST IMPLANTS LONGEST HISTORY

4,0 x 5,0mm

5,0 x 5,0mm

6,0 x 5,0mm

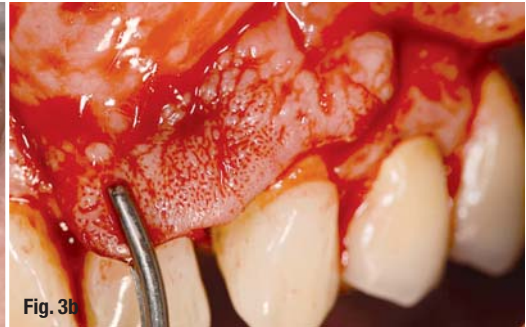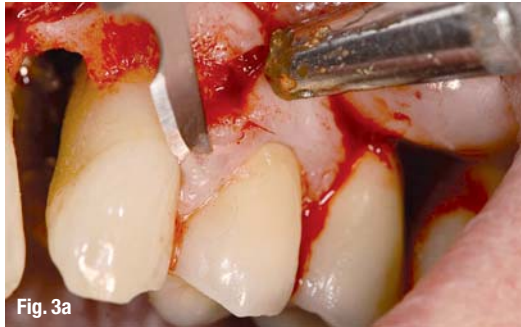
4,5 x 6,0mm

5,0 x 6,0mm

6,0 x 5,7mm

Seit 1985 » Einfach. Berechenbar. Wirtschaftlich.

Figs. 3a–b The mesial and distal papilla coronal to the relaxing incisions are de-epithelized and a periosteal relising incision at the base of the flap allows to move the flap coronally without tension.



when the marginal portion of the flap is able to passively reach a level more coronal to the CEJ and to cover the de-epithelialised anatomic papillae.

Two sling sutures are used to stabilise the coronal displacement of the buccal flap. The root surface may be conditioned to remove the smear layer and to obtain a surface free of organic debris. Biological elements as enamel matrix derivative gel (Emdogain®, Straumann, CH) or filling biomaterials in combinations or not with growth factors delivery may now be applied to the defect. A tension-free primary closure of the interdental papilla upon the bony defect is achieved with an internal horizontal mattress suture and the vertical releasing incisions are closed with interrupted sutures.

Usually, patients receive systemic antibiotic therapy and analgesic therapy to prevent post-operative pain and oedema and sutures are checked and removed eight days after surgery. Local plaque control is maintained by a 0.2 % chlorhexidine digluconate rinse (three times daily) for eight weeks. During this period, patients are recalled

weekly for professional prophylaxis. At-home mechanical cleaning of the treated area is allowed four weeks after completion of the surgical procedure, using an ultra-soft tooth-brush and a roll technique in apico-coronal direction. Interproximal mechanical cleaning with dental floss is allowed two months after the regenerative procedure. After the initial eight weeks, recall appointments for professional supragingival tooth cleaning are scheduled at one-month intervals for one year post-treatment. No attempt to probe or for subgingival scaling is made before the twelve-month follow-up examination.

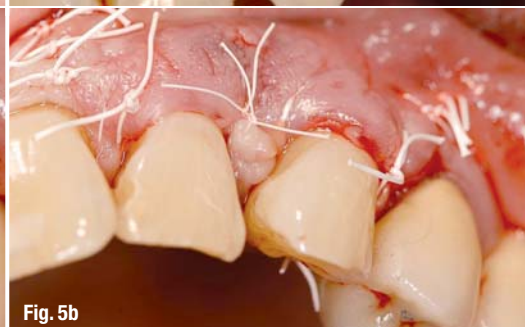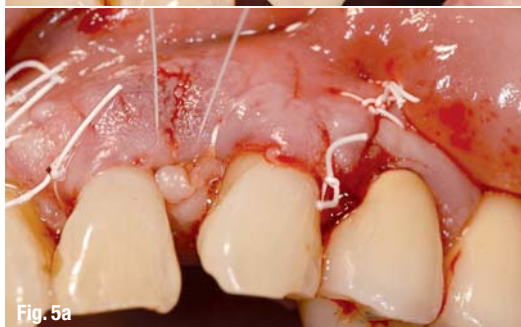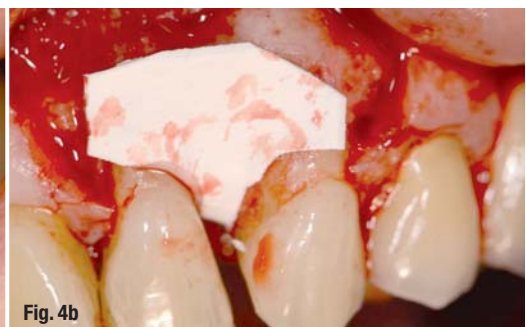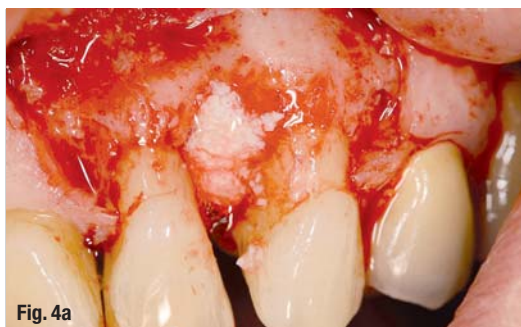Two main hypotheses have been described to explain the mechanisms involved in the regeneration of new periodontal structures including new cementum, new bundle bone and a functionally oriented periodontal ligament.

The first suggested mechanism is the cell occlusion mechanism originally postulated by Melcher in 1976¹ and then revised and integrated by different authors. According to this concept, five cellular

Figs. 4a–b The biomaterials are placed into the defect to promote regeneration and to stabilize the clot.

In this case, Emdogain (Straumann, CH) was mixed with BioOss (Geistlich CH) graft and protected with a collagen resorbable membrane (BioGide, Geistlich, CH).

Figs. 5a–b With a 5-0 Gore-Text suture, a sling suture suspended to tooth #22 and one suspended to tooth #23 will stabilize the flap coronally, firm on the teeth, creating a stable buccal Soft Tissue Wall. Now, an internal mattress suture with a 7-0 Gore-Tex will close the papilla, extroffletting the wound margins and allowing perfect adaptation of the flaps.



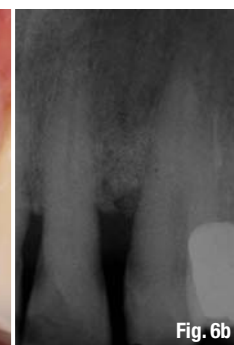
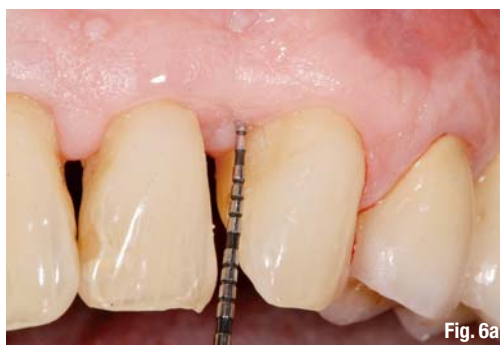populations can populate the defect following a surgical intervention: (1) epithelial cells, which are the fastest proliferating and the fastest migrating cells of all five groups, (2) gingival connective tissue cells, (3) alveolar bone cells, (4) periodontal ligament cells, (5) cementoblasts. Guided tissue regeneration uses barrier membranes excluding from the wound area epithelial and connective tissue cells in order to allow the slower cell groups to populate the defect and determine the regeneration of the new ligament. Epithelial cells are in fact inhibited from growing via contact inhibition. Contact inhibition is the natural process of arresting cell growth when two or more cells come into contact with each other or with a solid surface. In a Petri dish cell culture, normal epithelial cells proliferate and migrate centripetally until reaching the borders of the Petri capsule. In GTR, epithelial cell migration stops when the epithelium covers the membrane and comes into contact with the root surface.

The second mechanism is the blood clot stability mechanism. The fibrin component of the blood clot can attach to the alveolar bone, gingival connective tissue and root surface. It has been demonstrated by Wikesjo and coworkers that when the blood clot is not allowed to attach to the root surface, epithelial down-growth occurs and new connective tissue attachment formation is precluded. Instead, if the fibrin attachment to the root surface is not disrupted by any mechanical or physical trauma, the epithelium migrates over the clot and stops migrating when meeting the clot-root interface.

Both of these mechanisms well explain how it is possible to direct wound healing toward regeneration, repair in relation to the adopted technique or biomaterial used, whether it is a membrane, a bone substitute or just a stabilised clot.

The first human histologic evidence of a newly regenerated periodontal ligament dates back to 1982 when Nyman et al.² used a Millipore filter on a mandibular incisor which was previously involved in periodontitis, allowing cells originating from the periodontal ligament to repopulate the root surface during healing. Since then, a number of publications have shown histological evidence of a newly regenerated ligament with various surgical techniques, different biomaterials and growth factors.

At the meantime, we should still keep in mind that epithelial down-growth is reversible. Already in the 1980's, Listgarten et al.³ had demonstrated—in an animal model evaluating access flaps—that while the length of the junctional epithelium did not change between the three months and the



twelve months postoperative dates, this measure was "pushed" in a coronal direction thus reducing sulcus depth and increasing the length of the connective tissue attachment.

Conclusion

In light of this, the importance of maintaining the structural integrity of the gingival tissues as opposed to a pocket elimination procedure (i.e. apically positioned flaps, osseous resective surgery) must be increasingly stressed, especially when surgical treatment in the aesthetic area is warranted.

Periodontal therapy has been reshaped profoundly by the great amount of research and literature produced in the last few decades. What used to be a discipline of large, invasive flaps, has now evolved to a discipline mainly encompassing non-surgical therapy, risk management strategies, and minimally invasive flaps for the treatment of localised defects. This transformation rendered periodontal therapy of the aesthetic area a much less invasive and more acceptable approach, which has to be embraced by all practitioners dedicating their profession toward this exciting and continuously evolving specialty.

Editorial note: A list of references is available from the author.

Figs. 6a–b—The one-year result shows a pocket depth of 3 mm with a gain of 10 mm when compared to the baseline. In the radiographic image biomaterial is still detectable with an optimal bone filling.



contact implants

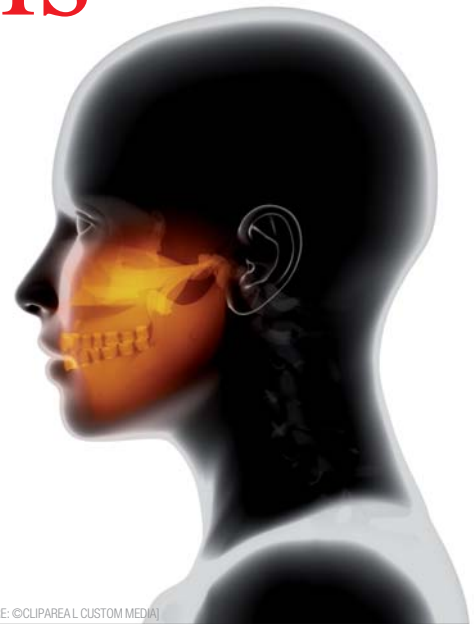Giulio Rasperini

Department of Biomedical, Surgical and Dental Sciences, Unit of Periodontology, Foundation IRCCS Ca' Granda Polyclinic, University of Milan, Milan, Italy
Via XX Settembre, 119
29121 Piacenza, Italy

giulio@studiorasperini.it

Bisphosphonate therapy and osteonecrosis of the jaw

Authors Johannes D. Bähr, Prof. Dr Dr Peter Stoll & Dr Georg Bach, Germany



(PICTURE: ©CLIPAREA L CUSTOM MEDIA)

_Introduction

Osteonecrosis of the jaw due to bisphosphonate was first described in 2003. The disease is called bisphosphonate-related osteonecrosis of the jaw (BRONJ). Dental implants are contraindicated for tumour patients under bisphosphonate therapy. In osteoporosis patients with oral bisphosphonate administration (not exceeding three years), however, the risk of developing osteonecrosis is considered to be very low. The following work provides an overview.

Fig. 1 Structural formula of pyrophosphate and basic structure of bisphosphonates with the side chains R1 and R2 (Arzneimittelbrief AMB 1998, 32, 41).

Fig. 2 Non-nitrogenous bisphosphonates of the first generation (Abu-Id 2010).

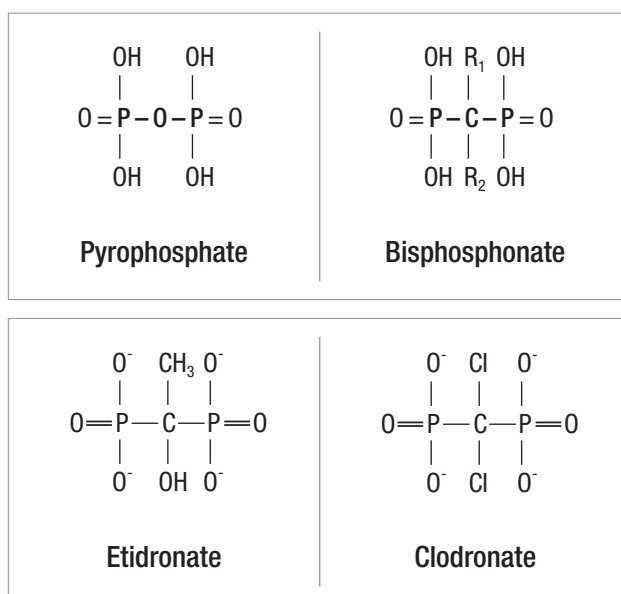
Menschutkin, a German chemist, was the first to achieve the synthesis of bisphosphonates in 1895. In the beginning, bisphosphonates were mainly used in the textile, fertilizer and oil industries thanks to their ability to inhibit the precipitation of calcium carbon-

ate. In the 1960s, they were used as detergent additives by Henkel company.

1968 was the year of the first medical application of bisphosphonates. The American orthopaedist Andrew Bassett was in charge of three children whose muscles had calcified in part. One of the three children (16 months old) was in a life-threatening condition, since his respiratory muscles had already been affected. Bassett turned to the Swiss physician Herbert Fleisch who had been dealing intensely with bisphosphonates. The two physicians used the bisphosphonate etidronate for the calcifications. Most of the fresh calcifications disappeared within a few days. Since the 1980s, bisphosphonates have found widespread use in medicine in particular thanks to their bone-strengthening effect.

_Chemical principles, mode of action and indication

Bisphosphonates are derived from pyrophosphates. On account of their strong affinity to bone, it was assumed that pyrophosphates might be used *in vivo* to prevent bone resorption. However, since they are inactivated quickly *in vivo*, they were not suitable as a drug. In search of substances having a similar, but prolonged effect, scientists came across bisphosphonates. The P-O-P skeleton of the pyrophosphates is replaced by a P-C-P skeleton in the bisphosphonates



Proven stability, high esthetics

« NobelReplace Conical Connection merges the well-proven implant body of NobelReplace Tapered with a tight internal conical connection. It is a versatile, easy-to-use implant which performs well in soft and hard bone. »



Prof. Alessandro Pozzi
Rome, Italy

NEW Option with
0.75 mm
machined collar

NobelReplace Conical Connection combines the original tapered implant body with a sealed conical connection, offering you and your patients an esthetic solution for all indications. The implant body mimics the shape of a natural tooth root, designed for high initial stability with all types of loading protocols including Immediate Function. Developed for restorations in the esthetic region,

NobelReplace Conical Connection offers a strong sealed connection with built-in platform shifting, designed to maximize soft tissue volume for natural looking esthetics. After 45 years as a dental innovator we have the experience to bring you future-proof and reliable technologies for effective patient treatment. **Their smile, your skill, our solutions.**



Visit nobelbiocare.com/nobelreplace



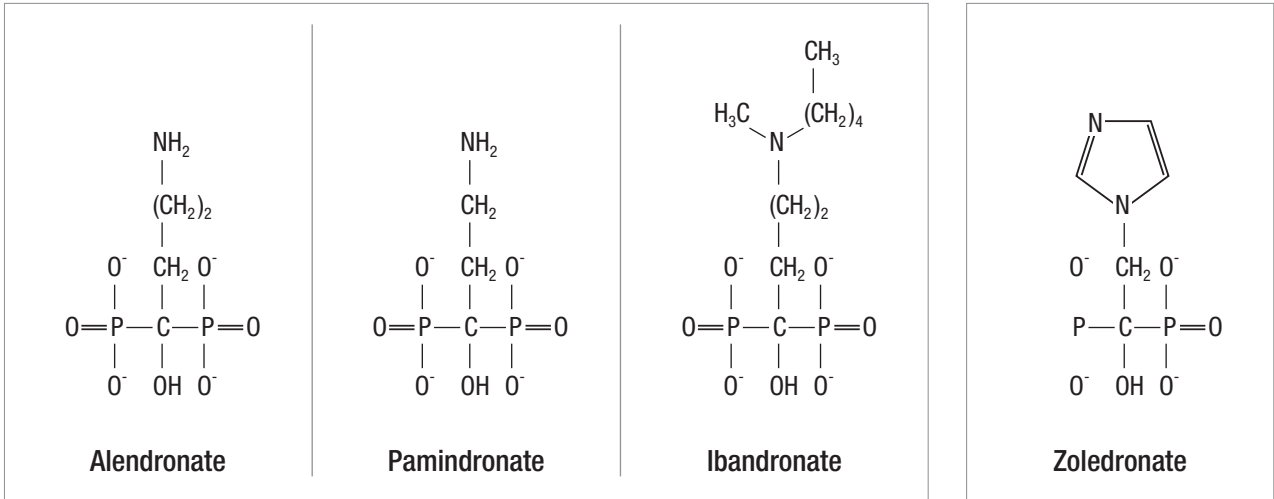


Fig. 3 Amino bisphosphonates of the second generation (Abu-Id 2010).

Fig. 4 Amino bisphosphonate of the third generation with nitrogen-containing heterocycle (Abu-Id 2010).

(Fig. 1). The P-C-P group makes the bisphosphonates highly resistant to enzymatic decomposition. A large number of bisphosphonates have been synthesised over the last 30 years. They differ in the two side chains that are bound to the carbon atom. In most bisphosphonates, the first side chain (R1) is an OH group. The second, long side chain (R2) essentially determines the character of the bisphosphonate. Three generations are distinguished according to the R2 side chains:

- The bisphosphonates of the first generation are the so-called non-amino bisphosphonates or alkyl bisphosphonates. They contain an aliphatic R2 side chain such as e.g. etidronate or are substituted by halogen (Fig. 2).
- The bisphosphonates of the second generation are amino bisphosphonates. They contain amino groups in the R2 side chain such as e.g. alendronate, pamidronate or ibandronate (Fig. 3).
- The bisphosphonates of the third generation are amino bisphosphonates as well. They are substituted on the nitrogen atom and have alkaline nitrogen-

containing heterocycles in the R2 side chain such as e.g. zoledronate (Fig. 4).

Some authors do not distinguish between bisphosphonates of the second and of the third generation. These authors subsume all amino bisphosphonates under the group of the second generation. Bisphosphonates act both on the cellular and on the biochemical level. The effects on the biochemical level are based on the side chains. The variability of the side chains determines the differentiation of the different bisphosphonates.

While the R1 side chain of the bisphosphonates is mainly responsible for the binding to the bone, the highly variable R2 side chain has a particular influence on activity. Derivatives with an amino group in the R2 side chain (amino bisphosphonates) are more active than those without such a group (non-amino bisphosphonates). Moreover, the longer the R2 side chain, the greater the activity. Bisphosphonates deposit on the

Tab. 1 Commonly used bisphosphonates and their relative potency compared to etidronate (Schindler 2009). All bisphosphonates except for clodronate have an OH group at their R1 group. At the R2 group, they have (except for clodronate) an aliphatic chain and/or a nitrogen-containing heterocycle.

Substance	Trade name	R1	R2	Relative potency
Editronate	Didronel®	-OH	CH ₃	1 x
Clodronate	Ostac® Bonefos®	-Cl	-Cl	10 x
Pamidronate	Aredia®	-OH	-CH ₂ -CH ₂ -NH ₂	100 x
Alendronate	Fosamax®	-OH	-CH ₂ -CH ₂ -CH ₂ -NH ₂	1,000 x
Risedronate	Actonel®	-OH	-CH ₂ -	5,000 x
Ibandronate	Bondronat® Bonviva®	-OH -OH	-CH ₂ -CH ₂ -N(CH ₃)-C ₅ H ₁₁	10,000 x
Zoledronate	Zometa® Aclasta®	-OH	-CH ₂ -	20,000 x

2 0 1 3



GREATER NEW YORK DENTAL MEETING

SCIENTIFIC MEETING:
Friday, November 29 -
Wednesday, December 4

EXHIBIT DATES:
Sunday, December 1 -
Wednesday, December 4

NO PRE-REGISTRATION FEE

Attend At No Cost
Never a pre-registration fee at the
Greater New York Dental Meeting

Mark Your Calendar
Educational Programs:
Friday through Wednesday,
November 29 - December 4

Exhibits:
Sunday through Wednesday,
December 1 - December 4

More than 600 Exhibitors
Jacob K. Javits Convention Center
11th Avenue between 34-39th Streets (Manhattan)

Headquarters Hotel
New York Marriott Marquis Hotel

Live Dentistry Arena - No Tuition

Latest Dental Technology & Scientific Advances

More Than 350 Scientific Programs
Seminars, Hands-on Workshops, Essays & Scientific
Poster Sessions as well as Specialty and Auxiliary
Programs

Educational Programs in various languages

Social Programs for the Entire Family

**ENJOY NEW YORK CITY AT ITS BEST DURING THE
MOST FESTIVE TIME OF THE YEAR!**

**The Largest Dental Meeting/Exhibition/
Congress in the United States**

89th ANNUAL SESSION



For More Information:
Greater New York Dental Meeting®
570 Seventh Avenue - Suite 800, New York, NY 10018 USA
Tel: (212) 398-6922 / Fax: (212) 398-6934
E-mail: victoria@gnydm.com / Website: www.gnydm.com



WWW.GNYDM.COM

Sponsored by: The New York County Dental Society and The Second District Dental Society

Fig. 5 First reports on bisphosphonate-related osteonecrosis of the jaw.

- **2003:** Marx (36 cases), Migliorati (5 cases), Carter et al. (3 cases), Wang et al. (3 cases)
- **2004:** Ruggiero et al. (63 cases)
Communication of the Ärztekommision [Medical Committee]
Dtsch. Ärzteblatt (Aug. 2004)
Hoefert et Eufinger (3 cases)
Information given by Novartis company (3 cases)
- **2005:** Marx (119 cases)

bone surface in the resorption lacunae under the osteoclasts. They are resorbed by osteoclasts and result in cell inactivation and a loss of their ruffled border. Due to the loss of their ruffled border, the cell surface of the osteoblasts diminishes and they thus lose their ability to resorb bone. In addition, an increased apoptosis of osteoclasts occurs at higher doses. Besides the inhibition of osteoclasts, osteoblasts are inhibited as well.

The therapeutic effect of bisphosphonates consists in the fact that the inhibition of osteoclasts exceeds the inhibition of osteoblasts. This results in a positive balance in bone remodelling in favour of bone formation and in a reduction of the bone remodelling rate. The most common clinical indication for bisphosphonates is the treatment of osteoporosis. They are highly effective in this field. They effect an increase in bone density and a reduction in bone loss both in postmenopausal and in steroid-induced osteoporosis. The field of application of bisphosphonates for malignant

diseases includes osteolytic bone metastases and multiple myeloma. The bisphosphonates contribute to reduce the risk of skeleton-related events in patients. They have positive effects on a series of complications such as acute hypercalcaemia, new bone metastases, diffuse bone pain and protect against pathological fractures. Osteoporosis treatment is usually carried out using tablets. Intravenous administration of bisphosphonates is common in particular in oncology. The dosing for the treatment of osteoporosis is many times lower than for the treatment in oncology.

The activity of a bisphosphonate is defined by the amount of substance that is necessary in order to effectively inhibit bone resorption. The higher the activity, the greater is the potency of the bisphosphonate. The relative potency of bisphosphonates is related to the potency of the non-amino bisphosphonate etidronate. Etidronate is the oldest bisphosphonate available for clinical use. Table 1 shows a selection of therapeutically proven bisphosphonates. Only 1–10 per cent of orally administered bisphosphonates are resorbed. They bind to albumin in the blood and have a very high affinity to hydroxylic apatite of the bone. The half-life period in bone ranges from years to decades. Accumulation occurs in case of repeated application. Elimination takes place via the renal route. Bisphosphonates have side effects. The most important side effects are: gastrointestinal problems, acute phase reaction, renal lesions and osteonecrosis of the jaw.

Fig. 6 Therapy recommendations for BRONJ depending on the stage of the disease (AAOMS, Ruggiero et al. 2009).

Stage 0 <ul style="list-style-type: none"> • unspecific symptoms • no bone necrosis 	<ul style="list-style-type: none"> • symptomatic pain therapy • if necessary, antibiotic therapy
Stage 1 <ul style="list-style-type: none"> • exposed necrotic bone • asymptomatic patients • no evidence of infection 	<div style="display: flex; align-items: center; justify-content: center;"> <div style="writing-mode: vertical-rl; transform: rotate(180deg); border: 1px solid black; padding: 2px;">antibacterial mouthwash solution (CHX 0,2%)</div> <div style="display: flex; flex-direction: column; align-items: center; justify-content: center; gap: 10px;"> <div style="border: 1px solid black; padding: 2px;">frequent recalls</div> <div style="border: 1px solid black; padding: 2px;">patient instruction</div> <div style="border: 1px solid black; padding: 2px;">Antibiotic therapy</div> <div style="border: 1px solid black; padding: 2px;">Pain therapy</div> <div style="border: 1px solid black; padding: 2px;">Surgical debridement</div> </div> </div>
Stage 2 <ul style="list-style-type: none"> • exposed necrotic bone • symptomatic patients • clinical evidence of infection 	
Stage 3 <ul style="list-style-type: none"> • exposed necrotic bone • symptomatic patients with pain and evidence of infection • evidence at least one of the following complications <ol style="list-style-type: none"> 1. pathological fracture 2. extraoral fistula 3. oral-antral communication 4. extended osteolyses 	

Bisphosphonate-related osteonecrosis of the jaw (BRONJ)

Bisphosphonate-related osteonecrosis of the jaw was described for the first time in 2003. Early reports are listed in Figure 5. More than 400 case series were published in the years that followed. The great increase in the number of case reports might also be because of the increased use of bisphosphonates in the treatment of osteoporosis and tumours. With respect to the definition of osteonecrosis of the jaw under therapy with bisphosphonates, there is no agreement in literature regarding nomenclature and inclusion criteria. The suggestion of the American Association of Oral and Maxillofacial Surgeons (AAOMS) is quoted most frequently. According to that, the disease is called bisphosphonate-related osteonecrosis of the jaw (BRONJ). The criteria for the presence of BRONJ are:

- current or earlier treatment with bisphosphonate
- uncovered, necrotic bone in the jaw for more than eight weeks
- no history of radiotherapy in the gnathofacial region.

Up to now, there is no satisfactory pathogenetic explanation for which mechanisms are responsible for causing osteonecrosis due to bisphosphonates in the end. Only hypotheses serve as approaches to explain



the occurrence of the disease. For example, in particular the inhibition of bone remodelling through bisphosphonates and the bisphosphonate-induced anti-angiogenesis are discussed as causes. It has not been established yet why bisphosphonate-related osteonecrosis only occurs in the jaw. The following particular features of the jaw are discussed as possible causes:

1. desmale ossification of the jaw
2. contamination of the jaw via the teeth
3. prominent points of the jaw with thin mucosal cover and
4. often secondary wound healing (e. g. dental extraction).

Risk factors for the occurrence of BRONJ include:

1. type and duration of treatment with bisphosphonates (the higher the dose and the longer the therapy, the greater the risk)
2. dento-alveolar operations
3. dento-alveolar infections and
4. demographic factors (risk increasing with age, lower in black population than in white).

A large number of associations and expert committees have published recommendations for the prevention and therapy of BRONJ:

- American Academy of Oral Medicine (AAOM) 2005 (Migliorati et al. 2005)
- Deutsche Gesellschaft für Zahn-, Mund- und Kieferheilkunde (DGZMK) [German Society of Dentistry, Oral Medicine and Orthodontics], Arbeitsgemeinschaft (AG) Kieferchirurgie [Working Group for Maxillary Surgery] and Deutsche Gesellschaft für

Mund-, Kiefer- und Gesichtschirurgie (DGMKG) [German Association for Oral and Maxillofacial Surgery] 2006 (Grötz and Kreuzsch 2006)

- Spanish Expert Panel Oncology, Hematology, Urology and Stomatology 2007 (Bagán et al. 2007)
- American Society for Bone and Mineral Research (ASBMR) 2007 (Khosla et al. 2007)
- American Dental Association (ADA) 2006, 2008 (updated) (Edwards et al. 2008)
- American Association of Oral and Maxillofacial Surgeons (AAOMS) 2007, 2009 (updated) (Ruggiero et al. 2009)
- French Expert Panel 2009 (Tubiana-Hulin et al. 2009).

Not all recommendations include strategies depending on defined stages of the disease in order to ensure that the treatment is initiated in a suitable manner according to the severity of the disease. And there are no randomised clinical studies that assess the effectiveness of these recommendations. The recommendations for prevention before treatment with bisphosphonates listed below correspond to the recommendation of the joint scientific statement of Deutsche Gesellschaft für Zahn-, Mund- und Kieferheilkunde (DGZMK) [German Society of Dentistry, Oral Medicine and Orthodontics], the Arbeitsgemeinschaft (AG) Kieferchirurgie [Working Group for Maxillary Surgery] and Deutsche Gesellschaft für Mund-, Kiefer- und Gesichtschirurgie (DGMKG) [German Association for Oral and Maxillofacial Surgery]:

- advice and information on the risk of necrosis of the jaw
- sanitation of all potential focuses of infection in the jaw

Tab. 2 Authors with publications on the treatment of BRONJ.

Authors	Patients treated (n)	Type of study	Type of therapy	Patients recovered (n)
Nocini et al. (2008)	7	retrospective	antib./surg.	6
Ferran et al. (2008)	1	case report	antib./surg.	1
Engroff & Coletti (2008)	1	case report	antib./surg.	1
Carlson & Basile (2009)	74	retrospective	antib./surg.	66
Stanton & Balasanian (2009)	33	retrospective	antib./surg.	28
Wongchuensoontorn et al. (2009)	3	retrospective	antib./surg.	3
Saussez et al. (2009)	20	retrospective	antib./surg.	4
Williamson (2010)	40	prospective	antib./surg.	40
Abu-Id (2010)	98	retrospective	antib./surg.	93
Nicolatou-Galitis et al. (2011)	67	prospective	antibiotic	10
Wilde et al. (2011)	24	prospective	antib./surg.	20
Hoefert & Eufinger (2011)	46	retrospective	antib./surg.	34

Tab. 3 Authors with publications on implant insertion with oral bisphosphonate therapy.

Authors	Patients	Implants	Losses	BRONJ
Jeffcoat (2006)	25	63	0	none
Fugazzoto et al. (2007)	61	169	0	none
Brooks et al. (2007)	2	11	0	none
Bell et al. (2007)	42	101	5	none
Grant et al. (2007)	115	468	2	none
Shabestari et al. (2007)	21	46	0	none
Torres et al. (2007)	1	6	0	none

- smoothing of sharp edges of bone
- sanitation of conservable teeth
- checking dental prostheses for pressure sore
- continual recall.

The therapy recommendations in Figure 6 show the recommendations of the American Association of Oral and Maxillofacial Surgeons (AAOMS), updated in 2009. Most publications and guidelines have recourse to these recommendations. The therapy recommendations are presented depending on the stage of BRONJ.

In general, it must be concluded that the use of oral antimicrobial mouthwash solutions combined with oral systemic antibiotic therapy is recommended in early stages. Superficial debridement is occasionally indicated as well. Extensive surgical treatment is mainly reserved for patients in more advanced stages. The treatments performed on BRONJ patients according to literature cannot be classified according to clinical staging, since most publications do not consistently describe the criteria for diagnosis, staging and choice of therapy. In most of the cases described, the treatment of BRONJ consists of a combination of antibiotic therapy and surgical intervention. Many studies, however, are retrospective studies. More and more prospective studies have been published recently. The combined antibiotic/ surgical treatment seems to be superior to pure antibiotic treatment. Table 2 shows a selection of authors who treated BRONJ patients and published this in studies.

The problem about literature evaluation is the poor comparability. Criteria for making the diagnosis, duration of bisphosphonate treatment, extension of the necrotic bone and/or description of the exact surgical procedure are absent in many cases. The treatment of BRONJ is complex and has not been investigated sufficiently. In many cases, the conservative approach does not result in recovery. While most of the treatment options suggested were investigated in a small

number of patients only, they offer new solutions for the future. In all cases, the surgical and non-surgical therapy depends on the extension of the lesions, but also on the patient's general state of health and their life expectancy.

Special implantologic aspects

Only very isolated reports on the integration of dental implants in tumour patients associated with intravenous bisphosphonate therapy can be found in literature. These reports agree that implant insertions should be refrained from in tumour patients with intravenous bisphosphonate therapy. These patients are considered to be at an excessive risk of developing BRONJ in the context of a dento-alveolar procedure. However, there is a certain number of reports on dental implants in patients under prolonged oral bisphosphonate therapy in literature. Table 3 shows a selection of authors who inserted implants in patients with oral bisphosphonate therapy and published this in studies.

The published cases suggest that the occurrence of BRONJ after implant insertion is rather rare under oral bisphosphonate therapy. Since implant insertion, however, constitutes a dento-alveolar procedure, implant insertion is associated with the risks of a dento-alveolar procedure under bisphosphonate administration, such as the risk of developing BRONJ, but to a much lesser extent than in tumour patients who were treated with bisphosphonates by comparison.

Grötz et al. (2010) recommend the preparation of an individual risk profile for potential implant patients that should include the following three criteria:

1. the patient's individual BRONJ risk,
2. the issue of increase or decrease in the risk of developing BRONJ due to the implantation, and
3. the issue of the necessity of augmentative measures. The diagram shown in Figure 7 helps to illustrate the indication algorithm. The diagram may be

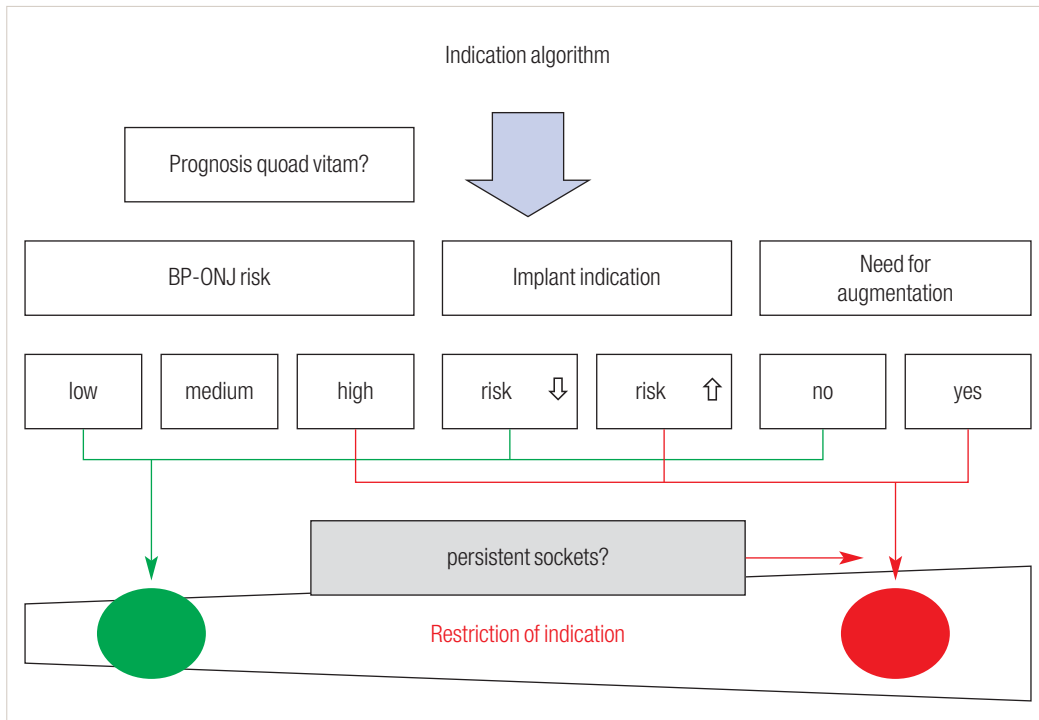


Fig. 7 Diagram for determining the indication for an implantation in case of bisphosphonate medication (Grötz et al. 2010).

useful in particular for patients who have been treated with bisphosphonates over a long period of time before implantation.

run the greatest risk of developing osteonecrosis of the jaw. Osteoporosis patients with oral bisphosphonate therapy of less than three years are less at risk.

Reports in literature agree that implant insertion in patients with oral bisphosphonate therapy of less than three years constitutes virtually no risk factor for BRONJ. However, implant follow-up should be particularly intensive in these patients as well since the area through which the implant was inserted constitutes an area at particular risk. The same applies to patients who had already received dental implants before a scheduled oral bisphosphonate therapy.

A dental-surgical procedure precedes the onset of the disease in most of the patients. A large number of associations publish recommendations regarding the prevention and therapy of the disease. The use of oral antimicrobial mouthwash solutions combined with oral systemic antibiotic therapy is recommended in early stages. Superficial debridement is indicated as well in some cases. An extended surgical treatment is mainly reserved to patients in more advanced stages.

_Prospects

Although longitudinal prospective studies are being carried out at present, most knowledge on BRONJ originates from the experience of treating physicians, from retrospective studies of patient records and from assumed conclusions of bone physiology and pharmaceutical research. Until long-term prospective studies confirm or correct the current procedures and therapies, we will be on uncertain ground when treating bisphosphonate patients. This problem might be present in particular regarding oncology patients with intravenous bisphosphonate therapy.

Dental implants are contraindicated in tumour patients under bisphosphonate therapy. In osteoporosis patients with oral administration of bisphosphonates (not exceeding three years), however, the risk of developing osteonecrosis is considered to be very low.

Editorial note: A list of references is available from the publisher.

_Summary

Osteonecrosis of the jaw is an undesired side effect of bisphosphonate therapy first described in 2003. Patients with multiple myeloma and skeletal metastases who are treated with intravenous bisphosphonates

_contact	implants
<p>Johannes Daniel Bähr Wilhelmstraße 3 79098 Freiburg/Breisgau Germany</p> <p>johannes.d.baehr@web.de</p>	

Advantages of 3-D planning for implants

Authors_Drs A. Grandoch & P. Ehrl, Germany

Introduction

Implantology is predominantly a surgical and prosthetic subject area. Its aim is both functional and aesthetic restoration. Today, one can place an implant in the jawbone with a high probability of success if there is good bone support. There are, however, concerns with regard to bone defects, optimum aesthetic and functional positioning of the implant and the soft-tissue situation, possibly requiring partial reconstruction. The ideal number of implants for large superstructures is still a matter of debate.

Functionality, durability and aesthetics are aims that should, in general, be achieved as simply as possible using favourable and conditionally reversible techniques with minimal damage, even in problematic cases. Restoring teeth today has become easier to achieve but whether the cost-benefit ratio is satisfactory must be established for each case. There is still no consensus on these aims and perhaps success can be defined only individually. Expectations regarding implantological solutions have increased owing to significant technological advances. One may distinguish between general success criteria valid for all implants and criteria for special indications. While some scientific societies recommend replacing lost teeth with implants as the optimal treatment, and bearing

in mind that the goal is restoration of natural conditions, one has to ascertain whether this is valid for single-tooth and multiple-tooth replacement for each case. Reasons for suboptimal solutions are manifold, ranging from poor initial conditions associated with a higher treatment risk to socio-economic limitations.

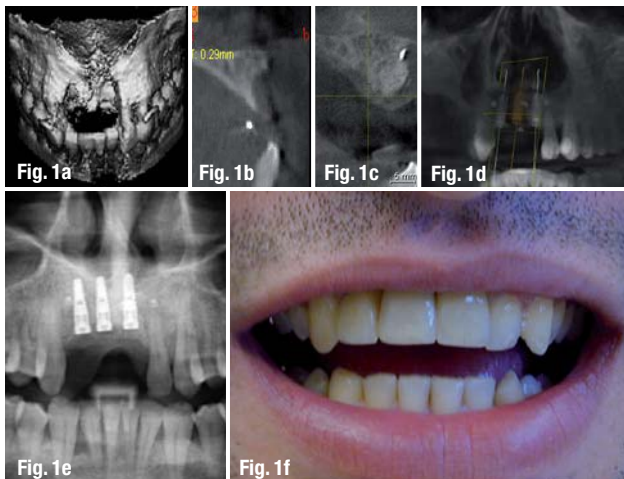
One cannot write about implant treatment in general, as too many parameters play a role, particularly because each case differs from another. Moreover, there are no general recommendations with regard to methodology. This is hardly surprising, since various methods are used, of which many have limited application and quickly become out of date. There is no widely agreed upon gold standard.¹

Methods

In 2000, CBCT was introduced to our clinic with hesitation initially and limited to more extensive problems and progressive diseases. It was used increasingly and has been used for almost all implant surgeries since 2008. Three-dimensional diagnostics undisputedly offer greater insight, thus increasing the quality of the treatment. Three-dimensional planning, however, always means considering the prosthetic planning and the anatomical substratum. This is done digitally or via conventional casts.

Even before the introduction of 3-D technologies, backward planning² demonstrated that viewing the desired treatment result is helpful in achieving the result. Here too, we initially applied backward planning to cases requiring extensive treatment at first, until we learned that planning is useful for single-tooth replacement too. Each of these techniques—conventional casts and CBCT scans—can be helpful, contributing to a distinct improvement in the treatment results in the hands of the experienced implantologist. The next step would therefore be to connect these two techniques. After purely digitally controlled navigation was found to be inaccurate, surgical guide systems, based on planning software, became available.

Figs. 1a-f_Single-tooth replacement with 3-D planning pre- and post-augmentation: Massive defects in the buccal lamella, regions 11 and 21 **(a)**. The dimensions of the defects are visible in the sagittal plane **(b)**. After horizontal bone grafting **(c)**. Three-dimensional planning post-augmentation **(d)**. Post-implantation **(e)**. Patient with crowns **(f)**.



43RD

INTERNATIONAL ANNUAL CONGRESS OF THE DGZI



"Practice-Oriented Implantology"

October 4–5, 2013 // Berlin, Germany // Hotel Palace Berlin

Congress President // Prof. Dr. Dr. Frank Palm/DE

Scientific Director // Dr. Roland Hille/DE


Gold Sponsor:



Silver Sponsor:



Bronze Sponsor:



FAX REPLY // +49 341 48474-390

Please send me further information on the
43RD INTERNATIONAL ANNUAL CONGRESS OF THE DGZI
on October 4–5, 2013, in Berlin, Germany.

Office Stamp

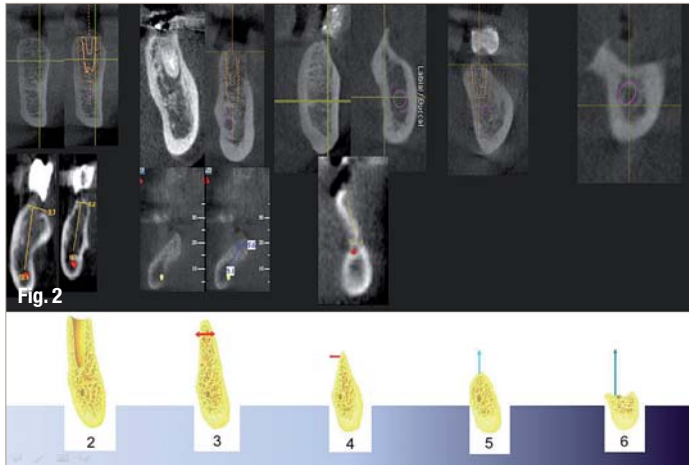


Fig. 2 Depiction of anatomical varieties in the lateral mandible (classification according to Atwood).

Currently, we are making the step from plaster cast and wax-up to digital model and digital reconstruction. This interesting new approach has to prove its worth in the practice first. Therefore, we have to determine which of the many digital features are essential in treatment of the patient.

Main features of 3-D planning

Only by the evaluation of 3-D data does a preoperative decision on how the desired prosthetic result can be obtained become possible. With the final result in view and mind, a solid basis for deciding upon the necessity and type of augmentation and whether removable or fixed dentures are indicated in edentulous jaws is provided. There are often bone defects, whose extent must be evaluated. They are classified according to Fallschüssel and Atwood and the classification demonstrates that, as a rule, horizontal bone loss occurs first, while vertical bone is lost gradually.

Restoring horizontal bone is important for prosthetic restoration primarily for aesthetic reasons in the anterior area and primarily for functional reasons in the lateral areas concerning the position of the implant in the dental arch. These defects can be optimally corrected via surgical restoration of the original bone volume. For each case, measurements for posi-

tioning the implant (such as inclination—to be performed by the surgeon) and measurements for the prosthesis (to be done by the dental technician) must be taken. The latter, for example, buccal crown overhangs or mucosal facings, prevent hygienic design of the superstructure and quite often result in aesthetic deficiencies.

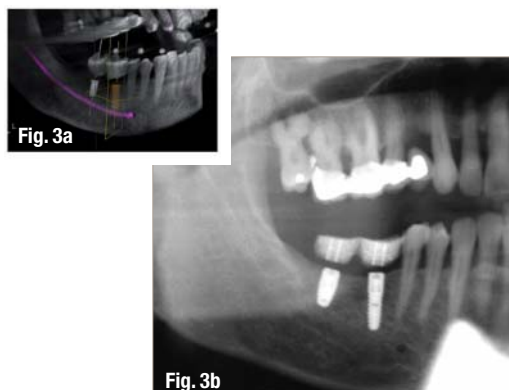
If restoration of vertical bone volume is necessary, for instance with Fallschüssel Class 4 frontal or 2 lateral or Atwood Class 4 defects, a more costly two-step technique has to be followed in most cases. At this point, it should be noted that almost all the atrophy patterns mentioned only involve the jaw and do not concern the functional components of the dental arches. Arutinov et al.³ postulate that this must be compensated for by angled implants. Kinsel et al.⁴ conclude that only the length of the implant is significant for implant loss. This means that as great a bone volume as possible must be used. All of the above-mentioned planning decisions can only be made soundly if information about both the 3-D anatomy and the desired prosthetic solution is available.

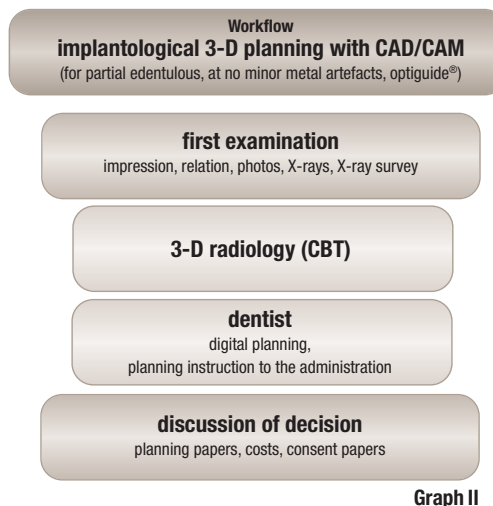
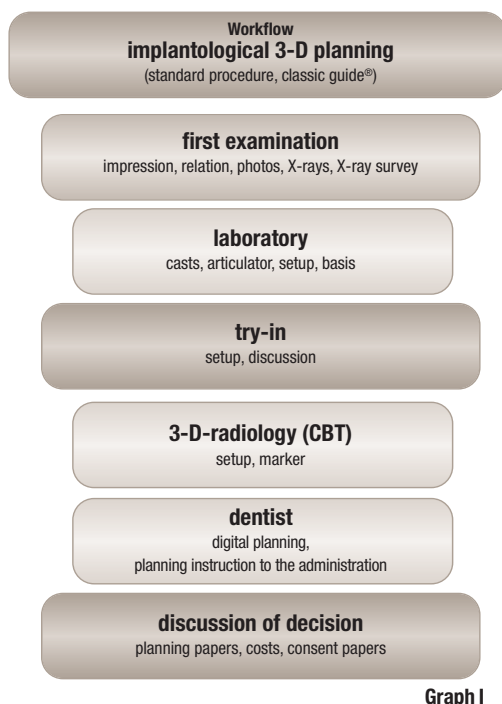
The guidelines of the European Association of Dental Implantologists⁵ offer a critical discussion of angled and short implants. Angled implants require a bone quality above 3, 3-D planning and guided implantation, among others. Planning based on an impression with fabrication of a planning cast is critical for the final outcome of implant placement and thus for the procedure. This will determine the required treatment steps and desired treatment outcome. Quite often, this step is not accorded the necessary importance in daily practice. Adequate planning should be done by the dentist and a special appointment with the patient should be made to obtain consent. With two-step procedures, repeating planning after augmentation and a second 3-D radiograph may become necessary.

Digital 3-D planning

Today's prosthetic planning possibilities offer alternatives to conventional casts. Two digital prosthetic planning tools will be discussed here, SimPlant (Materialise Dental) and SICAT/CEREC (Sirona). Both these tools are alternatives to the conventional approach described above via digital planning. With both methods, the surface of the neighbouring teeth and soft tissue is scanned and matched to the radiological 3-D data. This can be done from a cast (SimPlant and SICAT) or an intra-oral scan (SICAT OPTIGUIDE procedure). Then, a digital cast is created with the prosthetic planning programme. The objectives of these methods are simplification and shortening of the workflow (Graphs I & II).

Figs. 3a & b Planning in the lateral mandible with setup cast *in situ* (SICAT) (a). Post-implantation with surgical guide for control (b).





Graph I_Workflow for 3-D implant planning.

Graph II_Workflow for 3-D implant planning with CAD/CAM.

The precision of these methods is particularly noteworthy and figures for the overlap of the radiographic data and the optical scan obtained with the SICAT CAD/CAM method are available. The difference between CBCT data and the optical surface scan is between 0.03 (0.33) and 0.14 (0.18) mm.⁶ After scanning, crowns can be planned with the help of the CEREC crowns and bridges planning software. The precision of the digital SICAT method depends on the resolution of the respective data. For analogue impression techniques, for example, a precision between 0.1 and a maximum of 0.2 mm is required,⁷ as well as a gap of 0.027 to 0.101 mm between the crown and natural tooth.⁸

The precision of the two methods therefore is similar. This holds true if all error sources are taken into account: CBCT scan, the transfer to the surgical guide, the repositioning of the guide, the play of the drill and deviation when placing the implant. The surface scan improves precision. The advantage of this procedure is that the production of a planning cast is unnecessary (Graph II). The OPTIGUIDE method makes an important step towards the digitisation of prosthetic and implant planning, resulting in greater planning reliability and precision. Unfortunately, there are restrictions concerning partially edentulous jaws and cases with extensive metal artefacts.

_Single-tooth replacement

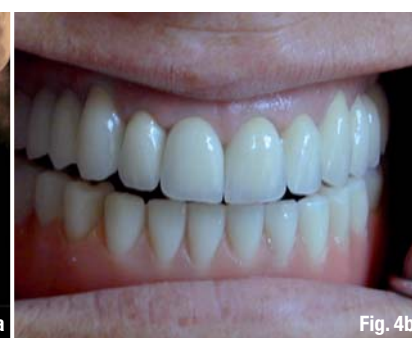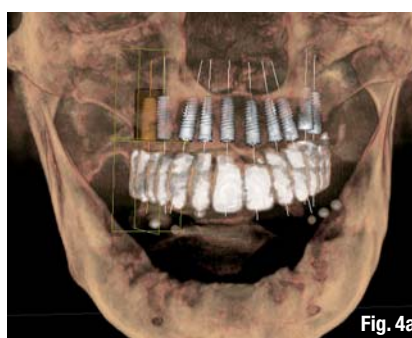
Expectations are high with single-tooth replacement. The target is to achieve a state equal to the conditions before tooth loss. Tooth replacement in the aesthetic region is particularly demanding. Anatomical prerequisites primarily determine the treatment method. For example, an implant may be placed into a particular alveolus immediately without 3-D planning. For delayed implantation, a cast and 3-D radiograph should be used. By planning the implant inclination and relation to the neighbouring teeth, the emergence profile and the positioning of the crown can be favourably planned. Guided implantation is particularly helpful in individual implants when several individual implants have to be placed or neighbouring teeth are endangered where there is only limited space. In addition, the patient's wish to see the expected outcome can be met. However, visualising optimum results involves the danger of arousing expectations that cannot be guaranteed. Figures 1a to f show the two-step reconstruction of a horizontal defect with 3-D planning.

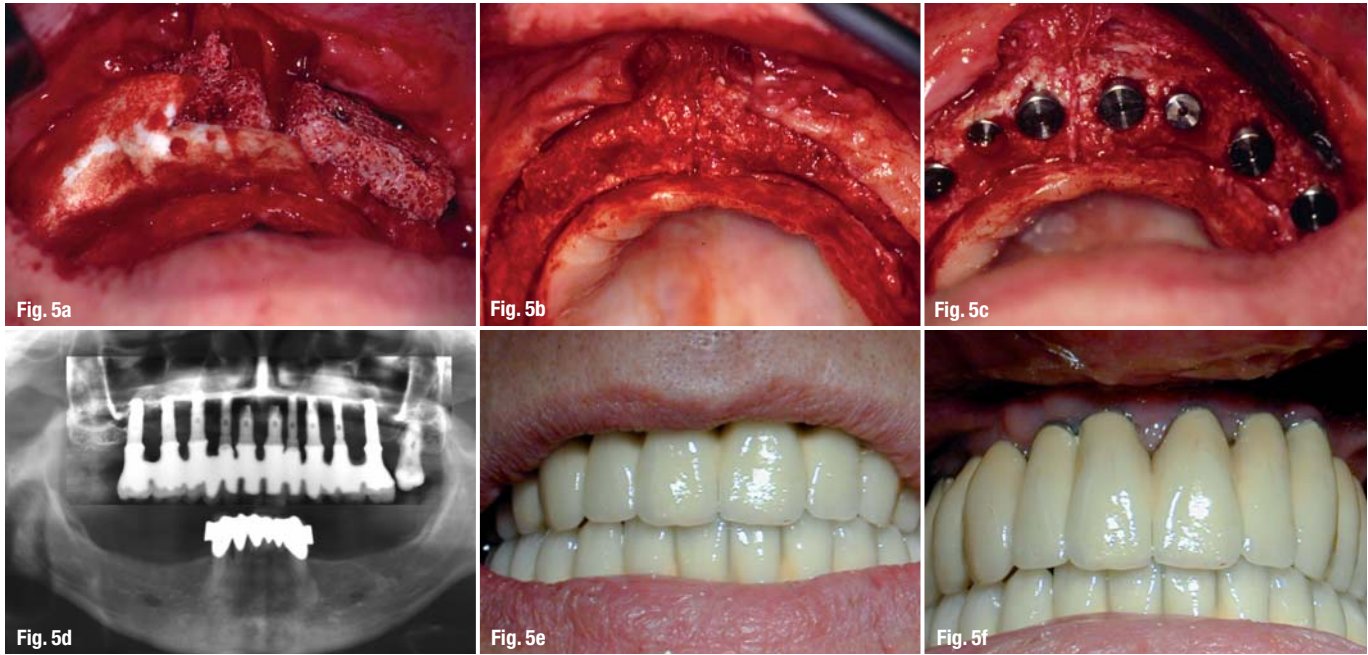
cal prerequisites primarily determine the treatment method. For example, an implant may be placed into a particular alveolus immediately without 3-D planning. For delayed implantation, a cast and 3-D radiograph should be used. By planning the implant inclination and relation to the neighbouring teeth, the emergence profile and the positioning of the crown can be favourably planned. Guided implantation is particularly helpful in individual implants when several individual implants have to be placed or neighbouring teeth are endangered where there is only limited space. In addition, the patient's wish to see the expected outcome can be met. However, visualising optimum results involves the danger of arousing expectations that cannot be guaranteed. Figures 1a to f show the two-step reconstruction of a horizontal defect with 3-D planning.

_Shortened row of teeth

In reconstruction of a shortened row of teeth, the function and particularly the support of the tem-

Figs. 4a & b_Three-dimensional planning in an edentulous maxilla (a). Prosthetic loading with good initial conditions (b).





Figs. 5a–f Two-step technique in a case of advanced atrophy of the alveolar process before prior to fixed prostheses. Horizontal and vertical augmentation (intra-operatively, fixed bone block (left) and covered with membrane cover (right); **a**). Healed post-augmentation (**b**). Post-implantation (**c**). Radiograph after placement of the bridge (**d**). Prosthetic result, lip reposed (**e**). Prosthetic result, lip raised (**f**). Despite augmentation, long crowns are were still required.

poromandibular joint is important. The number of teeth necessary for prostheses has not been determined definitively. Within the last few years, reconstructing up to the first molar, and up to the second premolar in cases with an extension, has been usual. Generally, alveolar atrophy progresses most rapidly horizontally in the lateral jaw area, starting buccally, and frequently is later followed by atrophy of the vertical dimension.

If one avoids augmentation or performs only minor augmentation, longer prostheses are necessary for short implants, which are situated more lingually than the natural teeth. The use of short implants in the lateral jaw is subject to several restrictions, such as good bone quality, primarily connected crowns or caps, no extension bridges, no lateral excursion contacts and no para-functional habits. Angulation is limited to 20 degrees. Furthermore, angled implants are not recommended for a shortened row of teeth according to the guidelines of the European Association of Dental Implantologists.⁵ If alignment is carried out with respect to antagonists in the natural dentition, positioning the new implant-borne crowns will

not lead to any functional losses, unless the antagonists were not functionally situated in the dental arches originally.

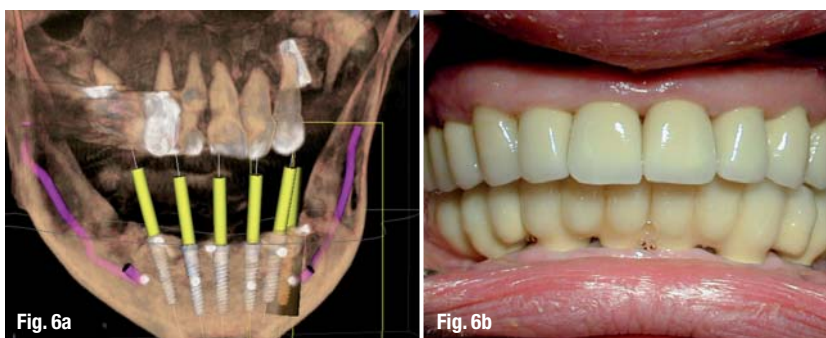
Space towards the cheeks must be regained, even if patients with a long case history sometimes complain about spontaneous cheek biting and bolus retention. One must choose carefully between the more pleasant approach of using short and angled implants with long crowns and the more difficult approach of bone augmentation. Three-dimensional planning provides indispensable information in cases like these. With reference to typical defect patterns, Figure 2 demonstrates that restoring bone volume for very different defects can be problematic. A typical reconstruction using a surgical guide for pilot drillings in a shortened row of teeth with good initial conditions is depicted in Figures 3a and b.

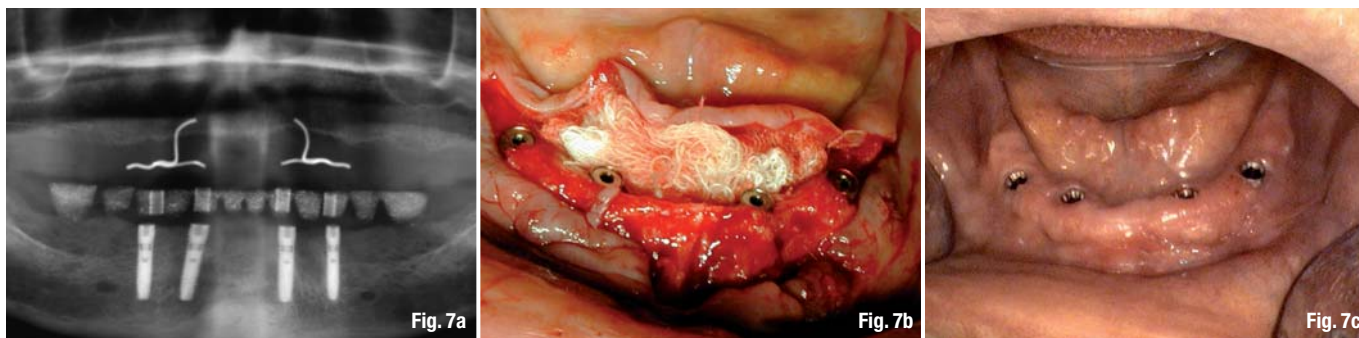
Edentulous jaw

Three-dimensional planning is of vital importance for determining the treatment approach for implantation in edentulous jaws. For instance, one has to decide upon whether and which augmentative measures are required and whether a removable or fixed prosthesis is suitable. With regard to the last point, it must also be decided whether extensive single-tooth replacement is possible, whether small or large bridges must be used, and whether a greater intermaxillary distance must be filled prosthetically by longer crowns or by a mucosa substitute.

The number of implants for fixed dental prostheses include the All-on-4 concept (Nobel Biocare), the consensus conference recommendations of six im-

Figs. 6a & b Loading of an edentulous mandible with a fixed bridge on inter-foraminal implants: Planning detail (**a**). Four years post-treatment (**b**).





plants in the mandible and eight in the maxilla, and tooth-by-tooth reconstruction up to the first molar. The multitude of planning information and treatment possibilities requires a great deal of planning, which is always justified because of its significant consequences. Planning based on digital casts is not appropriate in these cases, since the support of the cheeks and lips by the prosthesis is important and this can only be determined with the help of and for each patient. Here, the advantages of prosthetic planning are particularly evident.

Edentulous jaws often require a special approach (see Figs. 4a & b for an example). Extensive augmentation is frequently necessary (Figs. 5a–f). The required length of the teeth, however, has to be clarified with the patient before treatment and depends on the amount of tooth displayed during lip repose (Fig. 5e). Quite frequently, implants are placed inter-foraminally in the mandible, often because extensive augmentation is still problematic in the lateral mandible. Figures 6a and b show a patient with six implants and an extension bridge.

Even in cases of seemingly simple implantation for removable dentures in an edentulous jaw, 3-D planning and a planning cast are needed to verify functional reconstruction and soft-tissue support. In addition, they can aid determination of the positions of the implants in consultation with the dental technician and planning for adequate space for the attachment box.

Discussion

Three-dimensional planning for implants holds the advantage of higher quality owing to (a) risk identification; (b) planning reliability; (c) production of near-natural structures; (d) targeted and fast work; (e) patient compliance; and (f) cost transparency. These advantages are largely due to the greater amount and quality of information gained. Three-dimensional diagnostics enable us to obtain reliable information about the condition of the alveolar process and important anatomical structures. With the additional planning cast, information about the restoration of

function and aesthetics is obtained. Combining both information sources will result in optimal treatment planning. In addition, an experienced surgeon can address surprises if the patient is flexible. Intra-operative decisions may also need to be made if unexpected situations arise. Knowledge of 3-D data permits planning, which entails devising a well-considered procedure and obtaining the necessary tools and substitute material, for example suitable implants and bone substitutes. Owing to the traceability of diagnosis and treatment, as well as the resulting safety, patients will regard the procedure particularly positively.

A disadvantage is the higher initial outlay, but this is balanced by increasing use owing to a targeted and quicker workflow and thus less reworking. Implantation always requires a 3-D radiograph. These new techniques have greater logistical requirements than conventional dental procedures do and require extensive involvement of the teams involved in order to achieve treatment success.

It should be borne in mind that every surgery is accompanied by a certain risk in spite of the safety precautions taken. In addition, too much confidence in methodologies may lead to carelessness. Errors may even arise with 3-D planning, which may hold negative consequences for treatment. Therefore, it is important to be familiar with each step and error source and thus expert training is crucial. In addition, maintaining a critical attitude throughout treatment is necessary to avoid errors. The advantages of 3-D planning are so significant that it has become indispensable.

Editorial note: A list of references is available from the publisher.

_contact	implants
<p>Dr Dr Peter A. Ehrl andepend Berlin, Germany peter.ehrl@andepend.com</p>	

Figs. 7a–c X-ray after implantation with mucosa-born drilling template *in situ* (a). Surgical site with lingual position of the medial implants (b). After exposure (c).



Implant-supported rehabilitation after radiation therapy

Authors_Dr Umut Baysal, Dr Arzu Tuna & Dr Rainer Valentin, Germany

Introduction

The restoration of the masticatory function after therapy of malign tumours of the head and neck is of great importance for the social reintegration of oncological patients. Especially their localisation in the head-and-neck area poses high psychological and psychosocial demands on the patient. The following article gives insight into latest therapeutic successes as well as a patient case from the author's practice.

Practicing dentists play an important role the prevention and early detection of carcinoma of the oral cavity, but they are equally central in masticatory functional rehabilitation post radiationem.¹

In the majority, these are squamous cell carcinomas of varying localisation. Malign tumours of the salivary glands are less frequent (adenoid-cystic carcinomas, mucoepidermoid, adeno and salivary duct carcinomas), lymphoepitheliomas and sarkomas.² Adverse therapy effects often result from combined radio(chemo)therapeutical and surgical treatment, often affecting the physiological anatomy and function. However, both radiation and chemotherapy are integral aspects of the treatment, in addition to the tumour surgery itself. Head-and-neck radiation is performed in squamous cell carcinoma of the oral cavity and the oropharynx as well as malign tumours of the salivary glands and malign lymph nodes.¹

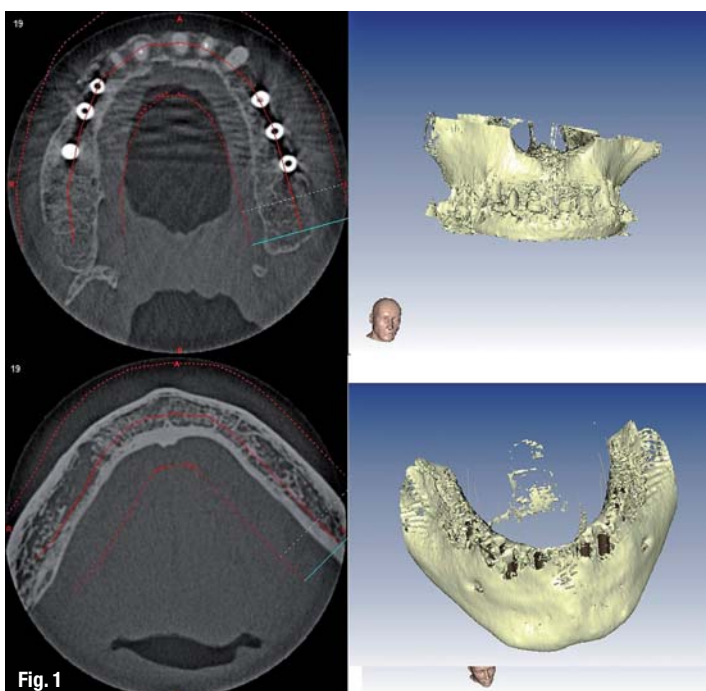
Therapeutic effects

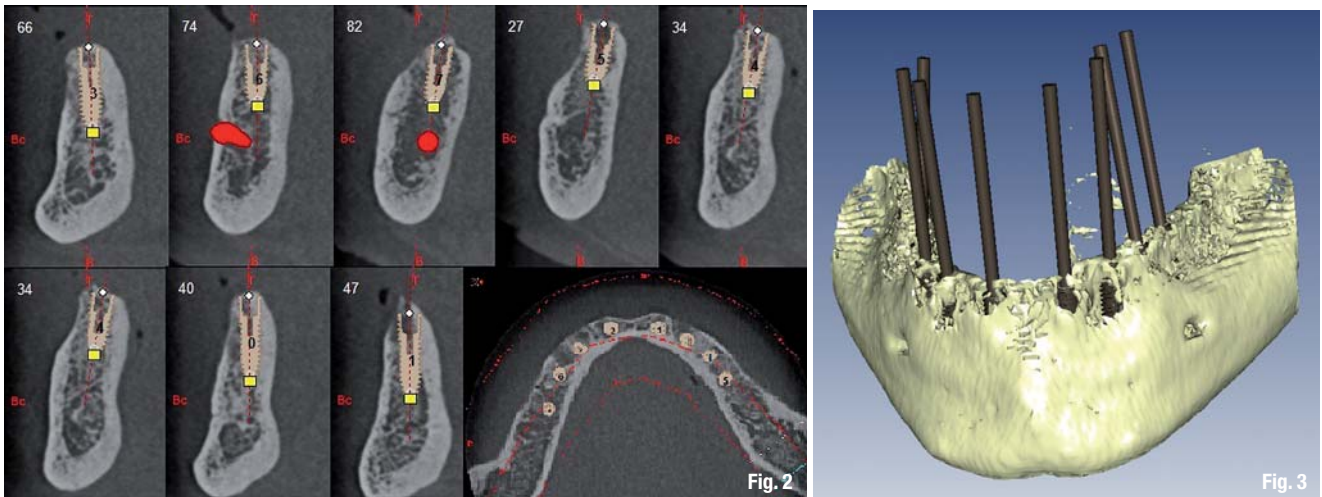
Early, mostly reversible therapy effects (mucositis) are differentiated from late, mostly permanent therapy effects (radioxerostomy, radiation caries, radiation fibrosis, risk of infected osteoradionecrosis (IORN)).²⁻⁵

Infected osteoradionecrosis (IORN) is the most severe local complication. Progressive osteolysis often can only be treated by partial resections of the jaw and they usually demand subsequent elaborate surgical rehabilitation.² IORN is often triggered by operations of the jaw or prosthesis pressure marks. In more than 60 % of IORN cases, infection stems from the dental area, which is increased by the factor three in cases of lacking periradiotherapeutic care.⁶

The extent of the extraction has been discussed controversially, but a selective diagnosis is recom-

Fig. 1_Preoperative condition: circular hybrid bridge in regio 16–26 with abutment teeth 12–23 and implants in regio 16, 14, 13, 24, 25, 26 and an edentulous mandible.





mended in radical extractions.² Further unwanted therapy effects are radiation caries, radio-induced xerostomia and radiation fibrosis. Radiation caries and conventional caries differ drastically in their incidence and course. An early rehabilitation of enamel and dentine lesions as well as therapy via fluoridation splints are significant aspects.^{7,8} Patients, however, see the greatest limitation in their quality of life in radio-induced xerostomia. In its process, many important functions of the saliva are lost. A lack in mucosa lubrication (physiological moistening of the mucosa) will only allow a limited adaptation of the gingivally-supported prosthesis, thus leading to an increase in the prevalence of prosthesis pressure marks. In addition, the remineralisation of enamel and the overall immune defence can be affected.⁹ Conventional prosthetic restorations will reach their lim-

its, consequently raising the demand to resort to implant-supported prostheses.

Implantation

Endosseous implants show five-year survival rates of 72 to 92%.¹ Loss rates are therefore above those of a non-irradiated jaw, but distinctly below those of natural, pre-radiotherapeutic healthy teeth of radiation therapy patients.² While data on titanium implants are available exclusively, there has been no scientific research on ceramics. Implants which have been inserted before radiation do not show any special features. However, peri-implant inflammation should be treated before radiation. While implantation is a significant aspect of tumour surgery¹⁰, implantation post radiationem occurs most frequently.²⁸ Usually, im-

Fig. 2_Virtual implant planning via IMPLA 3D, oro-vestibular cross section with Nervus alveolaris inf. (red).

Fig. 3_Virtual implant planning, depicting the axes.

Fig. 4_Intraoral situation before operation.

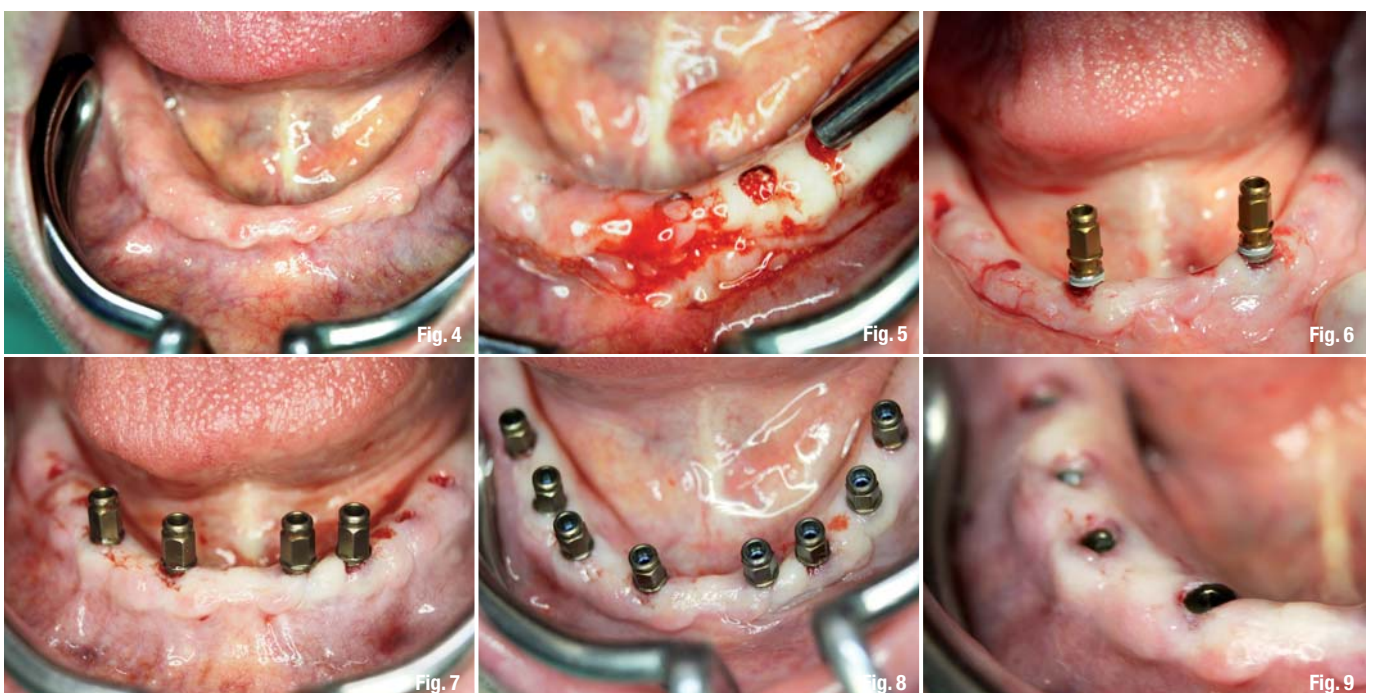
Fig. 5_Template positioned, with pilot drills in regio 33 und 34.

Fig. 6_Implants inserted in regio 33 and 34.

Fig. 7_Further insertion in regio 32 and 42.

Fig. 8_Condition after the planned insertion of eight implants.

Fig. 9_Condition after Insertion of the cover screws in the fourth quadrant.



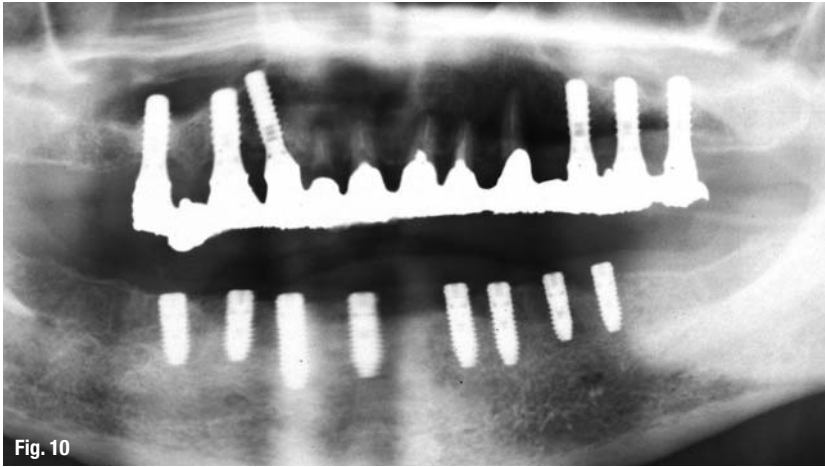


Fig. 10

Fig. 10 Postoperative OPG.

plantation is conducted six to twelve months after radiation, although the temporal interval between radiation and implantation has not been shown to have any influence on the prognosis of the implant.¹¹ The amount of time taken by the healing process is a different story. Here, a period of up to six months is average. Principally, bone augmentation after radiation therapy must be avoided.¹ Resulting from the necessity to minimise risks, three-dimensionally planned implant insertion is indicated, making flapless implantation and avoiding augmentation possible. Special local conditions often lead to an increase in the implant number in comparison to non-radiated patients.

Clinical case

A 70-year-old female patient presented with a circular hybrid bridge in regio 16–26 with abutment teeth 12–23 and implants in regio 16, 14, 13, 24, 25, 26 (Fig. 1). The mandible was edentulous and a removable prosthesis for teeth 36–46 was installed. The patient wished to have a fixed prosthesis for her lower jaw. She was diagnosed with a malign tumour of the salivary glands in 2009. As part of the pre-radiotherapeutic measures, all teeth were extracted from the mandible. Oncological treatment followed as a combination of radiation and surgical therapy. The tumour was removed in toto and no relapses occurred during the frequent recall sessions. Individual risk analysis and therapy planning were conducted in our practice. This included: identification of the radiation date, dose and the dose distribution in the head. Judging from the overall oncological prognosis of the patient, this allows for establishing an individual risk profile. For an absolute risk minimisation, template-guided implantation based on three-dimensional data (CBCT) was indicated. We aimed at making flapless operation without denudation of the radiated bone by template-guided implanta-

tion. Virtual implant planning (IMPLA 3D, Schütz Dental GmbH, Germany) gave the additional benefit of using the pre-existent bone material in total, with the aim of avoiding augmentative procedures (Fig. 2). With regard to the implant prognosis of radiated patients and the target of avoiding gingiva-based support, eight implants were planned in regio 36–46 for a conditionally removable bridge. OPG was used as a postoperative imaging procedure (Fig. 10).

Surgical procedure

As an adjuvant preoperative measure, the oral cavity was treated antiseptically (chlorhexidine 0.2%). Perioperatively, a systemic antibiotics was conducted (amoxicillin, 24 hours before surgery). After local anaesthesia, the template was positioned (Fig. 5), and eight pilot drills were performed. Expansion drills were done according to the manufacturer's protocol. After careful inspection of the drills via button probe, eight implants (IMPLA Cylindrical, Schütz Dental GmbH, Germany) were inserted (Fig. 8). By avoiding any incisions, sutures became dispensable. Punched areas were left to heal by themselves, based on granulation tissue formation (Fig. 9).

Conclusions

Positive long-term results prove the good prognosis for endosseous implants in the radiated jaw, which have a five-year survival rate of 72–92%.¹ However, it must be pointed out that these positive research outcomes were only achieved taking strict perioperative precautions and by close monitoring of the patient (implant recall).² An individual risk analysis and precise planning will support psychosocial integration by implant-supported rehabilitation of the masticatory function with predictable results.

Editorial note: A list of references is available from the publisher.

_contact

implants

Dr Umut Baysal

Dr Rainer Valentin
Deutzer Freiheit 95–97
50679 Cologne, Germany

u.baysal@gmx.de



Tribune CME



6 Months Clinical Masters Program in **Implant** Dentistry

2 May 2013 to 10 November 2013, a total of 12 days
in **Heidelberg (DE), Como (IT), Maspalomas (ES)**



Live surgery and hands-on with the masters
in their own institutes plus online mentoring and
on-demand learning at your own pace and location.

Learn from the Masters of Implant Dentistry:



Registration information:

2 May 2013 to 10 November 2013, a total of 12 days
in Heidelberg (DE), Como (IT), Maspalomas (ES)

Find out more on www.TribuneCME.com

Curriculum fee: **€ 11,900**

contact us at: tel.: **+49-341-48474-302** / email: info@tribunecme.com



Collaborate
on your cases

and access hours of
premium video training
and live webinars



University
of the Pacific

you will receive a certificate
from the University of the
Pacific



Latest iPad
with courses

all early birds will receive
an iPad fully loaded with
premium dental courses



100 ADA CERP
C.E. CREDITS

ADA CERP® | Continuing Education
Recognition Program

Tribune Group GmbH is the ADA CERP provider. ADA CERP is a service of the American Dental Association to assist dental professionals
in identifying quality providers of continuing dental education. ADA CERP does not approve or endorse individual courses or instructors,
nor does it imply acceptance of credit hours by boards of dentistry.

The **finesse** of the pink and the **power** of IPS e.max

Authors Rafael Santrich & Dr Larry Grillo, USA

Introduction

When damage to dentition is too severe for restorative treatment to be feasible, conventional dentures have been the treatment of choice. Conventional dentures, however, can be foul smelling and uncomfortable.¹ Additionally, jawbone resorption causes the dentures to become loose over time requiring readjustment of the jaw to ensure a proper fit.²

In some cases, if resorption has already occurred, the patient will no longer have sufficient bone structure to support dentures.² To overcome the disadvantages associated with conventional dentures, new implant materials and techniques have been developed, providing the growing edentulous population with more opportunities for functional, stable and comfortable treatments as well as decreased bone loss.³ Due to the amount of masticatory forces placed on the prostheses as a result of implant support, stronger, more durable substructures and denture teeth are necessary to accommodate wear.³

Zirconia is one of the strongest materials available in the dental industry today demonstrating a flexural strength of approximately 900–1,100 MPa.⁴ Ideal for high-stress restorations, including implant dentures, zirconia restorations boast a failure-free reputation according to current research.⁵ Designed and fabricated using CAD/CAM technology, zirconia substructures are stronger and more durable than traditional denture prostheses.⁶ Innovative techniques provide long-term and patient-pleasing results.

When fitted with customised lithium disilicate dentition, fixed implant prosthetics will not develop a foul

smell, require no realignment and provide a predictable, highly aesthetic and life-long solution. In addition, CAD/CAM technology can be used in the office or laboratory for indications including full-mouth restorations, fixed partial dentures, implant abutments, crowns, veneers, inlays, and onlays,⁷ contributing to faster and easier restorative treatments.

Suitable for restorations requiring high strength and exceptional durability, IPS e.max ZirCAD (Ivoclar Vivadent) is a yttrium-stabilised zirconia demonstrating a flexural strength of more than 900 MPa, and a fracture toughness of more than twice that of glass-ceramic materials.⁸

With approximately 50 per cent porosity, the pre-sintered blocks allow easy processing. Yet, once sintered to full density, its superior strength and inertness make it an ideal material for dental restorations.⁸ IPS e.max ZirCAD blocks (Ivoclar Vivadent) meet the functional requirements demanded by posterior masticatory forces.

Despite the use of different IPS e.max framework materials (lithium disilicate or zirconium oxide), aesthetic results can still be achieved due to a selection of natural and shaded pre-sintered zirconium oxide blocks for colour versatility, and when layered with aesthetic ceramic materials, such as IPS e.max Ceram (Ivoclar Vivadent), good aesthetics can be attained.⁹

The lithium disilicate ingots are specifically designed for press-on procedures indicated for zirconium oxide-supported gingiva portions, single-tooth restorations, anterior and posterior bridges, inlay-retained bridges, and implant superstructures.¹⁰

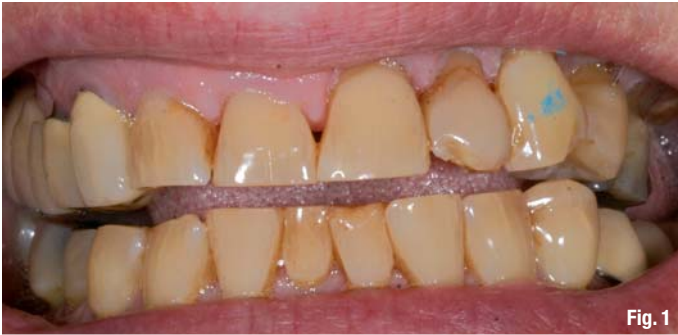

Fig. 1

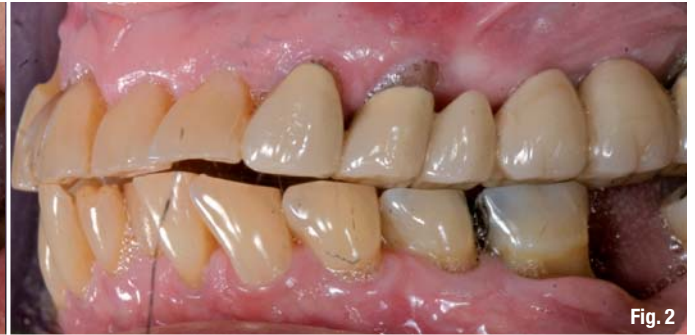

Fig. 2

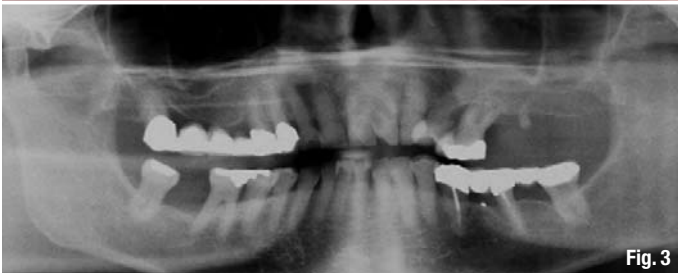

Fig. 3

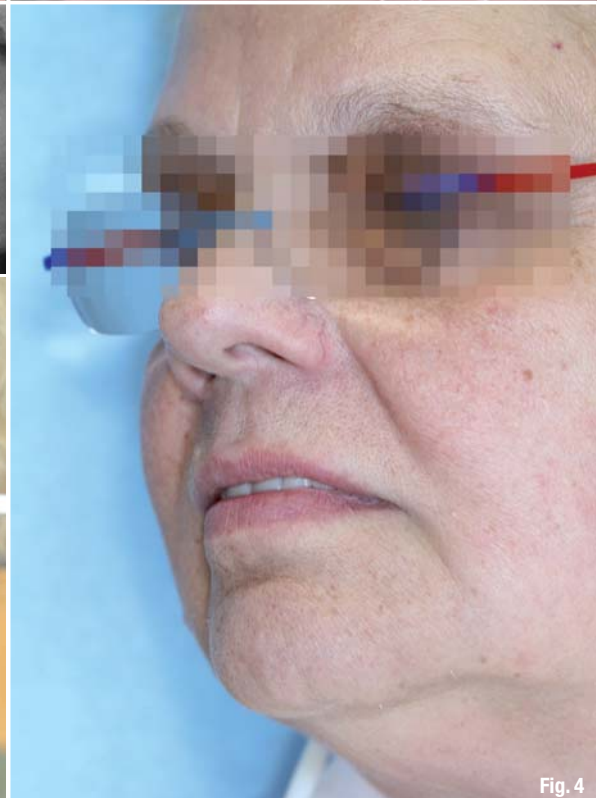

Fig. 4

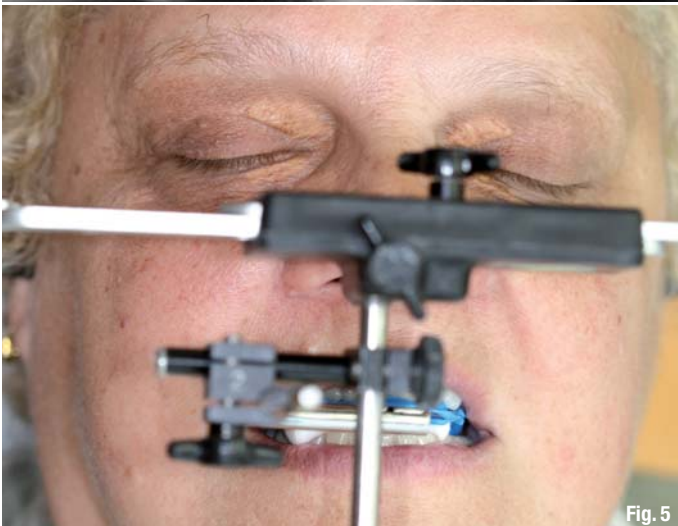


Fig. 5

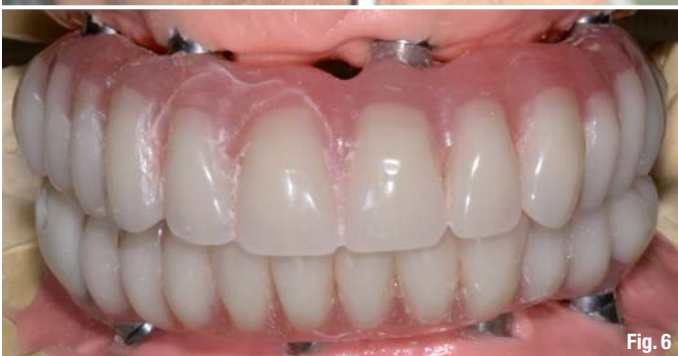

Fig. 6

Figs. 1 & 2_Preoperative images of the patient's dentition.

Fig. 3_Panoramic X-ray of the patient's mouth.

Fig. 4_Immediate dentures were placed the day of surgery.

Fig. 5_A face-bow transfer was performed.

Fig. 6_A zirconia-hybrid prosthesis would be fabricated for the upper arch and an acrylic prosthesis for the lower.

Fig. 7_Image of the duplicate denture.

Fig. 8_Plastic temporary abutment placed over the multi-unit abutment.

Fig. 9_Part A&B of the resin is mixed together.

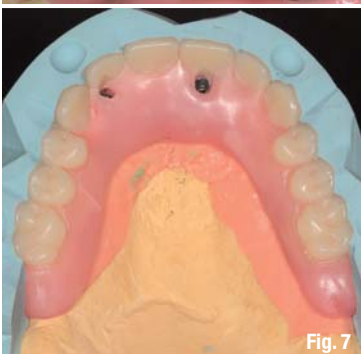

Fig. 7

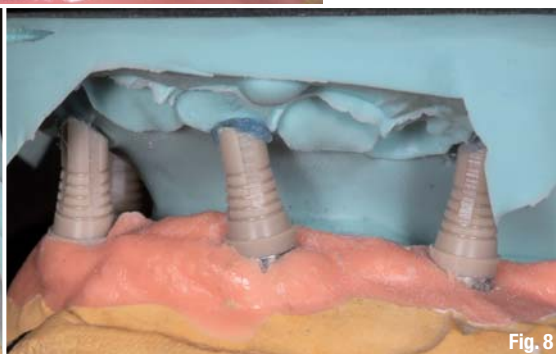


Fig. 8



Fig. 9

Fig. 10_The resin is applied to the denture.

Fig. 11_Image of the resin denture.

Fig. 12_The frame was designed and scanned.

Fig. 13_The zirconia frame was tried in.

Fig. 14_IPS e.max Ceram pink colours were chosen from the shade guide.

Fig. 15_The frame was characterised with Zirliner 1 and fired.

Figs. 16 & 17_A full-contour wax-up was completed.

Fig. 18_The frame was masked by layering IPS e.max Ceram in intensive pink porcelain, opal enamel white and opal violet.

Fig. 19_Characterisation of the porcelain was finalised using Essence stains.

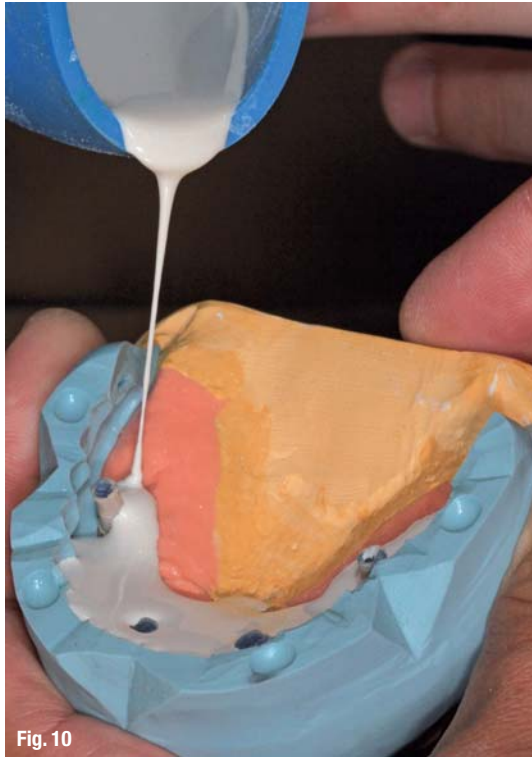

Fig. 10

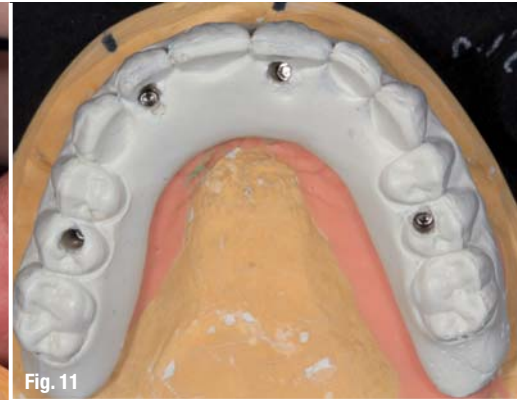

Fig. 11

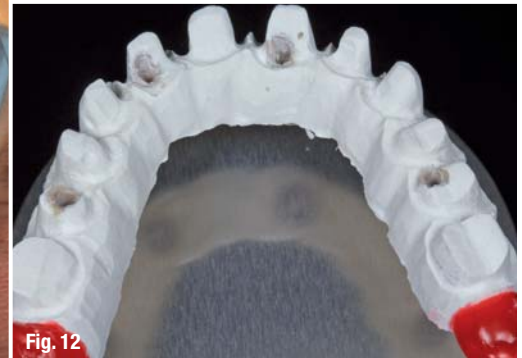

Fig. 12

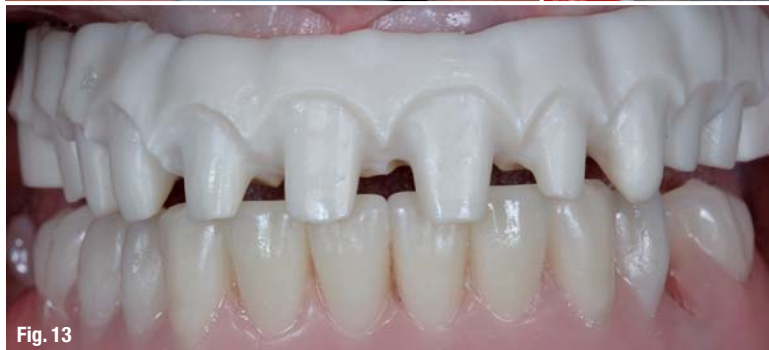

Fig. 13




Fig. 14

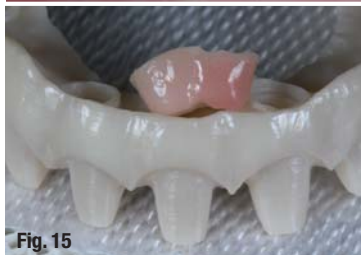

Fig. 15

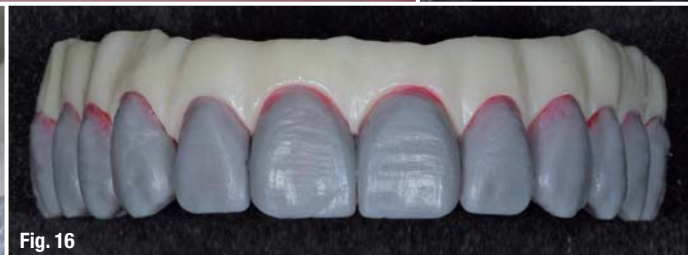

Fig. 16

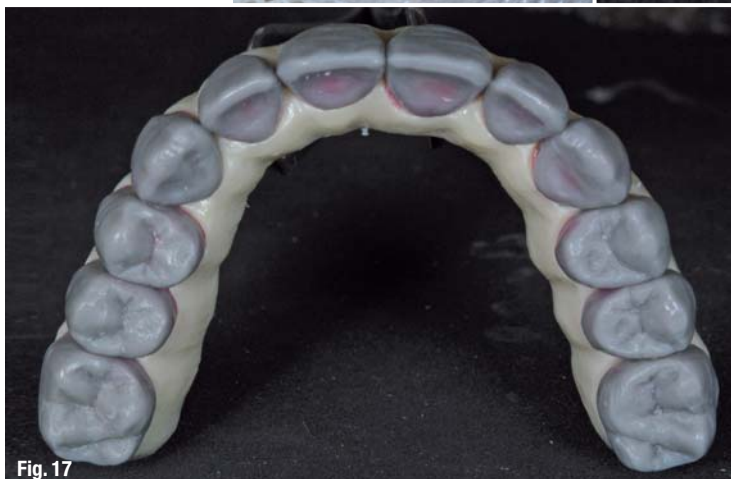

Fig. 17

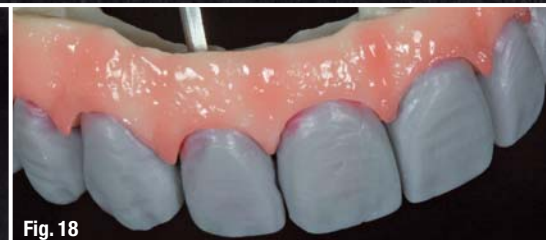

Fig. 18

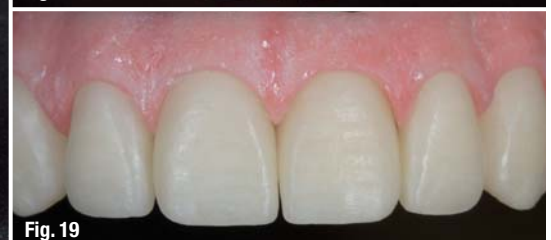

Fig. 19

Manufactured in nine block sizes, the larger ones suitable for long-span bridge frameworks or for stack milling and the smaller ones for copings, zirconia substructures can satisfy patient's demands for high-strength, highly aesthetic, functional, fixed prosthetic results.¹⁰

The All-on-4 treatment concept (Nobel Biocare) includes fixed and removable prosthesis and can be used in combination with a full-arch zirconia substructure as well as a variety of implants (Nobel Active, Nobel Biocare). The ability to screw a provisional prosthesis onto the implants directly after surgery provides edentulous patients with an immediate implant-supported restoration.¹¹⁻¹⁵ Accommodating a wide range of abutments and prosthetics, this technique benefits patients by providing an aesthetically pleasing, comfortable, stable and functional prosthesis.¹¹⁻¹⁶

Clinical Protocol

The patient presented with severely worn and damaged dentition (Figs. 1 & 2). After performing a panoramic X-ray of the patient's mouth, it was decided that the complete removal of all remaining teeth was necessary (Fig. 3). The treatment agreed upon was the application of the All-in-4 technique (Nobel Biocare).

Therefore, the first step was to guide the placement of the four RP Nobel Active implants, and the multi-unit transmucosal abutments used to facilitate tissue level emergence by creating a precision surgical implant guide. Once the implants were placed, impression copings were inserted, an impression was taken from which to create the master cast and immediate dentures were placed (Fig. 4).

A face-bow transfer was performed to idealise the parameters for a precision restoration (Fig. 5). At this point, the decision was made to fabricate a zirconia-hybrid prosthesis for the upper arch and an acrylic prosthesis for the lower (Fig. 6). A laboratory verification jig was created from the master cast to guarantee the accuracy of the final fit. To set tooth arrangement and function, an occlusal wax rim was created. The set-up was then screwed in, the bite verified, and phonetics, function, and aesthetics approved.

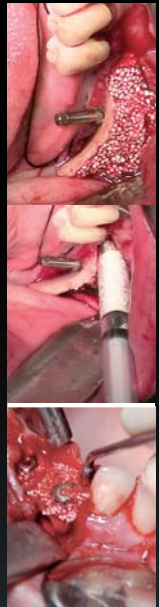Laboratory Protocol

The patient-approved immediate denture was duplicated and mid-line smile design and curve positions, i.e., Wilson spee, incorporated (Fig. 7). The plastic temporary abutment was placed over the multi-unit abutment (Fig. 8) and parts A and B of the resin were mixed and applied over the plastic abutment (Figs. 9 and 10), creating the resin denture (Fig. 11). The frame was designed and the scanning process performed (Fig. 12). The zirconia frame was tried in (Fig. 13). A variety of samples of IPS e.max Ceram were chosen from the shade guide to produce natural colouration and mask the white zirconia frame (Fig. 14). The colour was tested with the same background as the frame colour to evaluate the shade intensity of intensive dentin and dentin. The frame was characterised with Zirliner 1 and baked at 1,060 °C to create a bond between the zirconia and ceramic (Fig. 15).

A full-contour wax crown design was completed (Figs. 16 & 17). Intensive pink porcelain (IPS e.max Ceram) was built up to mask the frame and mixed with opal enamel white (OE4) and opal violet in specific areas to create a natural look. The bake speed was lowered to 35°C per minute, held for one minute at 760 °C, cooled at a rate of 25 °C per minute and held at 350 °C for 15 minutes (Fig. 18).

Characterisation of the pink porcelain was finalised using Essence stains (Ivoclar Vivadent). Low speed rates were used to fire the glaze. Fired at 35 °C to 730 °C for one minute, the glaze was then slowly cooled at 25 °C per minute and finally held at 350 °C for 15 minutes (Fig. 19). Next, the crowns were glazed with shades one and two of copper, white, cream, profundo, mahogany, ocean and sunset, then baked at 775 °C per one minute hold (Figs. 20-25).

sticky granules
bionic



easy-graft®
CRYSTAL

Ingenious: Simple handling and accelerated osteoconduction for long-term volume preservation.

SUNSTAR
GUIDOR®

Degradable Solutions AG
A Company of the Sunstar Group
Wagistrasse 23
CH-8952 Schlieren / Zurich
www.easy-graft.com

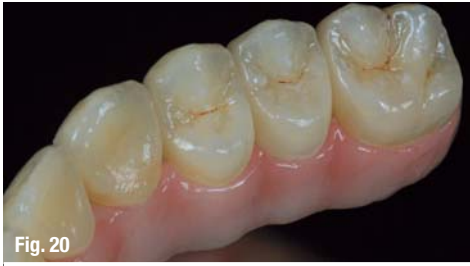

Fig. 20

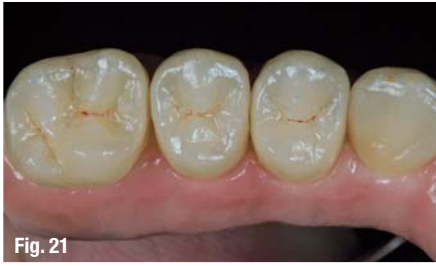

Fig. 21

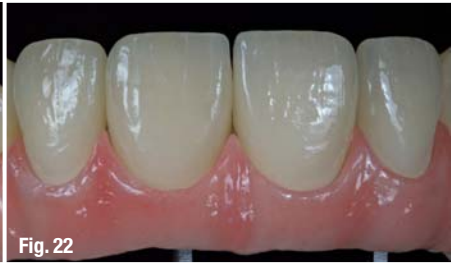

Fig. 22

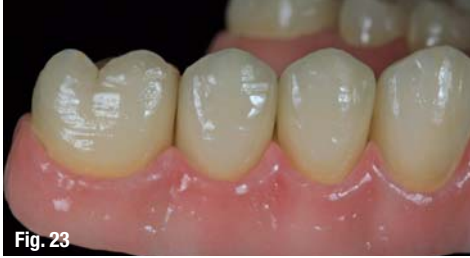

Fig. 23

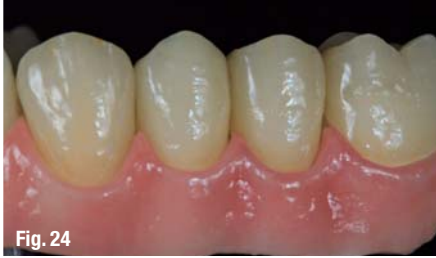

Fig. 24

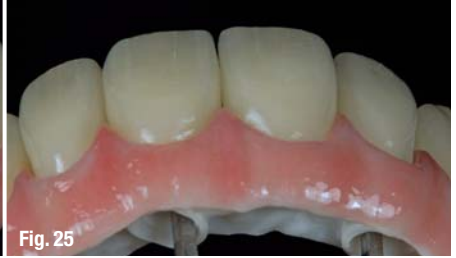

Fig. 25

Figs. 20–25 The crowns were characterised with shades one and two of copper, white, cream, profundo, mahogany, ocean and sunset, then fired.

Fig. 26 The case was ready for bonding.

Figs. 27–29 The case was primed with Monobond.

Fig. 30 The IPS e.max crowns were etched with 5 per cent hydrofluoric acid.

Fig. 31 The crowns were cemented into place, leaving the screw holds vacant.

Fig. 32 Image of the healthy soft tissue and the angulation of the multiunit abutments.

Fig. 33 The case was torqued into place.

Fig. 34 Image of upper arch with IPS e.max crowns and the Phonares acrylic teeth in the lower arch.

Fig. 35 Postoperative occlusal view verifying balance and occlusion.

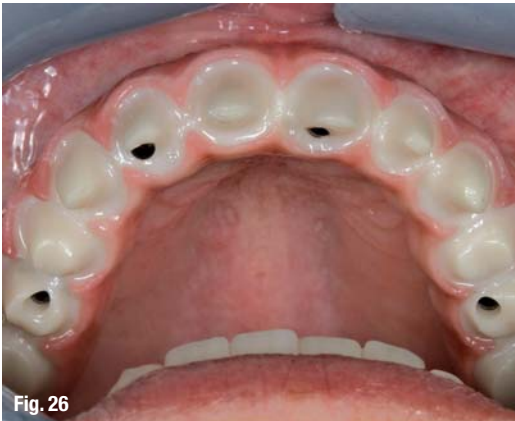

Fig. 26

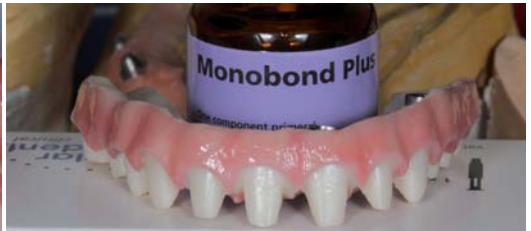

Fig. 27

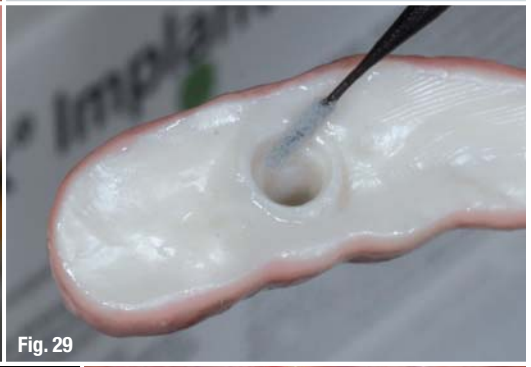

Fig. 29

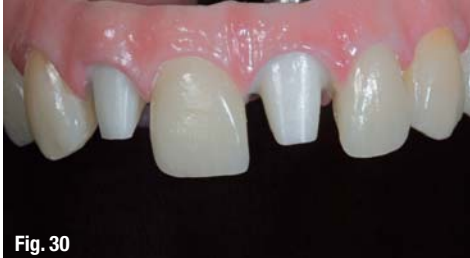

Fig. 30

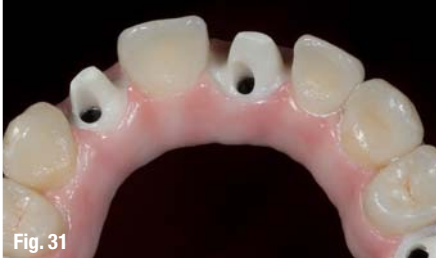

Fig. 31

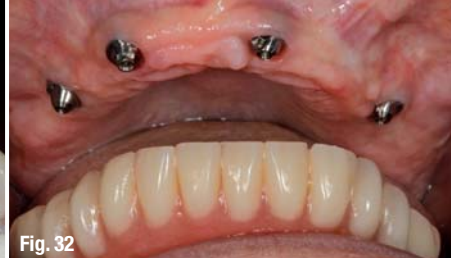

Fig. 32

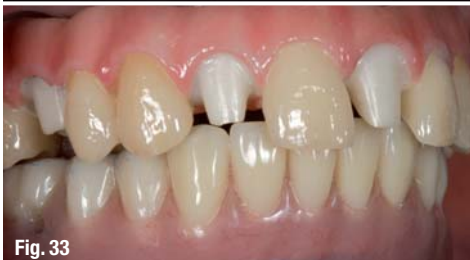

Fig. 33

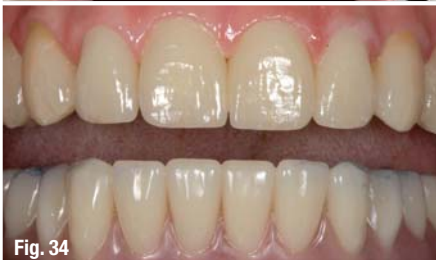

Fig. 34

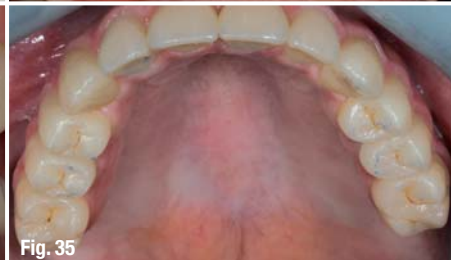

Fig. 35

_Seating

Once the patient was satisfied with the colour, phonetics, and smile line (Fig. 26), the case was prepared for bonding. The zirconia and titanium were primed (Monobond, Ivoclar Vivadent) to create mechanical and chemical retention in both materials. The case was then cemented using universal adhesive implant cement (Multilink Implant, Ivoclar Vivadent, Figs. 27–29).

Prior to cementing the crowns in place, they were etched with a 5 per cent hydrofluoric acid for 20 seconds (Fig. 30). All crowns were cemented into place except those that fit over the screw holds (Fig. 31), which would be cemented once the case was seated (Fig. 32). Finally, the dentures were torqued into place (Fig. 33). IPS e.max crowns were used in the upper arch and Phonares acrylic teeth in the lower (Fig. 34) to equipoise the forces and achieve a balanced occlusion providing the patient with the highest quality of function and phonetics (Fig. 35).

_Conclusion

Previously limited to sometimes ill-fitting and painful false teeth, edentulous patients today have a variety of sophisticated treatment options. Due to

their ease of use, predictability and its many advantages, CAD/CAM technology, pressable and milled ceramic materials and new implant structures enable dentists and laboratories to provide comfortable, stable and aesthetic treatments to edentulous patients.⁷

Newly developed, innovative alternatives are more durable, aesthetic and last longer compared to conventional options. Implant-supported dentures fabricated with materials such as zirconia and IPS e.max ZirPress not only demonstrate superior characteristics, but are stronger and more durable.^{3,17} Modern procedures and materials can satisfy patient demands by providing denture treatments that are long-lasting, strong and aesthetically pleasing.

_contact

implants

Rafael Santrich
Dental Designer

VM Lab Technologies
Advancing in Science & Art of Restoration

vmlab@me.com

AD

SMALL IN SIZE, GREAT IN PERFORMANCE...



IMPLA Mini-conetop:
specifically developed for supporting bar constructions



IMPLA Mini-balltop:
excellently suited to the overdenture technique

Dr. medic. (RO) Ch. Jerecinski, MSc., Paderborn
„IMPLA Mini implants are defined by their very high primary stability and the fact that they can be easily inserted.“



IMPLA Mini Implants

- » 50 years' experience in implantology
- » sand-blasted and acid-etched surface
- » minimally invasive procedure
- » short drilling protocol = shorter surgery times
- » economic implant restoration

Further information:
www.schuetz-dental.com

Newsletter registration:



Scan me.

<http://sdent.eu/newe>

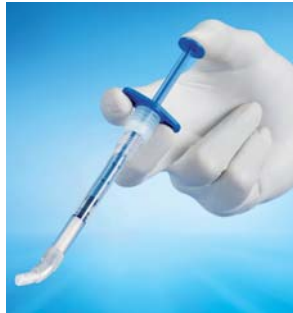

Manufacturer News

Geistlich

Bio-Oss Pen®—Convenience Dentists Need

The number 1 bone substitute* is again leading the way in oral bone regeneration. The Geistlich Bio-Oss Pen® is putting improved precision power into the hands of oral surgeons. With the new applicator, Geistlich Bio-Oss® granules are conveniently delivered to the surgical site. In a recent survey**, Geistlich Bio-Oss® users revealed the Geistlich Bio-Oss Pen® to be a



welcome new tool with excellent handling properties. device, we asked Geistlich Bio-Oss® users to judge the parameters of clinical user-friendliness and technical aspects. Nine out of ten dentists who tested the Geistlich Bio-Oss Pen® were convinced that the streamlined design provides an advantage. Geistlich Bio-Oss®, which has proven itself in clinical use for more than 25 years, fills the pen.

With a track record of good functional and aesthetic results, predictable outcomes, and long term success, dentists can rely on the new Geistlich Bio-Oss Pen® with the same confidence as with the Geistlich Bio-Oss® vials: nothing changed—just improved.

The pen design simplifies handling of the biomaterial particles by allowing accurate delivery of Geistlich Bio-Oss® granules to the surgical site. A curved applicator tip facilitates optimal access to defects, particularly in posterior regions difficult to reach. The Geistlich Bio-Oss Pen® is available in three variants: large granules (0.5g ~1.5cc) and small granules (0.25g ~0.5cc; 0.5g ~1cc). To evaluate the performance of the new

Planmecca

Brand-new CAD/CAM innovations

For Planmecca, the IDS trade fair was the ideal stage for proving its exceptional capabilities. At IDS, the company presented the Planmecca PlanMill™, an innovative CAD/CAM milling unit for high-precision prosthetic work. There are two versions of the fast, precise milling units available to provide the ultimate digital workflow both in dental surgeries as well as in the laboratory. Planmecca PlanScan™ is the first intra-oral scanner that can be fully integrated into a dental unit for digital 3-D scanning. Alternatively, this high-performance intra-oral scanning device can also be connected to a laptop. Planmecca PlanScan™ Lab is a new, highly precise and maintenance-free dental laboratory scanner. The intuitive interface makes scanning plaster models easy while providing reliable results.



the best available technology was already causing a stir right at the start of the IDS,” says Dieter Hochmuth, Managing Director of Planmecca Vertriebs GmbH.

“Dentists and dental technicians have varying ideas about the features and performance required of the devices they use, although both groups value ease of use very highly. With attractive IDS offers, we make top technologies accessible for all. This democratisation of

Planmecca Vertriebs GmbH

Walther-Rathenau-Str. 59
33602 Bielefeld, Germany

info@planmecca.de
www.planmecca.com

Ritter Implants System

Quality. Flexibility. Innovation. Made in Germany.

Founded in 1887 by the German Frank Ritter in New York, Ritter is one of the oldest prestige brands of finest dental equipment worldwide. Based on innovative ideas and a great entrepreneurial spirit, Ritter produced the first dental units already more than 125 years ago.

Today, Ritter products more than ever are an essential element in dental practices worldwide. Users appreciate the Ritter product range for their high-quality aspects and their reliability made in Germany. Due to their functionality and user-orientated construction, Ritter dental units contribute constantly to an optimised workflow of today’s modern dental practices.

In the course of the last years, Ritter has started to write a new success story with the launch of an innovative, state of the art implant system. The Ritter Implant Ivory Line provides two-piece Implants, such as the QSI Spiral Implant and TFI Twin Fissure Implant, as well as



one-piece implants called Mono Compress Implant MCI. Due to the super Nano surface, a quick and reliable osseointegration is guaranteed. Easy handling is provided by self-tapping threads and a coloured system of drills and implants according to their diameters.

Ritter Implants GmbH

Gruener Weg 32
88400 Biberach/Riß, Germany

info@ritterconcept.com
www.ritterconcept.com



* iData Research Inc., US Dental Bone Graft Substitutes and other Biomaterials Market, 2011.
iData Research Inc., European Dental Bone Graft Substitutes and other Biomaterials Market, 2012.
**Geistlich Pharma AG practice test, June 2012.

Camlog

Radically rethinking implant systems

The new implant brand iSy by CAMLOG was introduced at the 35th International Dental Show in Cologne. As the first premium manufacturer, CAMLOG in Germany is offering a more cost-effective solution for cases that allow the use of simple, standardised implant treatment concepts.

iSy stands for “intelligent System” and with just 70 components, iSy is extremely lean and allows treatment of most standard and low-risk cases. Even aesthetically demanding solutions can be realised thanks to the integration of CAD/CAM prosthetics. The concept also includes simplification of the



processes in the practice—from placing the implant to order and parts management to continuing education and training. The high degree of standardisation of all system components makes it possible for CAMLOG to offer iSy at a very attractive price without compromising quality. The products are all manufactured by CAMLOG in Wimsheim, Germany. The prosthetic assortment is also designed for maximum efficiency. For the final prosthetic restoration of iSy implants, a universal abutment, titanium-based CAD/CAM in two different gingival heights and Locator® abutments in five different gingival heights are available. iSy is also perfectly coordinated with the CAD/CAM solutions of CAMLOG. The implants are manufactured from titanium (titanium Grade 4) and have the Promote® surface with micro-macro structure familiar for the CAMLOG® and CONELOG® Implant System.

CAMLOG Biotechnologies AG

Margarethenstrasse 38
4053 Basel, Switzerland

info@camlog.com
www.camlog.com



Schütz Dental

Small in size—great in performance

Only three steps lead you to a safe implant restoration: a pilot hole, extension drilling and the insertion of the implant. If a two-piece implant is not an option for your patient, you can now offer an economic alternative: one-piece IMPLA Mini implants. IMPLA Mini implants feature a blasted and etched surface. They are available with two different heads: Mini-balltop is excellently suited to the overdenture technique while Mini-conetop was developed specifically for supporting bar constructions, if only limited space is available.

One-piece implants offer you a minimally invasive procedure and a short drilling protocol. The result: shorter surgery times. This means both you and your patient will benefit from a more economic implant restoration. IMPLA Mini implants can be inserted with the IMPLA surgery tray. Alternately, you can use the small IMPLA Mini surgery tray, put together especially for this purpose. Of course, all IMPLA Mini implants and the IMPLA surgery trays are “Quality made in Germany”.



Schütz Dental

Dieselstr. 5-6
61191 Rosbach, Germany

export@schuetz-dental.de
www.schuetz-dental.com

Straumann

New CAD/CAM prosthetic solutions

Straumann presented the new CARES Visual 8.0 software at the International Dental Show (IDS) in Cologne, Germany. The new software optimises digital workflows, increases design flexibility, improves ease of use, and extends Straumann’s prosthetic portfolio for implant- and tooth-borne restorations.



CARES 8.0 includes efficiency-driven functionalities such as simultaneous scan and design, mirror anatomy, intuitive design of screw-retained bars, and additional time-saving solutions. It also supports the proven concept of original prosthetics on original implants. Dental labs can use these latest features to work faster and more efficiently, result-

ing in a competitive advantage in a challenging marketplace.

With CARES 8.0, Straumann has completed the integration of its CAD/CAM system into the Dental Wings Open Software (DWOS) platform, offering customers an open system with innovative features and functionalities. Users now have several data input possibilities and the option of producing prosthetics through the CARES validated workflow or through an alternative milling process. CARES Visual 8.0 is free of charge for Straumann CARES customers running up-to-date software licenses.

Institut Straumann AG

Peter Merian-Weg 12
4052 Basel, Switzerland

info@straumann.com
www.straumann.com

AD

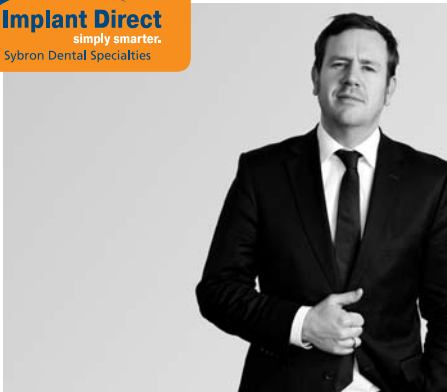become an author for "implants"

Please contact Claudia Jahn
✉ c.jahn@oemus-media.de

Implant Direct Europe

Product portfolio to expand in 2013

“This year, Implant Direct will be presenting product innovations in all four implant ranges. At the IDS trade fair, we presented the first Legacy™4 prototype in our Innovation Area and discussed potential variations on the concept with our guests,” said Timo Bredtmann, Sales Director Germany at Implant Direct. “The topic of compatibility plays the leading role in our corporate strategy. This is because, without cross-compatibility, only very few dental surgeries would be able to benefit from the improvements developed by Implant Direct. As such, the Tri-Lobe system is compatible with Nobel Biocare™, the Swish system is compatible with Straumann®, and the Legacy system with Zimmer® Dental.”



The products offer the ideal solution for the indication in question, regardless of experience or number of cases. “Our customers are faced with the challenge of solving individual cases—which is why we offer suitable products for this purpose. We expect that the concept of a mini version (3.0 mm diameter) of our GoDirect one-piece Locator implant will cause a real stir,” says Bredtmann. GoDirect offers all the advantages of the Locator with a one-piece construction and is a cost-effective solution for hybrid treatments.

It was also clear at the IDS that the Implant Direct product portfolio is set to expand with prosthetic elements and biomaterials. These innovations will be showcased in themed areas on the homepage, online shop and during advisory discussions at the dentist's surgery.

Implant Direct Europe AG

Hardturmstrasse 161
8005 Zürich, Switzerland

info@implantdirect.eu
www.implantdirect.de

Bicon Dental Implants

Simple. Predictable. Profitable.

Since 1985, the Bicon Dental Implant System has offered dentists a proven solution for missing dentition. The Bicon implant design comprises plateaus, sloping shoulders and a bacterially-sealed, 1.5° locking taper implant to abutment connection. With the plateau design, cortical like bone forms around and between each plateau. This Haversian bone allows for the routine use of 5.0 mm short implants. The sloping shoulder provides the necessary room for bone to support interdental papillae that are gingivally aesthetic. Bicon's 360° of universal abutment positioning provides for the revolutionary cementless and screwless Integrated Abutment Crown™, which consistently provides for a non-metallic aesthetic gingival margin.



Bicon Dental Implants

Arborway 501
Boston, MA 02130, USA

support@bicon.com
www.bicon.com

Degradable

Easy treatment of extraction sockets without membranes

To limit atrophy of the alveolar crest after tooth extraction, procedures in which the sockets are filled with bone or bone graft substitutes (socket preservation) are used in addition to gentle tooth extraction. The synthetic bone graft substitutes easy-graft™CLASSIC (β-TCP, completely bioresorbable) and easy-graft™CRYSTAL (60% HA/40% β-TCP, partly bioresorbable) are particularly suited for crest preservation after tooth extraction. After thorough cleaning and preparation of the socket, which must be free of inflammation, the putty-like easy-graft™ material can be applied directly from the syringe. Packing the material flat ensures intimate contact between the bone bed and the augmentation material. The granules are pressure resistant and do not chip. easy-graft™ is suitable for membrane-free application in four-walled sockets. Upon contact with blood, the porous material hardens in the extraction defect to form a solid body. Approximating the wound edges is sufficient and in many cases a tight wound closure is not required. Integration of the material occurs with an open technique. Mem-



brane-free techniques have the advantage that flap formation is prevented. Membrane-free techniques for socket preservation are possible with materials that harden in situ—for safe, minimally invasive crest preservation, ensuring the patient's wellbeing.

Degradable Solutions AG

A company of the SUNSTAR Group
Wagistrasse 23
8952 Schlieren, Switzerland

info@degradable.ch
www.easy-graft.com

IDS 2013 sets new records

Source_Koelnmesse GmbH

The 35th International Dental Show (IDS) posted record-setting results when it closed on Saturday, 16 March 2013, after five days in Cologne. The world's leading dental trade fair attracted 125,000 trade visitors from 149 countries. That figure represents an increase of six per cent compared to the previous event. Records were also set in terms of the number of exhibitors and the occupied exhibition area.

This year 2,058 companies (+5.3 per cent) from 56 countries presented a wide range of innovations, products and services on 150,000 square metres of exhibition area (+3.4 per cent). With 68 per cent of the exhibitors and 48 per cent of the visitors coming from abroad, the fair was also more international than ever before. "The degree to which IDS's global attraction increases from one event to the next is impressive," said Dr. Martin Rickert, Chairman of the Executive Board of the Association of German Dental Manufacturers (VDDI). "Thanks especially to the trade visitors' high level of internationality and decision-making authority; we expect the positive effects of the fair to continue for the rest of the business year. We're also expecting sustained growth in the German and international healthcare markets."

Trade visitors were also highly satisfied with the event. The visitor survey revealed that 74 per cent of visitors said they were (very) satisfied with IDS. What's more, the fair's comprehensive spectrum of products and numerous innovations caused 79 per cent of the visitors to rate the product range as either good or very good. In terms of reaching their trade fair goals, 74 per cent of the visitors surveyed said that they were satisfied or very satisfied. Overall, 95 per cent of the visitors surveyed would recommend a visit to IDS to their business partners.

"IDS is the top event for the dental market. In 2013, it again drew the attention of the international dental world," concluded Dr. Peter Engel, President of the German Dental Association (BZÄK). "Demographic developments will make continuous updates of healthcare structures necessary, and they will be dependent on technical advances and innovative therapies. At the trade fair, the industry has impressively demonstrated its ability to meet this challenge. But brainstorming for a (dentally) healthy future isn't required within the

dental sector alone. It also has to come from public policymakers. Germany is at an excellent international level technically and scientifically, as was demonstrated by this year's IDS. However, austerity regulations are making it more difficult for innovations to make their way to the dentists' practices."





CAMLOG Biotechnologies AG
Jordi Belart, COO

“For CAMLOG, this year’s IDS has been a full success”

At IDS 2013, CAMLOG introduced their new implant brand „iSy“, an innovative approach to implant dentistry. iSy Implant System offers implantologists extremely efficient, streamlined solutions for indications that allow the use of simple, standardised implant treatment concepts. With no more than 70 components, iSy is a highly “intelligent”, exceptionally lean implant system that stands for the simplification of processes in the dental office. Even aesthetically demanding solutions can be realised with iSy thanks to the integration of CAD/CAM prosthetics. However, we did not only launch iSy, the new implant system, but also announced our cooperation with Ivoclar Vivadent as “Authorised Milling Partner”.

With our brand DEDICAM, CAMLOG addresses the increasingly important CAD/CAM market and has thus become a supplier of choice of customised dental prosthetic components of the highest functional and aesthetic quality. The extensive DEDICAM portfolio will include abutments, bridges, bars, crowns, inlays, onlays and veneers made of materials such as tita-



nium, cobalt-chrome, ceramic and plastic. Presently, iSy and DEDICAM are only available in Germany but further countries will follow soon. CAMLOG is highly pleased to have experienced extremely positive feedback regarding both systems since these were introduced in Cologne at IDS 2013.

At IDS 2013, we were present with two booths, one for CAMLOG and one for the iSy Implant System. We held a press conference in which we informed first-hand about our innovations. For CAMLOG, this year’s IDS

has been a full success and our product launches have received an enormous amount of attention. We were able to foster existing relationships, had numerous contacts and also attracted considerable interest from potential future customers. As CAMLOG’s Chief Oper-



ations Officer, I particularly appreciate the IDS getting more and more international; both with regard to visitors and to exhibitors. For us as an internationally active company, this is of major importance.



Implant Direct Europe
Timo Bredtmann, Sales Director Germany

“A variety of products from one single source”

In our IDS Innovative Area, we presented implant prototypes which will be launched in 2013. There will be new products for all four implant lines. The refinement and improvement of already existing implant concepts as well as their compatibility with any needs of modern implant practices will make our system accessible for a wide range of users. For example, the new Legacy™4 will expand the spectrum of the already existing surgical and prosthetic measures of the Legacy series, multiplying the opportunities for its users. The Legacy system already guarantees a maximum of flexibility: six different diameters and five different lengths.

At IDS, it became obvious that our product portfolio has been expanded by prosthetic elements as well as an extensive product range in biomaterials. Visitors there-



fore experienced Implant Direct as an active member of the large dental Danaher group Sybron, along with KaVo and KerrHawe.

Our four implant lines, the prototypes of the new products and the advantages of compatibility seemed to have a magnetic effect on our visitors. Many of our guests were interested in our Biologicals—membranes, bone substitutes and suture materials. In addition, our visitors were enthralled by the advantages of a broad variety of prosthetic products coming from one single source.

IDS 2013 has been a great opportunity to directly compare product solutions and services. Where, if not in Cologne, is there a better chance to investigate both promises and benefits? Our visitors expressed their appreciation of our guiding principle “simply smarter”, describing both how we develop our products and how we present them to our customers.



Planmeca Vertriebs GmbH
Dieter Hochmuth, Managing Director

“A successful surprise”

For Planmeca, one of the market leaders in CBCT/ X-ray, the IDS trade fair was the ideal stage for proving its exceptional capabilities. At the IDS, the company presented the Planmeca PlanMill™, an innovative CAD/CAM milling unit for high-precision prosthetic work. There are two versions of the fast, precise milling units available to provide the ultimate digital workflow both in dental surgeries as well as in the laboratory.



Planmeca PlanScan™ is an ultra-fast intra-oral scanner for open CAD/CAM systems. Planmeca PlanScan™ is the

As a four-axis milling unit with an automatic six-tool changer, the surgery version can mill either wet or dry glass-ceramic, zirconia, PMMA and wax. In the laboratory version, the five-axis milling unit with automatic ten-tool changer can also process materials in standard ø 98 mm slices or blocks.

first intra-oral scanner that can be fully integrated into a dental unit for digital 3-D scanning. Alternatively, this high-performance intra-oral scanning device can also be connected to a laptop. The system offers exceptional user-friendliness and supports the perfect digital workflow.

Planmeca PlanScan™ Lab is a new, highly precise and maintenance-free dental laboratory scanner. The intuitive interface makes scanning plaster models easy while providing reliable results. Other advantages include automatic lens calibration, open STL, PLY and OBJ files. The scanner comes with Planmeca PlanCAD™, the perfect design tool for prosthetic work. With the innovative 3 x 3-D combination, Planmeca offers yet another industry first: DVT + 3-D facial photo + 3-D surface scan. “Dentists and dental technicians have varying ideas about the features and performance required of the devices they use, although both groups value ease of use very highly. With attractive IDS offers, we make top technologies accessible for all. This democratisation of the best available technology was already causing a stir right at the start of the IDS,” says Dieter Hochmuth, Managing Director of Planmeca Vertriebs GmbH. You can enquire about Planmeca’s IDS offers and order them directly by calling +49 521 560665-0 before 30 June.



Ritter Concept GmbH
Lutz Meyer, Marketing Manager

“Coming from the heart”

Ritter has started to write a new success story with the launch of an innovative, state of the art implant system, which was extremely well received at the IDS in Cologne. The Ritter Implant Ivory Line provides Two Piece Implants (Implant plus separate Abutment) as the QSI Spiral Implant and TFI Twin Fissure Implant as well as One Piece Implants (Implant and Abutment already connected) called Mono Compress Implant MCI. The system contains logically reduced and clearly arranged components of tools and abutments with the best features for all clinical cases. Due to the super Nano-Surface, a quick and reliable Osseointegration is guaranteed. Clever and easy handling is provided by self-tapping threads and a coloured system of drills and implants according to their diameters. Also Ritter presented three new prototypes with their dental units Contact Blue, Excellence Plus and Contact Comfort, which were received well by industry professionals.

These units come with a fantastic price, especially with regard to touchscreen displays. They have additional features and they can be pivoted to the left and to the right. Another innovation is the X-ray device Sirix VA-2.0. It is available in a mobile as well as a wall-mounted version and convinces by its novel design. Already on the first day of IDS, we experienced great feedback and success. We are glad that our efforts have paid off!

Our overall impression of IDS is positive: the concept of our booth as well as our products and innovations were praised by many visitors. They especially liked that they were given time to explore the products and enjoy the very special and familiar atmosphere at our booth. With regard to the development of the dental industry in general, I assume that there will be more investments in the future. Particularly for Ritter Germany, the de-

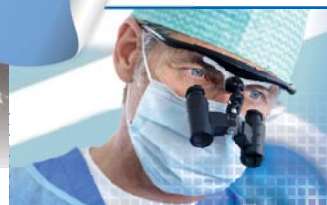

mand has grown unmistakably. For a year, we have been open to dental depots and we are glad that many loyal customers, who have been working on one special dialogue or format for 30 years, will again acquire their product of choice.



Osteology celebrates its 10th anniversary!

Regenerative Dentistry WITHOUT OSTEOLOGY is like dentistry without journals



INTERNATIONAL SYMPOSIUM

OSTEOLOGY MONACO

MAY 2-4, 2013

www.osteology-monaco.org

From 2 to 4 May, Monaco was the backdrop for the fourth International Osteology Symposium. The annual symposium has become established as one of the key series of congresses on oral regeneration in recent years. The event once again linked scientific expertise to specific practical needs and furthermore marked the tenth anniversary of the Osteology Foundation. As a result, 2,700 participants from around the world were drawn to this international platform on bone and tissue regeneration.

The two congress chairmen Niklaus P. Lang, Switzerland, and Massimo Simion, Italy, have put together a programme on decision-making with oral-tissue regeneration. Speakers of international repute shared their expertise on bone and soft-tissue regeneration and showcased practical treatment concepts. Several workshops, which were held the day before the congress, aimed at taking participants beyond theo-

retical exchange. These included seven practical and two theoretical workshops on various topics, including flap and suture techniques, soft-tissue augmentation, recession coverage, peri-implantitis and socket sealing.

From 2 bis 4 May, the Grimaldi Forum opened its gates to the 4th Osteology Symposium at Monaco's most Eastern beach Larvotto. More than 80 speakers offered interesting insights to their research, their experiences in oral regeneration and therapy concepts for the dental practice.

On Friday, the official Osteology press conference was held at the Van Dongen Room of the Grimaldi Forum. Prof. Dr Christoph Hämmeler, Prof. Dr Niklaus Lang, Prof. Massimo Simion and Dr Paul Nolte informed the audience on the history and future activities of Osteology, periodontitis and periimplantitis therapy, and standards and perspectives in oral bone and tissue regeneration. The Osteology research price was given to the best presentations in the categories basic and clinical research by a scientific committee.

The customary osteology celebration was held in the Salle des Etoiles on Friday evening. All in all, Osteology once more did justice to the foundation's purpose "Linking Science with Practice in Regeneration".

Fig. 1 Prof. Dr Christoph Hämmeler (President Osteology Foundation) gave insights to the foundation's anniversary and its activities.

Fig. 2 Niklaus P. Lang (Scientific Chairman), Massimo Simion (Scientific Chairman Osteology), Dr Paul Nolte (CEO Geistlich Pharma and Board Member der Osteology Foundation).

Figs. 3-6 Impressions 4th Osteology Congress in Monaco.

Be scientific!

Invitation for poster submission



In accordance with their 43th International Annual Congress from 4 to 5 October 2013 in Berlin, DGZI (German Association of Dental Implantology) will also offer poster presentations to the participants. As part of the corresponding poster com-

petition, three winners will be elected among the participants. Along with a financial reward, winners will be given the opportunity to hold their own scientific speech at the upcoming DGZI Annual Congress.

Participants can submit their posters until 31 August 2013. They should be submitted in print, DIN-format A0 (841 x 1,189 mm) and can be in landscape or portrait format.

DGZI e.V.

Prof. (Cairo University) Dr Roland Hille
Paulusstr. 1
40237 Düsseldorf, Germany

Tel.: +49 211 16970-77
Fax: +49 211 16970-66

dr-hille@t-online.de

Early-morning smokers

Greater risk of oral cancer

A recent US study of almost 2,000 adult smokers has revealed that people who smoke a cigarette upon waking in the morning are significantly more likely to develop oral or lung cancer. The researchers found that participants who smoked the soonest after getting up were the most at risk.



Researchers from the Pennsylvania State University analysed urinary samples provided by 1,945 adults for tobacco-specific biomarkers. About 32 per cent of the participants smoked their first cigarette within five minutes of waking, 31 per cent smoked within 30 minutes of waking and 19 per cent smoked more than one hour after waking.

The researchers found that NNAL, a chemical compound found in tobacco and tobacco products, was twice as high in samples of participants who smoked within five minutes of waking compared with those who waited for at least one hour before smoking their first cigarette, regardless of how many cigarettes they smoked per day, said Dr Steven A. Branstetter, lead author and assistant professor at the university's Department of Biobehavioral Health.

"We believe that people who smoke sooner after waking inhale more deeply and more thoroughly, which could also explain the higher levels of NNAL in their blood, as well as their higher risk of developing oral or lung cancer," Branstetter said. According to the Centres for Disease Control and Prevention, NNAL levels in smokers are about 50 to 150 times higher than in non-smokers. The findings were published in the April issue of the *Cancer Epidemiology, Biomarkers and Prevention journal*.

Patients with facial paralysis

Benefit from new therapy

More than 70,000 patients in Germany alone are affected by facial paralysis following injury or surgery. A new interdisciplinary therapeutic approach that combines physiotherapy, physiology and behavioural medicine may relieve the symptoms, which impair patients' quality of life significantly. The therapy entails recording the electrical activity of facial muscles using electrodes placed near a patient's eye or corners of the mouth. The activity is graphically visualised on a screen and can be observed by both patient and therapist. In addition, facial expressions are recorded on camera to help patients learn the movements.

The therapy was developed at the facial nerve centre at the Jena University Hospital's ENT clinic (Germany),

which is collaborating with various medical institutions to improve diagnostics and treatment of facial nerve disorders. According to Dr Orlando Guntinas-Lichius, director of the clinic, the collaboration, which was started in 2012, is unique in Europe.

For a year already, the centre has been offering the new treatment. Through various exercises, the recording of the electrical activity of the facial muscles and the respective neuro-feedback, the patients learned how to control all of their facial muscles in a new and better way, according to the centre. They trained three to four hours per day for more than two weeks at the clinic with a specialised team of ENT doctors, neurologists and physiologists.

implants
international magazine of oral implantology



Publisher

Torsten R. Oemus
oemus@oemus-media.de

CEO

Ingolf Döbbecke
doebbecke@oemus-media.de

Members of the Board

Jürgen Isbaner
isbaner@oemus-media.de

Lutz V. Hiller

hiller@oemus-media.de

Chief Editorial Manager

Dr Torsten Hartmann (V. i. S. d. P.)
hartmann@dentalnet.de

Editorial Council

Prof Dr Dr Frank Palm
frank.palm@klinikum-konstanz.de

Dr Roland Hille

dr-hille@t-online.de

Prof Dr Dr Kurt Vinzenz

kurt.vinzenz@aon.at

Dr Torsten Hartmann

hartmann@dentalnet.de

Dr Suheil Boutros

SMBoutros@aol.com

Editorial Office

Georg Isbaner
g.isbaner@oemus-media.de

Claudia Jahn

c.jahn@oemus-media.de

Executive Producer

Gernot Meyer
meyer@oemus-media.de

Designer

Sarah Fuhrmann
s.fuhrmann@oemus-media.de

Customer Service

Marius Mezger
m.mezger@oemus-media.de

Published by

OEMUS MEDIA AG
Holbeinstraße 29
04229 Leipzig, Germany
Tel.: +49 341 48474-0
Fax: +49 341 48474-290
kontakt@oemus-media.de

Printed by

Silber Druck oHG
Am Waldstrauch 1
34266 Niestetal, Germany

implants

international magazine of oral implantology
is published in cooperation with the German
Association of Dental Implantology (DGZI).

DGZI President

Prof Dr Dr Frank Palm
DGZI Central Office
Paulusstraße 1, 40237 Düsseldorf, Germany
Tel.: +49 211 16970-77
Fax: +49 211 16970-66
office@dgzi-info.de

www.dgzi.de
www.oemus.com

Copyright Regulations

implants international magazine of oral implantology is published by Oemus Media AG and will appear in 2013 with one issue every quarter. The magazine and all articles and illustrations therein are protected by copyright. Any utilization without the prior consent of editor and publisher is inadmissible and liable to prosecution. This applies in particular to duplicate copies, translations, microfilms, and storage and processing in electronic systems.

Reproductions, including extracts, may only be made with the permission of the publisher. Given no statement to the contrary, any submissions to the editorial department are understood to be in agreement with a full or partial publishing of said submission. The editorial department reserves the right to check all submitted articles for formal errors and factual authority, and to make amendments if necessary. No responsibility shall be taken for unsolicited books and manuscripts. Articles bearing symbols other than that of the editorial department, or which are distinguished by the name of the author, represent the opinion of the afore-mentioned, and do not have to comply with the views of Oemus Media AG. Responsibility for such articles shall be borne by the author. Responsibility for advertisements and other specially labeled items shall not be borne by the editorial department. Likewise, no responsibility shall be assumed for information published about associations, companies and commercial markets. All cases of consequential liability arising from inaccurate or faulty representation are excluded. General terms and conditions apply, legal venue is Leipzig, Germany.

implants

international magazine of oral implantology



Subscribe now!

I would like to subscribe to **implants international magazine of oral implantology** (4 issues per year) for €44 including shipping and VAT for German customers, €46 including shipping and VAT for customers outside Germany, unless a written cancellation is sent within 14 days of the receipt of the trial subscription. The subscription will be renewed automatically every year until a written cancellation is sent to OEMUS MEDIA AG, Holbeinstr. 29, 04229 Leipzig, Germany, six weeks prior to the renewal date.

▶ Reply via Fax +49 341 48474-290 to OEMUS MEDIA AG or per E-mail to grasse@oemus-media.de

You can also subscribe via www.oemus.com/abo

Last Name, First Name

Company

Street

ZIP/City/County

E-mail

Signature

Notice of revocation: I am able to revoke the subscription within 14 days after my order by sending a written cancellation to OEMUS MEDIA AG, Holbeinstr. 29, 04229 Leipzig, Germany.

Signature





DENTSPLY Implants – the new powerhouse in implant dentistry

DENTSPLY Implants is the union of two successful and innovative dental implant businesses: DENTSPLY Friadent and Astra Tech Dental*.

DENTSPLY Implants offers a comprehensive line of implants, including ANKYLOS®, ASTRA TECH Implant System™, and XiVE®, digital technologies such as ATLANTIS™ patient-specific CAD/CAM solutions, regenerative bone products and professional development programs.

DENTSPLY Implants is built upon the fundamental values of open-mindedness, a thorough scientific approach, a dedication to long-term clinical evidence and a

strong customer focus. Our current DENTSPLY Friadent and Astra Tech Dental customers can rest assured knowing that the world-class products they know will continue to be supported.

We are confident that dental professionals around the globe will come to recognize DENTSPLY Implants as their new partner of choice for integrated implant solutions, dedicated support and better patient care.

We invite you to join our journey to redefine implant dentistry.

*DENTSPLY Implants was launched in North America April 2012. Transition to the new business in other geographical locations around the globe will follow.

79571-USX-1212 © 2012 DENTSPLY /IH



ANKYLOS® ASTRA TECH IMPLANT SYSTEM XiVE® ATLANTIS™ ATLANTIS ISUS™ FRIOS® EXPELTEASE™ Facilitate™

www.dentsplyimplants.com

RetroMTA
مینرال تری اکسید آگریگیت سفید هیدرولیک
کلسیم زیرکونیوم

ADSEAL
سیلر بیس رزینی

Metapaste
هیدروکسید کلسیم + سولفات باریم

MD.ChelCream
ژل آرسی پرپ ۱۹%

Metapex
هیدروکسید کلسیم + ید

P & Bond
باندینگ نسل پنجم متا

META BIOMED

SPIDENT

Base.it
بیس و لاینر) دایکال نوری

EsFlow
کامپوزیت نانوفلو لایت کیور

Core.it
کریلد آپ دوآل کیور

Core-it Dual blue
Core-it Dual yellow
Flowable Core Build up Resin