





[www.azadmed.com](http://www.azadmed.com)



 azaadtejaratpars

 @azadmed2

 88 98 80 63 - 6

# implants

international magazine of oral implantology

3<sup>2009</sup>

**\_case report**

Bone quality, quantity and metabolism  
in terms of dental implantation

**\_case report**

Precautions for using zirconia implant  
abutments

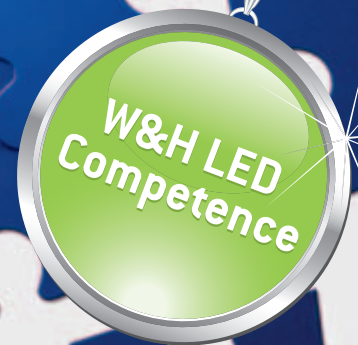**\_worldwide events**

5<sup>th</sup> Arab German Implantology Meeting  
DGZI in Damascus



# Now even more innovative

Easy-to-dismantle surgical instruments with LED and generator



**Easy to dismantle. Easy to assemble.** As simple as they are efficient: both the S-11 LED G and the WS-75 LED G can be completely dismantled. And, of course, they can be put back together again. Quick, simple and risk-free: meaning that you too are able to eliminate any risks and work in truly optimum hygienic conditions. Get the new standard for yourself: perfect light, global compatibility, precision, ergonomics – and complete safety.

Now at your local dental dealer or at [wh.com](http://wh.com)

# Implantology faces new challenges



Dr Friedhelm Heinemann  
President of DGZI

Dear colleagues,

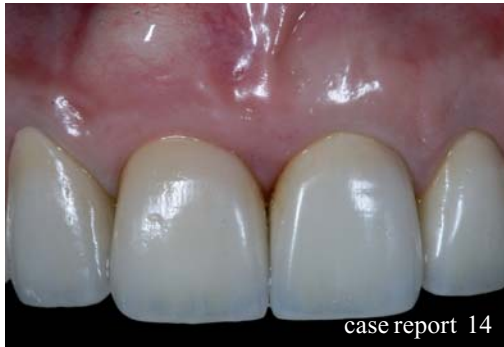in recent years, implantology has been considered to be THE driving force for innovations within dentistry. Companies and investors all over the world were impelled by the apparently infinite growth potential of this market. In the meantime, however, or so it seems, the mood has become much more reserved. Some implant systems have already been withdrawn from the market, and many companies do not act as aggressively as they used to. We have to find the answers to the following basic questions. Which are the real growth potentials of implantology, and how can implantology be placed on a changed market in the future? Contrary to the trend of the increase in gaining independence within our expert field, observable in the past, I believe that it will become more important to go back to the roots of implantology and consider it to be the real interface between parodontology, surgery and prosthetics. The broad digitalization within dentistry by means of 3-D diagnosis combined with modern planning and navigation software, including CAD/CAM manufactured dentures, implies this interface function, also from the technological point of view. Due to the digitalization of dental practices, team spirit is fostered, the flow of information is improved, and cooperation between the partners is facilitated. Prosthetic dental planning and the prosthetic guidelines for surgery will be easier to communicate, ultimately contributing to the achievement an optimal result, and thus efficiently meeting the desire of the patient. In this way, the old requirements and ideas for interdisciplinary cooperation can be realized in a much better manner. With this in mind, I would like to draw your attention to our 39<sup>th</sup> International Annual Congress which will take place from October 9<sup>th</sup> to 10<sup>th</sup> in Munich this year.

Thanks to the high class speakers from Germany and abroad, our Annual Congress will again become a special highlight in advanced professional training. I look forward to welcoming you in Munich.

Yours,

A handwritten signature in black ink, appearing to read 'Dr. F. Heinemann', with a long, sweeping underline.

Dr Friedhelm Heinemann  
President of DGZI



case report 14



worldwide events 40



Manufacturer news 41

| editorial

- 03 Implantology faces **new challenges**  
\_Friedhelm Heinemann, Germany

| report

- \_ case report
- 06 Bone quality, **quantity and metabolism** in terms of dental implantation  
\_Jochen Fanghänel, Tomasz Gedrange, Germany

- \_ case report
- 12 **Reconstruction of damaged fresh sockets** by connective-bone sliver graft from the maxillary tuberosity, to enable immediate dentoalveolar restoration (**IDR**)—  
A clinical case  
\_José Carlos Martins da Rosa, Darcymar Martins da Rosa, Carla Mônica Zardo, Ariádene Cristina Pértile de Oliveira Rosa, Luigi Canullo, Brazil and Italy

- \_ user report
- 18 Clinical outcomes of **flapless implant surgery** using a handpiece driven stereolithographic surgical guide  
\_Volkan Arisan, Z. Cuneyt Karabuda, Turkey

- \_ case report
- 26 Extraction, **immediate implant placement** and guided bone regeneration using a flapless approach  
\_Barry K. Bartee, DDS, MD, USA

- \_ case report
- 28 **Precautions** for using zirconia implant abutments  
\_Moustafa N Aboushellb, Egypt, and Rien van Paridon, Netherlands

\_ user report

- 32 Resorption mechanism of an **injectable calcium phosphate bone regeneration cement**—  
Radiographic and histological monitoring  
\_Sérgio Alexandre Gehrke, Brazil

| events

- \_ worldwide events
- 38 **DGZI Adria Congress on the Isle of Vis**  
\_Rolf Vollmer, Rainer Valentin, Germany
- \_ worldwide events
- 40 **5<sup>th</sup> Arab German Implantology Meeting DGZI in Damascus**
- \_ worldwide events
- 42 **Saudi Arabia—Tradition and modern times!** 20<sup>th</sup> Saudi Dental Society and 2<sup>nd</sup> National Guard “New Dental Era” International Conference 2009, organized in cooperation with the German Association of Dental Implantology (DGZI)  
\_Rolf Vollmer, Germany
- \_ implant events
- 45 **Selected Events 2009/2010**

| news

- \_ social news
- 46 **Congratulations and Happy Birthday** to all DGZI-members around the world
- \_ manufacturer news
- 47 **Manufacturer News**

| about publisher

- 50 Imprint


# NobelReplace™

The world's most used implant system.\*

Internal tri-channel connection for accurate and secure prosthetic restorations

TiUnite® surface and Groovy™ to enhance osseointegration

Implant design that replicates the shape of natural tooth roots



Color-coded system for accurate and fast component identification and ease of use

Color-coding: step-by-step drilling protocol for predictable surgical procedures

10 YEARS WITH  
TIUNITE® SURFACE  
New data confirm  
long-term stability.

\* Source: Millennium Research Group

Versatility, ease-of-use and predictability have made NobelReplace Tapered the most widely used implant design in the world.\* NobelReplace Tapered is a general use, two-piece implant system that performs both in soft and hard bone, one- and two-stage surgical procedures, while consistently delivering

optimal initial stability. NobelReplace Tapered is a system that grows to meet the surgical and restorative needs of clinicians and their patients – from single-tooth restorations to more advanced multi-unit solutions. Whether clinicians are just starting or are experienced implant users, they will benefit from a system that

is unique in flexibility and breadth of application.

Nobel Biocare is the world leader in innovative evidence-based dental solutions.

For more information, visit our website.

[www.nobelbiocare.com/nobelreplace](http://www.nobelbiocare.com/nobelreplace)

# Bone quality, quantity and metabolism in terms of dental implantation

**authors** Jochen Fanghänel\*, Tomasz Gedrange\*, Germany

\*Department of Orthodontics, Preventive and Pediatric Dentistry, Centre of Dentistry and Oral Health, Ernst Moritz Arndt University of Greifswald, Germany

## \_Abstract

Bone is the largest calcium storage, forms part of the supporting tissue and displays distinctive plasticity and adaptability. Thus, an adequate, differentiated composition and metabolism are required. The bone matrix consists of organic and inorganic structures. The cells, osteoblasts, osteoclasts, and osteocytes are responsible for bone formation, resorption and metabolism and, thus, for remodeling processes (formation and resorption) which permanently occur in bone tissue. Periosteum and endosteum form a functional unit with bone tissue itself and exercise protective, nutritive and growth functions.

The present paper provides an introduction to regular bone structure in the face area which is considered a precondition of successful implantation. The specific properties of the jaw bones have to be observed in this context.

## \_Introduction

The orofacial or stomatognathic system with its components forms a functional circle representing a biocybernetic system.<sup>11</sup>

A key role is played by bone, particularly the jaw bones. The structure of the osseous viscerocranium is targeted to withstand and divert the chewing pressure.<sup>2,11</sup> This requires a functional composition which is maintained even after osseointegration of bone graft substitutes (Fig. 1).

The periods of function and inactivity occurring in the jaw bones are more clearly noticeable than in any other bone of the body. For instance, the mandible and the maxilla display different atrophy processes.

Continuous remodeling which guarantees adaptation to arising forces requires healthy bone.<sup>8</sup>

### Bone composition

Bone is a specific connective tissue which mainly consists of the extracellular substance/bone matrix, cells, blood vessels, and nerves.

Weight distribution (in kilograms) in a 70 kg weighing man shows that bone and bone marrow rank high, as shown by selected examples in table 1.

**Table 1\_** Weight distribution (in kg) of tissues in a 70 kg weighing man in ranked order.

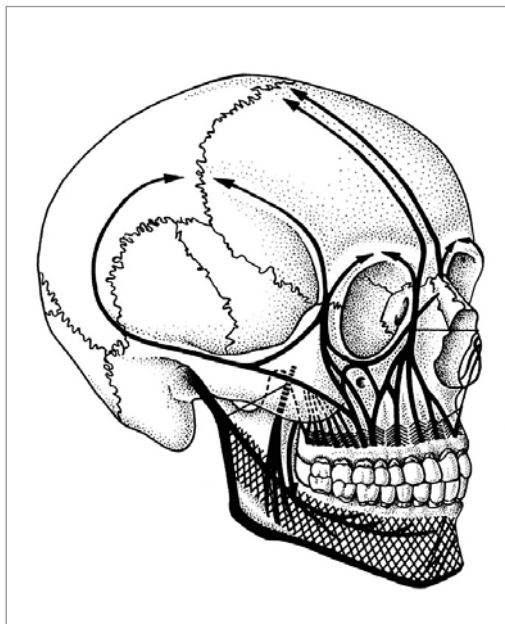
Muscles	30
fat	10
bone	7
bone marrow	3
blood	3
connective tissue	3
skin	2

### Bone matrix

It consists of organic and inorganic material.<sup>9</sup>

The inorganic material which determines bone

**Fig. 1\_** Trajectorial structure of viscerocranium.





NEW IMPLANTS, NEW ABUTMENTS  
**LIBERTY OF CHOICE**  
NATURALLY FROM **CAMLOG**

Reliable implants, patented Tube-in-Tube™ connection, and from now on as an option: platform switching. Camlog offers more. More information: [www.camlog.com](http://www.camlog.com)

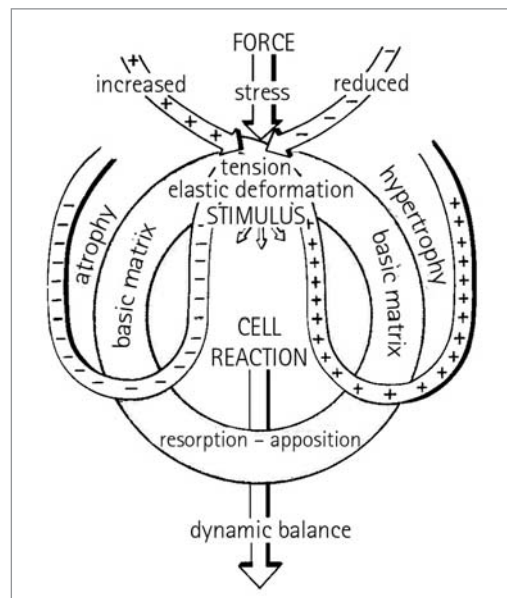

a perfect fit®

**camlog**



Fig. 2\_Osseous lamella.

Fig. 3\_Functional composition of bone and dynamic equilibrium.



stiffness, constitutes about half of the matrix. The major part (50 per cent) is composed by calcium and phosphate in the form of hydroxyapatite crystals. Additionally, non-crystalline calcium phosphate, citrate, hydrogen carbonate, and furthermore, magnesium, potassium, and sodium salts are found. The apatite crystals are surrounded by matrix substance and lie along the collagen fibrilles. A so-called hydration cover facilitates ion exchange between crystal and body fluids. The water content of the bone matrix amounts to 10–20 per cent. The water-free matrix contains 70 per cent inorganic and 30 per cent organic substance.

The non-calcified organic matrix is referred to as osteoid and provides the bone with the required elasticity. It mainly consists of collagen.

### Bone cells

Cells are indispensable for regular osseointegration processes.<sup>1,2</sup>

**Osteoblasts:** These mononuclear and nearly cubic shaped cells produce all essential organic matrix components of bone (osteoid). They are located exclusively at the surface of spongy trabecles, and synthesize and secrete collagen I, proteoglycans and glycoproteins. As their activity fades, the cells become increasingly flatter and form processes. The newly produced matrix proteins are released towards the surface of the existing bone matrix. The organic material enabling bone elasticity constitutes about 20 per cent. Finally, water amounts to about 10 per cent of the matrix substance.

The osteoblasts are activated by cytokines, growth factors and vitamin D3 and thereby enabled to induce osteoclast proliferation and differentiation.

**Osteoclasts** are multinucleate, large mobile cells resorbing mineralized bone and derived from the mononuclear phagocyte system. One surface of

resorbing osteoclasts is facing the mineralized bone tissue. The surface periphery is closely connected with the matrix by a sealing zone. The area surrounded by this zone displays numerous folds ("ruffled border"). Between the "ruffled border" and the bone matrix, there is an extracellular space, the so-called resorption lacuna where bone resorption occurs. The osteoclast secretes H<sup>+</sup> ions to the lacuna by means of a vacuolar ATPase located in the folded membrane, and the matrix minerals are dissolved in the acid milieu. The release of lysosomal enzymes leads to decomposition of the collagen fibrilles.

**Osteocytes** develop from osteoblasts and represent metabolic centres of the bone. These cells predominate in bone. Their cell bodies are located in the lacunae. With their processes, they are interconnected by nexuses. The processes permit intercellular substance transport and enable the coordination of metabolic activities. An exchange of compounds among osteocytes, mineralized matrix and blood vessel also occurs in the gap system between cells and calcified bone matrix.

The osteocytes respond to mechanical stress exerted on the bone and sustain the extracellular matrix. After their death, the matrix undergoes resorption.

The jaw area is very likely to exhibit a population of bone cells different from cells from other regions in terms of their origin, their involvement in specific local developmental and bone formation processes and their specific adaptation to local biomechanics. At the moment, it may be merely speculated whether the activity of such neuroectodermally derived "jaw osteoblasts" essentially contribute to perfect dental implant treatment outcomes.<sup>5</sup>

### Periosteum and endosteum

Their main functions are protection and nutrition as well as the continuing supply of osteoblasts for

thickness growth and successful defect repair.<sup>1,2</sup> The outer periosteum consists of fibroblasts, collagenous and elastic fibres (stratum fibrosum). The inner layer (stratum germinativum) is formed by divisible cells ("lining cells") which can differentiate into osteoblasts. The stem cells play an important role for bone growth and repair. Sharpey's fibres are bundles of collagenous fibres connecting the periosteum with the bone substance.

The endosteum fills the inner cavities of bone, is thinner than the periosteum, consists of progenitor cells and comprises only a slight amount of connective tissue. The endosteal border cells are resting osteoblasts forming a continuous cell assembly on the inner cortical surface and the Haversian canal walls

### Bone types

Woven bone and lamellar bone are distinguished according to the arrangement of osteocytes and collagen fibres.

– Woven bone (also "primary bone") is found only during bone development and repair processes, and, therefore, also in osseointegration. Its mineral content (higher radiolucency!) is lower. The collagen fibrils run irregularly rather than in lamellar form. This type of bone is replaced by lamellar bone except for suture areas.

– Lamellar bone (Fig. 2): The collagen fibres and other matrix components form lamellae of 3–7 µm thickness which are arranged in concentric layers around a central channel (Haversian canal).<sup>6</sup> This structure is referred to as Haversian system or osteon. Between the lamellae, the cell bodies of the osteocytes are located with processes running in respective channels (see above). Each channel harbors nutritive vessels, nerve fibres, and loose connective tissue. The canals communicate with the bone marrow cavity, the periosteum and with each other. Larger channels are Volkmann's canals which also run outward. The entire channel system reflects a complex and delicate microcirculation.<sup>4</sup>

Each osteon is surrounded by mineralized matrix with few collagen fibres (cementum). Immediately beneath the periosteum and around the marrow cavity lie more outer and fewer inner general lamellae. Between outer and inner general lamellae, the so-called osteons and the often irregularly shaped intermediate lamellae are located. The latter are residual lamellae of a Haversian system which was degraded during a remodeling process.

### Principles of bone structure

– Substantia compacta, Substantia spongiosa of the bones

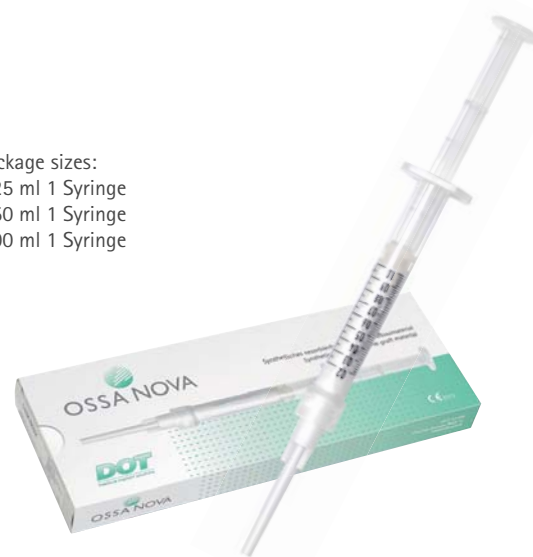The outer compact bone layer is referred to as substantia compacta, while the inner layer which possesses numerous interconnected cavities is termed substantia spongiosa. The latter represents a spongy

Easy.  
Safe.  
Quick.

## OSSA NOVA Bone Graft Material

- easy and safe application with a syringe
- pasty consistency for optimal defect alignment
- distinct capillarity for uptake of body fluids
- Integration into the natural bone remodelling process
- unhindered wound healing
- safe material due to synthetic origin

Package sizes:  
0,25 ml 1 Syringe  
0,50 ml 1 Syringe  
1,00 ml 1 Syringe

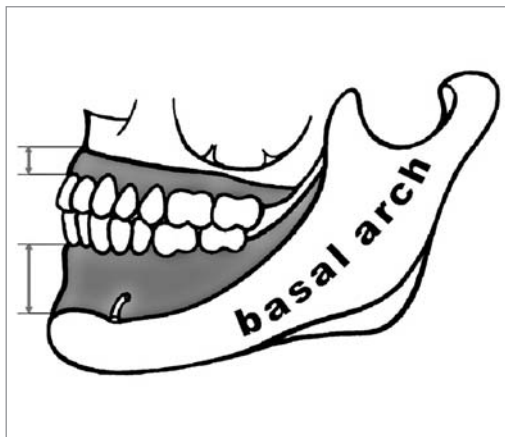

DOT is a leading supplier of innovative solutions for dental and orthopedic implants.

DOT GmbH  
Charles-Darwin-Ring 1a  
D-18059 Rostock  
Germany  
Tel.: +49(0)381- 4 03 35-0  
Fax: +49(0)381- 4 03 35- 99  
biomaterials@dot-coating.de  
www.dot-coating.de

**DOT**  
medical implant solutions

**Fig. 4** Vertical atrophy of the mandible.



trabecular framework. However, both structures show a lamellar bone composition. Spongiosa prevails in the maxilla, whereas the mandible is predominated by compacta.

Bone shape and composition are adjusted to its mechanical function. According to its trajectorial architecture, structure conforms to tension and strain trajectories. Bone substance is arranged in such a way that best possible absorption and transmission is achieved with minimum expense of material in the loaded area. The trajectorial construction, e.g., of the mandible, permits selective material usage in the loaded area.<sup>2</sup> This lightweight construction saves muscular strength for motor activity. Bone morphology is genetically determined and modified by external influences through differentiation. Bone is solid by virtue of its inorganic components and elastic due to its organic components. Thus, bone substance features a dynamic equilibrium of adaptation.<sup>2,3,8</sup> Figure 3 shows the oscillation between atrophy and hypertrophy, resorption and apposition.

#### Special properties of the jaw bones

The jaw bones as well as the tooth germs (except the enamel organ and enamel) develop from the neural crest cells which are preprogrammed for the facial region where to migrate.<sup>5</sup> Development of cartilage, bone and teeth, however, requires numerous interactions between the mesectodermal cells, the ectoderm and the inner body surface. Almost all jaw bones (including the alveolar process) develop to woven bone by desmal osteogenesis. The osteoblast progenitor cells are derived from neural crest cells. Ossification of the alveolar processes is closely associated with tooth germ development. Desmal ossification is recapitulated in reparative processes. Similarly, osseointegration of dental implants follows this principle.<sup>2</sup>

#### Jaw atrophy

Jaw atrophy is a major field of implantology. Such inactivity atrophy results from a lack of strain stimuli and reflects complex atrophic and resorptive

processes. Resorption of the (edentulous) alveolar processes is multifactorial and cannot be attributed to altered loading alone. Mechanical factors, biological and metabolic factors, and inflammatory causes are distinguished.

Mandibular involution is primarily vertical. The alveolar process is smaller than the basal arch which represents the constant part (Fig. 4). At old age, the mandible shows increased prominence.<sup>3</sup> Vertical bone resorption is increased compared to the maxilla. These changes are even more marked in females. The mandibular basal arch is more extended than the maxillary one: by up to ca. 3 mm during the first three years after tooth loss, and by 0.3 to 0.4 mm p.a. during the following years. This difference is compensated by alveolar process inclination resulting in oral inclination of the mandibular alveolar process and vestibular inclination of the maxillary one.

Besides the basal arch which may also exhibit resorption during old age, there are structures that are not subject to atrophic changes, such as linea mylohyoidea, linea obliqua, spina mentalis, tori mandibulares, and trigona retromolaria.<sup>3</sup>

The basal arch as well as the alveolar walls show a trajectorially oriented arrangement.

Alveolar process atrophy also leads to an altered mandibular angle. This angle amounts to 150° in newborns and to 120° in adults. At old age, the angle tends to return to childhood values and may even exceed 160°. These angular changes also exert an effect on the trigonum retromolare sinking down in atrophic bone and, thus, assuming an almost topographical relation to the pars obliqua of the mandibular canal. In atrophic bone, therefore, the trigonum retromolare fails to serve as an implant abutment site.<sup>10</sup>

Maxillary atrophy primarily occurs horizontally and only slightly in vertical direction. The alveolar process which provides only little space for the tooth roots, is larger in relation to the corpus maxillae.<sup>3</sup> Thus, the maxillary arch becomes more reduced. Due to resorption, its size decreases relative to the mandible. With increasing maxillary atrophy, the alveolar midcrest is displaced palatally (centripetally). Atrophy of the hard palate proceeds anteroposteriorly (Fig. 5) and may be of such an extent as to cause bone perforation and contact between oral and nasal cavity mucosa.

The alveolar process ends with the tuber retromolare behind the last molar. Before seven years of age, the tuber does not exist but as a rudiment. The alveolar canals for the nn. alveolares superiores posteriores develop from primordial alveolar sulci. Beyond 20 years of age, the tuber is fully differentiated, and alveolar canals are found. After 50 years of age, involution of the tuber occurs, and the alveolar canals reopen into alveolar sulci. These changes show that the tuber retromolare is not suitable as an implant abutment

site.<sup>10</sup> The anterior maxilla shows numerous channels harboring blood vessels and nerves which also present as sulci and open toward the maxillary sinus.<sup>7</sup> The torus palatinus, the crista zygomatico, and the spina nasalis anterior do not reveal any atrophic alterations. The chewing pressure abutments of the maxilla are not subject to atrophic processes and, hence, preserved.

#### Blood vessel supply

Blood vessel supply is a prerequisite of regular bone growth and metabolism. It is effected by means of the vasa nutricia which run without contortions through the corticalis into the medullary cavity (Fig. 2). Diaphyseal arteries branch out to marrow arteries. Several small arteries supply the metaphysis and epiphysis. The epiphyseal vessels display only few anastomoses with the metaphyseal and diaphyseal vessels. The corticalis is supplied from within and outside. The outer cortical sections are supplied directly by the periosteal vessels. Perfusion is increased in high-density bones compared to low-density bones. This should be considered for implantation.

Bone tissue lacks lymphatic vessels which occur only in the periosteum.<sup>1</sup>

#### Nerve supply

Nerves are indispensable for bone tissue viability as well. With the blood vessels, the nerves enter the bone, run in Volkmann's and Haversian canals (Fig. 2) and also reach the spongiosa. The nerve fibres are largely unmyelinated. The periosteum is innervated abundantly. There has been evidence of numerous transmitters (e.g., norepinephrine, neuropeptide Y).<sup>1</sup>

#### Bone function

Bone function is manifold and plays an important role for osseointegration.<sup>2,3</sup>

#### Supportive function

The bones make up the skeleton which determines skull weight and shape. Additionally, the skeleton provides the origin and attachment of the muscles which in turn influence cranial morphology. Owing to its biological plasticity, bone is capable of adaptation to stress.

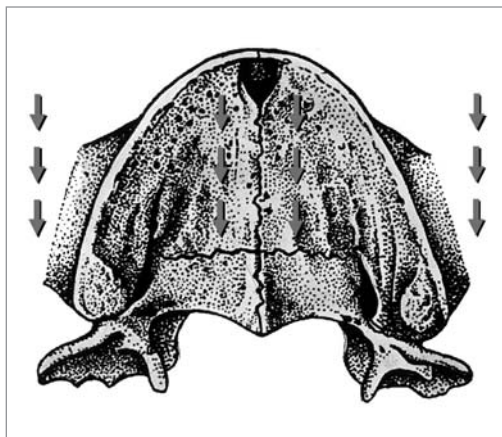
#### Protective function

The cranial bones protect the central nervous system, the sense organs, and the bone marrow.

Development of masticatory pressure pillars in the viscerocranium serves for diversion of the chewing pressure and the trajectorial structure of the mandible (Fig. 1).

#### Calcium storage

About 99 per cent of the body's calcium is stored in the skeleton. The stored calcium is mobilized, when



**Fig. 5** Horizontal atrophy of the maxilla.

blood calcium concentration declines. Calcium is mainly released from hydroxyapatite crystals in the spongy substance.<sup>1</sup> Acting as a calcium storage, bone tissue plays an important role in regulating calcium homeostasis.

#### Hormone and vitamin metabolism

Bone is related to hormone and vitamin metabolism. The osteoblasts possess receptors for parathyroid hormone, vitamin D3, cytokines and growth factors. They produce factors that increase osteoclast proliferation and differentiation. Calcitonin exerts a receptor-mediated inhibiting effect on osteoclast activity. Both androgens and estrogens generally stimulate bone anabolism and accelerate epiphyseal gap and suture closure. They facilitate mineralization and bone formation. Opposite effects are exerted by cortisol.

#### *This article was first published in:*

Biomedizinische Technik/Biomedical Engineering. Band 53, Heft 5, Seiten 215–219, Walter de Gruyter: Berlin, New York 2008. ISSN (Online) 1862-278X, ISSN (Print) 0013-5585, DOI: 10.1515/BMT.2008.041, October 2008\_

*The Literature list can be requested from the editorial office.*

#### \_contact

#### implants

#### **Prof Dr Jochen Fanghänel**

Department of Oral Anatomy,  
Centre of Dentistry and Oral Health,  
Ernst Moritz Arndt University  
Rotgerberstr. 8  
17489 Greifswald, Germany  
Phone: +49-38 34/86 71 53  
Fax: +49-38 34/86 71 13  
E-mail: fanghaen@uni-greifswald.de

# Reconstruction of damaged fresh sockets by connective-bone sliver graft from the maxillary tuberosity, to enable immediate dentoalveolar restoration (IDR)—A clinical case

**authors** José Carlos Martins da Rosa<sup>1</sup>, Darcymar Martins da Rosa<sup>2</sup>, Carla Mônica Zardo<sup>3</sup>, Ariádene Cristina Pértile de Oliveira Rosa<sup>4</sup>, Luigi Canullo<sup>5</sup>

<sup>1</sup> Private Practice in Caxias Do Sul, RS, Brazil

<sup>2</sup> Private Practice in Novo Hamburgo, RS, Brazil

<sup>3</sup> MSc student of Implant Dentistry, São Leopoldo Mandic Dental Research Center, Campinas, SP, Brazil

<sup>4</sup> Private Practice in Caxias Do Sul, RS, Brazil

<sup>5</sup> Department of Orthodontics, University of Bonn, Germany

## Abstract

This paper describes a procedure for immediate loading of an implant following tooth extraction, in a socket presenting severe damage to the vestibular bone plate and gingival recession in the region of the upper central incisors. The procedures of extraction of the tooth, immediate insertion of the implant, connective-bone graft from the maxillary tuberosity and immediate restoration were shown to be a predictable treatment alternative. These procedures led to restoration of the tooth, bone and gingival structures in a single surgical stage and to maintenance of the favorable esthetic and functional result 24 months afterwards.

## Introduction

The situations in which immediate loading of implants following tooth extraction is indicated are expanding. Maintaining the integrity of the support tissues during a tooth extraction procedure is an indispensable requirement for indicating immediate loading (Tarnow DP 1997, Brånemark P-I 1999, Buser D 1999).

When a tooth presents endodontic or periodontal damage, fractures or root reabsorption, some of the

bone framework may be compromised and may require surgical techniques to restore its anatomy, prior to implant insertion. When the bone damage is extensive, with changes in the level of the gingival margin, the esthetic risk increases and thus, immediate loading is contraindicated (Polizzi G 2000, Chen ST 2004, Lindeboom JA 2006, Schropp L 2008).

The aim of this paper is to describe a technique for immediate loading of an implant following tooth extraction, in a socket presenting severe damage to the vestibular bone plate and gingival recession in the region of the upper central incisors.

## Literature review

The finding of the phenomenon of integration between bone and titanium changed the course of dentistry. However, to promote osseointegration for a titanium fixture, it would be necessary to bury the implant in order to avoid premature loading, thereby requiring two surgical stages before inserting the prosthesis (Brånemark P-I 1977).

The development of studies aimed at diminishing the waiting period for prosthetic restoration has ensured the use of implants involving a single surgical stage and has imposed changes in the principles of osseointegration (Tarnow DP 1997, Brånemark P-I

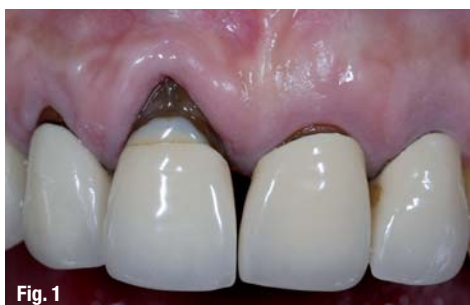

Fig. 1

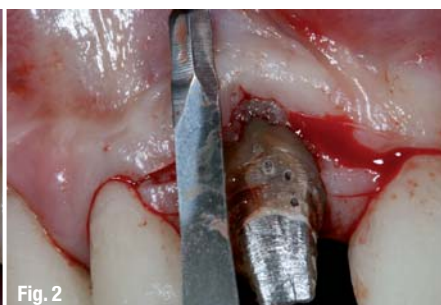

Fig. 2

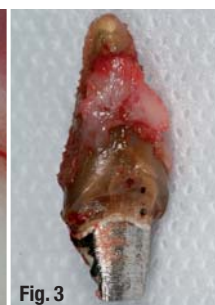

Fig. 3

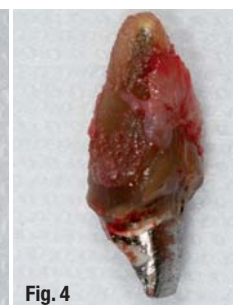

Fig. 4

1999, Buser D 1999). It has been shown that certain forces are important for triggering a series of biological reactions that accelerate the bone repair process, thus encouraging the use of implants for immediate loading (Romanos G 2001, Isidor F 2006).

The possibility of immediately replacing a damaged tooth has led to the achievement of success rates greater than 90 per cent in studies on immediate loading of implants following tooth extraction (Worhle PS 1998, Gomez-Roman G 2001, Hui E 2001, Kan JY 2003, Glauser R 2003, Malo P 2003, Tupac RG 2003, Schropp L 2005, De Kok IJ 2006, Barone A 2006, Degidi M 2007, Crespi R 2007, Canullo L 2007, Villa R 2008).

Primary stability is the most important factor in indicating that an implant can be brought into immediate functioning. This is associated with the quantity and quality of the bone material, the geometry of the implant and the surgical technique used (Polizzi G 2000, Covani U 2003, Hamerle CH 2004, Covani U 2007, Canullo L 2007, Schropp L 2008).

Implants of conical design are the type most indicated for receiving immediate loading following tooth extraction. They promote greater lateral bone compaction, thereby increasing the bone density; they adapt better to the socket; and they have a greater contact surface with the bone. These characteristics increase the initial stability and enable better spreading of occlusal loads (Gomez-Roman G 2001, O'Sullivan D 2000, Abbou M 2003, Friberg B 2003, O'Sullivan D 2004, Glauser et al 2007).

The presence of local infection due to disease or trauma in the damaged tooth interferes directly with the quantity and quality of the soft and hard tissues. It may change the alveolar architecture at the potential site for implant insertion. Additional loss of these esthetically important tissues may occur while treating the local infection, thereby increasing the involvement of esthetics. One or more socket walls may be impaired, with or without gingival recession, and surgical techniques may be needed to restore their anatomy, thus contraindicating implants with immediate loading (Polizzi G 2000, Chen ST 2004, Lindboom JA 2006, Schropp L 2008).

As a donor area, the maxillary tuberosity has a limited quantity of bone material available and presents low bone density and the difficulty of surgical access.

Its advantages are the excellent postoperative recovery, better graft repair and the ease of harvesting the graft material and adapting it to the receptor region, because of the bone malleability (Rosa JCM 2008).

Anatomical and functional recovery of the hard and soft tissues surrounding the post-extraction immediate loading implant was achieved by means of the technique of connective-bone sliver graft, as a single specimen harvested from the maxillary tuberosity.

## Clinical case report

The patient was a 50-year-old woman with a high smile line who came for treatment because of gingival recession in the region of the upper right central incisor.

At the clinical examination, periodontal probing of the compromised tooth showed severe damage to the vestibular bone plate, with gingival recession of 4 mm combined with vestibular bone loss to a depth of 10 mm, without apparent fistula.

Radiographic examination showed the presence of endodontic treatment, a short cast metal core, a metal/ceramic crown, bone height of 8 mm above the root apex and thickening of the hard layer in the region of the compromised tooth. Good bone material availability in the maxillary tuberosity was observed.

The treatment proposed consisted of extraction of the compromised tooth, curettage of the region, implant insertion, recovery of the socket defect by connective-bone sliver graft from the maxillary tuberosity and immediate temporary restoration. It was suggested to the patient that she might wish to replace the metal/ceramic crowns with metal-free crowns on the anterior teeth of the maxilla.

The following medications were prescribed:

— Amoxicillin 500 mg, taken as one capsule every eight hours, for seven days starting one hour before the procedure.

— Dexamethasone 4 mg, taken as one dose of 8 mg one hour before the procedure and then 4 mg per day for two more days.

— Paracetamol 750 mg, taken as one pill every six hours while in pain, beginning one hour before the procedure.

For better comprehension, the steps in the procedure will be described in detail in the following.

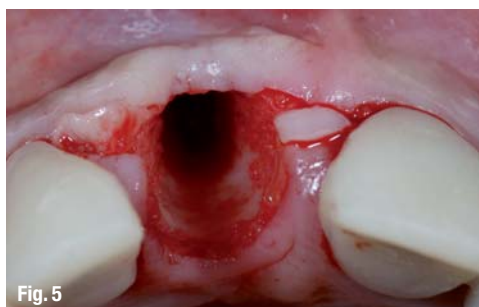

Fig. 5

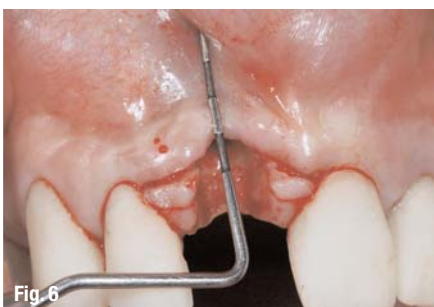

Fig. 6

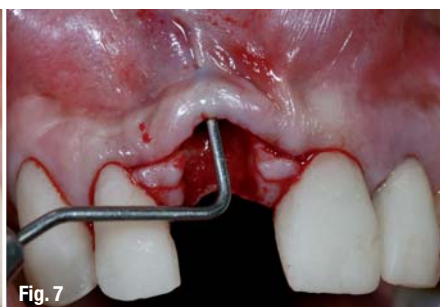
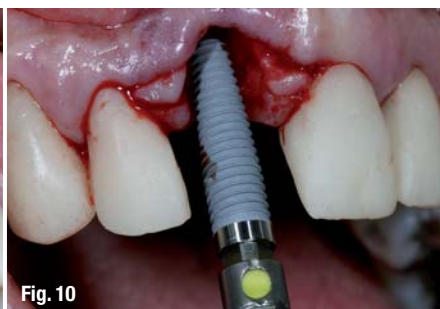
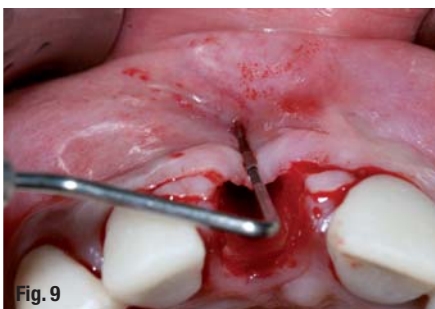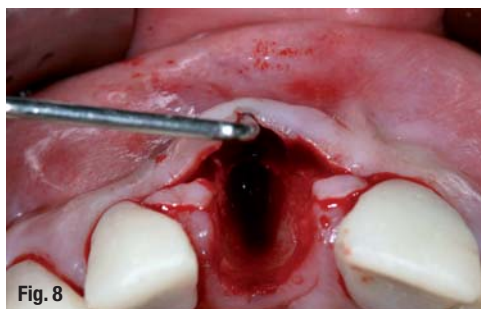Fig. 7



Sequence of procedures:

Ⓢ **Tooth extraction and implant insertion**

1. Infiltrative anesthesia of 2% mepivacaine, with norepinephrine, at the base of the vestibule, in the palate and near the papillae adjacent to the compromised tooth.

2. Double incision at the level of the mesial papillae and distally to the compromised tooth, using a microblade (69 WS Swann-Morton®, England). The aim of this incision was to reposition the gingival tissue coronally, thereby minimizing the trauma to the tissues and promoting scar-free first-intention healing.

3. Incision in the sulcus, using the microblade, around the tooth that was to be extracted.

4. Non-traumatic extraction of the tooth using a periosteal elevator, performing a pendular movement in the mesiodistal direction, with the aim of maintaining the integrity of the remaining bone walls.

5. Careful curettage of the socket, to remove the granulation tissue and the remains of the periodontal conjunctive tissue.

6. Probing of the socket walls to assess the degree of bone damage, in the apical-coronal and mesiodistal directions, and to confirm the anatomical shape of the defect.

7. Insertion of a NobelReplace™ Tapered TiUnite® (Nobel Biocare™, Göteborg, Sweden) implant, of dimensions 16.0 x 4.3 mm, with excellent apical stability and diameter compatible with the socket opening. By means of a surgical guide, the drill bits were directed towards preparing the bone bed, using the palatine wall to ensure adequate bone support and insert the implant in the ideal three-dimensional position. The implant bed preparation was started using the 2.0 cylindrical drill bit and continued using the 3.5 and 4.3 conical-shaped drill bits. The implant was inserted such that the ideal apical-coronal positioning was sought, independent of the abnormality of the gingival level. The implant platform was at a distance of 3 mm from the gingival margin of the homologous tooth. After insertion of the implant, the spirals remained exposed in the socket defect region.

8. Insertion of a temporary titanium abutment, adjustment of the occlusion and opacification of the metallic component by using photopolymerizable

opaque resin (Amelogen® Plus OW, Ultradent Products, Inc., USA);

9. Construction of a provisional crown using esthetic facet that was prepared earlier using photopolymerizable resin. The ideal emergence profile was established on the provisional crown, with free space to allow for accommodation of the soft tissues and to promote a thicker and more stable margin of gingival tissue;

10. Insertion of the provisional crown for adjustment of the occlusion in centric, habitual and excursive movements and for clinical confirmation of its adaptation, considering that the implant platform was above the gingival margin.

11. Removal of the provisional crown for finishing and polishing, and to perform the stage of reconstruction of the sockets bone defects.

Ⓢ **Graft harvesting**

12. Infiltrative anesthesia in the donor area by means of 2% mepivacaine, with norepinephrine, at the base of the vestibule and in the palatine portion of the maxillary tuberosity.

13. Incision following the distal outline of the second molar, to the full depth of the soft tissue, followed by two relaxing incisions in the posterior direction, thus reproducing the shape of the defect in the receptor region.

14. Longitudinal incision dividing the gingival tissue as far as the most posterior portion of the relaxing incisions, while maintaining a thickness of around 1 to 2 mm of connective tissue covering the bone tissue.

15. With the use of a straight chisel, the bone was cut along the relaxing incisions, with the aim of defining the bone fracture line. The chisel was positioned on the incision line surrounding the distal part of the second molar and was driven in deeper, as far as the distal limit of the relaxing incisions, in order to obtain a uniform bone/gingiva sliver. An incision was made in the distal portion of the gingiva to remove the sliver, while taking care to maintain an epithelial pedicle, to ensure better nutrition for the flap that would be used to cover the donor region.

16. Harvesting of bone marrow from the donor region to fill possible spaces between the bone sliver and the exposed spirals of the implant.

BEGO is an official  
co-partner of the German  
Olympic teams for  
**Vancouver 2010**  
**London 2012**

GO FOR GOLD.



Bionic Engineering Design transfer of  
optimal living nature solutions  
to technical products

BEGO Semados®  
Mini-Implant

BEGO Semados®  
S-Implant

BEGO Semados®  
RI-Implant

## BIONIC ENGINEERING DESIGNED IMPLANTS

BEGO Semados® patented Implants embody:

- Indication-optimised contour design
- Function-optimised implant-abutment-connection
- High purity and ultra-homogenous-surface
- Polished rim for an inflammation-free gingiva-attachment
- 100 % German design – 100 % German manufacturing
- Value for money

# Are You Interested?

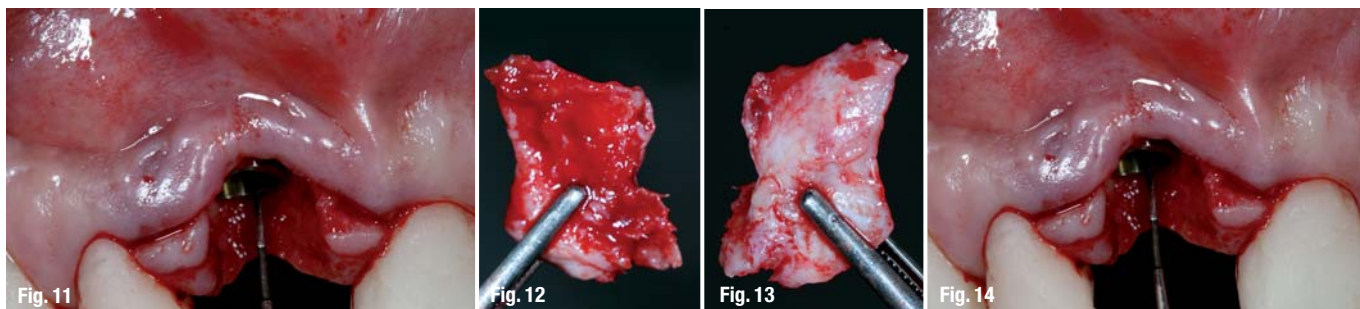
[info@bego-implantology.com](mailto:info@bego-implantology.com)

[www.adwork.de](http://www.adwork.de)

**BEGO**   
Partners in Progress

[www.bego-implantology.com](http://www.bego-implantology.com)





® **Suturing and stabilization of the connective-bone sliver**

17. Harvesting of gingival tissue between the double incisions, in the region of the papillae.

18. Detachment of the gingival flap to make it possible to reposition it coronally, free from tension.

19. Manipulation of the connective-bone graft to reproduce the shape of the socket defect.

20. Careful insertion of the connective-bone sliver, as far as the level of the implant platform, while leaving the bone portion in contact with the exposed spirals of the implant and the connective tissue portion in contact with the internal portion of the gingival flap.

21. Stabilization of the graft by means of suturing the connective tissue portion of the graft on the internal face of the gingival flap, and passive accommodation of the flap in order to suture the papillae using simple stitches.

22. Compaction of the bone marrow, that was taken from the maxillary tuberosity, between the vestibular surface of the implant and the graft, to ensure the final stabilization of the connective-bone sliver.

23. Insertion of the provisional crown on top of the implant.

24. Torque of 20 N on the attachment screw of the provisional crown and sealing of the palatine orifice with temporary filling material (Fermit, Ivoclar North America, Amherst, NY, USA).

25. Suturing of the gingival flap in the donor region, using simple stitches.

The patient was instructed not to place any loading on the region and to make topical applications of 0.12% chlorhexidine, three times a day for seven days.

After a three-month period to allow osseointegration and restoration of the bone and gingival architecture, an abutment made of Procera zirconia was inserted using torque of 20 N. At that time, the anatomical shape of the emergence profile obtained for the provisional crown on the implant was checked.

Transfer molding was performed on the implant emergence profile and on the neighboring teeth. The dies were scanned using Procera Forte to construct copings made of Procera alumina. After testing the copings, transfer molding was performed to enable personalized application of porcelain. The esthetic finish was determined according to the adequacy of the

gingival architecture and the crowns made of metal-free porcelain on the anterior teeth of the maxilla.

This technique was shown to be esthetically and functionally predictable: it minimized the surgical trauma and provided favorable results immediately and after 24 months of follow-up.

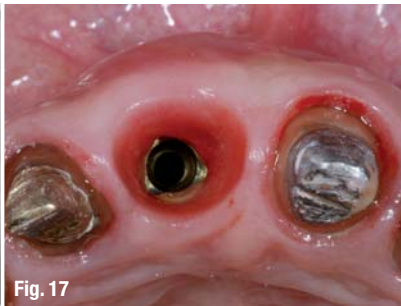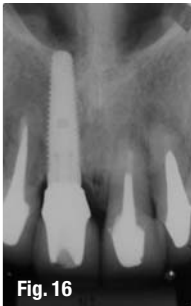
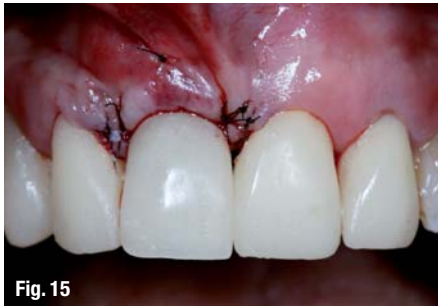**Discussion**

Immediate loading of implants following tooth extraction, in cases in which the support tissue is undamaged, is very well established in the literature (Tarnow DP 1997, Worhle PS 1998, Brånemark P-I 1999, Buser D 1999, Polizzi G 2000, Gomez-Roman G 2001, Hui E 2001, Kan JY 2003, Glauser R 2003, Malo P 2003, Tupac RG 2003, Covani U 2003, Hamerle CH 2004, Schropp L 2005, De Kok IJ 2006, Barone A 2006, Degidi M 2007, Covani U 2007, Crespi R 2007, Canullo L 2007, Schropp L 2008, Villa R 2008). Maintenance of the bone and gingival architecture, esthetic restoration and reduction of the treatment duration are the factors that have given recognition to the technique (Tarnow DP 1997, Brånemark P-I 1999, Buser D 1999). In addition to the initial stability, the biological changes that occur when an implant is put into use at an early stage are of great importance in the bone repair process (Romanos G 2001, Isidor F 2006, Vandamme K 2007).

In cases of tooth loss together with loss of support structures, the esthetic risks are greater. In such cases, implant insertion associated with grafting or with the use of membranes is indicated, so that function is reestablished only after a healing period.

Many papers have reported the use of grafts from the maxillary tuberosity for correcting socket defects (ten Bruggenkate CM 1992, Misch CE 1999, Rosa JCM 2008). The maxillary tuberosity presents the disadvantages of the limited quantity of bone material available, the low bone quality and the difficulty of surgical access. Its advantages are the greater speed of graft repair, the ease of harvesting the graft material and adapting it to the receptor region because of the bone malleability, and the excellent postoperative recovery (Rosa JCM 2008).

The bone and periosteal cells of the maxillary tuberosity behave as osteoprogenitor cells (Ciconetti A 2007). Knowing that the vascularization



pattern is vital for bone grafting success, the trabecular nature of grafts harvested from the maxillary tuberosity means that such grafts have high revascularization capacity and release growth factors to the receptor site. Hence, these grafts need to be transported rapidly, so that their fundamental properties are not lost (Prolo & Rodrigo 1985, Goldberg & Stevenson 1987).

With the aim of shorter time required for bone-implant integration, it needs to be emphasized that spongy bone presents greater vascularization and cellularization and is metabolically more active, thus favoring the initial osseointegration processes.

Stabilization of the bone graft in the receptor site is fundamental for avoiding micromovement and facilitates the graft neovascularization process. Graft revitalization and incorporation success depend on close contact between the graft and the host's vascular bed (Burchardt H 1983/1987, Abreksson T 1980/1980, Gordh & Alberius 1999).

With the passage of time and with appropriate mechanical stimulation, the mechanical resistance of the grafted area will tend to increase. Early low-intensity stimulation increases the local blood flow and contact osteogenesis (Burchardt & Enneking 1978, Abreksson T 1980/1980).

The use of a connective-bone sliver harvested from the maxillary tuberosity was indicated for restoration of the socket anatomy and compaction of the bone marrow established an improvement in bone density.

The technique of immediate loading of implants following tooth extraction, associated with grafting of a connective-bone sliver harvested from the maxillary tuberosity promoted acceleration of bone repair for the implant and graft and minimized the number of surgical procedures. The connective-bone sliver

not only restored the lost vestibular bone plate but also impeded cell competition between the hard and soft tissues, thereby promoting effective bone and gingival healing.

Immediate loading of implants following tooth extraction, associated with grafting of a connective-bone sliver avoids the need to subject the patient to several surgical procedures, such as bone grafting, gingival tissue grafting, implant insertion, surgery to reopen the implant and conditioning stages for the soft tissue surrounding the implant. This also avoids esthetic impairment through performing these procedures.

This technique promoted acceleration of the bone repair around the implant and in the graft, thereby providing effective connective-bone healing in a single procedure.

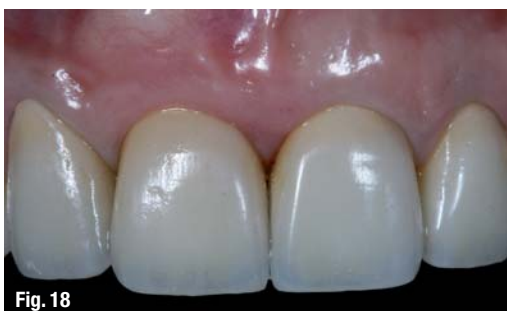### Conclusion

The connective-bone sliver graft from the maxillary tuberosity was indicated for recovery of the vestibular bone cortex of the damaged fresh socket and covering of the exposed spirals of the implant, and it increased the thickness and quality of the gingiva. In combination with coronal repositioning of a gingival flap, correction of the gingival recession was enabled.

The connective-bone sliver graft from the maxillary tuberosity impeded cell competition between the hard and soft tissues, thereby promoting effective bone and gingival healing.

Immediate loading of the implant in the damaged fresh socket associated with a connective-bone sliver graft from the maxillary tuberosity enabled dentoalveolar restoration in a single procedure. Although the technique requires long-term follow-up, the result obtained was satisfactory and promising.

*The Literature list can be requested from the editorial office.*



<b>_contact</b>	<b>implants</b>
<p><b>Dr Dr Luigi Canullo</b> Via Nizza 46 00198 Rome, Italy</p>	

# Clinical outcomes of flapless implant surgery using a handpiece driven stereolithographic surgical guide

**authors**\_Volkan Arisan\*, Z. Cuneyt Karabuda\*\*, Turkey

\*DDS, Phd, Dr, Istanbul University, Faculty of Dentistry, Department of Oral Implantology, Capa, Istanbul, Turkey

\*\*DDS, Phd, Assoc. Prof Dr, Istanbul University, Faculty of Dentistry, Department of Oral Implantology, Capa, Istanbul, Turkey

Computer aided planning and stereolithography allows clinicians to transfer the virtual implant positions to patient via surgical guide. Studies were presented using stereolithography recently, however most of were specific to an implant brand or type only. Hence, drill guidance and multiple numbers of guides inherits certain limitations and risks. A new type of surgical guide (Ötede®, Aytasarim, Ankara, Turkey) eliminating drill guidance was presented in this study.

## \_Material and methods

Following the anamnesis, clinical and radiologic examinations of the patients were completed. Patient consent form was taken for the use of a stereolithographic surgical guide and flapless surgery. Five patients were included for this study. Scan prosthesis were fabricated using duplication method and digital

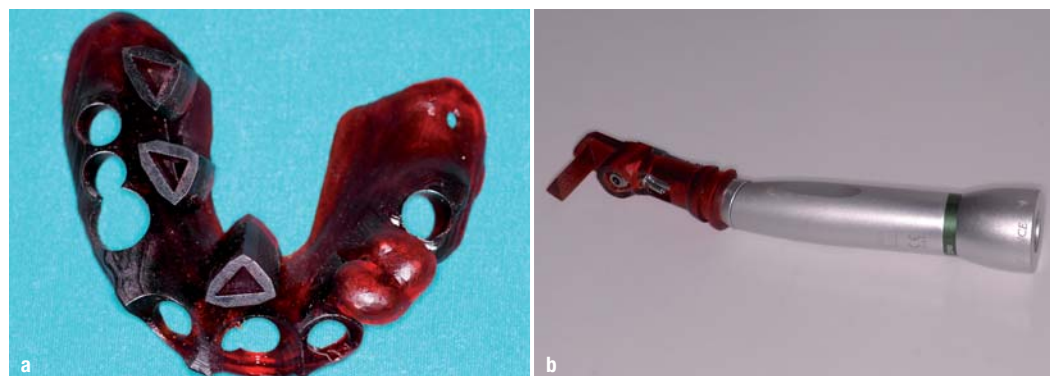volumetric tomography (DVT) were used for 3-D imaging of the patient's jaw anatomy. Implants were planned on the software according to the teeth and alveolar anatomy visualized on DVT images.

Surgical guide and handpiece attachment were fabricated with a fast prototyping machine. A triangular lock mechanism adapted on surgical guide and handpiece were used for guiding the osteotomy drills

**Table 1**\_Distortion values (mm) in periapical, panoramic and tomographic X-rays (Sonick et al. 1994)

	Mean distortion	Maximum detected distortion
Periapical	1.9	5.5
Panaromic	3.0	7.5
Computerised Tomography	0.2	0.5

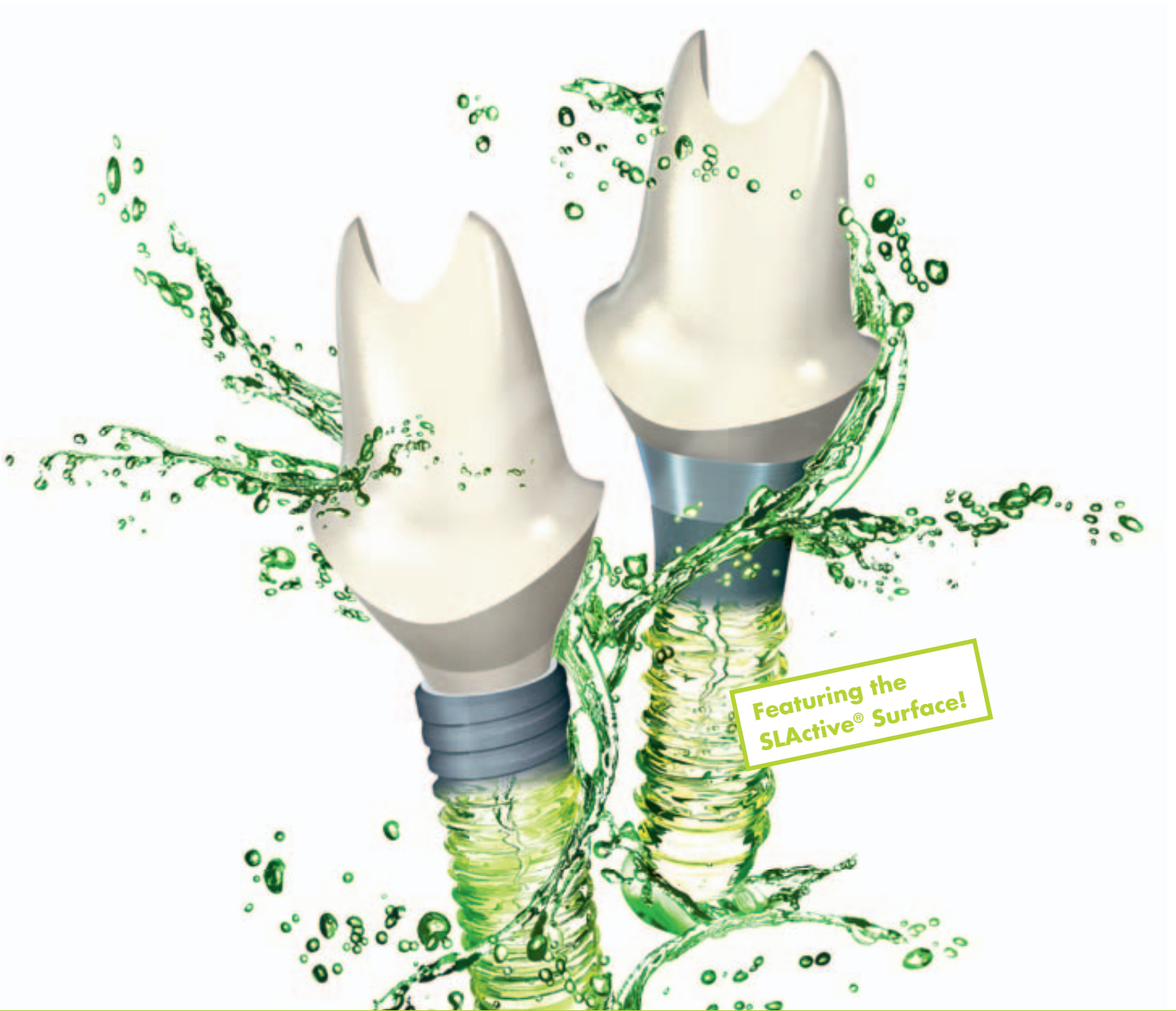**Fig. 1**\_(a) Surgical guide and (b) individual male triangular lock for the handpiece.





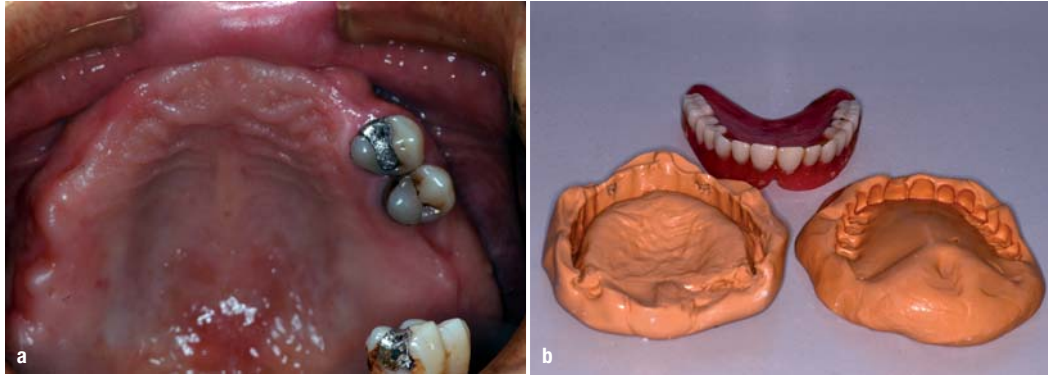
## PERFECT FIT BY DESIGN

In combining Soft Tissue and Bone Level implants with a comprehensive prosthetic portfolio, Straumann has devised one system for all indications. The **Straumann® Dental Implant System** – excellent product quality designed for convincing, naturally esthetic outcomes.



COMMITTED TO  
**SIMPLY DOING MORE**  
FOR DENTAL PROFESSIONALS

**Fig. 2** (a) Intraoral view of the maxilla, (b) duplication of the current prosthesis with Br<sub>2</sub>S<sub>4</sub>, (c) scan prosthesis, (d) planning phase.

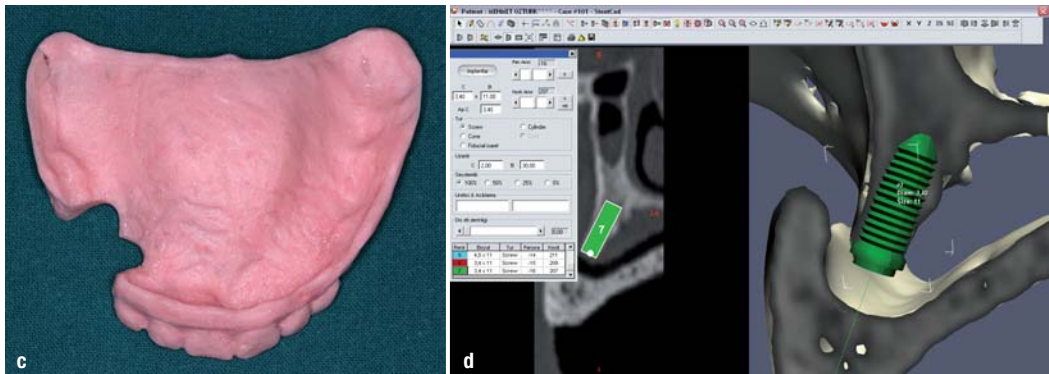


during surgery. The guide is adapted on the mucosa in occlusion to the opposing dentition then secured with fixation screws. Following the removal of soft tissue with a punch drill, osteotomy was performed and total number of 72 implants was inserted by this method. Patients were screened following the surgery and a new DVT were obtained at the stage of loading for examining the accuracy of the implant positioning. Postoperative swelling was almost unnoticeable and the pain was reported only for the day of the surgery. All implants except 2 were osseointegrated at the end of 3 months. The method enables clinician to plan and place implants without the need of an exposed flap in selected cases however a large group of cases should be analyzed for the routine use of this guidance.

### Introduction

Conventional implant planning mainly depends on panoramic X-rays. However certain drawbacks are present with panoramic and periapical X-rays such as distortion and two dimension restrictions. The difference in accuracy between different methods has been investigated and documented in a study by Sonick et al. (Table 1). Despite the acceptable mean distortion rate in panoramic and periapical X-rays maximum achieved distortion rates may lead to false proximity or intrusion to vital anatomic structures in rare occasions. Furthermore owing to the lack of anatomic references, visual planning and conventional implant placement is challenging especially in total edentulous cases. This type of a case is likely to end up with

implants engaging the approximal regions with undesired emergence profile and screw access hole. As a result the case may be a failure especially in highly demanding patients with high lip line. Surgical guides can be used to overcome this problem to a certain degree however the exact 3-D positioning is unfortunately impossible with guides based on radiologic markers, impressions and intra-oral bone mapping techniques. Following the introduction of the computerized dental tomography, diagnosis and treatment planning can be visualized on three-dimensional (3-D) images. Further development and integration of DICOM data on the specific dental implant software enabled to construct a 3-D view of the alveolar bone and place implants in real dimension accuracy. By the introduction of volumetric tomography, dose concerns with conventional CT imaging were not an issue of concern. Because the dose with a DVT is equal or slightly higher than a conventional panoramic radiograph. The surgery can be virtually performed on the computer using realistic implant fixtures. In case of having a scan prosthesis the ideal implant position can be assigned in relation to bone height, width, angulation and emergence profile. Necessity of angled abutment and possible screw access points can also be planned in advance the fabrication of the final prosthesis. Stereolithography is a relatively new advancing technology in the dental field. Engineering part of this technology is still in demand of dental view and opinion. Most systems can only offer direction guidance with the surgical guides, however few of them offer depth control but only when certain brands of implants were used. The technique is time



# PD VitalOs CEMENT<sup>®</sup>

The bone regeneration cement



## INJECTABLE

Ready to inject without premixing

## MINERAL

All-mineral concept

## OSTEOCONDUCTIVE RESORBABLE

A truly resorbable Calcium Phosphate cement

## HARDENING

Quick hardening in situ...  
stabilizing effect

EAO Monaco 2009  
Stand B131

1

stage

**Facilitates one-stage surgery**

**Optimized flow**  
complete and tight filling

**Stabilizing effect**  
strong adhesion to implant

**Solid interphase**  
cement

2-in-1

**Filler and barrier**  
bone substitute / membrane in one

**Cost effective**  
no membrane required

Ready  
to use

**Time saving**  
no premixing required

**Simplicity**  
directly injectable

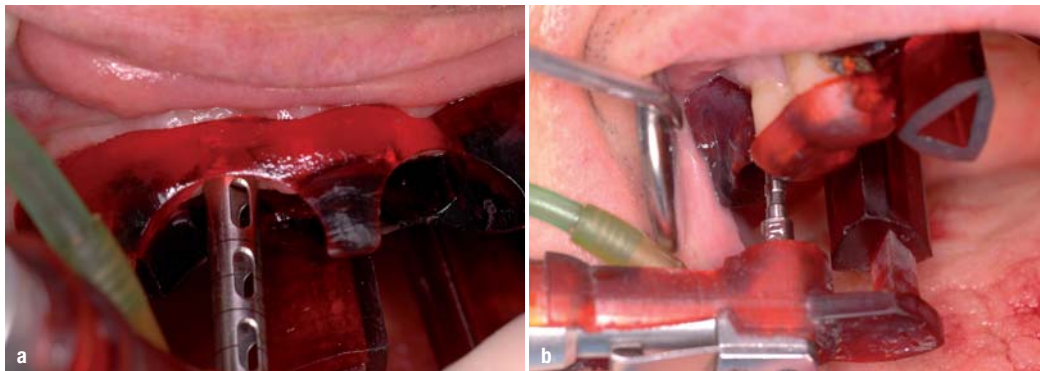
**Safe**  
reduced risk of  
contamination

[www.vitalos.com](http://www.vitalos.com)

Produits Dentaires SA / Switzerland



**Fig. 3** (a) Mucotomy was performed with a punch drill, (b) Original drills of the implant system were used for osteotomy.



consuming and costly at the moment and deviation rates is still an issue of concern. A new surgical guide (Ötede, Aytaşarım, Ankara, Turkey) is currently investigated in Istanbul University, Faculty of Dentistry, Department of Oral Implantology (Fig. 1). The main idea is to shift the guidance from drill to handpiece. A male-female triangular lock mechanism is placed to the guide. This enabled to drive the handpiece in the exact route and depth without drill dependency as seen in other systems like SimPlant, Aytaşarım3D etc. The new system requires individual stereolithographic key for the handpiece to be used in the surgery (Fig. 2). The handpiece and drills were scanned before surgery to simulate depth control and drill guidance with the handpiece.

### Material and methods

Following the anamnesis, clinical and oral examinations were performed for 5 patients with various edentulism types. The patients were informed about the flapless option with guided surgery and written consent was taken. Patient's current prosthesis was evaluated for the fit and positional accuracy. This prosthesis was duplicated in clinic with the negative impression technique. Cold polymerising acrylic was prepared with 10 per cent barium sulphate addition and mixed well then poured carefully into the drainage holes of the duplication mold. Following the setting, the mold was opened and the scan prosthesis is removed and trimmed and polished. The prosthesis is tried to ensure that the patient can wear it comfortably during tomographic scan. Any disturbing pieces or edges may lead patient to mis-position the prosthesis during scan causing error in the CT images (Fig. 2). The DICOM data is transferred to a personal computer. A 3-D implant image processing software (Implant3D, MediaLab, LaSpezia, Italy) was used to plan implants. Following the segmentation of the bone and prosthesis the implant placement is performed on the computer with guidance of the scan prosthesis.

Following the planning, the manufacturing of the surgical guide began. The system requires the scan of the handpiece head region. Drills to be used in the osteotomy were also required to be scanned for correct

depth control. All components were tried before surgery to ensure the proper operation of the triangular lock mechanism.

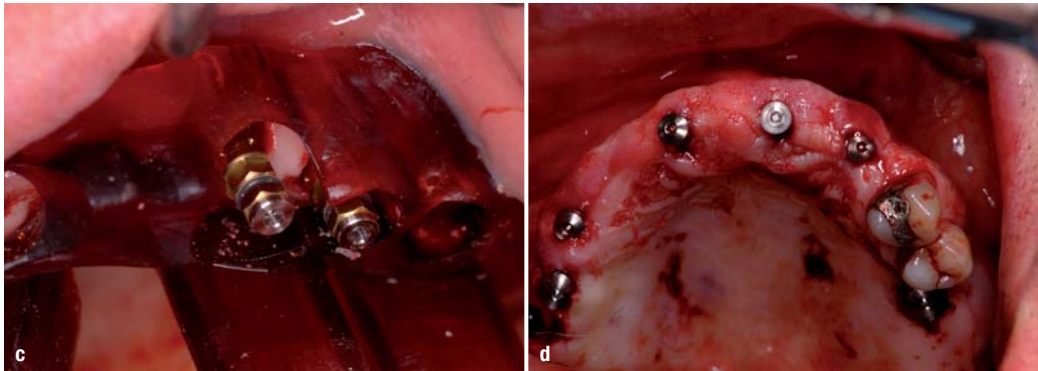
*Surgery:* The guide was tried once again for the accuracy of fit. Local anesthesia was administered with infiltration. Following the stabilization of the guide with fixation screws, handpiece lock was adapted to the handpiece. Mucotomy was performed with a punch drill. Routine osteotomy protocol was used using the triangular lock in the surgical guide. Depth control was also provided with the stop of the triangular lock. Following the insertion of the implants the guide was removed from the mouth and gingival formers are placed (Fig. 3). A total of 72 implants were placed in maxilla and mandible.

*Postoperative follow-up:* All patients were recalled after the surgery day and controlled everyday for a week. Then all patients were examined with one month intervals.

*Results:* Two implants in a patient were lost in the post-op second week. Rests of the implants were osseointegrated at the end of healing period. No complications were observed during the healing period. Swelling was minimal due to the flapless surgery. Pain complication was also recorded to be minimal and mainly experienced in the day of surgery.

### Discussion

As a result of the advances in fast prototyping and 3-D printing field, many stereolithography based surgical guide systems became available on the market for providing accurate positioning of dental implants. The procedure can be outlined as a 3-D engineering and many variations are present amongst systems. As a result the benefits vary depending on the design of the guide. All systems provide horizontal guidance but depth control is provided only in few systems intended for a specific implant system. The present surgical guide may use any type of implant drill after it has scanned. The top of the female lock mechanism attached on the surgical guide serves as a stopper for providing depth control. Drill guidance is the main base of direction in static surgical guides. To maintain the directional accuracy, most system provides se-



**Fig. 3** (c) Implants were inserted, (d) clinical view following the placement of the gingival formers.

quentially increasing diameter drill tubes either fixed or changeable. Inclusion of multiple numbers of drill guides during the surgery increases the surgical time, risk of deviation and complexity of the surgery. Some systems overcome the problem of multiple guides by using changeable tubes. However small tubes can be difficult to mount and remove in the oral environment. These small tubes bring the risk of inhalation, loss, stuck in place etc. Use of a single guide in this study significantly decreased the surgical time and relevant complications. Furthermore drill guidance requires the inclusion of metal tubes for the drill to be thoroughly operated. This may significantly reduce the irrigation and arise the risk of overheating in the osteotomy site owing to the friction and restricted liquid flow way through the metal tubes. The system used in this study does not contain any metal tubes in the drill pathway and has wide holes in the field of osteotomy allowing higher level of irrigation liquid to cool the osteotomy site. It should be always kept in mind that the risk of overheating can be a cause of failure in surgical guide systems and flapless surgery. The drill rpm should be below 750 rpm with maximum possible irrigation. Drill independency makes this system virtually suitable for any implant system which may be an advantage when compared to drill and implant system based guides.

## Conclusion

The new surgical guide in this study has promising features and advantages compared to similar stereolithographic surgical guide systems. Handpiece orientation adds additional comfort and freedom for the surgeon. Further analytic studies are required to evaluate the positional accuracy and additional benefits of this system.

## References

Sonick B. *Int J Oral Max Implants*, 1994;(9):455–460.  
 Poppe B, Looe HK, Pfaffenberger A, Chofoer N, Eenboom F, Sering M, Rühmann A, Poplawski A, Willborn K. Dose-area product measurements in panoramic dental radiology. *Radiat Prot Dosimetry*. 2007;123(1):131–4. Epub 2006 Aug 12.  
 Martegani P, Silvestri M, Mascarello F, Scipioni T, Ghezzi C, Rota C, Cattaneo V. Morphometric study of the interproximal unit in the

esthetic region to correlate anatomic variables affecting the aspect of soft tissue embrasure space. *J Periodontol*. 2007 Dec; 78(12):2260–5.

Buser D, Martin W, Belser UC. Optimizing esthetics for implant restorations in the anterior maxilla: anatomic and surgical considerations. *Int J Oral Maxillofac Implants*. 2004;19 Suppl:43–61.

Nickenig HJ, Eitner S. Reliability of implant placement after virtual planning of implant positions using cone beam CT data and surgical (guide) templates. *J Craniomaxillofac Surg*. 2007 Jun–Jul;35 (4–5):207–11. Epub 2007 Jun 18.

Widmann G, Widmann R, Widmann E, Jaschke W, Bale R. Use of a surgical navigation system for CT-guided template production. *Int J Oral Maxillofac Implants*. 2007 Jan–Feb;22(1):72–8.

Lascala CA, Panella J, Marques MM. Analysis of the accuracy of linear measurements obtained by cone beam computed tomography (CBCT-NewTom). *Dentomaxillofac Radiol*. 2004 Sep;33(5):291–4.

Meyer U, Wiesmann HP, Runte C, Fillies T, Meier N, Lueth T, Joos U. Evaluation of accuracy of insertion of dental implants and prosthetic treatment by computer-aided navigation in minipigs. *Br J Oral Maxillofac Surg*. 2003 Apr;41(2):102–8.

Sherry JS, Sims LO, Balshi SF. A simple technique for immediate placement of definitive engaging custom abutments using computerized tomography and flapless guided surgery. *Quintessence Int*. 2007 Oct;38(9):755–62.

Sarment DP, Al-Shammari K, Kazor CE. Stereolithographic surgical templates for placement of dental implants in complex cases. *Int J Periodontics Restorative Dent*. 2003 Jun;23(3):287–95.

Tardieu PB, Vrielinck L, Escolano E, Henne M, Tardieu AL. Computer-assisted implant placement: scan template, simplant, surgiguide, and SAFE system. *Int J Periodontics Restorative Dent*. 2007 Apr;27(2):141–9.

## contact

## implants

### Z. Cuneyt Karabuda

Istanbul University, Faculty of Dentistry  
 Department of Oral Implantology  
 34390, Capa, Istanbul, Turkey  
 Phone: +90-21 25 32 32 18  
 Fax: +90-21 25 32 32 54  
 E-mail: zcuneyt@istanbul.edu.tr





**Implant  
Direct™**

simply smarter.

[www.implantdirect.com](http://www.implantdirect.com)

## SwissPlant Implant

with All-in-1 packaging includes:  
Cover Screw, Healing Collar,  
Transfer and Straight Abutment  
with Snap-on Comfort Cap  
SwissPlant EU price = €145

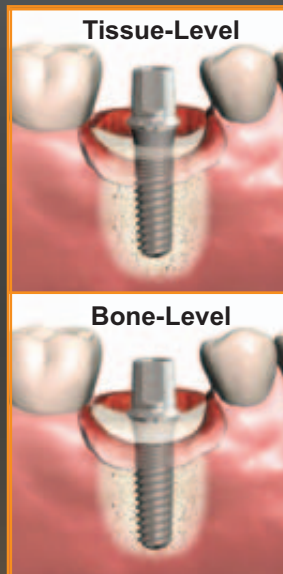



## New Generation Tissue-Level Implant

- Tapered, self-tapping with micro-threads
- Compatible with Straumann's 1-Stage implant
- Unique square/octagon internal connection
- Lightly blasted neck for 1- or 2-stage surgery
- More diameter options including 3.3mmD & 5.7mmD
- All-in-1 Packaging for added value.

### FEATURES AND BENEFITS

1. Body Design: Tapered with double-lead buttress threads
2. Surface/Body: SBM Medium Texture with 17 year history
3. Surface/Neck: SBM Light Texture for soft or hard tissue
4. Diameters: Standard 4.1mm and 4.8mm plus 3.3mm & 5.7mm
5. Platforms: Standard 4.8mm and 6.5mm internal octagon plus 3.7mm hex with Platform Switch
6. Fixture-mount/Transfer/Abutment: Engages square within octagon



\* The 4.1mm and 4.8mm SwissPlant implants can be inserted into soft bone using Straumann's drills. An additional drill is required for dense bone or countersinking for bone-level placement. Implant Direct's ratchet, insertion tool and 1.25mmD hex tool are also required.

**SwissPlant™**



## New Generation Bone-Level Implant

- Tapered, self-tapping with micro-threads
- Compatible with Zimmer's Screw-Vent implant
- Color coded hex/bevel conical connection
- Platform switching interface
- More diameter options including 3.2mmD & 5.2mmD
- All-in-1 Packaging for added value.

Implant Direct USA  
 • 27030 Malibu Hills Road,  
 Calabasas Hills, CA 91301  
 • Phone: +1 818 444 3333

Implant Direct Europe AG  
 • Förrlibuckstrasse 150,  
 8005 Zürich, Switzerland  
 • Phone: 00800 4030 4030

### FEATURES AND BENEFITS

#### 1 Body Design:

Evenly Tapered with self-tapping grooves from mid-point to apex.



#### 2 Thread Design:

Micro-threads with progressively deeper, double-lead, buttress threads.



#### 3 Surface Options - 17 year history:

SBM - medium rough texture;  
 HA Coating below micro-threads.



#### 4 Diameter Options:

Six Diameters from 3.2mmD to 5.7mmD in 0.5mmD increments.



#### 5 Conical Connection:

Lead-in Bevel above Internal Hex - 23 year history (Niznick #4,960,381)  
 Color Coded for easy Identification;  
 Platform Switching on 3.2mmD, 4.2mmD and 5.2mmD Implants.

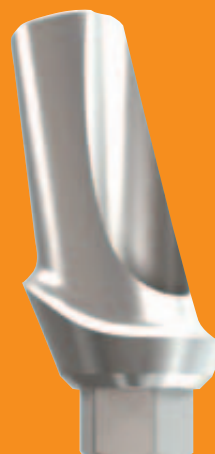


#### 6 Fixture-mount Packaging:


Fixture-mount standardizes insertion tools, serves as Transfer and can be shortened for use as Final Abutment.



**Legacy™ 3 Implant**  
 with All-in-1 packaging includes:  
 Cover Screw, Healing Collar,  
 Transfer and Straight Abutment  
 Legacy3 EU price = €125



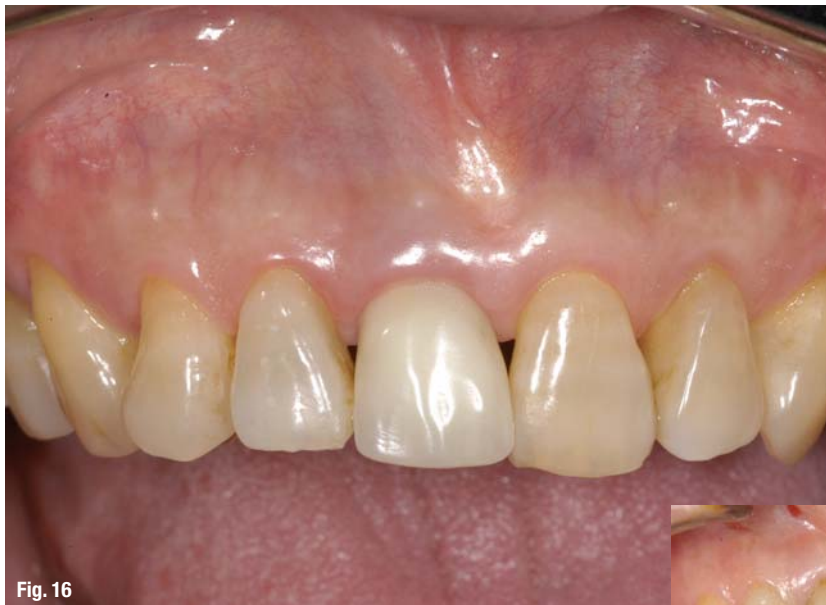Prosthetic compatibility with Screw-Vent, BioHorizons and MIS Implants



Legacy™ 3

# Extraction, **immediate implant placement** and guided bone regeneration using a flapless approach

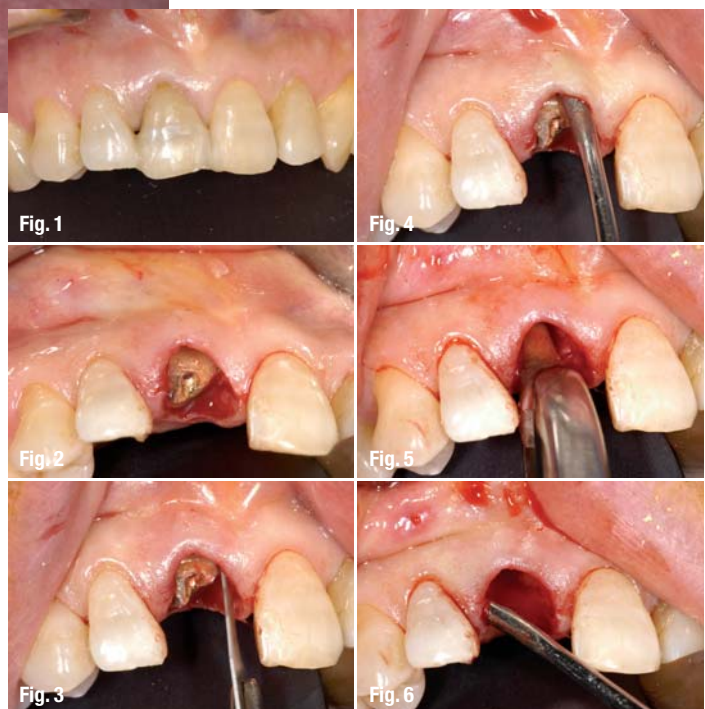
author\_Barry K. Bartee, DDS, MD, USA

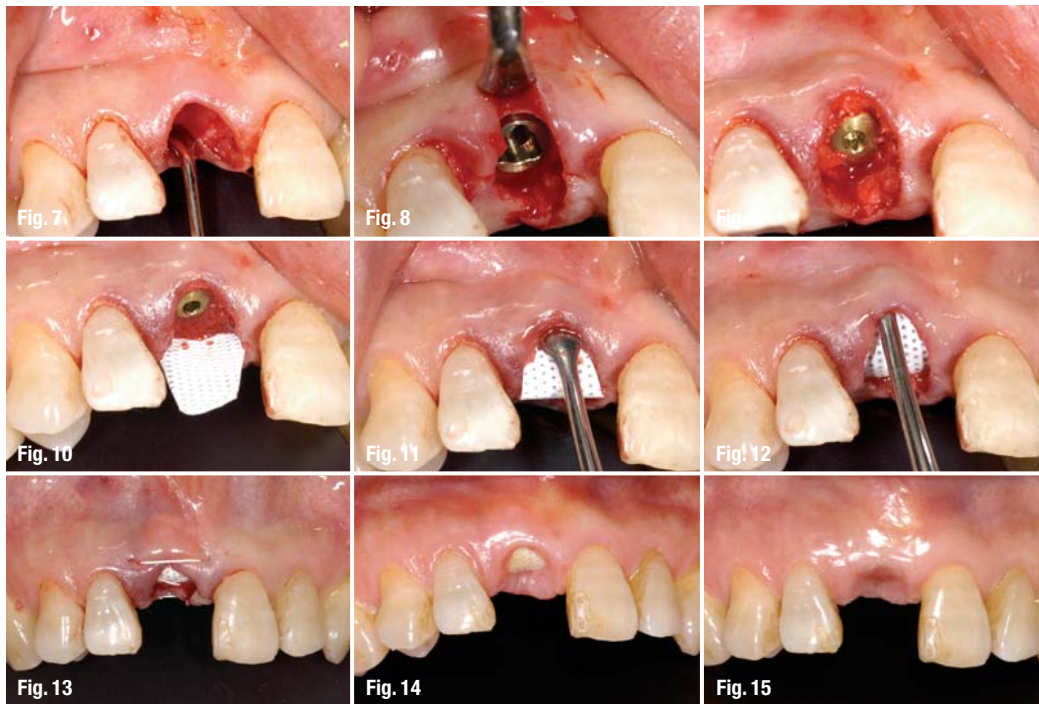


tical incisions to achieve primary closure. Because of the unique features of Cytoplast® dense PTFE membranes and the ability of the membranes to remain exposed in the oral cavity without risk of infection, the soft tissue architecture, keratinized tissue width and position of the mucogingival junction adjacent to the socket can be preserved. Using the minimally invasive tunneling technique described in this article facilitates minimally invasive socket reconstruction avoiding vertical incisions and incision of the interdental papillae. The technique described can be used for immediate implant placement, as in this case, or for socket preservation using particulate graft material if a staged approach is desired.

## Introduction

Esthetic requirements for implant supported restorations include the presence of natural soft tissue contours, and to the extent possible, the full presence of the interdental papillae. Regardless of the technique used for tooth extraction, some degree of soft and hard tissue loss is inevitable. The use of guided tissue regeneration membranes over sockets has been shown to be one method to preserve bone after extraction, but most techniques involve the use of large flaps and even ver-





## Case Presentation

This is a 60-year-old female who presented with a crown-root fracture of a non-vital maxillary right central incisor. The crown was temporarily stabilized with composite resin bonded to the adjacent teeth (Fig. 1). Extraction of the tooth and immediate implant placement was planned. To minimize soft and hard tissue recession, a flapless, minimally invasive extraction technique was employed (Fig. 2). The tooth root was extracted using only an intrasulcular incision. A #15 blade was used to sever the periodontal ligament and create space for root luxation and elevation (Fig. 3). Next, a subperiosteal pocket was created on the buccal and palatal aspect of the socket using a micro periosteal elevator (Fig. 4). Following luxation and initial elevation of the root with the micro elevator, the tooth was removed with forceps (Fig. 5). The interdental papillae were carefully undermined and elevated. This can be done with a small periosteal elevator or curette (Fig. 6). All remaining soft tissue was removed from the interior and margins of the socket with a sharp curette (Fig. 7). The implant osteotomy was done in the standard fashion, with the implant being placed against the palatal wall of the socket (Fig. 8). The gap between the facial aspect of the implant and the buccal wall was filled with a combination of autogenous bone chips harvested from the implant osteotomy combined with allograft bone (Fig. 9). A textured, high-density PTFE barrier membrane is placed. The membrane is trimmed, then placed into the superosteal pocket on the palatal aspect (Fig. 10). The membrane is then tucked under the facial flap (Fig. 11). Next, the membrane is tucked under

the interdental papillae, taking care to keep the edge of the material a minimum of 1.0 mm away from adjacent tooth roots (Fig. 12). A single 3-0 PTFE suture is placed to further stabilize the membrane. The membrane is intentionally left exposed, as primary closure is not required in this technique (Fig. 13).

Figure 14 shows the surgical site at three weeks. The exposed membrane is easily removed by grasping with a tissue forceps. Topical anesthesia may be used, but local anesthesia is not necessary.

The site at six weeks after implant placement (three weeks after membrane removal), reveals keratinized mucosa forming across the former extraction site (Fig. 15).

Figure 16 shows the clinical view following placement of the implant abutment and acrylic provisional restoration.

## Summary

The flapless technique described provides a minimally invasive approach to extraction with socket grafting or immediate implant placement. Because the interdental papilla remains intact, there is less disruption of blood supply. As a result, there is a greater potential for maintenance of soft tissue volume. In addition, the use of a dense PTFE membrane improves the predictability of immediate implant placement, excluding the requirement for primary closure and resultant disruption of soft tissue architecture.

Cytoplast® is a registered trademark of Osteogenics Biomedical, Inc.

© 2008 Osteogenics Biomedical, Inc. BBFY0607

## contact implants

**Barry K. Bartee, DDS, PA**  
3234 64th Street  
Lubbock, Texas 79413  
USA  
Phone: +1-806-792-0030  
Fax: +1-806-792-8730  
E-mail: dr2bkb@aol.com

# Precautions for using zirconia implant abutments

**authors** Moustafa N Aboushelib\*, Egypt, and Rien van Paridon\*\*, Netherlands

\*DDS, MSc, PhD, Dental Biomaterials department, Faculty of Dentistry, Alexandria University, Egypt

\*\*DDS, PhD, Materials Science Department, ACTA, University of Amsterdam and the Free University, The Netherlands

The introduction of zirconia to the dental field opened the design and application limits of all-ceramic restorations. Thanks to its high strength and fracture toughness long span posterior restorations are now possible with high accuracy and success rate. Additionally, its white color allowed better reproduction of the required color especially in the anterior zone. These properties made zirconia an interesting material for the construction of implant abutments and superstructures.<sup>1</sup>

The fabrication of zirconia implant abutments utilizes state of the art CAD/CAM technology which uses patient's models for the production of an individual customized abutment.<sup>2</sup> Moreover, the CAD phase allows accurate positioning and angulation of the zirconia abutment ensuring obtaining the best esthetics.

The fabrication of zirconia implant abutments is complicated by the problem of providing adequate fixation to the implant body. For titanium abutments, the fixation screw exerts direct pressure on the abutment which in turn is provided with external or internal hex to provide connection with the implant body. On the other hand, zirconia is a brittle

material and friction between the fixation screw and the internal surface of the ceramic abutment could produce high internal stresses which could lead to unexpected fracture.<sup>3</sup>

This problem is solved by insertion of a friction fit internal metallic nut (Procera zirconia abutment for Strauman implants) which is equipped with an external hex for establishment of proper contact with the implant body (Fig. 1). Additionally, the fixation screw interlocks with the metallic nut during tightening procedure (Fig. 2). This design is associated with the problem of generation of internal stresses which could lead to unexpected fracture of the zirconia implant abutment. This article evaluated the fracture causes of several broken zirconia implant abutments. Fractographic analysis of the broken segments allowed recognition of the location and site of the critical fracture.

## Case presentations

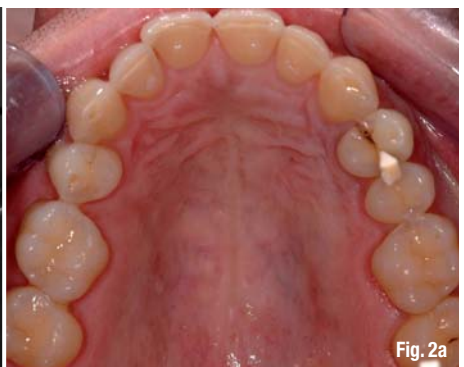

### Case 1

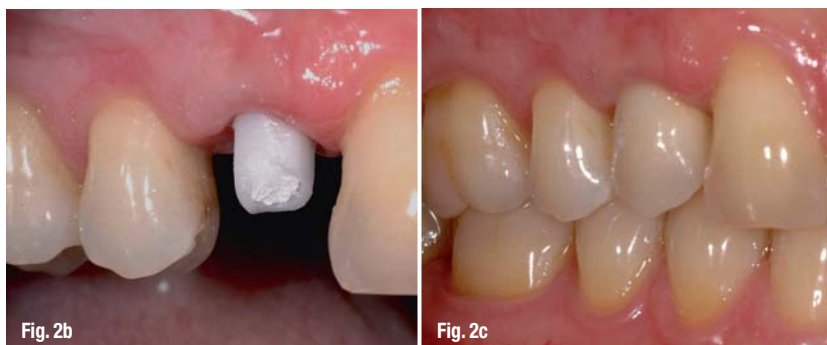A broken zirconia implant abutment was sent by the treating dentist for fracture analysis. Patients

**Fig. 1** SEM image, 27x. Internal metallic nut which depends on friction fit inside the zirconia implant abutment.

**Fig. 2** SEM image, 10x. The metallic fixation screw used to press on the metallic nut for providing adequate retention with the implant body.

**Fig. 2a** A broken maxillary premolar was extracted and implant was immediately inserted.





**Fig. 2b\_** Procera zirconia abutment. **Fig. 2c\_** Procera zirconia veneered crown inserted over the zirconia abutment.

records indicated that the patient complained of loosening of the implant supported zirconia veneered crown (tooth 21). The treating dentist also complained that the internal metallic nut lost friction contact with the zirconia abutment and that he had to re-assemble the components before screw fixation. The abutment was fractured after two incidence of screw loosening. The same problem led to fracture of the second abutment after which the dentist decided to insert a titanium abutment. Scanning electron microscopic examination indicated that the abutment was fractured due to pressure from the metallic screw nut.

#### The solution

Once the metallic nut has lost friction fit with the zirconia abutment it can not be correctly reinserted inside the abutment and areas of friction contact between the improperly assembled components could lead to generation of high internal stresses causing fracture of the zirconia implant abutment as was reported for the two examined abutments. A new abutment should be used in such case.

#### Case 2

A broken zirconia implant abutment was examined. SEM analysis revealed that it was an angled abutment which corrected the tilt of an implant replacing a maxillary lateral incisor. The entire buccal wall was fractured beneath the temporarily cemented zirconia veneered crown.

#### The solution

Zirconia is a brittle ceramic material that must be used in adequate thickness to gain full potential of its high strength. A minimal wall thickness (0.5-0.7mm) is required in the entire structure of the zirconia implant abutment. This thickness must be increased in areas of high stresses to avoid unexpected fracture. Tilt correction—resulted in over reduction of the buccal wall (0.3 mm thickness) which resulted in fracture of the weakened segment. To reduce possibility of fracture, it is recommend to use a metallic abutment for correction of angle of insertion.

#### Case 3

A broken veneer porcelain from a Procera zirconia superstructure. This new design combines both the implant abutment and the framework of the restoration in one single structure thus reducing the number of components the dentist uses during the prosthetic phase.

This single component zirconia structure does not utilize an internal metallic nut for achieving contact with the implant body. On the contrary, this single component super structure utilizes directly the fixation screw to obtain direct fixation to the implant body.

#### The solution

Using single component superstructures has several advantages as it simplify the handling procedure, does not require anti-rotation feature, and reduces the num-

# sticky granules

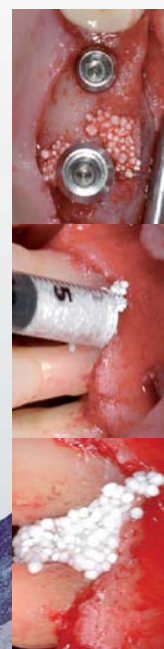
# bionic

**easy-graft™** 

injectable  
insitu hardening  
100% synthetic bonegraft

The  $\beta$ -TCP composite for all indications

easy-graft™



„the swiss rock...“

**DS**  
**DENTAL**

Degradable Solutions AG  
Wagistrasse 23 · CH-8952 Schlieren  
phone: +41 (0)43 433 62 60  
fax: +41 (0)43 433 62 61  
dental@degradable.ch · www.degradable.ch

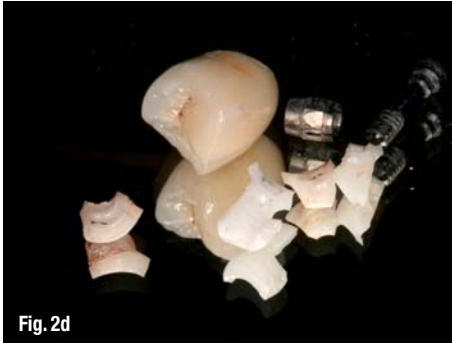

Fig. 2d

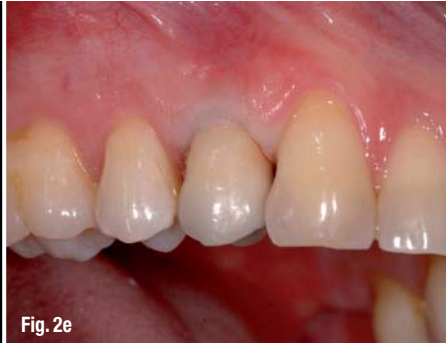

Fig. 2e



Fig. 3

**Fig. 2d\_** The first and the second Procera zirconia abutments were fractured after short period of service intra-orally.

**Fig. 2e\_** A new zirconia veneered crown was inserted over a titanium abutment. Observe the grayish color at the cervical margin.

**Fig. 3\_** Digital image demonstrating a fractured zirconia abutment due to over reduction of the buccal wall.

**Fig. 4a\_** Digital image of a broken veneer porcelain from a four unit implant supported fixed partial denture.

**Fig. 4b\_** Digital image demonstrating the contact surface with the implant body. Antirotation is not required for this fixed partial denture as the whole framework and the implant abutment are joined into a single superstructure.

ber of structural interfaces of the entire restoration. On the other hand, it requires careful design to provide adequate support for the veneer ceramic.

### Discussion

Analysis of the broken zirconia implant abutment gave insight about the cause of fracture. For Procera abutments with the metallic nut, the friction fit system lost adequate retention after a short service time in the mouth leading to loosening of the inserted restorations. According to complains of the treating dentists, it is not recommended to re-assemble the metallic nut and tighten the fixation screw as this will not result in reliable retention of the restoration. In such case, it is recommended to insert a new abutment from the manufacturer using patient's records.

Moreover, over tightening the fixation screw beyond the recommended torque could lead to generation of wedging forces inside the zirconia abutment. The screw head could exert pressure on the metallic nut leading to spreading of its vertical walls. Using a confirmatory X-ray before tightening the fixation screw and restriction to the recommended torque could prevent such problem. For cases with marked angle correction, it is recommended to use a metallic abutment in order to avoid over reduction of its axial walls.

On the other hand, using single component zirconia implant superstructure which is composed of zirconia abutment and the framework as one component could facilitate easier handling and simplify insertion procedure due to reduction of the components used. Moreover, careful design consideration of the requirements of both the abutment and the zirconia framework is mandatory to ensure good function of each element. Lack of adequate support beneath the veneer ceramic or over reduction of the axial walls of the zirconia abutment could lead to unexpected fracture.

### References

- [1] Wang H, Aboushelib MN, Feilzer AJ. Strength influencing variables on CAD/CAM zirconia frameworks. *Dent Mater.* 2008; 24:633-8.
- [2] Aboushelib MN, De Kler M, van der Zel JM, Feilzer AJ. CAD/CAM veneering of zirconia restorations. *Int J Prosthodont.* 2007; Accepted.
- [3] Canullo L. Clinical outcome study of customized zirconia abutments for single-implant restorations. *Int J Prosthodont.* 2007; 20:489-93.

_contact	implants
E-mail: info@aboushelib.org	

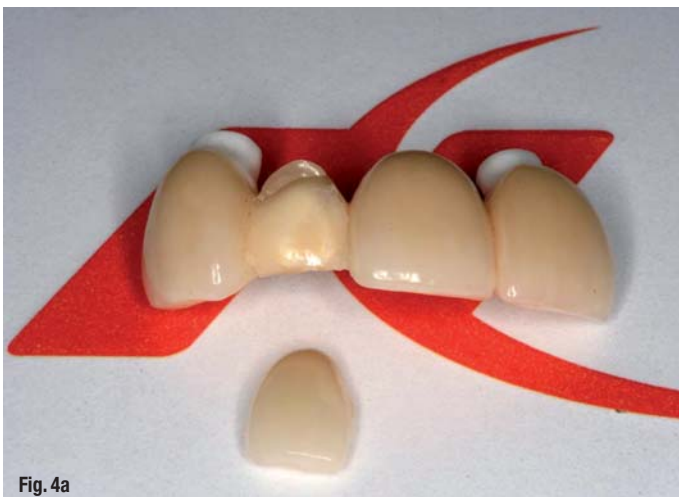

Fig. 4a

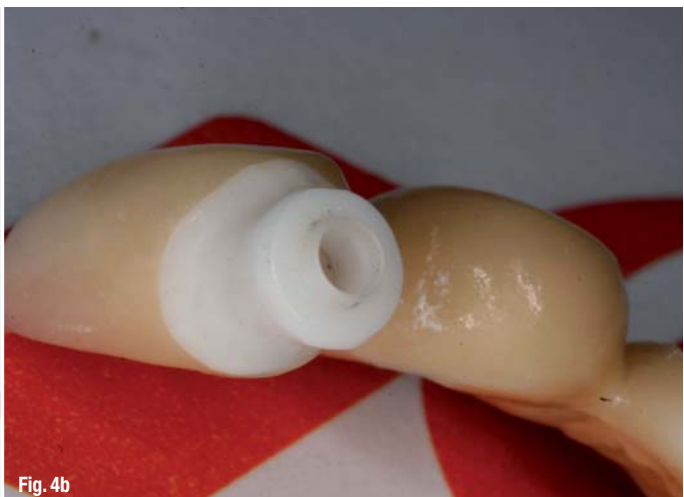

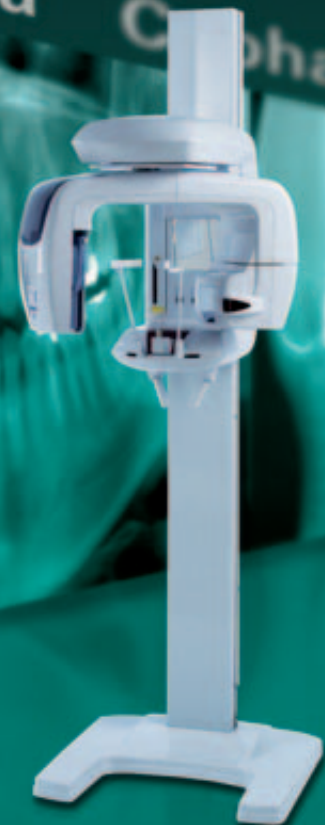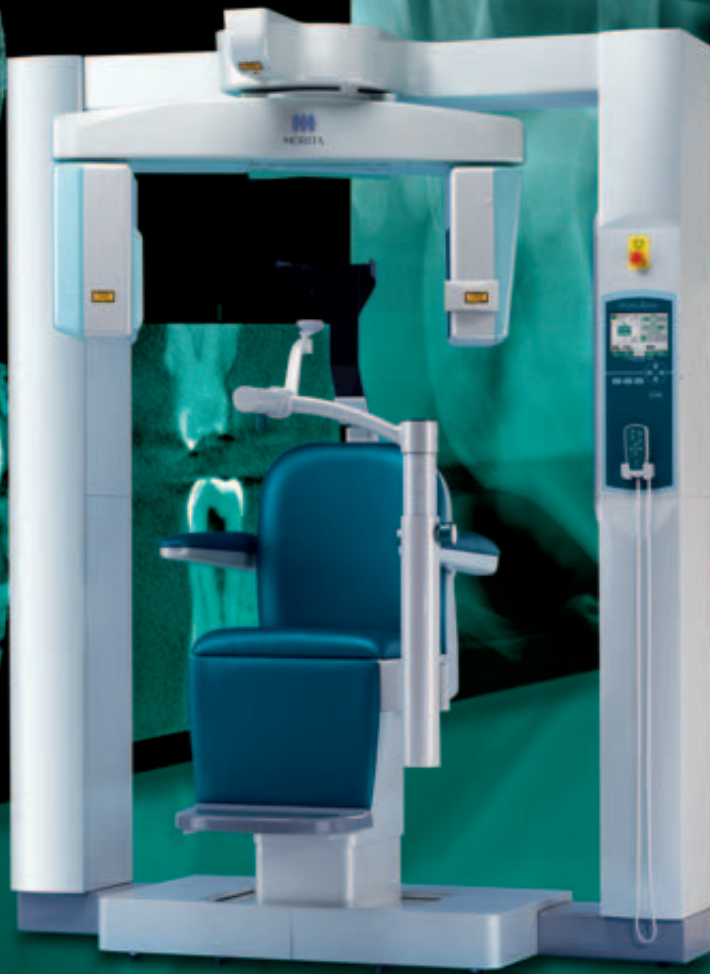Fig. 4b

3D

Panorama

Veraviewepocs 2D/3D

3D Accutomo 170



## The Number One in Every Class




J. MORITA MFG. CORP.

Whether your interest is digital panoramic, cephalometric or 3D imaging – at J. Morita you always get the best device for the most precise diagnoses. As a pioneer in volume tomography we are familiar with the high requirements of diagnosticians. Our wide variety of devices and choice of combinations provide you with the sharpest imaging of details down to 80 µm.

From the first step, upgradable 2D devices, to the basic version Veraviewepocs 3De and the high-quality X-Ray CT unit 3D Accutomo 170, one thing always remains unchanged: You obtain the highest imaging quality from the lowest effective radiation dose and the shortest scan times. Nothing is more elementary than the correct diagnosis.

Trust the number one in the class! We would be happy to advise you. Phone +49 (6074) 836-0 or visit our website at [www.jmoritaeurope.com](http://www.jmoritaeurope.com)



**Volume Size**

- 40 mm x 40 mm
- 60 mm x 60 mm
- 80 mm x 80 mm
- 100 mm x 100 mm
- 170 mm x 120 mm

Thinking ahead. Focused on life.





# Resorption mechanism of an injectable calcium phosphate bone regeneration cement—Radiographic and histological monitoring

author\_Sérgio Alexandre Gehrke, Brazil

## Introduction

Calcium phosphate cements have been extensively studied since the 80's for their application as bone substitutes in various indications, mainly in the orthopaedic and odontology fields. They are well suited for osseous repair and reconstruction, because they proved to be biocompatible, osteoconductive and resorbable. However, their main interest lies in the fact that they are easy to apply in situ, can be shaped, and finally harden, thus providing a stability which is beneficial to the reconstruction site and the whole bone formation process.

Calcium phosphate bone cements are often known as products exhibiting very slow resorption. It was even shown that a particular apatite cement presents extremely limited resorption and osteoconduction after 12 months in a sheep model for craniofacial repair (Zins 2008). This slow resorption characterizing some calcium phosphate cements is partly due to the absence of macroporosity in the hardened cement. Nevertheless, it is important, when dealing with bone cements, to look into their composition once hardened. Most of the calcium phosphate bone ce-

ments consist of apatite after setting (hydroxyapatite or carbonated apatite), which is the most stable phase in vivo. Another type of calcium phosphate cement is the brushite cement. Brushite is the less stable calcium phosphate compound in vivo, and the only one to be soluble in blood serum. This means that the chemical nature of brushite cements (quickly resorbed) theoretically compensates their lack of macroporosity (slowing down the resorption rate). This difference in resorption process between apatite and brushite cement was clearly evidenced by Apelt and co-authors in a sheep model study (Apelt 2003).

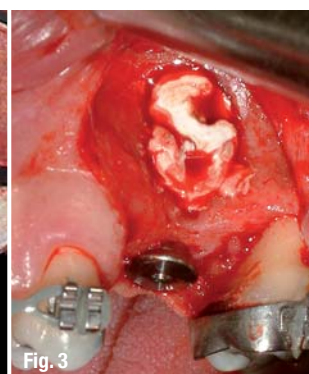
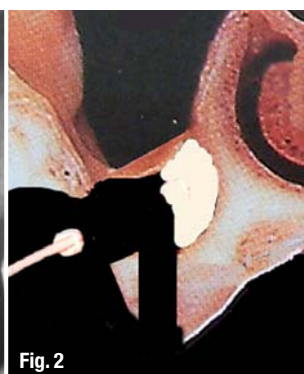
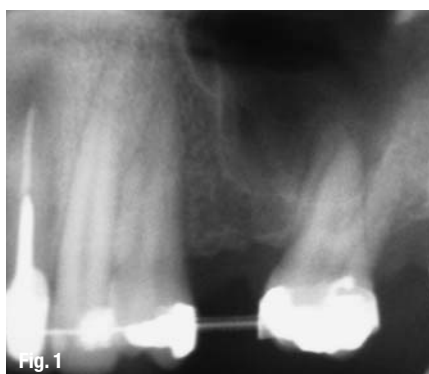As far as we know, most of the brushite cements are still in the development phase and only two of them are already on the market: one for orthopedic surgery (Jectos®, Kasios®, France), and one for dental applications. The latter is called PD VitalOs Cement® (Produits Dentaires SA, Switzerland). It has been specifically designed for dental surgery and offers the following practical advantages:

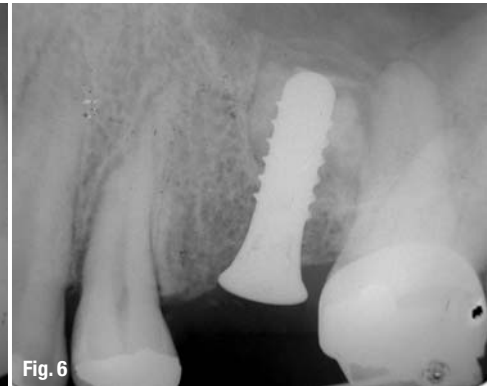
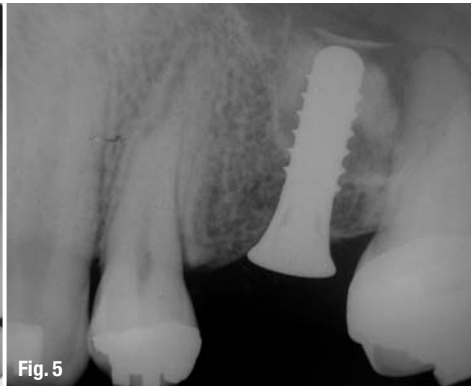
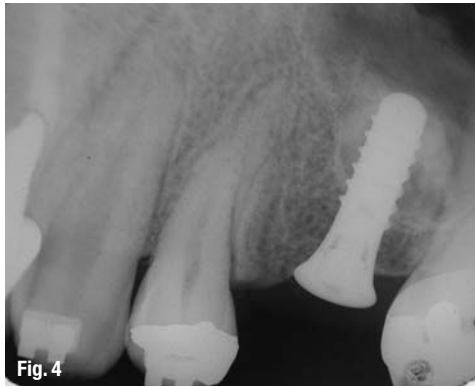- \_ It can be easily injected in cavities offering limited access;
- \_ It is ready to inject: no preparation of the cement is needed during surgery;

Fig. 1 Pre-operative radiograph (case I).

Fig. 2 Illustration of the installation of the first cement portion, against the inner wall of the sinus cavity.

Fig. 3 Sinus cavity completely filled with VitalOs, after installation of the implant.





— It anchors well onto the bone and implant surfaces, providing suitable stability between bone and implant;

— It hardens, acquiring its own mechanical stability;

— It shows adequate radiopacity allowing radiographic monitoring of its resorption.

This paper aims at understanding the resorption process of PD VitalOs Cement and simultaneous bone neoformation, when the cement is used in osseous defects around implants. Two cases were selected to show how the cement degradation can be followed up through radiographic monitoring. To illustrate and provide explanation to some of the findings, results of an *in vivo* study run by the author are presented as well. In this study, the resorption of various bone substitutes and simultaneous bone neoformation were followed up with the help of fluorescent bone markers.

### — Case I

The first case is a 30-year-old male patient, in good health condition, non-smoker, presenting with absence of tooth 25, with pneumatization of the maxillary sinus.

This situation required the regeneration of osseous tissue for the installation of a dental implant. As there was enough bone structure to provide the implant with primary stability, a sinus floor elevation was proposed, with installation of the implant in the same surgery.

### *Surgical protocol*

After administration of a local anesthetic, a lateral access to the sinus cavity was performed through a lateral window. Then, the sinus membrane was carefully lifted up to the desired height. The drilling of the site was performed according to the recommendations of the manufacturer. During this phase, particular attention was paid to avoid perforating the membrane with the drills. A gaze humidified with a vasoconstrictor solution was placed into the sinus cavity for five minutes to control the bleeding as efficiently as possible. Indeed, blood flow must be avoided during injection of the PD VitalOs cement in order to allow contact between Cement and bone and anchoring of VitalOs onto the sinus wall. Then, the cement was injected into the sinus to fill the space between the inner (nasal) wall of the cavity and the space prepared for the installation of the implant (Fig. 2). Once the cement was hard, the implant was installed as planned. Finally, the rest of the cavity was filled up with VitalOs up to the edges of the lateral window, without using a membrane. Indeed, the use of a membrane is not necessary with VitalOs, since the product acts itself also as a barrier.

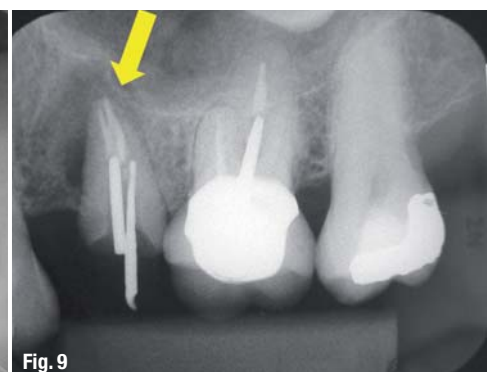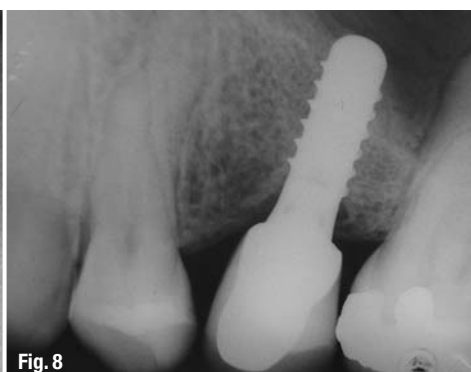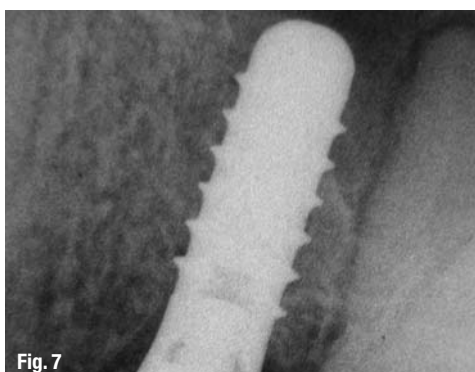
### *Radiographic control*

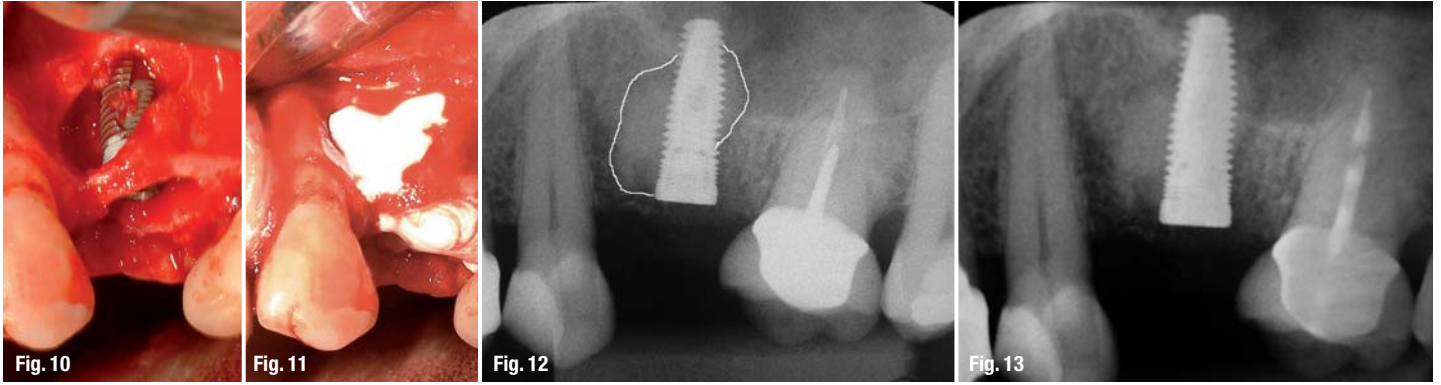
Thanks to the adequate radiopacity of the cement, it is easy to perform a radiographic follow-up and analysis of the resorption and new bone growth. Radiographs were therefore taken at 30, 60, 120 and 180 days after implant installation (Figs. 4–7), as well as 12 months (Fig. 8) after installation of the

**Fig. 4–7**— Radiographs of case I at 30, 60, 120 and 180 days after surgery.

**Fig. 8**— Radiograph of case I taken 12 months after loading.

**Fig. 9**— Pre-operative radiograph (case II).





**Fig. 10, 11**\_ Implant installation and filling with PD VitalOs Cement.

**Fig. 12–15**\_ Radiographs of case II at 30, 60, 120 and 180 days after surgery.

**Fig. 16**\_ Radiograph of case II taken 12 months after loading.

restoration, to follow-up the behavior of the new bone after loading of the implant.

**\_Case II**

The second case is a 40-year-old female patient in good health condition, non-smoking, presenting with a fracture of tooth 14 and presence of a large radicular cyst (Fig. 9) requiring removal of the root. The site presented a very large loss of bony structure, with fenestration of the buccal side of the socket wall. Therefore, the implant could only be stabilized in the inferior wall of the sinus cavity with the use of Summers' osteotomes.

*Surgical protocol*

After administration of a local anesthetic, the access to the remaining portion of the root was performed and the root was carefully extracted, paying attention to preserve as much as possible the remaining osseous tissue. Thorough curettage of the apical portion was made to remove completely the cyst and the soft tissues. The implantation bed was then prepared with the osteotomes in order to gain sufficient stability. The implant was installed (Fig. 10) and the large bony defect was filled with the injectable VitalOs Cement (Fig. 11). At this stage it is important to control bleeding during and after injection until the cement is set. This is done with the help of a suction canula in the vicinity of the hardening cement. Although the cement itself promotes to a certain extent hemostasis in the site where it is injected,

the bleeding occurring in the neighboring soft tissues must be controlled during the five minutes necessary for the cement to set.

*Radiographic control*

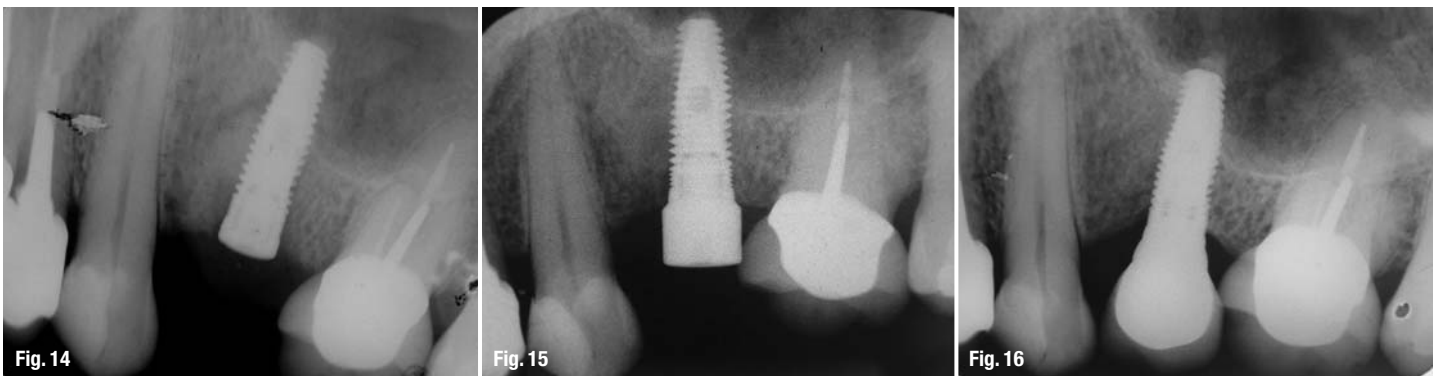
The control performed followed the same schedule described for the case I, i.e. radiographs were taken at 30, 60, 120 and 180 days after implant installation (Figs. 12–15), as well as 12 months (Fig. 16) after installation of the restoration.

**\_Histological study in animal model**

It is quite interesting to link the radiographic control of the presented cases with histological results obtained from a study where various bone substitutes were implanted in rabbit tibiae. The bone neoformation in the augmented cylindrical defects (4 mm diameter) was followed up by injecting poly-fluorochromic bone markers during the first weeks following surgery: alizarin after 14 and 21 days, calcein after 28 and 35 days, tetracycline after 42 and 49 days. The animals were sacrificed at day 56. The investigated products were two granular bone substitutes (Geistlich Bio-Oss® and Straumann® Bone Ceramic) and a bone cement (PD VitalOs Cement®).

**\_Results**

The radiographs taken 30 days after surgery show the beginning of resorption at the periphery of the





# Legacy™3 Implant System

## Conical Connection with Platform Switching


### All-in-one Packaging Including Implant, Cover Screw, Healing Collar, Transfer and Final Preparable Abutment

**THE NEXT GENERATION**  
in Implant Technology



#### FEATURES AND BENEFITS

- 1. Body Design:**  
Evenly Tapered with self-tapping grooves from mid-point to apex.
- 2. Thread Design:**  
Micro-threads with progressively deeper, double-lead, buttress threads.
- 3. Surface Options - 17 year history:**  
SBM - medium rough texture;  
HA Coating below micro-threads.
- 4. Diameter Options:**  
Six Diameters from 3.2mmD to 5.7mmD in 0.5mmD increments.
- 5. Conical Connection:**  
Lead-in Bevel above Internal Hex -  
23 year history (Niznick #4,960,381)  
Color Coded for easy Identification;  
Platform Switching on 3.2mmD,  
4.2mmD and 5.2mmD Implants.
- 6. Fixture-mount Packaging:**  
Fixture-mount standardizes  
insertion tools, serves as  
Transfer and can be shortened  
for use as Final Abutment.



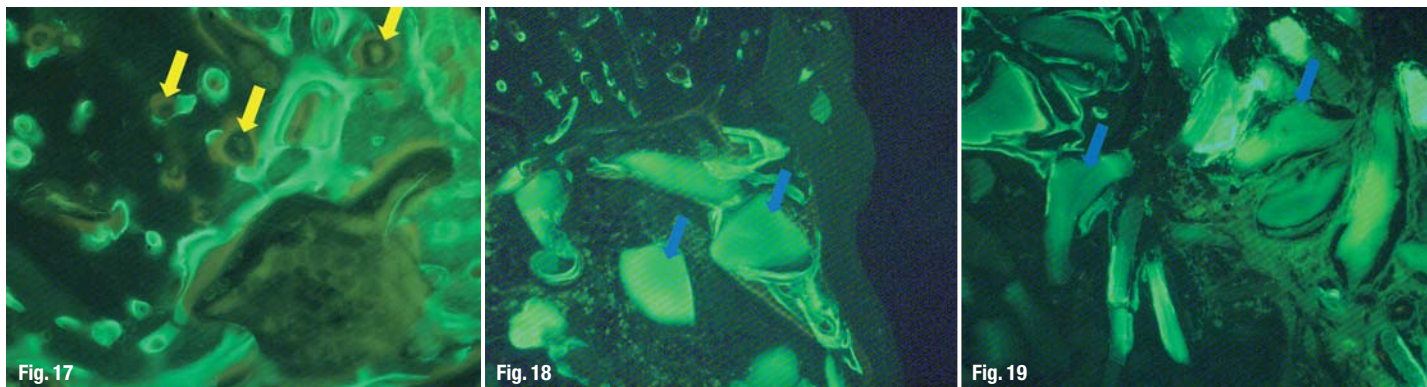
Prosthetic compatibility with Screw-Vent, BioHorizons and MIS Implants

Legacy™3



Implant Direct Europe AG • Förlibuckstrasse 150,  
8005 Zürich, Switzerland • Phone: 00800 4030 4030

Implant Direct USA • 27030 Malibu Hills Road,  
Calabasas Hills, CA 91301 • Phone: +1 818 444 3333  
[www.implantdirect.com](http://www.implantdirect.com)



**Fig. 17–19** Fluorescence histologies of sites filled with VitalOs, Bio-Oss and Bone Ceramic respectively.

VitalOs cement. This process progresses towards the center of the cement mass. In the sinus lift case, the progress also takes place from the coronal towards the apical region around the implant (yellow arrows on Figure 4). Across the different times of analysis it is possible to see that the material is gradually being replaced and the osseous tissue is being formed, apparently without incorporation of cement particles. At the end of the neoformation process, the newly formed bone displays radiographic characteristics which are similar to those of the native surrounding bone. This is also confirmed after 12 months of loading, where the bone around the implant has not resorbed, indicating a good preservation of the new osseous volume around the implant.

The results of the histological study show that the injectable brushite cement resorbs much more uniformly and rapidly than the granular materials (Figs. 17–19). It is also possible to state that the ossification process in the defects filled with VitalOs starts in the first weeks after augmentation: intensive brick-red areas due to alizarin indicate bone deposition between the second and the fourth week, and green areas due to calcein reveal the osteogenesis activity after 4–6 weeks. The coloration of the osteogenesis areas is more intense at every follow-up stage in the defects filled with the cement than in those filled with granular materials. This shows the maturity of the bone in the sites grafted with the brushite cement. Moreover, the organization of this newly formed bone tissue presents a structure which is more suitable for subsequent implant installation, i.e. a more organized and lamellar bone, with presence of osteons (yellow arrows, Fig. 17).

New bone formation is also seen in the defects grafted with granules. However, the bone deposition is stronger in the calcein phase (green fluorescence, see Figs. 18–19) than in the alizarin one (red), which indicates a delayed bone formation, starting four weeks after surgery. The fluorescence of the new bone tissue is weaker than in the sites filled with PD VitalOs Cement, which is a sign for lower maturity of the new bone tissue.

## Discussion

The radiographic follow-up of the augmented sites shows clearly that the resorption takes place from the cement periphery towards its center until it is completely substituted by newly formed bone.

Brushite cements are known to resorb from their outer surface in contact with bone, towards the inner core of the injected mass. The resorption of brushite takes place through a combination of dissolution and cell-mediated processes. The whole process happens at the bone-cement interface, called resorption front (Theiss 2005, Lu 2002). This resorption front can always be easily located on radiographs and allows accurate determination of the moment when the cement is completely resorbed and replaced by bone. An earlier publication of the same author in the first implants edition of this year showed that the newly formed tissue does not contain any cement remnants and displays a lamellar, well organized structure (Gehrke 2009).

As we could observe in the radiographic sequences presented here, the injectable VitalOs cement presents a good radiopacity during the whole duration of the resorption process. The cement is easily located on the radiographs because it produces white homogeneous areas that distinguish clearly from the surrounding bone structure. This difference is easily recognizable until the very end of the resorption process. The radiopacity of this cement was shown to be equivalent to that of cortical bone (Pittet 2002). These features definitely facilitate the follow-up of its resorption and help the professional determining when the implant can be loaded.

Why is it so important to determine accurately the right time for loading the implant? There are several reasons for this. First, to make sure that the structure surrounding the implant is able to withstand the stresses applied through the crown-implant system. The residual bone used as bed for implantation provides the initial stability to the implant, but in most cases its quantity and structure are not sufficient to support the stresses applied on the implant once it is in function. The presence of newly formed bone around the implant is therefore re-

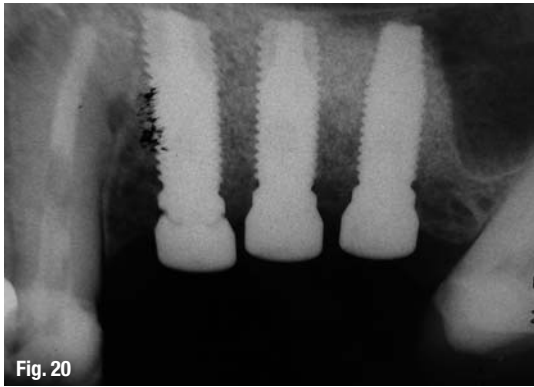

Fig. 20

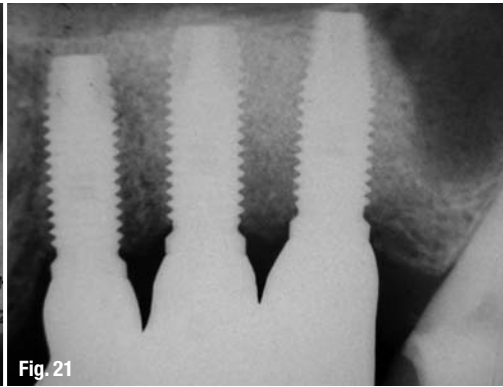


Fig. 21

**Fig. 20, 21**\_Radiographs of a case augmented with Bone Ceramic: 180 days after surgery and one year after crown installation, respectively.

quired to provide the required mechanical stability. Now, the time necessary for substitution of the graft material by newly formed bone may vary from one case to another. In a maxillary sinus as in case I, the cement generally resorbs completely in six months. Nevertheless, this period can be longer in older patients or in patients presenting metabolic disturbances. In these cases it is necessary to wait longer before starting the prosthetic phase.

In addition to that, this time period also depends on the volume or thickness of material applied: the larger it is, the longer it takes to resorb and be replaced by new bone tissue. These various factors influencing the resorption time of the graft material make it impossible to predict accurately when the augmented bone site will be ready to withstand the load applied onto the implant.

For all these reasons, the ease of location of the grafting material on radiographs is of great advantage: it allows following each patient individually to estimate the level of new bone reconstruction. This is important since this process is very much patient-dependent and should be assessed individually in order to choose the right time for installing the restoration. Finally, it is also the predictability of the treatment success which is increased through accurate radiographic monitoring.

The radiographic monitoring is more difficult to achieve with granular materials because their appearance on radiographs is closer to that of bone and the grafted area becomes eventually a mix of granules and bony tissue. To emphasize this, Figures 20 and 21 show radiographs of sites augmented with granular materials (Bone Ceramic), 180 days after augmentation and one year after crown installation, respectively. It can be seen that the newly formed bone is not as well defined as in the cases filled with the brushite cement (Fig. 15). The resorption mechanism of granular materials is also accompanied by new bone formation, but this takes place between the granules, most of them remaining eventually embedded in the new bone structure.

On the histologies, the bone markers showed that the substitution of the cement by bone starts during the first weeks after implantation. The bone tissue

eventually obtained after eight weeks in the model is well organized, displaying a much more suitable structure than the bone growing in the defects filled with granular materials. The results obtained here are in accordance with results from literature showing that brushite cements exhibit fast resorption (Theiss 2005, Lu 2002), despite their lack of macroporosity. This good capacity of resorption and substitution by osseous tissue confirms the osteogenic potential of PD VitalOs Cement.

## Conclusion

This paper evidences and discusses the different resorption kinetics and mechanisms occurring between a brushite calcium phosphate cement, VitalOs Cement, and granular bone substitutes. We showed that the good radiopacity of VitalOs allows more precise and secure monitoring of the resorption and substitution of the cement by new bone tissue. The neoformation kinetics is also patient-dependent and the ease to monitor radiographically the resorption process adds reliability to the overall treatment.

In summary, it was shown here that:

The radiopacity of the cement allows easy and reliable monitoring of the resorption process;

Osteogenesis starts earlier in the cement than in the granular substitutes presented here;

The bone neoformation is more intensive in contact with VitalOs than with granular products;

The cement is fully resorbed and its substitution by new bone tissue requires less time than with the granular substitutes. \_

*The literature list can be requested from the author.*

## \_contact

## implants

### **Dr Sérgio Alexandre Gehrke**

BioFace Institut

Dr. Bozano, 571

Santa Maria – RS, Brazil

E-mail: Sergio.gehrke@terra.com.br

# DGZI Adria Congress on the Isle of Vis

authors\_Rolf Vollmer, Rainer Valentin, Germany

## \_contact implants

### Dr Rolf Vollmer

First Vice President  
and Treasurer of DGZI  
Nassauer Str. 1  
57537 Wissen, Germany  
Phone:  
+49-27 42/91 10 53 or  
+49-27 42/96 89 30  
Fax: +49-27 42/25 47  
E-mail:  
info.vollmer@t-online

The sixth VIS Congress was held on the Isle of Vis in the picturesque village of Komila from July 12 to 13, 2009. The Adria Congress was the second meeting, which was organized together with DGZI (German Association for Dental Implantology). Komila is only a two-hour flight from Germany, and another two hours by ferry from Split, and one soon stands in an untouched countryside, where time seems to stand still. This statement is certainly right with regard to the beautiful nature, but not when you have a look at the highly sophisticated scientific program! The program was dedicated to general dentistry, with special focus on dental implantology and oral surgery. Internationally well-known speakers such as Dr Rainer Valentin and Dr Rolf Vollmer of the DGZI Board of Directors, enhanced the scientific program. Dr Istvan Urban gave an impressive report on modern possibilities for bone regeneration. Dr Istvan Urban works at the Sankt Istvan Hospital in Budapest, and he carries out scientific research in cooperation with the Loma

Linda University in California. The oral surgeon Dr Darko Slovska—the recently graduated first specialist in implantology of DGZI in Croatia—explained in detail the anatomical basics for a successful implantation, and showed the possibilities of how to avoid making mistakes. Added together, it was an outstanding program in a picturesque environment. DGZI wants to express their special thanks for the excellent organization to Prof Dr Bozidara Pavelica of the University of Zagreb, Dr Matko Bozic and Dr stom. Zeljko Feric from Split, as well as to Dr Rainer Valentin, member of the DGZI Board of Directors. It was generally agreed to hold next year's VIS Congress again on the occasion of the Corpus Christi holiday (June 3, 2010).

DGZI plans a stronger commitment next year, in order to offer a special curriculum during the Adria Congress, and in cooperation with the VIS Congress, to interested colleagues. As soon as we know more details, we will inform our members about it.



# 39<sup>TH</sup> INTERNATIONAL ANNUAL CONGRESS OF THE DGZI

Complications, Risks and Failures in the Oral Implantology

October 9–10, 2009, in Munich  
Hilton Munich Park

## SPECIAL PODIUM

„Periimplantitis –  
a challenge of  
the future“ with  
talk of experts

For registration visit us: [www.dgzi-jahreskongress.de](http://www.dgzi-jahreskongress.de)  
[www.event-dgzi.de](http://www.event-dgzi.de)

Information:  
Phone: +49-3 41/4 84 74-3 08  
Fax: +49-3 41/4 84 74-2 90  
[event@oemus-media.de](mailto:event@oemus-media.de)  
[www.dgzi.de](http://www.dgzi.de)  
[www.event-dgzi.de](http://www.event-dgzi.de)





## 5<sup>th</sup> Arab German Implantology Meeting DGZI in Damascus

The Arab German Implantology Meeting DGZI was held this year from April 8–10. The fifth meeting was organized together with the Dental Association in Damascus and in cooperation with the 3<sup>rd</sup> Syrian Annual Implantology Meeting

Because the first four Arab-German meetings in Dubai had been perceived as very successful, the neighbouring countries voiced the desire to now hold this meeting of highly qualified implantologists.

Thus, an agreement was reached with the Syrian Dental Association, with the result that the congress could be held in Damascus. Due to the interest of the Syrian Dental Association, DGZI decided to organize this year's meeting, together with the local Dental Association, in the megacity of Damascus. It was the aim of the organizers to offer a qualified congress close to other home countries, e.g. for colleagues from Iraq. The success of the meeting confirms that this was the right decision. The Syrian Dental Association counts 16,000 members. At the moment there are 2,200 colleagues, who are working as dental specialists in different fields. Many of them obtained their dental education in Germany or in other European countries. Dr Safoh Al Buni is their acting President. As in former years, he invited the presidents of the dental associa-

tions of all Arab countries to this congress, in order to talk about future plans, and the foundation of an Arab Implantology Association. DGZI can attest to setting standards in this region.

The following colleagues flew in from Germany: The DGZI members of the board Dr Rolf Vollmer, Dr Rainer Valentin, and Dr Roland Hille. They were accompanied by the speakers Prof Dr Werner Götz, Dr Martina Vollmer, Dr Dr Werner Stermann, Prof Dr Maik Vesper, Dr Peuthen, Dr Manfred Schreiber, Dr Gerd Rosenkranz, and Dr Robert Laux. Well-known speakers from Lebanon, Jordan, Egypt, Sudan, and Saudi Arabia completed the program.

A complete dental implantology spectrum was covered, ranging from sinuslift to immediate loading, complications, smoking, bone substitute materials, and aesthetics. The conference room was fully occupied from morning until night with over 450 participants. There was enough time for discussions, and the speakers gave answers to all kinds of interesting questions even during the breaks. The joint evening events took place in typical Syrian style, and atmosphere. A dental fair completed the event, and everyone involved agreed that the success of the event will continue in the region into 2010.





We thank also especially Dr Iyad Ghoneim for his excellent support of the organisation committee.

### Information about Syria

The Syrian Arab Republic is a state in the Middle East, which was of major importance in the ancient world that was especially characterized thanks to an early advanced civilization. Due to its location on the Mediterranean Sea, and the plateaus with its adjacent deserts inside the country, Syria covers a wide range of different terrains. One can walk on the old paths of the ancient world, and have a look at the history of civilized mankind on-site. The country's surface extends over 185,000 km<sup>2</sup>, there are 19 million inhabitants, and the majority of them speak Arabic. Since the seventies, Syria has to cope with rapid population growth, which causes many health and social problems. The relations with its direct neighbour Israel, and also with the United States of America are still very tense. Thanks to its oil resources, Syria is in a quite good situation, because the shortage of oil will lead to an enormous increase in value of "black gold" in the coming decades. Syria is certainly a country one should get to know.

### Damascus

Damascus is often praised as the "lively", "the mysterious", "the pearl of the Middle East", and sometimes even "the mother of all cities". Damascus is the largest city and the capital of the Syrian Arab Republic. It is

the oldest human settlement. Visitors will find it one of the most fascinating cities on earth, with 4,000 years of history, and populated 12,000 years ago. The old Aramaic name of the city was "Darmeseq", which means "place with abundant water". This allusion sounds a bit strange for a place that is situated in direct vicinity to the Arabian desert, but it refers to the fact that Damascus is located in one of the most fertile oases in the Middle East called the Oasis Ghouta region, a vital line, which is watered by the Barada river. One can visit the Damascus citadel, the former Roman main street Via Recto, the Christian Quarter with the famous House of Saint Ananias, the Chapel of Saint Paul, and of course the magnificent Umayyad Mosque, which once was planned to be the most wonderful and greatest Islamic mosque. In Damascus you can also observe something that has become very rare lately. Here, especially in the old part of the city, Muslims, Christians and Jews live together in peace. Churches and mosques stand side by side, and one is warmly welcomed by friendly, hospitable, and interested people. The city's atmosphere cannot be more oriental than it is already.

In the endless souqs of the old town one feels like being back in the times of the tales from 1001 Arabian Nights. One can admire the impressive caravanserais, visit the Hamams, pass by the madrasas, and then reach the city palaces. Lush gardens, luxury hotels, vivid coffee houses, and charming old houses make a visit to this city become a feast for the senses.

Our conclusion: A safe country, Arabic lifestyle, kind and helpful citizens and colleagues. \_



# Saudi Arabia—Tradition and modern times!

20<sup>th</sup> Saudi Dental Society and 2<sup>nd</sup> National Guard “New Dental Era” International Conference 2009, organized in cooperation with the German Association of Dental Implantology (DGZI)

author\_Rolf Vollmer, Germany

Prince Miteb bin Abdullah bin Abdulaziz, Deputy Commander of the National Guard for Military Affairs, patronized the 20<sup>th</sup> Saudi Dental Society and Second National Guard Conference and a Workshop themed 'New Dental Era' from April 20 to 22 in Riyadh.

Internationally renowned speakers with topics on Orthodontics, Dental Aesthetics, Dental Implants and Endodontics were the highlights of the scientific sessions. A special award was given to the best research project conducted by undergraduate and postgraduate students and another award for the best presentation in the poster session. Workshops were conducted by local and international speakers. International manufacturing dental and medical companies participated in the exhibition. A compilation of approved abstracts is published in the Journal of Dental Research under the IADR Saudi Arabian Section.

"The remarkable success of the last conference held in Jeddah of March 2008 is promised to be repeated, if not, paralleled as I invite you once again for this year's conferences.

This conference is accredited by the Saudi Commission for Health Specialties", said Prof Yousef F. Talic, President of the Saudi Dental Society. Through this outcome the National Guard Health Affairs and the Saudi Dental Society continued to contemplate the interest of the growing population of dentists in the Kingdom. The international conference was organized to keep our colleagues well-informed of the advances and challenges in the global society for this particular field of speciality. It offers a unique and dynamic experience for educational career advancement where topics of interest from various dental specialities were presented and discussed, Prof Yousef F. Talic summarized.





Dr Ali Al Ehaideb, Chairman, Dental Services—Central Region, National Guard Health Affairs pointed out:

The scientific lectures and continuing education (CE) courses are designed to widen and enhance our knowledge through the shared ideas and experiences of our distinguished international and local invited speakers who are well-respected and pioneers in their field of speciality. New approach, different techniques utilizing the state of the art modern technology waits for our colleagues. It will also highlight the display of modern instruments, supplies and equipment by internationally known participating dental & medical companies.

Thus, it is our privilege to encourage your participation for the success of this meaningful scientific event.

The German Association of Dental Implantology (DGZI) was invited as an cooperation partner and was represented by its 1. Vice-president and Treasurer Dr Rolf Vollmer as well as Dr Mazen Tamimi, the international representative of DGZI. Almost 1,500 dentist

participated in the meeting and agreed on the high level of education in Saudi Arabia.

### Information Saudi-Arabia

70 years ago the Kingdom of Saudi-Arabia was founded. On 23<sup>rd</sup> September, 1932, King Abd Al Asis III. Ibn Saud unified his Kingdoms Nejd and Hejaz to one big state. The constitution is based on the Quran.

Saudi Arabia is located on the Arabian Peninsula, and borders with Iraq, Jordan, Kuwait, Oman, Qatar, the United Arab Emirates, Yemen, the Red Sea, and the Persian Gulf. It is a desert country with extreme temperatures. From the middle of April until the middle of October daily temperatures of 45 °C and more can be reached. Whereas in the winter months January and February temperatures of 15 °C and less can be expected. At night the temperature in the desert can even be below the freezing point. The coastal zones have humid climate. Saudi Arabia is six times larger than Germany. Its size is approximately 2,15 million





square kilometres. Approximately 80 per cent of the Arabian Peninsula belongs to the kingdom, though only 20 million inhabitants live there, i.e. a quarter of the total German population. Colleagues from over 85 countries work as dentists. Education and training programs are highly ranked in Saudi Arabia. Every dentist has to prove his/her CME points regularly. A dentist is only allowed to place dental implants when he/she has obtained a so called license issued by the Ministry of Health.

Saudi Arabia is governed by an Islamic authoritarian monarchy under the reign of King Fahd bin Abd al-Aziz Al Saud, who is also the Prime Minister. The King and his widely ramified family stand at the top of the pyramid, followed by the tribal leaders and urban salesmen. The capital is the ancient Nejd capital Riyadh.

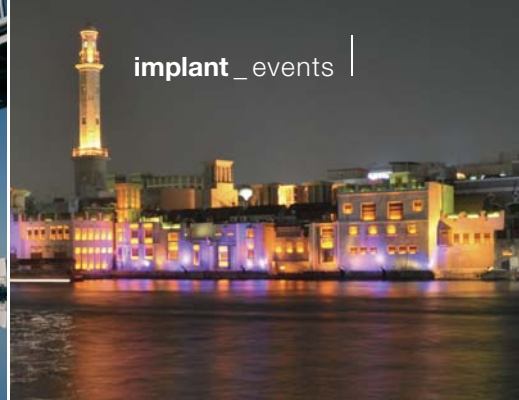Women have to wear long, black garments, and they have to wear a veil over their face. Driving is forbidden for women. It is also forbidden to eat pork and drink alcohol throughout Saudi Arabia. The import of drugs is strictly forbidden, and will be punished with draconian penalty.

The prosperity of the country is due to its oil production since 1933. In 1960 Saudi Arabia founded the Organization of Petroleum Exporting Countries

(OPEC), together with Iran, Iraq, Kuwait, and Venezuela. The aim of the coalition of the five most important oil exporting countries was a joint oil policy, and the stabilization of the world market price. Later on more oil producing countries joined this association. In the meantime Saudi Arabia has become the most important oil producing country in the world, and it controls approximately 26 per cent of all known oil reserves. Riyadh (Arabic "the gardens") is the capital of the Kingdom of Saudi Arabia, and its same-named province. The city counts 4,6 million inhabitants. The city is the economic, administrative, and cultural center of the country. It hosts numerous universities, museums, and monuments. Riyadh is the seat of the Saudi Arabian government, the parliament, all national boards, and numerous diplomatic missions.

Riyadh has been the capital of Saudi Arabia since 1932 when the country gained its independence. From the historical point of view the capital is an important transit city for the Arabian area, the pilgrim routes to Mecca and Medina, which are the most significant Islamic pilgrimage sites. The main palace of the royal dynasty has been located in Riyadh since 1824.





# Selected Events 2009/2010

## SEPTEMBER 2009

September 2–5

*FDI Singapore*

Singapore

Web: [www.fdiworlddental.org](http://www.fdiworlddental.org)

September 4–5

*6th Forum of Innovations in Dentistry*

Leipzig, Germany

Web: [www.event-fiz.de](http://www.event-fiz.de)

## OCTOBER 2009

October 9–10

*39th International Congress of DGZI*

Munich, Germany

Phone: +49-3 41/4 84 74-3 08

Fax: +49-3 41/4 84 74-2 90

Web: [www.event-dgzi.de](http://www.event-dgzi.de)

October 11–15

*58th Annual Meeting of AAID*

New Orleans, Louisiana,  
USA

Web: [aaid.com](http://aaid.com)

October 16–17

*4th International Computer Aided  
Implantology Academy Congress*

Istanbul, Turkey

Web: [www.tpidakademi.com](http://www.tpidakademi.com)

October 23–25

*1st European Implant Direct Congress*

Barcelona, Spain

Web: [www.implantdirect.eu](http://www.implantdirect.eu)

## NOVEMBER 2009

November 4–7

*AOS 7th Biennial Conference*

Queensland, Australia

Phone: +61-7/3858 5525

Web: [www.aosconference.com.au](http://www.aosconference.com.au)

November 27  
– December 2

*GNYDM Greater New York Dental Meeting*

New York, USA

Web: [www.gnydm.com](http://www.gnydm.com)

## MARCH 2010

March 2–4

*Biannual WFLD World Congress in Conjunction  
with UAE International Dental Conference &  
Arab Dental Exhibition*

Dubai, UAE

Web: [www.aeedc.com](http://www.aeedc.com)

## APRIL 2010

April 15–18

*IDEM International Dental Exhibition and Meeting*

Singapore

Web: [www.idem-singapore.com](http://www.idem-singapore.com)



**Congratulations and Happy Birthday** to all DGZI-members around the world



## JULY 2009

### 65<sup>th</sup> Birthday

Dr Reinhard Wiemers (12.07.)  
Dr Willi Plössner (21.07.)

### 60<sup>th</sup> Birthday

Dr Ladislaus Hanga (06.07.)  
ZÄ Elisabeth Dziemian-Behrend (14.07.)  
Dr Harald Passow, M.Sc. (15.07.)  
Dr Joachim Jost (16.07.)  
Dr Werner Albert (18.07.)  
Dr Josef Necsoi (19.07.)

### 55<sup>th</sup> Birthday

Dr Herrmann Baierlein (26.07.)  
Dr Walter Jakubec (28.07.)  
Dr Alexander Hellge (30.07.)  
Dr Fritz Kruse (31.07.)

### 50<sup>th</sup> Birthday

Dr Aristide Klaus Gundacker (14.07.)  
Dr Martin Trinder (21.07.)  
Dr Alexander Kukis (27.07.)  
ZA Robert-Georg Schankin (28.07.)  
Dr Dirk Bruns (30.07.)

### 45<sup>th</sup> Birthday

Dr Frank Friedrich (01.07.)  
Dr Rainer Karrer (04.07.)  
Dr Andreas Schorb (11.07.)  
Dr Muhammed Nassir (20.07.)  
Dr Ulrich Guthofer (25.07.)  
Dr Frank Schmid (26.07.)  
Dr Thomas-Ortwin Siegmund (27.07.)  
Dr Oliver Niemann (30.07.)

### 40<sup>th</sup> Birthday

Dr Stefan Scherg (02.07.)  
Prof. Dr. Marcel A. Wainwright (08.07.)  
Dr Paul Berlage (08.07.)  
Dr Mujahed Artaher (28.07.)  
Dr Carsten Lensing (30.07.)

## AUGUST 2009

### 75<sup>th</sup> Birthday

ZA Björn Ringheim (15.08.)

### 65<sup>th</sup> Birthday

Dr Lutz Lwowsky (14.08.)

### 60<sup>th</sup> Birthday

Dr Fritz Maier (03.08.)  
Dr Joachim Gerdes (15.08.)  
Dr Hans-Gerd Balks (30.08.)

### 55<sup>th</sup> Birthday

ZA Markus Pfennig (02.08.)  
Elisabeth Hesse (04.08.)  
Dr Stefan Neumeyer (12.08.)  
Dr Horst Langhanke (16.08.)  
Dr Matthias Schroeder (26.08.)

### 50<sup>th</sup> Birthday

Dr Klaus Harms (08.08.)  
ZA Paul Olbrich (17.08.)  
ZTM Michael Sips (18.08.)  
Dr George Gabbour (26.08.)  
Dr Gerda Söchting (28.08.)

### 45<sup>th</sup> Birthday

Dr Siegfried Tausend (02.08.)  
ZA Jörg Mertens (02.08.)  
Dr Saad Zemmouri (12.08.)  
Dr Christoph Geus (13.08.)  
Dr Christine Koehler (15.08.)  
Dr Andreas Meyer (26.08.)  
Dr Christof Jörg Becker (30.08.)  
Dr Jens Wilharm (31.08.)  
Dr Minh-Son Doan (31.08.)

### 40<sup>th</sup> Birthday

Dr Matthias Steinhoff (02.08.)  
Dr Milad Askaf (06.08.)  
Dr Sanath Pathirana (11.08.)  
Dr Jens Döring (16.08.)  
Dr Oliver Bogdanski (18.08.)  
Dr Karsten Ruffert (18.08.)  
Dr Niko Wierzbizki (21.08.)  
Dr Jan Lück (31.08.)

## SEPTEMBER 2009

### 75<sup>th</sup> Birthday

Dr Robert Meyer (04.09.)

### 65<sup>th</sup> Birthday

Dr Dr. Werner Stermann (16.09.)  
Dr Siegfried Schebesch (18.09.)  
Dr Wilhelm Imkamp (22.09.)

### 60<sup>th</sup> Birthday

Dr Helmut B. Engels (07.09.)  
Dr Olga Früh (12.09.)  
Dr Michael Klein (15.09.)  
Dr Anton Schaller (15.09.)  
Hanna Mehler (20.09.)

### 55<sup>th</sup> Birthday

Prof Dr (H) Peter Borsay (08.09.)  
Dr Bettina Möller (14.09.)  
Dr Dorothea Jacobi (14.09.)  
Dr Jochen Scopp (15.09.)  
Dipl.-Stom. Frank-Kersten Flack (16.09.)  
Dr Berend Reinhard Terveer (22.09.)  
Dipl.-Stom. Harald Sengewald (24.09.)  
Dr R. Gottschild (24.09.)  
Klaus Schnellbacher (29.09.)

### 50<sup>th</sup> Birthday

Dr Michael Svoboda (05.09.)  
Dr Andreas Stephan (23.09.)  
Dr Hubert Kubica (26.09.)  
Dr Ingo Ossysek (29.09.)

### 45<sup>th</sup> Birthday

Dr Christian Marmandiu (03.09.)  
Dr Hermann-Josef Antony (06.09.)  
Dr Mehmet Ay (07.09.)  
Dr Helena Kuksen (08.09.)  
Dr Matthias Stolpe (09.09.)  
ZA Nils Christian Martins (10.09.)  
Dr Abu Zarad Eyad (12.09.)

Dr Michael Peschke (17.09.)  
DDS Duesang Jang (17.09.)  
Dr Josef Kiebler (22.09.)  
Dr Marc Pape (28.09.)

### 40<sup>th</sup> Birthday

ZA Vincent S. Babori (09.09.)  
Dr Thomas Hoch (12.09.)  
Dr Kirsten Humsi (23.09.)

# Manufacturer News

## Implant Direct

### 1<sup>st</sup> European Implant Direct Congress, October, 23–25 2009!

Implant Direct will hold its first European Congress in the beautiful and central Mediterranean city of Barcelona from October 23<sup>rd</sup> to 25<sup>th</sup> 2009. The congress will focus on the daily challenges in the dental practice with the lead title "Challenging conventional thinking in Implant Dentistry". Outstanding clinical program with Live Surgeries. The scientific program features leading speakers such as Dr Gerald Niznick, Dr Marius Steigmann, Dr Aragoneses, Dr Fernando D'Avenia and many others, which will present the state of the art techniques of implant surgery and prosthetics. In addition, two live surgeries will be held at the leading dental training center COEC in Barcelona:

Dr Pedro Pena and Dr Marius Steigmann illustrating the latest techniques of soft tissue management and bone augmentation.

### Case competition—Send us your best clinical studies!

Implant Direct has initiated a case competition contest in which doctors from across Europe are invited to submit their cases. The top three entrants will be invited to our 1<sup>st</sup> European Implant Direct Congress in Barcelona where their cases will be presented. The top ten cases will be published in the Implant Direct casebook as well as be submitted for publication in selected European Implant Journal. Learn, relax and enjoy with an entertaining social and cultural program! Join us during our congress and register as soon as possible as places are limited to 350 attendants. Registrations via [www.implantdirect.eu](http://www.implantdirect.eu), and tollfree infoline 00800 4030 4030.



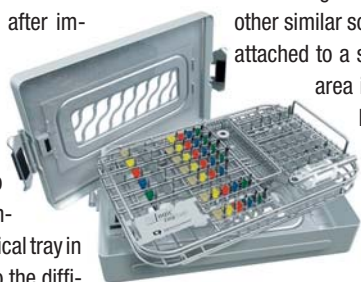
### Implant Direct Europe

Förrlibuckstrasse 150  
8005 Zürich, Switzerland  
E-mail: [barcelona@implantdirect.eu](mailto:barcelona@implantdirect.eu)  
Web: [www.implantdirect.eu](http://www.implantdirect.eu)

## Dentaurum

### The first surgical tray for cleaning and disinfecting machines

In the field of implantology up to now, rotating instruments with angled shafts and other additional components required longer and more time-consuming cleaning treatments after implantation. In manual cleaning and disinfecting methods, each instrument must be treated individually. Until now, it was not possible to clean the implantological instruments directly in the surgical tray in an automatic process, due to the difficulty in immersing the instruments in sufficient amounts of water and cleaning liquid. Now the new tioLogic<sup>®</sup> easyClean is available to save time and improve hygiene: The rotating instruments and additional components are placed back into their relevant positions directly after use and remain there during the entire cleaning and disinfecting process. Their position within the tray enables them to be thoroughly immersed and rinsed. The concept for the ideal retention fixture for rinsing rotating instruments, was developed in collaboration with the companies Miele Professional and Dentaurum Implants



GmbH. During this collaboration, the new Miele tray insert for general use in dental practices was developed and the specialised tioLogic<sup>®</sup> easyClean for the implant system from Dentaurum Implants evolved. The latter comprises all surgical instruments and all essential components required for preparing an implant site and for inserting tioLogic<sup>®</sup> implants. The components are arranged according to requirements during the course of surgery. The difference to other similar solutions is that every instrument is attached to a spring so that the contact surface area is minimal. This is why rose head burs and depth drills, surface cutter and conical formers can be entirely immersed in water and cleaning liquid. These can remain in their relevant positions throughout the whole treatment, including sterilisation. The Miele tray insert for dental practices comprises two areas with space for 30 drills with contra-angle handpiece ISO shafts and 15 positions for turbine shafts. This allows rotating instruments to be automatically treated whilst in the tray.

### Dentaurum Implants GmbH

Turnstraße 31  
75228 Ispringen, Germany  
E-mail: [info@dentaurum-implants.de](mailto:info@dentaurum-implants.de)  
Web: [www.dentaurum-implants.de](http://www.dentaurum-implants.de)

AD

**100% SAFETY DOCTOR - PATIENT GOAL REACHED**

Since our beginnings, we have always been focused on quality and innovation toward the battle against cross - contamination and infections.

In the last 20 years, we have ensured safety and protection to you and your patients, with advanced and reliable products. Tools that represent the ideal solution for who is operating in dentistry, implantology/oral surgery and general surgery.

With Omnia sure to be safe.

**Surgical Line**   **Safety Line**   **MAXIT<sup>®</sup>**

**OMNIA<sup>®</sup>**  
Disposable Medical Devices

OMNIA S.p.A.  
Via F. Delnevo, 190 - 43036 Fidenza (PR) Italy  
Tel. +39 0524 527453 - Fax +39 0524 525230  
[www.omniasrl.com](http://www.omniasrl.com)



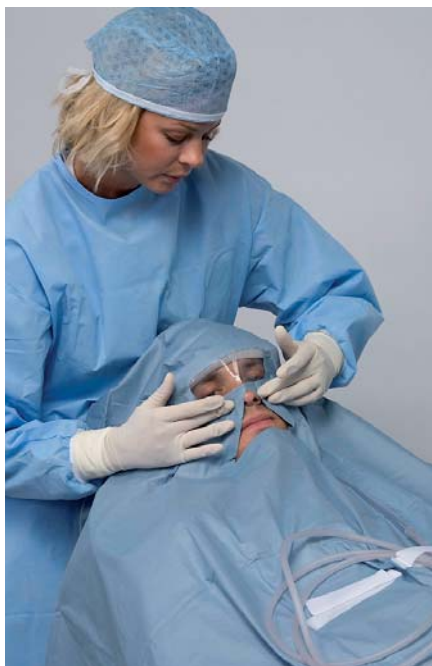Omnia

**Mono Drape  
"No Panic"**

Liquid and bacterial repellent patient drape with adhesive triangular shape 11 x 10 cm and integrated transparent plastic eye-shield. This mono drape, called "no panic", offers to the patient the opportunity to have visive communication with the operator during any kind of oral surgery, implantology or maxillo-facial surgery. The wide dimension of the drape makes it suitable for advanced surgery. Two velcrum loops fix in a safety and easy way surgical instruments and aspirators, avoiding random contamination.

**Omnia S.p.A**

Via F. Delnevo 190  
43036 Fidenza (PR), Italy  
E-mail: info@omnia srl.com  
Web: www.omniasrl.com



CAMLOG

**Bite registration posts  
for more safety even  
in difficult situations**

With the new bite registration posts, the CAMLOG® Implant System now offers even more options for fabrication of precision prosthetic restorations on implants. The CAMLOG bite registration posts have been developed for implant-supported measurement and transfer of the arch relations. They allow the fabrication of a precision bite registration even with limited occlusal space conditions and with inadequate residual teeth.

The color-coded bite registration posts have a prosthetic height of 8.1 mm. For bite registration, the bite registration caps are used or a splinted bite registration without caps is fabricated. Splinting the bite registration posts with plastic is recommended in particular for significantly reduced residual teeth or

Straumann

**Cheap implants:  
more expensive in the  
long run?**

In order to reduce costs, low-price manufacturers conduct little or no clinical research to prove that their implants will deliver long-term function and



Research, development and clinical testing – the way to innovative products.

esthetics. They also do little or nothing to advance dental education. Neither do they do anything to develop innovations that enhance the standard of patient care. If they did, the price of their products would rise dramatically.

Dental patients are rarely able to make an informed choice about the products that go into their mouths. They do not know, for instance, if the implant design has been tested to ensure that it will not fail or lead

to bone and soft tissue loss over time. Nor do they know what level of training their dentist has in implant dentistry. Patients are also unaware that the increase in low-cost manufacturers in recent years has led to a rise in the number of implants that need servicing but have to be removed because their origin cannot be traced.

Therefore, every patient should ask three important questions: 'Has the implant system been thoroughly tested?', 'How long is it guaranteed?' and 'Will replacement parts be available in more than 10 years' time?'. If not, there is a higher risk that the implant may have to be removed, which is unpleasant and costly.

Peace of mind comes at a price. The Straumann dental implant system is backed by long-term published clinical studies and a 10-year guarantee. It is supported by a broad education program for dental professionals so that patients receive a high standard of care. Premium solutions

may appear expensive initially, but they could well be cheaper in the long run. The question is: Can doctors and patients afford to save in the short term?

**Institut Straumann AG**

Peter Merian-Weg 12  
4052 Basel, Switzerland  
E-mail: info@straumann.com  
Web: www.straumann.com



for edentulous patients in order to achieve optimized support of the bite registration. Splinting is also possible with divergent implants, which is achieved thanks to a shortened post/implant connection in comparison to the Tube-in-Tube™ connection. The bite registration posts have a reduced-diameter shoulder support and are also suitable for platform switching in conjunction with CAMLOG® SCREW-LINE implants (not for implant diameter 3.3 mm). Thanks to the exact fit of all connecting parts, the CAMLOG bite registration posts ensure high precision when measuring and transferring the arch relations. They offer a strong plus for safety when determining the arch relations on implants even in difficult situations.

**CAMLOG Biotechnologies AG**

Margarethenstrasse 38  
4053 Basel, Switzerland  
E-mail: info@camlog.com  
Web: www.camlog.com

## BEGO Implant Systems

### New sales and marketing subsidiary in Barcelona



As a direct result of the outstanding sales development with the German-made Dental Implant Systems line BEGO Semados® implantology products and the constantly growing user base in Spain and Portugal, BEGO Implant Systems in Bremen, Germany, has decided to build up a new company in Spain, called BEGO Implant Systems Iberia, S.L..

"The new company has been formed to increase our market share and competitive strength in Spain and Portugal and to offer our customers a more direct interface to BEGO Implant Systems

sales and support people working close to our customers in the Iberia market", says Walter Esinger, General Manager of BEGO Implant Systems.

The logistic partner remains unchanged—MAB Dental/Dentimail will continue handling customers orders, as in the past. The direct sales representatives will visit customers personally and regularly in the future to introduce the BEGO Implant Systems product portfolio including the latest novelties from IDS 2009 in Cologne. The direct sales and support team in Spain and Portugal will be headed by Mrs Silvia Albiac. Silvia Albiac is already very well known in the Iberian Dental Implants Industry working previously for Klockner Dental Implants in Spain. General Manager of the new subsidiary will be Walter Esinger who is also General Manager of BEGO Implant Systems GmbH & Co. KG in Bremen, Germany. To celebrate the formation of the new company Silvia Albiac and her team recently come with some key users of the BEGO Implant System to a training course in Bremen and at the dental clinics of Dr Stefan Ries, in Wertheim where they participated in the course "Implantology meets Nouvelle Cuisine".

#### BEGO Implant Systems GmbH & Co. KG

Technologiepark Universität  
Wilhelm-Herbst-Straße 1  
28359 Bremen, Germany  
E-mail: info@bego.com  
Web: www.bego.com

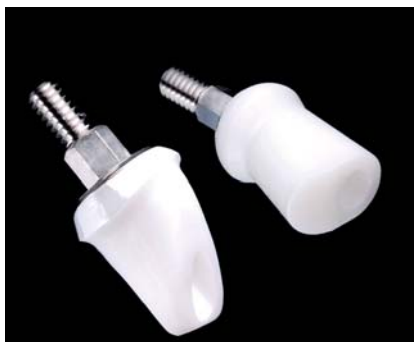## Sybron Implant Solutions

### The new Zirconium Abutment—for a naturally perfect result

The Zirconium abutment is a partially standardized abutment designed for the Pitt-Easy implant system. With this prosthetic abutment, the user will be able to comply with high aesthetic demands for an implant-supported denture.

The abutment consists of two parts, so that the modified Zirconium part is bonded with the titanium base in processing. The patented Zirconium abutment consists of the following parts:

- abutment base made of titanium (grade 4) with internal threads, preventing loss of the screw
- abutment blank made of high-quality TZP-A Zirconium oxide ceramics
- retaining screw for processing the abutment in the laboratory or in the dental practice (marking groove at the screw shaft)



— retaining screw for final insertion in the patient's mouth

A comprehensive instructions protocol shows the exact steps of use and processing of this abutment.

#### Sybron Implant Solutions GmbH

Julius-Bamberger-Str. 8a  
28279 Bremen, Germany  
E-mail: info@sybronimplants.de  
Web: www.sybronimplants.de

Premium  
quality at friendly  
prices



perfect aesthetics  
internal hex  
accelerated treatment

Xign®

Allfit®

The Allfit® Xign® implant system is designed for enossal dental implantations.

The Xign® implant system is suitable for single-step and dual-step implant protocols.

It is made of Grade 4 pure titanium.

Xign® implants are abraded with aluminium oxide and hot-etched and have an osmotically active nanocoating. All accessory parts are colour-coded.

**IHDE DENTAL**   
the implant.comany

Dr. Ihde Dental GmbH  
Erfurter Str. 19 · D-85386 Eching/Munich, Germany  
Telephone: (49) 89 319 761-0 · Fax (49) 89 319 761-33  
e-mail: info@ihde-dental.de · www.implant.com

# implants

international magazine of oral implantology



<b>Publisher</b>	Torsten R. Oemus	oemus@oemus-media.de
<b>CEO</b>	Ingolf Döbbecke Jürgen Isbaner Lutz V. Hiller	doebbecke@oemus-media.de isbaner@oemus-media.de hiller@oemus-media.de
<b>Chief Editorial Manager</b>	Dr. Torsten Hartmann (V. i. S. d. P.)	hartmann@dentalnet.de
<b>Editorial Council</b>	Dr. Friedhelm Heinemann Dr. Roland Hille Dr. Winand Olivier Prof. Dr. Dr. Kurt Vinzenz Dr. Torsten Hartmann Dr. Suheil Boutros	friedhelmheinemann@web.de dr-hille@t-online.de dr.olivier@t-online.de kurt.vinzenz@aon.at hartmann@dentalnet.de SMBoutros@aol.com
<b>Editorial Office</b>	Kristin Urban Katja Kupfer	k.urban@oemus-media.de kupfer@oemus-media.de
<b>Executive Producer</b>	Gernot Meyer	meyer@oemus-media.de
<b>Art Director</b>	Dipl.-Des. Jasmin Hilmer	hilmer@oemus-media.de
<b>Customer Service</b>	Marius Mezger	m.mezger@oemus-media.de
<b>Published by</b>	Oemus Media AG Holbeinstraße 29 04229 Leipzig, Germany Phone: +49-3 41/4 84 74-0 Fax: +49-3 41/4 84 74-2 90 E-mail: kontakt@oemus-media.de	

**implants** international magazine of oral implantology is published in cooperation with the German Association of Dental Implantology (DGZI).

**DGZI President** Dr. Friedhelm Heinemann  
DGZI Central Office  
Feldstraße 80, 40479 Düsseldorf, Germany  
Phone: +49-2 11/1 69 70-77  
Fax: +49-2 11/1 69 70-66  
E-mail: office@dgzi-info.de

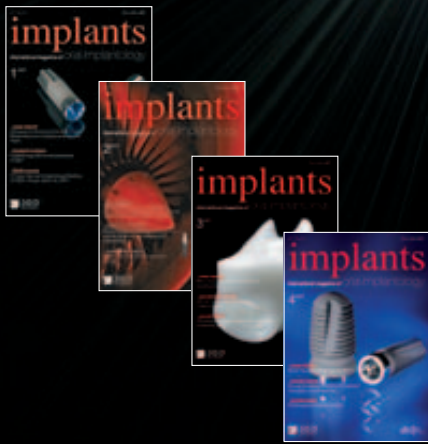[www.dgzi.de](http://www.dgzi.de)  
[www.oemus.com](http://www.oemus.com)

## implant\_Copyright Regulations

*\_the international magazine of oral implantology* is published by Oemus Media AG and will appear in 2009 with one issue every quarter. The magazine and all articles and illustrations therein are protected by copyright. Any utilization without the prior consent of editor and publisher is inadmissible and liable to prosecution. This applies in particular to duplicate copies, translations, microfilms, and storage and processing in electronic systems. Reproductions, including extracts, may only be made with the permission of the publisher. Given no statement to the contrary, any submissions to the editorial department are understood to be in agreement with a full or partial publishing of said submission. The editorial department reserves the right to check all submitted articles for formal errors and factual authority, and to make amendments if necessary. No responsibility shall be taken for unsolicited books and manuscripts. Articles bearing symbols other than that of the editorial department, or which are distinguished by the name of the author, represent the opinion of the afore-mentioned, and do not have to comply with the views of Oemus Media AG. Responsibility for such articles shall be borne by the author. Responsibility for advertisements and other specially labeled items shall not be borne by the editorial department. Likewise, no responsibility shall be assumed for information published about associations, companies and commercial markets. All cases of consequential liability arising from inaccurate or faulty representation are excluded. General terms and conditions apply, legal venue is Leipzig, Germany.

# implants

International magazine of oral implantology



for specialists around  
**the world**

Hereby I wish to subscribe to **implants** (4 issues per year)

44 €\* for German Customers | 46 €\* for Customers outside Germany

\*all prices include shipping and handling costs

#### PERSONAL DETAILS/SHIPPING ADDRESS

Name

Position/Dept.

Company

Address

Country/ZIP

Telephone

Facsimile

E-mail

Date/Signature

Your personal data will be recorded and retained by Oemus Media AG, Holbeinstraße 29, 04229 Leipzig, Germany. Your personal data is used for internal purposes only. The subscription will be renewed automatically every year until it is cancelled six weeks in advance before renewal date.

IM 3/09

#### PAYMENT OPTIONS

Credit Card:  VISA

MasterCard

Card Number

Expiry date

Name (as it appears on the card)

KPN/CW2/CVC2 No.

3-4 digits in the signature area on the back of the credit card

OEMUS MEDIA AG

Holbeinstraße 29

04229 Leipzig, Germany

Tel.: +49-3 41/4 84 74-2 01

Fax: +49-3 41/4 84 74-2 90

www.oemus.com

grasse@oemus-media.de



# EXTRAORDINARY

Introducing a new implant from one of the most respected names in dentistry - *Sybron*.  
Our new Sybron**PRO™XRT** incorporates an extraordinary array of features  
proven to address immediate stability, preservation of crestal bone<sup>2</sup>,  
and long-term aesthetics.

Call us today to experience the EXTRAORDINARY for yourself!

<sup>1</sup>Surgical and Mechanical Techniques to Increase Stability of Dental Implants. Kharouf, Zeineb; Oh, Hyeong Cheol; Saito, Hanae; Cardaropoli, Giuseppe; Bral, Michael; Cho, Sang-Choon; Froum, Stuart; Tarnow, Dennis. Ashman Department of Periodontology and Implant Dentistry, New York University. Research presented at the AO Boston 2008.

<sup>2</sup>Implant Design and Its Effect on Preservation of Crestal Bone Levels. Jang, Bong-Joon; Pena, Maria Luisa; Kim, Mean Ji; Eskow, Robert; Elian, Nicolas; Cho, Sang-Choon; Froum, Stuart; Tarnow, Dennis. Ashman Department of Periodontology and Implant Dentistry, New York University. Research presented at the AO Boston 2008.

**Sybron – Celebrating over 100 years of dental excellence**


Europe  
Sybron Implant Solutions GmbH  
Julius-Bamberger-Str. 8a  
28279 Bremen, Germany  
T 49.421.43939.0  
info@sybronimplants.de

United Kingdom  
4 Flag Business Road  
Vicarage Farm Road  
Peterborough, PE1 5TX, UK  
T 008000 841 2131

France  
16 Rue du Sergent Bobillot  
93100 Montreuil, France  
T 33.149.88.60.85

Australia  
# 10, 112-118 Talavera Rd  
North Ryde, NSW 2113  
T 61.2.8870.3099

HEADQUARTERS  
USA  
1717 West Collins Avenue  
Orange, California 92667  
T 714.516.7100



STATE OF THE ART  
**1th IMPLANT TECHNOLOGY**



Standard World Leader  
**OSSTEM**  
 IMPLANT



**03**

پیشگام در طراحی بایومکانیک و بایولوژیک نسل جدید فیکسچر و قطعات پروتزی  
 اولین ایمپلنت آسیا و برنده مطمئن و نام آشنای  
 جهانی در بازارهای بزرگ آمریکا، اروپا و استرالیا

**04**

تنوع بسیار بالای انواع فیکسچر و قطعات پروتزی برای طرح  
 گزیننه های پروتزی و استخوان و

**05**

**02**

پیشگام در طراحی بایومکانیک و بایولوژیک نسل جدید فیکسچر و قطعات پروتزی  
 دستیابی به مقام چهارمین ایمپلنت دنیا با کسب  
 بیش از ۷/۱۵٪ بازار جهانی ایمپلنت

**06**

تولید کننده انواع استخوان و  
 گزیننه های پروتزی برای طرح  
 انواع فیکسچر و قطعات پروتزی  
 گوناگون متناسب با شرایط انواع استخوان و  
 درمان های گوناگون متناسب با شرایط انواع استخوان و  
 ایجاد یکی از بزرگترین مراکز آموزش ایمپلنت  
 دنیا AIC به منظور تربیت ایمپلنتولوژیستهای  
 شایسته و حرفه ای

تلفن: ۰۲۱ ۸۹۸۰۹۳۰۶  
 فکس: ۰۲۱ ۸۹۸۰۹۳۰۶  
[www.osstem.ir](http://www.osstem.ir)  
[www.befrest.com](http://www.befrest.com)  
 تهران، فاطمی، خیابان کاج جنوبی، شماره ۳۴۴  
 ساختمان آوا  
[info@azadmed.com](mailto:info@azadmed.com)