





[www.azadmed.com](http://www.azadmed.com)



 azaadtejaratpars

 @azadmed2

 88 98 80 63 - 6

# implants

international magazine of oral implantology

3<sup>2010</sup>



| **research**

Timing of dental implant loading

| **case report**

Piezoelectric repositioning of the inferior alveolar nerve

| **meetings**

1<sup>st</sup> Hvar International Dental Congress



# SAVE CELLS

## NEW EMS SWISS INSTRUMENTS SURGERY – SAVING TISSUE WITH NEW INNOVATIONS IN IMPLANT DENTISTRY

The inventor of the Original Piezon Method has won another battle against the destruction of tissue when dental implants are performed. The magic word is dual cooling – instrument cooling from the inside and outside together with simultaneous debris evacuation and efficient surgical preparations in the maxilla.

### COOLING HEALS

A unique spiral design and internal irrigation prevent the instrument's temperature from rising during the surgical procedure. These features combine effectively to promote excellent regeneration of the bone tissue.

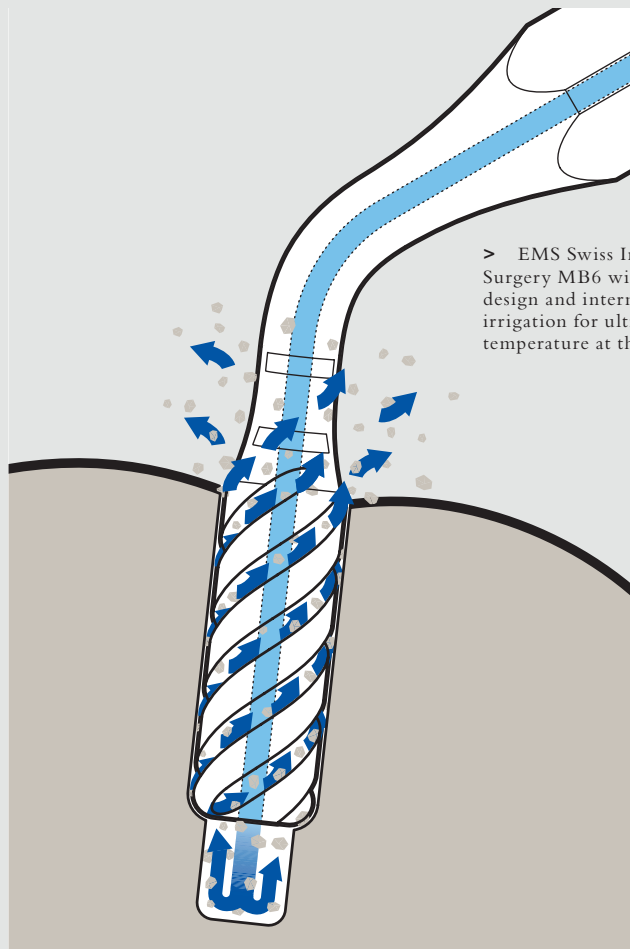
EMS Swiss Instruments Surgery MB4, MB5 and MB6 are diamond-coated cylindrical instruments for secondary surgical preparation (MB4, MB5) and final osteotomy (MB6). A spiral design combined with innovative dual cooling makes these instruments unique in implant dentistry.

### CONTROL SAVES

Effective instrument control fosters atraumatic implant preparation and minimizes any potential damage to the bone tissue.

### PRECISION REASSURES

Selective cutting represents virtually no risk of damage to soft tissue



> EMS Swiss Instrument Surgery MB6 with unique spiral design and internal instrument irrigation for ultralow temperature at the operative site

(membranes, nerves, blood vessels, etc.). An optimum view of the operative site and minimal bleeding thanks to cavitation (hemostatic effect!) further enhance efficacy.

The new EMS Swiss Instruments Surgery stand for unequalled Swiss precision and innovation for the

benefit of dental practitioners and patients alike – the very philosophy embraced by EMS.

For more information >  
[www.ems-swissquality.com](http://www.ems-swissquality.com)

**"I FEEL  
GOOD"**



# Celebrating 40 Years of DGZI in Berlin



Dr med dent Roland Hille

**“Nobody could have imagined** in 1970 what a success story oral implantology would turn out to be, when seven dentists, headed by Prof Dr Hans L Grafelmann, a dentist from Bremen, founded DGZI. In spite of various negative opinions, mainly from universities, this then-adventurous therapy was established in Germany against the mainstream, thanks to a great deal of perseverance and conviction, an incredible drive and much operative skill. There were a growing number of colleagues who were fascinated by the possibility of fixing dental prostheses on implanted new dental roots, a process which could give patients the feeling of no longer being handicapped.

40 years ago the obligatory tooth conserving methods were incomparable to current means and methods. Thus many patients, especially those with edentulous jaws, could achieve a completely new quality of life courtesy of intraosseous or subperiosteal implants. Let us remember: At that time, we did not have any bone substitutes, membranes etc. at our disposal, all of which are considered absolutely standard today. For the past four decades oral implantology has greatly influenced dental rehabilitation measures, and has without question become the most innovative discipline in dento-maxillo-facial medicine in the last 25 years.

On September 24, 1982, the DGZMK (German Association for Dento-Maxillo-Facial Medicine) approved implantology as a new method for use. Oral implantology also became scientifically in vogue, when universities intensified their research activities, and industrial companies sensed a new market with adequate financial resources.

In the beginning scientific journals referred to implantology as “the red light district in dental medicine”, but nowadays there is no doubt about the important role which this subdiscipline plays in dentistry. Patients actively request this therapy, and any colleagues who underestimate the importance of implantology for the success and future for their own dental practices will be left behind.

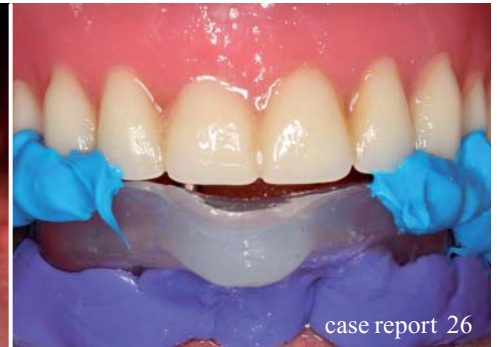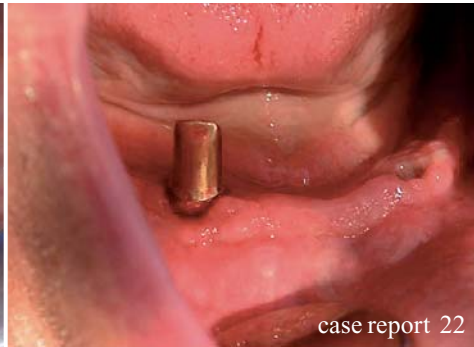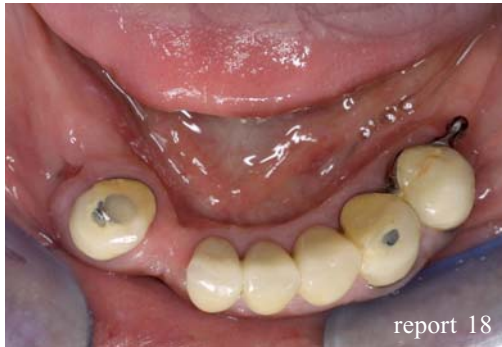DGZI has achieved significant accomplishments in education and advanced training, as up until now university education has not attached that much value to implantology. A postgraduate structured educational program has existed since 1998, which almost 1,500 colleagues have participated in and have learned from implantology specialists and university professors about the state of the art in implantology. Patients increasingly ask for treatment by a “DGZI Specialist in Implantology”, because such specialists often have much more operative skills than those colleagues who obtained a masters degree.

40 years of DGZI is truly a great milestone in Europe's oldest scientific implantological association, an association which also enjoys an extraordinarily good reputation nationally and internationally. The Consensus Conference for Implantology congratulates DGZI heartily and wishes all its members much success and an exciting future in oral implantology.

I hope to see you on the occasion of our anniversary congress on October 1 and 2 in Berlin.

Dr med dent Roland Hille  
President of the Consensus Conference for Implantology





| editorial

- 03 Celebrating **40 Years of DGZI** in Berlin  
| Dr Roland Hille

| research

- 06 **Timing** of dental implant loading  
| Dr Marius Hary Silvasan

| report

- 18 Lateralization of the **inferior alveolar nerve**  
| Dr Bernd Quantius

| case report

- 22 **Piezoelectric repositioning** of the inferior alveolar nerve  
| Dr Burghard Peter
- 26 **Success** without using cement  
| Dr Christoph Thiemann, Friedrich Schotsch

| study

- 28 **Comparing** various implant designs and surfaces  
| Dr Roy Leshem, David Leshem

| meetings

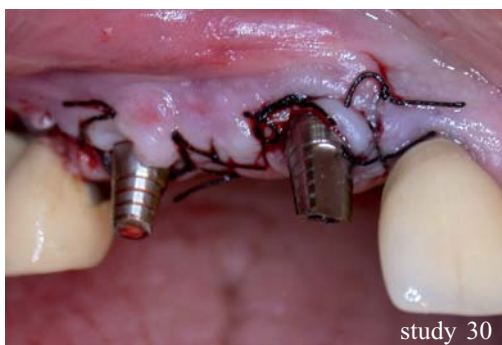- 34 **International** events 2010/2011
- 36 **1<sup>st</sup> Hvar** International Dental Congress
- 38 **EAO** Congress—Glasgow 2010
- 40 **Osteology** in Cannes  
| Dr Birgit Wenz
- 42 **3<sup>rd</sup> International CAMLOG** Congress

| news

- 44 **Manufacturer** news
- 48 **Congratulations** and **Happy Birthday** to all DGZI-members around the world

| about the publisher

- 49 | submission guidelines
- 50 | imprint



# NobelActive™

## A new direction for implants.

Dual-function prosthetic connection.

Built-in platform shifting.

Bone-condensing property.

High initial stability, even in compromised bone situations.

Adjustable implant orientation for optimal final placement.



10 YEARS WITH  
TIUNITE® SURFACE  
New data confirm  
long-term stability.

NobelActive equally satisfies surgical and restorative clinical goals. NobelActive thread design progressively condenses bone with each turn during insertion, which is designed to enhance initial stability. The sharp apex and cutting blades allow surgical clinicians to adjust implant orientation for optimal positioning of the

prosthetic connection. Restorative clinicians benefit by a versatile and secure internal conical prosthetic connection with built-in platform shifting upon which they can produce excellent esthetic results. Based on customer feedback and market demands for NobelActive, the product assortment has been expanded – dental professionals

will now enjoy even greater flexibility in prosthetic and implant selection. Nobel Biocare is the world leader in innovative and evidence-based dental solutions. For more information, visit our website

[www.nobelbiocare.com](http://www.nobelbiocare.com)

# Timing of dental implant loading

## A Literature Review

Author\_Dr Marius Hary Silvasan, Romania

**\_Osseointegration is the process** by which living bone attaches to the artificial surface of an implant by the formation of bony tissue without growth of fibrous tissue at the bone-implant interface.

### \_Introduction

Osseointegration is a highly dynamic process, which does not only address the formation of bone onto an implant surface after it has been placed, but it also addresses the remodelling or maintenance of bone during the life of the implant.

The long term success of an implant treatment is theoretically determined by factors related to the pa-

tient, the implant components and the treating clinicians.<sup>1</sup> Before the introduction of the Prof. Brånemark protocol, dental implants were commonly loaded at placement because immediate bone stimulation was considered to avoid crestal bone loss (Fig.1).<sup>2</sup> The clinician is often faced with the challenge of identifying the successful osseointegration of implant. Clinical success is often determined by a lack of mobility and ability of the implant to resist functional loading.<sup>3</sup>

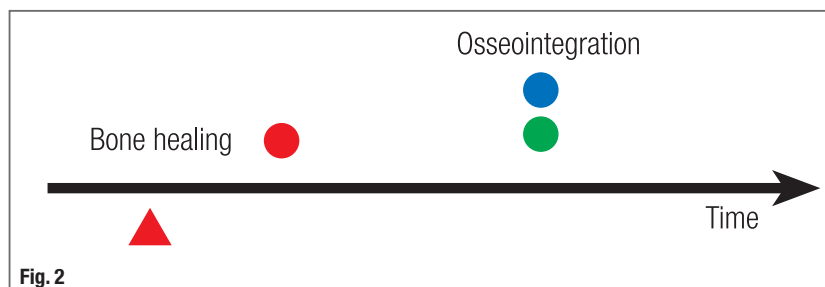
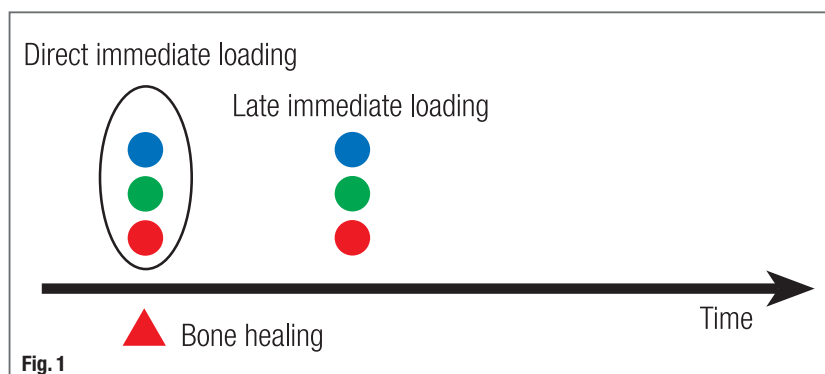
Radiographically, bone should appear to be closely apposed to the implant surface. The current achievable resolution obtained in medical imaging, however, is about 10 times less than what is required to observe a soft tissue cell. Therefore, radiographic assessment alone is unsuitable to determine with certainty if a soft tissue layer is present. When an implant is exposed to excessive micromotion at the bone-implant interface during healing, fibrous tissue encapsulation of the implant rather than osseointegration may occur. Conventional implant protocols have been based on the achievement of primary stability and prolonged non-loaded healing periods (Fig. 2).<sup>4</sup>

That was achieved by a two stage technique and an unloaded healing period of three to six months. Delayed implant loading was empirically based on the belief that the transfer of any micromotion to the implant surface during healing would result in fibrous encapsulation rather than osseointegration. A perceived psychological, economical and functional advantage of shortened treatment periods has encouraged clinicians to challenge this convention with immediate temporization (Fig. 3) and/or the early and immediate loading of dental implants.

The relative merits of these shortened loading protocols will be discussed with respect to their biologi-

**Fig. 1** Direct loading at placement and delayed loading after bone healing.

**Fig. 2** Conventional implant protocol without any loading performing the prosthetic in part after bone healing (e.g. Brånemark protocol).





cal implication, the current evidence based literature and the factors that might influence their outcomes. There is a growing body of published literature supporting reduced implant loading times. Abutment connection and placement of a restoration in occlusion with the opposing dentition of an implant at the time of surgery or within 48 hours of placement is referred to as "immediate loading". The functional restoration of an implant from 48 hours up to 3 months after placement has been defined as "early loading".<sup>5</sup> Both the immediate and early functional loading of implants before lamellar bone formation carry an inherent biological risk. Shortened loading protocols may expose the healing bone to implant interface to mechanical overload as described in Wolffs Law and Frosts Mechanostat theory (Fig. 4).

Interfacial micromotion above the biological threshold can result in the subsequent loss of implant stability. Rough titanium surfaces offer better implant anchorage in bone and more rapid bone deposition.<sup>6</sup> The general applicability of these principles will be considered as to their biological implications, the current evidence base and the factors that influence their results.

### Materials and Methods

Clinical reports on dental implants found in major scientific journals and through searching in PUB MED, QUINTESSENZ and MED-LINE, have served as the basis for this review. The following search terms, alone or in combination, were used: implant loading, immediate loading, early loading, delayed loading. After screening the titles and abstracts for possible relevance, they were ordered in full text. We also screened reference list of publications and relevant systematic reviews. To minimise bias, only RCTs of osseointegrated dental implants were considered. To be included, RCTs had to compare the same osseointegrated implants loaded at different times for a period of at least 12 months of loading.

For the purpose of this review immediate loading was defined as an implant put in function within 48 hours after its placement; early loading as those implants put in function from 48 hours up to 3 months after placement, and conventional loading as those implants put in function between 3 to 6 months after insertion. Implant mobility and removal of stable implants dictated by progressive marginal bone loss or infection have been assessed. Implant mobility of individual implants could be assessed manually or with devices such as Periostest® (Siemens, Munich, Germany) or Resonance frequency—Analysis—Osstell® (Integration diagnostics, Göteborg, Sweden). In our search we aimed at including randomized controlled trials. Most clinical reports were on a few implant sys-

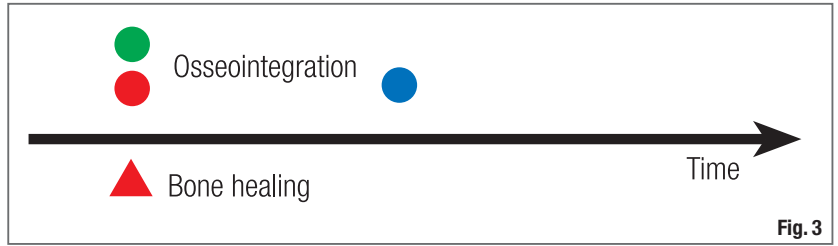


Fig. 3

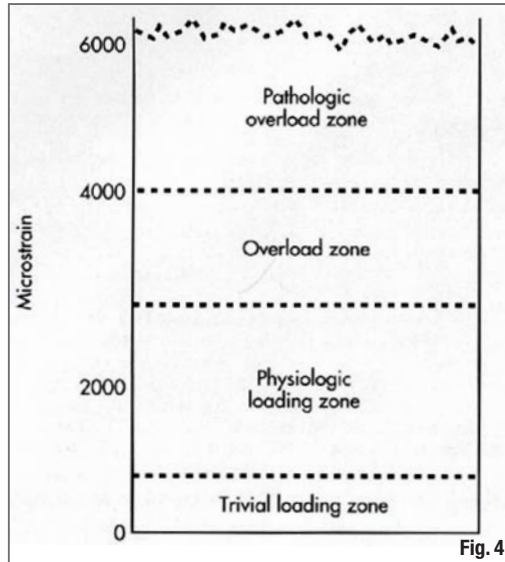


Fig. 4

Fig. 3\_Immediate temporization and delayed loading.

Fig.4\_Loading zones acc. to H. M. Frost

tems only and threaded commercially pure titanium implants ad modum Brånemark dominated the literature. The quality assessment of the included trials was undertaken independently. The following quality criteria were examined:

Allocation concealment was recorded as adequate (A), unclear (B), or inadequate (C), as described elsewhere [Higgins, Green S. Handbook for systematic reviews of interventions].

Allocation concealment was considered adequate if it was centralized (e.g. Allocation by a central office unaware of subject characteristics). If randomization was pharmacy controlled; if prenumbered or coded identical containers were administered serially to participants.

A score of A was recorded if there was a clear explanation for a withdrawals or dropouts in each treatment group or if there were no dropouts. If clear explanation for any dropouts were given, the risk of bias of the assessment of reasons for dropping out was evaluated. A "strong scientific basis" is required as well. A score of B was recorded if clear explanations for any dropouts or withdrawals were not provided. Articles or authors that stated that allocation concealment procedures were implemented but did not provide details on how this was accomplished were coded as unclear. A score of C was recorded if there

were "insufficient scientific basis" or any procedure that was entirely transparent before allocation, such as an open list of random numbers. Hence, after a thorough reading of the studies included in this review, one of these scores has been qualified according to accuracy and the underlying scientific bases.

## Results

In 2002, a consensus meeting was convened within the World Congress organized by the Spanish Board of Implantology in Barcelona.<sup>5</sup> There was an agreement on terminology for the timing of loading (immediate, early, delayed) and for the implant loading (occlusal loading and nonocclusal loading). According to this consensus meeting the following terminology was described:

### *Immediate loading*

The prosthesis is attached to the implants the same day the implants are placed

### *Early loading*

The prosthesis is attached at a second procedure, earlier than the conventional healing period of 3 to 6 months. The time of loading is started after some days/weeks.

### *Delayed loading*

The prosthesis is attached at a second procedure after a conventional healing period of 3 to 6 months.

### *Occlusal loading*

The crown/bridge is in contact with the opposing dentition in centric occlusion.

### *Nonocclusal loading*

The crown/bridge is not in contact in centric occlusion with the opposing dentition in natural jaw position.

The available literature demonstrates the possibility of achieving good results with different protocols, especially with immediate loading protocol, at least in good-quality bone, which supports the idea that these concepts may serve as a viable option in implant dentistry. However, the prerequisites for achieving and maintaining acceptable results and the limitations of immediate/early loading are not fully known. Moreover, the terminology used in these protocols is confusing since the difference between different protocols is not well defined, and publication titles can therefore be very misleading. Of 26 potential studies, 7 have been excluded because of insufficient patient selection data or prosthesis loading longer than one day (immediate loading), not corresponding to the Barcelona consensus, and 5 have been excluded since the follow up was shorter than 12 months. Fourteen

studies have been introduced in this review, the conclusions having been discussed on their basis.

The majority of the studies considered in this review registered a relatively short follow up. In 6 studies the follow up covered a period longer than 24 months.

Daniel Sullivan, Giampaolo Vicenzi, Sylvan Feldman performed a multicenter study: the performance of Osseotite implants after an 1 stage surgery and abbreviated healing period of 2 months in 10 private practice centers. 142 patients, partially or completely edentulous, enrolled in this early loading study, received 526 implants, 65.4 % in mandible and 34.6 % in maxilla. Implants were loaded after a healing period of about two months. The distribution of the prosthesis types included 118 single tooth restoration (118 implants), 134 short-span prosthesis (327 implants) and 16 long-span restoration (81 implants).

Eight of the eleven implant failures occurred during nonsubmerged healing prior to prosthetic loading. Provisional restoration was placed at  $2.1 \pm 0.5$  months, at which time implants were evaluated for mobility, gingival health and radiolucency. The cumulative success rate of these 526 implants was 97.9 % at 5 years.

These results suggest that success can be expected with Osseotite implants after a nonsubmerged reduced healing period of two months in this patient population.<sup>7</sup>

Par-Ölov Östman, Mats Hellman, Lars Sennerby evaluated in a prospective clinical study the radiographic and clinical outcome of immediately loading implants in the partial edentulous mandible over a 4 year follow up period.


96 patients were evaluated and 77 patients who met the inclusion criteria were included. A total of 111 fixed partial dentures supported by 257 Brånemark System implants (77 turned and 180 Ti Unite implants) was delivered. Four (1.16 %) of the 257 implants did not osseointegrate after 4 years. Three turned implants (3.9 %) and one oxidized implant (0.6 %) failed after 4 to 13 months. Immediate loading of implants with firm primary stability in partially edentulous areas of the mandible appears to be a viable procedure with predictable outcome.<sup>8</sup>

Richard P. Kinsel, Mindy Liss evaluated in a retrospective study the effects of implants dimensions, surface treatment, location in the dental arch, numbers of supporting implant abutments, surgical technique, and generally recognized risk factors on the survival of a series of single stage Straumann dental

# CONNECT YOUR COMPETENCIES

STRAUMANN® CARES® GUIDED SURGERY – GLOBAL EXCELLENCE MEETS LOCAL EXPERTISE

- **Local template production:** surgical templates with verified fit just in time from your local dental lab
  - **User friendly – open software system:** offers you large flexibility and easy usage
- **Customized cost model:** benefit from suitable price models for your personal business requirements



Please contact us at **0041 (0)61 965 1111**. More information on [www.straumann.com](http://www.straumann.com)

COMMITTED TO  
**SIMPLY DOING MORE**  
FOR DENTAL PROFESSIONALS



implants, placed into edentulous arches using an immediate loading protocol. Data were collected for 344 single-stage implants placed into 56 edentulous arches (39 maxillae and 17 mandibles) of 43 patients and immediately loaded with a one piece provisional fixed prosthesis.

Each patient received between 4 and 18 implants in one or both dental arches. Periapical radiographs were obtained over a 2 to 10 year follow up period to evaluate crestal bone loss following insertion of the definitive metal-ceramic fixed prostheses. A total of 16 implants failed to successfully integrate. Increased rates of failure were associated with reduced implant length, placement in the posterior region of the jaw, increased implant diameter and surface treatment. Implant length emerged as the sole significant predictor of implant failure.

In this prospective analysis, in 56 consecutively treated edentulous arches with multiple single stage dental implants loaded immediately, reduced implant length was the sole significant predictor of failure.<sup>9</sup> George Romanos, Georg Hubertus Nentwig evaluated immediate loading of oral implants on heavy smokers. Nine patients (5 male and 4 female) with a mean age of  $52.4 \pm 8.3$  years who smoked more than 2 packs a day for more than 10 years (heavy smokers) were included in this prospective clinical study. Seventy two implants, 6 implants in each jaw, 6 maxillae and 6 mandibles, made from commercially pure titanium (grade 2), with a progressive thread design and sandblasted surface (Ankylos, Friadent) were used. Provisional fixed prostheses had centric occlusal contacts and group function in the lateral movements of the mandible (immediate occlusal loading). Clinical and radiographic indices were evaluated at the start of loading and at 3 month intervals after loading. After a mean loading period of  $33.7 \pm 19.0$  months (range 6 to 66 months) one implant was mobile. All clinical indices had values in normal ranges. The Periotest values decreased with time, indicated increased security of implants in bone. Crestal bone loss was stable, with only two sites presented minimal vertical bone loss and six presented minimal horizontal bone loss. This study showed that immediate loading of oral implants may be successful in heavy smokers under some circumstances.<sup>10</sup> Gioacchino Cannizzaro, Michele Leone, Ugo Con Solo, Vittorio Ferri, Marco Esposito compared the efficacy of immediate functionally loaded implants placed with a flapless procedure (test group) versus implants placed after flap elevation and conventional load-free healing (control group) in partially edentulous patients. Forty patients were randomized: 20 to the flapless immediate loaded group and 20 to the conventional group. Implants in the immediately loaded group were provided with full acrylic resin temporary restoration in the

same day. Implants in the conventional group were submerged (anterior region) or left unsubmerged (posterior region) and left load-free for 3 months (mandibles) or 4 months (maxillae). 52 implants were placed in the flapless group and 56 in the conventionally group. After three years no dropouts or failures occurred.

When comparing baseline data with those at the years 1, 2, and 3 within each group, mean Osstell values of the flapless group did not increase, whereas there were statistically significant increases in the Periotest values.

Implants can be successfully placed flapless and loaded immediately without compromising success rates; the procedure decreases treatment time and patient discomfort.<sup>11</sup>

Roberto Crespi, Paolo Cappare, Enricho Gherlone, George E. Romanos performed a study to report a clinical comparative assessment of crestal bone level change around single implants in fresh extraction sockets in the esthetic zone of the maxilla either immediately loaded or loaded after a delay. Forty patients were included in a prospective, randomized study. All patient required 1 tooth extraction. Implants were positioned immediately after tooth extraction and were loaded immediately in the test group (20 implants) and after 3 months in the control group (20 implants). All implants were 13 mm long. Thirty implants had a diameter of 5 mm, and 10 had a diameter of 3.75 mm. Radiographic examination was made at baseline, at 6 months and at 24 months. After a 24-month follow up period, a cumulative survival rate of 100 % was reported for all implants. The success rate and radiographic results of immediate restorations of dental implants placed in fresh extraction sockets were comparable to those obtained in delayed loading group.<sup>12</sup> Two studies registered a 18 month follow up. Joseph Nissan, George E. Romanos, Ofer Mardinger, Gavriel Chaushu assessed the clinical effectiveness of immediate nonfunctional loading for single tooth implants placed in the anterior maxilla following augmentation with cancellous freeze-dried block graft, with clinical outcomes up to 18 months after placement. Implants were immediately restored with unsplinted acrylic resin provisional crowns. Eleven patients received 12 implants in the anterior maxilla, and intraorally radiographs were obtained immediately after implant placement and at 6, 12 and 18 months. Survival rate and radiographic marginal bone loss were evaluated at 0, 6, 12 and 18 months. Marginal bone loss did not extend beyond the first thread up to a 18 month follow-up.

Within the limits of this study, immediate non-functional loading for single-tooth implants placed

in the anterior maxilla following augmentation with cancellous freeze-dried block graft seems a promising treatment alternative.<sup>13</sup>

Roberto Crespi, Paolo Cappare, Enricho Gherlone, George E. Romanos evaluated the clinical and radiographic outcome of dental implants immediate placed and loaded into fresh extraction sockets after 18 months. Twenty-seven patients, 15 women and 12 men, received a total of 160 implants. 150 were placed immediately after extraction. The sockets in the study

had fully preserved walls, and 10 were placed in healed sites. Immediately after surgical procedure, all patients received the temporary prosthetic reconstruction in occlusion. Five months post surgery, definitive metal-ceramic restorations were cemented on abutments. Intraoral digital radiographic examination were performed 3 and 18 months after implant placement. Mean marginal bone loss 18 months after immediate loading was  $0.65 \pm 0.58$  mm to the mesial side and  $0.84 \pm 0.69$  to the distal side in the maxilla and  $1.13 \pm 0.51$  mm mesially and  $1.24 \pm 0.60$  distally

**Tab. 1** Summarized data from the studies/approaches used in this review with reference to immediate loading.

Load time	Splint time	Sit.	Impl. type	Follow up	No. of pac. No. of impl.	Succ. rate	Reference	Lev. of evid
Immediate loading	1 Day	Ed. mand.	Novum Brånemark	12 Months	10 pac. 30 impl.	86.7 %	Els De Smet et al.	B
Immediate loading	1 Day	Max. esthetic zone	Sweden & Martina	24 Months	20 pac. 20 impl.	100 %	Roberto Crespi et al.	C
Immediate loading	< 1 Day	Part. ed. mand.	Ti Unite Brånemark	48 Months	77 pac. 257 impl.	98.4%	Rar-Oslov Ostman et al.	B
Immediate loading	< 1 Day	Ed. max. Ed. mandib.	Ankylos Friadent	12-60 Months	9 pac. 72 impl.	98.6 %	George Romanos et al.	B
Immediate loading	1 Day	Part. Edent.	Zimmer Swiss Plus	36 Months	20 pac. 52 impl.	100 %	Gioacchino Cannizzaro et al.	B
Immediate loading	1 Day	Ed. max. 39 Ed. man. 17	Straumann	2-10 Years	56 pac. 344 impl.	95.6 %	Richard P. Kinsel et al.	B
Immediate loading	1 Day	Ant. maxila	3 I-9 impl. Zimmer-3 impl	18 Months	11 pac. 12 impl.	100 %	Joseph Nissan et al.	B
Immediate loading	< 1 Day	All Edent.	Bicon	12 Months	209 pac. 477 impl.	90.3 %	Mohamed S. Erakat et al.	B
Immediate loading	< 1 Day	Lat ed. mand.	Straumann	12 Months	20 pac. 40 impl.	97.5 %	Roberto Cornellini et al.	B
Immediate loading	< 1 Day	Ed. max. part.	Sweden & Martina	18 Months	27 pac. 160 impl. (150 after extr.)	100 %	Roberto Crespi et al.	C
Immediate loading	< 1 Day	Ed. max.	Zimmer Swiss Plus	12 Months	33 pac. 202 impl.	99 %	Gioacchino Cannizzaro et al.	B
Immediate loading	< 1 Day	Ed. max.	Various	60 Months	44 pac. 338 impl.	99.1 %	Degidi et al.	B
Immediate loading	1 Day	Ed. mandib.	Straumann	24 Months	9 pac. 36 impl.	100 %	Pedro Tortamano et al.	C

in the mandible. Within the limits of this clinical study, the results indicate that immediate loading of implants placed in immediate extraction sites can be carried out successfully.<sup>14</sup> Six studies covered a 12 month follow up. Els de Smet, Joke Duyck, Josvander Sloten, Ignace Naert performed a clinical trial to report on the implant outcome of delayed, early and immediate loading of implants in the edentulous mandible. On a consecutive basis, the first ten patients received an overdenture retained by 2 ball attachments four months after implant insertion (delayed), and the next 10 patients received an overdenture one week after implant surgery (early). The next ten patients were treated with a fixed prosthesis on 3 implants (Brånemark, Novum) either the day of or the day after surgery (immediate). All patients were followed for one year, half were followed for two years. One patient in each OD group lost both implants.

The losses occurred six months after loading in the delayed group and one month after loading in the early group. In the immediate group, one patient lost both distal implants five months after loading. In two other patients, one distal implant failed after one year of loading. Maximal bite forces increased over time for all groups. Marginal bone loss was the highest for the immediate group.

According to this prospective controlled clinical trial, the results achieved with early implant loading were comparable to those achieved with implants loaded after a delay. Distal implants are at higher risk for failure in the immediate loading protocol.<sup>15</sup> Pedro Tortamano, Tadashi Carlos Orii, Julio Yamanochi, Atlas Edson Moleros Nakame, Tatiana de Carvalho Guarnieri presented a new method for fabricating effective definitive prostheses to immediate load implants in edentulous patients. Nine patients received four implants each, and resin metal prostheses were installed less than 48 hours after implant placement. Clinical evaluation of soft peri implant tissues was conducted monthly after the sutures were removed, and radiographs were obtained 6, 12 and 24 months after the surgery. The periosteal revealed statistical values that were stable, with no mobility. No signs of inflammation and/or bleeding were observed. The radiographs did not reveal any continuous areas of radiolucency beyond the first thread of the 36 implants after 24 months.

Under immediate load, osseointegration of implants is possible, and the method for the fabrication of resin-metal prostheses has been reliable and predictable.<sup>16</sup> Giuseppe Luongo, Rosario Di Raimondo, Paolo Filippini, Federico Gualini, Cesare Paoleschi evaluated the concept of an immediate loading protocol in the posterior maxilla and mandible through

analysis of implant survival at 1 year. Eighty two ITI sandblasted, acid-etched (SLA) implants in 40 patients were loaded between 0 and 11 days after implant placement. The restorations consisted of either 2 splinted crowns or a 3-unit fixed prosthesis. All restorations were put into full functional occlusion. Periapical radiographs were evaluated for changes in crestal bone level from baseline to 1 year postloading. Three patients' implants were not loaded because of lack of primary stability, and a fourth patient was excluded from the study because of a protocol violation (more than 4 implants were used). The mean bone loss at 1 year  $0.52 \pm 0.98$ . The early results from this study indicate that early and immediate loading of two implants in the posterior maxilla and mandible may be suitable in selected patients. On the basis of one year observation, the results appear similar to those achieved with a delayed procedure.<sup>17</sup>

Mohamed S Erakat, Sung-Kiang Chuang Meghan Weed, Thomas B. Dodson estimated the 1-year survival rate of immediate vertical load splinted locking taper implants and identified the risk factors for implant failure. The study cohort was composed of 209 patients who received 477 implants. The overall one year Kaplan Mayer survival estimate was 90.3%. After controlling other variables, 3 variables—timing of implant placement relative to extraction (delayed implant placement after tooth extraction), coating of implant (uncoated), and increased number of pontics—were associated with an increased risk for implant failure. An overall 1-year survival estimate of 90.3% (95% CL: 86.9%, 93.7%) was calculated for immediately loaded splinted implants. After controlling other variables, 3 variables—timing of implant placement relative to extraction (delayed implant placement after tooth extraction), coating of implant (uncoated), and increased number of pontics—were associated with an increased risk for implant failure.<sup>18</sup> Roberto Cornelini, Filippo Cangini, Ugo Covani, Antonio Barone, Daniel Buser evaluated the success rate at 12 months of titanium dental implants placed in the posterior mandible and immediately loaded with 3-unit fixed partial dentures. Patients with missing mandibular premolars and molars were enrolled in this study. Forty implants with a sandblasted, large grit, acid-etched (SLA) surface (Straumann) were placed in 20 patients. Implant stability was measured with resonance frequency analysis using the Osstell device. Implants were included in the study when the stability quotient (ISQ) exceeded 62. At 12 months, only one implant had been lost because of an acute infection. The remaining 39 implants were successful, resulting in a 1-year success rate of 97.5%. Neither peri-implant bone levels, measured radiographically, nor implant stability changed significantly from baseline to the 12 month follow-up.





VARIO SR **SCREW-RETAINED**  
**COMPONENTS** FOR  
MORE **POSSIBILITIES**

For occlusally screw-retained crown and bridge restorations. Proven CAMLOG handling. Improves safety, saves time thanks to special aligning tool. CAMLOG offers more. Further information: [www.camlog.com](http://www.camlog.com)

a perfect fit™

camlog

Load time	Splint time	Sit.	Impl. type	Follow up	No.of pac. No.of impl.	Succ. rate	Reference	Lev. of evid
Early loading	2 Months	Ed. max. Ed. mandib.	Osseotite	60 Months	142 pac. 526 impl.	97.9 %	Sullivan et al.	B
Early loading	1-11 Days	Ed. post. mandib. Ed. post. max.	ITI Straumann	12 Months	40 pac. 82 impl.	98.8 %	Giuseppe Luongo et al.	B
Early loading	7 Days	Ed. mandib.	Novum Brånemark	12 Months	10 pac. 20 impl.	90 %	Els De Smet et al.	B

Load time	Splint time	Sit.	Impl. type	Follow up	No.of pac. no.of impl.	Succ. rate	Reference	Lev. of evid
Delayed loading	4 Months	Ed. mandib.	Novum Brånemark	1 Year Half 2 Years	10 pac. 20 impl.	90 %	Els De Smet et al.	C
Delayed loading	3 Months	Max. esthetic zone	Sweden Et Martina	24 Months	20 pac. 20 impl.	100 %	Roberto Crespi et al.	B
Delayed loading	4 Months	Part. Edent.	Zimmer Swiss Plus	36 Months	20 pac. 56 impl.	100 %	Gioacchino Cannizzaro et al.	B

**Tab. 2** Summarized data from the studies /approaches used in this review with reference to early loading.

**Tab. 3** Summarized data from the studies/approaches used in this review with reference to delayed loading.

The findings from this clinical study showed that the placement of SLA transmucosal implants in the mandibular area and their immediate loading with 3-unit fixed partial dentures may be a safe and successful procedure.<sup>19</sup> Gioacchino Cannizzaro, Michele Leone, Marco Esposito have performed a one year follow-up of a single cohort study. Thirty three consecutively treated edentulous patients received 202 implants in the maxila. In 10 patients, 53 implants were immediately inserted in fresh extraction sockets. Three implants in two patients did not reach sufficient stability and were left to heal for 45 to 90 days. All restorations (21 fixed prostheses and 12 overdentures) were delivered the same day of the surgery. No major complication occurred. Five patients experienced biologic complication, e.g. peri-implantitis; ten experienced prosthetic complication. Two implants failed in two patients but were successfully replaced the same day they were removed. No prosthesis failed. Implants placed in the edentulous maxilla with a flapless procedure can be successfully loaded the same day of surgery.<sup>20</sup> The activity around dental implants has been approached by Hiroto Sasaki et al. who performed a study to determine dynamic changes in bone metabolism around osseointegrated

titanium implants under mechanical stress. After insertion of implants, the uptake ratio increased during the first week and then decreased gradually. It was significantly higher than baseline on days 4.7 and 10 ( $p < 0.01$  Friedman test) and during the second and third week ( $p < 0.5$  Steel test). However, it was not significantly higher at 4 weeks and 7 weeks (i.e. metabolic activity had returned to the baseline level). The uptake ratio changed with the loading. With 2.0 and 4.0-N loading, change of activities over the 7 week experimental period was almost the same in terms of magnitude and timing. The ratio reached a maximum during the first week (more than twice that without loading) and then decreased a little. Metabolic activity returned to the baseline level at about 2 to 7 weeks after loading. The ratio from 3 days to 6 weeks after loading was significantly higher than without loading (Friedman and Steel test,  $P < 0.05$ ). There was no significant difference 7 weeks after loading. The results for the 0.5 and 1.0-N loading groups were similar but different from those for the 2.0 and 4.0-N loading groups. With the smaller loadings, the uptake ratio gradually increased after loading and returned to the baseline level at 7 days. It then decreased, reaching baseline level at 2 to 7

weeks after loading. With 1.0-N loading, the uptake ratio did not differ among measurement points (Friedman and Steel tests,  $P > .05$ ). The uptake ratios with the 2.0 and 4.0 loads were significantly higher than those with the 0.5 and 1.0-N loads (Tukey test,  $P < 0.05$ ).<sup>21</sup>

## Discussion

Successfully osseointegrated dental implants are anchored directly to the bone. However, in the presence of movement, a soft tissue interface may encapsulate the implant causing its failure. To minimize the risk of soft tissue encapsulation, it has been recommended that implants should be kept load-free by submerging them during the healing period.<sup>24</sup>

Immediately loaded or early loaded implants after insertion develop special and specific clinical implications with an impact on the treatment time. If it can be shortened to a very large extent it involves a significant fact to the benefit of the patients. The main purpose of these studies is actually the achievement of a successful final prosthesis. Implant loss is a significant risk factor in this respect.

This review has been intended for gathering data and information available in reference literature in order to achieve a clinical conclusion as to fixed or removable implant-supported prostheses based on time of loading. Attempts to use standard systematic review procedures (application of scientific strategies in ways that limit bias to the assembly, critical appraisal and synthesis of all relevant studies that address a specific clinical question) have not been entirely possible because of report variability, and this limits the ability to draw conclusive comments from the work.

Nowadays, immediate or early dental implants loading with a careful patients' selection is possible. The clinician's experience is an obligatory prerequisite in reaching optimum results with immediate loading. One of the conditions or requirements influencing the procedure success appears to be the high primary stability of the implant at the insertion time. In future, additional and well structured studies are important and necessary to complete a clear protocol for immediate and early loading. No statistical difference for prosthesis and implants success rate or marginal bone loss with different time of implant loading has been observed. All known risk factors and contraindications for osseointegration with a standard protocol will be equally or even more important with immediate or early loading protocols. It is thus implied that successful osseointegration with reduced loading protocols requires critical case selection and meticulous surgical and prosthetic management.

A surgical technique that minimizes heat generation and pressure necrosis is of particular importance with both early and immediate implant loading. It is also dependent on the quality and quantity of existing bone at the implant site and the ability to achieve and maintain adequate stability of the implant so that micromotion is kept below the biological threshold. The level of skill and experience of the surgeon play a role in treatment outcomes. The presence of infection in the implant area will affect osseointegration. Untreated periodontitis and periapical pathology must be addressed before implant placement, independent of the loading protocol.

Management of micromotion of the implant is critical for osseointegration and many studies stress the importance of minimizing functional loading in both centric and lateral excursion. Non axial loading is difficult to measure clinically and the ideal occlusal scheme has not been outlined. It is therefore impossible to state that parafunction is an implicit contraindication to immediate or early loading but it is generally considered to be a risk factor.

Relatively few data about the relationship between soft tissue and immediate or early loading are available. Marginal recessions around the immediately loaded implant were comparable to those conventionally loaded.<sup>22,23</sup>

Smoking has been shown to have a negative impact on osseointegration<sup>25,26</sup> and, as such, it must be also considered a potential risk factor for immediate and early loading protocols even though some studies showed that immediate loading of oral implants may be successful in heavy smokers under some circumstances.<sup>10,27,28</sup>

It is fundamentally necessary for a treatment plan to offer an advantage to the patient. Immediate and early loading benefits reduce surgical steps by eliminating the second procedure, shorten treatment time and provide a functional and psychologic advantage of prosthetic rehabilitation.

Immediate restoration or loading may be particularly attractive to a patient as temporization with a removable appliance is not required after implant fixture placement. The advantage must be carefully considered against a potential increased risk of failure for immediate or early loading times.

An increased success rate was generally stated in the studies; however, two studies<sup>15,18</sup> have revealed a relatively high failure rate. In one study<sup>15</sup>, one patient of each group lost both implants. The loss occurred six months after loading in delayed group and one month after loading in early group. In the immediate group,

one patient lost both distal implants five months after loading. In two other patients, distal implants failed after one year of loading. Marginal bone loss was the highest for the immediate group. In another study<sup>18</sup>, there has been reported a success rate of 90.3 %, i.e. 47 lost implants out of 477 inserted implants, respectively. It might be important to specify that Bicon implants were used in the study. It is worth mentioning that, in general, the success rate was high (95.6 % – 100 %), a fact confirming immediate and early loading of dental implants to be a viable treatment option.<sup>7,8,9,10,11,12,13,14,16,17,19,20</sup> Marginal bone loss was observed to be higher with immediately loaded implants.<sup>15</sup> Furtheron, bone loss has not been extended beyond the first implant thread.<sup>13,16</sup> Both implant length reducing and diameter shortening increase the risk of failure.<sup>9</sup> Another important aspect is that immediate loading can be achieved under circumstances of a high primary stability.<sup>8,9,10,11,12,13,14,15,16,17,18,19,20</sup>

### Conclusion and Clinical Relevance

Nowadays, immediate and early loading with outcomes comparable to conventional results is possible. However, a rigorously and thoroughly selected surgical and prosthetic management is of utmost importance and necessity in achieving the goal. It is also compulsory for dental implants to show a very good primary stability and bone quantity and quality as well as bruxism and parafunctional habits must be correctly assessed. The risk of failure with immediate and early loading is extremely high in the lateral maxillary area due to poor bone quality as well as when one tooth only is replaced. A high success rate has been observed when optimum density bone exists and when the implants are splinted. Biological limits in the immediate and early loading process of dental implants have not been entirely defined yet. Further researches are required and important for a more accurate setting of limits between immediate, early and delayed loading of dental implants.

### Summary

The scope of this review is to find an answer to the questions "when" and "how" implants can be loaded in different time after insertion. For the purpose of this review, immediate loading was defined as an implant put in function within 48 hours after its placement; early loading as those implants put in function from 48 hours up to 3 months after insertion, and conventional loading as those implants put in function between 3 to 6 months after placement. The review has been accomplished on the basis of 14 studies selected out of 26, with a minimum 12 month follow up. The concern for immediate or early loading after insertion determines special and specific clinical

implications with an impact on the treatment time since it is shortened to a very large extent, being thus a benefit to the patients.

The main purpose of the studies underlying this review is in fact the success of the final prosthesis, since implants loss engenders a great risk for prostheses. Immediate or early loading of dental implants is nowadays possible for carefully selected patients. All known risk factors and contraindications for osseointegration with a standard protocol will be equally or even more important with immediate or early loading protocols. It is thus implied that successful osseointegration with reduced loading protocols requires critical case selection and meticulous surgical and prosthetic management. A surgical technique that minimizes heat generation and pressure necrosis is of particular importance with both early and immediate implant loading. It is also dependent on the quality and quantity of existing bone at the implant site and the ability to achieve and maintain adequate stability of the implant so that micromotion is kept below the biological threshold. The level of skill and experience of the surgeon play a role in treatment outcomes. Biological limits in the immediate and early loading process of dental implants have not been entirely defined yet. Further researches are required and important for a more accurate setting of limits between immediate, early and delayed loading of dental implants.

*For reviewing this article and the support I thank Dr Roland Hille, Dr Rolf Vollmer and Dr Mazen Tamimi.*

*Cited literature upon request.*

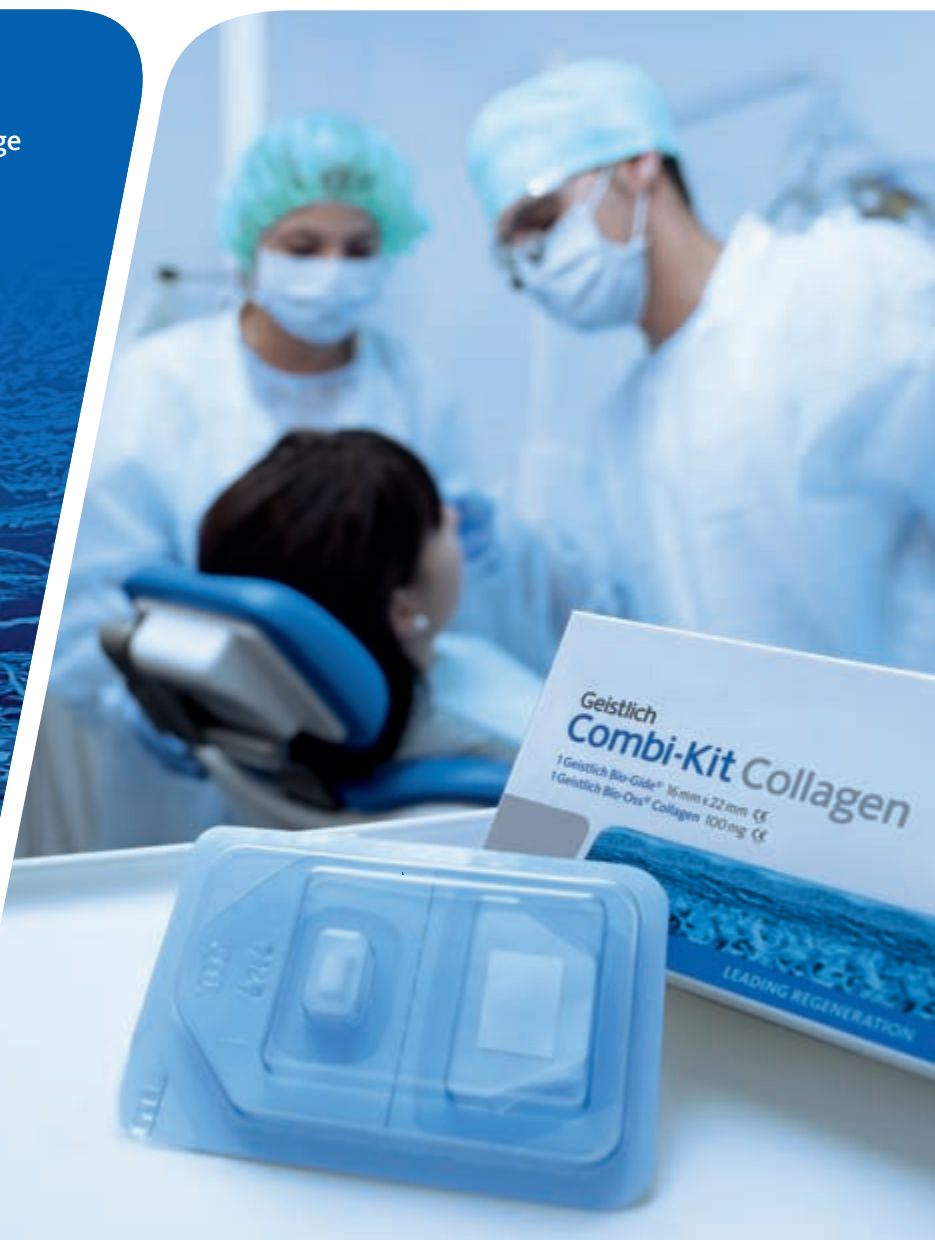_contact	implants
<p><b>Dr Marius Hary Silvasan</b>                  str. Romulus nr. 34A                  300238 Timisoara, Romania                  Phone: +40 722 367 490                  Fax: +40 256 294 085</p>	



# Geistlich Combi-Kit Collagen

## The new kit for success.

Geistlich Combi-Kit Collagen – the best kit for successful and predictable results in ridge preservation and minor augmentations.



# Lateralization of the inferior alveolar nerve

Author\_Dr Bernd Quantius, Germany

**\_Depending on the anatomical situation,** the lateralization of the inferior alveolar nerve may be one, or perhaps the only, solution to manufacture a fixed prosthesis for a patient with a free-end situation. This article describes the surgical technique used to minimize probable risks.

## **\_Problems**

If a patient with conservable residual dentition in the anterior mandibular area with a free-end situation requires an implant-supported restoration, problems may arise regarding the route of the inferior alveolar nerve. If the route of the nerve runs too far toward the crestal bone, or if there are already signs of atrophy in the crestal part of the jaw, a restoration with a common implant may be difficult, or even impossible. Here are several solutions for this problem.

One solution is the use of short implants (< 10 mm). The minimum length of common implant systems is 7–9 mm. Therefore, the bottom line for a conventional implant should be calculated with a safety margin of 2 mm, provided that there are approximately 9–11 mm of crestal bone. As observed in the mandible, the survival rates of 8 mm long implants

are similar to the survival rates of longer implants (Grant<sup>5</sup> 2009).

Another alternative is a vertical augmentation with autologous bone or allogenic materials. With respect to resorption, the long-term prognosis is controversial. Schlegel<sup>13</sup> states a resorption rate of approximately 30% after five years. Moreover, this solution must be excluded for those cases in which atrophy of the jaw bone is not due to insufficient crestal bone, but to the crestal route of the inferior alveolar nerve (Fig. 1). This method requires the usage of pelvic bone, which implies a second surgery site. Probable rates of long-term complaints in this area are partially stated as 11% (Cricchio<sup>1</sup> 2003).

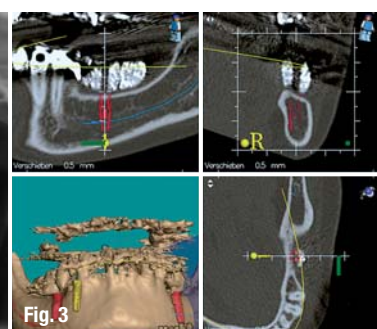
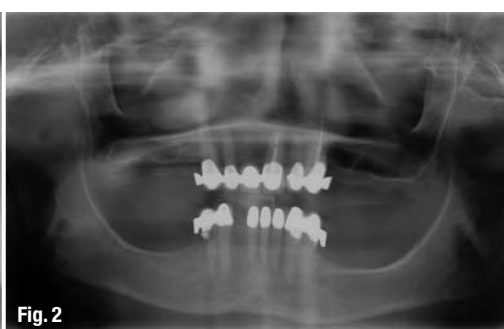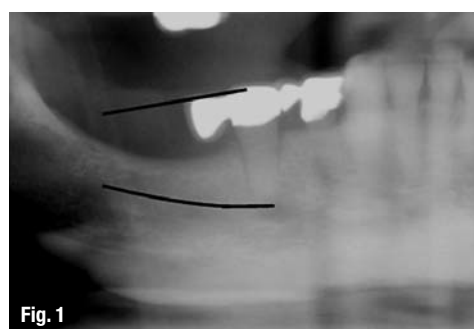
Another option is the osteodistraction in the lateral mandibular area. In order to place the distractor cranially to the nerve canal, a minimum of 8 mm residual bone substance is necessary for the application of this technique. Here, the resorption rate is lower than in cases of vertical augmentation (Esposito<sup>2</sup> 2009).

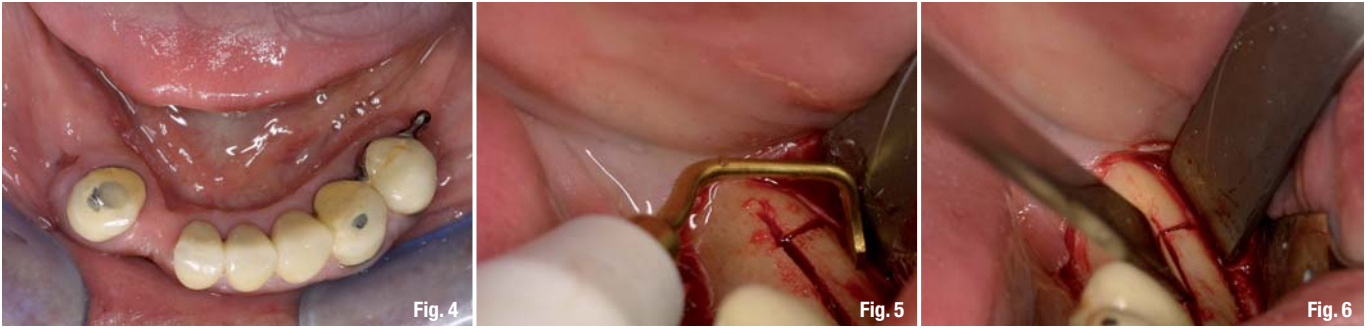Thus, the lateralization of the inferior alveolar nerve facilitates implantation in the lateral

**Fig. 1** \_Crestal route of the inferior alveolar nerve.

**Fig. 2** \_OPG before surgery.

**Fig. 3** \_Evaluation with Med 3-D software.





**Fig. 4**\_Clinical initial situation.  
**Figs. 5 & 6**\_Preparation of the buccal bony window with the cogged part of the Piezo device.

mandibular tooth area. There are two operative approaches cited in literature that suggest how to change the route of the nerve, and how to make implantation possible. This article describes a technique which minimizes risks thanks to exact planning and by using Piezo surgery.

**\_Surgical techniques**

In 1987, Jensen<sup>8</sup> and Nock were the first to publish this technique developed for the translocation of the mental foramen.

The technique shows the exit of the inferior alveolar nerve at the mental foramen. Being observed and taking care of the nerve, the foramen is extended into distal direction, thus the nerve's exit from the jaw is further distal and in the buccal direction.

This allows implantation in position 5 and/or 6 without damaging the nerve. Kan, Pelg and Ferrigno describe another surgical technique for the lateralization of the nerve, distal to the mental foramen. With this technique the inferior alveolar nerve stays intact in the area of the mental foramen. The technique is described in detail in this article. The fenestration of the compact bone was carried out distal to the foramen. The route of the nerve is visualized and the nerve lateralized. The optically controlled implant insertion is carried out leaving the nerve aside. After insertion the nerve will be put back into the bony window.

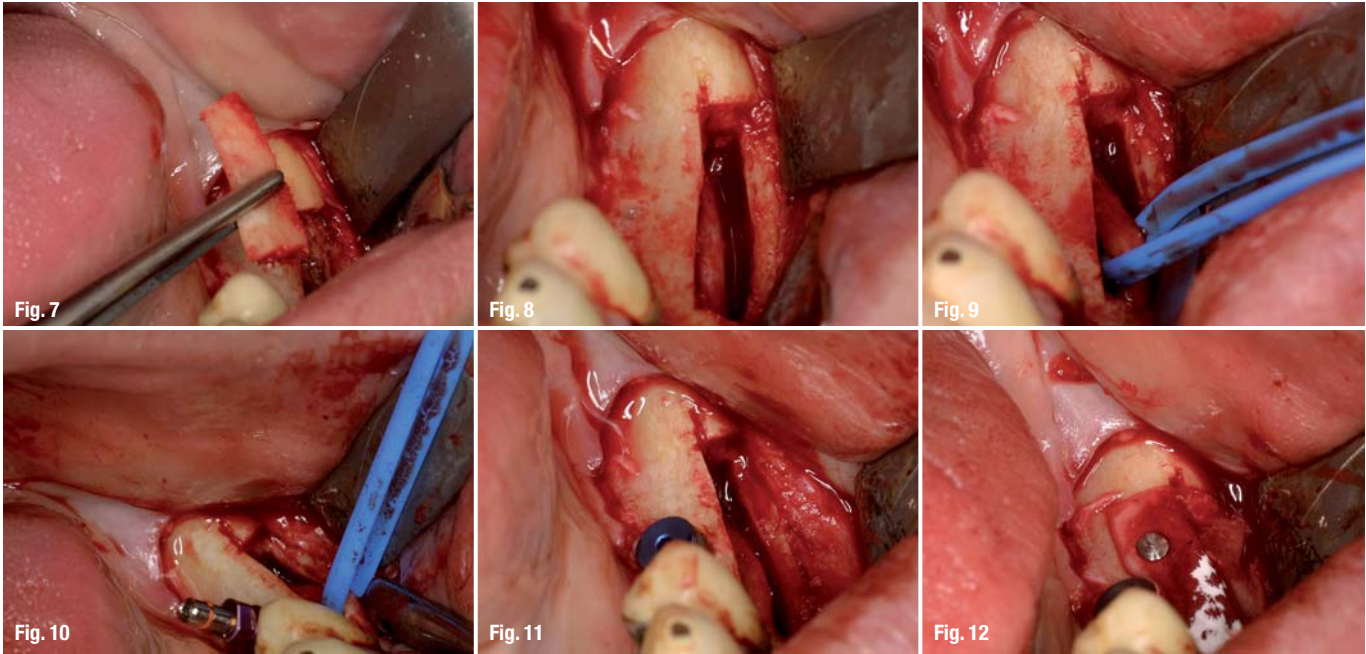
**\_Risks and complications**

This technique carries the important risk of temporary or even permanent irritation of the nerve, which may lead to anesthesia, hypesthesia

		Surgeries	Technique	Implants	Sensoric disorders	Survival rate
Rosenquist <sup>12</sup>	1992	10		26	0 % 12 M	96 %
Jensen <sup>7</sup>	1994	10	Displacement of the foramen	21	10 % 12 M 50 % 3 M	100 %
Kan <sup>6</sup>	1997	9 12	Displ. of foramen translocation	29 35	66,7 % 10-67 M 33,3 % 10-67 M	93,8 %
Peleg <sup>10</sup>	2002	10	Translocation	23	10 % 6W no permanent disorders	100 %
Ferrigno <sup>3</sup>	2005	19	Translocation	46	10 % 12 M	96 %

**Tab. 1**\_A variety of studies concerning the lateralization of nerves.





**Fig. 7** Preparation of the buccal bony window with the clogged part of the Piezo device.

**Fig. 8** Preparation of the nerve.

**Fig. 9** The encircled nerve.

**Fig. 10** Post-implantation status.

**Fig. 11** Repositioning of the nerve.

**Fig. 12** Covering with a collagen membrane.

or paresthesia. Several studies have considered this risk.

In his 1992 study Rosenquist<sup>12</sup> demonstrated that 12 months later sensory disorders could not be observed in all 10 patients (26 implantations). Peleg's<sup>10</sup> 2002 study did not show any permanent disorders either. Jensen<sup>7</sup> quoted 10% sensory disorders after 12 months. In 2005 Ferrigno<sup>3</sup> reached the same results, and he also agreed with the figure stated by Watzek<sup>14</sup>. The interesting retrospective study by Kan<sup>9</sup> 1997 is the only one that compares both surgical techniques, the "displacement of the foramen" and the "lateralization of the inferior alveolar nerve". He analyzed 21 surgeries (64 implantations) after 10 to 67 months. He found out that sensory disorders occurred significantly more often in cases of displacement of the foramen (66.7%) compared to the lateralization of the nerve (33.3%).

in the above-mentioned studies is between 93.8% and 100%. Kan describes for example another probable complication, i.e. a fracture of the mandible at the operation site. The mandible is weakened by the removal of the buccal corticalis, and by the crestal implantation at the same time, and thus there is an increased risk of fracture.

We observed temporary irritations of the mental nerve appearing as paresthesia in 90% of our own patients. These irritations disappeared completely within 8 weeks.

### Clinical procedures

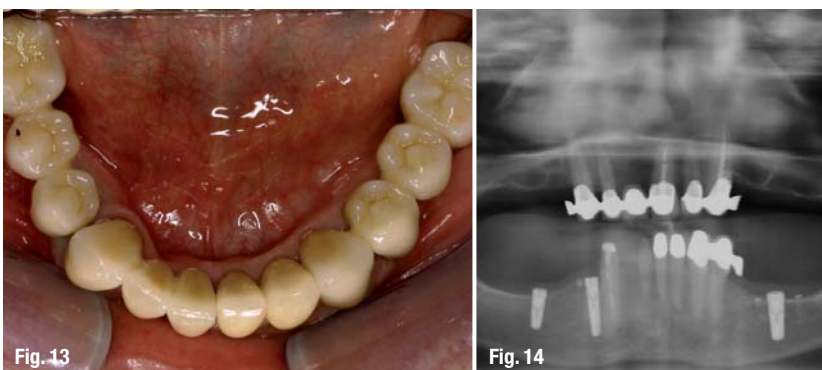#### Diagnosis

Thorough clinical and radiological examinations are crucial preparations for this surgical procedure. In addition to the conventional OPG (panoramic radiography) (Fig. 2), a three-dimensional examination using CT (computer tomography) or DVT (digital volume tomography) images, and their evaluation with the appropriate software, is absolutely necessary. Therefore it is possible beforehand to get a three-dimensional image of the route of the inferior alveolar nerve in the mandible. Figure 3 shows an evaluation using Med-3-D software.

The positioning of the buccal bony window should be especially considered when planning the surgery. After having prepared the buccal bony window and the implant cavity, it is of great importance to preserve enough bone in the buccal area of the implant, in order to guarantee sufficient primary stability.

**Fig. 13** Status following prosthetic restoration.

**Fig. 14** X-ray control.





### Operative procedures

After carrying out an insertion of the jaw ridge and the preparation of the mucoperiosteal flap, the mental foramen can be shown. This is important and enables orientation when positioning the lateral bone incision. The horizontal incision line starts approximately 3–5 mm distal of the foramen. The incision depth depends on the route of the inferior alveolar nerve distal from the foramen. Piezo surgery is recommended for the preparation of the bone incision and the latter preparation of the inferior alveolar nerve because it guarantees maximum safety for the soft tissue, while at the same time the risk of nerve irritation can also be reduced. After the removal of the buccal corticalis the nerve can be prepared in the cancellous bone. Usage of the diamond-coated part of the Piezo device is recommended for this procedure. After preparation, the nerve will be encircled with ethiloo silicone sling<sup>a</sup>.

The preparation of the nerve is followed by the insertion of the implant. In order to obtain sufficient primary stability, there must still remain enough bone in the buccal area after the preparation of the cavity. If there is not enough bone left, the buccal bone lamella may break during insertion, which might endanger the primary stability of the implant. The preparation of the counter corticalis is also suggested, provided that the implant is long enough. A previously manufactured—by means of 3-D diagnosis—orientation template, can be used for the bucco-lingual and mesio-distal positioning of the implant.

The nerve can be repositioned directly on the implant (in this case a CAMLOG Srewline, 4,3 x 13 mm, was used, Fig. 10 and 11) without taking any further measures. Some authors (Rosenquist<sup>11</sup>, Friberg<sup>4</sup>) state that the contact with sharp thread edges often causes chronic irritation. Use of implants with a low incisive thread is therefore recommended in order to avoid nerve irritation. After repositioning the nerve the bone cavity will be filled with bone chips, which were obtained by grinding the buccal compact bone. Afterwards, the cavity will be covered with the collagen membrane<sup>b</sup>, which will be fixed with membrane nails<sup>c</sup>. The wound is carefully closed with successive single interrupted sutures<sup>d</sup>. After a waiting period of three months, the fixed prosthetic restoration can

be done. During this time the operative site should not be irritated.

### Discussion

The lateralization of the inferior alveolar nerve offers patients the possibility of obtaining a fixed prosthesis in the mandible, provided that they have a conservable anterior residual dentition and a free-end situation.

This is sometimes the only feasible procedure to help patients obtain a fixed prosthesis, especially in those cases where there is only very little residual bone height depth left due to the route of the inferior alveolar nerve rather than atrophy. Other advantages are the fixation in the pre-existing bone, and the one site surgery, which make augmentative procedures unnecessary. This also avoids the disadvantages of other procedures for example the risk of resorption. The evaluation values for implant survival rates are similar to those for standard implantations. However, there are two reasons that might advise against a lateralization of the inferior alveolar nerve: (i) the complicated surgical technique requires a skilled surgeon and (ii) the risk of nerve irritation.

Patients have to consider 6–8 weeks of lasting paresthesia of the mental nerve, and the possibility of a permanent paresthesia cannot be excluded. It is therefore of utmost importance to inform the patient in detail beforehand. A rather rarely-occurring complication is a mandibular fracture in the area of the bony window. In 10 of the 11 lateralization surgeries carried out in the authors clinic, the function of the mental nerve was completely recovered within 6–8 weeks. In one case, one patient still suffers from permanent paresthesia, though it does not disturb much. However, even this patient would again decide upon this surgery instead of choosing a removable mandibular prosthesis as alternative solution. No case of implant loss can be reported. In all cases, the fixed implant-supported prosthesis could be manufactured according to the previous planning.

*Editorial note: The literature list can be requested from the author.*

<sup>a</sup> Ethiloo—Ethicon

<sup>b</sup> Bio-Gide—Geistlich Biomaterials

<sup>c</sup> Frios Membrannägel—DENTSPLY Friadent

<sup>d</sup> Ethibond Excel 4-0—Ethicon

\_contact

implants

**Dr Bernd Quantius MSc**

Giesenkirchener Str. 40

41238 Mönchengladbach, Germany

E-mail: B.Quantius@drquantius.de

# Piezoelectric repositioning of the inferior alveolar nerve

## Review and two case reports

Author\_ Dr Burghard Peter, Austria

### \_Abstract

In cases of moderate to severe atrophy in edentulous posterior areas of the lower jaw, diminished bone height between the alveolar crest and the mandibular canal may preclude placement of even the shortest implants. Repositioning of the inferior alveolar nerve has proven to be an excellent alternative to augmentation procedures. Especially in conjunction with piezosurgery the lateral nerve transposition provides a viable, reliable and relatively secure surgical procedure.

### \_Introduction

The first account about inferior alveolar nerve repositioning was published in 1977 by Alling<sup>1</sup> in the context of prosthetic rehabilitation of patients with severe atrophy and emergence of the mental nerve close to the alveolar crest. In 1987, Jensen and Nock<sup>2</sup> described the first inferior alveolar nerve transposition in conjunction with dental implant surgery.

Up to now, the nerve transposition technique has developed to an excellent alternative to aug-

mentation procedures for placement of dental implants in the lateral tooth area of the lower jaw.

The lateralisation of the inferior alveolar nerve offers the following main advantages:

- \_ Implants of greater length can be inserted simultaneously.
- \_ No bone grafting is needed.

However, nerve repositioning is a complex procedure, with a high risk of sensory disturbances.<sup>3</sup>

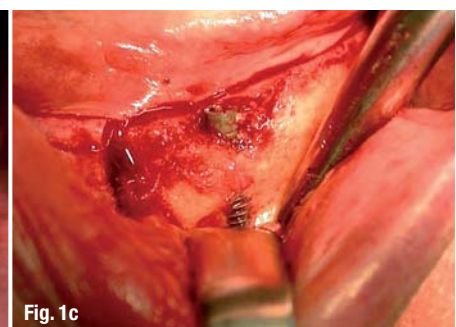
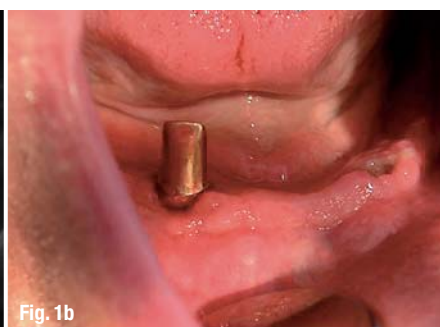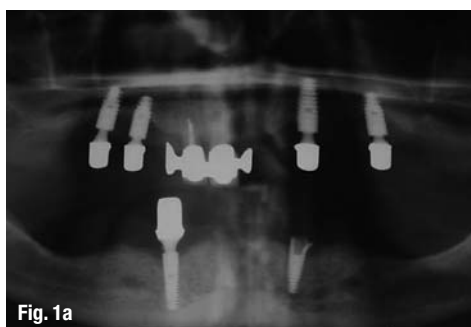
Since the introduction of an ultrasonic instrumentation for bone cutting in 1975 by Horton *et al.*<sup>4</sup> ultrasound-based piezoelectric devices have been applied increasingly often in head and neck reconstructive surgery, oncological cranio-maxillo-facial surgery, dysgnathic surgery, dental surgery and even in hand surgery.<sup>5,6</sup>

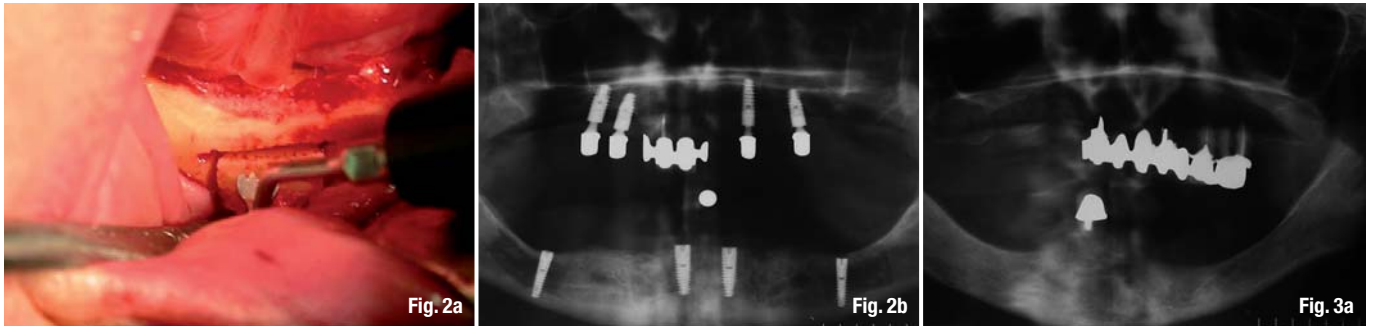
Subsequent to a publication of Vercellotti<sup>7</sup> in the year 2000 about piezoelectric oral surgery this method more and more has been used in dental implantology. The also as piezosurgery known technique is used in oral surgery to section hard tissues without damaging adjacent soft tissues.

Fig. 1a\_Radiographic initial situation, first case.

Fig. 1b\_Clinical initial situation, first case.

Fig. 1c\_Intraoperative situation before explantation of implant 44, first case.





In this connection an *in vitro* comparison of Metzger *et al.*<sup>8</sup> verified that the degree of nerve injury after piezosurgical inferior alveolar nerve transposition is lower than after usage of conventional rotary burs.

### Piezosurgery technique

Piezosurgery employs a specific instrument which transfers a significantly elevated level of ultrasound energy upon the bone surfaces. Thus this device is allowing osteotomy to be carried out even when the bone is highly mineralized and thick.<sup>4</sup>

The ultrasonic technique is characterized by a functional frequency of 25–29 kHz and the possibility of 30 Hz digital modulation. The system comprises a series of inserts of different forms with a linear vibration ranging from 60 to 200  $\mu\text{m}$ .<sup>6</sup>

In order to prevent an excessive increase in temperature the system is connected with a peristaltic pump for irrigating physiological solution.

### Surgical Procedure

The repositioning of the inferior alveolar nerve may be accomplished with general anaesthetic or intravenous sedation, but also in local anaesthesia alone. Independent of the used instrumentation we distinguish basically two surgical techniques as described below.<sup>9,10</sup>

**Lateralisation or anterior approach:** An osteotomy is performed around the mental foramen continuing with posterior bone removal until the nerve can be retracted past the last implant site.

**Fenestration or posterior approach:** The mental nerve and foramen are identified as before, but a cortical window is performed posterior the mental foramen at the planned fixture site. In conventional transposition procedures fine chisels are used for nerve exposition and mobilisation. Special piezosurgical inserts instead facilitate comparatively gentle access and visualisation of the nerve.

After carefully freeing, the nerve is separated using elastic vessel loops for applying gentle traction outwards as the implants are positioned.

The following two case reports explain a seldom (case 1) and a typical indication (case 2) for inferior alveolar nerve repositioning in the context of implant surgery.

### Case 1

In 2007, a 68-year-old male patient in good general health was referred by his dentist for explantation of two implants regio 34, 44. Overload induced, each implant- and abutment-screw-fractures and additional periimplantitis regio 44 had caused failure of the implants and the two years old crown- and sleeve-coping denture (Figs. 1a, 1b & 1c). Simultaneously and at most with a minimum of bone augmentation four implants ought to be inserted. As soon as possible, the patient wanted to be treated with an implant-supported fixed bridge-work. Four implants should be placed regio 32, 42 and in combination with an inferior alveolar nerve transposition regio 36, 46. Subsequent to a detailed consultation, study casts and a CT scan the patient was treated in local anaesthesia. After the extraction of the implants 34, 44 again two implants were installed interforaminal, regio 32, 42. Additionally, regio 36 and 46 implants were placed each in combination with a piezosurgery-assisted inferior alveolar nerve transposition (Figs. 2a & 2b). In the upper jaw already four Ankylos® plus implants (DENTSPLY Friadent, Germany) had been fixed for a tooth and implant supported removable denture. Accordingly Ankylos® plus implants also were used in this procedure. In combination with an uneventful healing process regular nerve function was assessed already two weeks post-surgery.

### Case 2

In 2008, a 69-year-old female patient in slightly reduced general health was referred by her dentist. In the upper and lower jaw all remaining teeth had to be extracted and each six implants ought to be

**Fig. 2a** Posterior piezosurgical approach regio 46, first case.

**Fig. 2b** Postoperative panoramic X-ray, first case.

**Fig. 3a** Radiographic initial situation, second case.

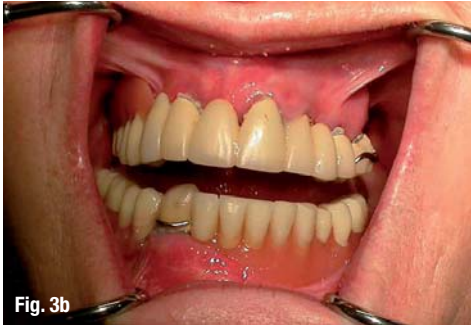

Fig. 3b

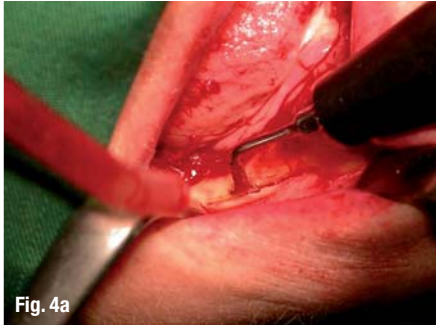


Fig. 4a

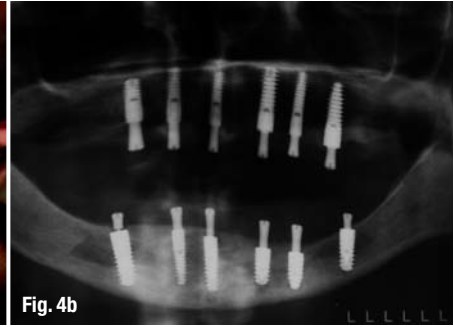


Fig. 4b

Fig. 3b\_Clinical initial situation, second case.

Fig. 4a\_Posterior piezosurgical approach regio 46, second case.

Fig. 4b\_Postoperative panoramic X-ray, second case.

fixed minimal-invasive with preferably less bone augmentation effort. In as short a timeframe as possible the osseointegrated implants should be ready for screwed implant-supported bridges in both jaws. After an extensive consultation, study casts and a CT scan the patient was treated in local anaesthesia as follows: In the mandible tooth 43 was extracted, four implants were inserted interforaminal and regio 36, 46 each one implant was placed post piezosurgical transposition of the inferior alveolar nerve. In the maxilla the teeth 12, 21, 23, 25, 26 were extracted and again six implants were anchored (Figs. 3a, 3b, 4a & 4b). Each Ankylos® plus implants (DENTSPLY Friadent, Germany) were used. Comparison of the postoperative (Fig. 4b) and the postprosthetic (Fig. 5) panoramic X-ray, 5 months later, impressively clarify the fast bony regeneration in both fenestration locations. An about eight months lasting, less than 1 cm mean diameter measuring area of minor hypaesthesia on the left chin side, did not impair patient satisfaction with the final reconstruction outcome.

### Discussion

Severe resorption of the posterior mandible poses one of the most difficult restorative challenges in dental implantology. Bone augmentation procedures (e.g. bone grafting or alveolar distraction) may increase the amount of bone in deficient areas. But these treatment options are costly, time-consuming and involve an elevated risk of inconveniences and complications.

Nerve repositioning has proved as an excellent alternative to augmentation procedures for placement of dental implants. The technique permits

implant therapy in atrophied lower jaws with insufficient vertical height superior to the mandibular canal. Integration of fixed bridges instead of removable appliances is enabled with just one surgical session even in instances, where—as described in the first case—only 2 implants can be installed interforaminal.

Safety and precision of the relocation of the inferior alveolar nerve have been further improved by the use of a new approach, the ultrasonic osteotomy. Piezoelectric surgery maintains blood-free sites and allows to perform precise linear and curvilinear osteotomies without the risk of cutting soft tissues.

Bone drills and oscillating saws represent more aggressive cutting instruments which are relatively difficult to control (e.g. due to the generation of macrovibrations) and which are more damaging to soft tissues.

Compared with these traditional cutting instruments the main disadvantage of piezosurgery concerns the increase in the operating time.

Independent of the osteotomy technique, nerve damage can be the result of an overstretched mucoperiosteal flap in the premolar area to achieve optimal view in the operating field. Especially with piezosurgery overstretching of the mental nerve can be reduced by creating smaller bone fenestrations.

Touching the inferior alveolar nerve with piezoelectric inserts results at most in roughening of the epineurium without harming deeper structures,<sup>8</sup> as far as heat injuries are prevented by an appropriate handling of the ultrasonic device.

Referring to the author's experience it seems to be favourable to place particulated bone around the implants just to prevent a direct nerve-fixture-contact and in order to aid the subsequent osseointegration. Additionally, or at the very least alone, the bone window should be covered by a re-

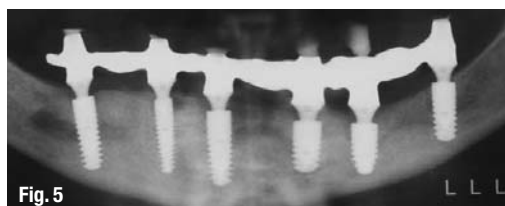


Fig. 5

Fig. 5\_Postprosthetic panoramic X-ray, second case.



# laser

international magazine of laser dentistry

sorbable membrane. Sensory changes after nerve repositioning seem to be less distinct after piezosurgery compared to conventional drill and oscillating devices. Nevertheless, at the first postoperative visit, a clinical assessment of the nerve function is mandatory.

Considering ethical and forensic implications, patients should be explicitly informed preoperatively that nerve injury might be expected to occur. In combination with implant placement, also the potential for mandibular fracture must be discussed with the patient.

The majority of our patients choose this treatment not in general anaesthetic or in intravenous sedation but just in local anaesthesia, which has proved to be reliably employable. In comparison to the application of conventional instruments patients detect the usage of piezoelectric devices usually less invasive. Accordingly, piezosurgery is well tolerated by the patients. Even in rare cases with persistent neurosensory deficits the patients were satisfied with the overall procedure.

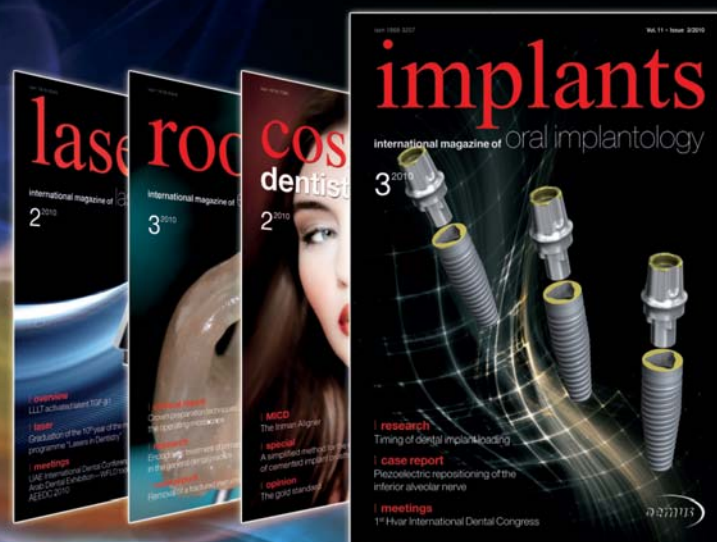Summarizing can be inferred, that especially in complex situations with compromised bone bed, the inferior alveolar nerve transposition should be taken into account as a viable treatment modality for the attainment of individually optimized implant-supported reconstructions.

## References

1. Alling CC. Lateral repositioning of inferior alveolar neurovascular bundle. J Oral Surg 1977; 35: 419.
2. Jensen O, Nock D. Inferior alveolar nerve repositioning in conjunction with placement of osseointegrated implants: a case report. Oral Surg Oral Med Oral Pathol 1987; 63: 263–268.
3. Nocini PF, De Santis D, Fracasso E, Zanetta G. Clinical and electrophysiological assessment of inferior alveolar nerve function after lateral nerve transposition. Clin Oral Implants Res 1999; 10: 120–130.

*Editorial note: The whole literature list can be requested from the author.*

_contact	implants
<p><b>Dr Burghard Peter</b>            Berchtesgadner Str. 11            5020 Salzburg, Austria            Tel.: +43 662 830808            Fax: +43 662 830808-11            E-mail: info@miramed.at            Website: www.miramed.at</p>	



## One issue free of charge!



**Subscribe now!**

You can also subscribe via  
[www.oemus.com/abo](http://www.oemus.com/abo)

- I hereby agree to receive a free trial subscription of **laser international magazine of laser dentistry** (4 issues per year). I would like to subscribe to cosmetic dentistry for € 44 including shipping and VAT for German customers, € 46 including shipping and VAT for customers outside Germany, unless a written cancellation is sent within 14 days of the receipt of the trial subscription. The subscription will be renewed automatically every year until a written cancellation is sent to OEMUS MEDIA AG, Holbeinstr. 29, 04229 Leipzig, Germany, six weeks prior to the renewal date.

▶ Reply per Fax +49 341 48474-290 to OEMUS MEDIA AG or per E-mail to [grasse@oemus-media.de](mailto:grasse@oemus-media.de)

Last Name, First Name

Company

Street

ZIP/City/Country

E-mail

Signature

Notice of revocation: I am able to revoke the subscription within 14 days after my order by sending a written cancellation to OEMUS MEDIA AG, Holbeinstr. 29, 04229 Leipzig, Germany.

Signature

# Success without using cement

## Prosthetic restoration of an edentulous mandible

Author\_Dr Christoph Thiemann, Friedrich Schotsch, Germany

**Fig. 1** \_Drilling template with titanium tube and lateral biteplates.

**Fig. 2** \_OPG control of the position of the implants before exposure.

**Fig. 3** \_Individual impression taking by means of bite registration.

**Fig. 4** \_Fixed impression post in the individual impression by means of bite registration.

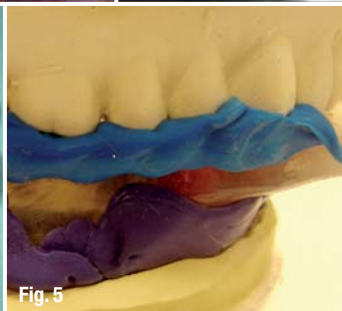
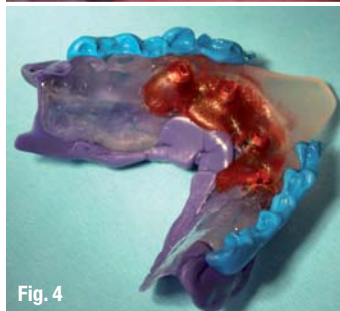
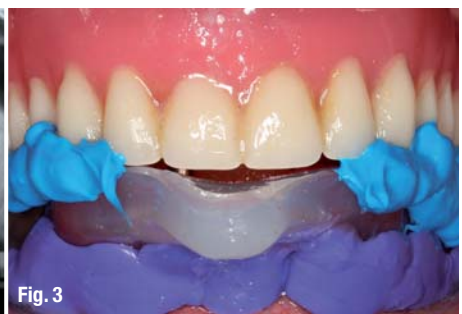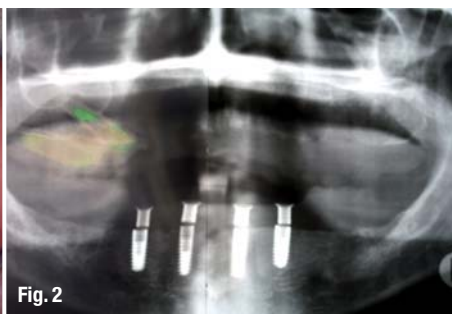
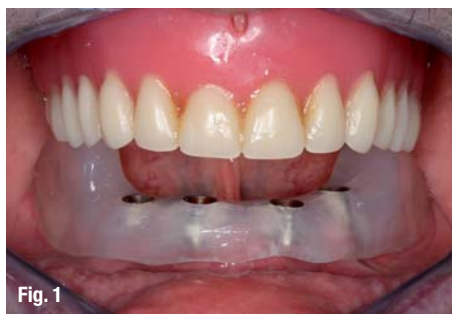**Fig. 5** \_Implant master cast with a gum mask and skull-related mounting of the models.

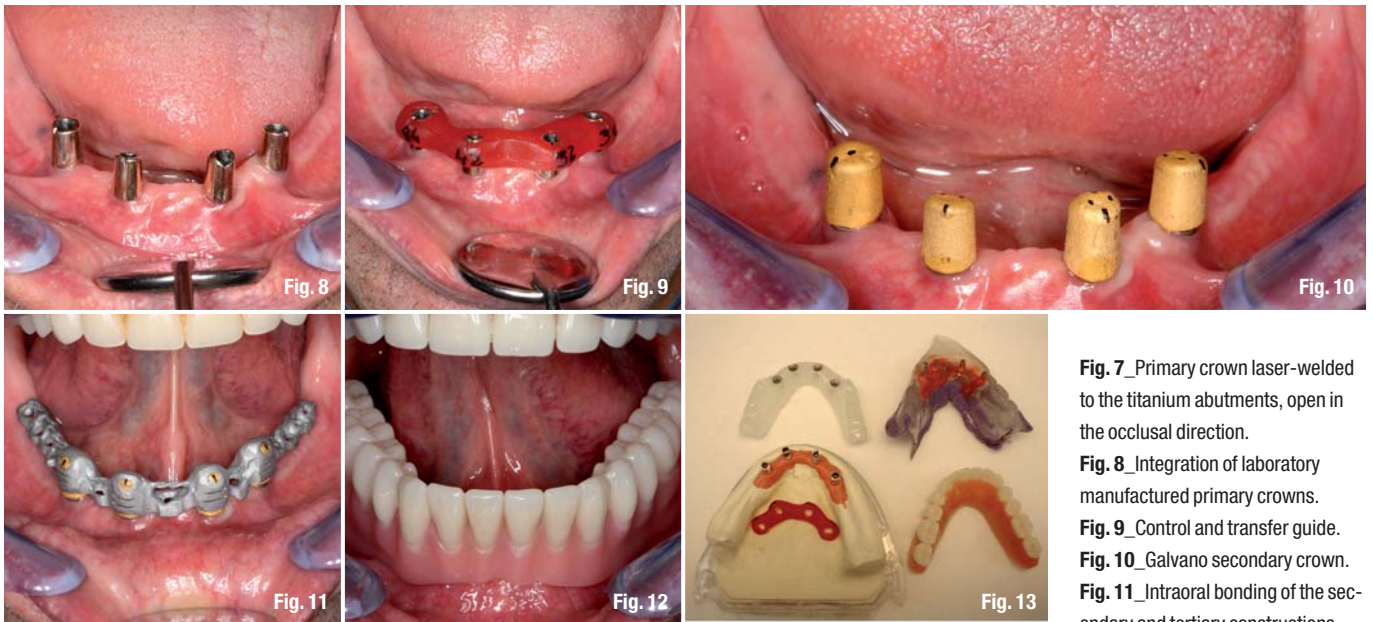
**Fig. 6** \_Four titanium abutments, one 15° angulated abutment.

\_The laboratory manufacturing of single-part laser corrected and implant-supported telescopic abutments—not a very difficult task to undertake. In the following we would like to explain the advantages of this cement-free method, as well as the related method for bite registration-supported individual implant dental impression.

A 50-year-old male patient with pronounced cardiovascular disease and instable complete mandibular denture was referred to us for prosthetic rehabilitation. After being informed of the different options for restoration, the patient chose a telescopic restoration on four interforaminal placed implants. Using the backward planning method and with the aid of the existing complete mandibular denture, we carried out the fixation of the bite, and took a functional impres-

sion by using a low viscosity A-silicon type material (e.g. Panasil Contact Plus, Fa. Kettenbach, Germany). On this basis, we manufactured a wax-up of a complete mandibular denture and a corresponding silicon matrix. Implant planning was transferred to the mounted complete mandibular denture model, and a template with a titanium drill guide and lateral biteplate made of light-curing resin (e.g. Primotec) was manufactured (Fig. 1). After this, the implant was inserted. Following anesthesia, a crestal cut was made from region 35 to 32 and 45 to 42. One mucoperiosteal flap for both sides of the mental nerve and the surgical site were prepared. The pilot hole preparations were made by using a drilling template. The angulation of the implants was controlled by means of parallel indicators. Thereafter, in order to achieve good osseointegration, at least three months' lasting healing time is





**Fig. 7\_** Primary crown laser-welded to the titanium abutments, open in the occlusal direction.  
**Fig. 8\_** Integration of laboratory manufactured primary crowns.  
**Fig. 9\_** Control and transfer guide.  
**Fig. 10\_** Galvano secondary crown.  
**Fig. 11\_** Intraoral bonding of the secondary and tertiary constructions.  
**Fig. 12\_** Incorporation of the manufactured prosthesis.  
**Fig. 13\_** The road to success: from backward planning (above, left) to the finished prosthesis (below, right).

recommended, which is ensued by implant exposure and soft tissue conditioning (Fig. 2). The taking of impressions of four implants was carried out with an individually manufactured, bite registration-supported open impression tray made of light-curing resin, given that the position of each implant is fixed by the drilling template. The impression tray is additionally equipped with biteplates that correspond to the fixed bite opening in vertical dimension (Figs. 3 and 4). The impression taking was done by using a low viscosity A-silicon type material, which is advantageous due to the four impression posts (PITT-EASY, Sybron Implant Solutions, Germany) being connected without force or strain with self-hardening resin (GC, Pattern Resin), through the use of the individually manufactured impression tray. Additionally, this special implant impression taking technique enables a simultaneous fixation of the jaw relation, because the patient is brought into the right bite position at the time the impression materials are set using biteplates. This is followed by the manufacturing of an implant master cast with a gum mask and skull-related mounting of the models (Fig. 5). Four titanium abutments (three V.D.L. abutments Anatomic Line straight; one 15° angulated PITT-EASY abutment, Sybron Implant Solutions) (Fig. 6) were individualized according to the soft tissue profile. They were also used to determine the height of the titanium abutments of the previously manufactured silicon matrix of the complete mandibular denture. Parallel primary crowns made of resin (GC, Pattern Resin) were modeled, milled, embedded, and cast on the abutments, observing the direction of insertion. These primary crowns have an occlusally open design. They are fixed on the titanium implant abutments, and after that, welded with a laser (Fig. 7). The laser-welding of the primary crowns and the titanium abutments requires very low power, as both alloys are extremely suitable

for laser-welding. The individual implant primary crowns are milled in parallel (1° or 2°) according to the initial situation. Both the amount and the height of the implant primary crown are important with regard to the alloy used. The galvano secondary crowns were manufactured afterwards. The manufacturing of the implant primary crown was carried out according to electroplating requirements, i.e. the use of copper-free noble metal alloys (e.g. Stabilor NF IV, company Degu-Dent, Germany). The galvano caps are directly galvanized onto the implant primary crown (Solaris, Degu-Dent). This is followed by the manufacturing of the transfer guide and the rotation lock with buccal labeling. The resin transfer guide is also used for control, especially before bonding the tertiary construction and the galvano secondary crown in the oral cavity (Figs. 8-11). The finalising of the implant can be done after bonding (AGC Cem, Wieland, Germany) the galvano secondary crown with the tertiary construction in the oral cavity. After the dental prosthesis had been incorporated, the patient was still under individual preventive medical supervision. The restoration did not show any radiological or clinical abnormalities (Figs. 12 and 13).

### **\_Conclusion**

The advantage of individually manufactured noble metal primary crowns, which are laser-welded to titanium abutments, is that they do not require cement for fixation. This construction can easily be removed even after its intraoral integration, and it thus guarantees the option for further extension of the prosthesis. Combining this with a telescopic galvano-superstructure also offers ideal adhesion and avoids friction. Another crucial advantage of this laboratory-based method is the cost-saving compared to industrially manufactured ready-made systems.

<b>_contact</b>	<b>implants</b>
<p><b>Dr Christoph Thiemann</b>                  Frankfurter Straße 69                  59425 Unna, Germany</p> <p><b>Friedrich Schotsch</b>                  Dental-Technik-Unna GmbH                  MPG geprüftes implantologisches Fachlabor                  Frankfurter Straße 67                  59425 Unna, Germany</p>	



# Comparing various implant designs and surfaces

## A clinical study

Authors\_Dr Roy Leshem<sup>1</sup>, David Leshem<sup>2</sup>, Israel

### \_Abstract

A clinical study of various types of Hi-Tec Implants (Herzlia, Israel)—uncoated titanium thread implants & push-in cylinder implants, coated with either TPS or hydroxyapatite (HA) surfaces, used by a surgical team in various surgical procedures. The purpose of the study was to find whether the design or coating of implants has any effect on the success rate and integration of the implant in different procedures. The study did not indicate any statistical significance in the success rate of the different implants in the different types of procedures: simple implantology, sinus lift procedures, bone augmentation and immediate extraction sites.

comparison between HA and TPS coated cylinder implants have been documented.<sup>3</sup> Use of implants varies in different procedures, and comparisons between the success rate in different procedures including placing implants immediately in to fresh extraction sits is documented<sup>4,5,6</sup> as well as success rate in different locations.<sup>7</sup>

The objective of the study was to present the success rate of fixtures of different designs and surfaces used in complex implant procedures, implants placed in internal sinus lift procedures (Figs. 1a–b), implants placed in lateral sinus lift procedures (Figs. 2a–b) bone augmentations, implants placed including grafting of buccal defect (Figs. 3a–d), and implants placed simultaneously with teeth extractions (Figs. 4a–d), all performed by one team.

The retrospective study was conducted on patients treated at the Maxillary Facial Dept. of the Meir Hospital, Kfar Saba Israel, and comprised of 144 implants consequently placed over a period of 4 years in 44 patients with partial or complete eden-

**Fig. 1a**\_Alveolar bone height 1 mm to sinus, before extracting second premolar.

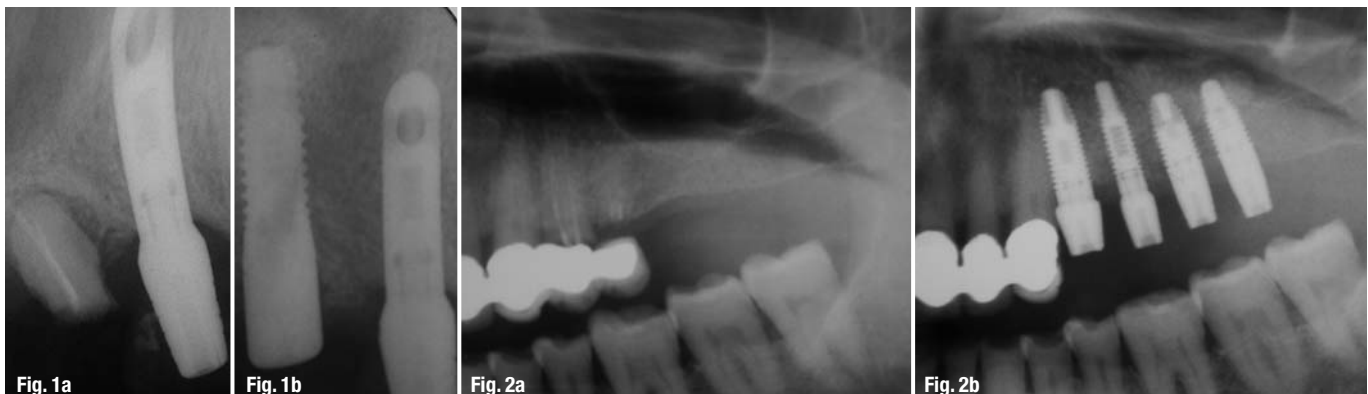**Fig. 1b**\_13 mm 4.2 thread implant placed with closed technique sinus augmentation.

**Fig. 2a**\_Alveolar bone height 3 mm to sinus.

**Fig. 2b**\_11.5 mm 5.0 thread implants placed with closed technique sinus augmentation.

### \_Introduction

Various implant designs and implant coatings are in wide use and success rates are of the various designs and surfaces are well documented Success rate comparison between HA coated and non coated threaded implants<sup>1,2</sup> as well as





# It's Time for a ReThink: High Quality at factory-direct Prices



**Spectra-System**  
Six application-specific implants  
All-in-One Package: €115



**Hexagon**



**Tri-Lobe**



**Octagon**



**Zimmer® Dental\***  
Legacy 1 Line  
Legacy 2 Line  
Legacy 3 Line  
Implant: from €100



**Nobel Biocare™\***  
RePlant Line  
RePlus Line  
ReActive Line  
All-in-One Package: from €115



**Straumann\***  
SX-Plant Line  
All-in-One Package: €145

All-in-One Package: includes implant, abutment, cover screw, healing collar, comfort cap and transfer

**In times of financial constraints –  
look for innovation with the best value!**

Implant Direct sets new standards with high-quality implants with low prices and value added All-in-One™ Packaging for only 115 Euro per implant, including the corresponding prosthetic components. Besides the unique Spectra System, we offer compatible implant systems to Nobel Biocare™, Straumann and Zimmer® Dental. Make a decision today and choose a path of smart solutions and considerably more profit.

\*Registered trademarks of Straumann, Zimmer® Dental and Nobel Biocare™



Tollfree Infoline: 00800 4030 4030  
[www.implantdirect.eu](http://www.implantdirect.eu)  
Europe's No. 1 Online Provider for Dental Implants



**Implant  
Direct™**

simply smarter.

Distribution of implants regarding sex and jaw			
Jaw	Female	Male	Total
Maxilla	44	36	80
Mandible	29	35	64
Total	73	71	144

**Tab. 1**

Distribution of implants regarding type of endulism & jaw				
Jaw	Complete edentulous	Multiple missing teeth	Single missing teeth	Total
Maxilla	20	55	5	80
Mandible	30	30	4	64
Total	50	85	9	144

**Tab. 2**

Distribution of implants by types of anesthesia			
Anesthetic	General	Local	Total
Maxilla	33	47	80
Mandible	10	54	64

**Tab. 3**

**Fig. 3a**\_Buccal defect connecting to the socket of first premolar with 2.0 mm remaining of buccal wall.

**Fig. 3b**\_Placing 4.2 mm Tapered Self Thread Implant.

**Fig. 3c**\_Complete closure after augmentation of buccal defect and socket.

**Fig. 3d**\_Final restoration with Zirconium Abutment.

tulous. Five implants failed (3.47%), two in the maxilla (2.81%) and three in the mandible (4.10%).

### \_Materials and Methods

The study consists of 144 consequently placed 3.50 mm hydroxyapatite-coated cylinder shape

implants (Smooth-Fit, Hi-Tec Implants, Herzlia, Israel).

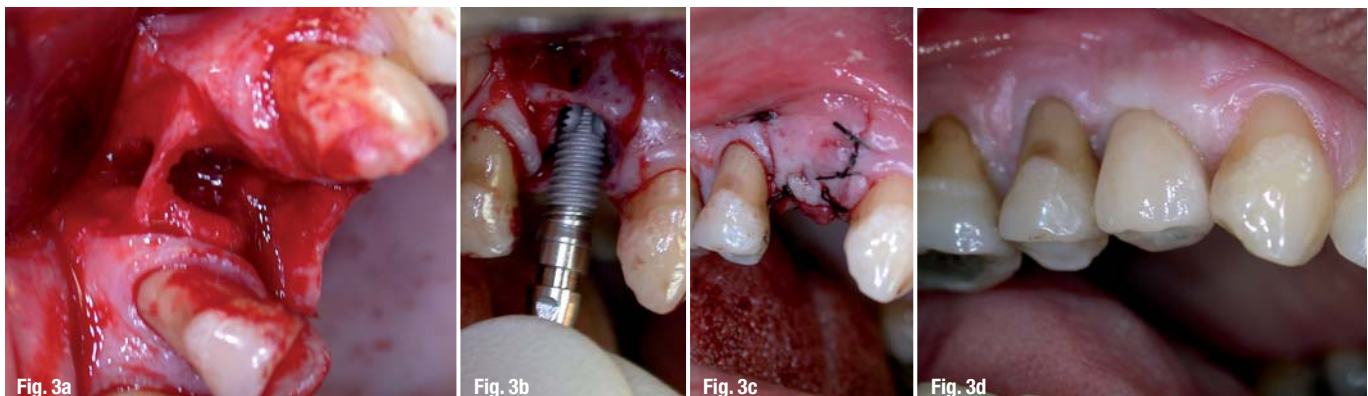
Titanium Plasma Spray Coated cylinder shape Implants (Smooth-Fit, Hi-Tec Implants, Herzlia, Israel). 3.75 and 5.00 uncoated Self-Tapping Thread Titanium Implants (Self Thread, Hi-Tec Implants, Herzlia, Israel). The coated fixtures were made of surgical titanium alloy, coated with 50 microns layer of hydroxyapatite or titanium plasma spray and have a 1 mm polished (uncoated) collar from the neck of the implant. The uncoated thread implants were made of surgical titanium alloy with acid etched surface. Various length implants were used.

The patient underwent routine medical, dental and radiographic assessment (including panoramic radiography) and was evaluated to determine whether the procedure was feasible and if positive, the treatment procedure was planned. Each patient was counseled concerning the nature of the treatment, and a comprehensive consent form was signed.

Surgical placement of the implants was based on the following procedure: The patient was placed under local or general anesthesia. Depending upon the site of the intended procedur, a mid-crestal, incision was made, and a flap was lifted exposing the under lying bone. An osteotomy was performed with internal irrigated drills using sterile physiological water. The implant was inserted into the prepared site and the flaps were closed by sutures. During this four year period surgeries were performed on 44 patients: 26 women and 18 men.

Stage II was performed under local anesthetic 3-6 months after Stage I.

This entailed opening a flap, exposing the cover screw and replacing it with a Titanium 3 mm or 5 mm Healing Cap (Hi-Tec Implants, Herzlia, Israel).



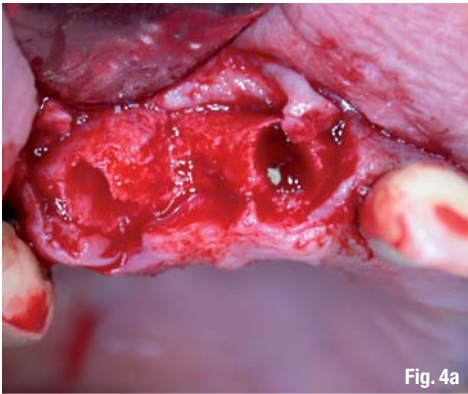


Fig. 4a

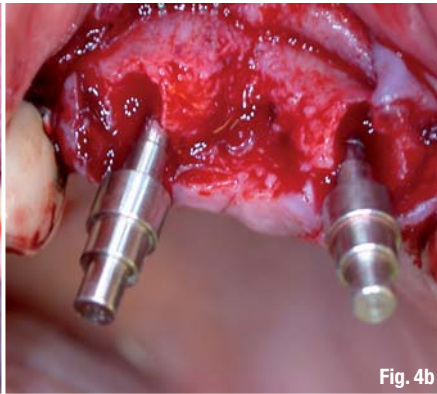


Fig. 4b

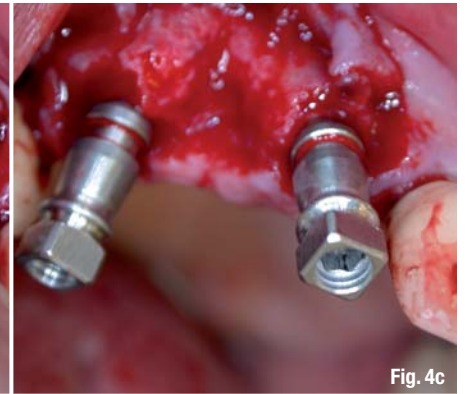


Fig. 4c

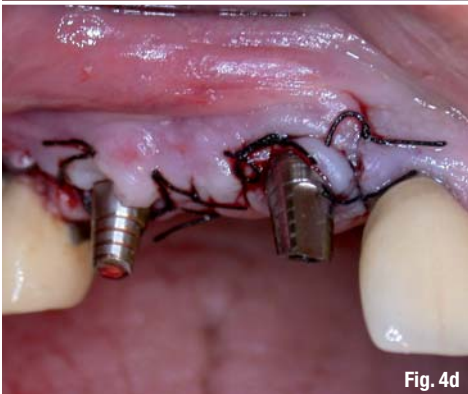


Fig. 4d

13 mm implant located in anterior maxilla was placed in a resorbed narrow ridge (2 mm). One 13 mm implant, placed in the anterior mandible, immediately after the extraction of a contaminated fractured tooth. No specific pattern regarding fixture size could be observed.

**Fig. 4a**\_Extraction of central incisor and canine.

**Fig. 4b**\_Paralleling tools in extraction sites.

**Fig. 4c**\_Two 3.75 mm Tapered Self Thread Implant placed in the fresh sockets.

**Fig. 4d**\_Abutments placed on implants for immediate provisional restoration.

All types of implants used in the sinus lift procedures presented a 100 % success rate. Four Implants were lost in immediate extraction sites, in resorbed bone sites, and poor bone quality, all lost implants were threaded non-coated implants, statistical significance was not substantiated. Using Pearson's Chi Square test a statistically significant association was found between the three types ( $p = 0.04$ )

## Results

There were no dropouts of patients during the follow-up stages. Prior to performing the prosthesis, the implant site was evaluated to determine osseointegration. Five implants 3.47% were recorded as failures during the follow-up period. Two of the failed implants, 2.81%, were in maxilla and three of the implants, 4.10%, in the mandible. Failed implants were present in five patients. The distribution of the failed implants regarding sex, jaw type, presented in the following table.

## Discussion

Two of the failing implants were identified and removed during Surgical Stage II and one was lost during preparation of temporary restoration. Two of the lost implants, posterior maxilla and posterior mandible, were 10 mm long. Three of the lost implants (anterior maxilla and anterior mandible, were 13 mm long.

The results of the study present 3.47% failure rate (five implants). This is a most favorable result taking into consideration that many of the implants were placed in most unfavorable sites including those with bone defects, unhealed bone extraction sites, sinus lift procedures, bone grafting sites, ridge augmentation and implants placed in extremely narrow ridges.<sup>4,5,6</sup> Implants lost were correlated to the posterior zone due to poorer bone quality,<sup>7</sup> narrow ridge and other unfavorable conditions. Posterior maxilla and mandible bone structure is less condensed and therefore the ability of firm osseointegration of the implant is reduced.

One of the failed implants (anterior maxilla) was placed in the site of bone augmentation and associated with a jaw splitting procedure during Stage I surgery, followed up by using a temporary full denture and commented in protocol at the time of implant placement.

### Failures were related to:

One 10 mm implant located in poor bone quality of posterior maxilla in an extraction site. One 10 mm implant located in posterior mandible. One

Distribution of implant length					
	8 mm	10 mm	13 mm	16 mm	Total
HA Smooth Fit	0	0	3	4	17
TPS Smooth Fit	0	12	33	18	63
Self Thread	0	22	42	0	64

Tab. 4

**Distribution of implant placement combined with bone grafting or sinus lift**

	Self Thread	TPS SmoothFit	HA Smooth	Fit Total
Bone graft	26	9	1	46
Sinus lift	6	22	7	35
Total	32	31	18	81

**Tab. 5**

**Distribution of implants placed in immediate extraction site**

	Self Thread	TPS Smooth Fit	HA Smooth Fit
	16	4	0

**Tab. 6**

**Distribution of failed implant with regard to jaw, sex & location**

Jaw Type	Female	Male	Posterior	Anterior
Maxilla	2	0	2	0
Mandible	2	1	1	2
Total	4	1	3	2

**Tab. 7**

**Distribution of lengths of failed implants**

	10 mm	12 mm	16 mm	Total
TPS Smooth Fit 3.5	0	0	0	0
HA Smooth Fit 3.5	0	0	0	0
Self Thread 3.75	1	3	0	4
Self Thread 5.00	1	0	0	1
Total	2	3	0	5

**Tab. 8**

Placing implants in poor quality bone in posterior areas and sites with complications increase the risk failure rate. It is even more crucial when the bone is not able to provide initial stability for implants or if the preparation has a fractured wall on one side or more. No considerable difference was noticed in the success rate when the implant placement was combined with bone grafting or bone grafting with sinus lifting.

Implant sites must therefore be evaluated prior to surgery and high risk sites should be bone grafted prior to inserting the implant in order to reduce the occurrence of early and late failures. Naturally should the necessity arise, the surgeon must be skilled in all the different procedures. One fixture that was considered successful during Stage II was found to be mobile during abutment connection. This raises the theory that in poor bone quality, opening and tightening of the healing screw can damage newly formed bone which will consequently resorb and lead to implant mobility.

The study did not find any statistical correlation between the success rates of different procedures to the types of implants used.

**\_References**

1. A comparison of hydroxyapatite (HA) – Coated threaded, HA – coated cylindric, and titanium threaded endosseous dental implants. Jeffcoat MK, et al. Int J Oral Maxillofac Implants. 2003 May-Jun;18(3):406–10.
2. A comparison of hydroxyapatite-coated Micro-Vent and pure titanium Swede-Vent implants. Evian CI. Int J Oral Maxillofac Implants. 1996 Sep-Oct;11(5):639–44.
3. A 5-year comparison of hydroxyapatite-coated titanium plasma-sprayed and titanium plasma-sprayed cylinder dental implants. Jones JD, et al. Oral Surg Oral Med Oral Pathol Oral Radiol Endod. 1999 Jun;87(6):649–52.
4. Immediate or early placement of implants following tooth extraction: review of biologic basis, clinical procedures, and outcomes. Chen ST, Wilson TG Jr, Hämmerle CH. Int J Oral Maxillofac Implants. 2004;19 Suppl:12–25.
5. Survival of immediately provisionalized dental implants placed immediately into fresh extraction sockets. Schwartz-Arad D, Laviv A, Levin L. J Periodontol. 2007 Feb;78(2):219–23.
6. Placement of hydroxyapatite-coated implants into fresh or recent extraction sites. Raymond AY. Dental Clinics of North America. 1992; Jan;36(1):97–115.
7. Implant zones of the jaws: implant location and related success rate. Tolstunov L. J Oral Implantol. 2007;33(4): 211–20.

**\_contact**

**implants**

**Dr Roy Leshem DMD**

1 Maskitstreet  
Herzlia, Israel  
E-mail: hitecimp@netvision.net.il

<sup>1</sup>Private practice, Herzlia, Israel

<sup>2</sup>Head of Pediatric & Craniofacial Plastic Surgery, The Tel Aviv Sourasky Medical Center, Israel.



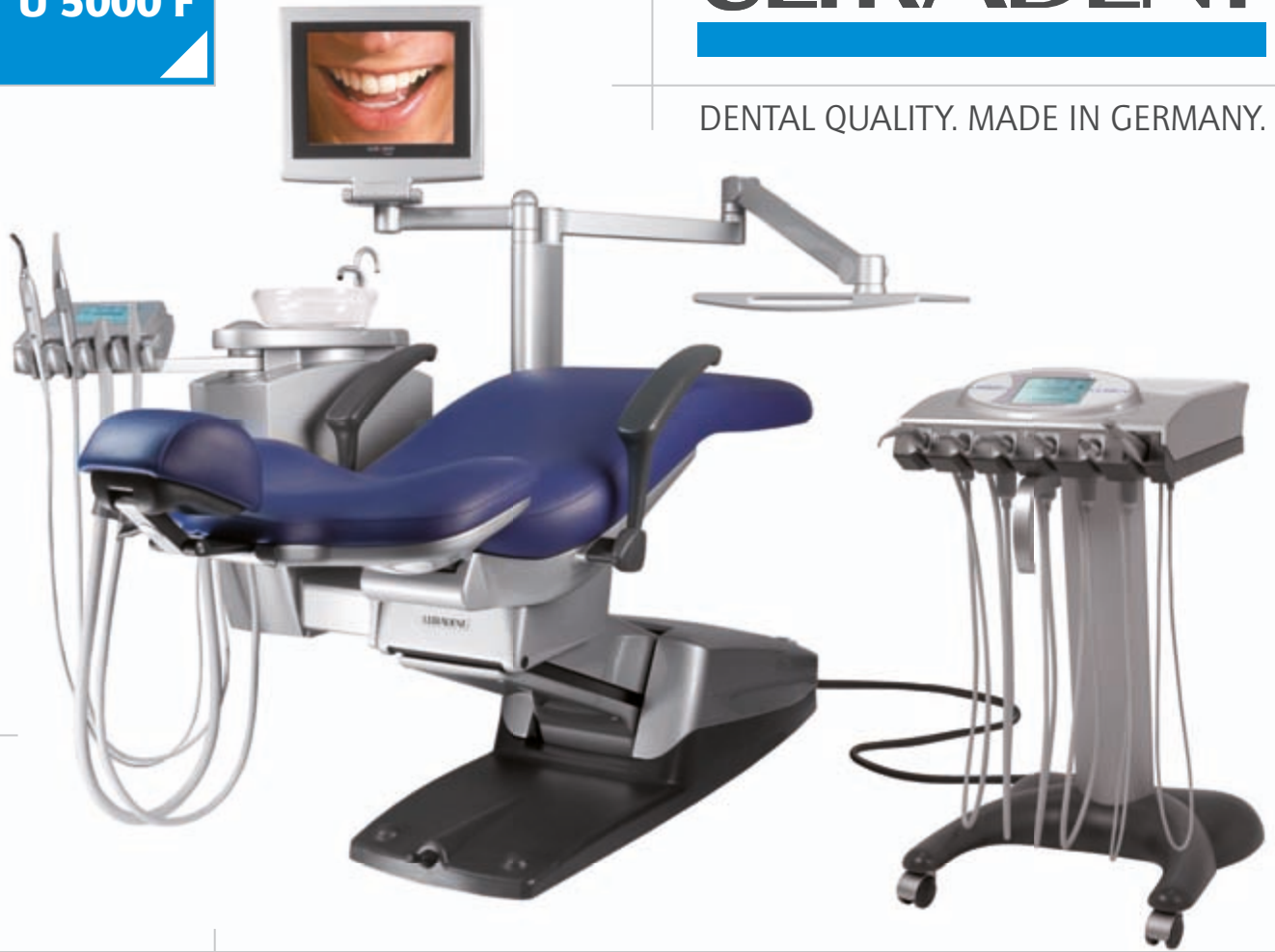
PREMIUM  
CLASS  
**U 5000 F**

# ULTRADENT

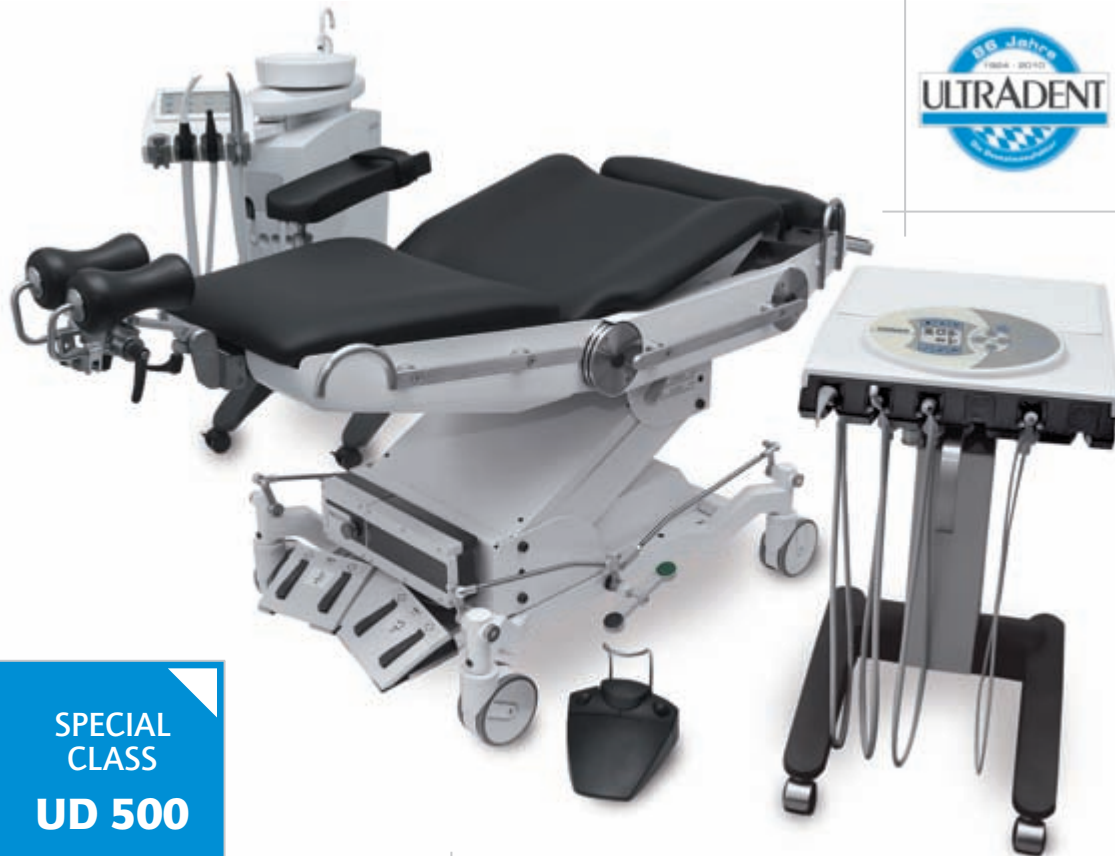DENTAL QUALITY. MADE IN GERMANY.



You  
deserve  
**PERFECTION.**



More  
safety.  
More  
comfort.



You  
deserve  
**INNOVATION.**

SPECIAL  
CLASS  
**UD 500**

New  
standards.  
New  
goals.

**ULTRADENT** Dental-Medizinische Geräte GmbH & Co. KG  
Germany - 85649 Brunnthal • Eugen-Sänger-Ring 10  
Fon: +49 89/420 992-70 • Fax: +49 89/420 992-50

[www.ultradent.de](http://www.ultradent.de)

# International events

## 2010

### 40<sup>th</sup> International Congress of DGZI

Where: Berlin, Germany  
Date: 01–02 October 2010  
Website: [www.dgzi.de](http://www.dgzi.de)

### 19<sup>th</sup> Annual Scientific Meeting of EAO

Where: Glasgow, Scotland  
Date: 06–09 October 2010  
Website: [www.eao.org](http://www.eao.org)

### AAID 59<sup>th</sup> Annual Meeting

Where: Boston, MA, USA  
Date: 20–23 October 2010  
Website: [www.aaid.com](http://www.aaid.com)

### ITI Education Week

Where: Toronto, Canada  
Date: 27–30 October  
Website: [www.iti.org/educationweek](http://www.iti.org/educationweek)

### 96<sup>th</sup> Annual Meeting of AAP

Where: Honolulu, USA  
Date: 30 October–2 November 2010  
Website: [www.perio.org](http://www.perio.org)

### 17<sup>th</sup> AIDC 2010

Where: Alexandria, Egypt  
Date: 2–5 November 2010  
Website: [www.aidc-egypt.org](http://www.aidc-egypt.org)

### 2<sup>nd</sup> Future Trends in Implantology

Where: Florence, Italy  
Date: 11–13 November 2010  
Website: [www.ftidental.com](http://www.ftidental.com)

### Annual Meeting of SGI

Where: Zurich, Switzerland  
Date: 12–13 November 2010  
Website: [www.sgi-ssio.ch](http://www.sgi-ssio.ch)

### ITI Education Week

Where: London, UK  
Date: 22–27 November 2010  
Website: [www.iti.org/educationweek](http://www.iti.org/educationweek)

### Greater New York Dental Meeting

Where: New York, NY, USA  
Date: 26 November–01 December 2010  
Website: [www.gnydm.org](http://www.gnydm.org)

## 2011

### 34<sup>th</sup> International Dental Show

Where: Cologne, Germany  
Date: 22–26 March 2011  
E-Mail: [ids@koelnmesse.de](mailto:ids@koelnmesse.de)  
Website: [www.ids-cologne.de](http://www.ids-cologne.de)

### International Osteology Symposium

Where: Cannes, France  
Date: 14–17 April 2011  
Website: [www.osteology-cannes.org](http://www.osteology-cannes.org)



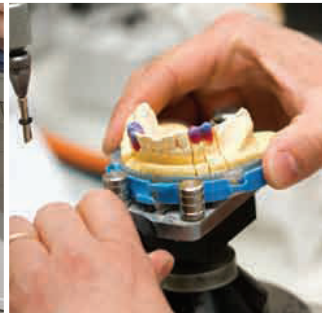
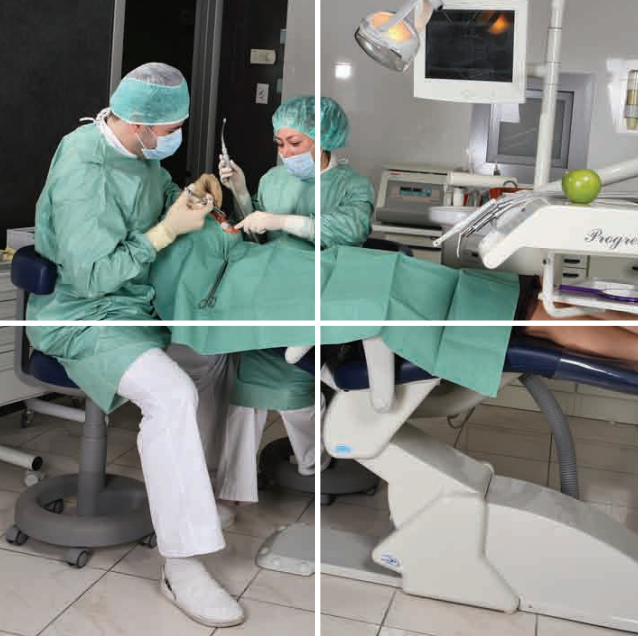

# DENTISTRY 2010



CME Accreditation

9 - 11 November 2010 • Abu Dhabi National Exhibition Centre, UAE



## The Definitive Dentistry Event in the Middle East

The conference will feature the most up-to-date information on the diagnosis and treatments available from international experts including:



**Renowned Dental Personality**  
 Prof Nasser Barghi,  
 Professor and Head of Division – Esthetic Dentistry,  
 University of Texas, San Antonio, USA



**Diplomate of the American Board of Oral Medicine**  
 Prof Juan Yepes,  
 Associate Professor and Director of Radiology,  
 University of Kentucky, USA



**Award Winner: Excellence in Dental Education**  
 Prof Patricia Reynolds,  
 Director of Flexible Learning – Dental Institute,  
 King's College, UK

Register your delegate place today  
[www.dentistryme.com](http://www.dentistryme.com)

Supported By



Organised By



Member Of



Media Partners



+971 4 336 7334

+971 4 336 4021

[dentistry@iirme.com](mailto:dentistry@iirme.com)

[www.dentistryme.com](http://www.dentistryme.com)

# 1<sup>st</sup> Hvar International Dental Congress



From 10<sup>th</sup> to 12<sup>th</sup> of June 2010, the HSK (Croatian Dental Chamber) in cooperation with Oral Dent company, supported by international associations like DGZI (Deutsche Gesellschaft für Zahnärztliche Implantologie e.V.), organized an extraordinary assembly of dental experts from all over the world on the island of Hvar, Croatia.

More than 40 lecturers from Europe, the United States of America and Middle East gave lectures on the island of Hvar. Well organized programs for dentists, dental technicians, many workshops, a Laser Symposium and a big international exhibition along with the educational program were provided. The whole event took place in the Grand Hotel Amfora, in the town of Hvar. It is important to mention that the Croatian Dental Chamber rated this congress with maximal 12 points. So the ranking of this congress was amongst the best events in Croatia in 2010. The organizers agreed that this dental highlight will be repeated in 2011. The date for the 2<sup>nd</sup> Hvar International Dental Congress will be published soon.

More information you will find on the website: [www.hvarkongres.hr](http://www.hvarkongres.hr)

International renowned lecturers participating the Hvar congress	
Dr David L Hoexter	USA
Dr Rainer Valentin	GER
Dr Thomas Schindler	AUT
Prof Dr Bilal Al-Nawas	GER
Dr Istvan Urban	HUN
Dr Suheil Michael Boutros	USA
Dr Francesco Mintrone	ITA
Dr Darko Slovsa	CRO
Prof Dr Claus Udo Fritzeimer	GER
Dr Mazen Tamimi	JOR
Dr Nadim Abou Jaoude	LBN
Prof Dr Nabil Jean Barakat	LBN
Doz Dr Jiri Holahovski	CZE
Dr Rolf Vollmer	GER
Dr Ulf Kruger Janson	GER
Dr Wolfgang Richter	AUT
Dr Luca Lorenzo Dalloca & MDT Roberto lafrate	ITA
Dr Stefano Ardu	CHE
Dr Dusko Gedosev	GER
Dr Gregory Brambilla	ITA
Prof Dr Ivica Anic	CRO
Prof Dr Ivana Miletic	CRO
MDT Harald Hoehr	AUT
Dr Vanja Coric	CRO
Dr Fay Goldstep	CAN
Dr Ross W. Nash	USA
Dr Elliot Mechanic	CAN
Dr George Freedman	CAN
Prof Dr Edward Lynch	GBR
Dr Orsolya Rigo	HUN
Prof Dr Hrvoje Juric	CRO
Prof Dr Bozidar Pavelic	CRO
Dr Zeljka Cabunac	SRB







ANNUAL DENTAL TRIBUNE STUDY CLUB


# SYMPOSIA AT THE GNYDM

NOVEMBER 28 – DECEMBER 1, 2010, 10:00 AM DAILY



For the third year in a row, the DTSC hosts its annual CE Symposia at the GNYDM, offering four days of focused lectures in various areas of dentistry. Find us on the Exhibition Floor in Aisle 6000, Room # 3.

Each day will feature a variety of presentations on topics, which will be led by experts in that field. Participants will earn ADA CERP CE credits for each lecture they attend. DTSC is the official online education partner of GNYDM.



**PLEASE SEE PROGRAM DETAILS UNDER [WWW.DTSTUDYCLUB.COM/GNYDM](http://WWW.DTSTUDYCLUB.COM/GNYDM)**

**REGISTER NOW: [WWW.GNYDM.COM](http://WWW.GNYDM.COM)**

**FREE FOR REGISTERED GNYDM ATTENDEES, BUT PRE-REGISTRATION IS RECOMMENDED.**

For more information, please contact Julia E. Wehkamp, C.E. Director, Dental Tribune Study Club  
Phone: (416) 907-9836, Fax: (212) 244-7185, E-mail: [j.wehkamp@DTStudyClub.com](mailto:j.wehkamp@DTStudyClub.com)

## SUNDAY, NOVEMBER 28

10:00 - 11:00 Howard Glazer, DDS, FAGD  
**BEAUTIFIL: GO WITH THE FLOW - COURSE: 3020**

11:20 - 12:20 John Flucke, DDS  
**LIGHT CURED ADHESIVE DENTISTRY - SCIENCE AND SUBSTANCE - COURSE: 3030**

1:20 - 2:20 Martin Goldstein, DMD  
**A SIMPLIFIED APPROACH TO MULTI-LAYER DIRECT COMPOSITE BONDING - COURSE: 3040**

2:40 - 3:40 Jay Reznick, DMD, MD  
**3D IMAGING AND CT-GUIDED DENTAL IMPLANT SURGERY - 3050**

4:00 - 5:00 Louis Malcmacher, DDS, MAGD  
**TOTAL FACIAL ESTHETICS FOR EVERY DENTAL PRACTICE - COURSE: 3060**

## MONDAY, NOVEMBER 29

10:00 - 11:00 Mrs. Noel Brandon-Kelsch  
**ECO-FRIENDLY INFECTION CONTROL-UNDERSTANDING THE BALANCE - COURSE: 4120**

11:20 - 12:20 Gregori Kurtzman, DDS  
**INCORPORATING NEW ADVANCES IN DENTAL MATERIALS AND TECHNIQUES INTO YOUR RESTORATIVE PRACTICE - COURSE: 4130**

1:20 - 2:20 Various Speakers  
**OPTIMIZING YOUR PRACTICE WITH 3D CONE-BEAM TECHNOLOGY - COURSE: 4140**

2:40 - 3:40 Daniel McEowen, DDS  
**HIGH RESOLUTION CONE BEAM WITH PREXION 3D - COURSE: 4150**

4:00 - 5:00 Maria Ryan, DDS, PhD  
**DETECTING CORONARY HEART DISEASE THROUGH PERIODONTITIS AND PERIIMPLANTITIS - COURSE: 4160**

## TUESDAY, NOVEMBER 30

10:00 - 11:00 Fotinos Panagakos, DMD, PhD  
**DENTIN HYPERSENSITIVITY - NEW MANAGEMENT APPROACHES - COURSE: 5110**

11:20 - 12:20 Greg Diamond, DDS  
**LASERS IN PERIODONTAL THERAPY - COURSE: 5120**

1:20 - 2:20 Dov Almog, DMD  
**INTRODUCTION TO CONE BEAM CT (CBCT), ESPECIALLY AS IT PERTAINS TO PREVENTION OF FAILURES IN ORAL IMPLANTOLOGY - COURSE: 5130**

2:30 - 3:30 Maria Ryan, DDS, PhD  
**DETECTING CORONARY HEART THROUGH PERIODONTITIS AND PERIIMPLANTITIS - COURSE: 5140**

4:00 - 5:00 Dwayne Karateew, DDS  
**CONTEMPORARY CONCEPTS IN TOOTH RELACEMENT: PARADIGM SHIFT - COURSE: 5150**

## WEDNESDAY, DECEMBER 1

10:00 - 11:00 Mr. Al Dube  
**BEST MANAGEMENT PRACTICE, WASTE MANAGEMENT FOR THE DENTAL OFFICE, AND OSHA COMPLIANCE - COURSE: 6060**

11:20 - 12:20 Glenn van As, DMD  
**HARD AND SOFT TISSUE LASERS - COURSE: 6070**

12:45 - 4:45 Drs. David Hoexter, Jeffrey Hoos, Dwayne Karateew, Enrique Merino, Kenneth Serota, Marius Steigmann  
**REVOLUTIONARY IMPLANT DESIGN UNVEILED: A COLLECTION FROM THE MASTERS - COURSE: 6080**

# EAO Congress— Glasgow 2010

## First EAO certificates to be awarded



The European Association for Osseointegration (EAO) will award its first Certificates in Implant-based Therapy at the EAO annual Congress which will be held this year in Glasgow from 6–9 October. As the only Europe-wide standardised assessment of implant-based therapy, the certificate will provide a benchmark for assessing knowledge and skills. The first candidates to participate in the new certification scheme will undergo their final examinations in Glasgow just prior to the awards ceremony. They will be questioned about six case studies they have submitted and will be required to demonstrate knowledge of theoretical and clinical implant based therapy. This includes basic knowledge of anatomy, pathology, biomechanics, physiology, histology, applied dental materials, applied pharmacology, radiology and biostatistics.

Candidates who successfully complete the certification programme will be able to demonstrate to both patients and regulatory authorities that they are competent to perform straightforward implant treatments. The certification process is both rigorous and time-consuming so the EAO will only initially be able to certify a limited number of candidates each year. However, it is expected this will increase as more resources are made available.

Details of the 2011 certification programme will appear later this year on the EAO website: [www.eao.org](http://www.eao.org)

The 2010 EAO Congress takes place at the Scottish Exhibition and Conference Centre (SECC) which is Scotland's premier national conference and concert venue. More than 3,000 dentists, academics and specialists from around the world are expected to attend to discuss some of the most important issues and dilemmas they face in daily practice. A world-class faculty of more than 40 speakers and chairpersons will be participating. There will also be a wide range of other attractions including multiple parallel sessions, master classes, short oral communications, a poster presentation, EAO Research Prize Competitions in Clinical and Basic Research, and a series of pre-congress 'step-by-step' courses. A large trade exhibition runs throughout the conference and there will be further industry satellite symposia presented by the main sponsors.

„We have nearly 500 abstracts submitted for the Clinical and Research competitions making this one of the leading forums for implant dentistry in the world," said EAO Scientific Chairman, and EAO President Elect Dr Paul Stone. There will be simultaneous translation to French, German, Italian and Spanish.

Advance bookings for the trade exhibition already indicate that it is likely to be one of the biggest ever organised by the EAO.

More details and registration information [www.eao.org](http://www.eao.org)




تحت رعاية  
سمو الشيخ حمدان بن راشد آل مكتوم  
نائب حاكم دبي، وزير المالية  
رئيس هيئة الصحة بدبي



Under the patronage of  
**H. H. Sheikh Hamdan Bin Rashid Al Maktoum**  
Deputy Ruler of Dubai, Minister of Finance  
President of the Dubai Health Authority

مؤتمر الإمارات الدولي لطب الأسنان و معرض طب الأسنان العربي  
UAE International Dental Conference & Arab Dental Exhibition



Delivering Science & Technology

إيدك  
**AEDDC**<sup>®</sup>  
Dubai 2011

[www.aeddc.com](http://www.aeddc.com)



**Largest Dental Event**  
in the **Middle East & North Africa**

1 - 3 February, 2011

مركز دبي الدولي للمؤتمرات والمعارض  
Dubai International Convention & Exhibition Centre

Organised by



Strategic Partner



Supported by



For more information, call or visit our website

**INDEX**<sup>®</sup> Conferences & Exhibitions Organisation Est.

P.O. Box: 13636, Dubai - United Arab Emirates | Dubai Healthcare City, Ibn Sina Bldg. #27 Block B, Office 203  
Tel: +971 4 3624717 | Fax: +971 4 3624718 | E-mail: [index@emirates.net.ae](mailto:index@emirates.net.ae) | Website: [www.aeddc.ae](http://www.aeddc.ae)



# Osteology in Cannes

## Beauty, function and their challenges

Author\_Dr Birgit Wenz, Switzerland



### Osteology Foundation

**In Cannes, the city of the rich and beautiful people, aesthetics has always played a major role, especially at the international film festival. In April 2011, the next international Osteology Symposium will illuminate aesthetics from a different side and put the spotlight on regenerative therapies with their current possibilities and limits.**

In recent years, regenerative therapies in implantology and periodontology have changed markedly, from pure hard tissue augmentation to comprehensive management and augmentation of bone and soft tissue. Both tissues are essential for a stable, functional and aesthetic outcome. The scientific programme of Osteology in Cannes reflects this fact: besides recent results on bone regeneration and the handling of complications, an important focus will be

on new treatments and products for soft tissue augmentation.

From 14–16 April 2011, experienced researchers and well-known practitioners will discuss the latest research results and current treatment concepts. The preliminary congress on Thursday will be entirely practice-oriented: in workshops the participants will be able to discuss treatment methods and train in them practically. The main scientific programme on Friday and Saturday will show which therapies are today's state of the art and underpinned by clinical evidence, how risk factors are assessed and how complications are treated. Talks and presentations on new studies and with specific treatment tips, and also the clinical forum with a podium discussion of clinical cases, will provide answers to the questions: what are today's possibilities and limits for regenerative therapy and in what direction will they develop?

The international Osteology symposia have become established in the last few years as the most im-







portant series of congresses on the topic of regeneration. Osteology in Cannes will again combine high-quality science with specific clinic and dental practice demands, on one of Europe's most beautiful coastlines. And while "more illusion than reality" is presented at the famous Cannes Film Festival, Osteology will show how clinicians can today achieve not only "reality" in regeneration that will also be "long-stay".

Osteology in Cannes—the topics:

- \_ GBR in implant patients—a critical overview
- \_ Clinical evidence for improvement of the long-term prognosis of teeth through GTR
- \_ Regenerative treatment of peri-implantitis

- \_ Sinus floor augmentation
- \_ Treatment of complex cases
- \_ Soft tissue aesthetics around teeth and implants
- \_ New treatment methods in soft tissue augmentation.

\_contact

implants

**Osteology Foundation**

Landenbergstrasse 35  
6002 Lucerne, Switzerland  
E-mail: [info@osteology.org](mailto:info@osteology.org)  
Website: [www.osteology-cannes.org](http://www.osteology-cannes.org)

# 3<sup>rd</sup> International CAMLOG Congress

“From science to innovations and clinical advances”



**\_Steady, sustained growth** even in economically difficult times and on the leading edge of technology: Camlog and more than 1,200 guests of the congress directed by Prof Wilfried Wagner, University of Mainz, had more than a few reasons to celebrate. This also included that today, CAMLOG ranks among the world's five leading companies in the scientific documentation of treatment success.

The 3<sup>rd</sup> International CAMLOG Congress has set lasting standards by the quality of the contributions and a balanced proportion of practical relevance and scientific underpinning. Impressive presentations on the topics of digital implant dentistry, soft-tissue integration, prosthetics, 3-D planning and augmentation left nothing to be desired from a clinical perspective.

Other topics included the pros and cons of platform switching, aspects of the biological width,

conical vs. Tube-in-Tube™ connections, the impact of implant positioning on hard- and soft-tissue development, CAD/CAM solutions, screw fixation vs. cementation, abutment materials and more.

Right at the beginning of the congress, Prof Jürgen Becker, University of Düsseldorf, the newly elected president of the Camlog Foundation for four years, who took over from the now honorary president of the Foundation, Prof Rolf Ewers, University of Vienna, emphasized the great importance of the Camlog Foundation in the continued advancement of implant dentistry.

With 60 scientific publications in 2009 alone, Camlog has also been successful in becoming one of the leading “evidence-based” implant providers.

In the end, a particular highlight of the congress was the outstanding panel of experts with remarkable solutions complemented by constructive contributions from the audience.

But the CAMLOG Congress 2010 in Stuttgart had even more to offer than just professional tidbits. Already before the actual congress, many participants attended the pre-program with practical and theoretical workshops or a visit to the Porsche or Mercedes-Benz Museums. At the alternative tour of the newly expanded state-of-the-art CAMLOG production plant in Wimsheim, more inquisitive participants were counted than in the Porsche Museum in Stuttgart.

The CAMLOG “Night of the Stars” party was a unforgettable experience where the guests were all received on a red carpet like in Hollywood—in-





cluding screaming fans and a glittering sparkling wine reception. Encouraged by the rousing Tina Turner impressionist Dana Smith and an equally convincing Robbie Williams show, the international CAMLOG community celebrated into the next morning.

continuing training and education to promote progress in implant dentistry and related fields to serve the patient. As part of its scientific mission, the Camlog Foundation has assumed patronage of the International CAMLOG Congresses, which take place every two years.

In his closing words, CAMLOG's CEO Dr Michael Peetz described the 3<sup>rd</sup> International CAMLOG Congress in Stuttgart as an outstanding and well-used opportunity to maintain networks and to further develop the team concept.

And it is Dr. Peetz's firm conviction that the CAMLOG Group is well on its way to becoming an international leader in implant dentistry with its user-friendly, high-precision and thoroughly documented dental implant system.

The Camlog Foundation is a foundation established by scientists under Swiss law. It engages in targeted supporting of gifted young scientists, promotion of basic and applied research, and



AD

# cosmetic dentistry

\_ beauty & science

**One issue free of charge!**

**Subscribe now!**

I hereby agree to receive a free trial subscription of **cosmetic dentistry** (4 issues per year). I would like to subscribe to **cosmetic dentistry** for € 44 including shipping and VAT for German customers, € 46 including shipping and VAT for customers outside of Germany, unless a written cancellation is sent within 14 days of the receipt of the trial subscription. The subscription will be renewed automatically every year until a written cancellation is sent to OEMUS MEDIA AG, Holbeinstr. 29, 04229 Leipzig, Germany, six weeks prior to the renewal date.

**Reply** via Fax +49 341 48474-290 to OEMUS MEDIA AG or per E-mail to [grasse@oemus-media.de](mailto:grasse@oemus-media.de)

Last Name, First Name

Company

Street

ZIP/City/Country

E-mail  Signature

Notice of revocation: I am able to revoke the subscription within 14 days after my order by sending a written cancellation to OEMUS MEDIA AG, Holbeinstr. 29, 04229 Leipzig, Germany.

Signature

IM 3/10

OEMUS MEDIA AG Holbeinstr. 29, 04229 Leipzig, Germany  
Tel.: +49 341 48474-0, Fax: +49 341 48474-290, E-Mail: [grasse@oemus-media.de](mailto:grasse@oemus-media.de)

# Manufacturer news

## CAMLOG

### Prosthetic components for occlusally screw-retained restorations

With the introduction of the new Vario SR prosthetic components, users are now able to choose between cement-retained or screw-retained crown and bridge restorations on CAMLOG® implants. Vario SR abutments are available in straight and in 20° and 30° angled versions for implant diameters 3.8/4.3/5.0/6.0 mm.

#### All advantages and indications at a glance

- Occlusally screw-retained crown, bridge and bar constructions
- Broadening the area of use of the CAMLOG® Implant System to include screw-retained crowns and bridges
- Up to 30° angled Vario SR abutments make bridging large implant axes divergences in splinted structures possible
- Special Vario SR components for impression-taking and cast fabrication

- Impressions can be taken using Vario SR abutment shoulders or implant shoulders
- Standardized fabrication of the prosthetic restoration with prefabricated components
- Sterile packaged and color-coded Vario SR abutments
- Temporary restoration with Vario SR protective caps or Vario SR titanium copings possible
- Proven CAMLOG handling

- Precise, mechanically sturdy and rotationally stable connection due to the patented Tube-in-Tube™ implant/abutment connection.

#### Prefabricated Vario SR prosthetic components

Burn-out plastic copings can be used to fabricate crown, bridge and bar constructions. The titanium caps have a retention surface on the outside and are designed for temporary or final bridge restorations made of plastic. Titanium bar caps are available for laser-welded bar constructions. For bridge and bar constructions, the impression can be taken using Vario SR impression caps, open or closed tray, directly over the Vario SR abutment already in its final position in the implant. The retention screw of the impression cap, open tray, can be shortened by 3 mm extra-orally if space limitations are encountered. For crown restoration, the impression can be taken directly over the implant shoulder using CAMLOG® impression posts, open or closed tray.



#### CAMLOG Biotechnologies AG

Margarethenstrasse 38  
4053 Basel, Switzerland  
E-mail: info@camlog.com  
Website: www.camlog.com

## Candulor

### “Removable or Fixed”—KunstZahnWerk 2011

Candulor has again joined up with CAMLOG to arrange the thrilling upcoming KunstZahnWerk (art of prosthetics) competition at the IDS 2011 in Cologne. As always, the latest patient case will be another fresh challenge to participants too.

Modern, innovative, yet in line with a dental technician's daily routine—these are the requirements for the new KunstZahnWerk competition. International participants from all over Europe, the USA and Canada show their proficiency at each IDS. The latest challenge is to make a total reconstruction combined with a complete prosthesis supported by the mucous membrane and to fit a denture held by an implant. All work has to be done using the Gerber set-up technique and the teeth and implant parts supplied free of charge by Candulor and CAMLOG. Candulor will provide you with the full patient case. Detailed information will aid you in solving this task. You will of course also get the appropriate plaster models, prosthetic teeth (Candulor Composite NFC) and implant parts. The finished prostheses may only be submitted in the Candulor Articulator or Condylator. There are further prizes for those

participants providing additional documentation to their work and prizes for the best documentation. A jury made up of prosthetics specialists and practitioners will judge every individual project. Each of the winners will be awarded their prizes at the Candulor press conference at the IDS in Cologne on Friday, 25 March, 2011. All the finished projects will be shown on the Candulor stand at the IDS 2011 in Cologne. The documentation we receive will be published in various professional journals.

#### Prices

1<sup>st</sup> prize: Cheque for €1.500,-

2<sup>nd</sup> prize: Cheque for €1.000,-

3<sup>rd</sup> prize: Cheque for €500,-

Further prizes for the best documentation along with many material prizes!

Register for participation by no later than 29 October, 2010. You can get the registration form on the internet from www.candulor.com or by phone on +49 7731 79783-0.

#### Candulor Dental GmbH

Am Riedemgraben 6, 78239 Rielasingen-Worblingen, Germany  
E-Mail: info@candulor.de, Website: www.candulor.de





Nobel Biocare

### Versatility, easy of use, predictability, and pleasing esthetic results

Nobel Biocare stands for 40 years of experience in restorative dentistry as well as four decades of scientifically-documented and successful implant systems. One of the innovations of the company is NobelReplace™, the time-proven and most frequently inserted implant system throughout the world that stands for versatility, ease of use, and predictability.<sup>1</sup> NobelReplace is very well-suited for a comprehensive range of applications ranging from the rehabilitation of single teeth to the restoration in completely edentulous patients.

NobelReplace is an implant system with impressive benefits and is therefore considered to be the implant system of first choice both in surgery and for the options of prosthetic management. NobelReplace is a universally applicable, two-part implant system for successful use in one- or two-stage surgical procedures both in soft and dense bone.

NobelReplace offers experienced and advanced users alike a comprehensive implant system that supports the treatment in virtually all indications of implantology. The root-like shape, grooves and TiUnite surface favor optimal primary stability and thus allow the implant to be used even in challenging indications, such as between diverging roots of neighboring teeth, in front of the mesial wall of the maxillary sinus or for insertion right after extraction. Considering the large number of treatment options that are available to date, an implant system like NobelReplace is a major benefit for the user and provides a high degree of flexibility. The NobelReplace implant system is universally applicable and offers many options for surgical treatment and downstream prosthetic management.

<sup>1</sup>Source: Millennium Research Group 2008

#### Nobel Biocare AG

P.O. Box 8058 Zürich – Airport, Switzerland

E-mail: [info@nobelbiocare.com](mailto:info@nobelbiocare.com), Website: [www.nobelbiocare.com](http://www.nobelbiocare.com)

#### EMS

### Piezon Master Surgery with three new instrument systems



Since it was introduced, Piezon Master Surgery—based on Piezon technology—has had a remarkable track record in many practices. Today, EMS has expanded the clinical scope of application of the Piezon Master Surgery product range. With an enhanced product offering—and special instruments such as Sinus System and Implant System—practitioners have access to technologies allowing them to work even more efficiently.

With Piezon Master Surgery, additional application-specific instruments are now available: a total of four perio instruments especially designed for resective and regenerative periodontal surgery, five advanced surgical instruments

for gentle and uniform sinus lifts, as well as six special fully diamondcoated instruments for implant applications with dual cooling system and extraefficient debris evacuation.

These instruments are seen as particularly suitable for four clinical applications: implant site preparation following extraction, implant site preparation following splitting of the alveolar ridge, implant site preparation in the posterior tooth area, and implant site preparation in compromised areas, such as a narrow alveolar ridge. In principle, instruments can be used at low OP temperature of no more than 33 degrees centigrade. They provide drilling efficiency and precision in the maxillary area.

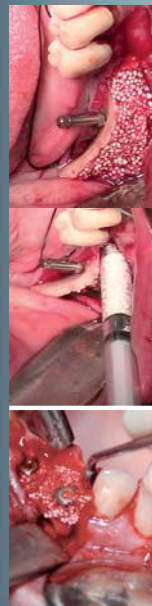#### EMS Electro Medical Systems S.A.

Chemin de la Vuarpillière 31, 1260 Nyon, Switzerland

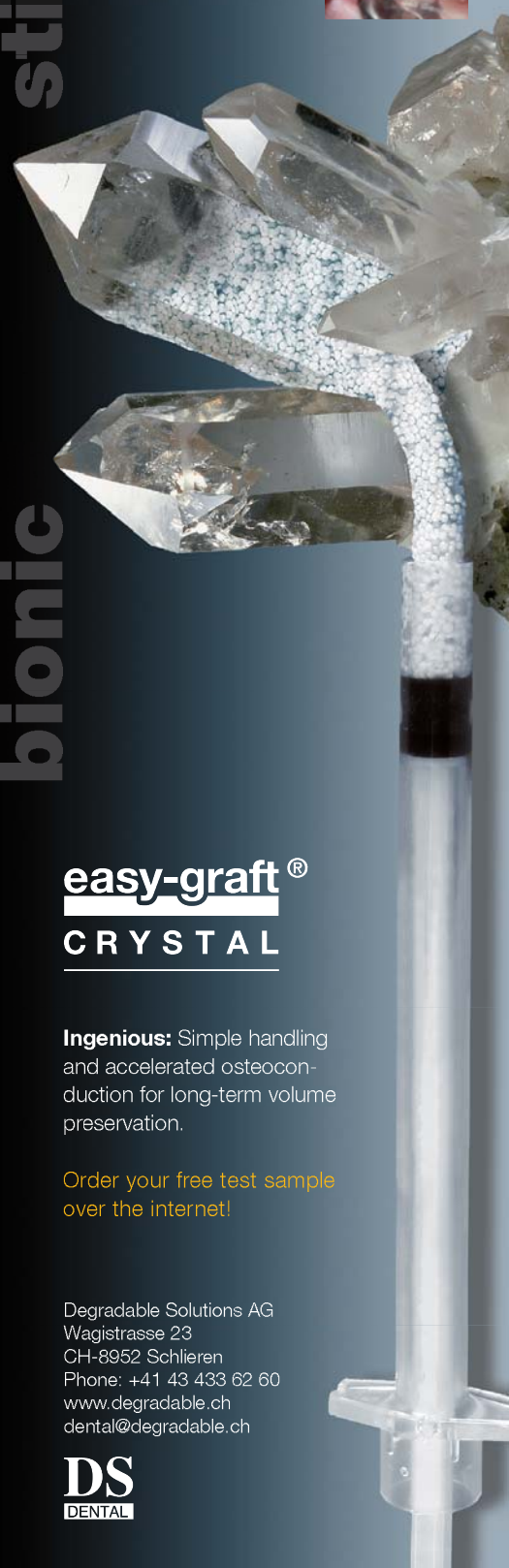E-mail: [welcome@ems-ch.com](mailto:welcome@ems-ch.com), Website: [www.ems-dent.com](http://www.ems-dent.com)



sticky granules  
bionic



AD  
easy-graft®CRYSTAL



### easy-graft® CRYSTAL

**Ingenious:** Simple handling and accelerated osteoconduction for long-term volume preservation.

Order your free test sample over the internet!

Degradable Solutions AG  
Wagistrasse 23  
CH-8952 Schlieren  
Phone: +41 43 433 62 60  
[www.degradable.ch](http://www.degradable.ch)  
[dental@degradable.ch](mailto:dental@degradable.ch)



ULTRADENT

**The future has begun at ULTRADENT**

A big celebration was held to mark the opening of ULTRADENT's new, modern company building at an event attended by the mayor, the media, the architects, prominent members of the dental profession and three generations of the Ostner family. Under the management of the current owner, Ludwig Ostner, ULTRADENT has, over the last 12 years, become one of the most familiar brands of modern treatment units in all areas of dentistry. The future of ULTRADENT also lies in the hands of the family, as Ludwig Johann Ostner, the son of the current head of the company, is joint managing director with his father and has already assumed responsibility for product development. Manufacturing many components in-house, the family enterprise develops and produces dental equipment that is characterized by excellent quality, superb reliability and practical design.



provide extensive logistical opportunities. Here an even larger exhibition area will be available, where our customers can experience the latest products put to practical use. Countless innovative product ideas, the company's own

patents and registered designs represent a competitive technological edge, exclusivity, maximum product reliability and long-term provision of spare parts.

Moreover, thanks to investments in development, the latest production technology and ongoing training for employees, ULTRADENT will be able to continue making its ideas and visions a reality in the future.

**Modern jobs in modern buildings**

Everything has been redesigned and reorganized, from the company's own paint shop, showroom and development department

right through to the warehouse and administrative area. This has created a light workplace fit for the future and the pleasure this gives the employees is clear to see. We can look forward to the new products from ULTRADENT.

**Good prospects. Dental quality made in Germany**

The success of the Munich-based dental specialist is proof that their concept is correct and the new head office at the Brunthal industrial park in Munich will

**ULTRADENT  
Dental-Medizinische Geräte GmbH & Co. KG**

Eugen-Sänger-Ring 10, 85649 Brunthal, Germany  
E-mail: info@ultradent.de, Website: www.ultradent.de

AD

**100% SAFETY DOCTOR - PATIENT GOAL REACHED**

Since our beginnings, we have always been focused on quality and innovation toward the battle against cross-contamination and infections.

In the last 20 years, we have ensured safety and protection to you and your patients, with advanced and reliable products. Tools that represent the ideal solution for who is operating in dentistry, implantology/oral surgery and general surgery.

With Omnia sure to be safe.

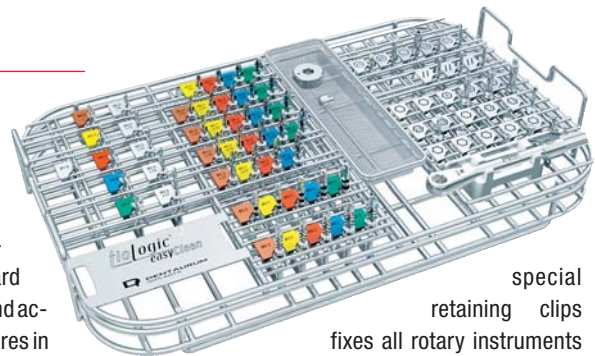
**OMNIA**  
Disposable Medical Devices

OMNIA S.p.A.  
Via F. Delnevo, 190 - 43036 Fidenza (PR) Italy  
Tel. +39 0524 527453 - Fax +39 0524 525230  
VAT. IT 01711860344 - R.E.A. PR 173685  
Company capital € 200.000,00  
www.omniaspa.eu

Dentaurum Implants

**Cleaning made easy**

Time-consuming work for staff, variable cleaning results and the associated expenses—that was standard practice for the preparation of drills and accessories after implantology procedures in the past. After every surgical procedure all instruments had to be manually cleaned one by one and then sorted into the right implant-surgery tray. Cleaning and disinfection of the completely filled implant-surgery tray was formerly not possible, because the instruments did not sufficiently come into contact with water and cleaning agents. Dentaurum Implants GmbH and Miele Professional have now worked together to develop an innovative system solution for efficient and reproducible machine preparation. The heart of this development is the tioLogic® easyClean surgery tray, which now enables consistent, outstanding machine cleaning and disinfection results in both dental practices and in centralized preparation centres in hospitals. This not only offers huge savings in time and costs but also significantly increased safety for users with the reproducible machine preparation results. The combination of the innovative grid structure with



special retaining clips fixes all rotary instruments and accessory components to hold them in position and to ensure that the instruments are completely cleaned with water and cleaning agent. All drills and accessory components can be replaced in the correct position in the implant procedure to remain in the correct order at all times throughout the operation. SMP GmbH of Tübingen, an independent institute specialising among other things in the testing and validation of medical devices, was commissioned to test and validate the cleaning results. The tests were an impressive confirmation of the preparation results of the instruments and accessory components in the tioLogic® easyClean.

**Dentaurum Implants GmbH**

Turnstr. 31, 75228 Ispringen, Germany  
E-mail: info@dentaurum-implants.de  
Website: www.dentaurum-implants.de





Susanne Breuer, Stephen Booth and Sandro De Gruttola represented Straumann at the Award Ceremony.

Straumann

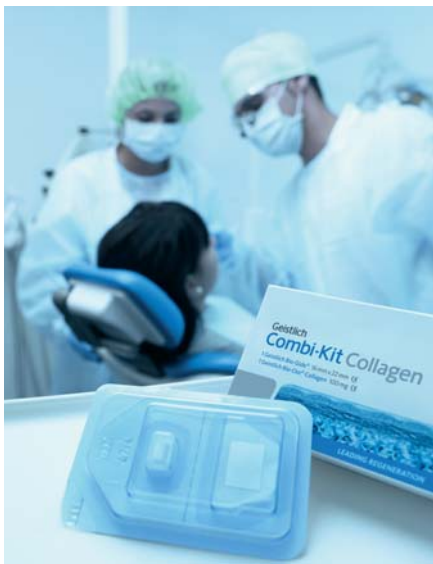**Medical Device Technology of the Year Award for Straumann's Roxolid**

Straumann, a global leader in regenerative, restorative and replacement dentistry, has been presented with the 2009 'Medical Device Technology of the Year Award' for Roxolid®, the company's innovative high performance material for dental implants.

The Award recognizes excellence in technological innovation and is one of the Best Practices Awards bestowed by Frost & Sullivan. Engineered and developed by Straumann, Roxolid is an alloy of titanium and zirconium which has been designed to increase reliability and confidence with small diameter implants. Roxolid can accommodate the sophisticated microstructuring processes required for Straumann's SLActive® surface technology, which enhances osseointegration. Roxolid has been undergoing a broad program of clinical trials in nine countries. Involving 60 centers and more than 300 patients, this is one of the largest clinical research programs ever undertaken by a dental implant company prior to market launch. Apart from the clinical program, Roxolid was made available to 450 selected specialists in a controlled release program, in which more than 11,000 implants were distributed.

**Institut Straumann AG**

Peter Merian-Weg 12, 4052 Basel, Switzerland  
E-Mail: info@straumann.com, Website: www.straumann.com



Geistlich Biomaterials

**The successful duo now also available as Combi-Kit Collagen**

The new Geistlich Combi-Kit Collagen combines two established and reliable products in a single package: Geistlich Bio-Oss® Collagen 100 mg and the native collagen membrane Geistlich Bio-Gide® in a new size of 16x22 mm. The Geistlich Combi-Kit Collagen® offers the perfect solution for Ridge Preservation, i.e. for the treatment of alveolar bone defects following tooth extraction, as well as for minor augmentations. Today the combined application of bone substitute materials and resorbable membranes to treat bone defects

has already become clinical routine and shows predictable and effective results (Aghaloo 2007; Sammartino 2009).

Scientific evidence and a wealth of practical experience reported have also shown that the insertion of Geistlich Bio-Oss® Collagen in an extraction socket may be the ideal way to preserve the alveolar dimensions (Ackermann 2009), and the inevitable loss of the bundle bone – and therefore of the buccal bone lamellae—following tooth extraction is compensated (Araujo 2008; Araujo 2009).

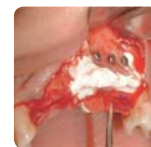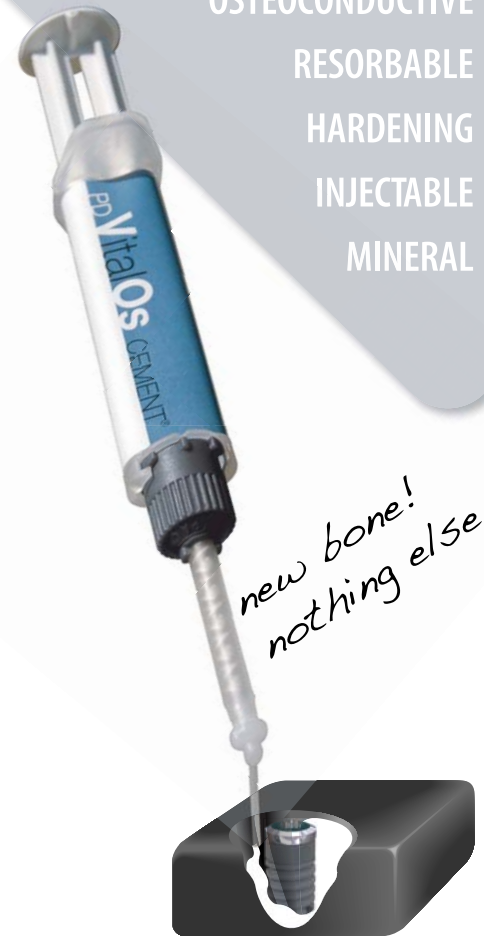**Geistlich Biomaterials**

Bahnhofstr. 40, 6110 Wolhusen, Switzerland  
E-mail: info@geistlich.ch, Website: www.geistlich.ch

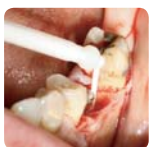The bone regeneration cement



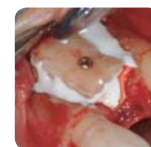- OSTEOCONDUCTIVE
- RESORBABLE
- HARDENING
- INJECTABLE
- MINERAL



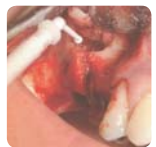bone splitting



peri-implant



onlay graft



sinus lift

*Clinical cases*  
[www.vitalos.com](http://www.vitalos.com)

Your distributor for Germany & Austria

Alexander Haid  
Tel. 0049 (0)700 69 69 90 90  
Fax: 0049 (0)700 69 00 90 90  
info@i-dent.org  
www.i-dent.org



intelligentes Dentalequipment

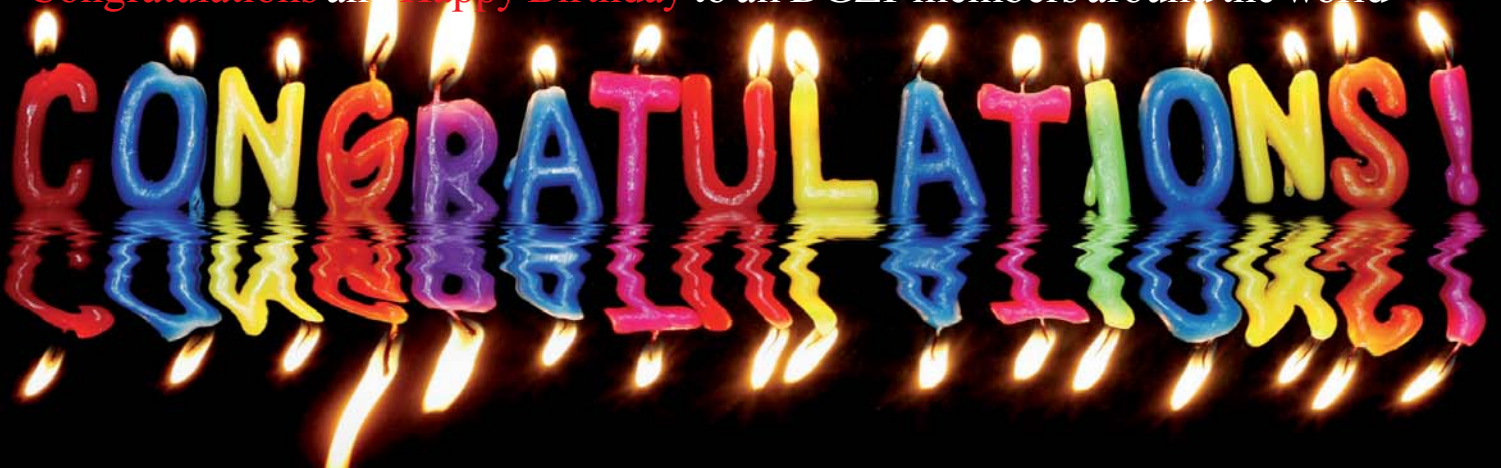Other countries:

[www.vitalos.com](http://www.vitalos.com)  
Produits Dentaires SA / Switzerland





**Congratulations and Happy Birthday** to all DGZI-members around the world



## JULY 2010

### 75<sup>th</sup> Birthday

ZA Tor Wahl (07.07.)

### 70<sup>th</sup> Birthday

Dr Dr Marius Rimbasiu (07.07.)

### 65<sup>th</sup> Birthday

Dr Horst Beck (06.07.)

ZÄ Renate Bauer-Küchle (08.07.)

### 60<sup>th</sup> Birthday

Dr Hans Florack (01.07.)

Dr Heinrich Meis (03.07.)

Dr Felix Schirner (04.07.)

Dr Eckhard Benninghoff (13.07.)

Dr Gerhard Martin Cube (14.07.)

Dr Dov Berger (17.07.)

ZA Jürgen Conrad (18.07.)

### 55<sup>th</sup> Birthday

Dr Alfred Plötz (03.07.)

Dr Hubert Stratz (11.07.)

Alabtah Zoher (25.07.)

Achim Kneuertz (26.07.)

ZT Stefan Reif (26.07.)

Dr Ralf August (29.07.)

### 50<sup>th</sup> Birthday

Dr Heike Gründler (01.07.)

Dr Wolfram Arndt (04.07.)

Dr Peter Pötschke (04.07.)

Dr Serge Bailly-Thuir (14.07.)

Dr Dr. Hans van der Elst (17.07.)

Dr Anton Öttl (25.07.)

Dr Gundula Flottmann (27.07.)

Dr Marton Yakubovich (28.07.)

### 45<sup>th</sup> Birthday

Dr Marwan Shahin (05.07.)

Dr Ralph Heel (14.07.)

Dr Michael Lenz (18.07.)

Dr Bernd Krebs (25.07.)

Dr Frank Seidel (30.07.)

### 40<sup>th</sup> Birthday

Dr Frederik Friese (07.07.)

## AUGUST 2010

### 70<sup>th</sup> Birthday

Dr Jürgen Oberbeckmann (12.08.)

### 65<sup>th</sup> Birthday

Dr Hans Konrad Hühnlein (01.08.)

Dr Bernd Ulrich (28.08.)

### 60<sup>th</sup> Birthday

Dr Volker Hellwich (13.08.)

Dr J.P. Flieller (14.08.)

Dr Klaus M. Linke (24.08.)

### 55<sup>th</sup> Birthday

Dr Adrian Wetz (01.08.)

Dr Sören Atrup Nielsen (23.08.)

Hans-Bodo Ronsheimer (23.08.)

Dr Salah Al-Tawil (30.08.)

### 50<sup>th</sup> Birthday

Dr Bassel Al Sibai (01.08.)

Jürgen Holzwarth (08.08.)

Dr Martina Frantzen (11.08.)

Dr Mattias Tamke (11.08.)

Jochen Graf (12.08.)

Dr Martin Mrowka (14.08.)

ZA Mario Ohlinger (15.08.)

Dr Mircea Teodor Parau (19.08.)

Dr Zeev Ormianer (23.08.)

Rainer Franz Latzko (29.08.)

### 45<sup>th</sup> Birthday

Haddad Jawad (02.08.)

Dr Andreas Meyer (03.08.)

Katrin Mielke (03.08.)

Dr Alexander Martin (13.08.)

Dr Sohayb Arrasat Al-Hindia (18.08.)

Silke Gudrun Bauer (19.08.)

Dr Janine Affeldt (20.08.)

Dr Martin Bauer (30.08.)

### 40<sup>th</sup> Birthday

Mohammad Khaled (17.08.)

## SEPTEMBER 2010

### 70<sup>th</sup> Birthday

Dr Dr Hans Hebbinghaus (07.09.)

### 65<sup>th</sup> Birthday

Dr Gerhard Brückmann (19.09.)

### 60<sup>th</sup> Birthday

Dr Heinz-Werber Heller (01.09.)

Dr Kaffan Murwan (05.09.)

Peter Quadfuß (16.09.)

John Giblin (17.09.)

Dr Roland Sireborn (23.09.)

Dr Bernd Neuschulz (29.09.)

### 55<sup>th</sup> Birthday

Dr Harald Wilkat (05.09.)

Dr Thomas Wiff (19.09.)

Dr Peter Aaen (19.09.)

Dr Wolfgang Ercken (22.09.)

Mouhamad Sameer Wahbeh (22.09.)

Dr Barbara Langen (23.09.)

### 50<sup>th</sup> Birthday

Dr Hubert Litter (02.09.)

Dr Jochen Heibach (04.09.)

Dr Christoph Falk (06.09.)

ZA Michael Quitzke (07.09.)

Dr Ralf Grießke (10.09.)

Dr Lutz Schneider (20.09.)

Dr Bernd Quantius (21.09.)

Torben Arlt (24.09.)

### 45<sup>th</sup> Birthday

Drs Jan-Guido Kisters (03.09.)

Dr Alexander Scholz (03.09.)

Dr Ulf Berkenkamp (06.09.)

Dr Thorsten Zickuhr (06.09.)

Dr Tom Wilken (13.09.)

Holger Heß (21.09.)

Dr Robert Bungartz (29.09.)

### 40<sup>th</sup> Birthday

Dr Uwe Held (05.09.)

## submission guidelines:

Please note that all the textual components of your submission must be combined into one MS Word document. Please do not submit multiple files for each of these items:

- \_ the complete article;
- \_ all the image (tables, charts, photographs, etc.) captions;
- \_ the complete list of sources consulted; and
- \_ the author or contact information (biographical sketch, mailing address, e-mail address, etc.).

In addition, images must not be embedded into the MS Word document. All images must be submitted separately, and details about such submission follow below under image requirements.

### Text length

Article lengths can vary greatly—from 1,500 to 5,500 words—depending on the subject matter. Our approach is that if you need more or less words to do the topic justice, then please make the article as long or as short as necessary.

We can run an unusually long article in multiple parts, but this usually entails a topic for which each part can stand alone because it contains so much information.

In short, we do not want to limit you in terms of article length, so please use the word count above as a general guideline and if you have specific questions, please do not hesitate to contact us.

### Text formatting

We also ask that you forego any special formatting beyond the use of italics and boldface. If you would like to emphasise certain words within the text, please only use italics (do not use underlining or a larger font size). Boldface is reserved for article headers. Please do not use underlining.

Please use single spacing and make sure that the text is left justified. Please do not centre text on the page. Do not indent paragraphs, rather place a blank line between paragraphs. Please do not add tab stops.

Should you require a special layout, please let the word processing programme you are using help you do this formatting automatically. Similarly, should you need to make a list, or add footnotes or endnotes, please let the word processing programme do it for you automatically. There are menus in every programme that will enable you to do so. The fact is that no matter how carefully done, errors can creep in when you try to number footnotes yourself.

Any formatting contrary to stated above will require us to remove such formatting before layout, which is very time-consuming. Please consider this when formatting your document.

### Image requirements

Please number images consecutively throughout the article by using a new number for each image. If it is imperative that certain images are grouped together, then use lowercase letters to designate these in a group (for example, 2a, 2b, 2c).

Please place image references in your article wherever they are appropriate, whether in the middle or at the end of a sentence. If you do not directly refer to the image, place the reference at the end of the sentence to which it relates enclosed within brackets and before the period.

In addition, please note:

- \_ We require images in TIF or JPEG format.
- \_ These images must be no smaller than 6x6 cm in size at 300 DPI.
- \_ These image files must be no smaller than 80 KB in size (or they will print the size of a postage stamp!).

Larger image files are always better, and those approximately the size of 1 MB are best. Thus, do not size large image files down to meet our requirements but send us the largest files available. (The larger the starting image is in terms of bytes, the more leeway the designer has for resizing the image in order to fill up more space should there be room available).

Also, please remember that images must not be embedded into the body of the article submitted. Images must be submitted separately to the textual submission.

You may submit images via e-mail, via our FTP server or post a CD containing your images directly to us (please contact us for the mailing address, as this will depend upon the country from which you will be mailing).

Please also send us a head shot of yourself that is in accordance with the requirements stated above so that it can be printed with your article.

### Abstracts

An abstract of your article is not required.

### Author or contact information

The author's contact information and a head shot of the author are included at the end of every article. Please note the exact information you would like to appear in this section and format it according to the requirements stated above. A short biographical sketch may precede the contact information if you provide us with the necessary information (60 words or less).

### Questions?

Kristin Urban (Managing Editor)  
k.urban@oemus-media.de

**implants**  
international magazine of oral implantology



**Publisher**

Torsten R. Oemus  
[oemus@oemus-media.de](mailto:oemus@oemus-media.de)

**CEO**

Ingolf Döbbbecke  
[doebbecke@oemus-media.de](mailto:doebbecke@oemus-media.de)

**Members of the Board**

Jürgen Isbaner  
[isbaner@oemus-media.de](mailto:isbaner@oemus-media.de)

Lutz V. Hiller

[hiller@oemus-media.de](mailto:hiller@oemus-media.de)

**Chief Editorial Manager**

Dr Torsten Hartmann (V. i. S. d. P.)  
[hartmann@dentalnet.de](mailto:hartmann@dentalnet.de)

**Editorial Council**

Dr Friedhelm Heinemann  
[friedhelmheinemann@web.de](mailto:friedhelmheinemann@web.de)

Dr Roland Hille

[dr-hille@t-online.de](mailto:dr-hille@t-online.de)

Prof Dr Dr Kurt Vinzenz

[kurt.vinzenz@aon.at](mailto:kurt.vinzenz@aon.at)

Dr Torsten Hartmann

[hartmann@dentalnet.de](mailto:hartmann@dentalnet.de)

Dr Suheil Boutros

[SMBoutros@aol.com](mailto:SMBoutros@aol.com)

**Editorial Office**

Kristin Urban

[k.urban@oemus-media.de](mailto:k.urban@oemus-media.de)

Eva Kretschmann

[e.kretschmann@oemus-media.de](mailto:e.kretschmann@oemus-media.de)

**Executive Producer**

Gernot Meyer  
[meyer@oemus-media.de](mailto:meyer@oemus-media.de)

**Designer**

Sarah Fuhrmann  
[s.fuhrmann@oemus-media.de](mailto:s.fuhrmann@oemus-media.de)

**Customer Service**

Marius Mezger  
[m.mezger@oemus-media.de](mailto:m.mezger@oemus-media.de)

**Published by**

Oemus Media AG  
Holbeinstraße 29  
04229 Leipzig, Germany  
Tel.: +49 341 48474-0  
Fax: +49 341 48474-290  
[kontakt@oemus-media.de](mailto:kontakt@oemus-media.de)

**Printed by**

Messedruck Leipzig GmbH  
An der Hebemärchte 6  
04316 Leipzig, Germany

**implants**

international magazine of oral implantology  
is published in cooperation with the German  
Association of Dental Implantology (DGZI).

**DGZI President**

Dr Friedhelm Heinemann  
DGZI Central Office  
Feldstraße 80, 40479 Düsseldorf, Germany  
Tel.: +49 211 16970-77  
Fax: +49 211 16970-66  
[office@dgzi-info.de](mailto:office@dgzi-info.de)

[www.dgzi.de](http://www.dgzi.de)  
[www.oemus.com](http://www.oemus.com)

**Copyright Regulations**

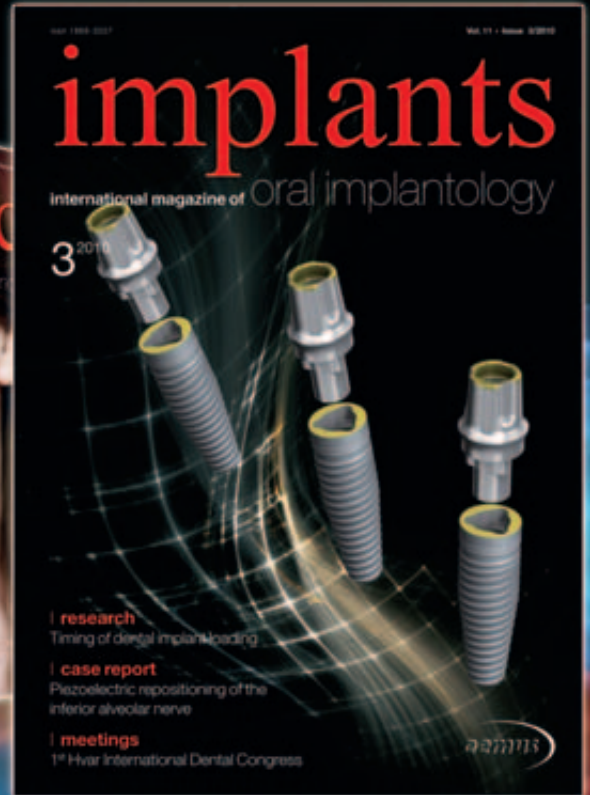**\_implants international magazine of oral implantology** is published by Oemus Media AG and will appear in 2010 with one issue every quarter. The magazine and all articles and illustrations therein are protected by copyright. Any utilization without the prior consent of editor and publisher is inadmissible and liable to prosecution. This applies in particular to duplicate copies, translations, microfilms, and storage and processing in electronic systems.

Reproductions, including extracts, may only be made with the permission of the publisher. Given no statement to the contrary, any submissions to the editorial department are understood to be in agreement with a full or partial publishing of said submission. The editorial department reserves the right to check all submitted articles for formal errors and factual authority, and to make amendments if necessary. No responsibility shall be taken for unsolicited books and manuscripts. Articles bearing symbols other than that of the editorial department, or which are distinguished by the name of the author, represent the opinion of the afore-mentioned, and do not have to comply with the views of Oemus Media AG. Responsibility for such articles shall be borne by the author. Responsibility for advertisements and other specially labeled items shall not be borne by the editorial department. Likewise, no responsibility shall be assumed for information published about associations, companies and commercial markets. All cases of consequential liability arising from inaccurate or faulty representation are excluded. General terms and conditions apply, legal venue is Leipzig, Germany.



# implants

international magazine of oral implantology



You can also subscribe via  
[www.oemus.com/abo](http://www.oemus.com/abo)

 **Subscribe now!**

## One issue free of charge!

I hereby agree to receive a free trial subscription of **implants international magazine of oral implantology** (4 issues per year).

I would like to subscribe to **implants** for € 44 including shipping and VAT for German customers, € 46 including shipping and VAT for customers outside of Germany, unless a written cancellation is sent within 14 days of the receipt of the trial subscription. The subscription will be renewed automatically every year until a written cancellation is sent to OEMUS MEDIA AG, Holbeinstr. 29, 04229 Leipzig, Germany, six weeks prior to the renewal date.

▶ **Reply** via Fax +49 341 48474-290 to OEMUS MEDIA AG or per E-mail to [grasse@oemus-media.de](mailto:grasse@oemus-media.de)

Last Name, First Name	
Company	
Street	
ZIP/City/County	
E-mail	Signature

Notice of revocation: I am able to revoke the subscription within 14 days after my order by sending a written cancellation to OEMUS MEDIA AG, Holbeinstr. 29, 04229 Leipzig, Germany.

Signature
-----------

Official care provider  
to the German Olympic teams  
since 2002

GO FOR GOLD.



Bionic Engineering Design transfer of  
optimal living nature solutions  
to technical products

BEGO Semados®  
Mini-Implant

BEGO Semados®  
S-Implant

BEGO Semados®  
RI-Implant

## BIONIC ENGINEERING DESIGNED IMPLANTS

BEGO Semados® patented Implants embody:

- Indication-optimised contour design
- Function-optimised implant-abutment-connection
- High purity and ultra-homogenous-surface
- Polished rim for an inflammation-free gingiva-attachment
- 100 % German design – 100 % German manufacturing
- Value for money

# Are You Interested?

[info@bego-implantology.com](mailto:info@bego-implantology.com)

[www.adwork.de](http://www.adwork.de)

**BEGO**   
Partners in Progress

[www.bego-implantology.com](http://www.bego-implantology.com)

 **ADMED**.com



## • Base it

بیس و لاینر (دایکال نوری)



- حاوی کلیسم هیدروکساید آپاتیت (دارای خاصیت رادیواپسیتی)
- شیرینکیج پائین ، چسبندگی بالا و استحکام در برابر پوسیدگی
- دارای مقاومت بیشتر از گلاس آینومر
- ایجاد بهترین عایق • ۴ سرنگ ۲ گرمی
- قابلیت ایجاد دنتین ثانویه با آزاد کردن یون های کلیسیم هیدروکسی و فسفات

You're  
the Artist

SPIDENT  
MADE IN KOREA



AZAD TEJARAT  
PARS.LTD

## • Es Flow

نانوکامپوزیت فلو



- مناسب برای ترمیم حفره های کلاس ۱ تا ۳ و کلاس عمیقی
- قابل استفاده در ارتودنسی
- دارای مقاومت و پولیش پذیری بالا
- با خاصیت افت پلیمریزاسیون اندک و ضریب ارتجاعی مشابه عاج دندان
- فلو پذیری مناسب
- ۲ سرنگ ۲ گرمی



Web: [www.befrest.com](http://www.befrest.com)



Email: [info@azadmed.com](mailto:info@azadmed.com)



Tel: +98 21 88 98 80 63 - 6 Fax: +98 21 88 98 75 72

تهران، خیابان فاطمی، خیابان کاج جنوبی، ساختمان آوا، شماره ۳۴

Add: Ava Building, No 34, Kaj St, Fatemi Ave, Tehran, Iran