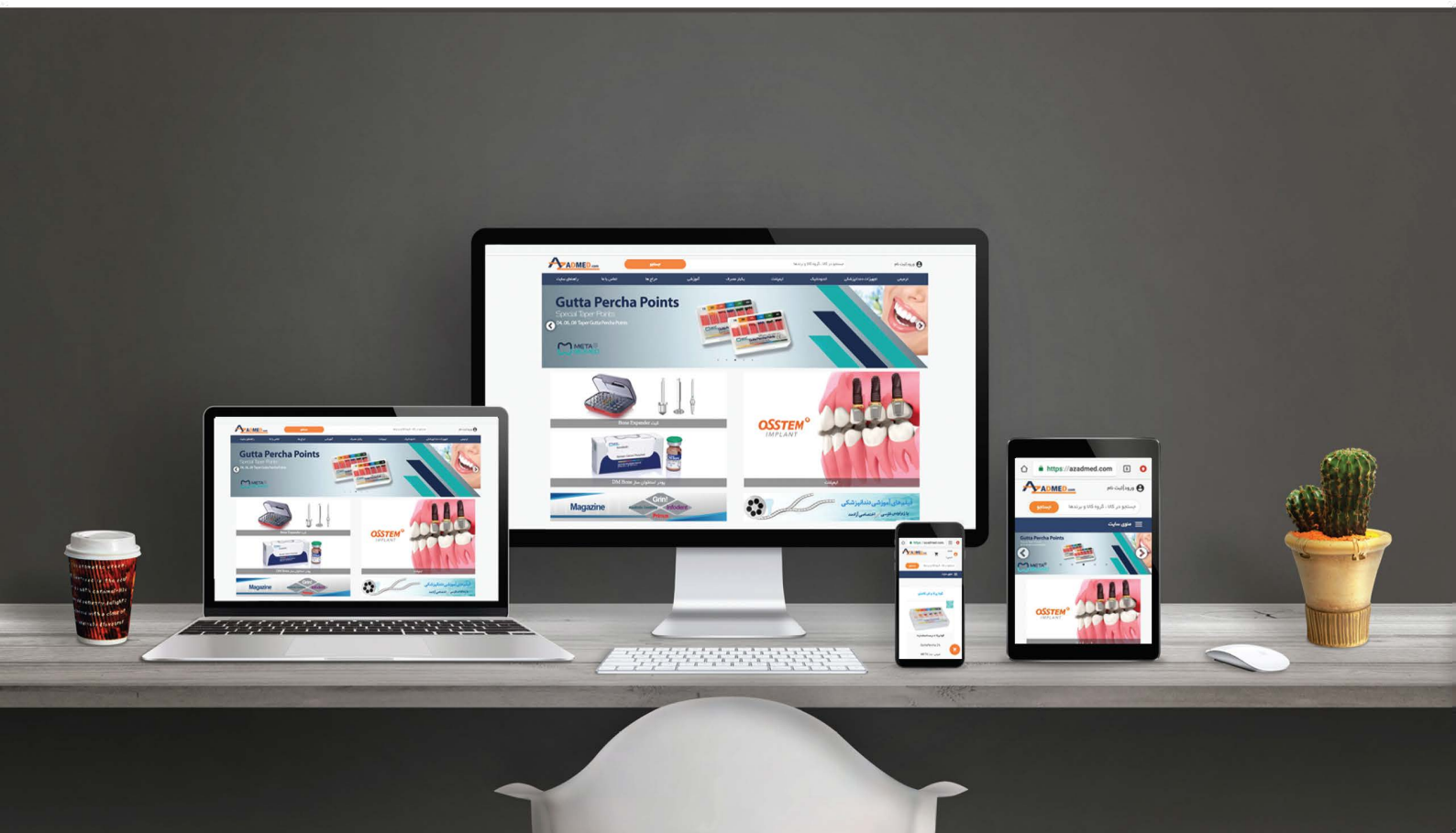




AZADMED.com



www.azadmed.com



 azaadtejaratpars

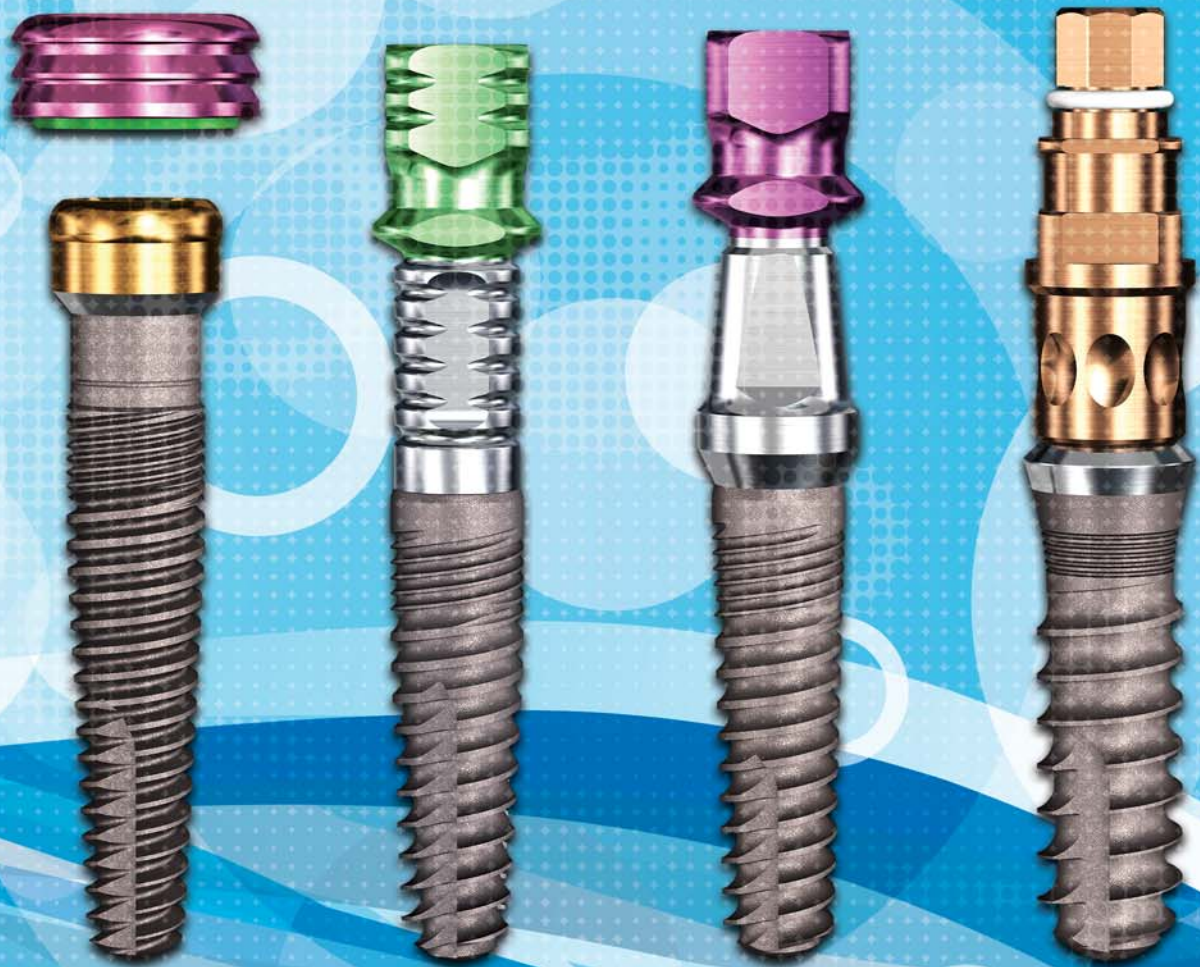 @azadmed2

 88 98 80 63 - 6

implants

international magazine of oral implantology

3²⁰¹²



| **research**

Rehabilitation of a complex case with zirconium dental implants

| **case report**

Immediate implantation in the anterior maxilla

| **industry report**

CAD/CAM-based restoration of an edentulous maxilla

IDENTICAL
IMPLANT SHAPE



TUBE-IN-TUBE™
CONNECTION



CONICAL
CONNECTION

CAMLOG is
TWICE AS GOOD

Conical – and of CAMLOG quality: The CONELOG® Implant System. First-class Tube-in-Tube™ or conical implant-abutment connection – all from one source.

For more information: www.camlog.com

a perfect fit™

camlog

To know **when** to do! To know **when** not to do!

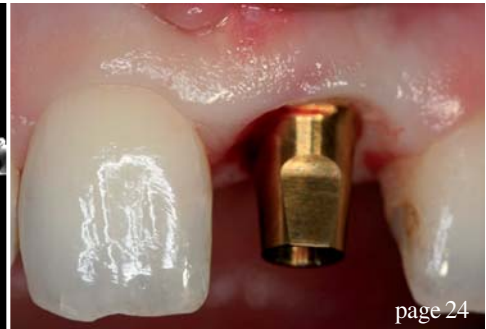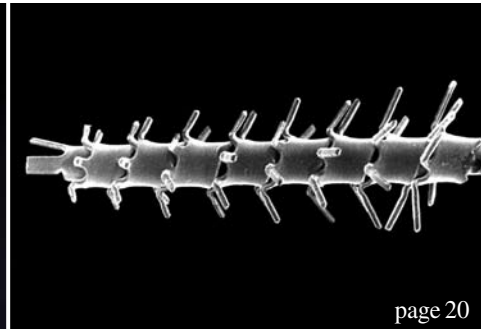

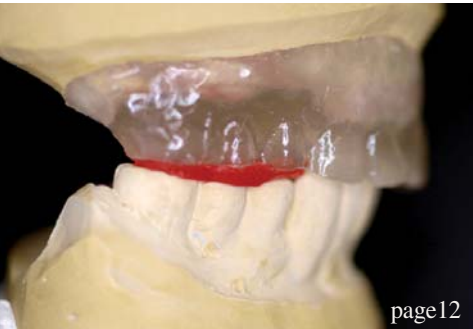
Dr Rolf Vollmer

Dental implantology has experienced a substantial change in the last 25 years. The treatment spectrum has been significantly expanded; simultaneously, our patients' expectations and demands in implant treatment have developed disproportionately. In addition, implant dentistry now is also an integral part of everyday dental practice. In spite of the growing importance of oral implantology, most dentists receive their education in implant dentistry after graduation with only little emphasis on the complexity and risks of implant treatment. Providing our patients with quality implant treatment motivates us to give the best our profession has to offer. This does however not imply that our treatments must be perfect to 100 per cent, since perfection such as this does not exist in the practice of implant dentistry. Instead, we must strive to achieve the best we can do for our patients. We need to work either as individuals or as members of a team to assure that implant treatment is safe, effective, and aesthetically acceptable. We can all play a part in providing quality dental implant treatment by being there for the patient with skills that are attained by proper education, experience, and counsel from those who have gained the necessary skills, knowledge, and judgment.

For 42 years, DGZI has organized its annual conferences in order to inform about scientific insights and "truths" established by research and evidence-based clinical observations. Not only for novice clinicians is attaining the proper education a continuing process, but it is also an ongoing enterprise for the highly experienced clinician. New developments occur with each passing day. Therefore, providing the best we can do for our patients and profession becomes an impossible task if we keep our blinders on and persist in our practice as we did yesterday. As early as the beginning of the 1990s did DGZI begin to administer an examination for particularly qualified colleagues, allowing them to both revise and prove their knowledge and skills to the advantage and the safety of their patients. The Curriculum Implantology was established as a systematic education for the newcomers as well as for the experienced implantologist. Some thousand colleagues have since passed the education successfully. A subsequent master studies postgraduate program can be attended additionally for more theoretical skills. In addition, a specialist and German board (GBOI) international examination was established by DGZI for clinicians who want to have their theoretical and practical experience tested by an international examination board. One of this year's DGZI highlights will be our International Annual Meeting in Hamburg from 5 to 6 October titled "Quality Oriented Implantology—Ways to Long-Term Success". Complex situations in dental implantology and the digitalization of surgery and prosthetics are discussed, along with a periimplantitis special session and discussion. Take your chance and register for the meeting as well as the German board and specialist examination. You can request more information from our central office in Düsseldorf (Tel. +49 211 1697077). I invite you all to join us and enjoy Hamburg where it is most beautiful, directly located on the Elbe River—at the heart of the harbour! Indulge in new culinary creations and an unforgettable atmosphere, combining state-of-the-art scientific meeting with maximum relaxation. Sincerely Yours,

1st Vice president of DGZI



| editorial

- 03 To know **when** to do! To know **when** not to do!
| Dr Rolf Vollmer

| research

- 06 **Rehabilitation of** a complex case with **zirconium dental implants**
| Dr Andrea Enrico Borgonovo *et al.*
- 12 **Impression and registration** for full-arch **implant dentures**
| Dr Gregory-George Zafiropoulos
- 20 **Time-saving** debridement of implants with **rotating titanium brushes**
| Dr Dirk U. Duddeck *et al.*

| case report

- 24 **Immediate implantation** in the **anterior maxilla**
| Dr Nikolaos Papagiannoulis *et al.*

| industry report

- 28 **Fixed full arch metal-free prosthesis on four SHORT® implants**
| Dr Mauro Marincola *et al.*
- 32 **CAD/CAM-based restoration** of an **edentulous maxilla**
| Arnd Lohmann

| business news

- 36 **Conical internal connections** will fuel **growth** in dental **implant market**
| Dr Kamran Zamanian *et al.*

| news

- 38 **Manufacturer** News
- 48 **News**

| education

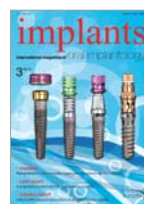- 40 **Master of Oral Medicine in Implantology**
| DGZ
- 41 **Celebrating the Triumph of Osseointegration**
| Frederic Love

| meetings

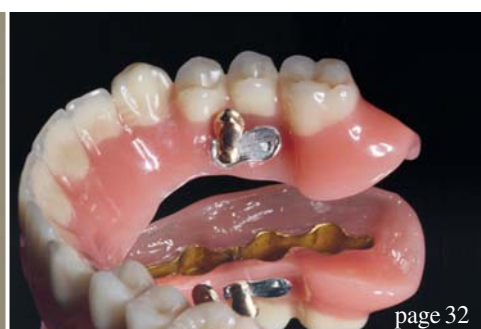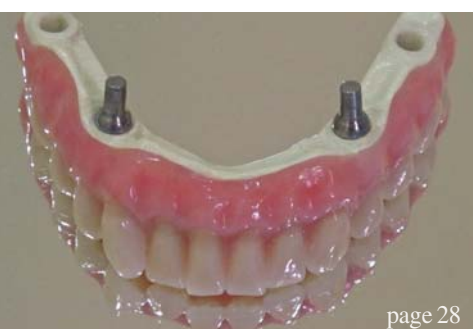- 35 **International** events 2012
- 42 **National Osteology Symposium** in Bonn
| Verena Vermeulen
- 44 **“Quality-oriented implantology”**
| DGZ

| about the publisher

- 50 | imprint

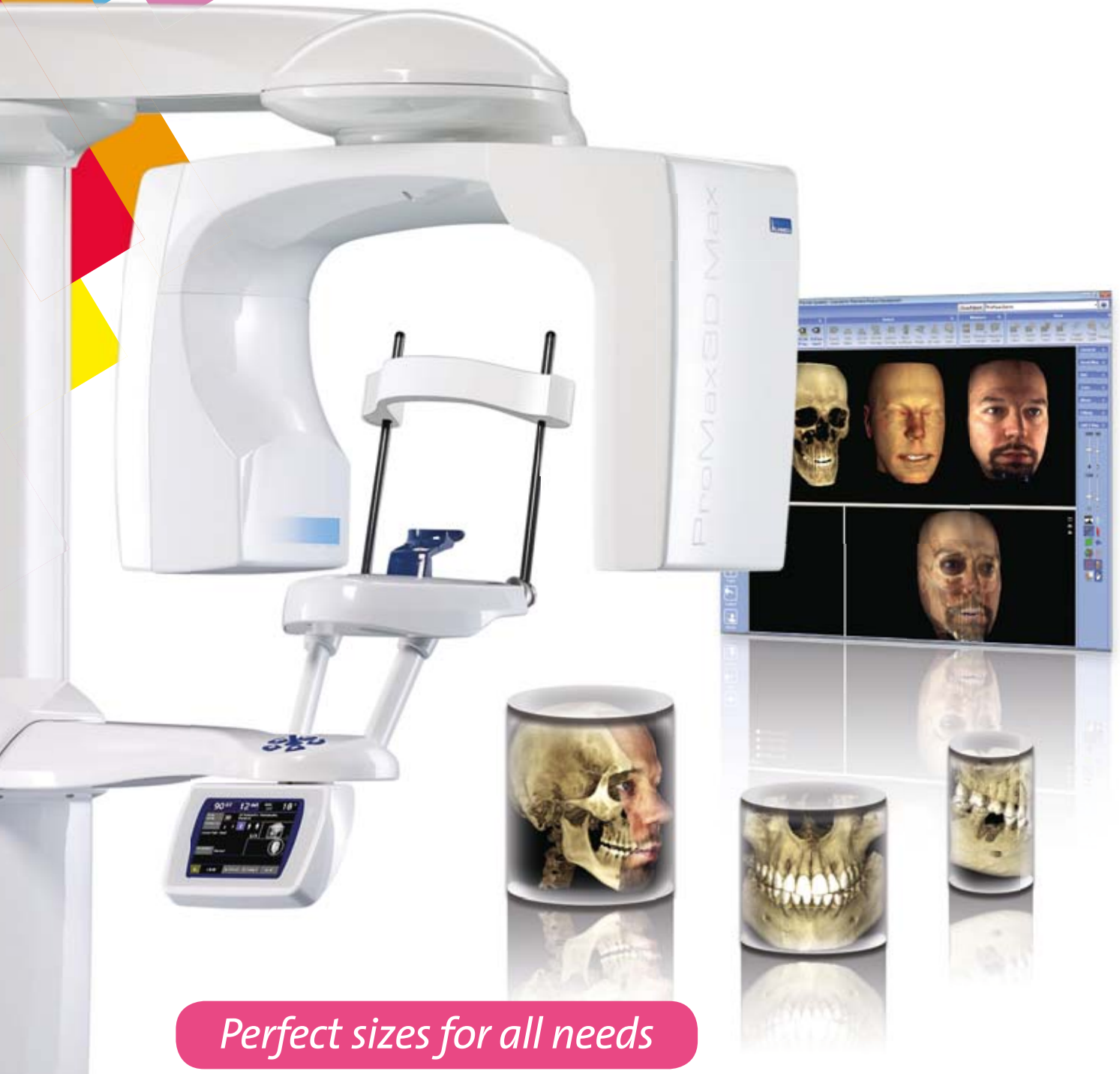

Cover image* courtesy of Implant Direct, www.implantdirect.com
Original Background: ©antishock
Artwork by Sarah Fuhrmann, OEMUS MEDIA AG.



Planmeca ProMax[®] 3D

Unique product family



Perfect sizes for all needs

3D X-ray • 3D photo • panoramic • cephalometric

Romexis[®] software completes 3D perfection



Digital perfection™

More information

www.planmeca.com

Planmeca Oy
Asentajankatu 6, 00880 Helsinki, Finland
tel. +358 20 7795 500, fax +358 20 7795 555
sales@planmeca.com

PLANMECA

Rehabilitation of a complex case with zirconium dental implants

Authors Dr Andrea Enrico Borgonovo, Dr Marcello Dolci, Dr Rachele Censi, Dr Oscar Arnaboldi, Dr Virna Vavassori & Prof Carlo Maiorana, Italy

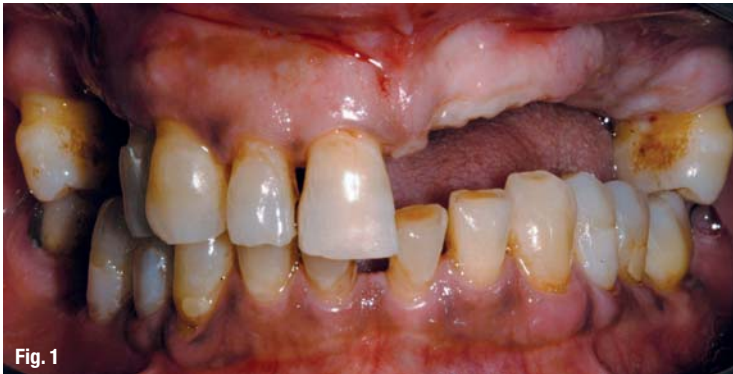

Fig. 1

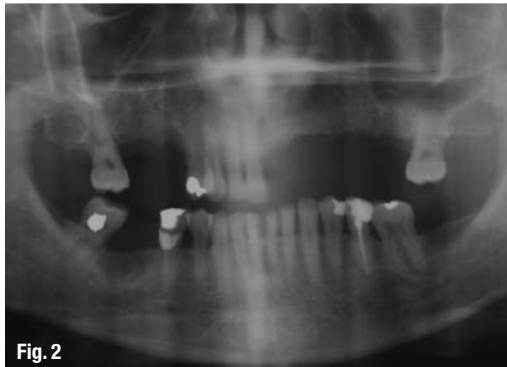


Fig. 2

Fig. 1 Pre-op clinical view.
Fig. 2 Pre-op radiograph.
Fig. 3 Preparation of implant site.

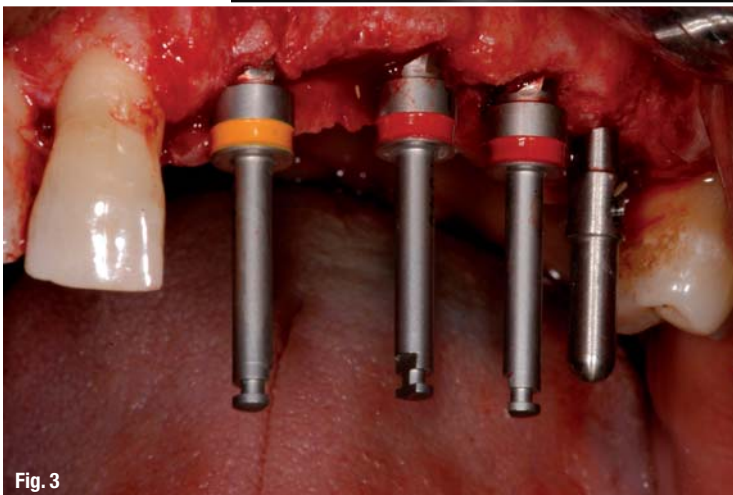


Fig. 3

Introduction

For several decades, dental implants have largely been used for the rehabilitation of completely and partially edentulous ridges with success. For this reason, implant dentistry has been the object of numerous investigations to further improve the effectiveness of this kind of device.^{1,2} Titanium is the material most often utilised for dental implants because of its favourable properties, such as its biocompatibility.^{3,4} However, aesthetic concerns may arise when restoring anterior teeth owing to the grey colour of this metal.

For this reason, new techniques and materials were developed to achieve better aesthetics, such as ceramic (zirconium) abutments^{5, 6} and metal-free restoration.^{7, 8} These prosthetic devices have already achieved assessable results. There are, however, some situations, resulting from a thin gingival biotype or incorrect tri-dimensional implant positioning, in which zirconium abutments and crowns are not able to obtain optimal aesthetics.^{9, 10}

Many authors¹¹ have attempted to solve these problems by coating titanium dental implants with white material such as ZrO_2 and Al_2O_3 . While the popularity of coating has increased, its use has remained controversial. Concerns have been raised owing to problems such as the dissolution and cracking of coatings, as well as the separation of coatings from metallic substrates, a phenomenon referred to as "delamination".

For the same purpose, Al_2O_3 implants have been tested in various clinical studies since the 1970s. They were commercialised in France, Germany, Japan and the USA. Among them, Tübingen implants are probably the most well known ceramic implants.¹² These im-

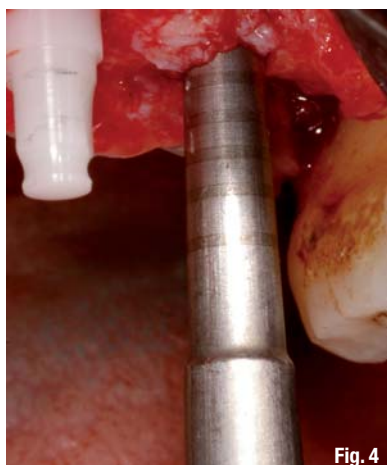

Fig. 4

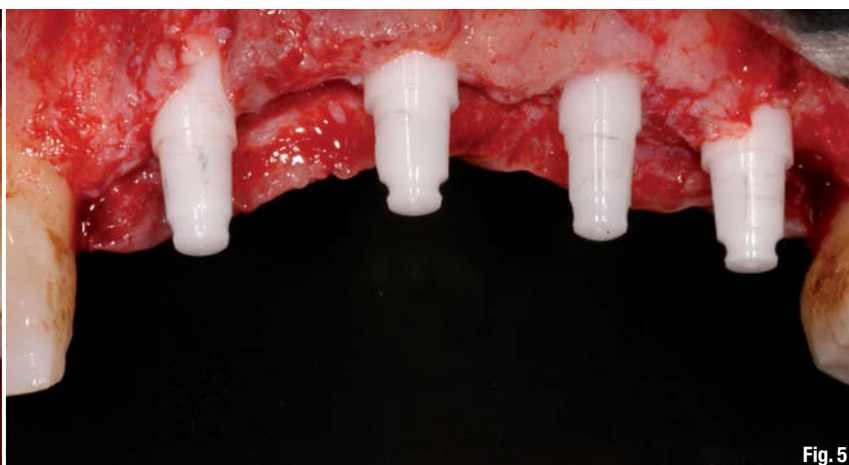


Fig. 5

plants were soon abandoned because of frequent implant fractures, mobilisation, loss of osseointegration and peri-implant bone loss. Most of these problems probably occurred owing to the inadequate mechanical characteristics of Al_2O_3 .^{13,14}

More recently, ZrO_2 has been introduced to dentistry for its good mechanical properties and high biocompatibility, combined with excellent aesthetics. While ZrO_2 has been largely used and documented in prosthetic dentistry, only few studies have reported clinical experiences with zirconium implants.^{15,16}

The aim of this article is to present a five-year follow-up study of a complex implant-prosthetic rehabilitation with ZrO_2 dental implants.

Case report

A 55-year-old male patient presented with partial edentulism in the left maxilla in regions 21 to 26 at the Department of Oral Surgery at the Dental Clinic at the University of Milan. The patient was in general good health and a non-smoker. However, lately he had had financial difficulties that had led to him taking inadequate care of his oral health and consequently losing teeth. After professional hygiene and oral hygiene instructions, the patient was re-evaluated for an implant-prosthetic rehabilitation. His edentulism was complex owing to the lack of numerous teeth and because the alveolar process had undergone moderate resorption. Yet, it was sufficient to insert four dental implants. There was no need for an augmentation procedure and the predictable level within the gingival marginal profile was not considered a problem because of the patient's low smile line (Figs. 1 & 2).

After a diagnostic wax-up, the surgical guide was created. A mucoperiosteal flap was raised with a vertical releasing incision distal to tooth 1.2. Four one-piece yttria-stabilised ZrO_2 (YSZ) implants (whiteSKY, bredent) were inserted. Two 4 x 12 mm implants were

positioned in regions 2.1 and 2.3, and two 4.5 x 12 mm implants in regions 2.5 and 2.6 (Fig. 3). After the implant sites had been prepared, implant insertion was performed using a surgical contra-angle handpiece and then a dynamometric key, at a maximum torque of 40 N. The fixtures were screwed in until the sanded surface reached the bone crest level, leaving the polished part untreated at transgingival level. A heterologous bone graft (Bio-Oss, Geistlich Pharma), together with a double layer resorbable membrane (Bio-Gide, Geistlich Pharma), was positioned on the implant placed in region 2.1 because of the thin cortical wall and to reduce bone resorption. A sinus lift was performed using Summers' osteotome technique to insert the implant with an adequate length (12 mm) in region 2.6 (Figs. 4–7). The flaps were sutured with non-absorbable 4.0 monofilament (Premilene, B. Braun). The removable partial denture was adapted in order to avoid any contacts with the implants.

The patient was prescribed a soft diet, antibiotic therapy with 1 g amoxicillin and clavulanic acid (Laboratori Eurogenerici) every eight hours for seven days and a 0.2% chlorhexidine mouth rinse (Corsodyl, GlaxoSmithKline) twice a day for 15 days. The patient attended a follow-up visit ten days later. The sutures were then removed and the implant stability was checked. The supra-gingival portion of the one-piece zirconium implant was minimally prepared with ETERNA burs (bredent) to achieve parallelism of the implant axes. Then the partial denture was replaced with a temporary acrylic resin bridge to enhance soft-tissue healing and guide the gingival profile (Fig. 8). In the temporary phase, particular attention was given to occlusion to ensure centric contact that was as light as possible and to avoid contacts in eccentric movements.

After four months, the temporary bridge was removed. Implant stability, probing depth and gingival health were examined. Furthermore, the occlusal surface of the temporary restoration was modified and

Fig. 4 Sinus lift using Summers' osteotome technique in region 2.6.

Fig. 5 The four implants are positioned.

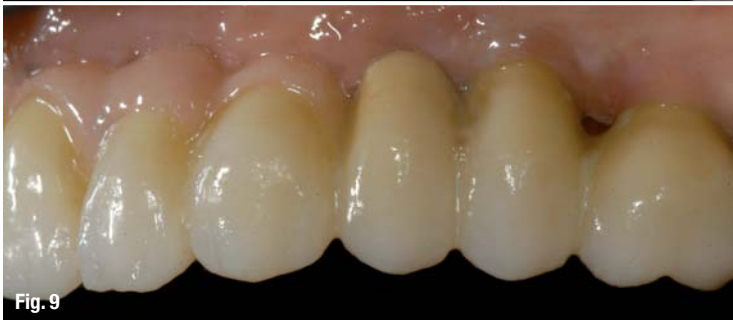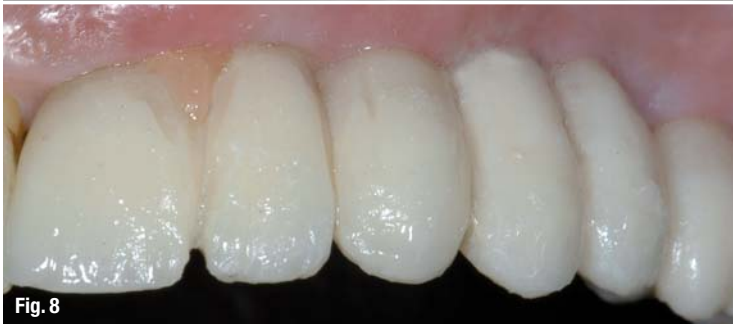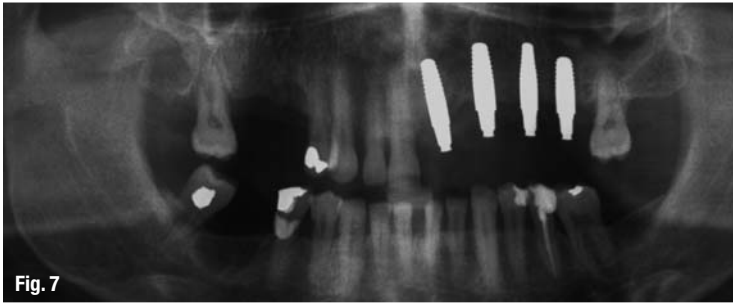
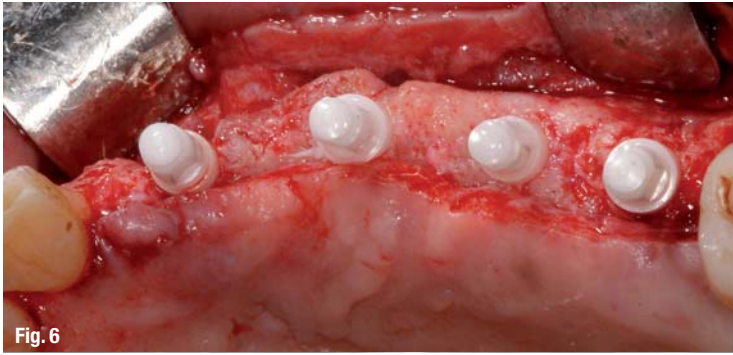


Fig. 6_ Occlusal view of the implants.
Fig. 7_ Post-op radiograph.
Fig. 8_ The acrylic resin temporary bridge is placed.
Fig. 9_ Clinical view of the all-ceramic ZrO₂ bridge five years after surgery.

the implants were loaded. Six months after surgery, the YSZ implants were definitively restored with a ZrO₂ bridge. A light-pink ceramic layer was applied to the marginal areas of regions 2.1 to 2.3 to better support the upper lip and limit the width of the interdental space (Fig. 9).

Follow-up appointments were scheduled for six months after prosthesis delivery and thereafter once a year. Periodontal indices were measured and standardised periapical radiographs were obtained. The plaque index and bleeding on probing scores were 1, except at the last follow-up. No implants had probing depth values of less than 5 mm. Mobility was not present at any site. No pain (spontaneous or on percussion) or paraesthesia was reported. From baseline to

five years after surgery, radiographical evaluation observed the absence of peri-implant radiolucency and no implant exhibited marginal bone resorption at any follow-up (Figs. 10 & 11).

Discussion

Titanium dental implants have proved to be highly successful in replacing missing teeth. Several studies have demonstrated the successful osseointegration of this material and its use for restoration in patients with partial or total edentulism.¹⁷ In recent years, numerous studies have focused on the development of implant surfaces to ensure better and faster osseointegration and to re-establish masticatory function in a shorter period.^{18,19} Although excellent results have been obtained in the maxillary anterior region by several clinicians, aesthetics remains a challenge for implant dentistry.

Titanium implants are of a grey colour, which can shine through gingival tissue, particularly in thin biotypes or in patients with a high smile line. Moreover, it must be considered that soft tissue around dental implants may shrink or develop gingival recession, or that peri-implantitis may occur, thus compromising the overall treatment outcome, particularly if treatment entails an aesthetic region.

In recent years, several solutions to this problem have been proposed. Various authors have suggested placing implants 3 to 4 mm apical to the cemento-enamel junction or free gingival margin of adjacent teeth, considering that soft-tissue margins around implants tend to re-establish a biological width.²⁰ Implants positioned too far apically in an attempt to establish appropriate biological width can cause gingival recession.²¹ Gingival recession may also develop in thin gingival biotypes because these tissues are more sensitive to trauma and inflammation. For these reasons, surgical approaches such as connective tissue grafts have been suggested to augment tissue thickness and improve peri-implant aesthetics.^{22,23} However, these techniques are not always completely predictable from an aesthetic point of view. Moreover, morbidity of the donor site and patient discomfort must also be taken into account. Other authors²⁴ have recommended colouring the implant neck, thus changing the optical appearance of peri-implant mucosa. For the same reason, a great number of investigations have been conducted on tooth-coloured implants. Various ceramics have been tested as coating material, such as ZrO₂ and Al₂O₃.^{13,26} However, even if the studies conducted in the 1990s showed better results than earlier investigations, these implants did not have adequate mechanical properties for long-term loading²⁷ or required large diameters that were incompatible with use in the anterior region with lim-



PERFECT FIT BY DESIGN

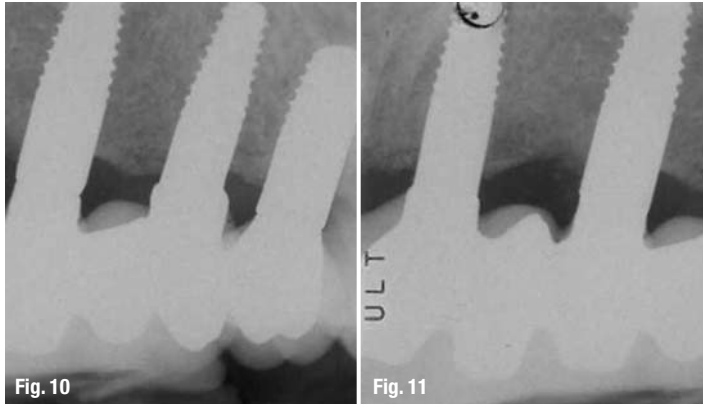
In combining Soft Tissue and Bone Level implants with a comprehensive prosthetic portfolio, Straumann has devised one system for all indications. The **Straumann® Dental Implant System** – excellent product quality designed for convincing, naturally esthetic outcomes.



Featuring the
SLActive® surface!

More information on www.straumann.com

COMMITTED TO
SIMPLY DOING MORE
FOR DENTAL PROFESSIONALS



Figs. 10 & 11 Periapical radiographs five years after surgery.

ited space.²⁸ Consequently, the indications for these implants were limited and they were withdrawn from the market.

More recently, YSZ has been utilised for dental implants. This new generation of ceramic implants exhibits good mechanical properties, combined with good optical properties and high biocompatibility. In fact, YSZ has a flexural strength similar to titanium and a textural strength similar to stainless steel.²⁹

A number of animal studies have demonstrated good osseointegration.^{30, 31} In further studies,³² the same authors have demonstrated osseointegration stability after a long-term loading period. Scarano³³ analysed the bone-implant interface in rabbit tibia, and observed neither fibrous tissue nor inflammation, with good bone-to-implant contact (68%). Similar results were obtained in monkeys by Kohal.³⁴

In another study, the same author compared stress distribution in YSZ implants and titanium implants, and observed similar stress distribution patterns.³⁵

Sennerby³⁶ studied the effect of varying surface roughness on extraction torque and bone-to-implant contact with YSZ implants compared with titanium implants six weeks after implant insertion. The results demonstrated that when surface roughness was enhanced, the two materials exhibited similar behaviour. Other studies^{37, 38} have confirmed that a treated YSZ implant surface provides good osseointegration at all times and after a long-term loading period.

These promising results led a still limited number of authors to test ZrO₂ implants on humans. The first few clinical studies are quite recent. Among these, Blatsche and Voltz³⁹ observed 98% osseointegration in 66 implants in 34 patients in a period of between two and five years. Kohal and Klaus⁴⁰ reported the stability of an YSZ implant in a fresh extraction socket with a graft material after loading. Oliva et al.⁴¹ reported one-year results for 100 YSZ implants with two different surfaces, in some cases combined with bone

augmentation and sinus lift procedures. Within this observation period, the authors reported a 100% survival rate and a 98% success rate in terms of absence of bleeding on probing, signs of inflammation, mobility and radiolucency. Similar results (93% success) were reported by Mellinghoff⁴² in a one-year follow-up study on 189 implants in 71 patients. These studies suggest that YSZ implants exhibit a good rate of osseointegration.

Improvements in zirconium surface characteristics will probably lead to interfacial biomechanical properties comparable to treated titanium surfaces in the future. Compared with titanium, plaque adhesion to zirconium surfaces is very limited because no chemical or physical bonding between ZrO₂ and plaque occurs.⁴³ This is an important feature for long-term survival.

These findings, together with the good mechanical properties characteristic of zirconium implants, are encouraging. However, further histological and clinical studies are needed to investigate long-term success and stability.

Conclusion

In conclusion, it can be stated that it is logical to use a ceramic material for the aesthetic regions. Zirconium dioxide is particularly suitable, since it offers tissue friendliness and a resistance comparable to titanium. Its increased tensile strength, superior mechanical properties, unsurpassed integration with tissue and aesthetic appearance, as well as the possibility of easy fabrication of the prosthetic restoration, may well result in partially YSZ becoming the most commonly used material in implant dentistry for aesthetic regions.

This case report has demonstrated that YSZ implants offer a successful rate comparable to titanium, with a higher aesthetic performance in the anterior region. For this reason, the authors recommend the utilisation of YSZ implants in cases like the one in this article.

contact

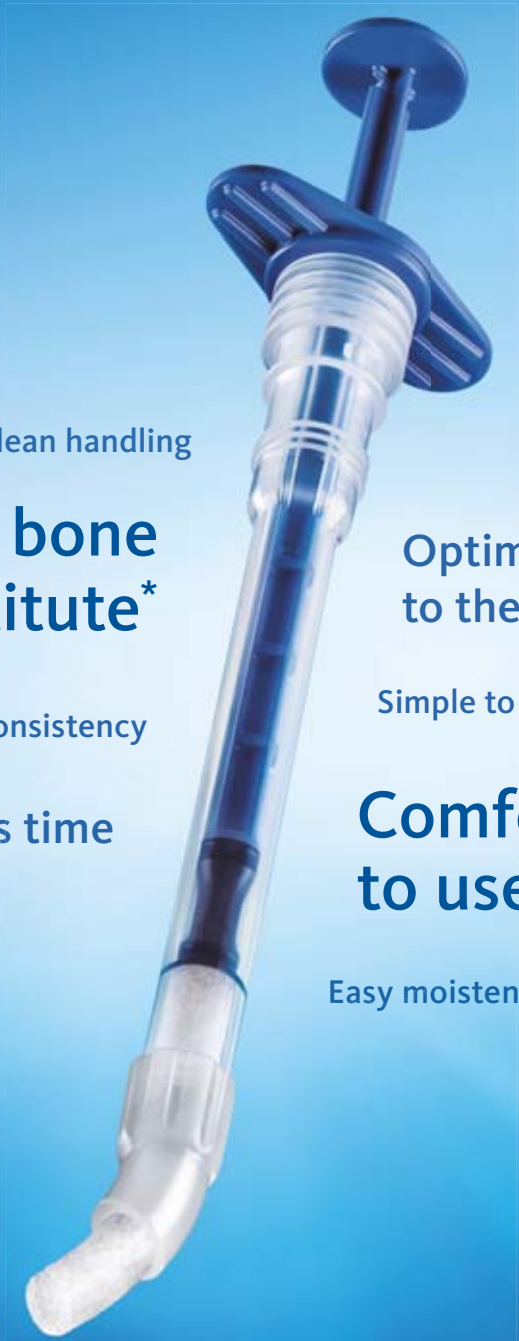implants

Dr Virna Vavassori

University of Milan
Dental Clinic
Postgraduate School of Oral Surgery
Via della Commenda 10
20122 Milan
Italy

virna.vavassori@hotmail.it

Nothing changed.
Just improved.



Clean handling

No. 1 bone substitute*

Optimal access to the defect

Very good consistency

Simple to use

Saves time

Comfortable to use

Easy moistening

New!

- ✓ Unwrap
- ✓ Moisten
- ✓ Use

* iData Research Inc., US Dental Bone Graft Substitutes and other Biomaterials Market, 2011.

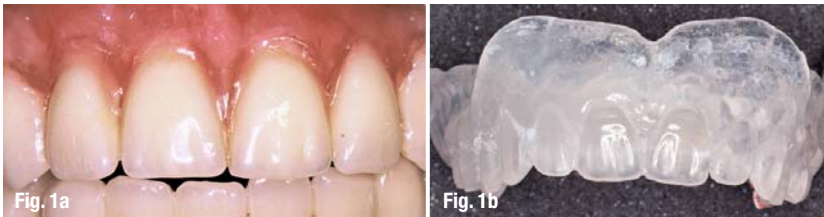iData Research Inc., European Dental Bone Graft Substitutes and other Biomaterials Market, 2010.

Please check for availability of this product with your country representative: www.geistlich-pharma.com

For more information visit:
www.bio-oss.com

Impression and registration for full-arch implant dentures

Author_Prof Dr Gregory-George Zafiropoulos, Germany



mination of the exact position of the placed implants) are often challenging and time-consuming tasks.¹

The aim of the current report is to present an impression and registration technique that allows the transfer of the interocclusal relationship, occlusal recording and esthetics that were initially applied to produce a full denture as a template for the reconstruction of the final full-arch implant.

_Materials and Methods

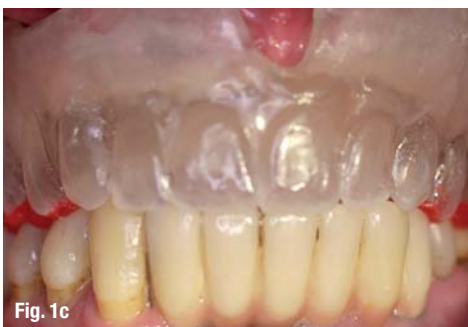Following multiple extraction of a non-salvageable rest dentition and the placement of six dental implants in positions #4, #5, #6, #11, #12, #13, a full denture was fabricated. After the extraction sites had healed and denture sores were eliminated, the function and esthetics of the denture was optimized. If necessary, angulations, shape and color of the denture teeth and the shape of the denture base were corrected (Fig. 1a). The resulting denture was used by the patient until the final restoration was delivered. For the final restoration of the maxilla, an implant-

_Introduction

Usually, a full denture is delivered following tooth extraction or implant insertion of a fully edentulous arch. A denture is usually used until the final restoration is performed. A well-designed full denture should fulfill the following criteria: 1) correct vertical height and maxilla-mandibular relationship; 2) accurate occlusion; 3) appropriate choice of teeth with regard to shape, length, width and position; 4) adequate lip support and 5) proper function and aesthetics to meet the patient's expectations. The final restoration should fulfill or surpass these requirements. Obtaining a correct impression and accurately evaluating the interocclusal relationship (e.g., interocclusal distance, occlusal recording and deter-

Fig. 1a_ Full denture in situ.
Fig. 1b_ Duplicate (DentDu) of the interim denture.

Fig. 1c_ Trial of the DentDu.
Fig. 2a_ Placement of the DentDu in the articulator.
Fig. 2b_ Pick-up impression system. On the left: titanium impression post (placed on the implant). On the right: plastic impression sleeve (will be left in the impression).

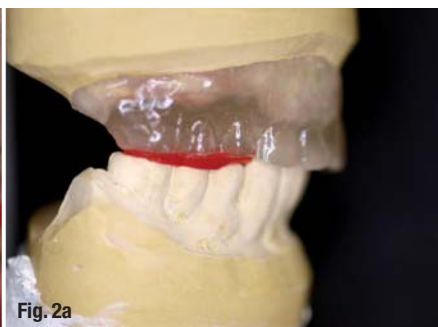

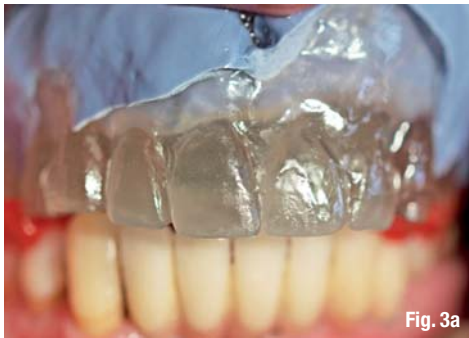


Fig. 3a

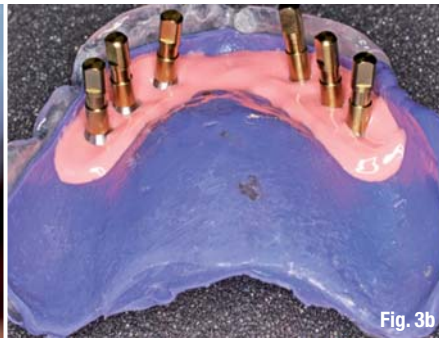

Fig. 3b

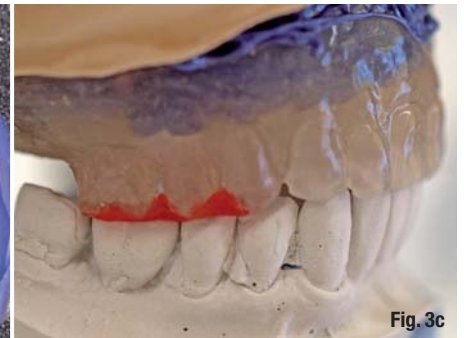


Fig. 3c

retained denture with telescopic crowns as attachments was planned.

After the implant was uncovered, the denture was modified to allow sufficient space for the healing abutments. A duplicate of the denture (DentDu) was made out of clear resin (Paladur, Heraeus, Hanau, Germany, Fig. 1b). A trial of the DentDu was performed and minor occlusal discrepancies were corrected (Fig. 1c). Bite records were taken in centric occlusion with modeling resin (pattern resin®, GC, Alsip, IL; Fig. 1c), using the casts of the original denture. Afterwards, the DentDu was placed in an articulator and a controlling of the occlusion was made (Fig. 2a) with the bite records. A pickup transfer system con-

sisting of a titanium impression post and a plastic impression sleeve was employed (Dentegris, Duisburg, Germany, Fig. 2b). The DentDu was carefully modified by creating internal clearance in the area of the implants so that it could be applied as an individualized custom tray. This permitted it to be fully seated when the impression posts were in place. Impressions were generated by a polyether material (Impregum, 3M ESPE, St. Paul, MI). During this process, the DentDu was kept in centric occlusion using the bite records (Fig. 3a).

The titanium impression posts were connected with the implant analogues and with the plastic impression sleeves (Dentegris), which were embedded in

Fig. 3a_ Taking the impression with the DentDu. The bite records were used to determine the exact position.
Fig. 3b_ Fabrication of the master cast.
Fig. 3c_ Placement of the cast into the articulator using the bite registrations.

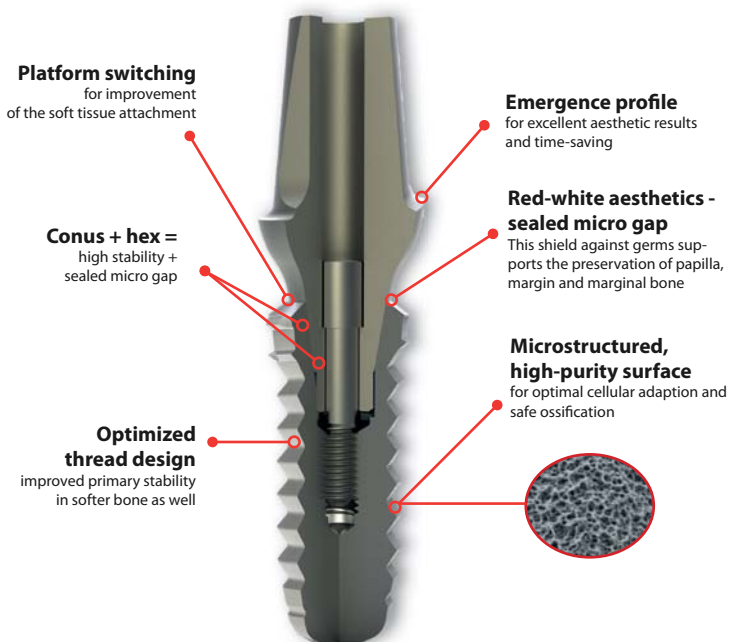
AD



YOUR ADVANTAGE! THE 2 IN 1 CONCEPT: Conical connection - with anti-rotation hex!



Micro Retention Conical Hybrid Connection



Increase your business with IMPLA!

You are a dental dealer and want to benefit on the daily growing implant business?

We are the right partners for you.

- » Official partner of DGZI "German Chamber of Implantology"
- » Controlled German Quality
- » Individual marketing packages
- » 50 years experience
- » Training concepts for your sales team and your customers

Call us today and become a partner.
For additional information visit our website:
www.schuetz-dental.com



Sign up for the exclusive IMPLA Newsletter:
<http://sdent.eu/newe>



IMPLA

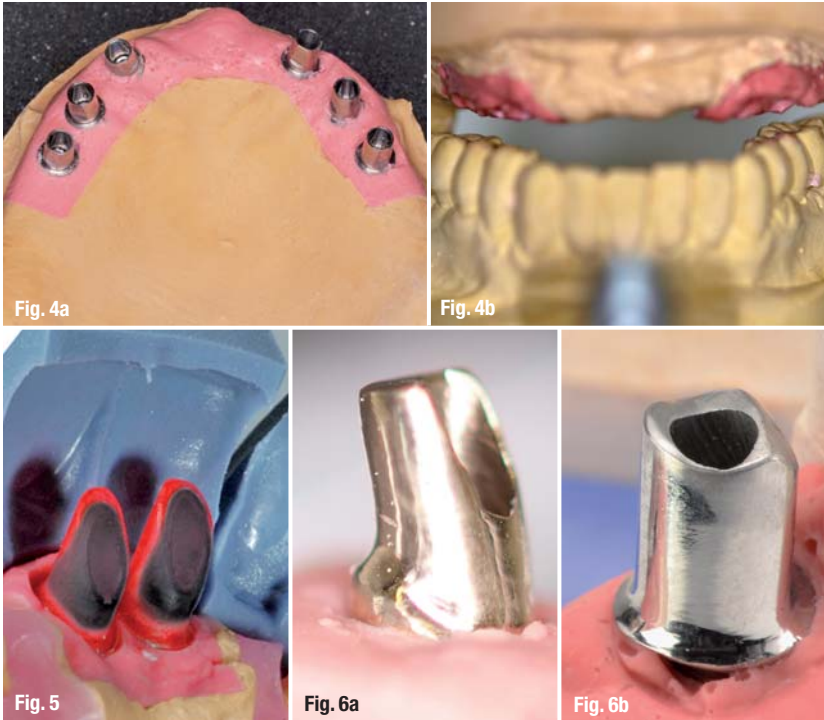


Fig. 4a_Master cast.
Fig. 4b_The master cast is placed into the articulator.
Fig. 5_The customized implant abutments are fabricated using a matrix of C-silicone.
Fig. 6a_Gold customized abutments.
Fig. 6b_Chromium cobalt (CrCo) customized abutments.
Fig. 6c_Electroformed gold copings.
Figs. 7a & 7b_The customized abutments are mounted on the implants using a transfer key.
Fig. 7c_Electroformed gold copings in situ.

the impression material (Fig. 3b). A master cast was then fabricated and articulated with the help of the bite records (Fig. 3c, Figs. 4a & 4b).

Customizable abutments (Dentegris) were taken to fabricate the implant abutments. Parallelism, angulation, position and shape of the implant abutments were determined using a silicon key fabricated from a matrix of C-silicone (Zetalabor, Zhermack SpA, Badia Polesine, Italy, Fig. 5). The dentist and the dental technician relied on two alternatives for customized abutments selection: 1) UCLA customizable abutments (UCLA, Dentegris) for casting with a gold alloy (for example, Portadur P4, Au 68.50 %, Wieland, Pforzheim, Germany, Fig. 6a) or 2) platinum-iridium customizable abutments (PTIR, Dentegris) for casting with a chromium cobalt (CrCo) alloy (for example, Ankatit, Anka Guss, Waldaschaff, Germany, Fig. 6b).

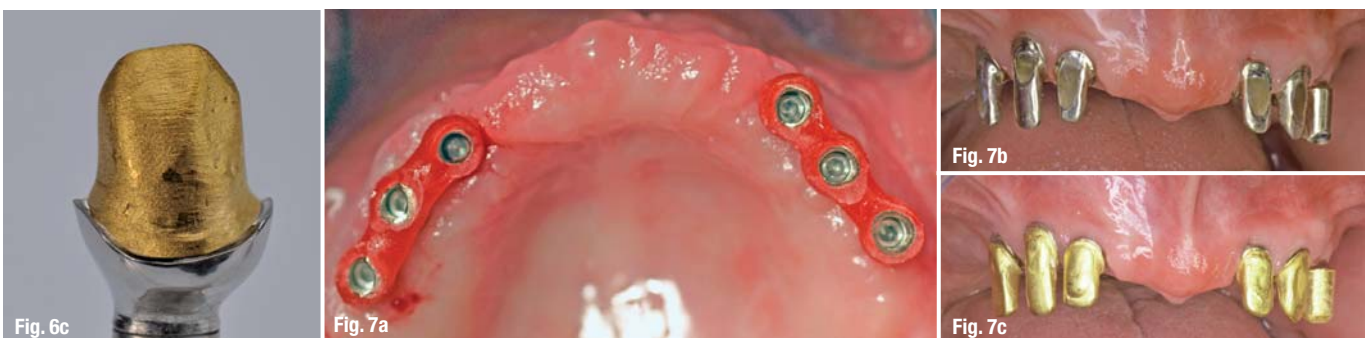After casting, the customized implant abutments were grinded, polished and served as the basis for the

fabrication of electroformed pure-gold copings with a thickness of 0.25 mm (AGC Galvanogold, Au > 99.9%, Wieland, Fig. 6c).²⁻⁴ The framework was then constructed via CAD/CAM. To ensure proper functioning of the framework, a plastic mock-up and a temporary fixed denture (TFD) were milled (ZENO-PMMA, Wieland). The customized implant abutments, the electroformed copings, the mock-up and the TFD were delivered by the dental laboratory for the next clinical session.

The abutments were transferred, positioned on the implants and torqued to 35 Nm using a resin transfer key (pattern resin, GC; Figs. 7a-b). From this point on, the customized abutments remained fixed in order to avoid any possible inaccuracies. The electroformed copings were placed on the implant abutments (Fig. 7c). The mock-up was placed over the electroformed copings and the occlusion was checked with the bite records (Figs. 8a-b). A final impression with a polyether impression material (Impregum, 3M ESPE) was taken with electroformed copings. The mock-up was further set up and used for the fabrication of a new (final) master cast. After the impression was taken, the TFD was fixed on the implant abutments using temporary cement (TempBond, Kerr, Orange, CA). It was then left in place until the delivery of the final restoration (Fig. 8c).

The new master cast was articulated with the help of the gold copings and the mock-up. The metal framework was milled (here: Titanium Zenotec TI, Wieland, Fig. 9a). The veneering of the superstructure was made using a light-cured indirect ceramic polymer (Ceramage, SHOFU, Menlo Park, CA, Figs. 9a-d). The electroformed gold copings were fixed in the metal framework using a self-curing compomer cement (AGC Cem, Wieland, Fig. 10).

The above-described procedures can be also performed in cases in which a fixed denture was planned for the rehabilitation of the full-arch (Figs. 11a & 11b, Figs. 12a-c) and in cases where part of the natural dentition is periodontally stable and can be applied as abutments. In these cases, the immediate full denture can be designed as a cover denture. From this cover



tiologic® easyclean ▽ en


tiologic®

easyClean Cleaning – so easy

Bronze sponsoring EAO

European Association for Osseointegration
October 11th–13th, 2012 – Copenhagen
Booth No. B 25

EAO



world innovation

Now possible:
machine preparation of the fully equipped surgical tray

4 GB USB-Stick for free

Get one 4 GB USB-Stick for free

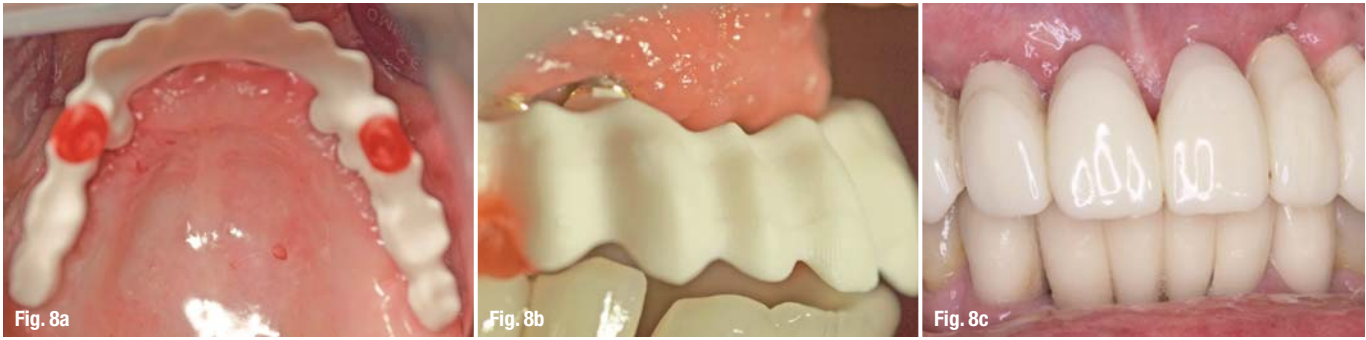Visit us at the EAO 2012 in Copenhagen and get your
4 GB USB-Stick on presentation of this ad for free.

The offer applies exclusively to the EAO 2012 and only while stock lasts. Only one voucher may be redeemed per person.



D DENTAURUM
IMPLANTS

Turnstraße 31 · 75228 Ispringen · Germany · Phone +49 72 31 / 803-0 · Fax +49 72 31 / 803-295
www.dentaurum-implants.de · E-Mail: info@dentaurum-implants.de



Figs. 8a & b_Brial of the mock-up.
Fig. 8c_Temporary fixed denture in situ.

denture, a DentDu could be fabricated and further used as described above (Figs. 13a-c).

Porcelain is a possible material for veneering of fixed-denture frameworks. If the angulation of the implants does not allow for taking impressions in the above-described way and an open-tray impression is preferable, fenestrations can be fabricated into the DentDu (Fig. 14).

_Discussion

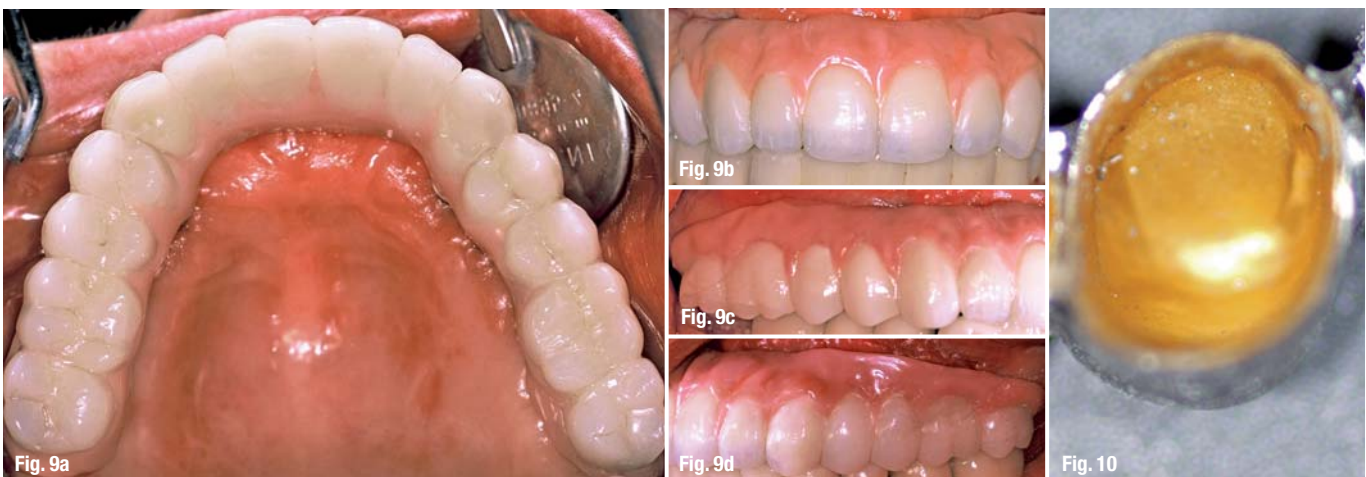The reconstruction of the fully edentulous arch with implant-retained dentures necessitates thorough planning and a precise and passive fit of the suprastructure. A previous study demonstrated that a passive fit between the implant superstructure and the underlying abutments is essential for the long-term success of the implant prosthesis.⁵ To achieve a passive fit, an accurate positioning of the implant replicas in the master cast must be assured. The impression technique and the splinting of the implant copings are factors which may contribute to errors in the final positioning of the implant analogs, thus leading to inaccuracies in the fit of the final superstructure.⁵⁻¹⁰ Furthermore, the angulation or proximity of the implants may inhibit proper seating of the impression copings and/or caps, which may also have a detrimental effect on the registration of the implant position.¹¹

The precise recording of the maxillo-mandibular, e.g. interocclusal, relationship is a prerequisite for achieving proper occlusion and a successful treatment outcome.^{1,10} The initially delivered denture allowed for the correction of the interocclusal relationship, tooth shape and color and angulations during the entire healing period. In this way, the patient was able to acclimatize to the function and esthetics of the denture. In the method described in this report, an accurate impression and recording of the full denture was achieved by using a duplicate as a custom tray for the impression. Therefore, it was not necessary to repeat all the steps usually needed for recording the interocclusal relationship, e.g. wax-up, etc., at the time of the fabrication of the final restoration.

If an open-tray impression is preferred, only minor changes to the procedure are necessary. This method is based on a previous publication.¹² In cases such as this, it is advisable to fabricate two DentDus. The impression can be taken by the first DentDu ; the second DentDu is used for the remaining steps. Customized abutments are applied instead of a bar, galvano copings allow a precise transfer coping, and secondary telescopes as well as different technologies are employed for the transfer of implant positions and for the construction of the superstructure.

Customized implant abutments allows for better angulations and shape, for improved occlusal force

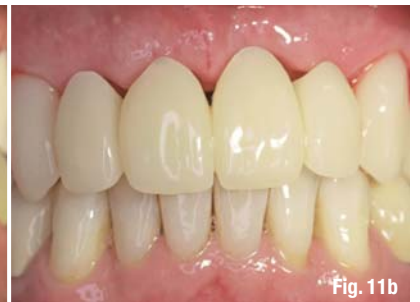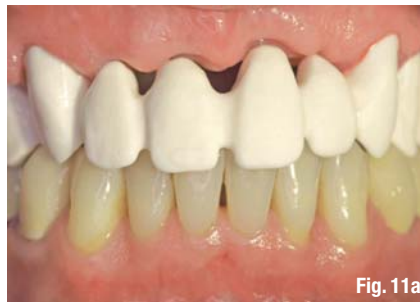Figs. 9a-d_Final telescopic crown retained implant denture, palatal; (Fig. 9a), anterior teeth (Fig. 9b), right side (Fig. 9c), left side (Fig. 9d).
Fig. 10_Placement of the electroformed copings into the frame.



transmission from the crown to the implant and the bone, and also for facilitating the fabrication of an esthetically pleasing implant-supported denture. Ways in which abutment design contributes to improved esthetics include changes in the location of the crown and changes in the dimension and/or form of the restorative platform.

Additionally, features of the abutment design contribute to the health and dimensional stability of the soft tissue. Current attempts to objectively define implant-restoration esthetics have focused on peri-implant mucosal parameters.^{13,14} The introduction of the UCLA abutment provided a custom solution for implant restorations. This direct-to-implant restoration concept provided adaptability. Through waxing and casting, the height, diameter and angulations can be addressed in order to provide a wide range of clinical solutions for problems associated with limited interocclusal distance, interproximal distance, implant angulations and related soft tissue responses.¹⁵

The customized implant abutments served as primary telescopes, and the electroformed copings served as secondary telescopes in cases where a removable denture with telescopic crowns was used as the attachment. Electroformed gold copings are as-



sociated with several advantages, in conjunction with both removable and fixed restorations. The galvanofforming and electroforming process yielded a precisely-fitted secondary coping for the implant abutment with a gap of only 12–30 μm . The gold electroformed coping saves space and is made of high-quality material.²⁻⁴ Using gold copings for the impression allows for the exact transfer of the form, angulations and position of the inserted customized implant abutments.

With the help of the milled mock-up, the future fit of the CAD/CAM fabricated framework can be evaluated and necessary changes in the shape of the restoration and occlusion can be made. Making these changes on the mock-up was easier and less time

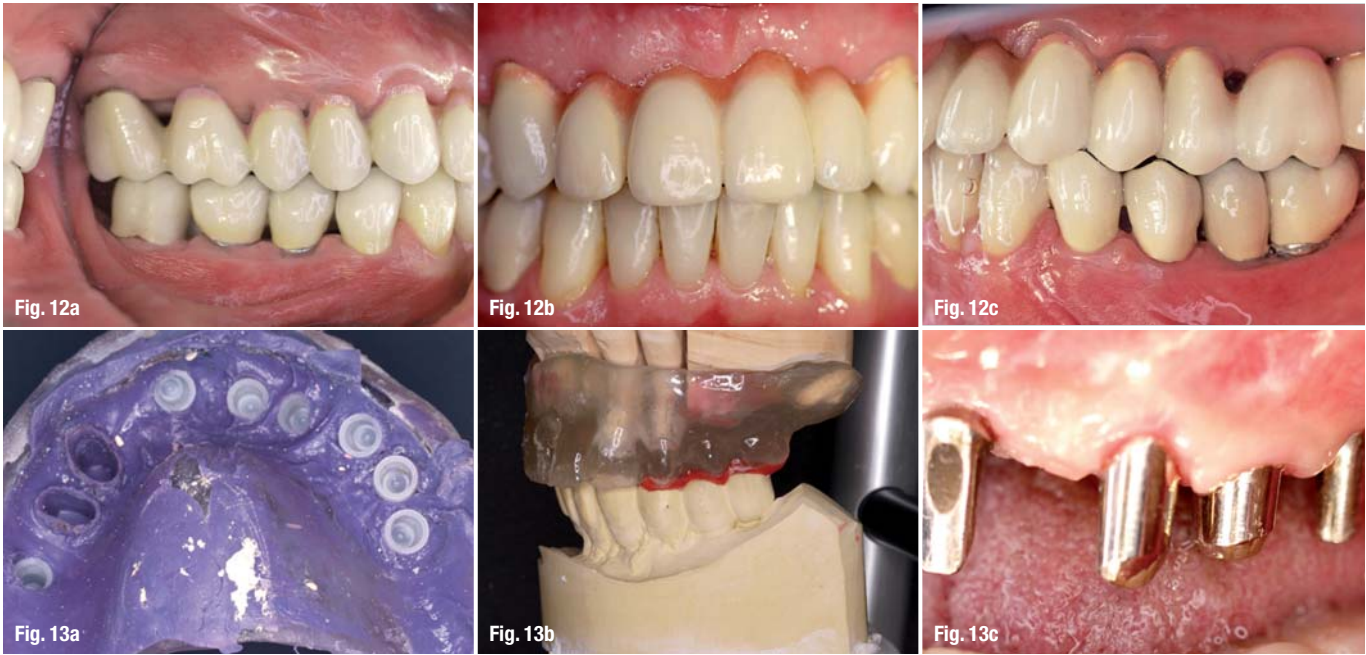
Figs. 11a & b A case of fixed implant retained denture for the maxilla full-arch rehabilitation: trial of the mock-up (**Fig. 11a**) and the milled temporary fixed denture is placed on the abutments (**Fig. 11b**).

AD

become an author
for "implants"



Please contact Claudia Jahn
✉ c.jahn@oemus-media.de



Figs 12a–c A case of fixed-implant retained denture for the maxilla full-arch rehabilitation, right side (Fig. 12a), anterior area (Fig. 12b), left side (Fig. 12c).

Figs. 13a–c Impression of a case with natural dentition (teeth #11 and #12) and implants. Master cast in the articulator with a duplicate of the over-denture in place (Fig. 13b). Gold copings fixed on the remaining teeth #11 and #12 and customized implant abutments mounted on the implants (both of them served as primary telescopes, Fig. 13c).

consuming than making them on the metal framework itself, and it was then possible to transfer them directly to the final framework. Furthermore, the mock-up almost “splinted” the electroformed gold copings during the impression, allowing for the exact transfer of the abutment position. At the same time, the vertical height and interocclusal relationship were recorded. The delivery of a milled temporary restoration permitted a slow and non-progressive loading of the implants, which then leads to bone remodeling.¹⁶ Abutments were left in place after mounting. Combined with the fabrication of a new cast, this further decreased the risk of inaccuracies during the transfer process.

Conclusion

The method described here can be used for full-arch restorations with both fixed and removable implant supported dentures. Accurate impressions can be accomplished and occlusion, vertical dimensions, as well as implant positions can be transferred while

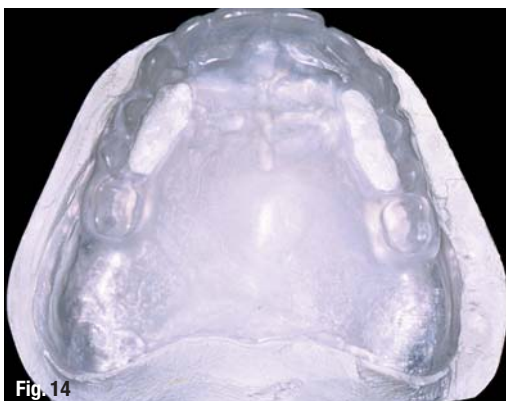facilitating the full-arch restoration process. In addition, this technique resulted in a reduction of the required chair time

Disadvantages of this technique lie in the fact that the quality of laboratory technician’s work meets higher demands than usual, and that the clinician also needs to acquire some additional skills. Further disadvantages of this method include the need for a highly qualified technical lab and higher technical costs relative to those associated with prefabricated titan implant abutments.

To date, this method has not been applied in conjunction with immediate implant loading. However, dentists and patients have come to expect this level of rehabilitative accuracy, precision, long-term success and aesthetics.

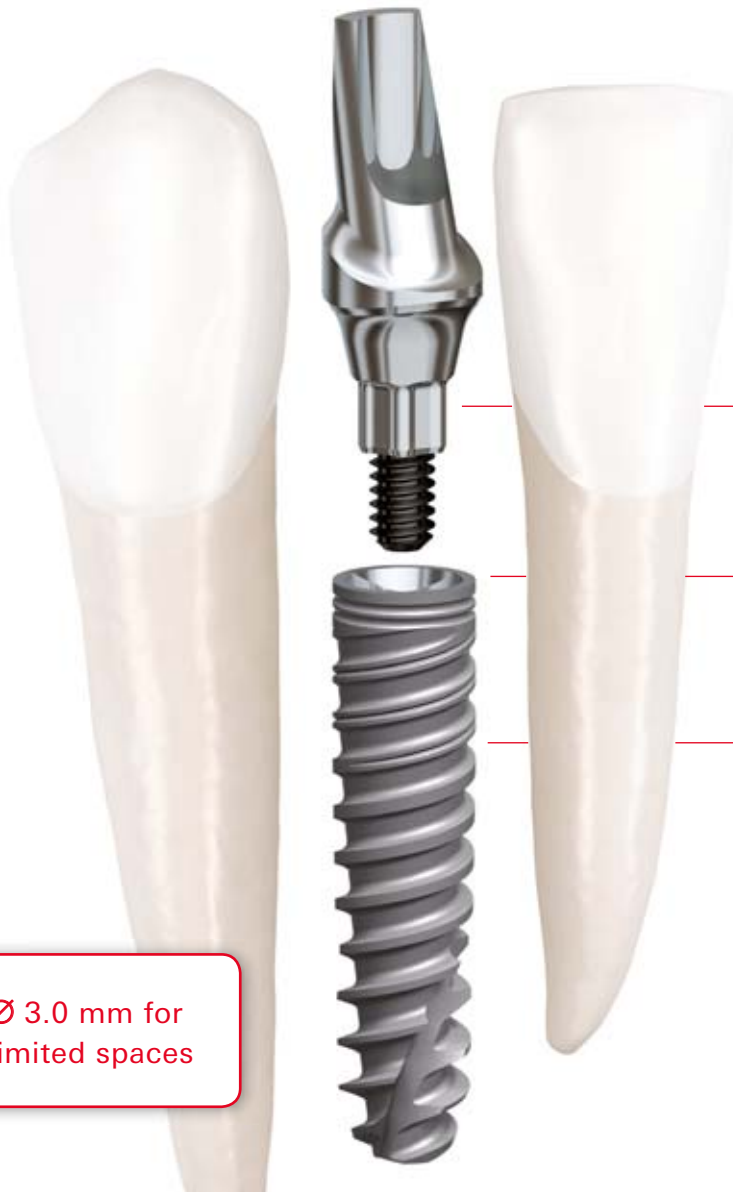
Editorial note: A complete list of references is available from the publisher.

Fig. 14 DentDu modified for open-tray impression technique.



_contact	implants
<p>Prof Dr Gregory-George Zafiropoulos Blaues Haus Sternstr. 61 40479 Düsseldorf, Germany</p> <p>zafiropoulos@blaues-haus-duesseldorf.de www.blaues-haus-duesseldorf.de</p>	

Smaller and stronger.



Safe implant placement in areas with limited space.

Maximum material strength and strong sealed connection.

High initial stability and bone preservation.

NEW

Ø 3.0 mm for limited spaces

ADMED.com

It's called NobelActive 3.0. This unique implant is the ideal solution for narrow spaces in the anterior region. The drilling procedure is designed to retain as much bone as possible, while the implant body and thread design condenses bone during insertion enhancing initial stability. The sharp apex and cutting blades enable you to adjust the implant position for optimal restorative orien-

tation. Together with the strong sealed connection and built-in platform shifting, NobelActive 3.0 allows you to safely produce excellent esthetic results. After 45 years as a dental innovator we have the experience to bring you future-proof and reliable technologies for effective patient treatment. **Their smile, your skill, our solutions.**



Visit nobelbiocare.com/active3



Time-saving debridement of implants with rotating titanium brushes

Authors Dr Dirk U. Duddeck, Dr Viktor E. Karapetian & Dr Andrea Grandoch, Germany

Introduction

The mechanical debridement of implants as part of peri-implantitis therapy is time-consuming and tedious. The use of rotating brushes with titanium bristles can result in significantly shortened treatment times. Compared with mechanical curettage, they ensure a gentler and more even treatment of the exposed portions of the thread.

Despite—or because of—the success story of oral implantology, peri-implantitis, associated with significant bone loss, is on the rise. A meta-analysis performed by Berglundh et al. in 2002 (which included periimplant mucositis) showed that the incidence of periimplant disease for different implant systems was between 5 and 8 per cent.¹ In fact, the prevalence of periimplantitis alone is assumed to be between 10 and 20 per cent today.^{2,3} The biological response to the implant and the implant's ability to integrate with the surrounding tissue are determined by the structure of the implant surface. Roughened implant surfaces to enlarge the bioactive surface are a clinically proven method and have been accepted by all manufacturers as the basis for

successful osseointegration of their implants.^{4,5} Advanced periimplantitis invariably leads to bone loss and, hence, to the exposure of implant surfaces, including threaded parts. One of the most frequently discussed topics in oral implantology today is that of finding the right treatment approach in this situation. In cases with pocket depths of more than 6 mm, surgical access followed by mechanical cleaning and decontamination of the exposed portions of the thread is certainly an option. Following bone loss, the implant surface is generally covered by concrements, necrotic bone and inflammatory tissue. Proper debridement thus requires mechanical cleaning of the implant surface to remove concrements and granulomatous tissue.

This mechanical debridement is generally performed by specific curettes. The vertical movements of these curettes, which have only limited contact with the implant thread, are not very efficient. It stands to reason that rotationally symmetrical, screw-shaped structures like those of most contemporary implants are more rapidly and more evenly debrided with rotary instruments (Fig. 1). Rotating brushes are capable of adapting more closely

Fig. 1 Mounted titanium brush (PeriBrush™, Tigran Technologies).

Fig. 2 The titanium brush was designed to match the implant architecture.

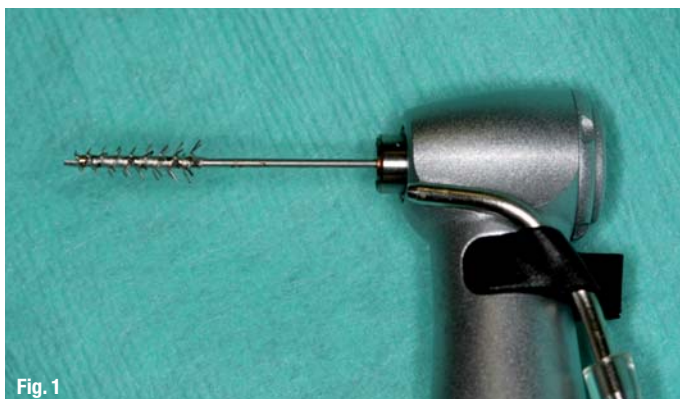

Fig. 1



Fig. 2



Fig. 3



Fig. 4

to the architecture of the implant. In a previous study⁶ we have analyzed the effect of rotating titanium brushes (PeriBrush™, Tigran Technologies; Fig. 2) on different types of implant surfaces. Implants with an anodized surface and implants with a titanium-blasted surface were examined with a scanning electron microscopic (SEM) and with a Keyence VHX 600 before and after treatment with a single-use rotating titanium brush as well as before and after curetting. For the purposes of this study, the brush was inserted into an angled hand piece and held against the implant while rotating at 300 to 600 rpm. Only minimal pressure was applied, because excessive pressure can bend the titanium brushes and reduce the cleaning effect. Under the light microscope, the traces of curettage are clearly visible (Fig. 3), whereas the treatment with the rotating brush results in only barely discernible damage to the implant surface. The brush has an even, slightly smoothing effect on the implant surface (Fig. 4). This is confirmed by the corresponding SEM images (Figs. 5–8).

The topographic effect of the rotating brush on the implants surface and on the brush itself is directly correlated with the horizontal load/force and the duration of the treatment. In the actual study "Clinical parameters for the use of rotating titanium debridement brushes" we analyzed the surface ef-

fects of different loads/forces between 10 and 60 g / 0.1–0.6 N on the surface of sandblasted and acid etched implants.

Four implants were fixed at the apex in Pattern Resin, GC. The Pattern Resin plate with the implant in the middle was fixed in a turning machine and carefully turned down until a complete rotational symmetry with the centered implant was achieved (Fig. 9). Two screws fixed the Pattern Resin plate with the centered implant on a motor driven plate of aluminum (Fig 10).

To ensure the different horizontal loads/forces onto the KaVo angel piece and therefore on the rotating PeriBrush, a spring based construction (spring steel wire) with defined distances of impression under load was used. The spring length shows a linear correlation to the load/force as seen in Fig-ure 11.

Fixed in an angle piece (KaVo), the Tigran™ PeriBrush™ transfers a defined horizontal load/force on the implants surface according to the predefined length of the spring. The angle piece works with additional rinsing at 600 rpm and has been applied vertically against the implant at an angle about 20–30 degrees, so that the bristles make contact with the circular side of the implant and also clean in be-

Fig. 3 Implant following mechanical debridement using a curette (light microscope, ×20).

Fig. 4 Implant following mechanical debridement using the titanium brush (light microscope, ×20).

Fig. 5 Implant surface before treatment (SEM, x100).

Fig. 6 Implant surface after curetting (SEM, x100).

Fig. 7 Implant surface after debridement using the titanium brush (SEM, x100).

Fig. 8 Implant surface after debridement using the titanium brush (SEM, x200).



Fig. 5

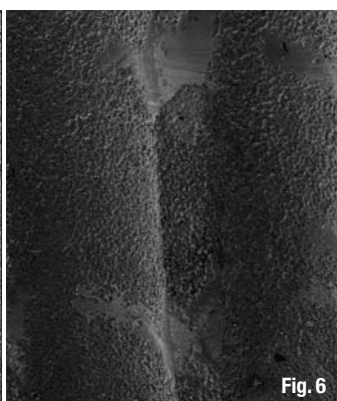


Fig. 6

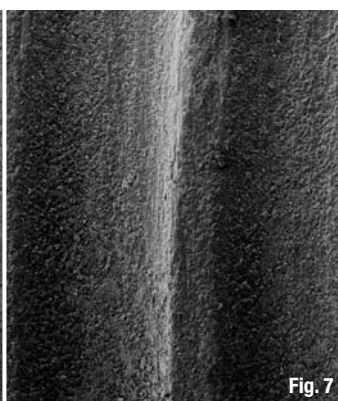


Fig. 7

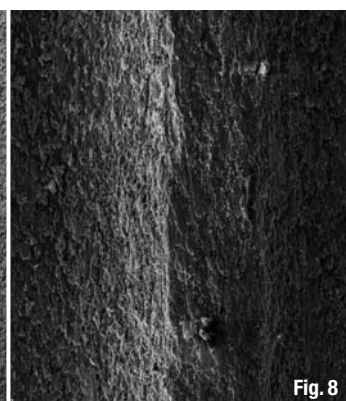


Fig. 8

Fig. 9_Turning machine with centered implant.



Fig. 9




Fig. 10

Fig. 10_Spring based horizontal load and overview of the lab situation.

Fig. 11_Spring length shows a linear correlation to the load/force.

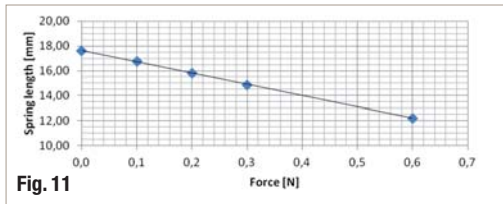


Fig. 11

tween the threads (Fig. 11). The round aluminum table rotated at 20 rpm (clinical measured average turns with the rotating device around the implant).

bending, but not rupturing the fine titanium bristles (Figs. 12–14).

Another advantage of the PeriBrush, beyond the gentler and more effective cleaning of the implant surfaces, is the significantly shortened treatment time. The implant surfaces can be cleaned within a few seconds under continuous irrigation with sterile saline solution (Fig. 15).

Samples of the Tigran™ PeriBrush™—before and after use—and dental implants with sandblasted-acid-etched titanium surfaces before and after the treatment with rinsing were investigated by scanning electron microscopy (SEM) after different loads/forces and treatment time. The load/force of 20 g/0.2 N for 60 seconds is the suggested and recommended normal treatment case and 60 g/0.6 N for 120 seconds of treatment time, as this load/force is the suggested worst case scenario.

Editorial note: A list of references is available from the author.

Fig. 12_Tigran™ PeriBrush™ before use.

Fig. 13_Brush after load/force of 20 g/0.2 N for 60 sec.

Fig. 14_Brush after load/force of 60 g/0.6 N for 120 sec.

Fig. 15_Clinical case exhibiting pronounced periimplantitis. Debridement is effected within 60 seconds under continuous saline irrigation.

SEM analysis confirmed the gentle polishing effect to the implant surface with all loads/forces in this study. Loads/forces of more than 60 g/0.6 N and 120 sec of treatment time (worst case) results in minor damage to the brush—caused by an uncontrolled vibration with a “slip-off” of the brush thus

_contact implants

Dr Dirk U. Duddeck
Dr Viktor E. Karapetian
Dr Andrea Grandoch
 Interdisciplinary Policlinic for Oral Surgery and Implantology
 Department of Oral and Maxillofacial Plastic Surgery, University of Cologne
 Head: Prof Dr Dr Joachim E. Zöller
 Kerpener Straße 62
 50937 Köln, Germany
 dirk.duddeck@uk-koeln.de

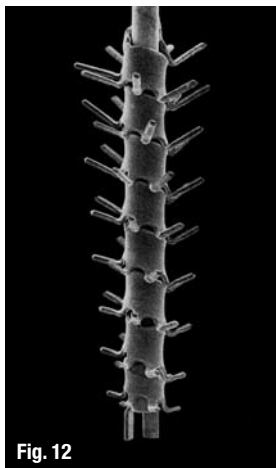


Fig. 12




Fig. 13




Fig. 14

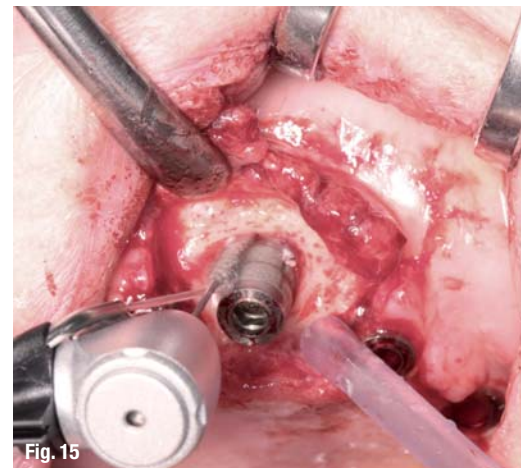


Fig. 15



Giornate Romane

Scientific Chairman

Prof. Dr. Mauro Marincola/Rom
Prof. Dr. Andrea Cicconetti/Rom

Implantologia senza limiti

April 12-13, 2013

Rom, Italy | Sapienza Università di Roma

Speakers

Prof. Dr. Hans Behrbohm/Berlin | Prof. Dr. Andrea Cicconetti/Rom | Prof. Dr. Rolf Ewers/Wien | Prof. Dr. Mauro Marincola/Rom | Prof. Dr. Marcel Wainwright/Düsseldorf | Prof. Mauro Labanca/Mailand | Priv.-Doz. Dr. Dr. Steffen G. Köhler/Berlin | Dr. Georg Bayer/Landsberg am Lech | Dr. Vincent J. Morgan, DMD/Boston | Dr. Marius Steigmann/Neckargemünd | Dr. Angelo Trödhan/Wien | Dr. Ulrich Volz/Meersburg

Organzier | OEMUS MEDIA AG

Holbeinstraße 29 | 04229 Leipzig, Germany | Tel.: +49 341 48474-308 | Fax: +49 341 48474-390 | event@oemus-media.de | www.oemus.com



fax this form to

+49 341 48474-390

Please send me further information on the *Giornate Romane – Implantologia senza limiti* April 12-13, 2013, Rom, Italy

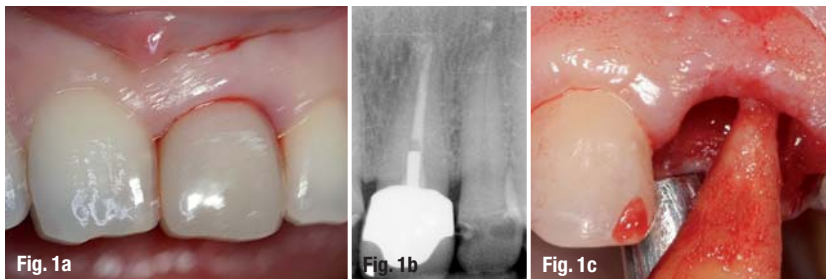
Office Stamp

implants 3/12

Immediate implantation in the anterior maxilla

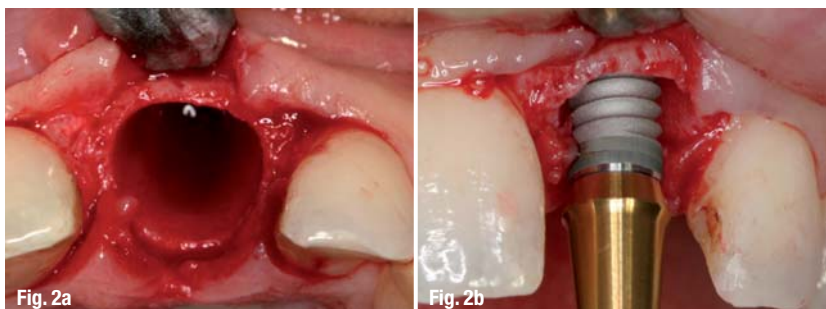
Planning in reverse

Authors_Dr Nikolaos Papagiannoulis, Dr Olaf Daum, Dr Eduard Sandberg & Dr Marius Steigmann, Germany



_Introduction

Endodontic and periodontal problems, such as surgical complications, often place before the professional the dilemma of choosing between tooth preservation and extraction. Correctly performed root planing usually leads to soft-tissue recession. In cases of tooth mobility, periodontal surgery can improve the situation only in the short term. Tooth loss eventually follows after some months or years, not to mention the aesthetic disadvantages of flap elevation and tissue excision after periodontal surgical treatment. Similar outcomes are predicted for teeth following endodontic treatment, particularly if they show complications or have undergone root resection. The combination of endodontic and periodontal problems, as with periodontal-endodontic lesions, endangers the tooth, as well as the bone and the anatomy of the jaw. Lesions such as these can result in severe defects, hampering any subsequent treatment with prostheses.¹



The question one ought to be asking is whether a tooth in the aesthetic zone should be treated until all treatment options have been exhausted or whether the extraction of this tooth at the right time could increase the success and aesthetic outcome of the implant treatment. The extraction of a tooth in the aesthetic zone immediately solves the inflammation problem, but the difficulties only begin at this point. There are many aspects to take care of in order to achieve aesthetic success. Analysis of hard and soft tissue, the implant system, time of implantation, flap design and closure of the area, implant position, implant dimensions, temporary treatment and prostheses are all factors that influence the treatment outcome massively.

_Case history

A 34-year-old female patient visited our practice two years ago, with complaints about her maxillary central incisor (tooth #21). The tooth had been treated endodontically eight years before. Five years later, the tooth had been retreated owing to complaints and she had undergone root resection a year later. Afterwards, an intra-radicular post and a metal ceramic crown had been placed.

At the time of the patient's first visit, the tooth was mobile, bled from the periodontal gap during brushing and caused pain, resulting in headaches. Considering the extended period for which the patient had been struggling with this tooth, a quick and effective decision had to be made.

_Findings

There were no general pathological findings. Clinically, we found a Grade I mobility in tooth #21, a mobile crown on tooth #21, and a bleeding on probing score of 3. The sulcus probing depth was 2 to 3 mm. The vertical percussion test was negative at this point (Fig. 1). The rest of the teeth exhibited no pathological findings.

The radiological control showed sufficient root filling. The crown was not optimally placed and the intra-radicular post was of insufficient length and diameter (Fig. 1). Our initial suspicion of inflammation at the root proved negative following a second X-ray.

Treatment focus

The replacement of the intra-radicular post and a new crown did not seem to be sufficient treatment. Owing to the caries under the crown, the crown lengthening necessary to establish adequate biological width and the patient's complaints regarding this region, any further effort to preserve this tooth made no sense to us. The aesthetic outcome was another reason to promote tooth extraction. Any further conservative therapy would have resulted in aesthetic deficiencies. The patient also desired an efficient solution that would put an end to the problems in this region. Furthermore, the adjacent teeth only had small fillings at the palatal surface and it would have been a pity to have to prepare them for prosthodontics. Also for this reason, the patient rejected prosthodontic treatment of the adjacent teeth.^{2-5,7}

Our decision was to extract the tooth and immediately place an implant in order to support the soft tissue, influence bone remodelling and offer a temporary tooth replacement without a flipper.^{6,3,7,8,9,10,1} As the maxillary anterior region is an aesthetically sensitive region, we planned for an immediate implantation with simultaneous guided bone regeneration (GBR).^{11,12} As for the prosthesis, we selected a biocompatible metal-ceramic crown for financial reasons.

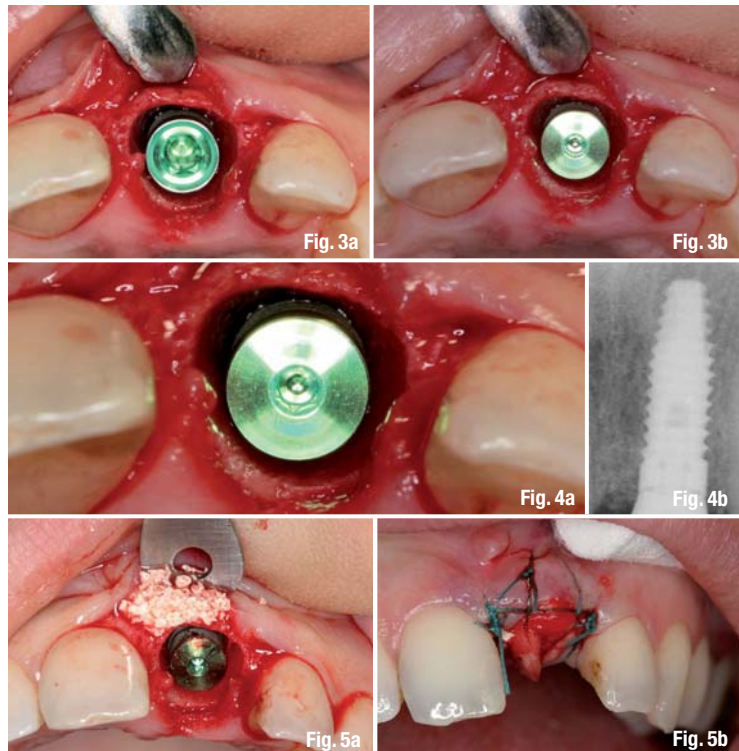
Treatment plan

Professional tooth cleaning and patient instruction

As a standard procedure, the patient received professional tooth cleaning before implantation in order to achieve optimal hygiene conditions. He also received behaviour and hygiene instruction and was encouraged to follow a good oral hygiene routine.

Extraction

The tooth extraction was performed as carefully as possible and the socket was decontaminated with chlorhexidine solution and tetracycline for ten minutes. Although mobile, the periodontal fibres were separated with a periosteal elevator. The tooth was mobilised with the same instrument until an atraumatic post extraction was possible. Together with the tooth, we managed to remove the apical cyst without needing to scale the socket. Careful inspection of the socket walls was necessary to prevent inflamed tissue affecting the GBR. There was also no perforation of the buccal plate (Fig. 1).^{9,13}

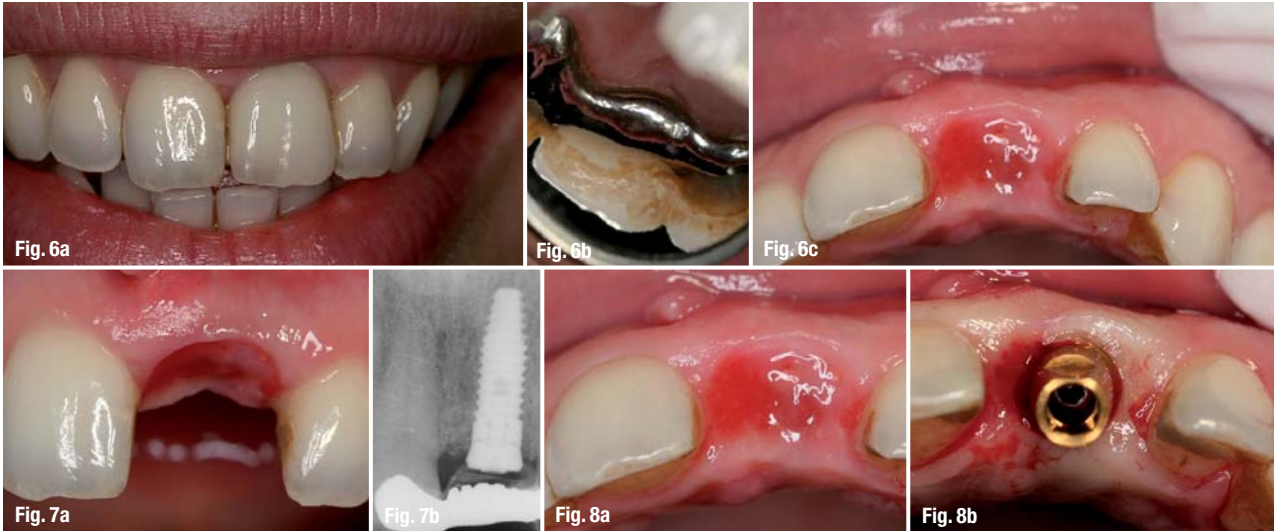


Implantation and guided bone regeneration

The implant we selected for this case was the internal hex Laser-Lok implant (BioHorizons), which is tapered with microgrooves at the implant neck. Our aim was to achieve maximal bone adaptation to the crestal portion and soft-tissue adaptation to the implant neck.^{14,15,10,17-19} We used a periodontal probe to inspect the socket. The socket was rinsed again with chlorhexidine solution before proceeding with the implantation. Apart from the final drilling, the drill sequence was performed with water irrigation. The last drilling was performed at 40 rpm/min and maximum torque in order to decrease the risk of ridge injury.

The gap width was 10.5 mm in the mesial-distal direction and 6 mm from the inner ridge in the oral-vestibular direction. The crestal thickness of the ridge walls was 0.5 to 1 mm (Figs. 2-4).^{6,7,9} Therefore, we decided to use a 4.6 mm implant with a length of 12 mm. Simultaneous to the implantation, we performed guided bone augmentation in order to fill the gap between implant and ridge and to influence bone remodelling during implant healing. The gap between the implant and buccal bone plate was 1.4 mm. Combined with the augmentation material (allograft using maxgraft, botiss) in this gap and on the buccal plate, we planned to preserve at least 2 mm buccally after bone remodelling.

One third of the implant was inserted. Augmentation followed and then we inserted the implant com-



pletely.^{20,6} In this way, we were ensured augmentation of the entire ridge and not only the crestal portion. For GBR, we used autologous bone extracted with a bone scraper (to preserve living osteoblasts) and non-resorbable hydroxyapatite (cerabone, botiss) for 3-D stability. The implant was placed sub-crestally at 1.5 mm in order to prevent under-coverage owing to bone resorption, which is inevitable following tooth extraction.²¹ Although the implant-neck design guarantees soft-tissue adaptation, we selected this kind of implant placement, since we feared unpredictable bone behaviour after so many years of continuous endodontic and inflammatory problems in this region.

Another advantage of this implant system is the all-in-one abutment, which supports positioning control and reverse planning for the prosthodontic treatment as an insertion aid. The implant was placed according to the best surgical position and the prosthetic position. A second all-in-one abutment was shortened to a length of 2 mm and used as a cover screw in order to achieve optimal soft-tissue support (Figs. 5 & 6). In this manner, we conditioned the soft tissue to form the final desired emergence profile.

Owing to the mild but unpredictable inflammation in region 21, we decided against a flap and primary closure of the operating area. The soft tissue was raised buccally in order to place a pericardium membrane (Jason, botiss). The membrane covered the

whole ridge up to the palatal wall, where it was secured between the gingiva and crestal ridge using a 4-0 Supramid horizontal mattress suture (S. Jackson). We placed a collagen fleece over the membrane to prevent proteolytic resorption of the exposed membrane. The fleece was secured with a 5-0 PROLENE criss-cross suture (ETHICON, Fig. 7).

Temporary crown

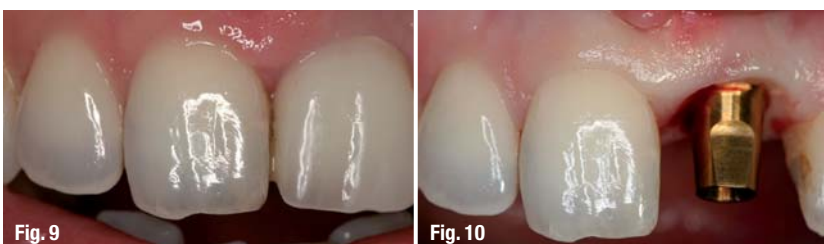Temporary treatment of the gap was crucial. Free granulation of the extraction wound resulted in a high risk of soft-tissue dehiscence. In order to fill the gap, to support and form soft tissue, and to rehabilitate the patient aesthetically, we trimmed the extracted tooth to form a pontic and attached it with flowable composite (Tetric EvoFlow, Ivoclar Vivadent) to the adjacent teeth. After soft-tissue coverage of the ridge, we attached a Maryland bridge to optimise aesthetics. The papilla support was perfect and the outcome until implant exposure was stabilised. The sutures were removed four weeks post-operatively and two weeks after the Maryland bridge had been attached, without having to remove it (Figs. 5, 6, 8 & 9).

Healing phase

During the healing phase, we followed a frequent recall pattern of one, two, three, four, eight, twelve and 16 weeks. In addition to hygiene instructions, the patient was informed about the importance of the control appointments. During the healing phase, there were no complications, inflammation or complaints from the patient.

Exposure

The implant was uncovered after 14 weeks. Owing to sufficient soft-tissue thickness on the labial side, we decided to uncover with a tissue punch. The tissue punch was 1 mm thick. The operation resulted in a soft-tissue height of 3 mm crestally up to the implant neck. The papillae were maintained, and labially the



contours of the bone and the soft tissue were harmonious and at optimum level aesthetically. These findings ensured a highly aesthetic outcome (Figs. 10 & 11).

Pre-prosthetic phase

At this point, we decided against a healing abutment. Assuming that implant transfer, abutment and healing abutment have the same emergence profile, we fabricated the final abutment after impression and inserted it with a temporary resin crown (Trim, Bosworth). The temporary crown had exactly the same form as the final crown and conditioned the tissue for the time needed to fabricate the final crown (Fig. 12).

Prosthetic phase

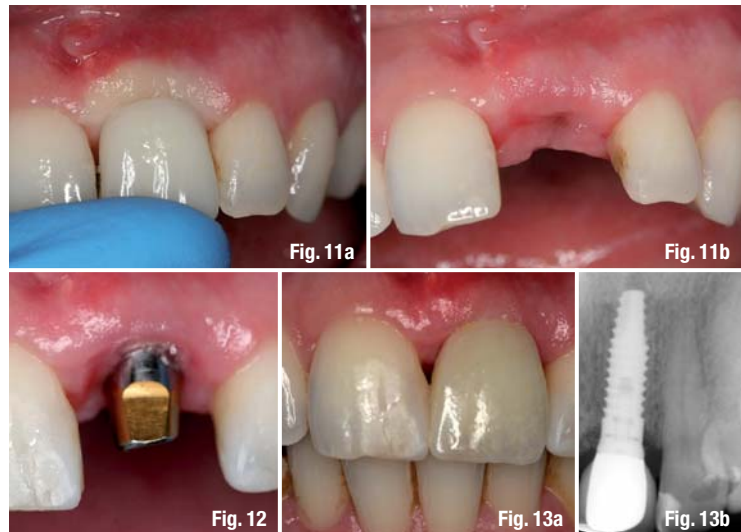
Two weeks after uncovering the implant, we performed the final crown fitting. The abutment length was 5.5 mm and the crown retention part had a length of 4.5 mm. The crown length was 8.5 mm and the distance between approximal contact and crestal bone was 4 mm (Fig. 13). The patient was pleased with the aesthetic outcome.

Recall appointments for clinical and radiological control took place at one week, as well as six, 12 and 18 months. At each appointment, stable conditions in the crestal bone and in the soft tissue were exhibited. At the 24-month follow-up, no recessions or clinical or radiological crestal bone resorption was apparent.

Discussion

Nowadays, we know that osseointegration works and we know how it works. We can also achieve predictable and repeatable results. The correct implant position is crucial for long-term success, and is both a surgical and a prosthetic parameter. No matter how well implants are inserted, grafted or osseointegrated, if the angulation and position are not beneficial for the prosthesis, the outcome will be neither aesthetic nor durable. The clinician must first decide where to place the abutment and decide upon the emergence profile before he performs the surgical part. As implantology becomes an increasingly important treatment option, osseointegration and a firm bite, as well as functional stability, aesthetic and long-lasting results, are more frequently demanded by the patients.

A crucial question has to be asked: now that aesthetics is becoming increasingly important, how much sense do conservative treatments make in cases such as the one described here? Is it better to extract a tooth causing ongoing problems at the right time, rather than trying to preserve it and losing bone and soft tissue? When we wait for too long, we lose bone and soft-tissue aesthetics and limit our implantological treatment options. In this case, extracting the tooth was the cor-



rect choice, as was placing the implant immediately. Seeking to influence bone remodelling by augmentation was also a good decision. Using an all-in-one abutment as a cover screw and scaffold for the soft tissue was also the only way to achieve an aesthetic outcome.

All these aspects, as well as correct positioning, prosthesis and recall, are factors that must be planned before surgery. Reverse planning is very important. If the planning is correctly structured, the surgical part entails only a drill sequence, especially when using computer guidance. Patients do not only want to eat with their teeth, but they want them to look good for a long time. This can only be achieved if we choose the right system for each patient, customise our operating protocol according to each individual situation, decide first where we want to place the abutment for perfect prosthetics and then manipulate the soft tissue without a scalpel. We can preserve the crestal bone by both adequate surgical bone treatments and soft tissue.

Each technique works well within its specific range of indication. The correct decision with regard to which technique to use, when and for which patient is the key to success. In addition, collaboration between surgeon, prosthetic specialist and technician is necessary to achieve the desired result.

_contact

implants

Dr Nikolaos Papagiannoulis

Heidelberg Clinic for plastic and
cosmetic surgery
proaesthetic
Brückenkopfstraße 1/2, 69120 Heidelberg

Tel.: +49 6221 6461-0
Fax: +49 6221 6460-20
www.proaesthetic.de

Fixed full arch metal-free prosthesis on four SHORT[®] implants

Authors_Dr Mauro Marincola, Italy, Dr Vincent J. Morgan, USA, Angelo Perpetuini & Stefano Lapucci, Italy

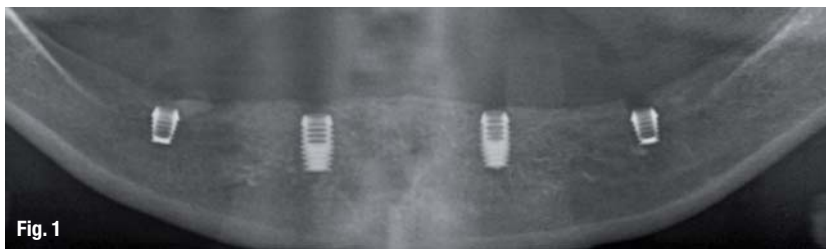


Fig. 1

Introduction

The concept of having only four SHORT[®] implants for the support of a fixed full arch non-metallic prosthesis (Trinia[™]), a CAD/CAM fiber reinforced resin, was first executed in 2010. The clinically based results performed in three different implant dentistry centers are showing clinical success because of Trinia's inherent mechanical and clinical properties. Another factor were the 360 degrees of universal abutment positioning provided by the Implants Locking Taper connection (Bicon[®]), which gives the opportunity to use the Trinia[™] prosthesis to orient and seat the abutments in the well of the implants. The Trinia framework may be covered with either customized poly-ceramic indirect composite material or by conventional denture teeth and resin.

In the following case presentation, we want to show how short implants have been successfully used to restore severely atrophic mandibles without the use of difficult bone augmentation procedures and complicated prosthetic suprastructures in the past decade.

Material and methods

Bicon Dental implants (Bicon LLC, Boston, MA, USA) were used for the reconstruction of the case, combined with a CAD/CAM fiber reinforced resin framework (Trinia[™]) and conventional denture teeth and resin prosthesis. Bicon implants can be characterized by their special macro-structure, including a root-shaped design with wide fins called plateaus, by a sloping shoulder and by a well which holds the abutment post by means of a Locking Taper connection.¹

The plateaus are of particular importance for the biomechanical performance, allowing SHORT[®] implants with a wide diameter to be used in any position in the oral cavity. Their insertion into the osteotomy, which has been prepared using atraumatic drills rotating at 50 rpm, is executed by using mechanical pressure. The countless micro-retentions created on

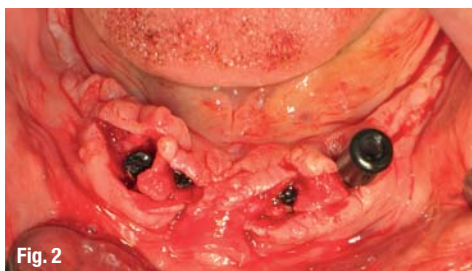


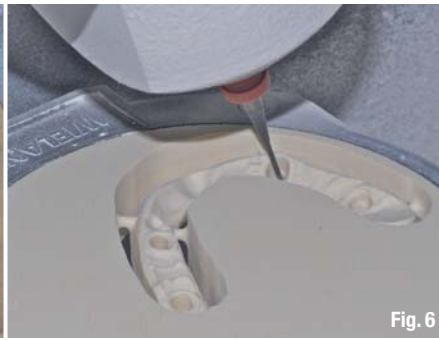
Fig. 2

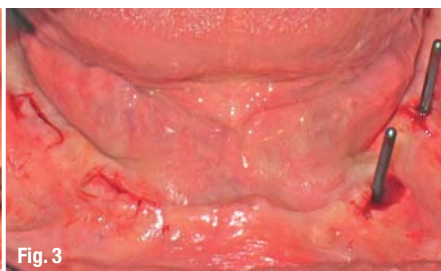

Fig. 3

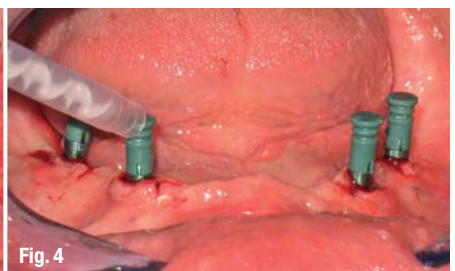
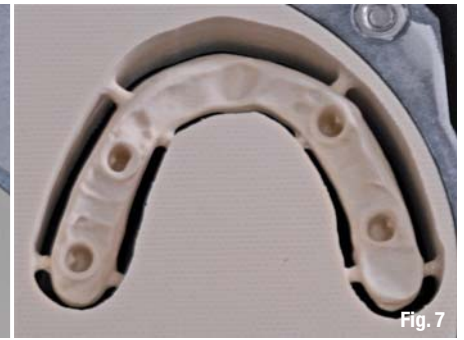
Fig. 4



the surface of the fin edges with the walls of the osteotomy ensure primary stability of the implant in the implant site. Furthermore, the wide spaces between the plateaus avoid vertical compression on the bone walls and rapidly collect the clotted blood, allowing rapid bone formation without the classic macrophagic and osteoclastic processes of bone resorption taking place. Thus well defined bone is formed, with haversian canals and blood vessels which enable continuous bone remodelling around the implant/bone contact surface. This ensures stability of the implant in any situation involving biomechanical stimulus.²

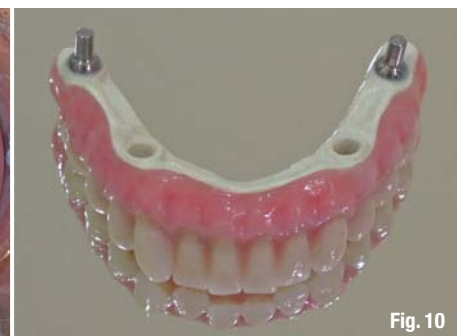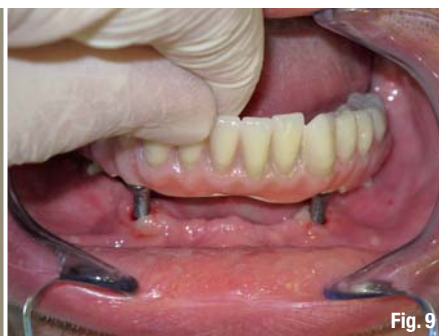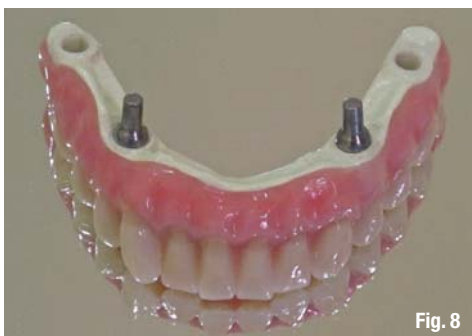The sloping shoulder is vitally important for the preservation of crestal bone after implant osseointegration and for implant function. The Bicon implant design offers platform switching with a neck which converges from the widest diameter of the first plateau, to 2 or 3 mm towards the crestal zone (converting crest module). In our patient, we used implants 5 mm in diameter, but the space taken up at crestal level is only 3 mm. This ensures bone augmentation above the neck, also because the implant is seated at least 1 mm below the crest during the first surgical stage. This allows the above structures, such as the crestal bone, periosteum and epithelium, to grow around the hemispherical base of the abutment and to give sufficient space for maintenance and the growth of the papillae.

Another important factor for obtaining long-term crestal bone stability is the bacterial seal within the connection between implant and abutment. If crestal

bone maintenance and the formation of papillae can only be achieved when the implant is placed in a sub-crestal position and by platform switching at the level of the implant neck, it is also true that this situation can only be accomplished if the connection is hermetically sealed from bacterial infiltration. Without this feature, the placement of a sub-crestal implant without a bacterial seal would result in the rapid spread of pathogens around vital structures, crestal bone, periosteum and epithelium. The result would be bone resorption well below the original crestal bone level.

Bicon's locking taper is a design feature ensuring crestal bone level maintenance around an implant with a convergent sloping shoulder placed sub-crestally.³ The Locking Taper is a precise connection formed by cold welding out of two surfaces of the same material which are brought into close contact with pressure. In this way, the oxidation layers—formed both on the abutment post and on the surface of the implant well—are detached.^{4,5} The prosthetic components (one-piece titanium abutments made from the same surgical grade titanium alloy as the implants) ensure maximum mechanical resistance and optimum biocompatibility. The subgingival hemispheric base geometry is ideal for the stability of peri-implant connective tissues.

The abutments are connected to the implant well by means of a post, which is 2 mm, 2.5 mm or 3 mm in diameter. Implants which are 3.0 mm and 3.5 mm in diameter are suitable for 2 mm posts, while implants of a diameter of 4.5 mm, 5 mm or 6 mm match with



abutments with a 3 mm post. All of the abutment posts have diameters or emergence profiles of 3.5, 4.0, 5.0 or 6.5 mm, suitable for allowing a natural anatomical shape of the soft tissues. Abutment diameters are therefore independent of implant diameters, which means that any implant may host the four different abutment emergence profiles. The different emergence profiles start from the 2 mm, 2.5 mm or 3 mm posts, placed at crestal bone level. The geometry of the abutments provides for platform switching even at a prosthetic level, which is of vital importance in the organization of the connecting tissue and the epithelial layer.

The suprapariosteal space involved in the shift from the connecting post diameter (2–3 mm) to the diameter of the abutment hemisphere (3–6.5 mm), allows a thicker and denser connecting tissue to form, resulting in the optimal preservation of the papilla. In the following case, all the selected abutments have a 3 mm post, as they must connect to the 3 mm wells of the 5.0 x 6.0 mm implants. Abutment post heights, inclinations and diameters are selected in the laboratory in accordance with the position of the implants relative to the anatomy of the alveolar ridge.

Trinia is a CAD/CAM multidirectional fiber reinforced resin material, which despite its light weight is capable of withstanding occlusal forces.

Case report

A 52-year-old male patient, presenting a severely compromised mandibular bone, was treated with the placement of four short implants. Two SHORT® implants (4.5x8 mm) were placed bilaterally at the canine region and two ULTRA SHORT® implants (4 x 5 mm) were bilaterally located at the first molar region (Fig. 1). The implants were placed in a two-stage surgery and they were uncovered after a healing period of three months (Figs. 2 and 3).

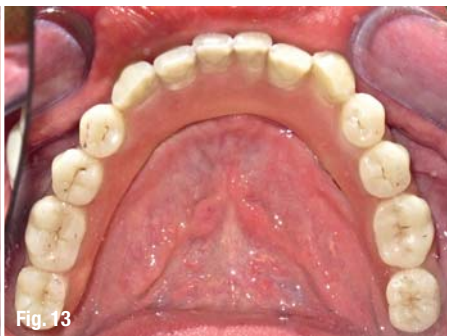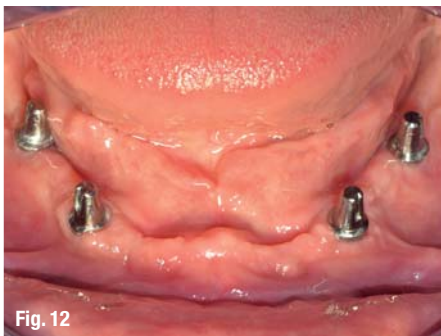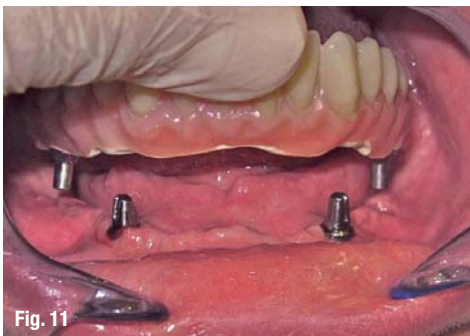Clinically, the prosthetic treatment began with an implant level transfer impression by inserting with only finger pressure a green impression post with its corresponding acrylic sleeve into the 3.0 mm implant well,

prior to recording their position by making an implant level impression with any conventional impression material (Fig 4). Upon the removal of the full arch impression, green impression posts were removed from the implant wells and inserted into an implant analog of the same color before inserting them into their corresponding acrylic sleeves within the impression.

Prior to the pouring of a stone model, a resilient acrylic was applied around the impression posts to simulate a soft tissue contour in the stone model. The stone model was used for the fabrication of a wax bite rim to record the occlusal registrations. After articulation of the models, appropriate abutments with the largest practical hemispherical base were selected and inserted into their corresponding implant analogs within the stone model. Their prosthetic posts were then milled parallel to one another (Fig. 5).

The model with the milled abutments was used to fabricate a light cured resin bar and denture tooth set up for an intra-oral confirmation of the arranged teeth. Once the denture set-up had been clinically approved, a facial occlusal silicone mask was initially formed over the denture wax set up. Prior to forming the lingual silicone mask, indexing or alignment grooves were placed in the facial occlusal mask. After fabrication of the lingual mask, grooves were cut into the stone model to prevent the subsequent entrapment of air, when acrylic was poured into the silicone flask through an anterior cut-away or aperture in the lingual mask. Prior to the removal of the wax denture tooth set up from the stone model, the facial lingual extent of the wax denture tooth set up on the alveolar ridge was marked on the stone model with a pencil.

After the removal of the denture teeth and wax from the resin bar, the teeth were cleaned and lingually roughened or modified prior to being facially glued to the facial occlusal silicone mask with cyanoacrylate glue. An uneven thin application of clear resin was then applied to the cervical area of the teeth on the mask to achieve an aesthetic stratification of the gingival denture resin. The facial occlusal mask and the resin bar were then repositioned on the model to confirm the appropriateness of their contours relative to each other



and particularly to the cervical gingival area of the intended teeth. If necessary, the resin bar may be modified by adding wax or by reducing it with a bur. Prior to its being sprayed and digitally scanned, the space between the resin bar and the ridge area between the pencil lines on the model is filled with a putty material, so that the milled framework can be in contact with the soft tissue of the edentulous ridge (Fig. 6).

After the model with the milled abutments and the resin bar were separately sprayed and scanned, the Trinia fiber resin bar was digitally designed on the computer with a minimum thickness of 7.0 mm throughout, an abutment clearance of 30 microns for cement and with a maximum cantilever extension of 21.0 mm. If necessary, the milled Trinia framework may have been judiciously reduced manually.

After cleaning the milled Trinia framework with alcohol, it was placed onto the milled abutments to evaluate and, if necessary, modify the marginal adaptation of the framework to the abutments and to the alveolar ridge of the model. The ridge side of the framework should be convex without any concavities. Additionally, the Trinia framework was used to confirm both the path of insertion of the prosthesis and the sequence of insertion of the milled abutments on the model. After the sequence and path of insertion were confirmed, the facial, occlusal and lingual masks were repositioned on the model and attached together with cyanoacrylate glue (Fig. 7).

A thin mix of denture resin was poured into the silicone flask through the anterior cutaway or aperture in the lingual mask. Final polymerization was achieved while the silicone flask and models were under hot water, with an air pressure of 3 bars. After polymerization, the Trinia prosthesis was removed from its silicone flask, then finished and polished in a conventional manner. Clinically, after the removal of the temporary abutments from the implant wells, at least two milled abutments were incompletely inserted into the prosthesis. If necessary, they were stabilized with an application of Vaseline, prior to their being transported to the mouth and inserted into the well of their implant (Fig. 8). The loosely fitting abutment facilitated its insertion into the well of the implant (Fig. 9). Once the abutment was initially seated, the prosthesis was removed for the definitive seating by tapping directly onto the titanium abutment. This seating process was continued until all of the abutments were definitively seated (Figs. 10 to 12).

Alternatively, an abutment could have been initially be loosely seated in the well of the implant, prior to the prosthesis being used to orient and seat the abutment in the well of the implant. Final or temporary cementation was achieved by first applying Vaseline over the

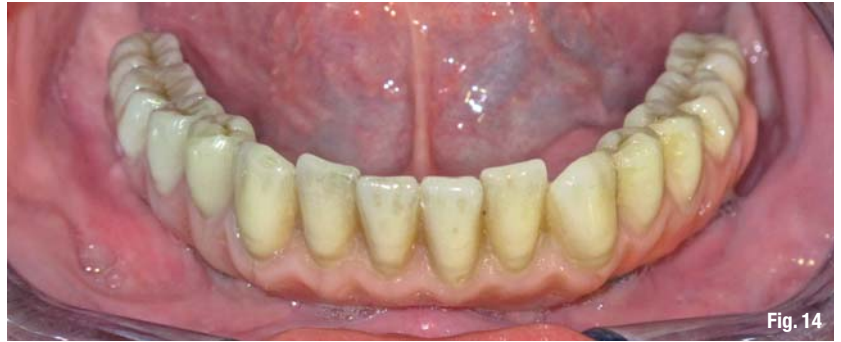

Fig. 14

ridge area of the prosthesis to facilitate the removal of any extraneous cement. Only a minimum of cement was applied to the bores in the Trinia framework before inserting the prosthesis in the mouth. The extraneous cement was blown away with an application of air under the prosthesis. The occlusion was evaluated and adjusted (Figs. 13 & 14).

Conclusion

Regardless of which type of material will ultimately be used to cover the Trinia framework, it was essential to have an anterior diagnostic positioning, wax rim, or arrangement of the intended teeth prior to the fabrication of the Trinia CAD/CAM framework.

In our clinical case, Meyor composite denture teeth were used for the final prosthetic to assure a good bio-mechanical force distribution around the four SHORT® implants. The follow-ups of our patients treated with the described technique was showing a good gingival response and no marginal bone loss around the platform switched implant neck of the SHORT® or ULTRA SHORT® implants (Bicon Dental Implants) used in our case presentation and in 60 other cases treated in three different Implant Dentistry Centers.

This technique of a fixed prosthesis on only four short implants deserves a clinical, long term, evidence-based study because of its low costs and reduced treatment time with minimum morbidity and good patient response.

Editorial note: A complete list of references is available from the publisher.

contact

implants

Prof Dr Mauro Marincola

Via dei Gracchi, 285
I-00192 Roma, Italy

mmarincola@gmail.com

CAD/CAM-based restoration of an edentulous maxilla

Author_Arnd Lohmann, Germany

_Introduction

There is probably no other treatment method that turns our patients' quality of life for the better so critically and predictably as the restoration of the edentulous jaw using implant-supported dental replacements (Alfadda et al., 2009). An implant-based, telescopic bridge should be viewed as the treatment of choice for the rehabilitation of an edentulous mandible (Abd El-Dayem et al., 2009). This is the conclusion drawn from the results of an investigation by Eitner and his colleagues in 2008, especially in anatomically difficult situations, in which an implant-supported superstructure guarantees an adequate prosthetic rehabilitation. Visser et al. showed in 2009 that the implant-supported restoration of the edentulous maxilla also represents a proven and effective treatment method with predictable success.

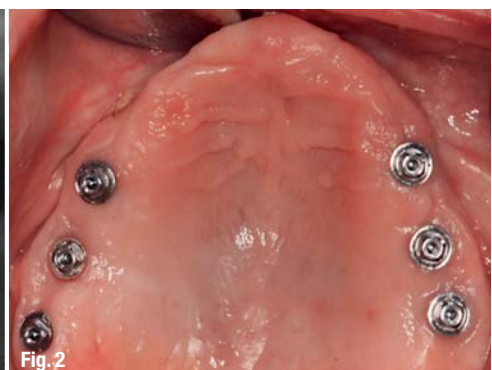
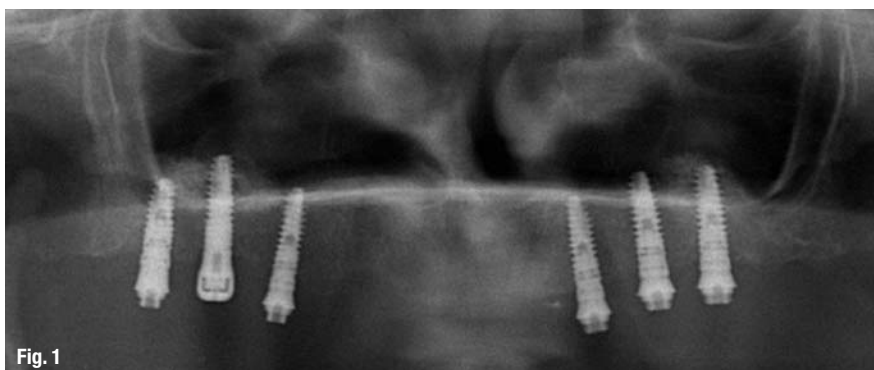
2008). A bar connection and telescopic crowns are favored for the edentulous maxilla, since, in contrast to flexible connections, these can prevent the denture from tilting. Which of these two connection types is to be preferred, however, seems unclear. Implants supporting telescopic crowns exhibit a reduced sulcus fluid rate, which is interpreted as a sign of a slight inflammation of the periimplant tissues. This, however, as Eitner and his colleagues showed, does not lead to a reduced rate of implant loss in comparison with implant-supported bars, even over a longer period. Bar-retained, implant-supported superstructures, on the other hand, are significantly less prone to repair, with the result that, according to the working party under Eitner, no alternative restoration can be identified as to be preferred. In each case, following extensive treatment, the patient treated expects—for him, from a financial and, above all, an emotional point of view—a substantially uncomplicated, mechanically “maintenance-free” rehabilitation. In this respect, restoration using a bar-retained, removable superstructure resembling a bridge is, for us, the first choice. As a matter of principle, we include two interlocking mechanisms to improve the wearing comfort. This prevents a reduction in the retention of the removable


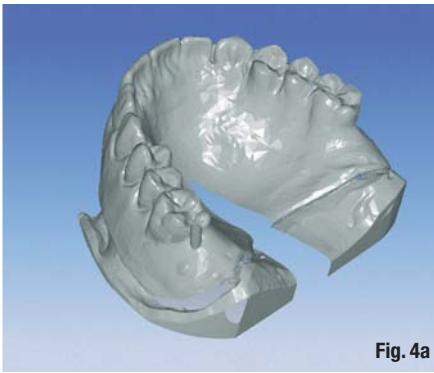
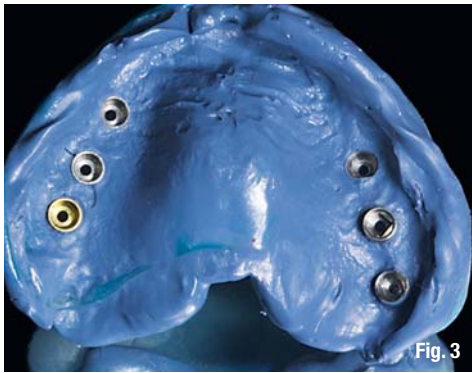
_Connection elements

Various anchoring elements such as bars, double crowns and a variety of prefabricated connection elements for the replacement of teeth have been discussed in the past (Alfadda et al., 2009; Eitner et al.,

Fig. 1_Orthopantomogram post insertion of the XIVE TG implant.

Fig. 2_The Friadent MP abutments transfer the working level from the edge of the bone to a supragingival level.





unit caused by abrasion. Furthermore, the interlocking gives the patient the important feeling of confidence, since unwanted loosening of the restoration is precluded.

Materials

Individually milled bars are usually cast in a chrome-cobalt or gold alloy. A recent option is the central CAD/CAM fabrication of virtually designed bar constructions in accordance to a model scan. This fabrication variant has numerous advantages: on the one hand, the tension-free fit of the bar on the implants is not affected by the shrinkage of the metal caused by cooling. On the other hand, it is possible to manufacture the bar from titanium, which may result in a reduction in gingival inflammation (Abd El-Dayem et al., 2009), since there is a better attachment of the tissues here. The team under Abd El-Dayem further concludes that both advantages together, the absolutely tension-free fit of the bar and the material itself, could lead to even less peri-implant bone resorption, which further improves the long-term prognosis.

Case presentation

A 73-year-old woman, a non-smoker with an unremarkable medical history, was given six implants with two milled bars as anchoring elements. Five XIVE S plus implants were inserted during a simultaneous sinus floor elevation and were allowed to heal submerged over six months. When the implant was

uncovered, a vestibular graft was performed with an apical transposition flap. Due to the less favorable bone volume in region 16, an additional XIVE TG plus implant was inserted subsequently for the purposes of the procedure and was immediately loaded (Fig. 1). The impression for the fabrication of the CAD/CAM bars was made four weeks later on the MP abutments inserted during this consultation (Figs. 2 & 3).

The advantage of the Friadent MP abutments is the transfer of the working level from the implant shoulder—that is, the crestal edge of the bone—to a supracrestal plane. Hence, the apposition of the marginal tissues on the abutment components is not affected by try-ins and other treatment steps. Furthermore, a simple visual check of the bar seating can be made. Figure 2 shows the patient's condition prior to impression making, with inserted Friadent MP abutments. The model fabricated using the MP analogs and a XIVE TG implant analog was sent to the DENTSPLY Scan Center with the temporary construction. The option of displaying and masking various structures, such as the soft tissues, the dental arrangement, the implants and the bar construction, allows a simplified check of the construction proposal (Figs. 4a–4d). This is adjusted to the practitioner's preferences as required. Galvanic bar latches are manufactured on the titanium CAD/CAM-fabricated bars, embedded in the openings for the slide axles. The tertiary structure is cast from a chrome-cobalt alloy. In order to guarantee a tension-free fit for the supported metal base, this was cemented to the bar

Fig. 3 Functional impression with FRIADENT MP impression abutments
Figs. 4 a–d Screenshots of the virtual bar construction with various overlays.

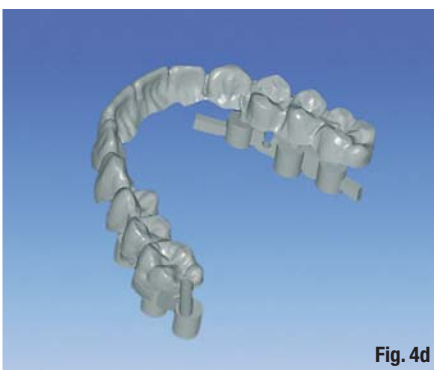



Fig. 5 Working model with bars, bar slides, tertiary structure and inserted slides.

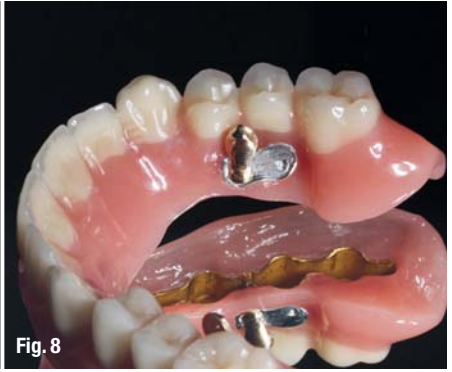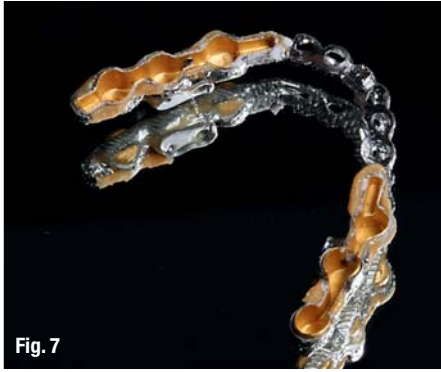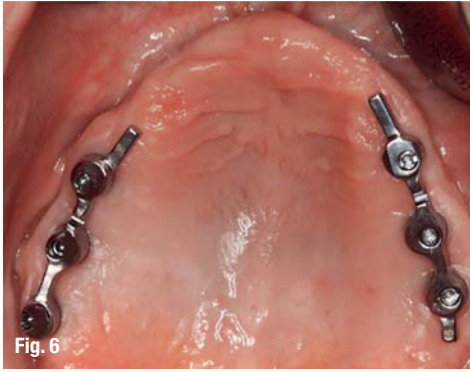


Fig. 6 Titanium bars in situ.
Fig. 7 The metal base was cemented intraorally.
Fig. 8 The finished tertiary structure with open slides.

latches in the patient's mouth. The Genios dentition (DENTSPLY DeTrey) was transferred to the manufactured framework (Figs. 5–8). The final restoration was adjusted to the patient's mouth and inserted (Figs. 9 & 10). The dentition showed excellent translucency. On follow-ups 27 months after the implant insertion and 21 months after the incorporation, the tissue conditions were stable (Fig. 11). The crestal bone level was still located on the implant shoulder. No resorption was observed.

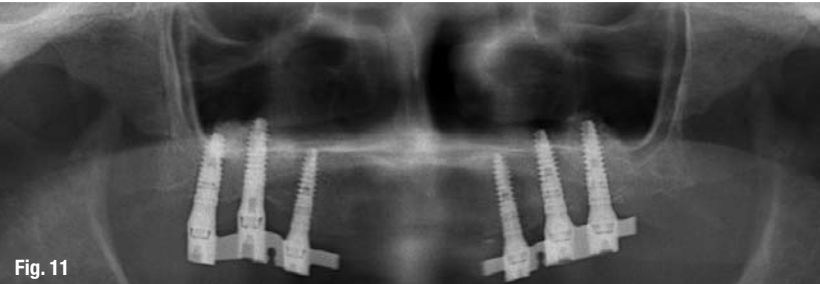
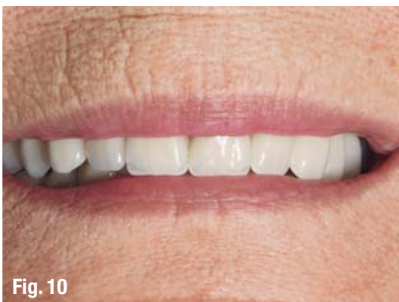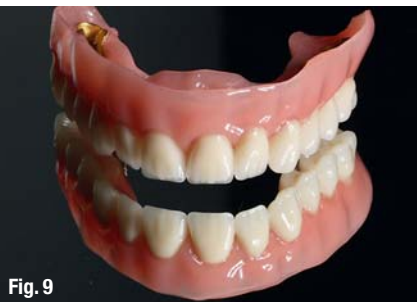who has used this new technique will immediately recognize. Together with the use of titanium as the component material, the tension reduction represents a further advance in the reproducible retention of marginal bone. Furthermore, the bar construction with latches restores the desired level of security and hence vitality to the patient.

Editorial note: A complete list of references is available from the author.

Conclusion

Because of its good primary stability, even in marginal situations, the XIVE implant system is applicable in an augmentation of the maxillary sinus with simultaneous implant placement. Where there is little remaining bone volume, the prerequisite for this is a classic, submerged healing phase without pressure. The option of relocating the connection level to an epigingival level following uncovering reduces the risk of a deterioration of the bone in the region of the implant shoulder due to manipulation. CAD/CAM fabrication of the bar constructions markedly improves the fit of these constructions, which a practitioner

Fig. 9 Frontal view of the finished superstructure.
Fig. 10 The incorporated restoration in the patient's mouth; excellent translucence of the selected dentition (Genios, DENTSPLY DeTrey).
Fig. 11 OPG for the follow-up; stable conditions almost two years after incorporation of the prosthetic restoration.



_about the author	implants
	<p>Dr Arnd Lohmann got his Licensure in Hamburg, Germany, in 2002 and worked as assistant doctor in Oral and Maxillofacial Surgery from 2002 to 2003. In 2003 he completed his dissertation. He has focused on Oral Implantology since 2003 and completed his Master of Science in Oral Implantology in 2007. He is a member of the German Society of Oral Implantology (Deutsche Gesellschaft fuer Orale Implantologie, DGO), the German Association of Dental Implantology (Deutsche Gesellschaft fuer Zahnärztliche Implantologie, DGZI) and the German Association of Oral Implantology (Deutsche Gesellschaft fuer Implantologie, DGI). He works in a partnership and medical practice with Dr Rainer Lohmann in Bremen, Germany</p>

_contact	implants
<p>Dr Arnd Lohmann, MSc Ostpreußische Str. 9 28211 Bremen, Germany</p> <p>Tel.: +49 421 443868</p> <p>mail@zahnarztpraxis-dr-lohmann.de www.zahnarzt-dr-lohmann.de</p>	

International events

2012

AAID 61st Annual Meeting

Washington, DC, USA
3–6 October 2012
www.aid-implant.org

42nd International Congress of DGZI

Hamburg, Germany
5–6 October 2012
www.dgzi-jahreskongress.de

ADF 2012 Conference and Trade Exhibition

Paris, France
27 November–1 December 2012
www.adf.asso.fr

7th CAD/CAM & Computerized Dentistry International Conference

Singapore, Singapore
6–7 October 2012
www.capp-asia.com

BDTA Dental Showcase 2012

London, United Kingdom
4–6 October 2012
www.dentalshowcase.com

3rd Congress of the European Society of Microscope Dentistry

Berlin, Germany
4–6 October 2012
www.esmd.info

World Dental Show 2012

Mumbai, India
5–7 October 2012
www.wds.org.in

Dental World 2012

Budapest, Hungary
11–13 October 2012
www.dentalworld.hu

Expodental Milan 2012

Milan, Italy
18–20 October 2012
www.expodental.it

NorDental – Dental Exhibition and Congress

Lillestrom, Norway
11–13 October 2012
www.npg.no

Dental-Expo St. Petersburg 2012

International Dental Forum
St Petersburg, Russia
30 October–1 November 2012
www.dental-expo.com



Conical internal connections will fuel growth in dental implant market

Authors Dr Kamran Zamanian & Ian van den Dolder, iData Research Inc., Canada

Introduction

The dental implant and bone graft substitute market is the most rapidly advancing segment of dental technology, and leading competitors in this market must consistently develop new products supported by research from scientific and academic organizations to remain competitive. Recent cases have demonstrated that when companies lose a segment of support from the scientific community, their market shares tend to suffer significantly.

The European dental implant and bone graft substitute market has been further challenged by recent economic instability and the eurozone crisis, which has created a consistent demand for lower-cost dental implant products. As a result, many lower-priced competitors have begun to seize larger market shares in almost every European market. In many segments, these competitors are either regional or sourced from overseas markets such as Brazil, Korea and Israel. Regenerative products and barrier membranes have been particularly affected by consumer austerity, as these products are discretionary in many cases. However, a growing number of consumers continue to demand high-quality products, guarantees of service and scientific improvements, which only premium manufacturers are equipped to offer. Conical internal connections is one such recent innovation, and currently constitute the fastest-growing connection type in the dental implant industry.

Many dental implant and bone graft substitute companies have looked to expand their product portfolio or create

new markets while they create package deals to offset competition from rapidly emerging lower-priced competitors. Significantly, many European and US companies involved in this market have begun to invest in rapidly emerging periphery markets such as Turkey.

Increasing prevalence of conical internal connections

Dental implants are connected to final abutments in one of three ways: internal connections, external connections or single-unit devices in which the implant and abutment are already attached. Furthermore, internal connections have two subsegments: butt-joint internal connections and conical internal connections. Research has shown that a lack of intimate fit of the implant in the abutment or movement of the implant can provide an area for bacterial growth. Conventional butt-joint connections provide a connection that can result in micro-movement between the implant and the abutment, creating a pump effect for bacteria into the connection area. When bacteria are present in the micro-gap, they can cause inflammation, tissue recession and bone loss. Recent clinical studies have demonstrated that, on average, conical connections offer a smaller micro-gap than butt-joint connections, in addition to a greater mechanical level of stability. As a result, conical connection types have become hugely successful in the dental implant market, and the majority of leading dental implant manufacturers have introduced conical internal connection products. Conical connection types will continue to represent one of the fastest-growing segments of the dental implant market.

Implants with internal conical connection like the NobelReplace CC shown in this picture have become more popular, according to iData Research. (Photo courtesy of Nobel Biocare, Switzerland)



Industry leaders identify Turkey as one of the fastest growing dental implant and final abutment markets in the world

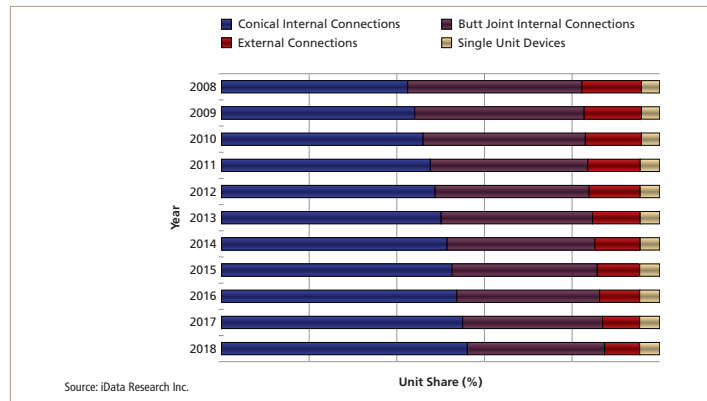
Turkey is one of the fastest-growing dental implant markets, congruent with strong economic growth that weathered the recession far better than the US and nearly any region in Europe. The technology of dental implants in this country has advanced rapidly, as most of the major players in the European market moved quickly to gain a strong market share in Turkey. Additionally, this market benefits from low labor costs, which adds to the incentive for implant companies to establish domestic subsidiaries or local distribution partners, fueling options for consumers. Turkey is also a popular destination for dental tourism, especially among patients from more expensive European markets. From 2008 to 2018, the Turkish dental implant, final abutment and computer-guided surgery market is expected to grow at a compound annual growth rate of 20.4%.

In May 2011, AGS Medikal Ürünleri, the first major Turkish company to produce dental implants, commenced operations in the province of Trabzon, on the coast of the Black Sea. The company was established with an initial 5 million Turkish lira investment. Market experts predict that the company will soon be joined by other Turkish dental implant manufacturers that will offer lower-priced products to compete domestically and later internationally with larger implant companies.

EU medical tourism directive will strongly impact the European dental implant market

The EU directive on cross-border healthcare that comes into force in 2013 will have a strong impact on the European dental implant market. This directive will target the medical tourism market, which is significant, as dental treatment procedures account for nearly half of medical tourism in most major markets. The directive gives patients the right to be reimbursed for treatment they receive in other EU countries. This could lead to more Western Europeans traveling to Eastern Europe, including Poland and Bulgaria, which are rapidly developing the quality of the medical services they offer.

The UK features one of the highest rates of outbound dental tourism, as patients are unaccustomed to large out-of-pocket costs for procedures, owing to the legacy of the National Health Service. Whereas rich patients from developing countries used to come to prestigious hospitals in the UK and elsewhere for treatment, outbound medical travel from the UK has been growing far faster than inbound over the past decade, as UK patients are increasingly traveling abroad for lower-cost care. Figures suggest more than 50,000 citizens of the UK go abroad for treatment annually. The number



of outbound medical tourists from the UK rose by 170% from 2002 to 2009.

Dental implant companies follow success of conical internal connection

Internal connection types as a whole are becoming increasingly dominant in the dental implant market. Conical internal connections and butt-joint internal connections represented 83.4% of implants with an internal connection in 2011. Conical internal connections is the fastest-growing segment of the market and expected to increase at a compound annual growth rate of 10.1% by 2018. NobelActive (Nobel Biocare) was one of the foremost early successes of conical connection types, and was rapidly adopted by consumers owing to clinical results demonstrating its greater stability and smaller micro-gap between implant and abutment. The majority of large companies now offer a conical connection, as this market is expected to overshadow butt-joint internal connections increasingly owing to the greater stability and perceived smaller-diameter micro-gap offered by conical internal connections. Many companies are combining these connection types with tapered shape and surface treatments as the current generation of premium products.

Additional information

The information contained in this article was taken from two detailed and comprehensive reports published by iData Research (www.idataresearch.net), entitled "European Markets for Dental Implants, Final Abutments and Computer Guided Surgery" and "European Markets for Dental Bone Graft Substitutes, Dental Membranes and Tissue Engineering." For more information and a free synopsis of the above report, please contact iData Research at dental@idataresearch.net.

iData Research is an international market research and consulting firm focused on providing market intelligence for the medical device, dental and pharmaceutical industries. Watch its short company movie at <http://www.idataresearch.net/discoveridata.html>.

Manufacturer News

Camlog

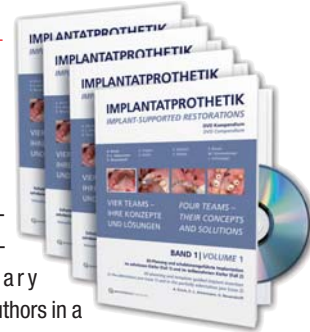
DVD / Blu-ray compendium on implant-supported restorations

Against the backdrop of new technologies, materials and methods, implant-therapy concepts in recent years have greatly changed and improved. This development is promoted and accelerated by the close cooperation of specialists from different disciplines, which is a prerequisite for achieving quality treatment outcomes. The DVD/Blu-ray compendium implant prosthetics "Four teams—their concepts and solutions," which was presented at the 4th International CAMLOG Congress in early May 2012 in Lucerne, documents the team work in an impressive manner.

"Four teams—their concepts and solutions" is a film production, which was co-developed by CAMLOG, a German dental publishing house and four

outstanding, interdisciplinary teams of authors in a time period of two years of work.

The four volumes of the compendium were produced in HD format and are characterized by their high quality as well as their detailed and precise pictures taken from the clinical and laboratory areas.



CAMLOG Biotechnologies AG

Margarethenstrasse 38
4053 Basel, Switzerland

info@camlog.com
www.camlog.com

Nobel Biocare

Global Symposium in New York City

Nobel Biocare will host the Nobel Biocare Global Symposium 2013 in New York. The event will take place from June 20–22, at the Waldorf Astoria in New York City. The Symposium's program will build on Nobel Biocare's mission "Designing for Life: Today and in the future."—"Designing for Life" is Nobel Biocare's commitment to helping dentists treat more patients with better solutions. And it is a commitment to improving the quality of life of every patient through solutions that are designed to deliver fully functional, natural-looking results with the aspiration to last a lifetime.



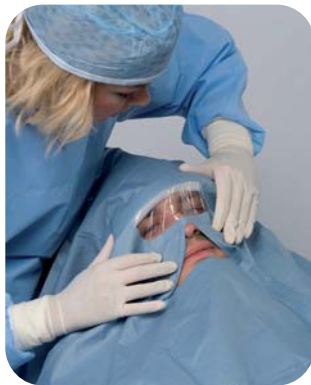[PICTURE: ©BOBBY20]

Omnia

Surgical patient drapes

Omnia offers a complete range of drapes, which are suitable for different applications and treatments, both for covering operating theatre surfaces and for draping and protecting the patient.

Drapes for patient draping are made either of absorbent/waterproof, non-woven fabric or Softesse®, a fluid-repellent, soft, drapable and highly breathable material for complete protection and comfort. Their whole surface is waterproof and they have fluid control systems and self-adhesive areas (self-adhesive U-shaped, hole or side), so as to allow a safe and accurate fixing and enhancing of the range of sterile fields.



side of the triangular opening allows its safe positioning on the nose of the patient. To protect the patient's eyes from any splash or accidental injuries, the drape has a protection window made of a transparent material that also allows an easy and immediate communication between the patient and the operator, thus avoiding unpleasant panic situations. The large size of the drape of 133 x 200 cm makes it particularly indicated for long and complicated surgeries, and the two Velcro strips allow fixation of aspiration tubing.

To cover the patient, Omnia offers a water repellent mono drape with a triangular opening of 11 x 10 cm and a surrounding adhesive strip which enables to fix the drape onto the chin of the patient. An adjustable aluminum band that runs along the upper

Omnia S.p.A

Via F. Delnevo, 190sx
43036 Fidenza (PR), Italy

info@omniaspa.eu
www.omniaspa.eu

Nobel Biocare

P.O. Box
CH-8058 Zurich Airport
Switzerland

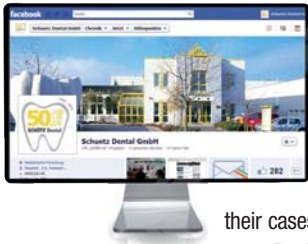info.switzerland@nobelbiocare.com
www.nobelbiocare.com

Schütz Dental



Become a fan on Facebook

Schütz Dental is now on Facebook! Becoming part of the Schütz Dental community brings many benefits. Users can find out how colleagues have increased their business with the IMPLA system and watch free training videos online. Moreover, they can communicate with colleagues and Schütz Dental to find out more about the Complete Digital Workflow including IMPLA 3D implant navigation. Customers can also promote their cases on the Schütz Dental Facebook page. Register for the IMPLA-Newsletter and stay up to date: <http://sdent.eu/newe>



Schütz Dental GmbH
 Dieselstr. 5-6
 61191 Rosbach, Germany
export@schuetz-dental.de
www.schuetz-dental.com

Straumann

Emdogain® 015 – the cost effective treatment option

Straumann is launching the cost effective treatment option Emdogain 015. The new package size allows the benefits of commercially available enamel matrix derivative to be profited from in daily practice.

Approximately 5 – 10 % of the general population suffer from severe periodontitis, a bacterial infection of the periodontium which, in most cases, has a chronic but painless progression.

Progress in biotechnology has led to ready-to-use products containing enamel matrix derivative (EMD). EMD stimulates an accelerated regeneration of lost periodontal tissue (gums, jaw bones and fine fibres).

Emdogain is applied after the surgical revision of the gum and bone pockets, and the gum is sutured. After a couple of weeks, formation of new tissue can be identified.

Straumann Emdogain has been documented in over 400 clinical publications for indications such as intrabony, furcation and recession defects.



With the new Emdogain 015 package, patients with smaller defects and patients subjected to bone grafting procedures can profit from faster wound healing, less pain and swelling due to the well documented effects of the proteins present in Straumann Emdogain.

Institut Straumann AG
 Peter-Merian-Weg 12
 4052 Basel, Switzerland

info@straumann.com
www.straumann.com

Dentaurum

Cleaning made easy: tioLogic® easyClean



The combination of the innovative grid structure with special retaining clips fixes all rotary instruments and accessory components to hold them in position and to ensure that the instruments are completely cleaned with water and cleaning agent. All drills and accessory components can be replaced in the correct position in the tioLogic® easyClean tray as they are used in the implant procedure to remain in the correct order at all times throughout the operation.

SMP GmbH of Tübingen, an independent institute specialising among other things in the testing and validation of medical devices, was commissioned to test and validate the cleaning results. The tests were an impressive confirmation of the preparation results of the instruments and accessory components in the tioLogic® easyClean.

Dentaurum Implants GmbH and Miele Professional have worked together to develop an innovative system solution for efficient and reproducible machine preparation. The heart of this development is the tioLogic® easyClean surgery tray, which enables consistent, outstanding machine cleaning and disinfection results in both dental practices and in centralized preparation centres in hospitals. This not only offers huge savings in time and costs but also significantly increased safety for users with the reproducible machine preparation results.

Dentaurum Implants GmbH
 Turnstr. 31, 75228 Ispringen
 Germany

info@dentaurum-implants.de
www.dentaurum-implants.de

AD

Since our beginnings, we have always been focused on quality and innovation toward the battle against cross - contamination and infections.

In the last 20 years, we have ensured safety and protection to you and your patients, with advanced and reliable products. Tools that represent the ideal solution for who is operating in dentistry, implantology/oral surgery and general surgery.

With Omnia sure to be safe.

OMNIA
 Disposable Medical Devices

OMNIA S.p.A.
 Via F. Delnevo, 190 - 43036 Fidenza (PR) Italy
 Tel. +39 0524 527453 - Fax +39 0524 525230
 VAT: IT 01711860344 - R.E.A. PR 173685
 Company capital € 200.000,00
www.omniaspa.eu



Master of Oral Medicine in Implantology

Author_DGZI

Since 2003, IMC Münster at Münster University has offered a master degree entitled "Master of Oral Medicine in Implantology". This Master Degree is internationally accredited by the "Akkreditierungsrat" in accordance with the "Bologna Criteria". The course consists of a web-based part on the one hand and a high amount of practical training on the other.

As the oldest professional non-profit association in implantology, the German Association of Dental Implantology (Deutsche Gesellschaft für Zahnärztliche Implantologie, DGZI) focuses its activities on the continuing education and training of dentists practicing in the field of implantology. The objective of these activities is the improvement of both quality and quality assurance as well as the safety of therapies in the interest of patients. Furthermore, they aim at providing factual information on existing therapeutic possibilities of implant-based tooth replacement.

DGZI curriculum graduates can now enroll in the 5th "Master of Oral Medicine in Implantology" course offered at special conditions and in English at Münster University since 2004. The international course is based on a cooperation agreement between DGZI/GBOI (German Board of Oral Implantology) and IMC Münster University, Germany. It is designed as an in-service training for practicing dentists and offers continuing practical, university-level education.

Within the field of dentistry, implantology has increasingly emerged as an area of specialization in its own right. The goal of the post-graduate university training course "Master of Oral Medicine in Implantology" for dentists is to provide students with in-depth, application-oriented scientific knowledge and practical skills in the areas of oral surgery and implantology. Its focus is placed on indication, planning, symptoms and surgery, as well as post-operative care, its association with prosthetics, as well as general dis-

eases and other individual disciplines in dental and oral diseases and maxillofacial surgery. The course particularly aims at the connection between theory and practice in the area of invasive surgical procedures. Students will be able to offer state-of-the-art oral surgery and implantology, consistent with forensic ethical standards.

The continuing education provided by the DGZI curriculum is recognized by a reduction of the tuition fee for the "Master of Oral Medicine in Implantology" course by almost one third of the total costs. The master course will have a duration of 24 months for DGZI curriculum graduates.

All conditions outlined in the official examination regulations of Münster University regarding the "Master of Oral Medicine in Implantology" must be fulfilled. This means that written examinations and case documentation must be completed. Case documentation takes place under supervision by DGZI/GBOI and includes the corresponding specifications of indication and documentation regulations (master thesis, defense and expert discussion). A professor serves as mentor for writing the master thesis.

_contact

implants

DGZI—Deutsche Gesellschaft für Zahnärztliche Implantologie e.V.

Feldstraße 80
40479 Düsseldorf, Germany

Tel.: +49 211 1697077
Fax: +49 211 1697066

sekretariat@dgzi-info.de
www.dgzi.de

Celebrating the Triumph of Osseointegration

Author_Frederic Love, Nobel Biocare

In 1952, Per-Ingvar Brånemark discovered the principles of osseointegration in Sweden. Thirty years later, in 1982, the discovery was acknowledged and his subsequent findings were confirmed at an epoch-making meeting of dental authorities organized by George Zarb in Canada.


Yet another thirty years have now passed, and Nobel Biocare is celebrating both these 30- and 60-years anniversaries in Sweden, Canada, and four other locations.

Starting the year-long celebration in the hometown of osseointegration—Brånemark's Gothenburg—Nobel Biocare brought together some of the best-known names in the field on March 21–23. The event began with a surprise entrance from Brånemark himself who delivered advice and thoughts for the future.

Ulf Lekholm then led experts from Scandinavia and the far corners of the world as they exchanged ideas and discussed promising areas for further exploration at this meeting.

Pioneers from the heady days of the Toronto Conference of 1982, such as George Zarb and Ragnar Adell, were honored and other speakers reminded participants of how far Per-Ingvar Brånemark, Nobel Biocare and their band of supporters have brought osseointegration since those days of breakthrough 30 and 60 years ago.

The programs of all five of the remaining Nobel Biocare Symposia 2012 celebrate the origins and



evolution of osseointegration as a practical and trusted treatment modality over the last six decades. Each program will also include lectures on recent advances in treatment, presented from surgical, prosthetic and laboratory perspectives.

3rd Nobel Biocare Congress Hamburg, 15 June, 2012.

Speakers will look towards the future as well, presenting current trends and possible future developments for bone-anchored restorative dentistry.

Under the common theme "Celebrating 60 years of osseointegration and 30 years of international acknowledgement" meetings will be held in Rimini, Italy (October 19–20), with the final symposium planned for Toronto, Canada (October 19–20) where the international breakthrough for osseointegration first took place.

National Osteology Symposium in Bonn

Fully focussed on soft tissue

Author: Verena Vermeulen, Osteology Foundation

_One topic, but many facets—the Osteology Symposium "Soft Tissue Special" on 24 March in Bonn encompassed a broad range of subjects from biological fundamentals to clinical practice.

It was the first time for an Osteology Symposium to be dealing solely with one issue. "Soft tissue management has become more and more important in the recent years, not only for periodontists" explained Prof Søren Jepsen, Bonn, who chaired the conference together with Prof Wilfried Wagner, Mainz. With conferences on the oral tissue regeneration having been dominated by techniques for guided bone regeneration for a long time, now the soft tissue management is taking the spotlight. Prof Wagner explained the awakening interest: "There are some attractive new biomaterials that could replace autologous soft tissue grafts for indications such as recession coverage, vestibuloplasty or gain of keratinized tissue. So, with the 'Osteology Soft Tissue Special' we wanted to provide a comprehensive overview on where we stand today on the soft tissue management and where we are heading." Main questions during the lectures were: Which grafts lead to good results in which indications? What are the opportunities and limitations of biomaterials as compared to free gingival grafts and connective tissue grafts, respectively?

_Differences between gingival and peri-implant mucosa

350 attendees joined the one-day symposium which took place in the former Federal German Bundestag in Bonn. The programme began with a lecture from the world-famous periodontist Prof Jan Lindhe. He described the key differences between the normal gingiva and the peri-implant mucosa. One important difference is the loss of collagen fibres in the mucosa due to tooth extraction and the ensuing resorption of bundle bone: In the peri-implant mucosa, the quantity of blood vessels and fibroblasts is lower, whereas the amount of collagen is higher. Thus, in many respects, the peri-implant mucosa resembles scar tissue.

_Biomaterials versus autologous grafts

Clinical applications followed the biological fundamentals. Firstly, Dr Markus Schlee, Forchheim, and Prof Anton Sculean, Bern, presented new data on the recession coverage. While Dr Schlee focused on single-recession coverage with the coronally advanced flap (modified Zucchelli technique), Prof Sculean demonstrated an advanced technique for coverage of multiple recessions, the modified tunnel technique. Both speakers had conducted their



own studies in which they compared autologous grafts with biomaterials such as the porcine collagen matrix Geistlich Mucograft®. The matrix is not cross-linked and consists of type-one and type-three collagen. It has a bilayer structure, with the compact structure providing protection, allowing its usage in both closed and open integrative healing processes. The spongy structure stabilises the blood clot and facilitates the ingrowth of cells and sprouting of blood vessels.

The data Dr Schlee and Prof Sculean presented show that autologous grafts and the collagen matrix yield comparable results. Although the autologous grafts are the gold standard for recession coverage, the advantages of the tissue substitute material are obvious: patients profit from reduced pain and swelling because none of their own tissue needs to be removed and the operation time is drastically diminished.

Other speakers also compared autologous grafts to tissue substitute materials—for indications like thickening of keratinized tissue, ridge preservation and vestibuloplasty.

Plenty of room for practical training

In soft tissue management, therapeutic success strongly depends on the practitioner's expertise. Thus it is important for him or her to know the material well and to practice the application correctly.

The speakers pointed out that the collagen matrix should best be used in a dry state and should be sutured carefully, if at all. Four workshops and an interactive forum in the afternoon offered plenty of room for training, discussions and experiences with new techniques and materials. At the very site of earlier political discussions, there were now heated debates on the importance of "morphotype" in the choice of therapy and optimal peri-implantitis treatment. There was, however, an agreement when it came to assessing the symposium: it was a real inspiration for everyday practice.

The next International Osteology Symposium will take place from May 2–4 in Monaco—save the date!_



“Quality-oriented implantology”

DGZI Annual Congress in Hamburg

Author_DGZI

Translation_Claudia Jahn/Leipzig



“Getting to know current practical and, more importantly, practicable ways of long-term success in implantology, that's what this year's international annual DGZI Congress is about”, Dr Georg Bach, chair of the board of DGZI (German Society for Dental Implantology) summarizes the congress' motto ‘Quality-oriented implantology—ways to long-term success’. “Just like in the previous years, we expect up to 500 participants from more than ten countries worldwide”, he adds.

To fulfil its motto, DGZI, Europe's oldest scientific society for implantology, has assembled an extensive program for dentists and their practice team on 5 and 6 October in Hamburg.

“We have been able to acquire renowned international speakers, covering topics such as soft-tissue and bone management and digital implantology by means of concepts from implant prosthetics”, Dr Roland Hille (Viersen, Germany), vice president of DGZI and scientific

coordinator of the congress, informs. “Exchange of information with colleagues and practical advice are of particular importance to the DGZI”, he continues.

Participants of previous congresses already know that international speakers inspire the audience with their detailed knowledge on the first congress day. They are also ready to answer any questions posed by their audience. The organisers also offer simultaneous translation during the international panel discussion. The second congress day is going to be equally exiting when Prof Dr Adnrea Mombelli (Genève University, Switzerland), Prof Dr Anton Sculean (Bern University, Switzerland) and Prof Dr Herbert Deppe (Munich University, Germany) face questions during the special podium and debate on Saturday.

“With periimplantitis, we focus on one of the most significant topics with regard to the long-term success of dental implants”, Dr Hille is convinced. Furthermore,





early birds will be rewarded if they arrive at the Hanseatic city already on Friday morning, since this is the time when "combined theoretical and demonstrational courses will be held and various topics are discussed. Moreover, we recommend visiting the dental trade fair, which presents more than 80 exhibitors, to gain direct information on products and their application or participate in one of the ten company workshops offered".

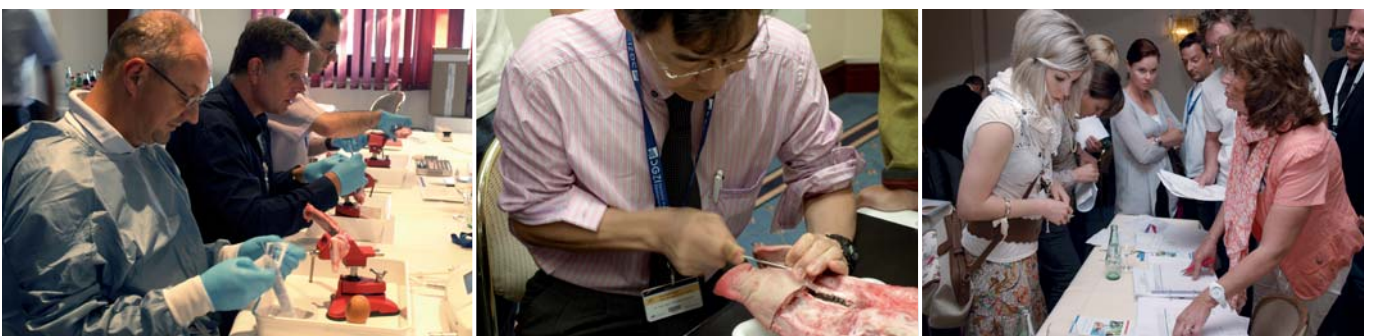
Lecturer Dr Gregor Petersilka (Würzburg, Germany) will present the state of the art of diagnosis, prognosis as well as surgical and non-surgical periodontitis therapy for implantological assistants in his compact seminar "Practical Periodontology" on Friday morning. "By noon, the practice team will have problems to decide which panel to attend", Dr Hille comments.

While the „Mainpodium" is held to discuss expert information for qualified dental employees (prophy-

laxis, caries, mucosa change, oral cancer prevention, periimplantitis, among others), the GOZ seminar presents the "most important changes in the GOZ (German Scale of Fees for Dentists) paragraphs, the handling of new forms and the realization of GOZ-factors including the relevant explanation", Dr Hille explains.

Saturday will be dedicated to a seminar on the profession of sanitation commissioner as well as a seminar about the "Vocational training as a quality management official". A multiple choice test will be held to measure the success in learning.

For more information, please download the programme as well as the registration form via www.DGZI.de. "DGZI also welcomes attendees on short notice who can register for the DGZI Annual Congress directly at Elysee Hotel Hamburg", Dr Bach adds.



42.

INTERNATIONAL ANNUAL CONGRESS OF THE DGZI

October 5–6, 2012
Hamburg//Grand Elysee

Quality oriented implantology—
Ways to long-term success



Gold Sponsor:
otmedical

Silver Sponsor:
straumann

Bronze Sponsor:
**LABORATOIRES
TEOXANE
GERMANY**

PROGRAMME · FRIDAY, OCTOBER 5, 2012

9.00 – 10.30 a.m. 1st PART WORKSHOPS

- 1.1 Dr. Daniel Ferrari, M.Sc./DE
Basics of internal and external sinus lifting using short porous and/or screw implants of the latest generation with identical interior connection (incl. hands-on course)—Part 1
- 1.2 Dr. Mazen Tamimi/JO
Impla—Modern Implants & 3-D Implantology (Workshop in English)
- 1.3 Dr. Marc Hansen/DE | Dr. Harald Hüskens/DE
The narrow jaw: Update ultrasonic surgery and diameter reduced implants in the aesthetic zone. Theory and practical training using artificial plastic jaws
- 1.4 Dr. Urs Brodbeck/CH | Dipl.-Ing. Holger Zipprich/DE
Biodenta—implants, prosthetic solutions and intraoral scanning device (incl. hands-on course)
- 1.5 Study group meeting DGZI

10.30 – 11.00 a.m. Break/Visit of the Dental Exhibition

11.00 a.m. – 12.30 p.m. 2nd PART WORKSHOPS

- 2.1 Dr. Daniel Ferrari, M.Sc./DE
Basics of internal and external sinus lifting using short porous and/or screw implants of the latest generation with identical interior connection (incl. hands-on course)—Part 2
- 2.2 Prof. Dr. Dr. Knut A. Grötz/DE
Complex situations in dental implantology—update augmentation measures
- 2.3 Prof. Dr. Dr. George Khoury/DE
Soft tissue management and tuning using cross-linked hyaluronic acid (HA)
- 2.4 Dr. Mario Kirste/DE
Socket preservation—the ultimate reference for the successful aesthetic implantation
- 2.5 Dr. Harald Hüskens/DE
Soft tissue from the blister—future or already reality?
MucoMatrixX—A new era of soft tissue augmentation

12.30 – 1.00 p.m. Break/Visit of the Dental Exhibition

Congress President:

Prof. Dr. Dr. Frank Palm/DE

Scientific Director:

Dr. Roland Hille/DE

MAIN PODIUM

Simultaneous translation German/English, English/German
Chairmen: Prof. Dr. Dr. Frank Palm/DE, Dr. Roland Hille/DE

1.00 – 1.15 p.m. Opening Ceremony
Prof. Dr. Dr. Frank Palm/DE
Dr. Roland Hille/DE

1.15 – 1.45 p.m. Prof. Dr. Dr. Jörg R. Strub/DE
Endo or implant?

- 1.45 – 2.15 p.m. Prof. Dr. Thomas Weischer/DE
Long term implant success in tumor patients—
is this really possible?
- 2.15 – 2.45 p.m. Prof. Dr. Werner Götz/DE
Dr. Rolf Vollmer/DE
Heat development during implant site preparation—
comparing steel and ceramic twist drills in D1/D2 bone
- 2.45 – 3.15 p.m. Prof. Dr. Dr. Albert Mehl/CH
Opportunities of CAD/CAM in implant prosthetics
- 3.15 – 3.35 p.m. Dr. Daniel Ferrari, M.Sc./DE
Minimizing the patient's stress by a specific op management
- 3.35 – 3.45 p.m. Discussion
- 3.45 – 4.45 p.m. Break/Visit of the Dental Exhibition

INTERNATIONAL PODIUM//4.15 – 6.30 p.m.

Simultaneous translation German/English, English/German
Chairmen: Prof. Dr. Amr Abdel Azim/EG, Dr. Mazen Tamimi/JO, Dr. Rolf Vollmer/DE

- 4.15 – 4.30 p.m. Mohamed Moataz M. Khamis B.D.S., M.S., Ph.D./EG
Achieving outstanding results with all ceramic CAD/CAM restorations together with dental laser
- 4.30 – 4.45 p.m. Prof. Dr. Suheil Boutros/US
Trabecular Metal Technology from Orthopedics to Dental Implantology—Early Results of Human Dental Implant Cases
- 4.45 – 5.15 p.m. Dr. Sami Jade/LB
Bleeding risk following implant surgery in the mandibular symphysis
- 5.15 – 5.30 p.m. Prof. Dr. Shoji Hayashi/JP
Clinical evidence and current future implant concepts in Yokohama clinic of Kanagawa Dental College
- 5.30 – 5.45 p.m. Dr. Osamu Yamashita/JP
Oral infection control for implantology
- 5.45 – 6.00 p.m. Dr. Tomohiro Ezaki/JP
Immediate implant placement on anterior and premolar upper teeth using CT scanning
- 6.00 – 6.15 p.m. Dr. Ramy Fahmy Rezkallah/EG
Seeing in to the future—External deception versus internal facts: Cone beam computed tomography revealing the reality
- 6.15 – 6.30 p.m. Discussion

PROSTHETICS PODIUM//4.15 – 6.30 p.m.

Chairmen: Prof. Dr. Peter Rammelsberg/DE, ZTM Christian Müller/DE
For further information on the podiums please refer to www.dgzi-jahreskongress.de

CORPORATE PODIUM//4.15 – 6.30 p.m.

Chairmen: Dr. Rainer Valentin/DE, Prof. Dr. Gerd Volland, M.Sc./DE

For further information on the podiums please refer to www.dgzi-jahreskongress.de

8.00 p.m. Evening Event at „AU QUAI“ Port Hamburg
on the river Elbe with live music

MAINPODIUM

Simultaneous translation German/English, English/German

Chairmen: Prof. Dr. Herbert Deppe/DE, Prof. Dr. Kai-Olaf Henkel/DE

- 9.00 – 09.30 a.m. Prof. Dr. Kai-Olaf Henkel/DE
Complications and failures in dental implantology
- 9.30 – 10.00 a.m. Prof. Dr. Herbert Deppe/DE
Implants in organ transplant recipients—is this possible?
- 10.00 – 10.45 a.m. Prof. Dr. Hans-Peter Weber/US
The digital process chain in implant prosthetics
- 10.45 – 11.00 a.m. Discussion
- 11.00 – 11.30 a.m. Break/Visit of the Dental Exhibition
- 11.30 – 12.00 a.m. Prof. Dr. Anton Sculean/CH
Innovative techniques and materials for the defect coverage in cases of multiple recessions

SPECIAL PODIUM

Periimplantitis: Explantation or treatment?

Presentation: Prof. Dr. Frank Palm/DE

- 12.00 – 12.30 p.m. Prof. Dr. Andrea Mombelli/CH
Epidemiology of periimplantitis: facts and fiction
- 12.30 – 1.30 p.m. Diskussion with the Speakers:
Prof. Dr. Herbert Deppe/DE
Prof. Dr. Andrea Mombelli/CH
Prof. Dr. Anton Sculean/CH
- 1.30 – 2.30 p.m. Break/Visit of the Dental Exhibition

Chairmen: Dr. Georg Bach/DE, Dr. Bernd Quantius, M.Sc./DE

- 2.30 – 3.00 p.m. Prof. Dr. Peter Rammelsberg/DE
The effects of simultaneously performed augmentation procedures on the implant prognosis
- 3.00 – 3.30 p.m. Priv.-Doz. Dr. Torsten Mundt/DE
Mini implants in the edentulous jaw—
A multicenter study in German dental centers
- 3.30 – 4.00 p.m. Prof. Dr. George Khoury/DE
Multifunctional use of hyaluronic acid (HA)—
perfect for regeneration management
- 4.00 – 4.15 p.m. Concluding Discussion
- 4.15 p.m. General assembly of the DGZI

Venue/Accommodation



Grand Elysee Hotel Hamburg
Rothenbaumchaussee 10, 20148 Hamburg, Germany
Tel.: +49 40 41412-0, Fax: +49 40 41412-733
www.grand-elysee.com

Room Rates

„Grand Standard“ Single 125,- € excl. breakfast Double 125,- € excl. breakfast
Breakfast 20,- € per Person

Reservations

Please book directly at the hotel using the keyword: „DGZI 2012“
Tel.: +49 40 41412-222, Fax: +49 40 41412-122, E-Mail: reservierung@grand-elysee.com
Note: Please inform yourself about possible special deals. It is possible, that cheaper rates can be found on the internet or via booking offices.

Room booking in various categories

PRIMECON | Tel.: +49 211 49767-20, Fax: +49 211 49767-29
info@prime-con.eu | www.prim-con.eu

Congress Fees

42nd International Annual Congress of the DGZI
(Friday, October 5, to Saturday, October 6, 2012)

Dentist/Dental Technician DGZI-Member	245,- €*
Dentist/Dental Technician Non-member	295,- €*
Assistants (with verification) DGZI-Member	120,- €*
Assistants (with verification) Non-member	135,- €*
Students (with verification)	conference charge only

*The 1st item is calculated incl. 7% tax in the name and for the account of the DGZI e.V.

Conference Charge

90,- € plus VAT

The Conference Charge is to paid by each participant and includes coffee breaks, conference drinks and lunch.

Evening Event at „AU QUAI“ Port Hamburg

69,- € plus VAT

Enjoy Hamburg, where it is most beautiful. Directly located on the Elbe River—in the heart of the harbor! Pamper yourself with fresh creations and an unforgettable atmosphere.

(Price includes dinner, wine, beer, softdrinks, transfer and live music)

Organizer

Organization



DGZI e.V.
Paulusstraße 1
40237 Düsseldorf
Germany
Tel.: +49 211 16970-77
Fax: +49 211 16970-66
sekretariat@dgzi-info.de
www.dgzi.de

OEMUS MEDIA AG
Holbeinstraße 29, 04229 Leipzig
Germany
Tel.: +49 341 48474-308
Fax: +49 341 48474-390
event@oemus-media.de
www.dgzi-jahreskongress.de
www.oemus.com

Note: For further information on the program and the general terms and conditions please refer to www.dgzi-jahreskongress.de

Fax this form to

+49 341 48474-390

OEMUS MEDIA AG
Holbeinstraße 29
04229 Leipzig
Germany

I hereby register the following persons for the 42nd International Annual Congress of the DGZI from October 5-6, 2012 in Hamburg, Germany (Please fill out/tick as appropriate):

NOTE: Please note, that you can only participate in one workshop in each part. Please mark your choice.

	<input type="checkbox"/> ①	Workshops
	<input type="checkbox"/> yes	<input type="checkbox"/> ② 1 st Part: _____
	<input type="checkbox"/> no	<input type="checkbox"/> ③ 2 nd Part: _____
Title, Surname, Name, Job Title		DGZI-Member Podiums (insert no.)

Evening Event: ____ (Please insert no. of persons)

Stamp/Address

I hereby accept the terms and conditions of the 42nd International Annual Congress of the DGZI.

Date/Signature

E-Mail:

Russian healthcare system

Improving but in need of investments

According to a new Espicom market research report, Understanding Russia's Regional Health Markets, the progress in improvement in Russia's health system is slow. Urban areas, particularly Moscow are of a high quality, but provision in rural areas remains poor.



Russia is the largest country in the world, with a land area of over 17 million square kilometres, encompassing eleven time zones. It has an estimated population of 142.9 million. Delivering universal high quality health services is a challenge.

Funding is at the heart of Russia's health improvement plans, and at the beginning of 2011 obligatory medical

insurance contributions increased from 3.1 % to 5.1 %, deductible from salaries. This will raise an additional R460 billion (US\$15.1 billion) over two years and will help cover the costs of overhauling, and equipping hospitals and polyclinics. The extra funds will also help to provide a wider range of free-of-charge medical services. With measures to increase income, however, has come the challenge of distribution and the recognition that, in common with countries such as India and China, there is a yawning gap between well provided for cities and the more remote regions.

In 2010, the government introduced the idea of a regional healthcare services modernisation scheme that aims to improve quality and availability of medical services and raise the profile of the medical profession. The decision to implement the required changes was difficult, particularly during a period of economic pressure. Healthcare modernisation is well overdue. To put this into context, over 30 % of hospitals lack a hot water supply, 8 % do not have a drinking water pipeline and 9% lack drainage.

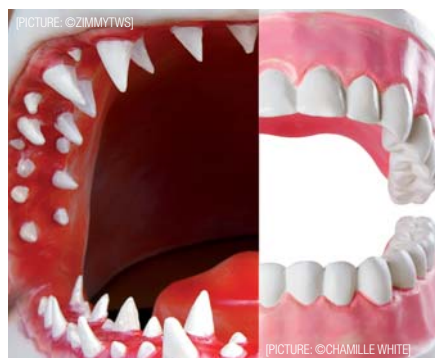For further information on the report please visit www.espicom.com/rmpr.

Tomorrow's dentures

Resemble Shark teeth

Researchers at the German University of Duisburg-Essen and the Max Planck Institute for Iron Research in Düsseldorf examined the teeth of two different sharks, the shortfin mako and the tiger shark, in terms of their structure, composition and mechanical properties. The teeth of both sharks were found to have a similar crystalline composition. According to the researchers, the interior of shark teeth contains dentine, a softer material also found in human teeth, while the enamel exterior is highly mineralised. Shark teeth contain fluorapatite, a very hard mineral, which could lead to the conclusion that they are harder than human teeth, which contain hydroxylapatite, a softer mineral, according to Dr Matthias Epple, Professor of Inorganic Chemistry at the university.

However, comparative analyses revealed that the hardness of shark teeth and human teeth was comparable, both for dentine and enamel. "This is mainly due

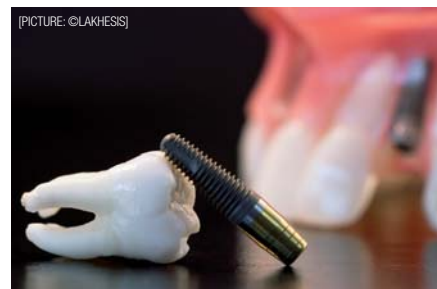

to the micro- and nano-structures of our teeth, in which crystals are highly ordered in a special topological orientation," said Epple. The scientists are now continuing their research on other shark species. They are hoping to recreate their dental structures for the production of dentures in the future. The study was published in the June issue of the Journal of Structural Biology.

Healing after implant placement

Stimulated by Biomaterials

Italian Researchers have found that blood platelet biomaterial significantly improves the healing process after placement of dental implants. In a case study, they observed beneficial short- and long-term results after the replacement of a fractured central incisor. In the article, they present a new approach to improving the outcome of anterior implants by using blood platelet concentrates. The paper reports on a case study of a 45-year-old female patient who had fractured an incisor in a sport-related accident. In an Italian private practice, the broken tooth was extracted and an implant inserted. In addition, a biomaterial of leukocyte- and platelet-rich fibrin (L-PRF) was used.



The scientists observed positive healing of the tissue two days after surgery. They found that the material acts as a bio-membrane that protects the implant from the oral environment. It appears to stimulate the growth of cells and to accelerate gingival healing and maturation. After seven days, they found that the gingival aesthetic profile was well defined. At six months, they reported a satisfactory final result that was still stable and aesthetic after two years. According to the researchers, L-PRF is simple, inexpensive and easy to prepare in only 15 minutes. Thus, it suits the practical needs of daily implant dentistry, in particular. Moreover, it is free of additives, such as anticoagulant, a substance that prevents the clotting of blood, or chemicals for activation, they said.

The project was conducted by researchers at the University of Geneva's School of Dental Medicine, the State University of New York at Buffalo's Department of Restorative Dentistry and the Chonnam National University's School of Dentistry in Gwangju, South Korea, in collaboration with two practitioners in Italy and Israel. The study was published in the April issue of the Journal of Oral Implantology.

Anaesthesia varies in

Orthognathic surgery and recovery

Orthognathic surgery, affecting the jaws and face, requires a balancing act in anaesthetic technique. Limiting blood loss, avoiding respiratory depression, and averting postoperative nausea and vomiting lead to optimum patient outcomes. The use of the drugs propofol and remifentanyl are increasing because they can meet these needs; however, patients may subsequently experience more postoperative pain.

The journal *Anesthesia Progress* presents a retrospective study of 51 patients in a single medical centre. The 21 orthognathic maxillofacial surgery patients in the group receiving intravenous propofol and remifentanyl experienced significantly higher pain scores. Anaesthesia for the 30 patients in the comparison group was maintained with inhalational agents and longer-acting opioids.

The drug remifentanyl is seeing increased use in orthognathic surgery because its short half-life can fa-

cilitate stable operating conditions while avoiding the undesirable postoperative consequences of morphine and other such agents. There is still a need for pain control in the postoperative period using longer-acting opioids that carry a greater potential for adverse effects.

The study was undertaken to ensure that achieving better intraoperative conditions did not come at the expense of patients' recovery. Variables of comparison included recovery time, occurrence of nausea and vomiting, pain scores, heart rate, and opioid dose administered in the four hours following surgery.

There was a trend toward shorter recovery times in the group receiving propofol and remifentanyl. The median recovery time was 65 minutes for this group and 93 minutes for the inhalation group. However, the



first group reported higher pain scores in the first four hours following surgery. No differences were found in early postoperative opioid use, heart rate, or nausea and vomiting.

With maxillofacial surgery, postoperative respiratory and gastrointestinal complications can be dangerous. While turning to drugs that can reduce these risks leads to better surgical experiences, it may also mean increased postoperative pain for patients. This study takes a first look at this occurrence and may be the stimulus for future controlled studies.

Full text of "The Effect of Anesthetic Technique on Recovery After Orthognathic Surgery: A Retrospective Audit," and other articles, *Anesthesia Progress*, Vol. 59, No. 2, 2012, are available at <http://www.anesthesiaprogress.org/toc/anpr/59/2>

Conical internal connections

Fuel growth in dental implant market

The dental implant and bone graft substitute market is the most rapidly advancing segment of dental technology, and leading competitors in this market must consistently develop new products supported by research from scientific and academic organizations to remain competitive. Recent cases have demonstrated that when companies lose a segment of support from the scientific community, their market shares tend to suffer significantly.

The European dental implant and bone graft substitute market has been further challenged by recent economic instability and the

Eurozone crisis, which has created a consistent demand for lower-cost dental implant products. As a result, many lower-priced competitors have begun to seize larger market shares in almost every European market. In many segments, these competitors are either regional or sourced from overseas markets such as Brazil, Korea and Israel.

Regenerative products and barrier membranes have been particularly affected by consumer austerity, as these products are discretionary in many cases.

However, a growing number of consumers continue to demand high-quality products, guarantees of service and scientific improvements, which only premium manufacturers are equipped to offer. Conical internal connections is one such recent innovation, and currently constitute the fastest-growing connection type in the dental implant industry.

Many dental implant and bone graft substitute companies have looked to expand their product portfolio or create new markets while they create package deals to offset competition from rapidly emerging lower-priced competitors. Significantly, many European and US companies involved in this market have begun to invest in rapidly emerging periphery markets such as Turkey. For more information and a free synopsis of the report, please contact iData Research at dental@idata-research.net.

Back pain

Stopped by Basel Cap for Dentists



A German company has developed a baseball cap aimed at helping dentists prevent back pain. Dentists usually work in a bent position, which affects the back negatively. The cap, inspired by the African tradition of carrying weight on the head (tallabé), has an integrated ergonomic weight inlay and can be worn standing up or sitting down.

According to the manufacturer, the effect of the tallabé is immediately evident. The muscles of the body begin to coordinate, and the body is encouraged to adopt an upright and relaxed posture.



implants
international magazine of oral implantology



Publisher

Torsten R. Oemus
oemus@oemus-media.de

CEO

Ingolf Döbbecke
doebbecke@oemus-media.de

Members of the Board

Jürgen Isbaner
isbaner@oemus-media.de

Lutz V. Hiller

hiller@oemus-media.de

Chief Editorial Manager

Dr Torsten Hartmann (V. i. S. d. P.)
hartmann@dentalnet.de

Editorial Council

Prof Dr Dr Frank Palm
frank.palm@klinikum-konstanz.de

Dr Roland Hille

dr-hille@t-online.de

Prof Dr Dr Kurt Vinzenz

kurt.vinzenz@aon.at

Dr Torsten Hartmann

hartmann@dentalnet.de

Dr Suheil Boutros

SMBoutros@aol.com

Editorial Office

Georg Isbaner
g.isbaner@oemus-media.de

Claudia Jahn

c.jahn@oemus-media.de

Executive Producer

Gernot Meyer
meyer@oemus-media.de

Designer

Sarah Fuhrmann
s.fuhrmann@oemus-media.de

Customer Service

Marius Mezger
m.mezger@oemus-media.de

Published by

OEMUS MEDIA AG
Holbeinstraße 29
04229 Leipzig, Germany
Tel.: +49 341 48474-0
Fax: +49 341 48474-290
kontakt@oemus-media.de

Printed by

Messedruck Leipzig GmbH
An der Hebemärchte 6
04316 Leipzig, Germany

implants

international magazine of oral implantology
is published in cooperation with the German
Association of Dental Implantology (DGZI).

DGZI President

Prof Dr Dr Frank Palm
DGZI Central Office
Feldstraße 80, 40479 Düsseldorf, Germany
Tel.: +49 211 16970-77
Fax: +49 211 16970-66
office@dgzi-info.de

www.dgzi.de
www.oemus.com

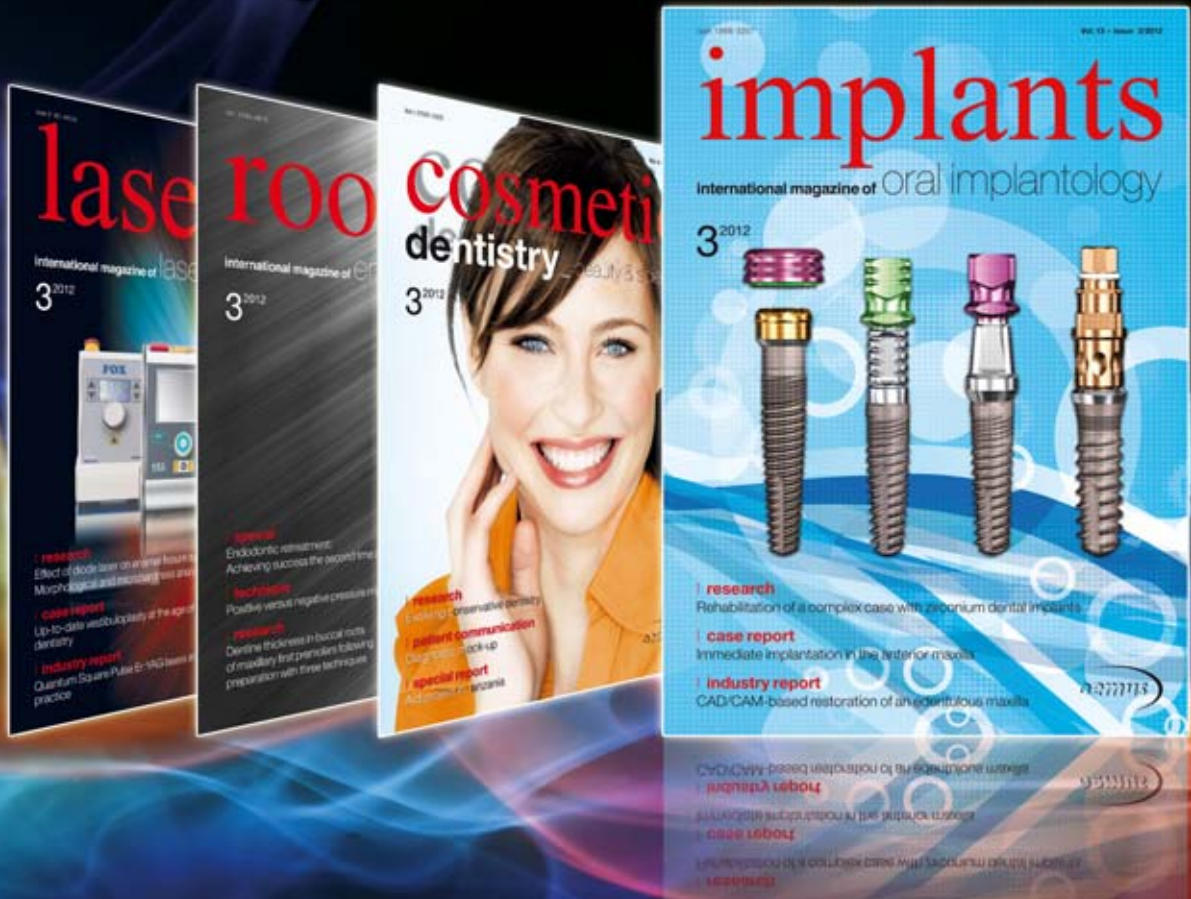Copyright Regulations

_implants international magazine of oral implantology is published by Oemus Media AG and will appear in 2012 with one issue every quarter. The magazine and all articles and illustrations therein are protected by copyright. Any utilization without the prior consent of editor and publisher is inadmissible and liable to prosecution. This applies in particular to duplicate copies, translations, microfilms, and storage and processing in electronic systems.

Reproductions, including extracts, may only be made with the permission of the publisher. Given no statement to the contrary, any submissions to the editorial department are understood to be in agreement with a full or partial publishing of said submission. The editorial department reserves the right to check all submitted articles for formal errors and factual authority, and to make amendments if necessary. No responsibility shall be taken for unsolicited books and manuscripts. Articles bearing symbols other than that of the editorial department, or which are distinguished by the name of the author, represent the opinion of the afore-mentioned, and do not have to comply with the views of Oemus Media AG. Responsibility for such articles shall be borne by the author. Responsibility for advertisements and other specially labeled items shall not be borne by the editorial department. Likewise, no responsibility shall be assumed for information published about associations, companies and commercial markets. All cases of consequential liability arising from inaccurate or faulty representation are excluded. General terms and conditions apply, legal venue is Leipzig, Germany.

implants

international magazine of oral implantology



Subscribe now!

I would like to subscribe to **implants international magazine of oral implantology** (4 issues per year) for €44 including shipping and VAT for German customers, €46 including shipping and VAT for customers outside Germany, unless a written cancellation is sent within 14 days of the receipt of the trial subscription. The subscription will be renewed automatically every year until a written cancellation is sent to OEMUS MEDIA AG, Holbeinstr. 29, 04229 Leipzig, Germany, six weeks prior to the renewal date.

▶ Reply via Fax +49 341 48474-290 to OEMUS MEDIA AG or per E-mail to grasse@oemus-media.de

You can also subscribe via www.oemus.com/abo

Last Name, First Name

Company

Street

ZIP/City/County

E-mail

Signature

Notice of revocation: I am able to revoke the subscription within 14 days after my order by sending a written cancellation to OEMUS MEDIA AG, Holbeinstr. 29, 04229 Leipzig, Germany.

Signature

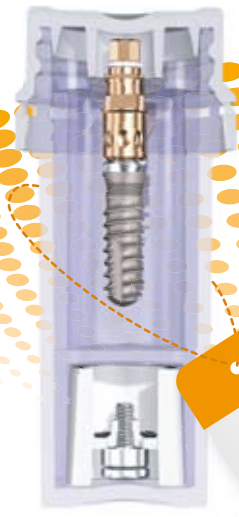


simply smarter



SwishPlus™

Compatible with Straumann®



All-in-1 Packaging includes implant, compatible carrier, cover screw & healing collar



Watch 10 minute 3D Graphic Video
Scan code or visit www.swishplus.eu

SwishPlus Advantages¹:

Internal Octagon (Niznick US Pat. #4,960,381 Licensed to Straumann)
Prosthetic compatibility with Straumann's Tissue-Level implants (Standard, Standard Plus and Tapered Effect)
Internal square broached in flats of octagon for fixture-mount engagement (Pat. Pend.)

- 1 Only 1mm of 2mm neck remains smooth for bone preservation* with deeper placement
- 2 Micro-grooves for improved tissue attachment & increased surface area
- 3 Progressively-deeper threads for increased initial stability and surface area
- 4 Vertical self-tapping grooves for ease of insertion and increased initial stability
- 5 Tapered apical end to initiate self-tapping insertion
- 6 Carrier demarcations align with flats of octagon for use with indexed SwishPlus abutments
- 7 Frictional carrier engages internal square, eliminating need for counter torque on removal

Carrier

Compatible with Straumann tool & standard ratchet



Our price	€75	€65	€65	€65	€65	€75	€90	€90	€27.50	€82	€75	€90	€65	€75



Price based upon EU list prices as of February 2012. All trademarks are property of their respective companies.
¹System Variation: 3.3mmD & 5.7mmD SwishPlus are tapered; 3.3mmD also has SwishPlant threads.
*Buser et al. Int J Oral Maxillofacial Implants 2005; 20: 677-686

• سازگارترین ایمپلنت دارویی دنیا

• اعجاز طراحی و تکنولوژی غوطه ور در کلسیم

• مناسب برای بیماران استخوانی و خونی

• بارگذاری چهار تا شش هفته

*This is
the First*

TS III CA

SUPER HYDROPHILIC SURFACE

OSSTEM[®] IMPLANT