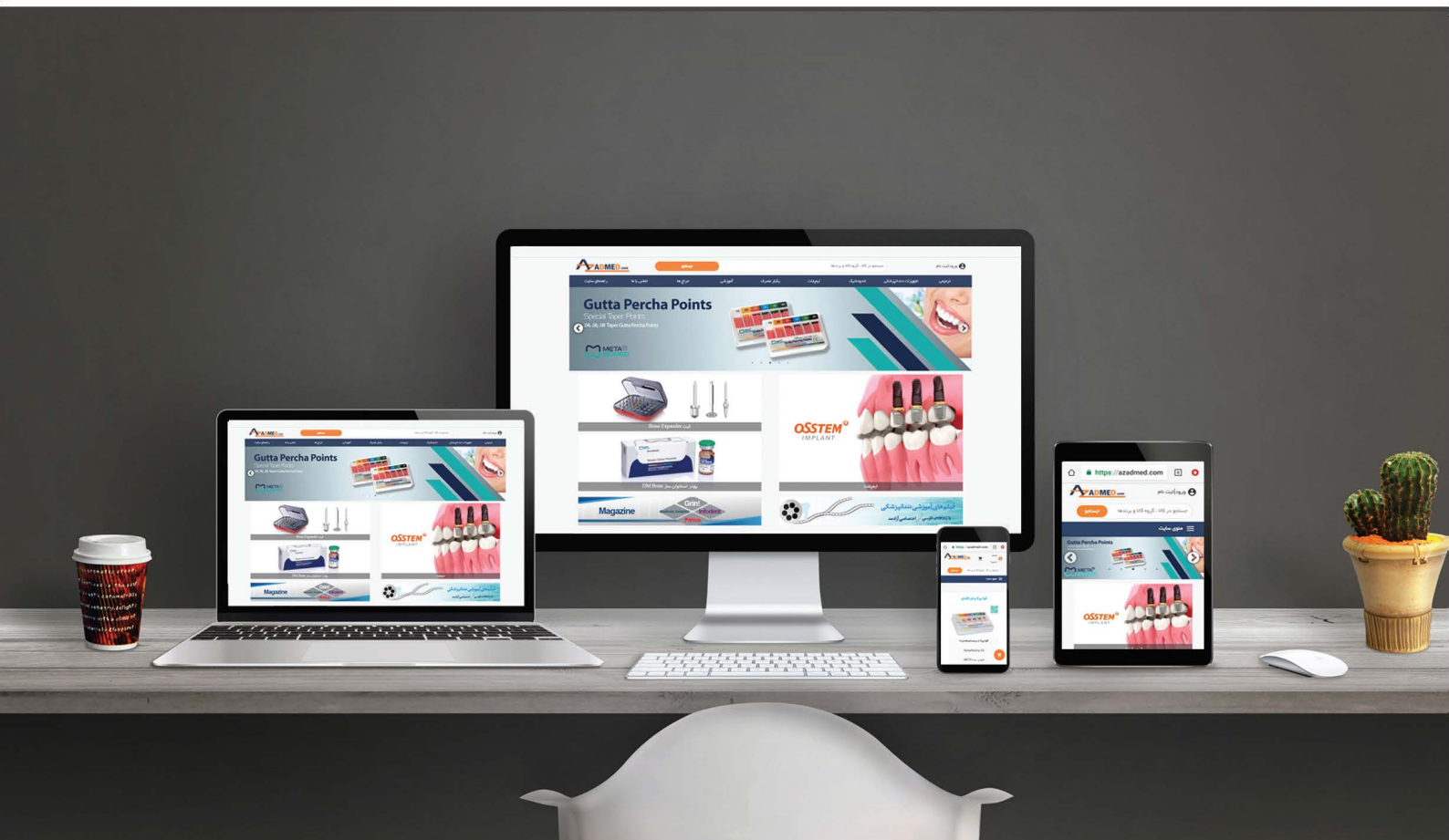




آزاد تجارت پارس  
AZAD TEJARAT PARS.LTD

**AZADMED.com**



[www.azadmed.com](http://www.azadmed.com)



 azaadtejaratpars

 @azadmed2

 88 98 80 63 - 6

# implants

international magazine of oral implantology

3<sup>2013</sup>



**A**  
ADMED  
.com

| **research**

Retromolar bone grafts prior to implant placement — Part I

| **overview**

Periimplant lesions — causes and treatment options

| **case report**

GTR and recession coverage in immediate implantation

0277113



## DENTSPLY Implants – the new powerhouse in implant dentistry

**DENTSPLY Implants is the union of two successful and innovative dental implant businesses: DENTSPLY Friadent and Astra Tech Dental\*.**

DENTSPLY Implants offers a comprehensive line of implants, including ANKYLOS®, ASTRA TECH Implant System™, and XiVE®, digital technologies such as ATLANTIS™ patient-specific CAD/CAM solutions, regenerative bone products and professional development programs.

DENTSPLY Implants is built upon the fundamental values of open-mindedness, a thorough scientific approach, a dedication to long-term clinical evidence and a

strong customer focus. Our current DENTSPLY Friadent and Astra Tech Dental customers can rest assured knowing that the world-class products they know will continue to be supported.

We are confident that dental professionals around the globe will come to recognize DENTSPLY Implants as their new partner of choice for integrated implant solutions, dedicated support and better patient care.

**We invite you to join our journey to redefine implant dentistry.**

\*DENTSPLY Implants was launched in North America April 2012. Transition to the new business in other geographical locations around the globe will follow.

**ANKYLOS® ASTRA TECH IMPLANT SYSTEM XiVE® ATLANTIS™ ATLANTIS ISUS™ FRIOS® EXPELTEASE™ Facilitate™**

[www.dentsplyimplants.com](http://www.dentsplyimplants.com)

# Dear colleagues,



Dr Roland Hille

The 43<sup>rd</sup> International Annual Congress of the DGZI takes place in Berlin, Germany – the city that never sleeps and which is always good for a surprise.

As in the previous years, DGZI has compiled a programme which is good for a surprise as well, although in a strictly implantological sense. It was our task to elicit practical and reliable concepts to support your individual success, following the motto "from practice—for the practice". Our speakers have applied their concepts successfully for many years. Therefore, they will tune in this year's congress motto "Practice-oriented Implantology" with their speeches on Saturday. Our special prosthetic podium supports DGZI's team spirit, offering a symbiosis of dental and dental technical topics from the perspective of sustainability as the only way to modern dentistry.

A firework of practice-oriented science will be held on Saturday. Renowned speakers will give you an update on the state of the art of practice-relevant topics. As has been known for many years, DGZI favours plain language. Following various controversial and refreshing discussions on short implants, mini implants and periimplantitis, this year's topic is the "All-on-Four Concept—Practice-oriented and science-based?". We are pleased that Dr Paolo Malo has accepted our request to present his concept and arguments during an open discussion. I am looking forward to hearing the results gained by discussion group and auditorium. Feel free to join the discussion! DGZI will accept each individual opinion. Furthermore, DGZI scientific advisory board has launched a scientific study on the All-on-Four Concept at the University of Bonn, Germany. Its results will be presented at the 43<sup>rd</sup> International Annual Congress of the DGZI for the first time.

Our international podium will again provide you with a cross section of international science, since DGZI is known to be the implantological society which has the best network in Germany. Our corporate podiums and the legendary party night at the Wasserwerk, Berlin titled "Lounging, Dining, Clubbing", will take you on a trip to the adventurous side of Berlin.


I am looking forward to welcoming you at this special weekend, which celebrates the German unification, at its centre stage in Berlin for the 43<sup>rd</sup> International Annual Congress of the DGZI.

Yours,

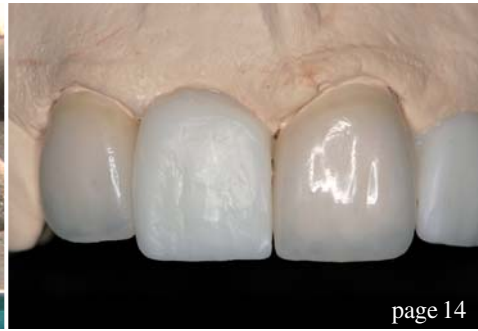Dr Roland Hille  
Scientific Director

Programme and  
registration form

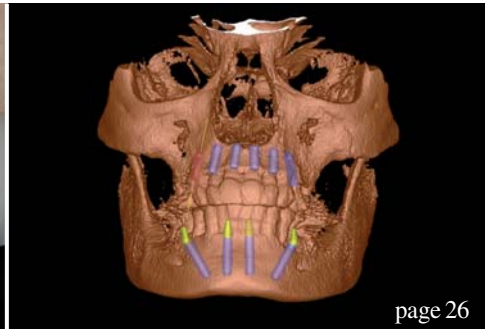




page 06



page 14



page 26

| editorial

03 Dear **Colleagues**  
| Dr Roland Hille

| research

06 **Retromolar bone grafts prior to implant placement—Part I**  
| Andreas Sakkas *et al.*

| case report

14 **GTR and recession coverage in immediate implantation**  
| Dr N. Papagiannoulis *et al.*

| overview

20 **Periimplant lesions — causes and treatment options**  
| Dr Georg Bach

26 **Fast & Fixed as an alternative treatment in cases of periodontitis profunda**  
| Dr Regina Schindjalova

| industry report

30 **The use of the LiteTouch Er:YAG laser in peri-implantitis treatment**  
| Prof. Tzi Kang Peng *et al.*

36 **Safe interdisciplinary navigation**  
| Dr Frank Schaefer *et al.*

41 **Peri-implantitis prophylaxis by sealing implant gaps and hollow spaces**  
| Prof. Dr Dr Claus Udo Fritzemeyer

| news

44 **Manufacturer News**

47 **News**

| meetings

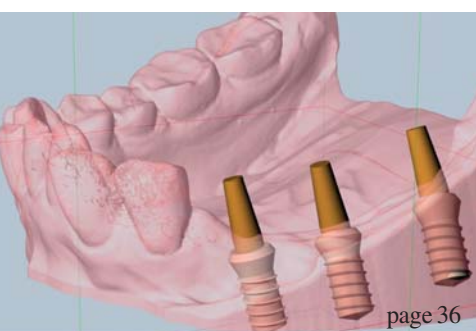
49 **Nobel Biocare Global Symposium 2013 in New York**  
| Nobel Biocare

| about the publisher

50 | imprint




Cover image courtesy of Isy by Camlog, [www.camlog.de](http://www.camlog.de)  
Original Background: ©Vladim Georgiev  
Artwork by Sarah Fuhrmann, OEMUS MEDIA AG.



page 36

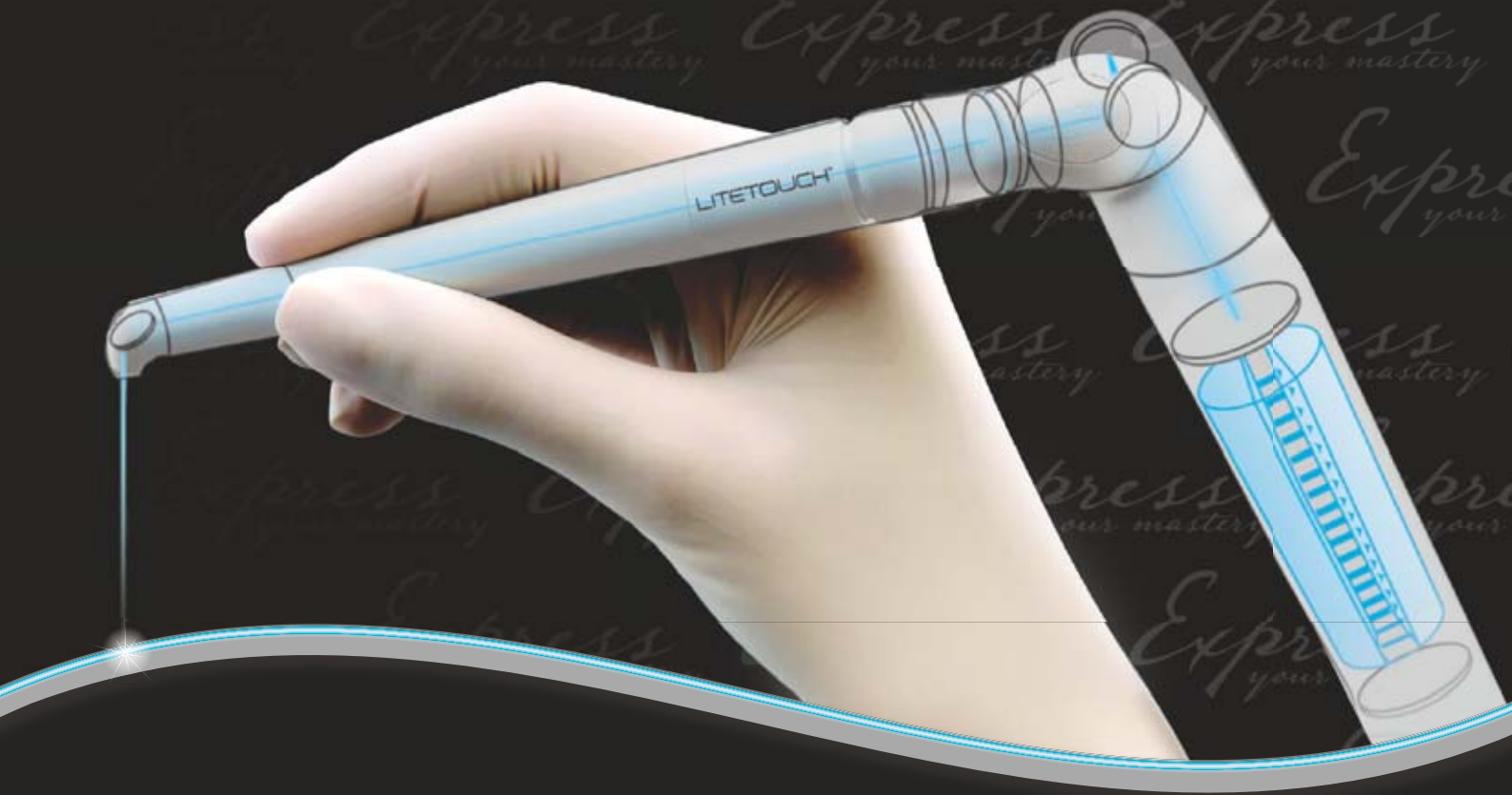

page 47



page 49

**Syneron**<sup>TM</sup>  
DENTAL LASERS



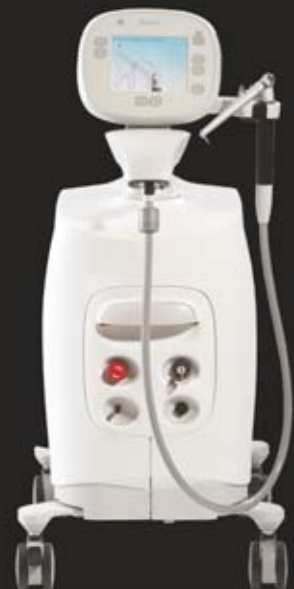Education. Technology. Family.

Join the Syneron Dental Lasers Family

presenting

**LITETOUGH**<sup>TM</sup>

The unique fiber-free Er:YAG laser  
that has changed the face of laser dentistry



L-1PB7/692EN



To learn more about our innovative technology solutions,  
contact: [dental@syneron.com](mailto:dental@syneron.com), [www.synerondental.com](http://www.synerondental.com)



# Retromolar bone grafts prior to implant placement

## Outcomes and complications—Part I

**Authors** Andreas Sakkas, Carsten Winter, Frank Wilde & Alexander Schramm, Germany

### Introduction

The dental rehabilitation of partially or totally edentulous patients with oral implants has become common practice with reliable long-term results.<sup>1</sup> However, unfavourable local conditions of the alveolar ridge due to atrophy, periodontal disease, trauma sequel, malformation or neoplasia may cause insufficient bone volume, which may complicate the therapy of the masticatory function with dental implants.<sup>2</sup> When alveolar ridges lack the appropriate bone volume, additional surgical reconstructive procedures are required.

The use of autologous bone grafts with dental implants was described originally by Brånemark et al. in 1975, and today is a well-accepted procedure in oral and maxillofacial rehabilitation.<sup>3-5</sup> Insertion of an endosseous implant requires sufficient bone volume for complete bone coverage. Physiologically, an ideal bone grafting material should provide osteogenicity, osteoinductivity and osteoconductivity for new bone formation. Despite some recent advances in bone-substi-

tute technology, autogenous bone grafts remain the "gold standard" in reconstructive surgeries because of their osteoinductive, osteoconductive and non-immunogenic properties. Guided bone regeneration (GBR) is an alternative technique to onlay grafting for localised alveolar ridge augmentation prior to dental implant placement.<sup>6,7</sup> The clinical potential of membrane techniques for bone regeneration was recognised by Nyman et al.<sup>8</sup> They demonstrated that membranes act as a physical barrier when applied over bone defects, preventing the ingrowth of competing, non-osteogenic cells into the membrane-protected space.<sup>7,9</sup> Space provision, such as guided tissue regeneration, was shown to be effective in regenerating new bone on atrophied alveolar ridge, either vertically or horizontally, with the use of a membrane. Similar to onlay bone graft, which also serves as a space maintainer, GBR may incur similar complications that pertain to the use of onlay graft. Complications related to GBR may come from membrane exposure, miniscrew exposure and contamination. Exposed membranes or fixation screws often cause local inflammation with decreased bone formation.<sup>10</sup>

**Figs. 1 & 2** Exposure of the recipient site for the graft prior to harvest, measurement of its dimensions and the minimal time elapsed between graft harvest and placement.

**Fig. 3** Preoperative situation.

**Fig. 4** Mean surgical time of five minutes for harvesting.

**Fig. 5** Inferior osteotomy connecting the posterior and anterior vertical cuts.

**Figs. 6 & 7** Fixing of the block grafts after appropriate separation into smaller parts.

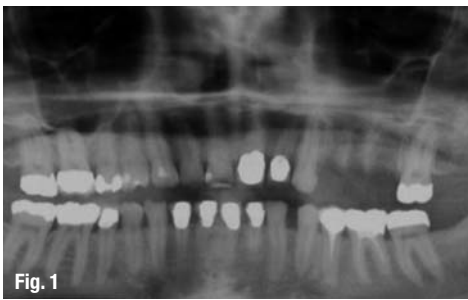


Fig. 1

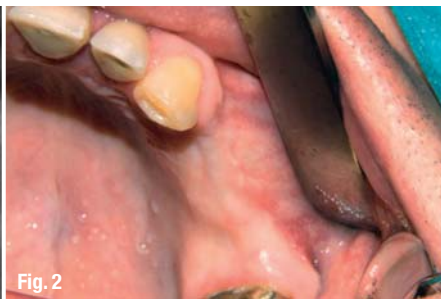

Fig. 2

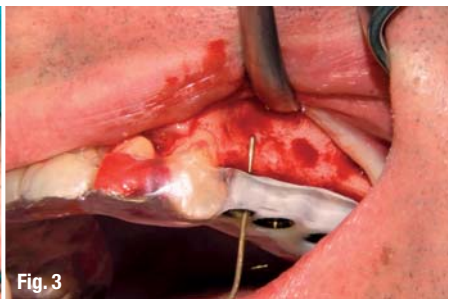


Fig. 3

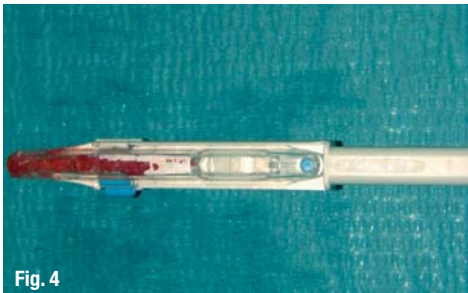


Fig. 4

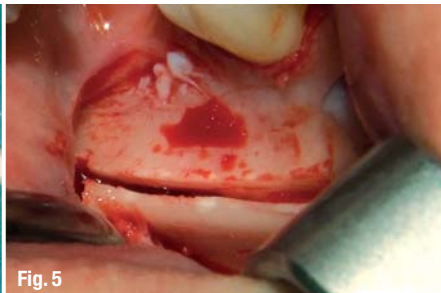

Fig. 5


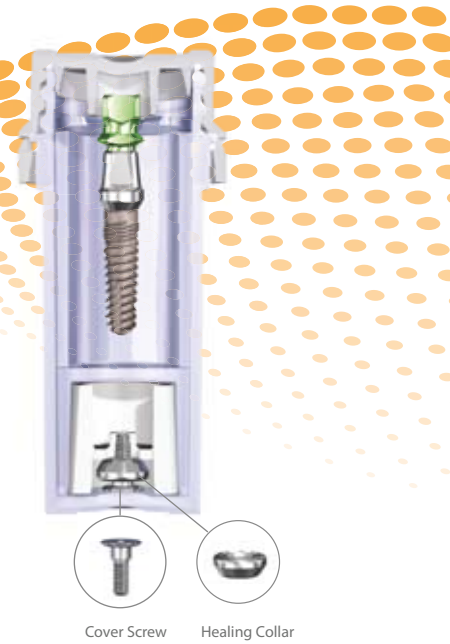


Fig. 6

# Legacy™ System

100% Compatible with Zimmer® Dental



**Reality Check**  
Zimmer Customers  
**Legacy™3 Implant**

All-in-One Packaging includes implant, abutment, transfer, cover screw & healing collar €145

## Legacy™ Implant System Advantages:

**Industry-Compatible Internal Hex**

Prosthetic compatibility with Zimmer Dental Screw-Vent®, BioHorizons® & MIS implants

**Surgical Compatibility with Tapered Screw-Vent®**

No need to change surgical protocol or tools

**Three Implant Designs & Packaging Options**

Allows for selection based on price, packaging or thread design

**Legacy1:** €115 includes cover screw, healing collar & plastic carrier

**Legacy2:** €130 includes cover screw, healing collar & temporary abutment/transfer

**Legacy3:** €145 includes cover screw, healing collar & preparable abutment/transfer

**Micro-Threads**

Reduce crestal stress for improved initial stability

**Widest Range of Dimensional Options**

The entire Legacy system includes seven implant diameters (3.2, 3.7, 4.2, 4.7, 5.2, 5.7, 7.0mm) & six implant lengths (6, 8, 10, 11.5, 13, 16mm)



Laboratory Abutment	Straight Snap-On	Straight Contoured	15° Angled Contoured	Gold/Plastic	Zirconia/Ti Abutment	Plastic Temporary Abutment	Ball Attachment	GPS™ Attachment	Angled GPS™ Attachment	Multiple-Unit w/Cap & Transfer	Angled
€60	€75	€75	€75	€90	€90	€30	€68	€90	€90	€75	€90

## Legacy™1

Standard "V" Threads  
Matches Screw-Vent®

## Legacy™2

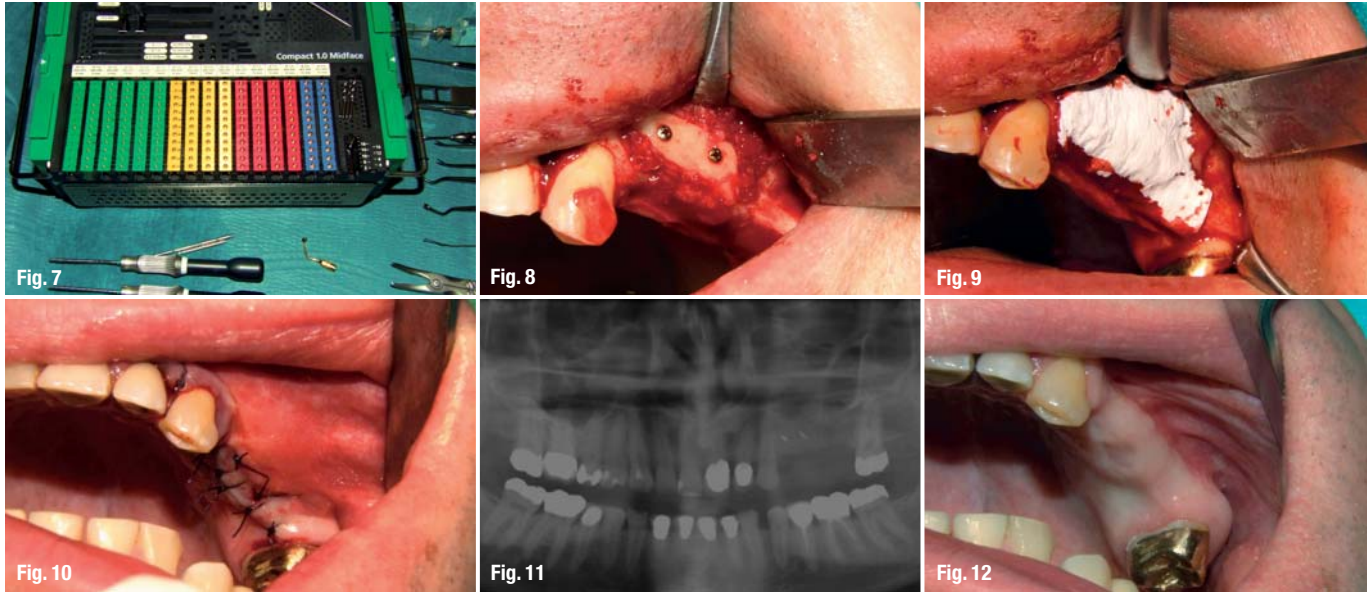
Spiral Threads  
for Increased Stability

## Legacy™3

Buttress Threads  
for Increased Surface







**Figs. 8 & 9** Filling of the small gaps between bone graft and alveolar crest with corticocancellous bone.

**Fig. 10** Periosteal releasing incisions.

**Fig. 11** Orthopantomographic control to evaluate the outcome of the surgical procedure.

**Fig. 12** Crestal incision and subperiosteal dissection of the alveolus, removal of the fixation screws. Implant site preparation with guidance from the laboratory-made splint. Positioning of the implants.

The significance of early membrane exposure on the regenerative outcome has been somewhat controversial in guided tissue regeneration and GBR procedures. Several studies have shown better responses when the membranes remained submerged than when they became exposed during healing.<sup>11,12</sup> However, other studies failed to show such differences.<sup>13,14</sup>

It must be pointed out that patients affected by partial edentulism do not easily accept major surgical procedures that may imply hospitalisation or general anaesthesia. These disadvantages, together with the fact that dental implants do not demand a large amount of bone, lead to the growing use of autogenous block bone grafts from intraoral sources rather than from extraoral.<sup>15-20</sup>

The use of the mandible as a donor site is said to be less invasive, to save surgical and anaesthetic time and to be accomplished in the outpatient operatory.<sup>13,21,22</sup> Harvesting of bone grafts from the retromolar region has been reported several times before.<sup>22-26</sup> In the repair of localised alveolar defects, bone grafts from the retromolar region offer several benefits: a) the proximity of donor and recipient sites that reduces operative and anaesthetic time; b) conventional surgical access; and c) making them ideal for outpatient implant surgery. Minimal discomfort and decreased morbidity are also reported for this type of bone grafting.<sup>27-29</sup> This technique can be combined with impacted third molar extractions.<sup>30</sup>

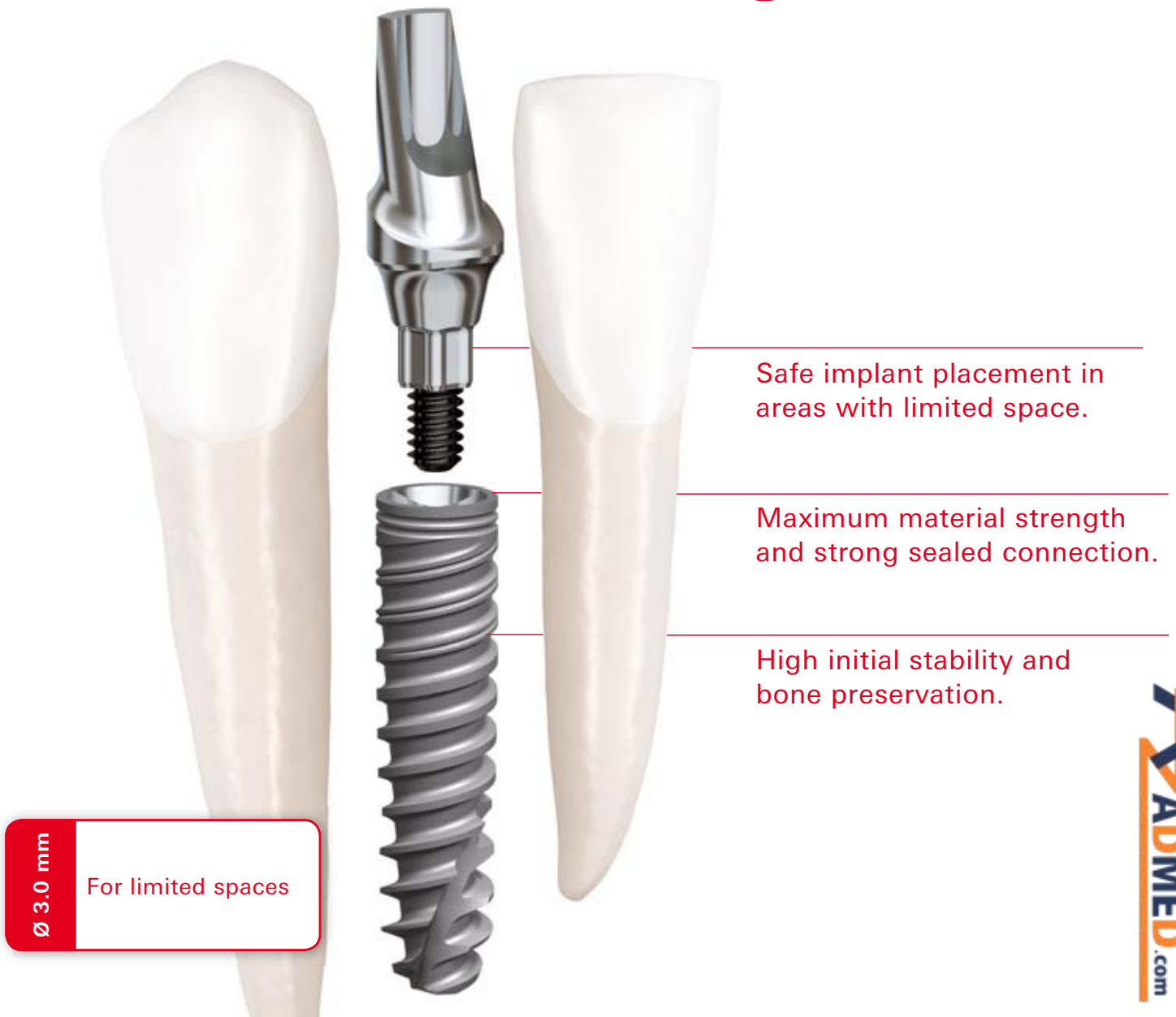The purpose of the present retrospective study was to evaluate the surgical success and to assess the rate of complications that arise from harvesting retromolar bone grafts in a group of partially edentulous patients prior to implant placement. We used a two-stage technique. In the first surgical stage, one or more cortico-

cancellous bone blocks harvested from the retromolar region were fixed with osteosynthesis titanium screws to the recipient site as onlay grafts to achieve a horizontal and/or vertical augmentation of the ridge volume. In the second procedure, three to six months later, the screws were removed and implants were placed. The results regarding bone augmentation, donor and recipient site morbidity, bone graft stability and resorption prior to implant placement were recorded during the postoperative period and healing phase. Complications associated with this procedure mostly involve infection, incision line opening, nerve dysfunction, wound dehiscence, loss of portion of the bone graft, and graft mobilisation (Table 1).<sup>31</sup> A short review of the literature is presented in Table 2.

### Materials and methods

A consecutive retrospective study was conducted on patients who underwent retromolar onlay bone grafting from January 2008 until January 2011. Files of 86 patients (77 males and 9 females) reporting 104 bone graft operations were reviewed. Patients ranged in age from 20 to 58 years (average 37.9 years). From the current study, patients were excluded if their data covered: a) grafting of bone defects caused by tumour resections, osteoradionecrosis and bisphosphonate-associated osteonecrosis, b) grafting of bone defects in syndrome patients with craniofacial involvement and with congenital malformations, such as cleft patients, c) grafting of extraction sockets and intraalveolar defects simultaneously with immediate implant placements and d) augmentations including the application of distraction osteogenesis. Medical history, cause of tooth loss and smoking status at the time of operation were recorded. All patients underwent primary clinical and radiographic examinations and were diagnosed as having an inadequate quantity of bone for implant placement.

# Smaller and stronger.



Safe implant placement in areas with limited space.

Maximum material strength and strong sealed connection.

High initial stability and bone preservation.

Ø 3.0 mm

For limited spaces

ADMED.com

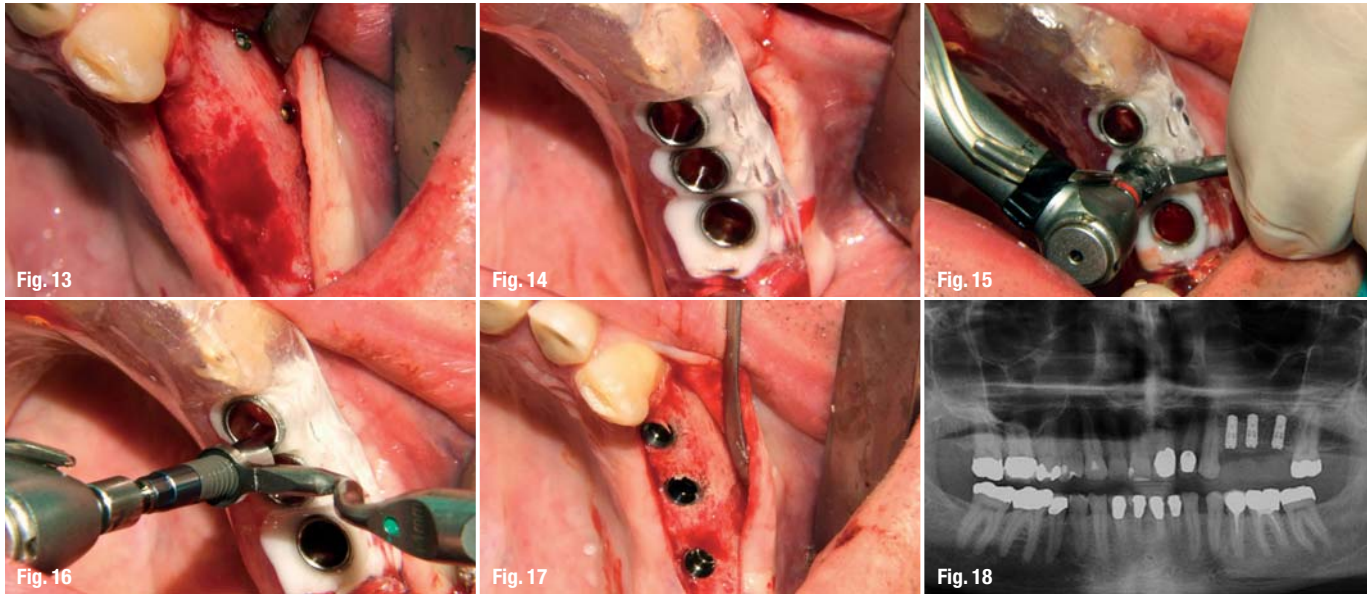
**It's called NobelActive 3.0.** This unique implant is the ideal solution for narrow spaces in the anterior region. The drilling procedure is designed to retain as much bone as possible, while the implant body and thread design condenses bone during insertion enhancing initial stability. The sharp apex and cutting blades enable you to adjust the implant position for optimal

restorative orientation. Together with the strong sealed connection and built-in platform shifting, NobelActive 3.0 allows you to safely produce excellent esthetic results. After 45 years as a dental innovator we have the experience to bring you future-proof and reliable technologies for effective patient treatment. **Their smile, your skill, our solutions.**



Visit [nobelbiocare.com/active3](http://nobelbiocare.com/active3)





**Figs. 13–18** Crestal incision and subperiosteal dissection of the alveolus, removal of the fixation screws. Implant site preparation with guidance from the laboratory-made splint. Positioning of the implants.

Table 3 shows the frequency of causes for the tooth loss. All the patients were informed in advance that bone reconstruction might be necessary prior to implant placement, since the need to augment the alveolar ridge can be evaluated correctly using panoramic radiographs only when there is vertical resorption of the ridge. Conventional radiographic examination provides little or no information about ridge thickness. Because of this, all the patients of the study underwent, except a conventional panoramic radiograph of the jaws, CT scans reformatted with Dentscan software. In disagreement with other authors, we believe that reformatted CT images always provide a precise treatment guide when the decision to graft or not to graft has to be made in critical cases.<sup>32</sup> A total of 104 alveolar segments were treated: 22 procedures involved the maxilla and 82 the mandible. In six of the augmented areas on the maxilla posterior, a Sinus elevation was also performed. Fifteen patients included in the study were treated in separate procedures for augmentation of different alveolar sites. Each augmented site was studied. 67 procedures were carried out under local anaesthesia and 37 under general anaesthesia. All sites were treated in a similar fashion. The number of bone blocks, donor sites and number of implants inserted in each augmented site were also recorded. The choice of donor site, left or right, was determined preoperatively, based on defect morphology and recipient site location. When the augmentation was planned in the posterior mandible, a single surgical field was needed, thus reducing patient discomfort. The recipient site was healed completely prior to graft surgery.

**\_Surgical protocol**

*Stage 1 surgery*

The bone harvesting procedure was performed using a standardised surgical technique. The anaesthesia of all patients was carried out with Ultracain™ D-S

(Hoechst Marion Roussel Deutschland, Frankfurt, Germany) containing 1:200,000 epinephrine at the donor and recipient sites. A single shot of 2,2 g amoxicillin and clavulanic acid (Augmentan®, GlaxoSmithKline Consumer Healthcare GmbH & Co. KG) or, if penicillin allergic, 600 mg Clindamycin (Clinda-saar®, MIP Pharma GmbH) as well as 250 mg Prednisolon (Solu-Decortin®, Merck Pharma GmbH) was administered intravenous to patients a few minutes prior to surgery.

The proposed recipient site for the graft was exposed prior to graft harvest in all cases. In this manner, the dimensions and morphology of the bony defect were measured, and minimal time elapsed between graft harvest and placement (Figs. 1 & 2). Figure 3 presents the preoperative situation. The recipient site was prepared and recon toured with the Safescraper (C.G.M. S.p.A., Divisione Medica META, Italy) by pushing the end of the devise toward the bone surface and simultaneously pulling the devise backward. Collection of 2–3 ml of bone was feasible with a mean surgical time of five minutes for harvesting (Fig. 4). The collected bone was preserved in a sterile environment until grafting. To access the ramus area, the concavity formed by the border between the ascending ramus and the external oblique ridge was identified and used as a starting point for the mucosal incision.

The incision was made medially to the external oblique ridge and extended mesially toward the buccal aspect of the second molar. Care was taken to ensure that the incision was not extended too far lingually, preventing damage to structures on the lingual aspect of the mandible. A mucoperiosteal flap was elevated superiorly, exposing the lateral aspect of the ramus. The osteotomy was carried out with an osteotomy kit for Piezosurgery® (Mectron, Deutschland Vertriebs GmbH) and was started anteriorly to the coronoid process at the

# A Real Breakthrough in Implantology.

Roxolid® SLActive® – Setting New Standards, Reducing Invasiveness

With Roxolid® SLActive® Implants we break new ground:

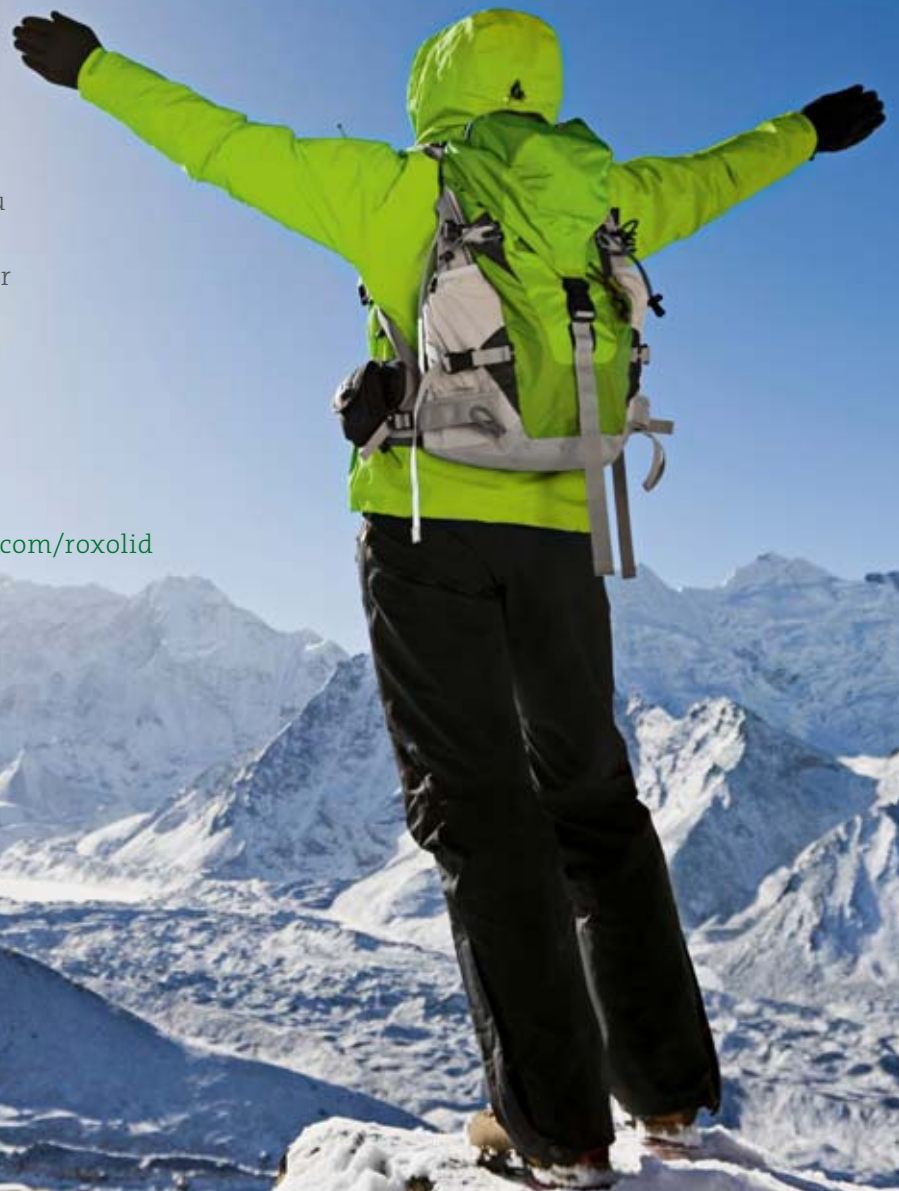- Eliminating invasive grafting procedures
- Increasing patient acceptance

Our new generation of implants provides you exceptional material strength combined with excellent osseointegration properties for greater confidence.

Now available:

- All diameters
- 4 mm Short Implant Line
- Loxim™ Transfer Piece

Discover more benefits on [www.straumann.com/roxolid](http://www.straumann.com/roxolid)



point were adequate bone thickness developed. A micro reciprocating saw was used to cut through the cortex along the anterior border of the ramus medially to the external oblique ridge. The anterior vertical cut was made in the mandibular body in the molar region with a vertical saw. The length of this cut was dependent on the size requirements of the graft and on the position of the inferior alveolar canal. The posterior vertical cut was made on the lateral aspect of the ramus, perpendicularly to the external oblique osteotomy. The inferior osteotomy connecting the posterior and anterior vertical cuts was made with a straight saw. This was a shallow cut into the ramus to create a line of fracture (Fig. 5). A thin chisel was gently tapped along the entire length of the external oblique osteotomy, and care was taken to parallel the lateral surface of the ramus, so that a fracture would occur at a particular level. This level was modified to predetermine the size of the corticocancellous bone graft. Thus, the splitting of the graft from the ramus was completed. The bone block was lifted carefully to ensure that the inferior alveolar nerve was not trapped within the graft. The donor area was filled with a collagen cotton sponge for local haemostasis.

The block grafts were then fixed with small-diameter titanium osteosynthesis screws (Matrix Midface, Synthes® 2011 NHS Supply Chain) after appropriate separation into smaller parts (Figs. 6 & 7). Corticocancellous bone, collected with the Safescraper, was then used to fill the small gaps between the bone graft and the alveolar crest (Fig. 8). In all cases, a collagen membrane (Bio-Gide, Geistlich Biomaterials, Wolhusen, Switzerland) was cut appropriately and adapted to cover the defect and extended 2 to 3 mm sideways, being laid over the graft in a saddle configuration. It was tucked underneath the palatal or lingual flap to cover the ridge and buccal defect, moistened, and pressed gently to adapt to the underlying bone (Fig. 9). Periosteal releasing incisions were made when necessary to achieve easy closure of the mucosal flaps on top of the grafts without tension (Fig. 10). An orthopantomographic control was performed postoperatively to evaluate the outcome of the surgical procedure (Fig. 11).

Postoperatively, patients were instructed to rinse their mouth with chlorhexidine 0.2% for two to three weeks twice a day. After this period, the sutures were removed. Removable provisional prostheses were adjusted generously. Patients were instructed to use their prostheses for cosmetic appearance and for eating rather than function for the whole period of healing, i.e. three months. At that time, patients were scheduled for implant surgery. No antibiotic therapy was continued after surgery and patients were instructed to use non-steroidal anti-inflammatory drugs (Ibuprofen®, Docpharm® Arzneimittelvertrieb GmbH & Co. KGaA) only if pain was present.

### Stage 2 surgery

After a healing period varying between three to six months after the grafting procedure, clinical and radiographic evaluations were performed and implants were placed in a routine fashion using the special program for guided implant surgery CoDiagnostiX® (IVS Solutions AG). All patients underwent CT scan before the implant placement to assess new bone formation and plan the accuracy of the implant position. A crestal incision and subperiosteal dissection of the alveolus were performed and the fixation screws were removed. Implant site preparation was performed with guidance from the laboratory-made splint and the implants were positioned (Figs. 12–18). We used bone-level type titanium implants. The most common in use were Straumann® Bone Level implants (Institut Straumann AG, Switzerland), followed by Astra® (Astra Tech Inc.) and Camlog® (CAMLOG Vertriebs GmbH, Germany). In total, 155 implants were positioned, 39 in the maxilla and 116 in the mandible. Three to six months later, the prosthetic work was started.

Clinical appointments were performed after surgery to evaluate any complication at the donor and recipient site, such as dehiscence, infection, swelling, sensory disturbances or haemorrhage. Graft loss and graft removal were defined as failure; swelling, wound dehiscence, incision line opening, infection with pus or temporary paresthesia were defined as complications. Buccal nerve damage from incision along the external oblique ridge as well as the damage of inferior alveolar nerve is possible. Graft incorporation was evaluated following the removal of the fixation screws. Statistical analysis included descriptive statistics using IBM SPSS Software for Windows. The significance level of  $p \leq 0.05$  for all statistical tests was definite. The residents of our department operated and followed upon all patients, and the results were analysed in percentage and presented in tables and diagrams.

### Disclosure

The authors do not have any financial interests, either directly or indirectly, in the products listed in the study.

### \_contact

### implants

#### Andreas Sakkas

Oral Surgeon  
Department of Oral and Maxillofacial Surgery, Facial Plastic Surgery  
Military Hospital Ulm and Academic Hospital University Ulm  
Ulm, Germany

Tel.: +49 731 17101701  
andreaszfc13@yahoo.gr

*Editorial note: To be continued in implants 4/2013 with results, an extensive discussion and tables. A full list of references is available from the publisher.*



# I AM A FAN

like most of my colleagues.

Dr. Leyli Behfar | Specialist in Oral Surgery

CAMLOG is my first choice when it comes to dental implants. With their high-precision implant systems, I find an answer for every indication. Implantations can be performed easily, efficiently and with excellent quality standards. CAMLOG is an inspiring partner in many ways – and that is getting around. [www.camlog.com](http://www.camlog.com)

a perfect fit™

camlog

# GTR and recession coverage in immediate implantation

**Authors**\_Dr N. Papagiannoulis, Dr E. Sandberg & Dr M. Steigmann, Germany

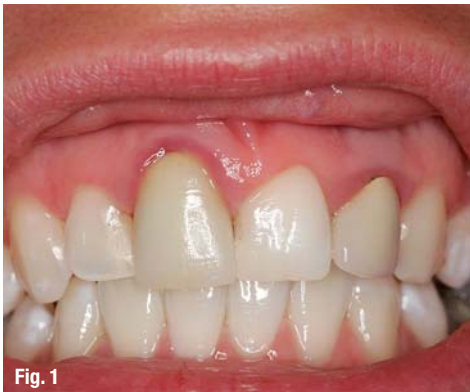

Fig. 1

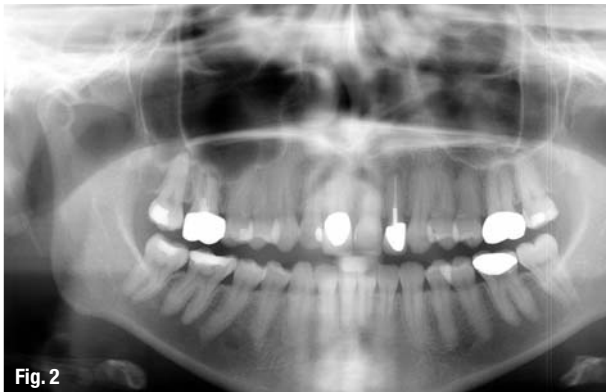

Fig. 2

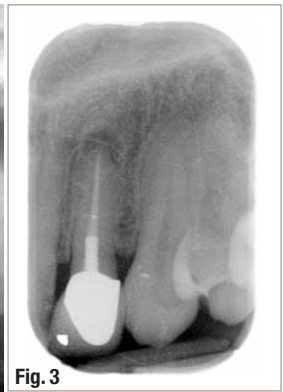

Fig. 3

**Fig. 1**\_Initial situation.

**Fig. 2**\_Preoperative panoramic radiograph.

**Fig. 3**\_Tooth 11 post-op.

## \_Introduction

Among the difficulties and challenges in immediate implantation, local inflammations of the hard or soft tissue are major criteria on how we implant. The behaviour after implantation, especially of the soft tissue, is only predictable when the diagnosis and the treatment concept are correct. Gum recessions are potential contra-indications for immediate implant placement.

Nevertheless, we have to take into consideration that soft tissue and recession coverage techniques function differently when applied to implants. A calculated risk is acceptable if the procedure prevents soft and hard tissue from absorbing, which can lead to compromised aesthetics and an unsatisfied patient.

**Fig. 4**\_Tooth 22 post-op.

**Fig. 5**\_Implant insertion tooth 11.

**Fig. 6**\_Implant inserted in tooth 11.

## \_Clinical and radiological findings

The patient visited the practice complaining about compromised aesthetics of the anterior maxilla. The first examination showed a challenging situation of teeth 11 and 22. In the past years, the almost 30-year-old patient had experienced the whole range of dentistry, including endodontology, periodontology, and surgical crown extension.

Teeth 11 and 22 were insufficiently restored, with tooth 11 showing a soft tissue recession Miller class 2 and tooth 22 showing an apical inflammation. Bleeding on probing was positive in 11 (grade 4), so were percussion and mobility in 22. The crown in tooth 11 was overextended, probably to cover recession. Crown 22 was also overextended, leading to secondary caries. The periodontal screening index on 11 was grade 3 with

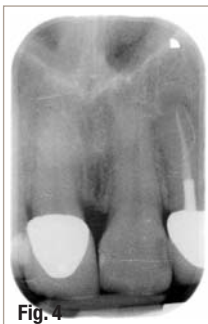

Fig. 4

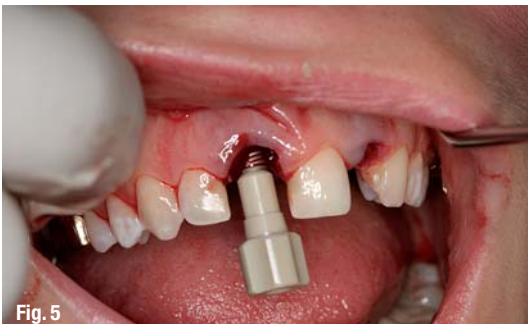

Fig. 5

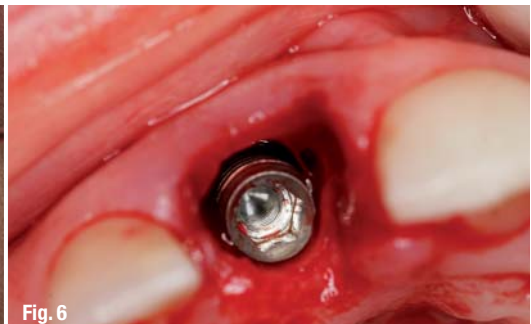

Fig. 6

## Join us at EAO Dublin!

Attend the interesting lectures about hard- and soft-tissue augmentations

Thursday, 17 October 2013, 11:00 – 13:00



PD Dr. Ronald E. Jung, Switzerland

Hard- and soft-tissue  
concepts for alveolar ridge  
preservations

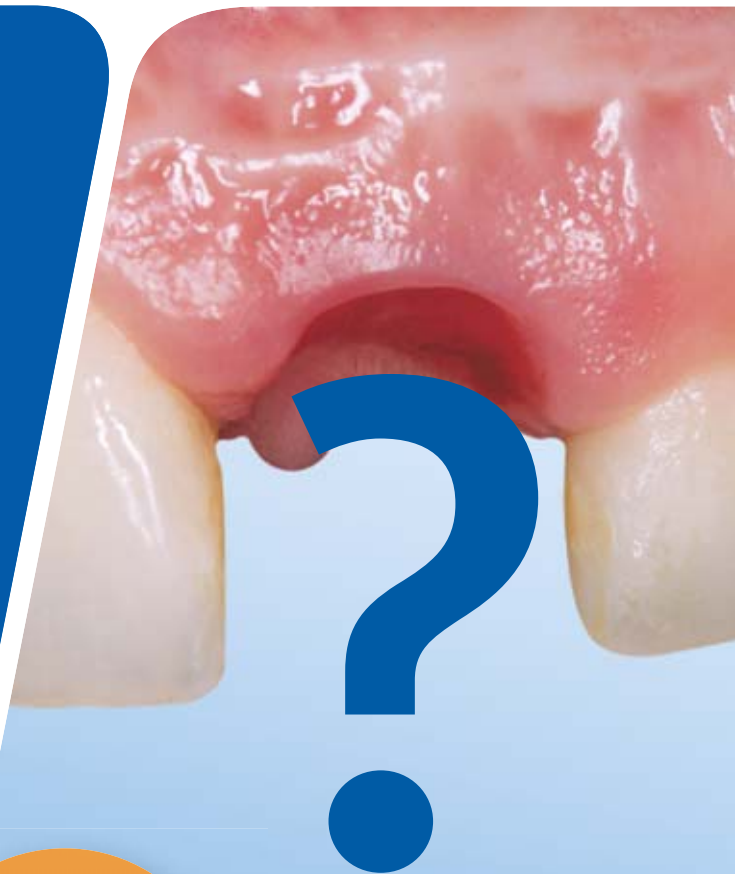

Dr. Daniele Cardaropoli, Italy

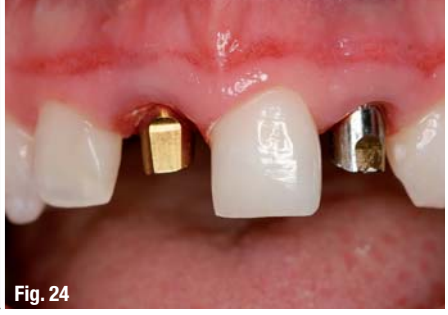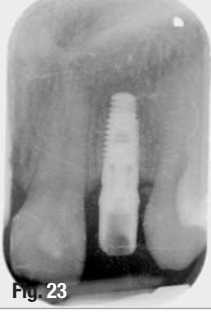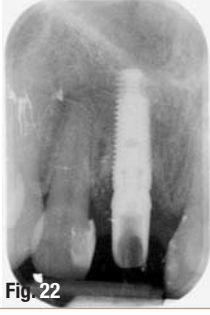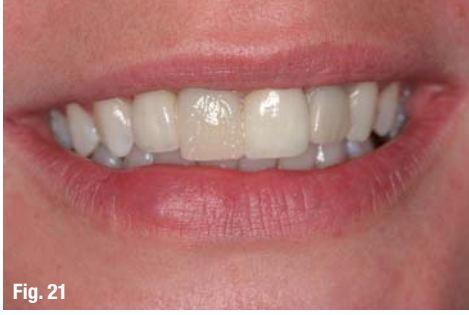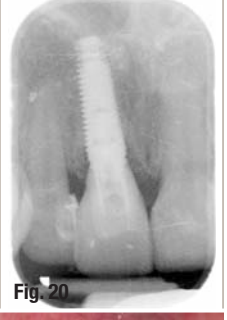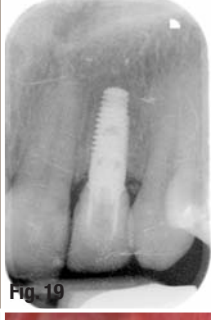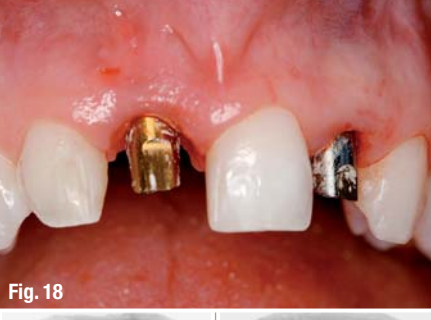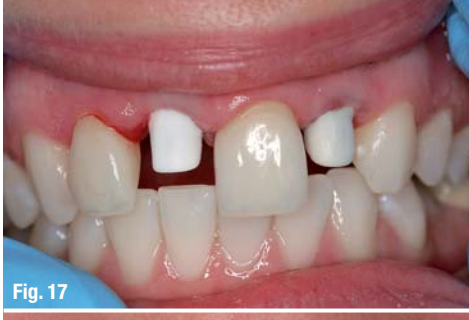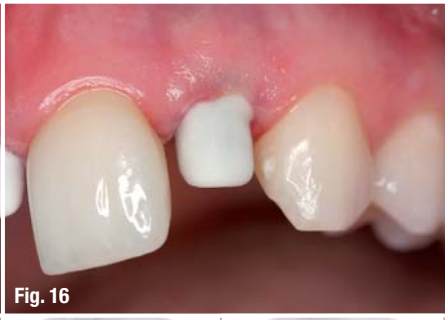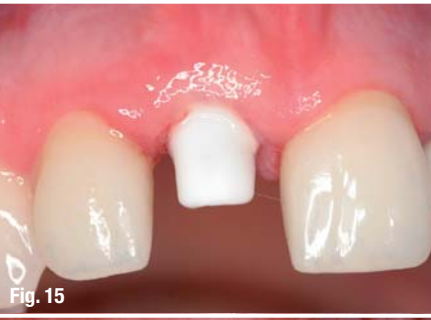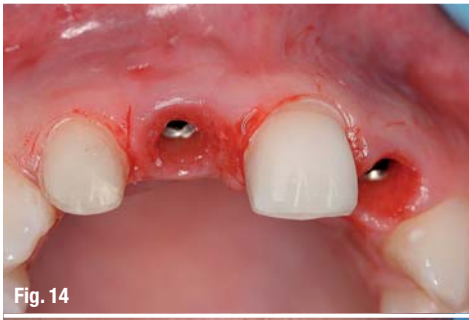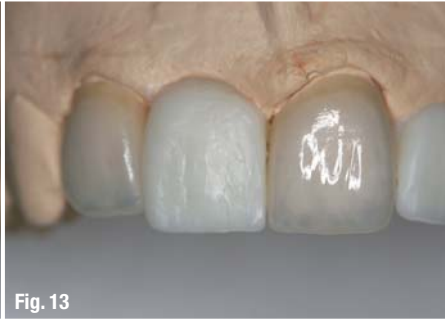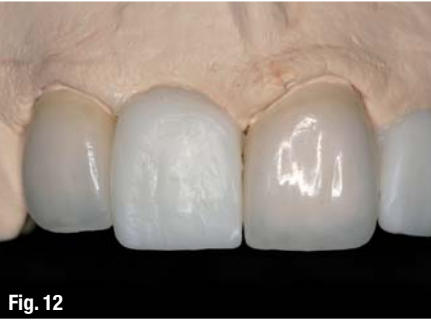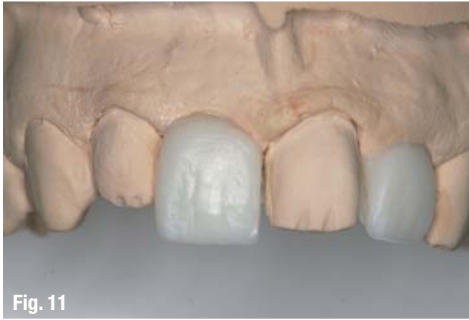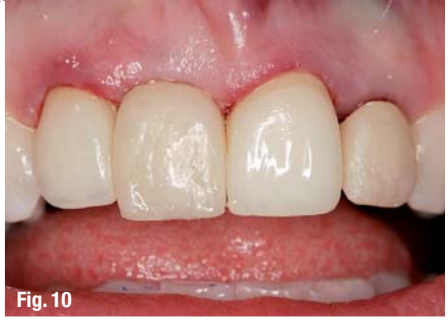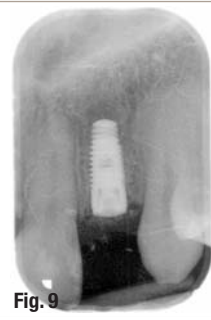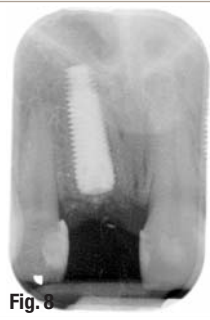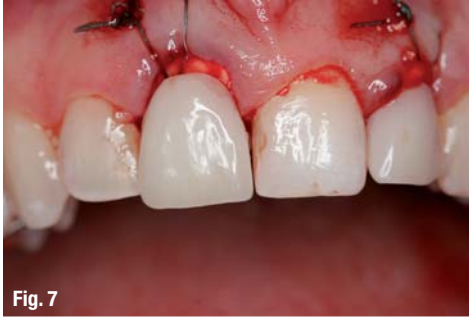The management of soft tissues  
in post-extractive site and  
periodontal plastic surgery

More information:  
[www.geistlich-pharma.com/dublin2013](http://www.geistlich-pharma.com/dublin2013)

Visit us  
at our  
booth #G1!







**Fig. 7**\_Provisional crown and GTR.

**Fig. 8**\_Tooth 11 post-op.

**Fig. 9**\_Tooth 22 post-op.

**Fig. 10**\_Three weeks post-op.

**Fig. 11**\_Provisional crown on the modell.

**Fig. 12**\_Veneers, biscuit bake.

**Fig. 13**\_Completed provisional crown and veneers.

**Fig. 14**\_Four weeks after re-entry.

**Fig. 15**\_Try-in of zirconium abutment 11.

**Fig. 16**\_Try-in of zirconium abutment 22.

**Fig. 17**\_Zirconium caps in occlusion.

**Fig. 18**\_Tissue quality four weeks after provisional placement.

**Fig. 19**\_Provisional crown tooth 22 after re-entry.

**Fig. 20**\_Provisional crown tooth 11 after re-entry.

**Fig. 21**\_Veneers and provisional crown placed after re-entry.

**Fig. 22**\_Try-in of abutment tooth 11.

**Fig. 23**\_Try in of abutment tooth 22.

**Fig. 24**\_Abutments and completed crowns.

3.5 mm mesially and 4.0 mm distally. The radiological control (Figs. 1–4) also shows a discrepancy between preparation and crown modelling in tooth 11. This artificial undercut and the minimized biological width were the main reasons for the local inflammation.

### \_Planning

Teeth 11 and 22 were to be extracted. A new crown on 11 would not offer any better aesthetic and functional results. Due to the root screw, the root treatment on 22 was risky and its result was unpredictable. Larger composite fillings on 12 and 21 compromised aesthetics additionally.<sup>2–5</sup>

The treatment plan included the following steps:

1. Extraction of teeth 11 and 22 with immediate implantation and guided bone and tissue regeneration.
2. Maryland Bridge as a temporary restoration.
3. Veneers on teeth 12 and 21 after implant re-entry.
4. Full ceramic crowns on teeth 11 and 22.

### \_Surgical phase

After extraction of teeth 11 and 22, the ridge was cleaned and disinfected. No injury or perforation of the buccal lamella was observed. The implant system used was tapered, with platform switching and high primary stability. The drill sequence was followed as provided by the manufacturer but with no irrigation and a low rotation of 50 to 70 rpm with maximum torque.<sup>10–14</sup>

Implants were placed slightly subcrestally so that the apical coronal position was 0.5 mm below bone level. In region 11, a 4.1 x 13 mm implant was inserted (Figs. 5–8) and an implant of 4.1 x 10 mm in region 22 (Fig. 9).<sup>6–8</sup> The gap to the buccal plate of 1 mm was augmented with a mix of  $\beta$ -TCP and HA 40%–60%.<sup>9,15</sup> No effort was made to manipulate the soft tissue recession or raise a flap. Cuts in this region would have led to major recessions because of the periodontal situation of the neighbouring teeth. For this reason, the recession in tooth 11 was left as it was. The crestal part of the extraction socket was covered with collagen tissue fleece. At last, a piece of dermis matrix was positioned crestally and slightly buccally to improve soft tissue quantity after healing.<sup>16–19</sup>

The provisional Maryland Bridge was manufactured with pontics on 11 and 22 for optimal soft tissue management (Figs. 10–13). Recall appointments were kept for one, three, seven, 14, 21 and 30 days and afterwards monthly.

### \_Provisional and healing phase

At four weeks postoperatively, the bridge was removed and teeth 12 and 21 were prepared to receive veneers. The soft tissue condition was optimal, without inflammation and with full epithelialisation of the wound. With a new temporary restoration, we forwarded soft tissue conditioning. Radiological controls were made after each cementation procedure to preclude cement rests and a risk of periimplantitis. Veneers were inserted before loading the implant for better colour adaptation of the supra-construction, but also after implant re-entry for an optimal emergence profile planning.

### \_Implant re-entry

The re-entry was performed three months postoperatively with a simple mucoperiosteal flap. The quality of the soft tissue was good so that a small crestal cut of 4 mm was enough to remove the healing screw. Instead of inserting a gingival former, we decided for a temporary abutment with a composite crown, resulting in a screw-retained provisional. No risk of cement rests was taken and the screw-retained temporary crown enabled us to manipulate soft tissue as desired for an excellent aesthetic outcome. The patient received this temporarily for four weeks and afterwards impressions were taken.

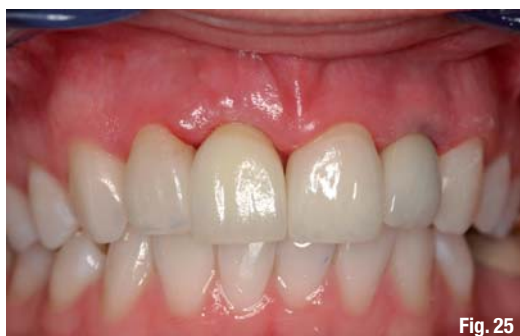### \_Restorative phase

The veneers were retained four weeks after implant re-entry (Figs. 13 & 14, 19–21). At this time, we had optimal conditions for colour selection and impression of the implants with customised implant copies. At the first abutment try-in (Figs. 15–18, 22 & 23) we could see the soft tissue regeneration and forming around the zircon caps. Even the gingival surface texturing is evident.

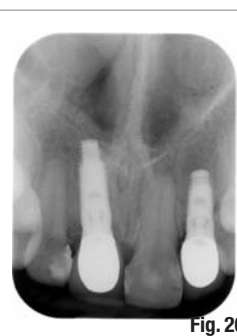**Fig. 25** Crowns completed.

**Fig. 26** Check-up of teeth 11 and 22 and crowns.

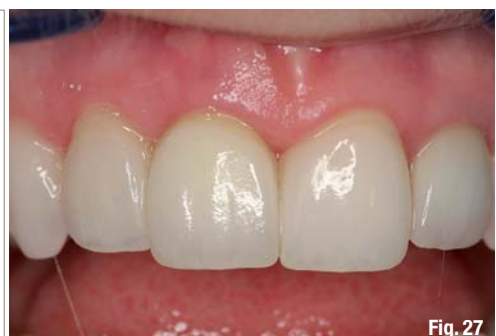**Fig. 27** Three months after insertion of crowns.



**Fig. 25**

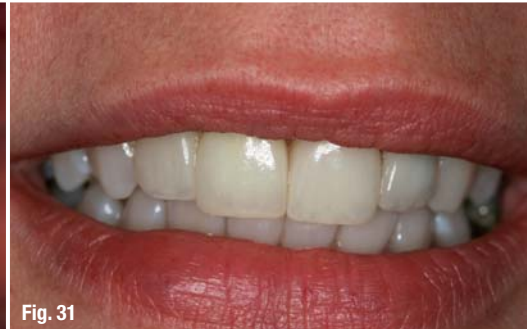
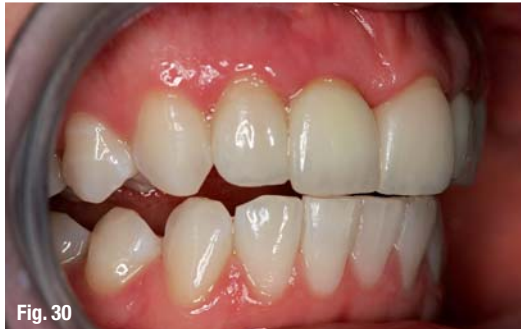
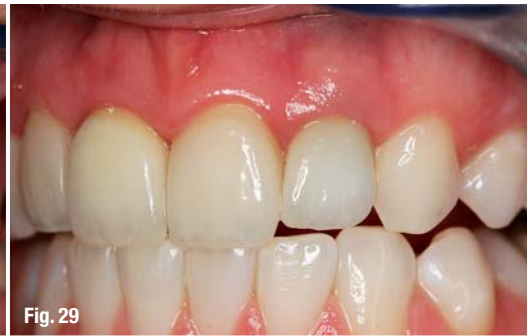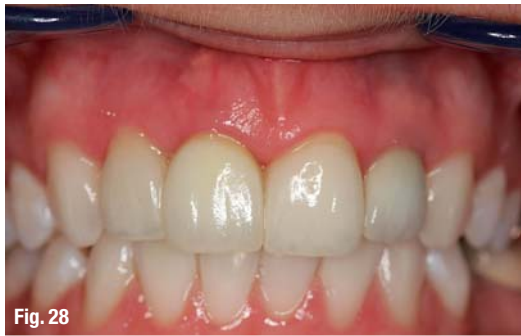**Fig. 26**



**Fig. 27**

Fig. 28\_Occlusion.  
 Fig. 29\_Left.  
 Fig. 30\_Right.  
 Fig. 31\_Smile.



The correct abutment and crown insertion (Figs. 24 & 25) were controlled with X-rays (Fig. 26). Not only did the surgical part lead to such highly aesthetic results, but also the technical part played a crucial role in the aesthetic outcome (Figs. 27–31). The soft tissue situation showed a slight improvement of the papilla on tooth 11 four weeks after loading.

### Discussion

The decision to extract the teeth and place implants immediately is always a risk. This risk is lowered if we understand why the tooth had to be removed, how biology works and what we can or must not do. In this case, a flap raise or papilla raise would have been fatal with regard to aesthetics, resulting in unpredictable and major defects. The implant position slightly beneath the crestal bone level is correct, calculating the inevitable loss of crestal height through the former local inflammation. The grafting of the buccal plate gap is also appropriate and leads to a higher predictability when performed with a combination of fast and slow, or slow and non-resorbable biomaterials.

Platform switching is a useful technique to offer soft tissue or hard tissue space to grow and a stable scaffold for support. When the system offers real platform switching, as seen here, hard tissue growing on the reversely bevelled implant neck prevents crestal bone resorption. Especially soft tissue growing and covering the implant neck will form a tissue ring around it, protecting the crestal bone from resorption as well. Prosthetics are as important as the surgical part. They encompass the final restoration with the emergence profile, the proximal contact and margin design, but the temporary restoration also is crucial for soft tissue

maintenance, management and long-term stability. As can be seen from the recall photos four weeks after loading, the soft tissue fills the proximal gaps if the conditions for it are fulfilled. The initial recession is gone and we created enough soft tissue for good aesthetic results. The tight interdisciplinary collaboration between surgeon, technician and restorative dentist finally guaranteed a satisfactory result and a happy patient.<sup>20-25</sup>

### \_contact

### implants

#### Dr N. Papagiannoulis

Proaesthetic Dental  
 Praxis für kosm. ZHK und Implantologie  
 Brückenkopfstr. 1/2  
 69120 Heidelberg, Germany

Tel.: 06221 9986482  
 Fax: 06221 9986484

[www.fsde.com.gr](http://www.fsde.com.gr)

#### Dr E. Sandberg

Zahnarztpraxis Dr Sandberg & Kollegen  
 Liebigstraße 11  
 60323 Frankfurt/Main, Germany

Tel.: 069 97097171  
 Fax: 069 97097272

[www.dr-sandberg.de](http://www.dr-sandberg.de)

#### Steigmann Institute

Bahnhofstraße 64  
 69151 Neckargemünd, Germany

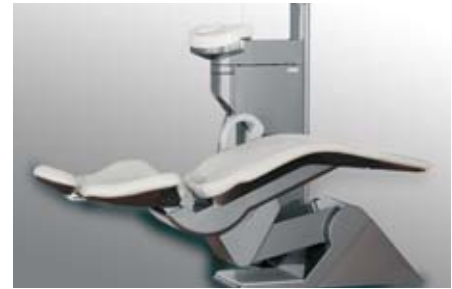**\_RITTER IMPLANTS SYSTEM  
\_Quality. Flexibility. Innovation.**



Founded in 1887 by the German Frank Ritter in New York, Ritter is one of the oldest prestige brands of finest dental equipment worldwide. Due to innovative ideas and a great entrepreneurial spirit, Ritter produced the first dental units already more than 125 years ago.

Today Ritter products are more than ever an essential element in dental practices worldwide. Users appreciate the Ritter product range for the high-quality aspects and the reliability - Made in Germany. Due to their functionality and user orientated construction, Ritter dental units contribute constantly to an optimized workflow of today's modern dental practices.

In the course of the last years, Ritter has started to write a new success story with the launch of an innovative, state of the art implant system. The Ritter Implant Ivory Line provides Two Piece Implants (Implant plus separate Abutment) as the QSI Spiral Implant and TFI Twin Fissure Implant as well as One Piece Implants (Implant and Abutment already connected) called Mono Compress Implant MCI. The system contains logically reduced and clearly arranged components of tools and abutments with the best features for all clinical cases. Due to the super Nano-Surface, a quick and reliable Os-



seo-Integration is guaranteed. Clever and easy handling is provided by self-tapping threads and a coloured system of drills and implants according to their diameters.

All Ritter Implants and Accessories are made by high modern CNC manufacturing machines. A combination of advanced machining and hand-finishing create the most accurate tools possible for the marking of ceramic drills.

The Ritter brand stands for high quality, state of the art technology and innovative products Made in Germany. The credo is to always provide customers and clients with the best services and prices combined with the most comprehensive dental solutions in the market.

More information:  
[www.ritterimplants.com](http://www.ritterimplants.com)

**NEW**  
...ask for your special start offer:  
Set price, incl. Implants, Analogs, Transfers  
Abutments, Healing Caps and Starter Tool Kit!

- Leipzig Fachdental, 06.-07. Sept.**  
Stand-Nr. 4A47
- Hamburg ID Nord, 21. Sept.**  
Halle A1, Stand-Nr. G43
- Stuttgart Fachdental Südwest,**  
11.-12. Okt. Stand-Nr. 4B44
- Frankfurt ID Mitte, 08.-09. Nov.**  
Stand-Nr. F34
- Implant Expo Frankfurt,**  
29.-30. Nov. Stand 107

**FAX VOUCHER**



YES, I want to save my benefit !  
Please contact us as soon as possible.  
I confirm with my address and signature / stamp

Number of Sets (max.10)	<input type="text"/>	NAME	<input type="text"/>
STREET	<input type="text"/>	VAT-NO.	<input type="text"/>
CITY / ZIP	<input type="text"/>	COUNTRY	<input type="text"/>
FON	<input type="text"/>	EMAIL	<input type="text"/>
DATE	<input type="text"/>	SIGNATURE	<input type="text"/>

**%**



# Periimplant lesions— causes and treatment options

Author\_Dr Georg Bach, Germany

## \_Introduction

While in the early stages of implantology, issues concerning the "healing" of artificial abutment teeth were in the focus of interest, those early complications have become rare due to improved implant forms, optimised minimally invasive diagnostic and surgical techniques, and especially because of improved implant surfaces.

Instead, "long-term complications" with implants that have been osseointegrated for many years, which are functioning and have developed periimplant infections, have become the focus of interest for dentists/implantologists.

### **Figs. 1–4\_ The hygienisation phase:**

The hygienisation phase is an essential treatment step at the beginning of periimplantitis treatment. Hard and soft plaque must be removed from the superconstruction and at the transition from gingiva to superconstruction. To avoid scratches on the implant surface, many authors recommend the use of plastic curettes or curettes with titanium covered ends. Additional disinfectant measures, i.e. rinsing with chlorhexidine digluconate, may be necessary. Polishing is the final step in this initial treatment regimen.

Now the patient has to be guided back to the straight and narrow: He or she has to be willing and, with enhanced instructions, also able to clean the superconstruction sufficiently. A continuous recall system guarantees the respective success monitoring. If the periimplant lesion is limited to mucositis, the hygienisation phase may even be the final step in the treatment of periimplantitis.

This type of infection on/around the implant, which can lead to serious bone loss and, if untreated, will result in the loss of the artificial abutment tooth (and generally also in the loss of the superconstruction), is referred to as periimplantitis.

There are two possible causes:

- Infectious/bacterial (as defined by MOMBELLI, 1987).
- Functional/aseptic, e.g. due to stress phenomena caused by not observing a balanced proportion of implant length/crown length and disregarding serious deficits of the osseous implant site (as defined by JASTY, 1991). Functional/aseptic periimplantitis is usually the exception.

The majority of periimplant infections are of bacterial/infectious origin. According to information provided by the only chair holder of dental implantology, Professor Dr Herbert Deppe, a prevalence of up to 15 per cent of implants can be expected after 10 years.

Thus, the prevention and treatment of periimplantitis have now become two of the major tasks in implantology. This article will provide information about tried and tested laser treatments, but also about new therapeutic approaches with laser light for the treatment of bacterial periimplantitis.

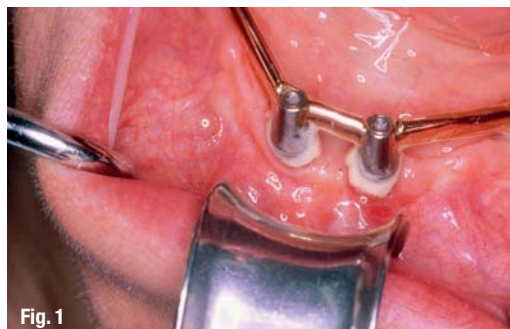

Fig. 1

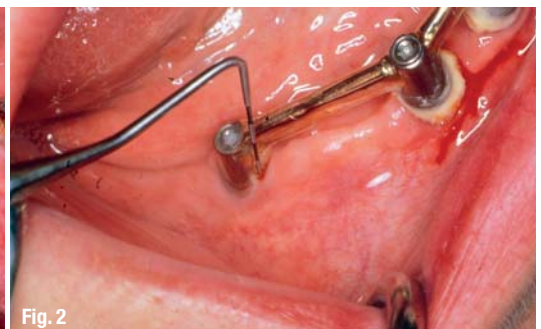

Fig. 2

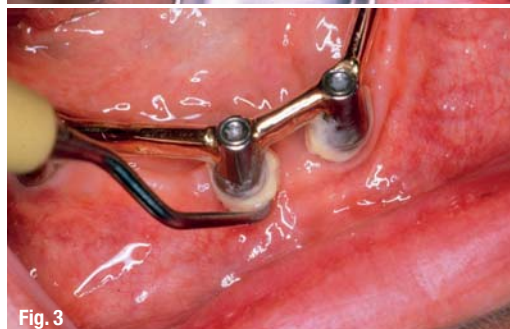

Fig. 3

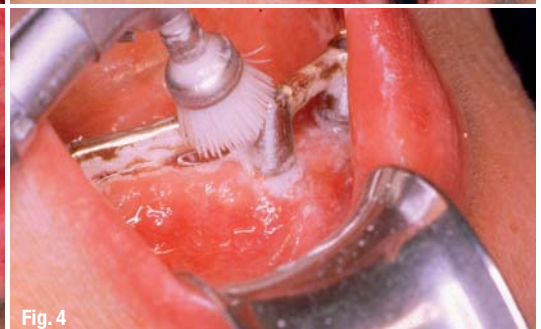

Fig. 4

## Treatment of the infectious form of periimplantitis

### The four-phase treatment scheme

Many authors agree on a four-phase regimen for the treatment of periimplantitis:

- 1) Initial treatment: This initial phase of PI treatment consists of diagnosing periimplant lesions (as early on as possible), cleaning and hygiene procedures as well as motivating/instructing the patient suffering from periimplantitis.
- 2) Surgical resective phase: After local anaesthesia and the creation of a soft-tissue flap, an image of the peri-implant defect (generally with its unique crater-like form) is taken, the granulation tissue is removed and the bone is cleaned.
- 3) Augmentative/reconstructive phase: The primary goal—although not always achievable—is an augmentation which will ultimately lead to a restitutum ad integrum: In this case, as opposed to an augmentation, the patient's own bone is not the gold standard; bone substitutes have become established.
- 4) Recall-Phase: All authors agree in their definition that recall is just as important as the actual treatment of a periimplant infection. If there is no adequate and short-term recall after the successful treatment of periimplantitis, recurrence will be just a matter of time.

## Explantation as a treatment option for periimplantitis

Explantation would indeed be a "treatment option" if the defect situation proves very difficult for executing the above-mentioned regimen or if the osseous lesions are so severe that there is only a poor overall prognosis for the implant. At times, explantation may even be the only choice if it can be assumed that, by leaving the implant in place, the infection would result in further bone loss that could prevent implantation at a later time or complicated augmentative measures.

### Use of laser light

There is more and more mention of the use of laser light in both the resective/surgical and the recall phases primarily. In principle, two types of laser light applications can be defined:

- a) Laser light application without morphological changes on the implant surface and without ablativ effect: decontamination.
- b) Laser light application with abrasive effect: ablativ treatment (possibly in combination with decontamination).

AD

**14 Years**  
6,0 x 5,7mm

**28**  
YEARS OF CLINICAL USE  
SINCE 1985  
SHORTEST IMPLANTS  
LONGEST HISTORY

5,0 x 5,0mm 4,0 x 5,0mm 6,0 x 5,0mm  
4,5 x 6,0mm 5,0 x 6,0mm 6,0 x 5,7mm

**Since 1985** » Simple. Predictable. Profitable.

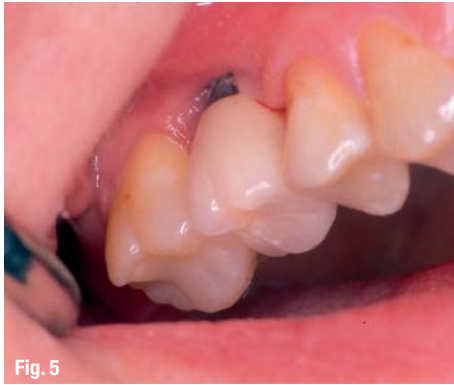

Fig. 5

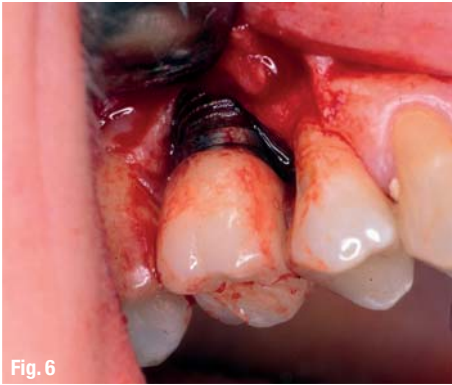


Fig. 6

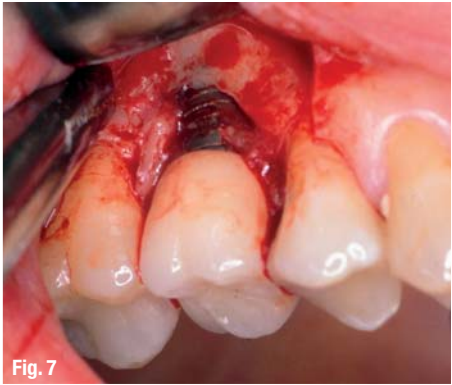


Fig. 7

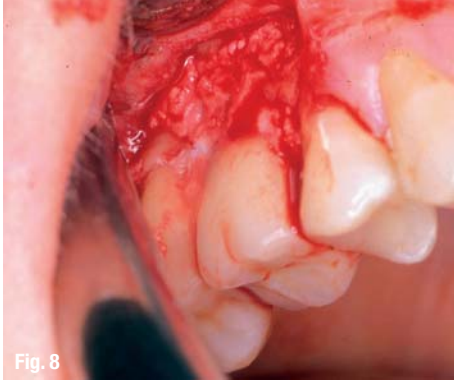


Fig. 8

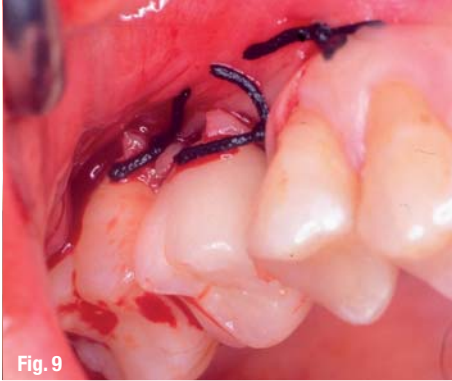


Fig. 9

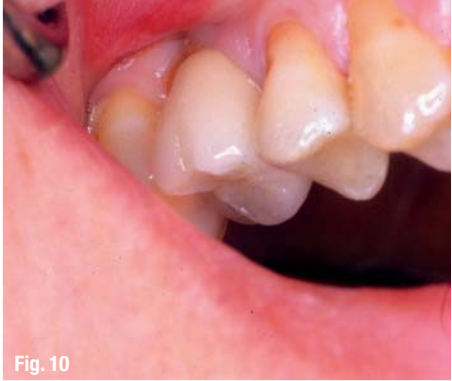

Fig. 10

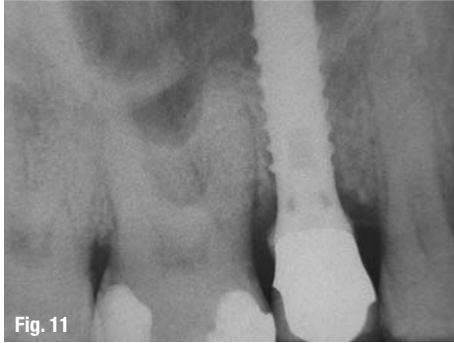

Fig. 11

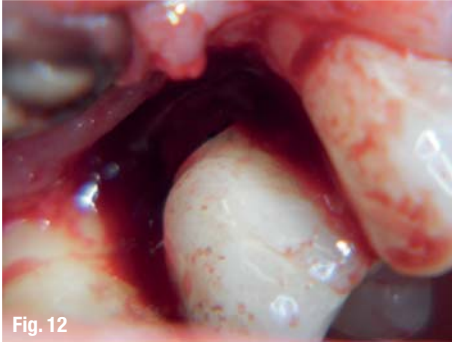

Fig. 12

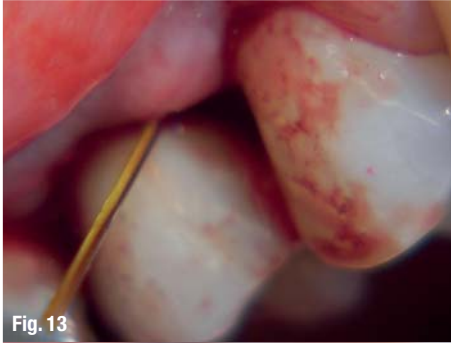

Fig. 13

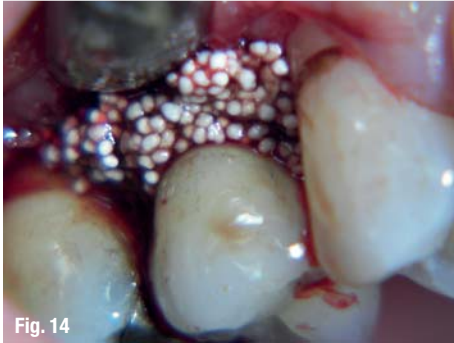

Fig. 14

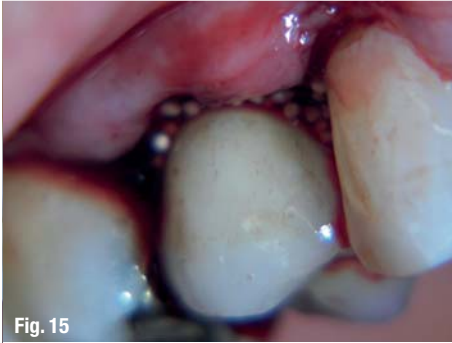

Fig. 15

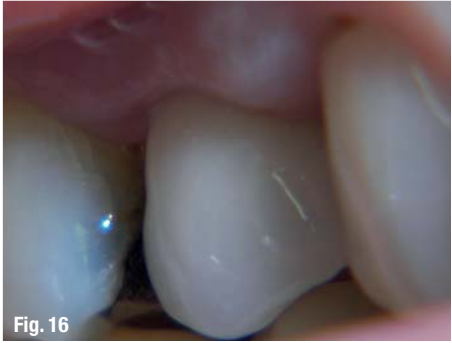


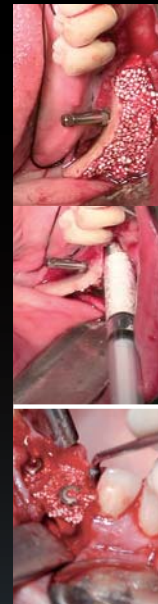Fig. 16

**Figs. 5–10** Simplified laser-assisted treatment of periimplantitis with a pasty bone substitute: The original clinical image (Fig. 5) already shows the typical symptoms of periimplantitis, which are confirmed after the creation of flaps (Fig. 6). A profound bone defect has developed around the artificial abutment tooth; the granulation tissue is thoroughly removed (Fig. 7). A pasty bone substitute (Ostim®) can be applied congruently with the defect (Fig. 8); the wound is then closed with a suture (Fig. 9). The last image of this case study (Fig. 10) shows the two-year check-up, which revealed a stable and

aesthetically pleasing result. Proponents of this procedure (use of a pasty bone substitute) emphasise the simple application of the bone substitute congruently with the defect and the advantage of a simplified treatment by foregoing the membrane (“periosteum is the best membrane”).

**Figs. 11–16** Laser-assisted treatment of periimplantitis with a bone substitute with improved application: The X-ray shows considerable vertical bone loss which has already reached the 50% mark of the coated portion of

the implant mesially. After thorough cleaning of the implant surface, a laser light decontamination (here with diode laser light—wavelength 810 nm—in cw mode—20 seconds—1 watt of power) is then performed in pure decontamination mode, non-ablative. Following application of the bone substitute, which is hardened with a bio linker in such a way that the particles can both be well applied and adhere to each other (easy-graft®), the wound is then closed with a saliva-proof suture. The last image shows the check-up after two years, fortunately with no clinical problems.



sticky granules  
bionic



easy-graft®  
CRYSTAL

**Ingenious:** Simple handling  
and accelerated osteocon-  
duction for long-term volume  
preservation.

SUNSTAR  
GUIDOR®

Degradable Solutions AG  
A Company of the Sunstar Group  
Wagistrasse 23  
CH-8952 Schlieren/Zurich  
[www.easy-graft.com](http://www.easy-graft.com)

The proponents of ablative treatment argue that they "kill two birds with one stone" by removing any contamination from the implant surface, by smoothing it and possibly eliminating any bacteria and microorganisms. The proponents of pure decontamination, on the other hand, point out the risks of unwanted effects on the implant surface, which would complicate or might even prevent the re-appositioning of the bone, and the excellent long-term results of pure decontamination. In this context, they also accept that, in their non-ablative form of laser treatment for periimplantitis, the implant surfaces must be cleaned with suitable manual instruments prior to laser light application.

## Technique for both of the two treatment options

### 1. Decontamination without ablative effect or morphological changes on the implant surface in the sense of a pure decontamination

The term "decontamination" was coined by the Freiburg Laser Research Group Bach/Krekeler and Mall in 1994–1995. They introduced the diode laser to dentistry, which had been unknown until then. For decontamination, the diode laser light (810 nm) is applied to the implant surface with the largest possible fiber (usually 600 µm) under contact and with constant movement. The authors from Freiburg indicated a maximum power of 1 W and an application time of no more than 20 seconds for the laser light treatment. A 30-second waiting period is necessary if there is a need for further laser light application on the same implant. In clinical applications, a waiting period of 20 seconds has proven to be completely sufficient. If an implant shows a surface that is exposed from the bone and that requires an application of laser light in excess of 20 seconds, the prognosis for this artificial abutment tooth should be categorised as unfavourable and the periimplantitis treatment considered questionable if not experimental.

Bach/Krekeler and Mall expressly caution against exceeding the time-time values, which would inevitably cause a heat build-up in the implant and in the periimplant bone, and thus lead to destruction. The parameters mentioned by these authors (1.0 W/ max. 20 seconds of laser light application) have been impressively confirmed by other authors (Sennhenn-Kirchner et al., Moritz et al.) and/or accepted by the device suppliers and manufacturers on the flourishing diode laser market.

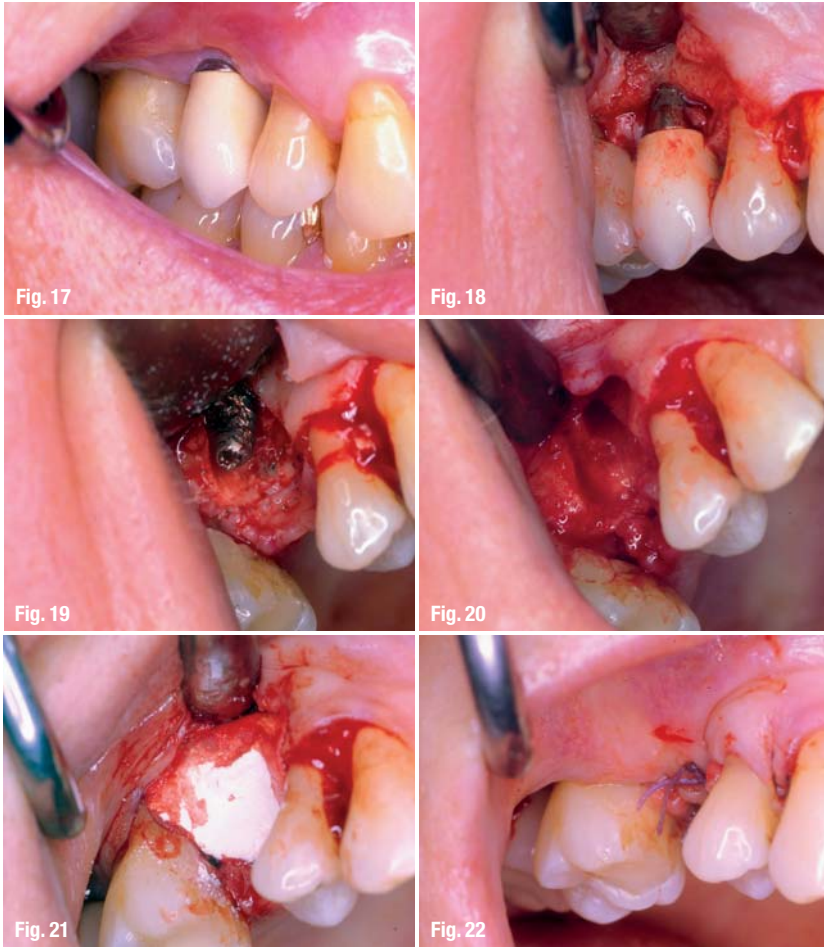Romanos et al. described the option of working with Nd:YAG lasers without changing the surface. However, there are no long-term and clinical results yet. The above-mentioned diode laser research group in Freiburg, on the other hand, submitted a ten-year study in 2005, proving a reduction in the recurrence rate from previously 30% (without laser) to now 11% (with diode laser). These authors called for an integration of diode laser decontamination as a standard procedure into tried and proven schemes for periimplant treatment. Long-term clinical findings for laser treatment of periimplantitis were also achieved with a further wavelength: CO<sub>2</sub> (gas) lasers have been used for the treatment of periimplantitis since the work of Deppe, Horch and colleagues (university of Munich) was completed.

Prof. Dr Herbert Deppe and his co-authors were able to prove that the use of the gas laser, which had been regarded critically for the treatment of periimplantitis until then, is appropriate here and will later—after the periimplant infection subsides—yield a favourable starting point for the regeneration of the supporting tissue. Deppe suggests the use of the CO<sub>2</sub> laser in continuous-wave (cw) mode with 2.5 W of power for 10 seconds. He works with a scanner and, if necessary, also with a dental powder jet and post-operative application of a membrane. A five-year study (Deppe and Horch, 2005) is also available.

### 2. Procedure with ablative effect (laser curettage) and possibly an additional decontaminating effect

– Er:YAG laser: Compared to the laser light decontamination procedure described above, the ablative laser light procedure uses additional wavelengths: This laser with ablative effect used for the treatment of periimplantitis is the Er:YAG laser. This wavelength has





**Figs. 17–22\_ The hopeless case— the explantation:** When looking at the initial clinical diagnosis (Fig. 17), only its unfavourable aesthetics might be noticeable. However, after creation of a soft-tissue flap, the “true extent of the horror” (Fig. 18) becomes visible: the defect extends all the way to the area of the implant apex. In particular, there is no bone left buccally (Fig. 19). Periimplantitis treatment does not appear very promising because of the extent of the osseous lesions. The artificial abutment tooth has to be removed, i.e. explanted (Fig. 20), leaving a profound defect. An augmentation is carried out to facilitate a new implantation at a later time, and a membrane is inserted (Fig. 21), followed by a saliva-proof suture (Fig. 22).

been successfully used in conservative dentistry for many years and is the only wavelength that has been scientifically backed, is suitable for practice and can be used to work on and prepare the hard-tooth substance. The names Keller and Hibst are closely connected to the Er:YAG wavelength.

We owe significant scientific studies of the Er:YAG laser to these two researchers from Ulm, Germany. In the past years, Keller and Hibst—after having fully researched the treatment of the hard tooth substance—turned their attention to further integrations with the Er:YAG laser, including studies regarding the use of this laser for the treatment of periodontitis and periimplantitis. For this, even special chisel-shaped laser light applicators were made available. In 2001, Schmelzeisen and Bach confirmed the suitability of the Er:YAG laser for removing tartar and concretions from the implant surface without damaging the implant surface. However, this requires a non-contact procedure with a 30 milli-joule pulse and a PRP of 10–30 ppt for a maximum of 30 seconds.

– “Er:YAG—threshold” for PI treatment: The research group around Frank Schwarz (Düsseldorf, Germany) was finally the one who determined the “threshold value” that today is generally considered binding for

ablative treatment of periimplantitis using an Er:YAG laser (irrespective of device and manufacturer): 13.1 J/cm<sup>2</sup>. Different values can cause thermal or mechanical damage. If Er:YAG light is applied correctly, however, it leaves a clean, homogenous and intact implant surface.

– Er,Cr:YSGG laser: First experiences were also gained with the latest laser wavelength, the Er,Cr:YSGG laser that was introduced to dentistry in the treatment of periimplantitis. The names Henriot and Ritschel (Hamburg, Germany) especially come to mind in this context. They described multiple uses of the Er,Cr:YSGG laser, more widely known as Biolase, in soft-tissue surgery and in hard tissue. The respective long-term experience and multi-centric studies are yet to be confirmed.

### Summary

There are two options for using laser light in the treatment of periimplantitis:

#### *Pure decontamination, non-ablative*

For this application, diode lasers with a wavelength of 810 nm and CO<sub>2</sub> gas lasers have gained acceptance. Solid scientific data and long-term studies are available for this form of diode laser light application which, however, requires conventional cleaning of the implant surface prior to the laser light application.

#### *Ablative, possibly with additional decontaminating effect*

Er:YAG laser and the Er,Cr:YSGG laser are available for this application. They can remove concretions and tartar from the implant surface without changing its original morphology. However, strict and limiting parameters must be observed with respect to performance and time. Regarding clinical and long-term experience, the ablative procedure has not yet reached the level of the purely decontaminating diode and CO<sub>2</sub> lasers.



<u>contact</u>	<b>implants</b>
<p><b>Dr Georg Bach</b>                  Rathausgasse 36                  79098 Freiburg/Breisgau                  Germany</p> <p>Tel.: 0761 22592                  Fax: 0761 2020834</p> <p>doc.bach@t-online.de                  www.herrmann-bach.de</p>	

# 43<sup>RD</sup>

## INTERNATIONAL ANNUAL CONGRESS OF THE DGZI



### "Practice-Oriented Implantology"

October 4–5, 2013 // Berlin, Germany // Hotel Palace Berlin

Congress President // Prof. Dr. Dr. Frank Palm/DE  
Scientific Director // Dr. Roland Hille/DE

Gold Sponsor:



Silver Sponsor:



Bronze Sponsor:



**DOWNLOAD**  
PROGRAMME AND  
REGISTRATION FORM



**FAX REPLY // +49 341 48474-390**

Please send me further information on the  
43<sup>RD</sup> INTERNATIONAL ANNUAL CONGRESS OF THE DGZI  
on October 4–5, 2013, in Berlin, Germany.

Office Stamp

# Fast & Fixed as an alternative treatment in cases of periodontitis profunda

Author\_Dr Regina Schindjalova, Varna, Bulgaria

## Introduction

In the last few years, the Fast & Fixed therapy concept has proven itself an effective alternative treatment to conventional tooth implantation methods. This is especially true for patients who suffer from the severe effects of periodontitis profunda, i.e., the loss of all teeth, as shown in the case of a 44-year-old patient which is described below.

The Fast & Fixed method has emerged as an efficient treatment concept, especially when immediate implants are inserted at an angle. With that method, implantation is possible even in cases of bone loss. It

saves time and expenses, while at the same time offering the patient safety of treatment. The survival rate of those implants is between 93.7 per cent and 99.6 per cent.<sup>1,2</sup>

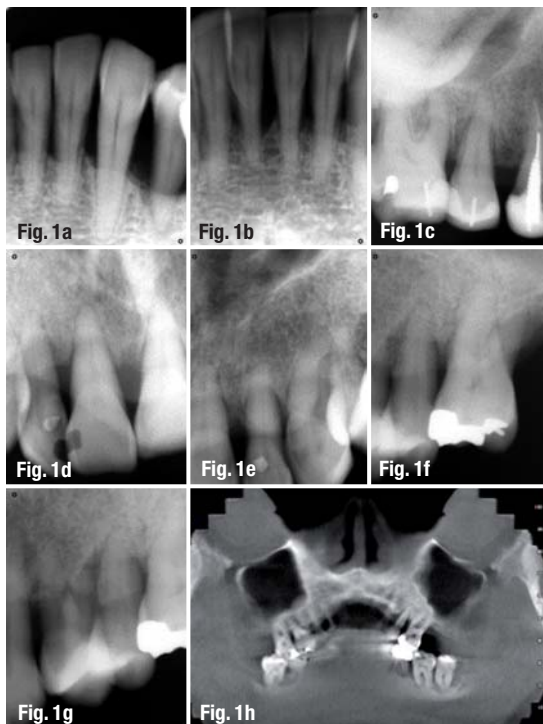
Studies that have examined the long-term survival of implants set at an angle and loaded immediately are especially interesting in this context. By looking at a time frame of ten years, it was proven that patients with reduced bone material can certainly profit from immediate implantations, in which the implants are set angularly. A loss rate of 2.9 per cent and, therefore, a success rate of 97.1 per cent were observed.<sup>3</sup>

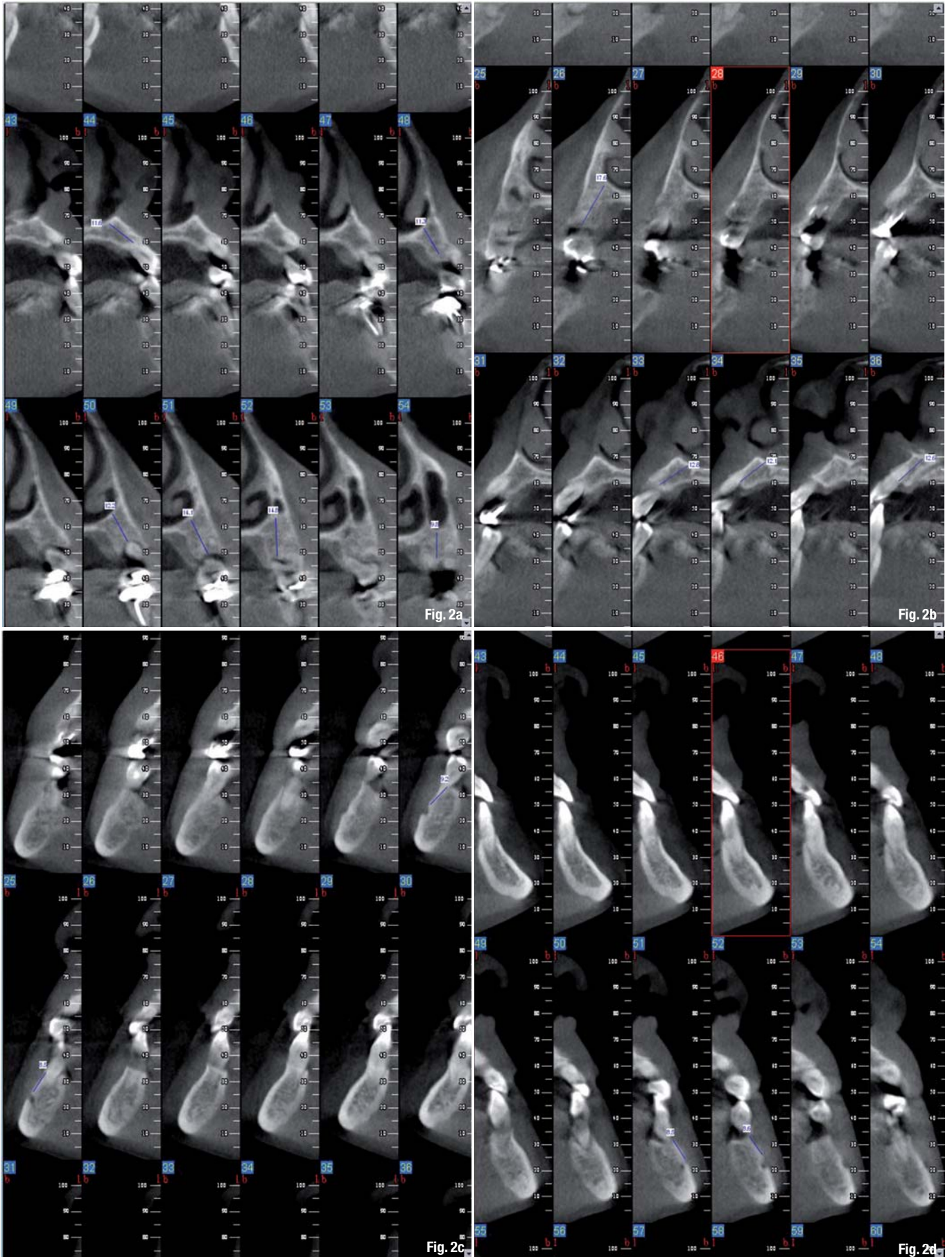
The Fast & Fixed method also compares favourably with delayed loaded implants. A large-scale study conducted in 2006 did not find significant differences between the two treatment methods when it comes to rates of healing and long-term success.<sup>2</sup>

However, when it comes to implants, it is important to always make sure that primary stability can be achieved, supported by well-fitting implants, so that safe healing and good load-bearing capacity of artificial teeth can be guaranteed. It is also important that the patient brings the proper conditions for an angular, immediate implantation: For complete treatment of the jaw he/she should be toothless (teeth may be extracted just before implantation begins). The implantologist should be experienced with regard to the method, and pre-operative diagnostics should have eliminated any possible risk factors.

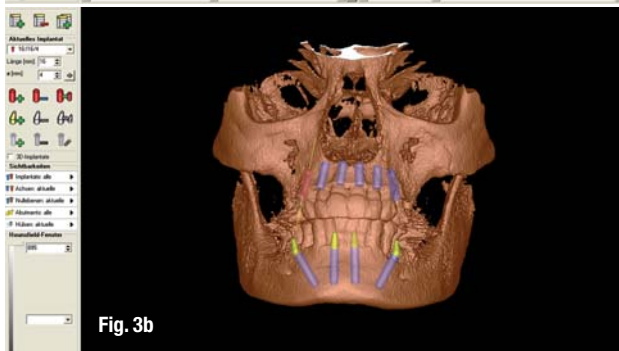
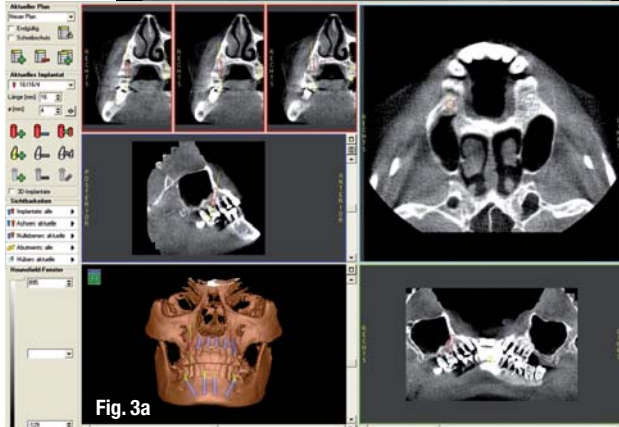
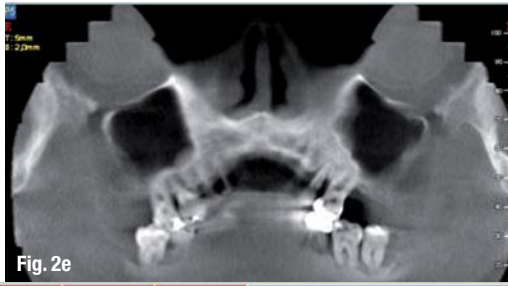Digital volume tomography is the best method for pre-operative diagnostics because the images are more precise and allow a better planning prior to implantation. Especially in cases of bone loss, this is of extraordinary importance so that a decision can be made

Figs. 1a-h Pre-operative radiological views.

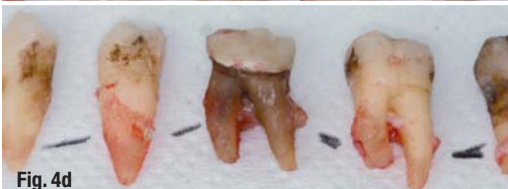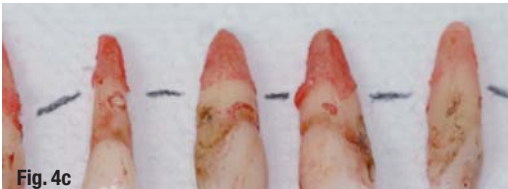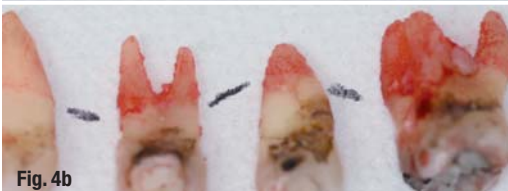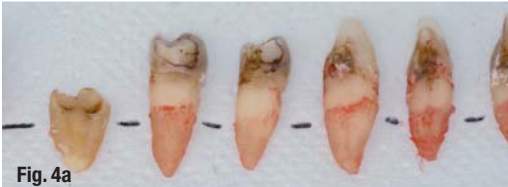




Figs. 2a-e\_Images taken with digital volume tomography.



**Figs. 3a & b**\_Co-Diagnostix Planning Software: Showing where to place implants.  
**Figs. 4a-d**\_Loss of tooth attachment shown during surgery.



whether or not an implantation is possible. With the proper planning software, actual preparations can be made virtually. For instance, in our clinic we use Co-Diagnostix.

### Case presentation

A 44-year-old female patient suffered from periodontitis profunda and came to our clinic with the specific wish of not wanting dentures under any circumstances—even as a temporary solution. All her teeth were extremely loose. Nutrition for her was limited to soft foods.

The plaque control report of our clinical examination showed optimal oral hygiene. The last professional cleaning had taken place six months ago. An additional professional cleaning was not performed since no improvements could be expected and no concretions would enter the mouth during extractions.

Concretions were found subgingivally and approx- imally, which the patient could not remove in spite of all her best oral hygiene efforts because they were located too deeply to be reached by a toothbrush or dental floss. Looseness of her teeth was between 2 and 3, but mostly at 3. Bone loss had taken place equally in the upper and lower jaw.

Further diagnostic examinations were conducted via digital tomography. Digital tomography precisely illustrates available space, nerve placements and topography of the jaw cavity. With this examination method it could be determined that the patient's teeth could not be saved.

Use of the Co-Diagnostix software facilitated detailed planning for the positioning of the implants and the necessary sinus lift of the right upper jaw. Highest precision planning was made possible by the three-dimensional images and precise data gained by the use of digital volume tomography in pre-operative examinations.

Diagnostic findings were confirmed during surgery: Natural fastening of the teeth in the upper and lower jaw was no longer possible. The teeth were extracted.

After the extraction of teeth in the upper jaw, four implants were set at an angle of 17 degrees—regio 14, 12, 22, 24. In regio 26, one implant was inserted at a 35 degree angle. Afterwards we began a sinus lift procedure in the right upper jaw. Through a window in the facial bone wall we detached and lifted the Schneider membrane from the sinus floor, the mesial and distal walls of the jaw cavity. The resulting space gave us the opportunity of anchoring endosseous implants by fill-

ing areas of the jaw with the bone replacement material Allograft made by Zimmer Dental. The implant in regio 16 was inserted at an angle of 35 degrees and fastened bicortically. The biological material Allograft was stabilised with the addition of a Bio-Gide membrane made by Geistlich.

After extraction of the teeth in the lower jaw and smoothing of the jaw tissue, implants in regio 35 and 45 were set at a 35 degree angle, and implants in regio 32 and 42 were set at a 0 degree angle. All implants—in the upper and lower jaw—were provided with abutments and prosthetic caps.

Prior to surgery, plaster models had been made. Additionally, the dental laboratory prepared a mock-up of the bite pattern, affixing synthetic teeth for the upper and lower jaws. This way, instead of taking a rough traditional bite pattern with silicone and an individual tray after the operation, a more effective and innovative method was used. Right after surgery, the prosthetic caps were powdered, and the prepared mock-ups with synthetic teeth were affixed.

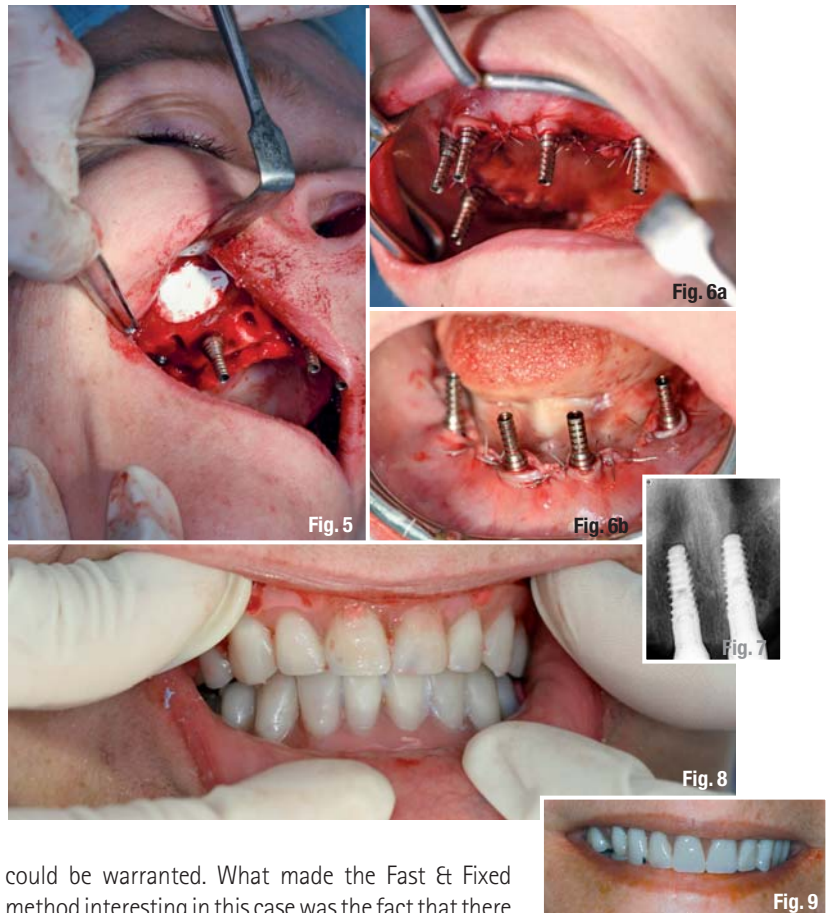
Advantages of this method: The base of the bite mock-up is used as an individual tray to show the dental technician the position of the gums. This is very important for making the base of the bridge. Using the synthetic teeth, the dental technician can determine and document the relation of the jaws, bite height, chewing-, central- and laugh lines, as well as shape and length of teeth for manufacturing the permanent dental prostheses.

This method allows the lab technician to begin making a long-term temporary solution. At the same time, this also results in enormous savings of time for the doctor and the dental technician. For the patient, there is one important advantage: A feeling of additional confidence. As in our case, the patient was able to see what her future prostheses would look like, making her feel more secure.

**Conclusion**

The Fast & Fixed therapy concept represents an interesting new development which has established itself in the last few years as a solution for toothless jaws.

This method makes a firmly seated and biomechanically supportive solution possible within 24 hours of implantation surgery. This was of special importance to our patient because she did not want removable dentures and preferred a fixed solution. Finishing her synthetic teeth the following day was made possible by the fact that no infection of the tissue was present on the day of surgery. The jaw bone was intact and was still of good quality, so that primary stability



could be warranted. What made the Fast & Fixed method interesting in this case was the fact that there was only limited bone density available, so that only angled insertion of the implants could lead to the desired success. Additional support was necessary in the right upper jaw which was obtained with the use of bone replacement material.

Bite impressions made prior to surgery saved the doctor additional time. The bite mock-ups are made exactly according to each patient's individual needs, thereby making the dental technician's work fast and efficient. The permanent prostheses are much easier to make since relation of the jaws, bite height, chewing-, central- and laugh lines, as well as shape and length of teeth had already been determined when making the mock-ups. Therefore, preoperative bite impressions and mock-ups represent an ideal addition to the Fast and Fixed method.

**Fig. 5** Stabilisation with BioGide Membrane.  
**Figs. 6a & b** Finished implantation in the upper and lower jaw, with soft tissue sutured.  
**Fig. 7** Post-op radiographs of the maxilla and mandible.  
**Fig. 8** Post-op fixed bite mock-up of the maxilla and mandible, checking occlusion for balance.  
**Fig. 9** Fixed long-term temporary solution with synthetic teeth made by Ivoclar, upper and lower jaw, 24 hours after surgery.

_contact	implants
<p><b>Dr Regina Schindjalova</b>                  Dentaprime-Zahnklinik                  St. Constantine Resort St. 27, No. 1                  9006 Varna, Bulgaria</p> <p>content@dentaprime.com</p>	

# The use of the LiteTouch Er:YAG laser in peri-implantitis treatment

**Authors**\_Prof. Tzi Kang Peng, Taiwan & Prof. Georgi Tomov, Bulgaria

## Introduction

With oral implantology experience its Renaissance, the growing incidence of peri-implantitis worldwide today is point of interest for both scientists and clinicians. Peri-implantitis is a disease of inflammatory nature which leads to the loss of the implant when left untreated.<sup>11,24</sup> The aetiological factors of peri-implantitis are very similar to periodontitis.<sup>2,24</sup> Different treatment modalities for the inflammatory soft tissue and bone lesions in peri-implants have been proposed—antibiotics, antiseptics, mechanical debridement, and surgical procedures have been suggested, depending on the grade of the clinical and radiographic manifestations.<sup>6,7,10,16,17</sup>

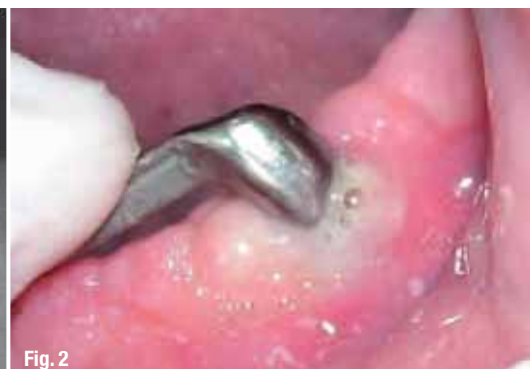
Treatment modalities such as scaling and root planing, used to treat roots with periodontitis, cannot be used in the same way on the threaded and retentive implant surfaces. The rough implant surface provides bacteria with shelter, unapproachable to conventional mechanical removal.<sup>23</sup> Conventional treatment procedures like closed peri-implant pocket debridement have shown limited success<sup>7,10</sup> whereas the treatment of peri-implantitis using open-flap procedures has shown more promising results.<sup>17</sup> Although the improved access to the implant surface

with open procedures can be seen as a fact, clinicians meet the same problems as encountered with open periodontal therapy. The decontamination of the retentive implant surface is much more complicated than the decontamination of a plane root surface.<sup>23</sup> The instruments used in periodontal treatment are too large to clean an implant surface from bacteria and any metal to metal contact during mechanical debridement has the potential to damage the implant surface.<sup>12,13</sup> The common antiseptic therapy seems to be effective against bacterial biofilm in *in vitro* conditions.<sup>5</sup> In addition, the local antibiotics used as an adjunct therapy to mechanical debridement has been advocated and shown to reduce bleeding on probing and probing pocket depth in patients with peri-implantitis,<sup>16</sup> but there are no data supporting the effect of antibiotics on the decontamination of implant surfaces and more specifically the endotoxin elimination.<sup>10,16,18</sup>

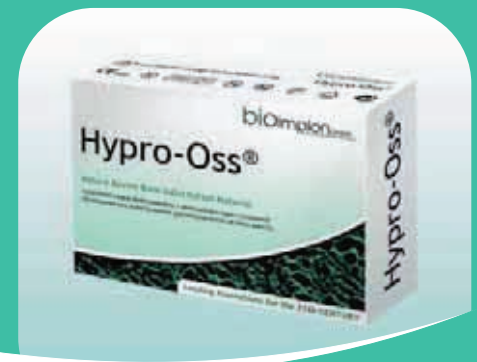Currently, there are no clinical studies or case series documenting successful regenerative procedures in periimplant bony lesions after conventional treatment. Some case series demonstrated limited bone fill after GBR procedures.<sup>6</sup> Another treatment modality that may offer an advantage over traditional mechanical treatment is the use of lasers.<sup>25,26</sup>

**Fig. 1**\_Periapical radiograph of a dental implant with bone loss of > 3 mm.

**Fig. 2**\_ Implant site prior to measurement (implant suprastructure still in place). Pus discharge is evident.



## THE NEW BONE GRAFT COMPOSITE OF THE 21<sup>ST</sup> CENTURY



### HYPRO-OSS

is a patented, revolutionary, natural, atelopeptidized and lyophilized bovine bone graft composite.

natural bovine bone composite with incorporated atelocollagen in each granule

30% collagen Type I free of telopeptide (atelocollagen) with native osteoinductive elements (TGF, BMPs, IGFs)

70% native osteoconductive bovine Hydroxyapatite components

powerful haemostatic and bacteriostatic effects thanks to native atelocollagen components

excellent handling due to effective hydrophilic properties and optimal cell adhesion

natural crystalline structure and optimal porosity guarantees long term dimensional stability

user reported: no swelling or hematoma complications after sinus lifting or other implantation procedures

new bone formation within the shortest period of time ever



histology after 4 weeks



histology after 14 weeks

Studies have demonstrated that the treatment with an Er:YAG laser has a bactericidal effect.<sup>8</sup> Er:YAG laser treatment can debride the implant surface effectively and safely without damaging.<sup>31,35</sup> Much better clinical results have been reported for Er:YAG laser treatment compared with non-surgical mechanical debridement.<sup>15,27,31,35</sup>

### Aim

The aim of the (present study) intercontinental research led by Syneron was to assess the clinical outcomes of an open-flap procedure performed with conventional mechanical therapy (CMT) or laser-assisted surgical treatment (LAS) with the novel LiteTouch Er:YAG laser (Syneron Dental Lasers) in patients with implants and a diagnosis of peri-implantitis.

### Materials and methods

The design was a single-masked, randomized six-month clinical intervention trial with two groups of patients diagnosed with peri-implantitis. The ethics committees of Cheng Hsin General Hospital, Taipei, Taiwan, and the Faculty of Dental Medicine, Plovdiv Medical University, Bulgaria, approved the study. Written consent was obtained from all enlisted patients. Patients were enrolled if they presented with at least one dental implant with bone loss of > 3 mm around the implant identified on intra-oral radiographs (Fig. 1), and with a PPD of > 5 mm with bleeding and/or pus discharge (Fig. 2) on probing. The study was conducted between September 2010 and August 2011 at the Cheng Hsin General Hospital and Plovdiv Medical University's Faculty of Dental Medicine. The following general criteria were used to exclude subjects from the study:

- subjects having taken medications likely to cause gingival hyperplasia within one month prior to baseline examination;
- subjects receiving regular periodontal maintenance treatment or having undergone any sub-gingival cleaning less than twelve months prior to baseline examination;
- subjects received peri-implantitis surgery of any type prior to baseline examination;
- subjects with clinically significant chronic illness (diabetes mellitus, compromised heart condition, rheumatism, joint replacement) requiring antibiotic prophylaxis;
- subjects having undergone systemic cancer therapy and/or radiation therapy at any time;
- subjects taking or having taken bisphosphonates;
- subjects having taken antimicrobials, steroids or non-steroidal anti-inflammatory drugs within one month prior to baseline examination;
- pregnant or lactating women;
- subjects engaged in excessive tobacco or alcohol intake or drug abuse.

Sixty-eight patients with a total number of 128 implants were included consecutively over a period of one year.

### Clinical measurements

The measurement scale used in this study was constructed in order to obtain quantitative measurement data:

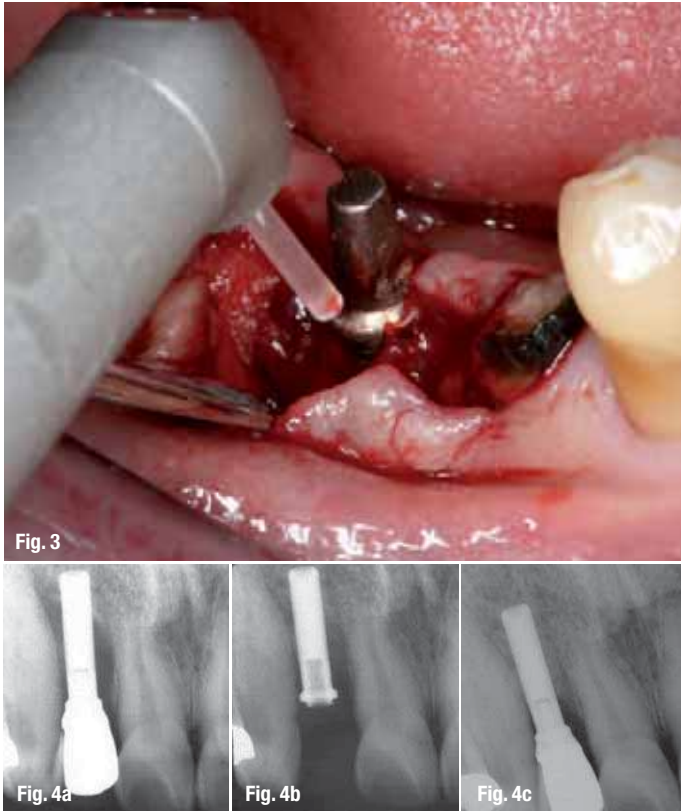
- PPD at four sites per implant (mm);
- presence/absence of BOP at the implant (four sites/implant), graded as follows:
- no bleeding, (1) point of bleeding, (2) line of blood and (3) drop of blood;
- bone loss (in mm on segment radiographs).

The PPD and BoP measurements were taken using a color-coded plastic periodontal probe (Kerr). All clinical measurements were obtained after removing the supra-structures. Intraoral standardized radiographs of sites of interest were obtained at baseline and at six months. Holders were used for standardization purposes. Radi-

**bioimplon** GmbH  
Biotech Innovation Pioneers

Friedrich-List-Str. 27, 35398 Giessen, Germany  
info@bioimplon.de  
www.bioimplon.de





**Fig. 3** Removal of plaque biofilm and granulation tissue using the LiteTouch Er:YAG laser with its 1.3 x 1.4 mm sapphire tip.

**Fig. 4** The periapical radiograph revealed peri-implantitis with bone loss of > 5 mm (a). The abutment was removed and surgical treatment using the LiteTouch laser was performed. Bone grafting with a biomembrane followed the laser treatment (b). The periapical radiograph revealed bone regeneration after six months (c).

ographs were analyzed by two of the study investigators after previous calibration.

### Hygiene phase (non-surgical phase)

Before treatment, the suprastructures were removed and the baseline measurements were taken. The goal of the initial phase was the reduction of as much tissue inflammation as possible. The patient moved on to the support phase once signs of improvement and reduction of inflammation had been observed. In case of persisting bleeding and pus discharge, a surgical procedure was planned. For this surgical phase, fifty-one of all sixty-eight patients with a total number of 100 implants were randomized with a lottery assignment.

### Surgical phase

If there was no significant improvement after the non-surgical phase (in the second week), a surgical intervention was planned (surgical phase). Surgical intervention was indicated in cases in which the conditions around the implant had failed to improve after the initial phase, but plaque control was adequate, and there was a need to retain the contaminated implant. The supraconstruction of the implants was removed in order to gain access and to preserve as much soft tissue as possible to cover the area after surgery. Patients were randomly assigned to one of the two treatment regimens.

### Conventional mechanical therapy (Group I)

Infiltration local anesthesia was used during treatment. The first incision was an internal gingivectomy, directed towards the bony ridge, which separates the peri-implant tissue from the mucosal flap. The flap was then raised to the level of the bony ridge, gaining access to the entire implant surface. The granulation tissue around the implant was carefully removed with sharp curettes and the implant surface was inspected for calculus deposits. The implant surface was then carefully cleaned using an ultrasonic device at low settings (PI tip, Piezon® ultrasonic unit, EMS). The PI tip was placed and used for approximately 60 seconds around the implant, ensuring coverage of the full circumference of the implant. Chemical debridement with a tetracycline solution was performed after ultrasound cleaning. In addition, bone augmentation was performed when required (21 patients; Bio-Oss, Geistlich Pharma; Dembone). During the study, all subjects received individualized oral hygiene instructions.

### Laser-assisted surgical treatment (Group II)

Under local anesthesia, gingivectomy and the separation of the peri-implant tissue from the mucosa were performed. The flap was raised to the level of the bony ridge, gaining access to the entire implant surface. The granulation tissue around the implant was removed with the LiteTouch Er:YAG laser (Fig. 3). Tip of choice was 1,300 micron, noncontact mode (distance between end of the tip and target tissue = 1.5 mm). If calculus deposits were found, the implant surface was then carefully cleaned with laser. Decontamination with a non-contact, defocused Er:YAG laser was performed by systematically moving the laser tip along the surface. The area was rinsed with a sterile saline solution. Bone augmentation was performed when necessary (19 patients; Bio-Oss and Dembone with or without an absorbable biomembrane). The tips and settings used during treatment are given in Table 1.

### Postoperative Instructions

The patients were prescribed clindamycin 150 mg x 50 tabs to avoid infection. They were also given ibuprofen 800 mg x 15 tabs for pain. Patients were instructed to rinse with chlorhexidine 0.2%, starting the next day, for two weeks three times a day, and were advised to maintain good oral hygiene.

### Support phase

The goal of the support phase was to maintain long-term treatment results. Regular examination of the soft tissue, plaque control, radiographs and minor

Procedure	Hard tissue/ soft tissue	Contact/ non-contact	Laser energy (mJ)	Pulse frequency (Hz)	Tip diameter x length (mm)	Waterspray level
Releasing incision of the flap	Soft tissue	Contact	200	35	0.4 x 17	5–6
Granulation tissue ablation	Soft tissue	Non-contact	400	17	1.3 x 14	6
Bone remodelling	Hard tissue	Non-contact	300	25	1.3 x 19	8
Implant decontamination	Hard tissue	Non-contact	150	45	1.3 x 17	6
Decortication for GBR technique	Hard tissue	Non-contact	300	25	1.3 x 19	8

**Table 1** Tips and settings used during laser treatment.

local treatments were performed, based upon the recall interval. If there was a recurrence of minor inflammation around an implant, the antibacterial periodontal treatment was repeated.

### Statistical methods

A statistical software package (SPSS) was used for the statistical analysis. Statistical significance was defined by a p-value of < 0.05. A change in PPD was defined as the primary outcome measure. The secondary outcome measure was a change in bone height. The data was also analyzed using independent t-tests for continuous variables with a normal distribution (equal variance not assumed; PPD, changes in bone height) and using the Mann-Whitney U-test for non-parametric data (BoP, suppuration) and a chi-squared test.

### Results

At baseline, a point of bleeding was found at 4.2% of all implant surfaces, a line of blood at 47.6% and a drop of blood at 56.9% of the sites. Statistical analysis failed to demonstrate baseline differences in BoP between different implant surfaces (p = 0.85). At six months, no evidence of bleeding was found in 81% of the implants in the LAS group and in 59% of the implants in the CMT group. The decrease in BoP was significant in both study groups (p < 0.001). Statistical analysis demonstrated differences in changes in BoP between the study groups (p < 0.001). The mean PPD reduction in the CMT and LAS groups was 0.8 mm (SD ± 0.5) and 1.7 mm (SD ± 1.3), respectively, with mean changes in bone height (loss) of -0.5 mm (SD ± 0.6) and -0.1 mm (SD ± 0.2), respectively (S) (Table 2). The proportional changes in bone height between baseline and six months, assessed from radiographs and defined at the implant level, are presented in Table 3. A positive treatment outcome, PPD reduction of > 4 mm and gain or no loss of bone were found in 59% of the CMT and 81% of the LAS groups, respectively (S). All subjects completed the study, and no implants were lost.

### Discussion

In modern oral implantology, lasers have a considerable spectrum of clinical application. The literature data revealed that different laser wavelengths are used on peri-implant tissues: treatment of peri-implant mucositis, treatment of infrabony defects, removal of peri-implant hyperplastic overgrowth tissue, preparation of bone defects for GBR.<sup>3,4,22,28,29</sup> Unlike mechanical decontamination methods, which cannot fully adapt to the irregularities on the surface of an implant, lasers can irradiate the whole surface, reaching areas that are too small to receive mechanical instrumentation. Recent *in vivo* studies have analyzed the outcome of peri-implantitis treatment using Er:YAG lasers<sup>1,21,27,31</sup> and CO<sub>2</sub> laser.<sup>3,28,29</sup> Many of these studies showed promising short-term results (less than six months), but report no long-term follow up. In the present study, differences in the reduction of BoP six months after treatment were found between LAS and CMT groups. While oral hygiene had improved greatly and no plaque was found at the treated implants, a large proportion of the implants in the CMT group continued to exhibit BoP at the six-month post-treatment assessments. In the present study, BoP was graded to distinguish the severity of inflammation and approximately 14% of the implants in the LAS and 41% in the CMT groups presented with bleeding, which was consistent with other data.<sup>30</sup> The reasonable explanation for these results is the quality of decontamination of the implant surface provided by the treatment approaches evaluated. Contaminants such as bacteria and their by-products, calculus, and granulations should be removed without modifying the

**Table 2** Proportional changes in PPD between baseline and six months, defined at the implant level based on the mean value of changes at four sites/implant.

PPD changes	CMT (%)	LAS (%)
<b>Decrease (mm)</b>		
> 4	1.2	37.4
3.1–4.0	7.9	35.0
2.1–3.0	14.0	7.9
1.1–2.0	35.4	12.1
0.1–1.0	1.7	4.2
<b>Unchanged (mm)</b>		
0.0	29.2	1.4
<b>Increase (mm)</b>		
0.1–1.0	7.9	0.0
1.1–2.0	1.2	0.0
2.1–3.0	1.0	0.0
3.1–4.0	0.0	0.0

Radiographic changes in bone height	LAS (%)	CMT (%)
<b>Decrease (loss in mm)</b>		
1.1–2.0	12.2	35.4
0.1–1.0	37.1	39.5
<b>Unchanged (mm)</b>		
0.0	29.3	4.2
<b>Increase (gain in mm)</b>		
0.1–1.0	17.4	12.5
1.1–2.0	4.9	2.1
2.1–3.0	7.1	6.3

**Table 3** Proportional changes in bone height between baseline and six months, defined at the implant level based on the mean value of changes in mesial and distal bone height.

implant surface and with respect to surrounding soft tissues. Numerous methods for the decontamination of implant surfaces have been suggested, either alone or in various combinations, as part of the surgical treatment of peri-implantitis. The literature data revealed that methods as cleaning with metal curettes and inappropriate ultrasonic tips or irradiation with Nd:YAG laser can damage the implant surface and could compromise the residual implant stability.<sup>9,20</sup> Air-powder abrasive units are often recommended for the surgical treatment of peri-implantitis. A recent study aimed at evaluating the influence of different air-abrasive powders on cell viability at biologically contaminated titanium dental implant surfaces revealed that no surface treatments led to mitochondrial cell activity values comparable to the sterile control group.<sup>33</sup> Citric acid application and sandblasting have also been recommended.<sup>18</sup> However, implant decontamination using sandblasting units have been associated with risks such as soft tissues damage and emphysema.<sup>34</sup>

Er:YAG lasers are seen as the most promising new technical modalities of treating failing dental implants, since their performance of tissue ablation is accompanied by a high bactericidal and detoxification effect.<sup>26,32</sup> When considering the use of Er:YAG lasers in the treatment of peri-implantitis, there are some crucial points with clinical importance. Power settings are variable, and the clinician must also choose a setting that will effectively disinfect the implant while not damaging the surface. A narrow range of power settings (100 mJ/pulse) was described in the literature.<sup>21,27,30,31,32</sup> Only one study used a higher power setting of 120 mJ/pulse.<sup>1</sup> The frequency was set at 10 Hz for each of the mentioned studies, however, neither the distance from which the laser was applied, nor the time of application to each implant was stated. In the present study, the settings used for implant surface decontamination are 150 mJ/45 Hz, at non-contact mode and constant movement. Another important point is the interaction between laser light and metal surfaces. This interaction is mainly determined by the degree of absorption and reflection. With a reflectance capacity of about 71%,<sup>19</sup> titanium implant surfaces do not absorb irradiation. Consequently, there is no increase in temperature which could damage the implant surface. Several investigations have reported on the promising ability of the Er:YAG lasers in implant surface debridement without producing thermal side-effects on implant surface and adjacent tissues.<sup>14,35</sup> Treatment of peri-implantitis

using Er:YAG laser therapy has been investigated before and appears to result in a more effective reduction in bleeding around implants than surgical debridement with hand instruments and sub-gingival application of chlorhexidine.<sup>1,27,30,31</sup> Irradiation with this specific wavelength seems to have a bactericidal effect on periodontopathic bacteria and remove bacterial biofilm. However, in order to treat the implants with the laser device in the present study, the suprastructures were removed, allowing the access to the implant surfaces to improve. Thus, the results of the present study are limited to implants where the suprastructures can be removed during treatment.

### Conclusion

Among lasers used in the field of dentistry, the Er:YAG laser seems to possess the characteristics most suitable for peri-implantitis treatment because of its ability to ablate both soft and hard tissue, as well as bacterial biofilm and calculus, without causing thermal damage to the adjacent tissues and implant surfaces. The decontamination effects of Er:YAG laser are also beneficial regarding peri-implantitis pathogenesis. In the present study, the use of the LiteTouch Er:YAG laser has been proposed for the treatment of peri-implantitis and the results indicate that the laser-assisted surgical therapy may lead to significant clinical improvements such as BoP and PPD reduction as well as a gain in clinical attachment. From a clinical point of view, these results advocate the Er:YAG laser as an alternative treatment modality to conventional mechanical therapy.

*With the collaboration of Dr Ke, Dr Yu, Dr Lu, Taiwan; Dr Kenny Chiu, Hong Kong; Drs Kanbayashi, Takahashi, Ikeda & Kamiya, Japan.*

*For more information about the LiteTouch™—the fiber-free Er:YAG laser, please visit: [www.synerondental.com](http://www.synerondental.com)*

*Editorial note: A list of references is available from the publisher.*

_contact	laser
<p><b>Prof. Tzi Kang Peng</b> DDS, MS, PhD, FICD Professor and Chair of the Department of Dentistry Cheng Hsin General Hospital Taipei, Taiwan</p>	
<p><b>Assoc Prof. Georgi Tomov</b> DDS, MS, PhD Associate Professor and Chair of the Department of Oral Pathology, Faculty of Dental Medicine Medical University of Plovdiv, Bulgaria</p>	



From 31 October to 2 November 2013

United Arab Emirates—Dubai  
**Atlantis The Palm**

## Towards Innovative Procedures and Technique in Dental Implantology



Dr Gernot Wimmer



Dr Khaled Abdel-Ghaffar



Dr Mario H. Rodriguez



Dr Mazen Tamimi



Dr Michael Payer



Dr Ramy Fahmy



Dr Nicole M. Geha



Dr Mohamed Moatiz



Dr Amr Abdel Azim



Prof. Nabil Barakat



Dr Rainer Valentin



Dr Rolf Vollmer



Dr Vedat Bankoğlu



Dr Martin Lorenzoni



Dr. Nadim Aboujaoude



Dr Martina Vollmer



Dr Roland Hille



Dr Suheil M. Boutros



Dr Werner Zechner



Note: For online registration please visit [www.dgzi-agic.ae](http://www.dgzi-agic.ae), for further inquiries please contact 0097126355527.

Fax this form to  
**+97126289833**

E-mail this form to  
**reg@dgzi-agic.ae**

I hereby register the following person for the 8<sup>th</sup> DGZI Congress from October 31 to November 2, 2013, in Dubai, United Arab Emirates (Please fill out this form):

First name:	Last name:	Title: <input type="checkbox"/> Dr <input type="checkbox"/> Prof. <input type="checkbox"/> Mr. <input type="checkbox"/> Mrs.
Office phone:	Fax:	E-Mail:
Institution:	Address/P.O. Box:	

Registration fees*	Early Bird Before September 30, 2013	September 30, 2013, to October 29, 2013	ON-SITE
<input type="checkbox"/> Dentists	US \$ 500	US \$ 550	US \$ 600
<input type="checkbox"/> Students & Interns	US \$ 400	US \$ 450	US \$ 500
<input type="checkbox"/> DGZI members	US \$ 300	US \$ 350	US \$ 400

\*Fees include: Congress Lectures, Access to exhibition hall and 3 days lunch at Atlantis The Palm Hotel, Dubai.

Payment Details: Money transfer (or bank deposit)  
 Abu Dhabi Islamic Bank: 1-56686-9; IBAN: AE-31-050-0000000015668699  
 Beneficiary: success Steps Seminars & Conference LLC

Stamp

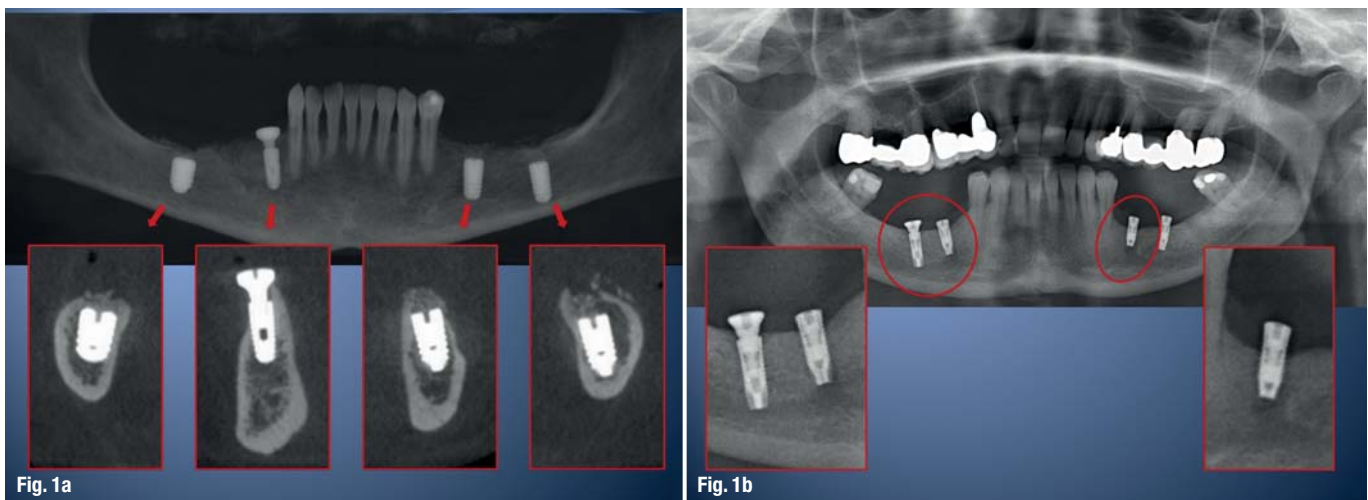
I hereby accept the terms and conditions of the 8<sup>th</sup> DGZI Congress.

Date \_\_\_\_\_

Signature \_\_\_\_\_

# Safe interdisciplinary navigation

**Authors** Dr Frank Schaefer, Dr Dagmar Schaefer, Dr Mike C. Zäuner & Master Dental Technician Jürgen Sieger



**Fig. 1** Current clinical cases as examples for inadequate 3-D diagnostics and manual placement:  
**a)** Implants in the third quadrant and the region of tooth 47 are impacted completely; those in the regions of teeth 37 and 47 have penetrated the mandibular nerve canal. These image sections show orthogonal alveolar ridge sections through the centres of the implants.  
**b)** Implants in the regions of teeth 35 and 45 have been fully inserted into the mental foramen. The mandibular nerve has a lesion in region 46.

## Introduction

Every day we hear about new curative procedures and their successful application in therapy. The new media broadcast information about medical performances worldwide instantly to wide sections of the population. This environment places greater demands on us, the operators, to meet our patients' increasing expectations for high quality.

It is increasingly less feasible for a "universal genius" to perform complex dental medical therapy alone—consistent interdisciplinary cooperation has become essential. Diagnostics and therapy strategies are necessary and increasingly extensive prerequisites which must be carried out prior to the actual manual dental procedures. Advance planning of therapeutic measures as well as the continuous use of treatment procedures and working instructions with regard to a quality management system form the basis for successful complex oral rehabilitations.

Three-dimensional imaging procedures, upon which dental diagnostics and implant navigation are based, are an important component. Navigation pro-

cedures are considered established methods in implantology. Although they have been in use for almost 20 years, colleagues continue to disagree about them vehemently even today. Comments range from "no need" and "won't work anyway" to "I cannot do without them".

For 3-D diagnostics and implant planning, meeting the requirements by processing and evaluating 3-D radiographic data is essential. In dentistry, cone-beam computed tomography is increasingly used as the source for 3-D radiological image data.

In its guidelines 2005: Cone-beam computed tomography (CBCT)—S1—Recommendation and 2012: Indications for implantological 3-D radiographic diagnostics and navigation-guided implantology—S2k guideline, DGZMK (German Society of Dental, Oral and Craniomandibular Sciences) debates this topic fundamentally. Not only are the technical principles, prerequisites and indications summarised and commented on, but they also discuss the currently feasible results when using navigation-guided implantation. The few *in vivo* data available show that deviations of 2.4 mm in 2005 at the implant tip appear to

have deteriorated to 4.7 mm in the 2012 S2K guideline. This also applies to deviations in the implant axes which have deteriorated from 4 degrees (2005) to 9.8 degrees (2012). In comparison, the deviations in the position of the implant tips decreased in the *in vitro* studies cited (2005: 6 mm; 2012: 2.5 mm), as did the deviations in the implant axes (2005: 11 degrees; 2012: 7.9 degrees).

These data show that all current types of 3-D navigation surgery are considerably better than manual implant placement without 3-D diagnostics but do not represent a reliable basis for an exactly planned procedure as demanded by the increased expectations placed on modern forms of medical therapy (Figs. 1a & b).

There is a multitude of causes of these deviations: Firstly, as described in detail in these publications, only a minimal amount of *in vivo* and *in vitro* data is available. Secondly, there are numerous options for errors due to working stages not always being carried out consistently and co-ordinately. It is even more important that all those involved follow standardised procedures: The prosthodontist, surgeon, dental

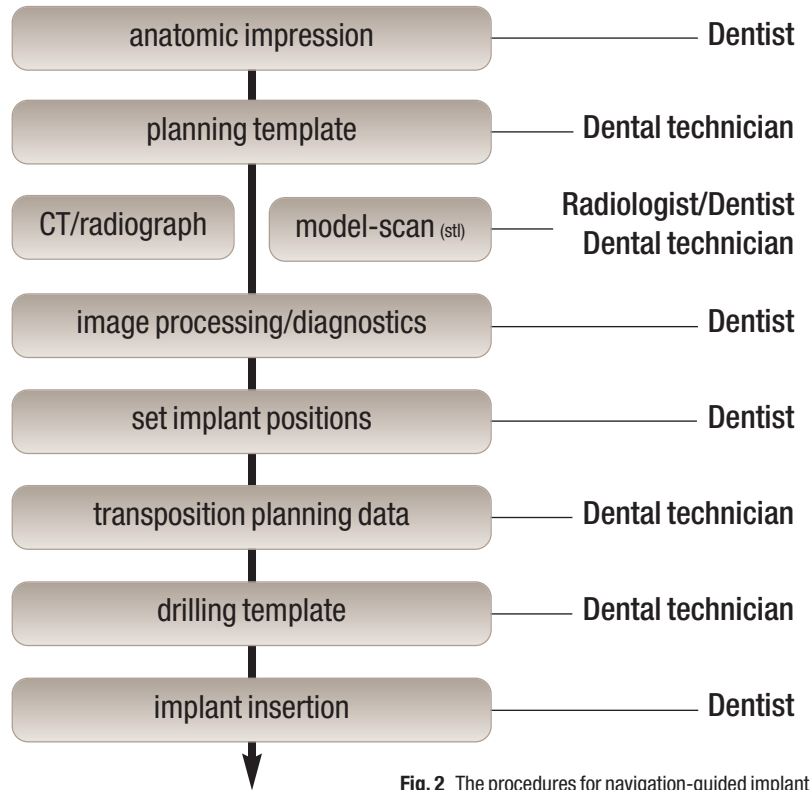


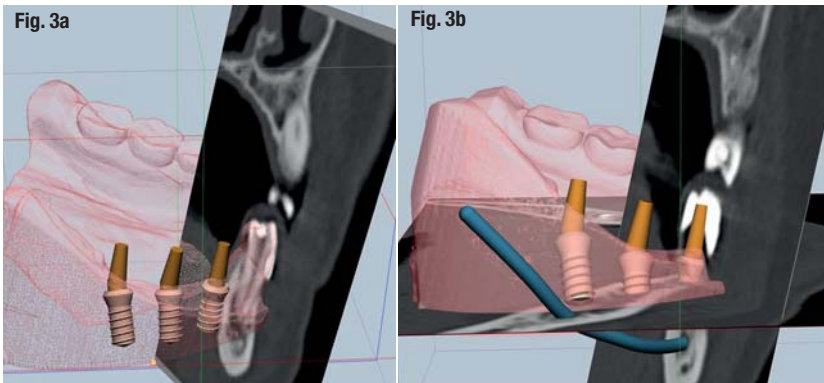
Fig. 2\_The procedures for navigation-guided implant placement using a template.

AD

become an author  
for "implants"

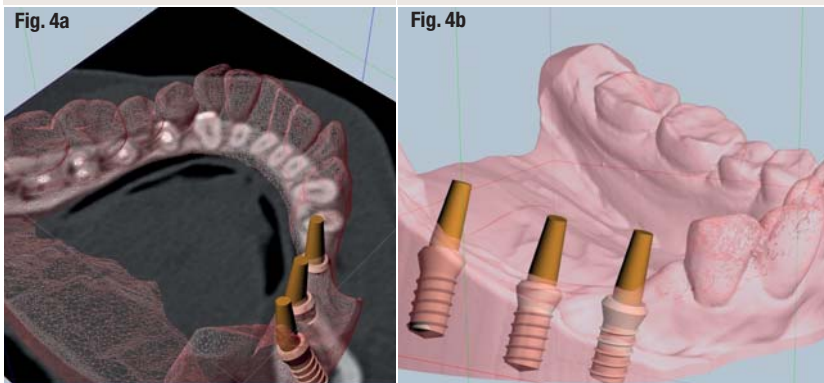


Please contact Claudia Jahn  
✉ c.jahn@oemus-media.de



▲ *Stl-data (mesh) in connection with picture of alveolar ridge cut and plannes implants with abutments.*

▲ *Stl-data (rendered) in connection with picture of alveolar ridge cut, z-level-picture, planned implants including abutments an rd reconstructed channel of N. mandibularis.*



▲ *Model mesh with z-level-cut.*

▲ *Rendered model with virtual (inside X-ray-date-file) planned implants.*

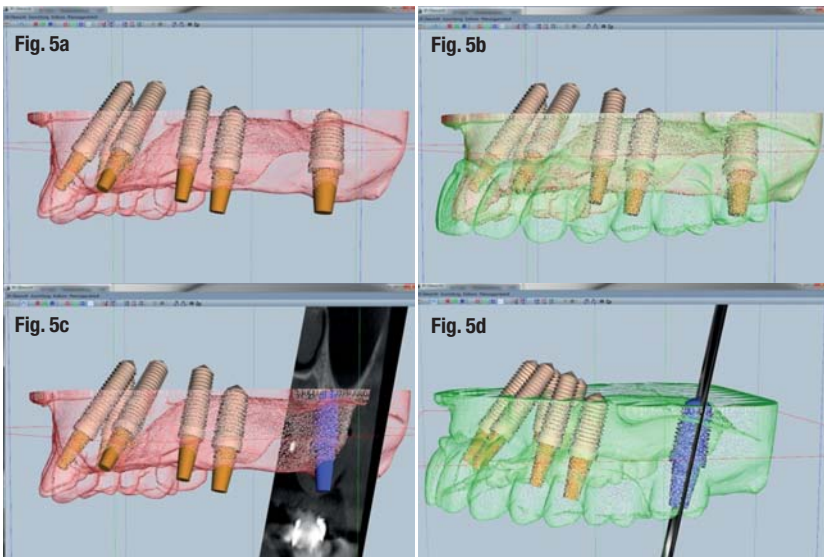


Fig. 5a

Fig. 5b

Fig. 5c

Fig. 5d

**Figs. 3a–b & 4a–b** A selection of the options for merging the optical scan of the model with 3-D radiological planning data.

**Figs. 5a–d** Merging the optical scan of the model (red) with an aesthetic set-up (green) using 3-D radiological planning data.

technician, radiologist, where relevant and, of course, the patient. The CTV system provides conveniently for this type of cooperation in planning and carrying out treatment, including the documentation of the responsibilities, concise treatment counselling with the patient and, last but not least, success evaluation.

### Error analysis

Errors during 3-D-based navigation-guided implant placement may have a multitude of causes. As

in all error analyses, one must differentiate between coincidental and systematic errors. It can be seen from the principal procedure for template-guided navigated implantation (Fig. 2) and from the number of its sub-stages and different persons involved that errors can—and do—occur in this working process. When analysing errors, it must be kept in mind that navigated implant surgery involves planning and operating within the range of millimetres or even below. In addition, errors during the sub-stages may have grave consequences for the ensuing stages. It is therefore advisable to analyse precisely and develop procedures for avoiding these errors.

Errors with the longest-lasting consequences have turned out to occur during impression-taking of the jaw planned for implant placement, when taking the 3-D radiograph as well as when retransferring the planned virtual implant position to the model or surgical navigation template.

The quality of the 3-D radiographic dataset is dependent on the image-taking procedure selected, be it CT, CBCT or truncated CBCT. Also, regardless of the machine used, all radiographs are subject to the laws of optics and exhibit distortion, interference and diffraction phenomena. Apart from that, the image may be blurred if the patient moves while it is taken. The actual pixel size in the image sensor of the unit also has an effect, as does the algorithm used for reconstructing the image in the X-ray machine. Last but not least, correct setting of the parameters and positioning the patient properly in the machine are also decisive for the quality. Assuming that the impression of the jaw was taken correctly and the planning template was fabricated properly, incorrect positioning of the template in the patient's mouth during image-taking also leads to far-reaching planning and transfer errors. Errors during and due to 3-D image-taking are always coincidental and therefore irreparable – which rules out compensating for them with diagnostics and planning.

Once the radiograph has been taken with an X-ray machine, which is subject to quality management based on the (German) radiation act, during the following image-processing, often too little attention is paid to retaining the information included in the primary image data. These processes are often not adequately certified and mostly do not comply with the radiation act. In addition, a loss of detail/structural information is thoughtlessly taken into account.

The difference between the patient's position when the radiograph was taken and the actual model of the jaw is especially crucial for retransferring the virtual implant positions to the model of the jaw. Retransferring with the various compensation mecha-

nisms (e.g. CeHa implant [X1;X2]™, coDiagnostiX [gonyX]™ etc.) may also be a considerable source of error for the transfer process. Intraoperative errors may also occur: an incorrectly placed surgical navigation template will certainly lead—in case of specific navigated implant placement—to malpositioning of the implants, thus possibly resulting in inadvertent, unplanned injury to the adjacent structures. Malpositioning of implants may also occur if the “half-guide” (only the pilot drilling is navigated) procedure is employed. As far as this is concerned, “full-guide” procedures appear safer but may be limited in their applicability. This excerpt of errors is a possible explanation for the relatively high inaccuracy of procedures used to date as documented in the above-mentioned DGZMK guidelines.

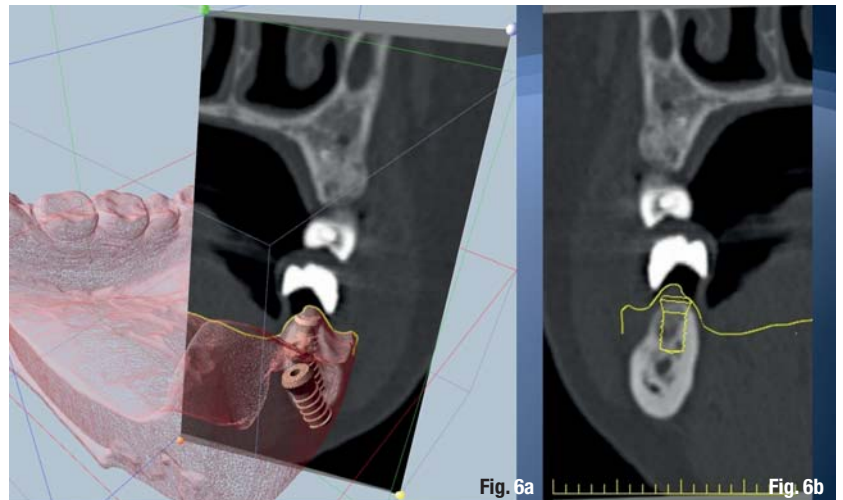
### Further development

The CTV system follows different paths, based on comprehensive theoretical and clinical evaluation, in order to attain interdisciplinary cooperation and reliable planning with only minimal toleration of errors. Use of the CTV system allows coincidental and therefore unforeseeable errors to be identified and, wherever feasible, systematic errors to be compensated for.

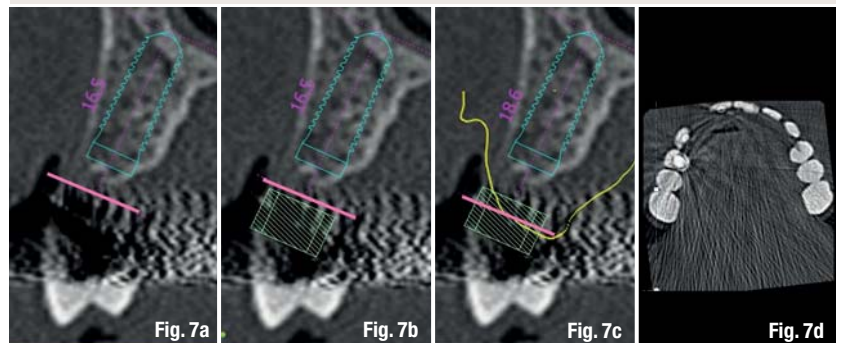
The quasi-analogue image processor developed for the CTV system is relatively tolerant where quality and alignment of the primary radiographic dataset are concerned. It permits any image sections in 3-D cubes to be created with no limitations to angles, distances and locations. These images reproduce impressive details and structures as do plain images, calculated panoramic tomographs and calculated teleradiographs. The operator is provided with the usual “analogue” image quality.

But the same applies here, too: The quality of the primary dataset and the density of the information it contains is decisive for the 3-D diagnostic and planning options. In addition, the CTV system merges data from an optical scan of the planning template, model and/or wax-up/aesthetic set-up and/or drilling template with the 3-D radiographic planning dataset (Figs. 3-5). This fully automatic matching process discovers and compensates for coincidental errors in images (Figs. 6 & 7).

Regarding bone availability and prosthesis positioning, the planning positions can thus be determined more comprehensively and exactly. When using this method, the emergence profile can already be estimated accurately during prosthetic (pre)planning. The surgical navigation template can also be fabricated based on STL datasets. When this template is then matched with image planning, the (virtual)



▲ Yellow line: automatically reconstructed line of gingiva on basis of model scan.

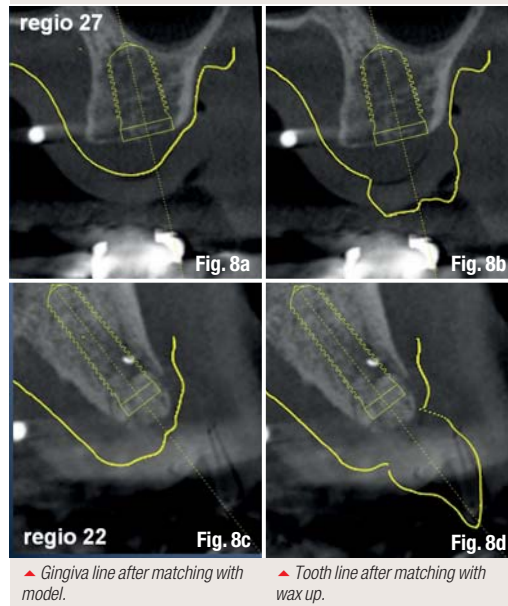


▲ Determined height of gingiva in X-ray planning (pink).

▲ Out of implant planning resulting position of the drill.

▲ Yellow line: real line of gingiva on basis of scanned model—sleeve below gingiva!

▲ Source of error: artefacts in CT-scan due to precious metal containing restoration (z-level-cut).



▲ Gingiva line after matching with model.

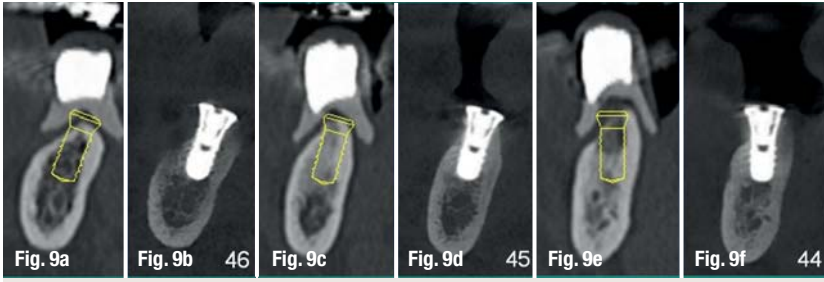
▲ Tooth line after matching with wax up.

**Figs. 6a–b & 7a–d** An example of error recognition – checking and determining the gingival contours on the planning radiographs using the scan of the model.

**Figs. 8a–d** The gingiva or tooth structures are recognised automatically when the radiological planning data are matched to the model of the jaw or wax-up.

planning positions can be checked for correct alignment with the sleeve positions in the template prior to placement. Starting with optical and radiological digital data, the entire planning and fabrication process is digitized from one single base without further interim stages, which eliminates inaccuracies



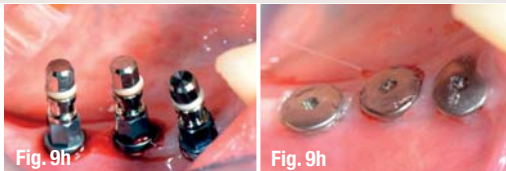


▲ Review of success: left – planning target, right – result.

**Figs. 9a-h** Clinical success—The condition after transgingival navigated implant placement (2012).

**Fig. 10** Matching to check for success—left: The 3-D radiological planning (blue implant) was made congruent with the model (red), wax-up (green) and 3-D image post-operatively (eclipsed by the virtual implant); right: Matching planning, postoperative radiograph with the gingival contours from the model of the jaw (2012).

**Fig. 11** Documentation of the responsibilities for the total process—below: RFID Reader, model base with RFID chip, customised Ident Keys for the RFID Reader.



▲ Clinical status after insertion implants—screwing parts (Straumann).  
▲ Clinical status immediatly after operation.

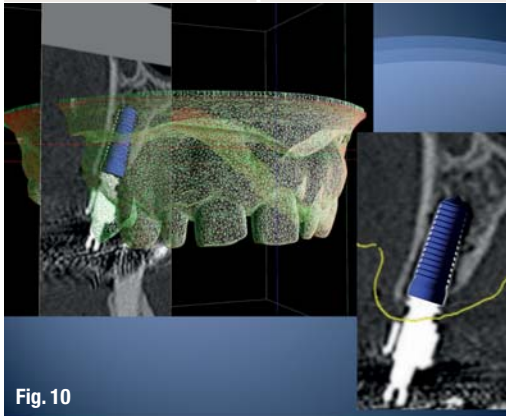


Fig. 10

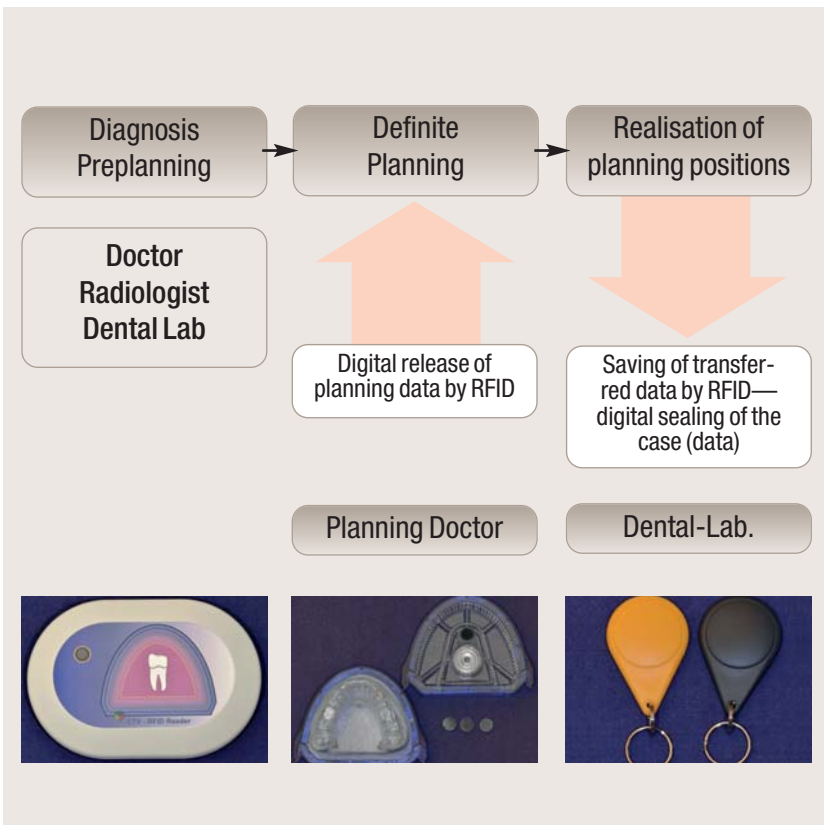
encountered with conventional methods involving transferring virtual positions to the actual model.

The CTV system provides for reliable postoperative examination once the implants have been placed. This means that unerringly precise congruency is achieved between planning dataset and postoperative 3-D radiological dataset for comparing the actual implant positions with the planned positions. It is irrelevant whether the planning and control datasets stem from the same machine (Figs. 8 & 9). This enables the user to check for success at an early stage as well as analyse the cause of any errors which may occur. This should lead to errors being avoided long-term (learning effect).

Of course, the CTV system can generate comprehensive and custom expandable, forensically dependable case documentations at the push of a button. They can be stored as PDF files, printed and/or forwarded. The use of RFID chips integrated into the model of the jaw ensures that the CTV system stores a complete documentation of the responsibilities as part of the total process (Fig. 10).

### Conclusion

The combination of radiological and optical data and simultaneous integration of CAD/CAM processes enables errors to be identified at an early stage and, together with suitable compensation measures, leads to a much better match between planning requirements and outcome. The numerous options for combining images create optimum conditions for interdisciplinary understanding as well as explaining the therapy strategy to the patient in a plausible and understandable manner. The indications of this new technique range far beyond mere implant planning and can be used in-house without having to purchase costly special equipment and transfer units.



_contact	implants
<p><b>Dr Frank Schaefer</b>          Praxis          Haarbergstr. 21          99097 Erfurt, Germany</p> <p>Tel.: 0361 4230713          PraxisSoft@web.de</p>	

# Peri-implantitis prophylaxis by sealing implant gaps and hollow spaces

**Author**\_Prof. Dr Dr Claus Udo Fritzemeier, Germany

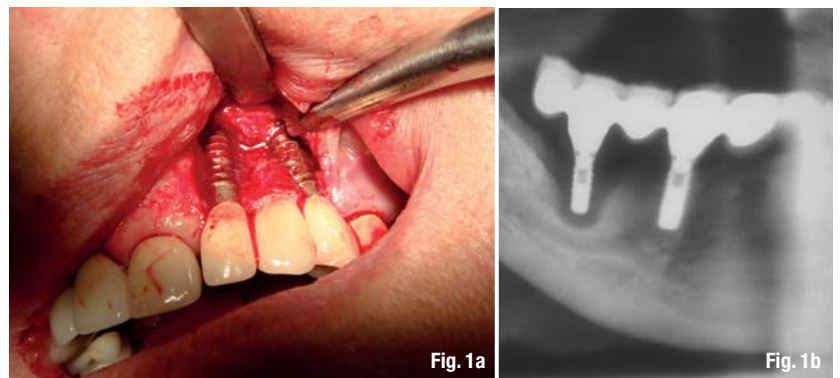
## Introduction

In the last decades, implantology has emerged as one of the most innovative enrichments in the field of dentistry. Considerable increase is expected in the future. Compared to earlier preprosthetic methods, endosseous implantology is a simple treatment that usually is not very stressful for the patients and offers many advantages, e.g. the physiological transfer of chewing forces into the bone, which—under certain conditions—even generates renewed bone growth.

Against this background, implantology with all its prosthetic treatment varieties is considered an established method. One of the most common and most feared complications occurring in implantology is peri-implantitis (Figs. 1a & b), which usually leads to implant loss when it remains untreated.

Initially, the periimplant tissue disease manifests itself as mucositis with progressive bone loss at the implant area, as described by Albrektsson et al.<sup>1</sup> The reasons for this disease pattern are complex, and various hypotheses about the development of peri-implantitis were proposed, amongst them insufficient oral hygiene, lack of fixed gingiva, and/or overstressed implants. These putative triggering factors contradict the statements of well-known implantologists, "An absence or insufficient width of keratinized gingiva is not linked aetiologically to the development of gingivitis and peri-implantitis" or "The functional strain placed on an implant cannot be solely held responsible for progressive bone loss"<sup>8,17</sup> That means that additional pathologic influences, which trigger and sustain the progress of the disease, must exist next to these ostensible causes.

Therapies reach from improved basic hygiene to antibiotics and disinfectant inserts into periimplant



pockets up to ultrasound treatments and laser curettage of inflamed tissues.<sup>4,8</sup> The main attention, however, should not be placed on therapy, but rather onto an efficient prevention of peri-implantitis.

**Fig. 1a**\_Peri-implantitis, clinically.  
**Fig. 1b**\_X-ray of peri-implantitis.

## Gaps and hollow spaces of assembled implants

It is a fact that assembled implants contain hollow spaces, which can be minimised but not prevented even by the most meticulous production. Because threads also hold gaps, the contamination of implant interiors with germs originating from the oral cavity is inevitable.<sup>2,11</sup>

Re-infection from an implant cannot be ruled out. On almost every assembled implant we noticed a putrid smell of its content, which was extracted with a cotton tip. In 1996 we initiated examinations which confirmed the assumption that gaps and hollow spaces in interior implants were contaminated with germs, which matched the germ spectrum of an interdental smear.<sup>4,5,9,12,14,15</sup>

Implant interiors in their dimensions, position and size are easily recognised by construction drawings, cross sectional shapes and X-rays, and so it be-

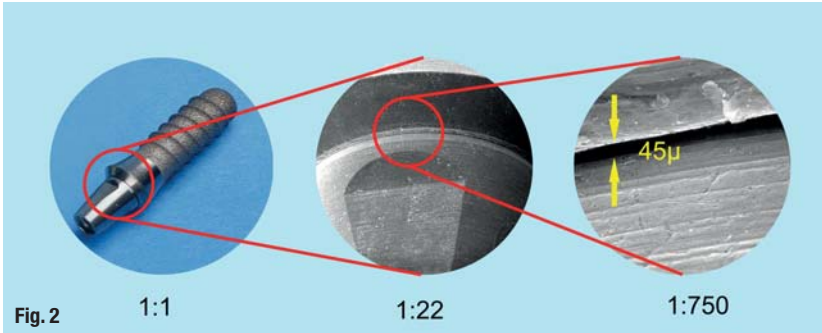


Fig. 2

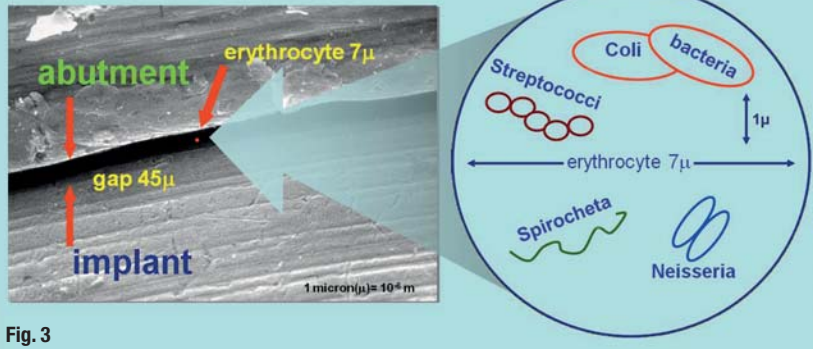


Fig. 3

**Fig. 2\_** Used implant randomly chosen, on which the marked area was light and electron microscopically examined (Brand is unnamed intentionally).

**Fig. 3\_** Gap situation between implant and abutment compared to an erythrocyte with a diameter of 7  $\mu$  ( $1 \mu = 10^{-6} \text{ m}$ ), 745 times enlarged.

The randomly chosen germs are depicted true to scale and compared to an erythrocyte.

comes clear that hardly any assembled implant is actually excluded from those facts.<sup>7</sup>

Of course, these considerations apply to screwed superstructures as well. Cemented superstructures seem to be sealed at first by the fastening cement, but everyone knows the smell that emerges when cement is drilled from crown and bridgework and gives evidence of germs permeating here as well.

The access paths of germs into the implant interior are easily comprehensible, and we were able to provide evidence by taking light and electron microscopic exposures of a used implant (Fig. 2). The paper "Implant Component Compatibility" by Binon et al. confirms this matter quite impressively.<sup>3</sup> The results showed that the macroscopically good fit re-

**Fig. 4\_** Sterilisable GapSeal<sup>®</sup> applicator with GapSeal<sup>®</sup> carpules.



Fig. 4

vealed severe flaws under electron microscopic examination.

Furthermore, the capillary forces and micro motions<sup>18</sup> between implant and abutment promote the exchange of infectious material, for which saliva is a good vehicle. Figure 3 shows the proportion of the gap located between implant and abutment compared to an erythrocyte.<sup>7</sup> In order to make the dimensions even more clearly, the randomly chosen germs shown are also matched to an erythrocyte exactly to scale.<sup>13</sup>

### Peri-implantitis through re-infection from an implant

The implant is contaminated with germs from the oral cavity as soon as it is opened for placement of the insertion tool. Germ growth starts immediately after fastening the locking screw, unless the implant interiors were previously treated with a material for sealing and combatting germs.


The breeding conditions—warmth, humidity and supply—enable bacterial growth and fungal colonisation in an ideal manner, so that re-infection of periimplant tissues via the gaps leading outwards is given. Regardless of which treatment of this important area around the implant is applied, it will always remain short-lived.

### Development and efficacy of GapSeal<sup>®</sup>

In order to counteract these re-infections, we developed a material based on a highly viscous silicone matrix and a bactericidal disinfectant in 1996. Antibiotics would not be sufficiently intensive or effective in a low dose. Moreover, they would contribute to sensitisation and the development of resistance. Afterwards we employed the so-called split-mouth technique to test the material against white Vaseline and determine the required admixture of disinfectant.<sup>15</sup>

The sealing material thymol has bactericidal, virucidal and fungicidal properties. It belongs to the microbiologically very effective materials, but is largely harmless to humans. Its disinfecting effect is about 30 times higher than that of phenol, but thymol has only a quarter of its toxicity. It also does not cause allergies.<sup>10,16</sup> The material met its purpose as gap and interior sealant more than satisfactorily and was subsequently named "GapSeal<sup>®</sup>" (Fig. 4).<sup>6</sup>

For the split-mouth studies, GapSeal<sup>®</sup> was applied to the right sides of the implants, and Vaseline to the left sides. During this clinical comparison, the Vaseline turned out to be thoroughly contaminated,



**Fig. 6** Use of applicator and carpules.

while GapSeal®-treated implants usually provided no evidence of germ growth. This is proven by the follow-up examinations, each of which was conducted six months afterwards.

The number of germs (CFU = colony forming unit) at each pertaining implant was determined through serial dilution, followed by counting the CFU's on the incubation plates. This process enabled a definite determination of germs contained in each interior implant smear.<sup>15</sup> We were able to prove the material's efficacy by conducting follow-up examinations between 1996 and 2000 and do not want to abstain from using GapSeal® ever since. These studies finally showed a statistically significant reduction in peri-implantitis in more than a third of all implants sealed with GapSeal®.<sup>15</sup>

## Application

Implant interiors can be sealed with GapSeal® immediately after inserting and removing the insertion tool, thereby eliminating the prospective peri-implantitis inducing the re-infection factor. For this purpose, the carpule must be inserted into the applicator at first, and the closing cap needs to be removed. It is recommended to bend the cannula slightly around the applicator shaft according to the filling situation. Excess material gushing from the implant when the closure cap is screwed in indicates a good filling situation (Fig. 6).

The material is delivered in sterile blister packs and the applicator is autoclavable to warrant sterility. In case the implant is treated with GapSeal® at a later point, thorough cleansing of the interior spaces with alcohol is recommended. Furthermore,

it is advised to fill the hollow spaces of screwed superstructures with GapSeal®. During implant re-entry at recalls, it is advisable to renew old material, which may be rinsed out with xylene or alcohol. GapSeal® is very stable; it retains its qualities in cemented works over years, and requires neither exchange nor replenishment.

## Results and discussion

Peri-implantitis is the most feared complication occurring in implantology, especially once the implant therapy with appropriate prosthetics is completed. Suggestions regarding the treatment exist in ample variations and are also put into practice. However, it seems to be more reasonable to prevent the causes for peri-implantitis, which certainly originate to a large percentage from re-infection out of implant gaps and hollow spaces. The possibility of germ colonisation in implant interiors exists and should be taken seriously. Attempts to combat re-infection have been described in specialised literature for years. Now GapSeal® with its sixteen years of clinical experience offers a truly effective prevention against peri-implantitis.

*Editorial note: A list of references is available from the publisher.*

contact

implants

**Prof. Dr Dr Claus Udo Fritzemeier**

Im Winkel 5  
40627 Düsseldorf, Germany

friham@fritzemeier.eu

# Manufacturer News

## Implant Direct

### New Swish™ Angled Overdenture Abutments

The new Swish™ Angled Overdenture Abutments feature a compact, one-piece angled base with screw-receiving head designed for reduced vertical height. Available in 15° and 30° for 4.8 mm platforms, these abutments simplify treatment of fully edentulous jaws by achieving parallelism when implants are inclined. With an industry-standard internal octagon connection, 4.8 mmD Angled Overdenture Abutments are compatible not only with the SwishPlant™ and SwishPlus™ but also with Straumann® Tissue-Level implants — offer-



ing Straumann customers a whole new way to treat fully edentulous patients. The Angled Overdenture Abutments package includes a one-piece angled base with screw-receiving head, Duo-Grip™ fixation screw, transfer and comfort cap.

#### Implant Direct Europe AG


Hardturmstrasse 161  
8005 Zurich, Switzerland

info@implantdirect.eu  
www.implantdirect.de

## Omnia

### PTFE surgical sutures

In addition to the traditional surgical sutures made of silk, polyester and absorbable PGA, Omnia expands its offer of surgical sutures by introducing the new generation. Omnia PTFE sutures are soft, biologically inert and chemically non-reactive. Main features of PTFE sutures are a great fluency of the thread along the tissues and a strong knot holding. Its material is highly tolerated in the oral cavity. Furthermore, PTFE sutures are optimal to limit inflammation, bleeding and other collateral effects which may occur during the soft tissue approximation. The sutures are available in different combinations of diameter and length with different kinds of needles. Omnia PTFE sutures can be applied in any implant, periodontal and bone



graft surgery, where the usage of a monofilament suture with low bacterial adhesion is recommended. PTFE sutures are available in convenient boxes of twelve pieces each

#### Omnia S.p.A.

Via F. Delnevo, 190sx  
43036 Fidenza (PR), Italy  
Tel.: +39 0524 52745

info@omniaspa.eu  
www.omniaspa.eu

## Geistlich

### Seal for good soft tissue outcome

Aesthetic treatment results are extremely important to patients. A key factor for success is the condition of the soft tissue. Many dentists take the opportunity to optimise soft tissue immediately after an extraction by sewing a tissue punch from the palate into the new socket. However, graft removal from the palate is painful and creates a second wound. By using a Geistlich Mucograft® Seal collagen matrix instead of autologous soft tissue, the dentist spares the patient pain and surgery time. The 8 mm disk is made of the same proven material as Geistlich Mucograft® colla-

gen matrix and displays the same properties. It protects the graft and creates soft tissue that matches perfectly the colour and texture of its surroundings. Geistlich Mucograft® Seal is sewn over an extraction socket that has been filled with Geistlich Bio-Oss® Collagen during a ridge preservation procedure. An undamaged buccal bone plate is a prerequisite for this. Products from Geistlich Biomaterials are marketed only after they have been scientifically tested and have demonstrated clear clinical value. An international advisory board, under the direction of Prof. Mariano Sanz,

## Straumann

### A new level of confidence for patients and dentists

Two of the largest international clinical studies performed to date demonstrated good clinical performance of Straumann Bone Level implants. Evaluating more than one thousand implants in Europe, the US and Australia, both studies reported high implant survival rates of more than 98% with practically no bone loss around the implants. The findings are considerably better than values reported in a comprehensive review of previously published studies with other implants. One of the studies, a large 'non-interventional study' (NIS) was conducted in Europe and the US, evaluating a total of 908 implants in 538 patients at more than a hundred dental practices in six countries. It revealed an implant survival rate of 98.5% after one year, the bone level remaining stable in the majority of cases. The investigators concluded that treatment with Straumann Bone Level Implants yielded successful outcomes in 'real life' conditions. The new studies add to the wealth of strong clinical evidence backing the Straumann dental implant system and thus provide very good reasons for patients and dentists to insist on Straumann implants rather than undocumented alternatives.



#### Institut Straumann AG

Peter-Merian-Weg 12  
4052 Basel, Switzerland

info@straumann.com  
www.straumann.com



Spain, assessed the new product. The experts' opinion was that ridge preservation in combination with Geistlich Mucograft® Seal is a predictable approach.

#### Geistlich Pharma AG

Bahnhofstrasse 40,  
6110 Wolhusen, Switzerland

www.geistlich.ch

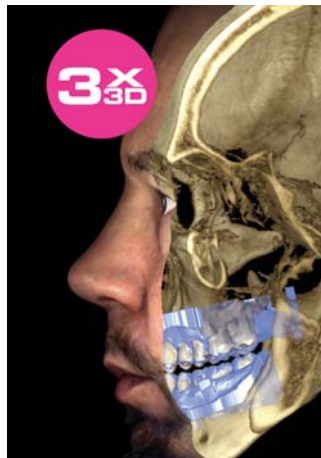Planmeca

**Three types of 3-D data with one Planmeca unit**

Planmeca's 3-D X-ray unit range now offers a combination of three different 3-D data. With just one unit, the user can acquire a patient CBCT image, 3-D face photo and 3-D model scan, and combine these data in one software suite. A virtual patient is created for different clinical needs.

**3-D model scanning:** Planmeca is proud to introduce a new imaging mode to its Planmeca ProMax® 3D X-ray units. The imaging mode is designed for scanning impressions and plaster casts. Impressions are automatically inverted to digital casts and instantly stored in the Planmeca Romexis® software in standard STL format. For orthodontic purposes, the STL data can be further analysed in the Planmeca Romexis® 3D Ortho Studio module. The Romexis database stores all digital casts together with other patient images. The 3-D model scans can also be utilised in orthognatic surgery planning and for follow-up of the patient's treatment progress.

**Planmeca ProFace®:** Planmeca ProFace® is a unique 3-D face photo system available for the whole Planmeca ProMax 3D family. Designed to fulfil the most diverse diagnostic needs of today's maxillofacial and dental professionals, the system generates both a 3-D face photo and a CBCT volume in just one imaging



session. The 3-D photo can also be acquired separately in a completely radiation-free process.

**Planmeca ProMax® 3D family:** The Planmeca ProMax 3D family is an intelligent, all-in-one X-ray unit range designed to obtain complete information on patient anatomy in the minutest detail. The units provide digital panoramic, extraoral bitewing, cephalometric, and 3-D CBCT imaging, 3-D face photos and now also 3-D model scans. The wide selection of volume sizes allows optimising the imaging area according to a specific diagnostic task. All patient images are conveniently processed in a single software suite, Planmeca Romexis.

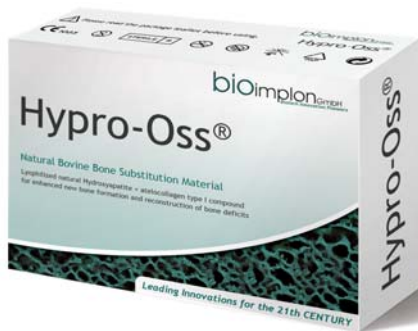**Planmeca Vertriebs GmbH**

Walther-Rathenau-Str. 59  
33602 Bielefeld, Germany

info@planmeca.de  
www.planmeca.com

Bioimplon

**Innovative lyophilized bovine bone graft**



One vision, two companies and many years of research conducted to the patented, revolutionary, natural, atelo-peptidized and lyophilized bovine bone graft composite "Hypro-Oss". After intensive research and development, medical researchers of Bioimplon and polymer chemistry engineers realized the breakthrough: A bone graft substitute, which potentially reduces or eliminates the need for autografts. In January 2013, the patented bone graft substitute "Hypro-Oss" was formally presented. It combines scaffolding properties with biological elements to stimulate cell proliferation, differentiation and osteogenesis. The atelo-peptidized Hypro-Oss was processed with a special lyophilization technol-

ogy, avoiding any heating of the material for preserving the natural bio-elements, which conduct complete new bone formation in just 14 weeks.

The Hypro-Oss has also strong hydrophilic properties, optimal cell adhesion, blood absorption, excellent handling and high biocompatibility because of the atelo-peptidation and lyophilization. The natural, crystalline structure and optimal porosity guarantees long-term dimensional stability. Thanks to the atelo-collagen, it has powerful hemostatic and bacteriostatic properties.

There are no swelling or hematoma complications after sinus lifting or surgical procedures according to many clinicians' observations.

**Bioimplon GmbH**

Friedrich-List-Str. 27  
35398 Gießen, Germany  
Tel.: +49 641 68681123  
Fax: +49 641 68681124

info@bioimplon.de  
www.bioimplon.de

AD

**OMNIA**  
Disposable Medical Devices

**You are n°1!  
don't be satisfied  
with a second choice, Pick up  
Omnia irrigation system!**

**OMNIA S.p.A.**  
Via F. Delnevo, 190 - 43036 Fidenza (PR) Italy  
Tel. +39 0524 527453 - Fax +39 0524 525230  
VAT. IT 01711860344 - R.E.A. PR 173685  
Company capital € 200.000,00  
[www.omniaspa.eu](http://www.omniaspa.eu)

Degradable

**Preparing for the future of implant dentistry**

The 22<sup>nd</sup> Annual Meeting of the European Association for Osseointegration (EAO) will take place in Dublin and Ireland from 17–19 October 2013, with the theme “Preparing for the Future of Implant Dentistry”.



Nearly 70 speakers and more than 3,000 delegates from around the world are expected to participate in the congress. The Sunstar Foundation is sponsoring the Breakfast Symposia on Friday, October 18, 7.45–8.45 am where Prof. Dr Engelke, University Göttingen, will be lecturing about „Alveolar Ridge Preservation using Endoscopically assisted Root Enucleation in Anterior Maxillary Extraction Sites“. As a silver sponsor Sunstar will present their products at the commercial exhibition which runs throughout the period of the congress. Visit them at booth no. S32 and learn more about the innovative product range.

**Degradable Solutions AG**

Member of Sunstar Group  
 Wagistrasse 23  
 Tel.: +41 43 4336260  
 Fax: +41 43 4336261  
 www.degradable.ch

DENTSPLY Implants

**First Jan Lindhe Satellite Symposium in China**



Numerous international experts are gathering to host a lecture series on the topic “Optimizing Implant Therapy” at the first Lindhe Symposium in October in Beijing, China. The topics covered at the symposium are as diverse as the field of implantology itself: from the planning of treatments, over functional and aesthetic aspects, to challenging situations during patient treatment.

Renowned speakers — such as Lyndon Cooper (USA), Ye Lin (China), Stefan Hassfeldt (Germany) and Jan Lindhe (Sweden) himself — ensure the presentation of interesting, evidence-based conclusions on different treatment procedures in implant dentistry. The objective of the event is to provide participants with new ideas for optimal patient care. The symposium is organized by Peking University, in association with the Univer-

sity of Gothenburg. This event is a supplement to the successful symposium in Gothenburg, Sweden, which is held every three years in honour of Jan Lindhe, a noted scholar and scientist in the field of periodontology and implant dentistry. It was founded in 2006 and is organised by the Sahlgrenska Academy at the University of Gothenburg. The Satellite Symposium in China will take place from October 26–27 in the Friendship Palace Hotel, Beijing.

DENTSPLY Implants is sponsor of the symposium.

More information and registration:  
[www.janlindhesatellitesymposium.com](http://www.janlindhesatellitesymposium.com)

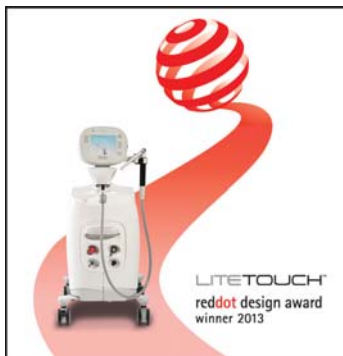**DENTSPLY Implants**  
[www.dentsplyimplants.com](http://www.dentsplyimplants.com)



Syneron Dental Lasers

**Red Dot Design Award in the Life Science and Medicine Category**

Syneron Dental Lasers, provider of innovative hard & soft tissue dental laser technologies, has been selected among the winners of the international Red Dot Award, for product design in the Science and Medicine Category. This year, a jury of international experts evaluated over 4,700 entries from 54 countries within 19 different products categories against key criteria including the degree of innovation, ergonomics, durability and ecological soundness. The awards were presented on July 1st at Aalto Theater in Essen, Germany.



The Red Dot jury selected LiteTouch as the award winner because of its innovative fiber-free laser delivery technology. Thanks to miniaturization of Syneron Dental Lasers' laser technology, the whole power generator is incorporated within the Laser-in-Handpiece™ mechanism. This innovative solution mimics the feel of the turbine drill,

yet incorporates laser-unique benefits: micro surgery, quicker healing, minimal invasive treatments and higher acceptance of patients to dental treatments.

Researches in the implants and surgery field suggested that bone surgery with LiteTouch™, when compared to the mechanical drill, may enhance bone regeneration by increasing the amount of growth factors present in stemcells. In addition Lite-Touch™ has been reported to be used successfully in implant therapy and for the treatment of periimplantitis.

**Syneron Dental Lasers**  
 Tavor Building, Industrial Zone  
 20692 Yokneam Illit, Israel

dental@syneron.com  
[www.synerondental.com](http://www.synerondental.com)

FDI congress gets off to

## A promising start



With the playing of the Turkish national anthem and the handover of the presidential chain of the FDI from Dr Orlando Monteiro da Silva to the president elect, Dr Tin Chun Wong, as only two of the highlights, the FDI Annual World Dental Congress was officially opened today at an opening ceremony in Istanbul. Local flavour was added through performances by Turkish percussionist Burhan Öçal and his group, followed by Fire of Anatolia, a dance show that offered a fusion of Anatolian dances, modern dance and ballet.

The audience was addressed by the Turkish Minister of Health, Mehmet Müezzinoğlu, who took the opportunity to thank the organisers for their great efforts in

hosting another outstanding event in Istanbul. Already on 29 August, thousands of visitors from all over the world were already swarming around the halls and exhibition areas of the Istanbul Congress Center.

In total, more than 12,000 dental professionals attended the four-day event, which has been organised by the Geneva-based organisation and the Turkish Dental Association. There were more than 160 lectures and presentations, as well as other events related to oral disease prevention and management. In addition, local and global manufacturers presented their latest products and services at the World Dental Exhibition on Level 5.

## CAD/CAM technology

### In dental education

While a number of dental laboratories use CAD/CAM technology these days, the computer-assisted design and fabrication of inlays, crowns and smaller bridges is not widely taught at dental schools yet. One of the first university hospitals in Germany to do so, Jena University Hospital teaches dental students to use state-of-the-art digital technology.

The small camera head passes over the teeth without touching them to obtain a 3-D digital image, which is displayed immediately on the screen. In this way, the patient is spared the usual biting into an impression compound. It is not possible to capture the entire dentition with just a single shot in all three dimensions. The dentist scans the teeth by moving the camera with its finger-sized head in a smooth motion over the teeth at a short distance to create a number of frames that can be joined to form a complete 3-D image.



The entire process is quick. Since the restoration can be placed immediately, the placement of temporaries and the usual waiting period of several weeks for permanent restoration are avoided. The camera is very precise and captures the opposing teeth, which is necessary for establishing good occlusion.

## CAMLOG

### The ever evolving world of implant dentistry

The CAMLOG Foundation will be holding the 5<sup>th</sup> international CAMLOG Congress in Valencia from 26–28 June 2014 (Spain). The congress will be held under the motto “The Ever Evolving World of

## camlogfoundation

Implant Dentistry” and promises to be the symbiosis of science and practice at the highest level.

The case at preceding CAMLOG congresses, the committee will once again comprise high-ranking scientific personalities and be presided over by Prof. Mariano Sanz (Spain) and Prof. Fernando Guerra (Portugal). True to its motto “The Ever Evolving World of Implant Dentistry”, continuous developments in the scientific and practical aspects of implant dentistry will be taken into account.

Congress participants can expect first-class presentations, which serve to deepen the specialist knowledge of the listeners on the one side, and contribute toward improving the clinical results in the daily practice of the dental physicians on the other. Main topics of the congress are the clinical concepts and recommendations, and also the complexity of multifactorial decision-making in implant dentistry.

Lectures and discussions will also be addressing controversial themes. Attention here will focus particularly on the implementation of these topics in daily implant practice. Apart from the top-class program of the scientific congress, the location of Valencia itself has a great deal of magnetism.

Due to its location on the Mediterranean and the agreeable climate that goes with it, the third largest city in Spain is highly appealing and offers something for all tastes.

### CAMLOG Foundation

Margarethenstrasse 38  
4053 Basel, Switzerland

Tel: +41 61 5654100  
info@camlogfoundation.org



## Nobel Biocare

### New foundation to improve oral health care

FOR is an independent, international initiative that unites professionals from various disciplines to improve oral health care and support humanitarian leadership. Young participants can benefit from personal mentorship and support in advancing their careers as emerging leaders. The mission of the new foundation is to achieve effective worldwide patient care through scholarship and humanitarian engagement. The foundation has three network key areas: Science, Education and Humanity.

“FOR SCIENCE” helps participants stay at the forefront of innovation and scientific breakthroughs by collaborating with leading experts and researchers from various fields. Additionally, a FOR participant becomes part of a leading science- and evidence-based organization at the frontiers of oral rehabilitation.

“FOR EDUCATION” provides an interactive learning platform; it aims to unite a global community of experts to provide clinical fellowship, mentorship, and mutual



support to improve the quality of life of patients. Young professionals can interact with mentors and peers for personal and professional development and life-long learning.

“FOR HUMANITY” recognizes humanitarian achievement and initiatives. They ensure support for humanitarian projects and provision of free products for treating patients in need. FOR welcomes active participation from all disciplines and specialties in the field of oral rehabilitation. FOR will look for shared humanitarian values, active participation, and a mutual commitment to contribute to the ideals of the foundation.

#### FOR CENTER

Werftstrasse 4, PO Box 2558  
6002 Lucerne 2, Switzerland

info@forcenter.org  
www.for.org

## International GBOI examination

### Register now!

The medical market and especially the dental market are becoming more and more globalised. DGZI has perceived a growing interest of foreign patients to receive a competent treatment from experienced German dentists. Especially patients from the Arabian region and the former GUS states appreciate quality and know-how “made in Germany” and use their stay in Germany for extensive dental treatments. For this reason, DGZI – the practitioner’s dental society for oral implantology – has decided already four years ago to offer experienced colleagues the opportunity to obtain the internationally acknowledged certificates “Expert in Oral Implantology DGZI” and “Specialist in Oral Implantology DGZI” of the German Board of Oral Implantology (GBOI).



Germany. Participants of the GBOI examination will receive a 20% discount on the congress fees. For questions or application forms, please contact the DGZI headquarters.

#### DGZI Headquarters

Paulusstraße 1  
40237 Düsseldorf, Germany  
Tel.: 0211 16970-77  
Fax: 0211 16970-66

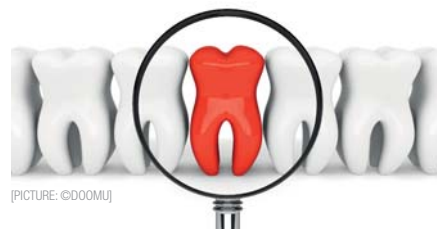sekretariat@dgzi-info.de  
www.DGZI.de

These two international certificates includes proof of qualified, subject-specific command of English. This year’s GBOI examination will take place Thursday, 3 October 2013, on the day before the 43<sup>rd</sup> International Annual DGZI Congress from 4 to 5 October in Berlin,

## European experts unite to

### Stop caries

The Alliance for a Cavity-Free Future, an international group of experts that promotes an integrated clinical and public health effort, has announced a new European chapter to bring together experts in dentistry and public health to create a collaborative focus for the implementation of key changes to dental health practices across Europe. One of the alliance’s targets is to enable every child born from 2026 to stay cavity free during his or her lifetime.



The alliance, first launched as a global initiative in 2010, calls for joint action to challenge leaders and stakeholders in the community to learn the importance of caries as a disease continuum by recognising that cavities are preventable and that in the early stages caries is reversible, and to develop comprehensive programmes for the prevention and management of dental caries appropriate for individual regions. Findings from a new omnibus survey of 4,500 European adults conducted online have highlighted the need for further education about dental caries at a public health level. According to 2013 figures from the WHO, dental caries affects up to 80 per cent of the world’s population. European countries have seen a marked improvement in levels of dental caries over the last 30 years; however, in many segments of the population, dental caries remains a significant burden, a study revealed in 2008. At a global level, the Alliance for a Cavity-Free Future has set three long-term goals. First, by 2015, 90 per cent of dental schools and dental associations should have embraced and promoted the new approach of caries as a continuum to improve dental caries prevention and management. Second, by 2020, regional members of the Alliance for a Cavity-Free Future should have developed and implemented integrated, locally appropriate, comprehensive caries prevention and management systems and monitoring. Third, every child born from 2026 should stay cavity free during his or her lifetime.

Further information on the launch of the European Chapter is available at [www.family.allianceforacavityfreefuture.org/en/us/whats-new](http://www.family.allianceforacavityfreefuture.org/en/us/whats-new).

# Nobel Biocare Global Symposium 2013 in New York

Source: Nobel Biocare

[PICTURE: ©ORHAN CAM]



Richard T. Laube, CEO Nobel Biocare



The Nobel Biocare Global Symposium 2013 in New York saw more than 2,000 dental professionals from around the world come together to explore the latest developments in implant dentistry under the theme "Designing for Life: Today and in the Future".

A varied and unique scientific program held over four days saw well over 100 leading professionals bring this theme to life as they imparted their knowledge, shared their experiences and presented the very latest innovative technology and clinical approaches. Over the course of the event delegates were taken through four complete "patient journeys": Missing Anterior and Posterior Single Teeth; Missing Multiple Anterior Teeth; Missing Multiple Posterior Teeth; and Managing the Terminal / Failing Dentition—The Transition to Edentulism.

The symposium also offered an introduction to Nobel Biocare's new fully-integrated digital treatment workflow for partially edentulous patients. With the secure, online NobelConnect network at its heart, Nobel Biocare is developing a seamless workflow which brings together the latest innovations at each stage of the treatment process.

Other innovations were also unveiled at the event. The announcement of the creos™ xeno.protect membrane marked the introduction of a new regenerative product to Nobel Biocare's products and solutions portfolio. Made of biodegradable collagen, the membrane is


easy to handle and creates a favorable environment for bone regeneration whilst preventing undesired cells migrating to the treatment site from surrounding soft tissue. The official launch date is to be announced in due course.

Although the symposium has come to an end the work of the Foundation for Oral Rehabilitation (FOR), inaugurated at the event, is only just beginning. FOR has been established by Nobel Biocare to deliver tangible progress across three key sections: FOR Education, FOR Science and FOR Humanity. The formal launch of the foundation saw the presentation of the first "FOR Humanity Award" to Goodwill Ambassador for the United Nations, Bertrand Piccard for his humanitarian work such as with the "Winds of Hope" foundation. Professor Per Ingvar Brånemark was also elected as the first Honorary Fellow of FOR and Dr. Patrick Henry was presented with a lifetime achievement award for his contribution to the industry.

FOR is a global initiative that will expand the reach of oral rehabilitation through knowledge sharing and humanitarian efforts, helping ensure the best practice discussed in New York will be implemented to the benefit of patients for generations to come. For those who weren't able to join us in New York, the key outtakes from the event and the latest developments following the launch of FOR will be appearing in the next edition of Nobel Biocare News and at [www.nobelbiocare.com](http://www.nobelbiocare.com).



Prof. George Zarb, chairman of FOR



**implants**  
international magazine of oral implantology



**Publisher**

Torsten R. Oemus  
[oemus@oemus-media.de](mailto:oemus@oemus-media.de)

**CEO**

Ingolf Döbbecke  
[doebbecke@oemus-media.de](mailto:doebbecke@oemus-media.de)

**Members of the Board**

Jürgen Isbaner  
[isbaner@oemus-media.de](mailto:isbaner@oemus-media.de)

Lutz V. Hiller

[hiller@oemus-media.de](mailto:hiller@oemus-media.de)

**Chief Editorial Manager**

Dr Torsten Hartmann (V. i. S. d. P.)  
[hartmann@dentalnet.de](mailto:hartmann@dentalnet.de)

**Editorial Council**

Prof Dr Dr Frank Palm  
[frank.palm@klinikum-konstanz.de](mailto:frank.palm@klinikum-konstanz.de)

Dr Roland Hille

[dr-hille@t-online.de](mailto:dr-hille@t-online.de)

Prof Dr Dr Kurt Vinzenz

[kurt.vinzenz@aon.at](mailto:kurt.vinzenz@aon.at)

Dr Torsten Hartmann

[hartmann@dentalnet.de](mailto:hartmann@dentalnet.de)

Dr Suheil Boutros

[SMBoutros@aol.com](mailto:SMBoutros@aol.com)

**Editorial Office**

Georg Isbaner  
[g.isbaner@oemus-media.de](mailto:g.isbaner@oemus-media.de)

Claudia Jahn

[c.jahn@oemus-media.de](mailto:c.jahn@oemus-media.de)

**Executive Producer**

Gernot Meyer  
[meyer@oemus-media.de](mailto:meyer@oemus-media.de)

**Designer**

Sarah Fuhrmann  
[s.fuhrmann@oemus-media.de](mailto:s.fuhrmann@oemus-media.de)

**Customer Service**

Marius Mezger  
[m.mezger@oemus-media.de](mailto:m.mezger@oemus-media.de)

**Published by**

OEMUS MEDIA AG  
Holbeinstraße 29  
04229 Leipzig, Germany  
Tel.: +49 341 48474-0  
Fax: +49 341 48474-290  
[kontakt@oemus-media.de](mailto:kontakt@oemus-media.de)

**Printed by**

Silber Druck oHG  
Am Waldstrauch 1  
34266 Niestetal, Germany

**implants**

international magazine of oral implantology  
is published in cooperation with the German  
Association of Dental Implantology (DGZI).

**DGZI President**

Prof Dr Dr Frank Palm  
DGZI Central Office  
Paulusstraße 1, 40237 Düsseldorf, Germany  
Tel.: +49 211 16970-77  
Fax: +49 211 16970-66  
[office@dgzi-info.de](mailto:office@dgzi-info.de)

[www.dgzi.de](http://www.dgzi.de)  
[www.oemus.com](http://www.oemus.com)

**Copyright Regulations**

\_implants international magazine of oral implantology is published by Oemus Media AG and will appear in 2013 with one issue every quarter. The magazine and all articles and illustrations therein are protected by copyright. Any utilization without the prior consent of editor and publisher is inadmissible and liable to prosecution. This applies in particular to duplicate copies, translations, microfilms, and storage and processing in electronic systems.

Reproductions, including extracts, may only be made with the permission of the publisher. Given no statement to the contrary, any submissions to the editorial department are understood to be in agreement with a full or partial publishing of said submission. The editorial department reserves the right to check all submitted articles for formal errors and factual authority, and to make amendments if necessary. No responsibility shall be taken for unsolicited books and manuscripts. Articles bearing symbols other than that of the editorial department, or which are distinguished by the name of the author, represent the opinion of the afore-mentioned, and do not have to comply with the views of Oemus Media AG. Responsibility for such articles shall be borne by the author. Responsibility for advertisements and other specially labeled items shall not be borne by the editorial department. Likewise, no responsibility shall be assumed for information published about associations, companies and commercial markets. All cases of consequential liability arising from inaccurate or faulty representation are excluded. General terms and conditions apply, legal venue is Leipzig, Germany.

# implants

international magazine of oral implantology



Subscribe now!

I would like to subscribe to **implants international magazine of oral implantology** (4 issues per year) for €44 including shipping and VAT for German customers, €46 including shipping and VAT for customers outside Germany, unless a written cancellation is sent within 14 days of the receipt of the trial subscription. The subscription will be renewed automatically every year until a written cancellation is sent to OEMUS MEDIA AG, Holbeinstr. 29, 04229 Leipzig, Germany, six weeks prior to the renewal date.

▶ **Reply** via Fax +49 341 48474-290 to OEMUS MEDIA AG or per E-mail to [grasse@oemus-media.de](mailto:grasse@oemus-media.de)

You can also subscribe via [www.oemus.com/abo](http://www.oemus.com/abo)

Last Name, First Name

Company

Street

ZIP/City/County

E-mail

Signature

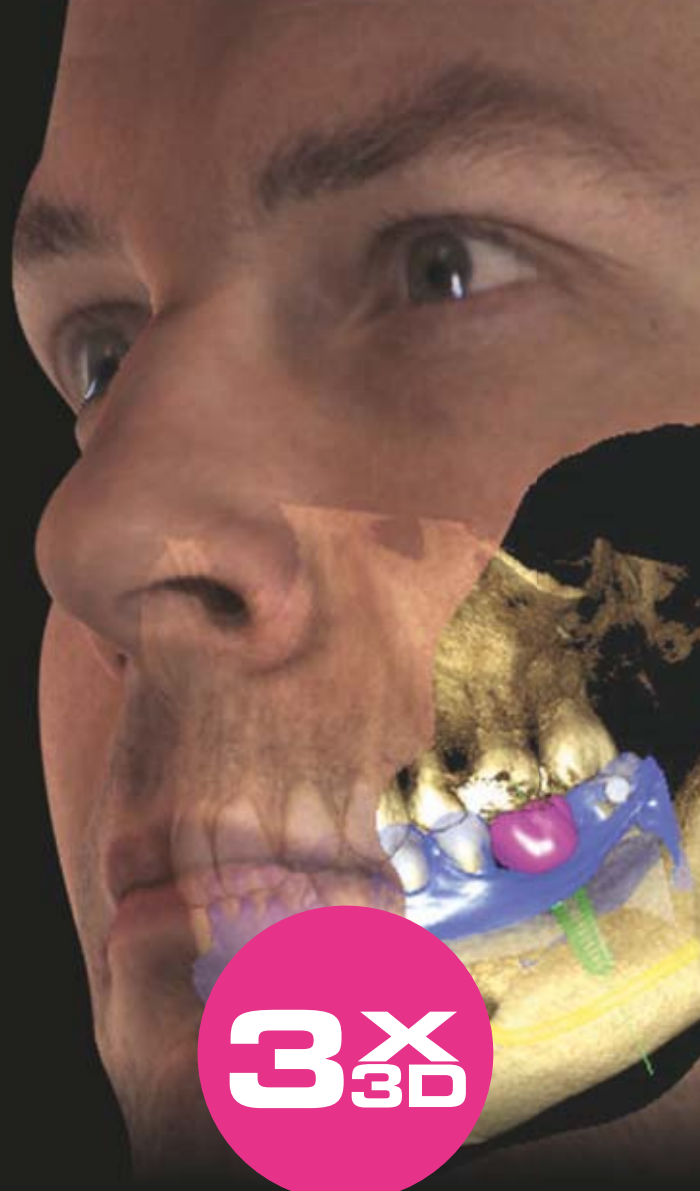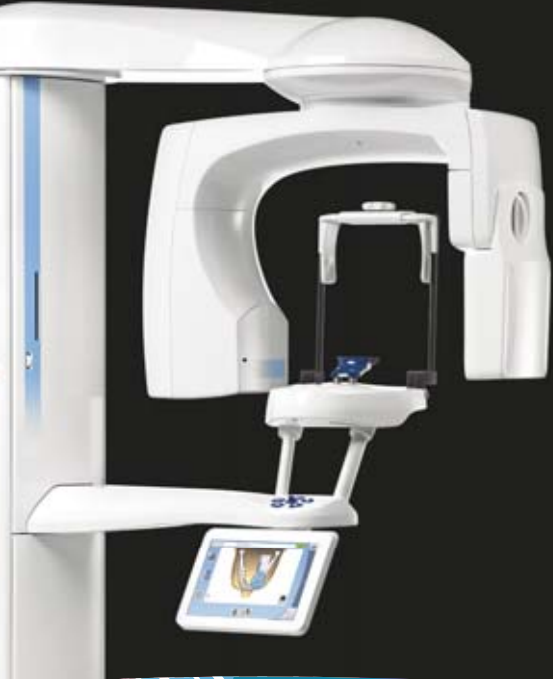Notice of revocation: I am able to revoke the subscription within 14 days after my order by sending a written cancellation to OEMUS MEDIA AG, Holbeinstr. 29, 04229 Leipzig, Germany.

Signature

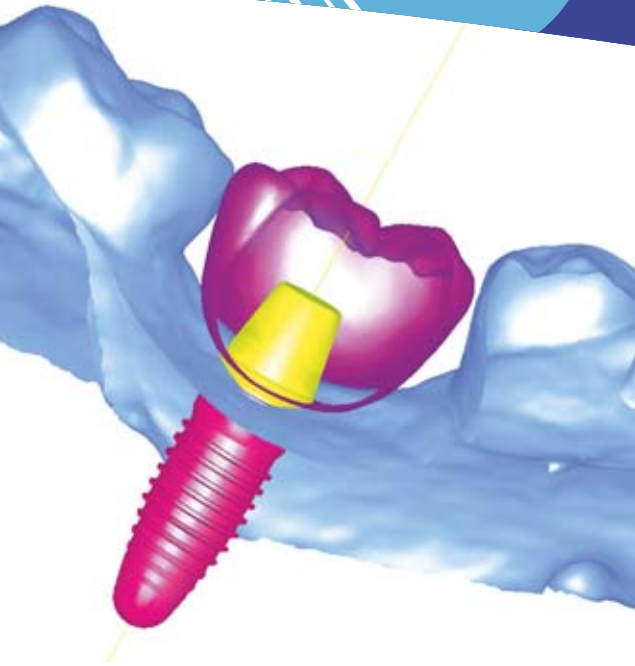



Planmeca ProMax® 3D  
Planmeca Romexis®

# Implant planning made easy



3x3D



**Planmeca Romexis® 3D Implant Planning** software offers the most sophisticated tools for the needs of modern implantology.

- Superimpose surface scan on to CBCT data
- Use crown library or import patient-specific crown from CAD system
- Position the implant using realistic implant and abutment libraries
- Verify the implant plan with verification tool
- Order surgical guide directly from the software

Find more info and your local dealer  
[www.planmeca.com](http://www.planmeca.com)



Planmeca Oy Asentajankatu 6, 00880 Helsinki, Finland. Tel. +358 20 7795 500, fax +358 20 7795 555, sales@planmeca.com, www.planmeca.com

**PLANMECA**

**ADMED**  
ADMED.com



- ISO: 8, 10, 15, 20, 25, 30, 35, 40, 45, 50, 55, 60, 70, 80, 90, 100, 110, 120, 130, 140
- Non-Standardized (Accessory sizes): XF, FF, MF, F, FM, M, ML, L, XL
- Special Taper Points: 04, 06

## گوتا فقط متا

✓ انعطاف پذیری بسیار بالا در حین کار

✓ پرفروش ترین در جهان

✓ رادیو اپستی عالی

✓ بی رقیب در قیمت و کیفیت

✓ مناسب جهت پر کردن کانال به روش تراکم جانبی و عمودی

✓ با بهترین بسته بندی ضد ریزش برای کاربری آسان



## کن کاغذی

موجود در انواع سایزها با قدرت جذب بالا، استریل و فاقد لینت  
در بسته بندی ۲۰۰ عددی کشویی ضد ریزش