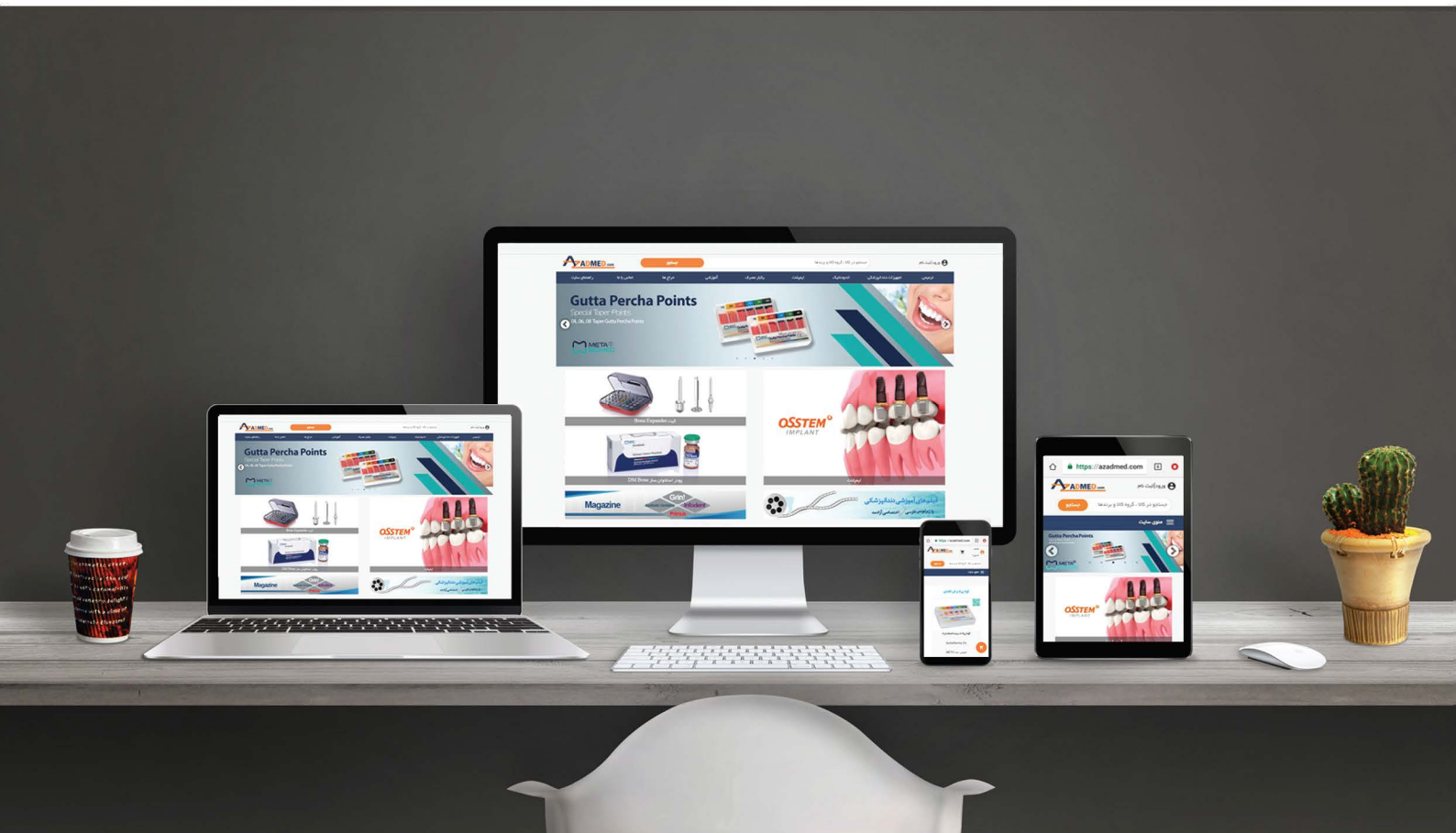







آزاد تجارت پارس
AZAD TEJARAT PARS.LTD

AZADMED.com



www.azadmed.com



 azaadtejaratpars
 @azadmed2
 88 98 80 63 - 6

implants

international magazine of oral implantology

4²⁰⁰⁹

_case report

True Anatomic Immediate Dental Implant Method

_case report

Safe and Effective Alternatives to Sinus Elevation in the Atrophic Posterior Maxilla—Part I

_worldwide events

Complications, Risks, and Failures in Oral Implantology



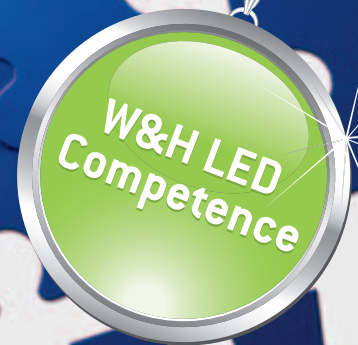DGZI
Deutsche Gesellschaft für
Zahnärztliche Implantologie e.V.





Now even more innovative

Easy-to-dismantle surgical instruments with LED and generator



Easy to dismantle. Easy to assemble. As simple as they are efficient: both the S-11 LED G and the WS-75 LED G can be completely dismantled. And, of course, they can be put back together again. Quick, simple and risk-free: meaning that you too are able to eliminate any risks and work in truly optimum hygienic conditions. Get the new standard for yourself: perfect light, global compatibility, precision, ergonomics – and complete safety.

Now at your local dental dealer or at wh.com



What a year! DGZI—throughout successful



Dr Friedhelm Heinemann
President of DGZI

Dear readers,

once again, the final edition of Implants lies before you, a year characterized by its many successful implantological DGZI curricula. Almost 1,000 interested dentists, dental technicians, and staff teams attended this year's DGZI events, for example, DGZI's 10th Expert Symposium/Spring-Meeting and the 39th DGZI Annual Congress. Additionally, the international examination of the German Board of Oral Implantology (GBOI) took place prior to the International Annual Congress. Altogether, more than twenty dentists took this difficult exam this year. All participants succeeded in correctly answering the theoretical questions as well as questions belonging to the specialist part of this wide-ranging performance review. Following the examination, examinees received GBOI certificates from the DGZI board and the highly qualified board of examiners. One of this year's highlights was the 33rd International Dental Show (IDS) in Cologne. DGZI once again had its own stand, which served as a perfect meeting point for DGZI members and national and international partners. Because of these results, the DGZI board comes to this positive conclusion: "This year's IDS performance exceeded all expectations, for we had more than 650 contacts with colleagues from all over the world." Next year, DGZI will look back on 40 years of existence, constant growth, and acknowledgement as the oldest European association in the field of dental implantology. Especially the coming year will prove that it will be worth to look back at the successful work of an association of dentists practicing implantology.

It is even more important to have a look ahead, and face a successful 2010. DGZI's 40th Anniversary will be celebrated in Berlin (October 1–2, 2010). We would like to invite you to this congress and look forward to your participation.

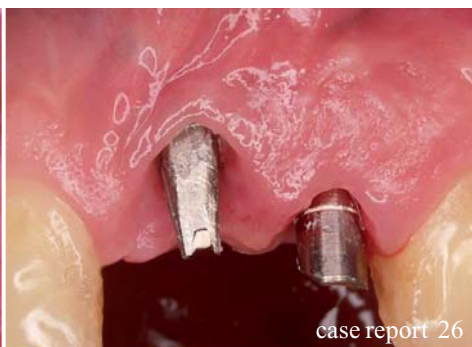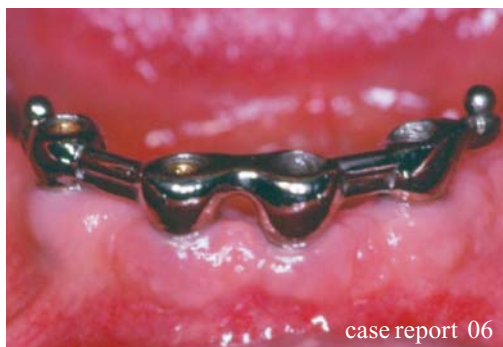Please enjoy this year's final issue of IMPLANTS.

In the name of the editorial board and the entire editorial staff, I would like to wish you a wonderful remaining 2009, and a successful start to 2010!

Yours,

A handwritten signature in black ink, appearing to read "Dr. Friedhelm Heinemann". The signature is fluid and cursive, with a long horizontal stroke extending to the right.

Dr Friedhelm Heinemann
President of DGZI



| editorial

- 03 What a year!
 DGZI—throughout successful
 _Dr Friedhelm Heinemann

| report

- _ case report
- 06 **Dental Implants**—Treatment Options for Compromised Clinical Situations—Part I
 _Suheil M. Boutros, USA
- _ case report
- 10 **True Anatomic Immediate Dental Implant Method**
 _Wolfgang Pirker, Alfred Kocher, Austria
- _ user report
- 16 **Safe and Effective Alternatives to Sinus Elevation** in the Atrophic Posterior Maxilla—Part I
 _Adel A. Chidiac, Kuwait
- _ case report
- 22 **Peri-implant Keratinized Mucosa**—Necessity, Surgical Technique and Healing
 _Felix Hänssler, USA, Norbert M. Salenbauch, Germany
- _ case report
- 26 **Dental Implants Aesthetic Complications**
 _Abdelsalam Elaskary, Egypt
- _ user report
- 30 **Use of Synthetic Bone Blocks** as an Alternative to Autologous Bone Block Grafts
 _Christian Mertens, Helmut G. Steveling, Germany

_ user report

- 34 **The Importance of Crestal Bone Preservation in the Use of Short Implants**
 _M. Marincola, Coelho PG, V. Morgan, A. Cicconetti

| events

- _ worldwide events
- 38 **Complications, Risks, and Failures in Oral Implantology**
 _Georg Bach, Germany
- _ worldwide events
- 41 **International Examination of GBOI in Munich**
- _ worldwide events
- 42 **FDI closes Annual World Dental Congress in Singapore**
 _Daniel Zimmermann, Germany
- _ implant events
- 44 **Selected Events 2009/2010**

| news

- _ social news
- 45 **Congratulations and Happy Birthday** to all DGZI-members around the world
- _ manufacturer news
- 46 **Manufacturer News**

| about publisher

- 50 **Imprint**


NobelReplace™

The world's most used implant system.*

Internal tri-channel connection for accurate and secure prosthetic restorations

TiUnite® surface and Groovy™ to enhance osseointegration

Implant design that replicates the shape of natural tooth roots



Color-coded system for accurate and fast component identification and ease of use

Color-coding: step-by-step drilling protocol for predictable surgical procedures

10 YEARS WITH
TIUNITE® SURFACE
New data confirm
long-term stability.

* Source: Millennium Research Group

Versatility, ease-of-use and predictability have made NobelReplace Tapered the most widely used implant design in the world.* NobelReplace Tapered is a general use, two-piece implant system that performs both in soft and hard bone, one- and two-stage surgical procedures, while consistently delivering

optimal initial stability. NobelReplace Tapered is a system that grows to meet the surgical and restorative needs of clinicians and their patients – from single-tooth restorations to more advanced multi-unit solutions. Whether clinicians are just starting or are experienced implant users, they will benefit from a system that

is unique in flexibility and breadth of application. Nobel Biocare is the world leader in innovative evidence-based dental solutions. For more information, visit our website.

www.nobelbiocare.com/nobelreplace

Dental Implants—Treatment Options for Compromised Clinical Situations

Part I—The Edentulous Mandible

author_ Suheil M. Boutros, USA

_Abstract

The patient who is totally edentulous in the mandible may not be able to consume a normal textured diet secondary to mobility of their denture. As they continue to lose alveolar bone height, the dislodgment pressure from the perioral musculature become greater than the retentive aspects of the prosthesis. This can cause discomfort, sores, and trauma to the mental nerve. The placement of endosseous implants into the anterior mandible is an excellent therapy for reconstruction, restoring these patients to a normal-textured diet, a normal nutritional intake, better health, and improved self-confidence.

The patient's options include a conventional denture, a tissue borne-implant-supported prosthesis, or implant-supported prosthesis. After an initial attempt to wear a conventional denture, many patients look forward to receiving implants because they are confident and comfortable with their decision to spend the money, dedicate the time, and deal with morbidity of implant surgery. In return, these patients often become easier to treat. Once the patient has made an informed decision after considering the recommendations of the implant team, the advantages of the different types of the prostheses, the financial responsibilities, and his or her personal desires and interests, surgery is scheduled.

Fig. 1_Ball O-rings over-denture.

Fig. 2_Zest locators over-denture.

Fig. 3_Four implants locator supported over-denture.

Fig. 4_Bar supported over-denture.

Fig. 5_Clips in the over-denture.

Fig. 6_Spark erosion milled supra-frame.

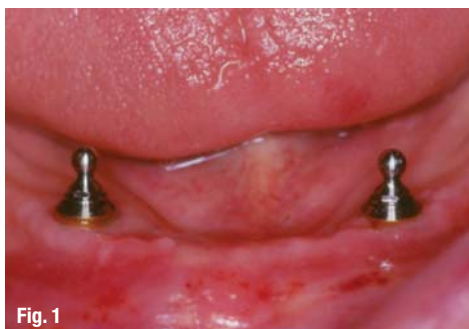

Fig. 1

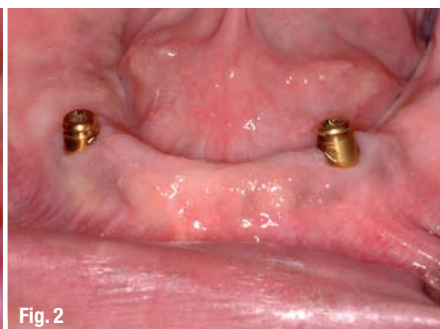

Fig. 2

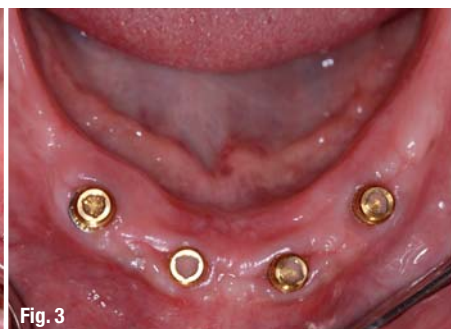

Fig. 3

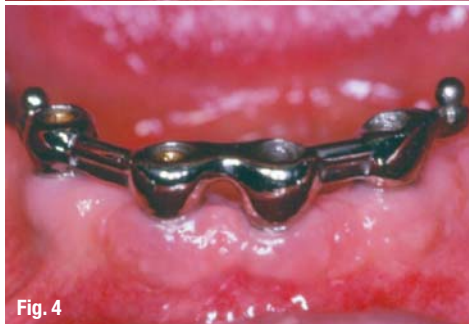

Fig. 4

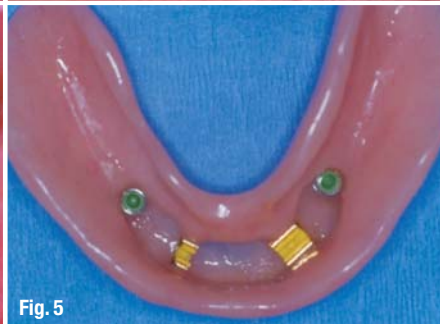

Fig. 5

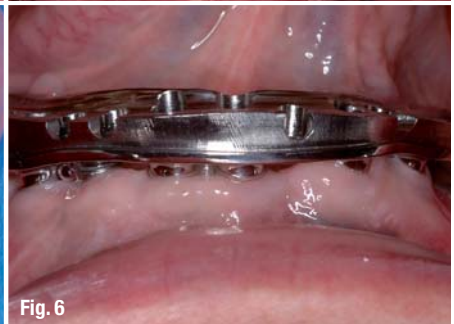
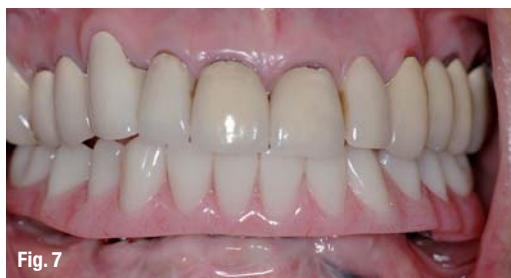
Fig. 6



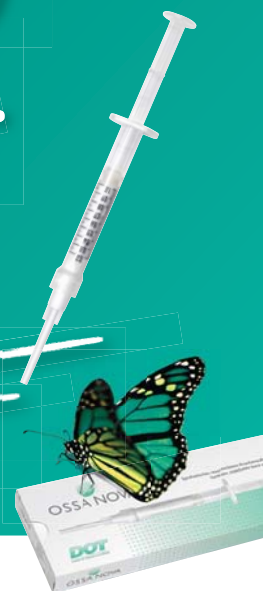Two implants (Implants retained tissue-borne prosthesis)

Generally when placing two implants for an over-denture, consideration should be given to the potential need for additional implants at a later time, in case the patient decides to change from a tissue-borne prosthesis to an implant-supported prosthesis. There are patients who enjoy the over-denture prosthesis, but complain of food getting caught under the denture, mobility of the prosthesis when speaking, swallowing, or chewing, and desire to eliminate changing O-rings or locators. For those patients who wish to retain a fixed-removable prosthesis, two to three additional implants may be placed in the anterior mandible. This is sufficient to support an implant-borne prosthesis. In preparation for a tissue-borne prosthesis, two implants should be 20 mm apart. Each implant 10 mm apart from the midline of the anterior mandible allows for future implant placement. The attachment options are ball O-rings (Fig. 1) or Zest locators (Fig. 2). If better retention is desired, four implants over-denture is recommended (Fig. 3).

Four implants (Implant retained and supported prosthesis)

The incision design is the same when placing four implants into the anterior mandible. The subperiosteal reflection should be sufficient to expose the lingual and labial cortices and the mental foramen bilaterally. After the periosteal reflection is completed, the surgeon has an excellent view of the operative site, the contours of the bone, and the location of the mental foramen. The mental foramen serves as the landmark to locate the distal implants. The most distal implants are placed at least five millimeters anterior to the mental foramen. A small round bur is used to place a depression in the bone to locate the implant site on one side of the mandible. A similar mark is placed on the opposite side of the mandible, a caliper is then set to seven to eight millimeters and the next implant locations are marked. If a fifth implant is to be placed, a mark is made in the midline of the mandible. The implant bodies are placed at a sufficient distance apart to ensure adequate space for restoration and hygiene (Figs. 4 and 5).

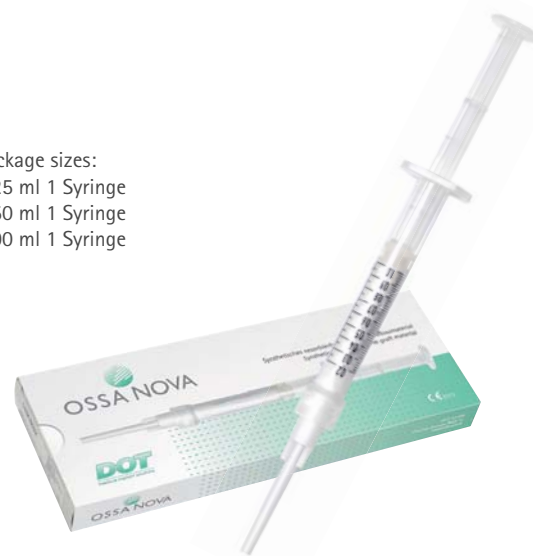Easy.
Safe.
Quick.



OSSA NOVA Bone Graft Material

- easy and safe application with a syringe
- pasty consistency for optimal defect alignment
- distinct capillarity for uptake of body fluids
- Integration into the natural bone remodelling process
- unhindered wound healing
- safe material due to synthetic origin

Package sizes:
0,25 ml 1 Syringe
0,50 ml 1 Syringe
1,00 ml 1 Syringe



DOT is a leading supplier of innovative solutions for dental and orthopedic implants.

DOT GmbH
Charles-Darwin-Ring 1a
D-18059 Rostock
Germany
Tel.: +49(0)381- 4 03 35-0
Fax: +49(0)381- 4 03 35- 99
biomaterials@dot-coating.de
www.dot-coating.de

DOT
medical implant solutions

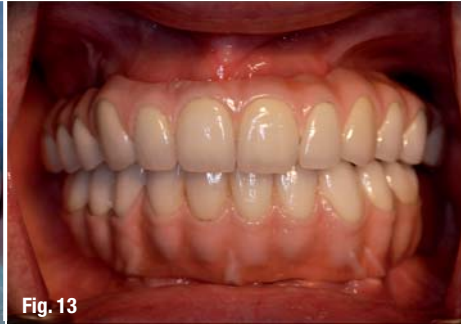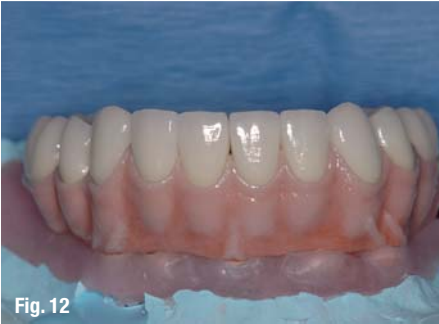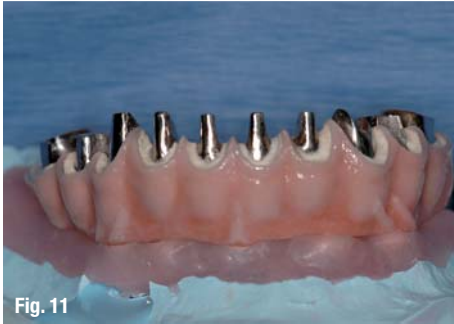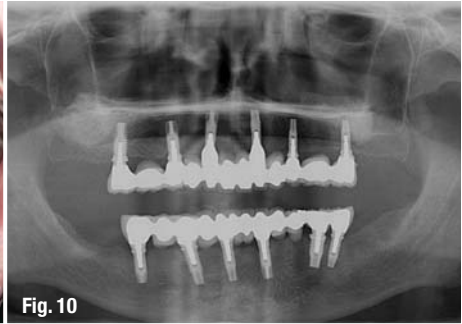


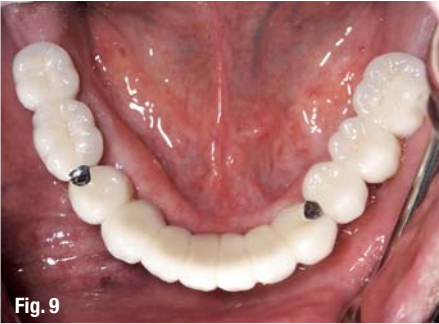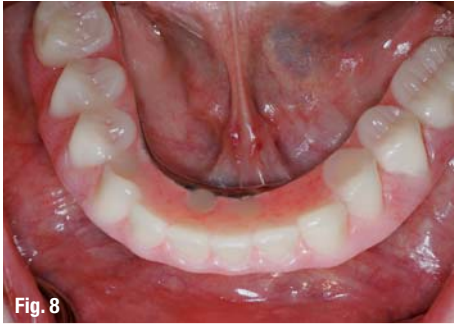Fig. 7_Fixed detachable prosthesis.

Fig. 8_Fixed detachable prosthesis, occlusal view.

Fig. 9_The fixed partial denture.

Fig. 10_One year follow-up.

Fig. 11_Casted supra-frame.

Fig. 12_Porcelain fused to metal crowns.

Fig. 13_Final prosthesis, one year in function.

_Five implants fixed detachable (Implant supported and retained prosthesis)

If the patient desires a fixed prosthesis, at least five implants are needed to support this structure. The most distal implants can support a small cantilever. This cantilever should not be longer than a tooth and a half or no more than 16–18 mm in length. In addition, the prosthesis should be at least two millimeters higher than the soft tissue to allow access for adequate oral hygiene. The metal framework can be casted or titanium-milled structure (Figs. 6, 7 and 8).

In general, the prosthesis does not need to be removed; unless there is a need to access the fixtures, in that case the supra-structure can be removed by carefully removing the retaining screws.

_The Fixed Prosthesis

When the patient wishes to have a fixed prosthesis that mimics their natural teeth, more implants are needed to be placed in the posterior region of the mandible, at least six to eight implants are required. In that case, the restoration can be porcelain fused to a metal fixed partial denture. This form of re-

placement can be done predictably if there is adequate bone, otherwise bone grafting will be needed (Figs. 9 and 10).

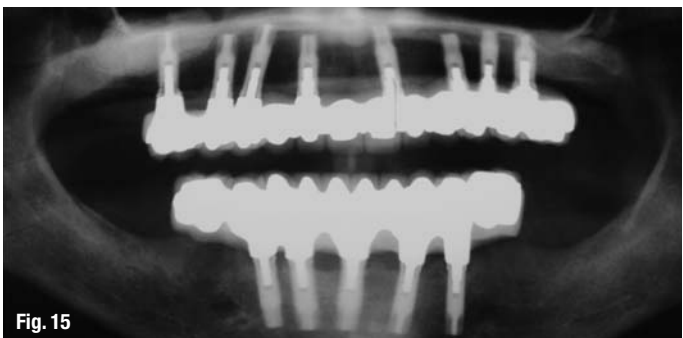
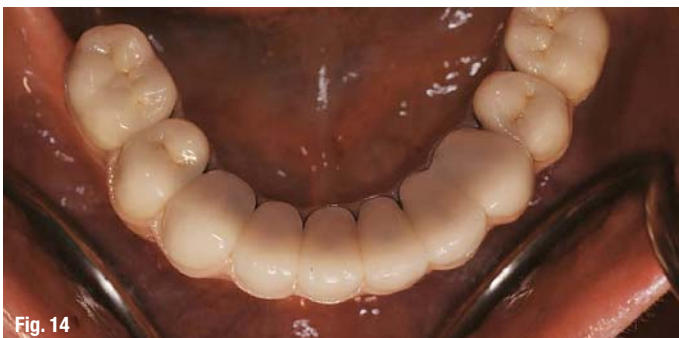The alternative to bone grafting is a supra-frame that compensates for the lost soft and hard tissue. In most cases, the supra-frame can be casted metal and the individual crowns can be porcelain fused to metal (Figs. 11, 12, 13, 14 and 15).

References are available upon request.

_contact	implants
<p>Suheil M. Boutros, DDS, MS Assistant Prof, Department of Periodontics University of Michigan Periodontal Specialists of Grand Blanc 8185 Holly Road, Suite 19 Grand Blanc, MI 48439 Phone: +1-810-695-6444 Fax: +1-810-695-4414 E-mail: sboutros@umich.edu</p>	

Fig. 14_Crowns cemented on sub-frame.

Fig. 15_One year follow-up.



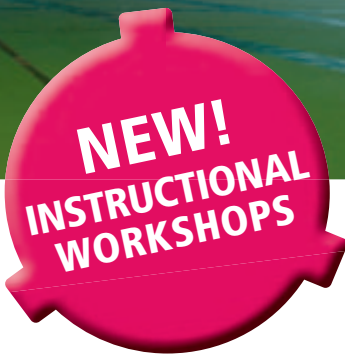


3RD INTERNATIONAL

CAMLOG CONGRESS

JUNE 10TH – 12TH, 2010

STUTT GART LIEDERHALLE



FROM SCIENCE TO INNOVATIONS AND CLINICAL ADVANCES

TOPICS

- Scientific and clinical advances, standard or platform switching restorations
- Restorative aspects and technical solutions
- Reports on current research
- Innovations in surgical site development
- Management of complications
- Meet the experts

SCIENTIFIC COMMITTEE

Prof. Dr. Jürgen Becker, Dr. Sven Marcus Beschnidt, Prof. Dr. Dr. Rolf Ewers

Prof. Dr. Dr. Dr. Robert Sader, PD Dr. Frank Schwarz, Prof. Dr. Dr. Wilfried Wagner

Under the aegis of the

 foundation

More information and registration: www.camlogcongress.com

True Anatomic Immediate Dental Implant Method

A Clinical Case

author_ Wolfgang Pirker, Alfred Kocher, Austria

Abstract

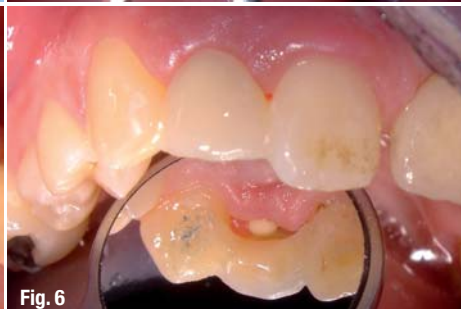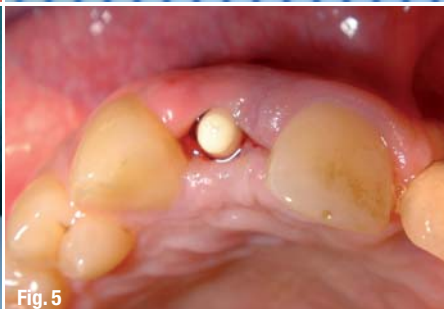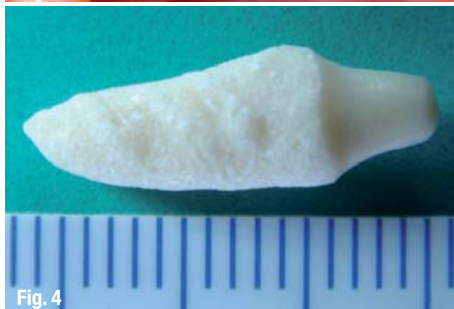
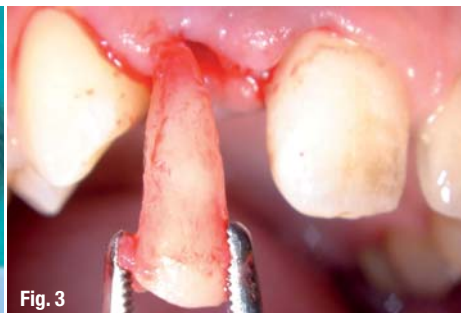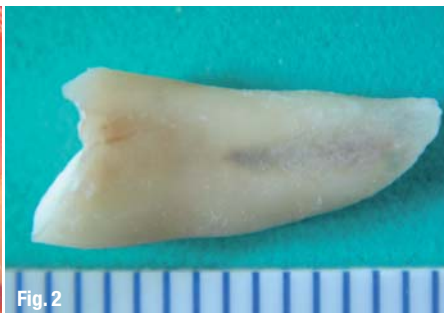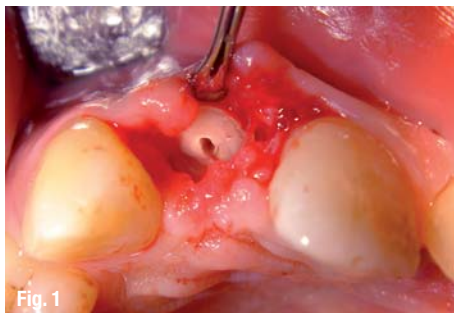
This paper describes a procedure for an immediate, truly root analogue, Zirconia dental implant placed into the extraction socket of a right lateral incisor. The tooth had to be removed because of a root fracture due to a trauma. The custom made root analogue Zirconia implant was roughened by sandblast and modified with macro-retentions in the interdental space. Seven days after extraction the implant was placed into the socket without any alterations of the root socket e.g. drilling or augmentation, by gentle tapping with a hammer and a mallet. Three months after root implantation a composite crown was cemented. No complications occurred during the healing period. An excellent esthetic and functional result was achieved. No clinically noticeable bone resorption or soft-tissue recession was observed at 15 months follow up. Sig-

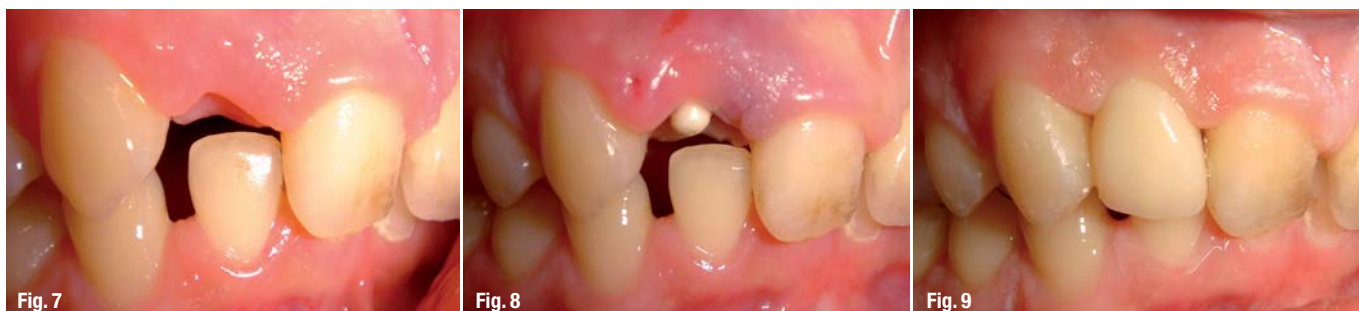nificant modifications such as macroretentions and diameter reduction next to the thin cortical buccal and palatal bone layer seem to indicate that primary stability and excellent osseointegration of immediate root-analogue Zirconia implants can be achieved, while preventing unesthetic bone resorption. This case warrants further clinical research in well controlled trials. For the first time a tooth colored, root identical implant is available and applied successfully in a clinical trial.

Introduction

Replacement of lost teeth using oral implants is an accepted treatment modality with well documented, high long-term success rates of up to between 90% and 100% at 10-year follow up.¹ More recently immediate implantation within a few days of extraction has

- Fig. 1 Removal of the root.
- Fig. 2 Extracted root.
- Fig. 3 Extracted root next to the extraction socket.
- Fig. 4 True anatomic Zirconia implant with macro-retentions.
- Fig. 5 Root analogue implant in place immediate post operative (occlusal view).
- Fig. 6 Provisional Maryland bridge in place.





been performed clinically in highly selected cases only. However, the indication is nowadays expanding. The major advantages of immediate implant placement are the reduction in treatment time with fewer surgical interventions leading to an improved quality of life and overall cost reduction, and most important socket preservation due to early functional load. Present dental implant strategies that work successfully in delayed implantology have serious limitations regarding functionality and esthetic outcome in immediate implantology.

The main reasons for these shortcomings are based on the fact that currently available dental implants are axially symmetric and made of titanium. In fact, they resemble the natural root neither in form nor in colour. The lack of the correct fit in most instances has to be compensated by multiple complex additional treatments such as bone augmentation, guided tissue regeneration as well as gum plasty. These procedures are time consuming, not fully predictable, generally costly and cause in addition great strain to the patient.

One has to keep in mind that these invasive procedures serve only the purpose to model the bone around a non-fitting titanium implant.

The indication for conventional immediate dental implantation is therefore still strictly limited to a very low percentage of patients with single tooth loss. Furthermore, due to the high sophistication and risk of the procedures the results are extremely dependent on the skills and experience of the surgeon and the compliance of the patient, respectively. Hence, the outcome is hardly predictable and the treatment therefore not suitable for everyday general practice.

On the other hand, a good primary stability and perfect esthetic outcome is simply and safely achieved, by taking advantage of the up to date principles of differentiated osseointegration, the use of Zirconia, a highly biocompatible implant material, combined with the preciseness of the latest CAD/CAM technology. This approach works only in combination with macroretentions in the interdental space and diameter reduction next to the cortical bone.

Compared to conventional implant strategies, the novel, individualized immediate Zirconia dental implant matches the extracted root both in form and color, respects and does not alter the underlying anatomy of the extraction socket and does not require any additional

straining surgical interventions. This most innovative approach is presented herein to a broad expert audience for discussion.

Hodosh and colleagues were the first to use custom-made root-analogue implants placed into the extraction socket, reducing bone and soft-tissue trauma.² Experimental studies with root-identical titanium implants yielded extremely favourable results with clear evidence of osseointegration and clinical stability.^{3,4} The ensuing clinical trial resulted in 100% primary stability at insertion and 1-month follow-up. Due to the high failure rate of 48% over the short time period of 9 months, this particular implant system was not recommended for clinical use.⁵ The present authors selected root-identical implants with significant modifications by 1) using Zirconia for its excellent biocompatibility, plaque-resistance and improved esthetic results; 2) adding micro-retentions to the entire root surface and macro-retentions strictly limited to the interdental space to get beyond primary stability and improve osseointegration; 3) reducing the diameter of the implant next to the thin cortical bone to avoid fracture and pressure-induced bone loss; and 4) choosing a single-stage implantation resulting in immediate, albeit limited, functional load via the crown stump for prevention of bone recession.

Surgical method

A 27-year-old male patient was referred to our practice for implant treatment of a fracture of the right lateral maxillary incisor (Fig. 1–3). After informed consent was obtained, the root was carefully extracted under local anesthesia (Ultracain DS Forte, Aventis), avoiding any damage to the socket and soft tissue. The extraction socket was cleaned by means of curettage, and an iodoform soaked cotton gaze was placed in the socket. The root was laser scanned and macroretentions were designed strictly limited to the interdental space, sparing the buccal and lingual face, to prevent fractures at the time point of insertion of the thin cortical bone layer. In addition a crown stump was designed for later connection to the crown. The implant was then milled from a zirconium dioxide block (specifically, yttrium-stabilized tetragonal Zirconia polycrystal), and the surface roughened by sandblast and sintered for 8 hours to achieve the desired mechanical properties (Fig. 4). Then the implant was cleaned in an ultrasonic bath contain-

Fig. 7 Pre operative situs.

Fig. 8 Root analogue implant in place immediate post operative (buccal view).

Fig. 9 Final result at 15 months follow-up.

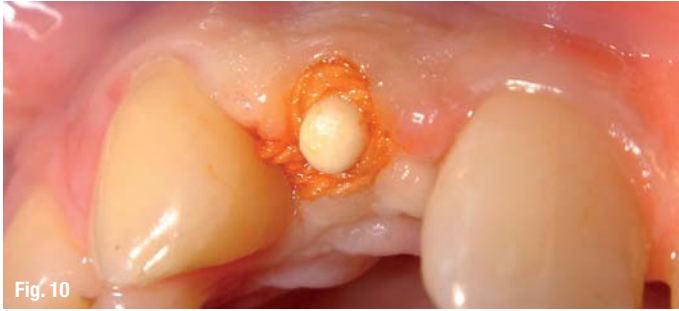

Fig. 10

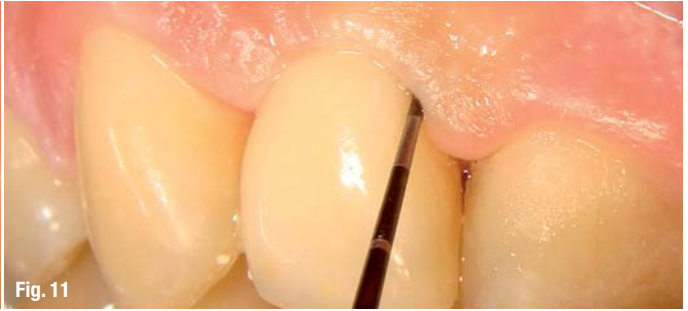

Fig. 11

Fig. 10_ Situation before impression with Retraction Cord in place.

Fig. 11_ Full restoration at 15 months, no bleeding on probing.

ing 96% ethanol for 10 min, packaged and sterilized in a steam sterilizer. On day 7 the iodoform cotton gaze was removed, and the alveolar socket again curetted and flushed with sterile physiologic saline solution. The custom-made individualized implant was then placed into the socket by gentle tapping with a hammer and a mallet (Fig. 5). Primary stability was achieved as checked by palpation and percussion. The patient received post-operative analgesics (Parkemed 500 mg, Pfizer) on demand and antibiotic medication (Augmentin 625 mg, GlaxoSmithKline) for 4 days. During the healing period the patient received an acrylic Maryland bridge (Fig. 6).

At the control visit 10 days later a clinically healthy marginal area was present, and no postoperative pain or swelling was reported. There was no bleeding or wound infection. After 3 months a composite crown was cemented. At 15 months follow up the patient presented with a stable implant, unchanged peri-implant marginal bone level as monitored by radiographs and soft-tissue parameters, and no bleeding on probing (Figs. 7–14). Hence, as well as an excellent esthetic result there were no signs of periodontitis or bone or soft tissue recession.

Discussion

This case report describes the successful dental root replacement with an individualized Zirconia implant in a single patient. The exact technique has been described by our group in an earlier manuscript.^{9,10}

Rotationally symmetric titanium implants have stood the test of time for decades in delayed implantation with success rates of up to 98%. But conventional implants were originally constructed for insertion in healed jaw bones, and are primarily not really suited to be inserted into the irregular formed extraction socket. Immediate implantation is—against the suggestion of

some commercials and smaller studies—by no means a standard treatment. It does have a limited indication and requires experienced specialists.

The main reason for the limited indication of immediate single tooth replacement is primarily the lack of bone quantity in the extraction socket, which prohibits adequate bone drilling in the apical region to achieve primary stability requiring a healing period of a submerged implant without any functional load. Scientific literature reports on success rates of immediate implants are similar to delayed implants. However, one has to keep in mind that cases of immediate implantation described in the literature are between 2 to 5% of all implant cases, comprise highly selected patients with limited indications and can therefore not be compared to the standard treatment in the real world.

The natural extraction socket represents the ideal anatomy and starting point for a root formed implant. The anatomic bone situation is ideal for the absorption of the load of a root analogue implant.

On the other hand the fact that the rotationally symmetric implants does not fit at all, leads to a horizontal and vertical atrophy described also as remodeling. In many cases the atrophied bone especially in the presence of thin soft tissue does not appear natural with a grayish gingiva or even visible implant shoulders. These complications may occur within days after implantation or after years in the context of old age involution. A correction of this failure requires a number of invasive procedures with questionable outcome. Old age involution cannot be prevented, therefore it is advisable to use root coloured implants.

The wide array of different available implant forms clearly indicates that osseointegration does not primarily depend on the form of the implant. Aside from

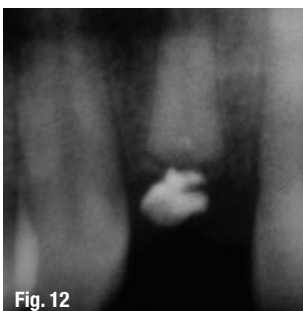


Fig. 12

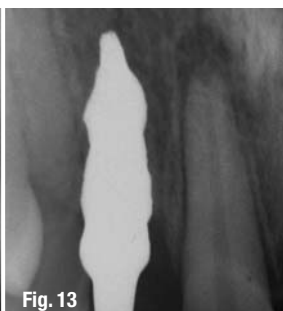

Fig. 13

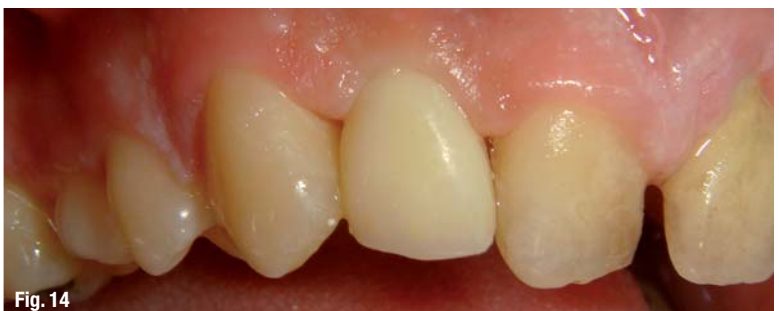

Fig. 14

BEGO is an official
co-partner of the German
Olympic teams for
Vancouver 2010
London 2012

GO FOR GOLD.



Bionic Engineering Design transfer of
optimal living nature solutions
to technical products

BEGO Semados®
Mini-Implant

BEGO Semados®
S-Implant

BEGO Semados®
RI-Implant

BIONIC ENGINEERING DESIGNED IMPLANTS

BEGO Semados® patented Implants embody:

- Indication-optimised contour design
- Function-optimised implant-abutment-connection
- High purity and ultra-homogenous-surface
- Polished rim for an inflammation-free gingiva-attachment
- 100 % German design – 100 % German manufacturing
- Value for money

Are You Interested?

info@bego-implantology.com

www.adwork.de

BEGO 
Partners in Progress

www.bego-implantology.com

the surface it is important to prepare the implant site in an atraumatic way and to achieve a perfect bone to implant contact.

There is absolutely no logical reason at all not to use the already existing intact tooth socket as implant site and to adapt the implant to the tooth socket instead of the vice versa approach including drilling, bone trauma, bone loss and additional bone augmentations.

All attempts in the long history of dental science to fix homologue, heterologue or allogeneic root analogue implants into a fresh extraction socket failed due to the conical root form, rejection and lack of preciseness and were therefore not established. With the implementation of the modern CAD/CAM technology it became easily possible to manufacture an exact copy of the dental root.

“Differentiated Osseointegration”

The fundamental advantage of this innovative implant system is not only the reconstruction of the anatomy of the individual tooth, but also the fact, that it is possible to consider the underlying bone quantity and quality. This way the surface of the implant can be modified accordingly. Macro-retentions (protrusions) are a conditio sine qua non for the safe fixation of a root-formed and therefore conical implant in the bone. Macro-retentions have to be strictly limited to spongy bone, since only spongy bone can absorb pressure without fracture at a remote site. Micro fractures cannot be avoided, but in contrast to fractures of cortical bone fractures in spongy bone remain limited with reduced damage and quick regeneration due to the excellent blood supply always present in spongy bone.

Another reason for the high regenerative potential of spongy bone lies in its extensive vascularization. Retentions in the area of the thin cortical bone leads irrevocably to fractures, sometimes at remote sites, with subsequent bone recession. In order to be on the safe side and avoid fracture of the thin cortical bone at any cost, the implant is reduced at the buccal and lingual face by approximately 0.1–0.2 mm. The principle of differentiated osseointegration therefore dictates the innovative implant design. In areas without macro retentions no fracture or impression induced resorption takes place and primary osseointegration occurs without delay. Only by consideration of these different healing modalities osseointegration can be accomplished in conical or root-analogue formed implants.

Advantages of the novel method

No bone drilling and drilling guides are necessary. Associated risks are avoided.

No bone drilling equals no operative trauma, no bone loss, no damage to neighboring structures including dental roots, mandible nerve, or maxillary sinus. The exact fit of the implant leads to an optimized

implant-bone contact surface and thus maximal primary stability with shorter healing periods, because there are no gaps between the implant and the bone. Furthermore additional surgical interventions like bone augmentation, guided bone or tissue regeneration are not required. The exclusive use of root colored Zirconia leads reproducibly and predictably to satisfying esthetic results. The single piece implant is exposed to a reduced functional load from the beginning, preventing bone and soft tissue recession. Absolutely no secondary prosthetic parts, no specific surgical instruments, drilling equipments and screw drivers are required. The single stage implant is put in place by use of a mallet and a hammer. Absolute no tool kit is necessary and no special knowledge about the confusing and highly company specific numerous secondary implant parts and there individual names is required. The crown stump can be adapted by means of grinding at any time by use of conventional dental equipment.

Disadvantages

At the present time patients with damaged periodontal ligament are excluded (careful extraction is mandatory)

- Currently only single stage implants are available.
- Position of misaligned tooth cannot be corrected.
- Method in its infancy, further studies are necessary.
- Dental implant is not yet on the market available.

This case, which is part of a larger ongoing clinical trial, demonstrates that immediate placement of significantly modified, root-analogue, non-submerged Zirconia implants yields excellent results superior to previously described custom made root-analogue titanium implants with a uniform surface.

The Literature list can be requested from the editorial office.

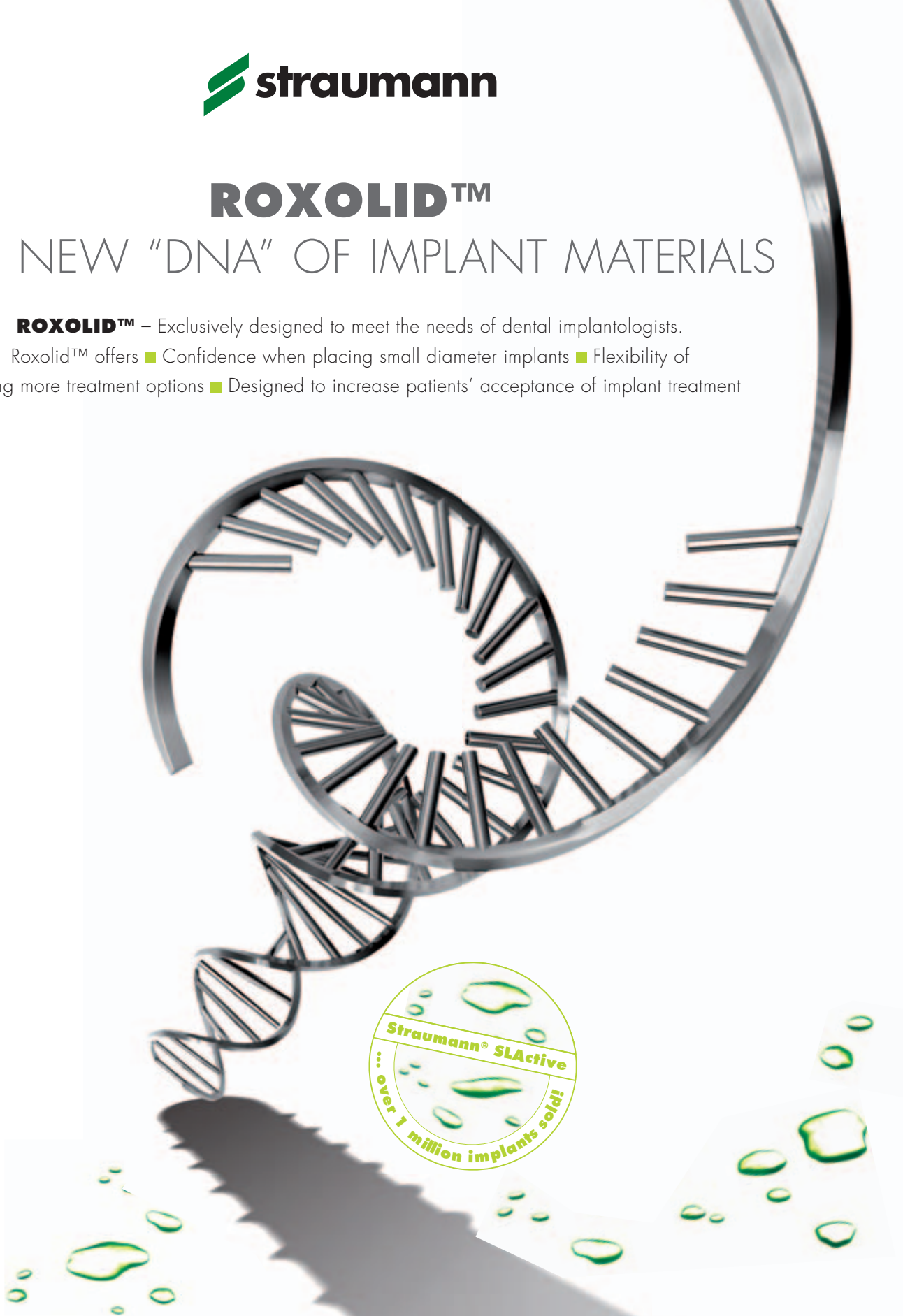_contact	implants
<p>Wolfgang Pirker, MD, DDS Maxillo-Facial Surgeon Schulerstraße 1–3/65 1010 Vienna, Austria Phone: +43-1/5 12-24 00 E-mail: info@face.at</p>	
<p>Alfred Kocher, MD Professor of Surgery Medical University of Vienna Währinger Gürtel 18–20 1090 Vienna, Austria Phone: +43-6 64/2 61 85 69 Fax: +43-1/5 12-2 25 28 E-mail: Alfred.Kocher@meduniwien.ac.at</p>	



ROXOLID™

THE NEW "DNA" OF IMPLANT MATERIALS

ROXOLID™ – Exclusively designed to meet the needs of dental implantologists.
Roxid™ offers ■ Confidence when placing small diameter implants ■ Flexibility of
having more treatment options ■ Designed to increase patients' acceptance of implant treatment



Please contact us at **+41 (0)61 965 11 11** More information on www.straumann.com

COMMITTED TO
SIMPLY DOING MORE
FOR DENTAL PROFESSIONALS

Safe and Effective Alternatives to Sinus Elevation in the Atrophic Posterior Maxilla

Part I—A Masters Thesis

author_ Adel A. Chidiac, Kuwait

_Maxillary sinus elevation and bone augmentation are acceptable techniques that may provide sufficient bone quantity and quality for implant support in the posterior atrophic maxilla (Wallace SS et al. 2003). Yet, given the morbidity risk plus cost and time consuming effects, these techniques are to be reconsidered. Simpler and safer protocols are therefore required for the posterior maxilla where bone resorption, deficient posterior alveolar ridge, and increased pneumatization of the sinus all result in a minimal hard tissue bed thus render implant placement difficult (Frank R et al. 2005).

_1. Introduction

The present thesis seeks: (1) to show that applying to specific alternative implantation techniques in the atrophic posterior maxilla is (a) safer than, and (b) as effective as, maxillary sinus elevation and bone augmentation techniques; and (2) to address simplified implantation protocols (Brånemark PI et al. 1995).

The examined alternative techniques are set out in four sections respectively: Short Implant, Tilted Implant, Tuberosity Implant and Disk Implant.

Section one highlights the insertion of short implants in less than 10 mm bone height under the sinus provided they are well anchored in the residual bone (Deporter D et al. 2000). Section two draws attention to the insertion of (longer) tilted implants in the remote available bone avoiding anatomical vital structures such as arteries, nerves and sinus antrum (Pierrisnard L et

N = 630 ITI	35 (6 mm)	141 (8 mm)	454 (10–16 mm)
Survival rates	94.3%	99%	97.4%

Table 1_ Study of short Straumann implants versus long implants.

Survival Time (mo) of 6 x 5.7 mm Implants vs. non 6 x 5.7 mm					
Time	N° of 6 x 5.7 mm		N° of non 6 x 5.7 mm		p
	Implants at risk	Survival (%)	Implants at risk	Survival (%)	
0	45	100	124	100	
12	NA				
24	31	92.2 ±4	87	95.2 ±2	78
36	16	92.2 ±4	83	94.1 ±2	NA
48	12	92.2 ±4	39	92.4 ±3	NA
60	7	92.2 ±4	29	92.4 ±3	NA
	3	92.2 ±4	19	92.4 ±3	NA

NA = not applicable; P= statistically difference

Table 2_ Study with short Bicon implants.

Premium
quality at friendly
prices

al. 2003). Section three emphasizes the insertion of implants in the maxillary tuberosity to benefit from available bone usually discarded. In each of the above sections studies are displayed with the aim of examining the results in terms of safety and effectiveness and thus verifying the comparability to the sinus elevation and bone grafting procedures. Section four throws light on Disk Implant that tries to adapt the shape of the implant to the shape of the bone rather than the way around (Ihde S. 2007). It is early, however, to verify the comparability of such attempt due to shortage of studies.

2. Aim

The reason of examining specific alternatives to sinus elevation and bone augmentation in the atrophic posterior maxilla is to verify whether they are performed with less time consumption, less cost, and less invasive surgeries yet still with comparable and satisfactory results. Examined alternatives in this thesis are tilted implant, short implant, tuberosity implant and disk implant. The aim is to report long term survival rates of these alternatives and to show that applying them is safer than, and as effective as, maxillary sinus elevation and bone augmentation.

3. Materials and Methods

3.1 Short Implants

- (a) A study involved 630 Straumann implants [35 (6 mm long), 141 (8 mm) and 454 (10–16 mm)] placed in 264 patients within 1994 and 2003. Two-year survival rates were comparable between short (6 mm), (8 mm), and longer (10–16 mm) implants in this population (Table 1; Arlin ML. 2006).
- (b) A 98.9% survival rate was the result of a retrospective evaluation of 273 consecutive posterior partially edentulous patients treated with 745 implants (7–9 mm) supporting 338 restorations over 1–5 years period (Misch CE et al. 2006).
- (c) 129 patients (68 women, 61 men) were treated over a 4-year-period with fixed prostheses supported by 265 different-sized implants: 154 (10 mm) standard and 111 (8 mm) short. Survival rates were 97.9% for 10 mm and 97.1% for 8 mm (Romeo et al. 2006).
- (d) For 293 patients treated with 532 short implants (2001–2002), the overall survival rates were 99.2% and 98.7% for the implant- and subject-based analysis, respectively (Anitua E et al. 2008).
- (e) A retrospective study involved 237 patients treated with 408 short Brånemark implants: 131 (7 mm) and 277 (8.5 mm) with final fixed prostheses delivered 4 to 6 months later. Cumulative survival rates after 5 years were 96.2% (126/7 mm) and 97.1% (269/8.5 mm) (Malo P et al. 2007).
- (f) A cohort study over 5 years involved a total of 62 implants: 28 (6 x 5.7 mm) test group and 34 (non 6 x 5.7 mm) control group non-short (8–14 mm). The survival rates over 5 years were 100% for the test group and 96.8% for the control group. No significant difference was found between the two groups regarding mean changes of radiographic bone levels (Caterina V et al. 2008).
- (g) A study on Bicon implants (6 x 5.7 mm) (Fig.1) reports a survival rate comparable to non-6 x 5.7 mm implants. 172 implants were used 34.3% of which were placed in the posterior maxilla. Survival rates were 92.2% ± 2% for 6 x 5.7 mm and 95.2% ± 2% for non-6 x 5.7 mm implants. The comparable survival rates estimates for 6 x 5.7 mm and non 6 x 5.7 mm suggest that 6 x 5.7 mm implants can bear a functional load after placement. The results are consistent with the findings of Vehement and colleagues in their study (Table 2) (Gentile MA et al. 2005).
- (h) A study compared wide diameter short implants (WSI) (6 mm in ø x 5.7 mm in length) (Fig. 2) to narrow and long implants (NLI) (3.5 mm x 11 mm) in various bone densities with finite element analysis (FEA) applied. The results showed that the WSI demonstrated better biomechanical force distribution



perfect aesthetics
internal hex
accelerated treatment

Xign[®]

Allfit[®]

The Allfit[®] Xign[®] implant system is designed for enossal dental implantations.

The Xign[®] implant system is suitable for single-step and dual-step implant protocols.

It is made of Grade 4 pure titanium.

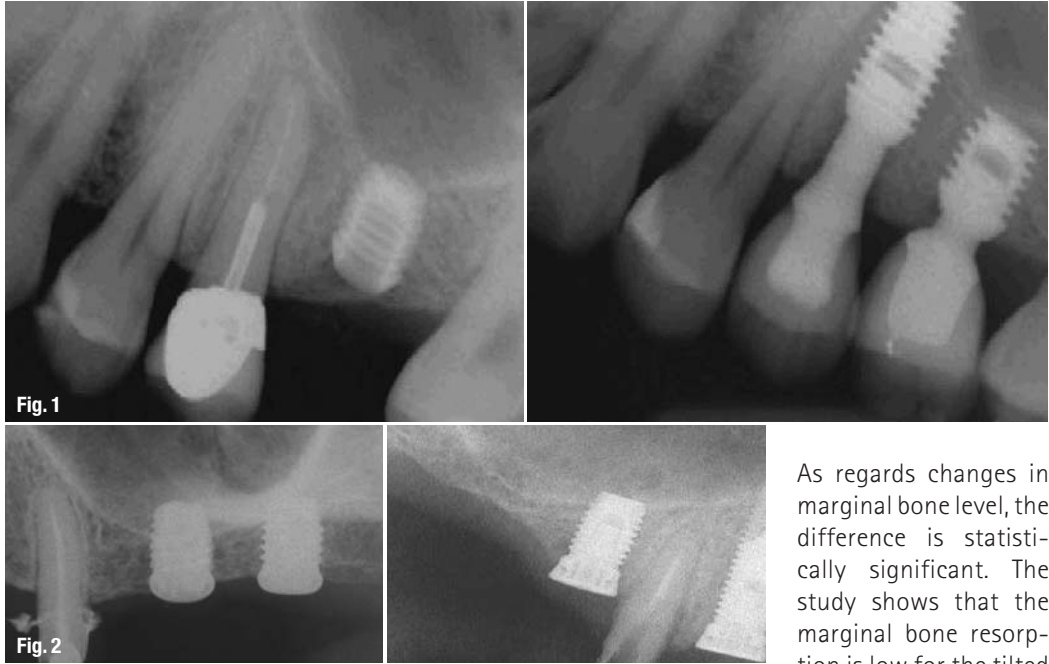Xign[®] implants are abraded with aluminium oxide and hot-etched and have an osmotically active nanocoating. All accessory parts are colour-coded.

IHDE DENTAL 
the implant.company

Dr. Ihde Dental GmbH
Erfurter Str. 19 · D-85386 Eching/Munich, Germany
Telephone: (49) 89 319 761-0 · Fax (49) 89 319 761-33
e-mail: info@ihde-dental.de · www.implant.com

Fig. 1_Short Bicon (6 x 5.7 mm) implants in the posterior maxilla.

Fig. 2_Radiographs of short wide implants (Nobel Biocare) (Courtesy of Prof. Barakat N. Lebanese Univ.).



As regards changes in marginal bone level, the difference is statistically significant. The study shows that the marginal bone resorption is low for the tilted implants as recorded

than the NLI when horizontal forces were exerted. WSI may be considered for implantation in anatomically compromised regions and of poor bone quality (Bozkaya D et al. 2004).

(i) Various studies performed by different authors show 95.8% mean survival rates as illustrated in (Table 3) (Gentile et al. 2005).

below in (Table 5) (Calandriello R et al. 2005).

The reason behind the lower bone resorption for the tilted implants may be related to the position of the implant neck relative to the bone crest. Mesially, the neck is positioned suprcrestally, whereas distally it is positioned subcrestally, thus resulting in a favorable tissue seal (Hermann JS et al. 2000).

3.2 Tilted Implants

(a) Eighteen patients (mean age 64) were treated with 60 implants between January 2001 and December 2003, and followed up within a range of one to four years. Survival rates were 97.0% for axial implants (1 failure out of 33) and 96.3% for tilted implants (1 failure out of 27). The cumulative implant survival rates were 96.7%. The study shows no statistical differences in primary stability between tilted and axial implants (Table 4) (Roos J et al. 1997).

(b) A further study involved 25 patients rehabilitated with 29 partial fixed prosthesis supported by 101 Brånemark Implants: 59 installed in axial direction and 42 installed in tilted direction. Patients were followed up within an average of 37 months. Success rates were 91.3% for axial implants and 95.2% for tilted implants. The cumulative success rate was 93.1% after 5 years. The study shows no statistical difference in pri-

Table 3_Various studies about short implants.

Author	N of yrs.	Implant brand	Length of implants	Survival rate
Bruggenkate 1998	6 yrs.	Straumann	6 mm	94%
Friberg et al. 2000	5 yrs.	Brånemark	short	95.5%
Davarpanah et al. 2001	3 yrs.	Osseotite 3i	short	98.45%
Fugazzotto 2008	7 yrs.		7 to 9 mm	95.1%

mary stability between tilted and axial implants (Table 6; Carlos A et al. 2001).

Tilted implants show bone loss of 0.14 mm during the first year of loading with minimal changes observed in the marginal bone height. During the first 60 months of loading, the mean bone loss was 1.21mm for tilted implants and 0.92mm for axial implants. Measurements of periosteal variations were not affected by the degree of inclination in respect to the remaining bone. The study shows no significant differences between distal and mesial marginal bone level of tilted and axial implants (Tables 7, 8) (Carlos A et al. 2001).

(c) Another study included 19 patients (6 men and 13 women) with severely resorbed edentulous maxillae (CL IV, CLV) who were treated with tilted implants and fixed dental prostheses 8–12 years previously. In this study, posterior implants were tilted antero-posteriorly more than 30 degrees. The study shows that one man lost one implant whereas one woman lost two implants. No gender difference in the success rate was observed: 97.05% for men and 97.10% for women (Annika R et al. 2007).

The study also shows that the overall success rate of the implants after 8 to 12 years was 97%. Indeed, radiographic examination after this

period revealed bone resorption in 10% of the remaining 100 implants. The mean bone loss for 5 patients was 1.2 mm compared to the immediate postoperative radiographic findings, whereas no bone loss was observed for the other 14 patients according to the criteria of Albrektsson et al. (1mm during the first year after loading and 0.2 mm each thereafter (Albrektsson T et al. 1986).

3.3 Tuberosity implants

Several studies were performed to examine the safety and effectiveness of implantation in the maxillary tuberosity (Table 9)

Implant	Mean value, Ncm	SD, Ncm
Axial (n = 32)	48.1	± 28.3
Tilted (n = 26)	41.9	± 27.5

Table 4 Insertion torque of axial and tilted implants of survival implants.

Implant	6 months	1 year
Axial	0.63 ± 0.86 mm	0.82 ± 0.86 mm
Tilted	0.54 ± 0.74 mm	0.34 ± 0.76 mm

Table 5 Changes in the marginal bone level.

Follow up Time (yr)	Number of Implants				Success Rate	
	Beginning of Period	Drop out	Failed	Surviving	During period (%)	Cumulative (%)
Tilted at placement	42	1	0	0	100	100
0–1	41	0	0	2	95.2	95.2
1–2	27	2	0	0	100	95.2
2–3	25	1	0	0	100	95.2
3–4	17	2	0	0	100	95.2
4–5	13	2	0	0	100	95.2
5–6	12	2	0	0	100	95.2
6–7	9	1	0	0	100	95.2
Axial at placement	59	2	2	1	95.0	95.0
0–1	54	0	0	2	96.3	91.3
1–2	37	5	0	0	100	91.3
2–3	31	3	0	0	100	91.3
3–4	19	3	0	0	100	91.3
4–5	15	3	0	0	100	91.3
5–6	13	3	0	0	100	91.3
6–7	8	1	0	0	100	91.3

Table 6 Implant success rate for tilted and axial implants.

- (a) 72 Brånemark implants were inserted with an average follow up of 21.4 months; the results showed 93 % success rate (Bahat O. 1992).
- (b) 65 implants were inserted with a follow up of 4 years; the results showed 95 % success.
- (c) 42 implants inserted in the posterior maxilla 29 of which in the tuberosity were followed up annually; only 1 of the 42 implants was lost at the second stage surgery (Venturelli A. 1996).

3.4 Disk Implants

Over a 48 months period, 627 laterally inserted disk implants were placed in 72 consecutive patients with completely edentulous maxillae using an immediate loading protocol. The postrestorative follow-up of these patients ranged from 6 to 48 months. 98% of the implants were radiologically and clinically osseointegrated (Scortecci G. 1999).

	0-1 years	1-2 years	2-3 years	3-4 years	4-5 years	Total
Tilted n						
MBL (mm)	40	25	24	17	11	
Mesial (SD)	0.51 (0.39)	0.31 (0.35)	0.21 (0.37)	0.09 (0.17)	0.07 (0.17)	1.19
Distal (SD)	0.64 (0.39)	0.26 (0.36)	0.17 (0.26)	0.06 (0.16)	0.09 (0.17)	1.22
Mean (SD)	0.57 (0.50)	0.29 (0.32)	0.19 (0.28)	0.08 (0.11)	0.08 (0.12)	1.21
Axial n						
MBL (mm)	53	32	28	16	12	
Mesial (SD)	0.43 (0.50)	0.20 (0.20)	0.10 (0.13)	0.06 (0.10)	0.06 (0.10)	0.85
Distal (SD)	0.43 (0.44)	0.22 (0.28)	0.14 (0.13)	0.06 (0.08)	0.11 (0.10)	0.96
Mean (SD)	0.43 (0.45)	0.23 (0.28)	0.12 (0.10)	0.06 (0.06)	0.08 (0.09)	0.92
Manova test	p > .40	p > .14	p > .14	p > .55	p > .86	

Table 7 Marginal bone loss of tilted and axial implants during follow-up.

Check-up	Tilted Implants	Axial Implants
At placement	-2.62 (-2.97)	-3.57 (-1.88)
First year	-3.54 (-1.47)	-4.05 (-1.54)
Second year	-4.25 (-1.15)	-4.37 (-1.10)
Third year	-4.38 (-1.10)	-4.36 (-1.19)
Fourth year	-4.76 (-1.20)	-5.10 (-0.74)
Fifth year	-4.73 (-1.27)	-5.00 (-0.85)

Table 8 Variations of mean Periotest (PTV) values of tilted and axial implants depending on time.

Bahat O 1992	72 impl.	21.4 mo	93%
Khayat P et al	65 impl.	48 mo	95%
Venturelli A 1996	29 impl.	12 mo	99.9%

Table 9 Safety and effectiveness of implantation in the maxillary tuberosity.

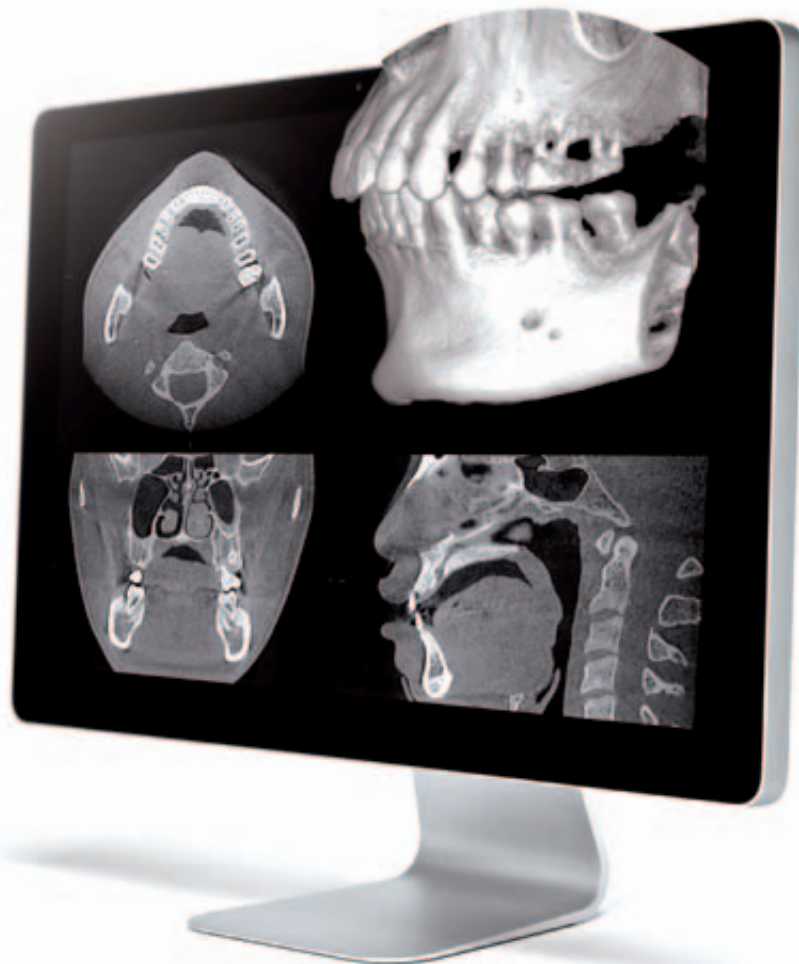For the support I thank:

- Prof Nabil Barakat , Lebanese University, Beirut, Lebanon
- Dr Mazen Tamimi, Private Practice, Amman, Jordan
- Dr Rainer Valentin, Private practice, Cologne, Germany
- Dr Rolf and Martina Vollmer, Private practices, Wissen, Germany

The publication will be continued with Part II in the next magazine.

_contact	implants
Dr Adel Chidiac International Clinic P.O. Box 6649 Salmiya 22077 Kuwait E-Mail: adelchidiac10@hotmail.com	

Diagnostic
Information
Treatment
Care
Healing



Spectrum unites sharpness

There is hardly another dental equipment manufacturer who demonstrates such a passion for perfection as the Japanese, family-owned company Morita. Our work reflects the highest standards in terms of quality, reliability, precision and customer satisfaction.

One example: With its total of nine image formats the 3D Accuitomo sets the pace in 3D volume tomography. Even when the size is 170 × 120 mm the images do not lose any of their sharpness. This quality is achieved by J. Morita solely by using flat panel detector (FDP) technology. This is the only process which creates a balanced distribution of contrasts. The world over there is no other dental equipment manufacturer with a greater store of know-how and a wider range of products in the field of volume tomography than J. Morita.

Feel free to discuss 3D volume tomography with us – call us directly:
+49 (60 74) 8 36-0

www.jmoritaeurope.com



MORITA

Thinking ahead. Focused on life.

Peri-implant Keratinized Mucosa—Necessity, Surgical Technique and Healing

author_ Felix Hänssler¹, Norbert M Salenbauch²

¹New York University, Department of Periodontology and Implant Dentistry, Department of Biomaterials and Biomimetics, USA;

²Private practice, Dres. Salenbauch & Walther, Göppingen, Germany

Necessity

Today, the need for peri-implant keratinized tissue is still questionable. The issue could be answered by considering the periodontal scientific knowledge. Long term studies made obvious that a minimum of keratinized tissue around teeth is not required to maintain periodontal health, clinically.¹⁻⁴

However, the periimplant mucosa is different to the supraalveolar tissue around teeth. The amount of collagen is higher and less fibroblasts are present⁵, and the tissue structure is more similar to scar tissue.⁵ The organisation of the collagen fibres is different, too. Periimplant fibres don't insert in smooth implant/abutment surfaces, instead they run parallel.⁵ Blood supply, i.e. vessels are more pronounced around teeth and therefore the peri-implant immune defense might be compromised.⁶ Non-keratinized mucosa has

a different structure with less collagen fibres and dominating elastic fibres, which is the reason for its mobility.^{7,8}

A main difference to teeth is the fact, that implant placement itself is a mucogingival surgical procedure, i.e. the character of the surrounding tissues can be created during implant placement or second stage surgery without an additional surgical intervention.

In an early histologic study Schroeder showed that implants placed in fixed mucosa result in healthy soft tissue conditions, 6–20 months after implantation of hollow-cylinder implants in monkeys.⁹ However, keratinized mucosa as well as non-keratinized mucosa is capable to defense reaction against bacterial attack.¹⁰ Wennström analysed the influence of the soft tissue character to the condition of the periimplant tissues. There was no difference in plaque accumulation and

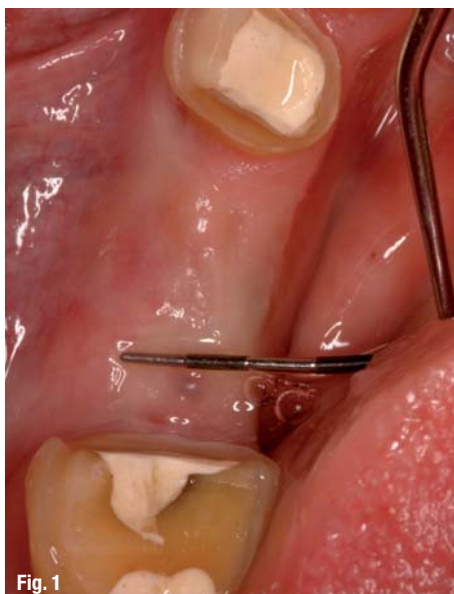

Fig. 1

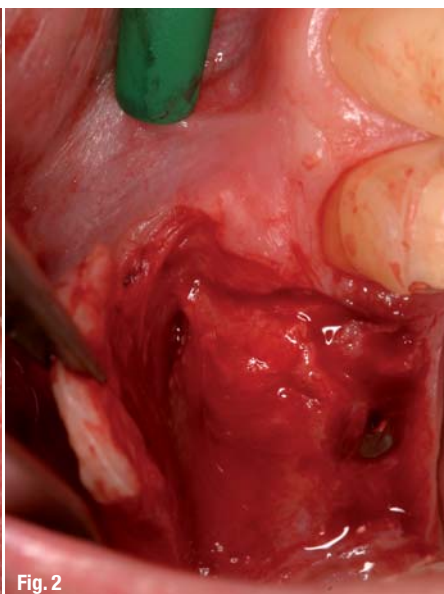


Fig. 2

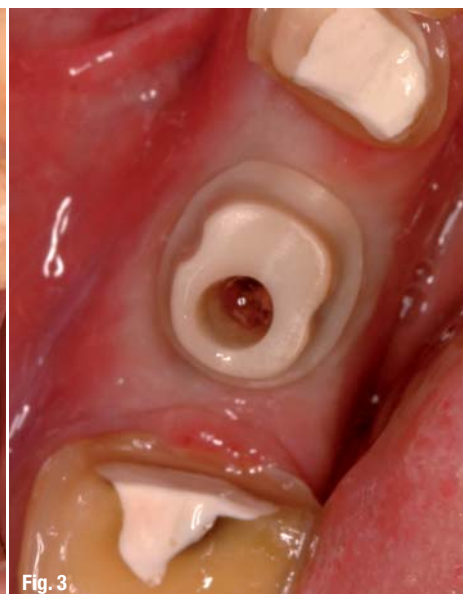


Fig. 3

peri-implant health between a keratinized mucosa width of < 2mm and > 2mm.¹¹ Several other authors report from healthy situations without keratinized mucosa around implants, too.^{12,13}

However, Chung and coworkers showed statistical significant differences in plaque accumulation and gingival inflammation when comparing implants with < 2mm keratinized mucosa and implants surrounded with > 2mm keratinized mucosa. The annual bone loss was more pronounced in the group with less than 2mm keratinized mucosa.¹⁴ A correlation between keratinized mucosa and implant loss was established, too. In a study of 443 implants, 2.9% implant loss (97.1% success rate) occurred in the group of implants surrounded with keratinized mucosa, while 29.5% implant loss (70.5% success rate) occurred in the group of implants without keratinized mucosa.¹⁵

Studies are confirming significant more bone loss and inflammation¹⁶ as well as a higher susceptibility to inflammation without keratinized mucosa.¹⁷⁻²¹ This position is supported by several authors.^{11, 20, 22-31}

Summarized, there is a higher risk for plaque accumulation, inflammation, and periimplantitis without keratinized tissue. If a perfect oral hygiene is established, non-keratinized mucosa might be maintained healthy.²⁵ This explains the good results in studies mentioned above, concluding periimplant stability

without keratinized tissue. However, a long lasting ideal oral hygiene can not be guaranteed for every patient and maybe compromised due to general diseases later. Therefore it is recommended to create keratinized tissue of at least 2 mm. Beside the functional aspect, keratinized tissue is esthetically more appealing.³²

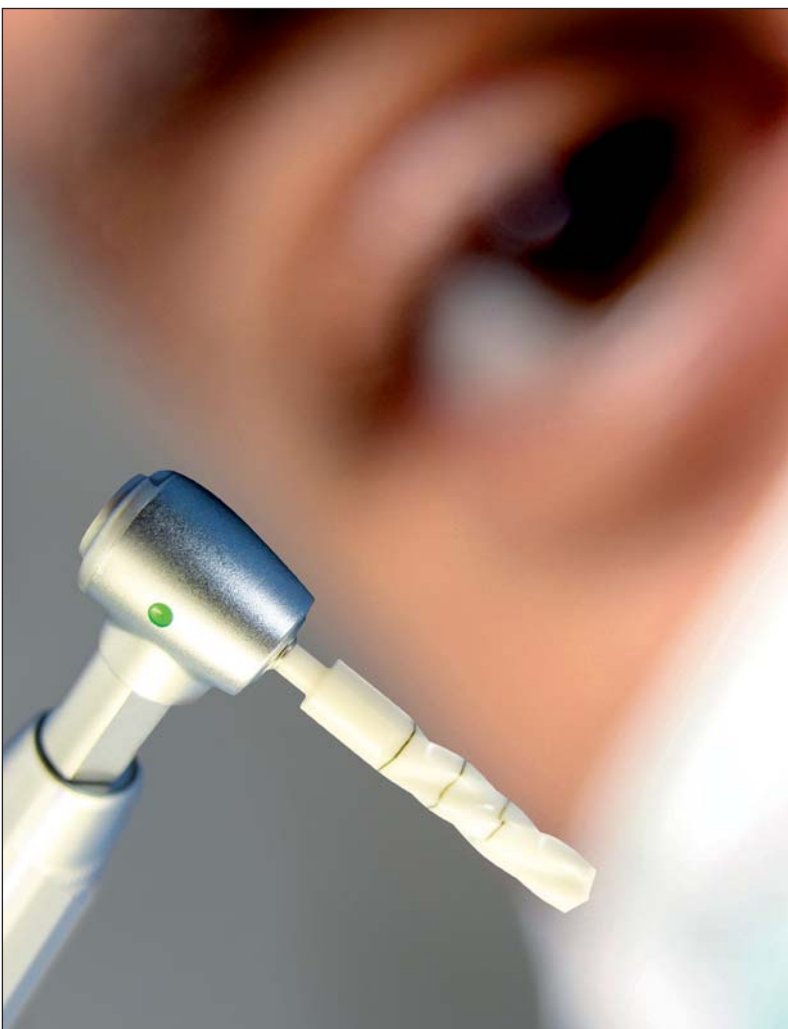Surgical techniques

Basically, two different approaches are used to create keratinized mucosa around implants.³³⁻³⁵ Depending on the amount of missing keratinized tissue, apically repositioned flaps (Figs. 1-3) or free gingival grafts (Figs. 4-6) are the procedures of choice. Considering both techniques, free gingival grafts are more predictable. However, healing of the donor site is often uncomfortable for the patient. Besides, color match of tissue taken from the palate and the recipient bed is critical. A combination of an apical repositioned flap with a free gingival graft is also shown.³⁴

Healing

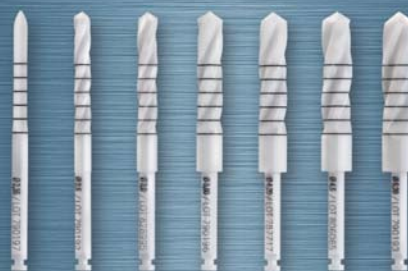The healing of free gingival grafts was discovered in histologic and clinical observations. After fixation of the graft on the recipient bed it is solely dependent upon diffusion from its host bed, this occurs most efficiently through the fibrin clot.³⁶ At the first day, cap-

AD

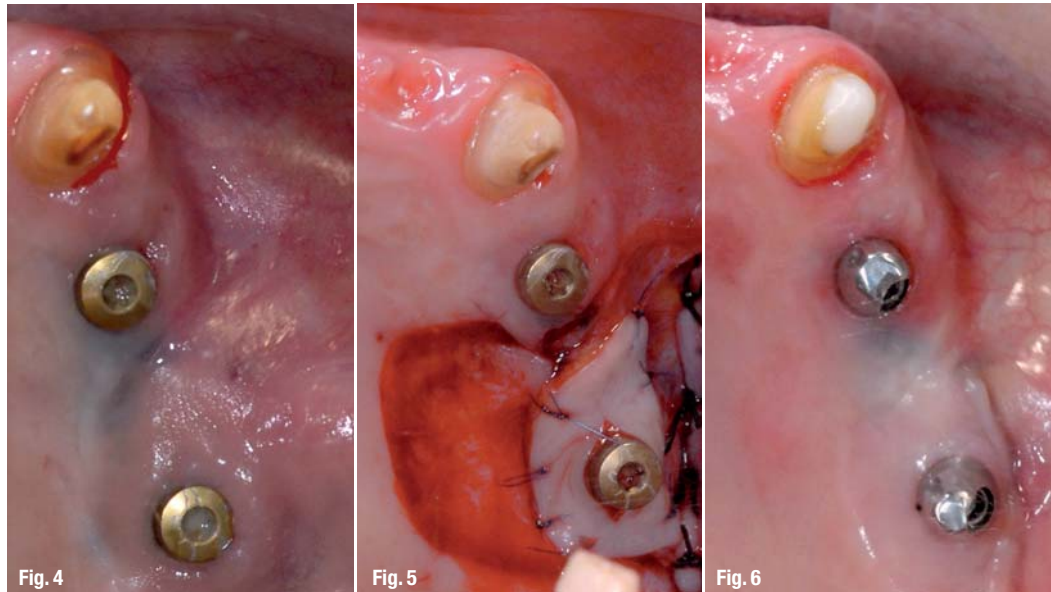


maxon dental

Ceramic Drills for Implantology.



When patients insist on metal-free treatment, maxon's ceramic drills can be applied. The maxon ceramic drill is based on three-lip drill geometry, which means that the implantologist can guide the drill securely and quietly. The ZrO₂ ceramic cutting edges are exceptionally sharp and undergo almost no wear and tear. www.maxondental.com



illary proliferation begins. Between second and third day, some capillaries have extended into the graft.³⁶ An adequate blood supply appears to be present about the eighth day.³⁷ A connective tissue union between the graft and its bed begins around the fourth day and is complete by the tenth day.³⁸ If the graft is placed on a strong bleeding recipient bed or no adequate application of pressure is allowed after surgery, a hematoma will form. This will separate the graft from its bed and the risk for necrosis will increase, since neither rapid capillary penetration nor nutriment diffusion can occur through the hematoma.³⁹ Therefore, pressure against the graft for five minutes is recommended after surgery.³⁸ When transplanted, a diffusion system will maintain the graft for approximately three days until circulation is restored.³⁶ The thinner graft can be easily maintained by diffusion and is easier to vascularize. The thicker graft shows more desquamation, its vascularization is delayed and necrosis occurs. A graft properly immobilized on the nonbleeding, rigid recipient bed will undergo rapid vascularization.³⁸ In contrast, if the graft is mobile, the ingrowing capillaries will be torn. This tearing results in bleeding and hematoma formation.⁴⁰ To support adaptation and immobilization a crossing suture over the entire transplant must be placed. In suturing, the graft is stretched to conform to the recipient bed. This tension counteracts primary contraction and aids vascularization by reopening the grafts collapsed vessels.³⁷ It appears that ten weeks is a sufficient time for complete histological healing of a graft of intermediate thickness (0.75 mm), but 16 weeks may not be long enough for complete healing of a thick graft (1.75 mm).⁴¹ The shrinkage of the free gingival graft is about 24%.⁴² Rateitschak et al observed patients over 4 years, finding that graft shrinkage occurred during the first 30 days and then remained constant.⁴³

Healing of the donor site is characterized by epithelialisation and regeneration of the connective tissue. Farnoush wrote that the healing process proceeds by secondary intention and that reepithelialisation takes about 2–4 weeks, depending on the wound size and surgical technique.⁴⁴ The application of hemostatic agents can accelerate wound healing. The placement of oxidized regenerated cellulose over the wound exhibited complete healing after 21 days.⁴² Healing and regeneration of the underlying connective tissue will take at least 9 weeks.^{45,46}

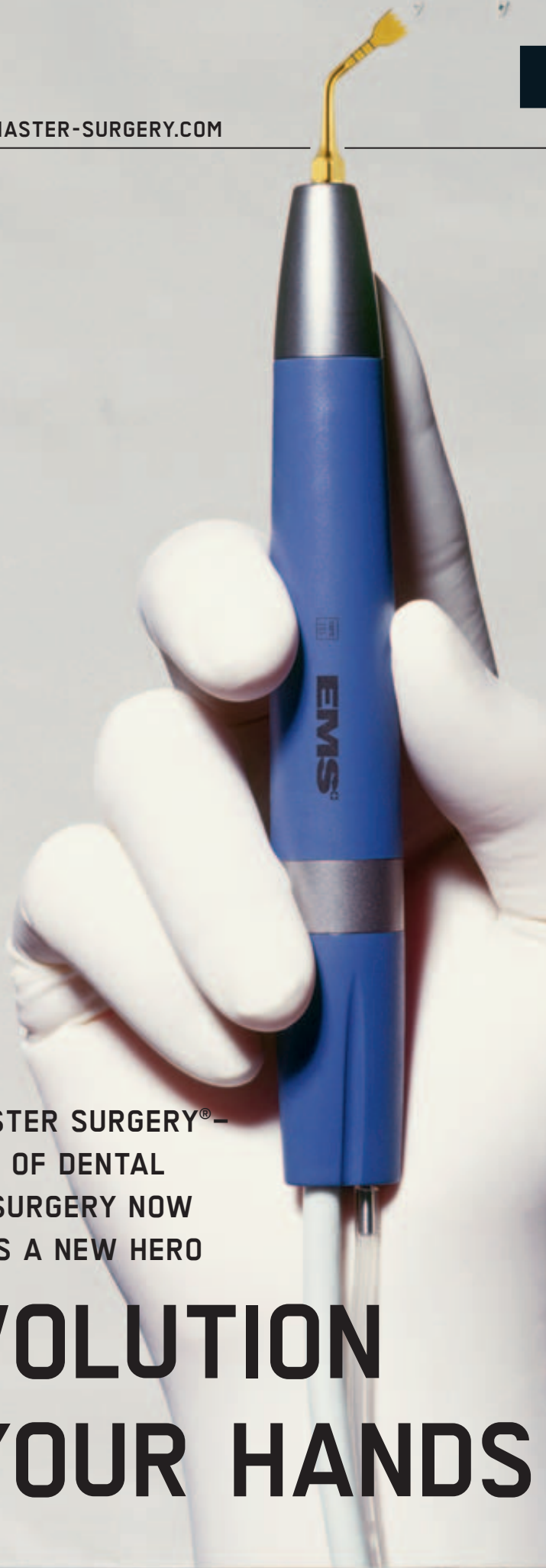Conclusion

Due to a possible decrease in oral hygiene and the fact, that implant placement itself includes peri-implant mucogingival surgery keratinized tissue must be created around implants. The appropriate surgical technique depends on the residual amount of keratinized mucosa. Small-sized dimensions can be generated by an apical repositioned flap while a large dimension will be established with a free gingival graft. A complete healing of a free gingival graft can be expected after approximately 12 weeks.

_contact	implants
<p>Felix Häussler, Dr med dent Department of Periodontology and Implant Dentistry Department of Biomaterials and Biomimetics New York University College of Dentistry 345 East 24th Street New York, NY 10010, USA E-Mail: haenssler@nyu.edu</p>	

WWW.PIEZON-MASTER-SURGERY.COM

EMS 
ELECTRO MEDICAL SYSTEMS



PIEZON MASTER SURGERY® –
THE WORLD OF DENTAL
AND ORAL SURGERY NOW
CELEBRATES A NEW HERO

**REVOLUTION
IN YOUR HANDS**

INNOVATIVE technology, easy to operate, multiple applications, exclusive instruments, great results, extensive experience – the Original Piezon Method now also available for periodontal surgery, implantology, oral and maxillary surgery.

> Piezon Master Surgery



UNIQUE in the realm of surgery – 3-touch panel for intuitive user guidance.

EXCLUSIVE design tailored to the new piezoceramic surgery handpiece – the new Swiss Instruments Surgery.

REVOLUTIONARY in the smallest details – once you've experienced Piezon Master Surgery, you'll ask yourself: Why didn't we have this before?



For more information,
please visit www.piezon-master-surgery.com

Dental Implants

Aesthetic Complications

author_ Abdelsalam Elaskary, Egypt

_Treatment complications can range from fracture of the prosthetic components till reaching the failed condition, however, the complications that are of concern in this chapter is the possible complications in the aesthetic zone, that involves the possibility of failure due to aesthetic reasons. An implant with successful osseointegration can still fail if the final prosthesis does not provide the optimal required esthetics. Failure to achieve proper esthetics could be due to several reasons, some of which are untreatable. The esthetic outcome of an implant-supported restoration is affected by four main factors: (1) implant placement, (2) soft tissue management, (3) bone grafting considerations, and (4) prosthetic considerations. The possible treatment complications in the aesthetic zone can be divided according to the reason of the occurrence:

_Technical reasons

This is concerned with the etiological reasons of implant failures or complications, which are failure due to host factors, surgical placement, implant selection, and/or restorative problems. It usually occurs as a result of implant in a wrong place (Fig. 1) or implant misplacement (e.g., placement of the implant in an infected socket, pathological lesion, or immature bone previously augmented or placement of a con-

taminated implant in the osteotomy), infection or soft tissue complications, lack of biocompatibility, excessive surgical trauma, and/or lack of primary stabilization of the implant, or after immediate loading or at the time of the second stage surgery. This could be due to excessive torque during abutment connection when inserted into grafted or D4 bone. It probably happens because of an insufficient bone contact surface area with the implant and possibly because of poor surface treatment of the fixture.

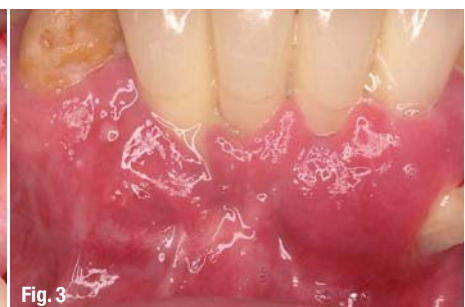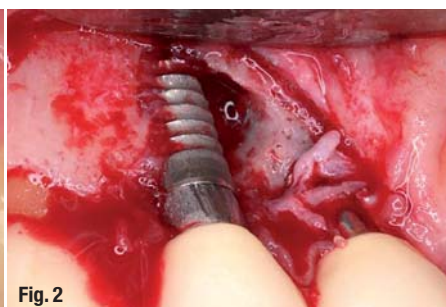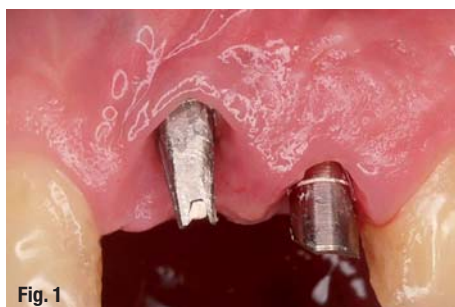_Biological reasons

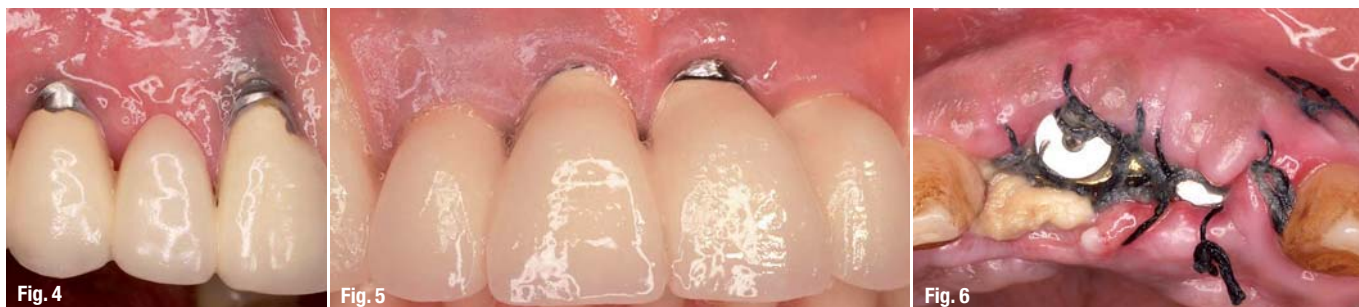That involves; the bacterial invasion of the peri-implant tissues that results in soft tissue inflammatory changes and rapid bone loss. This condition was termed peri-implantitis and was defined by Meffert¹, (Meffert RM 1992) as the progressive loss of peri-implant bone as well as soft tissue inflammatory changes. This definition implies that both bone loss and soft tissue inflammation occur together as a result of bacterial invasion. On the other, Tonetti and Schmid² (Tonetti MS, Schmid 1994), divided the host's reaction to bacterial invasion into two groups: peri-implant mucositis, which implies that the inflammatory changes are localized only to the surrounding soft tissue, and peri-implantitis (Fig. 2) in which the reaction affects the deeper soft tissues and

Fig. 1 Implant miss placement shows soft tissue discrepancy.

Fig. 2 Sever peri-implant bone loss due to retrograde peri-implantitis.

Fig. 3 Exfoliation of bone graft material from the soft tissue indicating the failure of the bone graft and the need for re-grafting.





surrounding bone. The latter explanation may be based on the concept that the tissues surrounding a functioning oral implant can be divided into two distinct anatomical compartments, both with well-defined functions. These are the soft tissues, which can seal the implant from aggression of exogenous bacteria, and bone, which plays the supporting role for the implant³ (Esposito M, Hirsch J-M, Lekholm U, et al.1998).

Personal factors

As the overall clinical success dental implant rely on cooperation among a dental team that involves the patient as well. Each member has his or her own role for certain stages of treatment. The poor clinical skills of the clinician might lead to the failure to obtain a reasonable aesthetic result; also the well-trained laboratory technician contributes to the long-term success of dental implant therapy both esthetically and functionally.

Tissue deficiency

Soft or hard tissue loss can be a detrimental factor for the success of dental implants (Fig. 3), As Krekeler et al.⁴ (Krekeler G, Schilli W, Diemer J. 1985) suggested a relationship between implant failure and the absence of an adequate band of keratinized mucosa surrounding the abutment. This suggested relationship was based on the ability of the keratinized mucosa to withstand bacterial insult and aggression. Also, supporting this concept, Tonetti and Schmid² (Tonetti MS, Schmid 1994), stated that the late failures that occur as a result of peri-implantitis (infectious etiology) occur because of defective function of the soft tissues. Therefore, the marginal peri-abutment tissues should constitute a functional barrier between the oral environment and the host bone by sealing off the osseous fixture site from noxious agents and thermal and mechanical trauma.⁴ Gingival loss leads to continuous recession around the implant with subsequent bone loss. This will lead to a soft tissue type of failure. On the contrary, Strub et al.⁵ (Strub J, Gaberthuel T, Grunder U 1991) stated that the keratinized mucosa or dental plaque does not seem to be related to implant failure but that its presence might facilitate the patient's hygienic procedures. (Fig. 4) However, in the aesthetic zone, the relationship between the available keratinized mu-

cosa and the overall success of the implant supported prosthesis is of great values. The most common soft tissue complication would be the soft tissue marginal recession (Fig. 5) or discrepancy, which might be influenced by many factors such as:

- 1) biocompatibility of the trans-mucosal components, as the adhesion of the junctional epithelium and connective tissue is possible only on highly biocompatible materials.
- 2) Repeated removal and placement of the abutment leads to cell tear and biological width disruption, because the repeated unscrewing the abutment mechanically disrupts the cellular attachment mechanism and might lead to apical migration of the cells.
- 3) Loosening of the Implant interface connection forms a gap that harbors bacteria that can invade the surrounding tissues, the further long term screw losing activates bone loss and apical tissue migration.
- 4) A muscle pull on the implant site might lead to a continuous steady gingival recession as it happens around natural teeth.
- 5) The location of the implant-abutment connection in relation to the gingival level, as it is suggested that when the location of the implant-abutment connection above the gingival level, the gingival recession and its inflammatory gingival response is highly reduced.
- 6) Shear loading beyond reasonable limits can destroy the marginal bone crest leading to non-interlocking implant surfaces which subsequently leads to gingival recession.
- 7) The location of the smooth collar of the implant in relation to the bone level might induce bone resorption due to the less bone affinity to smooth surfaces which might lead to the possible migration of the attachment apparatus.
- 8) The continuous pressure induced from a removable prosthesis might lead to gingival recession.
- 9) Premature delivery of the final prosthesis (min two months) has proven to lead to post insertion gingival recession as the soft tissue should reach a stable remodeling status prior to final crown insertion.
- 10) The amount of osseous contouring in the second stage surgery might stimulate further bone resorption that initiates gingival recession.
- 11) The geometry of the implant diameter in relation to the size of the abutment used that might influence bone levels via platform switching.

Fig. 4 Keratinized tissue deficiency.

Fig. 5 Post loading soft tissue recession.

Fig. 6 Wound sloughing due to smoking.

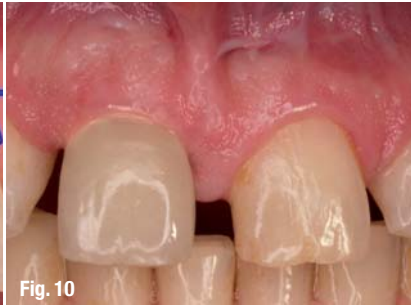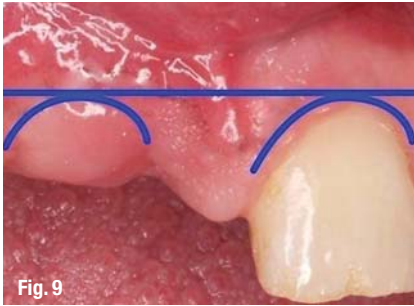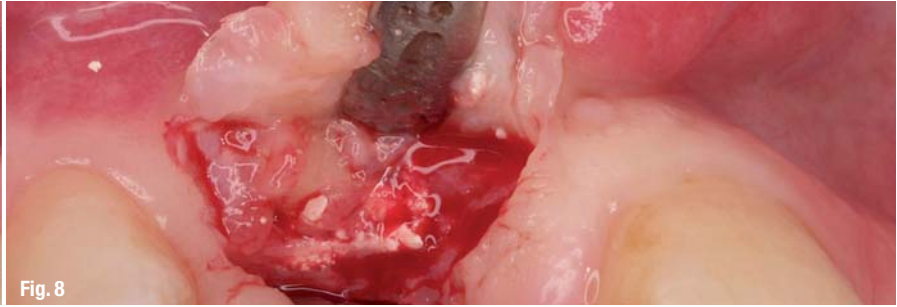


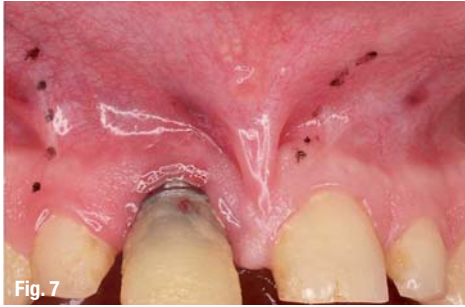Fig. 7 Failed implant in the aesthetic zone due to improper biomechanical reasons.

Fig. 8 The case post implant removal and 4 months post grafting.

Fig. 9 The soft tissue status post grafting, note the blue line that indicates the excess soft tissue and bone regenerated.

Fig. 10 The case restored.

12) The use of alcohol disinfectants for the healing abutments might lead to cell death or the peri-implant tissues and to further recession. On the other hand the loss of the Supporting alveolar bone leads to serious treatment complications, Adell et al.⁶ (Adell R, Lekholm U, Rockler B, 1981) stated that marginal bone height depends on both proper marginal stress distribution and adequate function of the marginal soft tissue.

Systemic factors

Systemic factors that might lead or potentate treatment complications are plenty:

- 1) Osteoporosis is a common oral bone disease that influences implant placement, the problem arises from the unbalance between the rate bone resorption/formation process with emphasis on resorption, the cortical plates become thinner, the trabecular bone pattern more discrete & advanced demineralization occurs, it affects females twice than males, especially after the menopausal period in females. It does not constitute an absolute contra indication for dental implants, but it influences the treatment path.
- 2) Smoking is increasingly cited in the literature as a risk factor in soft tissue healing⁷ (Wakley GK, Baylink DJ, 1988), periodontal health^{8,9}, (Bergström J and Preber H. 1994) (Grossi SG, Zambon J, Mcchtei EE, 1997) and implant therapy. Speaking about smoking, several controversial points of views are being made to relate smoking to dental implant failure; the modern science has proven that there is a potential increased risk of smoking on the long and short term success of dental implants (Persson L, Bergström J, Gustafsson A, 2003) (Fig. 6).¹⁰
- 3) Patient's psychological ability to commit to long term Treatment and maintenance programs

must be an integral part of the examination and selection process. During the consultation, the clinician should determine whether the patient is psychologically capable of making the necessary long-term commitment. For example, phobic or highly anxious individuals may have low pain thresholds and refuse to present for treatment follow-ups. On the other hand, patients whose dental complaints stem from somatization disorders will probably not be satisfied with the results of implant therapy (Melamed BG 1989).¹¹

4) Diabetes mellitus does not directly affect the failure of dental implants. A Consensus expressed that the placement of implants in patients with metabolically controlled diabetes mellitus does not result in a greater risk of failure than in the general population;¹² but a group study stated that diabetic patients experience more infection in clean wounds than non-diabetics (Goodson WH, Hunt TK 1979).¹³ The liability of infection is probably due to thinning and fragility of the blood vessels so as to alter blood supply. In conclusion, current surgical opinion is that patients with well-controlled diabetes (below 250 mg/dl) probably do not encounter inordinate operative risks, while patients with poorly controlled diabetes or high risk patients (more than 250 mg/dl) may frequently experience wound failure (Smith RA, Berger R, Dodson TB. 1992).¹⁴ Therefore, poorly controlled diabetic patients present more difficult management problems and postponement of the surgery is recommended until better control is achieved.

5) Alcohol consumption is detrimental to the success of the dental implantology procedures (Sampson HW, Perks N, Champney TH, 1996) (Spencer H, Rubio E, Indreika M, Seitam A, 1986)^{15,16}, because it contributes negatively to osteoporosis, osteopenia. This statement is supported by the studies that suggested that alcohol intake leads to a negative bone balance effect and progressive bone loss (Lindholm J, Steinliche T, Rasmussen E, et al. 1991)¹⁷ this in turn may lead to insufficient bone volume for application of dental implants. A study (Bombonato K, Brentegani G, Thomazini A, et al. 2004)¹⁸ that evaluated the possible effect of alcoholic beverage administra-

tion on reparative bone formation around hydroxyapatite tricalcium phosphate implants inside the alveolar socket in rats confirmed that a significant delay in reparative bone formation was detected in the alveolus of alcoholic rats by a histometric differential point counting method.

Biomechanical & loading factors

Biomechanical, over loading and parafunctional habits are all critical factors that matter to the long term success of the implant supported restorations in the aesthetic zone is the improper application of the cantilevers within any prosthetic design (English CE, 1993) (El Askary AS, Meffert RM, Griffin, 1999) (El Askary AS, Meffert RM, Griffin, 1999).¹⁹⁻²¹ For partially edentulous patients, it places offset loads to the implant abutments and results in greater tensile and shear forces on cement or screw fixation especially when the number of implant used for support is diminished. Many problems can be associated with cantilevers supported by dental implants. Such problems include fracture of the prosthesis (Rangert B, Gunne J, Sullivan DY, 1991)²², de-integration (Lekholm U, Adell R, Brånemark P-I, 1985)²³, and bone fatigue (Johns RB, Jemt T, Heath MR, et al, 1992).²⁴ If any given three units pros-

thesis is supported by two implants and has a cantilevered tooth, the bending moment may be twice that of a prosthesis in which both ends are supported. With occlusal forces acting on the cantilever, the implant becomes a fulcrum and is subjected to axial, rotational, and torsional forces.

Discussion

The ideal implant treatment plan is based on the patient's needs, desires, and financial commitment. Within the scope of this review, the different reasons for implant failure and its contributing factors should be addressed, It seems that overloading the implant (traumatic occlusion, bending moments, and excessive cantilevers) and parafunctional habits are considered to be primary factors for biomechanical implant failures. On the other hand, cross infection from periodontally involved teeth into implant sites is a factor in the biological aspect of implant failures. Failure of dental implants has, in general, multi-factorial dimensions and could be due to a single factor or a combination of more than one. Proper data collection, patient feedback, and accurate diagnostic tools will help to point out the reasons for failure (Figs. 7-10).

_contact	implants
<p>Dr Abdelsalam Elaskary Alexandria, Egypt E-mail: askary@askaryimplants.com</p>	



CHAMPIONS[®] IMPLANTS

easy, successful and affordable

directly from a known German manufacturer

70 €

22 lengths and diameters



SQUARE-SHAPED



16 lengths and diameters

TULIP

- The „Champions“ inspire customers to all indications, cost performance, patient compliance with time and everyday life
- Bone condensation and implantation according to the minimally invasive, flapless, transgingival method
- Gentle MIMl implantation with more than 20.000 successful immediately loaded implants since 1994
- Best primary stability through crestal micro thread -> safe immediate loading
- Zirconium-blasted, etched Ti-IV surface
- „Intelligent“ dental neck area for each mucosa thickness
- Zirconium ‚Prep Caps‘ (for optional cementing) for compensating divergences & aesthetics & immediate loading for dentist chamfer preparation (GOZ 221 / 501)

- Excellent German Milling and Laboratory Center, including the Master Dental Technician, for biocompatible, first-class & perfectly priced tooth replacement (One zirconium framework: 94 € One ceramic laminate: 94 €) (Phone: +49 (0) 6734 - 961592 Fax: +49 (0) 6734 - 960844)
- Planning, diagnosis and therapy assistance free of charge and patient marketing service
- No initial investment for the first delivery on commission



EXCITING ADVANCED TRAINING WORKSHOPS FOR: DENTISTS WITH CERTIFICATES & BEGINNERS & ‚ONLY-WOMEN-POWER‘ & UPDATER CHAMPIONS-MOTIVATION COURSES

Incl. many live implantations & safe prosthetic concept (15 or 30 education points)

Courses taught by Dr. Armin Nedjat (Flonheim/Mainz), specialized in Implantology, Diplomate ICOI, developer and consultant of Champions

For more information, course dates, orders:
 Phone: +49 (0) 6734 - 6991 • Fax: +49 (0) 6734 - 1053

Info & online shop: www.champions-implants.com


DVD available for free



Use of **Synthetic Bone Blocks** as an Alternative to Autologous Bone Block Grafts

author_ Christian Mertens¹, Helmut G. Steveling¹, Germany
¹ Department of Oral and Maxillofacial Surgery, University of Heidelberg

Fig. 1_ NanoBone® | block.
Fig. 2_ Radiographic situation prior to augmentation (cone beam CT).



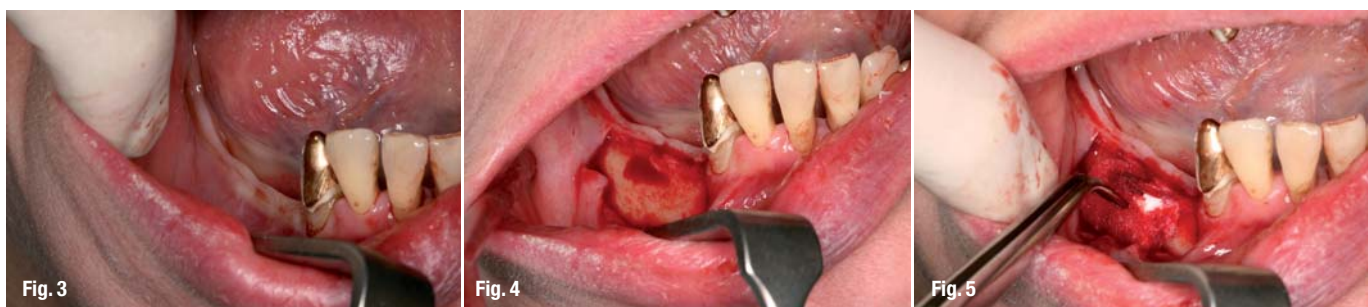_In modern implantology, correct three-dimensional positioning of implants, as well as sufficient bone material are of great importance in order to reach satisfactory and predictable results. Resorption processes, traumatic tooth losses or chronic inflammatory processes such as chronic periodontal diseases, however, often result in severe reduction of bone material. If affected areas are intended to serve as implant beds, augmentation will often be required during the same or in a previous intervention. While autologous bone is still considered to be the gold standard, bone substitute materials have proven successful particularly in cases of rather small defects. Their use may decrease patient's morbidity, shorten treatment duration and reduce treatment costs. However, if the defect exceeds a certain size, autologous bone grafts will have to be used, usually in the form of blocks. Intraoral bone removal poses the problem of limited availability. Extraoral donor sites, however,

require treatment under general anesthesia or under in-patient conditions, which is why patients frequently reject this type of surgery.

In particular in cases of edentulism in the molar and premolar region, patients tend to prefer fixed dental prostheses, however, the problem of a significantly narrowed alveolar ridge often occurs in the molar area of the mandible.

The use of the NanoBone® | block (Artoss, Germany) constitutes a possible alternative to autologous bone blocks. The nanocrystalline material, that has already proven reliable in many trials in a particulate form, has been available on the market in the form of blocks for a short time. Preclinical trials using animal models have shown high rates of bone formation within a relatively short period of time. The following follow-up observation was initiated to find out whether the bone substitute material used in the form of blocks proves successful as a possible alternative to autologous bone.

Fig. 3_ Clinical situation before surgery.
Fig. 4_ Narrow alveolar ridge.
Fig. 5_ Adaptation of NanoBone® | block to local bone.



Material and Methods

The synthetic bone reconstruction material NanoBone® consists of nanocrystalline hydroxylapatite embedded in a silica gel matrix. This matrix has an interconnecting porosity up to the range of nanometer, 50% of which have an average pore size of 35 nm. This creates a large inner surface of 85 m²/g, important for the accumulation of autologous proteins. The fir cone-like granules have a loose packing of a packing-density of approx. 40%, which results in ideal spaces for vascularization.

Since the product is manufactured using the sol-gel process at low temperatures, it is a non-sintered hydroxylapatite, whereas, based upon the manufacturing process conventional ceramics and bioglasses are sintered and thus have a correspondingly reduced inner surface.

Studies have shown that, within approximately two weeks after the implantation of NanoBone®, the silica gel matrix becomes an organic matrix consisting of osteocalcine, osteopontine and BMP-2 (Götz et al. COIR). The structure then corresponds to extracellular bone matrix. Subsequently, the augmented area is remodeled, i.e. osteoclasts decompose the material and, at the same time, osteoblasts produce new natural bone.

The change in matrix described above constitutes the precondition of fast bone regeneration. Trials using animal models have shown a quick angiogenic development of the augmented material (Gerber et al.).

Blocks based on the same technology are now available. The NanoBone® | block used here is 5 mm thick, 10 mm high and 15 mm large (see Fig.). In contrast to the granulate, interconnecting macropores ensure the vascularization of the augmentation area in this case. The pores have a size of approx. 200 µm and account for approx. 50%.

The synthetic bone reconstruction material NanoBone® consists of nanocrystalline hydroxylapatite embedded in a silica gel matrix. The morphology of the hydroxalapatite in the NanoBone® | block is identical to biological hydroxylapatite in bone (plates of a thickness of 3 nm and diameter of approx. 50 nm). This fact and the adapted gel matrix result in an inner surface of 120 m²/g. The interconnecting pores in the silica gel have a size of 10 to 20 nm.

Clinical follow-up

In this follow-up observation, the new synthetic NanoBone® | blocks were used on both sides in the patient's molar and premolar areas of the mandible.

AD



6th

6th Arab-German Implantology Meeting of DGZI

and Second International Dental Congress of Faculty of Oral & Dental Medicine/Cairo University

Cairo, Egypt | March 23–26, 2010

Congress Chairman:
Dr. Rolf Vollmer, Germany

Scientific Chairman:
Dr. Mazen Tamimi, Jordan

The German Association of Dental Implantology (DGZI) presents this meeting in cooperation with Faculty of Oral & Dental Medicine/Cairo University.

Information/Registration:

For other countries:
E-mail: drtamimi@drtamimi.com
drtamimi@dgzi-international.com
www.dgzi-international.com

For Egypt:
E-mail: drazim2001@yahoo.com

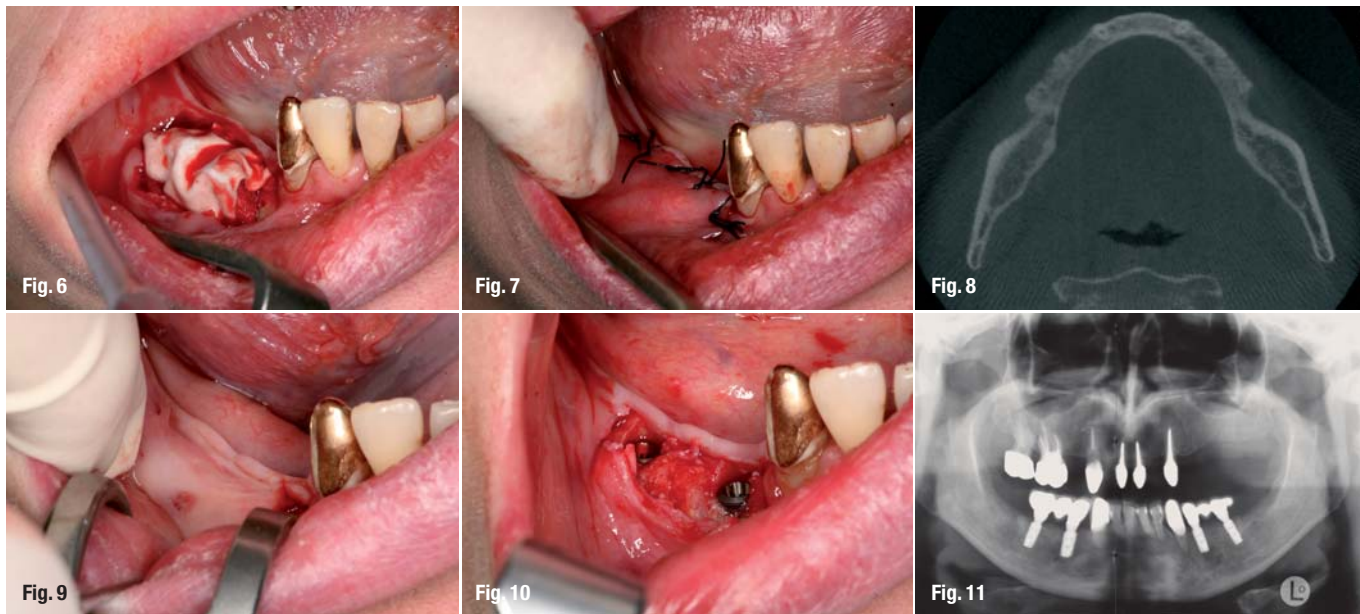


Fig. 6 Block coverage by means of collagen barrier membrane.
Fig. 7 Situation after wound closure.
Fig. 8 Radiographic situation after six months healing period (cone beam CT).
Fig. 9 Clinical situation prior to implant surgery.
Fig. 10 Good osseointegration of the blocks, high primary stability of implants.
Fig. 11 Radiographic follow-up after prosthetic rehabilitation.

Both sides were partially edentulous, starting from region 034 and 044. The jaw areas were atrophied since the teeth had been lacking for a long time and the patient has had a telescopic dental prosthesis retained on teeth 33 and 43 up to present. In the context of the necessary replacement of the prosthesis, the patient asked for a fixed prosthesis. Palpatory examinations showed a very narrow clinical situation, which was confirmed by three-dimensional X-ray analysis using cone beam CT.

Augmentation was carried out under local anesthesia. After crestal incision, vertical relief incisions were carried out in the vestibule and a mucoperiosteal flap was created. After exposure of the bone surface, some bleeding points were created using a fine round bur through the vestibular corticalis. The bone block was then adapted to the base using a scalpel. When the block lied flush against the base, it was fixed by gently tightening the osteosynthesis screws. In the present case, a single mini-screw was used in each case. Since the block is fragile, the fixing has been changed over to a 2-hole microplate and two microscrews in the meantime in order to avoid the breaking of the block. Subsequently, the edges were rounded. In the present case, the block was covered using a collagenous membrane and the buccal mucosa flap was advanced and then sutured with black silk sutures.

Four Astra Tech implants (Astra Tech, Mölndal, Sweden) were inserted six months after the augmentation—again under local anesthesia. Again, a crestal incision with minimum distal relief was carried out. After exposure, the material presented good osseointegration, without fibrous infiltration. During the drilling process, the newly formed bone showed high stability and all implants were inserted with good primary stability.

Results

After a healing time of six months, the NanoBone blocks used showed good bone infiltration, making it possible to retain implants with sufficient primary stability. Thus, the procedure used in this case may constitute a possible alternative to autologous block grafts. However, this will have to be verified by studies covering a correspondingly large number of cases.

Discussion

The nanocrystalline blocks used constitute a possible alternative to autologous bone blocks. The block provides a sufficient primary stability to be used safely for augmentation. The clinical procedure, however, differs from the use of e.g. autologous blocks removed from the retromolar space. The special structure of the block provides for the complete osseointegration of the augmentation material and thus for a sufficient gain in volume for safe implantation.

_contact	implants
<p>Dr Christian Mertens Department of Oral and Maxillofacial Surgery, University of Heidelberg Im Neuenheimer Feld 400 69120 Heidelberg, Germany Phone: +49-62 21/56 73 03 Fax: +49-62 21/56 42 22 E-Mail: christian.mertens@med.uni-heidelberg.de</p>	



Legacy™3 Implant System


Conical Connection with Platform Switching All-in-one Packaging Including SBM Implant, Cover Screw, Healing Collar, Transfer and Final Preparable Abutment = € 130

THE NEXT GENERATION
in Implant Technology



FEATURES AND BENEFITS

- 1. Body Design:**
Evenly Tapered with self-tapping grooves from mid-point to apex.
- 2. Thread Design:**
Micro-threads with progressively deeper, double-lead, buttress threads.
- 3. Surface Options - 17 year history:**
SBM - medium rough texture;
HA Coating below micro-threads.
- 4. Diameter Options:**
Six Diameters from 3.2mmD to 5.7mmD in 0.5mmD increments.
- 5. Conical Connection:**
Lead-in Bevel above Internal Hex -
23 year history (Niznick #4,960,381)
Color Coded for easy Identification;
Platform Switching on 3.2mmD,
4.2mmD and 5.2mmD Implants.
- 6. Fixture-mount Packaging:**
Fixture-mount standardizes
insertion tools, serves as
Transfer and can be shortened
for use as Final Abutment.



Straight Contoured, HLA Abutment, 15° Angled Contoured, Straight Snap-On, Gold/Plastic, Titanium Temporary Abutment, Plastic Temporary Abutment, Ball Attachment, Screw Receiving, Locator Abutment

Prosthetic compatibility with Screw-Vent, BioHorizons® and MIS Implants

Legacy™3



Implant Direct Europe AG • Förlibuckstrasse 150,
8005 Zürich, Switzerland • Phone: 00800 4030 4030

Implant Direct USA • 27030 Malibu Hills Road,
Calabasas Hills, CA 91301 • Phone: +1 818 444 3333
www.implantdirect.com

The Importance of Crestal Bone Preservation in the Use of Short Implants

authors_ Marincola M.*, Coelho PG**, Morgan V.**, Cicconetti A.****

* Ass. Professor, Department of Implant Dentistry, University Cartagena, Cartagena.

** Ass. Professor, Department of Biomaterials and Biomimetics, NYU.

*** Clinical Director, Implant Dentistry Centre, Boston.

**** Ass. Professor, Department of Oral Surgery, La Sapienza University, Rome.

It is general consensus that maintenance of bone around dental implants is one of the most important features in long-term treatment success achievement, and that progressive bone loss drastically decreases the survivability of dental implants under occlusal loading (Kitamura 2005, Horowitz 2008). Although the achievement of osseointegration after implantation is important in obtaining treatment success, it does not necessarily indicate that this bone-biomaterial interface will keep its integrity throughout the patient's life, since a large number of factors play a role on the kinetics of mineralized tissue (King 2002, Tawil 2006). Of particular interest to the private practitioner is the crestal bone loss after implantation occurring during the first year after implant placement once this loss will drastically affect the biomechanical anchorage of the prosthetic restoration and possibly jeopardize the proposed treatment (Leonard 2009).

Factors causing crestal bone loss

This loss may be attributed to several factors including

- excessive occlusal forces,
- trauma during the surgical procedure,
- inflammation/infection,
- implant exposure during soft tissue healing,
- implant-abutment gap present in the great majority of implant systems commercially available (bacteriological colonization),
- early loading of a not biomechanically competent bone-biomaterial interface,

implant bulk device design, particularly the crest module profile.

Among the potential causes described above, many can be avoided by the clinician through proper treatment planning and patient management, while others can be evaluated/avoided through engineering concepts. It is important to note that in most cases there is not a single factor but the synergy of various causes mediating the progressive mineralized tissue loss around dental implants.

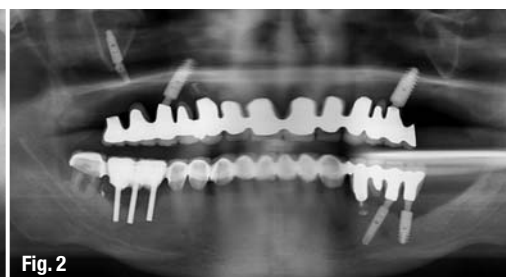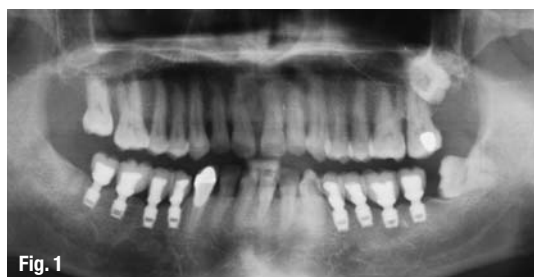It is evident that full control of all the variables playing a role on bone loss around implants after implantation, especially around the implant crest module during the first year of implantation, is beyond any clinician's domain, once there is contribution from the biological (patient), human technical (clinician) and engineering (implant bulk design and connections) aspects to this complex problem.

Among the contributing factors that are in control of the private practitioner is a proper treatment planning to enable the right number and positioning of implants is a major issue. Once the proper number and position of implants is achieved, it facilitates proper restoration and occlusal adjustment thus diminishing to a great extent the human technical contribution to crestal bone loss (Figs.1 and 2).

Another controllable factor is the engineering aspect of the implant system. The factors to be considered are the implant crest module and the implant-abutment connections (Tada 2003). Although there is some evidence that both design considerations play a significant role on the crestal bone loss

Fig. 1 Proper treatment planning replacing the lost teeth with single crowns on short implants. Note the crest preservation over the intra-osseous Bicon Short Implants.

Fig. 2 Missing criteria for proper treatment planning. Poor implant placement with evidence of crestal bone loss.



around implants, quantification of this processes have not been experimentally shown to date due to the multifactorial nature of the subject. The theories described in this series of articles rationalize crestal bone loss related to crest module design and implant connections (particularly the one linking the implant to its respective abutment). These theories are in qualitative agreement with clinical observations for different implant designs.

The implant crest modules biomechanics

There are currently three different basic designs of implant crest modules available in commercial scale (Bozkaya 2004). These different geometries are shown in Figure 3. Schematic representation of commercially available implant systems and their respective crest modules are presented in Figure 4. Throughout this article, the crest module which sides diverge to occlusal will be called "vase shaped" (VS), the one which sides do not diverge or converge (parallel) "cylindrical" (C), and the one which sides converge to occlusal "rocket shaped" (RS). The qualitative static mathematical analysis regarding this three different crest module designs have been previously demonstrated during the late 80's and is mentioned in several implant dentistry textbooks (Bidez 1992).

The most desirable way to approach this type of problem is through mechanical and mathematical formulations with the aid of computer software (Finite Element Analysis), but qualitative understanding of the crest module role can be easily achieved through simple arguments on single tooth implant restorations as follows:

1) The forces that an implant is subjected during function are complex in nature due to the oblique planes comprising a crown, which make these forces oblique in nature thus resulting in vertical and horizontal force components. These vertical and horizontal force components will cause moments (force multiplied by the distance) in most instances, which may increase significantly the load which the implant is subjected. Unless the load is vertical and perfectly aligned with the implant long axis, a horizontal force component acting on the implant will always exist (Petrie 2002).

2) Consider the schematic drawing of a vase shaped, a cylindrical, and a rocket shaped implant in a bone domain as shown in Figures 5a through 5c. In these

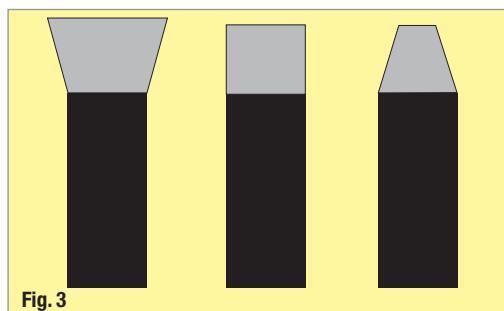


Fig. 3

Fig. 3 The three different crest module designs from left to right: "vase shaped", "cylindrical", and "rocket shaped".

drawings, one should first note that the width of the bone domain is the same for all implant types and that these implants are inside this domain through their whole extent (the crest module is totally submerged in bone). It is also important that the implant diameters are the same (as if they were to be used to restore the same region).

It can be observed that in the cervical region of the crest module the bone amount around the module (red arrows) is smaller for the vase shaped implant than for the other two types, which leaves the vase shaped implant with a smaller amount of bone for force dissipation, showing that the bone around this crest module design is more likely to be overloaded and lost due to prosthetic occlusal function than the other two (Lemons 2004). This condition would be clinically accentuated in knife-edge ridges, where a lesser amount of bone would be present around the implant's crest module. This theory is in qualitative agreement with clinical findings where vase shaped implants present a slow but progressive bone loss after some implantation time in-vivo and rocket shaped (biomechanically more favorable) implants present none or very little bone loss as time elapses in-vivo (Venuleo 2008) (Figs. 6 to 8).

In spite of the higher amount of bone around the cervical part of the crest module of the cylindrical implant compared to the vase shaped implant, it has been shown by mathematical models which were in agreement with clinical observations have shown that there is an extensive progressive bone loss around implants presenting this geometry. This is likely due to the high interfacial shear stresses (pure shear) that these implants are subjected under vertical loading. For the other two crest module geometries, this progressive bone loss does not happen to the same extent and can be explained through simple



Fig. 4

Fig. 4a-e Commercially available implants with different crest module designs. From left to right: Nobel Biocare (VS), ITI (VS), AstraTech (VS), Ankylos (RS) and Bicon (RS).

Fig. 5 Implants on a bone domain of the same size. One should note the amount of bone present on the topmost part of the implant (presented by red arrows). The amount of bone around the crest module is of fundamental importance on occlusal forces distribution.

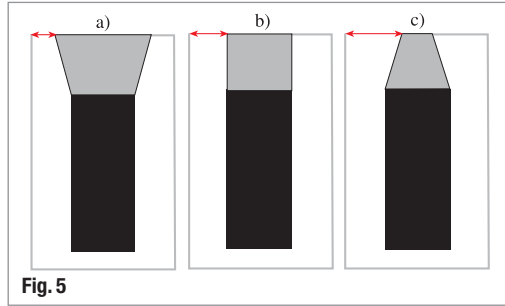


Fig. 5

mathematical calculations where the load vector (resultant) is broken into components that are dependent on the crest module angulations, and interfacial shear stresses are attenuated when compared to cylindrical shaped crest modules. A simple representation of the reaction forces resulting from a vertical load on a vase shaped implant is shown in Figure 9 (vector magnitudes are not representative of their actual magnitude).

Further aggravation of the problem takes place as progressive bone loss occurs around the implants regardless of crest module design. As bone is lost (due to unfavorable biomechanical condition) from the upper part of the crest module downwards, implant anchorage is lost and there is an increase in load bearing of the remaining bone around the module due to an increase in the moment value (the moment increases proportionally to bone loss). This finding has been the subject of various laboratory and clinical research protocols, especially around vase shaped implants where theoretically this bone loss would evolve until catastrophic failure occurred, which is not the case. Interestingly, this bone loss usually stops at the first thread region and in most instances does not represent implant failure. In fact, these implants remain in place for long periods of time in function without any complications throughout its lifetime (Mericske-Stern 2001). This sudden stop at the first thread might be related to bacteriological contamination that may occur due to the presence of a gap on the implant-abutment connection (King 2002). Also, this phenomenon has been taken into account by several private practitioners around the world, who have changed their surgical and restorative protocols to circumvent the drawbacks of such bone loss in order to achieve better results, especially in esthetically compromised regions where the bone loss around

the implant crest module makes difficult the handling of soft tissues. It has been also reported by clinicians that the microthreads present on the crest module of an implant system have significantly reduced bone loss (Figs.10 and 11).

Conclusion

In summary, it is widely accepted that the bone loss around implant's crest module is multidisciplinary in nature and that from an engineering perspective these are related to device design (crest module design and implant connections). From a purely mechanical standpoint, if same diameter implants with the three crest module designs available are to be placed in a given region, the rocket shaped crest module implant will be less likely to loose bone due to the higher amount of bone around its crest module, which will theoretically help dissipating the functional loads (Li Shi 2007).

It is paramount to remember that a long term preservation of the crestal bone makes the use of short implants predictable and encourage the clinician to use short implants in all kind of bone dimension and bone quality. The rocket shaped module of an sloping shoulder can be considered as the ideal implant design for a homogeneous occlusal force distribution around the implant neck/crestal bone.

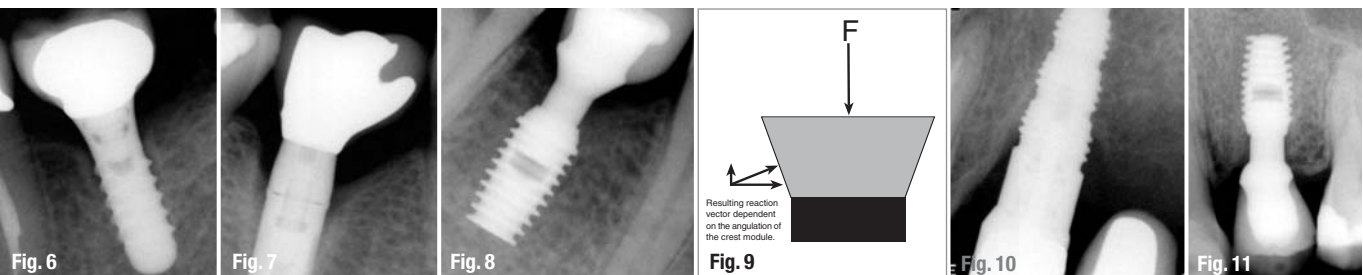
In the past, it was believed that dental implants needed to be at least 10 mm in length to assure successful functioning of osseointegrated implants. However, recent studies show that short (< 10 mm) dental implants can perform well. Particularly, the plateau or fin design of dental implants with a bacterially sealed 1.5° locking-taper connection has provided for successfully functioning dental implants as short as 5.0 mm in length. Additionally, they have shown that short unsplinted dental implants had less crestal bone loss than longer splinted dental implants.

Fig. 6 and 7 Cone shaped crestal bone loss around a vase shaped (left) and a cylindrical (right) implant neck after a period of loading.


Fig. 8 Note the crest preservation around the rocket shaped implant neck. The sloping shoulder guarantees a platform switching at implant level with bone growth over the neck.

Fig. 9 Decomposition of the reaction vector (dependent on the module geometry) resulting from a vertical load F applied to the implant.

Fig. 10 and 11 Comparison between a vase shaped (left) and a rocket shaped (right) implant design at crest level.



_contact	implants
<p>Prof Dr Mauro Marincola Via dei Gracchi, 285 00192 Roma, Italy E-mail: mmarincola@gmail.com</p>	



Dear Colleagues,

we take great pleasure in inviting you to participate in the 1st Hvar International Dental Congress.

From 10. to 12. of June 2010., HSK - Croatian Dental Chamber in cooperation with Oral Dent company, supported by three international associations DGZI - Deutsche Gesellschaft für Zahnärztliche Implantologie e.V., IADFE - International Academy for Dental Facial Esthetics and ESCD - European Society of Cosmetic Dentistry organizes an extraordinary assembly of experts from all over the world on the island of Hvar, Croatia.

More than 40 lecturers from Europe, the United States of America and Middle East will give lectures on the island of Hvar. We organize programs for dentists, dental technicians, many workshops, Laser Symposium and big international exhibition. Along with the educational program, we organize luxurious entertaining social programs with numerous surprises during all three congress days.

The whole event will be held in Grand Hotel Amfora, in the town of Hvar, in the period of 10. to 12. of June 2010. It is important to mention that the Croatian Dental Chamber rated this Congress with the maximal 12 points, which ranks this Congress among the best events in Croatia in 2010.

All dental companies which are interested in participation and renting exhibition booths on this congress can find all the information on our web site www.hvarkongres.hr or can contact us directly via e-mail info@hvarkongres.hr We will be happy to provide you with detailed information.

Looking forward to welcoming you on the island of Hvar.

Sincerely Yours,

the Organizing committee

Lecturers:

Dr. David L.Hoexter - USA
 Prof.Dr. Bilal Al-Nawas - GER
 Dr. Istvan Urban - HUN
 Dr. Suheil Michael Boutros - USA
 Dr. Francesco Mintrone - ITA
 Dr. Darko Slovsa - CRO
 Prof.Dr. Claus Udo Fritzscheimer - GER
 Dr. Mazem Tamimi - JOR
 Dr. Nadim Abou Jaoude - LBN
 Prof.Dr. Nabil Jean Barakat - LBN
 Doz.Dr. Jiri Holahovski - CZE


Dr. Rainer Valentin - GER
 Dr. Rolf Vollmer - GER
 Dr. Ulf Kruger Janson - GER
 Dr. Wolfgang Richter - AUT
 Dr. Luca Lorenzo Dalloca & MDT Roberto lafrate - ITA
 Dr. Stefano Ardu - CHE
 Dr. Dusko Gedosev - GER
 Dr. Gregory Brambilla - ITA
 Prof.Dr. Ivica Anic - CRO
 Prof.Dr. Ivana Miletic - CRO

Dr. Thomas Schindler & MDT Harald Hoehr - AUT
 Dr.Vanja Coric - CRO
 Dr. Fay Goldstep - CAN
 Dr. Ross W. Nash - USA
 Dr. Elliot Mechanic - CAN
 Dr. George Freedman - CAN
 Prof.Dr. Edward Lynch - GBR
 Dr. Orsolya Rigo - HUN
 Prof.Dr. Hrvoje Juric - CRO
 Prof.Dr. Bozidar Pavelic - CRO
 Dr. Zeljka Cabunac - SRB

HVAR 2010 CONGRESS

INTERNATIONAL DENTAL CONGRESS CROATIA

10.06.2010. - 12.06.2010.



www.hvarkongres.hr

Complications, Risks, and Failures in Oral Implantology

author_Georg Bach, Germany

DGZI consciously chose this provocative and at the same time honest topic for its 39th DGZI Annual Congress. Once more, about 500 professionals—dentists specialized in implantology as well as oral and maxillofacial surgeons—met in Munich (October 9–10) for expert exchange.



_Once again, DGZI succeeded in arranging an extraordinarily attractive scientific program with highly qualified speakers. It perfectly linked practice and research and therefore fully corresponded to the philosophy of the oldest European expert association for implantology. In the morning of the first congress day the participants were "tuned in" for the 39th DGZI Annual Congress, thanks to the great number of extremely well-booked workshops. "We must, and we will also face the specifically problematic aspects of our field of expertise, namely implantology, which are often excluded at most congresses." With this clear and quite self-critical avowal Dr Friedhelm Heinemann, President of DGZI, opened the congress. Although complications and risks of modern implantology methods are manageable for

experienced implantologists, the number of mistakes and failures naturally increases due to constantly increasing numbers of incorporated tooth abutments, according to Dr Heinemann. The DGZI President showed extraordinary media competence when he easily managed a conference circuit with Prof Walter in Dresden, Chairman of DGZPW (a scientific association, which closely cooperates with DGZI). Prof Walter was thus able to address the audience in Munich with his "digital message".

_International speakers, podium 1 and 2

The main podium has already achieved a kind of cult status. It takes place in the afternoon of the first congress day and is traditionally dedicated to



international speakers. Thus, many speakers, especially from Arabic countries, have been able to present their experiences with complications occurring in implantology.

While colleagues Boutros, Barakat, Al-Garni, and Tamimi talked about rather general complications, Jaoude, Geha, and Elaskary emphasized failures that occur when applying certain methods.

Final speaker was colleague Odeh who reported on the application of mini dental implants in orthodontics. In addition to the main podium, there were two adjacent podia taking place at the same time. The well-balanced contributions of podium 1 mainly focussed on hard tissue, whereas podium 2 addressed the issue of how to avoid complications, the so called "trouble shooting". A successful evening event in the SKY BAR of the Hilton hotel completed the first congress day and offered an opportunity for collegial and friendly exchange to the constantly growing DGZI family.

_ "Meet & Break" on the second congress day

The second congress day was divided into three comprehensive sessions.

Before the beginning of the scientific program we introduced a novelty: "MEET and BREAK" was a great opportunity for an informal get-together of congress participants, speakers, and exhibitors. A small breakfast was offered in the extremely well-stocked exhibition rooms, and many of the participants took the chance for collegial interchange. The extraordinary good feedback certainly encourages us to offer "Meet and Break" on future events. Prof Dr Thomas Weischer delivered the opening speech of the second congress day titled: "Complications and Solutions in Oral

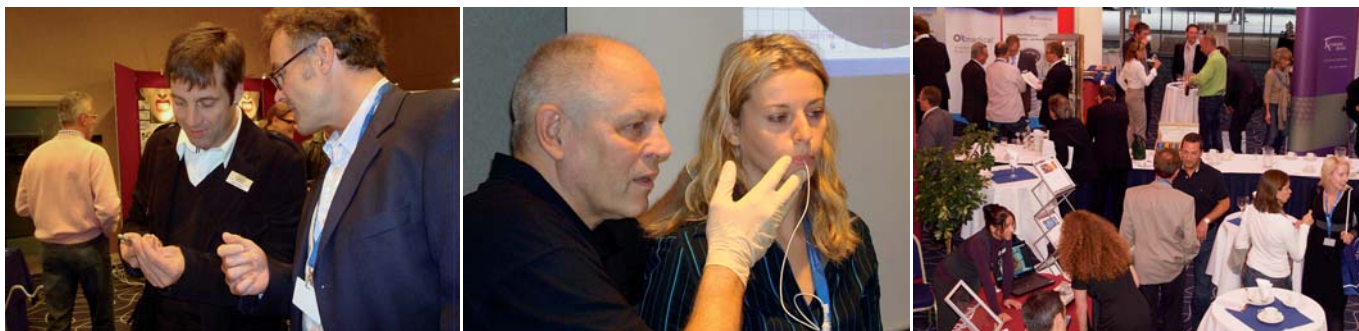Implantology". At the beginning of his speech he already pointed out that the general statement, stating that implants can obviously be equated with success, is not correct. In addition to rare surgical complications, especially inflammatory complications may lead to partial or even absolute failures. Prof Weischer presented numerous case studies of general, surgical (exemplified with the mandible fracture), inflammatory (exemplified with local osteomyelitis and implant fractures), prosthetic and esthetic complications, as well as nerve damage. Prof Dr Georg Nentwig talked about "Avoiding Early Functional Failures after Implantation in the Compromised Jaw Bone". The university professor from Frankfurt made a perfect link to the review lecture of the previous speaker by specifically referring to early functional failures. Prof Dr Norbert Kübler spoke about "Extreme Cases in Dental Implantology". His introductory words were as follows: "I would like to present a potpourri of interesting cases to you, which you can only see at universities". The professor from Düsseldorf kept his promise and presented highly interesting cases. Prof Kübler presented extraordinarily well documented and impressive case studies ranging from dramatic cases of trauma patients, e.g. a complete dentogenesis imperfecta, a pseudoprognathism due to cleft lip and palate (cheilognathopalatoschisis), an alleged titanium allergy (one-piece full ceramic implants were used in this case), a pronounced periodontitis marginalis (template conducted implantation), treatment with disc implants, and even MAV.

Implantology". At the beginning of his speech he already pointed out that the general statement, stating that implants can obviously be equated with success, is not correct. In addition to rare surgical complications, especially inflammatory complications may lead to partial or even absolute failures. Prof Weischer presented numerous case studies of general, surgical (exemplified with the mandible fracture), inflammatory (exemplified with local osteomyelitis and implant fractures), prosthetic and esthetic complications, as well as nerve damage. Prof Dr Georg Nentwig talked about "Avoiding Early Functional Failures after Implantation in the Compromised Jaw Bone". The university professor from Frankfurt made a perfect link to the review lecture of the previous speaker by specifically referring to early functional failures. Prof Dr Norbert Kübler spoke about "Extreme Cases in Dental Implantology". His introductory words were as follows: "I would like to present a potpourri of interesting cases to you, which you can only see at universities". The professor from Düsseldorf kept his promise and presented highly interesting cases. Prof Kübler presented extraordinarily well documented and impressive case studies ranging from dramatic cases of trauma patients, e.g. a complete dentogenesis imperfecta, a pseudoprognathism due to cleft lip and palate (cheilognathopalatoschisis), an alleged titanium allergy (one-piece full ceramic implants were used in this case), a pronounced periodontitis marginalis (template conducted implantation), treatment with disc implants, and even MAV.

_Special podium on peri-implantitis

In accordance with the congress topic, a special podium on peri-implantitis with highly qualified speakers was organized. This eminently important topic was





addressed by three qualified experts, each presenting his individual point of view. The first speaker of this special podium, which was eloquently and amusingly moderated by Prof Frank Palm, was Prof Dr Andrea Mombelli. He is the parodontologist to whom we owe the definition of septic peri-implantitis, thanks to his publication issued in 1987. Prof Dr Herbert Deppe and Prof Dr Dr Soren Jepsen were the subsequent speakers. An expert talk with the speakers, again moderated by Prof Dr Dr Frank Palm, completed this session which, without doubt, was a highlight of the 39th DGZI Annual Congress.

immediate loading (nearly the same success rate as later loading of implants), 3-D image processing and digital planning/manufacturing of dental prostheses, complications, and peri-implantitis. The audience was especially impressed by the possibilities of "impression-free practice" and the realization of highly precise implant prosthetics by means of digital impression and construction.

Please note: DGZI offers a special service. The PowerPoint presentation and its numerous references can be downloaded to your own computer from the DGZI homepage www.dgzi.de.

Scientific Review

Another novelty was presented at the end of the scientific program—a Scientific Review. DGZI President Dr Friedhelm Heinemann and Dr Georg Bach evaluated numerous journals and composed a "scientific concentrate" which they presented to the audience. The review topics were novelties concerning implant surfaces (turning away from high roughness and orientation towards hydrophilic surfaces), the renaissance of

The 39th DGZI International Annual Congress was rounded off by a final discussion. In his closing remarks DGZI President Heinemann pointed out the important "Forty-Years-DGZI Anniversary" next year in Berlin. This congress, which will be organized in cooperation with DGZPW, will be dedicated to the field of implant prosthetics.

Information
www.dgzi-jahreskongress.de



International Examination of GBOI in Munich

A side event of the 39th Annual DGZI Congress

There is certainly something good to be said about globalization. Markets grow together and everyone benefits from one another's know-how. For a considerable time, one may have watched the growing internationalization within medicine, especially within the dental medicine market. There has been a growing demand for quality "made in Germany". Many German dentists are already working abroad, they have associates all over the world, and they are very successful engaging themselves internationally. Recently, we have also noticed an increasing interest among patients from abroad, who want to be proficiently treated in Germany by expert colleagues. Already last year, DGZI, which is the oldest European association in the field of oral implantology, decided to offer the opportunity to obtain the internationally acknowledged certificate "Specialist in Oral Implantology DGZI" and "Expert in Oral Implantology DGZI" of the German Board of Oral Implantology (GBOI) to specialized colleagues. With this additional examination, participants also obtain an international certificate as proof

of their qualified knowledge of English. "The second international examination of GBOI was a side event of the 39th Annual DGZI Congress, which took place this year in Munich (October 9–10, 2009). More than twenty participants took the challenge to answer the often very difficult questions belonging to the theoretical part of the examination, and also to the ongoing specialist questions of the international board of examiners. For this purpose, DGZI succeeded in gathering an independent international team of experts consisting exclusively of university professors of renowned universities. And according to participants, the following is what they conclude about the experience: Ambitious and challenging, a great experience and a forward-looking qualification in a global world.

The next international examination will be offered as a side event during the 40th DGZI International Congress in Berlin, in October 2010.

For more information please contact the DGZI Office in Düsseldorf.

Phone: +49-2 11/1 69 70-77



FDI closes Annual World Dental Congress in Singapore

author_Daniel Zimmermann, DTI

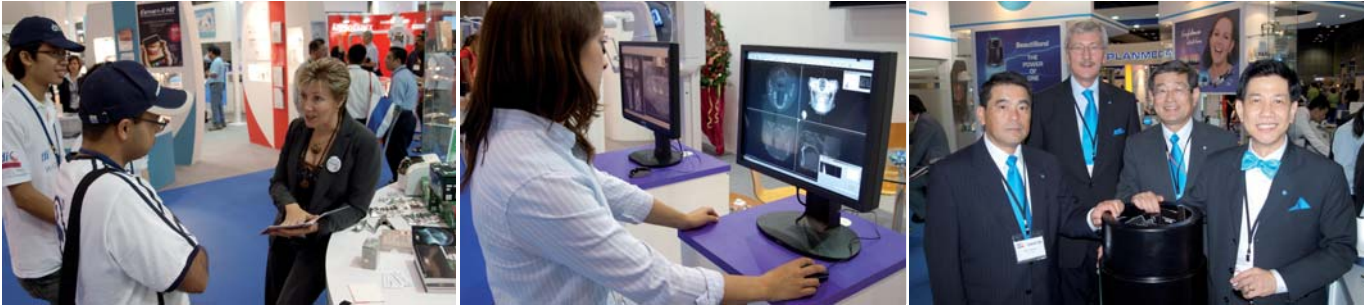Singapore has a long and successful relationship with the dental profession. Not only does the city state host the oldest running dental school in Asia; first implants were placed here by Dr Henry Lee almost 20 years ago. Nowadays, the island boasts a workforce of over 1,000 dentists that are both educated internationally and make use of the latest state-of-the-art equipment.

Large international manufacturers such as 3M ESPE and Straumann have taken advantage of Singapore's position as a trading hub and serve most of their customers in the Asia Pacific region from here. With IDEM Singapore, the city also hosts a dental trade show every two years that not only attracts dental professionals from Singapore but also from other countries in South East Asia.

It was no surprise that the FDI World Dental Federation, who represents the interests of dentists globally, decided to organise yet another one of their Annual World Dental Congresses (AWDC) in Singapore. An AWDC was held here before in 1990 and the FDI has been cooperating with the Singapore Dental Association (SDA) in organising IDEM Singapore's scientific programme for almost four years.

This year's congress was held in conjunction with Singapore's Oral Health Month, an annual campaign that aims to improve oral health by offering free dental screenings to every Singaporean. According to the latest Adult Oral Health Survey conducted island-wide in 2003, almost half (46 per cent) of the respondents indicated that they visit the dentist at least once a year; the average mean DMFT was 8.1 and about 10 per cent of the respondents were caries free. A SDA spokesperson said that more than 200 private dentists will be participating in the screenings that will take place during weekends over the course of September.

Visitors were spoilt by this year's scientific programme, which did not only feature popular topics like implants, aesthetics, and periodontics, but also gave insight into new challenges and developments in dentistry. Among others, the prevalence of oral cancer, salivary biomarkers as well as the therapeutic potential of dental stem cells and tissue engineering were discussed. Limited Attendee Courses were expended to give participants the chance to learn in a more intensive and intimate environment. Auxiliaries and office personnel had the chance to get their hands on the New Patient Experience in a special full day programme. As one participant put it: "What strikes me about this congress is how it brings together so many different specialist areas in dentistry, all under the same roof."



Though official numbers have not yet been released, exhibitors speaking to Dental Tribune Asia Pacific said that visitor's numbers clearly did not meet their expectations. In spite of this, most exhibitors also reported increased numbers in sales and business deals. Plenty of new products and processes were introduced, for example, surgical instruments and handpieces that now come with built-in and long-lasting LED lights. Nobel Biocare introduced their newest product NobelProcera for the first time to Singaporean dentists during an official launch dinner held at the Charlton Hotel on Bras Basah Road. The system aims to combine industrialised production processes with versatile and individualised aesthetics for dental restorations.

In addition, continuing education was offered to trade show visitors through Dental Tribune in collaboration with the DT Study Club, who held their first online symposia outside the United States.

Members of the 2010 Local Organising Committee invited to next year's congress in Salvador da Bahia in Brazil, home country of the newly appointed FDI president Dr Roberto Vianna. Dr Vianna, who took over the presidency from Dr Burton Conrod, Canada, received his DDS from the Federal University of Rio de Janeiro in 1965. Since then, he has been serving for many national and international health organisations, including the World Health Organization and the Latin America Association of Dental Schools.

"I am very happy to lead the FDI as president over the next two years. The organisation is, of course, the voice of dentistry, but more so, it is a means of empowering dentists to think about oral health on another level, for the benefit of the greater population," Dr Vianna said. "I would like to contribute and help spread the FDI message; to accomplish the ob-

jectives expressed in our mission. The FDI is a strong organisation that continues to improve. I'd like to see us focus on developing our relationships and networks, both across the organisation and outside. I am very happy with the direction we are moving in. Since I became part of the Executive Committee there have been a lot of positive changes—new staff members, the relocation of head office, our Executive Director—and important projects, like the Global Caries Initiative (GCI)," he added.

The GCI is a collaborative project led by the FDI with the long-term goal of eradicating dental caries. In July 2009, the Rio Caries Conference was held in Brazil to launch the initiative and a series of follow-up events are expected over the next ten years. Dr Vianna also announced that he will support the GCI throughout his term as president.

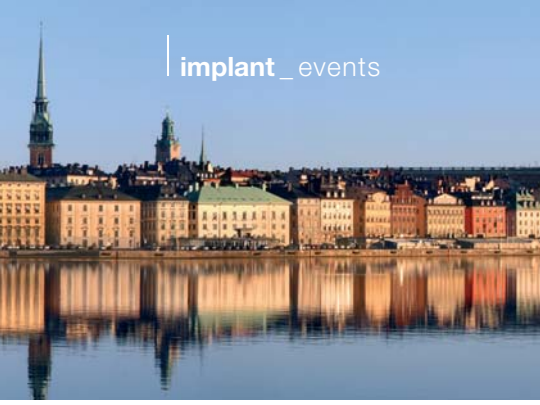
Another important advocacy tool during his term will be the new Oral Health Atlas, which was launched at the FDI Pavilion in Singapore and will be available at Amazon UK after the FDI congress. According to Dr Vianna, this will be a landmark publication that will strengthen the FDI's position as a world leader for the promotion of oral health information by demonstrating the state of world oral health in easy language, for everybody (from dentists to government delegates to the general public).

Speaking about the 2010 FDI Annual World Dental Congress in his home country Brazil, Dr Vianna borrowed a phrase from France's national anthem, "le jour de gloire est arrivé" (now is here our glorious day): "I am very excited to see the AWDC come back to South America, for only the third time in FDI's history. There has been a lot of breakthrough research and development in Brazil in recent years. Hosting the annual congress will further strengthen oral health promotion across the region."



Source: FDI





Selected Events 2009/2010

NOVEMBER 2009

November 4–7

AOS 7th Biennial Conference

Queensland, Australia

Phone: +61-7/3858 5525

November 11–15

58th Annual Meeting of AAID

New Orleans, Louisiana,
USA

Web: www.aosconference.com.au

Web: www.aid.com

November 27
– December 2

GNYDM Greater New York Dental Meeting

New York, USA

Web: www.gnydm.com

MARCH 2010

March 2–4

*Biannual WFLD World Congress in Conjunction
with UAE International Dental Conference &
Arab Dental Exhibition*

Dubai, UAE

Web: www.aeedc.com

March 23–26

*6th Arab-German Implantology Meeting &
2nd International Dental Congress of
Oral and Dental Medicine /Cairo University*

Cairo, Egypt

Web: www.dgzi-international.com
E-Mail: drazim2001@yahoo.com

APRIL 2010

April 15–18

IDEM International Dental Exhibition and Meeting

Singapore

Web: www.idem-singapore.com

MAY 2010

May 12–16

32nd Asia Pacific Dental Congress

Colombo, Sri Lanka

Web: www.apdc2010.com

JUNE 2010

June 10–12

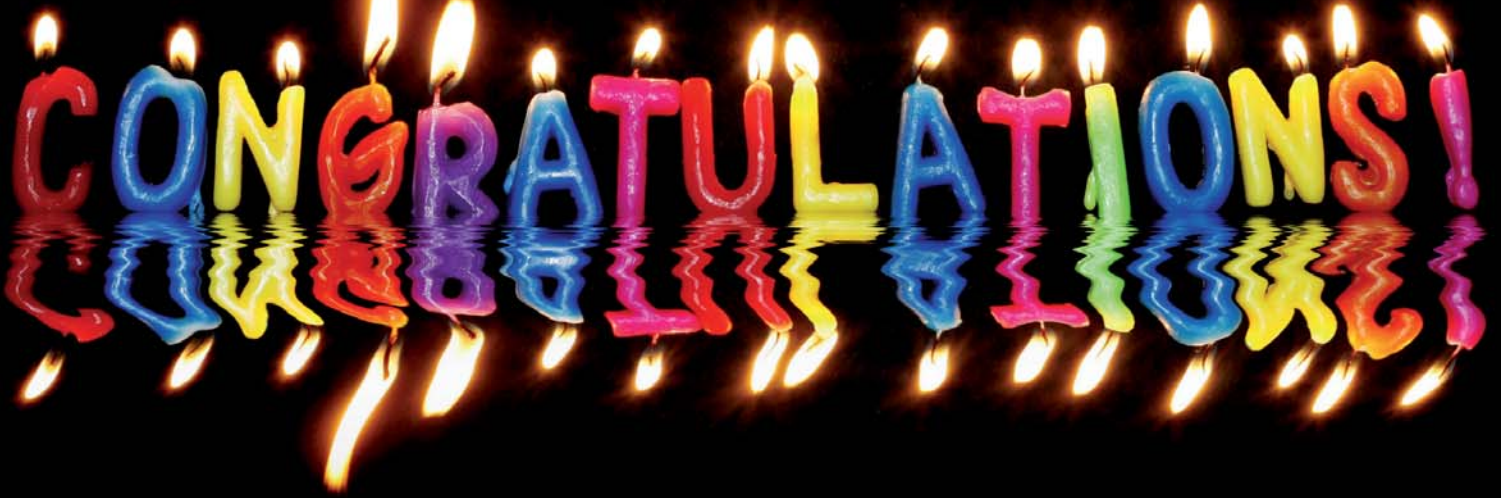International Dental Congress, Hvar Congress

Hvar, Croatia

Web: www.hvarkongres.hr



Congratulations and Happy Birthday to all DGZI-members around the world



OCTOBER 2009

75th Birthday

ZA Per Olov Tynelius (04.10.)

70th Birthday

Prof Dr Klaus-Ulrich Benner (16.10.)

65th Birthday

ZA Per Momkvist (04.10.)
Dr Otmar Jürgens (08.10.)
ZA Horst Lehmann (12.10.)
Dr Dr. Cord-Eberhard Kotthaus (31.10.)

60th Birthday

Dr Heiner Neller (04.10.)

Dr Horst Joachim Groninger (09.10.)
Robert Hedderich (13.10.)
Dr Eduard Fraas (24.10.)
Dr Meinolf Sowinski (27.10.)

55th Birthday

Dr Holger Essiger (24.10.)

50th Birthday

Dr Arno Moll (02.10.)
Dr Marit Wendels (06.10.)
Dr Alexander Kreis (16.10.)
Klaus Ostermann (21.10.)
Dr Reinhard Kramer (23.10.)

Drs Bart Van de Voort (23.10.)
Dr Rolf Simon (27.10.)

45th Birthday

Dr Gerd Thorsten Pletz (02.10.)
Dr Burghard Bode (12.10.)
Dr Bruno Spindler (12.10.)
Dr Ovidiu Smarandache (15.10.)
Dr Ingo Röller (25.10.)
Thomas Hahn (25.10.)
Liliane Allemann (27.10.)
Dr Günther Lay (28.10.)
Dr Georg Bach (29.10.)
ZA Jörg Vicari (30.10.)

Dr Adolf Gerhard Liebscher (31.10.)

40th Birthday

Dr Jochen Schmidt (22.10.)
Dr Markus Blume (24.10.)
Steffen Tretner (27.10.)
Dr Hayder Abdul Sada (29.10.)
Dr Marco Schmitz (30.10.)

NOVEMBER 2009

65th Birthday

Dr Peter Laschka (02.11.)

60th Birthday

Dr Dr Peter Herz (21.11.)
Dr Farah Yacoub Ayoub (28.11.)
Dr Peter Gehlhar (28.11.)

55th Birthday

Dipl.-Stom. Gabriele Herold (13.11.)
Dr Dr Thomas Engelhardt (15.11.)
Dr Frank Stawitz (17.11.)
Dr Wolfgang Ungermann (21.11.)
Dr Norbert Franz Kromer (25.11.)
Dr Jolanta Zakrzewska (25.11.)
ZA Sören Hansen (26.11.)

50th Birthday

Dr Stavros Moisiadis (01.11.)
Heike Isbaner (04.11.)
Dr Abu Salem Subhi (10.11.)
Dieter Steinborn (14.11.)
Gregor Heering (18.11.)

45th Birthday

Dr. Martin Bertram (18.11.)
ZA Manouchehr Kami (19.11.)

40th Birthday

Dr Albacha Ayman (03.11.)
Dr Taher Hiba (10.11.)
Dr Detlef Adler (17.11.)

DECEMBER 2009

75th Birthday

Jörg Enderlein (03.12.)
ZA Johann Ullmann (26.12.)

70th Birthday

Dr Metin Gürlük (07.12.)
Dr Peter Beckmann (26.12.)

65th Birthday

Dr Gerard Scortecchi (13.12.)
Dr Erhard Keller (24.12.)

60th Birthday

ZA Jochen Zimmermann (11.12.)
Dr Achim Rust (15.12.)
Dr Stephan Ostritsch (25.12.)
Dr El Sayed Abou Shahba (26.12.)
ZA Edgar Grossimlinghaus (26.12.)

55th Birthday

Maria Lück (02.12.)
Dr Stephan K. Hausknecht (09.12.)
Dr Stefaan De Brabandere (15.12.)
Dr Frank-Ingo Nehm (19.12.)
Dr Hans Walter Raupach (22.12.)
Bernd Esser (29.12.)

50th Birthday

Dr Ulrich Schulze (03.12.)
Dr Michael Rasche (13.12.)
ZA Peter Scheffke (14.12.)
Tomruk Senay (15.12.)
Dr Gregor Feuerstein-Börner (19.12.)
Dr Uwe Steinhaus
Dr Senichi Suzuki (27.12.)

45th Birthday

Dr Jürgen Oeder (03.12.)
Dr Jan Minea (05.12.)
Dr Rüdiger Mintert (08.12.)
Dr Thomas Rieger (21.12.)

ZA Klaus Goldschmidt (22.12.)
Dr Thomas Krämer (24.12.)
Anke Ryguschik-Bruhn (27.12.)

40th Birthday

Gunnar Millow (06.12.)
Dr Thilo Grahneis (10.12.)
Dr Heinz-Otto Lausch (12.12.)
Oberstabsarzt Sabine Stadermann (27.12.)

Manufacturer News

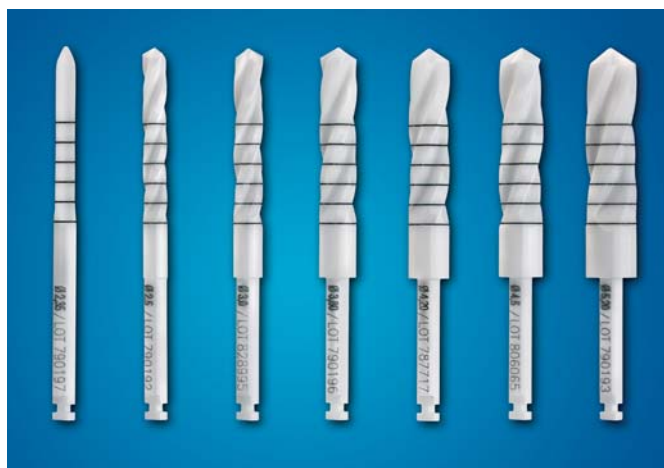maxon dental

Ceramic drills for implantology

maxon motor, manufacturer of high-precision technical components made of high-performance ceramics, is now offering a new dental drill for metal-free preparation of implant beds. The company is seeking partners for international distribution. The ceramic drills are available in seven standard diameters, but can be produced in different sizes if required.

Patients who insist on metal-free treatment for implants and prosthetics often do not want to come into contact with metal in the preparation of their implants either. Users of traditional titanium implants can also benefit from the excellent properties of maxon's new ceramic drill.

Unlike traditional drills, maxon's ceramic version is based on three-lip drill geometry, which means that the implantologist can guide the drill securely and quietly. The ZrO_2 ceramic cutting edges are exceptionally sharp and undergo almost no wear and tear. Even after 100 applications, they are still sharp, while traditional steel drills must be discarded after around 20 applications. maxon's ceramic drill can be sterilised at least 100 times in standard autoclaves, representing an environmentally friendly and economic alternative to single-patient drills. The smooth surface of the new ceramic drills prevents the colonisation of bacteria. The white colour also means that the drilled bone material can be immediately assessed for its re-use for the bone structure. Reading the drill progress is made easier by the space markings engraved with the laser. maxon's ceramic drill is available in a range of diameters and lengths. If required, maxon can produce



these drills in any size, duly branded with the relevant partner firm's logo. maxon motor GmbH, Sexau, has been certified under ISO 13485:2003 for the development, production and distribution of ceramic implants. It also complies with these guidelines for the manufacture of these drills.

maxon motor GmbH

Untere Ziel 1, 79350 Sexau, Germany

Tel.: +49-76 41/91 14-113

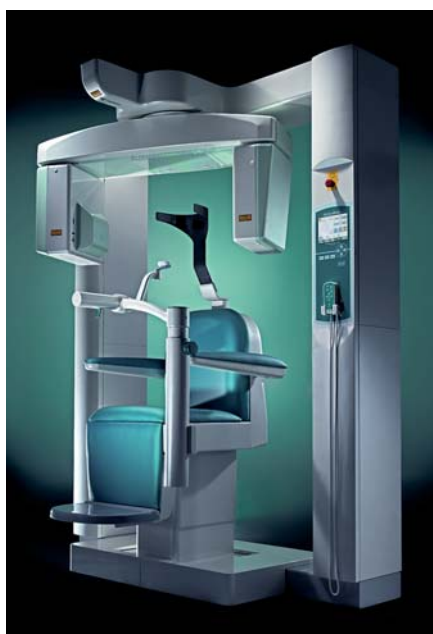E-mail: ceramic@maxonmotor.com

www.maxonceramic.com

J. Morita

3D Accutomo provides four new image formats

New intermediate formats permit the ambitious diagnostician to make use of a total of nine imaging formats. J. Morita have now enhanced the capability of the 3D Accutomo by adding another four image sizes. Visitors to this year's IDS in Cologne were genuinely pleased to see the image quality across the whole range from $\varnothing 40 \times H 40$ to $\varnothing 170 \times H 120$ mm. Even the sceptics will be convinced by the resolution realized by the voxel size of $80 \mu m$ in the largest format. The large field of view (FOV) is suitable for the precise diagnosis of the whole head region. Enhanced image dynamics enable greater precision in the visualization of hard and soft tissue. The built-in flat panel detector (FPD) technology provides a 14-bit greyscale and creates a balanced distribution of the contrasts. The 3D Accutomo can



3D Accutomo 170: High resolution from $\varnothing 40 \times H 40$ mm up to $\varnothing 170 \times H 120$ mm

be used with many different applications, for example in the fields of implant therapy, for examinations of apical lesions, images of jaw joint, impactions, endodontics, restorative dentistry and surgery. The practitioner chooses between imaging regions without having to forego consistent high-resolution. Patient radiation dosage remains low. The especially developed zoom-reconstruction function is also a feature of the 170 version. This "magnifying lens" permits, for example, using a 80×80 image with a voxel size of $160 \mu m$ to produce detailed views of the regions of interest with a voxel size of $80 \mu m$. And the enlarged image with $80 \mu m$ is even sharper. This eliminates the need to make secondary detailed images which could expose patients to X-rays unnecessarily.

J. Morita Europe GmbH

Justus-von-Liebig-Straße 27a

63128 Dietzenbach, Germany

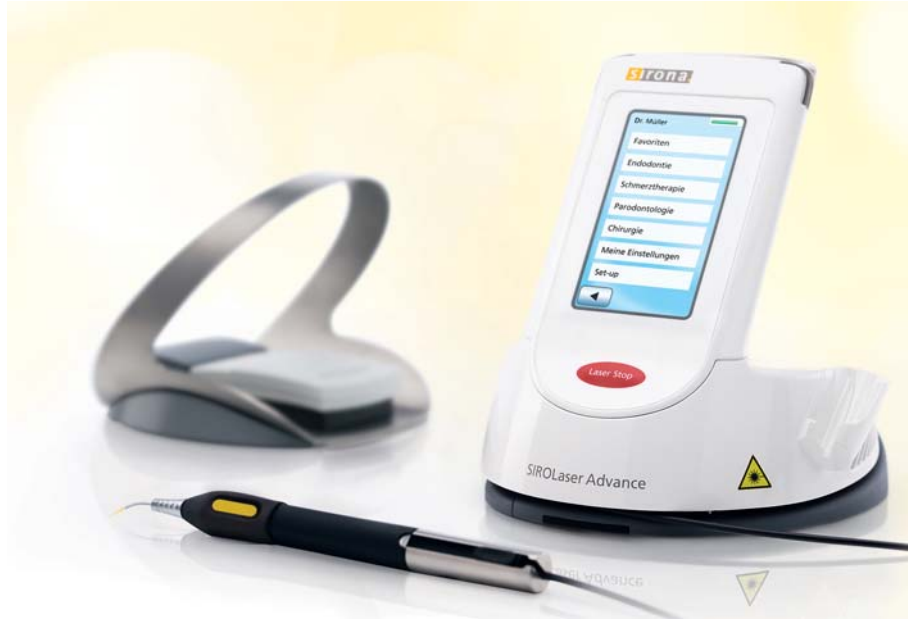E-mail: info@jmoritaeuropa.com

Web: www.jmoritaeuropa.com

Sirona

SIROLaser Advance sets new standards of user-friendliness and flexibility

Sirona's SIROLaser Advance combines state-of-the-art laser technology with outstanding user-friendliness. The color touchscreen, clearly structured menus and self-explanatory symbols provide the ideal basis for easy operation. The SIROLaser Advance caters for a broad spectrum of applications. The pre-set programs ensure quick and effective therapy in the area of periodontics, endodontics, surgery and pain relief. If required the dentist can view additional information about each individual preset in a help menu. The dentist is free to adapt the SIROLaser Advance to his or her individual mode of working. Up to 24 different applications can be programmed. In his role as system administrator the dentist can also configure profiles for five additional users. In addition, the SIROLaser Advance anonymously stores the parameter data of each treatment session. For patient documentation purposes this data can be easily transferred to a PC with the aid of a USB flash drive.



The SIROLaser Advance offers preset therapy programs for the most important laser applications in the field of periodontics, endodontics, surgery and pain relief.

The SIROLaser Advance is operated via the light-touch finger switch or via the optional foot control. In combination with the high-power rechargeable battery pack the SIROLaser Advance can be deployed flexibly in the dental practice.

Sirona Dental Systems GmbH

Fabrikstraße 31
64625 Bensheim, Germany
E-mail: contact@sirona.de
Web: www.sirona.de

Implant Direct

The world's first one-piece Locator Implant

Implant Direct, Europe's No. 1 Online Provider for Dental Implants, launches the world's first one-piece Locator Implant called GoDirect. This patented implant innovation by Dr. Gerald Niznick, US based pioneer in implant dentistry, incorporates a Locator component in a one-piece implant.



The implant will be launched in the diameters 3.0 mm, 3.7 mm, 4.7 mm and in the length 10 mm, 11.5 mm and 13 mm whilst the prosthetic Locator component comes in variable heights of 2 and 3 mm. The Locator interface is compatible with the currently available Locator prosthetic components, as well as instruments. The All-in-One Packaging approach of Implant Direct includes the Locator Implant, an impression cap and a

snap-on comfort cap for the direct price of 115 Euro per package. This innovative added value package allows to reduce costs for hybrid treatment options whilst maintaining high quality standards.

Implant Direct Europe
Förllibuckstrasse 150
CH-8005 Zürich, Switzerland
Tollfree Infoline: 00800/40 30 40 30
E-mail: info-eu@implantdirect.com
Web: www.implantdirect.de

Omnia

Basic Implant Set by Omnia

The sterile Basic Implant Set by Omnia was designed for implant surgery, where a suitable level of sterility and safety for both surgeon and patient is required. It is indicated for small surgery, packaged in double sterile wrapping and consists of one



operator gown SMS size L, one assistant gown, two operator caps, one patient cap, one drape 2-layers

50 x 75 cm with adhesive size, one patient drape 2-layers 75 x 90 cm with adhesive U-shape, tubing sleeves 120 cm Omnisleave, and one waste bag

Omnia S.p.A
Via F. Delnevo 190
43036 Fidenza (PR), Italy
E-mail: info@omniasrl.com
Web: www.omniasrl.com

Straumann

Roxolid™—Increasing the choice of treatment options

Mechanical stability and osseointegration are of highest importance with small diameter implants. Designed specifically for dental implants, Roxolid™ has higher fatigue and tensile strengths than pure grade 4 titanium. Straumann's new high performance material is an alloy of titanium and zirconium – the only two metals commonly used in implantology that do not inhibit the growth of bone forming osteoblast cells which are essential for osseointegration. Preclinical studies have shown that bone integration is better with Roxolid than with pure titanium. Furthermore, Roxolid implants feature Straumann's SLActive® surface technology, cutting implant healing times in half as compared to the gold standard SLA® surface. This delivers peace of mind for

treatments with small diameter implants. Roxolid has been undergoing one of the largest clinical research programs ever undertaken by a dental implant company prior to market launch. Roxolid small diameter implants are expected to offer a number of advantages to dental professionals and patients, particularly in situations where space between teeth is limited or where bone preservation is a major concern. These benefits, combined with less invasive treatments, might open the door for clinicians to increase patients' acceptance to implant treatment.

After having obtained regulatory clearance, Roxolid is now available in North America and in Europe.

Institut Straumann AG

Peter Merian-Weg 12
CH-4052 Basel, Switzerland
E-mail: info@straumann.com
Web: www.straumann.com

Dr. Ihde Dental

Dr. Ihde Dental—the implant company

Dr. Ihde Dental is a well-known manufacturer of consumables and implant systems active in Germany

and in many parts of Europe. The company is in the business of marketing all popular implant systems and prosthodontic accessories for all implant-supported indications, along with a broad range of everyday little helpers and consumables for the dental office and laboratory.

Dr. Ihde Dental has been producing implant systems since 1996, turning into a true implant company, an international player in this market. All implant lines are continuously expanded, improved, and updated to incorporate and accommodate the most current scientific findings in oral implantology. In addition, Ihde Dental closely cooperates with well-renowned oral implantologist of many years' standing to ensure that its implants meet all the requirements of everyday clinical practice. All implants are produced

in Europe, meeting the most stringent German and Swiss quality standards. The Dr. Ihde Dental implant lines have been proven for many years and can be used simply and safely for all indications. Some systems are designed to permit immediate loading, The KOS implant, for example, allows this attractive treatment modality to be employed in a manner that is particularly appreciated by patients. The implant is inserted transgingivally; the definitive restoration can be delivered within only five days.

Dr. Ihde Dental GmbH

Erfurter Straße 19
85386 Eching, Germany
E-mail: info@ihde.com
Web: www.ihde-dental.de

AD



Since our beginnings, we have always been focused on quality and innovation toward the battle against cross-contamination and infections.

In the last 20 years, we have ensured safety and protection to you and your patients, with advanced and reliable products. Tools that represent the ideal solution for who is operating in dentistry, implantology/oral surgery and general surgery.

With Omnia sure to be safe.

Surgical Line **Safety Line** **MAXII®**



OMNIA®
Disposable Medical Devices

OMNIA S.p.A.
Via F. Delnevo, 190 - 43036 Fidenza (PR) Italy
Tel. +39 0524 527453 - Fax +39 0524 525230
www.omniasrl.com

CAMLOG

Cooperation with Materialise Dental and SICAT

The CAMLOG® Guide System, the precise system for safe, template-guided implantation and temporary restoration can from now on also be used with the planning softwares from Materialise Dental and SICAT. The computer-aided, three-dimensional planning systems Materialise Dental "SimPlant®", SICAT "GALILEOS Implant" and "SICAT Implant" enlarge the CAMLOG® Guide System application possibilities not only through further program options but also through centrally manufactured drilling templates. With the new coop-

erations, CAMLOG users are offered an ideal expansion of possibilities in addition to the CAMLOG® Guide System's specific advantages such as:

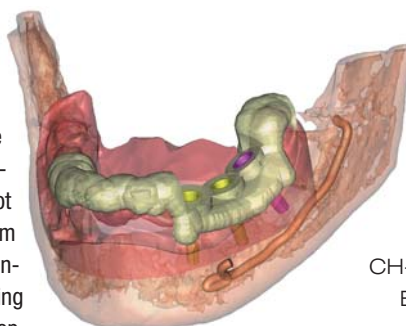
- _ only few drills necessary;
- _ only one guiding sleeve with fixed depth stops on drills and insertion posts of the implants;
- _ accurate guidance of instruments and implants;
- _ no investment in additional instrument trays.

C. HAFNER's „CeHa imPLANT®" and IVS' „coDiagnostiX®" planning systems continue to be compat-

ible with the CAMLOG® Guide System and allow decentralized fabrication of drilling templates in the dental laboratory.

CAMLOG Biotechnologies AG

Margarethenstrasse 38
CH-4035 Basel, Switzerland
E-Mail: info@camlog.com
Web: www.camlog.com



THE BUSINESS OF DENTISTRY



**INTERNATIONAL DENTAL
EXHIBITION AND MEETING
April 16-18, 2010**

The Sourcing & Education Platform in the Asia Pacific

Join a turnout of over 6,000 manufacturers and distributors, potential partners, visitors and delegates from across the globe. IDEM Singapore 2010 is enriched with opportunities from trading and showcasing of high-quality dental equipment to learning and development in the field of dental practice. This event is a "must-attend" for every dental and associated professionals.

Uniquely Singapore: Where Great Things Happen

Now ranked among the world's top cities for meetings, Singapore is also a country with one of the most sophisticated dental markets. Come discover a world of unique contrasts in Singapore and sample an exciting weekend in this beautiful multi-cultural garden city.

Endorsed By:



Supported By:



Held In:



In Cooperation With:



Organizers:



International
Ms Sharon Ng
Tel: +65 6500 6722
Fax: +65 6296 2771
s.ng@koelnmesse.com.sg

Europe Only
Ms Daniela Basten
Tel: +49 221 821 3267
Fax: +49 221 821 3671
d.basten@koelnmesse.de

Singapore Dental Association

we energize your business

implants

international magazine of oral implantology



Publisher	Torsten R. Oemus	oemus@oemus-media.de
CEO	Ingolf Döbbecke Jürgen Isbaner Lutz V. Hiller	doebbecke@oemus-media.de isbaner@oemus-media.de hiller@oemus-media.de
Chief Editorial Manager	Dr Torsten Hartmann (V. i. S. d. P.)	hartmann@dentalnet.de
Editorial Council	Dr Friedhelm Heinemann Dr Roland Hille Dr Winand Olivier Prof Dr Dr Kurt Vinzenz Dr Torsten Hartmann Dr Suheil Boutros	friedhelmheinemann@web.de dr-hille@t-online.de dr.olivier@t-online.de kurt.vinzenz@aon.at hartmann@dentalnet.de SMBoutros@aol.com
Editorial Office	Kristin Urban Katja Kupfer	k.urban@oemus-media.de kupfer@oemus-media.de
Executive Producer	Gernot Meyer	meyer@oemus-media.de
Art Director	Sarah Fuhrmann	s.fuhrmann@oemus-media.de
Customer Service	Marius Mezger	m.mezger@oemus-media.de
Published by	Oemus Media AG Holbeinstraße 29 04229 Leipzig, Germany Phone: +49-3 41/4 84 74-0 Fax: +49-3 41/4 84 74-2 90 E-mail: kontakt@oemus-media.de	

implants international magazine of oral implantology is published in cooperation with the German Association of Dental Implantology (DGZI).

DGZI President
Dr Friedhelm Heinemann
DGZI Central Office
Feldstraße 80, 40479 Düsseldorf, Germany
Phone: +49-2 11/1 69 70-77
Fax: +49-2 11/1 69 70-66
E-mail: office@dgzi-info.de

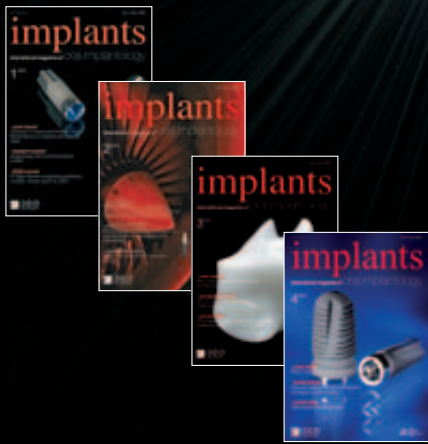www.dgzi.de
www.oemus.com

implant_Copyright Regulations

_the international magazine of oral implantology is published by Oemus Media AG and will appear in 2009 with one issue every quarter. The magazine and all articles and illustrations therein are protected by copyright. Any utilization without the prior consent of editor and publisher is inadmissible and liable to prosecution. This applies in particular to duplicate copies, translations, microfilms, and storage and processing in electronic systems. Reproductions, including extracts, may only be made with the permission of the publisher. Given no statement to the contrary, any submissions to the editorial department are understood to be in agreement with a full or partial publishing of said submission. The editorial department reserves the right to check all submitted articles for formal errors and factual authority, and to make amendments if necessary. No responsibility shall be taken for unsolicited books and manuscripts. Articles bearing symbols other than that of the editorial department, or which are distinguished by the name of the author, represent the opinion of the afore-mentioned, and do not have to comply with the views of Oemus Media AG. Responsibility for such articles shall be borne by the author. Responsibility for advertisements and other specially labeled items shall not be borne by the editorial department. Likewise, no responsibility shall be assumed for information published about associations, companies and commercial markets. All cases of consequential liability arising from inaccurate or faulty representation are excluded. General terms and conditions apply, legal venue is Leipzig, Germany.

implants

International magazine of oral implantology



for specialists around
the world

Hereby I wish to subscribe to **implants** (4 issues per year)

44 €* for German Customers | 46 €* for Customers outside Germany

*all prices include shipping and handling costs

PERSONAL DETAILS/SHIPPING ADDRESS

Name

Position/Dept.

Company

Address

Country/ZIP

Telephone

Facsimile

E-mail

Date/Signature

Your personal data will be recorded and retained by Oemus Media AG, Holbeinstraße 29, 04229 Leipzig, Germany. Your personal data is used for internal purposes only. The subscription will be renewed automatically every year until it is cancelled six weeks in advance before renewal date.

IM 4/09

PAYMENT OPTIONS

Credit Card: VISA

MasterCard

Card Number

Expiry date

Name (as it appears on the card)

KPN/CW2/CVC2 No.

3-4 digits in the signature area on the back of the credit card

OEMUS MEDIA AG

Holbeinstraße 29

04229 Leipzig, Germany

Tel.: +49-3 41/4 84 74-2 01

Fax: +49-3 41/4 84 74-2 90

www.oemus-media.de

grasse@oemus-media.de



EXTRAORDINARY

Introducing a new implant from one of the most respected names in dentistry - *Sybron*. Our new Sybron**PRO™XRT** incorporates an extraordinary array of features proven to address immediate stability, preservation of crestal bone², and long-term aesthetics.

Call us today to experience the EXTRAORDINARY for yourself!

¹Surgical and Mechanical Techniques to Increase Stability of Dental Implants. Kharouf, Zeineb; Oh, Hyeong Cheol; Saito, Hanae; Cardaropoli, Giuseppe; Bral, Michael; Cho, Sang-Choon; Froum, Stuart; Tarnow, Dennis. Ashman Department of Periodontology and Implant Dentistry, New York University. Research presented at the AO Boston 2008.

²Implant Design and Its Effect on Preservation of Crestal Bone Levels. Jang, Bong-Joon; Pena, Maria Luisa; Kim, Mean Ji; Eskow, Robert; Elian, Nicolas; Cho, Sang-Choon; Froum, Stuart; Tarnow, Dennis. Ashman Department of Periodontology and Implant Dentistry, New York University. Research presented at the AO Boston 2008.

Sybron – Celebrating over 100 years of dental excellence


Europe
Sybron Implant Solutions GmbH
Julius-Bamberger-Str. 8a
28279 Bremen, Germany
T 49.421.43939.0
info@sybronimplants.de

United Kingdom
4 Flag Business Road
Vicarage Farm Road
Peterborough, PE1 5TX, UK
T 008000 841 2131

France
16 Rue du Sergent Bobillot
93100 Montreuil, France
T 33.149.88.60.85

Australia
10, 112-118 Talavera Rd
North Ryde, NSW 2113
T 61.2.8870.3099

HEADQUARTERS
USA
1717 West Collins Avenue
Orange, California 92867
T 714.516.7800



www.sybronimplants.com

Standard World
Leader



This is
the First

TSIII SA

OSSTEM[®]
IMPLANT



Tel: +98 21 88 98 80 63 - 6

Web: Azadmed.com