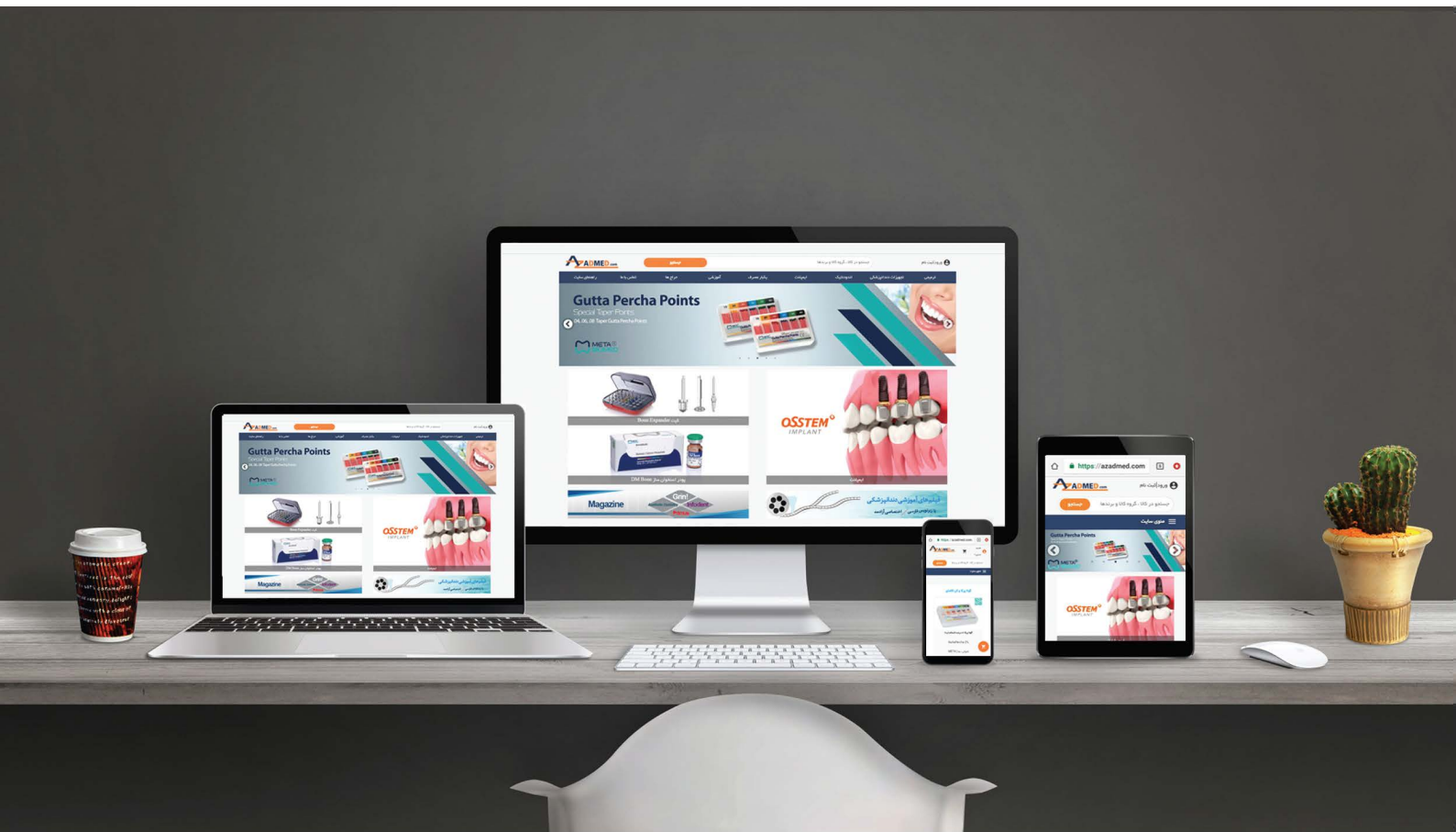




**AZADMED.com**



[www.azadmed.com](http://www.azadmed.com)



 [azaadtejaratpars](https://www.instagram.com/azaadtejaratpars)

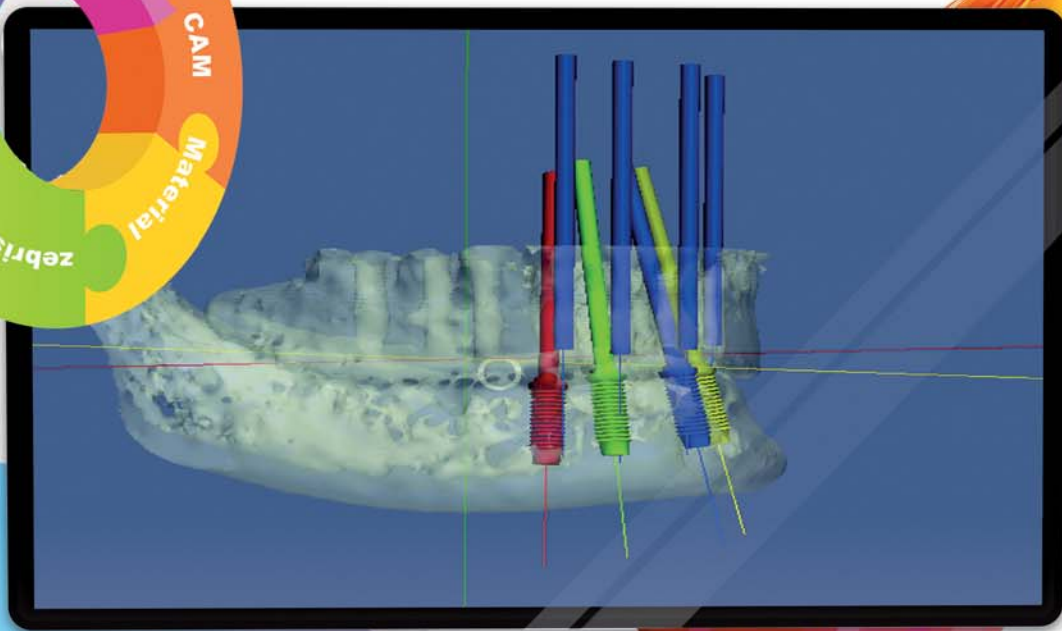
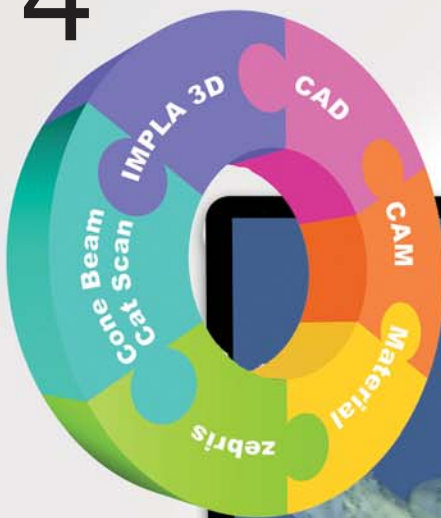
 [@azadmed2](https://www.telegram.com/@azadmed2)

 88 98 80 63 - 6

# implants

international magazine of oral implantology

4<sup>2011</sup>



| **clinical study**

Flapless implant surgery and its effect on peri-implant soft tissue

| **case study**

New concepts in computer-guided implantology

| **meetings**

Implantology in Cologne



# More options, same original body.

---

Two new connections  
to choose from.

---

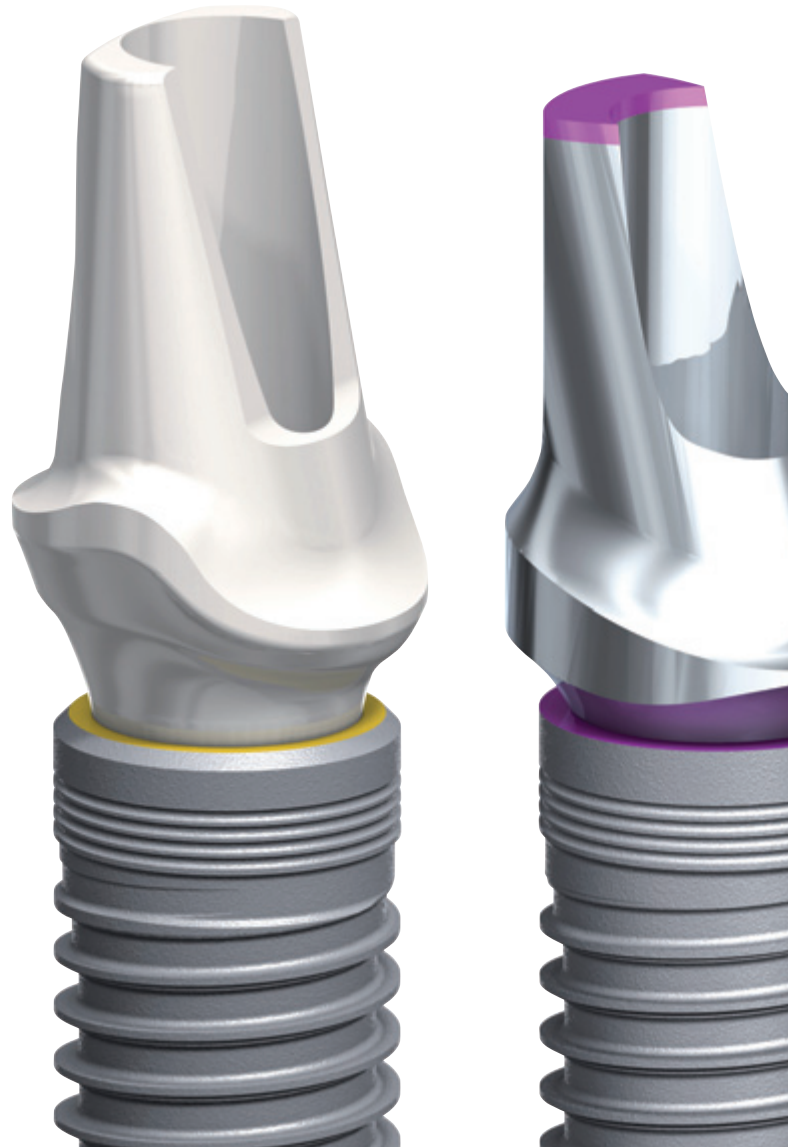
Designed to maximize  
soft tissue volume.

---

Established and clinically  
proven tapered implant body.

NEW

With platform  
shift and conical  
connection



**They're called NobelReplace Conical Connection and NobelReplace Platform Shift.** Broaden your restorative options while keeping the benefits of the clinically proven NobelReplace Tapered implant, such as color-coded components and standardized step-by-step drill protocol for ease-of-use and predictable outcomes. Developed for restorations in the esthetic region, NobelReplace Conical

Connection combines platform shifting with a strong sealed connection, whereas NobelReplace Platform Shift offers platform shifting on the internal tri-channel connection with its unrivalled tactile feel. After 45 years as a dental innovator we have the experience to bring you future-proof and reliable technologies for effective patient treatment. **Their smile, your skill, our solutions.**



Visit [nobelbiocare.com/replaceccps](http://nobelbiocare.com/replaceccps)



# What **should** and what **must** be done?



Dr Georg Bach

**—Certainly many readers must have chuckled** when they read the main topic of the podium discussion of DGZI's 41<sup>th</sup> International Annual Congress, which has now concluded. Not only did the city of Cologne show its nicest and most hospitable sides, but the congress itself also pleased and satisfied our members, friends, and guests from abroad. The congress' two training days packed with information, its attractive dental exhibition and its thorough and perfect organization (for which we kindly give our thanks to the Oemus Media AG Team) will surely leave lasting and positive impressions on all participants. There was a good deal of enthusiastic debate, controversial discussions, and even a fight or two in Cologne!

The latter of course took place only in the typically friendly and collegial DGZI manner. The podium discussion in particular highlighted many recent different developments in implantology, some of the possibilities relating to those developments and the existing differences in qualification, knowledge and opinions.

Neither DGZI nor the audience have succumbed to the temptation to commit completely and exclusively to one or another philosophy. As is so often the case in life—the happy medium is best choice.

## **What should and what must be done?**

In the end, and whatever you decide to do, it will be up to you, dear readers and friends. You have to take your decisions according to your expertise, your experience and your skills!

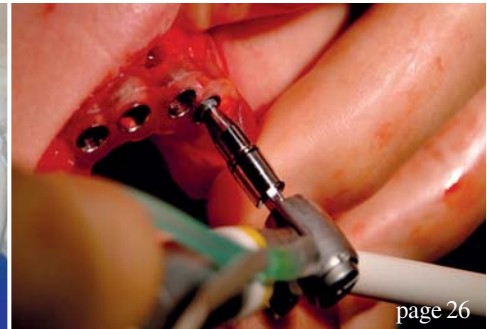
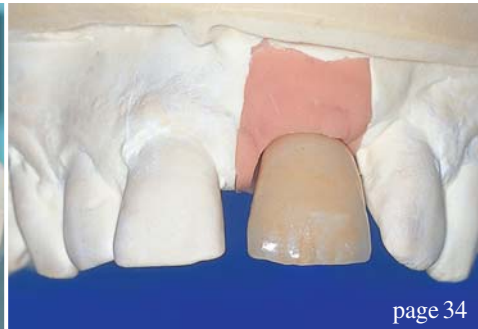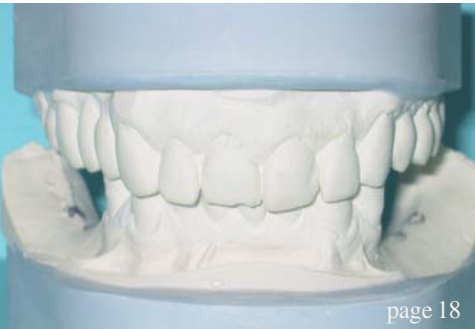We hope that our congress was of some (ideally even much) help in your important decision making. We also hope to have reduced the existing inhibition levels with regard to new techniques and possibilities, because one can only take a decision and balance between "digital" and/or "conventional" treatments when looking at the issues neutrally.

At this point, I would like to cite Prof. Dr. Dr. Frank and say that, "Digital implantology is not the future—digital implantology is today!"

With this in mind, I wish you a happy reading of our up-to-date Implantology Journals.

Dr Georg Bach  
Course instructor for DGZI continuing education





| editorial

- 03 What **should** and what **must** be **done**?  
| Dr Georg Bach

| clinical study

- 06 **Flapless implant surgery** and its effect on **peri-implant soft tissue**  
| Dr Kai Höckel *et al.*
- 18 Consideration of an **uncommon approach** in the atrophied posterior zone  
| Dr Maen Aburas *et al.*

| case study

- 26 **New concepts** in computer-guided implantology  
| Dr Gian Luigi Telera

| user report

- 34 Second implantation after **implant fracture**  
| Dr Michael Hopp *et al.*
- 38 Use of **tilted implants** in the **treatment** of the edentulous posterior maxilla  
| Prof Gregor-Georg Zafiroopoulos

| education

- 40 Fascination of **Laser Dentistry**

| meetings

- 42 **Implantology** in Cologne  
| Jürgen Isbaner
- 44 **20<sup>th</sup> Annual Congress of the EAO**  
| Daniel Zimmermann
- 49 **International events 2012**

| news

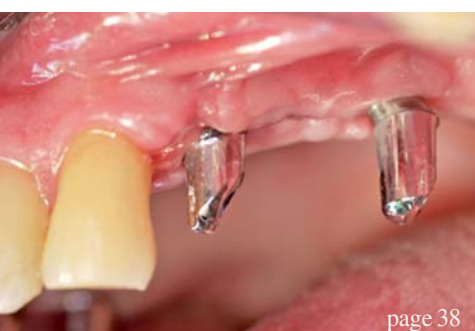- 46 **Manufacturer News**

| about the publisher

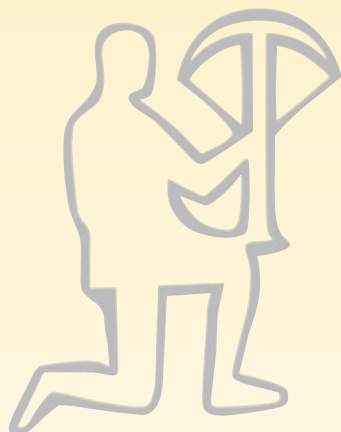
- 50 | imprint







Cover image "Complete Digital Workflow" courtesy of Schütz Dental, [www.schuetz-dental.com](http://www.schuetz-dental.com)  
Artwork by Sarah Fuhrmann, Oemus Media AG.



# IMPLA™ Implants - simply safe



	<p><b>IMPLA™ Dual Surface</b></p> <ul style="list-style-type: none"> <li>• ideal for compact bone</li> <li>• optimised for gingiva-level insertion</li> </ul>
	<p><b>IMPLA™ Micro Retention</b></p> <ul style="list-style-type: none"> <li>• optimised for soft bone and sinus elevation</li> <li>• ideal for primary stability</li> </ul>
	<p><b>IMPLA™ Mini Implant</b></p> <ul style="list-style-type: none"> <li>• ball or conical attachment</li> <li>• minimally invasive</li> <li>• easy to insert</li> </ul>
	<p><b>IMPLA™ Cylindrical</b></p> <ul style="list-style-type: none"> <li>• no additional thread cutting necessary</li> <li>• integrated platform switching</li> </ul>



**IMPLA™ 3D**  
Navigation



**IMPLA™ surgery box**  
The all-round box

For more information visit our homepage  
[www.schuetz-dental.com](http://www.schuetz-dental.com)  
or request our catalog!



# Flapless implant surgery and its effect on peri-implant soft tissue

## A prospective longitudinal clinical study

**Authors**\_Dr Kai Höckl, Prof Peter Stoll, Dr Georg Bach, Prof Wolfgang Bähr & Verena Stoll, Germany

### Abstract

#### *Background and aim*

Minimally invasive implant insertion may offer the reduction of peri-implant inflammation, pocket depth and crestal bone loss, as well as minimisation of post-surgical complications. The goal of the present study was to clinically investigate the soft-tissue response and to compare the outcome obtained with flapless, placed implants of three different manufacturers.

#### *Materials and methods*

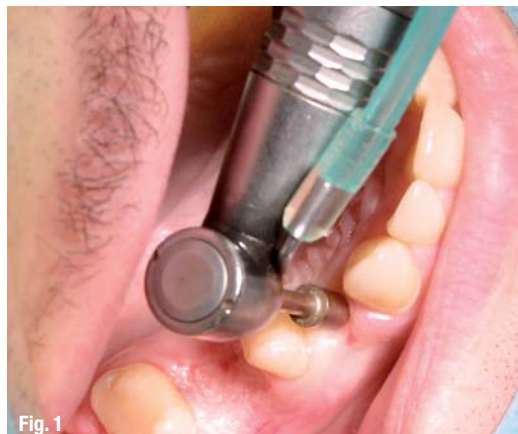In this clinical study, 346 implants inserted in 115 patients between January 2001 and February 2009 were examined. A total of 337 two-piece titanium (235 Straumann and 102 Thommen) and nine one-piece zirconium-dioxide implants (Z-Systems) were used. The patient sample included seven smokers, two patients with diabetes mellitus, seven patients

with bleeding disorders and one patient undergoing intravenous bisphosphonate therapy. Regular clinical examination of stability and peri-implant soft-tissue status was performed one, two, three, four and 16 weeks after implant insertion.

All implants were loaded for at least 12 months with either fixed or removable prosthetic restorations. Attachment level, bleeding on probing (BOP), secretion, plaque and keratinised gingiva were documented.

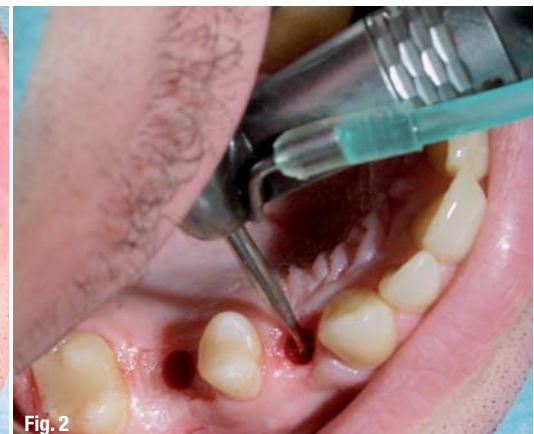#### *Results*

After loading, one of the 347 implants was lost. The survival rate of the Straumann implants ( $n = 235$ ) was 99.6%, that of the Thommen implants ( $n = 102$ ) was 100% and that of the Z-Systems implants ( $n = 9$ ) was 100%. Thus, the general survival rate was 99.9% after a mean follow-up period of three years and eight months.



**Fig. 1** \_Tissue punch to expose the alveolar crest.

**Fig. 2** \_Start of the drill sequence with the rose drill.



**Fig. 2**

## CHEAPLY IMPLANTS BETTER IMPLANTS AS IHDE DENTAL



SAY IT TO ALL!

[www.banal-implants.de](http://www.banal-implants.de)



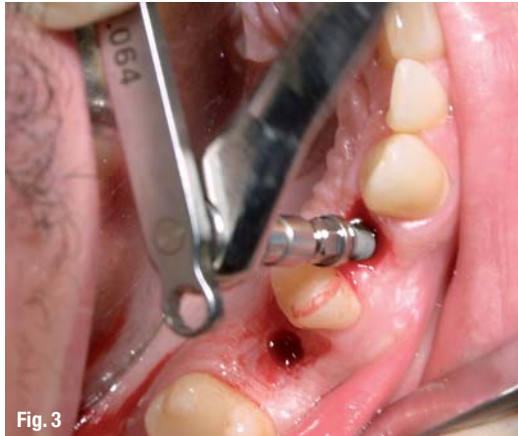

Fig. 3

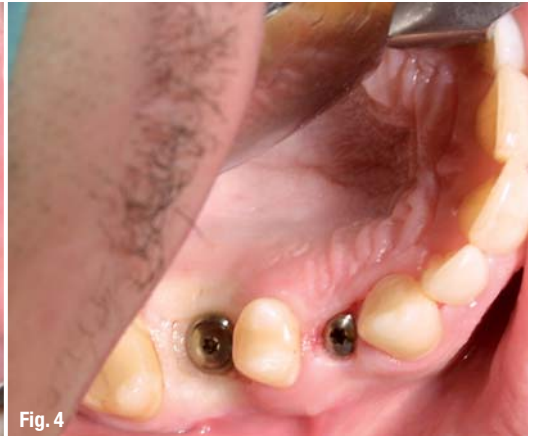

Fig. 4

Fig. 3\_Flapless implant insertion.

Fig. 4\_Immediately after implant insertion.

A positive bleeding score (BOP) was found at 106 of the 346 implant sites (30.63%). A significant difference was documented between Straumann implants, where bleeding occurred only in 14.9%, and Thommen implants, where a positive bleeding score was found in 38.2%.

No differences between the three implant types were found in terms of probing depth (PD). The mean PD was 2.4 mm irrespective of the implant design. Bleeding score was significantly higher for those implants without keratinised mucosa. Of the Straumann implants, 161 were surrounded by a band of keratinised tissue, as were 74 Thommen implants. Only 38 Straumann (26.4%) and 22 Thommen (30.6%) implants showed positive BOP. Eight of the nine Z-Systems implants were placed in keratinised mucosa and none of them showed any signs of inflammation.

#### Conclusions and clinical implications

The results presented in this article demonstrate that healthy peri-implant soft tissue can be obtained following minimally invasive surgery and transgingivally placed implants. Flapless implant insertion shows a success rate comparable to conventional implant surgery. The results of this study prove that flapless implant surgery is a predictable procedure. In addition, our findings lead to the conclusion that a band of keratinised gingival tissue around implants minimises soft-tissue bleeding.

#### \_Introduction

In conventional implant surgery, more or less extensive flaps are created to expose the surgical field. Since the beginnings of implantology, the technique has been gradually modified and refined to the one- or two-stage procedures most frequently used today. Despite these modifications, the surgical process has remained remarkably constant. After exposure of the jaw bone by preparing a mucoperiosteal flap, the implant is inserted into a cavity cre-

ated by careful bone drilling. Thereafter, the covering soft tissue is sutured to its previous place (Adell *et al.* 1985).

Initial bone loss seems to be caused by interrupted blood supply that follows removal of the periosteum (Ramfjord & Costich 1968; Wood *et al.* 1972; Kleinheinz *et al.* 2005). Flapless procedures utilise only a small soft-tissue punch to expose the alveolar crest (Fig. 1). The size of the surgical field corresponds therefore to the implant diameter.

The term "minimally invasive" or "flapless" implant surgery describes an alternative procedure to conventional incision and flap preparation (Figs. 2–4; Sclar 2007). In addition, this atraumatic approach allows good preservation of the anatomically important gingival and periodontal structures (Al-Ansari & Morris 1998; Zetz & Qureshy 2000; Kan *et al.* 2000). Flapless surgery is becoming increasingly popular and patient acceptance of this procedure is very high. The limited surgical trauma minimises: (a) intra-operative bleeding; (b) surgical time; (c) risk of infection; and (d) post-surgical complaints such as swelling and pain related to the surgical trauma. In many cases, second-stage surgery, i.e. measures to expose the implant shoulder, can be avoided (Stoll 2008). Flapless surgery may help to avoid significant bone loss. The tissue punch used has a diameter similar to that of the inserted implant. Animal studies have demonstrated the importance of the punch diameter. A punch diameter that is minimally smaller than the implant diameter had a positive effect on healing (Lee *et al.* 2009).

It is well known that conventional surgical procedures using titanium screw implants result in very successful long-term survival rates of 94 to 99% (Adell *et al.* 1985; Behneke *et al.* 2000; Cochran *et al.* 2002; Roos-Jansaker *et al.* 2006). This longitudinal study aimed to determine whether flapless, i.e. transgingival, minimally invasive, implant placement can lead to a success rate comparable to con-

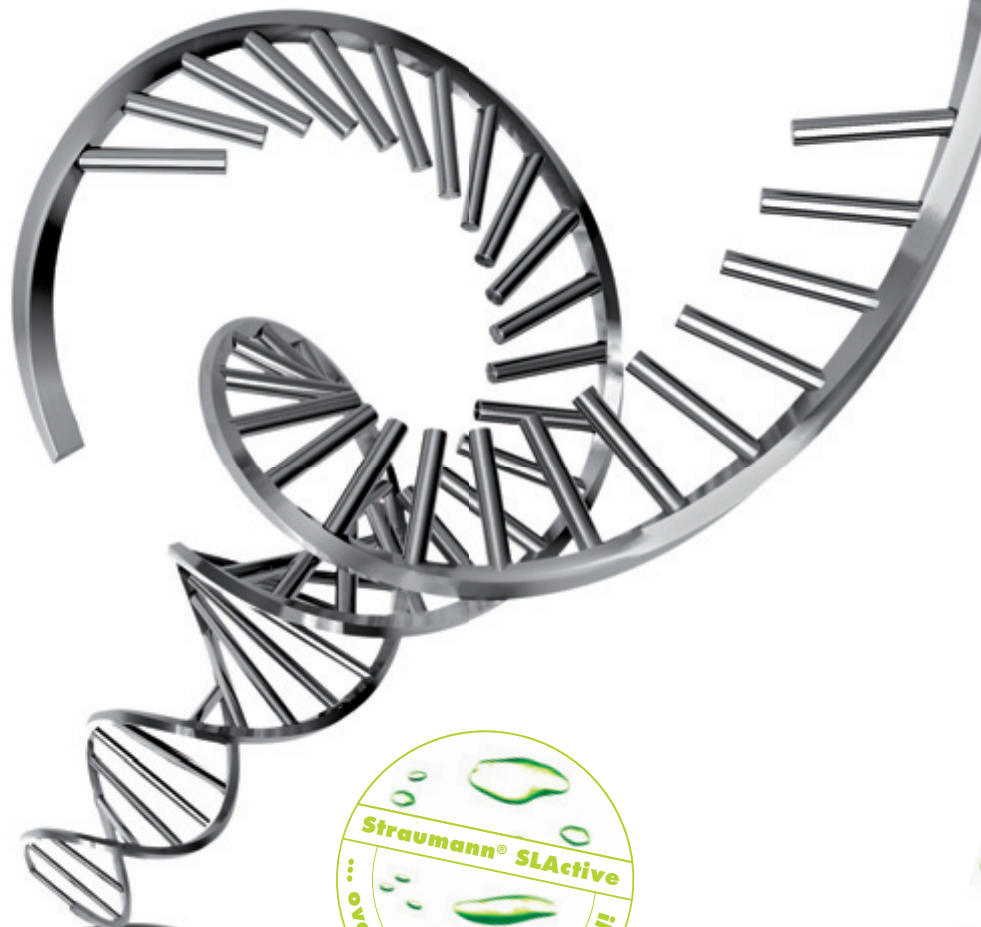


## ROXOLID®

# THE NEW "DNA" OF IMPLANT MATERIALS

**ROXOLID®** – Exclusively designed to meet the needs of dental implantologists.

Roxolid® offers ■ Confidence when placing small diameter implants ■ Flexibility of having more treatment options ■ Designed to increase patients' acceptance of implant treatment



Please contact us at **+41 (0)61 965 11 11**. More information on [www.straumann.com](http://www.straumann.com)

COMMITTED TO  
**SIMPLY DOING MORE**  
FOR DENTAL PROFESSIONALS

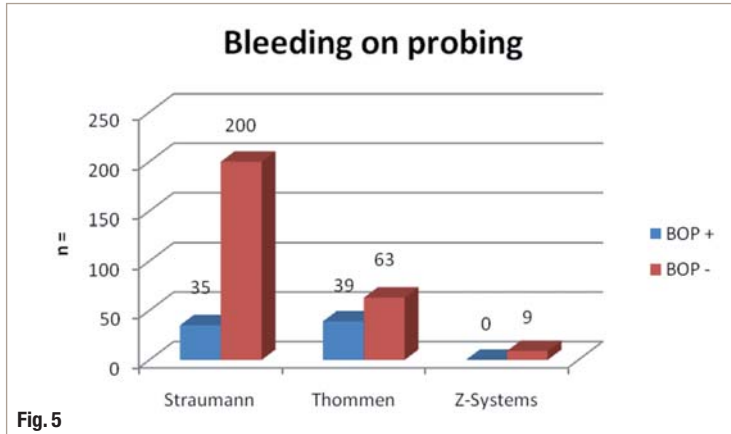


Fig. 5 Bleeding on probing.

ventional insertion. The clinical performance of dental implants with different design (two types of titanium two-piece implants with different machined collar height and zirconium-oxide one-piece implants) and from different manufacturers was compared. Soft tissue health was evaluated in particular. The relationship of keratinised mucosa and the health status of peri-implant soft tissue was analysed.

### \_Materials and methods

In this study, 347 implants inserted between January 2001 and February 2009 were evaluated. All were placed by one surgeon using the flapless surgical protocol. The patients were recruited from the six months resp. one-year recall programme.

For the purposes of the clinical longitudinal study, 115 (67 female and 48 male) patients with a mean age of 63 (18 to 85) were followed up. They received a total of 347 implants: 236 Straumann, 102 Thommen and nine Z-Systems. The patient sample included seven smokers, two patients with diabetes (receiving oral antidiabetics), seven patients with hemorrhagic diathesis (receiving oral anti-coagulants) and one patient with intravenous bisphosphonate therapy. Patients were excluded

Fig. 6 Probing depth PD distribution.

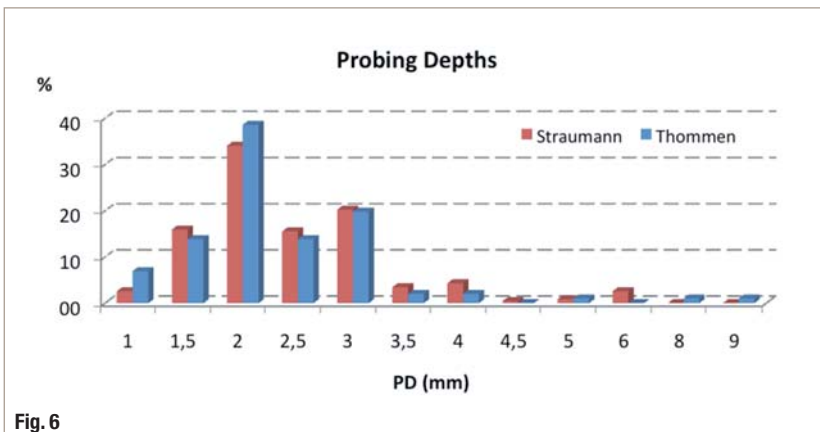


Fig. 6

from the study if they showed severe general medical contra-indications. Patients elected received one shot of standard prophylactic antibiotics (penicillin 1 Mio IU or clindamycin 600 mg p.o.) one hour before surgery. The implant bed was prepared according to the recommendations and instrumentation of each manufacturer.

Straumann (Standard and Standard+) and Thommen Medical (ELEMENT and CONTACT) titanium two-piece implants, and Z-Systems zirconium-dioxide one-piece implants (Z-Look3) were used. The implants used had a platform diameter of 3.5 to 6.5 mm (Straumann: 3.5 mm, 4.8 mm and 6.5 mm; Thommen: 3.5 mm, 4 mm, 4.5 mm and 5 mm; Z-Systems: 5 mm and 6 mm). The soft-tissue punches used in this study showed a diameter of 4 or 5 mm.

Post-operative clinical examination of stability and peri-implant soft tissue was performed one, two, three, four and 16 weeks after implant insertion. Radiological examination was done before and immediately after implant surgery, after osseointegration and one year after prosthetic loading. All implants were loaded for at least 12 months with either fixed or removable prosthetic restorations.

Mouth hygiene was assessed visually and classified into four categories: very good (no plaque, no tartar), good (little plaque, little tartar), medium (some plaque, some tartar) and poor (excessive plaque, excessive tartar). The presence or absence of keratinised gingiva was also recorded.

The gingival depth resp. thickness around the implant neck was measured with a calibrated probe. The measurement was done with slight pressure exerted from the gingival margin until resistance was encountered. For implants, as opposed to natural teeth, an increased pocket depth of up to 4 mm is acceptable without further measurements (Behneke *et al.* 1997). This is due to the parallel orientation of the connective tissue fibres. Bleeding on probing and pathological secretion were recorded. Selected results were tested by means of the Wilcoxon U test (NPAR1WAY procedure, SAS Ver. 9.1.3.) for non-normally distributed data. Significance was assumed if  $p < 0.05$  ( $\alpha = 5\%$ ). The number of tests was limited to minimise the probability of false-positive results.

### \_Results

The 3.75 (0.25–9.7) year follow-up period of all implants showed only one failed (explanted) implant (Straumann). This was due to peri-implant in-



4<sup>TH</sup> INTERNATIONAL

# CAMLOG CONGRESS

MAY 3<sup>RD</sup> – 5<sup>TH</sup>, 2012

LUCERNE, SWITZERLAND



## FEEL THE PULSE OF SCIENCE IN THE HEART OF SWITZERLAND

- "State of the art" in implant dentistry
- Internationally renowned scientific committee, well-known speakers
- First-class workshops
- Lucerne – world-famous congress venue
- Groovy party – "Let's rock the Alps!"
- Attractive partner programs in Lucerne and surroundings
- Excellent price-performance ratio

## SCIENTIFIC COMMITTEE

Prof Jürgen Becker, Prof Fernando Guerra, Prof Frank Schwarz,  
Prof Thomas Taylor, Prof Hendrik Terheyden,  
Prof Georg Watzek, Prof Axel Zöllner





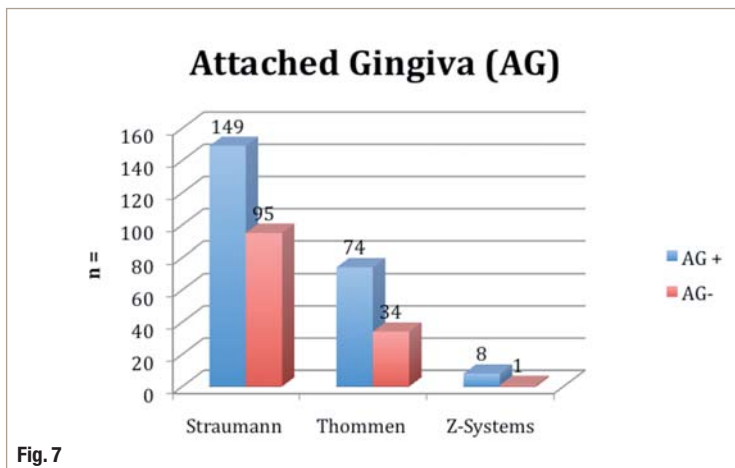


Fig. 7

**Fig. 7\_ Attached gingiva.** fection and reduced stability. The resulting overall survival rate was 99.7%. Of the 236 Straumann implants, 235 were clinically controlled with a mean follow-up period of 5.4 (0.75–8) years. The corresponding survival rate for Straumann implants was therefore 99.6%. The mean follow-up period for the 102 Thommen implants was two (0.25–9.7) years. No Thommen implant had failed when this article was written. In this subgroup, one case of bisphosphonate-related osteonecrosis of the jaw (ONJ) was discovered, surprisingly, at the final follow-up. The two implants were retained following local and antibiotic treatment, i.e. were deemed survivors. None of the Z-Systems implants failed during the mean follow-up period of two (0.8–3.8) years.

Sulcus bleeding on careful probing was observed in 19% of the implants ( $n = 67$ ). With regard to the different manufacturers, BOP was observed in 14.9% of the Straumann implants ( $n = 35$ ) and in 38.2% of the Thommen implants ( $n = 32$ ). The difference was statistically significant (Fisher's ex-

**Fig. 8\_ Bleeding on probing for implants with AG.**

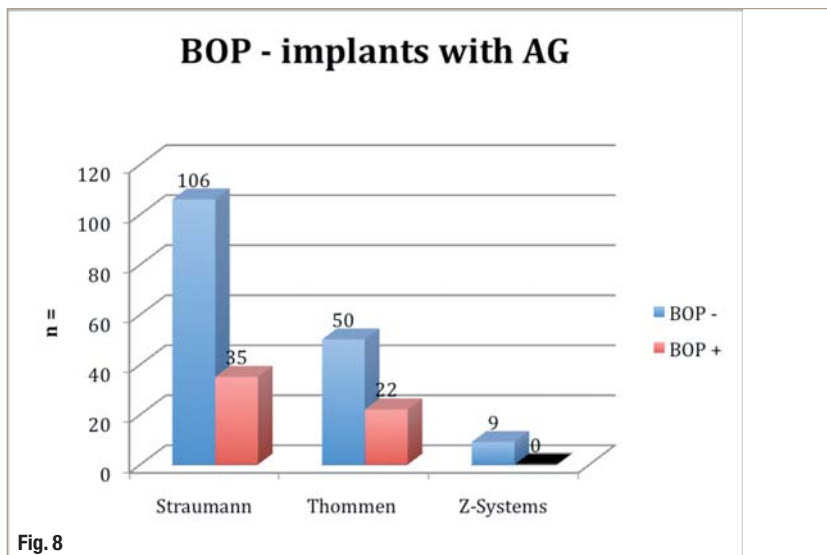


Fig. 8

act test,  $p < 0.05$ ). None of the nine Z-Systems implants showed BOP (Fig. 5). The evaluation revealed 89% of implants ( $n = 308$ ) with a PD of between 1 and 3 mm. A PD of 4 to 6 mm was found in 10% of implants ( $n = 34$ ). (The PD value distribution for Straumann and Thommen implants is shown in Fig. 6.) Only one female patient with a PD of 8 mm and 9 mm was documented (ONJ). No differences were found in PD between the three implant types. The mean PD of all 346 implants was 2.4 mm irrespective of the implant design.

Of all implants, 70% ( $n = 244$ ) were surrounded by keratinised, attached gingiva (AG). This was the case for 68.5% of the Straumann implants ( $n = 161$ ), 72.5% of the Thommen implants ( $n = 74$ ) and 89% of the Z-Systems implants ( $n = 8$ ; Fig. 7).

Based on the results observed, an attempt was made to establish a correlation between:

1. AG and BOP; and
2. AG and PD.

*Attached gingiva and bleeding on probing*

The influence of soft tissue on peri-implant health is not conclusively elucidated. Of the 346 implants studied, 244 were surrounded by AG and only 27.9% ( $n = 68$ ) of these exhibited BOP. Of the 236 Straumann implants, 161 were surrounded by AG and 26.4% ( $n = 38$ ) of these were BOP positive. Of the 102 Thommen implants, 74 were surrounded by AG and 30.6% ( $n = 22$ ) of these were deemed BOP positive. Of the nine Z-Systems implants, eight were surrounded by AG and all of them were BOP negative (Fig. 8). The difference in the number of patients with AG and positive BOP between Straumann and Thommen implants was statistically significant ( $p < 0.05$ ; 26.4 compared with 30.3%). Also the converse relationship, i.e. the correlation between the absence of AG and positive BOP, was also evaluated. This was found in 67.9% of the Straumann implants ( $n = 38$ ), compared with 64.7% of the Thommen implants ( $n = 22$ ). The difference was statistically significant ( $p < 0.05$ ).

*Attached gingiva and probing depth*

The mean PD for the 244 implants surrounded by AG was 2.4 ( $\pm 0.9$ ) mm. The 102 implants without AG had an identical PD of 2.4 ( $\pm 0.7$ ) mm. A statistically non-significant trend was seen in the Thommen implants. The 74 Thommen implants surrounded by AG showed a PD of 2.2 ( $\pm 1.1$ ) mm, whereas the 34 implants without AG showed a mean PD of 2.8 ( $\pm 1.4$ ) mm. The eight Z-Systems implants surrounded by AG had a mean PD of 1.5 mm. The single implant without AG had a PD of 2 mm (Fig. 9).

# ADVANCED TISSUE-MANAGEMENT

## The easy way to aesthetics.

PARASORB Sombrero®

RESODONT®

PARASORB® HD Cone

GENTA-COLL® HD Cone



### RESODONT®

- ▶ naturally cross-linked, with no chemical additives
- ▶ quick and easy to cut to size and apply, both sides can be used
- ▶ rapid integration in the surrounding tissue
- ▶ highest degree of product safety and excellent biocompatibility

### PARASORB Sombrero®

- ▶ to cover and simultaneously fill the alveolus (socket preservation)
- ▶ offers a defined regeneration matrix
- ▶ formation of a stable bony implant bed after a relatively short time
- ▶ improved long-term aesthetic and functional results particularly in the anterior region

### PARASORB® HD Cone GENTA-COLL® HD Cone

- ▶ rapid and safe haemostasis
- ▶ reduction of alveolar ridge atrophy
- ▶ optionally comes with antibiotic protection for high-risk patients (e.g. diabetics, smokers, immune-suppressed patients)

## \_Discussion

The study aimed to assess the long-term clinical outcome of minimally invasive, flapless surgery with a particular focus on the peri-implant soft tissue. This longitudinal study investigated whether, with respect to soft tissue, it is possible to obtain results comparable to or even better than the standard, more invasive, flap surgery. To date, there is only a limited number of such studies. Three different implant designs were compared. Ample evidence is available documenting the long-term implant survival rate of >90% after five years with classical, trapezoidal flap surgery (Behneke *et al.* 2000; Mericske-Stern *et al.* 2001; Romeo *et al.* 2002).

Surprisingly, there is limited information on the long-term outcome of the flapless surgical protocol. Until now, published papers have reported the outcome only up to 18 months (Brodala, 2009). In a multicentre clinical study, Becker *et al.* (2009) evaluated 57 patients. They demonstrated that the results are similar to those obtained with the conventional flap protocol. After five years, 37 of these patients were followed up and the survival rate remained as high as 98.7%. This is comparable to the result obtained in the present study, with a slightly longer than average follow-up time of three to four (maximum of 9.7) years and 99.6% of surviving and fully functional implants at the time of the last follow-up.

The predictability of transgingival healing following flap preparation has been extensively investigated. Numerous studies concluded that there is no difference between implants that healed in submerged or open fashion (Ericsson *et al.* 1997; Buser *et al.* 1990, 1999; Abrahamsson *et al.* 1999; Weber *et al.* 2000). For flapless surgery, despite a modification of the surgical approach, osseointegration can be achieved in a predictable way (Campelo & Camara 2002; Sclar 2007; De Bruyn *et al.* 2009; Jeong *et al.*

2007, 2010; Rousseau 2010). Concerns of a higher failure rate, caused by the inevitable contamination of the sterile implant surface by oral bacterial flora, were not confirmed. The results of an animal study proved that contamination of the soft tissue before surgery has no negative impact on implant osseointegration (Ivanoff *et al.* 1986). Adherence to aseptic conditions during surgery nevertheless remains an important implantation success factor (Adell *et al.* 1985; Sennerby & Lekholm 1993).

Recently, in a controlled retrospective study Rousseau (2010) was able to demonstrate that in the correct indication range the success of minimally invasive transgingival implantation is the same as that of the classical protocol: minimally invasive, 98.3%; conventional, 98.5%. Nevertheless investigations of the peri-implant soft tissue following minimally invasive surgery are rare: 24, 44 and 241 patients have been followed up over a period of four to 12 months (Oh *et al.* 2006; Lee *et al.* 2009; Jeong *et al.* 2010, respectively).

The influence of keratinised peri-implant AG on the occurrence of peri-implant inflammation is still a controversial issue (Marquez 2004). In this study, a relationship between AG and implant survival was not established. We analysed the PD and BOP clinical parameters, which can be measured in a practice setting with reasonable technical equipment. This comparison should allow the assessment of peri-implant tissue health. An animal study demonstrated that missing AG resulted in significantly increased recession and slightly higher attachment loss (Warrer *et al.* 1995). This result implied that the absence of AG around implants increases plaque-induced tissue damage. The implication was validated in a clinical study (Bouri *et al.* 2008) of 2008 implants, which remained in situ for at least 12 months. The presence of at least 2 mm of AG was accompanied by minimal alveolar bone loss and improvement of indices that describe peri-implant tissue health. The same study demonstrated that in the

Fig. 9 Correlation of AG with PD.

Fig. 10 Peri-implant soft tissue before insertion of fixed prosthetic restoration (Straumann).

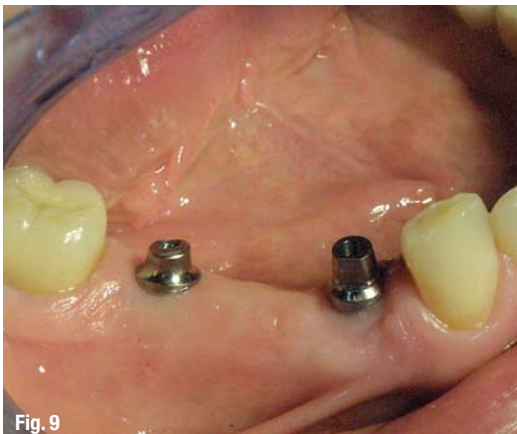

Fig. 9

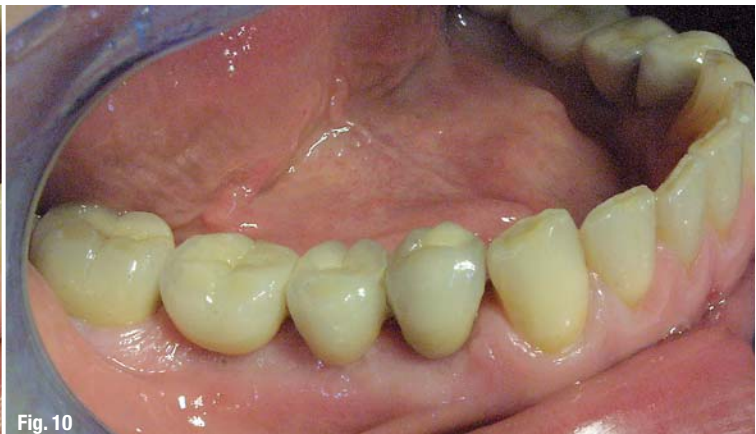

Fig. 10



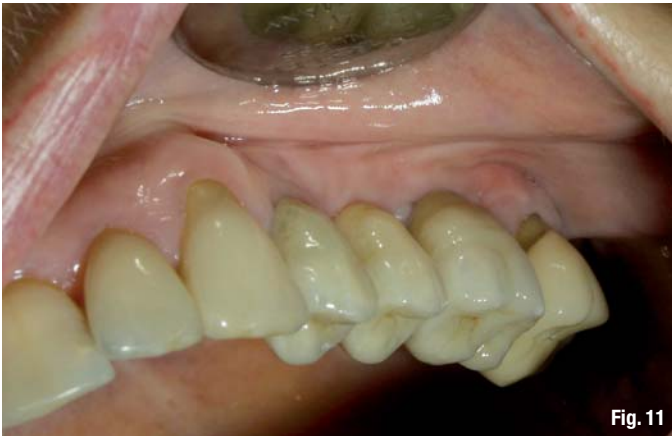

Fig. 11

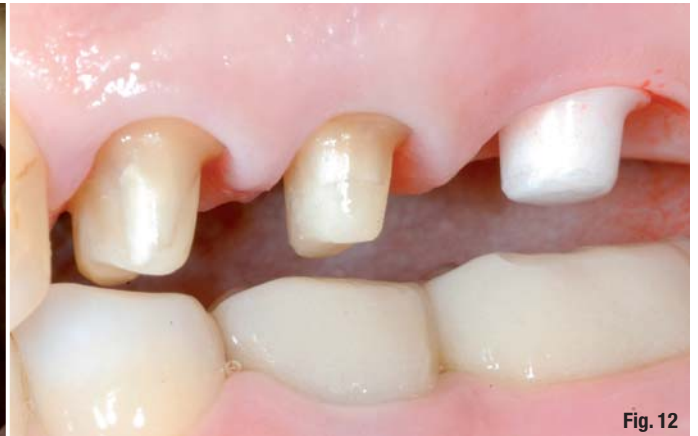

Fig. 12

control group the implants with less than 2 mm of AG had significantly increased BOP frequency. In addition, radiographic examination showed a higher average bone loss when AG was not sufficient. These results however have to be viewed with caution: Meijer *et al.* (1992) stated that the resolution of conventional X-ray is limited and minimal changes in the marginal bone will often not be recognised. This was confirmed in an animal experiment (Caulier *et al.* 1997). Current 3-D imaging techniques such as CT or DVT (digital volume tomography) offer an improved picture of the peri-implant bone quality (Mengel *et al.* 2006). However, legal considerations prohibit a more frequent X-ray follow-up.

In a study of 26 patients, Krekeler *et al.* (1983) found that the presence of AG improved gingiva's sensitivity to inflammation caused by mechanical irritation. It seems therefore likely that AG is advantageous for the health of the peri-implant tissue but it is not a prerequisite condition. According to the authors, plaque control is the most important factor for the absence of peri-implant inflammation. A further study provided contradictory results. This clinical study found a correlation between AG and the incidence of mucositis (Roo-Jansaker *et al.* 2006). The authors reasoned that implants without keratinised tissue have a tendency to gingiva recession and therefore less peri-implant pockets will be found. This was confirmed by Chung *et al.* (2006) in a retrospective multicentre study of 69 patients with 339 implants. In this study, the appearance of plaque and peri-implant lesions was significantly increased around implants with AG. Unfortunately, this was not confirmed in further clinical studies. It was shown that neither the presence or the width of keratinised mucosa, nor the mucosal border mobility had an influence on plaque control or on the inflammatory status of the peri-implant tissue (Block *et al.* 1990; Strub *et al.* 1991; Wennström *et al.* 1994; Hanisch *et al.* 1997; Cairo *et al.* 2008). According to Wennström *et al.* (1994), there was no negative ef-

fect of keratinised tissue on bleeding behaviour or plaque control, although 61% of the implants showed no peri-implant AG.

The latter findings are in line with the results presented in this article. Of the 346 implants, 244 were surrounded by keratinised tissue. Our findings confirmed that less BOP is found in the presence of AG. This is independent of the implant type used (zirconium-oxide or titanium) and design (one or two piece). We therefore conclude that in the presence of keratinised alveolar mucosa, susceptibility to peri-implant inflammation is reduced. This was also the conclusion of a recent multicentre study (Eccelente *et al.* 2010), but the finding must be treated with caution. Recently, it was also demonstrated histologically that peri-implant inflammation can be found even in the absence of clinical signs (Nahas *et al.* 2010). In a human study, the authors investigated 12 samples obtained at implant uncovering (second-stage surgery). The presence of chronic, inflamed peri-implant infiltrates was shown in the absence of clinical symptoms.

In this study, only 26.2% of Straumann and 31.9% of Thommen implants displayed BOP (the difference was not significant). Only one of the eight Z-Systems implants was BOP positive. No conclusion is possible based on this small number of implants. It seems likely nevertheless that the soft-tissue integration of zirconium-oxide implants is as good, if not better, as suggested by Blaschke and Volz (2006).

It is known that AG has a positive impact on peri-implant health (Krekeler *et al.* 1983; Warrer *et al.* 1995; Bouri *et al.* 2008; Adibrad *et al.* 2009). In a meta-analysis of the role of local risk factors in implantology, no relationship was found between the presence of keratinised mucosa and implant survival (Martin *et al.* 2009). Our results demonstrate that the presence of keratinised gingiva around implants may lead to less peri-implant inflammation and has no immediate effect on implant survival.

**Fig. 11** Peri-implant soft tissue with restoration inserted.

**Fig. 12** Peri-implant soft tissue with restoration inserted (Thommen Element).



Furthermore, the clinically measurable PD was analysed, thus allowing conclusions concerning the inflammatory status of the peri-implant tissue (Shou *et al.* 2002). The PD measurement is one of the most important parameters for clinical characterisation of the implant condition (Behneke *et al.* 2002). It is of central importance also because of the similarity of the tissues surrounding teeth and implants. The value measured is related to marginal bone loss (Quiryren & Listgarten 1990). For natural dentition, a PD of 1 to 3 mm is considered to be physiological, though around implants the healthy or pathological values vary. A PD of 1.5 to 3.5 mm was found to be optimal by Behneke *et al.* (1997). The values found in our study are significantly different. Although the mean PD was not influenced by the presence of AG in the case of Straumann implants, i.e. PD remained constant at 2.4 mm, for Thommen implants a significant difference was found. It needs to be emphasised that the polished collar height of the Straumann implants used was 1.8 mm (Standard+) and 2.8 mm (Standard), whereas for Thommen implants this was 1.5 mm (CONTACT) and 1 mm (ELEMENT). One can only speculate that the polished collar of 1.8 mm and 2.8 mm together with keratinised AG may lead to a reduced PD and also slightly higher BOP. On the other hand, shorter polished collars are preferred prosthetically because in the long-term they lead to an aesthetically more favourable outcome. The analysis presented has also shown that in the presence of keratinised gingiva, minimally invasive transgingival implantation led to stable implant integration with respect to soft tissue.

The PD values measured in this study (overall mean of 2.4 mm) are comparable to published results. A PD of 2.2 mm that remained constant over four years was reported (Becker *et al.* 2009). This value seems reasonable when considering the anatomical parodontal structures. Similar to natural teeth, biological width is formed around implants too. This begins at the implant–abutment interface and ends, as with natural teeth, at the limbus alveo-

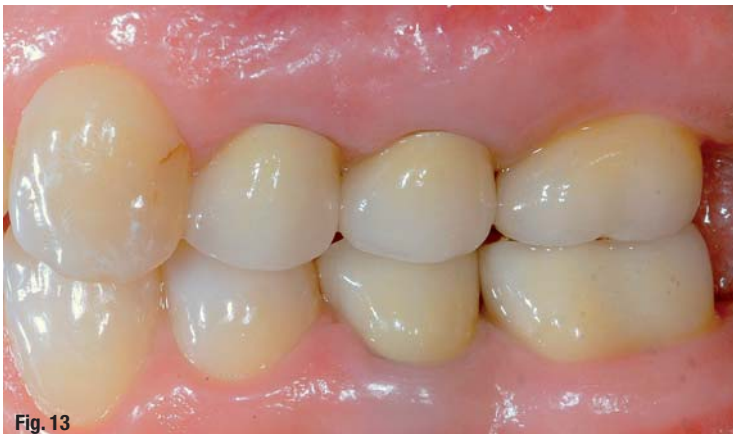laris (Buser *et al.* 1989, 1992; Ericsson *et al.* 1996; Cochran *et al.* 1997; Hermann *et al.* 1997; Abrahamsson *et al.* 1997; Kohal *et al.* 1999; Hermann *et al.* 2000). It is known from animal studies that the dimensions of biological width are similar around implants and natural teeth (Buser *et al.* 1989, 1992; Cochran *et al.* 1997; Ericsson *et al.* 1995). The height of the implant–mucosal complex is 3 to 4.8 mm and the dimensions of its components seem to vary more around implants than around teeth (Berglundh *et al.* 1991; Hermann *et al.* 2000). Our results confirm these findings; the most frequent PD values were 2 and 3 mm. This corresponds well with the published biological width (Berglundh *et al.* 1991; Weber *et al.* 1996). The consequence of frequent abutment replacement was a more apically attached connective tissue and increased incidence of marginal bone loss (Abrahamsson *et al.* 1997, 2003). Transgingival healing with immediate restoration of the implants helps to reduce the frequency of abutment changes; it may hence lead to more stable bone levels.

As mentioned above, one female patient had a PD of 8 and 9 mm with pus secretion. This occurred in the presence of a symptomatic bisphosphonate-related ONJ at already osseointegrated and restored implants. The patient had been taking Zolendrate for three years as an adjuvant therapy for mammary carcinoma. She did not report this and it was only revealed by inquiry of her oncologist. The infection resolved after systemic antibiotics and careful local treatment. To date, the implants are in situ and symptom free.

Following minimally invasive insertion of titanium implants, in most cases healthy peri-implant tissue was found in this study. BOP was seen for only 14.9% of Straumann implants, compared with 38.2% of Thommen implants. This difference may be explained by the higher polished collar of Straumann (2.8 mm and 1.8 mm) in comparison with Thommen implants (1.5 mm and 1 mm). In the same way as PD, this finding can be related to the height of the mucosal implant complex. Histological investigation (not feasible within the scope of this study) would be needed to confirm this assumption.

The influence of the micro-gap (50–100 µm for most commercial implant systems) between the implant and its abutment (or secondary prosthetic parts) is controversial. The micro-gap can be populated by bacteria and thereby affect both the peri-implant bone loss and the peri-implant soft tissue (Scarano *et al.* 2005). Clinical studies that compared one- and two-piece implants have found significantly more inflamed sites around two-piece than around one-piece implant systems (Broggini *et al.* 2003). Such a trend was also confirmed in this study.

**Fig. 13** Peri-implant soft tissue before prosthetic restoration (Z-Look3).



**Fig. 13**

The presence of BOP is considered to be a readily available parameter that reflects peri-implant health (Heitz-Mayfield 2008). Its clinical importance is not always equivocal and should be assessed cautiously in relation to additional parameters. The presence of BOP is generally considered to be a symptom of inflammation; nevertheless, the complete opposite was also found. Lang *et al.* (1990) in their thorough study demonstrated that the absence of BOP is only clinically meaningful if found in several consecutive measurements, i.e. negative prediction value of 98%. The presence of BOP had no clinical relevance (positive prediction value of 6%). The negative prediction value appears to be true in implantology too (Lang *et al.* 1994; Becker & Gansky 2007). To confirm a peri-implant inflammation, measurement of matrix metalloproteinase activity (MMP-8/collagenase-2) would be necessary. Ma *et al.* (2000) and Xu *et al.* (2008) have shown that this enzyme activity allows distinction between diseased and healthy tissues.

## **\_ Conclusion**

In addition to peri-implant soft-tissue preservation, minimally invasive implantation offers important advantages. This is particularly true for elderly, medically compromised patients, who typically present with limited bone availability and/or poor bone quality in addition to congenital or anti-coagulant-induced bleeding diathesis, as well as general medical contra-indications that make larger augmentative intervention quite challenging. In these patients, excellent results can be obtained using a minimally invasive, transgingival approach and patient chewing comfort can be improved dramatically. As only the soft tissue the size of the implant diameter will be excised, the implant acts as a tamponade that may effectively diminish bleeding from the bone and soft tissue.

In early stages, the flapless technique was recommended to inexperienced surgeons. It soon became clear that this type of surgery is technically very sensitive. Achieving success requires a much higher level of clinical experience than originally thought. Van de Velde *et al.* (2008) found no relationship between surgical experience and precision using synthetic models. This finding has to be viewed with criticism because a successful minimally invasive surgery depends to a large extent on the correct assessment of the anatomical situation and this skill can be only obtained through long-term clinical experience. False assessment of the anatomic conditions may lead to bone perforation or false implant position. These severe complications can only be avoided through long-term implantological practice.

Dental implantology has changed with the introduction of combined X-ray and DVT machines and easy access to CT. Prospective planning and the feasibility of 3-D implant site evaluation have led to increased popularity of minimally invasive implantology (Sclar 2007). Promising results were reported by recent studies that tested the transfer accuracy of planning with drilling templates manufactured using various methods (Van Assche *et al.* 2010; Danza & Carinci 2010; Lomzynski & Mierzwinska-Nastalska 2010; Neugebauer *et al.* 2010). The number of patients treated using minimally invasive methods will undoubtedly increase in future. Thanks to exact planning before surgery and data transfer to suitable templates, patients will have access to high quality solutions with minimal surgical intervention. In the hands of inexperienced dentists, who would blindly rely on planning with templates, planning error when doing computer-assisted implantology may lead to disastrous results (Van Assche *et al.* 2010; Stoll 2010).

Flapless implant insertion in this study demonstrated a success rate comparable to conventional implant surgery. Our results are congruent with the recently published recommendations of the ITI Consensus Conference in September 2010 (Weber *et al.* 2010). The presented results demonstrated that flapless implant surgery is a predictable procedure. It has the advantages of preserving mucosal health around dental implants. The statistically higher rate of bleeding around Thommen implants is possibly associated with the shorter polished collar. The low positive prediction value of BOP must not be forgotten. Overall good peri-implant soft-tissue health conditions were found around all three implant types (Figs. 10–15). This study has confirmed that a band of keratinised gingival tissue around implants is not absolutely necessary but can minimise soft-tissue inflammation.

*Editorial note: A list of references is available from the publisher.*

### **\_contact**

### **implants**

#### **Dr Kai Höckl**

c/o KOSMedics Private Hospital for Aesthetic Surgery and Laser Medicine, Prof Stoll & Partner

Wilhelmstr. 3  
79098 Freiburg/Breisgau  
Germany

kai.hoeckl@web.de

# Consideration of an uncommon approach in the atrophied posterior zone

## Part I: Extraction plus technique

**Authors** \_ Dr Maen Aburas, UAE, & Dr Ralf Gutwald, Germany

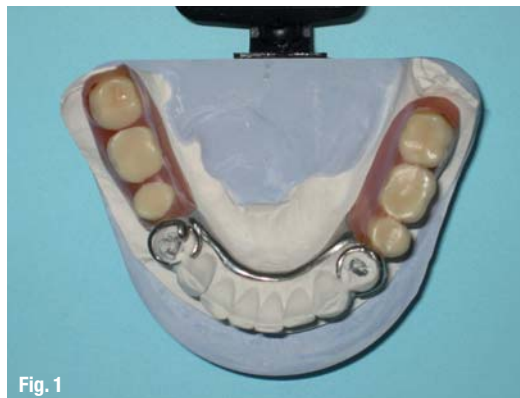

Fig. 1

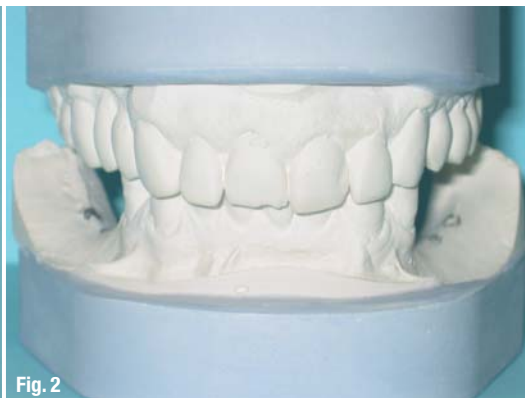

Fig. 2

**Figs. 1, 2, 3 & 4** \_ Study cast frontal, bilateral views and the mandible cast with the partial denture.

### Introduction

In the past, it was a significant challenge for clinicians to achieve implantation in the alveolar ridge of the posterior zone with restricted bone height, for which the alternative treatment choices were limited. However, procedural and technological developments have enabled implantation in most cases of severe bone resorption through the use of complex bone aug-

mentation techniques, such as bone transmission, sinus lifting, distraction and nerve transpositioning, and the use of bone substitute, membrane and nail fixation, which might increase the risk of complication and failure. Generating new bone in a free-end saddle in a vertical dimension is very difficult to achieve and some patients are unwilling to go through such a protracted treatment plan, considering the possible impact on their general health and psychological condition, as

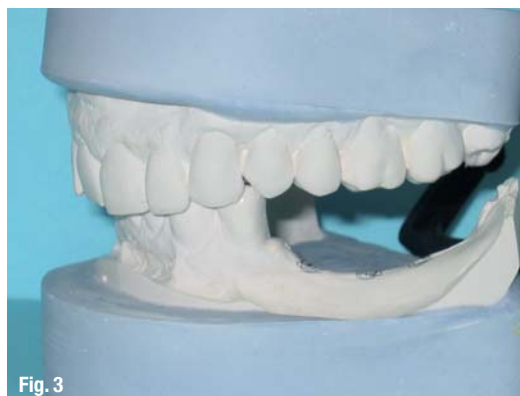

Fig. 3

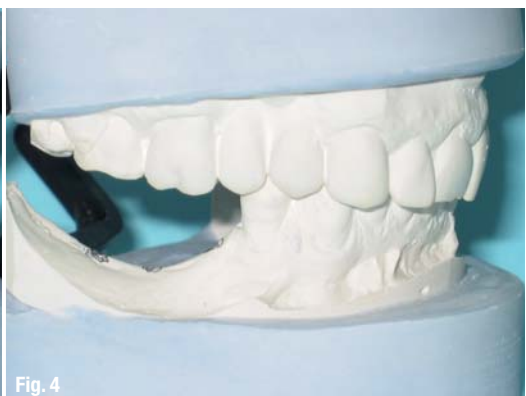

Fig. 4



Geistlich  
**Bio-Gide®**

The Original  
remains unique.

**PROVEN:**

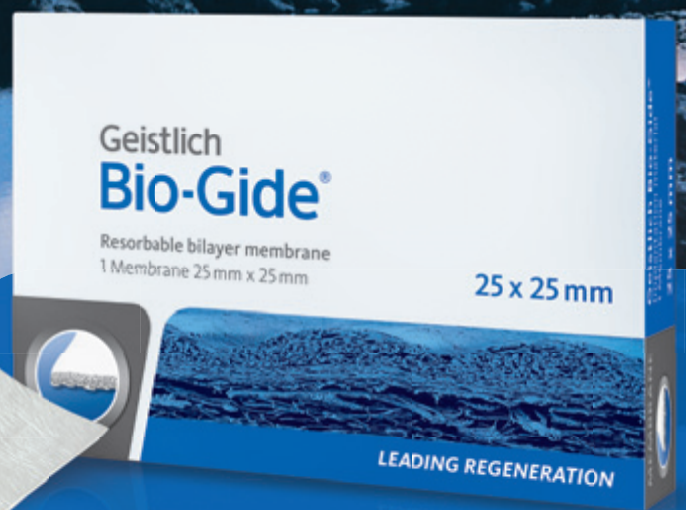Early membrane  
vascularisation supports  
bone regeneration<sup>1</sup>

**Geistlich Bio-Gide® –  
The Original**

**RELIABLE:** 15 years of clinical experience

**PROVEN:** More than 150 scientific studies

**EXPERIENCED:** 160 years of  
Geistlich Collagen Competence



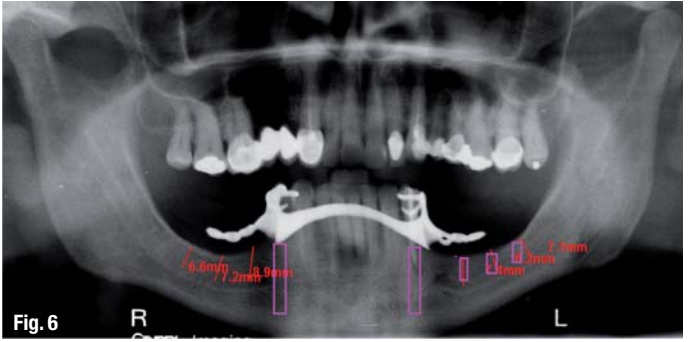
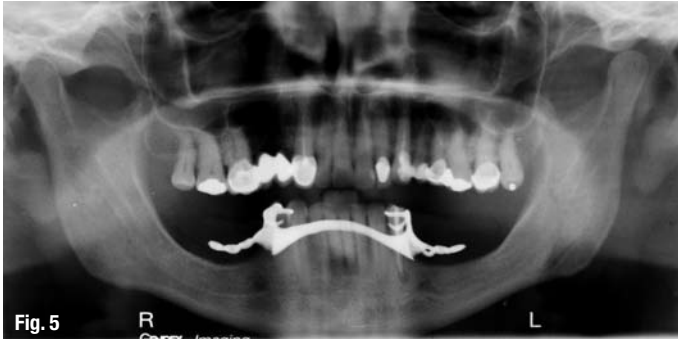[www.bio-gide.com](http://www.bio-gide.com)

 **swiss made**



<sup>1</sup>Schwarz F et al. Clin. Oral Implants Res. 2008; 19 : 402-415





**Fig. 5** Panoramic radiographic with partial denture and limited alveolar bone height 7–9 mm above the inferior alveolar.

**Fig. 6** Panoramic radiographic with the treatment plan drawing.

**Tab. 1** Survey 1 which presented Case A1 and Case B1 and all the alternatives under each case and clinicians can mark.

**Fig. 7** Post-operative panoramic radiographic revealed the implant placement as planned.

**Fig. 8** The flaps were re-positioned in a submerged surgical approach except the extracted site implants.

**Fig. 9** shows the impression caps and synOcta positioning cylinders snapped into place prior to the final impression.

well as the cost. This scenario means that we have to find a good solution for those patients who cannot undergo such a difficult procedure, bearing in mind that the use of short implants alone is not advisable in many cases. The onus is on us to come up with a simple and standard means of implantation to save time and pain and to minimise the risk of complication and failure. The principle of the new technique proposed here—the extraction plus procedure—is the extraction and sacrifice of the adjacent natural tooth, followed by the insertion of a long implant to support shorter implants that are inserted where bone height is limited. Through this new technique, we can convert a complicated procedure (guided bone regeneration – GBR) into a simple standard procedure with less pain, saving time and cost and minimising the risk of complications.

### Materials and methods

#### Method

The success and application of the technique discussed in this article were determined through two surveys and a clinical case. Two questionnaires were administered to the respondents (surveys 1 and 2). The respondents were then asked to rank the alternative techniques (including extraction plus tech-

nique) as a good alternative means of treatment for each of the two cases presented. They were given the following options: the first choice of alternative

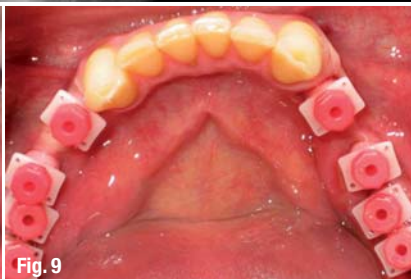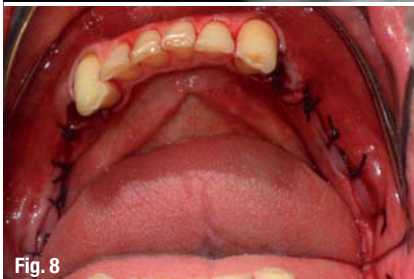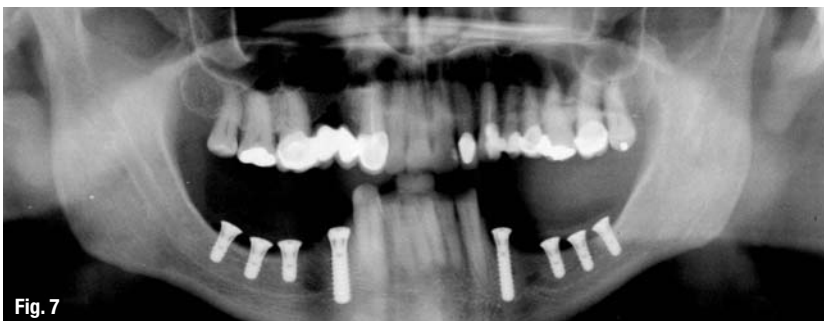
Mandibular Case (A1)		Maxilla Case (B1)	
	Alveolar bone height above the nerve - 8mm		Alveolar bone height 5-7 mm
	To extract #4 to fix 1 long and 3 short implants (one stage surgery)		Extract #5 to fix 1 long and 2 short implants (one stage surgery)
	To fix 3 short implants (one stage surgery)		To fix 2 short implants (one stage surgery)
	To augment by bone block (two stage surgery)		Internal sinus lifting (one or two stage surgery)
	Distractor device (two stage surgery)		Window with bone block (two stage surgery)
	Nerve transpositioning (one stage surgery) to fix 3 long implants		

**Table 1**

treatment (most preferable; indicated with +++); the second choice (more preferable; indicated with ++); the third choice (preferable; indicated with +); and not considered a viable alternative treatment (indicated with -).

#### Survey

For survey 1 (Table 1), case A1 was a free-end saddle mandible with atrophic alveolar bone height about 8 mm above the inferior alveolar nerve canal but with sufficient width; and case B1 was an atrophied free-end saddle maxilla with teeth #26 and 27 missing and an alveolar ridge height of about 5 to 7 mm to the sinus floor and sufficient alveolar width. For survey 2 (Table 2), the two cases presented were the same, except that in case A2 the first premolar and in case B2 the second premolar had a peri-apical cystic lesion and were considered unhealthy teeth.





## Behind every successful implantologist is an Implantmed



Scan the QR code with  
your mobile telephone  
for more information on  
Implantmed



With the new Implantmed you perform implant procedures with maximum precision. The unit is easy to operate and guarantees longer working without fatigue – thanks to the **lightweight**, yet **powerful motor** and the ergonomically-shaped contra-angle handpiece. And the integrated **thread cutter function** helps you with especially hard bone.

implantmed



**Respondents**

The study respondents were clinicians involved in the implantology field (dentists and oral and maxillo-facial surgeons). The data was collected from May

2008 to May 2009 from 77 respondents, self-categorised into three groups: beginners, intermedials and experts. We obtained 19 respondents from Brazil, Chile, Colombia, Latin America and Peru during the International Implantology Conference of Dentoflex held in São Paulo, Brazil, from 14 to 16 November 2008. Nine respondents, obtained through colleagues working in Dubai and Sweden, came from Sweden. Ten respondents were obtained through another colleague working in Oslo, Norway, and who visits Dubai regularly. The remaining 39 respondents were master's students in and professors of the MSc International Programme in Oral Surgery and Implantology at Danube University Krems, Austria, and came from Australia, Germany, and Eastern European and Middle Eastern countries.

**Tab. 2\_** The only difference in survey 2 that the first premolar in Case A2, and, the second premolar in Case B2, both are considered as doubtful teeth.

DANUBE UNIVERSITY KREMS MSc in Oral Surgery / Implantology		Student: Dr. Maen Aburas ID No. : 0764808	
Survey 2			
Name: _____		Dentist: <input type="checkbox"/> Maxillofacial or Oral Surgeon: <input type="checkbox"/>	
Beginner: <input type="checkbox"/>		Intermediate: <input type="checkbox"/> Expert: <input type="checkbox"/>	
Please mark (+) for preferable, (++) for more preferable, and (+++) for most preferable treatment for the cases given, considering duration of treatment, minimum of risk and complications			
Mandibular Case (A2)	Alveolar bone height above the nerve-8mm	Maxilla Case (B2)	Alveolar bone height 5-7 mm
1	To extract #4 to fix 1 long and 3 short implants (one stage surgery)	1	Extract #5 to fix 1 long and 2 short implants (one stage surgery)
2	To fix 3 short implants (one stage surgery)	2	To fix 2 short implants (one stage surgery)
3	To augment by bone block (two stage surgery)	3	Internal sinus lifting (one or two stage surgery)
4	Distractor device (two stage surgery)	4	Window with bone block (two stage surgery)
5	Nerve transpositioning (one stage surgery) to fix 3 long implants		
			<b>Table II</b>

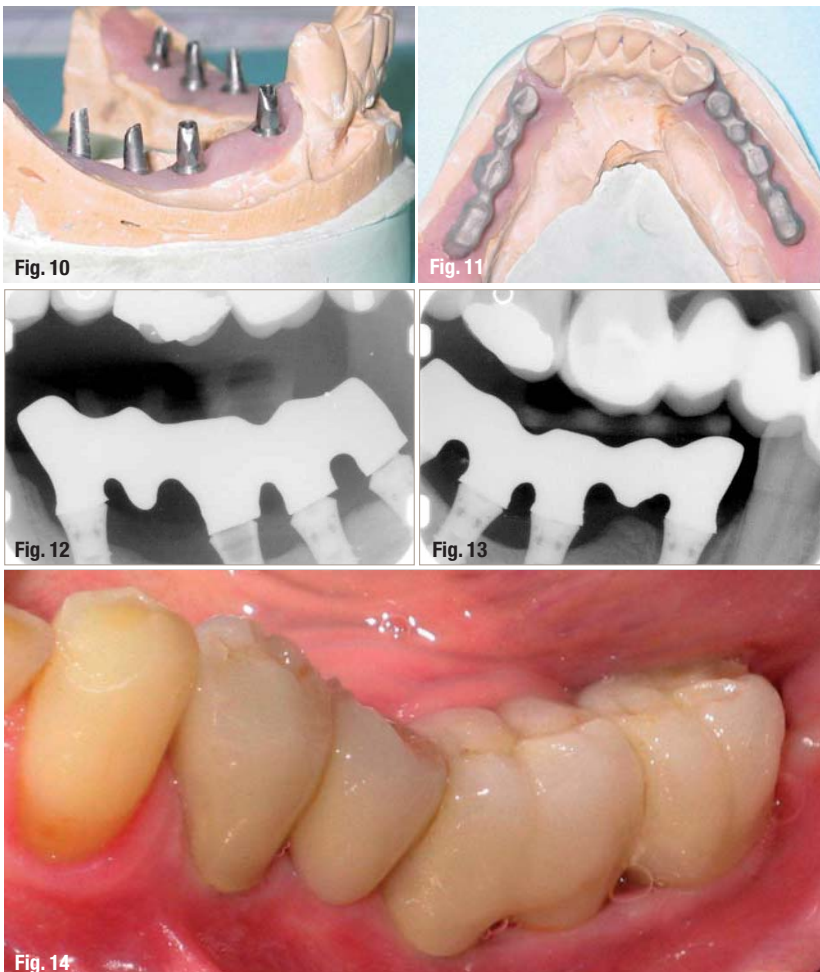
**Fig. 10\_** Shows the master cast lateral view with the synOcta selected abutment in parallelism.

**Fig. 11\_** Shows the master cast occlusal view of the metal framework.

**Fig. 12\_** Shows the radiograph taken to assess the marginal adaptation of the metal framework left side.

**Fig. 13\_** Shows the radiograph taken to assess the marginal adaptation of the framework right side.

**Fig. 14\_** shows the final restoration in seated left side.



**\_Results of surveys**

Of the 77 respondents, nine considered themselves beginners, 50 intermedials and 18 experts. The statistics of the data collected from the surveys for cases A1, B1, A2 and B2 are shown in Tables 3 to 4.

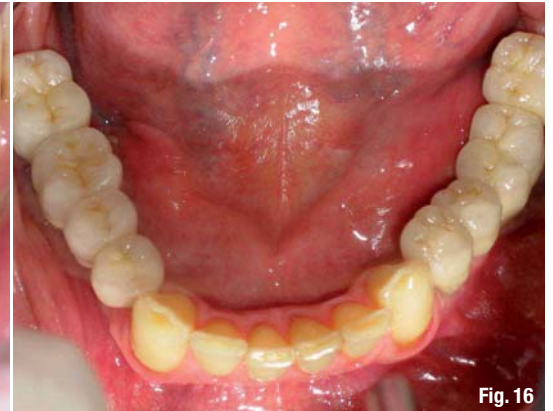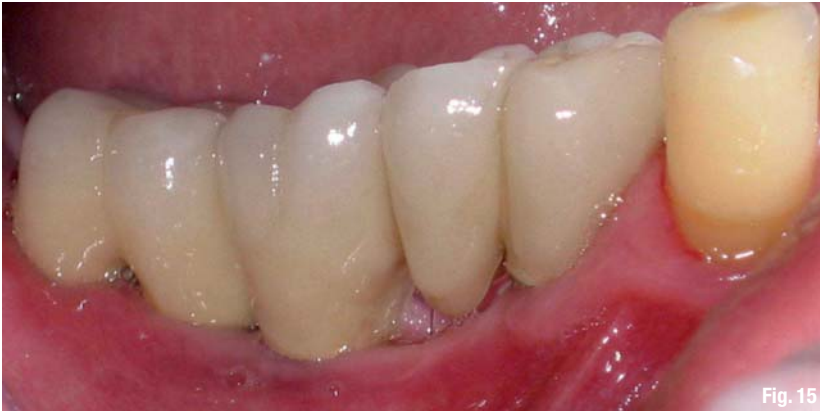**\_Discussion**

From the results that we obtained for case A1-1, we found that 18% of the respondents agreed by (+++) and 30% agreed by (++) , which indicates that the extraction plus technique is their first choice of alternative treatment. If we consider them together, this means that 48% would use the extraction plus technique in order to avoid the complications of other alternatives, but 40% disagree with extracting an intact tooth. For case A2-1, 58% of the respondents agreed by (+++) and 18% agreed by (++) , which totals 76%, and only 16% disagreed.

For case B1-1 (maxilla case), 10% agreed by (+++) and 18% (++) , but 49% disagreed with this alternative. In case B2-1, however, 45% agreed by (+++) , 26% by (++) and only 20% disagreed, which means that clinicians strongly preferred the extraction plus technique as a good alternative in the posterior zone, where there is an unhealthy tooth but not in the case of a sound and healthy one.

Regarding the alternative treatment using short implants in the mandible, for case A1-2, 58% of the respondents agreed by (+++) , 21% agreed by (++) and only 9% disagreed with this choice, which reflects that the clinicians strongly preferred the short implant alternative to the other difficult and complicated alternatives and would not use the extraction plus technique. But for case A2-2, 22% agreed by (+++) and 22% would not use this technique, which reflects clinicians' hesitation to use the short implant alternative in the case of an unhealthy tooth.





For the maxilla case B1-2, 22% of the respondents gave (+++), 26% gave (++) and 39% disagreed, but for case B2-2, 16% gave (+++), 21% gave (++) and 45% disagreed. These results reflect a balance between those who agreed and disagreed with this technique, which means that the clinicians were hesitant to give definite decisions on the short implants alternative in the posterior maxilla.

For the bone block augmentation technique in the mandible through two-stage surgery in case A1-3 and case A2-3, there were no significant differences in the results of the case A1-3, where 9% agreed by (+++), 19% agreed by (++) and 38% disagreed, compared with that of case A2-3, where only 6% agreed by (+++) and 17% agreed by (++) and 50% disagreed. This indicates that clinicians tried to avoid the complications on both donor and recipient sides associated with bone augmentation by the bone block (autogenous) technique, aside from it being a more time-consuming alternative treatment.

From the results of cases A1-4 and A2-4, it is clear that the mandible distractor device was not preferred because for case A1-4, 3% gave (+++), 9% gave (++) and 59% disagreed and for case A2-4, only 1% gave (+++) and 69% disagreed. This reflects the rare use and difficulties of application of this device and clinicians' desire to avoid complications of this alternative treatment.

For the last alternative presented for cases A1 and A2, nerve transpositioning, the results for both cases A1-5 and A2-5 were the same, where only 3% agreed by (+++) and almost 80% disagreed with this complicated and risky technique being a viable alternative treatment.

The results of case B1-3 demonstrate that internal sinus lift is the most preferable alternative technique (60% agreed by (+++), 21% by (++) and only 5% disagreed), compared with the results of case B2-3, which demonstrate that clinicians did not support the use of this technique in the case of an unhealthy tooth (31%

gave (+++) and 13% disagreed). This demonstrates clinicians' confusion and no definite decision when it seems doubtful that the natural tooth can be preserved, and clinicians may prefer the extraction plus technique alternative in this situation.

In comparison, using external window sinus lift with a bone block graft for case B1-4 was not much more preferable, as evident from the results: 14% agreed by (+++), 26% agreed by (++) and 34% disagreed. The positive results for this technique decreased even further in case B2-4, where only 8% gave (+++), 14% (++) and 55% disagreed. These results demonstrate that the clinicians considered this technique a good alternative treatment when the natural tooth is healthy but not when its survival is doubtful, in order to avoid the complications associated with this technique.

### Conclusion for surveys

The extraction plus technique was considered by the respondents as one of the better alternatives, especially when the tooth to be extracted was unhealthy but less so when the tooth to be extracted was healthy. Using the short implant technique in the mandible was

**Fig. 15\_** Shows the final restoration in seated right side.

**Fig. 16\_** Shows the occlusal view of final restoration.

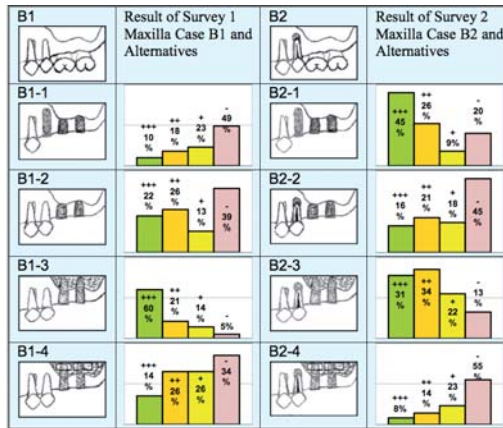
A1	Result of Survey 1 Mandible Case A1 and Alternatives	A2	Result of Survey 2 Mandible Case A2 and Alternatives
A1-1	+++ 18% ++ 30% + 12% - 40%	A2-1	+++ 50% ++ 16% + 8% - 16%
A1-2	+++ 50% ++ 21% + 12% - 9%	A2-2	+++ 22% ++ 44% + 12% - 22%
A1-3	+++ 9% ++ 19% + 34% - 38%	A2-3	+++ 6% ++ 17% + 27% - 50%
A1-4	+++ 3% ++ 9% + 28% - 60%	A2-4	+++ 1% ++ 9% + 25% - 69%
A1-5	+++ 3% ++ 4% + 14% - 79%	A2-5	+++ 3% ++ 3% + 13% - 81%

**Table III**

**Tab. 3\_** Comparison between the result of survey 1 mandible case A1 and alternatives with the result of survey 2 mandible case A2 and alternatives.



**Tab. 4\_** Comparison between the result of survey 1 maxilla case B1 and alternatives with the result of survey 2 maxilla case B2 and alternatives.



**Table IV**

preferred to using it in the maxilla posterior zone. The internal sinus lifting technique was the most preferable technique for use in the maxilla than the other alternatives. Overall, the clinicians found complicated alternatives, such as the bone distraction and nerve transpositioning techniques, the least preferable.

### \_Clinical case

On 24 September 2005, a 49-year-old, healthy, non-smoking male presented with a bilateral free-end saddle mandible and had worn a removable partial denture for more than 11 years. The patient's chief complaint was discomfort when eating, which called for the replacement of the posterior missing teeth for functional reasons. The patient's medical history revealed no significant findings. The results of the extra-oral examination showed a normal facial profile and the intra-oral examination revealed missing teeth #35–37 and 45–47 and a removable partial denture (mandible; Figs. 1–4). Upon radiographic examination, an inadequate root canal treatment with peri-apical cystic lesion (tooth #34) and limited alveolar bone height (7–9 mm in length above the inferior alveolar nerve canal) but with an acceptable bone width on both sides of the mandible was confirmed (Fig. 5).

During the evaluation of the case, the bone augmentation technique (GBR) was introduced to the patient but he refused to undergo this procedure because it was difficult for him to accept the idea of harvesting bone from other parts of his body for use as the bone graft. His other reason for rejecting this treatment was his limited time for visits for the long treatment period necessary for the procedure suggested. The new extraction plus technique was suggested to the patient as an alternative treatment. The treatment would entail extracting teeth #34 and 44 and immediately inserting long implants in the sites of the extracted teeth as support of the short implants to be inserted where the alveolar bone height is limited in place of the missing teeth #35–37 and 45–47 (Fig. 6). The patient accepted the treatment.

During the surgical procedure, an incision was made from the canine crest of the keratinised gingiva to the distal of the second molar of the left mandible mucosa. After a sulcular incision, the full thickness mucoperiosteal flaps were elevated, exposing the alveolar ridge. Using a non-traumatic tooth extraction technique, teeth #34 and 44 were removed with no damage to the surrounding alveolar ridge and the vestibular and lingual bone plate kept intact. The peri-apical cystic lesion on the socket was removed by curettage. After preparation of the tooth socket, a 12 mm length implant was placed. Then drilling was done in region 36 to avoid a mental foramen, followed by drilling in regions 37 and 38 at regular 3 to 4 mm distances. The three short implants placed were 6 mm in length and standard ITI Straumann implants, with 4.1 diameter and 4.8 mm platform diameter. The same procedure was followed on the right mandible, other than the curettage of the socket of 44. Primary stability was achieved in all implants and the submerged surgical approach was followed except for the implants placed into the extraction sites. Panoramic radiography was done after surgery (Figs. 6 & 7). The patient was prescribed a 625 mg antibiotic and instructed to rinse with a 0.2% chlorhexidine mouthwash, use a cold compress and eat a soft diet.

Three months post-treatment the patient returned for a follow-up treatment and it was found that all implants had gained osseointegration successfully and healing caps were provided. The prosthetic phase was begun on 1 April 2006, which was later than the usual time owing to the patient's travelling timetable. Probing of the peri-implant soft tissue found that it was healthy and there was no bleeding around the mucosa of the implant. It was decided to take the final impression for prosthodontics using the impression caps and synOcta positioning cylinder (Straumann) to obtain the master cast (Figs. 8 & 9). After selection of the appropriate abutments, a metal framework was constructed and the prosthetic procedures followed the protocol until the correct seating of the prosthesis was achieved and cemented in the patient's mouth (Figs. 10–16).

### \_contact

### implants

**Maen Aburas, DDS, MSc**

Omaya Medical Center  
P.O. Box 21494  
Dubai, UAE

**Ralf Gutwald, MD, DDS, PhD**

Hugstetter Str. 55  
79106 Freiburg/Breisgau, Germany

ralf.gutwald@uniklinik-freiburg.de

# SwishPlus™ Implant Line

Compatible with Straumann\* Dental Implant System

**NEW**

SCAN ME



Video SwishPlus

## Octagon



**115 Euro**

**All-in-One Packaging for only 115 Euro includes implant, carrier, extender and cover screw.**



- 1 Available in four diameters\* 3.3, 4.1, 4.8, 5.7mm and six lengths 6, 8, 10, 12, 16mm
- 2 2mm neck half textured for tissue-level or esthetic placement
- 3 Micro-grooves for improved tissue attachment & reduced stress
- 4 Progressively-deeper single-lead threads for increased surface area & compatibility
- 5 Self-tapping groove for increased initial stability
- 6 Tapered apical end to initiate self-tapping

*Start with a free sample!\*\*  
Be simply smarter!*



Solid Abutment Kit



Straight Narrow Abutment

Straight Snap-on

Straight Contoured

15° Angled Contoured

Gold/Plastic

Zirconia/Ti Abutment

Angled Zirconia/Ti Abutment

Plastic Temporary Abutment

Ball Attachment

GPS™ Attachment

Screw Receiving

## Innovation & Quality with Added Value!

Implant Direct Sybron sets new standards with high-quality implants that combine low prices and value added All-in-One™ Packaging for as low as 115 Euro per implant, including the corresponding prosthetic components. In addition to the unique Spectra System and the implant systems compatible to Nobel Biocare™, Straumann® and Zimmer® Dental, Implant Direct Sybron offers prosthetic solutions for every indication starting from only 65 Euro.

\*A registered trademark of Institute Straumann  
\*\*Offer available for new customers only. One free implant per practice.



Tollfree Infoline: 00800 4030 4030  
[www.implantdirect.eu](http://www.implantdirect.eu)

Europe's No. 1 Online Provider for Dental Implants



# New concepts in computer-guided implantology

## Part I: Thread timing and implant phase

Author\_Dr Gian Luigi Telara, Italy



Fig. 1a



Fig. 1b



Fig. 1c

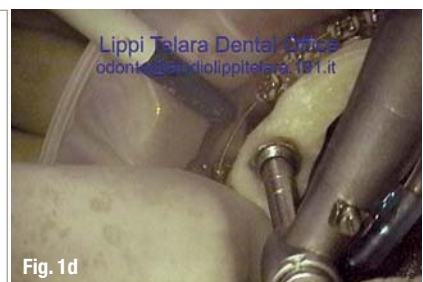

Fig. 1d

**Fig. 1a** Components of the bottle-neck device.

**Fig. 1b** Embedded sleeve.

**Fig. 1c** Osteotomic sleeve.

**Fig. 1d** Modified extender to fit the osteotomy sleeve—any hand-free surgical kit will work.

**Fig. 1e** Bottle-neck.

**Fig. 1f** Bottle-neck created.

**Fig. 1g** Bottle-neck created.

**Fig. 1h** Bottle-neck created.

**Fig. 1i** Assembly while being screwed.

### \_Abstract

In recent years, there has been growing interest in guided implantology. A digital work-up is certainly a great benefit for clinicians to better understand their patients' bone morphology and density and consequently to correctly plan implant positions, and to have their hands guided during implant placement by means of a surgical guide. There are many systems on the market today and many authors have studied post-operative CT scans and planning scans by means of superimposition, in seeking to understand the secret to achieving the perfect correspondence and the best system, but this perfect accuracy has not yet been found and there appears to be a missing link between planning and the actual implant position. I have developed a device (Den-

tal Implant Positioning System, International PCT IT 2009 000192, WO 2010/125593 A1; patent pending) that respects the implant spiral movement when being screwed in accordance with mathematical criteria. The same criteria are also important in theorising limits and achieving accuracy using computer-guided implantology. This article presents two cases that were treated using this device.

### \_Introduction

Accuracy in guided implantology is an issue. The ability to perform implant placement both safely and correctly, in order to load a pre-surgical CAD/CAM bar or cementable metal final framework prosthesis and to digitise the entire procedure, is widely researched. Accuracy



Fig. 1e



Fig. 1f



Fig. 1g



Fig. 1h



Fig. 1i



is a value also in a classical II-stage protocol and respecting hard and soft tissues for long-term implant site stability.

There is an ongoing debate amongst clinicians regarding which is the best available system. Vercauysen summarises this debate.<sup>1</sup> The article reviews only some of the published articles on this topic. All of these articles emphasise the error margins and that they can be considered clinically more or less acceptable, and determine accuracy in implant placement by means of superimposition.

In mathematical terms, "precision" means the repeatability of a measurement, and "accuracy" refers to the correspondence of this measurement to the truth. In our field, accuracy has been considered the correspondence of the placed implant to the planning.

Fortin defines "accuracy" as an ideal, at present somewhat impractical, when considering a definitive prosthesis for immediate loading, with the present systems only offering predictable results (and as such only long-term reinforced provisionals will be available), but does not quantify a threshold.<sup>2</sup> According to Di Giacomo, at present a post-operative impression appears to be always necessary for immediate loading with a definitive prosthesis.<sup>3</sup> Guided implantology is far better than a free-hand approach, however. A guard-rail-like guide is certainly better than nothing.

Many systems are available today, and from a theoretical perspective they have been categorised into semi-active and passive systems. The systems in the first category, whatever the technique used to make the surgical guide (STL or stone surgery), have metal smooth guiding sleeves, which the implant and the implant-driver must pass through, and the second systems, also called navigation systems, do not have any metal sleeves and the surgeon is guided by the monitor. In this category, the surgical handpiece is indexed to spatial markers inside a surgical guide that is inserted into the patient's mouth, but not in the surgical area. These spatial coordinates are viewed by an infra-red system, which transfers data to the computer, allowing the clinician to follow the surgical steps on the monitor. Alarm lights and sounds will warn the clinician of deviations from the desired position.

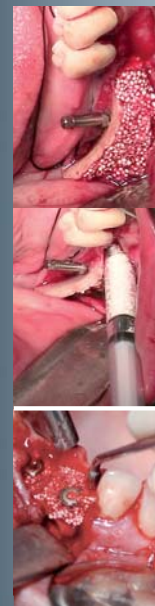I propose a new definition of a passive system: a passive system must allow any operators (i.e. it must be operator independent) to achieve the same, repeatable results at an acceptable inaccuracy threshold.<sup>4</sup> The accepted inaccuracy must allow clinicians to obtain a good metal-to-metal fit without placing tension on the implants. This "to what extent" predictability can determine the reliability of treatment. In fact, in fixed prostheses on natural teeth, passivity (at an acceptable gap) is about 40 to 50  $\mu$  in the arch; the same values could be considered acceptable for prostheses on implants. According to this definition, none of the systems on the market has replicable results, and have metal or virtual smooth sleeves. They must thus be considered metal or virtual smooth semi-active systems.

I have developed a new device according to the mathematical concepts of thread timing and implant phase, which can be applied to the implant movement while being screwed, thus allowing clinicians passivity during implant placement. In the future, owing to the predictability of implant placement, the proposed device could be fundamental to achieving the desired goals in computer-guided implantology.

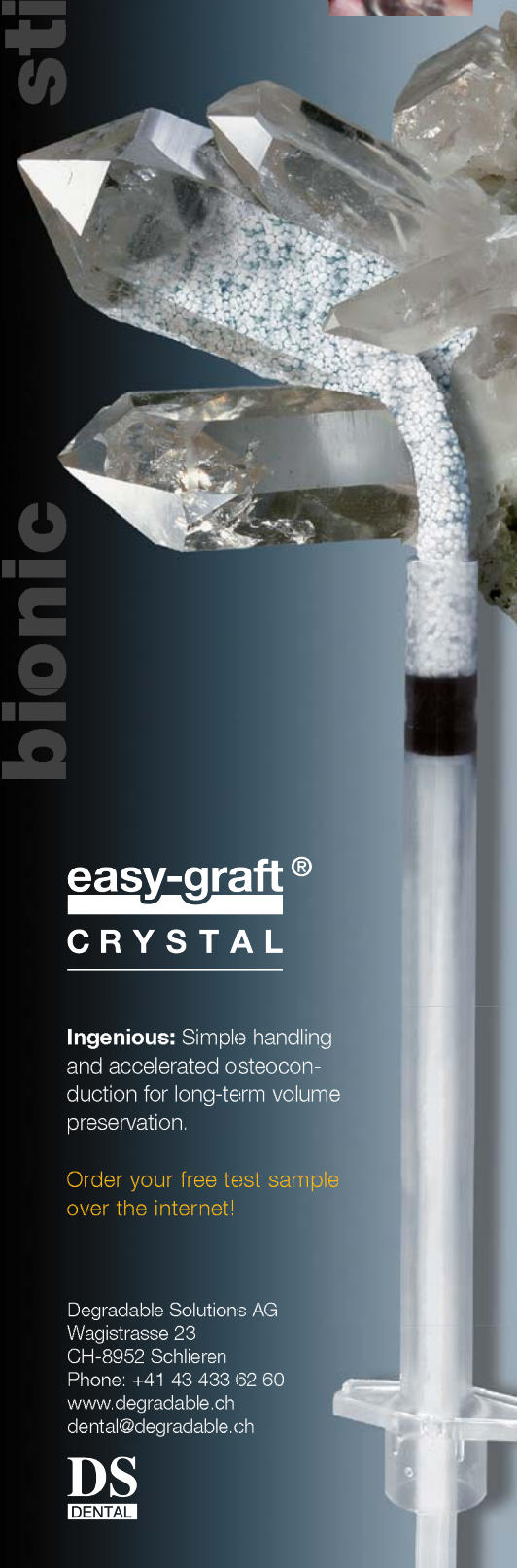## Materials and methods

The implants were placed using the bottle-neck-like device, which begins implant rotation before it can touch the bone, thereby avoiding bone interference with implant movement owing to bone density gradients ("bone guidance"). The prototype of the device (Fig. 1a) consists of:

- an internally threaded sleeve ("embedded sleeve", with a "helical gear" feature at its top that is useful during implant placement; Fig. 1b);



sticky granules  
bionic



**easy-graft®**  
**CRYSTAL**

**Ingenious:** Simple handling and accelerated osteoconduction for long-term volume preservation.

Order your free test sample over the internet!

Degradable Solutions AG  
Wagjstrasse 23  
CH-8952 Schlieren  
Phone: +41 43 433 62 60  
www.degradable.ch  
dental@degradable.ch

**DS**  
**DENTAL**



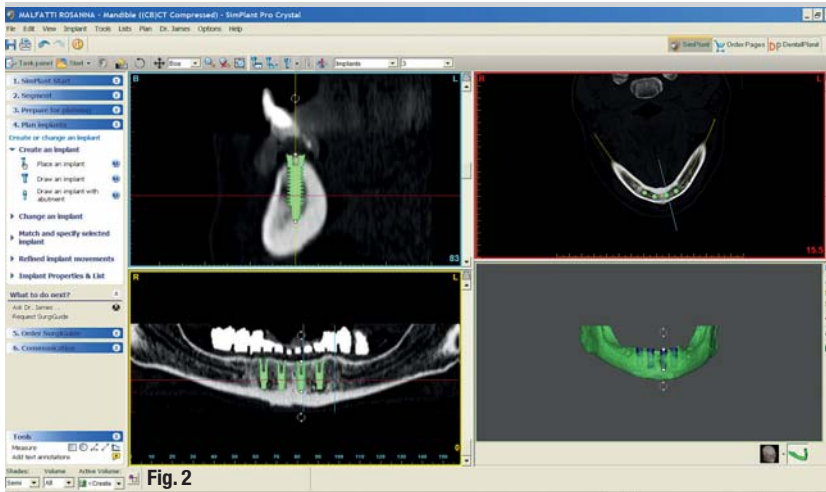


Fig. 2

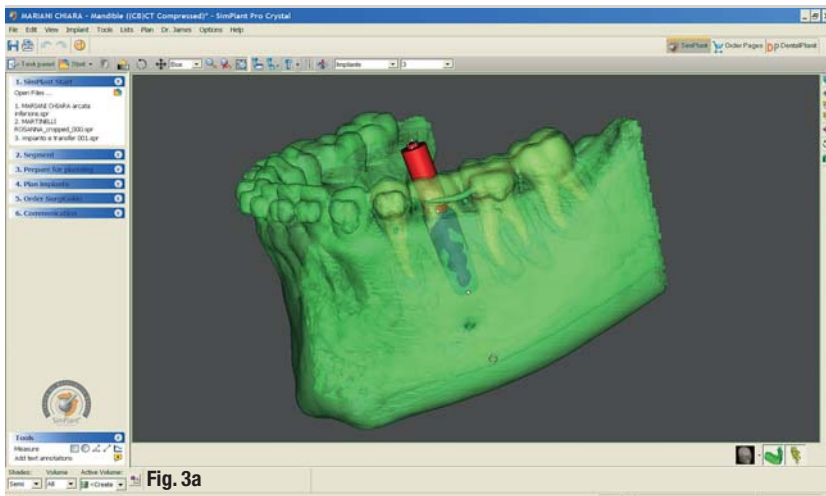


Fig. 3a

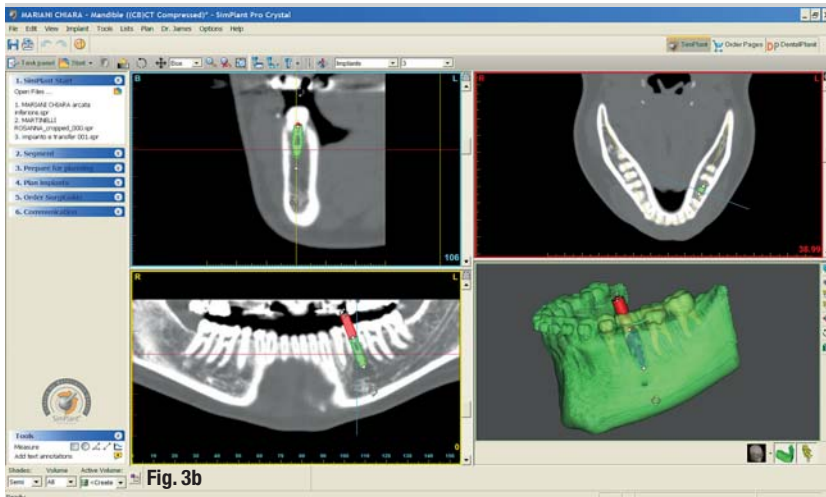


Fig. 3b

Fig. 2 Surgery planning for the STL case.

Fig. 3a Surgery planning for the stone case.

Fig. 3b Surgery planning for the stone case.

- an externally threaded sleeve ("osteotomy sleeve", which has to be inserted into the embedded sleeve and serves as a regular sleeve for the osteotomy drills (because it is internally smooth; Fig. 1c);
- a modified extender for drills (Fig. 1d);
- an externally threaded sleeve, longer than the osteotomy sleeve, that acts as a "bottle-neck" and is screwed into it (Fig. 1e); and
- the "bottle-plug", which is screwed onto the bottle-neck (Figs. 1f-h).

For the osteotomy, I used a regular surgical kit, not a dedicated one to precision, just modifying a plain extender to fit any osteotomy surgical kits (general and not guided surgical kits). The extender should match up with the sleeve before the drill touches the bone. The prototype was realised with no endo-stop features in the extender; only lines indicate depth.

The bottom end of the bottle-plug is provided with a helical gear (to match up with the corresponding embedded sleeve's helical gear; Fig. 1i). The bottle-plug in the prototype device consists of two components, the cylindrical screwed part and the lid, and they are fastened together with a joint. The lid is integrated into the implant mounting component; thus, while the bottle-plug is being screwed onto the neck, the implant mount is entering inside the bottle-neck, forcing the implant downwards. The implant mount has a hollow to allow for an implant fastening screw (the same as used to fix implants and abutments, just longer, to allow for minimal screwdriver length, when it is necessary to unfasten the components at the end). The mount also has a gauge for a wrench at its top (but it can work for a hand-piece driver as well). Once implant placement has been carried out, the mount can be unscrewed from the implant and vertically unfastened from the bottle-plug. At this point, the surgical guide can be removed easily, with no risk of hex undercuts.

The device must resist the vertical dislodging torque created when screwing the implant into the bone. A screwed bottle-neck performs well for this purpose and the lid must be fastened to the vertical part of the bottle-plug. A sleeve to be screwed on the bottle-plug bottom can be realised. SimPlant Pro Crystal (Materialise Dental) was used only to plan the implant position (Figs. 2-3a & b), but instead of using a surgical guide, a STL digital cast with analogue implant holes for placing analogues was used in the first case reported (Fig. 4). A plain stone model with a (presumably) correct analogue position was used for the second case reported (Fig. 5). In both cases, the analogues were fastened to the device, screwed to it, and then the device was secured to a bite-like thing (using plain relining resin for the provisionals) to obtain a surgical guide (no surgical guide fixation to the bone was considered; Fig. 6).

No guided tapping drill was used. This is something that should be considered, especially in high density bone. It could imitate the implant, with acuminate threads and narrow body, to be screwed to the bottle-plug, or a bottle-plug dedicated to the tapping step, with the tapping part integral to the bottle-plug itself.

In both clinical cases, the device was assembled chairside to allow for minimal vertical clearance (Figs. 7a-d). A resin for baseplate was then used to create jigs to check accuracy between the models and the mouth.



Fig. 4

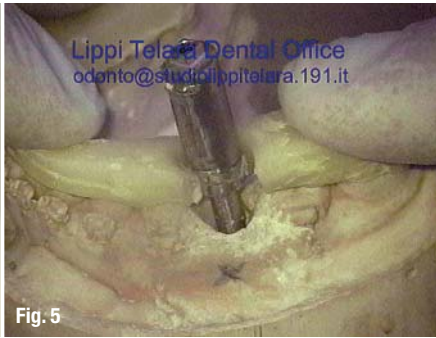

Fig. 5

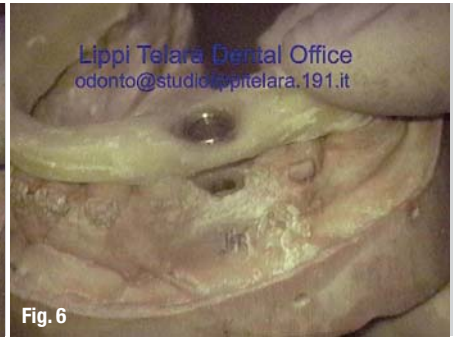

Fig. 6

**\_Results**

The case results were satisfactory. The device was easy to use (Figs. 8a & b) and jig correspondence between the abutments screwed on the analogue models and the clinical implant positions was obtained.

For the STL case, four abutments were modelled on the STL model, the resin jig was created directly in the mouth, and then its correspondence to the same abutments was checked on the STL model (Figs. 9a-c). For the stone case, a transfer was screwed onto the analogue, the resin jig was created, and then its correspondence was clinically checked (Figs. 10a & b).

**\_Discussion**

The present systems do not offer sufficient and reliable accuracy because they do not consider the concepts of thread timing and implant phase. Their weak point is the smooth sleeve (whether metal or virtual), which does not have any control over the mechanics of a screw, which an implant is. Shooting a bullet makes sense, but shooting a screw does NOT.

*Smooth sleeve-dependent inaccuracy*

The first element to be considered is the gap between the implant mount and the sleeve. A twisting implant apex is the natural effect. When the implant is guided by a smooth sleeve, the position in the arch will be correct only if the implant mount does not ever touch the sleeve during the process, but when the dentist is working there will always be contact, which will result in an error in B-L and M-V position. This is what I call the "position paradox effect" of a guiding smooth sleeve (similar to a guard-rail).

Since the sleeve has a top and a bottom plane, this paradox effect is reproduced in both these two planes, and an axis deviation is a natural consequence (what I call the "axis paradox effect of a smooth sleeve"). The gap affects position and axis: these parameters go hand in hand. Depending on the gap entity, it is possible to calculate the implant apex twisting entity, using simple proportionality (Fig. 11a). At a 20 mm depth from the top of the sleeve (approximately 13 mm below the ridge),

the linear deviation will be 0.8 mm (1.6 mm on the diameter that is the possible implant apex twisting entity). Trigonometry is an easy way to calculate the deviation angle of the implant axis (sine/cosine and tan/cot rules). If the gap is 0.1 mm (0.2 on the diameter), the axis deviation will be a deviation of 2° 20' (Figs. 11b-d).

Tapered implants can engage bone at an even greater angle, particularly if the driver is conical at its first part. Consequently, it will work only at the end of the implant placement phase. According to the previous considerations, I suggest that it does not work efficiently. This cone-shaped driver limits too large an insertion torque because it may be damaging; however, the larger the axis deviation, the greater the torque perceived by the operator, who will be given an inaccurate sense of implant stability.

**Fig. 4** Analogues in the STL model.  
**Fig. 5** Surgical guide created for stone surgery.  
**Fig. 6** Surgical guide created for stone surgery.

**Fig. 7a** Assembly.  
**Fig. 7b** Assembly.  
**Fig. 7c** Assembly in the stone-based surgical guide.  
**Fig. 7d** Assembly in the STL-based surgical guide.  
**Fig. 8a** Surgical guide in the mouth.  
**Fig. 8b** Surgical guide in the mouth, showing the helical gear in particular.



Fig. 7a



Fig. 7b

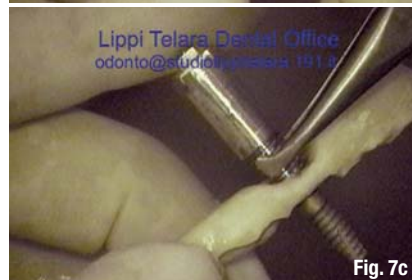

Fig. 7c

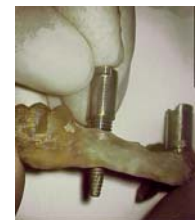

Fig. 7d

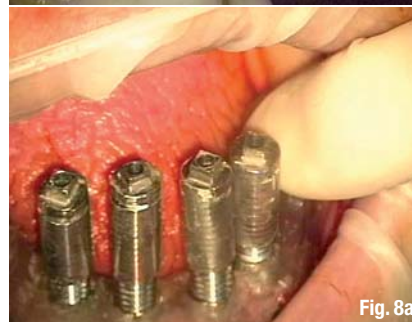

Fig. 8a

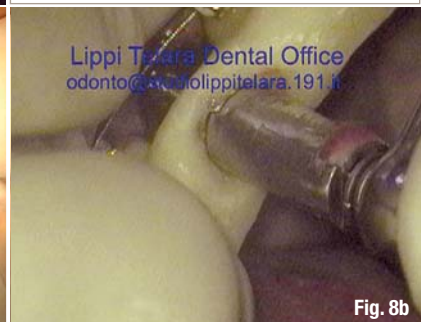


Fig. 8b



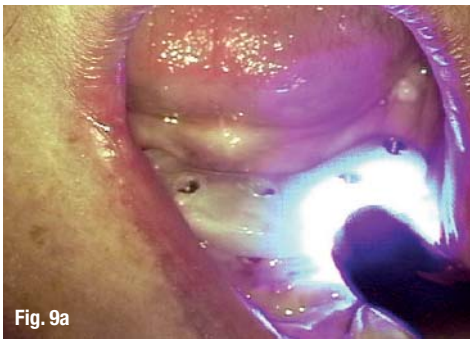

Fig. 9a

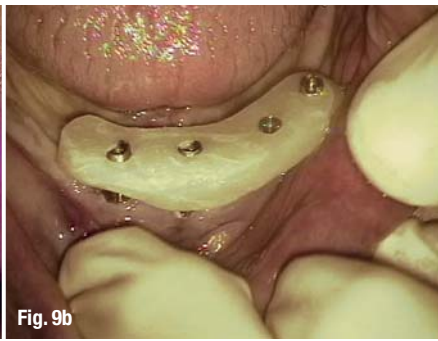

Fig. 9b

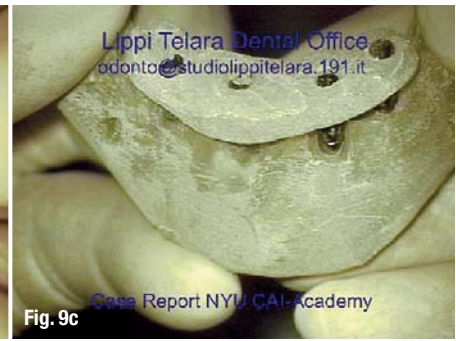

Fig. 9c

**Fig. 9a**\_Jig created in the mouth for the STL case.

**Fig. 9b**\_Jig created in the mouth for the STL case.

**Fig. 9c**\_Jig verified against the model in the STL case.

The good results reported in publications could have been affected by right-handed operators in isotropic D2 and D3 bone or by working in sites in which cortical plates can directionally address implant placement. Excellent results reported could have been affected by working in low-density bone, where the marketed system allows for a good axis and depth, but the drills created a truncated cone volume devitalised area (depending on the drill blades' cutting power and operator's hand force), because the low-density trabeculae would be drilled 360° around. The hex would be missed anyway. The second matter to be considered is bone guidance. Depth and anti-rotational feature orientation depend on bone morphology and density.

When the implant has started its rotation inside the bone, it is not possible to change the threading pattern: while screwing the implant, the platform will move increasingly deeper downwards to the bone. Since it is possible to index a hex to a peripheral point along the circumference and a point along the same circumference can be indexed to the implant thread, the need to change the platform depth and hex orientation and control the threading pattern (implant phase) will be indicated. Any painted notch to index the hex and the sleeve is misleading information and naïve, as it is approximate, that is, no implant phase, and dependent on notch size, point of view (parallax) and operator's visual acuity.

**Fig. 10a**\_Jig created on the stone model in the stone case.

**Fig. 10b**\_Jig verified in the mouth in the stone case.

Once the implant has started its rotation, it is not possible to correct the position by redirecting the implant, as the apex is inserted into the bone and will act as a fulcrum. Even if the operator redirects the implant

axis, the implant body will remain displaced in position (B-Land M-D). Moreover, the redirection would be done by sight, which is dependent on the operator's visual acuity and a parallax error is a possibility.

The axis deviation introduces another concept: bone response in terms of bone density and bone anisotropy. As a matter of fact, on the other side of the surgical guide, when the implant touches the bone, with a smooth sleeve it is impossible to predict when it starts being screwed. The moment the implant starts rotating depends on the bone friction, depending on the density (HU), and the progression of the osteotomy and the implant insertion will be dependent on the HU gradient (anisotropy), which describes how rapidly the density changes per unit of length along the three spatial coordinates inside the bone. Unless we use a device able to force implants in a precise position (referred to as the surgical guide) along a path engineered according to a particular mechanics, the bone will determine the implant threading pattern (bone density for initial screwing, whether or not a crestal bone drill has been used) and bone density gradient, or anisotropy for the subsequent axis.

Accepting inaccuracy, manufacturers and researchers have created depth-control systems in the hope of offering certainty about this parameter at least, but the gap will be responsible for not only position and axis deviations, but also depth errors. In fact, the implant mount endo-stop will match up with the sleeve at an angle. The first contact will be beyond the desired depth, and keeping on screwing the implant will create a great torque with surgical guide deformation and tension on the bone.

The complete contact will correspond to a deeper implant position than desired. The correct depth may be halfway (maybe operator dependent and determined using the naked eye). Depth error, axis deviation and translation in crestal position in the axial deviation direction will be the results (Figs. 12a-e).

The likelihood of ideally positioning two implants is one out of seven billion and 500 million possibilities (just a few million less, if it is any comfort to us). And this eval-

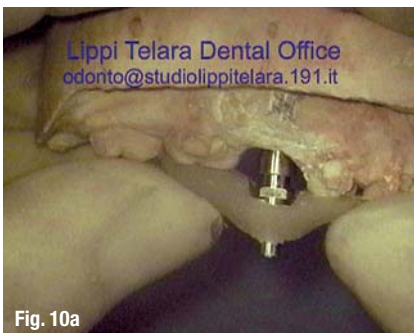

Fig. 10a

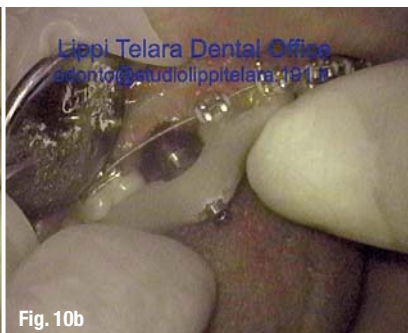

Fig. 10b



uation comes from a 0.1 mm mean deviation and 1° deviation, which implies insufficient inaccuracy. Fancy what the chances would be of achieving acceptable accuracy.

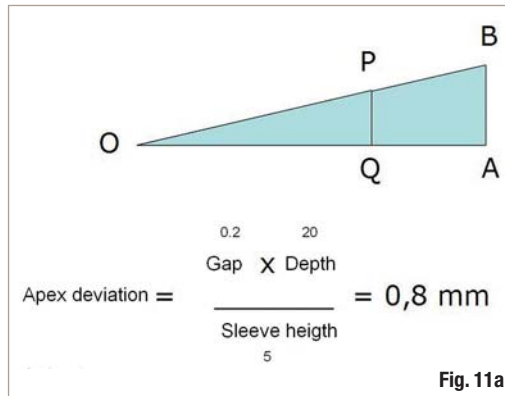
*Thread timing and implant phase*

From a mathematical perspective, it is possible to describe all implant spatial coordinates concentrated on the platform, where we can summarise everything, and calculate its trajectory to create kind of a spiral path, through which it is possible to start and stop an implant platform along all the parameters, thus being able to truly speak of implant-guided prosthodontics.

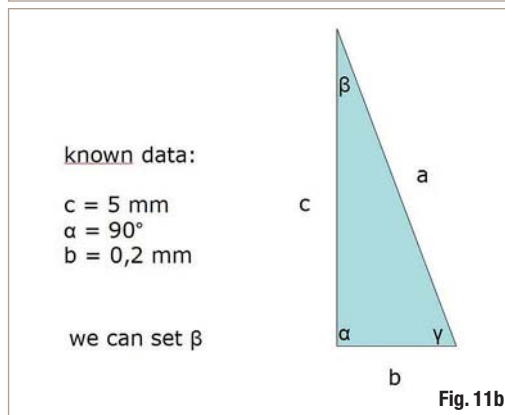
The idea is based on the following: when screwing a coca-cola plug onto the bottle-neck, the final position will always be the same (Figs. 13a & b). Once two final positions have been found, two threads will be inside the plug; once three final positions have been found, three threads will be present on the plug. The label written on the plug can be considered to be a hex (or a trilobe). So the hex, that is the platform, can easily be reproduced in its position because the thread pattern and hex are indexed to each other. This means that if we can control the threading pattern, we can consequently control the platform position too.

According to this consideration, all the parameters that define the platform position can be controlled. The parameters are the position in the arch (B-L and M-D), the axis, the depth and the anti-rotational feature (classically, a hex) orientation.

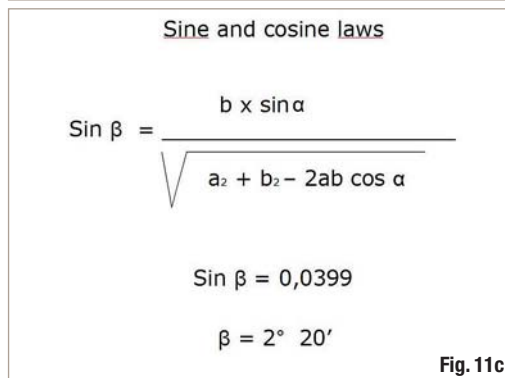
The mechanical engineering of a screw is quite different from that of a bullet (smooth sleeve) and was defined by Archimedes (applications of an endless screw are still in use today, like the meat mincer) and by Euler (Swiss mathematician, who died in St Petersburg more than two centuries ago). In particular, Euler pointed out that the movement of a circle (in our field, the implant platform) can be described with mathematical formulas: a point along the circumference (in our field the perimetric projection of a part of the hex) can be projected along a plane orthogonal to the direction of the circle movement itself (in our field, the progression of the platform while the implant is being screwed in multiplanar reconstructions). The projection will describe a sine wave (in our field, the sine wave period can be identified with the implant thread pitch). With this in mind, I developed the device discussed in this article, which controls the threading pattern. In mechanical engineering, this is called thread timing, and the hex position can be defined as hex timing. For both of them we can speak of phase control (i.e. we can speak of the phase of the implant, both for the thread and the hex). Along this spiral track, the implant can be theoretically and actually screwed and unscrewed as many times as we desire (back and forth), and it will always be possible to know



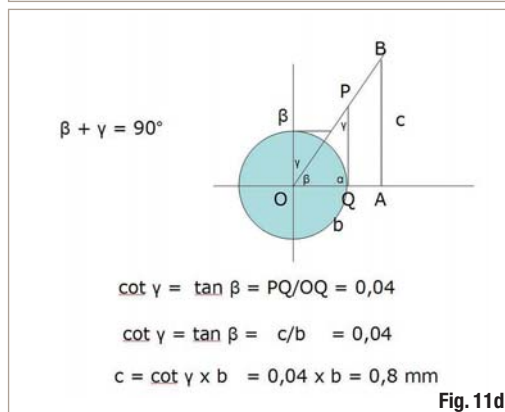
**Fig. 11a**\_Mathematical proportion to calculate the linear radial apex deviation.



**Fig. 11b**\_Calculation of the trigonometric angle deviation.

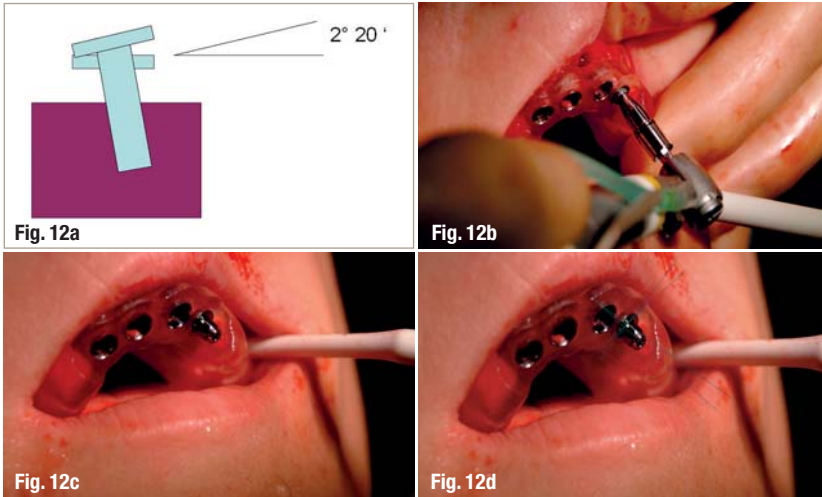


**Fig. 11c**\_Calculation of the trigonometric angle deviation (sine/cosine rule).



**Fig. 11d**\_Calculation of the trigonometric angle deviation (tan/cot rule).

the hex position at the end of the spiral path (final analogue and implant position; Figs. 14a–c). As a spiral circular motion is transformed into a pure translation, a threaded device will respect also position and axis. The information needed to correctly (position and axis, anti-rotational feature and depth) place an implant is in its



tion deviation (in the arch this will signify a possible 2/100 mm deviation), no axial deviation, depth and anti-rotational feature correspondence. This discrepancy is within the limits that allow the clinician to make a pre-made final prosthesis and allows for presumably optimal long-term tissue stability.

Some of the systems available also consider hex orientation position, but in order to seat the implant correctly with regard to the anti-rotational feature, an extra rotation may be needed. Speaking of "correctly", at which angle resolution? If the feature described is in the shape of two points (painted or alike) to be vertically aligned, what is the point dimension? What is the eye resolution? Is it possibly a parallax error? Extra-rotation is an implicit admission of inaccuracy: the depth will not be respected as well, and the implant platform depth may be a little above or below the desired position (it depends on the degree to which the operator is out of phase, more or less than 180°). It is easy to realise that, unless all this has been calculated, all attempts to find the anti-rotational feature position and depth are only guesswork—a waste of time! Thread timing and implant phase have not been respected. Forget any notches on the implant mount and smooth sleeves, if anti-rotational feature orientation is the goal. Notches are history in digital guided implantology.

**Fig. 12a** Missed implant position parameters in the depth-control systems owing to congruent triangle considerations (implant axis deviation and endo-stop angle).  
**Fig. 12b** Missed implant position parameters in the depth-control systems owing to congruent triangle considerations (implant axis deviation and endo-stop angle).

platform and inside its threads. By creating in the surgical guide a track along which the implant is screwed before its contact with the bone, it is logically possible to start and stop the implant with a final seating with all the parameters always reproduced. We can thus decide when to stop the implant during its fall along this spiral track. The final position will always be the same, that is repeatable, and operator independent. The device meets my earlier definition of a passive system.

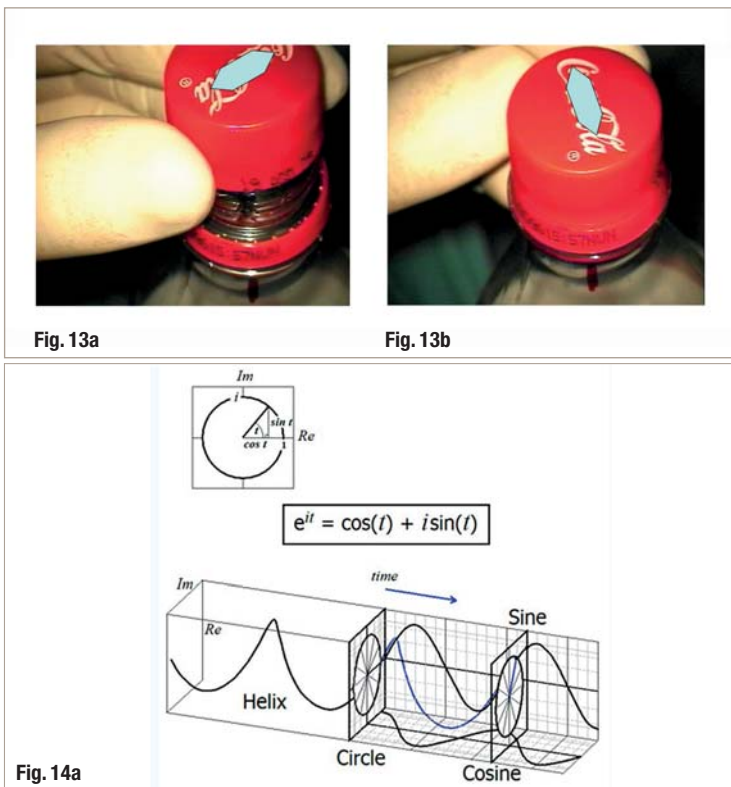
The maximum precision possible will be what manufacturers can effectively offer (a 1/100 mm is expected to be realistic), which corresponds to the actual implant placement. With a threaded system, there is no axial deviation. Therefore, there will only be a 1/100 mm posi-

Once we have set a threading pattern, it is possible to set the stop point simply making a helical gear (a helical gear is realised by contouring the thread along its 360° run; a vertical step will be present once we have gone 360° all round) both in the bottle-neck plug and in the embedded sleeve (the coordinating feature inside the surgical guide), so that a vertical stop is realised in the device. When the two vertical parts match up, we can be certain that the hex is just where we have engineered it to be.

The device pitch must have the same implant pitch because differences will lead to bone stripping. In fact, a difference in implant and mount insertion speed (i.e. the distance covered in depth every 360°) and a different wave period (i.e. thread pitch), will lead to something different from an out of phase working device; it will lead to bone stripping. In particular, a longer mounting period will force the implant downwards into the bone, with consequent vertical bone stripping, whereas a shorter mounting period will force the implant to rotate horizontally, with consequent horizontal bone stripping. Self-tapping implants should show better torque control.

*Rigidity*

The device must be secured to the surgical guide to resist the rotational torque and vertical torque always present during the implant rotation inside the bone.



*Components and undercuts*

In the prototype device, a driver for a ratchet was used. It was completely redundant because the ratchet can cooperate directly with a plug-top feature for a ratchet at its top; thus, the driver is something that can be eliminated. Once the assembly has been fixed to the embedded sleeve, the plug can be screwed with the fingers, at least until sufficient torque is found, when a ratchet can be used.

When multiple implants have been planned, in case of divergent implants, hex undercuts could prevent the surgical guide from releasing itself from the bone, once the implants have been placed. In order to resolve this, the device, at least the mounting part, must be removed from the surgical guide. The device is thus divided in two components and the lid, which is integral to the driver, can be unscrewed, leaving the surgical guide along with all the other components still fastened to it, but disengaged from the implants, freely and easily removable. For single implant placement, the lid is not necessary, because there are no hex undercuts. In this case, a bottle-plug with one component will be sufficient.

*Crest module*

The implant crest module morphology does not affect this guiding device because the bottle-neck's internal diameter is just a little wider than the implant diameter at any point (platform or below the platform). By the way, additional threads in the crest module are not important either because, mathematically speaking, they are harmonic waves of the implant period (thread pitch).

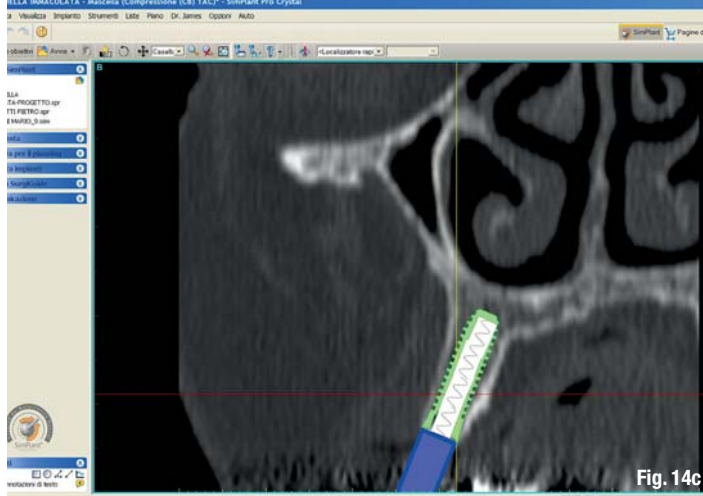
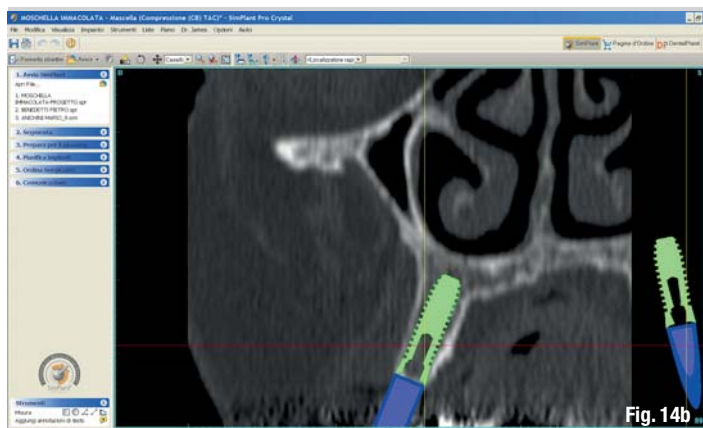


*Master cast*

The helical gear can easily be oriented vestibularly in the threaded guiding device before pouring the master model.

*Vertical clearance*

To make the correct surgical guide, the helical gear must be engineered in the planning at a multiple pitch distance from the bone, just equalling the implant length (the implant must start rotating before it touches the bone to avoid bone guidance). For instance, the dis-



tance will be 9 or 10 mm for 9 or 10 mm long implants with a 1 mm pitch, and the distance will be a multiple of 0.75 for a 0.75 mm pitch (9 mm will correspond to 12 implant revolutions and 10.5 mm to 14 revolutions). The average mouth opening values should be considered. In case of tapered implants, a short distance can be considered because the implant apex can enter the osteotomy hole without being engaged. To reduce vertical clearance, the device can be pre-assembled, thus obtaining a working length even shorter than that of the present systems (Fig. 15). A shorter vertical clearance is possible also with trans-mucosal implants because the platform results are more superficial.

*Editorial note: A list of references is available from the publisher.*

\_contact
implants

**Dr Gian Luigi Telara**  
 Studio Odontoiatrico Lippi Telara  
 Via Vorno, 9/4  
 55060 Guamo Lucca (Italy)  
 Tel.: +39 0583 947568

lippitelara@gmail.com

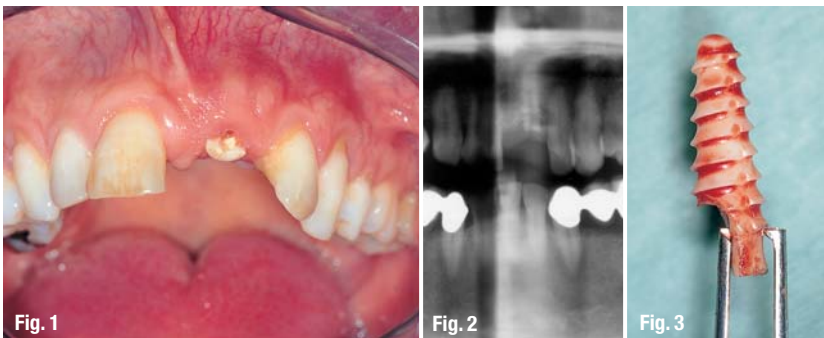- Fig. 12c\_** Missed implant position parameters in the depth-control systems owing to congruent triangle considerations (implant axis deviation and endo-stop angle).
- Fig. 12d\_** Missed implant position parameters in the depth-control systems owing to congruent triangle considerations (implant axis deviation and endo-stop angle).
- Fig. 13a\_** Coca-cola screw plug analogy.
- Fig. 13b\_** Coca-cola screw plug analogy.
- Fig. 14a\_** Euler's formula.
- Fig. 14b\_** Euler's formula in applied mathematics.
- Fig. 14c\_** Euler's formula in applied mathematics.
- Fig. 15\_** Vertical clearance paragon.

First published: Dent. Implantol. 8, p. 374-382 (2004), Spitta Verlag



# Second implantation after **implant fracture**

**Authors**\_Dr Michael Hopp, Andreas Klar, Prof Dr Reiner Biffar, Germany



influenced by bone availability and, potentially, fractures to the alveolar process as well as inflammations. These properties determine the temporal and technical approach for a replacement implant. Attention must be paid to the primary stability of second implants, which is easily achieved through the use of implants with a larger diameter, if possible of the screw type.

## \_Case description

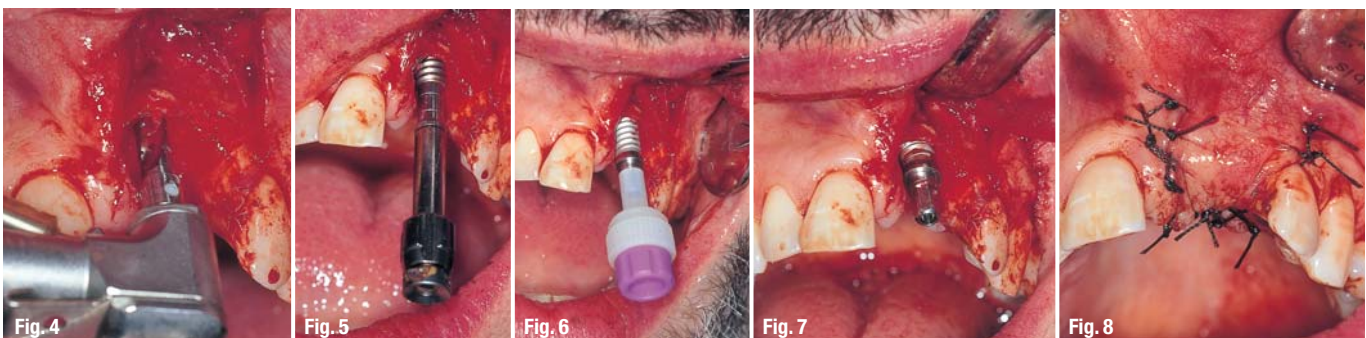
The first implant was placed in region 21 in the now 54-year-old patient after a front tooth had been lost in 1992. An  $Al_2O_3$  implant manufactured by Cerasiv was inserted. It is interesting to note that the first implant fractured during placement and was replaced with an implant of the same structure. The healing process was without complications and occurred over a period of 6 months. After the location had been opened up, a titanium insert was cemented into the implant, this was then shaped and a metal ceramic crown added. The diastema had been left after the first implant, in accordance with the patient's wishes.

Over the 12-year period of the implant being in place, the non-inflammatory peri-implant tissue was of note, the sulcus of which extended down epithelially over the years, thus reducing the amount of active bony interface. The patient fell off a bicycle at the end of 2003 and fractured the implant in the re-

**\_To date, implant fractures** are regarded as an extreme situation, to be feared due to the severe injuries to the jaw and the destruction of the supra-contruction. The reality is often different in cases of the effects of force (fall, blow, etc.). Fracture of the implant often remains the exception, as screws or abutments fracture instead, or the damage to the bone remains manageable and repeat treatment is possible. The following case shows the procedure for a replacement implant with an IMPLA screw implant after fracture of a ceramic implant.

Ceramic implants are susceptible to fracture due to their hard and brittle properties.<sup>1</sup> Furthermore, surrounding epithelial growth into the depths of the alveolus has been observed for such implants<sup>2</sup>, which can result in subsequent loss of the entire implant with no bleeding. The possibility of a replacement implant is therefore generally always an option and

- Fig. 1** \_Original situation following fracture, frontal view.
- Fig. 2** \_X-ray (section) of the fractured implant.
- Fig. 3** \_Fractured implant.
- Fig. 4** \_Pilot drilling to extend the depth of the implant cavity.
- Fig. 5** \_After mechanical preparation of the implant cavity the cutter is now applied.
- Fig. 6** \_After the thread is cut the implant is placed in the bony cavity.
- Fig. 7** \_Implant in situ.
- Fig. 8** \_Suture closure of the trapezoidal flap.



# 42<sup>ND</sup>

## INTERNATIONAL ANNUAL CONGRESS OF THE DGZI



October 5–6, 2012


Hamburg//Elysee Hotel



Gold Sponsor:



Silver Sponsor:



Bronze Sponsor:



### FAX REPLY

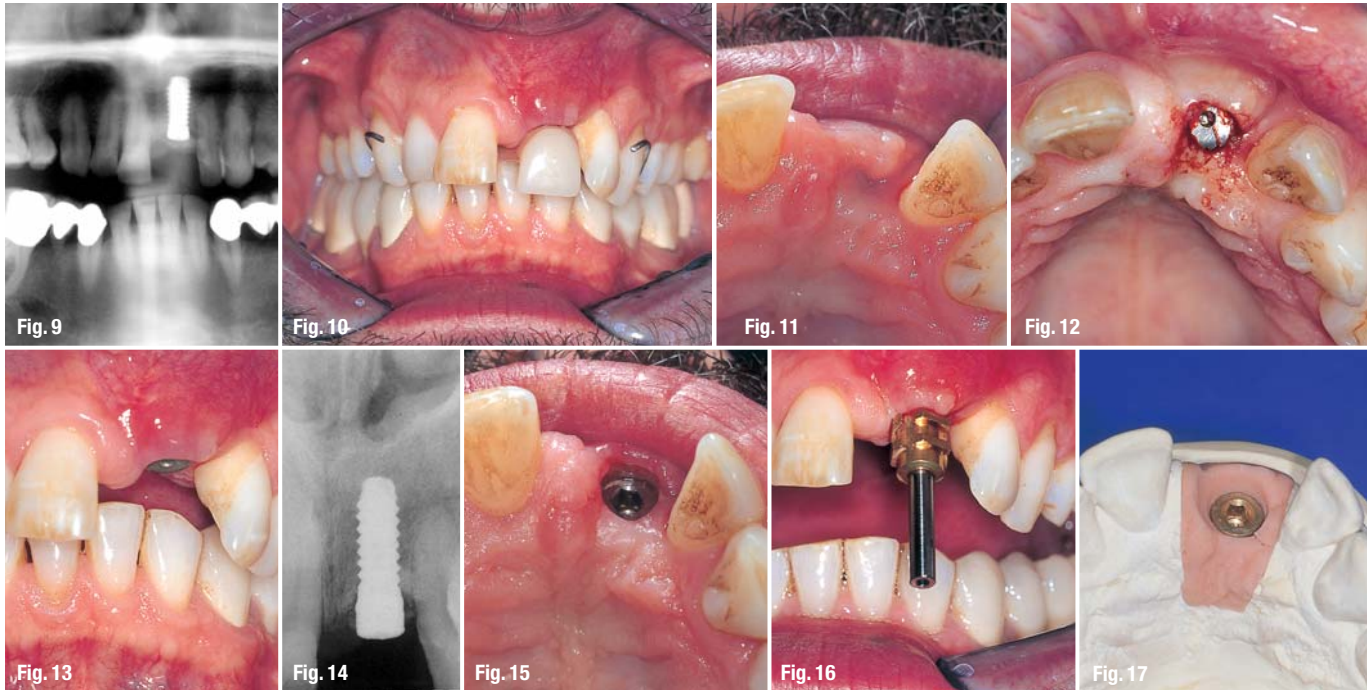
**+49 341 48474-390**

Please send me further information on the  
42<sup>ND</sup> INTERNATIONAL ANNUAL CONGRESS  
OF THE DGZI October 5–6, 2012, in Hamburg, Germany.



Office Stamp





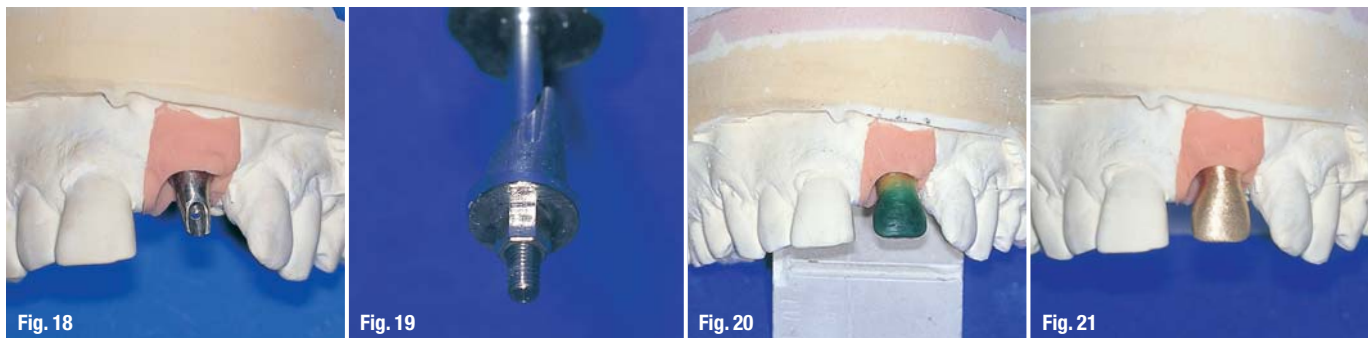
**Fig. 9** OPG after implantation.  
**Fig. 10** Temporary restoration with a removable denture.  
**Fig. 11** Situation after healing process, seen from occlusal view.  
**Fig. 12** After opening up.  
**Fig. 13** Situation with the gingiva former.  
**Fig. 14** Implant with good osseointegration.  
**Fig. 15** Gingival situation after opening up.  
**Fig. 16** Inserted impression post.  
**Fig. 17** After taking the impression the model with gingiva mask is produced.  
**Fig. 18** Adapted abutment.  
**Fig. 19** Internal hexagon to prevent rotation.  
**Fig. 20** Model of the crown.  
**Fig. 21** Processed crown cap prior to application of the ceramic.

gion of the neck, losing the prosthetic crown (Fig. 1). Figure 2 shows the situation on an X-ray image. The patient was treated with antibiotics (Clindamycin 900 mg/d), the planned intervention was explained to the patient and the removal of the implant and new implant planned for two days later. After preparation of a trapezial flap with a crestal incision and removal of the ceramic implant (Fig. 3), the deep-seated epithelium and connective tissue was removed and the remaining bony cavity prepared for the placement of a new implant with a greater diameter (Fig. 4). The remaining implant bed was revealed to be a very solid cortical structure, such that a thread had to be pre-cut for the new implant (Fig. 5). The IMPLA implant (Schütz Dental Group, Rosbach), 14.5 millimetres in length and with a diameter of 5.3 millimetres, was inserted and the insertion aid was removed (Figs. 6 & 7). To compensate for the loss in bone height in the crestal region, an augmentation was carried out using BioOss (Geistlich) and covered with the resorbable membrane, Ossequest (W. L. Gore, Putzbrunn). The membrane was fixed in place using the implant's cover screw and the margins of

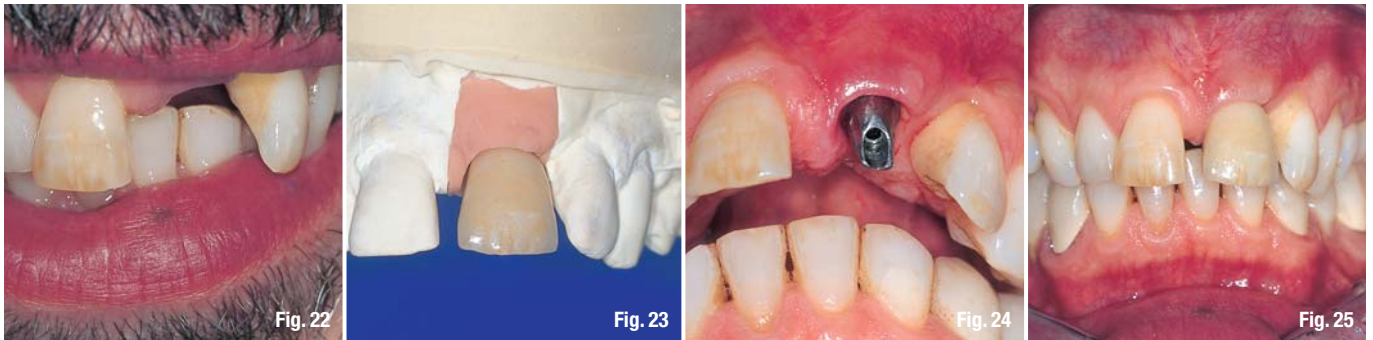
the muco-periostal flap. The site of the operation was closed with 9 simple interrupted sutures (Fig. 8) after mobilization of the muco-periostal flap through periost slitting and a control X-ray was taken (Fig. 9).

During the 6-month healing phase, a denture with a prosthetic tooth anchored with a clamp was worn (Fig. 10), which had been relined underneath with Flexor CC (Schütz Dental, Rosbach) to prevent any pressure on the site.

Following healing (Fig. 11), the covering mucosa was opened with a semi-circular cut with a scalpel under local anaesthetic (Fig. 12) and a cylindrical gingiva former, 2 mm in height, was inserted (Fig. 13). The X-ray shows an implant with good osseointegration (Fig. 14) and, to a large extent, maintenance and restoration of the gingival structures (Fig. 15). Only the papillary region between 21 and 22 is reduced. The prosthetic treatment was conducted after the gingival tissues had healed. The impression was made using Impregum (3M ESPE, Seefeld) and







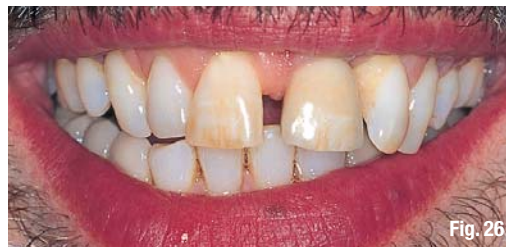the open tray technique (Fig. 16). The model made from type-IV gypsum with a gingival mask permits the production of an aesthetically high-quality crown (Fig. 17). An angled abutment was selected to correct the angulation and adapted to follow the line of the gingiva (Fig. 18). The internal hexagon connection prevents rotation (Fig. 19). A cementable metal ceramic crown, based on an alloy with a high gold content that can be fired, completes the restoration (Fig. 20). The diastema at the front was left in accordance with the patient's wishes, as was the slightly rotated and paradontally worn no. 2 (Fig. 21). The otherwise triangular crown of the no.1 was rounded off distally so that the papillary triangle between 21 and 22 was less prominent. The colour was adjusted to the lively colour of 11 in the laboratory in the presence of the patient (Figs. 22 & 23). The abutment (Fig. 24) was screwed in at a torque of 20 N/cm and the crown was inserted for three weeks on a provisional basis (Fig. 25).

Final cementing has not yet been carried out as the temporary cementing is very stable and it was not possible to remove the crown using adequate means. Figure 26 shows the lips and a portrait of the patient. The functional and aesthetic restoration was therefore successful.

## Discussion

Rapid treatment in cases of second implantations is advantageous, as the alveolar bone is not changed any further or resorbed. Treatment with an antibiotic such as Clindamycin, that penetrates into the bone, should always be administered first to restrict the peri-implant inflammation and inflammation due to the fracture. A closed approach and adherence to the standard required healing time is to be favoured in cases of an additional fracture of the alveolar bone or differences between the geometry of the implant and bone availability, which both require augmentation procedures. Situations where a diastema is present are particularly complicated from an aesthetic perspective. The division of the gap when using conventional prosthetics usually produces unsatisfactory results as the teeth with a replacement crown

are wider than those without. In such cases, an implant is the only viable alternative. The no. 2 that was rotated in the current case was fashioned more aesthetically through application of a direct or indirect veneer and build-up of the papilla. However, the patient's consent is prerequisite to this.



**Fig. 22** The gap requiring restoration.  
**Fig. 23** Fired ceramic crown.  
**Fig. 24** Inserted abutment.  
**Fig. 25** Crown in situ.

**Fig. 26** Oral situation.

Dispensation with or a temporal delay to conventional permanent cementing does not constitute a contradiction to the production of a cemented crown. The timing of the final restoration can easily be delayed as the abutment is not susceptible to attack by caries and loosening of the crown is rapidly noticed. The crown is checked for loosening at the regularly spaced recall appointments.

*Editorial note: A list of references is available from the publisher.*

## contact

## implants

### Dr Michael Hopp

Kranoldplatz 5, 12209 Berlin, Germany

### ZTM Andreas Klar

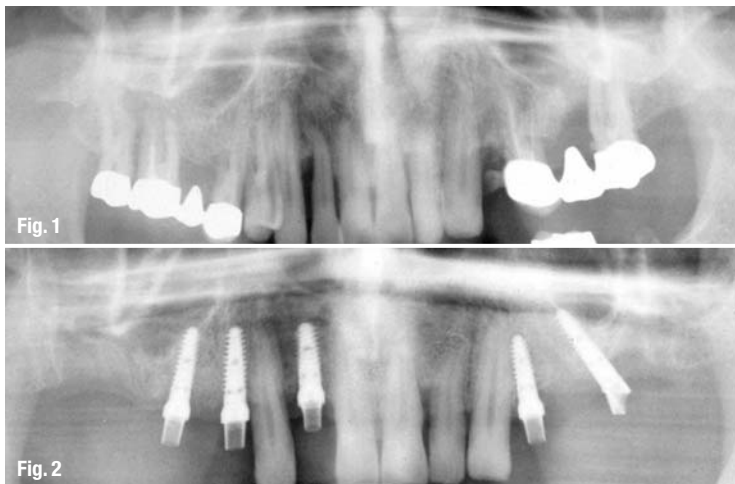
Certified Dental Technician  
 Dental Laboratory Rübelling & Klar  
 Ruwersteig 43, 12681 Berlin, Germany

### Prof Dr Reiner Biffar

Ernst Moritz Arndt University of Greifswald  
 Centre of Dentistry and Oral Health  
 Dept. of Prosthetic Dentistry and Dental Materials  
 Rotgerberstr. 8, 17475 Greifswald, Germany

# Use of tilted implants in the treatment of the edentulous posterior maxilla

Author\_Prof Gregor-Georg Zafiropoulos, Germany



**Fig. 1** \_The orthopantomogram shows the initial situation.

**Fig. 2** \_Individual implant abutments 14 and 16 (both inserted axially).

**Fig. 3** \_Individual implant abutments 24 (inserted axially) and 26 (tilted).

**Fig. 4** \_The orthopantomogram shows implant placement and impression.

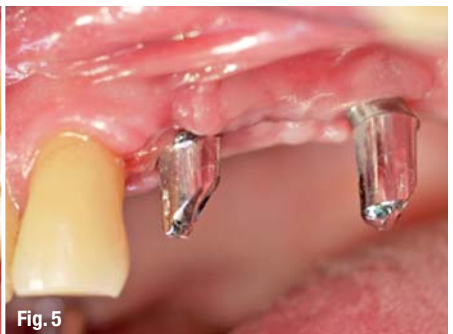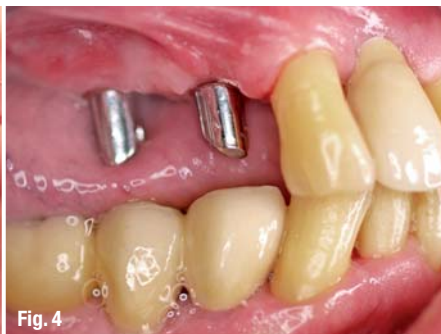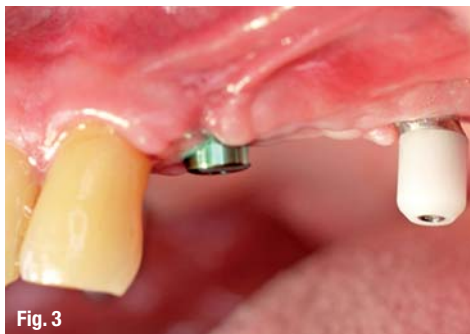\_This case report describes the technique of implant insertion in the edentulous maxillary posterior region at an angle of 35° to avoid a sinus lift procedure and immediate restoration using fixed partial dentures (FPD), e.g. bridges.

Since the introduction of the technique of inserting posterior tilted implants at an angle of up to 35° (in relation to the vertical axis) and the corresponding prefabricated abutments for the treat-

ment of the edentulous maxilla or mandible, implant dentistry has experienced a change in its previously established, conventional surgical and prosthetic thinking (Maló *et al.* 2003, 2005, 2006). With implants inserted in this unorthodox manner, implementation of regenerative measures in the posterior regions of the atrophic and/or partially edentulous maxilla and mandible is avoided, allowing immediate loading and restoration.

Clinical studies show that the success and survival rate of implants inserted at such an angle are comparable to those inserted at a conventional angle (Khatami & Smith 2008; Krekmanov *et al.* 2000; Hinze *et al.* 2010). Further results demonstrated that there was no significant difference in bone loss between implants inserted with a conventional axis and those inserted at an angle (regardless of jaw and/or region; Zampelis *et al.* 2007; Francetti *et al.* 2010).

This implantation technique was developed for the rehabilitation of an edentulous jaw, but only very little information is available about its application for rehabilitation of partial edentulism in posterior regions with FPD (Rocuzzo *et al.* 2009; Cordaro *et al.* 2009). This report presents observa-



tions made over one year of a representative case, in which the edentulous posterior regions of the maxilla were reconstructed using implant-supported FPDs.

## Case report

A 51-year-old male patient (non-smoker) presented himself at the practice of a colleague because of advanced periodontal destruction in the maxillary arch one year before the start of the treatment described in this report (Fig. 1). Teeth #12, 14 to 18, 24 (retained root) and 25 to 27 were extracted. The extraction sockets were covered with dPTFE membranes (Cytoplast, Osteogenics Biomedical) with no additional use of grafting material, as previously described (Hoffmann *et al.* 2008; Zafiroopoulos *et al.* 2010). The mucoperiosteal flap was repositioned and fixed in the region of the papillae using interrupted sutures (Cytoplast, Osteogenics Biomedical). The membranes remained partially exposed and were removed after four weeks. The edentulous areas were then fitted with a model cast prosthesis.

About one year after the extractions in the maxilla, the patient presented at our practice for implant treatment. The patient suffered from bilateral chronic sinusitis and would not allow a sinus augmentation to be performed. Five implants (3.75 mm in diameter and 11.5 mm in length; SoftBone, Dentegris) were placed in regions 12, 14, 16, 24 and 26. The implants inserted in regions 12, 14, 16 and 24 were inserted conventionally, i.e. axially, and an internal sinus lift was performed in region 16 (Fig. 2). The implant inserted in region 26 was inserted at an angle of 35° to the vertical axis and immediately provided with a 35° titanium abutment (DAAS abutment 35°, Dentegris; Fig. 3). An impression was taken using system-specific impression posts (pickup posts were used for the axially placed implants and DAAS posts for the tilted implants, both Dentegris) and a polyether impression material (Impregum, 3M ESPE; Fig. 4). The implants were then provided with system-specific healing caps (Dentegris; Fig. 5).

Three days after implantation, transfer keys were used to fit individual abutments. To fabricate the individual abutments, platinum/iridium/plastic abutments (PTIR abutments, Dentegris) were used as a modelling aid consisting of a prefabricated cast-on base made of platinum-iridium and a screw channel made of residue-free burn-out plastic. To fabricate the abutment for 26, a system-specific castable plastic cylinder (DAAS plastic cylinder, Dentegris) was used. On the same day, both a metal framework made of a cobalt-chromium alloy (ZENOTEC NP, Wieland) and a temporary restoration made of plastic (ZENO-PMMA; Wieland) were milled for immediate restoration of implants 14 to 16 and 24 to 26. The framework was fitted and the temporary restoration was fixed using a temporary cement (TempBond, Kerr; Figs. 6–11). Four months after implant placement and progressive immediate loading with the long-term temporary restoration, the final restoration was fitted using a temporary eugenol-free cement (Implant-Provisional, Alvelogro; Fig. 12).

## Conclusion

Under certain conditions (no active periodontal disease, good patient cooperation, good bone quality), successful early or immediate loading of implants in the posterior maxilla is possible in selected cases. Primary stability and implant design play a major role in the success of the implantation and restoration/loading of bridge restorations on tilted implants (Javed & Romanos 2010, Javed *et al.* 2011). On the basis of the scientific results published to date, it is not possible to discuss evidence-based contraindications (based on the required and measurable values of primary stability, bone density and quality, and influence of occlusal forces). As a result, many questions remain unanswered and risks uncertain (Rocuzzo *et al.* 2009).

In our opinion, the primary benefit of using tilted implants is not necessarily the option of immediate implantation and loading, but firstly the avoidance of augmen-

# TRI

dental implants



**TRI® Performance Concept**  
A revolutionary new implant concept  
in implant dentistry

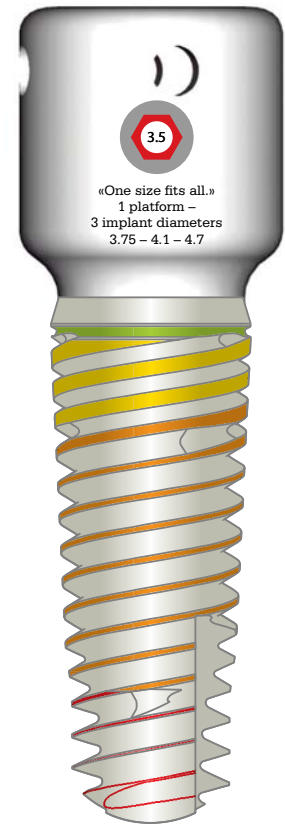


Image:  
Esthetic Healing Collar (TVHC 50-60-A)  
For soft tissue suture fixation, 45 Euro  
TRI-Vent Implant (TV41B11), 115 Euro

### 1. TRI® – Friction

This frictional connection guarantees maximum stability and eliminates the risk of a microgap in the platform switch concept.

### 2. TRI® – BoneAdapt

The patented conical implant body has been designed to perform and adapt ideally in the respective bone areas.

### 3. TRI® – Grip

The apical part of this implant allows for a maximum of initial stability for all indications, but specifically for immediate placement.

**Enhanced Hard and Soft Tissue Management with the patented TRI Dental Implant System. Designed in Switzerland. Made in Germany.**

### TRI® Performance Days

23.11.2011 Reggio Emilia

26.11.2011 Hamburg

#### Speaker:

Dr. Marius Steigmann

#### Scientific Co-ordinators:

Sergio Spinato

Alberto Caffarri,

Roberto Franceschetti

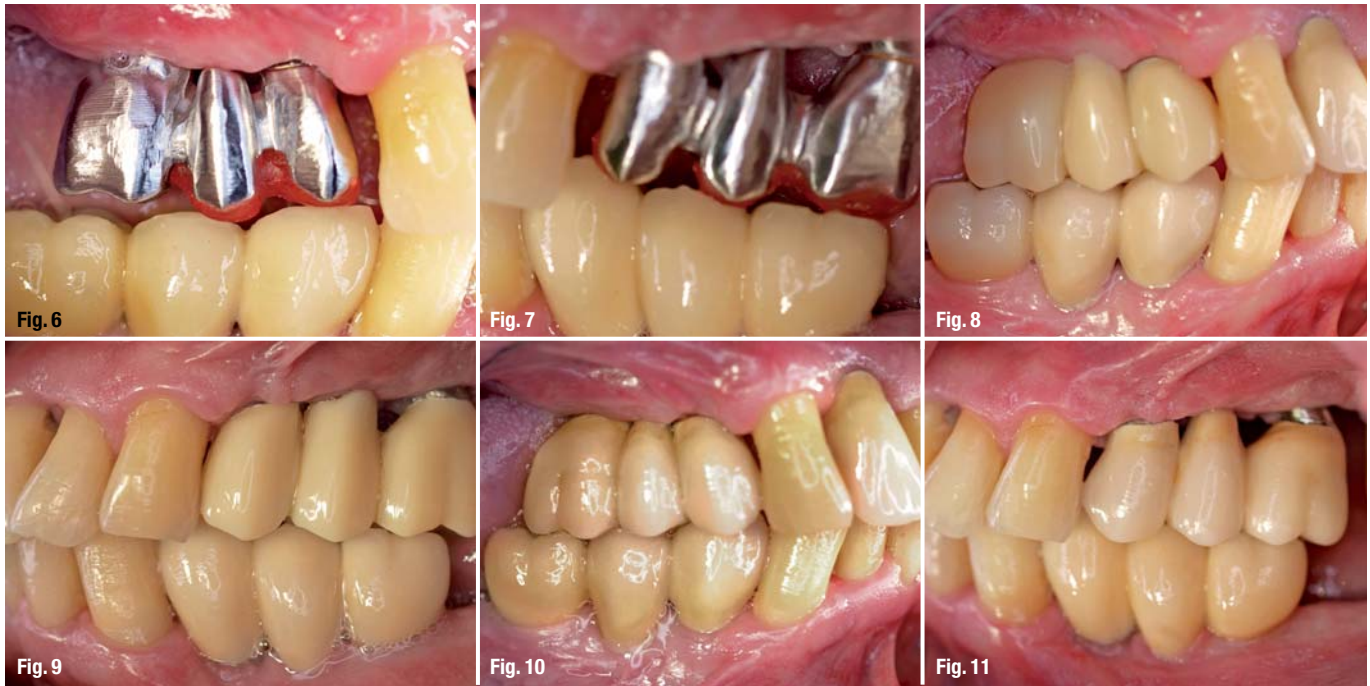
Test FREE sample!

Through Research Innovative

www.tri-implants.com

Gratis Infoline: 00800 3313 3313





**Fig. 5**\_Implants with healing caps (here an axially placed implant in region 24 and an implant placed at a 35° angle with a DAAS healing cap in region 26).

**Figs. 6 & 7**\_Fitting of the metal frameworks.

**Figs. 8 & 9**\_The implants loaded with temporary FPDs made of ZENO-PMMA.

**Figs. 10 & 11**\_The implants loaded with final metal ceramic FPDs.

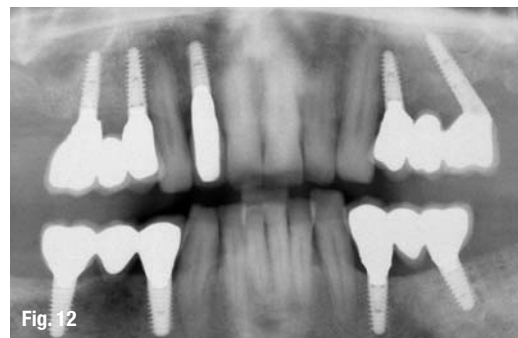tative measures (e.g. sinus lift) and secondly treatment with a fixed restoration (Rosén & Gynther 2007; Aparicio *et al.* 2001). Regardless of the many positive scientific reports, the dentist should be aware of the risk of implant loss associated with immediate implant placement and loading. In addition, the dentist should define his/her own limits and select patients based on strict criteria.

**References**

C. Aparicio, P. Perales & B. Rangert, Tilted implants as an alternative to maxillary sinus grafting: A clinical, radiologic, and periosteal study, *Clinical Implant Dentistry and Related Research*, 3/1 (2001): 39–49.  
 L. Cordaro, F. Torsello & M. Rocuzzo, Implant loading protocols for the partially edentulous posterior mandible, *International Journal of Oral and Maxillofacial Implants*, 24/7 suppl. (2009): 158–168.  
 L. Francetti, D. Romeo, S. Corbella, et al., Bone level changes around axial and tilted implants in full-arch fixed immediate restorations. Interim results of a prospective study, *Clinical Implant Dentistry and Related Research* (published online 26 Oct. 2010) <DOI 10.1111/j.1708-8208.2010.00304.x>

M. Hinze, T. Thalmair, W. Bolz, et al., Immediate loading of fixed provisional prostheses using four implants for the rehabilitation of the edentulous arch: A prospective clinical study, *International Journal of Oral and Maxillofacial Implants*, 25/5 (2010): 1011–8.  
 O. Hoffmann, B.K. Bartee, C. Beaumont, et al., Alveolar bone preservation in extraction sockets using non-resorbable dPTFE membranes: A retrospective non-randomized study, *Journal of Periodontology*, 79/8 (2008): 1355–69.  
 F. Javed & G.E. Romanos, The role of primary stability for successful immediate loading of dental implants. A literature review, *Journal of Dentistry*, 38/8 (2010): 612–20.  
 F. Javed, K. Almas, R. Crespi, et al., Implant surface morphology and primary stability: Is there a connection? *Implant Dentistry*, 20/1 (2011): 40–6.  
 A.H. Khatami & C.R. Smith, "All-on-Four" immediate function concept and clinical report of treatment of an edentulous mandible with a fixed complete denture and milled titanium framework, *Journal of Prosthodontics*, 17/1 (2008): 47–51.  
 L. Krekmanov, M. Kahn, B. Rangert, et al., Tilting of posterior mandibular and maxillary implants for improved prosthesis support, *International Journal of Oral and Maxillofacial Implants*, 15/3 (2000): 405–14.

*Editorial note: The whole list of references is available from the publisher.*



**Fig. 12**\_Orthopantomogram after restoration.

<b>_contact</b>	<b>implants</b>
<p><b>Prof Gregor-Georg Zafiropoulos</b>                  Blaues Haus, Sternstr. 61                  40479 Düsseldorf                  Germany</p> <p><a href="mailto:zafiropoulos@blaues-haus-duesseldorf.de">zafiropoulos@blaues-haus-duesseldorf.de</a></p>	

”Action is the foundational key  
to all success.“

Pablo Picasso



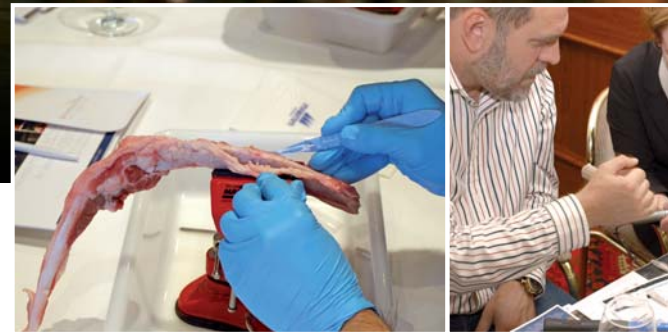become an author for “implants”

► Contact Georg Isbaner: [g.isbaner@oemus-media.de](mailto:g.isbaner@oemus-media.de)



# Implantology in Cologne

Author\_Jürgen Isbaner, Germany



**The 41<sup>st</sup> International Annual Congress** of the German Association of Dental Implantology (DGZI) took place in Cologne the weekend of September 30 to October 1, 2011. Over both congress days we welcomed up to 450 participants coming from all over Germany, Middle East, and Japan.

This year's congress was just as well received as other previous and successful DGZI congresses. DGZI president, Prof Dr Dr Frank Palm, and the scientific organizer of this year's congress, Dr Roland Hille, commented that it was DGZI's aim to inspire colleagues with up-to-date expert information and practical tips about implantology. The theme of "Implantology today—requirements, possibilities and expectations" allowed for an especially broad array of scientific lectures. Within the frame of a very complex scientific programme, renowned speakers from home and abroad presented current trends and topics on almost the whole range of modern implantol-

ogy. DGZI, the oldest European implantological association, kept to its goal of surprising the audience with expert speakers who are the best in their fields.

## **What should and what must be done?**

A current topic which will no doubt continue to be debated in future discussions of dental practice was highlighted in the podium discussion "Digital implantology—What should and what must be done?" The combining of navigated implantology and intraoral digital impression (direct data capturing) with digital workflow is currently an issue in the spotlight for dentists and dental technicians as well as patients. "The future of dental medicine is more exciting than it has been ever before", says Dr







Hille. "The development potential of industries seems to be endless, and expectations and technical desires of patients are unlimited. DGZI sees its role as a companion on the way to future—but nevertheless we do not lose sight of technologies' suitability for practical use."

### From theory to practice

From the very start of the congress a great range of workshops and hands-on courses were offered for practical exercises. The participants could become familiar in detail with the current developments concerning implants, bone substitutes and membranes, as well as with diagnosis, navigation and CAD/CAM technologies.

Especially during this IDS year, the abundance of new products and technologies meant that much more information was required. Collegial interchanges coupled with some helpful tips were of very special importance.

Thanks to the many exhibitors who enabled direct contact to industries, participants had access to products and their practical applications.

In addition to the programme for dentists there was an accompanying programme for technical implantology assistance staff. At the top of their agenda were e.g. tooth decay and periodontitis prophylaxis, communication with patients and hygiene in the dental practice.

The 42<sup>nd</sup> Annual Congress of the DGZI will be held in Hamburg, Germany, from October 5 until October 6, 2012.   



# 20<sup>th</sup> Annual Congress of the EAO

Author\_Daniel Zimmermann

Photos\_Annemarie Fischer, Germany

The 20<sup>th</sup> annual congress of the European Association for Osseointegration (EAO) took place under less-than-ideal conditions. Huge piles of garbage bags littered the narrow alleys of the Greek capital, and metro buses and trains were not running for most of the time owing to the ongoing public service strikes. Furthermore, air-traffic controllers in several European countries threatened to stop working during the week in which the congress was to take place. Despite these unfavourable circumstances, more than 3,000 dental clinicians and researchers in the field of implantology attended the dental implant event of the year, which took place at the Megaron Athens International Conference Centre not far from the Presidential Mansion in Athens.

Since 1991, the Brussels-based EAO has organised congresses in different European cities annually, for example, in the Scottish metropolis Glasgow last year and the principality of Monaco in 2009. Despite the prevailing mood of the financial crisis, this year's congress, organised in partnership with three Greek dental organisations, went relatively smoothly, the organiser said. Speaking to Dental Tribune in Athens, most visitors and exhibitors also expressed satisfaction with the scientific and commercial offering. Their only criticism was the distri-

bution of booths over three levels inside the venue that seemed to favour only those companies exhibiting on the ground level. Improvements in this regard were announced, however, by the organisers for next year's event.

In advance of the congress, German professor Friedrich Wilhelm Neukam from the University of Erlangen, who chaired the Organising Committee this year with Prof. Asterios Doukoudakis from the University of Athens, had said that implant treatment planning would be a major topic, particularly with regard to new imaging techniques and computer-assisted implantation. In a scientific session held on Thursday and moderated by Prof. Christoph Hämmerle from the University of Zurich in Switzerland, the latest methods for computer-aided implant fabrication were discussed by renowned specialists in the field like Dr Theodoros Kapos (USA) and







Prof Sandro Palla (Switzerland). In addition, University of Pennsylvania professor Michael Bergler presented the latest CAD/CAM systems and discussed their current and future impact on dental laboratories in Europe.

Other topics received with great interest were genetic predictability for dental implant loss, which has not yet been scientifically proven, and the pros and cons of implant treatment in adolescents.

In addition to their established product lines, industry players introduced several innovations at EAO. At a press conference held on the second day of the congress, for example, the US implant company Zimmer presented its latest implant design to dental journalists in Europe exclusively. Several new products were also revealed by other industry giants like Nobel Biocare and Straumann. The latter showcased its new small-diameter, soft tissue-level implant, as well as a new restorative material developed in collaboration with 3M ESPE. According to the company, it combines nano-ceramic components with a highly cross-linked resin matrix for improved

aesthetics and stability in the fabrication of dental crowns, inlays, onlays and veneers.

Nobel Biocare announced NobelClinician, new diagnostic and treatment planning software for Apple and Windows operating systems, as well as two new NobelReplace implants with a complete range of pre-fabricated and individualised prosthetic solutions. Further innovations were also exhibited by Keystone Dental, Tigran from Sweden, and the Swiss company CAMLOG.

"We are very pleased with the high-level presentations and scientific works showcased here," remarked Neukam. "However, we are still facing many challenges in clinical research. The conclusions of many speakers were that more research is needed to be able to generate consensus statements in the field."

According to Neukam, the organisation's next congress is scheduled for October 2012 and will look back at implantology research over the past 20 years. It will be held in the Danish capital of Copenhagen.





# Manufacturer News

## CAMLOG

### 4<sup>th</sup> International CAMLOG Congress

Scientific and technical precision have long been at home in Switzerland. Switzerland is not only unmatched in watch technology, but also at the forefront throughout the world in various other areas of technology. This includes medical technology, in which Switzerland is traditionally well represented—not in the least by Basel-based CAMLOG Biotechnologies AG, parent company of the internationally successful CAMLOG Group.

During the 4<sup>th</sup> International CAMLOG Congress from May 3 through 5, 2012 in Lucerne, many recognized speakers will present on a variety of scientific and tech-



nical subjects about state-of-the-art of implant dentistry. Congress participants will have the opportunity to increase their academic knowledge on the one hand, and to further improve their clinical results in their daily practice on the other. With “in the heart of Switzerland”, the second part of the symposium leitmotif, CAMLOG will create a traditional Swiss environment for the Congress, in which the international par-

ticipants will be introduced to the latest implant dentistry developments in a most memorable ambiance. The highly popular CAMLOG Party will be held at the evening of May 4 unusual altitude of 1,600 meters above sea level with a sensational alpine view—Let’s rock the Alps! is the motto. CAMLOG is looking forward to feeling the pulse of science in the heart of Switzerland on the occasion of the 4<sup>th</sup> International CAMLOG Congress. Registration for the Congress is now open at: [www.camlogcongress.com](http://www.camlogcongress.com)

#### CAMLOG Foundation

Margarethenstrasse 38  
CH-4053 Basel, Switzerland

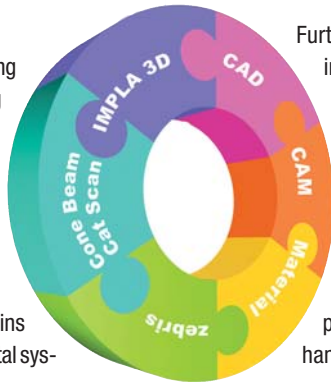
[info@camlogfoundation.org](mailto:info@camlogfoundation.org)  
[www.camlogfoundation.org](http://www.camlogfoundation.org)

## Schütz Dental

### Complete Digital Workflow

It’s done! Digital networking now offers you outstanding advantages. These advantages will set you apart from your competitors and will ensure your long-term success.

This Digital Workflow contains several well-coordinated digital sys-



tems. Schütz Dental offers the connection of: Tizian™ CAD/CAM, zebis (TMJ function analysis), IMPLA 3D (implant surgery navigation).

Furthermore, the user has the option to integrate other open systems, such as e.g. CT and CBCT systems, intra-oral scanners and laser sintering systems: This complete Digital Workflow only available from Schütz Dental! The significant advantages for you: increased safety, more efficient work, higher precision, independence and enhanced image.

Of course, this Digital Workflow is continuously developed further and our team is constantly seeking additional networking possibilities. Contact us today to make an appointment for an individual demonstration to experience the new features yourself, and do not forget to ask for more information on the official, exclusive kick-off event, as well!

#### Schütz Dental GmbH

Dieselstr. 5–6  
61191 Rosbach, Germany

[export@schuetz-dental.de](mailto:export@schuetz-dental.de)  
[www.schuetz-dental.com](http://www.schuetz-dental.com)

## Implant Direct Sybron

### New SwishPlus™ Offers Surgical & Prosthetic Compatibility with Straumann

SwishPlus™, a new addition to the Implant Direct Sybron product line, offers a unique combination of design improvements while providing compatibility with Straumann’s surgical and insertion instruments as well as prosthetic components. Like the Straumann tissue level implants, SwishPlus™ has a straight-walled body with flat-based threads matching the 1.2mm pitch to make it surgically compatible with

Straumann’s drills and bone taps. A long, vertical cutting groove is provided for self-tapping insertion and the apical end narrows to help initiate insertion. The threads get progressively deeper and extend right to the apex for additional surface area and initial stability. Designed for versatility in implant placement, the 2 mm flared neck has the textured surface extending up 1 mm to facilitate deeper insertion in the esthetic zones without contributing to bone loss when a smooth neck is placed sub-crestal.

The SwishPlus™, like the Straumann implant, has an internal octagon, originally licensed to Straumann in 2000 under Niznick’s #4,960,381 internal

connection patent. The SwishPlus™ fixture-mount not only allows for placement with either Straumann tooling or a standard ratchet but it also offers a clinical advantage. Each implant comes in an All-in-One Package with the frictional fixture-mount, a cover screw for two-stage healing and a 2 mm healing collar for only 115 Euro.



#### Implant Direct Sybron

Europe AG  
Hardturmstrasse 161  
8005 Zürich, Switzerland

[info@implantdirect.eu](mailto:info@implantdirect.eu)  
[www.implantdirect.eu](http://www.implantdirect.eu)

Degradable Solutions

**Sunstar Suisse SA takes over Degradable Solutions**

The privately-owned Sunstar Group, one of the world's ten largest companies in the field of Mouth and Body Care, is announcing the complete takeover of Degradable Solutions AG. Sunstar Suisse SA has taken over all the shares of the company, a spin-off of the Federal Institute of Technology Zurich (ETH), from the previous private owners. Dr Kurt Ruffieux, the founder and CEO of Degradable Solutions, will from now on manage the company as an autonomous business unit of Sunstar. The entire organisation with more than 25 staff, and all activities at the headquarters in Schlieren near Zurich, are also being taken over. At the same time, Masakazu Nakamura, CEO of Sunstar Suisse SA, and Cyril Alemany, Director New Business Development of Sunstar Suisse SA, are joining the Board of Directors of Degradable Solutions. The parties have agreed not to divulge any details about the transfer price.

With this takeover, Sunstar is significantly expanding the technology sector of regenerative medical products. This core competence of Degradable Solutions involves products that have a temporary function in the body and then degrade automatically. The company attracted attention with the injectable bone regeneration material easy-graft, which rapidly advanced to 3<sup>rd</sup> place in the European dental market. The two partners intend to bring together existing designs under the umbrella brand of GUIDOR, develop new pioneering therapies and products, and thus gain a leading position in the market.

Masakazu Nakamura, CEO of Sunstar Suisse SA, comments: "With Degradable Solutions, we are broadening our worldwide technology network by adding a unique gem. As a spin-off of the internationally renowned ETH, Degradable Solutions is much more than a promising start-up company. With products that have already been successfully launched on the market, and a complete value creation chain from research via development and production to marketing, Degradable Solutions is excellently positioned in a rapidly growing market with high margins. This acquisition takes us closer to the vision of positioning Sun-



star as a total-oral-health-company. With the internationally patented and certified know-how of Degradable Solutions, we can take the vital step of expanding our products and services from prevention to therapy."

Dr Kurt Ruffieux, the founder and CEO of Degradable Solutions, adds: "Today is an important day in the history of our company. With the globally active Sunstar, we have found the best partner for the next phase in our growth. Not only do we work in the same field of medicine, and our technology and product ranges supplement each other perfectly, we also share the same philosophy. As focused private companies, we both have a commitment to research and development, and the conviction that continuous innovation is capable of steadily improving both the well-being of patients as well as cost-effectiveness in the healthcare field. Our staff and I look forward to the future of Degradable Solutions as part of the Sunstar Group."

**Degradable Solutions AG**

Wagistrasse 23  
8952 Schlieren, Switzerland

info@degradable.ch  
www.degradable.ch

BEGO Implant Systems

**Former S-Line Tray and drills phase-out on the 1<sup>st</sup> January 2012!**

End of 2010 BEGO Implant Systems presented the new BEGO Semados® S-Line TrayPlus with the appropriately redesigned drills.

The new tray contains everything except the S 5.5 drill module, which can be ordered separately as required. Drill stops are not included but a drill stop tray can be ordered separately if required. The long awaited optimized surgical tray is not only more clearly organized but also easier to use.



The drills have undergone to a complete redesign—the cutting geometry has been optimized for noticeably smoother and safer working when preparing the implant bed. Moreover, extremely clear depth mark-

ings in the form of block laser marks and additional grooves help to accurately gauge drilling depth. The paralleling posts and depth gauge have been modified in line with the new drill geometry—for optimum implant bed preparation. The internal cooling feature has been removed from the new drills for hygiene reasons.

This was the ideal way to meet hygiene chain requirements as prescribed by QA standards; furthermore, there is no longer any need for time-consuming cleaning of the internal cooling channel using cleaning reamers.

By way of transition, the previous generation of S-Line surgical trays (large), containers, drills (with internal cooling) and other BEGO Semados® S-Line instruments will still be available for purchase until the end of 2011.

**BEGO Implant Systems GmbH & Co. KG**

Technologiepark Universität, Wilhelm-Herbst-Straße 1  
28359 Bremen, Germany

info@bego-implantology.com  
www.bego-implantology.com

Straumann

**Straumann presents new small-diameter soft tissue-level implant**

Designed for limited inter-dental spaces or narrow bone ridges, the new Straumann® Standard Plus Narrow Neck CrossFit® ('NNC') small diameter soft tissue-level implant offers increased flexibility and additional treatment options, combining the exceptional strength of Straumann's proprietary Roxolid® material, the rapid osseointegration of the SLActive® surface and the reliability and improved handling advantages of the CrossFit®



connection. The NNC implant is indicated for a variety of uses, including single-tooth replacement and multiple-tooth replacement with bridges and fixed or removable overdentures. The new implant facilitates soft-tissue management and can be placed in a one step procedure.

Roxolid has been the key to the development of the NNC. The material's physical strength has enabled Straumann to develop a small diameter implant with an internal rather than an external connection. The design of the implant-abutment interface

provides an excellent seal and distributes the biting pressure optimally. It also offers greater flexibility for prosthetic angulation.

A broad portfolio of surgical and standard prosthetic components is available for the NNC and will be complemented by custom abutment options shortly after the full market release.

**Institut Straumann AG**

Peter Merian-Weg 12  
4052 Basel, Switzerland

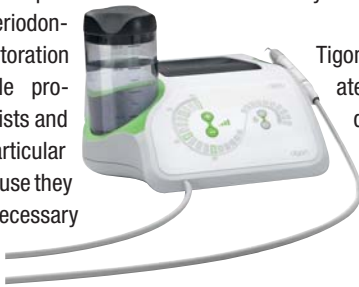info@straumann.com  
www.straumann.com

W&H

**Perfection made simple**

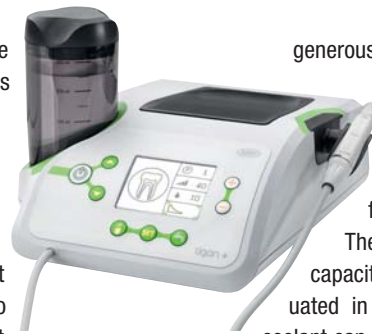With Tigon+ W&H has developed a piezo scaler that optimally meets the needs of the patient and dentist.

Tigon+ has some unique features. The best for the patient: the temperature-controlled fluid. Even sensitive teeth and gums are no longer irritated from now on. Three temperature setting are available for selection. The heating is very easy to set on the display and can also be switched off as required. The five preset programmes (Prophylaxis, Periodontology, Endodontics, Restoration and a freely selectable programme) mean that dentists and dental technicians in particular work more efficient, because they avoid the otherwise necessary manual setting of func-



tions for the scaler and machine. The navi-tooth on the display shows which programme is currently in use. The three power modes allow the user to define the scaler power according to their preferences. Dentists and dental technicians work in the safe knowledge of not treating the tooth too gently or too hard, but working with just the right pressure. The W&H LED technology ensures perfect lighting conditions and allows the user improved visual perception and the same contrast sensitivity as in daylight. The handpiece and LED ring can be thermally disinfected and sterilized effortlessly.

Tigon—a piezo scaler that can be operated with ease. The user increases or decreases the power of the scaler by simply pressing the plus and minus keys and the coolant flow rate at the same time. Other advantages: a stable-standing coolant tank, a



generously dimensioned tray and here too, of course, a handpiece with innovative LED technology ensuring perfect lighting conditions. The coolant tank has a capacity of 400 ml and is graduated in 50 ml steps—so the coolant can be mixed directly in the coolant tank. In addition, the tank stands solidly and stably, even when not attached to the device. It is convenient to set down instruments on the generously equipped tray during treatment. The user can then remove the tray—together with the 360° rotating handpiece support—from the Tigon and thermally disinfect and sterilize it.

**W&H Deutschland GmbH**

Raiffeisenstraße 4  
83410 Laufen, Germany

office.de@wh.com  
www.wh.com

Nobel Biocare

**Nobel Biocare successfully launches a CHF 120 million domestic straight bond issue**

Nobel Biocare has successfully launched its inaugural CHF-denominated domestic straight bond issue in the aggregate principal amount of CHF 120 million with a coupon of 4 %, due 10 October 2016.



Nobel Biocare will use the bond proceeds to partially refinance the outstanding convertible bond, which becomes due in November 2011. Nobel Biocare views this bond issue as a particular success given the current, highly volatile market environment.

**Nobel Biocare Holding AG**

P.O. Box  
8058 Zurich, Switzerland

info.switzerland@nobelbiocare.com  
www.nobelbiocare.com



# International events

**2012**

**AEEDC Dubai**

Dubai, UAE

31 January – 2 February 2012

[www.aeedc.com](http://www.aeedc.com)

**Annual Meeting of AO**

Phoenix, AR, USA

1–3 March 2012

[www.osseo.org](http://www.osseo.org)

**ITI Congress Germany**

Cologne, Germany

27–28 April 2012

[www.iti.org/events](http://www.iti.org/events)

**6<sup>th</sup> CAD/CAM & Computerized Dentistry  
International Conference**

Dubai, UAE

3–4 May 2012

[www.cappmea.com](http://www.cappmea.com)

**IADR General Session & Exhibition**

Rio de Janeiro, Brazil

20–23 June 2012

[www.iadr.org](http://www.iadr.org)

**FDI Annual World Dental Congress**

Hong Kong

29 August–1 September 2012

[www.fdiworldental.org](http://www.fdiworldental.org)

**AAID 61<sup>st</sup> Annual Meeting**

Washington, DC, USA

3–6 October 2012

[www.aid-implant.org](http://www.aid-implant.org)

**42<sup>nd</sup> International Congress of DGZI**

Hamburg, Germany

5–6 October 2012

[www.dgzi-jahreskongress.de](http://www.dgzi-jahreskongress.de)



**implants**  
international magazine of oral implantology



**Publisher**

Torsten R. Oemus  
[oemus@oemus-media.de](mailto:oemus@oemus-media.de)

**CEO**

Ingolf Döbbbecke  
[doebbecke@oemus-media.de](mailto:doebbecke@oemus-media.de)

**Members of the Board**

Jürgen Isbaner  
[isbaner@oemus-media.de](mailto:isbaner@oemus-media.de)

Lutz V. Hiller

[hiller@oemus-media.de](mailto:hiller@oemus-media.de)

**Chief Editorial Manager**

Dr Torsten Hartmann (V. i. S. d. P.)  
[hartmann@dentalnet.de](mailto:hartmann@dentalnet.de)

**Editorial Council**

Prof Dr Dr Frank Palm  
[frank.palm@klinikum-konstanz.de](mailto:frank.palm@klinikum-konstanz.de)

Dr Roland Hille

[dr-hille@t-online.de](mailto:dr-hille@t-online.de)

Prof Dr Dr Kurt Vinzenz

[kurt.vinzenz@aon.at](mailto:kurt.vinzenz@aon.at)

Dr Torsten Hartmann

[hartmann@dentalnet.de](mailto:hartmann@dentalnet.de)

Dr Suheil Boutros

[SMBoutros@aol.com](mailto:SMBoutros@aol.com)

**Editorial Office**

Georg Isbaner  
[g.isbaner@oemus-media.de](mailto:g.isbaner@oemus-media.de)

**Executive Producer**

Gernot Meyer  
[meyer@oemus-media.de](mailto:meyer@oemus-media.de)

**Designer**

Sarah Fuhrmann  
[s.fuhrmann@oemus-media.de](mailto:s.fuhrmann@oemus-media.de)

**Customer Service**

Marius Mezger  
[m.mezger@oemus-media.de](mailto:m.mezger@oemus-media.de)

**Published by**

Oemus Media AG  
Holbeinstraße 29  
04229 Leipzig, Germany  
Tel.: +49 341 48474-0  
Fax: +49 341 48474-290  
[kontakt@oemus-media.de](mailto:kontakt@oemus-media.de)

**Printed by**

Messedruck Leipzig GmbH  
An der Hebemärchte 6  
04316 Leipzig, Germany

**implants**

international magazine of oral implantology  
is published in cooperation with the German  
Association of Dental Implantology (DGZI).

**DGZI President**

Prof Dr Dr Frank Palm  
DGZI Central Office  
Feldstraße 80, 40479 Düsseldorf, Germany  
Tel.: +49 211 16970-77  
Fax: +49 211 16970-66  
[office@dgzi-info.de](mailto:office@dgzi-info.de)

[www.dgzi.de](http://www.dgzi.de)  
[www.oemus.com](http://www.oemus.com)


**Copyright Regulations**

\_implants international magazine of oral implantology is published by Oemus Media AG and will appear in 2011 with one issue every quarter. The magazine and all articles and illustrations therein are protected by copyright. Any utilization without the prior consent of editor and publisher is inadmissible and liable to prosecution. This applies in particular to duplicate copies, translations, microfilms, and storage and processing in electronic systems.

Reproductions, including extracts, may only be made with the permission of the publisher. Given no statement to the contrary, any submissions to the editorial department are understood to be in agreement with a full or partial publishing of said submission. The editorial department reserves the right to check all submitted articles for formal errors and factual authority, and to make amendments if necessary. No responsibility shall be taken for unsolicited books and manuscripts. Articles bearing symbols other than that of the editorial department, or which are distinguished by the name of the author, represent the opinion of the afore-mentioned, and do not have to comply with the views of Oemus Media AG. Responsibility for such articles shall be borne by the author. Responsibility for advertisements and other specially labeled items shall not be borne by the editorial department. Likewise, no responsibility shall be assumed for information published about associations, companies and commercial markets. All cases of consequential liability arising from inaccurate or faulty representation are excluded. General terms and conditions apply, legal venue is Leipzig, Germany.

# implants

international magazine of oral implantology



Subscribe now!

I would like to subscribe to **implants international magazine of oral implantology** (4 issues per year) for €44 including shipping and VAT for German customers, €46 including shipping and VAT for customers outside Germany, unless a written cancellation is sent within 14 days of the receipt of the trial subscription. The subscription will be renewed automatically every year until a written cancellation is sent to OEMUS MEDIA AG, Holbeinstr. 29, 04229 Leipzig, Germany, six weeks prior to the renewal date.

Reply via Fax +49 341 48474-290 to OEMUS MEDIA AG or per E-mail to [grasse@oemus-media.de](mailto:grasse@oemus-media.de)

You can also subscribe via [www.oemus.com/abo](http://www.oemus.com/abo)

Last Name, First Name

Company

Street

ZIP/City/County

E-mail

Signature

Notice of revocation: I am able to revoke the subscription within 14 days after my order by sending a written cancellation to OEMUS MEDIA AG, Holbeinstr. 29, 04229 Leipzig, Germany.

Signature





Official care provider  
to the German Olympic teams  
since 2002



GO FOR GOLD.



Bionic Engineering Design transfer of  
optimal living nature solutions  
to technical products

BEGO Semados®  
Mini-Implant

BEGO Semados®  
S-Implant

BEGO Semados®  
RI-Implant

## BIONIC ENGINEERING DESIGNED IMPLANTS

BEGO Semados® patented Implants embody:

- Indication-optimised contour design
- Function-optimised implant-abutment-connection
- High purity and ultra-homogenous-surface
- Machined rim for an inflammation-free gingiva-attachment
- 100 % German design – 100 % German manufacturing
- Value for money

**Are You  
Interested?**

[info@bego-implantology.com](mailto:info@bego-implantology.com)


[www.adwork.de](http://www.adwork.de)

**BEGO**   
Partners in Progress

[www.bego-implantology.com](http://www.bego-implantology.com)



Standard World  
Leader



This is  
the First

TSIII SA

**OSSTEM**<sup>®</sup>  
IMPLANT



Tel: +98 21 88 98 80 63 - 6

Web: Azadmed.com