

www.azadmed.com



Instagram: [azaadtejaratpars](https://www.instagram.com/azaadtejaratpars)

Telegram: [@azadmed2](https://www.t.me/azadmed2)

Phone: 88 98 80 63 - 6

implants

international magazine of oral implantology

3²⁰¹⁴



| **research**

20 years of membrane-protected bone regeneration

| **case report**

Double crowns made of a new high performance polymer

| **industry report**

Replacement of teeth through implantation and ridge expansion

Team-work **in** the dental office



Dr Rolf Vollmer

Team-work, team player, team spirit—these terms indicate crucial social skills in almost every sphere of life. We can only succeed if we work as part of a team. In dentistry, as in many other fields, regardless of skill and the protocols in place for many treatment situations, circumstances arise for which guidelines are lacking. Challenges like this can result in stress, anger and helplessness among the dental team.¹

One way of determining the optimum response to such situations in dentistry is to consider what others are doing to overcome these problems. We could consider an example from a non-medical area: the aviation industry. Sometimes flight crews, who are expected to operate as a team, do not co-operate as well as they should and miscommunication can then arise.¹ In order to address this, crew resource management training for flight crews was developed all around the world. Crew resource management is concerned with interpersonal skills, including behaviour training and conflict resolution.¹ It considers how we cope with everyday and unusual situations as a team, and the requirements of being a good team member.¹

Feeling motivated and cheerful places the crew in a better position for dealing with conflict resolution and situations for which there is no checklist or protocol.¹ Achieving the professional and relaxed atmosphere necessary for teamwork in such situations is the pilot's responsibility.¹ In order to do so, he or she should be able to make the rest of the crew feel valued and, therefore, good manners and courtesy are important.¹ Furthermore, according to Lufthansa pilot Rolf Stünkel and aviation journalist and pilot Jürgen Schelling, a good pilot requires discipline, curiosity and a sense of humour.¹ Discipline is needed to make reliable decisions in a fast-changing high-tech environment, and curiosity about one's colleagues and new procedures helps to facilitate the work process, as does a sense of humour, they state in their article.¹

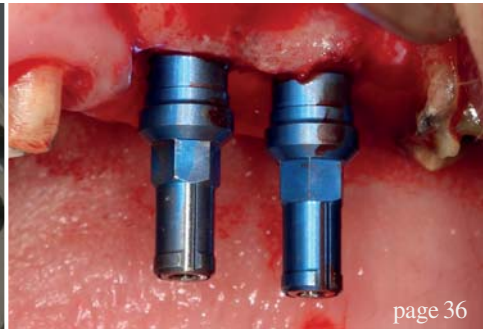
Crew resource management was developed for the aviation industry but it has wide application. Try applying it in your daily practice. Just replace the word "pilot" with "dentist" or "implantologist" and "crew" with "dental team".

I hope you will enjoy our magazine and our annual meeting in Düsseldorf!

Best regards
Dr Rolf Vollmer

¹ Stünkel, Rolf & Schelling, Jürgen, "Team spirit in the cockpit", *thinkx*, 1 (Spring 2014), 16–22.

<http://www.seminarselect.de/fileadmin/downloads/Thinkx_Magazin.pdf> accessed 21 July 2014.



| editorial

03 **Team-work in the dental office**
| Dr Rolf Vollmer

| research

06 **20 years of membrane-protected bone regeneration**
| Jiaoshou (Prof.) Dr Frank Liebaug *et al.*

16 **Ridge augmentation for an atrophied posterior mandible using NanoBone block—Part II**
| Dr Omar Soliman *et al.*

| case report

24 **Double crowns made of a new high performance polymer**
| Dr Rolf Vollmer *et al.*

| industry report

36 **Replacement of teeth through implantation and ridge expansion**
| Carlos Barrado *et al.*

| interview

42 **Honoured with the highest standards in implant dentistry**
| Interview by Dr Rolf Vollmer

| meetings

44 **Düsseldorf—Beauty on the Rhine**
| Katrin Maiterth

46 **5th International CAMLOG Congress in Valencia**

| news

40 **Manufacturer News**

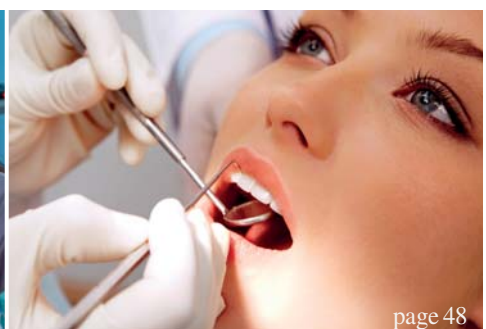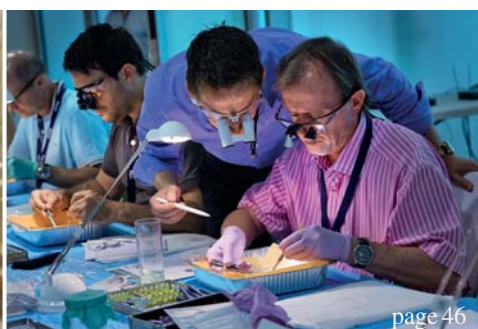48 **News**

| about the publisher

50 | imprint



Cover image courtesy of Bicon, www.bicon.com
Original Background: © Tarchyshnik Andrei
Artwork by Sarah Fuhrmann, OEMUS MEDIA AG.



**ASTRA TECH
IMPLANT SYSTEM**



Join the **EV**olution

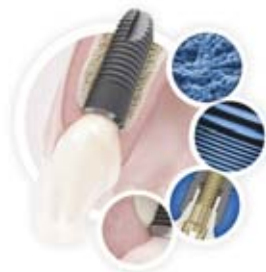

The new
ASTRA TECH Implant System™ EV
– now available

Learn more



www.jointheev.com



The foundation of this evolutionary step remains the unique **ASTRA TECH Implant System BioManagement Complex**, well-documented for its long-term marginal bone maintenance and esthetic results. www.dentsplyimplants.com

DENTSPLY
IMPLANTS

20 years of membrane-protected bone regeneration

A report

Authors Jiaoshou (Prof.) Dr Frank Liebaug & Dr Ning Wu, Germany

Dental implantology has developed to a reliable and successful clinical routine procedure for all those cases where an adequate bone material is available. But this precondition is not always met. Nevertheless, today also patients with a bone situation which is not optimal for implant insertion do wish an improvement of function and aesthetics—they actually consider this to be granted.

Introduction


The use of barrier membranes for the regeneration of bone defects has changed dental implantology in the course of the last 20 years a lot. The principle titled as "membrane-protected bone regeneration" was first described by Hurley et al. in 1959. Already in the 1960s, a research group around Bassett and Boyne tested and described micro porous cellulose

acetate laboratory filters (Millipore) for the treatment of cortical defects on long bones and the osseous reconstruction of the jaw. The basic idea of the authors was to use filter material for the isolation of bone defects against the cells of the adjacent, fibrous soft tissue and to create an appropriate milieu for osteogenesis. However, these pioneering studies did not immediately lead to a broad clinical application of barrier membranes on patients. Actually, the clinical possibilities of the membrane technology were not recognised until the early 1980s where the research group around Karring and Nyman systematically investigated the use of barrier membranes in different experimental and clinical studies on periodontal regeneration.

Already at the end of my studies about stomatology, especially the possibilities for periodontal regen-

Fig. 1 Example for different non-resorbable, titanium-mesh-reinforced ePTFE membranes, which are available in different forms and sizes depending on the manufacturer.

Fig. 2 Close up clearly shows the titanium-mesh reinforcement in the non-resorbable membrane material.



YES!



I WANT IMPLANTS

MADE BY DENTAURUM.

20 years of expertise, reliability and innovation
in implantology – worldwide. Say yes!



Membrane types	Amount of patients questioned	First surgery	Second surgery for membrane removal	Overall assessment three month after membrane augmentation
Non-resorbable, titanium-mesh-reinforced ePTFE membrane	32	7	5	7
Resorbable ePTFE membrane	52	8	0	8
Collagen membrane	196	9	0	10

Tab. 1 Subjective patient satisfaction during and after augmentative procedures in our practice from 1994 to 1999, five years, total number of cases $n = 280$, average satisfaction based on a subjective satisfaction scale 0 = very unsatisfied ... 10 = very satisfied.

eration were of great interest to me. At this time, great hopes were placed on the so-called GTR (Guided Tissue Regeneration) technique for treating extensive periodontal bone defects. A few years later, the membrane technique was tested as part of experimental studies on bone regeneration for larger alveolar ridge defects. Based on the studies' promising findings, the clinical use of membranes on implant patients started in the late 1980s (Nyman et al. 1990).

Despite this, it was not before the beginning of the 1990s until the discussion of this application found its way to congresses. From this time, works by Wachtel and Bernimoulin are to be named (Wachtel 1990, Wachtel and Bernimoulin 1991). In 1994, I purchased the first book dealing with this issue by Buser, Dahlin and Schenk for my private, scientific library. Under the title "Guided Bone Regeneration in Implant Industry", the authors published after five years of intensive experimental and clinical preparation the first English-speaking issue of this book in 1994, which could rouse a large interest for this topic on my side as well as among implantological experts. Since then, the GBR technique has constantly developed.

carded or kept them (Tab. 2). Thereby, an important criterion for the selection of the operation method and the used type of membrane was also the patient's subjective feeling (Tab. 1).

Aims of membrane application

- Undisturbed regeneration of bone through a barrier function against the adjacent soft tissue.
- Avoidance of graft resorption particularly in autologous bone transplants.
- Protection against loss or dislocation of bone or bone graft substitute particles.
- Protection of the regenerate in case of wound dehiscence.

Depending on the used membrane type, the desired bone regeneration is given the required time and rest in a defined area. Especially the reservation of space volume defined by a surgeon can be perfectly ensured by the use of titanium-reinforced membranes (Figs. 1 & 2). Before the insertion into the operation area, these membranes can be tailored and also bended, as shown in Fig. 3 only exemplarily.

Tab. 2 Assessment of the handling for the operator and subjective evaluation of the plastic coverage and healing process, total amount of cases $n = 280$.

Always about to find better and for the patient more gentle treatment methods, in the last 20 years I applied different membrane types in the clinical daily routine (Tab. 3), compared their suitability and application parameters and based on the outcomes, dis-

From 1994 to 1996, I thus used non-resorbable, titanium-mesh-reinforced membranes from the company W. L. Gore and Associates, Inc. USA, at first. Although, I as an operator was very satisfied with the clinical outcomes of the bone regeneration in

Membrane type	First surgery		Second surgery		Wound dehiscence	
	simple	difficult	simple	difficult	after 8 days	after 30 days
Non-resorbable, titanium-mesh-reinforced ePTFE membrane	6,25 % (2)	93,8 % (30)	28,2 % (9)	71,9 % (23)	9,4 % (3)	21,9 % (7)
Resorbable ePTFE membrane	11,5 % (6)	88,5 % (46)	0	0	3,8 % (2)	11,5 % (6)
Collagen membrane	59,5 % (117)	40,5 % (79)	0	0	1,5 % (3)	5,1 % (10)

Implant planning made easy

Planmeca PlanScan®

Planmeca ProMax® 3D

3X
3D

Planmeca Romexis® software offers a completely integrated and digital workflow for modern implantology. From intraoral scanning to easy prosthetic design and realistic implant libraries, the most sophisticated implant planning tools are just a few mouse clicks away.

- All the scanned and design data for prosthetic works is immediately available and can be mapped with the patient's CBCT data
- Use crown library or patient-specific crown from CAD system
- Verify the implant plan with verification tool
- Order surgical guide directly from the software
- Share data easily with partners through **Planmeca Romexis® Cloud** image transfer service

Find more info and your local dealer

www.planmeca.com

PLANMECA



Planmeca Oy Asentajankatu 6, 00880 Helsinki, Finland. Tel. +358 20 7795 500, fax +358 20 7795 555, sales@planmeca.com

Manufacturers/ Distributors	BEGO Implant Systems	BEGO Implant Systems	Geistlich Biomaterials
Product name	BEGO Collagen Membrane	BEGO Collagen Fleece	Geistlich Bio-Gide
Origin	porcine pericardium-collagen	porcine collagen	porcine (pig)
Resorption a) Service life b) Behaviour on exposure c) Behaviour on exacerbation	a) > 3 months b) stable c) can be left with appropriate oral hygiene	a) 2–4 weeks b) – c) –	a) on request by Geistlich b) normally without complications, healing by free granulation, removal of membrane unnecessary c) in case of exposure of membrane an antimicrobial treatment is recommended
Recommended treatment before use	–	–	membrane-cutting to defect size
Processing before use	cut to size, can be applied wet and dry	cut to size, apply dry, fast hydrogenation	no further processing needed
Recommended fixation	unnecessary, pin or suture if needed	ns.	sticks well to defect, additional fixation with titanium-pin or double-layer-technique (Buser) in case of bigger defects
Available sizes	15 x 20 mm 20 x 30 mm 30 x 40 mm	20 x 20 mm	25 x 25 mm (6,25 m ²) 30 x 40 mm (12,0 m ²)
Price per membrane	15 x 20 mm: 90 Euro 20 x 30 mm: 110 Euro 30 x 40 mm: 165 Euro	12 pieces = 200 Euro	from 122 Euro
Scientific references	on request	on request	on request (more than 80 publications)
Distribution in GER since	2009	2009	1996
Ranges of application	implantology, periodontology, sinus floor elevation, defect surgery, biological protective barrier also at risk of infection	reconstruction, protection of Schneider'sche extraction site, bleeding complication, biopsy points, bone defects	implantology, periodontology, defect surgery, sinus floor elevation, extraction sockets, GBR/GTR, resorption protection
Homepage	www.bego-implantology.com	www.bego-implantology.com	www.geistlich.de

Tab. 3

94 per cent of the cases, for most patients the necessary second surgery was subjectively more burdensome than the first one. As a questionnaire of my patients had shown, they were relatively satisfied with the therapeutic measure—meaning the first surgery and the overall treatment. But there was also a remarkable number of patients who considered the second surgery for the removal of the non-resorbable membrane materials as disturbing and even more burdensome than the first one (Tab. 1). This has im-

proved with the introduction and application of resorbable ePTFE membranes, which were and still are available in different configurations on the dental market—depending on the field of application. As long as there was no surgery for membrane removal, the patients were relatively satisfied with the therapy from the beginning to the end (Tab. 1). The handling of a titanium mesh reinforced ePTFE membrane with its complete plastic coverage puts enhanced requirements on the oral surgeon depending on the area of

Geistlich Biomaterials	RIEMSER Arzneimittel AG	RIEMSER Arzneimittel AG
Geistlich Bio-Gide Perio	Epi-Guide	Cytoplast TXT-200; Cytoplast TI-250 (titanium-reinforced)
porcine (pig)	synthetic (polylactid)	synthetic (PTFE)
a) on request by Geistlich b) normally without complications, healing by free granulation, removal of membrane unnecessary c) in case of exposure of membrane an antimicrobial treatment is recommended	resorbable a) barrier function: 2–4 months, complete resorption within 12 months b) depending on material only low bacterial colonisation in case of an exposition (special pore structure counteracts exposition), exposed areas usually resorb without complications within short time c) in the unlikely case of a renewed infection, the membrane should be removed and the infection eliminated	a) non-resorbable b) without complications. Membrane was designed for exposed surfaces c) in the unlikely case of a renewed infection, the infection should be eliminated first
membrane-cutting to defect size (possible with supplied sterile pattern)	remove focus of inflammation in the defect area, clean bone, maybe fill up with bone regeneration material	remove focus of inflammation in the defect area, clean bone, maybe fill up with bone regeneration material
no further processing needed	cutting with surgical scissor, briefly soak with blood from the defect	cut to size, round off edges
sticks well to defect, additional fixation with titanium-pin or double-layer-technique (Buser) in case of bigger defects	membrane can be fixed by blood contact, further fixation with resorbable suture or tacks if needed	overall suture with non-resorbable suture material, e.g. Cytoplast PTFE-Suture (do not perforate)
16 x 22 mm (3,52 m ²)	18 x 30 mm	different cuttings and forms between 1,2 x 2,4 and 3,0 x 4,0 cm optionally titanium-reinforced
113 Euro	109 Euro	from 49,90 Euro (1,2 x 2,4 cm)
on request (more than 80 publications)	Arthur R. Vernino et al., Int. Journal of Periodontics and Restorative Dentistry 1999; 9(19):57–65	on request
1998	2001	2007
implantology, periodontology, GBR/GTR	periodontology, implantology, GBR/GTR	recovery surgery, defect surgery, GBR/GTR, no primary wound closure necessary
www.geistlich.de	www.RIEMSER-dental.de	www.RIEMSER-dental.de

lesion. The plastic and de-energised coverage often proves to be difficult (Tab. 2). However, the clear room stabilisation and the volume preservation (Fig. 3) are particularly to be highlighted as the core advantages.

For the sake of completeness, I want to mention my use of a direct applicable GTR barrier for the coverage of periodontal bone defects—which is especially indicated for an infestation of bifurcation—on the protection of augmentation material. In the then

dental market, this barrier was available under the name Atrisorb® of the company Atrix Laboratories, Inc., Fort Collins, USA. Although the clinical healing process was unremarkable, a dimensional stability of this viscously applied barrier materials after hardening was not traceable. At least, there was no dislocation of particles from the materials placed into the defect. Due to the few patients treated in this way, these were not included into the evaluation of the questionnaire.

Fig. 3 By bending the inner titanium frame, the desired room volume above the bone defect can be fixed and kept stable, similar to today's commercial tent poles.




Fig. 3

Fig. 4 Patient with a clear buccal retraction of the processus alveolaris, about 18 years after loss of teeth and following bone resorption in regio 24, 25 as well as narrowing of gaps by a mesial migration of 26.

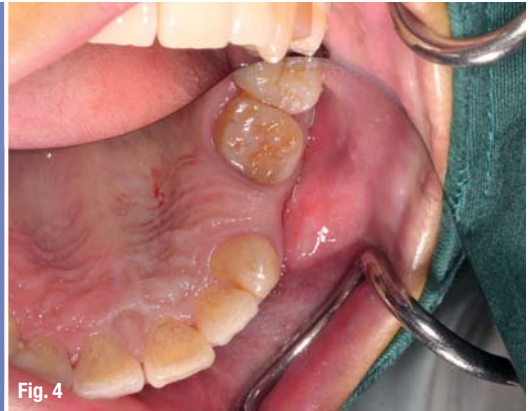

Fig. 4

Fig. 5 After implant insertion 24 and simultaneous augmentation of the buccal defect area by a mixture of autologous bone chips and Bio-Oss granulate with a particle size 0,25 to 1,0 mm, Fa. Geistlich Pharma AG, Wolhusen, Switzerland, a clear widening of the processus alveolaris is prepared and the desired bone regeneration is supported evidence-based.

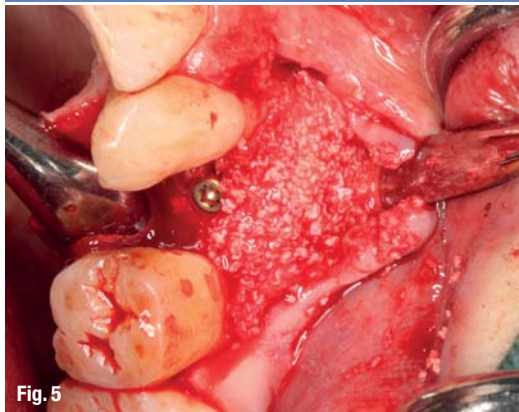


Fig. 5

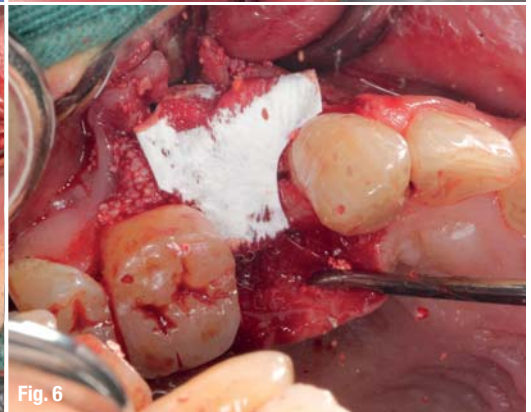

Fig. 6

Fig. 6 After tailoring and examination, the Bio-Gide membrane is placed on the augmentation material.

Already since 1996, I increasingly switched to the clinical application of collagen membranes. Besides the effective barrier function, the good wound healing properties were and still are the reason why I am using these materials almost exclusively for my patients' treatment now. Both the handling as well as the patient compliance is in most cases superior to the old methods using titanium mesh reinforced ePTFE membranes (Tab. 1 & 2).

isolation of the wound coagulum and promotes the proliferation, migration and adhesion of cells. Furthermore, when reducing the membrane materials there is no need to fear irritations of the tissues or the desired regeneration processes, which in contrast can occur for synthetic materials. In Table 3, the membrane materials used in my practice from 2001 until 2014 are listed with their different properties.

As Plöger described in 2003 already, natural collagen membranes do influence tissue integration in a positive way. Amongst our treatments, only 1.5 per cent of the cases of membrane application showed low dehiscence after eight days and about 5 per cent after 30 days. This was a revolutionary improvement compared to the titanium mesh reinforced, non-resorbable as well as resorbable ePTFE membranes. Under a local antiphlogistic treatment, the lowly exposed collagen membranes do heal without complications, whereas the other membrane types need be removed promptly in case of a wound dehiscence. In principle, all membrane expositions or wound dehiscence are clinically controllable. But they also require the frequent scheduling of patients and at least weekly follow-ups and wound cleaning, which is reflected by a lower patients rating (Tab. 1). For this, the reason can be seen in the fact that collagen chemotactically works on fibroblasts and thus enhances the primary wound closure. Today it seems to be undisputable that it supports the development and stabil-

In the direct clinical comparison, the handling of the native collagen membrane—in our case Bio-Gide® by Geistlich Pharma AG, Wolhusen, Switzerland—was remarkably easier. After unpacking out of the delivered sterile box, this material can be tailored without problems and thus adapted to the defect and configuration size (Figs. 4–6). Soaking or moistening with any liquids before application is not needed; shortly after the application, the membrane material becomes saturated with the surrounding blood and the below defect area (Figs. 7 & 8). Regardless of autologous bones or bone graft substitutes of different origins, the adhesion to bone walls and the adaption to the augmentation material is much better than for synthetic membranes—if it is possible at all. Thus, I used resorbable pins for membrane consolidation only in the beginning of my augmentative work. Today, I am adapting the barrier material below the adjacent periost (Fig. 7). However, collagen membranes do always need dimension stable bone graft substitutes or autologous bones to prevent the room volume from collapsing.

A black and white photograph of a woman with long, wavy hair, wearing a dark, short-sleeved dress and high-heeled shoes. She is sitting in a modern, white, egg-shaped chair. There are two other similar chairs visible in the background, one to the left and one to the right. The setting is a bright, minimalist room with a white floor and walls.

I AM A FAN

like most of my colleagues.

Dr. Leyli Behfar | Specialist in Oral Surgery

CAMLOG is my first choice when it comes to dental implants. With their high-precision implant systems, I find an answer for every indication. Implantations can be performed easily, efficiently and with excellent quality standards. CAMLOG is an inspiring partner in many ways – and that is getting around. www.camlog.com

a perfect fit™

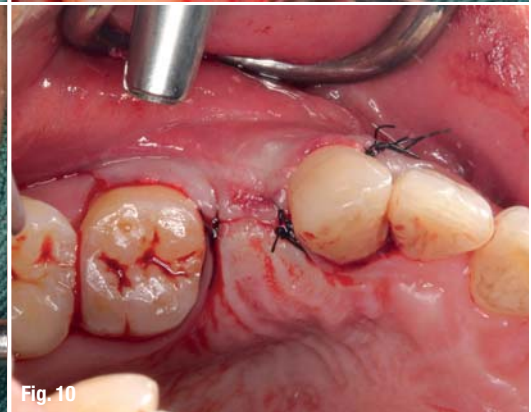
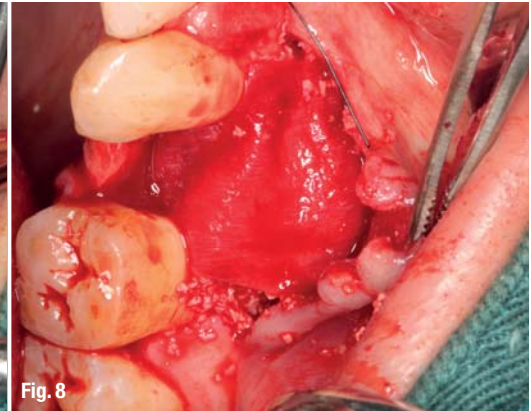
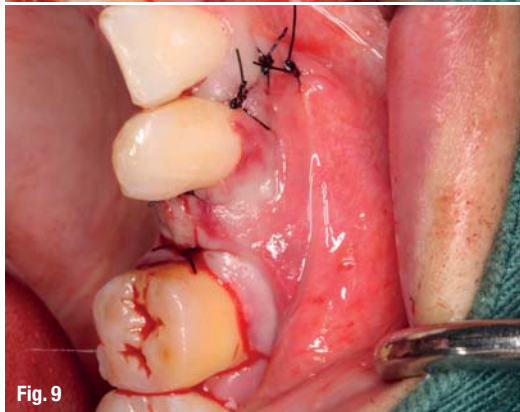
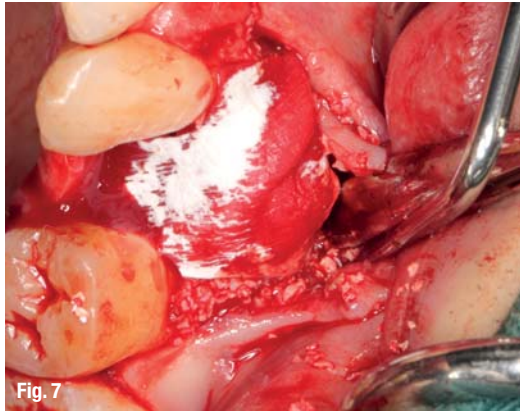
camlog

Fig. 7_The Bio-Guide-membrane can be adapted well under the surrounding periost without absorbable pins and saturates itself with the patient's blood from the edges.

Fig. 8_The membrane is completely soaked with the patient's blood and can be plastically covered by mucoperiosteal flaps.

Fig. 9_Complete, primary wound closure from buccal.

Fig. 10_Also the occlusal view and examination confirms the de-energised closure of the mukosa which is not unimportant for the healing process; due to flap advancement, the vestibulum could be saved well.



If the operator can achieve a primary and de-energised wound closure, fissure dehiscence is a rare exception and possibly due to subjective patient factors. Usually, I use 5/0 or 6/0 fissure material in augmentation surgery, whereby the Bio-Guide membrane, which I am using oftentimes, is available in the dimensions 13x40 mm, 25x25 mm or even 30x40 mm. Thus, the operator has an option for almost every indication and can choose the most economic, i.e. most priceless option, which is also in the patient's interest.

I must not forget to point out the remarkably good material properties of this membrane regarding tensile strength and foldability, which is not granted for every competitor. Thus, I often perform external sinus lift operations with very small lateral bone space, whereby I fold the membrane—in the same way as a model ship is inserted into a bottle—and then unfold it before it becomes saturated with liquid. In this way, the Schneider'sche membrane in the paranasal sinus is stabilised for a long time and a perforation of undesired dislocation of augmentation material is prevented successfully (Liebaug & Wu, 2011).

Conclusion

Without the application of augmentative treatment methods—particularly the membrane protected bone regeneration—I would have helped only

few patients to get a fixed or high-quality implant-supported dental prosthesis in the past 20 years. In my therapy concept, a successful dental implantology begins already or at best with the socket preservation and ridge preservation simultaneously to the tooth removal. But these measures do make sense when afterwards a conventional prosthetic rehabilitation with fixed bridges or combined fixed and removable telescopic or bed-load prosthesis will be planned. The application of barrier membranes—particularly collagen membranes—has developed to a very reliable and successful clinical routine procedure for all those cases where an adequate bone material in height and width shall be generated for later therapy measures.

contact

implants

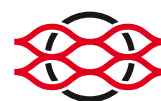
Jiaoshou (Prof.) Dr Frank Liebaug

Scientific Director of Ellen-Institute,
German Institute for Dental Research
and Education
Professor University Shandong, China
Arzbergstr. 30, 98587 Steinbach-Hallenberg
Germany

Tel.: +49 36847 31788
www.zahnarzt-liebaug.de
www.ellen-institute.com



creos™
xenoprotect



Experience the difference.

The creos xenoprotect membrane offers outstanding handling properties and an extended barrier function.



Save valuable time and reduce the risk of membrane failure thanks to the outstanding handling properties and high tear resistance of this biodegradable collagen membrane.

Approach your sales representative for a hands-on demonstration of the membrane. To feel it is to believe it. We're confident you'll notice the difference straight away.

- Extended barrier function
- Outstanding handling
- Fast and predictable tissue healing
- Easy fixation and suturing

 Demonstration video

creos.com/xenoprotect-demo



Find out more on: creos.com/xenoprotect

Ridge augmentation for an atrophied posterior mandible using NanoBone block

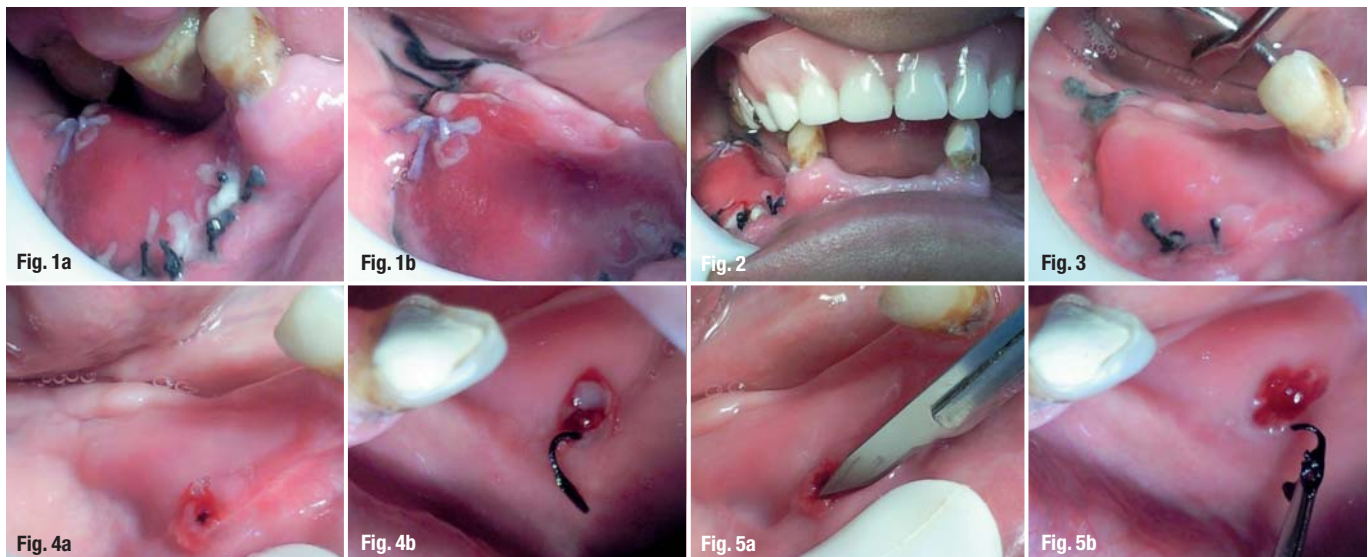
Part II: Treatment outcome of clinical complications

Authors_Dr Omar Soliman & Prof. Dr Dr Mohamed Nassar, Egypt

_In the previous issues of **implants international magazine of oral implantology** (implants 1/2014) the authors gave a detailed introduction to their topic. In this issue, their report is completed.

At the time of implant placement, usually four months after the grafting procedure, the remodelling process is still underway. Even seven months after grafting, significant amounts of non-vital bone can be found.⁸ Certain factors may influence the efficacy of the regeneration process. Revascularisation of the graft is crucial to tissue nutrition and regeneration. Revascularisation of a cancellous bone graft is ten-fold faster than that of a cortical bone graft.⁹ The regenerative potential of the residual ridge is also an important factor. Highly atrophied ridges usually consist of cortical bone that is not well vascularised and does not provide many cells.¹⁰ These factors can

influence the time needed for remodelling of the graft. Clinically, poor bone regeneration can be visually established from poor bleeding because of an inadequate blood supply, or from an inhomogeneous structure. Sometimes, even a clear border between the grafted bone and residual ridge can be observed.⁵ In most cases, the screw has to be removed before implants can be placed after bone grafting. If the graft is not properly integrated, implant placement can loosen the graft. Mechanical stability of the graft is an important factor for proper bone regeneration and integration. It is well known that osteoblasts differentiate into fibroblasts under mechanical overload.¹⁰ If mobility of the graft is observed, soft tissue has to be removed, bleeding should be provoked and mobile fragments have to be secured with the screws to allow the tissue to heal for another three or four months.⁵ Another reason for insufficient integration





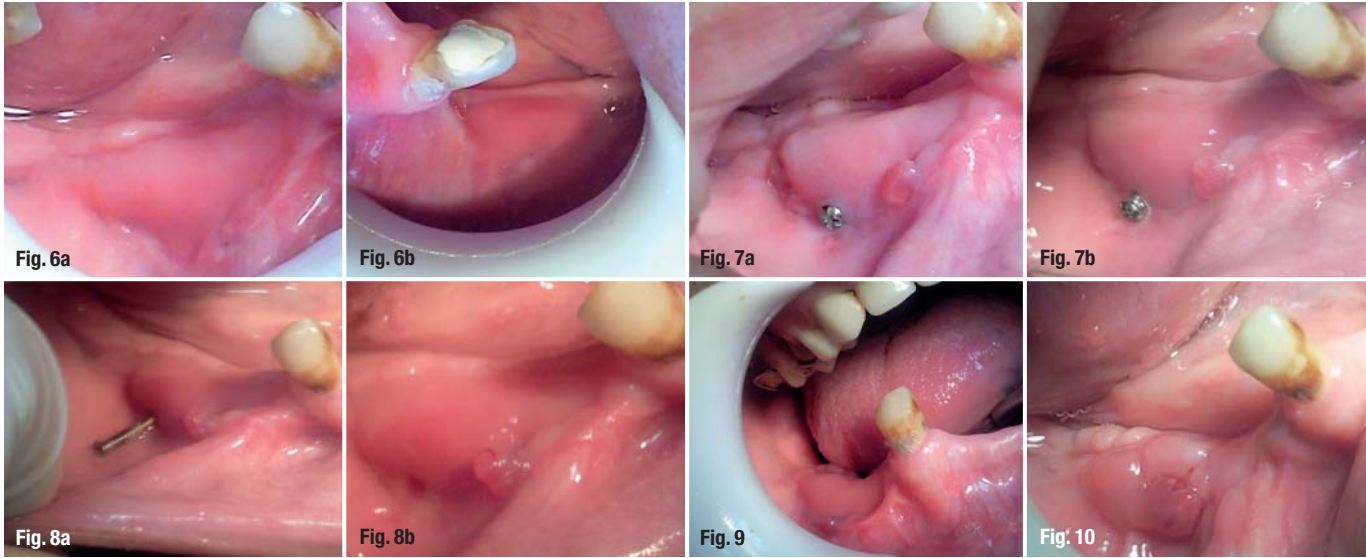
More than an implant. A sense of trust.

The Straumann® Dental Implant System is a worldwide leading solution for general practitioners and specialists. Our commitment to research ensures high quality backed by independent science. Producing innovations that improve patient care has made us a trusted business partner in over 70 countries.

www.straumann.com

60 YEARS


simply doing more



of bone grafts is the migration of soft tissue, such as connective tissue, between the grafts, or between the graft and the residual ridge.⁴ There should be proper adaptation of the graft to the defect. All the gaps between the block graft and the residual ridge must be filled with bone chips to prevent ingrowth of the connective tissue. If all of the gaps are sealed with particulate bone, no membrane is needed to prevent the ingrowth of soft tissue, but titanium mesh can be useful in some cases to stabilise the grafted material and to hold it in place. If fibrous or granulation tissue is present in the grafted area, it should be removed before grafting.⁵ Resorption may be identified by the appearance of the fixation screw through the tissue as the soft tissue follows the underlying bone. Regeneration is commonly observed in block grafts.¹²⁻¹⁴ Dehiscence leads to a higher percentage of resorption. Combining a membrane with a block graft has been reported to achieve less bone resorption.¹⁵ However, a high complication rate, such as dehiscence

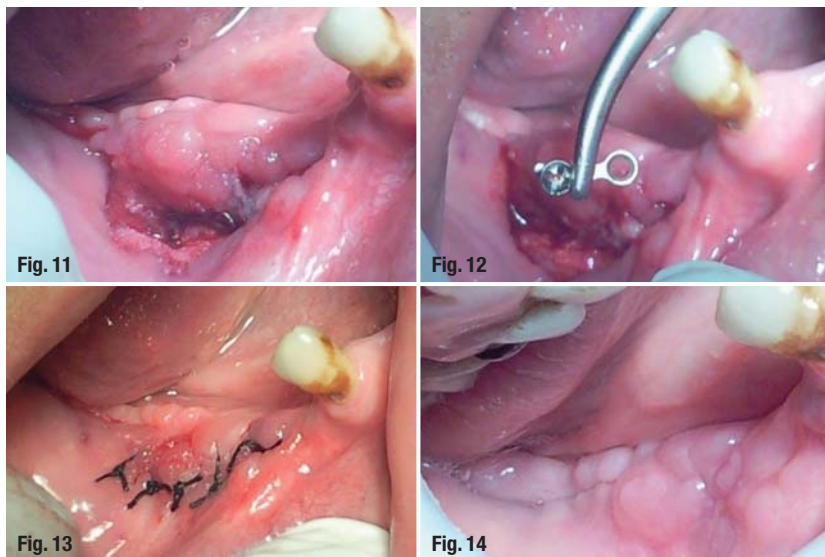
of up to 14%¹⁶ or 18%¹⁷ with resulting infection or resorption, has been reported in connection with non-resorbable membranes, making this approach less attractive. Titanium mesh may be useful for avoiding resorption and appears to cause less dehiscence than do other non-resorbable materials.¹⁸

Bone remodelling and resorption after grafting

Parallel to the healing of transplanted bone, including revascularisation and remodelling, the volume of the grafted area is reduced in the first few months after the surgical procedure. Bone resorption of different forms and intensity is a typical phenomenon after the transplantation of a free bone graft.¹⁹ There are different reasons for this bone resorption, depending on the graft technique, localisation, the type of surgery, soft-tissue pressure and muscle function. The bone quality of the graft and of the recipient site, the amount of revascularisation and revitalisation, and some genetic parameters influence the intensity of this bone resorption.

Resorption of the grafted bone has been found to be influenced by the following parameters:⁶

- 1) Bone blocks inside the contours of the alveolar crest for reconstruction of a failed bone wall showed significantly greater and faster resorption than those grafted inside the contours. This resorption of the grafted bone outside the contours can be influenced by implant insertion into the grafted area, thereby moderating resorption.
- 2) Functional loading of the grafted bone with an implant reduces the amount of bone resorption. When implants had not been inserted in the grafted area, the majority of the bone




The IMPLAnt

Clinical experience since 1963

Premium quality at a fair price

Part of the digital workflow



For more information, please visit
www.schuetz-dental.com

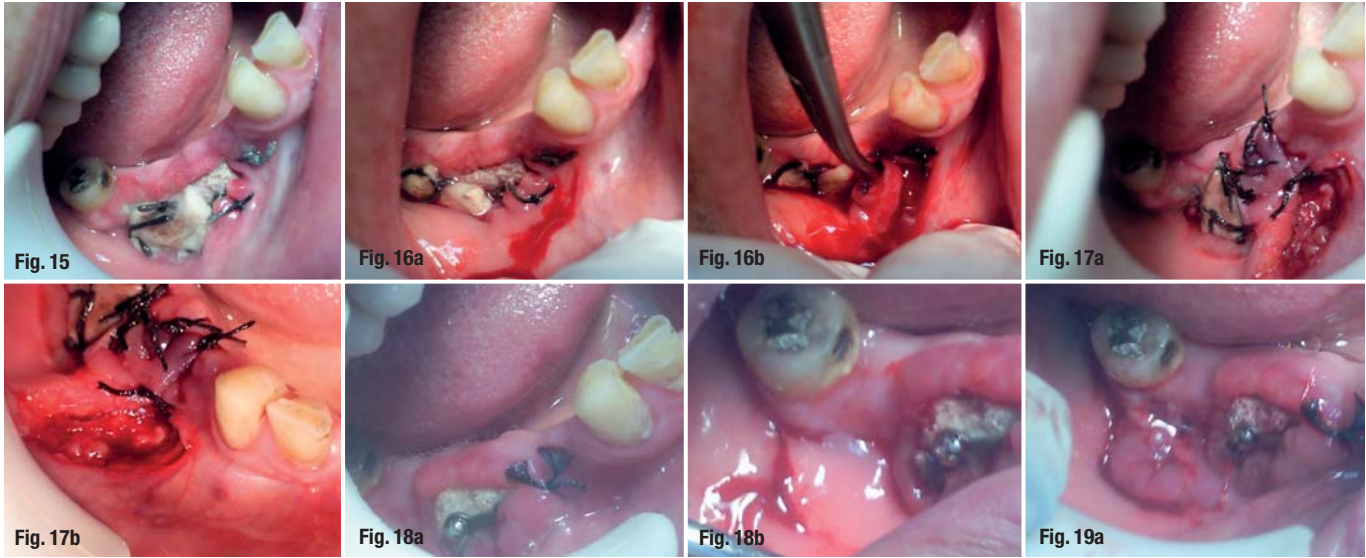


Schütz Dental GmbH • Dieselstr. 5-6 • 61191 Rosbach/Germany
Tel.: +49 (0) 6003 814-365 • Fax: +49 (0) 6003 814-907
www.schuetz-dental.com • export@schuetz-dental.de



Since 1963

IMPLA



- gained resorbed after eight months, especially in the grafted bone outside the contours.
- 3) Overextension of the bone graft is not a prophylactic measure against resorption: the greater the overextension of the grafted area, the greater the resorption.
 - 4) The location of the grafted area appears to have an influence on the intensity of resorption. Maximum resorption of the grafted bone four months after surgery was found in the anterior region of the mandible, followed by the posterior region. This phenomenon can be explained by muscle activity.
 - 5) The type of flap and use of the tunnel technique for grafting procedures appear to reduce the amount of bone resorption. This can be explained by the influence of periosteal integrity on osteoclast activity.

Nerve injury

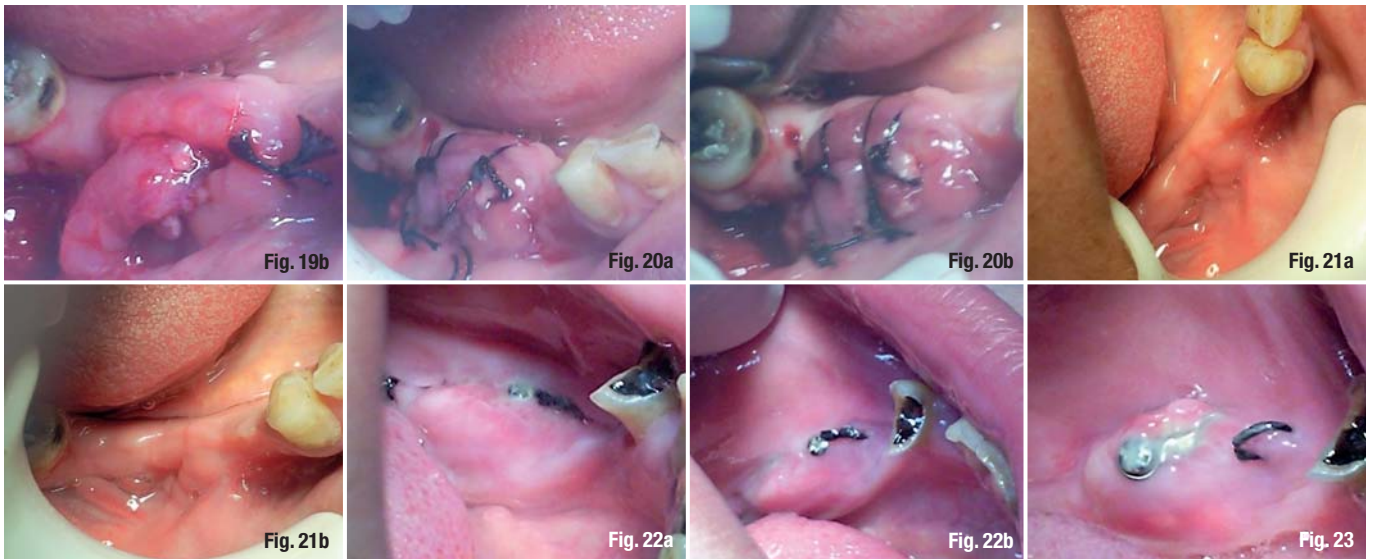
Trauma to the inferior alveolar nerve during implant placement may lead to loss of or altered sensation (paraesthesia) or to painful symptoms (dysaesthesia). Numerous unpleasant sensations may be described by the patient, including numbness, a crawling feeling, constant or periodic sharp pain, itching, tingling, hypersensitivity and burning, throbbing, pins and needles, prickling, and warmth or cold. In implant dentistry, these sensations often affect the lower lip, chin and the lower anterior gingiva. Rarely, the tongue may also have an altered sensation. Patients with tongue symptoms suffer a loss of taste. According to Girard et al., the inferior alveolar nerve may have the potential for recovery up to two years after injury.²⁰ However, Sunderland estimates that 75–90% of distal nerve atrophies are irreparable after one year of altered feeling.²¹

Classification of nerve injuries

- 1) **Neurapraxia:** neurapraxia is a mild injury caused by compression injury to the nerve or retraction of the nerve. Examples of compression injuries include
 - pressure from saline or blood from the implant site while the implant is being screwed into position;
 - post-operative bleeding within the bone or around the mental foramen;
 - an implant inserted into the mandibular canal;
 - a piece of bone that invaded the canal during site preparation or implant insertion; and
 - a tie-back suture on the facial or lingual flap.

In neurapraxia, there is no axonal degeneration distal to the point of the nerve injury, but there is a temporary conduction block during nerve recovery. Spontaneous recovery of the altered sensations most often occurs weeks after this type of injury. When the patient presents with symptoms of a nerve injury within two days of surgery, an oral dose of a corticosteroid (e.g. Decadron 8 mg) decreases inflammation and swelling in the region. If the nerve trunk is compressed or retracted during surgery beyond the usual protocol, the intravenous form of a corticosteroid (e.g. 1–2 mm of Decadron 4 mg/ml) may be applied (not injected) to the injured area for 1–2 minutes. This direct application will decrease the risk of Nissl body disintegration, which causes the paresthesia.²²

- 2) **Axonotmesis:** axonotmesis is a nerve injury with loss of axonal continuity but with the general structure of the nerve remaining intact (the endoneurium is preserved). These injuries are more significant and may result in dysaesthesia or less-than-normal nerve recovery. Examples of axonotmesis injuries include



- a nerve stretch injury from reflection of a soft-tissue flap;
- an implant drill proceeding through the top of the neurovascular canal; and
- an implant violating the canal.

If a post-operative radiograph shows that an implant may have slightly violated the canal space, it is prudent to unscrew the implant, introduce Decadron 4 mg/ml into the osteotomy site and place a shorter implant after 2–3 minutes. In addition, a corticosteroid is given orally for three to five days (the usual dose is 8–12 mg in the morning of the first day, 4–6 mg in the morning of the second day and 2–4 mg in the morning of the third day).²³

3) Neurotmesis: neurotmesis is the complete severance of the nerve trunk. When this occurs, all axons distal to the injury undergo Wallerian degeneration. Anaesthesia of the soft tissue innervated by the affected nerve is a consequence of this condition. When a discontinuity or gap is present between the nerve ends, scar tissue forms between the structures and axonal sprouts from the proximal aspect of the nerve are prevented from penetrating the endoneurial tubules. Neurotmesis is suspected when anaesthesia is present or has been present for more than three months.

Complications during and after second-stage implant surgery

Exposure of the graft

Even several months after grafting, significant amounts of non-vital bone can be found.²⁴ Vascularisation of the transplanted bone is poorer than in the residual crest, and neither a humoral immune response nor secondary wound healing is

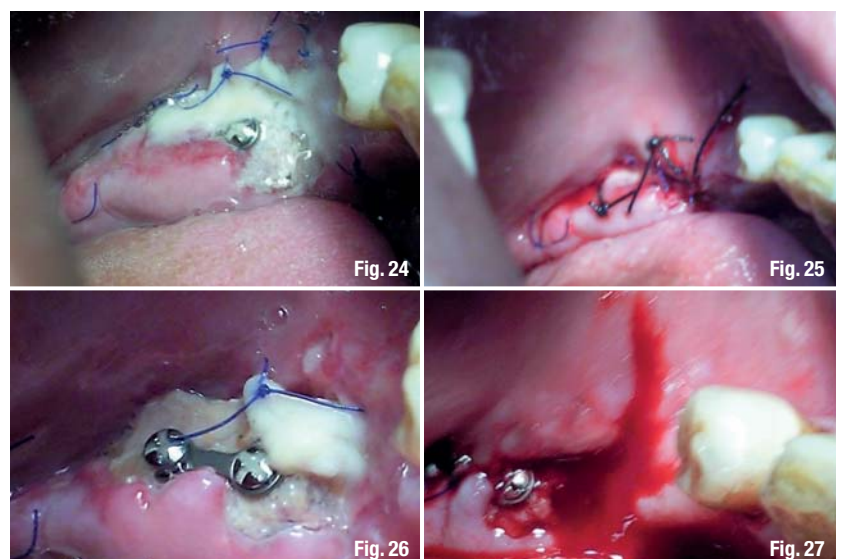
guaranteed. This leads to the necessity of careful soft-tissue management in second-stage surgery. Several techniques are reported to achieve adequate peri-implant soft tissue.²⁵ If parts of the transplanted bone are exposed, soft-tissue closure has to be surgically performed after debridement.⁵

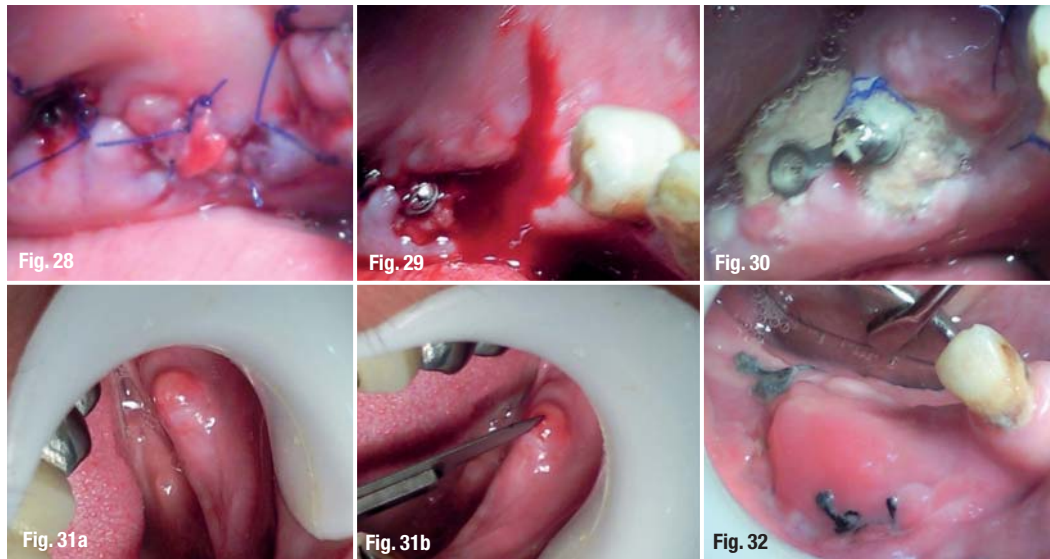
Mobility of the implant

If an implant fails in the augmented site, granulation tissue has to be removed carefully. Radiographic evaluation and implant placement can be performed six to eight weeks later.⁵

Flap necrosis

Traumatic surgery, infection or insufficient vascularisation may lead to flap necrosis. Secondary healing can take place if the underlying bone is vital and well vascularised. If the underlying bone is still premature, complications can arise.⁵





Late complications after prosthetic restoration

Bone loss

In an experiment on dogs, Berglund and Lindhe demonstrated that the thickness of peri-implant soft tissue influences the amount of bone resorption that takes place after second-stage surgery to establish biologic width.²⁶ In this process, a biological interface between the bone, soft tissue and implant is established, which is composed of the barrier epithelium (2 mm) and the connective tissue attachment (1–1.5 mm). These phenomena result in bone loss of up to 2 mm on a radiograph. A higher rate of bone loss may be of concern because it can be the result of mechanical overload or chronic inflammation of the peri-implant soft tissue.⁵

Loss of attached gingiva

A loss of fixed gingiva is frequently observed around implant restorations. Bengazi et al. and Grunder reported an average loss of 0.5 mm of fixed gingiva in the initial years after prosthetic restoration.^{27,28} In the mandible, vestibuloplasty and connective tissue grafts are suitable techniques to shape aesthetic and functional peri-implant soft tissue.⁵

Treatment outcome of clinical complications

A traumatic ulcer affecting the overlying mucosa of a maxillary molar (Figs. 1a&b) was treated with a maxillary partial denture to maintain centric occlusion (Fig. 2), protecting the overlying mucosa and NanoBone block graft. After the treatment, a complete healing of the traumatic ulcer was observed (Fig. 3). During this treatment, the use of a chlorhexidine solution several times a day was useful in re-

ducing bacterial infiltration. An infection of the NanoBone graft (Fig. 4a) and Fisiograft (Fig. 4b) from the suture was treated by removing the suture (Figs. 5a & b), prescribing an antibiotic and a mouthwash, which in total lead to a complete healing (Figs. 6a & b).

In the early healing stage, the screws have to remain in place for proper stabilisation of the graft. In four cases, a fixation screw had loosened and become exposed in the late stage of graft healing (Figs. 7a & b). This screw was removed to prevent infection of the graft (Figs. 8 a&b). In three cases, the soft-tissue perforation healed after several days (Fig. 9). In cases in which the area around the mini-plate and the second cover screw became inflamed (Fig. 10 & 11), we removed the remaining cover screw and mini-plate (Fig. 12), sutured the wound (Fig. 13), and the soft tissue healed after several days (Fig. 14).

In a case in which the mesial part of the NanoBone graft had become exposed (Fig. 15), a mesial mucosal pedicle graft was performed to cover the exposed bone graft (Figs. 16a & b). Afterwards, the wound was sutured (Figs. 17a & b). For the same case, the distal part of the graft had become exposed (Figs. 18a & b) and a distal mucosal pedicle graft was performed to cover the exposed graft (Figs. 19a & b), but the graft size markedly decreased. Then, a wound suture was performed (Figs. 20a & b).

A decrease in augmentation size was noticed (Figs. 21a & b). Once the cover screws (Figs. 22a & b) and mini-plate had been exposed but not loosened (Fig. 23) with partial exposure of the graft (Fig. 24), resuturing of the dehiscence area was performed (Fig. 25) after reducing the volume of the NanoBone

graft (Fig. 26) and performing buccal relieving incisions (Fig. 27) with resuturing afterwards (Fig. 28). However, this led to a larger exposed surface of the NanoBone graft (Fig. 29) owing to subsequent flap necrosis. The NanoBone graft had to be removed completely owing to infection and the result was a total graft failure.

An infected NanoBone graft (Fig. 30) was treated by incision and pus drainage (Fig. 31 a&b). The NanoBone graft healed but decreased in size (Fig. 32).

Conclusion

Careful patient follow-up after ridge augmentation using a NanoBone block is very important for the success of the augmentation procedure. Great attention to detail and a meticulous technique may prevent the progression of complications to failure of the graft. Treatment of a bone block graft exposed in the early stage is very difficult and has a poor prognosis. To date, there is no predictable method for treating this type of complication. Resuturing the dehiscent area at an early stage can lead to an even larger exposed surface of the graft owing to subsequent flap necrosis. Therefore, it is better to wait until the soft tissue matures. During this time, the use of a chlorhexidine solution sev-

eral times a day can be useful in reducing bacterial infiltration. After a period of at least four weeks, surgical closure can be performed after reducing the volume of the block graft. However, the probability of saving all or parts of the graft is very low.⁵

Editorial note: This is the second part of a two-part article, the first of which was published in implants 1/14 ("Ridge augmentation for an atrophied posterior mandible using NanoBone block"). A complete list of references is available from the publisher.

_contact

implants

Dr Omar Soliman

PhD Candidate Perioimplant Dentistry

Tel.: +20 1009634358, +20 1201005457
Omar.Soliman77@yahoo.com

Prof. Dr Dr Mohamed Nassar

Professor of Perioimplant Dentistry
Faculty of Dentistry, Tanta University, Egypt

Tel.: +20 1121522221
prof_mnassar@yahoo.com

AD

[PICTURE: ©SERGEY NIVENS]

Publish - your - expertise

Hand in your article.

Please contact:   

Editorial manager
Georg Isbaner
g.isbaner@oemus-media.de

Editor
Katrín Maiterth
k.maiterth@oemus-media.de

Double crowns made of a new high performance polymer

Author_Dr Rolf Vollmer, Dr Martina Vollmer, ZTM Michael Anger & Dr Rainer Valentin

_Double crowns in form of telescopic or conical crowns have been used for many decades in dental prosthetics. In the beginning of dental implantology prosthetics, there were still doubts about the transfer of these constructions on the implant-supported dentures. However, in the practical application more and more telescopic or conical prosthetics recently prevail.

_Introduction

In the 70s and 80s, the bar restoration on implants was the first choice e.g. by Ledermann (1979). Over the years, more and more telescope or conical crown applications have been described for implant-supported dentures. From the experience of the author it is clearly determinable that a double crown restoration in the mandible with four implants and secondary crowns is indicated. For example, they would provide very good and stable long-term results in electroplating technique (Figs. 1a & b).

The alternatives offered in form of attachments of various kinds stabilise the prosthesis more or less depending on the condition of the jaw. However, these attachments are usually inferior in fixation compared to a double crown restoration. Especially, one-piece implant systems—possibly with implants reduced in diameter and length—with simple ball retaining elements, such as rubber rings, are absolutely inappropriate in terms of a later change of the superstructures. A restoration with double crowns is more complex for both the dentist and the technician with regards to efforts and costs. In the following, a new technique is described using prefabricated parts and a new material combining the advantages of telescopic or conical crown technology with the ease of processing and manufacturing. The application should possibly be done as chair side alternative, which is reasonably priced in the dental laboratory. For fixed detachable prostheses, new possibilities for avoiding screw retention are also described.

Figs. 1a & b Individually made telescopic crowns with secondary parts electroplated in "passive fit" technology glued to a metal frame.

Figs. 2a & b Telescopic crowns on IMC cylinder implants (Dr. Nikola Laux 1984).

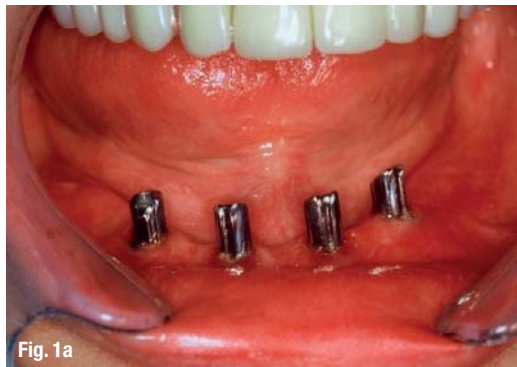

Fig. 1a

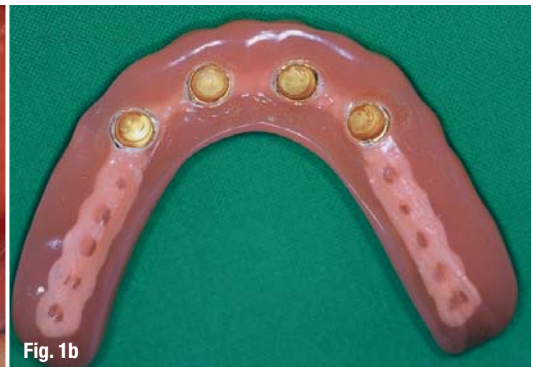

Fig. 1b

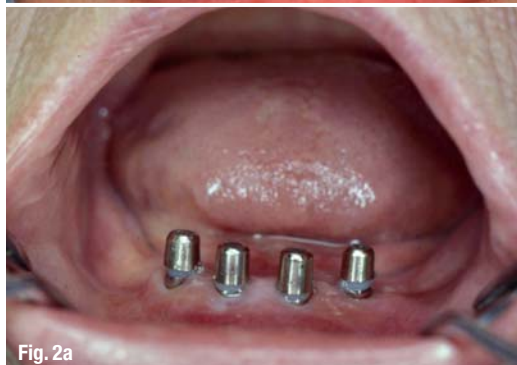

Fig. 2a

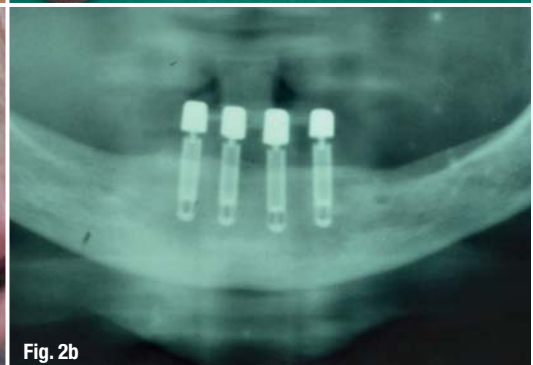


Fig. 2b

44TH

INTERNATIONAL ANNUAL CONGRESS OF THE DGZI

Been there already?
Concepts in Implantology

September 26–27, 2014
Düsseldorf, Germany | Hilton Hotel

Scientific Director: Prof. (CAI) Dr Roland Hille/DE

SPEAKERS

Prof. Dr Florian Beuer/DE
Priv.-Doz. Dr Kai-Hendrik Bormann/DE
Prof. Dr Suheil Boutros/US
Prof. Dr Herbert Deppe/DE
Dr Dirk U. Duddeck/DE
Prof. Dr Wolf-D. Grimm/DE
Priv.-Doz. Dr Friedhelm Heinemann/DE
Prof. Dr Kai-Olaf Henkel/DE
Prof. Dr Guido Heydecke/DE
Dr Detlef Hildebrand/DE
Priv.-Doz. Dr Dr Marcus O. Klein/DE
Prof. Dr Johannes Kleinheinz/DE
Prof. Dr Regina Mericske/CH
Dr Dr Manfred Nilius/DE
Prof. Dr Dipl.-Ing. Jürgen Richter/DE
Dr Achim W. Schmidt, MSc/DE
Prof. Dr Dr Ralf Smeets/DE
Prof. Dr Thomas Weischer/DE
Prof. Dr Dr Richard Werkmeister/DE

DAY TICKETS AVAILABLE!

PROGRAM
44th INTERNATIONAL
ANNUAL CONGRESS OF THE DGZI



Gold Sponsor

otmedical[®]

Silver Sponsor

straumann
simply doing more

Bronze Sponsor

Implant Direct
simply smarter.

DGZI
Deutsche Gesellschaft für
Zahnärztliche Implantologie e.V.

FAX REPLY // +49 341 48474-290

Please send me further information on the
44TH INTERNATIONAL ANNUAL CONGRESS OF THE DGZI
on 26–27 September, 2014, in Düsseldorf, Germany.

Office Stamp

Historical development of double crown systems

From literature it is known that Starr was probably the first who reported, in 1886, about a removable bridge made of double crowns. In English literature Peeso (1924) reported about possible applications of the double crown systems. In Germany it was Häupl in 1929 and Böttger in 1961. The breakthrough of double crown systems took place in Germany in 1969 with Körber (1988) who advocated the use of conical crowns with a defined angle of convergence. Over the decades the conical crown has become known as "German crown" which refers to the frequent use in the German-speaking area until today. According to Körber (1988) double crown systems should include, among other things, exactly fitting pillar integration, secondary splinting with an axial directed periodontal load and firm support during function which is easily removable for hygienic reasons. Furthermore, the production should be as efficient as possible and a high economic effect should arise by a very long survival rate, which can be expected.

Körber (1988) distinguishes telescopes according to their form:

Cylindrical telescope: It hardly tolerates technical inaccuracies and is therefore, according to Körber, classified as problematic in manufacturing.

Cone-shaped telescope: With regard to the fit there is a high tolerance, it allows production with a low error rate.

Resilience telescope: Primary and secondary parts should have some backlash in the occlusal region in order to have some space on top of each other under load. The telescope should only undertake the functions of friction and indirect connection of the retaining teeth (bracing).

Definition of the cone angle for double crown systems

The three systems—the telescope crown, the conical crown and the resilience telescope—are double crown systems, which differ by the type of fit and adhesion. The determining factor for the strength of adhesion is according to Heners (1990), the convergence angle.

In the early days of implant dentistry one was still sceptically about the use of double crown systems on implants. At this time, as one of the first colleagues the dentist Dr Nikola Laux from Hamburg, Germany, introduced the use of telescopic crowns on implants (IMC cylinder implants) in 1984 (Figs. 2a & b). In 1996, two of the authors (Vollmer, R. and Vollmer, M.) provided a mandibular removable prosthesis with six implants and telescope crowns with secondary parts made of Teflon already (Figs. 3a & b).

Convergence angle & value at various double crowns:

Telescopic crown: $\alpha = 0^\circ$ (clearance only)
 Conical crown: $0^\circ < \alpha < 8^\circ$
 Resilience telescope: α may only be so large that just an adherence occurs

Largest recommended convergence angle: $\alpha < 10^\circ$ (with double crown systems according to Muhs, 2006)

Advantages of the double crown technique

1. Straightforward extensibility after losing a primary crown.
2. Possibility of extra-oral repairing.
3. Better and easier periodontal hygiene compared to fixed prostheses.
4. Parallelisation of abutment teeth in the case of divergences.

Disadvantages of the double crown technique

1. Complicated, precise and technical manufacturing, high demands on the technician.
2. High costs for the work of the technician and for the material (e.g. use of precious metal, electroplating).
3. In order to achieve aesthetic results, an intensive substance reduction of the abutment teeth must take place. If this is not possible, the result in the anterior areas of the jaws is aesthetically often unsatisfactory.
4. The use of ceramic veneers fusing to the secondary parts in the front area is risky (chipping).
5. Loss of adhesion and pull-off force after a certain time.
6. Missing or difficult possibilities of activation (post electroplating, fabrication of additional attachments).
7. When using an inexpensive base metal (non-precious metal) / Eco-gold combination, corrosion can occur leading to excessive friction.

The material PEEK—A historical review

For a long time, plastics were frequently used in the dental field. Light weight, an easy processing ability compared to metals and ceramics, are some of the benefits. The most known plastics are Polyoxymethylene (POM) and Polymethylmethacrylate (PMMA).

PEEK (Polyetheretherketone) is a newer polymer which is also used for medical products since the mid-90s (Fig. 5). The material was developed in 1978 and mainly used for mechanical engineering and in the automobile industry initially. Meanwhile, PEEK is used for the production of biomaterials in medicine, e.g. for artificial vertebral bodies, anchoring screws, artificial

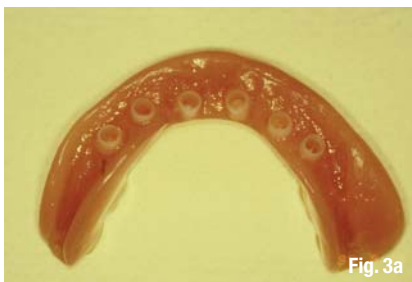


Fig. 3a

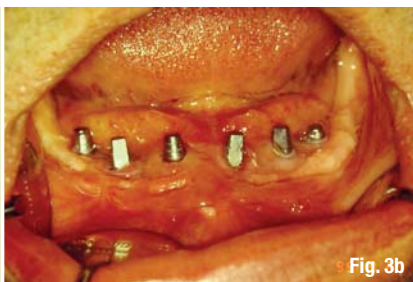

Fig. 3b



Fig. 4

joints etc. Since the original material has a dark colour, it initially appeared to be not suitable for dental applications. However, one succeeded to vary the colour of the material so that it could also be used for temporary restorations and abutments (Kirsch, 2002).

Today the following indications are cited: full crown caps for single crown copings, full anatomical bridges, scaffolds for veneer bridges, primary crowns, inlays, inlay bridges and Maryland bridges. So far, the approval of the material was limited to removable or conditionally removable (screwed) dentures. This means that with the described material metal-free dentures, secondary parts, over structures with combined dentures, implant-supported full crowns in the posterior region and conditionally removable, screw-retained bridges can be realised.

A distinction has to be made between pure PEEK and PEEK with additives. Recently, industrially manufactured blanks (Fig. 4) are available with an authorization

for definitive and removable dentures (e.g. dental discs "Tizian PEEK Blanks" Schütz Dental Ltd., Germany). The material has no additives and is used in medicine for many years now. Since the highly pure PEEK material contains no additives—such as barium sulfate—it is not visible on X-ray control images (Fig. 6). Other manufacturers, however, use additives such as barium sulfate deliberately for a radiographic display.

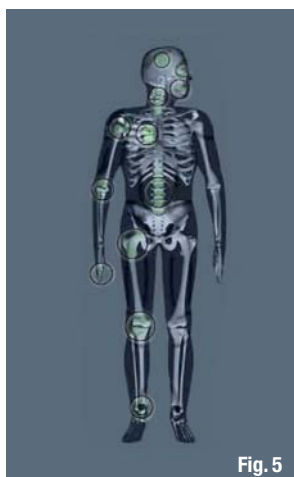


Fig. 5

Also, a so-called white-PEEK is offered in the field of dental prosthetics from different companies. This material is mixed with up to 20 per cent titanium dioxide which makes the colour lighter or whitish. In this method, the hardness (flexural strength) of the material is raised, but at the same time the sliding property is deteriorated. Another disadvantage is that from the material titanium dioxide ions go in solution and work like a ventilation element after a certain period of wear. This can lead to discolouration of the gingiva. Therefore, pure, medical PEEK for prosthetic parts processing is rather recommended.

other disadvantage is that from the material titanium dioxide ions go in solution and work like a ventilation element after a certain period of wear. This can lead to discolouration of the gingiva. Therefore, pure, medical PEEK for prosthetic parts processing is rather recommended.

Figs. 3a & b_Full denture with Teflon secondary crowns (Vollmer, R. & Vollmer, M. 1996).

Fig. 4_PEEK prosthetic parts milled from so-called blanks (dental discs Tizian PEEK Blank, Schütz Dental Ltd., Germany).

Fig. 5_Applications of PEEK in the human body (Source: elements 39, issue 2/2012).

Figs. 6a–c_CNC machined PEEK abutment (Dental lab/milling center Anger, Remagen, Germany). No radiological visibility of the PEEK secondary part.

Fig. 7_Prefabricated primary parts of different angulations (Schütz Dental Company Ltd., Rosbach, Germany).

Figs. 8a–c_Clinical situation with more severe atrophy of the mandible in the posterior region (a); production of total mandibular denture before implant exposure (b); marking the implant positions (c).



Fig. 6a



Fig. 6b



Fig. 6c



Fig. 7

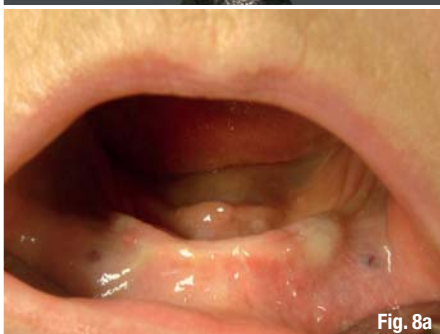

Fig. 8a

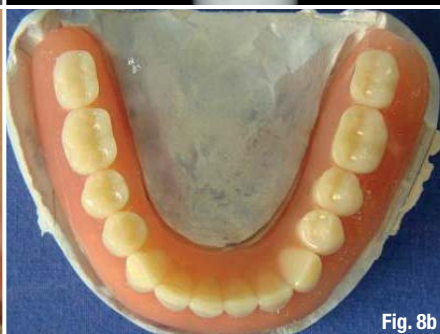

Fig. 8b

The properties of PEEK

PEEK is dimensionally stable up to a temperature of about 152 degree Celsius, the material is high melting, about 334 degree Celsius. PEEK is resistant to water and ionising radiation. Therefore, the physical properties do not change even during sterilisation at 170 to 180 degree moist/heat sterilization at 200 degree Celsius/one bar or during sterilisation using gamma radiation. The chemical consistency is very good. It only reacts with concentrated sulfuric acid (H₂SO₄). Therefore, the use in the oral cavity is safe and the material has the CE mark for medical devices. The low specific mass, the elasticity similar to the one of bone, the absence of metals and the toughness, combined with an almost non-existent material fatigue makes the material an ideal partner in prosthetic dentistry and implantology.

Processing PEEK

To process PEEK the so-called "semi-finished" base material is needed which is produced in several ways of powders or pellets for later processing. These are:

- Extrusion
- Injection molding
- Selective laser sintering (SLS technology)
- CAD / CAM.

CAD/CAM technology

Since the material allows processing using CNC mills very well, the CAD/CAM technology is used to produce the finished parts. Elaborate individual work assignments of the dental technician in the form of scaffold modelling with subsequent individual polymerization can be avoided.

Tasks and objectives

The application of the double crown technique on implants will be described in the following. The prior mentioned advantages of the new material PEEK for dentistry should be used for dental implant superstructures by prefabricating standardised parts. The mentioned advantages of the double crown technique should remain and the disadvantages should be largely avoided or allow a reconstruction in a cost effective way.

A system is described to combine the advantages of the already known traditional custom-made double crowns with individually milled primary parts with the advantages of double crowns with industrial prefabrication.

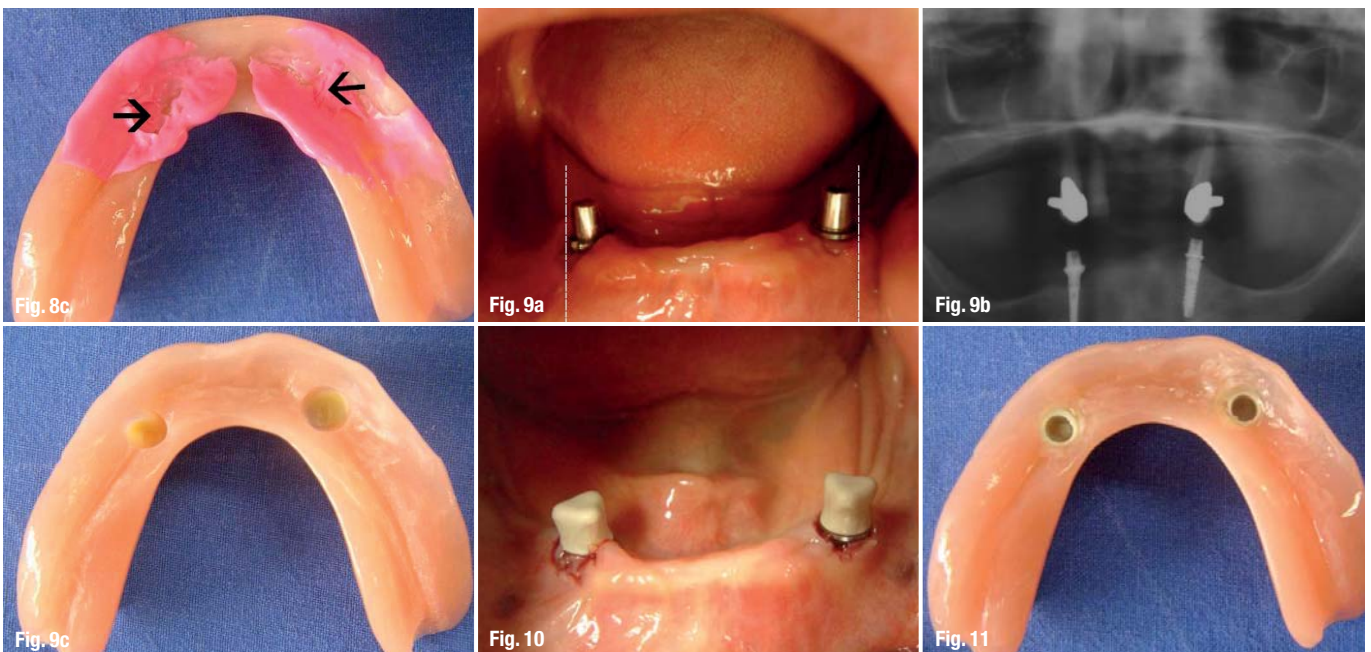
Prefabricated cone parts are used with different angular deviations of the implant abutment (Fig. 7). For these abutments perfectly fitting PEEK caps are manufactured using CAD/CAM technology.

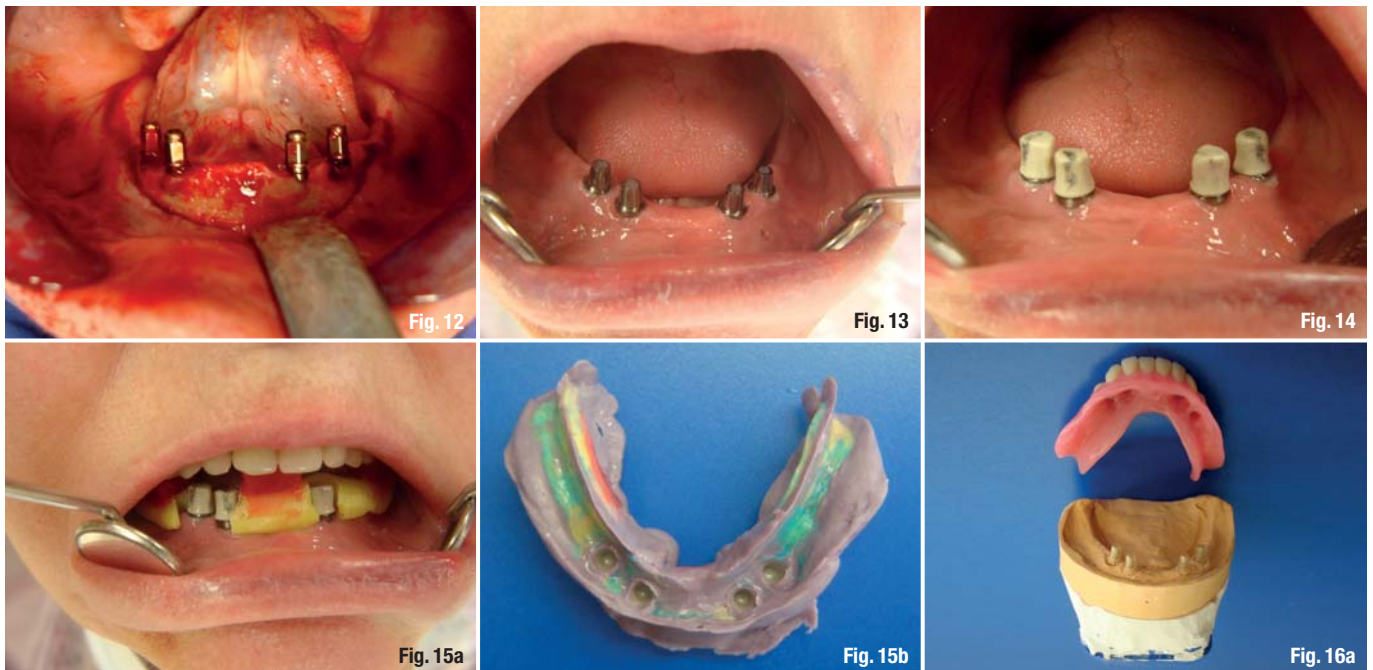
Different indications and case documentations

Case 1: Removable prosthesis on two implants—direct procedure

The cone primaries can be parallelized in the patient's mouth without time consuming impression taking and transfer to a model. Only an X-ray control recording to verify the abutment seating is useful. The previously made full mandibular denture (Figs. 8a-c) is marked with silicone at the implant exit points after tissue exposure. Then, the prosthesis is milled (Figs. 9a-c) and adjusted in the patient's mouth to the implant abutments covered with the PEEK caps (Fig. 10). In doing so, no later tension can arise. Using an acrylic resin,

Figs. 9a-c Parallelisation of the primary parts in the mouth (a); X-ray control (b); grinding out the prosthesis for gluing the secondary parts (c).
Fig. 10 PEEK secondary parts in site.
Fig. 11 PEEK abutments polymerised in the prosthesis.





the PEEK caps are then glued in the patient's denture directly (Fig. 11). This method enables a so-called "passive fit" of the removable prosthesis. Due to the good adaptation of the PEEK material to the primaries a suction effect develops in addition to the friction of the parts. The primary parts can—if necessary—be sand-blasted and thus roughened to increase the friction effect. Nevertheless, this is not required in most cases if there are sufficient parallel surfaces. In the present case, in spite of an in the posterior area severely atrophic mandible, one has been able to achieve a very good stabilisation of the removable prosthesis without having the effect of a rotation around the linking axis of the implants.

Case 2: Removable prosthesis on four implants – half-direct procedure

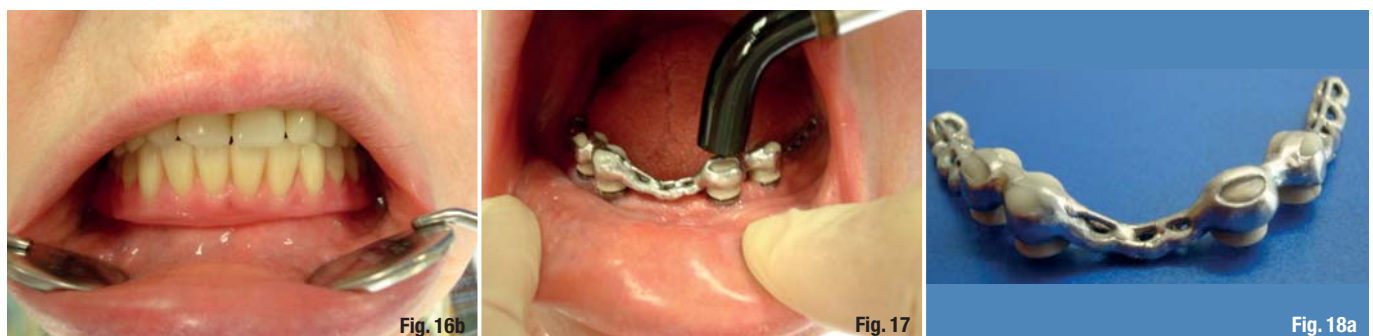The female 79-year-old edentulous patient had received a new lower denture about one year ago. She was very unhappy all the time, until she had been informed by an acquaintance about the possibility of dental implantation. After appropriate education and measurement of the bone volume, four implants were

inserted in the anterior mandible (Fig. 12) to provide a supply with prefabricated titanium primary telescopic crowns and PEEK secondary crowns.

After three months of healing, the titanium copings were then parallelised in the patient's mouth (Fig.13). The PEEK caps were adjusted to the primary crowns (Fig. 14) and both bite registration and functional impression were made in one step procedure (Fig. 15). In the meantime, the existing prosthesis of the patient was already supplied with two PEEK caps and a soft relining, so that the primary abutments no longer had to be removed.

In the next session, the wax try (Figs. 16a & b) and the tertiary framework try-in was done. After the wax try-in, the secondary PEEK crowns were placed back in the mouth again and the premade model casting reinforcement was tried in. Since the fit was very good, according to the passive-fit method, the gluing of the PEEK abutments with the tertiary structure in the patient's mouth was made with a dual curing material (Fig. 17).

Fig. 12_Implants after insertion.
Fig. 13_Secondary conical parts parallelised and fixed.
Fig. 14_Try-in of the PEEK secondary parts.
Figs. 15a & b_Impression fixing the PEEK parts and bite registration in one step.
Figs. 16a & b_Wax up of the teeth and try-in of the full denture.
Fig. 17_Tertiary framework try-in and gluing in the patients mouth for passive fit.
Figs. 18a–c_Repositioning of the metal frame and check of the passive fit.



Figs. 19 a & b_Prosthesis finished and final incorporation.



Fig. 18b

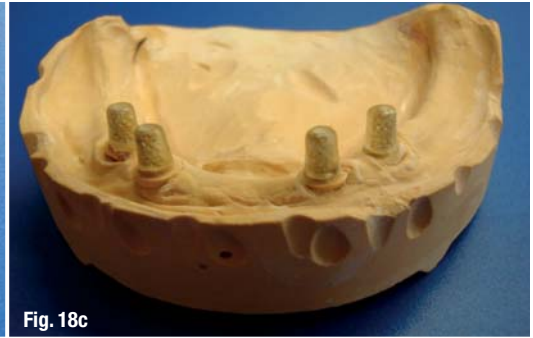


Fig. 18c

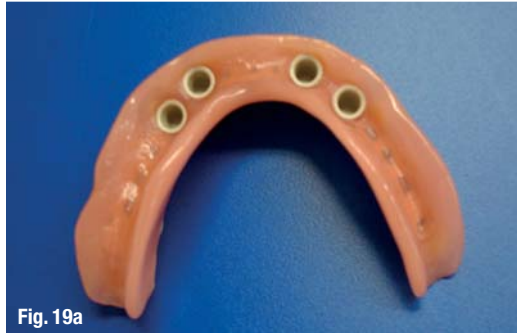

Fig. 19a

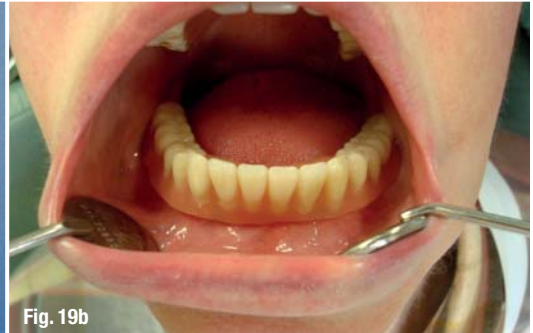

Fig. 19b

After the removal of the bonded parts, the complete part was reset to the working model (Figs. 18 a & b). There were no deviations or tensions detected. In the dental laboratory, the total work now could be completed so that the integration of the prosthesis was already at the next meeting (Figs. 19 a & b).

The PEEK abutments "run" or glide on the primaries very good. The prosthesis has a very solid tension-free fit and can still be easily removed by the patient. Prostheses pressure points have not occurred.

Case 3: Fixed or removable prosthesis on nine implants—screwing or cementing or none of both?

The female patient's age was 51 when about 14 years ago, in the year 2000 she received maxillary and mandibular implants. The wish of the patient at that time was not wearing removable parts in her mouth. Later in the maxilla, a fixed ceramic fused to metal bridge restoration was incorporated. In the lower jaw, a 14 unit acrylic bridge metal enforced from one piece was integrated. A retrievability was provided as in the anterior region a larger defect was already present. This region

was used to stabilise the interim prosthesis with so-called bicortical screws.

However, since it turned out that after the healing the bicortical screws were absolutely stable and firmly healed, they were left in the jaw and incorporated into the prosthetic construction.

After about ten years, the patient started having problems at the distal right implant which turned out to be loose and had to be removed (Fig. 20). After a small makeover, the existing bridge was then reintegrated.

The implant failure had likely been caused by the so-called medial shift (Fig. 21) of the mandible and the cantilever construction. Sometimes, this effect is also observed in bridges in the mandible, ranging from the anterior region to the wisdom tooth. Especially when the patient is older and the lower jaw shows a decrease of density, it comes to this release or decentering effect. For this reason, appropriate separation points should also be included in the mandibular

Fig. 20_Situation ten years after full implantation. Loss of one implant in the lower right mandible.

Fig. 21_Medial shift by the masticatory muscles.
Figs. 22a & b_Original bridge designed for cementation. Signs of wear, discolouration, abrasions and cracks.

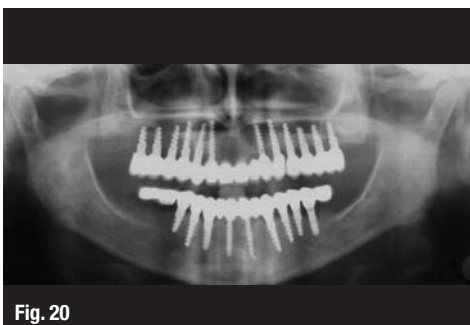

Fig. 20

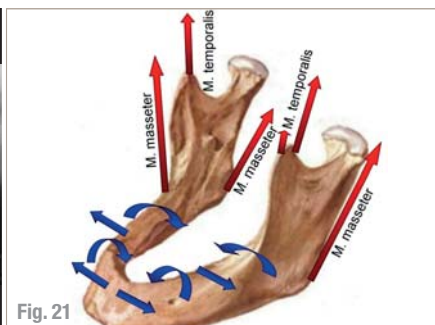


Fig. 21

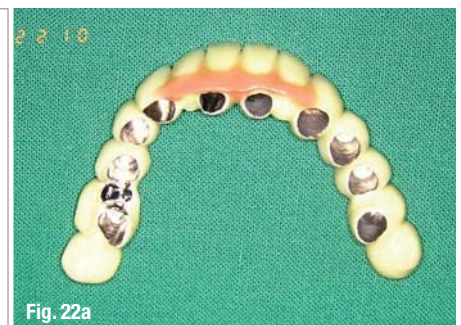

Fig. 22a

INTRODUCING



**DIGITAL
DENTISTRY
SHOW**

AT
INTERNATIONAL EXPODENTAL MILAN

16 | 17 | 18 OCTOBER 2014

EXHIBITION

LIVE PRODUCT PRESENTATIONS

HANDS-ON WORKSHOPS

PRINTED REFERENCE GUIDE

COFFEE WITH THE EXPERTS

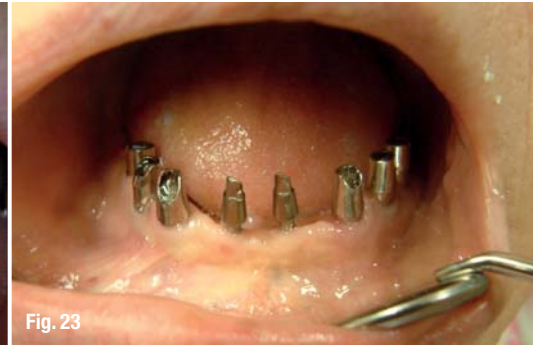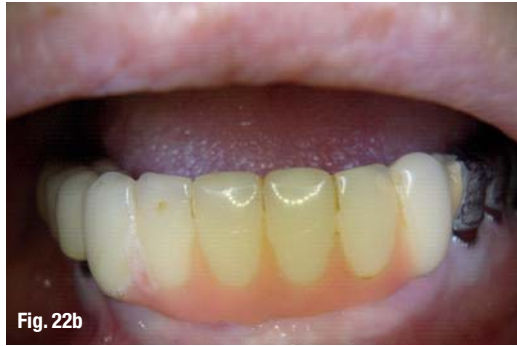www.DigitalDentistryShow.com

Organized by Dental Tribune International in cooperation with Promunidi.
Dental Tribune International | Holbeinstraße 29 | 04229 Leipzig | Germany
T +49 341 48474 134 | F +49 341 48474 173
E info@digitaldentistryshow.com | W www.DigitalDentistryShow.com

dti Dental
Tribune
International

PROMUNIDI

Fig. 23 Clinical situation after removing the bridge.



bridge restorations. Cantilever constructions should be avoided whenever possible.

Over the years, the gingiva of the patient was for whatever reasons much more sensitive and the patient had great fear to lose more implants in the lower jaw. She wore the existing bridge structure only as a kind of a loose removable bridge. Since the design was intended for at least a temporary cementation, it always came to a wear and chipping of the plastic veneers, which could no longer be repaired (Figs. 22a & b). Now, in 2014, the patient is 65 years old and a new treatment-plan with three divided bridges for cementation was suggested. However, she refused and insisted to get a part that is removable or to have the old one repaired, which for technical reasons was not possible. There were different solutions discussed including new primary telescope parts and electroplating technique for the secondary parts. A decision was not made by the patient especially because of cost reasons. The only statement was that she wanted to have something like a removable bridge.

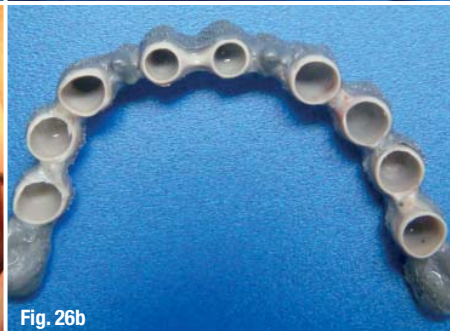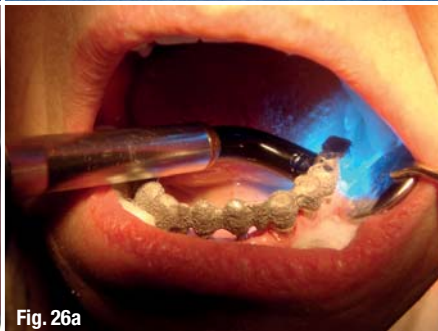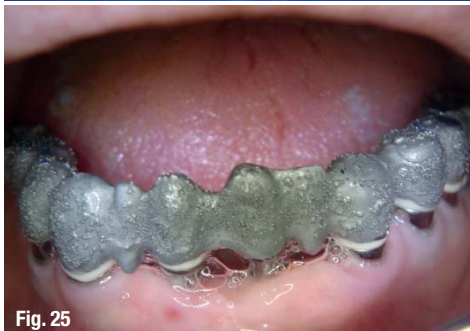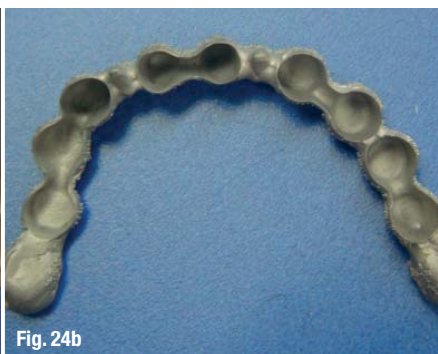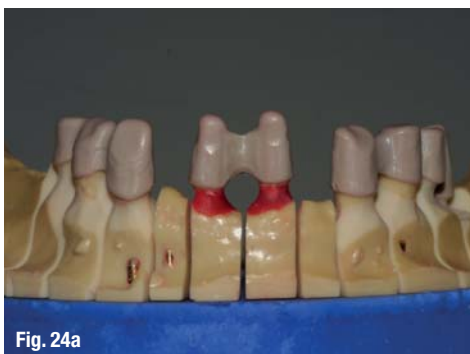After assessments and parallelism measurements of the existing models in the dental laboratory, it turned out that there was also the opportunity to design a new restoration with the help of PEEK secondary crowns and a tertiary cast framework for acrylic pontics without removing the original abutments (Fig. 23). The patient agreed on this proposal.

First, the PEEK secondary parts, some of which were splinted, were tried in (Figs. 24a-c). The fitting was very good. The model casting reinforcement for the tertiary structure also fitted perfectly (Fig. 25). So the bonding of both (PEEK and metal frame) similar to the previous case was done directly into the patient's mouth (Figs. 26a & b). In this case, a pick-up impression in the double mixing method was manufactured (Fig. 27). The bite was registered over the tertiary structure. The result was a very good matching, stress-free, removable bridge with a pleasant chewing comfort that meets the needs and expectations of the patient (Figs. 28 & 29).

Figs. 24a-c_New designed secondary parts made of PEEK; Tertiary structure.

Fig. 25_Try-in of the tertiary structure.

Figs. 26a & b_Glueing the tertiary structure to the PEEK secondary crowns.

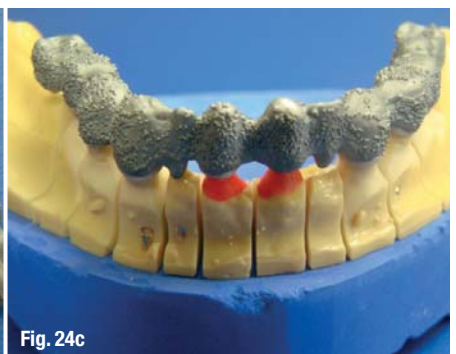

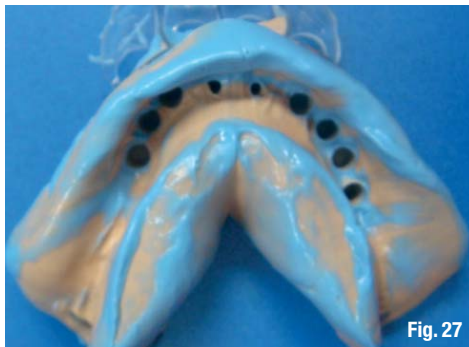


Fig. 27

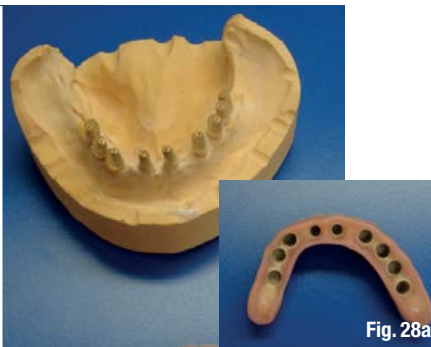


Fig. 28a

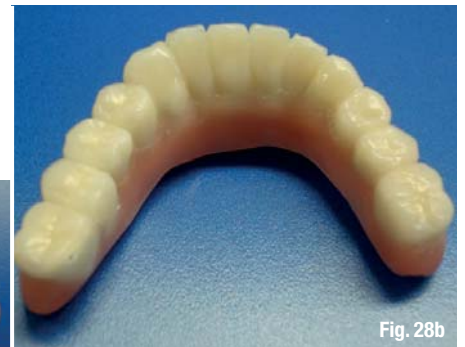

Fig. 28b

Case 4: Fixed prosthesis on two implants and three unit bridges—screwing or cementing or none of both?

This 77-year-old patient was already supplied with multiple implants and wanted the gap 23 to 25 to be filled with a fixed bridge (Fig. 30). Since it was a FP 3 option or indication according to C.E. Misch and hygiene deficits of patients had to be corrected with the help of a professional dental cleaning, in this case we decided to manufacture, similar to the previous case, a removable bridge which was neither cemented nor bolted.

The process was corresponding to the case before. The difference was that we were using porcelain fused to metal. The bridge was glued in the mouth to the two PEEK caps (Figs. 31, 32a & b). Now, the patient has a very good chewing comfort. The prosthesis can be removed from the prophylaxis assistant very well. The problem of a cemented bridge with the appropriate cement residues, a possibly too strong adhesion and a difficult retrieve possibility was avoided as well as the disadvantages of screwing. The use of ceramic ve-

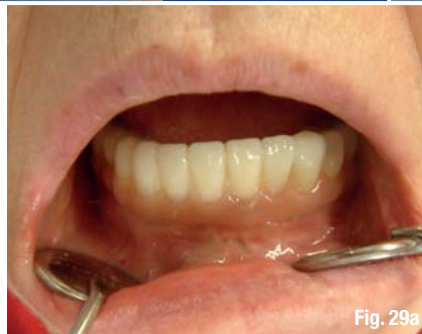

Fig. 29a

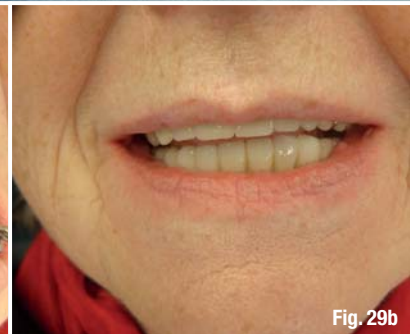

Fig. 29b

neers fused to the secondary parts is possible and chipping avoided (Fig. 33).

Case 5: Removable prosthesis on four implants and Locator® attachments—unsatisfied patient

The patient, aged 81 years, had significant problems with the adhesion and fit of his lower jaw full prosthesis for years. Because of cost concerns a bar or telescoping construction using electroplating was omitted. Although the initially applied two anterior implants with a simple ball connection device ensured a stabilization of the prosthesis, there were always returning pressure sores and points in the posterior region of the mandible

Fig. 27_Impression to fix the superstructure.

Figs. 28a & b_Final prosthesis.

Figs. 29a & b_Clinical situation.

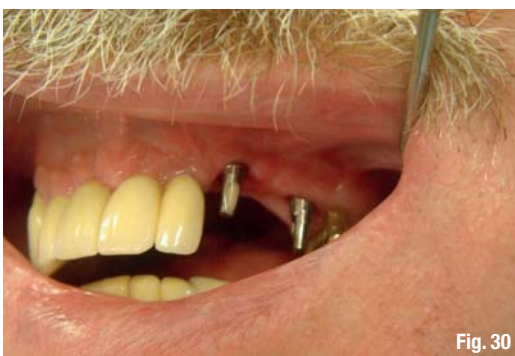

Fig. 30

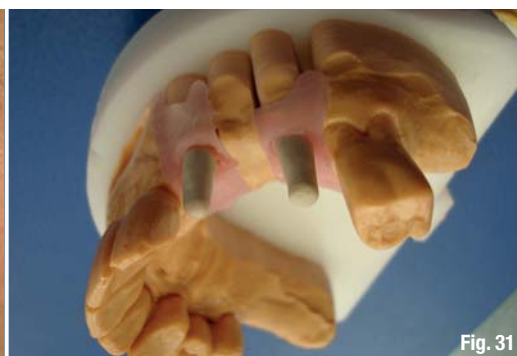

Fig. 31

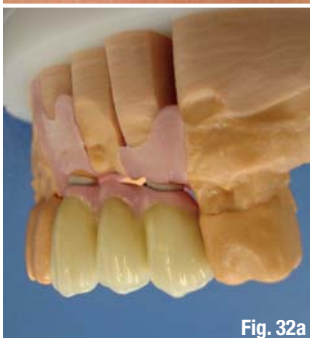

Fig. 32a

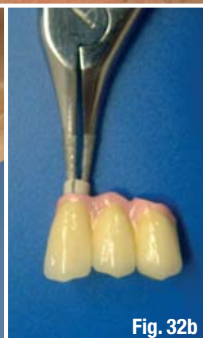

Fig. 32b

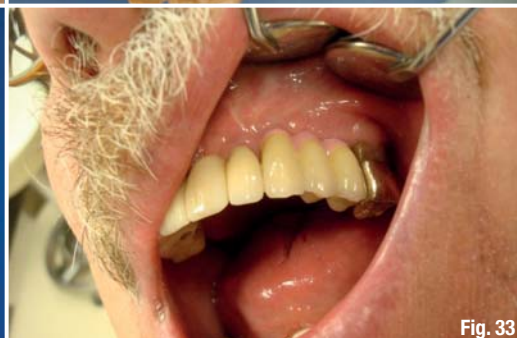

Fig. 33

Fig. 30_Clinical situation, FP 3/4 acc. to C.E. Misch.

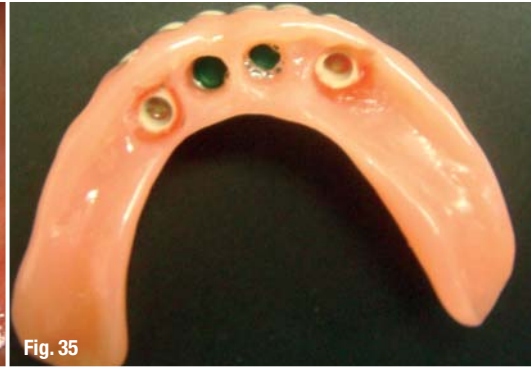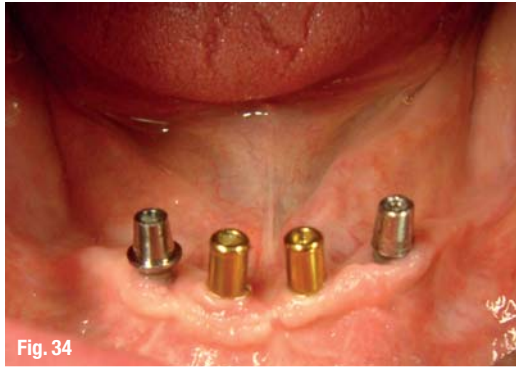Fig. 31_Peek parts on the stumps.

Figs. 32a & b_Porcelain fused to metal bridge with PEEK secondaries before glueing together.

Fig. 33_Finalised bridgework.

Fig. 34 Combination of Locator® abutments and prefabricated conical crowns for better stabilisation.

Fig. 35 Remanufactured mandibular denture.



causing pain. Later, two more implants were placed anterior because of the patient's request for a better stabilization of his prosthesis. However, the construction on four implants with Locator® attachments brought only a little improvement. Still, the patient was not 100 per cent satisfied, even though the prosthesis was underlined and perfectly fitting the jaw. Later, to eliminate the tilting movements in the distal jaw area during mastication, two Locators® were replaced by a prefabricated cone crown system with PEEK secondary parts (Fig. 34).

The immediate stable position and the perfect fit of the mandibular denture were amazing. Finally, the patient got the desired result, which was within his personal budget (Fig. 35).

Discussion

In recent years, a variety of proposals for affordable dental implant solutions for the patient are made according to Held. If one earlier estimated that four implants are necessary for a stable construction in the mandible, we are confronted with concepts varying from All-on-4® (Paolo Malo) to "All-on-One" ("Better one than none") e.g. a multicentre study by the University of Kiel, Prof. Dr Matthias Kern. The aim of the study is to provide more and more patients with a cheap and simple reconstruction in limited indications such as a very strong distal atrophy of the mandible. In general, money-saving reduced implant solutions have the disadvantage that the loss of a single implant already leads to a complete redesign and start from the beginning. This has to be considered during the complete planning process. A construction of two implants only with the use of pre-fabricated parts is—at least in the lower jaw—a good compromise between a minimal solution (one implant) with a very restricted indication and an only moderate stabilisation and prosthetic cost effective solutions that are based on at least four implants. The new high-performance polymer PEEK offers in combination with prefabricated conical crowns many ways especially with the use of CAD/CAM technology to expand the prosthetic range on a low-cost basis. The corrosion phenomena when using non precious metals/Eco gold can be avoided.

Conclusion

The bar prosthetic construction in the mandible propagated by Ledermann (1979) is currently the only scientifically validated indication. Every other described technique still requires further clinical testing and scientific evidence of their suitability.

The here described treatment option should combine the advantages of a high-quality implant restoration with the advantages of low-cost simple fabrication. The use of prefabricated components and the use of a new cost economical material enable well-fitting stable constructions, especially in cases of advanced mandibular atrophy. New indications like cement and screw less fixed solutions are of special interest and very challenging. Ceramic veneers can be fused to the secondary parts also in cases of removable bridges and avoid chipping.

New materials in the implant prosthetics will continue to offer new additional possibilities. Here, the imagination of colleagues for further development is almost not limited. The use of ceramic veneers fusing to the secondary parts in the front area is risky (chipping). There is still much to do. Let's do it!

Editorial note: A list of references is available from the publisher.

<u>contact</u>	implants
<p>Dr Rolf Vollmer Nassauer Str. 1 57537 Wissen, Germany info.vollmer@t-online.de</p> <p>Zahntechnik Michael Anger Drususstr. 8–9 53424 Remagen, Germany info@ma-fraeszentrum.de</p>	





CROIXTURE

PROFESSIONAL MEDICAL COUTURE



EXPERIENCE OUR ENTIRE COLLECTION ONLINE

WWW.CROIXTURE.COM

Replacement of teeth through implantation and ridge expansion

A case report

Authors Carlos Barrado & Juan M. Ambros, Spain

Introduction

The use of implants with a tapered design and a short drilling sequence is an increasingly common trend, since such implants allow us to perform simple, quick and minimally invasive surgery in the bone. Working with an implant system that has a short drilling sequence also allows us to use a simple and ergonomic surgical tray, which facilitates the work of the surgeon and support staff (Fig. 1).

Moreover, the use of threaded osteotomes is a simple, predictable surgical technique that allows the dentist not only to place implants in areas with a narrow transverse diameter without bone regeneration, but also to improve bone quality in the receiving area and to reduce the drilling sequence in cases of immediate post-extraction implantation.

In the clinical case presented here, transverse bone volume was needed to place two implants in

Fig. 1 BEGO Semados® RS/R SX-Line Trayplus.

Fig. 2 Initial situation.

Fig. 3 C.B.C.T. scan study of the clinical case.

Fig. 4 Tooth 24 after preparation and beginning of the surgical procedure.



Fig. 1

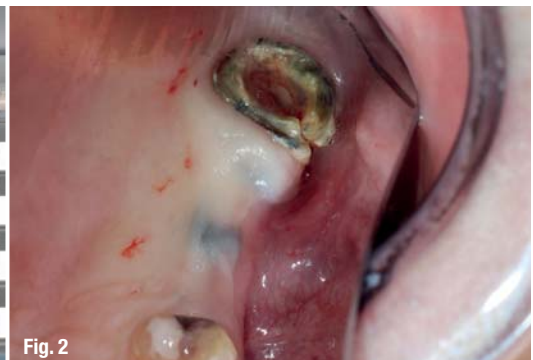

Fig. 2

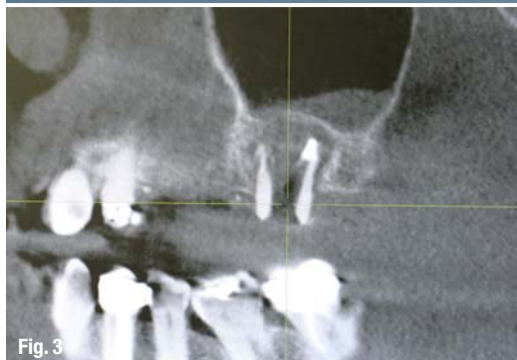

Fig. 3

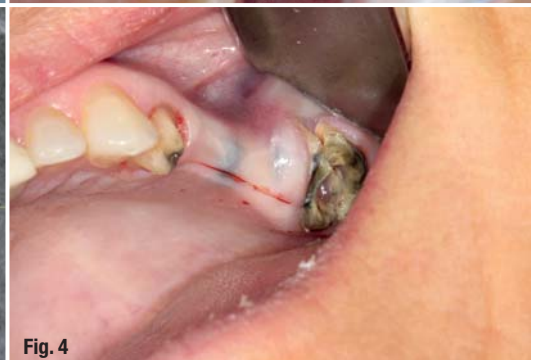

Fig. 4

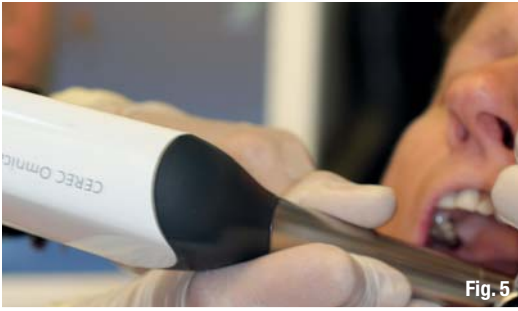

Fig. 5

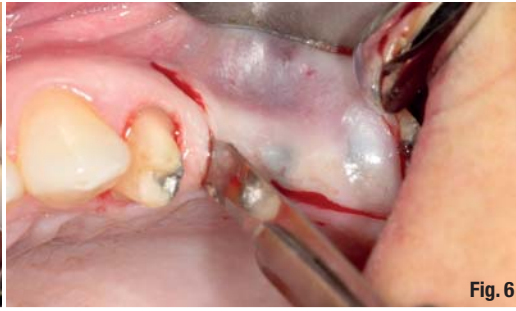


Fig. 6

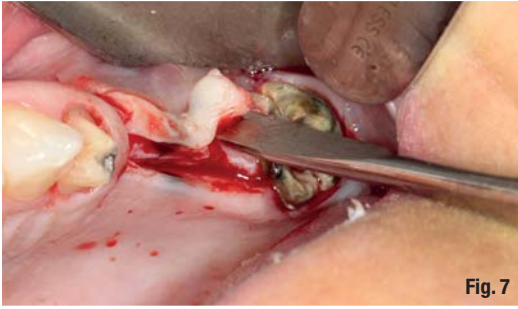

Fig. 7

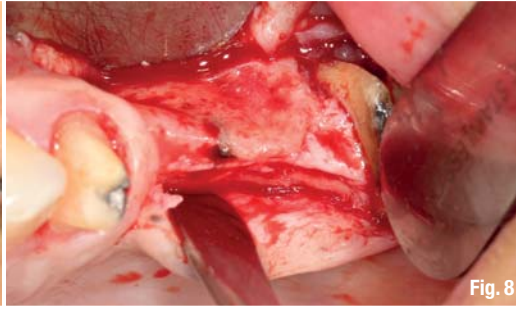


Fig. 8

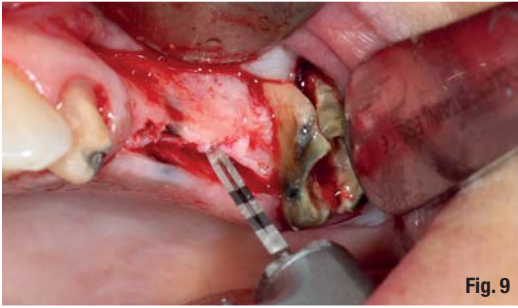

Fig. 9

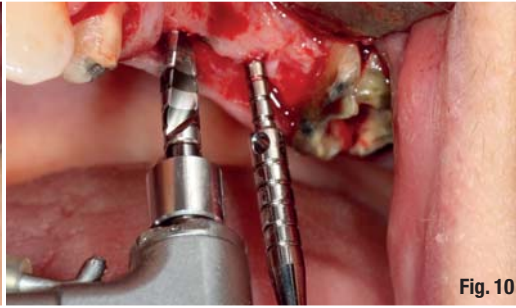

Fig. 10

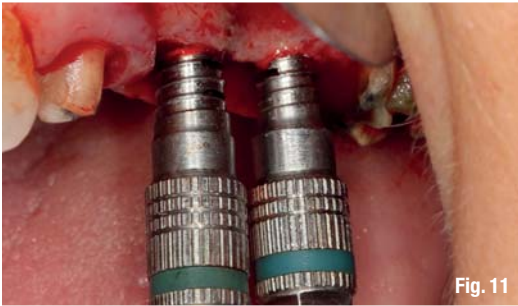

Fig. 11

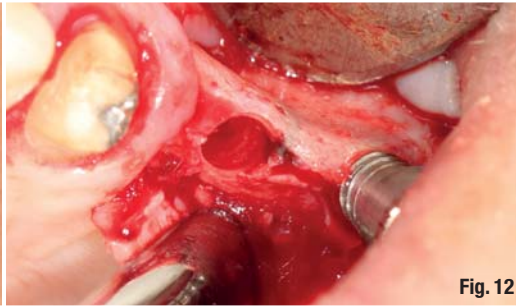


Fig. 12

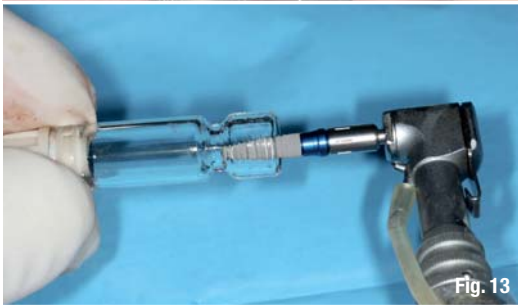

Fig. 13

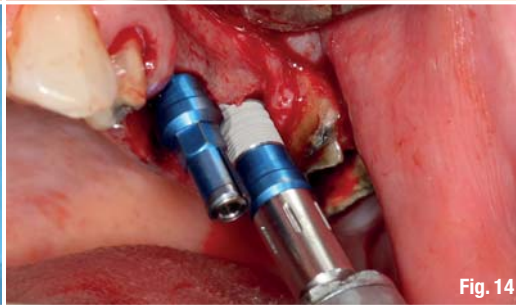


Fig. 14

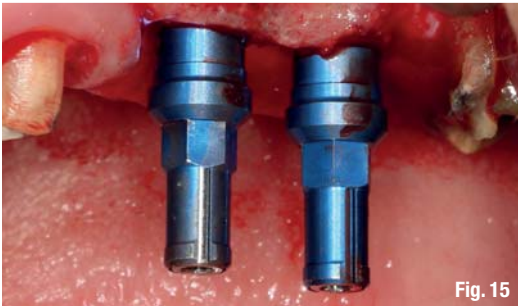

Fig. 15

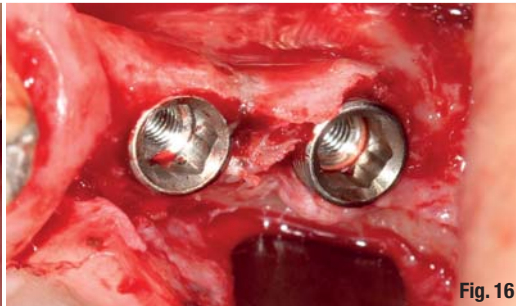

Fig. 16

Fig. 5_Digital image made with CEREC Omnicam camera.
Figs. 6–8_Mucoperiosteal full thickness flap with mesial vent for papillary preservation.
Fig. 9_Drill Pilot Marker RS/RSX-Line 1.6.
Fig. 10_Depth drill RS/RSX Line 2.5 and paralleling post RS/RSX-Line.
Fig. 11_Threaded osteotome.
Fig. 12_Implant bed after preparation.
Fig. 13_BEGO Semados® RSX Implant.
Fig. 14_Insertion of the implants.
Fig. 15_Implants after placement, presenting a colour coded insertion post, optimal parallelism and preservation of the buccal wall.
Fig. 16_Occlusal view of the internal connection of the BEGO Semados® RSX implant.

Fig. 17_Implants connection area covered with a colour coded cover screw.

Figs. 18 & 19_ISQ measures.

Fig. 20_Removal of fractured tooth (27) and the surrounding granulation tissue.

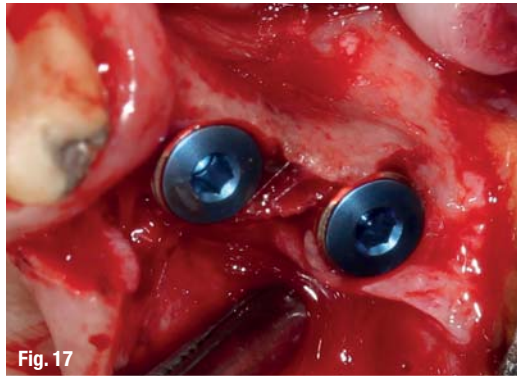


Fig. 17

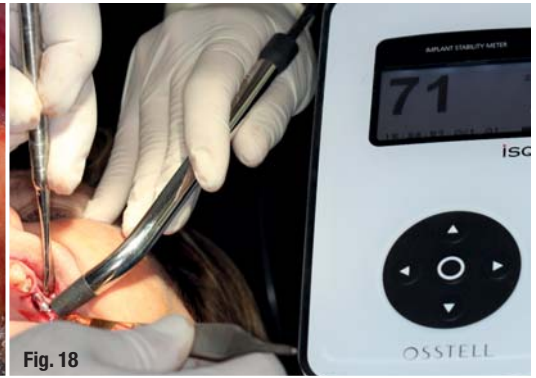

Fig. 18

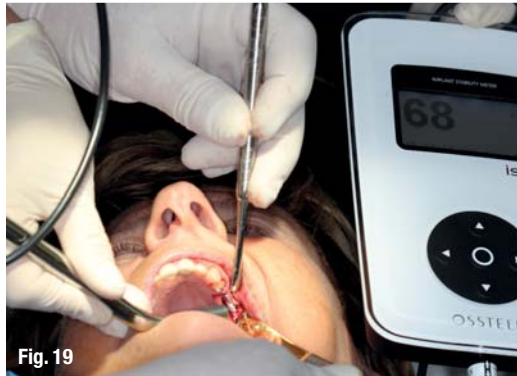

Fig. 19

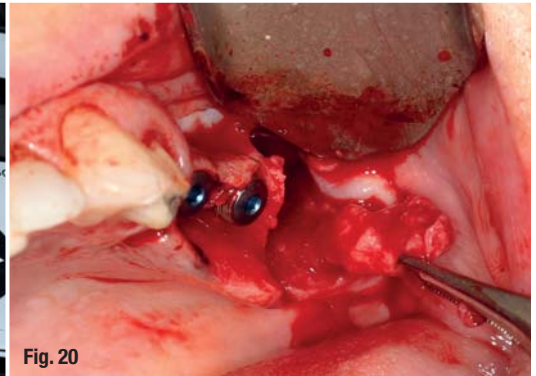


Fig. 20

positions 25 and 26. Instead of guided bone regeneration with an autogenous bone block or xenogenic bone substitute material covered with a collagen membrane, a crestal expansion with threaded osteotomes was proposed. Also, it was decided to use BEGO Semados RSX implants (BEGO Implant Systems) because of their macroscopic tapered design and high self-tapping property.

Clinical case

A 60-year-old non-smoking female patient without any noteworthy clinical pathology or current drug treatment came to our clinic reporting pain and swelling in tooth 27, which was a supporting element of a bridge on teeth 24–27 (Fig. 2). A root fracture with a large apical cyst affecting the three roots of the molar was observed on a CBCT scan (Fig. 3). Based on this finding, the following treatment plan was proposed to the patient:

- 1) extraction of tooth 27 with cyst removal;
- 2) bone regeneration of the area using a xenograft particulate bone substitute material (BEGO OSS, BEGO Implant Systems), covered with a resorbable collagen membrane (BEGO Collagen Membrane, BEGO Implant Systems);
- 3) replacement of teeth 25 and 26 using two implants (BEGO Semados RSX) and bone expansion;
- 4) seating of a full lithium disilicate ceramic crown (IPS e.max, Ivoclar Vivadent) on tooth 24 fabri-

cated with the CEREC system (Sirona Dental) in the clinic on the same day of the surgery;

- 5) seating of full lithium disilicate ceramic crowns (also IPS e.max) on the implants placed in regions 25 and 26 three months after the surgery.

After removal of the old fixed prosthesis, and before starting the surgery, tooth 24 was prepared (Fig. 4) and a digital image captured (Fig. 5). Thus, the lithium disilicate ceramic crown could be designed and fabricated with the CEREC system while the implant surgery was performed. Finally, the crown could be cemented at the end of surgery. In order to start the surgery, a full-thickness mucoperiosteal flap with a mesial vent for papilla preservation was raised (Figs. 6–8).

Threaded osteotomes were used after the initial drilling (Figs. 9–11), taking into account the transverse bone loss that existed in the area, as well as the emergence profile of the implant and the future prosthesis. This step had two aims: good 3-D location of the implant and bone condensation, which would improve the bone quality in the receiving area (Fig. 12).

For this clinical case, it was necessary to use an implant that could be easily and atraumatically inserted in order to prevent a greenstick fracture of the buccal cortical wall. Owing to their tapered body design and high self-tapping property, two BEGO Semados RSX implants were selected (Figs. 13–15). This implant was also selected because of

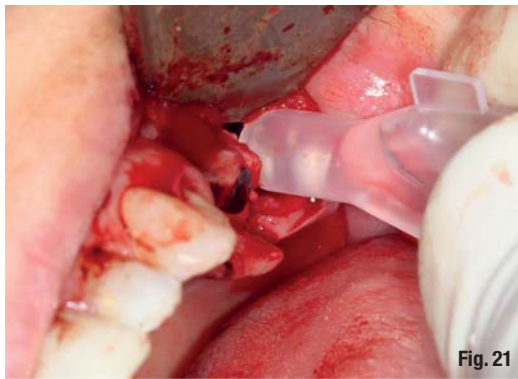


Fig. 21

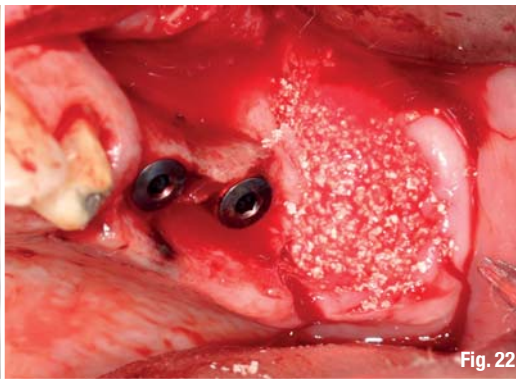


Fig. 22

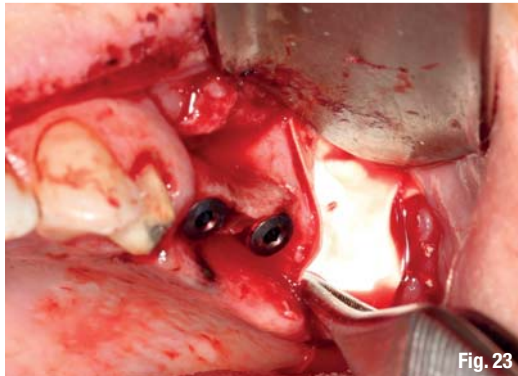

Fig. 23

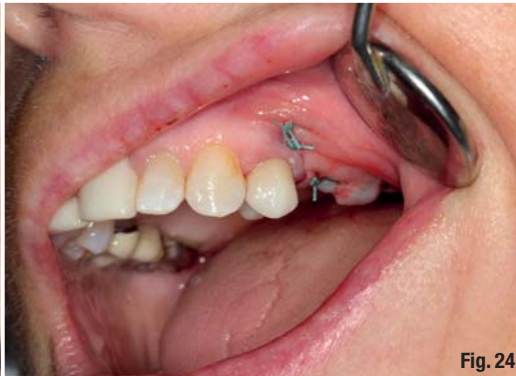

Fig. 24

Fig. 21_Alveolar cleaning with saline solution and antibiotic.

Fig. 22_Cavity filling with BEGO OSS.

Fig. 23_Graft area covered with a resorbable collagen membrane (BEGO Collagen Membrane).

Fig. 24_Sutured operated region and tooth 24 restored with a full lithium disilicate ceramic crown.

its shoulder design and type of connection, which can influence the long-term success of treatment with regard to the maintenance of bone and gingival tissue. With respect to the design, the implant presents a shoulder with bionic microgrooves for enlargement of the implant surface and reduction of stress peaks in crestal bone. The 45-degree internal connection has an anti-rotational hexagon and platform switching (Fig. 16).

In accordance with the clinical case planning, which anticipated a three-month osseointegration period after implantation, the implant connection areas were covered with cover screws (Fig. 17). The primary stability of the implants was measured by resonance frequency analysis (Osstell ISQ, Osstell). The values obtained were more than acceptable: implant stability quotient (ISQ) values of 71 and 68 (Figs. 18 & 19).

In the sequence, fractured tooth 27 was extracted and the surrounding granulation tissue was removed (Fig. 20), followed by our clinical protocol for cystic cavity treatment before immediate post-extraction implantation and/or bone regeneration. This entailed surgical alveolar cleaning with a saline solution and antibiotic (ciprofloxacin; Fig. 21) prior to filling of the cavity with a bovine bone substitute material (BEGO OSS; Fig. 22) hydrated with a saline solution and blood from the area. The graft area was then covered with a resorbable collagen membrane (BEGO Collagen Membrane; Fig. 23). Finally, the operated region

was sutured and tooth 24 was restored with a full lithium disilicate ceramic crown (Fig. 24).

Conclusion

As the presented case has demonstrated, an implant system with a short drilling sequence allows the surgeon to use a simple and ergonomic surgical tray, which facilitates the work of the surgeon and support staff. Using threaded osteotomes, the dentist can place implants in areas with a narrow transverse diameter without bone regeneration. Furthermore, he or she can improve bone quality in the receiving area and reduce the drilling sequence in cases of immediate post-extraction implantation.

contact

implants

Carlos Barrado

Médico Estomatólogo
Barcelona, Spain
info@clinicabarrado.com

Juan M. Ambros

Médico Estomatólogo
Barcelona, Spain
drambros@gmail.com

Manufacturer News

Bicon Dental Implants

Simple. Predictable. Profitable.

Since 1985, the Bicon Dental Implant System has offered dentists a proven solution for missing dentition.

The Bicon implant design comprises plateaus, sloping shoulders and a bacterially-sealed, 1.5° locking taper implant to abutment connection. With the plateau design, cortical like bone forms around and between each plateau. This Haversian bone allows for the routine use of 5.0 mm short implants.

The sloping shoulder provides the necessary room for bone to support interdental papillae that are gingivally aesthetic. Bicon's 360° of universal abutment positioning provides for the revolutionary cementless and screwless Integrated Abutment Crown™, which consistently provides for a non-metallic aesthetic gingival margin.



Bicon Dental Implants

Arborway 501
Boston, MA 02130, USA
www.bicon.com

Straumann

More than a partnership. A synergy of strengths.

It is estimated that as many as one in every two implant treatments requires bone augmentation. As a global leader in implant dentistry, Straumann has teamed up with botiss, a leading manufacturer of high-quality biomaterials for dental hard and soft tissue regeneration, to provide comprehensive solutions that address this need.

The partnership between the two companies means that their combined regenerative lines cover all indications and preferences for oral tissue regeneration products—an ideal complement to Straumann's dental implant and prosthetic systems. The company's CEO, Marco Gadola commented: "botiss will enable us to offer an unparalleled range of regenerative solutions to support implant and periodontal procedures. Their quality, effectiveness, handling characteristics and clinical track record will have great appeal to our customers—as will the possibil-



ity to obtain every component for a complete solution from one company."

At this year's EAO congress—taking place 25–27 September in Rome—Straumann will start to exclusively distribute the botiss products in most Central and Western European countries.

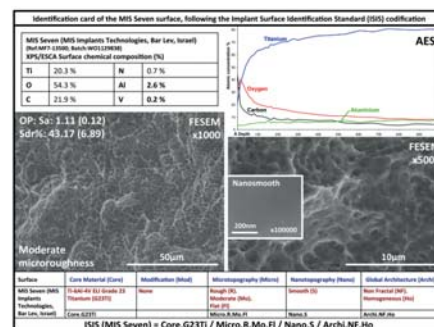
Institut Straumann AG

Peter Merian-Weg 12
4052 Basel, Switzerland
www.straumann.com

MIS

Implant surfaces with enhanced purity

Long-term clinical success of dental implants is dependent on a number of critical factors including implant design, bone quality and quantity, surgical techniques and clinician's skills. However, above and beyond implant materials and geometry, the topography and chemistry of the implant; surface treatment and surface quality is just as important in achieving high success rates.



Numerous studies suggest a predictable and more rapid osseointegration of implants using surface treatments in a combination of sand-blasting and acid-etching. Osteoblast proliferation and differentiation depends on the micro and nanostructures on the surface of the implant that closely mimic the natural bone matrix. MIS implant surfaces most closely mimics the natural cancellous (spongy) bone configuration and has enhanced surface purity when tested against other major implant brands using SEM technology.

Using surface characterization technology, MIS can guarantee that our implant surfaces uphold the highest standards of surface quality with a 99.8–100% pure Titanium-oxide surface, as well as the validation of full coverage by sand-blasting and acid-etching. These surface treatments help eliminate various surface contaminants while increasing the implant surface area, generating a hydrophilic surface with micro and nanostructures for optimum osseointegration.

MIS Implants Technologies GmbH

Simeonscarre 2
32423 Minden, Germany
www.mis-implants.com

ULTRADENT

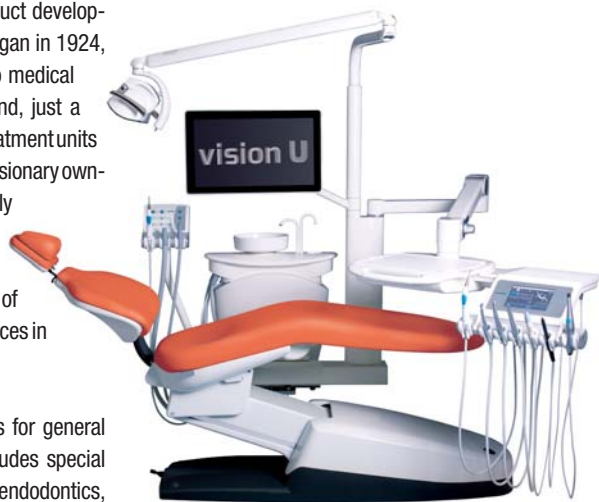
Innovations for dental practices for 90 years

ULTRADENT was founded 90 years ago in Munich. With a host of ideas and its own concepts, the dental manufacturer has set new standards and is considered to be exemplary in the area of dental equipment. Practical design and the use of innovative technologies remain key requirements for product development. The company's success story began in 1924, when Hans Ostner founded the electro medical equipment manufacturing company and, just a few years later, production of the first treatment units began. Thanks to successful products, visionary owners and committed employees, the family enterprise led by Ludwig Ostner and his son Ludwig-Johann developed into one of the most well-known suppliers of modern treatment units for dental practices in all areas of dentistry in the 21st century.

surgery and pediatric dentistry. Ergonomic treatment chairs, operating lamps, integrated small-scale equipment and a modernisation concept for dental practices round off the range of products.

With vision U, the company is presenting a revolutionary multimedia concept, which is a quantum leap in treatment unit equipment.

The wishes and requirements of dentists, orthodontists, surgeons and their patients form the basis of the day-to-day work. User-oriented design, low-maintenance components and strict quality management ensure lasting satisfaction among the company's customers and partners. The close partnership with specialised dental retailers guarantees comprehensive advice and knowledgeable, reliable service. All of this benefits the customers. The company is even able to fulfil individual and unusual requirements.



ULTRADENT Dental-Medizinische Geräte GmbH & Co. KG
 Eugen-Sänger-Ring 10
 85649 Brunnthal, Germany
www.ultradent.de

In addition to compact treatment units for general dentistry, the product programme includes special units for orthodontics, implantology, endodontics,

Nobel Biocare

Natural for guided bone and tissue regeneration



It is estimated that half of all dental implant cases require a regenerative procedure.¹ In order to ensure the best possible outcome for the patient, a dental professional therefore needs regenerative materials that can be relied upon. That is where creos xenoprotect, the natural barrier membrane, comes in.

Designed for use in guided bone regeneration (GBR) and guided tissue regeneration (GTR) procedures, the material offers good handling properties and creates a favourable environment for healing.

As any movement can disrupt the formation of new bone, the ability to place a graft accurately and securely is essential for effective healing. For this very reason, the biodegradable collagen membrane offers good strength without compromising its handling properties. With a lesser increase in size when hydrated compared with competitive products², the product takes the guesswork out of trimming the membrane. It can be cut to match the treatment area when dry with less risk that it will not fit the defect site when applied. Easily unfolded and not sticky when moistened, the barrier membrane can be repositioned without removing the graft material. It is designed to behave exactly as is desired, allowing the clinician to focus on ensuring the best possible standard of care for the patient.

Nobel Biocare Services AG
 P.O. Box, 8058 Zurich-Airport
 Switzerland
www.nobelbiocare.com

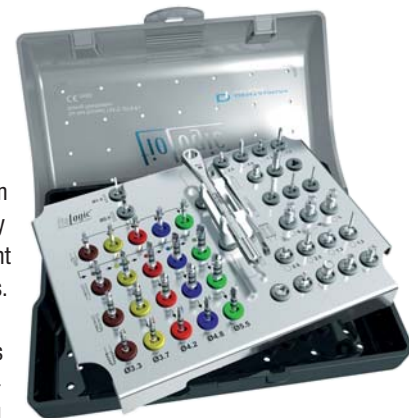Dentaurum Implants

Flexibility meets efficiency

The newly developed instrument set in the tioLogic[®] ADVANCED surgical tray offers maximum flexibility for the implant site preparation with fewer instruments.

The drilling protocol of the instruments allows an atraumatic preparation individually adapted to the bone quality and an individual regulation of the drilling depth for maximum primary stability. All preparation instruments in the surgical tray can be used for the insertion of tioLogic[®] and tioLogic[®] ST implants. For the tioLogic[®] ST implant, the macro and micro design of the implants has been further developed under biomechanical aspects.

The new modified self-tapping thread geometry combined with the reduced thread pitch allows a fast and atraumatic implant insertion with a constant insertion torque, as well as high primary stability. In addition, the 7.0 mm implant expands the range of indication for reduced vertical bone availability. The implant also follows the well-proven S-M-L concept of the implant system and is, thus, compatible with all existing prosthetic abutment lines of tioLogic[®] implants. They are perfectly aligned with the accredited product range.



Dentaurum Implants GmbH
 Turnstr. 31
 75228 Ispringen, Germany
www.dentaurum-implants.de

¹ Buser, D. 20 Years of Guided Bone Regeneration. Quintessence Publishing 2010, p. 15
² Data on file, Nobel Biocare

Honoured with the highest standards in implant dentistry

Interview by Dr Rolf Vollmer

At this year's annual meeting of the Academy of Osseointegration (AO) in Seattle, Prof. Dr Suheil Boutros received the AO fellowship credentials.



Prof. Dr Suheil Boutros (middle) receiving the Fellowship award with Stephen Wheeler, President of AO at that time (left) and Russel Nishimura, Vice President (right).

For more than ten years now, Dr Suheil Boutros is supporting the German DGZI as a keynote speaker, publishing many articles and being US representative of the association. Furthermore, he is an AAID Associate and Diplomate and successfully finalised the DGZI expert and specialist examination. The AO credentials are recognised by numerous state boards. They demonstrate the highest standards in implant dentistry. DGZI as well as the other organisations support the clinical and research in-

terests worldwide and by their credentials demonstrate the recognition for the achievements of their colleagues.

This year Prof. Dr Suheil Boutros will be a keynote speaker on the annual DGZI meeting in Düsseldorf from 26 to 27 September. On the meeting, he will refer about "Restoratively Driven Surgical Practice—from Single Tooth to Full Arch" and "Controlled Ridge Splitting (CRS) as an alternative technique to autogenous bone grafting".

implants international magazine of oral implantology talked to Prof. Dr Boutros about his latest award.

Doctor Boutros, which steps have you done in order to become a "Fellow" in the Academy of Osseointegration?

Dr Boutros: The first step in becoming a Fellow in the Academy of Osseointegration is to join the Academy as an Active member. Individuals may not enter the Academy as a Fellow. The following prerequisites are required of applicants:

First, the applicant must be a qualified DMD/DDS /PhD or equivalent, with a minimum of ten years actively involved in dentistry in either a clinical or research setting or working in an implant-related academic position for a minimum of three days per week (excluded is a post-graduate training/research).

Second, the applicant must be a member of the Academy of Osseointegration (AO) for five consecutive years.

Third, the applicant must have attended a minimum of three Academy of Osseointegration Annual Meetings within the last seven years. And finally, the applicant is required to provide supporting testimonials from two current Fellows of the Academy of Osseointegration.

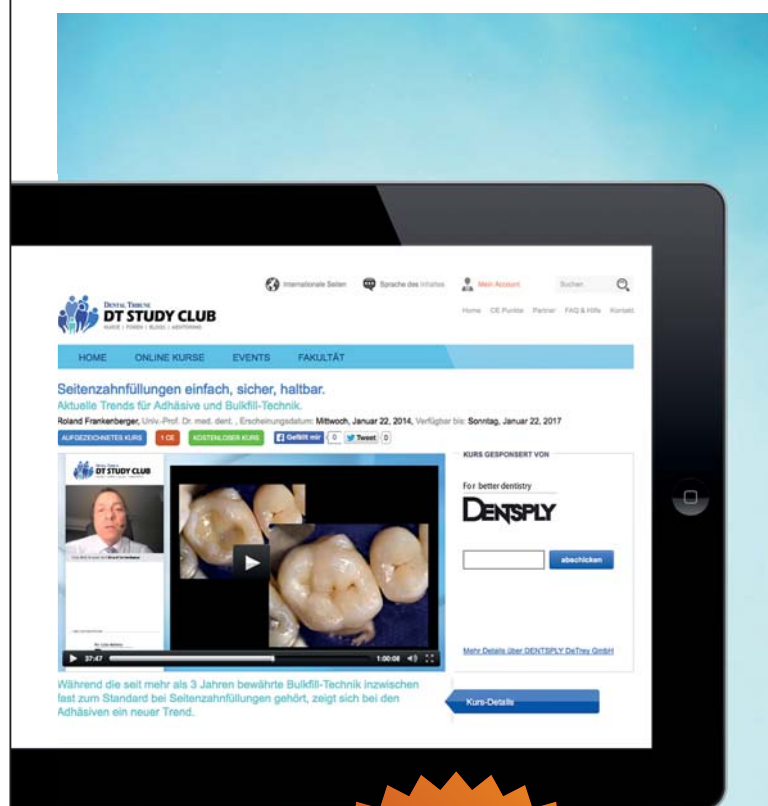
Thanks a lot for these information. We are looking forward to see you at the DGZI meeting in Düsseldorf and listen to your latest lectures with very interesting topics.

_curriculum vitae	implants
Education	
<ul style="list-style-type: none"> – University of Minnesota, School of Dentistry, Minneapolis, Minnesota. – Masters of Science, Certificate in Periodontics. – University of Detroit Mercy, School of Dentistry, Detroit, Michigan. – Doctor of Dental Surgery (DDS) Degree. 	
Experience	
<ul style="list-style-type: none"> – Since November 1997: Private practice, Grand Blanc, Clarkston & Dearborn Heights, Michigan. The practices focus on dental implants, regenerative treatment, periodontal plastic surgery and conscious sedation. – March 1996 to October 1997: Private practice, Minneapolis, Minnesota. Multi-location practice limited to periodontology and dental implantology. 	
Teaching experience	
<ul style="list-style-type: none"> – Since 2009: German Board (GBO) examiner. – Since September 2002: Dean's Faculty: Visiting Assistant Professor, Department of Periodontics, University of Michigan, School of Dentistry, Ann Arbor, Michigan. – January 1998 to July 2000: Assistant Professor, Department of Periodontics, and Surgical Consultant, Implant Centre, University of Detroit Mercy, School of Dentistry, Detroit, Michigan. 	
Honours	
<ul style="list-style-type: none"> – 2014: Fellow of the Academy of Osseointegration, Fellow of the International College of Dentists, Fellow of the American College of Dentists. – February 2012: Advisory Board Member and Consultant, Zimmer Dental, Carlsbad, California. – Editorial Board Member of implants, the official implant journal of the German Association of Dental Implantology (DGZI). 	

_contact	implants
<p>Suheil Michael Boutros, DDS, MS 8185 Holly Road, Suite 19 Grand Blanc, Michigan 48439, USA</p> <p>Tel.: +1 810 695-6444</p> <p>smboutros@periodonticsonline.com www.PeriodonticsOnline.com</p>	

Join the largest educational network in dentistry!

www.DTStudyClub.com



Register for
FREE!

Düsseldorf— Beauty on the Rhine

Author: Katrin Maiterth

[PICTURE: ©TELESNIUK]

“Düsseldorf mäkt sech fein” (Düsseldorf adorns itself)—this phrase does not only apply for the fifth season—carnival season—which is intensively celebrated in the Rhine metropolis. No matter if it is spring, summer, autumn or winter: With its fine range of arts and culture, noble restaurants and traditional pubs, first-class architecture as well as wide streets and places, the city is always worth a visit. On the 26 to 27 September, the metropolis at the Rhine is hosting the 44th International Annual Congress of the DGZI.

The medieval Düsseldorf was first mentioned in the 12th century. What is for sure is that Düsseldorf received municipal rights in 1288. With the establishment of fixed market days, trading started in the Rhine city and thus the cultural as well as economic wealth. After the building of Carlstadt in the beginning of the 18th century, the Carlplatz became the location for the one-week market which was carried out four times a year. Today, the marketplace is still in use six days a week throughout the year and offers fruits, vegetables, eggs, meat, poultry, fish and baked goods as well as the traditional potato fritter with applesauce.

Next to Carlstadt is the Old Town—with over 260 pubs also known as “the longest bar in the world”. Here, everyone finds a suitable locality: house brewery, lounge, cocktail bar, electro club or fine restaurant. However, there is no getting around the traditional Düsseldorf dark beer. Everyone who wants to learn more about the high art of brewing is welcomed to set out on the brewery path. Even elector Jan Wellem (1658–1716), whose bronze equestrian statue stands on the marketplace in front of the town hall, tippled with the Düsseldorf citizens in the house “En de Canon”. Today, the

restaurant invites to its delicious good plain German cooking, like Königsberg meatballs, Düsseldorf mustard roast or “Canon fooder” as medallions of pork is referred to.

Along the Old Town’s front line, the Rhine promenade reaches over 1.5 km, from the Oberkasseler bridge to the state parliament. The promenade was built between 1990 and 1997. What had been a busy street with much traffic for decades is a vivid boulevard today. Especially in the summer, the Mediterranean-like lifestyle of the people finds its expression here. From one of the countless cafés and bars bordering the promenade one can watch the passing by Rhine ships without ruffle. These do not only transport commercial goods, but also offer space for sightseeing, events and recreation.

Another good place to stroll around is the “Kö” as Düsseldorf’s citizens name their Königsallee lovingly. The world-famous luxury street is a catwalk and resting place at the same time—true to the motto “seeing and being seen”. Boutiques, jewellers, shopping malls and stores invite to watch, try and buy; there is also the possibility to hire a personal consultant for the perfect shopping trip. Rest can be found in one of the luxury street’s cafés. A specific characteristic is the Kö’s water moat, which separates one side of the alley from the other. Artfully designed bridges with richly ornamented fountains and sculptures built a connection between the two sides and simultaneously give the luxury mile a romantic flair.

At any time of the year, the Düsseldorf citizens know how to adorn themselves and their city—whether in the Kö, the Old City or along the Rhine. Convince yourself!_

German Association of Dental Implantology

(Deutsche Gesellschaft für zahnärztliche Implantologie e.V., DGZI)

Founded in 1970



Please send your membership application to:

Central Office &
Secretary of the Board

DGZI e.V.

Paulusstr. 1
40237 Düsseldorf

DGZI e.V.
Paulusstr. 1
40237 Düsseldorf
Germany

Phone: +49 211 16970-77
FAX: +49 211 16970-66

GERMANY

office@dgzi-info.de
www.dgzi.de

MEMBERSHIP APPLICATION FORM

Please complete this application form in block letters.

PERSONAL DATA

NAME	FIRST NAME
TITLE	CITIZENSHIP
DATE OF BIRTH	
STREET	CITY, ZIP CODE
COUNTRY	
PHONE, COUNTRY AND AREA CODE	FAX
E-MAIL	Homepage
SPECIAL QUALIFICATION	
SPOKEN LANGUAGES	

Do you have experience in implantology?

Yes No

MEMBERSHIP FEE

I wish to apply for membership of the DGZI.

- Full membership (outside Germany) – 125 Euro p.a.
- Students/auxiliaries (outside Germany) – 60 Euro p.a.
- I have transferred the annual fee to the DGZI bank account c/o Dr Rolf Vollmer:
IBAN: DE33 5735 1030 0050 0304 36 | KSK Altenkirchen |
SWIFT/BIC: MALADE51AKI

AGREEMENTS

I hereby agree to have my personal data processed and published for all purposes of the DGZI.

SIGNATURE

PLACE, DATE

PAYMENT

By credit card:

Please use your: (Please mark as appropriate)

Visa MasterCard

Card holder's name _____

Card number | | | | | | | | | | | | | | | | | | | | | |

Expiry date ____ / ____

5th International CAMLOG Congress in Valencia




Fig. 1

Figs. 1 & 2 Against the impressive scenery of Ciudad des las Artes with its utopic-like architecture of Palau de les Arts (Fig. 1, on the right of the background), the congress delegates used the breaks for further in-depth discussions amongst colleagues.

Fig. 3 Numerous delegates took the opportunity of attending the practical or theoretical pre-congress workshops.

_This year's 5th International CAMLOG Congress was held in Valencia from June 26-28 with the motto "The Ever Evolving World of Implant Dentistry". The Ciudad de las Artes y de las Ciencias, a unique city of the Arts and Sciences, offered the perfect scenario for the congress. Over 1,300 delegates from all over the world and 66 internationally renowned speakers and moderators had travelled to this exceptional event in the architectural highlight Palau de les Arts. In the presentations and the practical and theoretical workshops specialised topics and studies were discussed, practice-relevant new trends were presented and current practical examples demonstrated.

_The scientific programme

With the International Congresses, the CAMLOG Foundation offers a unique forum for further education and discussion for oral implantologists, surgeons, dental technicians, dental professional staff, students, industry and the media. The congresses have always aspired to spark off visionary trends in implant dentistry. Against this background, Congress Presidents Prof. Dr Fernando Guerra and Prof. Dr Mariano Sanz, together with the CAMLOG Foundation President Prof. Dr Jürgen Becker, invited to an exchange of ideas among scientists, practitioners and companies. The high-level and diverse program offered a total of 28 scientific presentations over five sessions. The expert audience praised the evidence-based results and the remarkably practical approach. Common to all presentations was the persistent desire to give patients the best treatment.

The highlight of both congress days was the panel discussion on "Complications—what can we learn from them?". Four experts presented complications



Fig. 2

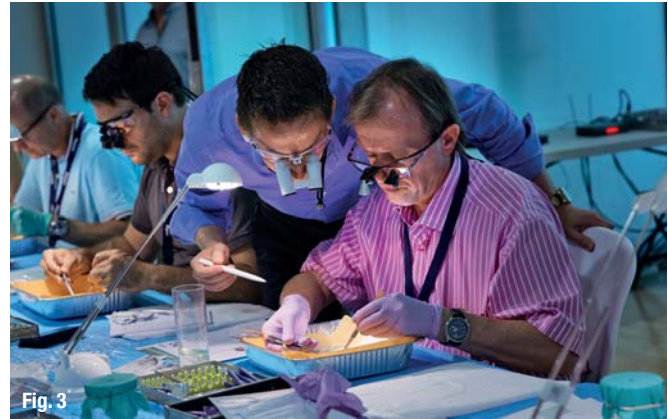

Fig. 3

of implant treatment and restorations which had occurred in practice in the sixth session. Congress delegates were asked to join the panel to discuss solutions and possible approaches. The audience was involved by the moderators Prof. Dr Mariano Sanz and Prof. Dr Fernando Guerra to vote on the treatment options, while the experts presented their solutions to round off the session.

Numerous delegates also took the opportunity of attending the practical or theoretical pre-congress workshops, when renowned speakers explained scientifically proven surgical and prosthetic techniques and treatment concepts. The workshops provided



Fig. 4



Fig. 5



Fig. 6

excellent opportunities for a fruitful exchange between dental professionals and industry partners. The insights gained then lead to further in-depth discussions amongst colleagues on the following two days of the congress.

The poster competition

On occasion of the 5th International Congress, scientists, dentists and dental technicians submitted their research or case studies for the poster competition. The company's committee accepted 37 posters from Austria, Germany, India, Italy, Spain, Portugal and Turkey. The scientific level for the posters equaled those of the presentations and the submission criteria were high. Awards for the best posters came to a worthy conclusion during the award ceremony on the podium.

The team Salomão Rocha, Wilfried Wagner, Jörg Wiltfang, Fernando Guerra, Maximilian Moergel, Eleonore Behrens, and Pedro Nicolau were delighted to receive the first prize with their topic "Platform switching versus platform matching: Two-year results from a prospective randomised-controlled multicenter study" which convinced the committee and the congress participants. After the award ceremony, the award winners presented the study. The group received 2,000 euro as prize money.

The second prize in the amount of 1,500 euro went to the team Monika Puzio, Artur Blaszczynszyn, and Marzena Dominiak. The topic of their study was: "Comparative ultrasound assessment of keratinized gingiva thickness around implants after the augmentation treatment in esthetic zone—preliminary results". The prize money of 1,000 euro went to the team in third place, Burçin Vanlioglu, Yasar Özkan,

and Yasemin Kulak Özkan. They presented results on the "Clinical and radiographic outcome of Camlog implants in partially edentulous cases after an observation period of 10 years".

Una gran fiesta en familia

The legendary CAMLOG party was fully booked. The drive to a Spanish hacienda was already dominated by an incredible atmosphere of anticipation and expectations. Each participant had received a "Spanish passport" which entitled to admission. The Hacienda Masiá Xamandreu is a sprawling, meandering event location embedded in typical country-style gardens. An authentic reception with Mediterranean hospitality started the family festival "Una gran fiesta en familia" with excellent Spanish delicacies, traditional arts and infectious Spanish music. The evening reaches its climax in the party zone with dancing music and the performance of a lady soul singer.

The impressions gained and the many discussions during the two days of the congress were a convincing display of how the International CAMLOG Congress will help shape the future of implant dentistry and the ever important role of networking.

Fig. 4 Highly concentrated, the delegates followed the scientific-based lectures at the CAMLOG Congress.

Fig. 5 Jürg Eichenberger (President of the Administrative Board of CAMLOG Holding AG) and Peter Braun (CEO CAMLOG).

Fig. 6 The Congress Presidents Prof. Dr. Mariano Sanz and Prof. Dr. Fernando Guerra.

contact

implants

CAMLOG Foundation
Margarethenstrasse 38
4053 Basel, Switzerland

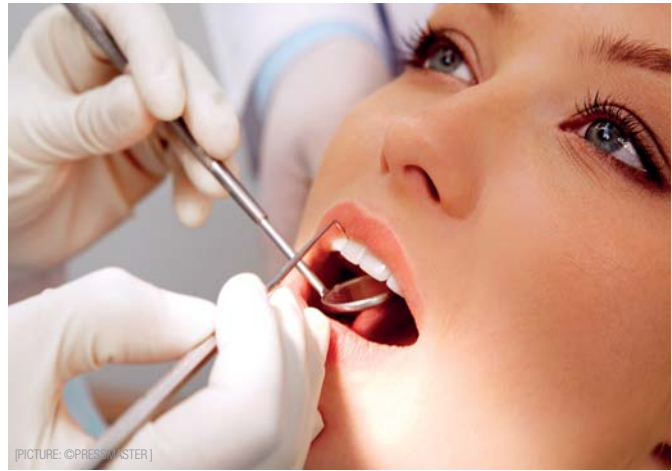Tel +41 6156541-00
www.camlogfoundation.org

Periodontal therapy may

Save patients over US \$ 5,000 per year

A number of studies have linked periodontitis to systemic diseases, such as diabetes, and complications in pregnancy. Now, new research has provided additional evidence that receiving treatment for periodontal disease may result in reduced health care costs and fewer hospitalisations for pregnant patients and individuals with certain chronic conditions.

In the study, researchers at the University of Pennsylvania reviewed insurance claims data of almost 340,000 individuals who had been diagnosed with periodontitis and were either pregnant or had one of the following conditions: Type 2 diabetes, coronary artery disease, cerebrovascular disease and rheumatoid arthritis. They found that treating periodontal disease was associated with statistically significant decreases in annual medical costs of 40.2 per cent (US\$2,840) for diabetes patients, 40.9 per cent (US\$5,681) for patients with cerebrovascular disease, 10.7 per cent (US\$1,090) for patients with coronary artery disease, and 73.7 per cent (US\$2,433) for pregnant patients. In addition, a significant decrease in hospital admissions was observed in some of the groups. "These cost-based results provide new, independ-

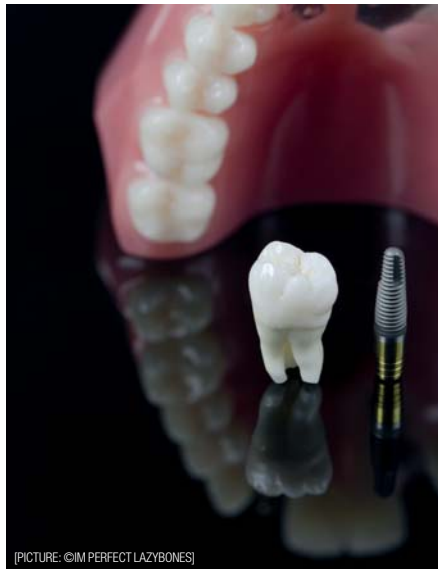

[PICTURE: ©PRESSMASTER]

ent, and potentially valuable evidence that simple, non-invasive periodontal therapy may improve health outcomes in pregnancy and other systemic conditions," the researchers concluded. The study, titled "Impact of Periodontal Therapy on General Health: Evidence from Insurance Data for Five Systemic Conditions," was published in the August issue of the *American Journal of Preventive Medicine*.

Cochrane reports no evidence for

Superior long-term success of dental implants



[PICTURE: ©IM PERFECT LAZYBONES]

Promising superior clinical outcomes, plenty of new dental implants are launched to markets each year. A report by researchers from the Cochrane Oral Health Group in Melbourne and Manchester has recently suggested that there may be no differences in terms of long-term success, regardless of the shape of the implant or the material used.

The researchers reviewed randomised clinic trials conducted around the world from the group's own database. From this, the only statistically significant difference observed was in relation to surface preparations, with smoother (turned) surfaces being found to be less prone to bone loss associated with periimplantitis than were rougher surfaces.

Similar results were reported by the group in a series of earlier reviews, of which the first was published in 2002. In the most recent update, two of the review authors independently compared 38 different implant types, which had been placed in 27 trials involving more than 1,500 patients, ranging from the early 1980s to early 2014.

According to Cochrane, there are more than 1,300 different dental implants available on the market today. The total value of fixed tooth replacements was estimated to be US\$3.4 billion in 2011, a figure that some analysts expect to almost double in the next five years owing to the increasing demand of an ageing population and more dentists starting to place dental implants.

Straumann acquires

12 per cent of RODO Medical

Global dental implant manufacturer Straumann has announced that it has purchased about 12 per cent of RODO Medical's shares for an undisclosed sum. The U.S. company has developed a novel system that simplifies the implant restoration process significantly. RODO Medical's Smileloc System is a retention mechanism utilizing shape memory properties



of nitinol, a nickel-titanium alloy, which has been used in stents and other medical devices, including orthodontic archwires and endodontic files, for many years. It allows for easy fixation of crowns or dentures to implant abutments without the need for retaining screws or cement, the two main methods for securing restorations, the latter of which has been associated with complications. "Smileloc is an innovative concept," said Straumann's CEO Marco Gadola. "The first clinical results are promising and I agree with the developers that, when it becomes commercially available, it might substitute some of the current fixture technology."

Right in time for its anniversary

OT medical presents image film




Audio visual communication of companies gain greater importance more and more since motion pictures do trigger emotions and transmit compact information on short ways. The Bremer implant manufacturer OT medical is using the communication device image film to present the company in its anniversary year by means of a modern film.

Since five years now, the motto of the Bremen OT medical GmbH is „Innovative precision made in Germany“. Constant research and development, quality control

without compromises and modern manufacturing processes do convince practitioners worldwide. Thereby, attributes as customer-orientation, friendliness, good availability and short delivery times are as a matter of course to the implant manufacturer. Founded in 2008, OT medical has established itself as a successful newcomer in dental implantology and thus the company present itself with a new, pleasant image film.

Oftentimes, films do say more than thousand words and are more personal and authentic than a brochure. However, what is needed to create a successful image film is a good idea. With the screenplay for its current image film, the company had the right idea. To capture as much authenticity as possible, the film shooting was done during the ongoing daily business and thus connects the company's philosophy with professionalism and close customer proximity in a sympathetic manner. After two exhausting but great shooting days, all scenes are ready and the result is worth seeing. . .



Nobel Biocare sues Neodent USA for Patent infringement

In a press release, Nobel Biocare stated: "In March 2014, Neodent USA launched its line of Drive CM dental implants in the US. In its complaint, Nobel Biocare alleges that these implants, imported from Brazil, have striking similarities to the design of the NobelActive implants which Nobel Biocare commercially launched in 2008. Further, Nobel Biocare asserts that Neodent USA has relied on Nobel Biocare's history of successful clinical data in marketing the Neodent product."



According to the Swiss-based company, both US patents asserted in the lawsuit relate to technology for aiding the surgical installation and successful integration of the implants in a variety of patient bone types. Nobel Biocare has asked the court for an injunction barring sales of Neodent's infringing dental implants, payment of money damages due to Nobel Biocare's lost sales, and recovery of its attorney fees for the lawsuit.

In response to the allegations, Neodent USA said that it intends to defend itself vigorously against Nobel's allegations of patent infringement relating to one of its implant ranges. The company stated that, prior to launching Drive CM, Neodent obtained in-depth evaluations to ensure that its designs respected all valid intellectual property rights.

"The preliminary design of NobelActive was invented and developed by an Israeli team at AlphaBioTec Ltd—not originally by Nobel Biocare, as many people believe. We did our homework before launching our range of implants in the US, especially the Drive CM, and we are confident that we have not infringed any patents," said Tony Susino, CEO of Neodent USA.

Indian teenager has

Over 200 teeth extracted



According to the Indo-Asian News Service (IANS), a private Indian news agency, Ashik Gavai, a Grade 10 pupil, was admitted to the hospital on 10 July complaining of pain and with an immense red swelling on the right side of his face.

After a series of tests and examinations, the doctors suggested that a complex composite odontoma, a benign odontogenic tumour, was causing the symptoms. During the subsequent 7-hour surgery, they found that the abnormal growth measured about 3.5 x 2 cm. The surgeons removed 232 teeth, with even more developing, from the tumour. As the numerous small teeth were difficult to count, the doctors believe that in total there may have been more than 350 teeth.

The doctors said that the boy had first noticed the swelling about a year and a half ago. However, high costs prevented him from seeking medical care and the tumour had grown unabated.

IANS reported that the boy's medical expenses were covered by Rajiv Gandhi Jeevandayee Arogya Yojana, a health scheme that ensures free care for low-income families, which was introduced by the Maharashtra government last year. Odontomas are usually asymptomatic and are often discovered during routine dental X-rays. Several factors, including local trauma, infection, family history and genetic mutation, may cause anomalous tissue development in odontomas.

implants
international magazine of oral implantology



Publisher

Torsten R. Oemus
oemus@oemus-media.de

CEO

Ingolf Döbbecke
doebbecke@oemus-media.de

Members of the Board

Jürgen Isbaner
isbaner@oemus-media.de

Lutz V. Hiller

hiller@oemus-media.de

Chief Editorial Manager

Dr Torsten Hartmann (V. i. S. d. P.)
hartmann@dentalnet.de

Editorial Council

Dr Roland Hille
dr-hille@t-online.de

Prof. Dr Kurt Vinzenz

kurt.vinzenz@aon.at

Dr Torsten Hartmann

hartmann@dentalnet.de

Dr Suheil Boutros

SMBoutros@aol.com

Editorial Office

Georg Isbaner
g.isbaner@oemus-media.de

Katrin Maiterth

k.maiterth@oemus-media.de

Claudia Jahn

c.jahn@oemus-media.de

Executive Producer

Gernot Meyer
meyer@oemus-media.de

Designer

Sarah Fuhrmann
s.fuhrmann@oemus-media.de

Customer Service

Marius Mezger
m.mezger@oemus-media.de

Published by

OEMUS MEDIA AG
Holbeinstraße 29
04229 Leipzig, Germany
Tel.: +49 341 48474-0
Fax: +49 341 48474-290
kontakt@oemus-media.de

Printed by

Silber Druck oHG
Am Waldstrauch 1
34266 Niestetal, Germany

implants

international magazine of oral implantology
is published in cooperation with the German
Association of Dental Implantology (DGZI).

DGZI

DGZI Central Office
Paulusstraße 1, 40237 Düsseldorf, Germany
Tel.: +49 211 16970-77
Fax: +49 211 16970-66
office@dgzi-info.de

www.dgzi.de
www.oemus.com
www.implants.de

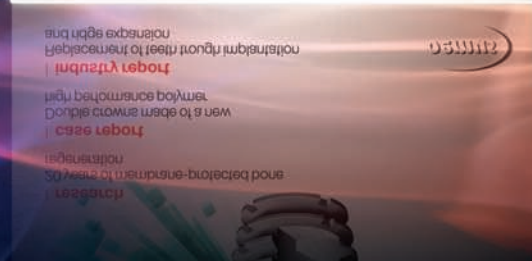
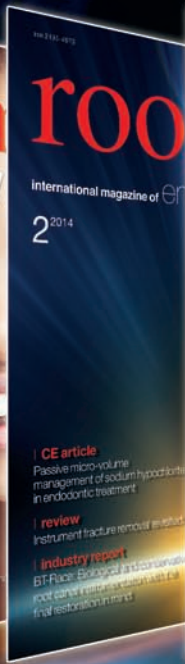
Copyright Regulations

implants international magazine of oral implantology is published by Oemus Media AG and will appear in 2014 with one issue every quarter. The magazine and all articles and illustrations therein are protected by copyright. Any utilization without the prior consent of editor and publisher is inadmissible and liable to prosecution. This applies in particular to duplicate copies, translations, microfilms, and storage and processing in electronic systems.

Reproductions, including extracts, may only be made with the permission of the publisher. Given no statement to the contrary, any submissions to the editorial department are understood to be in agreement with a full or partial publishing of said submission. The editorial department reserves the right to check all submitted articles for formal errors and factual authority, and to make amendments if necessary. No responsibility shall be taken for unsolicited books and manuscripts. Articles bearing symbols other than that of the editorial department, or which are distinguished by the name of the author, represent the opinion of the afore-mentioned, and do not have to comply with the views of Oemus Media AG. Responsibility for such articles shall be borne by the author. Responsibility for advertisements and other specially labeled items shall not be borne by the editorial department. Likewise, no responsibility shall be assumed for information published about associations, companies and commercial markets. All cases of consequential liability arising from inaccurate or faulty representation are excluded. General terms and conditions apply, legal venue is Leipzig, Germany.

implants

international magazine of oral implantology



Subscribe now!

I would like to subscribe to **implants international magazine of oral implantology** (4 issues per year) for €44 including shipping and VAT for German customers, €46 including shipping and VAT for customers outside Germany, unless a written cancellation is sent within 14 days of the receipt of the trial subscription. The subscription will be renewed automatically every year until a written cancellation is sent to OEMUS MEDIA AG, Holbeinstr. 29, 04229 Leipzig, Germany, six weeks prior to the renewal date.

▶ Reply via Fax +49 341 48474-290 to OEMUS MEDIA AG or per E-mail to grasse@oemus-media.de

You can also subscribe via www.oemus.com/abo

Last Name, First Name

Company

Street

ZIP/City/County

E-mail

Signature

Notice of revocation: I am able to revoke the subscription within 14 days after my order by sending a written cancellation to OEMUS MEDIA AG, Holbeinstr. 29, 04229 Leipzig, Germany.

Signature





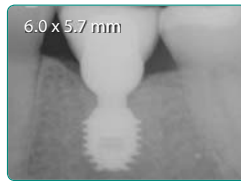
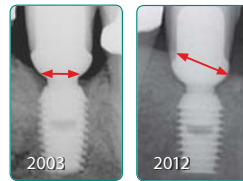

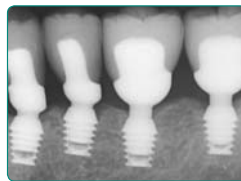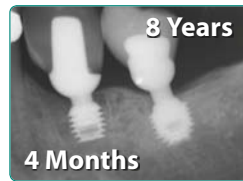

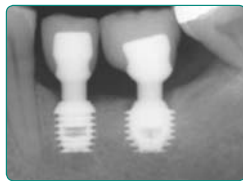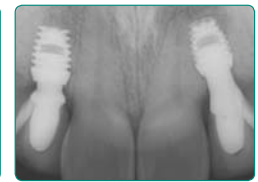
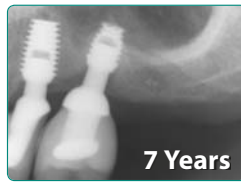
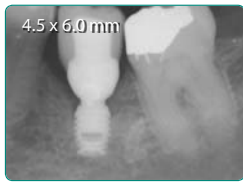
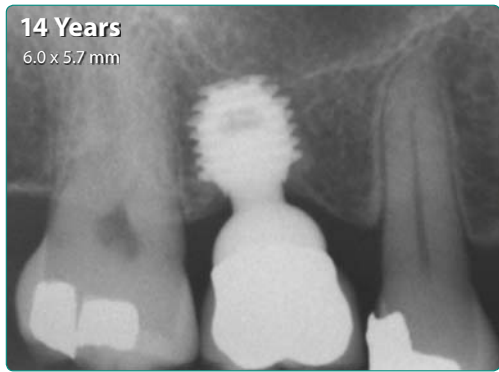
bicon®

DENTAL IMPLANTS

Since 1985 » Simple. Predictable. Profitable.



SHORT™ IMPLANTS



OSSTEM[®]
IMPLANT

**This is
the First**

TS III CA

SUPER HYDROPHILIC SURFACE



Tel: +98 21 88 98 80 63 - 6
www.azadmed.com

Fax: +98 21 88 98 75 72
www.osstem.ir