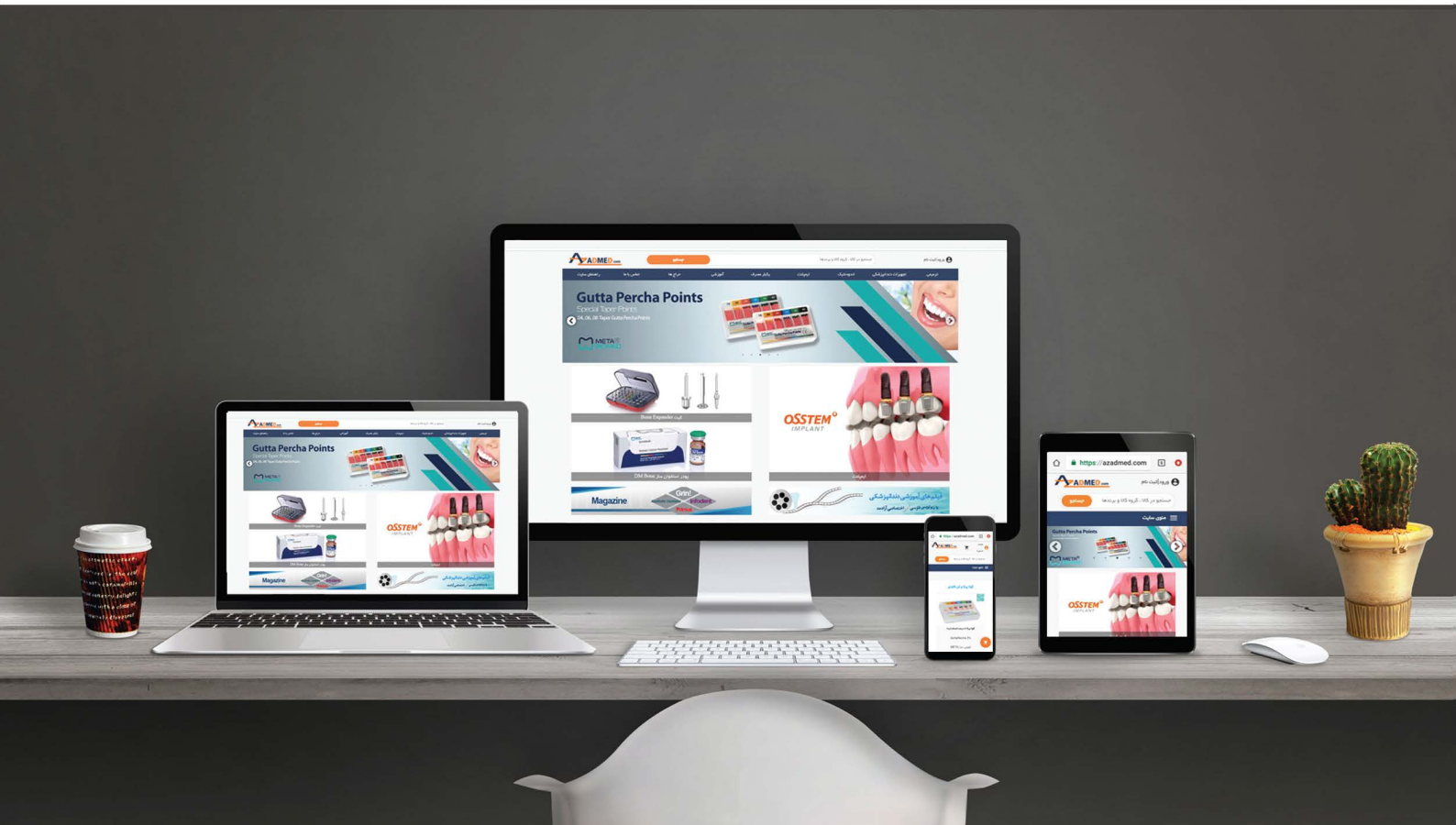




آزاد تجارت پارس  
AZAD TEJARAT PARS.LTD

**AZADMED.com**



[www.azadmed.com](http://www.azadmed.com)



 azaadtejaratpars

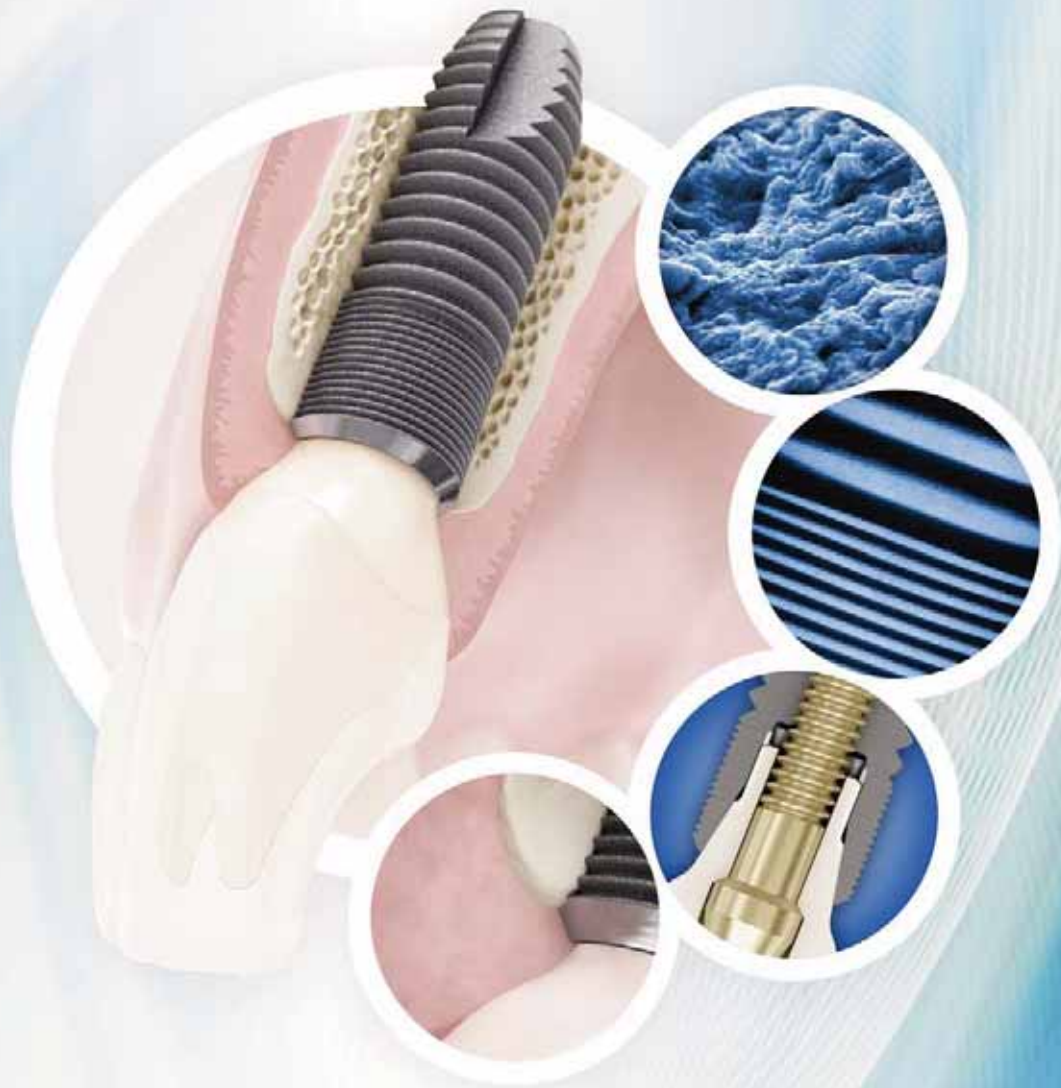 @azadmed2

 88 98 80 63 - 6

# implants

international magazine of oral implantology

4<sup>2014</sup>



| **research**

Clinical and radiological performance of short implants

| **case report**

Permanent implant prostheses

| **overview**

Improvements in digital implant prosthetics

NEW

**ASTRA TECH  
IMPLANT SYSTEM**



# Simplicity

## without compromise

The design philosophy of the ASTRA TECH Implant System EV is based on the natural dentition utilizing a site-specific, crown-down approach supported by an intuitive surgical protocol and a simple prosthetic workflow.

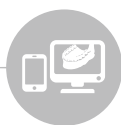- **Unique interface with one-position-only placement for ATLANTIS patient-specific abutments**
- **Self-guiding impression components**
- **Versatile implant designs**
- **Flexible drilling protocol**

The foundation of this evolutionary step remains the unique ASTRA TECH Implant System BioManagement Complex.

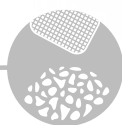
For more information visit  
[www.jointheev.com](http://www.jointheev.com)



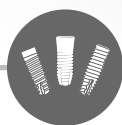STEPPS™



SIMPLANT™



SYMBIOS™



ANKYLOS™



ATLANTIS™

**ASTRA TECH  
IMPLANT SYSTEM**

XiVE™

[www.dentsplyimplants.com](http://www.dentsplyimplants.com)

**DENTSPLY  
IMPLANTS**



Prof. Dr Herbert Deppe

# Dear colleagues,

\_On this years' 44<sup>th</sup> congress of the DGZI in Düsseldorf, I was elected president of the society by the members' assembly after being assessor of the executive committee for three years. In my role as the president-elect, I want to move forward the intensification of the contacts with other specialised fields as periodontology or colleagues from prosthetics and biomechanics. Thereby, I would like to extend the already existing personal contacts as well as those of the DGZI and also initiate joint congresses with other specialised fields as the German Association for Periodontology. Furthermore, it is my heartfelt concern to intensify the collaboration between oral maxillofacial surgeons and the dental profession.

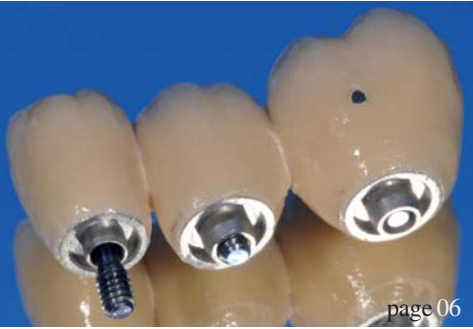
Traditionally, the DGZI has also a lot of international contacts, especially to colleagues in Japan and Switzerland. We are also strongly connected with the Arabian area, although keeping contact here is not easy in view of the continuing political tensions. This is another issue, which I would wish to address intensively within the executive committee. In general, there is no need to reinvent the DGZI. We should tackle things in all modesty. Thereby, we want to remain faithful to our values which are on the one hand letting established practitioners feel at home in the DGZI and on the other hand stick to the clear scientific demand of our society.

In the upcoming year, we as the German Association of Dental Implantology (DGZI) are faced with a lot of challenges. From my point of view, one of the biggest challenges is the strengthening of the implantological societies, which should occur in a cooperative way. The difficulty of establishing this cooperative thought becomes clear when thinking of the joint event of the big implantological societies in Munich planned in the year before which unfortunately failed to come about. In the area of science, development has to focus on materials research on the one hand—especially in the area of high-performance ceramics—but also on the bioligisation of implants on the other hand.

Finally, a personal remark should be allowed: We have to remind ourselves day-to-day that we have one of the greatest professions. Here, modesty is called for. This also includes the insight that one or another step is better made by someone else and thus react accordingly. With this in mind, I would go along with the executive committee: Keep your feet on the ground—and keep reaching for the stars!

Yours sincerely  
Prof. Dr Herbert Deppe

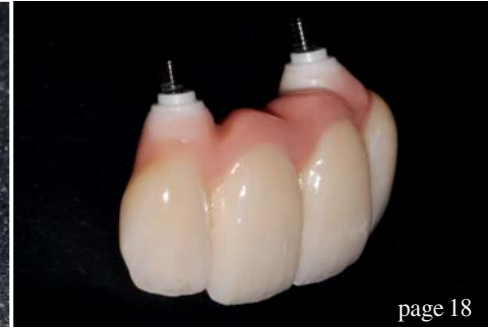



page 06



page 14



page 18

| editorial

03 Dear colleagues  
| Prof. Dr Herbert Deppe

| research

06 Clinical and radiological performance of short implants  
| Dr Jean-Nicolas Hasson *et al.*

| case report

14 Permanent implant prostheses  
| Dr Arzu Tuna *et al.*

| overview

18 Improvements in digital implant prosthetics  
| Dr Joannis Katsoulis

| economy

26 Dental implant competitors shake things up  
| Kristina Vidug

28 Cost-benefit and affordability of dental implant restorations  
| Prof. Hugo de Bruyn

| interview

32 Dentistry from the heart: Dr Suheil Michael Boutros

34 "Taking the advantages of digital dentistry to a new level"  
| 3Shape

| opinion

36 Is continuing education of implant dentistry sending the wrong message?  
| Dr Sebastian Saba *et al.*

| meetings

38 Simplifying dental implant treatment  
| EAO

40 On the test bench: Concepts for implantology  
| Dr Georg Bach

44 „Hold the profile of the DGZI and intensify contacts to other scientific societies”  
| Markus Brakel

46 bone & tissue days 2014  
| Georg Isbaner

47 Dentium World Symposium  
| Georg Isbaner

| news

22 Manufacturer News

48 News

| about the publisher

50 | imprint



Cover image courtesy of DENTSPLY implants,  
[www.dentsplyimplants.de](http://www.dentsplyimplants.de)  
Original Background: © Toria  
Artwork by Sarah Fuhrmann, OEMUS MEDIA AG.



page 38



page 40



page 47



# More than an implant. A sense of trust.

The Straumann® Dental Implant System is a worldwide leading solution for general practitioners and specialists. Our commitment to research ensures high quality backed by independent science. Producing innovations that improve patient care has made us a trusted business partner in over 70 countries.

[www.straumann.com](http://www.straumann.com)

**60** YEARS

  
simply doing more



# Clinical and radiological performance of short implants

## A clinical study with two years follow up

**Authors** Dr Jean-Nicolas Hassen, Dr Jacques Hassid, Dr Dominique Aubazac, France & Paul Zeman PhD, Switzerland

[PICTURE: ©ALICE-PHOTO]

**The aim of this study** was to assess the clinical and radiological performance of short (6.5 mm) implants inserted in the premolar and molar regions of the maxillae. Eligible patients had to have a residual bone height of at least 6.5 mm and a bone width of at least 6.0 mm. Restoration was performed as single crowns or fixed large-span bridges and followed for up to two years after insertion.

### Background

The reconstruction of missing teeth in posterior regions is hampered by the limited bone availability and insufficient bone quality typically found in the posterior regions due to post-extraction bone atrophy both apico-occlusally and bucco-palatally, a pneumatized sinus, etc. Significant functional forces in the posterior segments of the maxillae, among other factors, increase the risk of implant failure.<sup>1</sup> Similar anatomical limitations are mentioned in the recent review by Estafanous et al.<sup>2</sup>

#### Bone quality

Restoration with implants in posterior regions is more complex if, for example, permanent teeth were lost at young age, bone quality is poor (D3 and D4 according to Misch's classification), or enhanced bone resorption due to mucous stimuli is present, and implant placement is complicated by the presence of anatomic structures such as the sinus cavity or inferior alveolar nerve.<sup>3</sup> Particularly in the maxillae, the use of short implants (i.e. the endosseous part is < 7 mm long) is advantageous to avoid sinus floor augmentation (sinus lift).

Several bone augmentation techniques have been developed with the goal of increasing the bone volume before implant placement, thereby allowing the use of longer and wider-diameter implants. The surgical problems and potential failures of such techniques have been clinically extensively documented.<sup>4</sup> The placement of shorter implants has the potential to avoid the need for such techniques. This would be beneficial for patients both in terms of reduced morbidity and financially.

#### Survival rates

Although early papers on short implants reported higher implant loss rates,<sup>5-8</sup> recent systematic literature reviews have found that initial survival rates were comparable to that of longer implants and thus constitute a viable alternative to additional augmentation procedures. This correlates well with the fact that model calculations by finite element analysis indicate clearly that the distribution of horizontal and vertical loading forces is similar to that of longer implants.<sup>9-12</sup> Other calculations have also demonstrated that bone stress should be almost independent of implant length; a more important role was assigned to implant diameter.<sup>6, 13, 14</sup>

Recent reports indicate that it is possible to achieve highly acceptable implant survival rates with the current short implants.<sup>1, 14</sup> Stellingsma et al. have shown survival rates of 88–100% in atrophied mandibles.<sup>13</sup> A survival rate of 96% was reported for short implants in severely atrophic maxillae.<sup>15</sup> Esposito et al. compared the three-year post-loading outcomes of short and long (with guided bone re-

# Implant planning made easy

Planmeca PlanScan®

Planmeca ProMax® 3D

3<sub>3D</sub>X

**Planmeca Romexis® software** offers a completely integrated and digital workflow for modern implantology. From intraoral scanning to easy prosthetic design and realistic implant libraries, the most sophisticated implant planning tools are just a few mouse clicks away.

- All the scanned and design data for prosthetic works is immediately available and can be mapped with the patient's CBCT data
- Use crown library or patient-specific crown from CAD system
- Verify the implant plan with verification tool
- Order surgical guide directly from the software
- Share data easily with partners through **Planmeca Romexis® Cloud** image transfer service



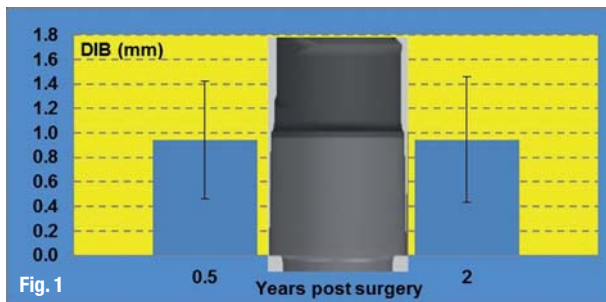
Find more info and your local dealer  
[www.planmeca.com](http://www.planmeca.com)



Planmeca Oy Asentajankatu 6, 00880 Helsinki, Finland. Tel. +358 20 7795 500, fax +358 20 7795 555, sales@planmeca.com

# PLANMECA





**Fig. 1** Peri-implant (mesial and distal) bone level around short implants six months (0.5 years) and two years after implant insertion. The implant shoulder is included to visualise the periapical bone level also in relation to the implant geometry.

generation) implants in a randomised parallel group study.<sup>16</sup> They concluded that in cases with limited residual bone of 7–8 mm over the mandibular canal short implants are a viable alternative to vertical augmentation. The treatment is faster, cheaper and associated with reduced morbidity.

It is to be noted that implant insertion into pristine bone was compared with implants placed after preliminary sinus lift elevation.<sup>17</sup> In this prospective study, which included 393 implants and 155 patients treated in two groups, the implants placed into augmented sinuses had a lower survival rate compared with implants placed into pristine bone.

#### *Crown-implant ratio*

Excessive crown-implant ratios have been hypothesised to be detrimental to long-term withdrawal. For obvious reasons, this ratio must be given particular attention when using short implants. Birdi et al. determined the crown-implant ratios of 309 single-tooth implant-supported restorations on short implants.<sup>18</sup> The mean follow-up time was 21 months and the mean crown-implant ratio was 2, that is, rather unfavourable for a tooth. No statistically significant relationship was found between the crown-implant ratio and implant success, or the mesial or distal periapical bone level.

#### *Short implants in posterior regions*

De Santis et al. studied short implants ( $\leq 8.5$  mm) placed in edentulous posterior regions, predominantly in the mandible, that were affected by high bone resorption.<sup>3</sup> After one- to three-year follow-up, they found a survival rate of 98.1% (i.e. only 2 of 107 implants were lost) and a success rate of 96.3% (i.e. only 4 of 107 implants failed the predefined success criteria). The results of this study therefore also support the use of short implants in posterior regions with highly resorbed bone. In this context, it is important to be aware that the implant length used by Brånemark et al. in their original protocol was established empirically.<sup>19</sup>

The implants at that time had a machined (smooth) endosteal surface. Current implants with microstructured endosteal surfaces are charac-

terised by improved osseointegration and increased bone-implant contacts. Together with optimised geometry, contemporary implants are superior in maintaining implant stability.<sup>3</sup> This in turn should allow the use of shorter implants. Short implants are typically described as  $< 10$  mm long,<sup>20</sup> but Hagi et al. have described short implants as  $< 7$  mm long.<sup>21</sup> A European Association for Osseointegration consensus conference defined short implants as  $\leq 8$  mm. This is more practicable, as implants  $> 8$  mm had been commonly used for a long time without any particular problem related to their length.<sup>22</sup>

#### *Survival rates in studies reviewed*

In a recent review on the meta-analysis of short implant survival studies,<sup>20</sup> it was found that the cumulative survival rate in the majority of the studies was similar to that of longer implants (92.5% and 98.4% for implants with machined and rough surfaces, respectively) and concluded that rehabilitation using short implants is a reliable treatment.<sup>23</sup> This conclusion is to be understood within the limitations of a meta-analysis and the lack of well-designed randomised trials. A similar conclusion was drawn by Telleman et al. from their systematic literature review of the survival rate of 2,611 short implants that were placed in partially edentulous patients.<sup>24</sup>

Nevertheless, Telleman et al. found an increase in implant survival (from 93.1 to 98.6%) that was associated with increasing implant length (from 5.0 to 9.5 mm).<sup>24</sup> The authors believe that there is fair evidence that short implants can be placed in partially edentulous patients, but with a tendency towards an increasing survival rate according to implant length and a better prognosis in the mandibles of non-smokers. Morand and Irinakakis in their earlier literature review also concluded that, even though short implants are commonly used in the areas of the mouth under increased stress (posterior region), the success rate of short implants is similar to that of longer implants when careful case selection criteria have been applied.<sup>25</sup> Annibaldi et al. too concluded in their systematic review on short implants that prostheses retained by short implants in patients with atrophic alveolar ridges appears to be a successful treatment option in the short term, but recommended further studies to determine its success in the long term.<sup>26</sup>

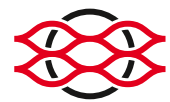## **\_Clinical study**

#### *Patients*

This prospective case series included 56 consecutive patients (35 females and 21 males) referred for dental implantation to three different practices (JNH, JH and DA). Patients were entered into the study consecutively, that is, with no specific selec-



creos™  
xenoprotect



## Experience the difference.

The creos xenoprotect membrane offers outstanding handling properties and an extended barrier function.



Save valuable time and reduce the risk of membrane failure thanks to the outstanding handling properties and high tear resistance of this biodegradable collagen membrane.

Approach your sales representative for a hands-on demonstration of the membrane. To feel it is to believe it. We're confident you'll notice the difference straight away.

- **Extended barrier function**
- **Outstanding handling**
- **Fast and predictable tissue healing**
- **Easy fixation and suturing**

 **Demonstration video**

[creos.com/xenoprotect-demo](http://creos.com/xenoprotect-demo)



Find out more on: [creos.com/xenoprotect](http://creos.com/xenoprotect)

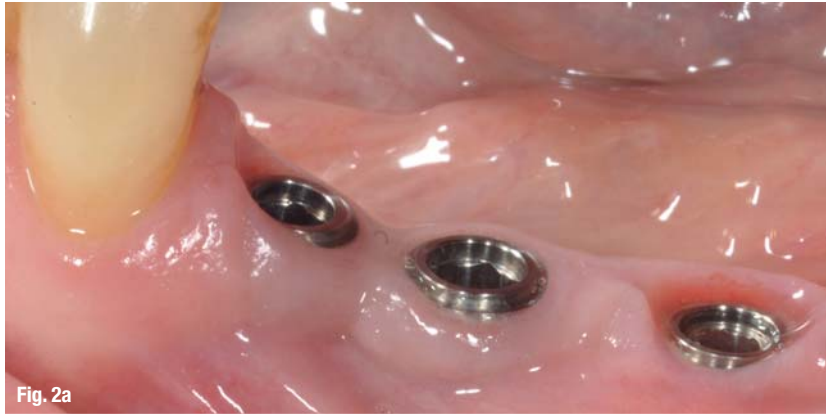


Fig. 2a

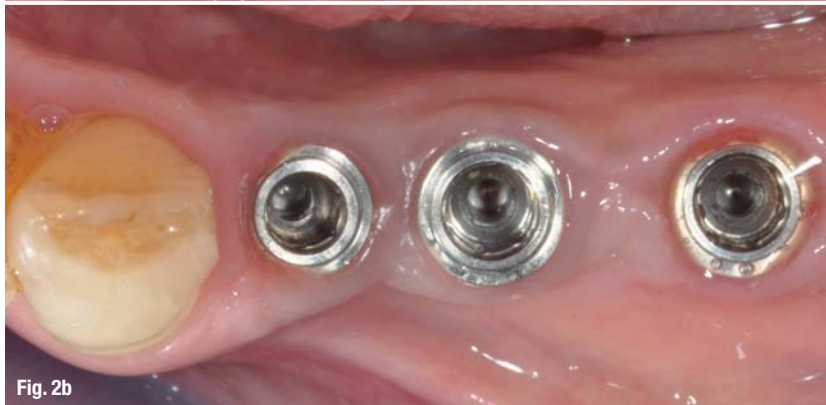

Fig. 2b

**Fig. 2** Three implants placed in the right mandible; a) buccal view; b) occlusal view. The healing abutments were removed after two months of transgingival healing.

tion criteria apart from the routine assessment of their suitability to undergo implant surgery, good overall physical status (ASA 1 or 2) and at least one missing tooth in positions 15–17, 25–27, 35–37 or 44–47. At the implant site, they had to have a vertical bone height between 6.5 mm and 8.0 mm, as well as a minimal bone width of 6.0 mm, assessed by virtual implant placement using SIMPLANT software (Materialise Dental). This is based on a native image obtained by cone beam computed tomography (CBCT). Particular attention was given to maintaining a 2 mm safety zone from the mental nerve to avoid any trauma during the surgery due to an initial radiographic error.

Moreover, patients had to present with a normal occlusion (no open bite), including an opposing arch offering adequate occlusal support. Implants were not placed in heavy smokers (more than five cigarettes per day); patients with heavy bruxism, untreated periodontal disease or poor plaque control; or a position where an implant had been lost previously. Implants were inserted into healed bone; that is, implant placement was performed at least three months after tooth extraction. No crestal bone augmentation was performed.

Eligible patients were informed about all of the available alternative therapeutic options. They were included only if they agreed to treatment with short implants. The participating patients were therefore

not exposed to any additional risk and this case series was therefore not qualified as research. In compliance with valid ethical requirements (Declaration of Helsinki, October 2013), the patients were instructed about the details of their participation and a written informed consent form was explained to them and signed prior to any intervention.

#### *Surgical procedure*

The standard surgical one-stage procedure was performed under local anaesthesia. Patients received antibiotic premedication 1 hour before surgery (2 g amoxicillin or 600 mg clindamycin if allergic to penicillin) and rinsed for 1 minute with a 0.15% chlorhexidine mouthwash.

The drilling protocol was performed according to the manufacturer's recommendations. The bone quality (D1–D4) was recorded in the patient's chart. The insertion depth of the implant was determined by the anatomy of the surrounding bone. Particular attention was given to avoiding contact between any rough surface and the soft tissue. The implants used were titanium implants of 6.5 mm in length and with a 1.0 mm polished collar, and platform diameters of 4.0, 4.5, 5.0 or 6.0 mm. They had a hydrophilic, moderately rough endosteal surface (ELEMENT implant RC INICELL, Thommen Medical).

At the end of the surgery, patients were instructed to apply standard mouth hygiene procedures, including rinsing with a chlorhexidine mouthwash immediately after implantation. Paracetamol 1 g every 6 hours was given for 48 hours. No antibiotic or anti-inflammatory medication was prescribed after implant placement. The sutures were removed after one week.

#### *Restoration*

The implants were occlusally loaded with resin temporary crowns between eight and 12 weeks after surgery. For permanent prosthetics, patients were referred back to their dentist at least two months later. As a result, some of the restorations were still provisional at the final examination.

#### *Implant stability*

The implant stability was assessed by tactile investigation. The implants were considered to be stable in the absence of any signs of mobility, pocketing, bleeding on probing or pain during the investigation.

#### *Follow-up*

The patients were followed up two months after loading and follow-up visits were scheduled at least once per year. The routine follow-up programme included oral hygiene reinforcement, scaling and radiographs (when needed).





# I AM A FAN

like most of my colleagues.

Dr. Leyli Behfar | Specialist in Oral Surgery

CAMLOG is my first choice when it comes to dental implants. With their high-precision implant systems, I find an answer for every indication. Implantations can be performed easily, efficiently and with excellent quality standards. CAMLOG is an inspiring partner in many ways – and that is getting around. [www.camlog.com](http://www.camlog.com)

a perfect fit™

camlog



*Radiographic marginal bone level assessment*

Routine periapical radiographs were deemed unnecessary; therefore, in order to check that osseointegration was uneventful, radiographs were taken at six months and two years after surgery. Care was taken to use the parallel-perpendicular technique; that is, the sensor holder was placed parallel to and the radiograph tube perpendicular to the implant axis to ensure optimal projection for each patient. Particular attention was given to obtaining a radiograph that would show the apex of the implant and the occlusal aspect of the crown in order to evaluate the clinical root-crown ratio. Along with the clinical check, the radiographs were used for quantitative bone-level evaluation. This was done by a single evaluator (PZ) using ImageJ (National Institutes of Health, current version). The images were scaled using the known implant thread height.<sup>27</sup>

*Results*

Fifty-six patients received 77 short implants. The average patient age at implantation was 59 (34–77) years. One patient was on anticoagulant therapy and one had a cardiovascular disease. Two patients underwent simultaneous bone augmentation with deproteinised bovine bone mineral and autogenous bone as filling material. Forty-three (56%) implants were placed in the maxillae (15–17, 25–27) and 34 (44%) in the mandible (35–37, 45–47).

Of the 77 implants placed, 16 (21%) had a platform diameter of 4.0 mm, 37 (48%) of 4.5 mm, 17 (22%) of 5.0 mm and seven (9%) of 6.0 mm. In two of the three participating centres (DA and JH), the maximal insertion torque using the MONO torque

ratchet (Thommen Medical) was recorded for 40 implants. Sixteen implants (40%) were inserted at 20 Ncm, 22 implants (55%) at 30 Ncm and two implants (5%) at 35 Ncm, suggesting good bone quality at the inserted sites. This corresponded well with the fact that no implant was lost, that is, an apparent 100% implant survival rate.

The radiographic evaluation of the peri-implant bone height confirmed the remarkably stable bone level achieved with the use of this implant (Fig. 1).<sup>27–29</sup> The peri-implant bone level stabilised at  $0.9 \pm 0.5$  mm (mean  $\pm$  standard deviation) beneath the microgap, that is, beneath the implant-abutment connection. The implants used have a 1.0 mm machined collar. Therefore, in this patient population, the bone level also stabilised at the interface to the moderately rough endosteal surface.

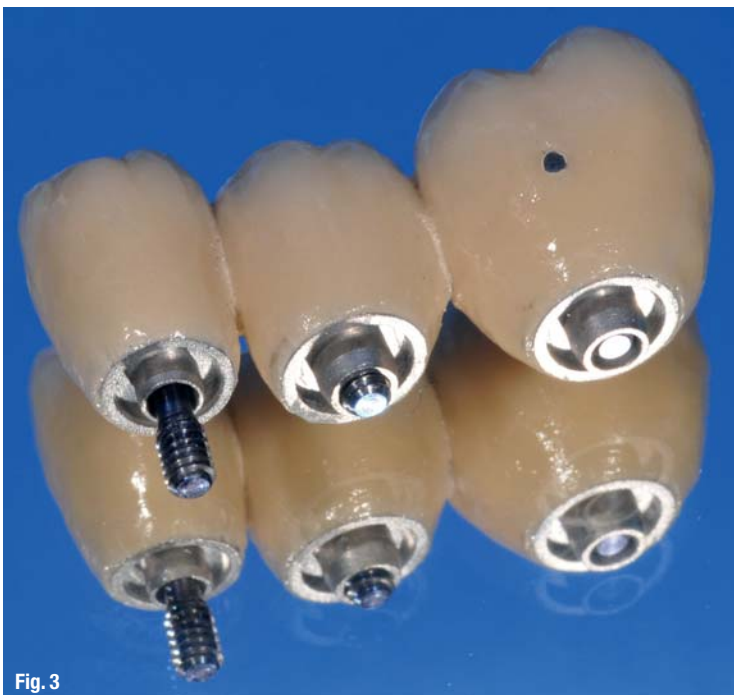One patient, a 74-year-old female patient in the cohort reported above, presented with a partially edentulous right posterior mandible. The teeth had been extracted more than three months before and three implants were placed into the healed sites. Owing to the limited distance from the nerve channel, that is, to avoid the risk of its injury, short implants were inserted in replacement of the second premolar and first molar (positions 45 and 46). The implants were covered with healing abutments.

After two months of uneventful transgingival (non-submerged) healing, the healing abutments were removed (Figs. 2a & b) and the soft tissue around the implants was found to be fully conditioned. A periapical radiograph was taken that confirmed the absence of any pathological signs (not shown). An open-tray impression was taken. The framework was screw attached to ensure that a passive fit was achieved, the occlusion checked, and the permanent restoration (Fig. 3) completed and screw attached within two weeks of removal of the healing abutments. An intra-oral photograph taken after two years of function demonstrates the very favourable and predictable outcome (Fig. 4).

**Discussion**

Recently, short dental implants have proven to be as successful as longer implants. This improvement<sup>30</sup> can be explained by the use of short implants for specific indications and the improved initial diagnosis resulting from the widespread use of CBCT, which has been available since the turn of the century, improved implant design and our ability to identify risk factors for peri-implantitis.<sup>31, 32</sup> The availability of diagnostic tools with improved accuracy that enable more widespread manufacturing of

**Fig. 3** Permanent bridge (porcelain-fused to metal) before insertion.



**Fig. 3**

(precise) surgical guides has contributed to the increased survival and success of short implants. This improvement in hard-tissue management has been accompanied by more precise soft-tissue diagnosis (thin biotype) management, which in turn may have contributed to the improved survival and success rates observed in recent publications.

*No mechanical advantage for longer implants*

Studies using finite element analysis have generally found that the highest stress is only exerted on the crestal part of the dental implant, whereas little force is transmitted to the apical part. In accordance with this finding, longer implants thus should not show any mechanical advantage if only this aspect is considered. This particular point is supported by the results of the case series presented in this article. We have demonstrated that the success of short implants is similar to that of long implants. Moreover, the crown-implant ratio of < 2 does not appear to be of any importance, leaving open the question of the need to splint short to long implants.

*Survival rate of short implants is similar to longer ones*

Our findings support the feasibility of treating single missing teeth with short implants. In a recently published clinical investigation of short dental implants restored as single-unit non-splinted crowns, 221 short (L 6.0–9.0 mm; D 3.7–5.6 mm) implants placed and restored in 168 patients were followed for 27 months.<sup>33</sup> The survival rate in the maxillae was 88.6%, whereas it was 96.0% in the mandible. Cigarette smoking, diabetes mellitus and bone augmentation procedures were not associated with an increased (early) implant failure rate. The researchers concluded that the survival rate of short implants restored as single crowns over an average of 37 months was favourable and comparable with that of longer implants.

*Less invasive surgical protocol*

The case illustrated demonstrates the high predictability of the selected treatment protocol (Figs. 2–4). Were short implants not available, a much more invasive surgical protocol would have been needed. Consequently, a significant clinical risk was avoided and the treatment was more advantageous financially.

*Peri-implantitis*

The eventual development of peri-implantitis remains a major problem. Two factors are to be considered: the ability to provide optimal plaque control, which may be difficult owing to the posterior location of these implants, and adequate periodontal support. This aspect should be addressed by appropriate hard- and soft-tissue management, that is,

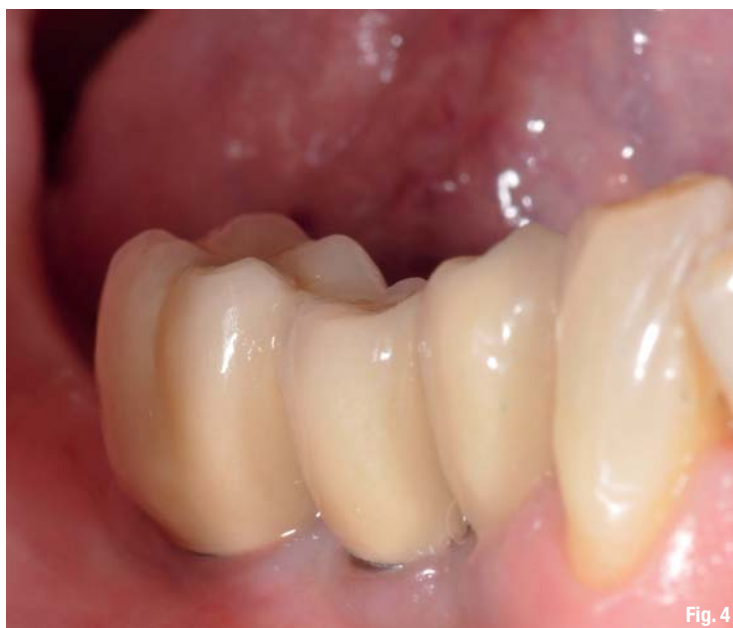

Fig. 4

ensuring sufficient surrounding bone on the facial and lingual/palatal aspects and optimal soft-tissue biotype.

**Fig. 4** Buccal view of the permanent bridge two years after implant placement.

**Conclusion**

Within the limitations of this case series, the reliable and predictable use of short implants for up to two years was confirmed. The results obtained in a multicentre setting confirmed the positive observations reported by other authors. Minimal periapical bone loss (< 1 mm) was found radiographically. Long-term studies are still needed to establish whether there are any specific risk factors pertinent to the use of short implants.

*Editorial note: A list of references is available from the publisher.*

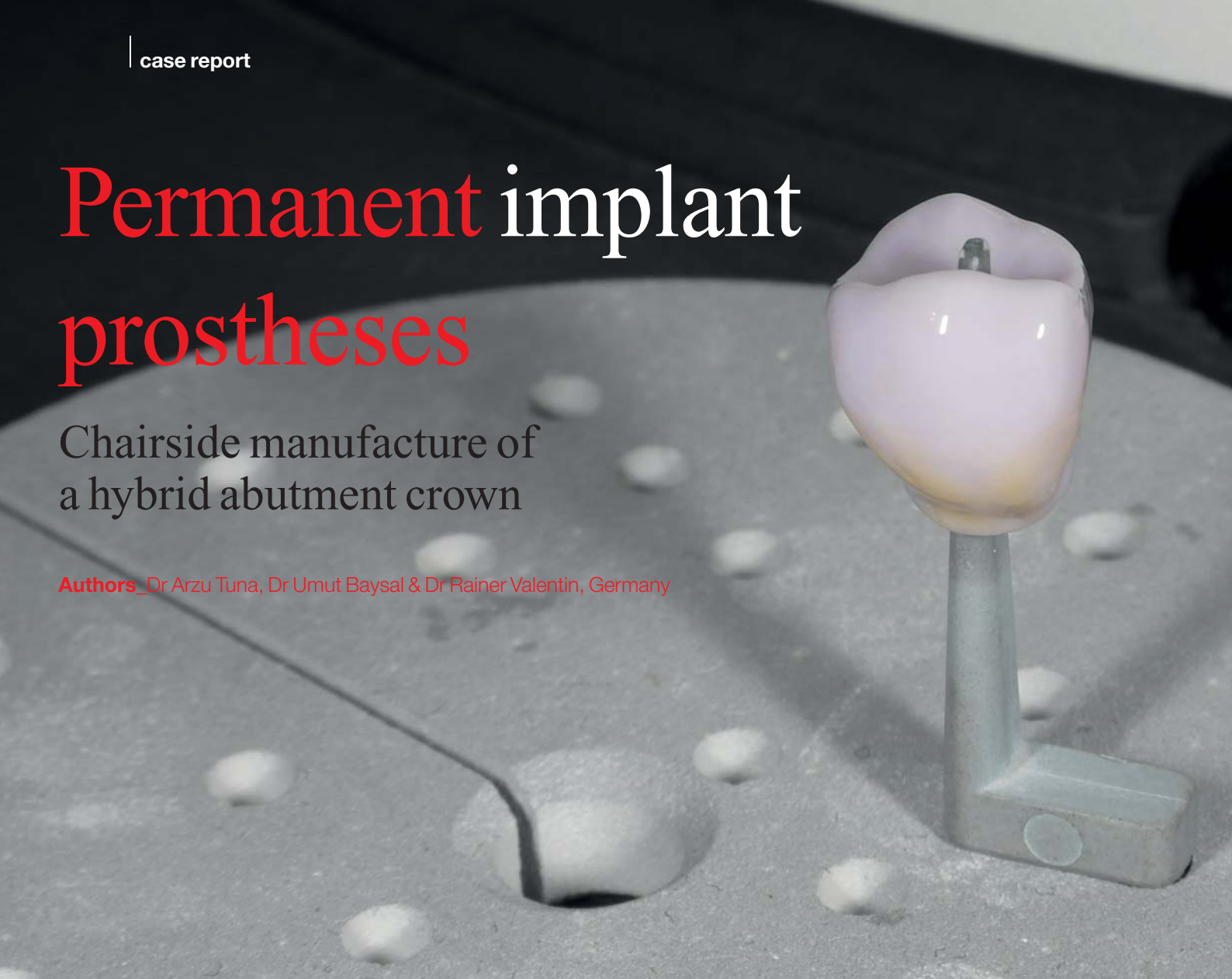|  |          |
|--|----------|
| _contact   | implants |
| <p><b>Dr Jean-Nicolas Hasson</b><br/>                 5, rue du Werkhof<br/>                 F-68100 Mulhouse, France<br/>                 hasson@hrmet.fr</p> |          |

|  |          |
|--|----------|
| _about the author  | implants |
| <p><b>Dr Jean-Nicolas Hasson</b> received his degree in Periodontics at the University of Southern California in 1981. His practice is dedicated to Periodontics and Dental Implants in Mulhouse (France) and he is teaching at the University Louis Pasteur Dental School (Strasbourg).</p> |          |

# Permanent implant prostheses

## Chairside manufacture of a hybrid abutment crown

**Authors** Dr Arzu Tuna, Dr Umut Baysal & Dr Rainer Valentin, Germany



**Fig. 1** Tooth 26, which proved not worth preserving, after root resection.

**Fig. 2** The state of tooth 26 after extraction.

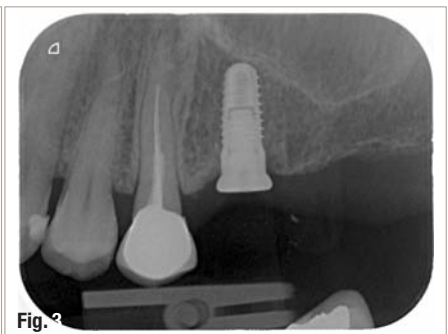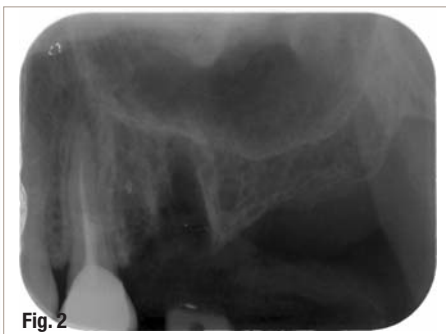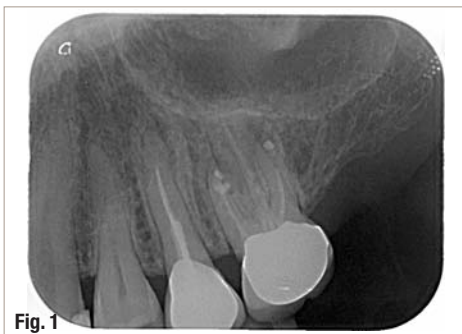**Fig. 3** Implantation after 12 weeks.

In the past ten years, CAD/CAM restorations have been established as standard in implant prostheses. The advantages of such restorations include the chairside use of full ceramics and digital impressions. Owing to the introduction of ceramic blocks with prefabricated twist-proof screw channels, the workflow for the chairside manufacture of individual hybrid abutments and hybrid abutment crowns can be applied in daily practice. By means of the cases reported in this article, the indications, suitable materials and attachments, and related studies are discussed.

### Case reports

#### Case 1

In September 2013, a 35-year-old patient came into our practice for the first time. The general anamnesis found no peculiarities. She complained of pain in the second quadrant. The clinical and the radiological examination found that tooth 26 was not worth preserving (Fig. 1). The patient was subsequently informed of the treatment options, which were revision of the root canal filling, and a second root resection and extraction with subsequent im-





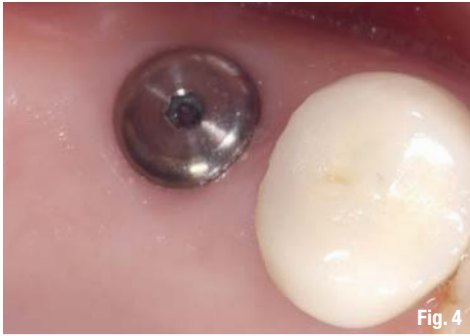

Fig. 4

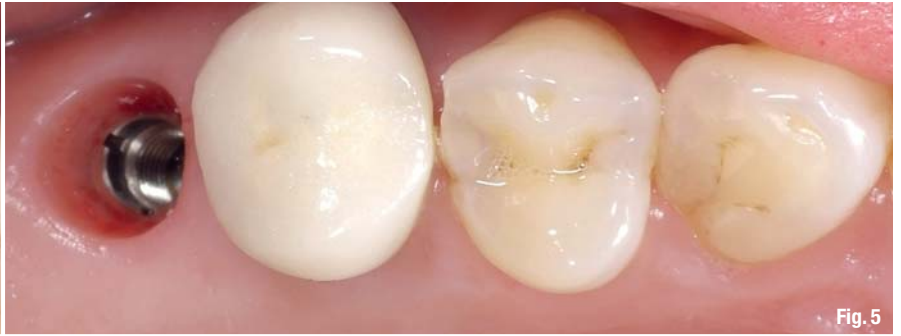

Fig. 5



Fig. 6

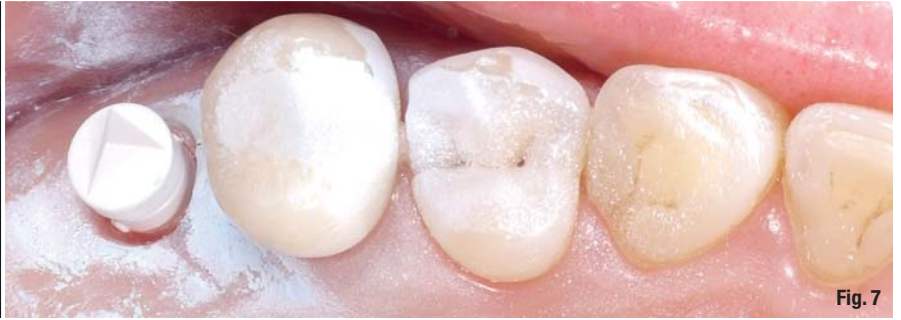

Fig. 7

plantation. Finally, tooth 26 was extracted and implantation followed 12 weeks later (4.3 mm x 9 mm CAMLOG implants; Figs. 2–4). We decided against closed healing and the implant was closed with a flat gingiva former (2 mm). With this, a further operation to expose the implant could be avoided.

*Chairside workflow*

Ten weeks after implantation, the prosthetic restoration was performed in one session without a physical model. A digital impression was taken by means of CEREC Bluecam (Sirona Dental Systems). Since no exposure of the implants was necessary and there were no open wound edges, we were able to use the powder for the scanning procedure without any concerns (Fig. 5). After the insertion of the CAMLOG TiBase (Sirona Dental Systems; Fig. 6), which served as the titanium adhesive abutment for the chairside-manufactured hybrid abutment crown made of lithium disilicate (IPS e.max, Ivoclar Vivadent), the appropriate scan body (Sirona Dental Systems; Fig. 7) was placed on the TiBase. Before taking the impression, the placement of the TiBase was radiologically controlled (Fig. 8).

The virtual construction was created by means of CEREC Software 4.2 (Sirona Dental Systems) and was built up similar to the crown's construction. An advantage of the virtual construction is the more flexible control of the emergence profile. The pressure on the gingiva can be adjusted individually, and displacements of about 5 mm have proven to be unproblematic.

Further parameters, such as minimum strength and position of the screw channels, should be adjusted and included in the construction according to the manufacturer's instructions. The manufacture of the hybrid abutment crown was achieved with the CEREC MC XL milling unit (Sirona Dental Systems; Fig. 9). After the colour determination, the low translucency A2 A16 (L) ceramic block was selected.

After glazing and colouring, the crystallisation or combination firing was done (Programat CS, Ivoclar Vivadent). The monolithic polished abutment crown was then extra-orally attached (Multilink Hybrid Abutment, Ivoclar Vivadent) to the TiBase (Fig. 10). The hybrid abutment crown was screwed in and the

**Fig. 4** Four weeks after implantation.  
**Fig. 5** The situation before the digital impression.  
**Fig. 6** CAMLOG TiBase.  
**Fig. 7** Preparation for the digital impression.

**Fig. 8** Radiological control of the TiBase.  
**Fig. 9** The hybrid abutment produced by the milling unit.  
**Fig. 10** The hybrid abutment crown with luting composite.

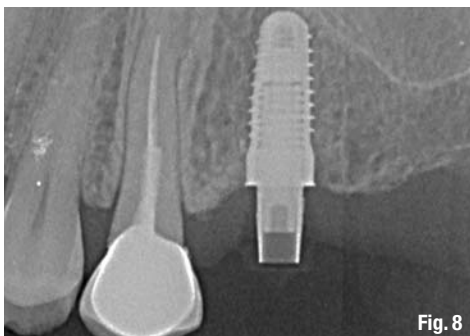


Fig. 8

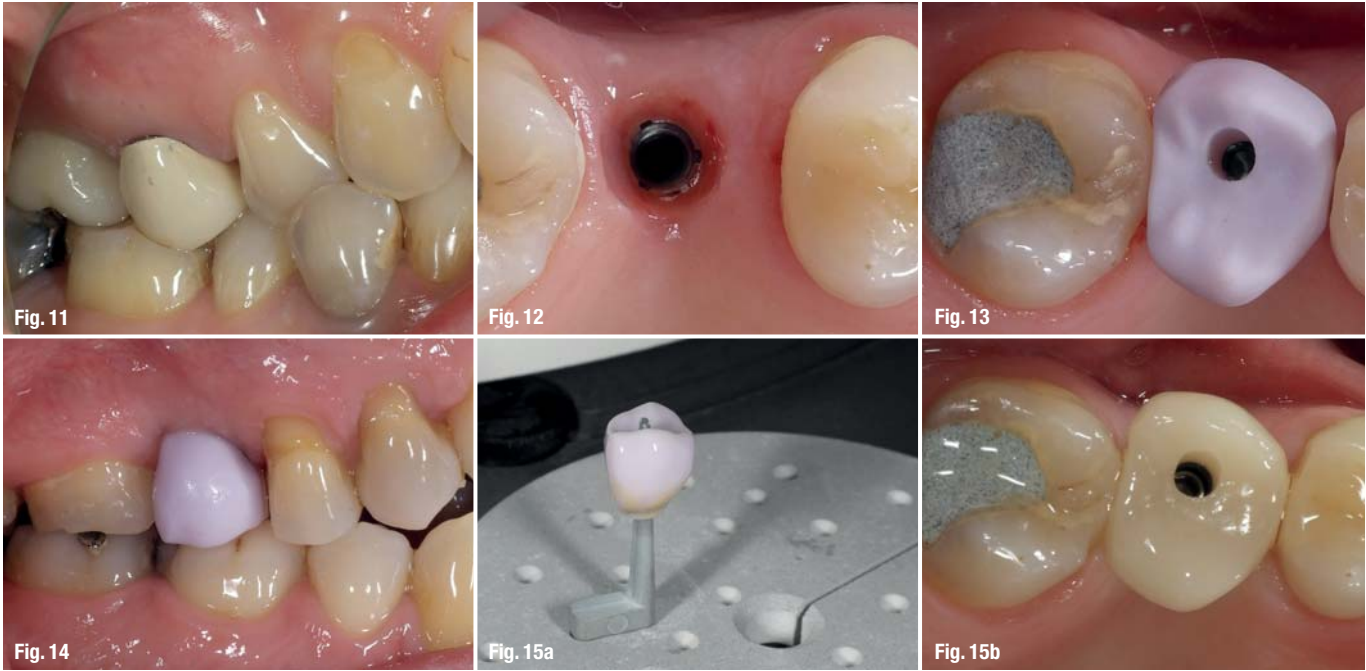


Fig. 9

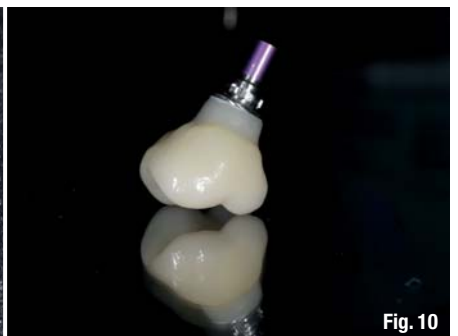

Fig. 10





**Fig. 11**\_Intraoral view after insertion.

**Fig. 12**\_Case 2: three months after implantation.

**Figs. 13& 14**\_Try-in of the hybrid abutment crown before crystallisation firing.

**Fig. 15 a**\_The hybrid abutment crown on the firing tray before crystallisation firing.

screw channel was sealed with PTFE tape (3M ESPE) and composite (IPS Empress Direct, Ivoclar Vivadent; Fig. 11).

*Cases 2 and 3*

Figures 12 to 18 illustrate the cases of the second and third patients. Both patients were treated following the same treatment plan described in the first case.

show the try-in of the hybrid abutment crown before crystallisation firing. After the try-in, the polished ceramic crown was glazed, coloured and filled with auxiliary firing paste (IPS Object Fix Putty, Ivoclar Vivadent; Figs. 15a-c). Case 3 shows restoration in region 15 (Figs. 16-18).

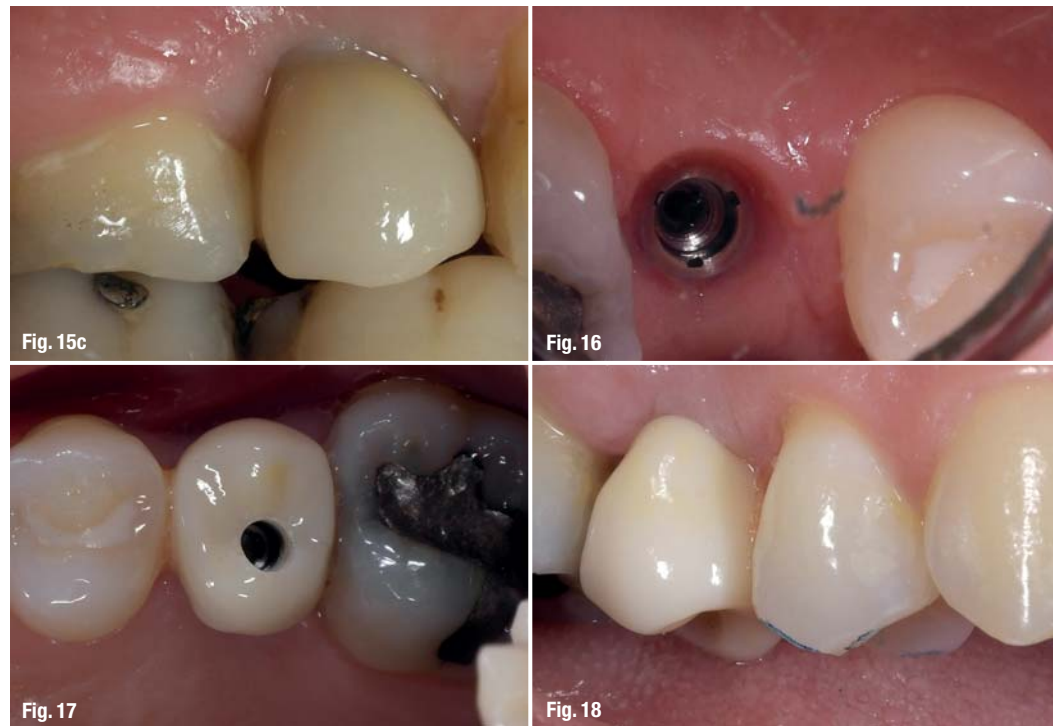**\_Discussion**

Restoration using CAD/CAM methods has been established as standard in implant prostheses. Besides the industrial manufacture of materials and the

Case 2 demonstrates the prosthetic restoration of an implant in region 26 (Fig. 12). Figures 13 and 14

**Figs. 15b & c**\_Intra-oral view of the crown.

**Figs. 16-18**\_Case 3: implant restoration in regio 15.



consequent high quality, the individualised, tooth-coloured design of the emergence profile and flexibility regarding construction (angulation, dimension) are further advantages. Furthermore, digital treatment concepts offer the possibility of chairside restoration and shortened treatment duration without compromising the healing period. Systems that do not require the use of powder offer the possibility of detecting the implant position during implant insertion and thus the possibility of a prosthetic restoration during exposure. In this way, the design and dimensions of the superstructure can be ideally created without the need for individual gingiva formers. From an aesthetic aspect, it makes sense to have a natural and tooth-coloured emergence profile. In view of possible recession, the risk of exposed metallic elements can be avoided.

### Conclusion

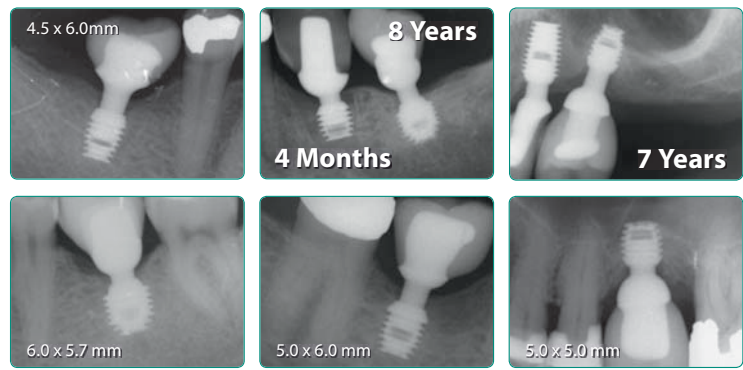
As described in the cases reported, the hybrid abutment and the hybrid abutment crown together offer a suitable alternative to full-ceramic abutments made of zirconium dioxide ceramic. Contrary to zirconium dioxide abutments, the mating surface to the implant body is made of titanium and not of zirconium dioxide ceramic. Since zirconium dioxide ceramic is harder than titanium, the implant body can be affected by material abrasion, which appears to be confirmed by recent studies. In addition, a dark discolouration of the surrounding gingiva can arise from the worn-off titanium particles, similar to amalgam tattoos. In aesthetically significant areas, such as the anterior maxillary zone, this would be a serious complication and could arise years after insertion. Regarding the adhesive bond between the TiBase and abutment body, the initial data is very promising. If adhesion is performed carefully according to manufacturer's instructions, it should not fail.

Finally, further studies are needed to clarify the biocompatibility of adhesive gaps with the surrounding tissue positioned 0.4 mm from the implant shoulder and ideally also from the bone.

contact

**implants**

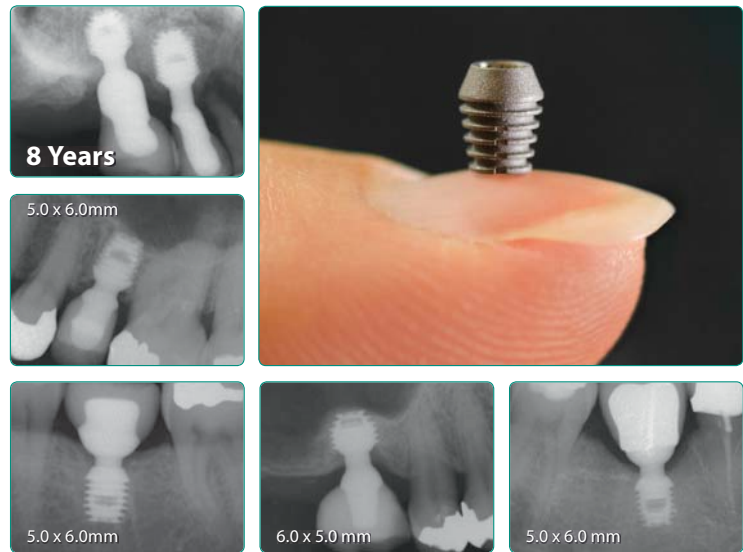
**Dr Arzu Tuna**  
**Dr Umut Baysal**  
 Praxis am Nordwall  
 Nordwall 2  
 57439 Attendorn, Germany  
  
[www.zahnarzt-attendorn.de](http://www.zahnarzt-attendorn.de)



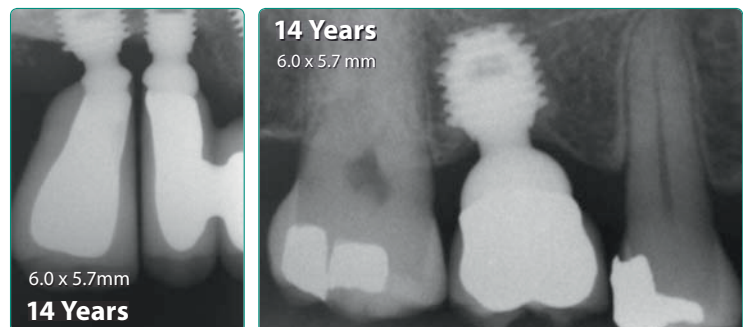
## **SHORT** IMPLANTS

**Since 1985**

- » Simple.
- » Predictable.
- » Profitable.



**SHORTEST IMPLANTS  
LONGEST HISTORY**



**bicon**<sup>®</sup>  
DENTAL IMPLANTS

Bicon Europe Ltd. ■ Hauptstr. 1 ■ 55491 Buechenbeuren  
 Germany ■ Phone +49 (0)65 43 / 81 82 00 ■ Fax +49 (0)65 43 / 81 82 01  
[germany@bicon.com](mailto:germany@bicon.com) ■ [www.bicon.de.com](http://www.bicon.de.com)

# Improvements in digital implant prosthetics

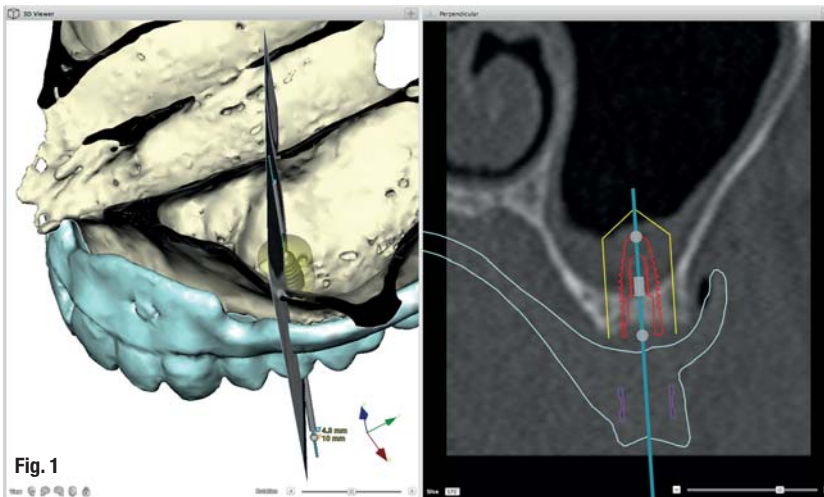
Author\_Dr Joannis Katsoulis, Switzerland

## \_Introduction

In contemporary dental medicine, computers and implants are closely linked. By dealing with this topic, the question arises whether one can speak about a(n) (r)evolution in planning and manufacturing of implant-supported reconstructions in the field of implant prosthetics.

Dental prosthetics are concerned with the restoration of lost teeth and tooth-bearing tissues in the oral cavity. Loss of teeth and edentulism are quite frequent in old age and often the main reasons to visit a dentist. Hence, dental implants have become important means of therapy, whereby computer-assisted procedures play an increasing role in the daily routine of the dental practice. Thus, it is no contradiction to use modern computer tech-

Fig. 1\_Virtual implant-planning based on volume tomography.



nology and new materials equally for young and old people.

The continuous advancement of specialised fields in radiological imaging, manufacturing methods in the engineering industry and dental implantology have extended the possibilities of decision making, planning and surgical as well as prosthetic realisation of a therapeutic plan. Actually, this proceeding of dental medicine only has been made possible by bringing together these formerly independent disciplines, which basically depend on the increased performance of digital data processors.

## \_Revolution or evolution?

Despite these developments, many colleagues do not consider a computer a helping advice in their daily routine. Any digitalisation of a certain practice area needs a modification and adaption of the whole team's workflow, depending on the scope of digitalisation. This requires a large effort of all employees involved, the willingness to learn from earlier mistakes and to keep pace with the progressing digital technologies. One thing is certain: Innovations in dental medicine do occur more often and faster nowadays. Therefore, evolution or revolution does not depend on the given digital possibilities but rather on the individual experience and know-how.

In dental medicine, computer technology is no more a real technological revolution. Virtual implant-planning based on volume tomography has



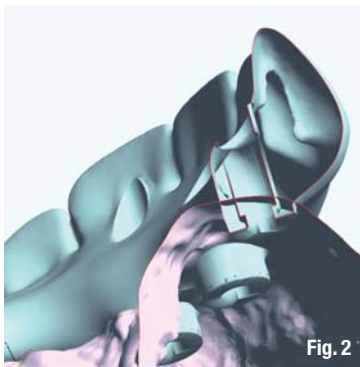


Fig. 2

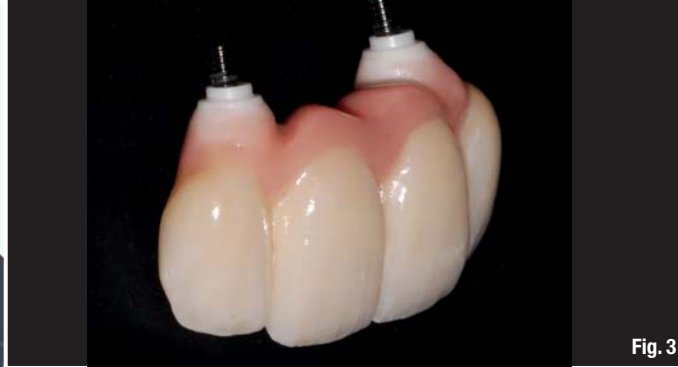

Fig. 3

Fig. 2\_Design of CAD/CAM-FDP framework.

Fig. 3\_Full-ceramic reconstructions screwed together on the implant's level.


facilitated the decision making and information for a patient for quite some time now (Fig. 1). Computer-assisted implant placing occurs with high precision in partially or fully edentulous patients.<sup>1</sup> Here, the so-called backward planning ensures a high level of predictability of the surgical and prosthetic result. The surgical realisation of the 3-D planning with stereolithographic splints is an important advancement in complex cases and can contribute to less invasive and rapid proceedings in selected cases. By this, one can precisely determine whether a completely "flapless" procedure is possible for single or all planned implants in the jaw and which augmentative technique is indicated.<sup>2</sup> Espe-

cially for older patients with relatively more risks when implanting, a well-planned, minimally-invasive proceeding with a shortened operation time is of advantage.<sup>3,4</sup>

Additionally, the digitalised anatomical and prosthetic conditions can be analysed virtually and with the help of clearly-formulated criteria contribute to the decision making in case of either fixed or removable implant-borne reconstructions.<sup>5</sup> It has turned out that the proportion of bone in the upper jaw is clinically often overestimated.<sup>6</sup> According to the characteristics of an atrophy of the alveolar ridge, the prosthetic-oriented planning

AD

## Implant Surfaces and Osseointegration



DOT offers a wide range of technologies for surface modification of dental implants and components:

- Blasted/etched surfaces (DUOTex®, CELLTex®)
- Bioactive calcium phosphate coatings (BONIT®, BONITex®)
- PVD coatings of drills and abutments
- Anodising of prosthesis screws (DOTIZE®)
- Color anodising of implant components


As part of our supply chain concept we offer as an extra service the cleanroom packaging of dental implants and instruments including their labelling.

DOT GmbH · A Member of the Eifeler-Holding  
 Charles-Darwin-Ring 1a · 18059 Rostock  
 Phone: +49(0)381-4 03 35-0 Fax: +49(0)381-4 03 35-99  
 info@dot-coating.de www.dot-coating.de



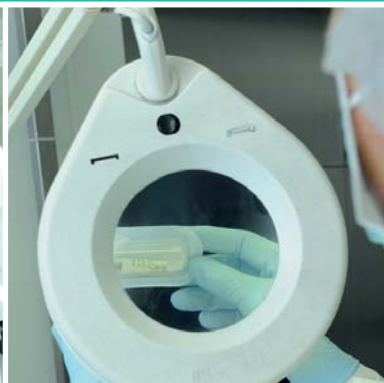A-dental-091014-EN

### Coloring of Implant Components




Visit us at IDS 2015!  
 Hall 11.2 / Stand R, 33

### Cleanroom Packaging of Implants






**Figs. 4 & 5** Fitting accuracy below 50 µm seems to be possible for full-arch reconstructions.



**Fig. 4**



**Fig. 5**

will control the implant positioning and type of reconstruction of the operation virtually in advance.

### CAD/CAM technologies in implant prosthetics

Closely connected to computer-assisted implant planning is the CAD/CAM technology (Computer-Aided Designing/Computer-Assisted Manufacturing), which has significantly changed the dental medicine in the course of the past twenty years.<sup>7</sup> The more parallel dental implants can be planned and clinically placed, the easier and more stable the design (Fig. 2) of CAD/CAM frameworks/FDPs (Fixed Dental Prostheses) and bars made of titanium or zirconia can be kept. These materials are also characterised by improved technical and biological features. Consequently, technical and biological complications are to be expected less often.<sup>8,9</sup>

Depending on the connection type of implant systems, also full-ceramic reconstructions can be screwed together directly on the implant's level (Fig. 3).

The fitting accuracy of implant-borne CAD/CAM-titanium and -zirconia reconstructions are significantly higher than the conventionally produced bridges with cast alloys.<sup>10</sup> By now, most of the major manufacturers offer their own CAD/CAM systems and have centralised production facilities for manufacture of frameworks and bridges at their disposal. Thus, a fitting accuracy below 50 µm (Fig. 4 & 5) seems routinely possible for full-arch reconstructions with the required care and know-how of the production process.<sup>11-13</sup>

The CAD/CAM production is specific for metals like titanium and ceramics, as for example zirconia.

For milling with CNC-machines, especially suited milling cutters are used. After the milling of zirconia in the overdimensioned green-/white-body, the final crystallisation (sintering and HIP) of the work piece is made. Despite of automated and mechanical processes, the CAM step requires the experience of specialised engineers who are able to oversee the processes and step in if problems occur.

The current development efforts and advancements take place in the area of software possibilities and the connection of individual digital sub-areas. Thereby, a universal data format (STL) enables the forwarding of data by intra- or extraoral scanners via CAD- and CAM software. However, it probably might take some time until the various providers will open their systems completely and thus enable users to freely choose between the digital work steps.

*Editorial note: A list of references is available from the publisher.*

#### contact

#### implants

**PD Dr med. dent. Joannis Katsoulis, MAS**

Department of Reconstructive Dentistry and Gerodontology  
School of Dental Medicine  
University of Bern  
Freiburgstrasse 7  
3010 Bern  
Switzerland

joannis.katsoulis@zmk.unibe.ch



# EUROPEAN CLINICAL MASTERS PROGRAMS IN IMPLANT DENTISTRY 2015

University Meets Practice

## SESSION I – Universidad de Sevilla, Spain (closed)

|          |                   |                                |
|----------|-------------------|--------------------------------|
| Friday   | <b>27.03.2015</b> | Prof. Dr Daniel Torres-Lagares |
| Saturday | <b>28.03.2015</b> |                                |



## SESSION II – Semmelweis Universität Budapest, Hungary (closed)

|          |                   |                                |
|----------|-------------------|--------------------------------|
| Thursday | <b>14.05.2015</b> | Prof. Dr Divinyi Tamas         |
| Friday   | <b>15.05.2015</b> |                                |
| Saturday | <b>16.05.2015</b> | Prof. inv. Dr (H) Peter Borsay |



## SESSION III – Uniklinik Hamburg-Eppendorf, Germany Borsay Implant Institute Hamburg, Germany

|          |                   |   |
|----------|-------------------|---|
| Thursday | <b>12.11.2015</b> | Prof. Dr Dr Ralf Smeets<br>Prof. Dr Dr Max Heiland            |
| Friday   | <b>13.11.2015</b> | Prof. inv. Dr (H) Peter Borsay                                |
| Saturday | <b>14.11.2015</b> | Prof. inv. Dr (H) Peter Borsay<br>Certificate Awards Ceremony |



Universitätsklinikum  
Hamburg-Eppendorf



### MORE INFORMATIONS:

**Scientific Director**  
Prof. inv. Dr (H) Peter Borsay  
Borsay Implant Institute  
Hamburg, Germany

### REGISTRATION:

[www.borsay-institute.com](http://www.borsay-institute.com)

**phone:** +49 40 6024242  
**e-mail:** peter@borsay.com



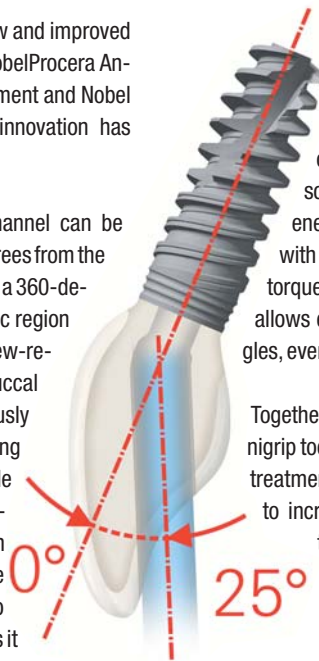
# Manufacturer News

Nobel Biocare

## Aesthetics from a new angle

True innovation is about finding new and improved ways to do things. With the new NobelProcera Angulated Screw Channel (ASC) abutment and Nobel Biocare's Omnigrip tooling, true innovation has been achieved.

With the abutment, the screw channel can be placed with an angle of up to 25 degrees from the axis of the implant, anywhere within a 360-degree radius. In the anterior aesthetic region this makes it possible to use screw-retained restorations where a buccal screw access point would previously have ruled them out. When designing the abutment, the screw access hole can instead be positioned on the lingual side of the restoration. When used on molars or premolars, the ability to tilt the screw channel into the most convenient position makes it easier for the clinician to place, and access, the restoration. As a one-piece restoration the abutment requires less labor from the dental lab and so is produced more quickly, reducing costs.



The benefits of the ASC abutment are only possible thanks to the introduction of the associated Omnigrip tooling. The tip of the screwdriver allows the screw to be tightened and loosened within the angulated channel with the same accessibility and torque as if the channel were straight. It allows easy handling from multiple angles, even in the posterior.

Together, the ASC abutment and the Omnigrip tooling offer clinicians not just new treatment possibilities, but opportunities to increase the number of screw-retained restorations they place.

**Nobel Biocare Services AG**


P.O. Box  
8058 Zurich-Airport  
Switzerland  
www.nobelbiocare.com

Schütz Dental

## Cylindrical Cone Connection

Schütz Dental presents the new implant of the IMPLA family: an internal conical connection with anti-rotation protection. The cylindrical multi-purpose implant is endowed with self-tapping thread and internal conical connection with anti-rotation protection. The basic cylindrical shape of the implant is complemented by synchronous threads up to the implant shoulder. In many cases, the implantologist can quickly adapt the insertion depth.

Advantages of the new implant are an integrated platform switching (A) for the preservation of the marginal bone level and improvement of the soft tissue attachment. Another advantage is the secure connection (B) where micro movements



between implant and abutment are minimized. Last but not least, the self-tapping thread (C) serves a maximum of flexibility, a reduced time and effort for the surgery, and a very high primary stability. The implant with its micro-structured and high purity surface is blasted and etched for an optimal cell adaption and safe osseointegration.

IMPLA implants stand for clinical experience since 1963, premium German quality at a fair price and part of the digital workflow.

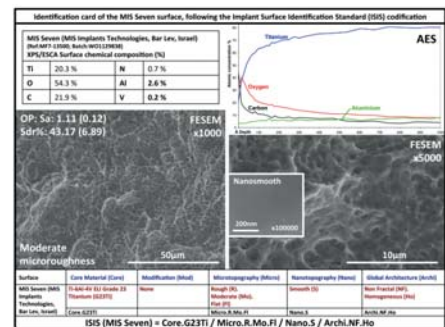
**Schütz Dental GmbH**

Dieselstr. 5–6  
61191 Rosbach, Germany  
www.schuetz-dental.com

MIS

## Implant surfaces with enhanced purity

Long-term clinical success of dental implants is dependent on a number of critical factors including implant design, bone quality and quantity, surgical techniques and clinician's skills. However, above and beyond implant materials and geometry, the topography and chemistry of the implant; surface treatment and surface quality is just as important in achieving high success rates.



Numerous studies suggest a predictable and more rapid osseointegration of implants using surface treatments in a combination of sand-blasting and acid-etching. Osteoblast proliferation and differentiation depends on the micro- and nanostructures on the surface of the implant that closely mimic the natural bone matrix. MIS implant surfaces most closely mimics the natural cancellous (spongy) bone configuration and has enhanced surface purity when tested against other major implant brands using SEM technology.

Using surface characterization technology, MIS can guarantee that our implant surfaces uphold the highest standards of surface quality with a 99.8–100% pure titanium oxide surface, as well as the validation of full coverage by sand-blasting and acid-etching. These surface treatments help eliminate various surface contaminants while increasing the implant surface area, generating a hydrophilic surface with micro- and nanostructures for optimum osseointegration.

**MIS Implants Technologies GmbH**

Simeonscarre 2  
32423 Minden, Germany  
www.mis-implants.com



Sunstar GUIDOR

## Membrane-free ridge preservation following extraction



Removal of teeth results in horizontal and vertical changes to both hard and soft tissues. Ridge (socket) preservation procedures describe the process of filling the freshly prepared socket with bone graft substitutes to reduce subsequent alveolar crest atrophy. The focus is for simple and safe measures ensure patient discomfort is kept to a minimum.

The alloplastic (no tissue of human or animal origin) bone graft substitutes easy-graft® CLASSIC (completely resorbable) and easy-graft® CRYSTAL (partly resorbable) are particularly suited to ridge preservation following tooth extraction. The two materials differ in how they break down in the body. The CLASSIC

substitute is completely resorbed and replaced by bone typically over the course of several months often in conjunction with a planned implant placement. In contrast, the CRYSTAL substitute undergoes partial replacement with new bone with a proportion of the remaining hydroxyapatite component integrating itself within the hard tissue, ensuring long-term volume stability.

The system comprises two components: spherical granules in a single-use syringe and Biolinker™ activator which makes the granules sticky and mouldable. Upon contact with body fluids, the material hardens within minutes forming a perfect analogue to the socket. The high porosity of the substitute allows the absorption of blood and has a positive effect on the healing process.

**Sunstar Deutschland GmbH**

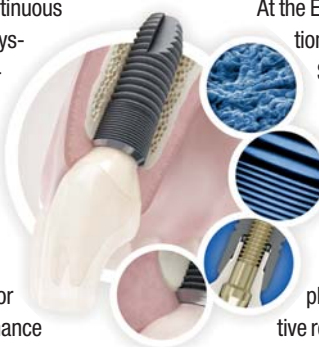Aiterfeld 1  
79677 Schönau, Germany  
www.sunstargum.de

DENTSPLY Implants

## Simplicity without compromise

DENTSPLY Implants' next step in the continuous Evolution of the ASTRA TECH Implant System continues. The system EV is designed with a site-specific, crown-down approach based on the natural dentition for increased surgical simplicity and flexibility and restorative ease. The foundation of this evolutionary step is the Implant System BioManagement Complex, well documented for its long-term marginal bone maintenance and aesthetic results provided by the combination of the key features: the OsseoSpeed surface, Micro-Thread, Conical Seal Design and Connective Contour.

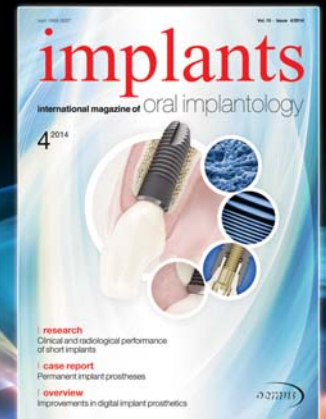The main objective of the new system is to further improve system logic, robustness and user friendliness. Simplicity without compromise has permeated the evolution of the implant system EV and the new implant system is a result of the collaborative input and insights from dental professionals throughout the global dental industry.



At the European Association of Osseointegration (EAO) Annual Meeting in Rome, Italy, September 25–27, the company presented SIMPLANT computer guided implant treatment with the ASTRA TECH Implant System EV. The computer guided implant treatment is a comprehensive system based on 3-D imaging, allowing for precise implant planning and predictable restorative results. Using this with the new Implant System EV unlocks the potential of digital driven crown-down planning and enhances the treatment outcomes for the benefit of the patients. Furthermore, working with a complete digital workflow allows for even greater simplicity and efficiency in the treatment process.

**DENTSPLY Implants**

Steinzeugstraße 50  
68229 Mannheim, Germany  
www.dentsplyimplants.com



You can also subscribe via  
[www.oemus.com/abo](http://www.oemus.com/abo)

 **Subscribe now!**

I hereby agree to receive a free trial subscription of **implants international magazine of oral implantology** (4 issues per year). I would like to subscribe to **implants** for € 44 including shipping and VAT for German customers, € 46 including shipping and VAT for customers outside of Germany, unless a written cancellation is sent within 14 days of the receipt of the trial subscription. The subscription will be renewed automatically every year until a written cancellation is sent to OEMUS MEDIA AG, Holbeinstr. 29, 04229 Leipzig, Germany, six weeks prior to the renewal date.

Reply via Fax +49 341 48474-290 to OEMUS MEDIA AG or per E-mail to [grasse@oemus-media.de](mailto:grasse@oemus-media.de)

Last Name

First Name

Company

Street

ZIP/City/County


E-Mail

Signature

Notice of revocation: I am able to revoke the subscription within 14 days after my order by sending a written cancellation to OEMUS MEDIA AG, Holbeinstr. 29, 04229 Leipzig, Germany.

Unterschrift

OEMUS MEDIA AG  
Holbeinstr. 29, 04229 Leipzig  
Tel.: +49 341 48474-0  
Fax: +49 341 48474-290  
E-Mail: [grasse@oemus-media.de](mailto:grasse@oemus-media.de)



CAMLOG

**Extended guide system for template-guided implantation**



The guide system of CAMLOG is used for template-guided preparation of the implant bed and for insertion of CAMLOG® and CONELOG® SCREW-LINE implants following prior 3-D diagnostics and 3-D planning. Following its successful launch in the fall of 2008, the CAMLOG guide system has been extended by the CONELOG SCREW-LINE implants and now continues under the name "Guide System".

The system includes implants with pre-assembled insertion posts, as well as laboratory and surgical instruments. All components of the system are matched precisely to one another. Colour-coded guide sleeves and single-use surgical instruments

enable safe use. Additional sleeves and depth stops are not required. The depths of the implant beds are prepared stepwise with guided single patient drills, and the implant is inserted accurately to the planned placement depth using the pre-assembled insertion post with guide shaft.

The portfolio of the guide system has been extended by CAMLOG® SCREW-LINE Promote® plus implants of a diameter of 3.3 mm and length of 16 mm. These are now available in the lengths of 9, 11, 13 and 16 mm and the diameters of 3.3, 3.8 and 4.3 mm. CONELOG® SCREW-LINE implants are available in the guide system with the lengths of 7, 9, 11, 13 and 16 mm and the diameters of 3.3, 3.8 and 4.3 mm.

The existing guide system is fully compatible with the new "Guide System" in terms of surgical application.

**CAMLOG Biotechnologies AG**  
 Margarethenstrasse 38  
 4053 Basel, Switzerland  
 www.camlog.com

Bicon Dental Implants

**Simple. Predictable. Profitable.**

Since 1985, the Bicon Dental Implant System has offered dentists a proven solution for missing dentition.



The Bicon implant design comprises plateaus, sloping shoulders and a bacterially-sealed, 1.5° locking taper implant to abutment connection. With the plateau design, cortical like bone forms around and between each plateau. This Haversian bone allows for the routine use of 5.0 mm short implants.

The sloping shoulder provides the necessary room for bone to support interdental papillae that are gingivally aesthetic. Bicon's 360° of universal abutment positioning provides for the revolutionary cementless and screwless Integrated Abutment Crown™, which consistently provides for a non-metallic aesthetic gingival margin.

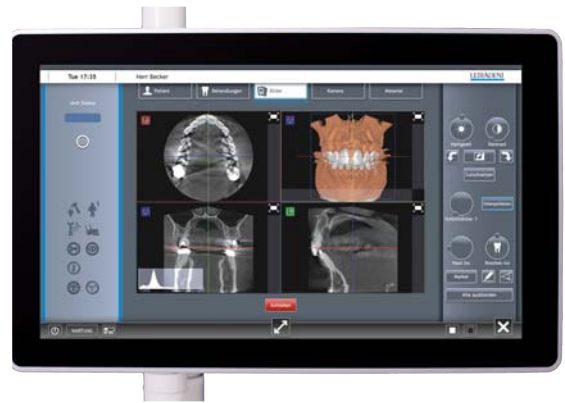**Bicon Dental Implants**  
 Arborway 501  
 Boston, MA 02130, USA  
 www.bicon.com

ULTRADENT

**The digital future for dental units**

vision U, the new multimedia system is also entertainment, infotainment service, provides system control and remote diagnosis, saves data for quality management and can even be used as a diagnostic monitor for X-ray images.

The system is easy to use as a tablet computer and meets all the requirements of dental practices now and in the future. It is approved by the MPG (German medical devices law). The smart touch functions can be used with one finger, two fingers and two hands, e.g. for image rotations around a defined axis, and



also work flawlessly with gloves. The multimedia system can display the patient data and images. It includes an intraoral camera with auto-focus bar code/QR code recognition and an interactive 2-D/3-D X-ray viewer for JPEG and DICOM data formats.

The system provides an additional function that records all data before, during and after treatment. This makes quality management easier and increases security for the dental practice. The employees receive appropriate cleaning and hygiene instructions from the system before and after treatment.

Together with the ULTRADENT premium class, the system realises many technical visions, ensures captivation, satisfaction and a future-oriented dental practice. So, enjoy this (r)evolution and put this innovation to use in your dental practice.

**ULTRADENT Dental-Medizinische Geräte GmbH & Co. KG**  
 Eugen-Sänger-Ring 10  
 85649 Brunnthal, Germany  
 www.ultradent.de

Rectification

**TRI Implants vs Straumann**

The EAO *today* edition in Rome featured a prominent interview article with CEO Tobias Richter and CTO Sandro Venanzoni of TRI Dental Implants, a Swiss manufacturer of dental implant solutions, on their respective launch of the TRI Octa Tissue Implant Line at the EAO Congress 2014. During the interview, several comments were made by the TRI Dental Implants Management, that may be considered misleading and require clarification based on the request of the Institut Straumann AG, as follows below.

The following statements are subject to rectification:

1. Statement A: "Considering the fact that several key executives in our company previously worked at Straumann, the tissue level implant has always been close to our heart as a product that could provide predictable long-term results for our customers." Only two members of the management at TRI Dental International are former employees of Institut Straumann AG: CEO Tobias Richter was former Director for Marketing (Europe) and CTO Sandro Venanzoni was former Head of Product Management Computer Guided Surgery at Institut Straumann AG. The mentioned other members of the TRI Dental management have joined the team from other leading implant companies.

2. Statement B: "(...) which enables us to integrate the tapered implant body guarantees better primary stability compared with the parallel-walled Straumann tissue-level implants."

This statement is based on clinical experience only with the TRI tapered bone level implant that has the same implant body as the TRI tissue level implant, but is otherwise not yet proven by scientific evidence. TRI Dental Implants does not have scientific evidence to make statements concerning the primary stability of their implants compared with Straumann® implants.

3. Statement C: "Together with our TRI+ digital interface, the combination of bone and tissue level implants will guarantee the best long-term results both in the anterior and posterior regions, as well as for edentulous regions." TRI Dental Implants used the term "best long-term results" as a general marketing term that is not scientifically proven. TRI has specified this statement in an edited version of the article accordingly.

4. Statement D: "(...) to adopt the Straumann octagonal connection and enhance it with our TRI friction



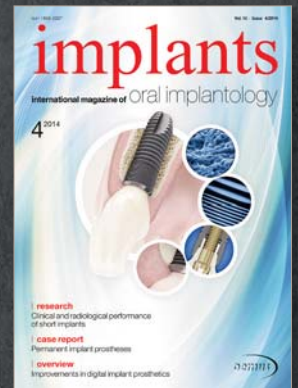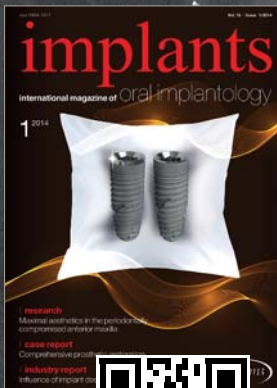[PICTURE: ©AMASTERPHOTOGRAPHER]

technology for the maximum implant abutment stability." This statement is misleading as the intent of this statement was purely to reference that TRI Dental Implants have only combined the octagonal connection initially developed by Straumann and has combined it with the existing TRI Friction technology of the TRI Dental Implant System. No reference to the performance in relation to Straumann was intended.

Source: TRI Implants/Dental Tribune

AD

**Dear authors, thank you for your contributions in 2014!**



To publish in 2015, please contact [g.isbaner@oemus-media.de](mailto:g.isbaner@oemus-media.de)

[PICTURE: ©SERGEY NIVENIS]



# Dental implant competitors shake things up

Author\_Kristina Vidug, USA

In 2013, the global dental implant market—composed of the sale of dental implant fixtures, final abutments and other devices—was valued at over US\$3.7 billion. The European market, valued at nearly one-third of the global market at close to US\$1.2 billion, contracted through 2014, as uncertain economic conditions continued to reduce procedure volumes and as more low-cost competitors entered the market, driving down prices.

These factors hampered the expected economic recovery and resumption of growth projected for 2013. As a result, the dental implant market will continue its decline before stabilising in 2015. Only then will the European market slowly begin to recover. Factors such as low gross domestic product growth and high unemployment continue to render dental implant procedures—which are primarily paid out of pocket by patients—cost prohibitive, while alternatives, such as bridges and dentures, that are perceived as more affordable will represent attractive options.

## Straumann's strategy

Dental implants were invented in Sweden; as a result, it is not surprising that a great number of premium manufacturers are based in Continental Europe. In the past, premium manufacturers, such as Straumann and DENTSPLY Implants, were able to rely on their long-standing reputations in the market and the high quality of their products to command higher prices than did some of their competitors.

More recently, however, some of the premium competitors have employed strategies to appeal to increasingly cost-conscious consumers. For instance, Straumann has reduced the price of its titanium implants by 15 per cent in Austria, Germany and Switzerland. While the price change only came into effect in the first quarter of this year, the strategy appears to have been effective because the company reported a six per cent rise in first-quarter revenue compared with a six per cent decrease in the same period last year.

The price reduction has come at a perfect time: while economic conditions begin to slowly improve, consumers are still extremely price sensitive. These price cuts therefore allow dental professionals to offer premium implant products to their patients at a reduced rate.

Straumann's price reduction is not its only foray into the value market. In the first quarter of this year, the company purchased US\$30 million worth of bonds from low-cost South Korean dental implant manufacturer MegaGen. The investment, which will be converted to shares in 2016, will help bolster Straumann's revenue while allowing it to participate in both the premium and value seg-



[PICTURE: ©SASHKIN]

ments, thus appealing to a wide range of practitioners and patients alike.

### The Zimmer–Biomet merger

Straumann is not the only company shaking things up in the world of dental implants. Zimmer Dental recently announced its acquisition of rival Biomet. While both companies are better known for their orthopaedic products, they are fairly significant competitors in the dental industry as well. Lay-offs are not uncommon when companies merge, especially when the companies in question offer the same types of products. This can have a negative impact on sales in the short term, as the newly conjoined companies' sale force decreases, leading clients to switch to other competitors.

However, this will not be the case with the Zimmer–Biomet merger, at least not in the short term, as the sales teams from both companies are expected to be retained through the merger. The cost of retaining both sales teams has been estimated at US\$400 million. While the effect of this acquisition on the market remains to be seen, the fact that the sales force will not be decreasing bodes well for the newly merged companies, likely resulting in an increased market share in the dental implant segment.

### Great deal of activity

There is discussion of merger and acquisition activity among other companies in the segment too, with Nobel Biocare reportedly in talks to sell to private equity firms and strategic buyers. While these talks are still in the very early stages, what is certain is that there has been a great deal of activity in the competitive landscape in the past several years.

This, combined with the afore-mentioned economic factors, is turning this once stable and mature market into a dynamic, action-filled space. With the dental implant market set to rebound in Europe and with revenues expanding in other countries—particularly in the rapidly developing BRIC and Middle Eastern markets—the global industry is poised for even further change, and the competitive landscape could look entirely different a few years from now.

about the author

**implants**

**Kristina Vidug** is Market Research Analyst at Decision Resources Group, a US-based market information provider. The company offers analysis and critical information on issues within the healthcare industry.

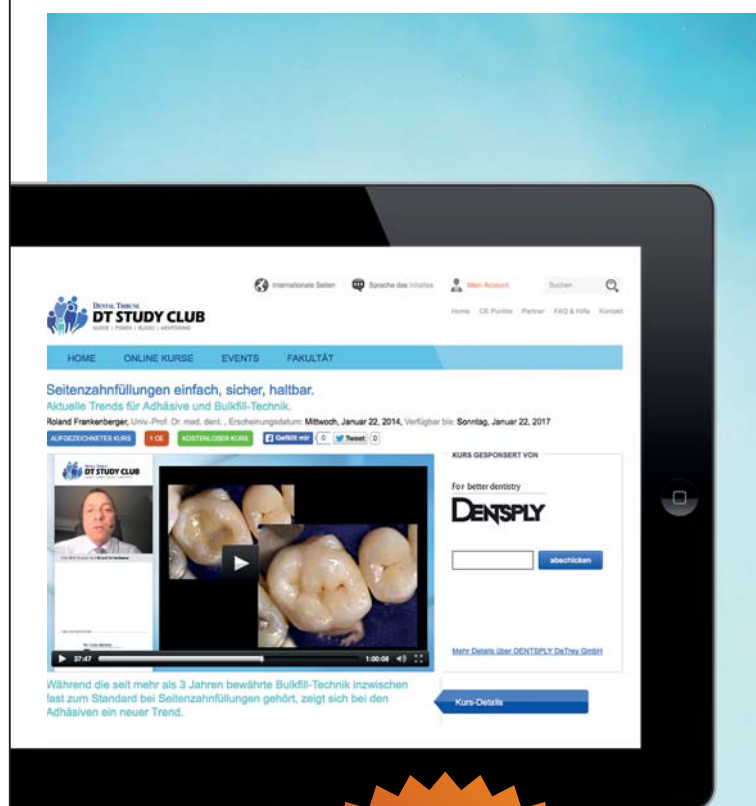
# Join the largest educational network in dentistry!

[www.DTStudyClub.com](http://www.DTStudyClub.com)



**DT STUDY CLUB**

COURSES | DISCUSSIONS | BLOGS | MENTORING



Register for  
**FREE!**

**ADA CERP**® | Continuing Education Recognition Program

**fdi** **diti** Dental Tribune International

ADA CERP is a service of the American Dental Association to assist dental professionals in identifying quality providers of continuing dental education. ADA CERP does not approve or endorse individual courses or instructors, nor does it imply acceptance of credit hours by boards of dentistry.

# Cost–benefit and affordability of dental implant restorations

Author\_Prof. Hugo de Bruyn, Belgium

[PICTURES: ©CREATIONS, ©PATHDOC]

**\_Nowadays, dental implants are well established** in daily practice and are well known and accepted by the public. They allow anchorage of removable and fixed dental prostheses in a predictable way. The efforts of scientists in collaboration with the implant industry have led to continuous improvement in clinical outcomes owing to the modification of implant surfaces, implant design and prosthetic connections. Together with a better understanding of biology, these developments yield fewer implant failures despite the usage of implants in compromised or at-risk patients.

In their consensus reports, the European Association for Osseointegration (EAO) stressed the need for additional research in the field of patient-centred treatment outcomes, including the economic impact of implant restorative treatments.<sup>1</sup> Patient-centred outcomes consider a number of parameters that are not always objectively measurable, in contrast to implant survival, bone loss, peri-implant health and incidence of complication, for example. Patient-centred outcome variables include patient satisfaction with a given treatment, improved masticatory ability and aesthetics, the absence of speech problems and the subjective evaluation of oral health-related quality of life.

## **\_Greater attention to cost–benefit**

In light of a growing interest in health economics, greater attention is also being given to the cost–benefit of tooth replacements. In economics, cost–benefit analysis compares the cost of making a product or delivering a service to the direct benefit to the individual or the society, including the revenue, the product or service will generate in the long term. Applied to dental or medical care, this analysis would have to consider resource expenditure relative to potential medical benefits, such as longer survival, reduced pain or morbidity, and greater comfort. Such an analysis would seek to determine the best choice considering limited resources, and it would weigh the possibility of undesirable outcomes and side-effects against the potential of a positive treatment outcome.

A cost–benefit analysis would consider these aspects together with the costs involved in terms of chair time, patient-related time, handling complications, and satisfying patients' expectations and preferences. It has become a part of the process of determining necessity in delivery of qualitative care and it brings the patient to the centre of decision-making. In dental science, these aspects are largely uncovered.

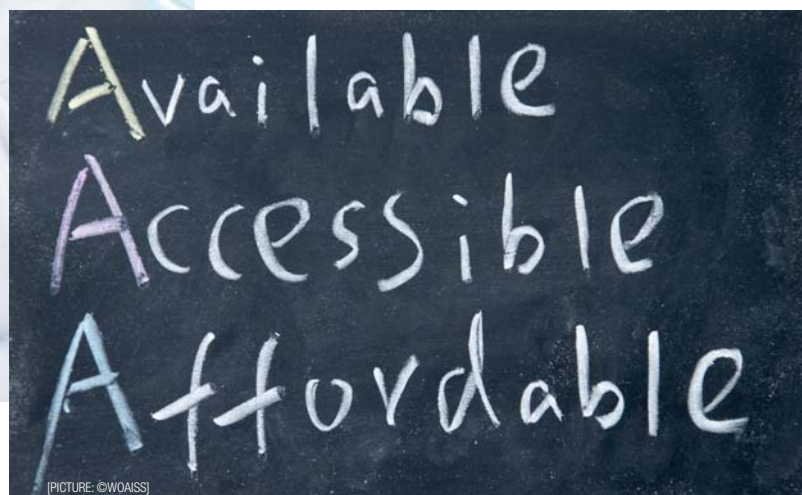



implants, believing that ceramics are better than acrylic teeth, and regarding aesthetics as being of sole importance.

### **\_The best option**

Long-term clinical studies demonstrate that a single implant is the best option for a missing tooth. It has a greater initial cost, but has a survival rate of above 95% and can be considered more cost-effective than a three-unit conventional bridge.<sup>3</sup> Studies have also found that implant-retained overdentures are worth the price given the increase in quality of life and treatment satisfaction. Further-



### **\_Tooth replacement**

In the context of implant treatment, it is well established that edentulousness and wearing of a complete denture have a number of negative physiological, functional and psychosocial effects. These influence oral function and aesthetics, as well as satisfaction, self-esteem, body image and quality of life.<sup>2</sup> Consequently, improving the retention of a denture by fixation on to two to four implants or the fixation of a fixed complete dental prosthesis on to four to six implants has a tremendous effect on oral health-related quality of life. However, adaptation to tooth loss varies individually and many patients cope very well with fewer teeth and do not always desire replacements, let alone dental implants.

In Europe, the demand for tooth replacement is increasingly based upon normative and theoretical grounds and not always on patient-specific assessment. Clinicians are often stuck in dogmatic, non-evidence-based thinking. Often, they impose their personal view concerning the suggested treatment option. Some examples to illustrate this are favouring long implants and bone grafting instead of short implants, believing that the more implants the better, favouring over-dentures on connected

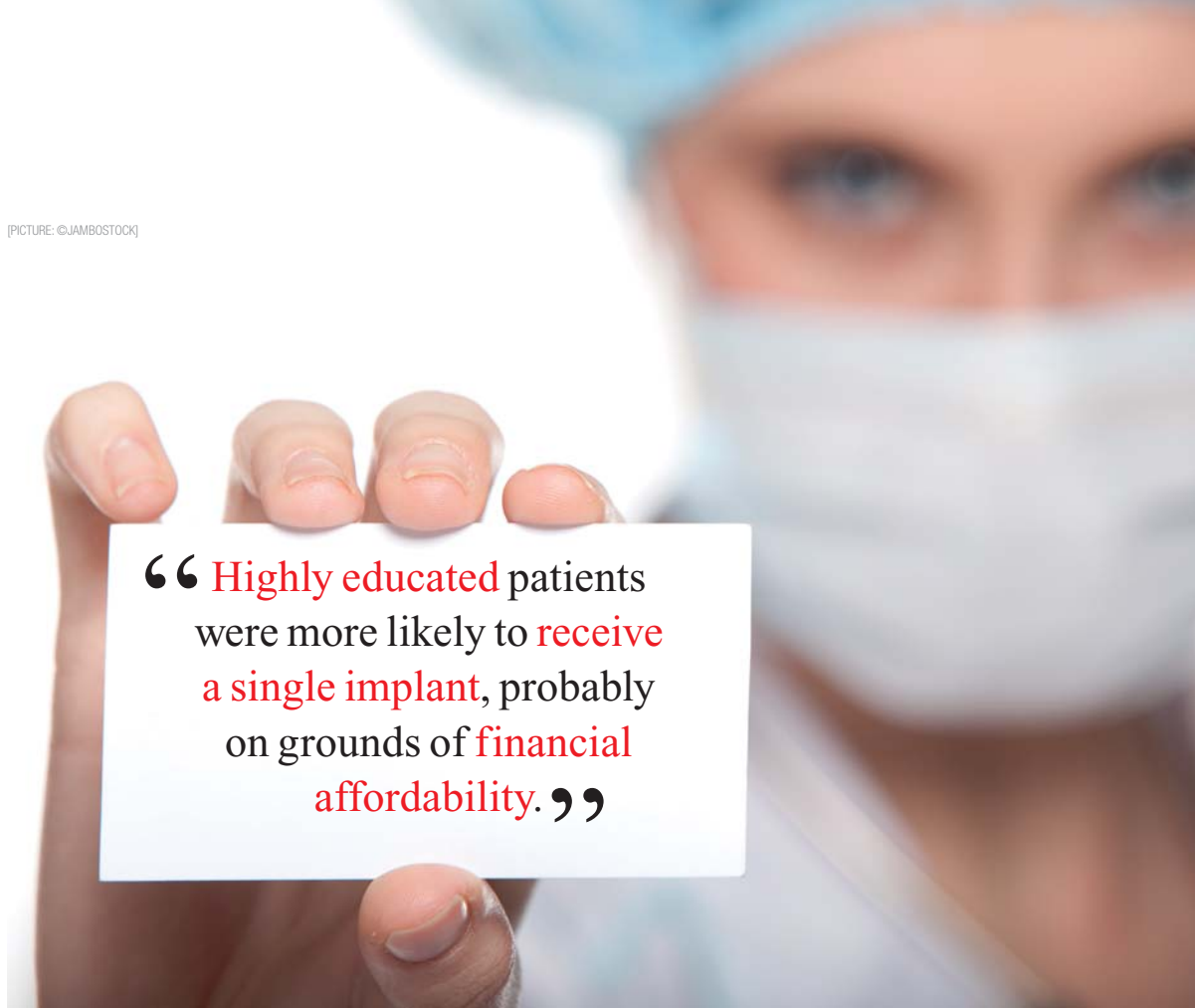more, when patients' resources are limited, the two-implant solution is a better option from a cost-benefit perspective than a fixed dental prosthesis on four to six implants.

Unfortunately, patients' financial situation imposes a significant barrier to treatment choice. Although dental implants have become a mass product, the price does not reflect normal economic trends in price reduction. On the contrary, prices rise yearly. The high-tech evolution of 3-D radiographic analysis, the use of stereolithographic-guided surgery, the need for individualised aesthetics, and the increased use of additional regenerative procedures have all further increased the total cost. Although these techniques offer the ability to facilitate surgery and enhance aesthetics, the cost aspect is seldom taken into account.

### **\_Affordability of implant treatment**

One can question whether this does not lead to exclusive treatments for the happy few. In Europe alone, every year close to one million patients become completely edentulous. It is unlikely that they can afford dental implants. Research in Austria has

[PICTURE: ©JAMBOSTOCK]



“ **Highly educated** patients were more likely to **receive a single implant**, probably on grounds of **financial affordability**. ”

found that the average person considers implants too expensive and blames the dentist for the high price.<sup>4</sup> Additionally, 59% of the patients expected a lifetime longevity. A previous study showed that 23% of the patients would not opt for implants at all.<sup>5</sup>

Another study assessing treatment advice given after tooth extraction by Flemish general dentists in Ghent demonstrated that replacement was not recommended in 42% of cases. Of the remaining cases, 54% opted for a removable appliance and only one-fifth received advice for a single implant crown. It appeared that highly educated patients were more likely to receive a single implant, probably on grounds of financial affordability. Hence, despite evidence that a single implant is the best, cost-effective way to replace a missing tooth, it is seldom advised. It is obvious that other patients' and clinicians' arguments prevail in the decision-making process.<sup>6</sup>

**\_What the future brings**

Given the current economic situation, dental health care expenditure will probably slow down or even be reduced. With budget cuts and savings deemed necessary in the EU for the coming decade, an insecure situation or the perception thereof by many patients will require difficult choices. In many countries, national health or private insurance seldom reimburses patients for implant prostheses,

leading to large groups of patients requiring replacements but being without the means to pay for them. The remaining patients can afford dental implants, but have high and often unrealistic expectations regarding the device and are very critical.

It is a challenge for clinicians to deal with these economic factors and offer good treatment to as many patients as is feasible. The clinician should advise the patient which treatment option is preferable based on individual risk assessment, but the patient's preferences, including financial affordability, and the long-term cost-benefit aspects are gaining importance and cannot be neglected. \_

*Editorial note: A list of references is available from the publisher.*

**\_about the author** **implants**

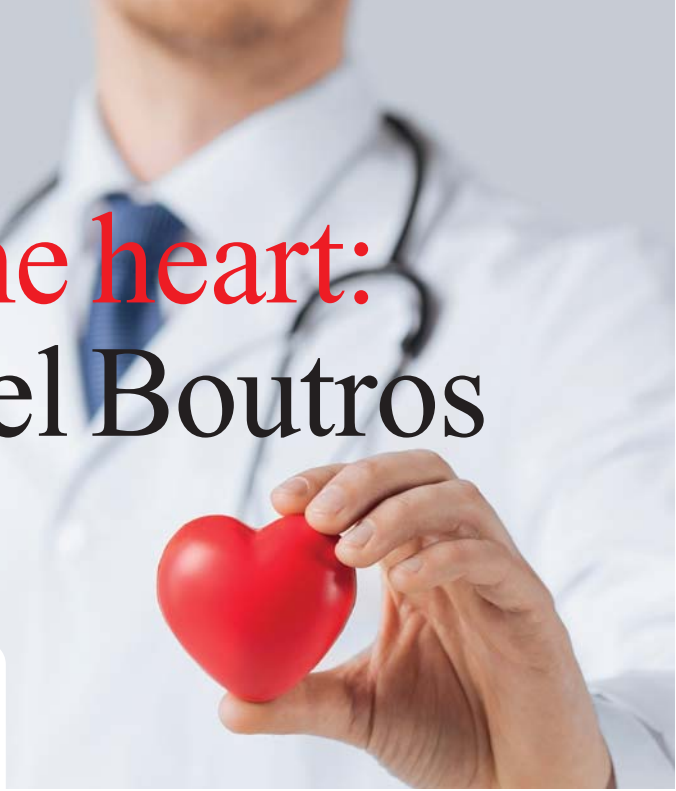

**Prof. Hugo de Bruyn** is Chairman of the Department of Periodontology and Oral Implantology at Ghent University Hospital in Belgium. As part of the EAO 2014 scientific programme, he presented a paper on cost-effectiveness.





# Dentistry from the heart: Dr Suheil Michael Boutros



*What can you tell us about your background?*

I am a graduate of University of Detroit Mercy School of Dentistry in Detroit, Michigan, and earned my Master's degree and specialty certificate in periodontics from the University of Minnesota School of Dentistry. I have been in private practice since 1996, with offices in Grand Blanc, Clarkston, and Flint, Michigan. In addition, I have been on the Dean's faculty at the University of Michigan School of Dentistry in Ann Arbor, Michigan, since 2002.

*Is your practice limited to implants?*

We offer the full scope of periodontal therapy, including regenerative therapy and periodontal plastic surgery, in addition to a strong emphasis on advanced bone grafting and dental implant surgery.

*Why did you decide to focus on implantology?*

During my residency in the early 1990s, I witnessed the need for dental implants and the future of helping edentulous patients restore their functionality and improve confidence. I became well

trained in placing dental implants. Once I started in private practice, I continued to attend continuing education courses to further educate myself on the innovative improvements in the industry. At that time, I launched our own dental study club after seeing the need to further educate the dental professionals within our community.

*How long have you been practicing, and what systems do you use?*

I have been in full-time private practice limited to periodontics and implant surgery since 1996. Over the years, I have worked with several systems, but I mainly use Zimmer®, BIOMET 3i™ and a few Nobel Biocare®.

*What training have you undertaken?*

After graduating from dental school, I completed three years of postgraduate studies in periodontics at the University of Minnesota where I earned a MS degree. Since I completed my residency, I have attended numerous continuing education courses, including hands-on courses. Now I present several hands-on courses as a faculty member at the Zimmer Institute and BIOMET Institute for Implant and Reconstructive Dentistry (IIRD). I have been involved with several implant organizations, and in addition to the American Academy of Periodontology, I am an active member of the Academy of Osseointegration and the American Academy of Implant Dentistry.

*Who has inspired you?*

My father was a true inspiration in my life. He always encouraged me to work hard and to see every challenge as an opportunity to grow. I have carried the values he has instilled in me every day in business and my personal life. Of course, I would not be here today without the continuous support of my

[PICTURE: ©SYDA PRODUCTIONS]

**Fig. 1** \_Dr Suheil Michael Boutros.

**Fig. 2** \_The surgical suite during implant surgery at Dr Boutros' Grand Blanc office.



Fig. 1

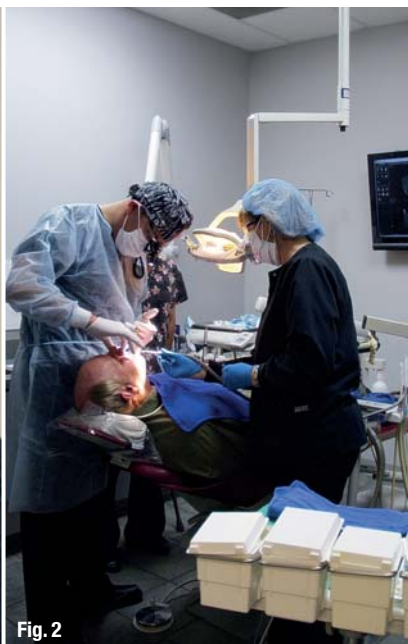

Fig. 2

wife and our two children. Professionally, I value my mentors at the University of Minnesota and especially my graduate periodontology program director, Dr. James Hinrichs.

*What is the most satisfying aspect of your practice?*

I love what I do! We treat every patient like a friend or a family member. Our patients become part of our family, and since we have a periodontal practice, we get to see long-term successful implant therapy outcomes. We do a lot of volunteer work for the community and through a programme called "Dentistry from the Heart." I was able through a generous grant from BIOMET 3i™ to place multiple implants and restore patients' function and aesthetics.

*Professionally, what are you most proud of?*

Recently, I was inducted as a Fellow of the Academy of Osseointegration, which is a great honour and recognition.

*What do you think is unique about your practice?*

I am very proud of my great staff that has made our practice an elite practice. Our great relationship with our referring offices has made our office the go-to office in the community. Also, our corporate partners, where I am a consultant for Zimmer Dental and lecturer and opinion leader for BIOMET 3i™ makes our practice a progressive and a cutting-edge technology practice.

*What has been your biggest challenge?*

Balancing between the busy professional life and family. Since I am on the faculty at the University of Michigan, I would like to find more time to spend with the graduate students. Last, continue to incorporate new technologies in our office.

*What would you have become if you had not become a dentist?*

A physician and more specifically, an orthopaedic surgeon.

*What is the future of implants and dentistry?*

Definitely CAD/CAM restorations. In addition, I would say Zimmer Trabecular Metal implants. Because of their successful long-term history in orthopaedics, treatment time has been reduced significantly, and made treatment possible in some of the medically compromised patients that otherwise would not be able to receive implant therapy.

*What are your top tips for maintaining a successful practice?*

First, treat everybody the way you like to be treated. Second, maintain a great communication



Fig. 3



Fig. 4



Fig. 5

and relation with our referring offices and continue to grow our study club that allows us to update our referrals on the latest technologies and products.

*What advice would you give to budding implantologists?*

Find a mentor if you are just starting out. Stay within your comfort zone, and always have an exit strategy. I can't emphasize enough the importance of diagnostic tools and treatment planning and taking more continuing education and hands-on courses. Last, have well-trained staff.

*What are your hobbies, and what do you do in your spare time?*

Travel with my wife and our two children. I like to ski, swim, and boat.

*Editorial note: Reprinted from Implant Practice US Volume 7, Number 4.*

**Fig. 3** The staff of Periodontal Specialists of Grand Blanc, Clarkston, and Flint, Michigan.

**Fig. 4** Dr Boutros doing an implant consultation at his office, explaining the benefit of dental implants to a patient.

**Fig. 5** Dr Boutros and his wife, Gada, in Venice, Italy.

**\_contact**

**implants**

**Suheil Michael Boutros, DDS, MS**

8185 Holly Road, Suite 19  
Grand Blanc, Michigan 48439

Tel.: +1 810 695-6444

smboutros@periodonticsonline.com  
www.PeriodonticsOnline.com

# “Taking the advantages of digital dentistry to a new level”

Source\_3Shape

3Shape’s latest release of the TRIOS® digital impression solution was presented in Chicago Midwinter, where especially the new Shade Measurement and HD Photo features created a stir among dental professionals. The dentist Dr Simon Kold evaluated the new features.

*—Already before Chicago,* selected dentists were given the opportunity to try out TRIOS® in their own clinics. However, Dr Simon Kold of the Herning Implant Center went even further. Challenged by a difficult tooth discoloration case, he saw a unique opportunity to gauge the shade measurement against the conventional method. In the following interview, Dr Simon Kold spoke about his evaluation procedure and the results.

*—How did you evaluate the Shade Measurement feature?*

Quite coincidentally, at about the same time I was asked to try out the new feature, I was met with a perfect case that was quite demanding in terms of get-

ting the shades right. A young male patient, with otherwise perfect teeth, had a noticeably discoloured central incisor that he wished replaced. The fact that the case involved a solitary tooth, and it was at the front, put extra stress on achieving perfect shade matching to the existing teeth—so it was just the kind of case I needed to test the digital shade measurement method through a harsh trial situation.

*—Tell us about the actual test.*

The beauty of the test lays in its simplicity. Basically, I worked with my lab to create two new crowns for the same treatment, and then compared how each one looked in the patient’s mouth. One crown was created using the traditional method I always used before—i.e. by matching the shades manually and sending the found shade values plus patient photos to the lab. The other crown was created using the digital Shade Measurement and HD Photos.

*—What were your experiences with using these functionalities?*

Shade measurement couldn’t be easier, because it happens automatically while I am scanning. All the shades are stored in the impression, and I can display the shade values in the most significant tooth areas which I select. The photo feature is equally easy to use. Just position the scanner tip and snap the picture. In this case, I performed a pre-preparation scan and took an array of the feature to show aesthetic details. After preparing the tooth, I only needed to rescan over the prep area, because TRIOS® automatically merges new scans with the previous pre-preparation scan, saving me loads of time. At this stage, I took additional images to get a clear picture of the margin line area.

Fig. 1 Before treatment: the patient with a discoloured central incisor.

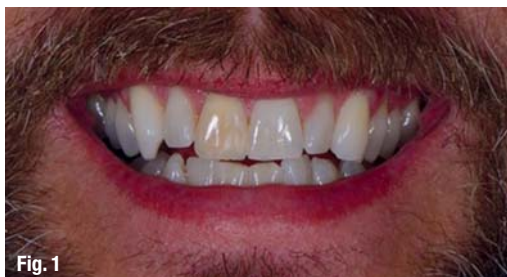

Fig. 1





[PICTURE: ©SERGEY NIVENS]

tient's mouth. However, on very close inspection and under optimal lighting, I noted very slight unintentional shadowing on the traditionally made crowns. So in this particular case—TRIOS® actually came out a slight winner.

*After the application of the measurement, what did you conclude?*

Well, first of all, I am very happy to know that I am equipped with a shade measurement solution that saves me an abundance of time and let me achieve results that are at least as good as the slower and less handy traditional method. Just to double-check our findings, we ran a similar test with another patient shortly after—and ended with a similar positive outcome. The great thing about the new features is that they allow me to easily convey more information along with significant details to the lab together with the digital impression—information I capture while I am scanning anyway. In our clinic, we have been taking almost all of our impressions digitally, and the benefits for our business have been enormous. But now, the direction 3Shape is taking by adding other functionalities that one can perform while scanning, is simply taking the advantages of digital dentistry to a new level.

*What results did you achieve?*

I work with a great lab, and I have always been taken aback by their ability to produce crowns with well-matched shades. Therefore, I was quite eager to see how this crown that was based on the shade measurement would cope against an equivalent shaded in the traditional way. To be honest—both crowns looked fantastic—on the model and in the pa-

Thank you very much for this interview.

[\\_contact](#)

[implants](#)

www.3shape.com  
info@3shape.com  
Tel.: +45 70272620

- Fig. 2** Before preparation of the tooth: Dr Kold performed a pre-preparation scan and took HD Photos to capture details about the original situation.
- Fig. 3** Scanning after preparation, with an additional HD Photo for easy margin-line detection during design.
- Fig. 4** On the TRIOS® screen, selecting the relevant areas on the neighbour incisor brings forth the captured shade values that the lab can use to make a well-matched crown.
- Fig. 5** Two crowns created: based on the Shade Measurement (left); based on the traditional shade-matching methods (right).
- Fig. 6** Comparison in the mouth: the crown in the top picture is based on TRIOS® Shade Measurement, and crown in the bottom picture is based on the traditional shade-matching methods.
- Fig. 7** Seated: the final crown based on the Shade Measurement.

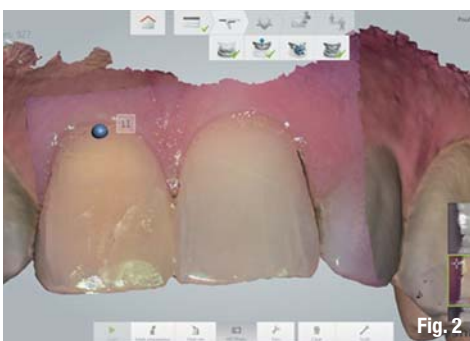


Fig. 2

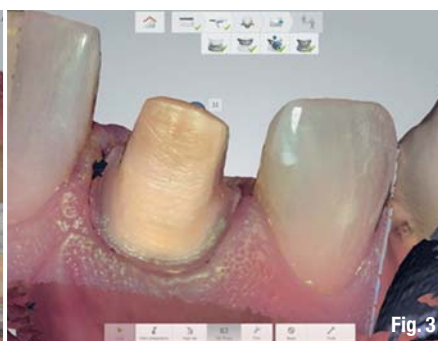

Fig. 3

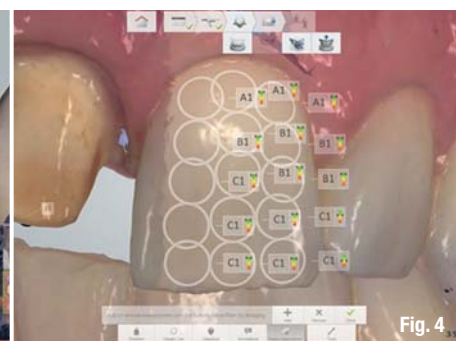

Fig. 4

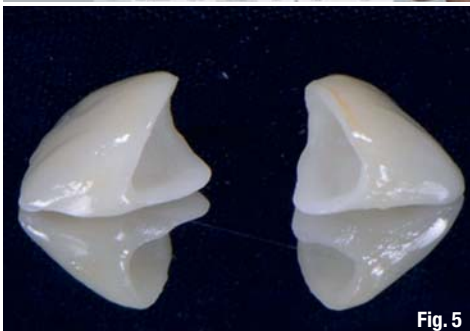

Fig. 5

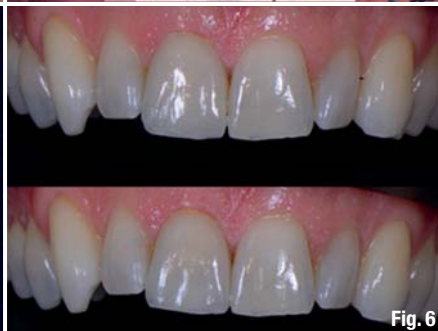

Fig. 6

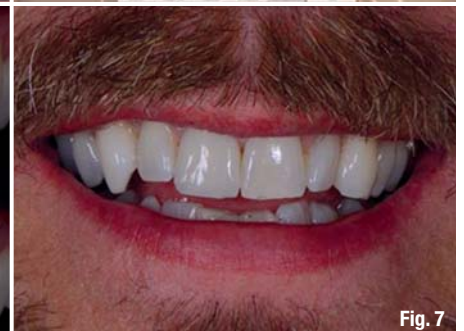

Fig. 7

# Is continuing education of implant dentistry sending the wrong message?

## The risk of extinction

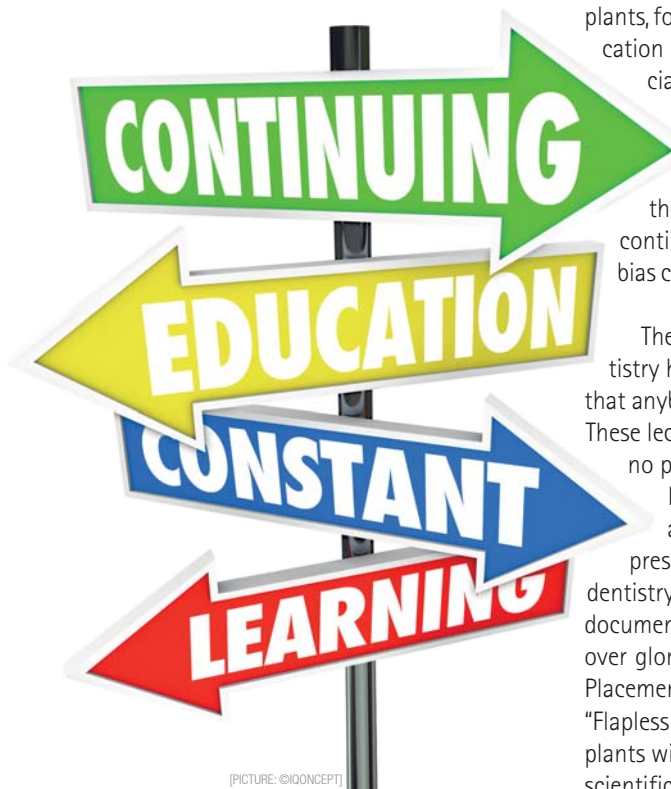**Authors** Dr Sebastian Saba & Dr Michael Moscovitch, Canada

Over the past few years, it appears that there has been an increase in continuing education. Many of the courses are about implant dentistry and the conventional courses that form the basis of learning the skills of saving teeth have been fewer in number. Obviously, everybody wants to learn how to surgically place a dental implant. It appears that some apparent "need" of patients has driven clinicians to subscribe to these weekend courses in surgery so they can respond to these patient "needs." However, patients see their

dentist regularly to save their teeth, not to have their teeth sacrificed for implant dentistry. Are we sending the wrong message here?

Originally all courses were provided by clinicians and researchers with a broad scientific support, justifying the concepts and designs for implant dentistry. Longitudinal and retrospective clinical data, scientifically based, were always presented to justify a design improvement, clinical protocol, or change in concepts like Submerged vs. Non Submerged Implants, for example. Lately, however, continuing education courses appear more sales oriented. Clinicians with biased viewpoints try to provide an objective view, but exhibit a clear conflict of interest, which generates doubt about their objectivity. Clinicians today therefore find it more challenging to select a continuing education programme that lacks any bias conclusions.

The whole marketing approach to implant dentistry has been to "oversimplify" the protocols so that anybody can place or restore a dental implant. These lectures appear to be purely mechanical with no prosthodontic considerations. Gone are the lectures showing long term data substantiating implant protocols and design. The presence of this oversimplification of implant dentistry and lack of academic control of scientific documentation has the dental field overrun with over glorified concepts like "All on 4", "Immediate Placement and Loading With Teeth in a Day", and "Flapless Surgery" all used in marketing dental implants without any respect for the prior established scientific data. There is a need for long term clinical



(PICTURE: ©I00NCEPT)

observations of dental protocols, materials, and surgical approaches. This provides key insight to diagnoses and treatment directions.

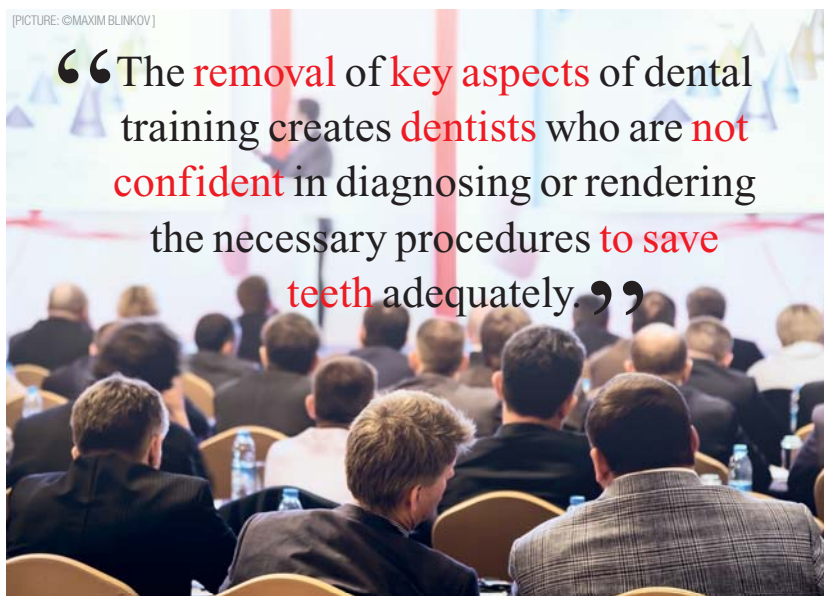Is continuing education a facade for marketing? In the absence of consistent scientific protocols, are 95% success rates, as previously promised, seen regularly? If not, what is the problem here? The lack of academic oversight has allowed the corporate community to introduce new products, designs, and concepts under the scientific radar. This oversight has provided an open invitation to "Cloned Implant Systems" or "Aftermarket Implant" companies of questionable origin, to infiltrate dental practices under the guise of "Compatibility" without any scientific information. The systems with questionable origin, scientific documentation, and quality control may be one factor contributing to reduced success rates.

Once the courses are completed, most clinicians receive the golden label of approval, a dental certificate of completion that they can hang on their dental mantel at the office. On Monday morning, they become changed and charged individuals. They have been pre-programmed to now look at patients as potential implant patients. Their approach to dentistry has changed overnight. In the past, they spent four to five years in dental school learning most of the skills to save teeth. These skills involve different forms of dentistry, not limited to periodontics, operative dentistry, or endodontics. They spent countless hours understanding how to negotiate root surfaces in debridement, root canal curvatures in endodontics and multiple techniques in operative dentistry to save teeth. But overnight, all that has changed. Why spend so much time saving teeth, when you can remove them and place a dental implant at half the time? Is this really better for the patient? Why burden the patient with multiple periodontal procedures to save teeth when the alternative is here?

This approach seems to be contagious in the thinking of clinicians today. Many are concerned that dentists are not promoting the right approach to saving the integrity of the natural dentition. This attitude is so contagious that even some endodontists are learning to place dental implants. Is this not a clear conflict of interest? What is their motivation? Are we doing enough to teach dentists how to diagnose and prognose the ailing dentition? When does the ailing dentition become a failing dentition? When is it appropriate to choose implant dentistry over conventional, time-proven and predictable conventional dentistry?

The removal of key aspects of dental training creates dentists who are not confident in diagnosing or rendering the necessary procedures to save teeth ad-

[PICTURE: ©MAXIM BLINKOV]



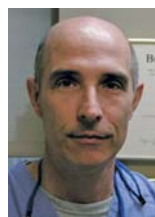equately. Their clinical skills in recognising and managing ailing dentitions are limited. Their ability to recognise when and where dental implants may be used can be influencing their ability or motivation to save teeth. Are we not creating a situation where we may not be doing what's best for our patients?

The way to address this issue is to exercise more caution when approaching continuing education. Choose your lecturers carefully, expect more from these sources of information, and learn more from your time commitments to continuing education. The true "need" should be to go back to basics and learn how to save teeth first, so patients are able to keep the most natural dental implant of them all.

**\_about the authors** **implants**



**Dr Michael Moscovitch** is an Assistant Clinical Professor, Division of Restorative Sciences, at Boston University, and Clinical Instructor, McGill University Residency Program at the Jewish General Hospital in Montreal. He also maintains a private practice in Montreal limited to prosthetics and implant dentistry.



**Dr Sebastian Saba** is the Editor-in-Chief of *Dental Tribune Canada*. He has a private practice in Montreal limited to prosthetic and implant dentistry.





(PICTURE: ©EZEPICS STUDIO)

# Simplifying dental implant treatment

Source\_EAO

From 25 to 27 September 2014, more than 4,000 people gathered for the 23<sup>rd</sup> European Association for Osseointegration's (EAO) scientific meeting in Rome. Dentists and industry specialists came from across the world to hear international experts describing the latest developments in implant dentistry.

## Interactive sessions

The three day meeting in Rome featured arena sessions exploring ways of simplifying dental implant treatment without compromising quality or predictability. This year's event saw a number of changes to the congress format. For instance, the main sessions

Fig. 1 More than 4,000 participants joint the 23<sup>rd</sup> EAO Congress.



## European Prizes for Clinical Research in Implant Dentistry

**Prosthetic Aspects.** Awarded to: Nicole Winitsky (Sweden): "Implant infra-position after 15-year follow-up of Brånemark implants in the anterior maxilla in young patients. A prospective cohort study."

**Surgical Aspects.** Awarded to: Yvonne De Waal (Netherlands): "Factors associated with success or failure of surgical peri-implantitis treatment."

**Basic Research in Implant Dentistry.** Awarded to: Yuelian Liu (Netherlands): "Osteoinductive biomimetic calcium phosphate bone substitute for bone regeneration."

**Poster Presentation.** Awarded to: Georg D. Strbac (Austria): "Thermal effects of a combined irrigation method during implant site drilling. A standardized *in vitro* study using a bovine rib model."

were held under a theme that ran throughout the whole event for the first time. In order to render the sessions more interactive, speakers presented in the form of a debate, offering different approaches to the same clinical problem. Attendees had the opportunity to contribute using an innovative voting system via their smartphones to express their opinion on a particular question.

## Awards for scientific research

There were also seven sessions where the best new scientific research was showcased. With 617 accepted submissions, a record number of abstracts were accepted for the congress in Rome. At a prestigious award ceremony, four European prizes for research in implant-based therapy were awarded for the best presentations and posters by Dr Bjarni Pjetursson, a member of the scientific committee, and EAO President Dr Pascal Valentini. During the scientific meeting, three



Fig. 2



Fig. 3

**Fig. 2** Marc Gadola, CEO Straumann, opened the Straumann Symposium as part of the EAO congress.

**Fig. 3** Werner Groll, Group Vice President DENTSPLY Implants.

candidates were also awarded the EAO's Certificate in Implant-based Therapy. This is the only Europe-wide standardised assessment of skills and expertise within the field of implant-based therapy. Before being awarded their certificate, each candidate submitted six clinical cases, and then sat a multiple choice examination, as well as being interviewed about their cases. Certificates were awarded to Kamil Khabiev, Algirdas Puisys and Gang Chen.

### Dinner at the Vatican

The social highlight was the EAO members' dinner at the Vatican. 300 people experienced an exclusive private tour of the Vatican Museums and Sistine Chapel before sitting down to a four-course meal surrounded by ancient Greek and Roman sculptures. Demand was so high that the EAO organised an additional private tour for a further 300 people who were unable to attend the dinner.

### Upcoming congress

The next scientific meeting will be held from 24 to 26 September 2015 at Stockholmsmässan, the Stockholm International Fairs and Congress Centre in Sweden, and will celebrate the 50<sup>th</sup> anniversary of dental implant treatment. The programme in Stockholm will reflect the progress the EAO has made over the last 50 years, as well as focus on current and emerging techniques. The sessions will educate participants on vari-

ous aspects of implant dentistry, including tissue regeneration, challenges of implant treatment for elderly patients, digital technologies, peri-implantitis and other complications with dental implants.

"There is a strong emphasis on practical clinical messages that dentists can use in their daily practice. We hope that this combination of historical perspective and cutting-edge techniques will ensure there is something of relevance for everyone," said president-elect Prof. Björn Klinge, who invited all of the participants to his hometown of Stockholm during the closing ceremony on Saturday afternoon.

Abstracts for the upcoming congress can be submitted from December 2014 until 1 April 2015.

|   |                 |
|---|-----------------|
| <u>background</u>   | <u>implants</u> |
| <p>Dental implants replace the root of a missing natural tooth, providing a secure foundation for a crown, bridge or other dental prosthesis. They are scientifically proven to be a reliable long-term treatment option for many patients.</p> <p>The European Association for Osseointegration (EAO) was founded in the early 1990s and its aim is to 'Bridge the gap between science and clinical practice'. It brings together researchers, scientists and dentists to discuss best practice in implant dentistry based on an evaluation of the scientific evidence.</p> <p><a href="http://www.eao.org">www.eao.org</a>   <a href="http://www.eao-congress.com">www.eao-congress.com</a></p> |                 |



Fig. 4



Fig. 5

**Fig. 4** Dr Bjarni E. Pjetursson, scientific head.

**Fig. 5** Richard T. Laube, CEO Nobel Biocare, and Melker Nilsson, also Nobel Biocare.



# On the test bench: Concepts for implantology

Author\_Dr Georg Bach



**Fig. 1** Prof. Dr Herbert Deppe, newly elected DGZI President, and Dr Roland Hille, DGZI Congress-President.

„Celebrating the 44<sup>th</sup> annual congress of a scientific society is in itself a special event—if one can additionally choose the beautiful scenery of a Rhine metropolis, an extraordinary combination is developed!“—Using these words, Prof. Dr Roland Hille, vice-president of the German Society for Oral Implantology (Deutsche Gesellschaft für Zahnärztliche Implantologie, DGZI), who was also congress-president, hits the point.

Not only the lucky number and the attractive location were special: On 26 and 27 September, both congress days were packed with high-demanding lectures, workshops, top-class speakers from Germany and abroad as well as partly controversial discussions. The event was held under the motto

“Nothing new? Concepts in implantology”, with more than 500 participants, that found their way to Düsseldorf.

Another highlight of the event was the members' assembly integrated into the annual congress. On this occasion, Prof. Dr Herbert Deppe (Munich) was elected new president of the DGZI. The experienced implantologist, researcher and university teacher is the successor of Prof. Heiner Weber (Tübingen).

## Discovering commonalities

For many years now, commonalities between implantology and laser dentistry are reported, especially when it comes to the establishment of private practices—also against the resistance of the universities. In view of this, a joint congress of the two societies DGZI and DGL (Deutsche Gesellschaft für Laserzahnheilkunde e.V.) was perfectly logical. With this, the societies had the opportunity to demonstrate their solidarity and furthermore show important intersections between implantology and laser dentistry.

At the end of the congress, DGL president Prof. Dr Norbert Gutknecht stated: “Despite the connection we are having for many years now as well as having





[PICTURE: ©OLIVER HOFFMANN]

done a lot of jointly and successful projects in the past, I am particularly impressed of how much we can still learn from each other!"

### Education

Already in 2012, the DGZI launched its initiative "Quality-oriented Implantology", which has caused a lot of attention in the dental and general public. Continuing this initiative, the DGZI has placed one of its main focal points on the implantological education in the past years. This does not only address implantological beginners but also experienced implantologists.

This theme was also dominant in different activities that were organised by the DGZI throughout the year and had also an influence on the annual congress, the DGZI curricula, the society's public relation as well as on activities of the society's study groups.

### Dental medicine—dental technique

"Activating the interface 'dental medicine—dental technique' is a matter of personal importance for the DGZI!" With this clear statement, Christian Müller, a master dental technician from Freiburg/



**Fig. 2** \_DGZI Board: (from left) Dr Valentin, Dr Bach, Prof. Dr Deppe, Dr Hille and Dr Vollmer.

**Fig. 3** \_The scientific programme attracted a lot of participants.

**Fig. 4** \_Dr Rolf Vollmer and his wife Dr Martina Vollmer at the DGZI booth.

**Fig. 5** \_During the breaks, there was a lot of time for collegial exchange.





**Fig. 6** (middle, from left) Dr Kobayashi, Dr Moriyama and Dr Kléncke were awarded for completing the DGZI educational programme "Specialist Implantology".

**Fig. 7** Prof. (CAI) Dr Roland Hille meets with Claudia Lindemann from the congress main sponsor OT medical.

**Fig. 8** Practical training during the congress workshops.

Breisgau, joined the DGZI board as the first non-dentist two years ago. An eloquent sign of this cooperation is the "Curriculum implant prostheses" that the DGZI carries out with the Fundamental GmbH and its maker Klaus Osten. Thus, this interface is an essential part of each congress in the form of the "Main Podium Special—Prostheses". Under the lead of Chairmen Prof. Dr Guido Heydecke (Hamburg) und PD Dr Friedhelm Heinemann (former DGZI president), six top-class presentations were given.

Master dental technician Joachim Maier presented the controversial topic "Full ceramics on implants" and demonstrated the reason for complications that often occur with this new material—which is wrong in his point of view. Joachim Maier rather pointed out that all forms of full-ceramic super structures have proven to be effective—in case

one knows the materials limitation and is able to control its machining. Indeed, consequent selection criteria, a good diagnosis and a close cooperation between dental technician and dentist are needed. Given these criteria, "zirconium oxide is working over many years!", Maier stated. Dr Kay Vietor followed this statement seamlessly with his presentation on "monolithic implant restorations with zirconium abutments". The ITI fellow could draw a positive summary after seven years of practical experience.

The prosthetic aspect was also present in the scientific programme on Saturday. Hereby, the presentation by Dr Julia Wittneben (Switzerland) is worth mentioning. In her lecture, Dr Wittneben spoke about her decision-making on the question "screwed or cemented super construction". In the last years, cemented crowns and bridges placed on implants dominated the fixed implant prostheses. Critical voices on this topic have been raised regarding the risks of a peri-implantitis caused by remaining cements ("cementitis"). During her lecture, Dr Wittneben could convincingly demonstrate the legitimacy of both procedures.

Prof. Florian Beurer, who is teaching at the university in Munich, spoke about a prosthetic topic, too: Aesthetics on implants. Normally, this issue is assigned to a good planning and surgery. Prof. Beurer pointed out a new aspect which is the influence of the used materials. In using relative new options that offer current materials as zirconium oxide on super constructions and mesial structures, dental restorations can be carried out which seemed inconceivable a few years ago.

### International exchange and networking

In addition to the focus on established practices, the international networking belongs to one cornerstone of the DGZI's philosophy. For many years now, close relationships exist to friendly associated societies in North America, Japan and the Arabian area. Colleagues from abroad are always present at the DGZI congresses and actively participate in the scientific programme. With this, another tradition—the "International Podium"—is established, which is an inherent part of the annual congresses.

The first speaker at this years International Podium was Prof. Dr Rolf Vollmer, vice-president and treasurer of the DGZI, who is responsible for the societys successful "foreign policy". In his presentation, Prof. Dr Vollmer spoke about the new high-performance plastic PEEK that can be used for many indications in the area of implantology. "The potency

of this new material in our scientific field is not yet fully understood", the DGZI vice stated. Prof Dr Vollmer is expecting an expansion of the PEEK-use in dental medicine and especially in implantology.

Prof. Dr Suheil Boutros (USA), Dr Mario Rodriguez (Mexico) and Prof. Dr Mazen Tamimi (Jordan) spoke about surgical topics. In his presentation, Prof. Dr Boutros discussed controlled bone-splitting as a real alternative to complex, expensive and with a higher morbidity associated augmentation procedures. In contrast, his colleague from Jordan, Prof. Dr Tamimi, pointed out the importance of implant key positions and especially a good diagnosis as basis for a stringent planning. Dr Wolf Ulrich Mehmke supported this demand in his lecture. The Mexican speaker Dr Rodriguez gave a comprehensive and systematic overview about aspects of the biological and functional integration of implants.

### Intensive discussion

"We can also have disputes in the DGZI. But if we are disputing, it is always constructive." The quote of the newly elected president Prof. Dr Deppe was fully met by this years Podium "DGZI controversial". After two talks by Dr Dr Manfred Nilius who is a proponent of the digital diagnosis and value chain, and Prof. Dr Dipl.-Ing. Ernst-Jürgen Richter who supports analogous implantology, the two speakers discussed about benefits of both approaches for patient and handler.

The discussion "Stone Age Implantology versus Computer Games" was moderated by Dr Bach. Both speakers, Dr Dr Nilius and Prof. Dr Richter, could convincingly prove the legitimacy for both concepts. Despite their countless differences, the speakers agreed that future generations of dentists have a clear affinity towards new digital procedures and know how to successfully implement them in their daily practice.

### Implantological diversity

At his opening greeting, Prof. Dr Hille referred to the importance of an intensive exchange of opinions, experiences and scientific knowledge. The times when scientific knowledge was exclusively gained by universities has long since passed. This was impressively proved by the "Corporate Podium". Whether new procedures (as nitrous oxide, augmentation with human bone blocks, one- or multi-piece ceramic implants and interim restorations) or proven concepts (as restorations of jaws with extreme atrophy)—the Corporate Podium included many practice-relevant insights and take-home messages.



At the end of the two-day congress, all participants agreed that the event was a whole success. The date for the upcoming meeting is settled already: On 2 and 3 October 2015, the 45<sup>th</sup> Annual Congress of the DGZI will take place in Wiesbaden.

**Fig. 9** Dr Bach moderated the debate "DGZI controversial".

**Fig. 10** Dr Dr Nilius (left) and Prof. Dr Richter (right) discussed about the benefits of digital and analogous implantology.

**Fig. 11** Focus on international networking: Colleagues from Japan participated at the DGZI congress as well.

### contact

### implants

#### DGZI main office

Paulusstraße 1  
40237 Düsseldorf, Germany

Tel.: +49 211 16970-77  
Fax: +49 211 16970-66

sekretariat@dgzi-info.de  
www.dgzi.de



# „Hold the profile of the DGZI and intensify contacts to other scientific societies”

Author\_Markus Brakel, Germany

On the 44<sup>th</sup> annual congress of the German Association of Dental Implantology (DGZI), Prof. Dr Herbert Deppe was elected president of the society by the members' assembly. For three years, Prof. Deppe was assessor of the executive committee. As associate professor for dental surgery and implantology he teaches at the TU Munich and due to his huge engagement he has a lot of contacts to other scientific societies and institutions in the dental world. In the following interview carried out by Markus Brakel, press spokesman of the DGZI, Prof. Deppe talks about goals and challenges concerning his presidency but also the DGZI in total.



Prof. Dr Herbert Deppe

*„Since your establishment, dental implantology has undergone a tumultuous development which is still continuing. As the oldest German implantological society, where do you see the DGZI's currently biggest challenges?”*

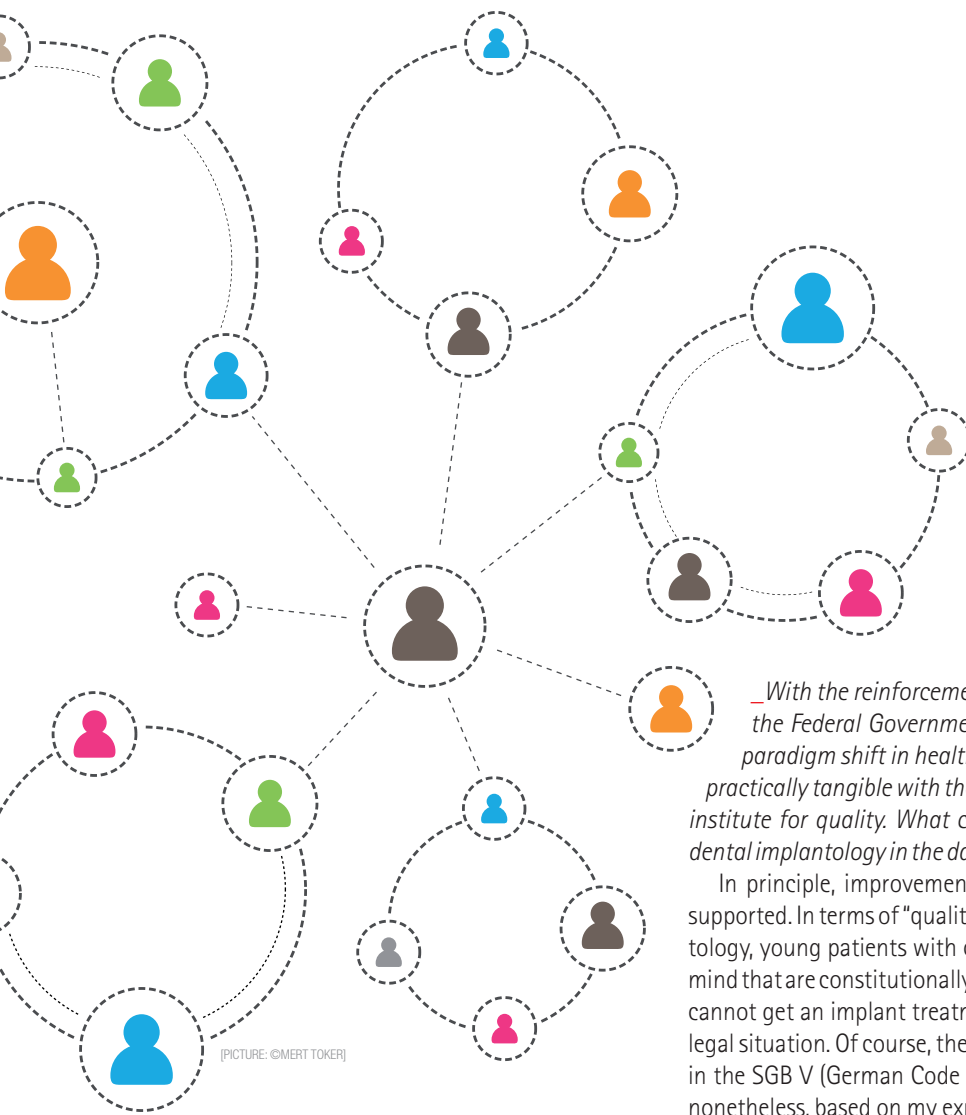
Prof. Deppe: In regard of the implantological societies, I see a big challenge in their strengthening. Spin-offs lead to small organisations with possibly only a few hundred members, which are not taken seriously anymore. Such negative consequences can be seen on the part of the trade unions. For me it is important to tackle this in a cooperative way. The difficulty of establishing this cooperative thought becomes clear when thinking of the joint event of the big implantological societies in Munich planned in the year before which unfortunately failed to come about. That's pretty sad, I think.

For science, development has to focus on materials research on the one hand—especially in the area of high-performance ceramics—but also on the bioligisation of implants on the other hand. This means: moving away from “death material” towards the “tooth from the test tube”. Experiments on mice do already point the way for how to grow a “third teeth”. This is one of the challenges science has to face.

Speaking of education, a training of all those who have not dealt with implantology yet is very important to me—this especially includes the dental technicians. From my point of view, the DGZI is a leading force in the integration of dental technicians.

*„Which goals did you set yourself for your presidency?”*

In the first place, I want to move forward the intensification of the contacts with other specialised fields as periodontology or colleagues from prosthetics and biomechanics. Thereby, I would like to extend the already existing personal contacts and those of the DGZI; here is still something to do. As leading author or co-author of three guidelines of the DGZMK, I have good contacts to other specialised fields as the German Association for Periodontology, which I would like to win for joint congresses.



Furthermore, it is my heartfelt concern to intensify the collaboration between the oral and maxillo-facial surgeons and the dental profession. Of course, this should be understood at the disposal of the patients' health in order to search for the patient's best solution as a team. Hereby, I would propose the excellent cooperation of the DGMKG and the BDO in Bavaria as a leading example.

*Keyword: international contacts. The DGZI has a close connection especially to Japan. Which importance has the professional exchange across state borders for you?*

International contacts exist—as you already said—traditionally in the DGZI especially to colleagues in Japan and Switzerland. However, we are also strongly connected with the Arabian area. At the moment, I think that the strengthening of the already taken paths is more important than getting worked up over something new. Especially in the Arabian area this is currently not easy. This is also what we notice at the TU where it is difficult to keep in contact with the local universities, since over there was not only an awakening of spring but also some icy breeze, which makes it not easier in all cases. Therefore, I would be happy if we could address this topic intensively within the executive committee.

*With the reinforcement of the factor quality, the Federal Government of Germany plans a paradigm shift in health policy which becomes practically tangible with the foundation of the new institute for quality. What could this mean for the dental implantology in the daily practice?*

In principle, improvements in quality should be supported. In terms of "quality" in the area of implantology, young patients with cleft palate come to my mind that are constitutionally lacking teeth and often cannot get an implant treatment due to the current legal situation. Of course, there are exceptional cases in the SGB V (German Code of Social Law V), which nonetheless, based on my experiences, are too much restricted. I can imagine that the DGZI will contribute to this. Future will show if there can be achieved a solution with the new quality institute.

*Which profiles should the DGZI gain during your presidency among the scientific societies in the long run?*

There is no need to reinvent the DGZI. We should tackle things in all modesty. Thereby, the DGZI has a distinctive profile: the society has always seen itself as representative of the practising colleagues as well as the universities, where special credits go to my predecessors. For me it is out of the question that we will further carry out award ceremonies for doctoral theses and offer curricula to university and practice. However, we want to stick to our values which are on the one hand letting established practitioners feel at home in the DGZI and on the other hand stick to the clear scientific demand of our society. One could say: In old spirit to new goals! Thereby, a personal remark should be allowed: We have to remind ourselves day-to-day that we have one of the greatest professions. Here, modesty is called for. This also includes the insight that one or another step is better made by someone else and thus react accordingly. With this in mind, I would go along with the executive committee: Keep your feet on the ground—and keep reaching for the stars!

**Many thanks for this interview!**

# bone & tissue days 2014

Author\_Georg Isbaner



Fig. 1\_botiss biomaterials and Straumann (from left to right): Oliver Bielenstein (botiss), Marc Gadola (CEO Straumann) and Dr Drazen Tadic (botiss).

Figs. 2 & 3\_With more than 65 speakers and about 20 workshops, an ambitious further education training was put together.

From 18 to 20 September, more than 800 international participants joined the bone & tissue days in Berlin. With more than 65 speakers and about 20 workshops, an ambitious further education training was put together in the area of dental augmentation techniques. Local experts and specialists from university spoke about new, innovative technologies, treatment and therapy concepts. Thereby, they were accompanied by live operations and practical exercises. The event was organised by the company botiss whose headquarter is in Berlin. A further topic of the congress was the recently established cooperation between Straumann and botiss.

Already in the first half of the year, botiss and Straumann announced their cooperation in the area of bone graft substitutes within the context of the ITI annual congress in Geneva. After an intensive phase of coordination, at a press conference in Berlin botiss announced that from now on, botiss can fully supply the worldwide biggest implant manufacturer in nearly all European countries and in America. Prior to this announcement, the logistical chain for the sensitive medical products was continuously expanded and employees of both companies were thoroughly trained on the products. Furthermore, botiss will help to distribute Emdogain®—a product for tissue regeneration by Straumann—in Germany from now on.

Straumann CEO Marc Gadola emphasised the specialty of this deal: "With this cooperation we have exclusive rights to distribute botiss products in nearly all European countries and America. Furthermore, we can also offer botiss products in Germany." Oliver Bielenstein, Managing Partner, botiss biomaterials, explained why this is a quite strong relationship: "We have the most comprehensive offer of clinically proven materials for oral tissue regeneration. This implies among others membranes for guided tissue and bone regeneration, a full set of bovine, allogeneic and synthetic bone graft substitutes as well as products for soft-tissue healing." The cooperation between the two companies will not be restricted to the area of products. As "The Straumann/botiss biomaterials Young Periodontal Professional of the Year"-award shows, the cooperation also includes a conceptual level. With the award, young dentist under the age of 35 shall be encouraged to stronger engage themselves in the area of periodontology. The price will be awarded at the next bone & tissue days in 2015.

\_contact

implants

**botiss dental GmbH**

Hauptstr. 28  
15806 Zossen by Berlin,  
Germany

Tel.: +49 33769 8841985  
Fax: +49 33769 8841986  
contact@botiss.com



# Dentium World Symposium

Author\_Georg Isbaner

On 24 and 25 October, the South Korean implant manufacturer Dentium invited to a two-day symposium in New York. More than 900 participants joined the event. Since 14 years now, Dentium which is after all number two in the Asian market has made itself a name with practice-oriented solutions and a full range of implant products.

## Scientific programme

On both congress days, internationally recognised experts from implantology spoke in the Marriott Marquis at the New York Times Square. The lectures dealt with issues of immediate loading, bone regeneration as well as hard and soft tissue management. On Friday, Dr Myron Nevins opened the symposium and led the numerous participants through the top-class programme.

## Innovation and practice

The second congress day started with a special speaker: Dr Sung-Min Chung, who is a recognised, practicing implantologist and at the same time CEO and founder of Dentium, illustrated by means of own patient cases the rich product range of the company. Dentium can be said to be a reliable full-service provider, be-

ginning with a broad surgical instrumentation, implantological auxiliaries as for example easily produced navigation templates and special devices, and ending with a comprehensive implant range and prosthetic materials. Above all, the company has dedicated itself to the simplification of working processes: Each abutment fits on all implant diameters of the manufacturer and thus ensures a simple and clear handling. The implants are optimally designed for Platform Switching, offer a solid internal conical connection and have a S.LA (Sandblasted with Large grits and Acid etched) surface. Prof. Dr Georgios Romanos appreciated the Dentium implant system for its high primary stability and wide variety of application. Actually, he assumes the manufacturer in being the worldwide number one implant line someday.

## Next events

For the upcoming IDS, Dentium will present some novelties. Furthermore, the company organises the next World Symposium in autumn 2015 that will be held in Shanghai. In 2016, the hosting country is already scheduled: Then, Dentium will invite everyone interested to Germany.

→ [www.dentium.com](http://www.dentium.com)



Fig. 1\_ From left: Dr Sang Chung Lim, Dr Sung-Min Chung, CEO and founder of Dentium, as well as Roy Kim, European Manager Dentium. – Fig. 2\_ More than 900 participants joint the two-day symposium.

Danaher Corporation publishes

## Public tender offer for publicly held shares of Nobel Biocare

On October 1, 2014, Danaher Corporation published the public tender offer for all publicly held registered shares of Nobel Biocare Holding AG with a par value of CHF 0.40 each, as announced on September 15, 2014. The offer price is CHF 17.10 in cash per registered share.

On September 14, 2014, Nobel Biocare's Board of Directors unanimously decided (with one member not participating) to recommend that Nobel Biocare's shareholders accept the offer of Danaher. The Board of Directors of Nobel Biocare reviewed the offer in detail and determined that the all-cash offer is in the best interests of Nobel Biocare, its shareholders, employees, customers and suppliers. The report of the Board of Directors regarding the offer has been published in the offer prospectus of Danaher today. N+1 Swiss Capital AG provided a fairness opinion for Nobel Biocare's Board of Directors in which it confirmed that the offer price of CHF 17.10 in cash per registered share is fair and appropriate from a financial point of view.

On September 29, 2014, the Swiss Takeover Board decided that the offer of Danaher is compliant with the statutory provisions relating to public tender offers. Danaher Corporation (NYSE: DHR) is a global science and technology innovator committed to helping its customers solve complex challenges and improving quality of life



around the world. Its family of world class brands have unparalleled leadership positions in some of the most demanding and attractive industries, including health care, environmental and communications. The company's globally diverse team of 66,000 associates is united by a common culture and operating system, the Danaher Business System. In 2013, Danaher generated \$19.1 billion in revenue and its market capitalization exceeded \$50 billion.

BPA exposure may contribute to

## Asthma development in children

In the past, bisphenol A (BPA), an endocrine-disrupting chemical that can also be found in dental composites and sealants, has been linked to a number of health conditions, including obesity, allergies and cancer. Now, researchers have found evidence that prenatal exposure to BPA is associated with diminished lung function and the development of persistent wheeze in children, which are indicators for asthma, one of the most common chronic childhood disorders.

In order to examine the effect of BPA on lung function and wheeze in children, researchers at the University of Maryland School of Medicine followed women through pregnancy and their children through age 5. In total, the study included 398 mother-infant dyads. They collected maternal urine samples at 16 and 26 weeks of pregnancy and maternal urine samples annually to assess BPA exposure.

According to the study, prenatal BPA exposure during early pregnancy was associated with diminished lung function, increased likelihood of wheeze, and a persistent wheeze phenotype in young children.

According to estimates by the Centres for Disease Control and Prevention, about 7 million children under the



age of 18 are affected. Although secondhand smoke and air pollution have been identified as factors for the development of asthma in children, the reasons for increasing rates of the disease in the past decades are still poorly understood by scientists. The present study thus provides new evidence that BPA may contribute to this development.

Dental technician

## sues actor Charlie Sheen

As New York Daily News reported, the US actor Charlie Sheen, best known for his role as Charlie Harper in the sitcom "Two and a Half Men" is being sued for sexual assault by a dental technician. The woman claims Sheen, under the influence of drugs, grabbed her breast and tried to tear off her bra at a dental office in Los Angeles. The actor attacked her during a dental appointment: The woman was trying to put on a mask for nitrous oxide on Sheen's face when he grabbed her breast and pulled at her scrubs and bra strap. The dental technician also claims that Sheen was high on a combination of crack cocaine, Theradol and alcohol. A representative of the actor, however, denied the accusations and said that Sheen had taken some pain medication prior to the appointment because he had suffered a shoulder injury, and suggested that this medication had apparently not mixed well with the nitrous oxide.

Sheen's lawyer, Marty Singer, told the newspaper that the story was entirely unreal and that the lawsuit was only filed for opportunistic reasons. Sheen has been hospitalised several times for substance abuse. He has faced a number of charges for assault, felony and criminal mischief in the past.



Neodent Spain and Neodent Portugal

## Join forces as Instrandent

In October, Neodent, the leading South American dental implant company, announced that the subsidiaries in Spain and Portugal will join forces on January 1, 2015, to serve customers as Instrandent Iberia SL.

The main objectives of the combination are to strengthen the Neodent brand in Iberia, to increase efficiencies between the countries and the Brazilian headquarters, and to deliver outstanding service to customers. Instrandent Iberia will maintain its Spanish office in Madrid and will open a new office for Portugal in Lagoas Park/ Porto Salvo.

Matthias Schupp, Executive Vice President Neodent, noted: "Neodent products have grown considerably in both countries. By combining the two subsidiaries, we will become even stronger, strengthening our professional back office and delivering first class service to customers."




Dr Sandro Matter, Executive Vice President Instrandent, stated: "In addition to offering outstanding product quality, Instrandent's goal is to make life easier for customers."

Although the two entities will operate separately for the remainder of this year, Mr Jorge Herrera, Neodent Director in Spain, will also lead the Sales and Marketing activities for Portugal from October 1, 2014.

Japanese researchers discover

## New antiseptic agent to fight periodontitis



after only 30 seconds of exposure. In addition, they observed that NBW3 had no significant impact on human oral tissue.

Conventional antibiotic therapies for treating periodontitis hold the risk of several side-effects, such as the development of bacterial resistance and adverse host reactions.

However, NBW3 is produced from ozone, which has strong antimicrobial activity against bacteria, fungi and viruses, and thus does not induce antimicrobial resistance. Ozonated water usually retains its potency for only a short period, but NBW3, which the researchers produced, using a patented technique, retains its oxidation ability for more than six months. This stability allows for the bottling and use of NBW3 as a disinfectant. Although the results of the present study are promising, these in vitro models cannot

In *in-vitro* experiments, researchers at Tokyo Medical and Dental University and the National Institute of Advanced Industrial Science and Technology in Japan tested the effectiveness of NBW3 against *Porphyrromonas gingivalis* and *Aggregatibacter actinomycetemcomitans*. They found that the levels of both bacteria dropped to below the lower limit of detection

be directly translated into clinical situations, in which NBW3's potency may be reduced by dental patients' saliva. Therefore, further research is needed.

DENTSPLY Implants

## Expands into new markets

DENTSPLY Implants expands into new markets and recently opened the first office in Beijing, China, a market where ANKYLOS and XiVE implant lines have been present and successful since 1998. In conjunction with the opening, the ASTRA TECH Implant System was introduced to the Chinese market.

From the perspectives of dentists per capita and dental implant penetration, China's dental industry is still relatively immature. But with the growing dental market size, especially the surge of high-end businesses such as dental implants, coupled with the consumption upgrading and the increasing awareness over dental health, China's dental industry is projected to maintain rapid growth.



"We are looking forward to this exciting development and potential growth in the very dynamic Chinese market," says Lars Henrikson, Group President DENTSPLY Implants.

However, China is not the only market in Asia where the company expands its business. "We are also preparing for the expansion of ATLANTIS abutments into several new markets, something I know many customers are waiting for. One of those new markets is Japan, where our abutments will be launched later this year," continues Lars Henrikson.



**implants**  
international magazine of oral implantology



**Publisher**

Torsten R. Oemus  
[oemus@oemus-media.de](mailto:oemus@oemus-media.de)

**CEO**

Ingolf Döbbecke  
[doebbecke@oemus-media.de](mailto:doebbecke@oemus-media.de)

**Members of the Board**

Jürgen Isbaner  
[isbaner@oemus-media.de](mailto:isbaner@oemus-media.de)

Lutz V. Hiller  
[hiller@oemus-media.de](mailto:hiller@oemus-media.de)

**Chief Editorial Manager**

Dr Torsten Hartmann (V. i. S. d. P.)  
[hartmann@dentalnet.de](mailto:hartmann@dentalnet.de)

**Editorial Council**

Prof. Dr. Herbert Deppe

Prof. Dr Kurt Vinzenz  
[kurt.vinzenz@aon.at](mailto:kurt.vinzenz@aon.at)

Dr Torsten Hartmann  
[hartmann@dentalnet.de](mailto:hartmann@dentalnet.de)

Dr Suheil Boutros  
[SMBoutros@aol.com](mailto:SMBoutros@aol.com)

**Editorial Office**

Georg Isbaner  
[g.isbaner@oemus-media.de](mailto:g.isbaner@oemus-media.de)

Katrin Maiterth  
[k.maiterth@oemus-media.de](mailto:k.maiterth@oemus-media.de)

Claudia Jahn  
[c.jahn@oemus-media.de](mailto:c.jahn@oemus-media.de)

**Executive Producer**

Gernot Meyer  
[meyer@oemus-media.de](mailto:meyer@oemus-media.de)

**Designer**

Sarah Fuhrmann  
[s.fuhrmann@oemus-media.de](mailto:s.fuhrmann@oemus-media.de)

**Customer Service**

Marius Mezger  
[m.mezger@oemus-media.de](mailto:m.mezger@oemus-media.de)

**Published by**

OEMUS MEDIA AG  
Holbeinstraße 29  
04229 Leipzig, Germany  
Tel.: +49 341 48474-0  
Fax: +49 341 48474-290  
[kontakt@oemus-media.de](mailto:kontakt@oemus-media.de)

**Printed by**

Silber Druck oHG  
Am Waldstrauch 1  
34266 Niestetal, Germany

**implants**  
**international magazine of oral implantology**  
is published in cooperation with the German  
Association of Dental Implantology (DGZI).

**DGZI**

DGZI Central Office  
Paulusstraße 1, 40237 Düsseldorf, Germany  
Tel.: +49 211 16970-77  
Fax: +49 211 16970-66  
[office@dgzi-info.de](mailto:office@dgzi-info.de)

[www.dgzi.de](http://www.dgzi.de)  
[www.oemus.com](http://www.oemus.com)  
[www.implants.de](http://www.implants.de)

**Copyright Regulations**

**implants international magazine of oral implantology** is published by Oemus Media AG and will appear in 2014 with one issue every quarter. The magazine and all articles and illustrations therein are protected by copyright. Any utilization without the prior consent of editor and publisher is inadmissible and liable to prosecution. This applies in particular to duplicate copies, translations, microfilms, and storage and processing in electronic systems.

Reproductions, including extracts, may only be made with the permission of the publisher. Given no statement to the contrary, any submissions to the editorial department are understood to be in agreement with a full or partial publishing of said submission. The editorial department reserves the right to check all submitted articles for formal errors and factual authority, and to make amendments if necessary. No responsibility shall be taken for unsolicited books and manuscripts. Articles bearing symbols other than that of the editorial department, or which are distinguished by the name of the author, represent the opinion of the afore-mentioned, and do not have to comply with the views of Oemus Media AG. Responsibility for such articles shall be borne by the author. Responsibility for advertisements and other specially labeled items shall not be borne by the editorial department. Likewise, no responsibility shall be assumed for information published about associations, companies and commercial markets. All cases of consequential liability arising from inaccurate or faulty representation are excluded. General terms and conditions apply, legal venue is Leipzig, Germany.

# 45<sup>TH</sup>

## INTERNATIONAL ANNUAL CONGRESS OF THE DGZI

**SAVE  
THE DATE**  
October 02-03  
2015

October 02-03, 2015

Wiesbaden, Germany | Dorint Hotel Pallas

Scientific Director: Prof. (CAI) Dr Roland Hille/DE

IMPRESSIONS  
44<sup>th</sup> INTERNATIONAL  
ANNUAL CONGRESS  
OF THE DGZI



Gold Sponsor

**ot**medical®

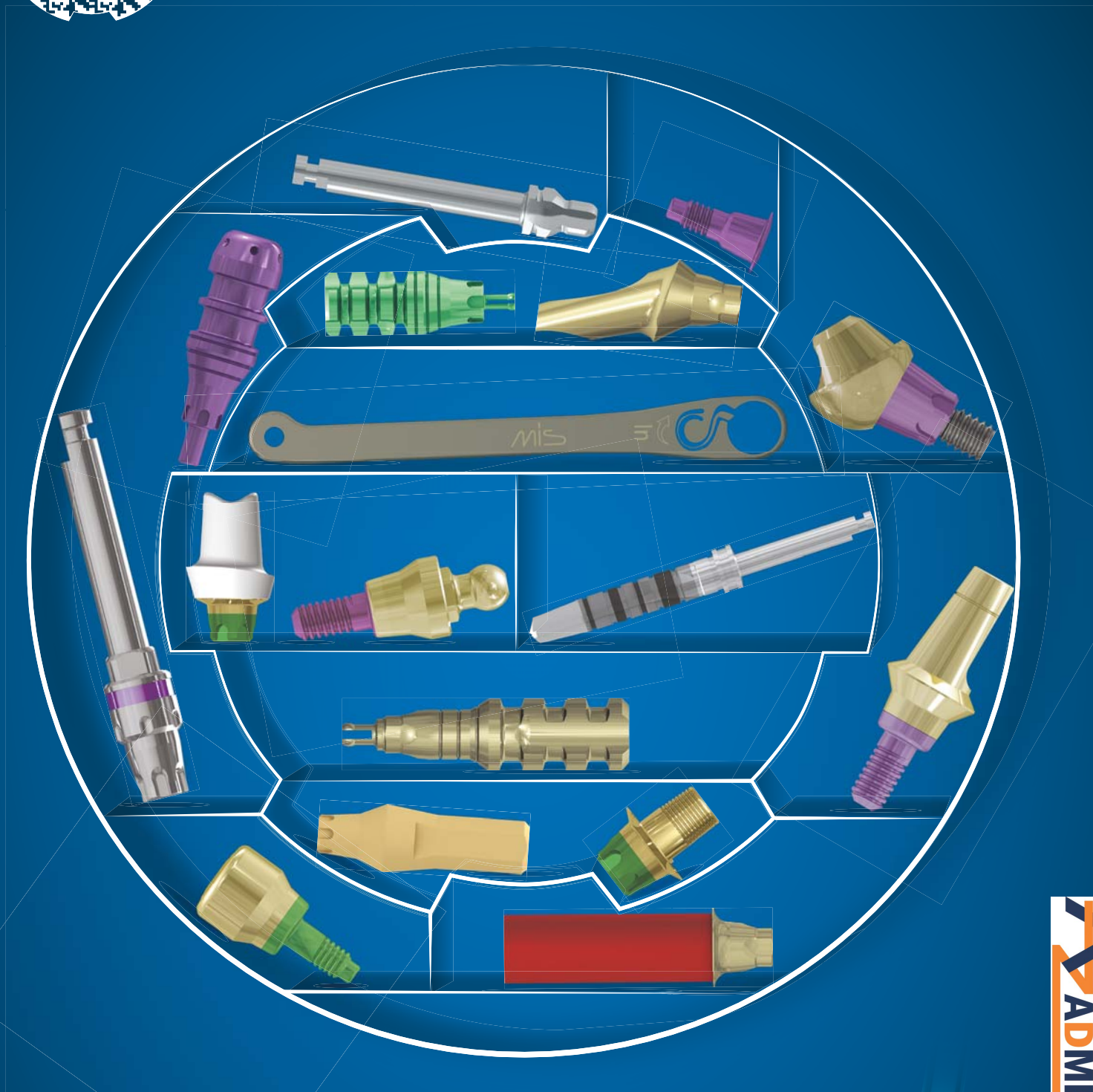
**DGZI**  
Deutsche Gesellschaft für  
Zahnärztliche Implantologie e.V.

**FAX REPLY // +49 341 48474-290**

Please send me further information on the  
45<sup>TH</sup> INTERNATIONAL ANNUAL CONGRESS OF THE DGZI  
on 02-03 October, 2015, in Wiesbaden, Germany.

Office Stamp





## COMPLETE IN EVERY WAY MAKE IT SIMPLE

The C1 Conical Connection implant system is suited for use with a comprehensive range of tools and complementary products engineered to make surgical procedures simpler and more efficient for high success rates and beautiful outcomes. To learn more about the C1 and MIS, visit: [www.mis-implants.com](http://www.mis-implants.com)

MIS<sup>®</sup>  
C1



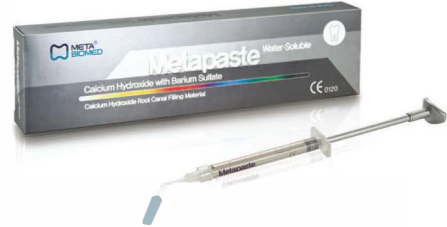



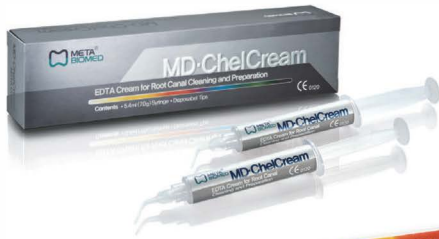• سیلر بیس رزینی  
ADSEAL



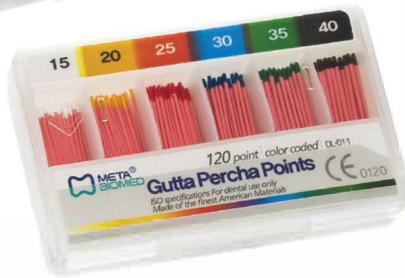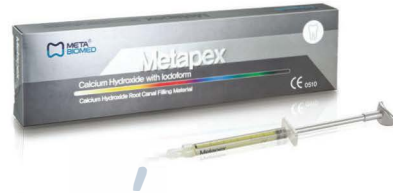• هیدروکسید کلسیم + سولفات باریم  
Metapaste



• ژل آرسی پرپ ۱۹٪  
MD.ChelCream



• هیدروکسید کلسیم + ید  
Metapex

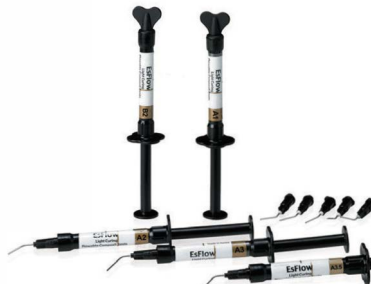

• گوتا پرکا  
Gutta Percha Point

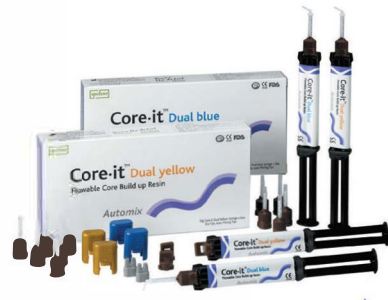- ISO sizes : 10, 15, 20, 25, 30, 35, 40, 45, 50, 55, 60, 70, 80, 90, 100, 110, 120, 130, 140
- Non-Standardized (Accessory sizes): XF, FF, MF, F, FM, M, ML, L, XL
- Special Taper Points : .04, .06, .08 protaper : F1, F2, F3



Base.it  
(بیس و لاینر) دایکال نوری



EsFlow  
کامپوزیت نانو فلو لایت کیور



Core.it  
کریبلد آپ دوآل کیور