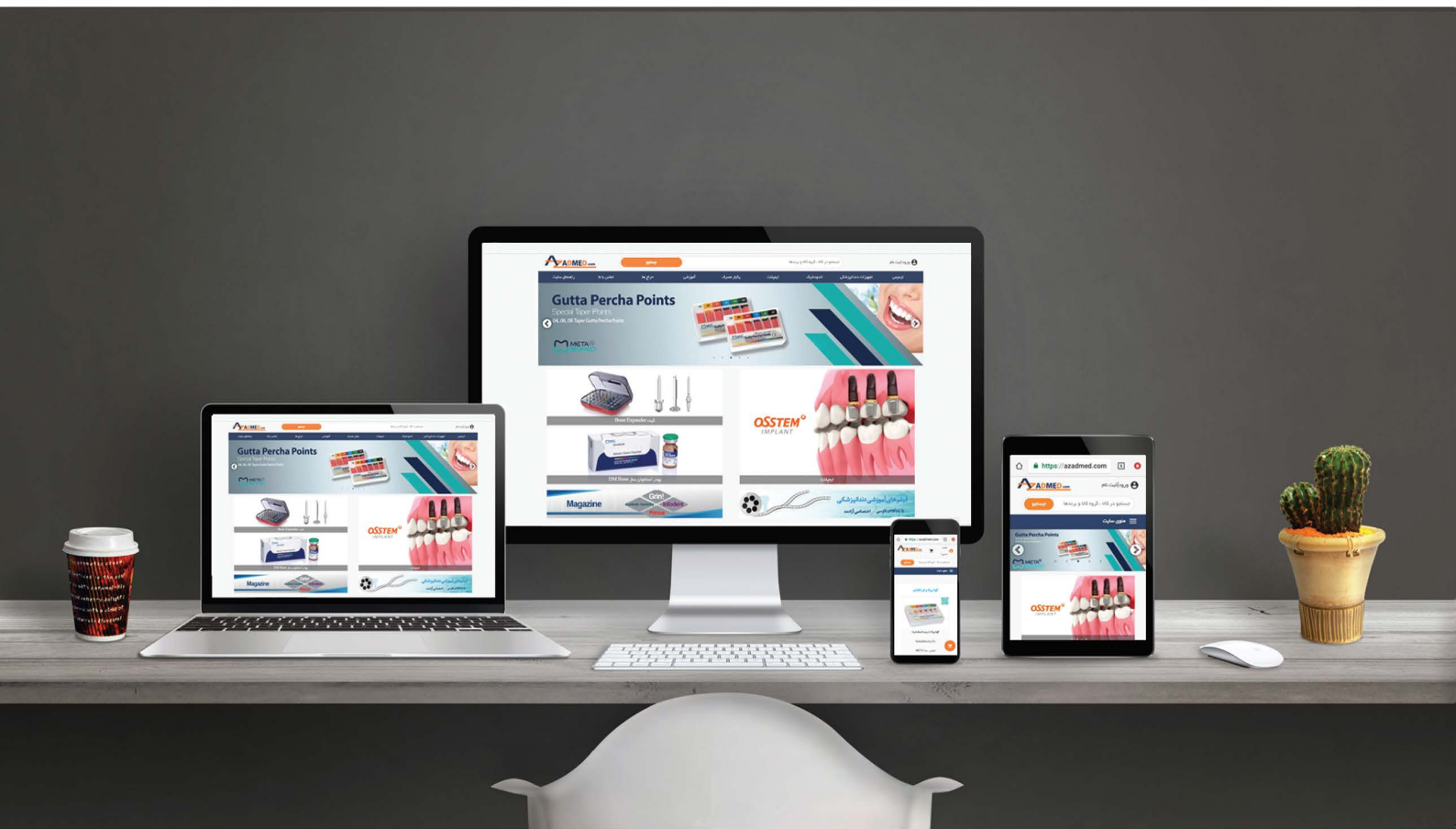




AZADMED.com



www.azadmed.com



 azaadtejaratpars

 @azadmed2

 88 98 80 63 - 6

implants

international magazine of oral implantology

2²⁰¹⁶



ADMED
ADMED.com

research

Morbidity after harvesting of autologous pelvic bone

case report

Bimaxillary implant restoration by all-ceramic bridges

interview

A nuanced perspective on periimplantitis



It is not a trick. It is
legendary science.
Discover the magic of
the tapered standard.

Designed for excellent primary stability thanks to an apically tapered implant with groundbreaking material and surface technology for maximizing predictability.

The Bone Level Tapered Implant – the new tapered standard. Engineered in Switzerland, home of Straumann.

<http://blt.straumann.com>



Material

Roxolid®



Surface

SLActive®



Education at its best



Dr Rolf Vollmer

Responding flexibly to individual and contemporary demands on further education has always been a strength of the DGZI e.V. Thus, we have established various further-education opportunities with the DGZI curriculum, our study groups and the DGZI International Annual Congress, which this year takes place from 30 September to 1 October in Munich—the last Oktoberfest weekend. All of those events can be adapted to individual learning demands.

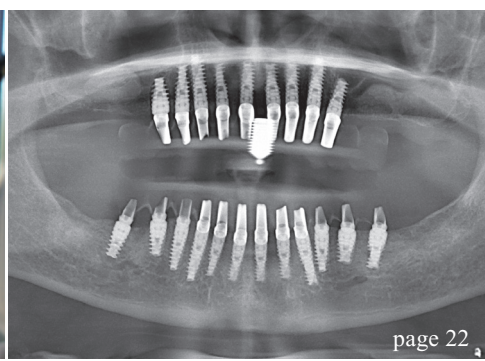
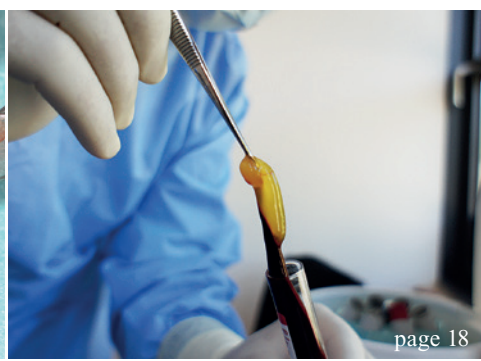
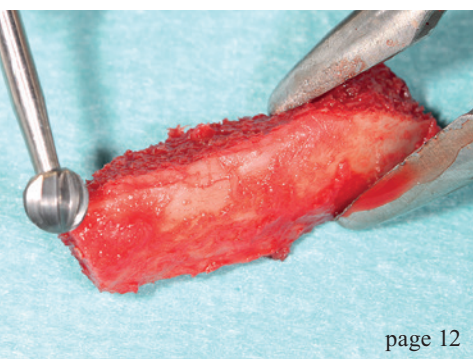
At the same time, Europe's oldest specialist association of dental implantology aims at discovering and training new opinion leaders, who can prove themselves in our DGZI Young Generation study groups for the first time. Only in this way can our society achieve to maintain implantology as a pioneering discipline for modern therapy approaches and technical innovation in dentistry.

In this regard, I should also mention the DGZI Implant Dentistry Award, which is granted annual at the DGZI International Annual Congress. This international award, which is endowed with 10,000 Euros, is granted by the DGZI scientific board in order to acknowledge ground-breaking scientific achievements in implantology. Therefore, it is the DGZI's most important form of honouring which is aimed at all implantologists in training who engage themselves in academics and science. The final date for this year's applications is 30 June 2016. Please contact our headquarters for further information.

I would like to end with encouraging you to enjoy reading this latest edition of **implants international magazine of oral implantology**.

Warm regards,

Dr Rolf Vollmer
First Vice President and Treasurer of the German Association of Dental Implantology



| editorial

03 Education at its best
Dr Rolf Vollmer

| research

06 CBCT zones of the jaw
Souheil Hussaini

12 Morbidity after harvesting of autologous pelvic bone
Prof. Dr Dr Peter Stoll, Dr Verena Gaydoul,
Dr Verena Stoll, Dr Kai Höckl & Dr Georg Bach

| case report

18 A-PRF as sole grafting material in sinus lifts
Dadi Hrafnkelsson

22 Bimaxillary Rehabilitation
OA Dr Björn Dziedo, CA Prof. Dr Dr Stefan Schermer &
Dr Elena Mihalcioiu

| industry

30 Fixed implant-supported prostheses
Zhe qu, Xiang zhang & Lan ma

36 A nuanced perspective on periimplantitis
Dr Stefan Holst

| events

42 6th International CAMLOG Congress
in Krakow

| news

38 manufacturer news

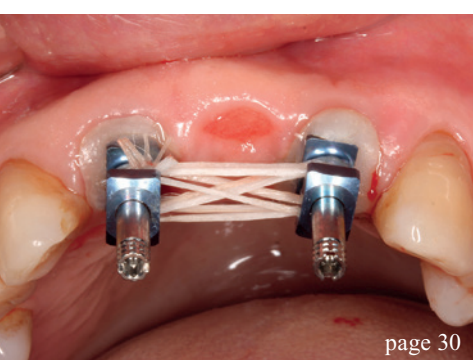
46 news

| about the publisher

50 imprint



Cover image courtesy of Nobel Biocare Deutschland GmbH
www.nobelbiocare.com



Implant planning made easy

Planmeca PlanScan®

Planmeca ProMax® 3D

3_{3D}X

Planmeca Romexis® software offers a completely integrated and digital workflow for modern implantology. From intraoral scanning to easy prosthetic design and realistic implant libraries, the most sophisticated implant planning tools are just a few clicks away.

- All the scanned and design data for prosthetic works is immediately available and can be mapped with the patient's CBCT data
- Use crown library or patient-specific crown from CAD system
- Verify the implant plan with verification tool
- Order surgical guide directly from the software
- Share data easily with partners through **Planmeca Romexis® Cloud** image transfer service



Find more info and your local dealer
www.planmeca.com

PLANMECA

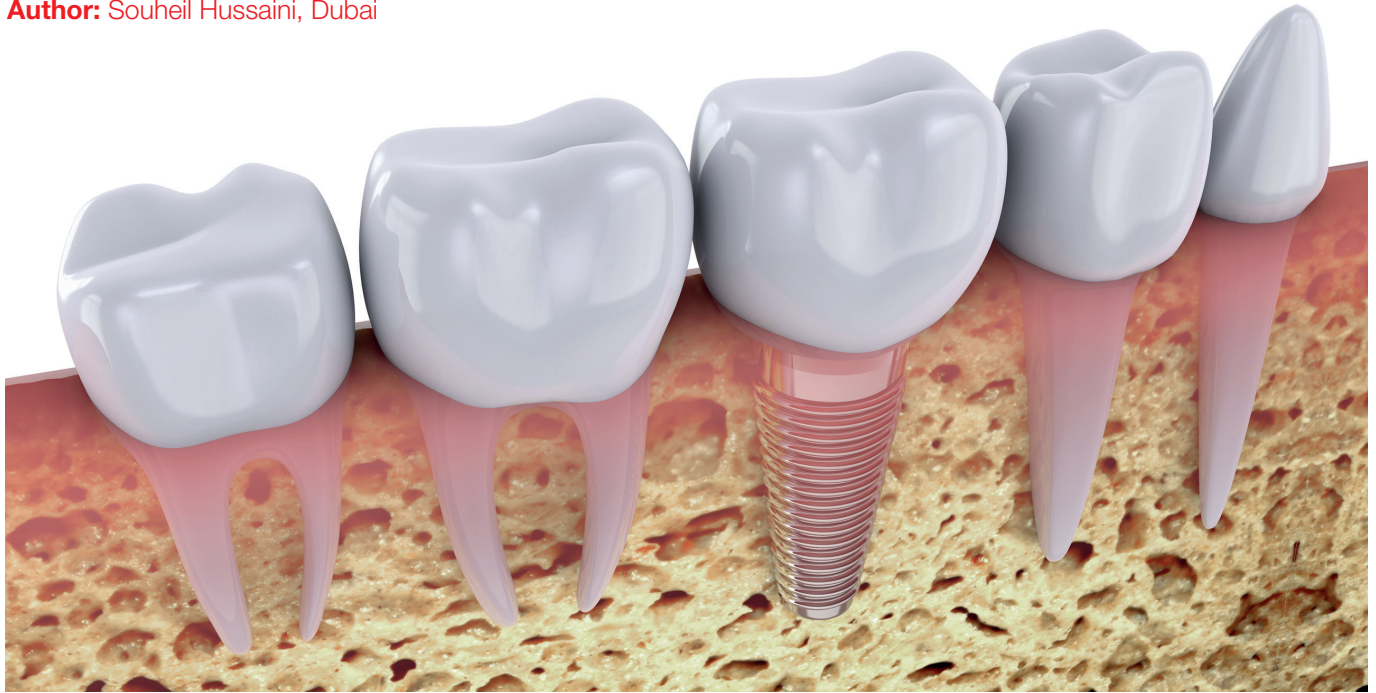

Planmeca Oy Asentajankatu 6, 00880 Helsinki, Finland. Tel. +358 20 7795 500, fax +358 20 7795 555, sales@planmeca.com

CBCT zones of the jaw

Bone quality related to implant location

Author: Souheil Hussaini, Dubai



© romma/Shutterstock.com

Introduction

The causes of early implant failures during the osseointegration process include poor quality and quantity of bone and soft tissue,¹⁻⁸ the patient's medical condition,^{2,6,8-10} unfavorable patient habits (bruxism, heavy long-term smoking, poor oral hygiene, others),^{3,4,6,8,11} inadequate surgical analysis and technique,^{3,7-9,11} inadequate prosthetic analysis and technique,^{3,7,8,11-13} suboptimal implant design and surface characteristics^{6,9,13} implant position or location¹⁴ and unknown factors.

This article attempts to further investigate implant location as one of many factors in early stages of diagnosis that improves success rate in implant dentistry treatment. Predisposing factors to implant complications in different jaw regions are discussed.

CBCT Zones D1 to D5 is formulated to better analyse implant dentistry procedure preparation during the diagnostic phase based on the location that has a logical sequence during examination of the alveolar ridge of both maxilla and mandible to have pre-existing information regarding the demands and the clin-

ical requirements in different zones of the jaws. This article identifies the Hounsfield units (HFU) of different alveolar jaw regions, according to which dental implants can be inserted with better understanding of what to expect.

Five CBCT zones are identified in this article in a logical sequence: the discreet zone D1 being the anterior mandible, the danger zone D2 being the posterior mandible, the death zone D3 being the anterior maxilla, the demand zone D4 being the posterior maxilla and the delicate zone D5 being the posterior maxilla that requires sinus lift procedure.

Zones D1–D5 are related to the bone quality classification of Lekholm & Zarb.¹⁵ D1 known as an interforamina area in which a careful diagnosis should be made due to the following procedure, bone density is very high and the osteotomy drills could heat the bone, irrigation temperature could facilitate healing response, dullness of the drills during osteotomy should be counted for, tap drills are required, arterial supply in the symphysis area should be considered and this area is utilised as a donor site for the chin (symphyseal) block bone graft. D1 includes six

Nobel Biocare Global Symposium

June 23–26, 2016 – New York

Where innovation comes to life



Register
now

nobelbiocare.com/global-symposium-2016

An experience beyond the ordinary

The Nobel Biocare Global Symposium 2016 program will offer unparalleled clinical and scientific education, as well as in-depth hands-on training. Held at the Waldorf Astoria in New York, it's a unique opportunity to experience how innovation can come to life in your daily work.

Design your own learning experience

Choose from numerous lectures, forums, master classes and hands-on sessions – from over 150 of the best speakers and presenters in the world. This must-attend event will cover a vast variety of techniques and treatment solutions, from diagnosis to treatment completion. Don't miss this opportunity. Sign up now and we'll see you in New York!



[Read more about the Symposium](#)



anterior teeth: four incisors and two canines. A thin alveolar process in this area necessitates implant diameter selection of a narrow-to-standard diameter (3–4 mm). Based on many case reports, a penetration of the thin lingual mandibular cortex during an implant insertion in this area on occasion can lead to serious bleeding with formation of expanding sublingual haematomas.^{16–24} Haemorrhage from a branch of the sublingual artery (a branch of the lingual artery), the submental artery (from the facial artery), or the mylohyoid artery (from the inferior alveolar artery, a branch of the maxillary artery) or their anastomoses can in some cases cause a life-threatening airway compromise.^{19–22} Tepper et al. demonstrated the presence of at least one (sometimes multiple) lingual perforating vascular bone canal(s) and suggested a routine CT examination prior to an implant procedure in this area.²¹ A similar report of serious haemorrhage from an implant insertion in the first mandibular premolar position also suggests a common arterial supply of all eight mandibular front teeth and one more reason for including first premolars in this zone.¹⁶ A successful placement of two to six implants in this zone in many edentulous arch cases offer a stable foundation for a variety of implant-retained and implant-supported removable and fixed mandibular prostheses. A symphyseal (chin) monocortical block bone graft harvested in this area is often used for the horizontal augmentation of bone in other regions, especially for the anterior maxilla.

D2 is a bilateral area of the alveolar ridge of the posterior mandible from the first premolar to the retromolar pad. The mental foramen in the front and the inferior alveolar canal below limits this functional implant zone. An implant's success in this area relates to the quality (density) of bone and quantity of preserved alveolar ridge, among other factors. The ramus block bone graft is often harvested in the proximity of this zone. Embryologically, this bilateral mandibular alveolar zone develops above the inferior alveolar canal. The alveolar height between the inferior alveolar canal and the alveolar crest is routinely analysed in oral implantology when posterior mandibular implants are considered. A heavy masticatory demand during function, especially for people with parafunctional habits, necessitates an insertion of two to three implants into this region for replacement of missing first, second premolar, first molar, and occasionally the second molar.

D3 is a zone of the alveolar ridge of the anterior maxilla (aesthetic area), including six front teeth: four incisors and two canines. Part of the anterior maxilla is a protruding alveolar process with thin labial and thick palatal cortical plates covering and protecting the upper front teeth. A prominent position

of the anterior maxilla and upper front teeth in the face is responsible for bone and soft-tissue injuries.²⁵ Fracture of crowns and roots, subluxation, displacement and avulsion of teeth are frequent in this zone.²⁵ The main blood supply to the anterior maxilla is derived from the branches of the maxillary artery: the anterior superior alveolar artery (from the infra-orbital artery), the greater palatine artery, and the nasopalatine artery. A middle superior alveolar artery is occasionally described as a branch of the infra-orbital artery that supplies the region of the canine tooth. The anterior and middle superior alveolar arteries anastomose with the posterior superior alveolar artery to form an arterial network feeding both endosteal and periodontal plexuses.

Another traumatic event in the life of the alveolar ridge is a tooth loss. A tooth extraction, or periodontal disease also leads to bone resorption. The progression of healing after a tooth extraction goes through certain resorptive stages of fibrin clot organisation (first four weeks), immature (woven) bone formation (four to eight weeks), mature (lamellar) bone development (eight to twelve weeks), and bone stabilisation stage (twelve to 16 weeks or about four months).^{26–28} Post extraction bone resorption is always three-dimensional, with the greatest loss of bone in the bucco-palatal or horizontal direction (the width) and occurring mainly on the buccal side of the alveolar ridge.²⁸ Schropp et al. reported that two thirds of the horizontal bone loss occurs within three months and one-third takes place within the remaining nine months of the first year post extraction.²⁹ A mean reduction of the width of the ridge has been reported to be 5 to 7 mm within a six-month period or 50 per cent during the twelve months following tooth extraction.²⁹ The loss of bone height is smaller, reported to be about 1 mm within the first six months post extraction.^{20,29} If a bone grafting and implant treatment approach is not considered soon after trauma, the atrophy of the alveolar process of the anterior maxilla continues with time. Resorption of the buccal plate compromises the anatomy of the edentulous alveolar ridge and makes it difficult to place an implant in the prosthetically favourable position.³¹ Even when a dental implant is placed, its strength is diminished without the presence of a buccal cortical plate. Using a two-dimensional finite-element model for stress analysis, Clelland and associates demonstrated low stresses and high strains surrounded the implant for the all-cancellous (lack of cortical plate) bone model.³² When a layer of thick cortical bone was added to the model, it had a significant impact and improved stresses and strains on the implant.

D4 is related to first and second premolars in the maxillary region and rarely first and second molars.

Although this area is not considered the maxillary anterior teeth, it is still a prime concern for the patients during conversation and smiling. In addition to two anterior premolar teeth, two posterior molars are not considered as a separate class in this group if sinus lift is not required due to their common bone quality. These implants once restored are the longest support in front of maxillary sinuses. Park, Hyo-Sang et al. reported that the cortical bone density of the maxilla ranged approximately between 810 and 940 HFU at the alveolar bone except for the maxillary tuberosity (443 HFU at the buccal and 615 HFU at the palatal alveolar bone), and between 835 and 1,113 HFU at the basal cortical bone except for tuberosity (542 HFU).³³ The cortical bone density of the mandible ranged between 800 and 1,580 HFU at the alveolar bone and 1,320 and 1,560 HFU at the basal bone. The highest bone density in the maxilla was observed in the canine and premolar areas, and maxillary tuberosity showed the lowest bone density. Density of the cortical bone was greater in the mandible than in the maxilla and showed a progressive increase from the incisor to the retromolar area.

D5, known as the sinus zone, is a bilateral zone of the alveolar ridge of posterior maxilla located at the base of the maxillary sinus from the second premolar to pterygoid plates. There are certain common features of replacement of missing tooth or teeth (rarely two premolars and commonly one or two molars) with dental implants in this zone. It often relates to the degree of sinus pneumatisation and vertical bone deficiency that may require supplemental surgical procedures in the subantral area in order to place endosseous implants.

This bilateral maxillary posterior zone that extends from the second premolar to the pterygoid plates is located at the base of maxillary sinuses (antra of Highmore). Embryologically, the hard palate and the

alveolar process of the maxilla form the barrier between the maxillary sinus and the oral cavity. The bone height between the floor of the maxillary sinus and the alveolar crest is routinely analysed in oral implantology when posterior maxillary implants are contemplated. An increase of sinus volume or sinus pneumatisation after a loss of posterior tooth/teeth often necessitates vertical bone augmentation with a sinus lift procedure. The bone of this region is also known to have compromised bone quality (types 3 and 4) that can increase an implant failure rate. The main blood supply to the posterior maxilla derives from the posterior superior alveolar artery, the greater and lesser palatine arteries (all from the maxillary artery), the ascending pharyngeal branch of the external carotid artery, and the ascending palatine branch of the facial artery. An injury to the posterior superior alveolar artery during the lateral approach for subantral augmentation can cause haemorrhage that may require coagulation.

Materials and method

From a database of 1,134 patients who had received 4,800 dental implants from 2001 till August 17th 2015, randomly a prosthodontist with no knowledge of these criteria was requested to select 100 files from the data base and present them for this study. The 100 files had received panoramic and cone beam computed tomography (CBCT, Table 1) during their diagnostic visit. The average HFU of the randomly selected 100 cases was calculated.

Results

Hounsfield unit: The data in table #1, out of 100 samples, demonstrated that the average HFU was the minimum in D5 (213 HFU), and followed by D4 (528 HFU), D3 (561 HFU), D2 (599 HFU) and D1 (654 HFU) in ascending order respectively (Fig. 1 and Table 2).

Discussion

There are few literature reports that attempt to study implant location, among a multitude of other factors, to determine its influence on the success or failure of dental implant treatment. Becker et al. evaluated 282 implants placed in the maxillary and mandibular molar positions in a prospective study.³⁴ The six-year cumulative success rate (CSR) for maxillary posterior implants was 82.9 per cent, for mandibular posterior, 91.5 per cent. He concluded that CSR in the posterior regions is lower than usually reported for anterior regions of the maxilla and mandible due to differences in bone quality and quantity. Eckert et al. assessed 1,170 endosseous implants placed in partially edentulous jaws in a

Technical data

Anode voltage	60–90 kV
Anode current	1–14 mA
Focal spot	0.5 mm, fixed anode
Image detector	Flat panel
Image acquisition	Single 200 degree rotation
Scan time	7.5–27 s
Reconstruction time	2–25 s

Table 1

Average HFU of different areas in the mouth

Zones (D1–D5)	No. of Cases	Avg. HFU per zone
1	14	655
2	33	599
3	31	562
4	19	529
5	3	213
Total	100	

Table 2

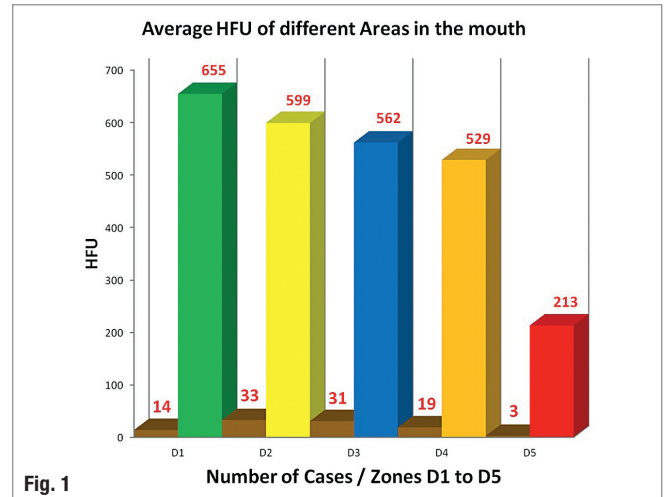


Fig. 1

retrospective study: anterior maxilla, posterior maxilla, anterior mandible, and posterior mandible.³⁵ In his report, the location of implants did not appear to have any effect on implant survival, implant fracture rates, screw loosening, or screw fracture. Parein et al. analysed 392 consecutively placed Brånemark implants that were inserted in 152 partially edentulous posterior mandibles and restored with 56 crown and 168 bridge restorations in a long-term retrospective study.³⁶ The CSR of all implants in the posterior mandible was 89.0 per cent at six years.

Fewer complications were found in implant prostheses located exclusively in the premolar region versus molar and mixed molar-premolar implant restorations. Drago investigated the location-related osseointegration of 673 implants placed in 169 patients that were observed from seven months to eight years following occlusal loading.¹⁴ Implant osseointegration was 89.1 per cent in the anterior maxilla, 71.4 per cent in the posterior maxilla, 96.7 per cent in the anterior mandible, and 98.7 per cent in the posterior mandible. Moy et al. analysed implant failure rates and associated risk factors, observed implant failure of 8.16 per cent in the maxilla and 4.93 per cent in the mandible.³⁷ Increased age (over 60) was strongly associated with the risk of implant failure. Bass et al., evaluating 303 patients with 1,097 implants over a three-year period, assessed the success rate of implants in the maxilla at 93.4 per cent and 97.2 per cent in the mandible.³⁸ Poor bone quality played the major role in implant failure with bone quantity demonstrating less importance.

All presented reports appear to agree that the CSR of dental implants is generally high and that implant location plays an important role in implant success. CSR of implants in the mandible seems to be slightly higher than in the maxilla—a difference of about 4 per cent. The success rate of implants in the anterior regions seems to be higher than in the posterior re-

gions of the jaws, mostly due to the quality of bone: about 12 per cent difference between anterior maxilla and posterior maxilla, and about 4 per cent difference between anterior mandible and posterior mandible. On the basis of reviewed literature reports, an implant treatment in the anterior mandible appears to be the most successful. The posterior maxilla appears to be the least successful region of the jaws for implant rehabilitation.

Conclusion

There is a trend of escalating levels of HFU in different parts of the oral cavity. The highest being the anterior mandible, followed by the posterior maxilla, posterior mandible, anterior maxilla and posterior maxilla with sinus lift procedure respectively. Estimated HFU can assist the surgical phase, as the number of the ancillary procedures can be pre-estimated according to different areas in the mouth during the diagnostic phase.

Editorial note: A list of references is available from the publisher.

contact

Dr Souheil R. Hussaini, BDS, MS

Oral Implantology Medical Center
 204 Al Wahda Building, Port Saeed Rd, Deira,
 PO Box 39695 Dubai, UAE
 Tel.: +971 4 2956595
 Fax: +971 4 2958757
 souheilh@eim.ae
 www.ID-SC.com



BARCELONA DREAM TEAM MAKE IT SIMPLE

MIS is proud to introduce the Global Conference Speakers Team: Alexander Declerck • Anas Aloum • Andrea Pilloni • Arndt Happe • Björn-Owe Aronsson • Carles Martí-pagés • Carlo P. Marinello • Christian Coachman • David García Baeza • Eduard Ferrés-padró • Eli Machtei • Eric Van Dooren • Federico Hernández Alfaro • Florian Schober • France Lambert • Gabi Chaushu • Galip Gürel • Giulio Rasperini • Guillermo J. Pradies Ramiro • Gustavo Giordani • Hilal Kuday • Ignacio Sanz Martin • José E. Maté-sánchez De Val • José Nart • Juan Arias Romero • Korkud Demirel • Lior Shapira • Marco Esposito • Mariano Sanz Alonzo • Miguel Troiano • Mirela Feraru-Bichacho • Mithridade Davarpanah • Moshe Goldstein • Nardi Casap • Nelson Carranza • Nitzan Bichacho • Nuno Sousa Dias • Pablo Galindo-Moreno • Stavros Pelekanos • Stefan Koubi • Tommie Van de Velde • Victor Clavijo • Vincent Fehmer • Yuval Jacoby. To learn more about the conference visit: www.mis-implants.com/barcelona



Morbidity after harvesting of autologous pelvic bone

A Prospective longitudinal study

Authors: Prof. Dr Dr Peter Stoll, Dr Verena Gaydoul, Dr Verena Stoll, Dr Kai Höckl & Dr Georg Bach, Germany

Introduction

The industry offers numerous biological and synthetic bone replacement materials and partly pays great advertising expenses to place them on the market. The autologous bone graft, on the contrary, applied with outstanding success in oral and maxillofacial surgery for decades, has no lobby. Is the application of autologous bone grafts, which needs to be harvested beforehand in a second surgery, outdated under these circumstances?

To anchor dental implants in the jawbone successfully, sufficient vertical and transversal bone substance must be available.¹ If there is not enough bone substance, either you have to abstain from inserting implants or you have to create the necessary requirements. The quality value of materials for eliminating the bone deficit is defined by their biological potency and biomechanical properties.²

The autologous bone graft is the only material so far that complies with the condition necessary for

successful bone augmentation according to Garg et al., namely osteogenesis, osteoinduction, and osteoconduction in equal measure.³ Besides intra-oral donor areas like the chin, the retromolar region, zygomatic buttress, and calvaria, mainly the tibial head as well as the anterior and posterior iliac crest bones are suited in particular for larger bone deficits.⁴⁻⁸ We do not, however, want to discuss the numerous bone replacement materials, BMP, stem cell fractions, or PRP, available on the market in this study.^{9,10}

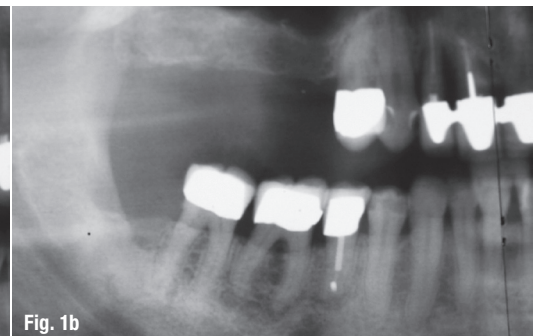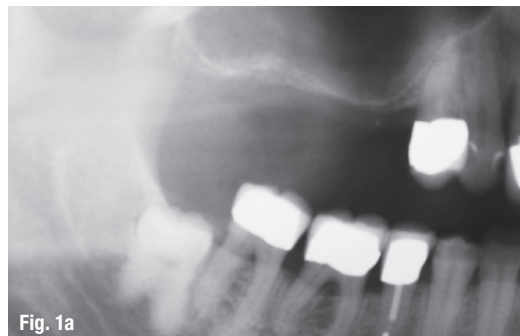Patient population and method

The purpose of this prospective longitudinal study is to examine the morbidity after harvesting and transplanting autologous pelvic bone to eliminate jawbone deficits.

69 adult patients (37 f/32 m) aged between 31 and 73 years (average age at the time of the intervention 57.8 years, median age 52.5 years) who had undergone harvesting of autologous bone

Fig. 1a: Bone deficit region 15–18, alveolar bone thin as an eggshell.

Fig. 1b: St. p. lateral sinus lift with consolidated bone before implant insertion.



Introducing Innovative and High-Quality Restorative Solutions



INCLUSIVE®
TAPERED IMPLANT SYSTEM



Industry-standard Internal Hex Connection

NEW!

HAHN™
TAPERED IMPLANT

Industry-standard Conical Connection



INCLUSIVE®
MINI IMPLANT SYSTEM



INCLUSIVE®
PROSTHETIC COMPONENTS



Industry-compatible Prosthetics

For more information

+49 (0) 69-2475 144 30

www.glidewelldirect.com | orders@glidewelldental.de

Glidewell Direct is actively seeking distribution channels

GLIDEWELL DIRECT  **EUROPE**
CLINICAL AND LABORATORY PRODUCTS

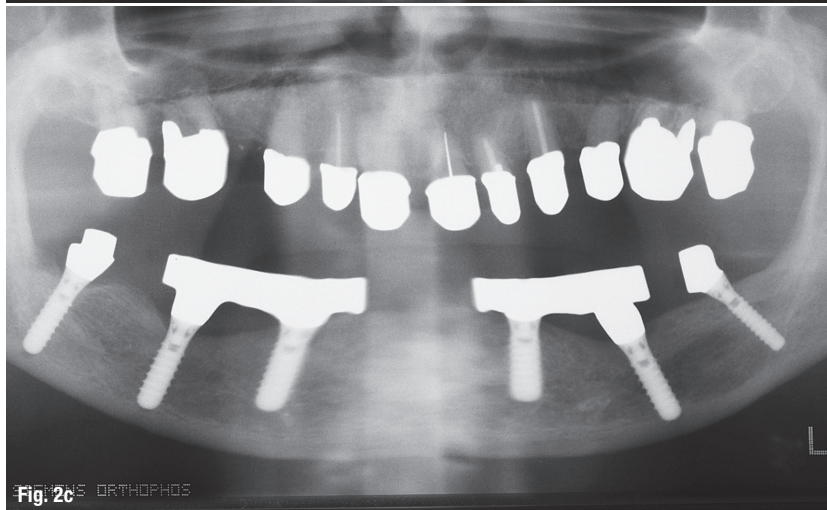
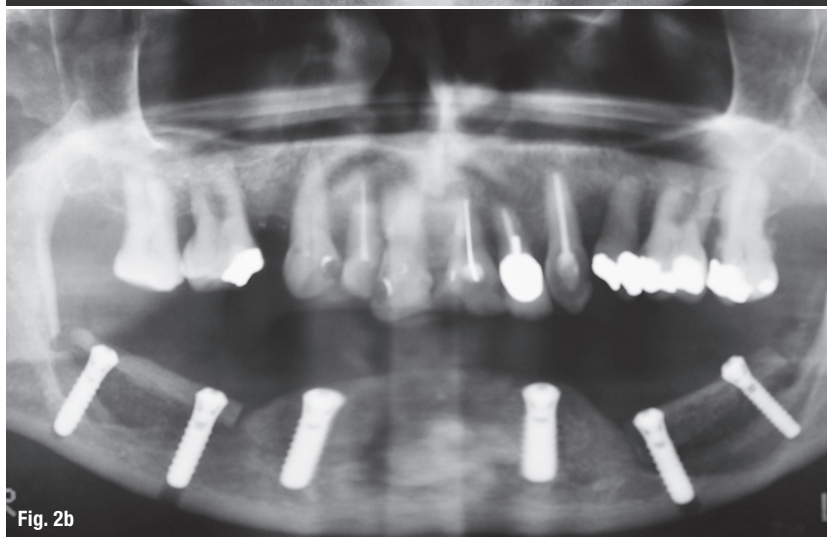
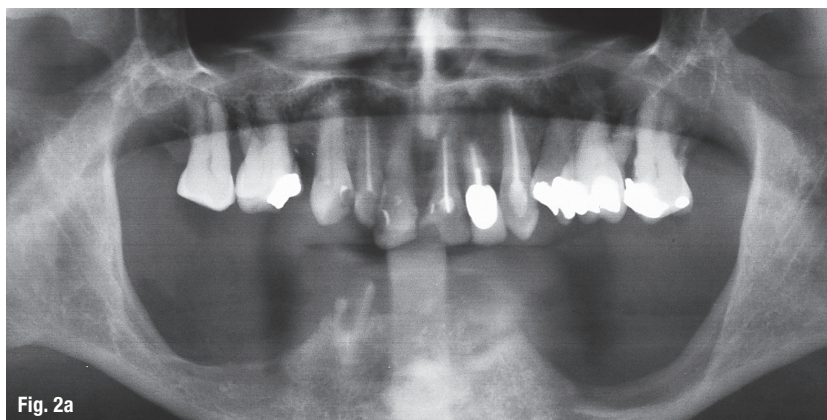


Fig. 2a: Bilaterally advanced atrophy of the alveolar ridge in the lower jaw with an insufficient prosthetic bed. – **Fig. 2b:** St. p. nerve lateralisation and onlay osteoplasty with cortical/cancellous bone flakes from the iliac crest bilaterally in the lower jaw, fixation of bone flakes with implants 35, 37, 45, 47, implant insertion 33, immediate implant insertion after extraction 43. – **Fig. 2c:** St. p. osseous consolidation and prosthetic supply.

graft from the anterior iliac crest bone between 2002 and 2010 participated in the study. The surgery was indicated on the grounds of the dimension of the available jawbone deficit (Figs. 1 & 2), considering its localisation as well. Criteria for exclusion were heavy nicotine (more than ten cigarettes/day) and drug abuse, diabetes mellitus

requiring insulin, coagulation disorders, and bone diseases.

All interventions were executed under short-term antibiotic prophylaxis (Cefotiam [Spizef®], Grünenthal GmbH or Clindamycin [Sobelin®], Pfizer) under general anaesthesia by the same surgeon, exposing at first the donor site of the anterior iliac crest bone in a minimally invasive procedure, i.e. by making a 3 to 4 cm long skin incision along the Langer lines and subcutaneously, if possible without cutting muscles, nerves, and vessels. By creating two periosteal flaps, the periosteum was pushed aside over the iliac crest bone. Using a micro-oscillating saw, cortico-cancellous bone blocks were removed or, by means of a hollow drill, cylinders from the cancellous bone. The periosteum was thoroughly adapted and closed; the wound was sutured in layers. A continuous subcutaneous suture was made (Fig. 3). Suction drainage was obtained from regularly. Before the final transplantation, the cortico-cancellous bone was modelled to fit the graft bed and stored intermediately in venous autologous blood; amorphous cancellous bone was homogenised and stored intermediately in venous autologous blood as well until fitted in the graft bed (Fig. 4).

According to the specified follow-up schedule, check-ups took place the following day, after one, two, and three postoperative weeks and in the course of the prosthetic treatment, at the latest after six months. Then, further follow-ups took place within the bounds of the semi-annual implant examinations. The results were recorded in writing. They were analysed by means of a checklist comprising intraoperative injuries such as haemorrhages, injury of nerves (e.g. genitofemoral nerve, lateral cutaneous nerve, iliohypogastric nerve), and peritoneal perforation. Possibly persisting sensibility disorders like complete failure of sensibility or paraesthesia (e.g. burning sensation) were grouped with intraoperative complications. In addition, infections, impaired wound healing, secondary haemorrhages, possibly available pains, their intensity (analogue scale between 1 and 10) and duration as well as motor function limitations were registered. Finally, the quality of the scar was assessed and the subjective opinion of the patient on the result of the treatment obtained.

Results

Intraoperative complications like heavy vascular bleeding requiring ligature did not appear in any of the cases and were not expected because of the patients anatomy. Almost regularly, however, postoperative suffusions in various intensities occurred, albeit with no clinical relevance. Transections of

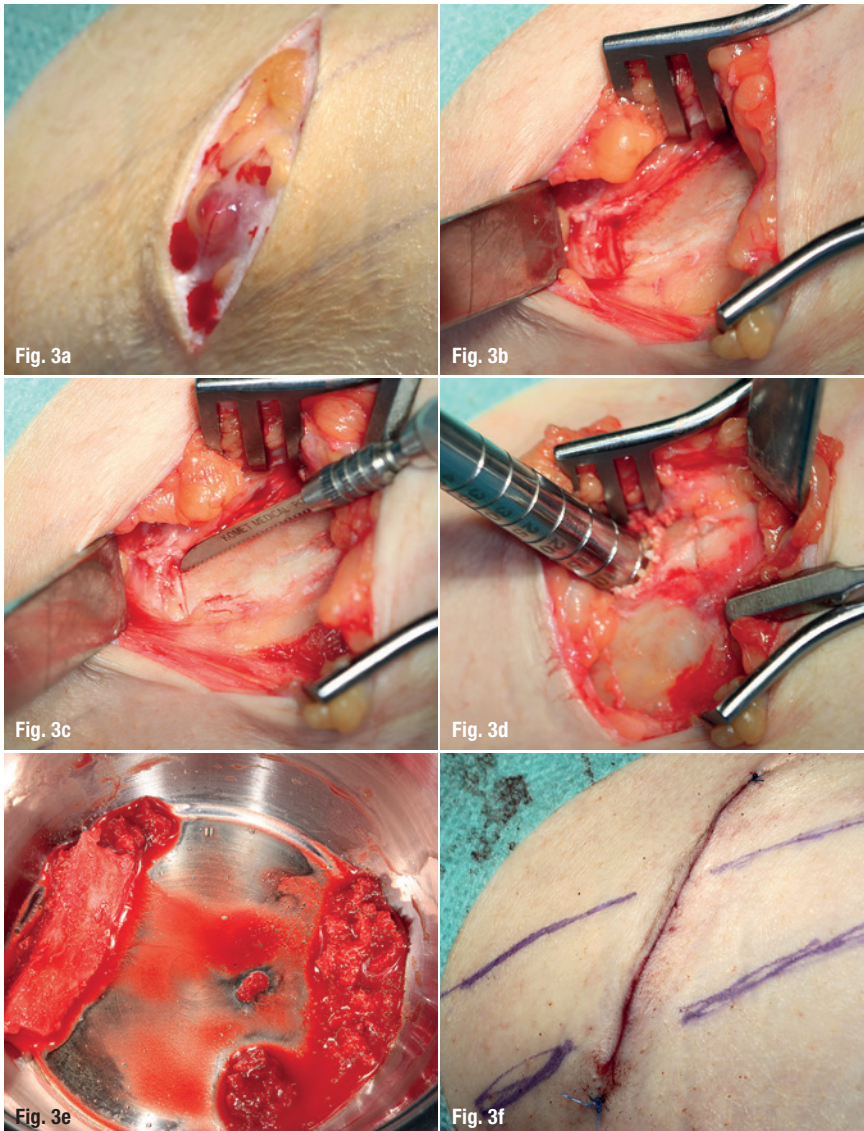


Fig. 3a: Skin incision along the Langer lines perpendicularly to the iliac crest. – **Fig. 3b:** Representation of the iliac crest. – **Fig. 3c:** Harvesting of a cortical/cancellous bone flake using the oscillating saw. – **Fig. 3d:** Harvesting of cancellous bone cylinders using the hollow drill. – **Fig. 3e:** Cortical/cancellous bone flake and homogenised cancellous bone. – **Fig. 3f:** Continuous subcutaneous suture.

motor or major sensitive nerve branches and the associated functional failures were not recorded. Peritoneal perforations, for example by the hollow drill, were theoretically possible, but did not occur either. Infections, impaired wound healing, or secondary haemorrhages requiring intervention did not occur.

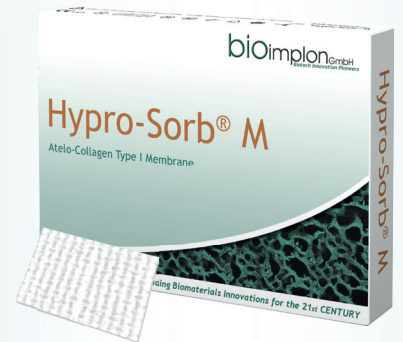Postoperatively, a sensibility disorder tending to remission (hypoesthesia) of the donor site was noticed only in two patients (1.38%) within the first three weeks. Eleven (14.2 %) patients did not suffer from any postoperative pain of the donor site. 58 (85.8 %) patients stated to suffer from pains of the pelvic donor site when they

came out of anaesthesia. Within two weeks, the major share of the patients did not feel any pain of the donor site anymore (Fig. 5). In no case were the pains described as unendurable.

Temporary movement restrictions, e.g. when standing up or climbing stairs, occurred relatively frequently with 62.32% (43 patients), but were individually and subjectively overlaid, amongst others with regard to the dimension of the intervention. In any case, they disappeared completely after two weeks at the latest.

All patients were satisfied with the aesthetic result of the donor site. 65 (94.2 %)

The New Generation of Hypro-Sorb® M Atelo-Collagen Membrane for GBR & GTR



- ✓ innovative semi-rigid membrane
- ✓ natural, pure, bovine Atelo-Collagen
- ✓ highest biocompatibility
- ✓ free of immunogenic telopeptides
- ✓ excellent handling properties
- ✓ optimal barrier function
- ✓ completely resorbed within 6 months

bioImplon_{GmbH}
Biotech Innovation Pioneers

Bioimplon GmbH
Friedrich-List-Str. 27
35398 Gießen
+49 (0)641 6868 1123
www.bioimplon.de

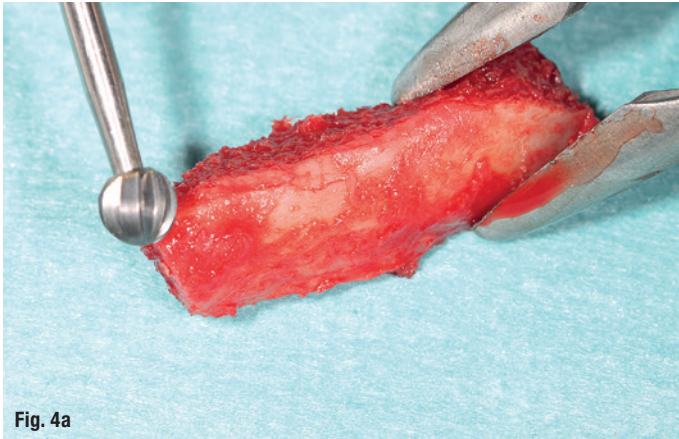


Fig. 4a

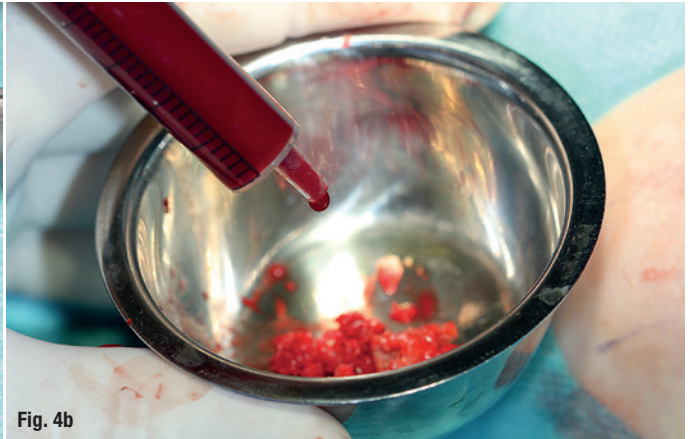

Fig. 4b

Fig. 4a: Processing of the bone block.

Fig. 4b: Intermediate storage of grafts in venous autologous blood.

said the result was very good, four (5.8%) said it was good. None of the patients stated any impairment of any kind. All patients would undergo bone harvesting from the iliac crest again.

Discussion

The success of autologous bone for jawbone augmentation with its low morbidity and complication rate is well known.^{11–15} Not for nothing is it called the gold standard. Compared to bone created in laboratories, it provides more reliable results.¹⁶ Compared to Straumann BoneCeramic® (BoneCeramic®, Straumann AG; hydroxyapatite and tricalcium phosphate), BioOss® (BioOss®, Geistlich; bovine bone) and Puros® (Puros®, Zimmer Dental; allograft cancellous particles), the vital autologous bone performs best and yields the best *de novo* bone formation.¹⁷ The success rate is high as well in combination with other materials.^{12,18}

The necessity to perform pelvis surgery under general anaesthesia and the fact that the patient should be monitored at the hospital at least for a short time makes the harvesting of pelvic bone appear laborious, however. In addition, there may be general medical and individual reservations against opening a second operating field.

Besides the easily accessible anterior iliac crest, for which the patient does not need to be repositioned for the jawbone augmentation, there are further options. When harvesting bone from the dorsal part of the iliac crest, however, repositioning of the patient causes a substantial loss of time. All other donor sites mentioned above are associated with a limitation of available material, so that they are suited to fill only minor defects in contrast to the iliac crest, where sufficient quantities of cortical and cancellous bone are available.

Within the scope of the present prospective longitudinal study, the anterior iliac crest was chosen

exclusively as the donor site of autologous bone. The same experienced surgeon always harvested the graft, thus ensuring a standardised and speedy procedure. In addition, as the patient did not need to be repositioned, a second team could expose and prepare the graft site simultaneously. This can neither be realised effectively by the procedure of intra-oral bone harvesting nor by harvesting of material from the posterior iliac crest. The timesaving is remarkable and certainly has an effect on the hygienic situation.

Within the scope of this study, the jawbone situation is not addressed in detail. We may remark, however, that no graft loss occurred in the transplant bed. This correlates with the patients' assessment to undergo the surgery again.

Serious intraoperative complications, secondary haemorrhage, infections, or impaired wound healing did not occur, certainly also because of the strict exclusion criteria like nicotine abuse and diabetes requiring insulin.

Subjective paraesthesia and short-time temporary functional impairments when standing up or climbing stairs were predominant. The evaluation of surgery-related pain, in this case focused on the pelvic region, is difficult, as pain is an individual, subjectively-biased sensation that is usually modulated by means of analgesic medication in particular after surgeries. Usually and in this study, the intensity of available pain is given by the patient him-/herself on an analogue scale ranging from 1 (minimum) to 10 (maximum). This information is also a measure of the analgesic effectiveness and can therefore not be used in the strict sense (Singh et al. 2009, Fasolis et al. 2012)^{19,20}. Improved postoperative analgesia bears great potential after all. We drew the conclusion by administering an additional long-lasting local anaesthetic at the end of the operation (Carbosthesin®, AstraZeneca; Bupivacaine). The effect is promising.

Pain duration

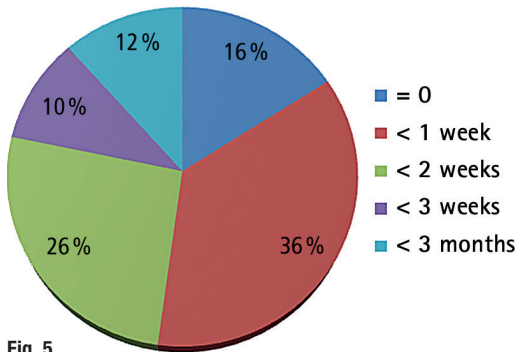


Fig. 5

All patients rated the aesthetic result of the donor site as very good or at least as good. At the time of the final examination, none of the patients reported any complaints that might be attributed to the surgery.

Conclusion

According to the analysis of our results, in particular in view of the low morbidity of the donor site, we can confirm the excellent suitability of autologous pelvic bone to eliminate deficits of the jawbone when indicated accordingly.²⁰ If larger quantities are

needed, the autologous pelvic bone is still the method of choice despite the drawback of the second intervention. The chances of healing and the resistance against infections are unexcelled due to the great ontogenetic power of the fresh, vital autologous bone. The method guarantees assured success, the results are well predictable. The "gold standard" term is still justifiable.

Editorial note: A list of references is available from the publisher.

contact

Praxis Prof. Dr Dr Stoll & Partner

Dr Kai Höckl
 Dr Verena Stoll
 Wilhelmstr. 3
 79098 Freiburg/Breisgau, Germany

AD




PUBLISH
 YOUR
 EXPERTISE!

Become an author for implants—
 international magazine of oral
 implantology

Please contact:

Georg Isbaner
 Editorial manager
 g.isbaner@oemus-media.de





© Rost9/Shutterstock.com

A-PRF as sole grafting material in sinus lifts

Author: Dadi Hrafnkelsson, Denmark

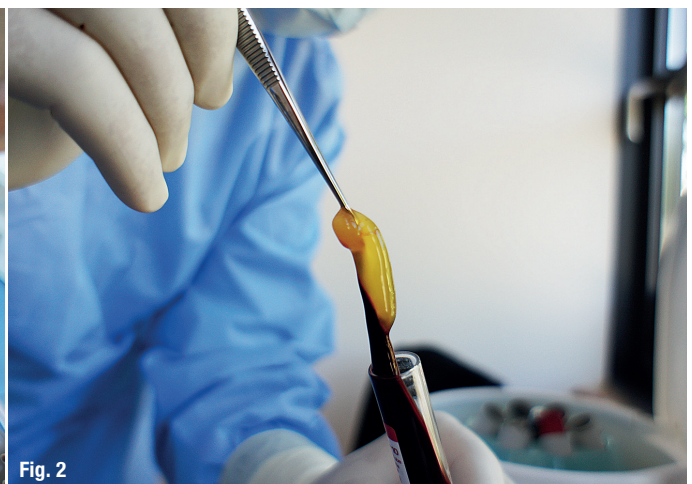
Introduction

Fig. 1: Three glasses with venous blood placed in the centrifuge.

Fig. 2: A-PRF clot.

Reduced residual bone height underneath sinus maxillaris is solved by lifting the Schneiderian membrane from the floor of the sinus using either

the osteotome technique or the lateral window approach. By these means, it is possible to place a dental implant to anchor a fixed or removable prosthesis. In these treatments, it is custom to use biomaterials to keep the volume around the



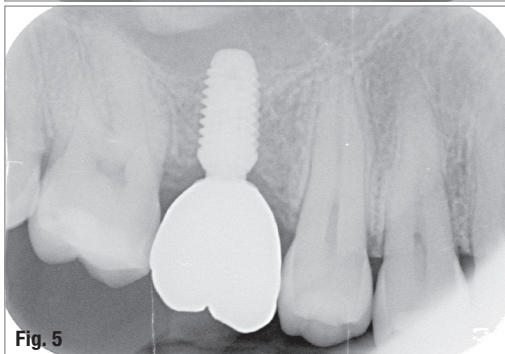
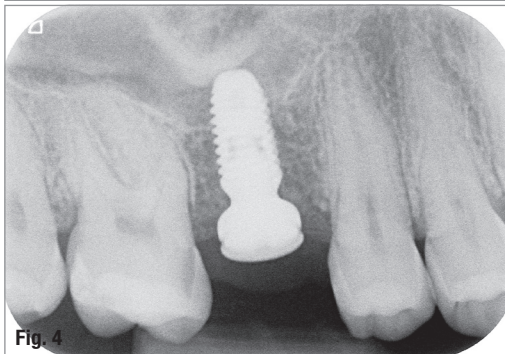
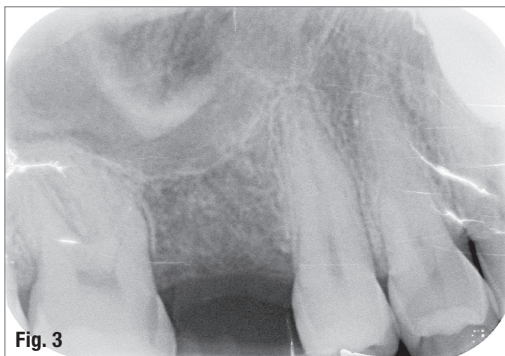
"my job is to design great smiles."

NucleOSS produces
smart designs, brave smiles

Fig. 3: Case 1, pre-operative.

Fig. 4: Case 1, immediately after operation.

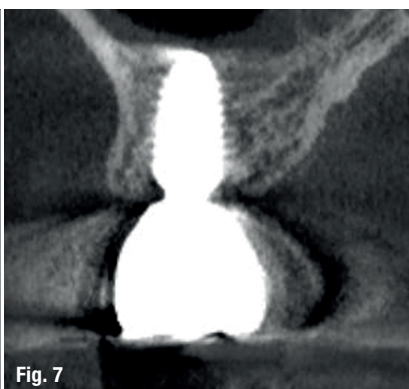
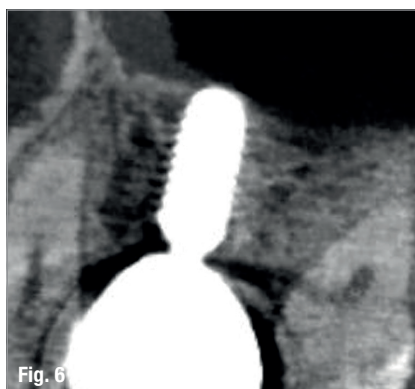
Fig. 5: Case 1, 14 weeks after operation.



dental implant and finally make way for osseointegration of the implant.

The purpose of this case presentation is to describe the author's experience of using A-PRF (Advanced platelet-rich fibrin) as sole grafting material and to show that it is possible to get good bone formation around the dental implant inside the sinus without the use of biomaterials. Two operations were performed under local anaesthesia, venous blood was collected and A-PRF made. Osteotomy was done

Fig. 6 & 7: Case 1, six months post-op.



by means of osteotomes (Summers technique). There were no perforations to the Schneiderian membrane, A-PRF membranes were placed inside the sinus and the dental implant placed achieving adequate primary stability in both cases. Impressions were taken after twelve weeks. From cone beam computed tomography it is clear that bone formation has taken place inside the sinus underneath the Schneiderian membrane. Both of the two implants were fully osseointegrated and restored successfully.

State of research

In the year 2003 Lundgren et al. published a concise paper¹ showing the spontaneous bone formation in the sinus after removal of a cyst.¹ The space that was once filled with the cyst became filled with bone without any further operations. Lundgren and his colleagues proposed that if space is maintained, bone can form without the use of biomaterials. Lundgren then did a study that was published in 2004, where 19 dental implants were placed with the Summers technique and no biomaterial was used.² In this procedure, the implants are used as "tent pegs" that hold the Schneiderian membrane from collapsing to the floor of the sinus; the blood that fills the gap then turns to bone in time. The results were that a lot of extra bone had formed around the implants without the use of biomaterials.

Other authors followed and published similar studies that confirmed Lundgren's results.³⁻⁹ To get a good filling of blood can be a challenge in this procedure because one cannot predict how much blood there will be between the sinus floor and the Schneiderian membrane after the operation. A-PRF can be seen as a good and advanced blood clot that is easy to obtain. In addition, one can control how much the filling will be. In 2009 Mazor and colleagues published a paper where A-PRF was used to fill this space.¹⁰ 25 sinus lifts were performed in 20 patients and 41 dental implants placed. The authors used the same method as Lundgren did earlier, except for filling the space between the sinus floor and the Schneiderian membrane with A-PRF membranes. The results showed an increase in bone height between 7 and 13 mm (mean \pm SD: 10.1 \pm 0.9 mm).

Mazor and colleagues also took examples for histology six months after the operation that showed a well formed bone full of osteoblasts and osteoclasts in their lacunae. In 2013 Tajima and colleagues published a similar paper where the mean bone height increase was 7.5 mm.¹¹ It can be seen from Figs. 1-10 below that the bone does not go all the way over the apex of the implants. Therefore, it

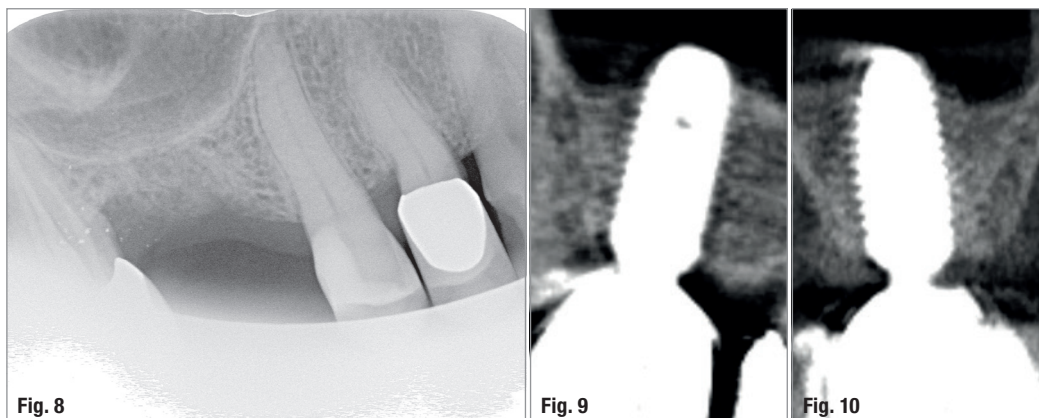


Fig. 8: Case 2, pre-operative.
Fig. 9 & 10: Case 2, six months after operation.

is helpful to look at a paper published by Palma and colleagues: in an animal study, they discovered that although there was not bone over the apex of the implants, the apex was covered by the Schneiderian membrane.¹² A-PRF has been well introduced in the literature over the last years by Dohan and colleagues.¹³⁻¹⁶

Cases

Two patients were treated in Godt Smil Odense over 16 months. Both of these patients had one thing in common, they did not want any animal products to be used in the treatment and therefore choose to use A-PRF as their sole grafting material. Both patients were in good general health and do not smoke. Venous blood was sampled with a so-called butterfly (Vacurette® Greiner bio-one) and the rule is 10 ml of venous blood for every dental implant, plus 10 ml for each mm of planned bone height. The blood is collected in 10 ml tubes (A-PRF®+) and are centrifuged according to Choukroun's protocol.

Operation

Premedication is 2,000 mg Imadrax (Amoxicillin), 1,000 mg Pinex (Paracetamol) and 400 mg Ibumetin (Ibuprofen) 60 minutes before treatment. The oral cavity was rinsed with 0,2% Chlorhexidin for one minute. Local anaesthesia was administered buccally and palatally (Xyloplyin® dental adrenalin 20 mg/ml + 12.5 microgram/ml lidocaine hydrochloride + adrenalin, DENTSPLY). The mucoperiosteal trapezoid flap was raised and osteotomy was performed using the Summers technique. A-PRF membranes were placed into the sinus underneath the Schneiderian membrane. Valsalva tests were negative for both patients. The dental implant (K3Pro Sure) was inserted and the last A-PRF membrane was placed over the area, underneath the incision line.

Both dental implants had good primary stability. Sutures were Glycolon 6-0 (Resorba). No further bone augmentations were done. Postoperative med-

ication was Imadrax (Amoxicillin), 500 mg 4 times a day for three days, Ibumetin (Ibuprofen, 400 mg) in combination with 1,000 mg Pinex (Paracetamol) as needed. Both patients were instructed to remain on soft diet for the next two days, no physical activity for seven days. Abutment operation was performed after twelve weeks and both dental implants received a screw-retained Prettau® full-ceramic crown.

Discussion

It is not possible to have valuable results from a small case presentation like this, but it is clear that a considerable amount of bone has formed around the implants, both dental implants were stable six months after loading. There was no BOP at control three months after loading. Previous publications on this matter confirm that it is safe to use A-PRF to increase the bone height in sinus maxillaris using the Summers technique when the primary stability of the implant is good.^{3,4,10,11,17} Further research in this area is much needed.

Editorial note: A different documentation of the same cases has been published in The Icelandic Dental Journal. A list of references is available from the author.

contact

Dadi Hrafnkelsson, Cand Odont

Overtandlæge
 Godt Smil Odense/Godt Smil Hørsholm
 Hovedgaden 55 C, 2. sal
 2970 Hørsholm, Denmark
 Tel.: +45 70294020

Bimaxillary Rehabilitation

Implant-supported zircon-ceramic bridges

Author: OA Dr Björn Dziedo, CA Prof. Dr Dr Stefan Schermer & Dr Elena Mihalcioiu, Germany

Introduction

In September 2014, a dentist-anxious 63-year-old patient from abroad presented with a relatively limited time window and the desire for a fixed, metal-free biological dental restoration in our clinic. The case was discussed in the interdisciplinary team of surgery, prosthodontics, dental technician and anaesthesiology and planned with the patient in our international office as a stationary patient for one-stage full-ceramic treatment case.

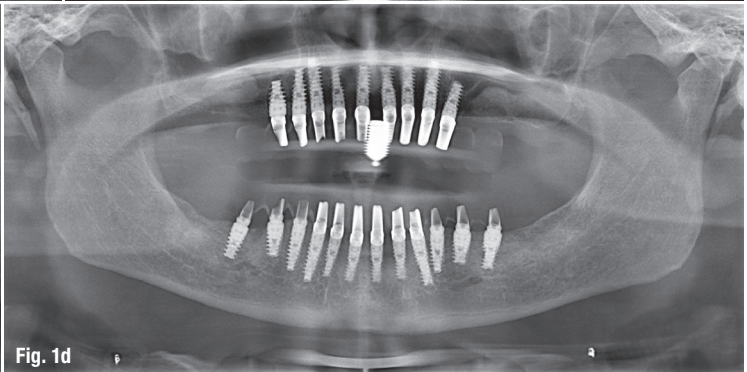
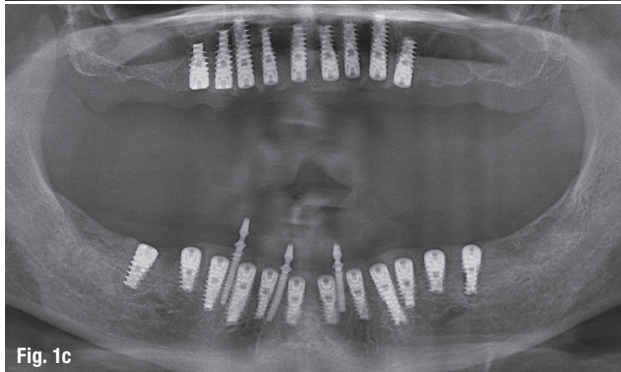
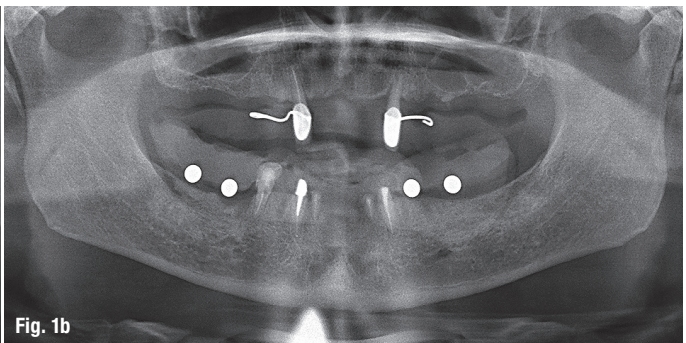
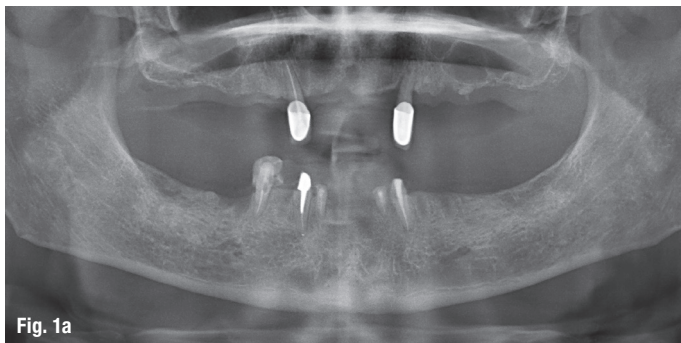
workplace need an extremely fast therapy with visible milestones. Experienced surgeons and prosthodontists work hand-in-hand from planning the surgery up until aftercare. The lead prosthodontist requires an extremely experienced and skilled dental technician at his side.

History—clinical examination—consultation

Besides a well-adjusted diabetes mellitus and coronal predisposition after successful cardiac surgery, the patient was well, his medical history without pathological findings. Dental inspection revealed massive horizontal ridge atrophy in the lower jaw and an extensive horizontal and vertical atrophy of the upper jaw. The removable clasp denture would

- Fig. 1a:** OPG initial findings.
- Fig. 1b:** OPG with reference spheres.
- Fig. 1c:** OPG postoperative.
- Fig. 1d:** Control-OPG for evaluation of the fitting of the abutments, the mock-up is seated maxillary, including the radiopaque pin for joint-registration.

The International Office personnel took care of the administrative procedures, visa and travel issues and tried to make the stay optimal here for everyone involved. Foreign patients and anxious patients, as well as patients with a strong involvement into their



This is



Very smart,
very simple,
very iSy.



iSy. The intelligent system.

iSy is the sensible, lean implant system that ensures cost-efficient implant treatment whilst still offering reliable CAMLOG quality. Whether digital or conventional, whether transgingival or subgingival: thanks to its intelligent design, the implant sets and the three treatment models, iSy is versatile and flexible – adding real added value to your daily practice by its easy handling and efficient workflow. And all this at an unbeatable cost-benefit ratio. Have a look and see for yourself:

www.isy-implant.com

Fig. 2a: Situation after implant exposure after two weeks.

Fig. 2b: Impression with individualised foil tray with additional retentions.

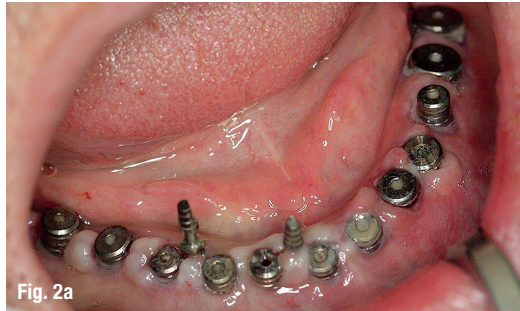

Fig. 2a

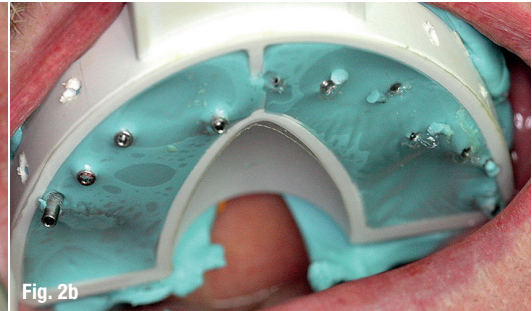


Fig. 2b

have compromised the patient's quality of life significantly, the remaining teeth would have been weakened and bone loss accelerated. In the mandible, an insufficient temporary bridge of 33–45 had been established. Extraorally, a negative lip line, the typical symptom of a vertical loss of occlusal plane, was detected. A CMD-test, in which the maximum jaw movements and symmetries were evaluated at opening and closing, revealed an age-appropriate finding with no evidence of pathological changes of the temporomandibular joints. Oral inspection revealed residual dentition not worth retaining with a mobility of 2 to 3.

To estimate the risk for implant insertion by periodontal pathological bacteria, a bacteria risk test and Interleukin-1 test was taken from gingival fluid on all teeth using sterile paper points. The panoramic X-ray (Fig. 1a) confirms the already known clinical dental report. Neither for the surgery, nor for an advanced treatment plan, digital volume tomography would optimise the final result and was therefore not performed. In the posterior region of the maxilla, due to massive horizontal and vertical bone resorption, implantation is not possible without expanded augmentation on both sides. The lower jaw, however, provides sufficient vertical bone volume, so we can fulfil the desire of the patient of a fully loaded and functional lower jaw by inserting implants and horizontal reconstruction using alloplastic synthetic bone. In the upper jaw, nine implants were planned. To determine the possible implant length on OPG, a 5 mm reference sphere was used (Fig. 1b). The bacterial diagnosis showed a greatly increased bacterial count (> 1 million) of *denticola forsythus* and *treponema denticola*.

Preprosthetic treatment and surgery

In order to reduce the previously identified bacterial load, the patient started two days before surgery with the antibiotic treatment by Clindamycin per os and a professional dental cleaning. When selecting the antibiotic, we followed the recommendation of the laboratory test results, which recommended the use of Metronidazole or Clindamycin. We see Metro-

nidazole as much more prone to possible side effects. We especially followed the recommendations of the American Heart Association with Clindamycin. We have very good experiences with Clindamycin due to its bone penetration ratio. The patient's own medication was maintained.

Impressions and bite registration followed for the production of removable temporary prostheses. In general anaesthesia, all teeth were extracted, followed by the excision of granulation tissue. In the upper jaw, bilateral external sinus lifts were performed with accretion of hydroxyapatite (Ostim®, Heraeus-Kulzer) and membrane (Cerasorb®, Curasan) and a total of nine implants (Alpha bio TEC) were inserted. In the lower jaw, twelve implants and three temporary implants were inserted to stabilise the prosthesis (immediate provisory implant, Nobel Biocare). Bone edges were smoothed, bone defects filled with alloplastic bone substitute material (Ostim®, Heraeus-Kulzer). Tension-free wound closure and the fitting of the temporary prostheses ended the surgery. The patient received inpatient care in the hospital. The postoperative panoramic X-ray was inconspicuous (Fig. 1c). Postoperatively, in addition to the antibiotic, ibuprofen and nose decongestants (Otriven®) were prescribed. Eleven days postoperatively, sutures were removed. All wounds were completely closed, which should allow a good prognosis for hard and soft tissue consolidation. The patient was in a good general condition.

Implant exposure followed four months after implantation. When exposing, the temporary implant in region 32 was extracted due to lack of space.

Implant imprints

After two weeks of healing time after the exposure, the patient presented a well-healed gingiva (Fig. 2a). The prosthesis on the two temporary implants in the lower jaw have fulfilled their function as stabilisers, now they had to be removed before the upcoming impression. The resulting defect was filled with alloplastic bone substitute material. The open impression (pick-up technique) of many close-set implants with laboratory-manufactured individual impression trays is difficult from our perspective.

YES!



**I WANT
IMPLANTS**

MADE BY DENTAURUM.

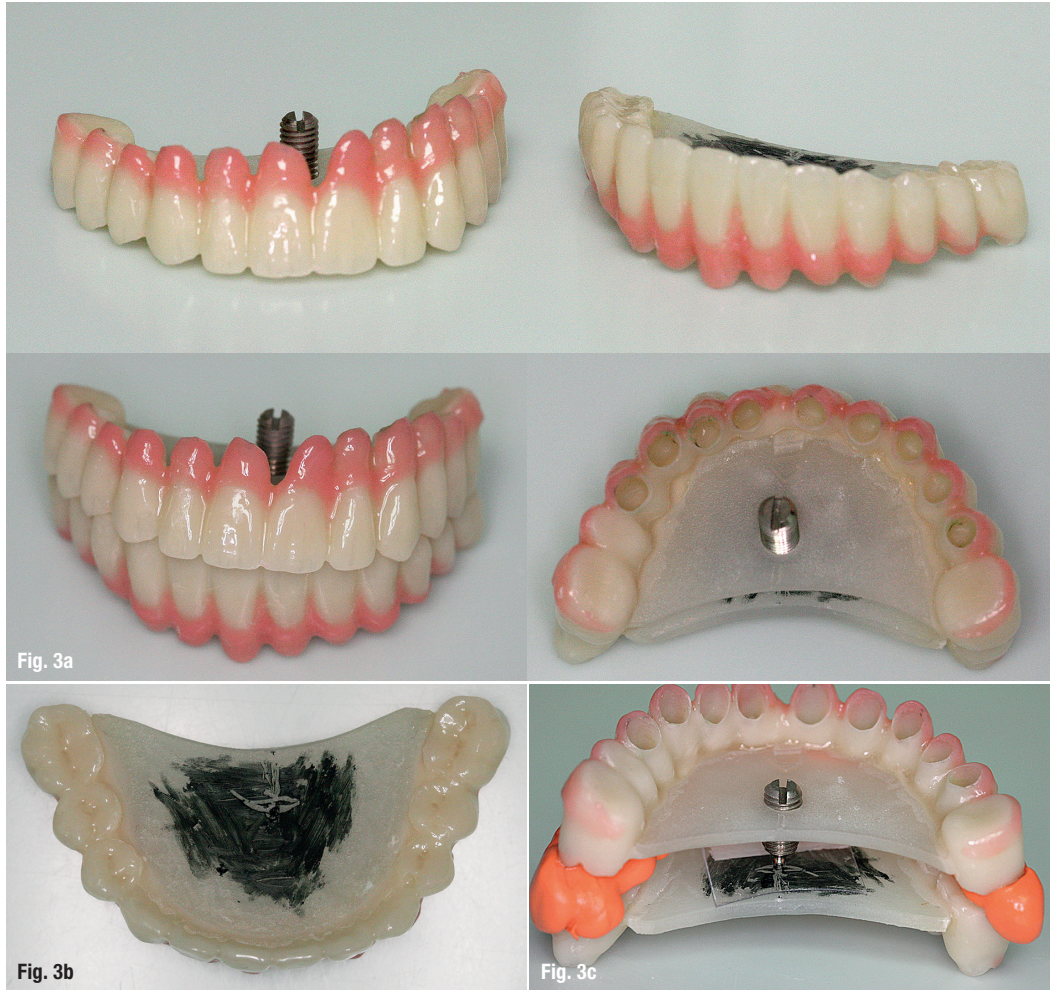More than 20 years of expertise, reliability
and innovation in implantology – worldwide.
Say yes!



Fig. 3a: "PÜR"-mock-up bridges with pin registration set.

Fig. 3b: Visualising the joint movements on the mandibular.

Fig. 3c: Bite encryption of the pin registration plate.



On the one hand, the technician must guess the implant orientation correctly, on the other hand, sometimes the impression material overflows through the impression tray holes due to the pressure exercised while taking the impression. A possibly necessary reworking on the individual tray due to the divergence of implant positions can adversely affect stability, which could lead to breakage during impression taking. That is why we only use the Miratray® impression tray (Hager&Werken) in implant-supported dentures. The penetrable foil seal prevents overflow of the impression material (Fig. 2b). Thus, incorrect positioning of the tray is

almost impossible. The plastic tray can be reworked for patient comfort at the edges and individualised. In this case, retentions can be drilled for the impression material (Fig. 2b). The double-impression technique itself is carried out in a mixing method in combination of high and low viscous silicone. This is followed by the selection of the desired tooth shade. The recommendation of age-appropriate tooth colour shade was refused by the patient and he opted for the VITA colour A1. The gum colour is determined using a gum-colour ring (GC initial gum set) in the presence of the dental technician.

Fig. 4a: Parallelism check between bipupillary line and occlusal plane.

Fig. 4b: Parallelism check between occlusal plane and Camper's plane.

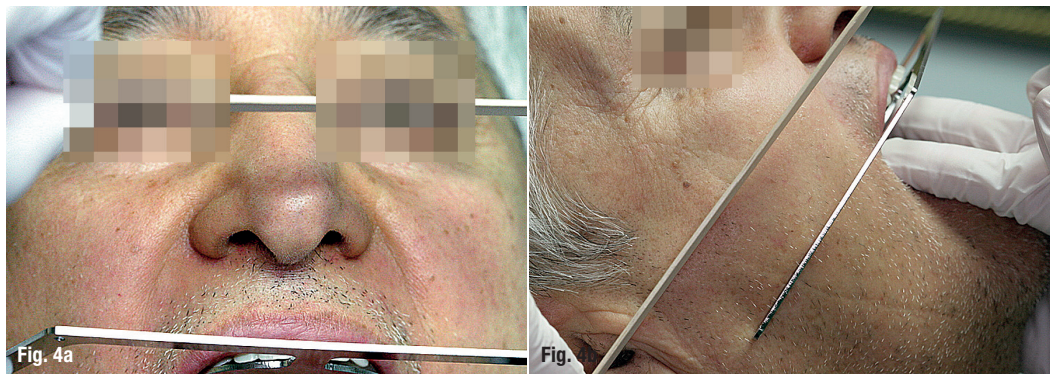

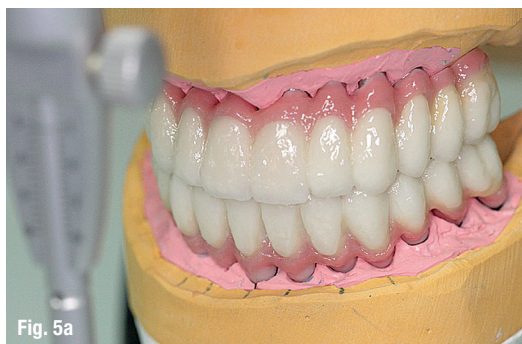


Fig. 5a

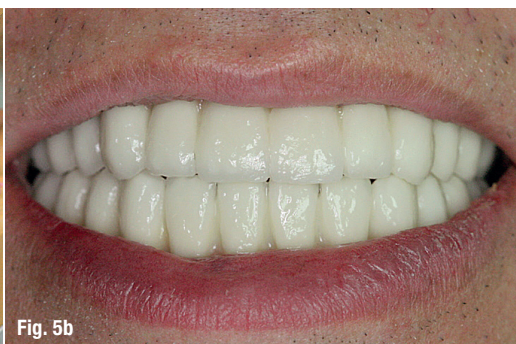

Fig. 5b

Fig. 5a: Bisque ceramic in articulator.

Fig. 5b: Bisque ceramic *in vivo*.

(Aesthetic) Fitting

For large circular fixed restorations, a fully sculpted mock-up was made of model plastic in the desired tooth colour and possible tooth shape (Figs. 3a–c). This prosthetic feature served as a trial run, as a quality transition and a rehabilitation supply ("PÜR"-mock-up Berlin clinic model, Figs. 3a–c) and was originally developed by us specifically for extensive supplies, cases of this kind, and cases with total atrophic alveolar ridges so we could check the fit, the bite and aesthetic wishes of the patient for the future dentures.

In this step, zirconium is not yet milled. If the mock-up does not fit, a second check-up impression can be made simply via the individual implant abutments for the production of a new model for the master technician. The abutments were screwed in with 20 N/cm in accordance to the agreement with the master dental technician and the manufacturer. The seat of the abutments would be evaluated after transferring by using a transfer key on the panoramic X-ray (Fig. 1d). The mock-up was used for the aesthetic check before the ceramic is made. Tooth colour, teeth shape and placing give the patients a real idea about the result. Change requests can easily be modified in the plastic denture. Furthermore, and most importantly for the patients' requirements, the "PÜR"-mock-up serves to hold off the moveable soft tissue, avoiding any need of a repeated exposure of the implants from the newly-grown tissue in the distal lower jaw under local anaesthesia.

The next step was the evaluation of the parallelism of the occlusal plane with the camper's plane and the bipillary line using the Candulor bite fork (American Dental Systems®, Figs. 4a & b). The mock-up was supplied with a registry plate made in the laboratory (Figs. 3a–c). After successful try-in and aesthetic fitting, the functional jaw movement registration via supporting pin registry was done (Fig. 3b) with subsequent bite encryption by registration silicone (Fig. 3c). In the present case, the patient had found his habitual occlusal position. If he had not done so, we would have performed an additional

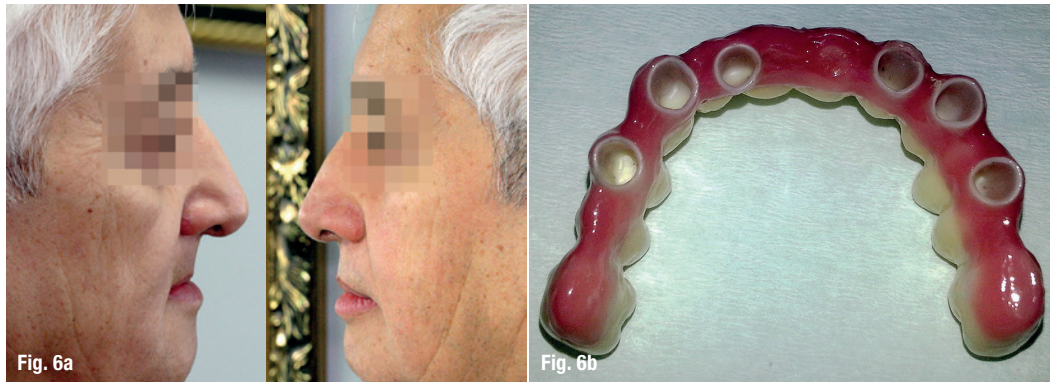temporomandibular joint movement registration using software-supported evaluation (zebris JMA system).

In the laboratory, the zirconium framework was milled and the veneering ceramics were applied according to the wish of the patient. Thus, the next step was the try-in of the bisque ceramic, which was made two days later (Figs. 5a & b). Usually, we advise a few days testing time for the patient to give us a feedback about aesthetics and function of the "PÜR"-mock-up. Due to the quite large phenotypic changes of patients, the testing period is both psychologically and functionally informative. The mock-up also serves as temporary denture and the patient can "practise" his new bite situation. From our point of view, this step significantly reduces the risk of ceramics chipping by habitual improper load or measures sensation induced malocclusion of definitive restorations. By the exclusively implant-supported tooth replacement, the neural feedback of the periodontium is missing. The absence of tactility specifically increases the risk of fracture of ceramic and can lead to traumata of the hard and soft tissue together with pain sensations. Since the patient comes from abroad and wanted to be supplied as soon as possible, the testing period was skipped, which was acceptable due to the good compliance and uncomplicated occlusal conditions of the patient. Practicing the new bite and education about the necessity of careful biting in the first days after placing the dentures were therefore important and crucial for the success of the treatment.

Bisque ceramic try-in

The information supplied by the mock-up was then incorporated into the planning of the zirconium/ceramic work and implemented by the dental technician. The data, which had already been entered to the computer by model scan, were now transmitted to the CNC 5-axis milling machine (Zenotec select hybrid, Wieland Dental), and milled from a solid zirconia blank, minus the space for the veneering ceramic that would be topped up manually by the master dental technician.

Fig. 6a: Profile of the left side without and the right side with bridges.
Fig. 6b: Convex basis of the bridge.



The surface texture and translucency of the ceramics compared to the plastic mock-up surprised the patient and increased his anticipation for the finished work (Fig. 5a & b). After tightening the abutment with a torque wrench to 20 N/cm, both the maxillary and the mandibular bridges were placed into their end position without any tension. Even after the use of pin registration, the bite is unusual for the patient and should be guided by the practitioner. Only after the patient independently reproducible has found the "new" bite, the occlusal examination by Shimstock film (Coltène®) can take place. Deflective occlusal contacts can be removed with a dental drill under water cooling. Bite registra-

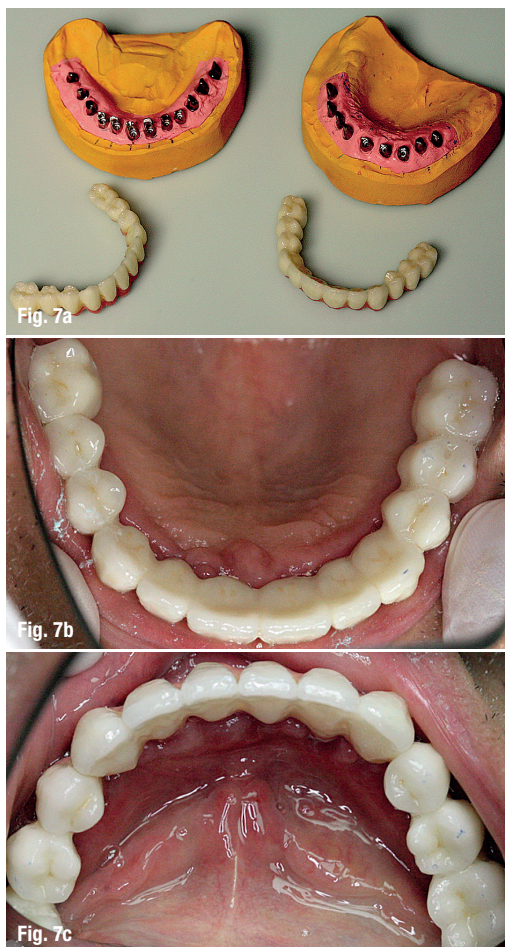
tion serves as visual check for all uniform occlusal contacts.

The profile without and with bridges is shown in figure 6a. It is plain to see how the upper lip seems voluminous, caused by lip support through the maxillary anterior teeth. At the ceramic try-in, oral hygiene was practised together with the patient using interdental brushes (TePe®). Close gap areas were identified interdental or between the ceramic and gingiva and expanded in the laboratory. It is always important to ensure that the basis of the dentures is designed convexly by the dental technician as represented in figure 6b by the bridge of another patient. The hassle-free oral hygiene must be ensured, specifically for older patients with partly limited motor skills.

Completion

Already one day after bisque ceramic try-in, the bridges were finished and inserted (Figs. 7a-c). After removal of gingiva formers, the gum was inflammation-free. The inner edge of the implant was filled with CHX gel and screwed in the abutments with 30N/cm according to the manufacturer's recommendations. Due to the multiple transmitting of the abutments in the previous steps, we used new abutment screws for the final screw, the abutments were cleaned with alcohol and sealed with plastic pellets and Cavit. The fit of the bridges was controlled again. The static and dynamic occlusion was bilaterally sufficient in the posterior area. Front and canines had no static occlusion. The all-ceramic upper and lower bridges were cemented with temp bond NE (Kerr™). Studies prove the good sealing and good biocompatibility of zinc-oxide non-Eugenol cements and recommend it for implant crowns and compounds.⁵ The number of abutments did not give rise to fearing independent loosening of the prosthetic. However, the option of removing the bridges is reasonable for cleaning or reworking reasons. Tooth size and tooth shape were in harmony with the facial appearance (Fig. 8). The patient is very happy with the final result. Then, once again, oral hygiene by using interdental

Fig. 7a: Final mandibular and maxillary bridges ready for the patient.
Fig. 7b: Maxillary bridge *in vivo*.
Fig. 7c: Mandibular bridge *in vivo*.



brushes were explained with urgency by a dental hygienist or a prophylaxis assistant.

Discussion

The patient came to our office with the desire for fixed dentures, which can be achieved in many different ways by using modern therapy concepts. Removable dentures, which would ensure no disadvantage in relation to durability, aesthetics and hygiene, were rejected by the patient. We often experience well-informed patients, who specifically ask for full ceramic, zirconium or one-stage supplies. Therefore, it is very important to discuss all possible treatment options with the patient, because their knowledge often comes from unknown sources, and it can be unclear if they might have too high expectations on the final result.

For a dental prosthesis which is only supported by implants, the jaw bone is the most significant in this context anatomically/physiologically. During the planning we orient ourselves first by the number of tooth roots to be replaced as the minimum number required, to avoid more bone resorption and to safely support the prosthetics. In the upper jaw, nine implants could be placed bilaterally in the posterior region due to strong resorption to replace the total of usually 24 tooth roots (17–27 in a complete dentition in the maxilla). In the lower jaw, twelve implants were inserted quantity to replace the 18 tooth roots in full dentition of 37–37 because of the better bone. Due to the patient who was from far abroad, we decided to do an all-in-one surgical procedure, where we remove all remaining teeth, reconstruct the vertical and horizontal bone defects and insert implants. A two stage surgical procedure with implantation in a second appointment has no significant benefit in this case in our opinion. The interesting discussion about the advantages and disadvantages of both variants would go beyond the scope of this prosthetically-oriented case demonstration.

The biological behaviour of teeth and implants as a carrier of dentures differs fundamentally.¹² Implants are ankylosed, teeth are connected with the bone by the periodontal ligament. The protective mechanoreceptive function,⁴ the better perceptions of bite force^{10,13} and the precise pain perception^{10,13} are lost with extraction of teeth and the associated loss of the periodontal ligament. The tactility of the osseointegrated implant is set off by other sensors. Kineberg and Murray described this compensation in their study of 1999 as "Bone perception",⁶ which cannot achieve the tactility of the periodontium. This bone perception, as an alternative feedback results from an interaction of receptors of the temporomandibular joints, skin, perios-

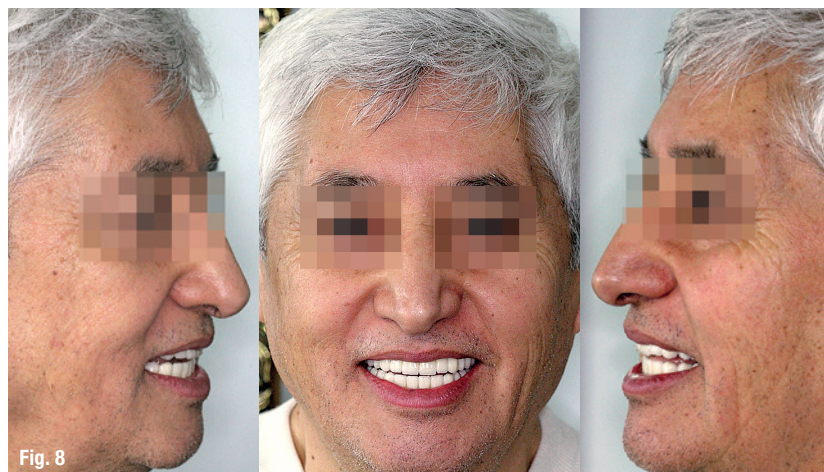


Fig. 8

teum and, in addition, of the mucosa by the use of mucosa carrying dentures. The tactility of implant-supported dentures is up to nine times less compared to natural teeth.^{3,4,9,10} To minimise the risk of overloading bite force by large implant-supported dentures, teeth should be maintained whenever possible to obtain the periodontal feedback,¹² which was not possible in the presented case.

To reduce the risk of crestal bone resorption, screw loosening and fractures on the scaffold or veneering^{3,8} of the definitive zirconium/ceramic restoration by abnormal masticatory forces in static and dynamic occlusion, the plastic mock-up should be worn to condition an alternative neural feedback. For implant impressions, we always use the pick-up technique. This has the highest accuracy compared to the repositioning technique.^{1,7,14} As impression material, we prefer A-silicones rather than polyether because it tends to be more accurate due to its high hardness. In combination with the customisable foil Miratray[®] implant tray, the impression for purely implant-supported dentures is easy, which is confirmed by stress-free incorporation in a rehearsal of the mock-ups. Performing large surgical/prosthetic restorations of the orofacial system requires close interdisciplinary cooperation between surgeon, prosthodontist, master dental technician as well as good compliance and resilience of the patient.

Editorial note: A list of references is available from the publisher.

contact

OA Dr Björn Dziedo
BERLIN KLINIK
Department of Prosthodontics
Leipziger Platz 3
10117 Berlin, Germany
prothetik@berlin-klinik.de

Fig. 8: Final result after cementation.

Fixed **implant-** supported prostheses

Minimally invasive **immediate rehabilitation** of the anterior maxilla

Authors: Zhe qu, Xiang zhang & Lan ma, China

This paper discusses a case of continuous absence of maxillary anterior teeth which is treated by immediate implant-supported prostheses. The simple plate made preoperatively was used for flapless implant surgery. Temporary restorations induce soft tissue forming and ultimately achieve better aesthetic results.

A non-impression transfer device called (die) was made on the plaster model. Flapless implant surgery was conducted with the guide of the plate; two bone-level implants were placed. The immediately fabricated prosthesis was placed on the same day. The definitive prosthesis was placed after a healing time of six months.

A middle aged female patient presented at Dalian Stomatological Hospital for a consultation to repair the continuous absence of maxillary anterior teeth (11, 21, 22) with implants. The oral examination and the cone beam computed tomography (CBCT) were carried out and an impression was obtained. When the plaster cast was available, a diagnostic wax-up was made and hot press was used to form a simple

plate. During the following period, individual implant stability and soft tissue response to the provisional prosthesis were good. When the definitive prosthesis was done after six months, excellent aesthetic results were achieved with the papilla by filling the interdental space, resulting in an absence of the black triangle and a harmoniously scalloped gingival margin.

Fig. 1: Frontal view of the partially edentulous area.

Fig. 2: Occlusal view of the partially edentulous area.

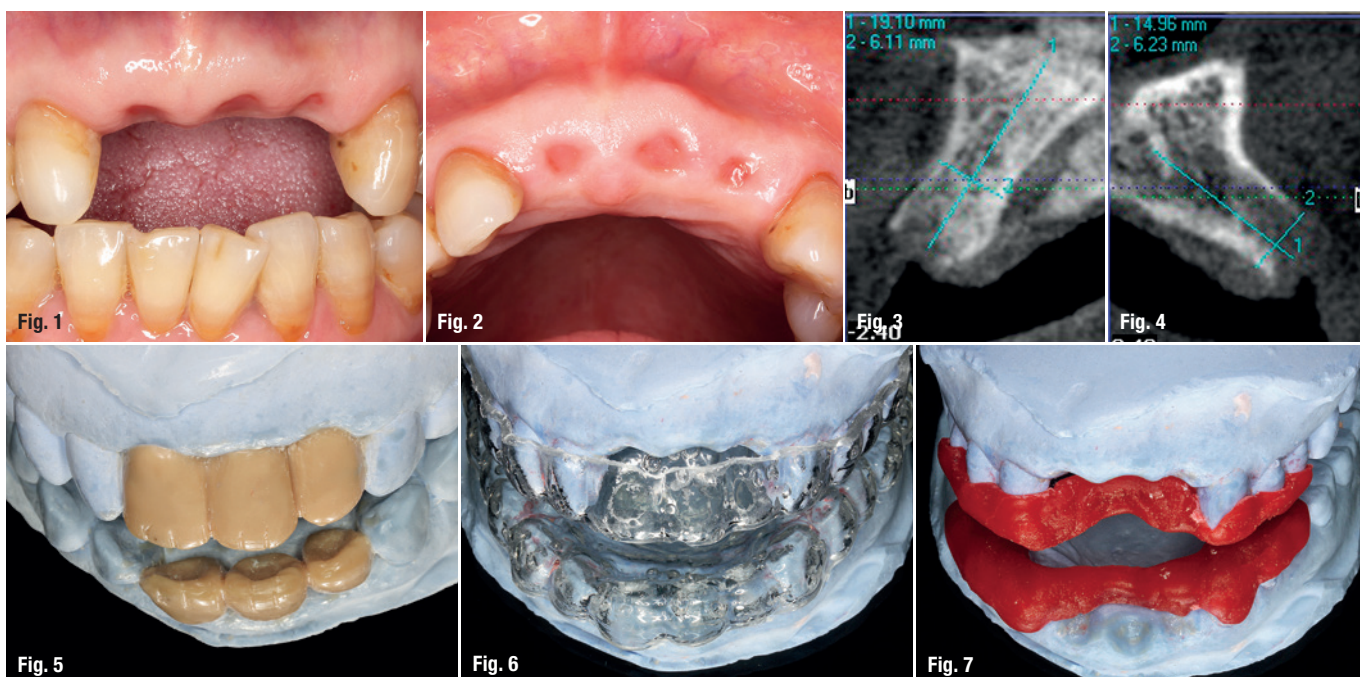
Fig. 3: CBCT radiograph of 11.

Fig. 4: CBCT radiograph of 22.

Fig. 5: Diagnostic wax-up.

Fig. 6: Simple plate fixed on the plaster model.

Fig. 7: Non-impression transfer die made of acrylic resin.



Materials and methods

General condition

A 52-year-old female patient with missing two central incisor and one left lateral incisor (11, 21, 22). These teeth were extracted three months ago due to heavy caries. The patient requested implant therapy. The extraction points were healed and the gingiva was healthy. cone beam computed tomography (CBCT) showed sufficient bone height and width in the edentulous span, with 19.1 mm in height and 6.1 mm in width at the right central incisor alveolar bone, 14.9 mm in height and 6.2 mm in width at the left lateral incisor. The patient was in good health and had no history of bruxism or other bad oral habits. The diagnosis was a dentition defect of the maxilla.

Treatment design

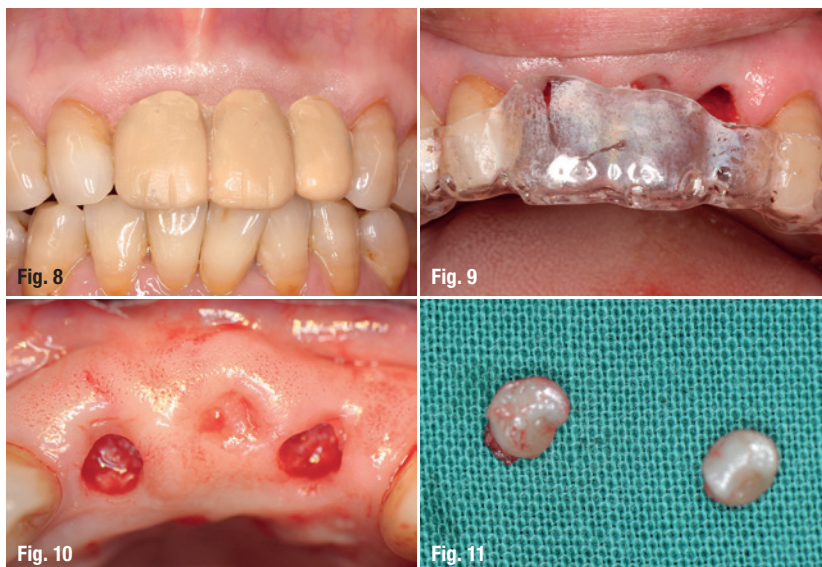
Two implants were placed in sites 11 and 22, immediate rehabilitation of the three teeth with a two-implant supported bridge and final prosthesis was made after six months.

Materials

One implant system (BEGO Semados RSX-Line, BEGO, Germany) and acrylic resin (PATTERN RESIN, Japan) were applied.

Treatment protocol

1. Clinical examination was conducted before surgery. Assess of the quality and quantity was based on the CBCT. All conditions were fit the criteria for implant surgery.
2. Two impressions were made with polyether silicone rubber and two plaster model were obtained. One was used to make the diagnostic wax-up on the



edentulous sites and then hot press was applied to form a simple plate to guide the implants to be placed in an optimal position. A non-impression transfer die was made on the other one using acrylic resin, and two holes were made on sites 11 and 22 of the model.

3. The die was tried in by the clinician to ensure stability. Plate and die were soaked in liquid with 75 per cent of alcohol for thirty minutes.
4. Implant placement was performed under local anaesthesia (4% articaine with 1:100,000 adrenaline). The simple plate was used to guide the implant to be placed in an optimal position. Then flapless implant surgery was conducted, two implants were placed at the sites of 11 and 22 (BEGO Semados RSX 3.75 mm × 15 mm). The ISQ value of the two implants were 80 and the primary stability was

- Fig. 8:** Trying the wax-up.
Fig. 9: Simple plate assisting in determining the implant position.
Fig. 10: Flapless technology with punch.
Fig. 11: The soft tissue removed.
Fig. 12: Frontal view of the implants.
Fig. 13: Occlusal view of the implants.
Fig. 14: Placing of the open-tray impression posts.
Fig. 15: Placement of the die.
Fig. 16: Combination of posts and die with acrylic resin.
Fig. 17: Three-dimensional position of the implants.

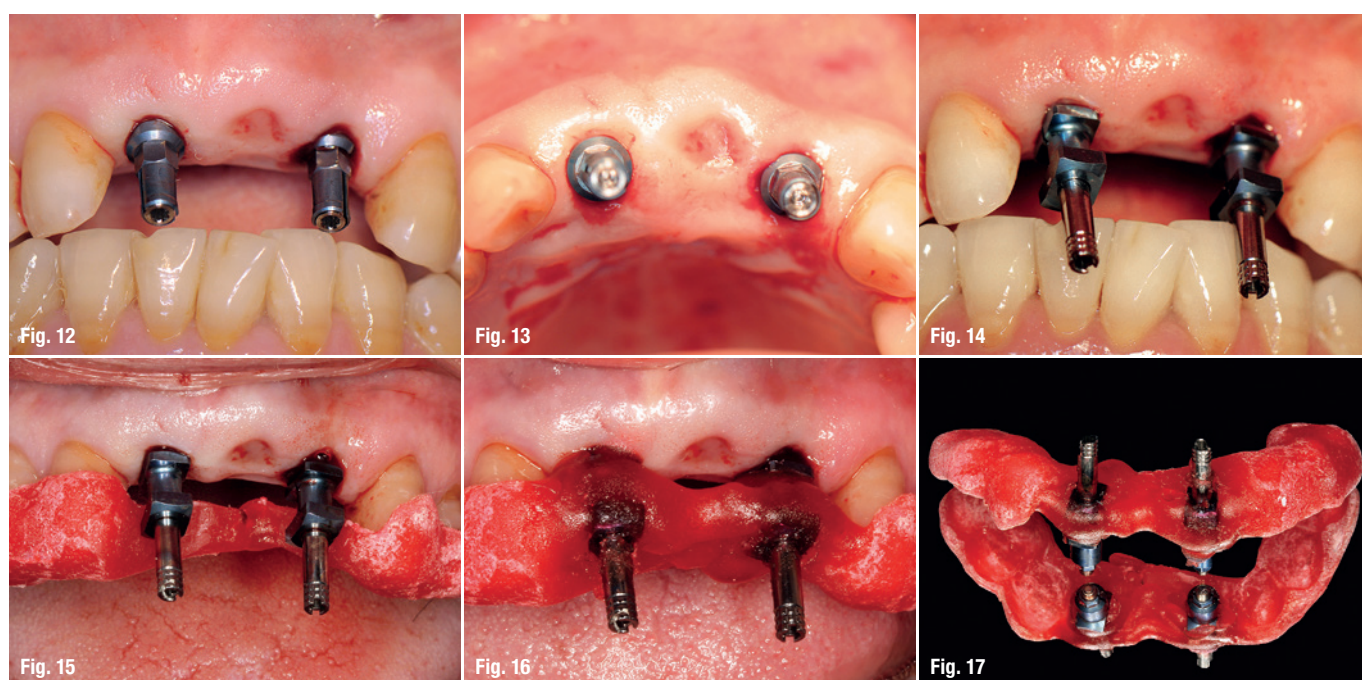

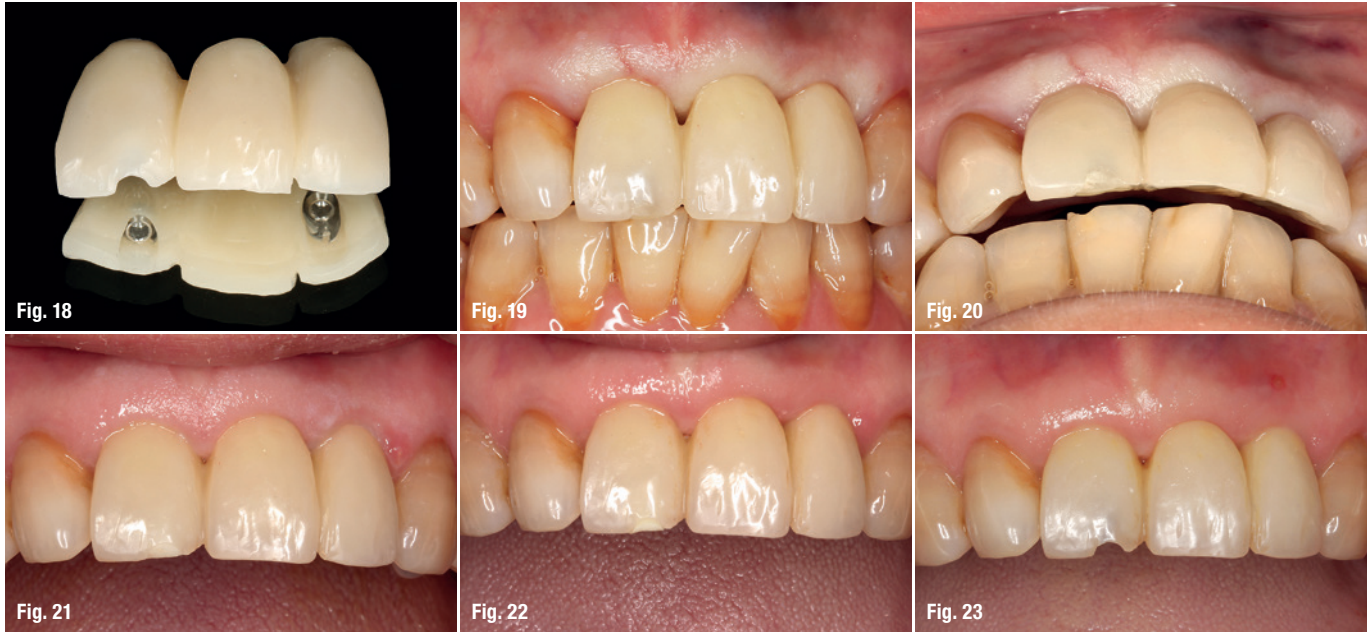


Fig. 18: Provisional prosthesis.

Fig. 19: Frontal view of the provisional prosthesis.

Fig. 20: Implant-protected occlusion.

Fig. 21: Frontal view after ten days.

Fig. 22: Frontal view after one month after surgery.

Fig. 23: Appearance of the fistula after two months post-surgery.

gained. The abutments and open-tray impression posts were fixed onto the implants before suture.

- In the prosthetic procedure, the clinician connected the open-tray impression posts and the die with acrylic resin. Then the three dimensional position of the implants was transferred onto the plaster model. Implants were replaced and the remaining gap was filled with acrylic resin. After the placing of the healing abutments onto the implants and shade selection, the patient was able to take a break. The polymeric porcelain (Ceramage) screw-retained provisional prosthesis (PSTTiA, BEGO, Germany) was manufactured at the laboratory and delivered to the clinician within three or four hours.
- The prosthesis was inserted after being delivered to the clinician. When adjusting the occlusion, implant-protected occlusion guidelines were fol-

lowed. The screw holes were closed with light-curing resin.

- Antibiotics (amoxicillin and ornidazole) were given daily for three to five days after surgery. The patient was educated to maintain oral health. The evaluation of implant stability, oral hygiene, occlusion and soft tissue was conducted every four weeks. The surface of the provisional prosthesis was adjusted to induce a good shape of the gingiva. A fistula appeared at the buccal surfaces of the soft tissue after two months of the surgery. Fortunately, periapical radiography showed good osseointegration. After treated with hydrogen peroxide and minocycline hydrochloride for several times, it was therefore healed.
- Based on the good osseointegration of the periapical radiography, the good stability of the im-

Fig. 24: Periapical radiograph two months later.

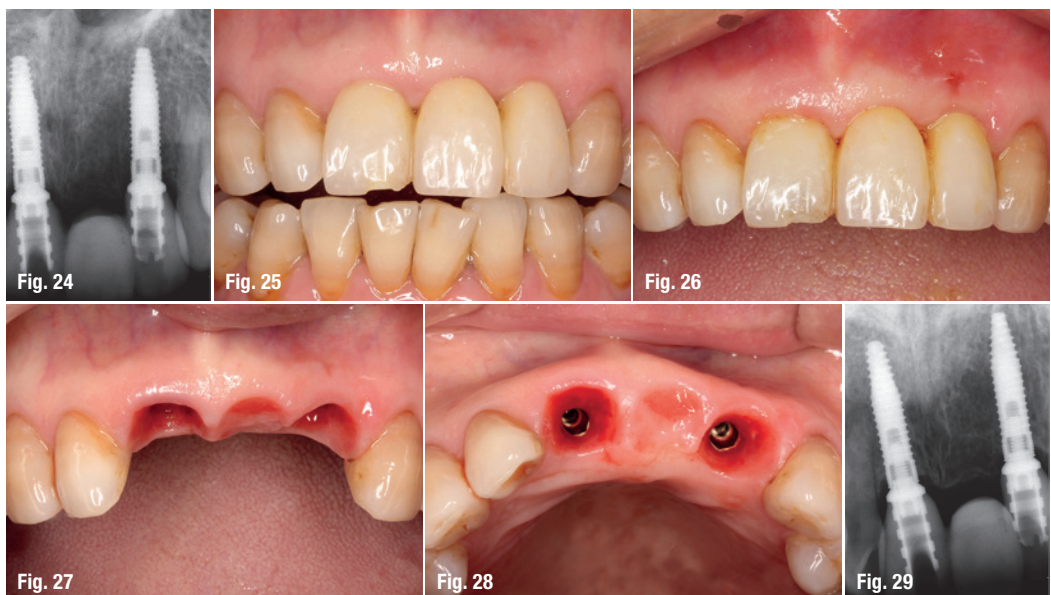Fig. 25: Frontal view three months later.

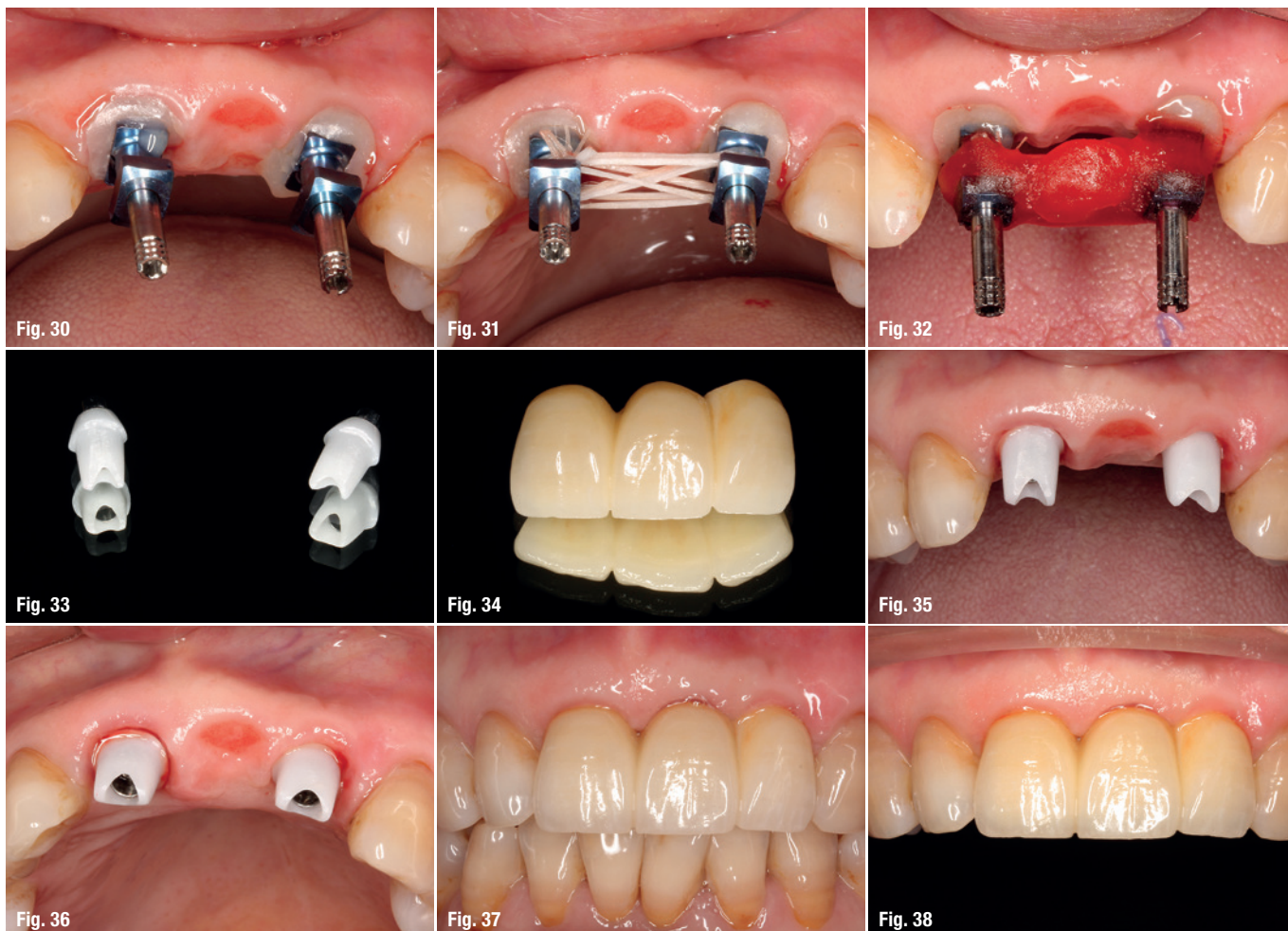
Fig. 26: Frontal view five months later.

Fig. 27: Frontal view six months later.

Fig. 28: Occlusal view six months later.

Fig. 29: Periapical radiograph six months later.





plants and high ISQ (ISQ of 11 and 22 were 78.81, respectively), the final restoration protocol was conducted six months after implants placement. The final abutments (PSCATi, BEGO, Germany) and prosthesis were made of zirconia.

Results

Evaluation methods

Assessment of the soft tissue and prosthesis was based on the pink aesthetic score (PES) and white aesthetic score (WES) put forward by Fürhauser and Belser, respectively. Variables of the pink and white aesthetic scores are shown in tables 1 & 2.

Analysis

The PES and WES were 14 and 10, respectively. All variables got maximum scores. The patient was highly satisfied with form, colour, translucency and surface texture.

Discussion

Flapless technology

Over the past decade in oral surgery, the concept of minimally invasive surgery has been established,

consisting in taking advantage of advancements experienced in diagnostic techniques and specific surgical instruments, to perform surgical procedures infringing as little damage as possible to the patient by minimal incisions or even flapless (punch). There are many advantages that have made flapless surgery a technique increasingly demanded and used by clinicians in implantology. Flapless surgery prevents the reflection of soft tissues and the absence of suture reducing the surgical trauma. As a result, the necessary wound healing process is minimal. It also leads to minimal interference on the blood supply, as a consequence of higher osseointegration (greater contact between bone and

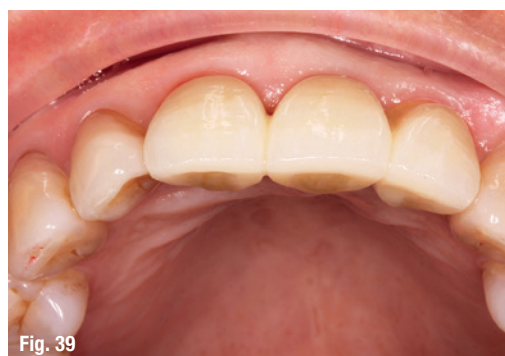

Fig. 30: Placement of the open-tray impression posts.

Fig. 31: Connecting the posts with dental floss.

Fig. 32: Connecting the posts with acrylic resin.

Fig. 33: Personalised zirconia abutments.

Fig. 34: All-ceramic zirconia crowns.

Fig. 35: Zirconia abutments fixed onto the implants.

Fig. 36: Occlusal view of the zirconia abutments.

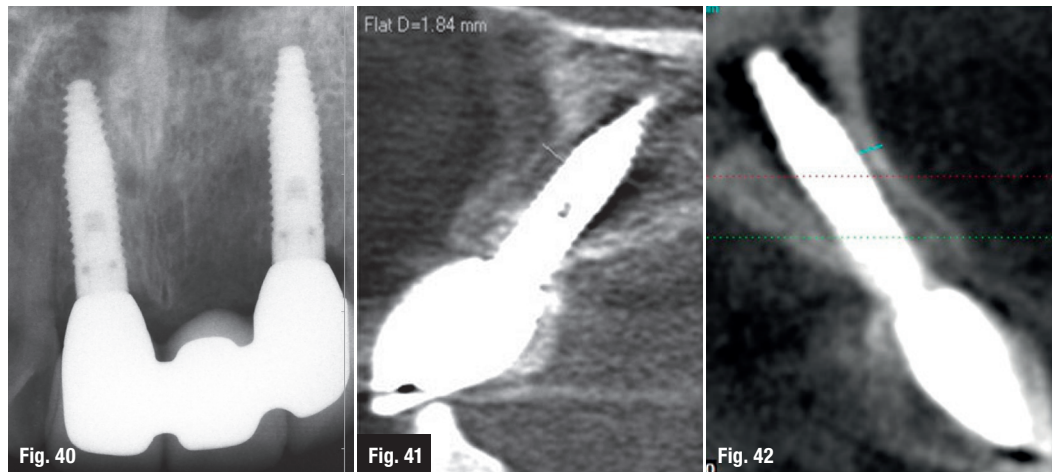
Fig. 37: Frontal view of the final prosthesis.

Fig. 38 & 39: Occlusal view of the final prosthesis.

Fig. 40: Periapical radiograph showing excellent precision.

Fig. 41: Periapical radiograph of 11 after one year.

Fig. 42: Periapical radiograph of 22.



implant (BIC), less periimplant bone loss and less gingival inflammation. Another advantage of flapless surgery that both the clinician and patient appreciate is the significant reduction in intraoperative and postoperative bleeding. The absence of flap and suturing greatly simplifies the surgery, shortening its duration in most of the cases. For these reasons, patients will feel more comfortable and less swelling, pain and other complications in and after the surgery.

However, one should always notice that this type of surgery requires special concentration as it comes from a technique without direct vision of the bone. This implies the importance of a preoperative design of the precise position of the implants. And strict in-

clusion criteria should be established. The following principles must be observed in the flapless procedure:

1. More keratinised tissue must be present (at least 5.0 mm) because the flapless procedure requires the actual removal of some of the tissue; and
2. more bone width (at least 4.5 mm) must be available without undercuts of more than 15°. Since visibility is more limited when using the flapless technique, it is more difficult to ensure that the implant is positioned in the centre of the crestal bone. In the reported case, a patient with sufficient bone volume and good health was chosen, and preoperative design was made through the CBCT radiograph and the wax-up. The surgery

Variables of the pink esthetic score

Variables		Absent	Incomplete	Complete
Mesial papilla	Shape vs. reference tooth	0	1	2
Distal papilla	Shape vs. reference tooth	0	1	2
Level of soft tissue margin	Level vs. reference tooth	Major discrepancy > 2 mm	Minor discrepancy 1–2 mm	No discrepancy < 1 mm
Soft tissue contour	Natural, matching reference tooth	0	1	2
Alveolar process	Alveolar process deficiency	0	1	2
Soft tissue color	Color vs. reference tooth	0	1	2
Soft tissue texture	Texture vs. reference tooth	0	1	2
Maximum total PES 14				

Table 1

Variables of the white esthetic score

Variables	Major discrepancy	Minor discrepancy	No discrepancy
Tooth form	0	1	2
Tooth volume/outline	0	1	2
Color (hue/value)	0	1	2
Surface texture	0	1	2
Translucency	0	1	2

Maximum total WES 10

Table 2

was conducted by an experienced surgeon and a simple plate was used to assist the position of the implant.

operation, flapless implant surgery with immediate restoration in the aesthetic area can be a satisfying therapy.

Immediate loading

Traditionally, implant treatment is based on a two-stage protocol with a healing period of three to six months during which the implants are submerged to achieve osseointegration. Recently, this clinical suggestion has been challenged. Numerous clinicians now advocate immediate or early loading of implants. The advantages of immediately loaded implants are clear: they require shorter treatment periods and allow immediate recovery of function and aesthetics. The clinical performance and prognosis of the single-stage surgical protocol are known to be comparable to the traditional two-stage method. There are some articles reporting a cumulative survival rate of 95%, which is investigated immediately loaded single implants.

Results from these studies suggest that immediate loading could achieve equal success rates to those found in delayed loading. Many studies reported a greater satisfactory rate and less marginal bone loss in patients with immediate loading compared to delayed loading. Another benefit of this technology is its improvement of aesthetics and function in partially edentulous patients, especially patients with absence of anterior tooth. In addition, we can get better soft tissue morphology with the adjustment of the provisional prosthesis. In our case, the patient lost her anterior tooth of the maxilla and had high demands on her appearance. For these reasons, immediate loading was the best therapy for her.

Conclusion

With strictly selected indications, carefully designed treatment plans, and a carefully conducted

With the maturing of dental planting techniques, immediate restoration after implant surgery has become a field of interest in clinical treatment and scientific research. Conventional rehabilitation with implant-supported prostheses have a long period of waiting before the patients receive the upper prosthesis—this period differs between six to twelve months. This may have some kind of aesthetics, function, pronunciation, and mental health effects on patients with a missing anterior maxilla tooth. Many studies have shown that implant survival rate and marginal bone loss of immediate restoration were not statistically significant compared to conventional rehabilitation. Immediate reconstruction can greatly reduce the time the patient has to spend with an incomplete dentition. Furthermore, the provisional prosthesis can shape the morphology of the soft tissue and achieve effects desired by patient and clinician.

contact

Zhe qu, Xiang zhang & Lan ma

Dalian Stomatological Hospital
No. 935 Changjiang Road Shahekou District
Dalian, China
Tel.: +86 411 84625234
13604151642@sohu.com
www.dlkq.cn

A nuanced perspective on periimplantitis

Source: Nobel Biocare, Interview by Dr Stefan Holst, Switzerland

Fig. 1: Professor Tomas Albrektsson:
 "The frequency of periimplantitis has been grossly exaggerated in the literature. All bone loss that happens in the first year is definitely not periimplantitis."



One of the most widely quoted scientists in dental implantology, Professor Tomas Albrektsson, worries that periimplantitis is increasingly used as an alarming label for benign marginal bone loss around implants. On a recent visit to Zurich, Switzerland, he took questions from Dr Stefan Holst, Nobel Biocare's Vice President of Implant Systems and Research, on this topic.

According to some wide-spread yet crude definitions, periimplantitis can be characterised by a periimplant bone loss of as little as 1.0 mm in the first year after initial treatment. Since some post-treatment bone loss is all but inevitable during initial bone remodelling in even the most successful and long-lasting cases, such definitions lead, as a matter of course, to controversy.

Dr Stefan Holst: Periimplantitis is currently a prominent discussion topic at various events and

congresses. Is the nature of these discussions beneficial for the implantology community or could it be a threat to our reputation?

Prof. Albrektsson: When incorrect biological reasoning is done, it is always a threat. When we look at the clinical outcomes in long-term studies, they are so much better than many of those that we are hearing and reading about. I'm very critical of this. It is trying to make problems of things that may not be that problematic.

The frequency of periimplantitis has been grossly exaggerated in the literature. All bone loss that happens in the first year is definitely not periimplantitis. We see bone remodelling and bone loss for very different reasons. This bone loss is benign in that it doesn't threaten the implant.

Then we have a disease called periimplantitis which, with controlled implants placed by properly trained individuals, is a rare disease, but still one of some magnitude. With 1–2% of modern controlled implants showing clear signs of disease at ten years or more of follow-up, we can't ignore it. But we are not helped by the exaggeration of the figures. There are 13 different definitions available for periimplantitis. And we can be without the great majority of those.

“We see bone remodelling and bone loss for very different reasons.”

Holst: How does a clinician determine whether bone loss is a natural physiological reaction or that caused by disease?

Albrektsson: From the clinician's standpoint, we should take all types of marginal bone loss seriously—even if the great majority of implants with some bone

loss will never develop periimplantitis. The problem is that we don't know which ones.

For example, one reason for problems with bone loss is cement remnants in the soft tissue. If you remove that in time, the bone loss stops. The implant can function happily ever after, without any problems. But there is also the possibility that if you leave the cement remnants in place for 10, 15 or 20 years, then periimplantitis may follow with the same implant.

A clinician should always take action when he or she sees marginal bone loss or rather the preface of it, which is called mucositis. Mucositis is only the first sign of an immunological reaction; it has nothing to do with anything else but immunology, which is unfortunately not understood by many of our clinical colleagues.

Holst: Recent studies based on the Swedish population imply that implant brand plays a role in periimplantitis. Is this not misleading given that so many factors influence treatment outcomes?

Albrektsson: Many of the figures that are being quoted, be that in the recent Swedish publication or others, are lamentably unrealistic. They have used the most liberal definitions they can find of what they call a disease when in reality it is no such thing.

Our own studies of long-term follow-up on implants demonstrate very clearly a similar, small percentage of implants that are hit by periimplantitis, they are between 1 and 2%, whether you prefer one of the major implant systems or the other, is no difference.

But implant systems that say they are similar to other documented implants, and therefore need no documentation of their own, are not to be trusted. Clinicians need to pick an implant system that has its own documentation published in peer-reviewed papers. If that doesn't exist, don't buy it. Never forget that buying a cheap implant that is undocumented can prove to be very expensive.

Holst: Based on your clinical experience, what are the factors that play a role?

Albrektsson: It is complications to treatment that cause bone loss. We call it the "Triad of Poor." First, poor implant systems. As mentioned, these exist and are sold at a cheap price. Again, you should avoid these implant systems.

Second is poor clinical handling by clinicians without the right skills. Finally there is what we can term poor patients—those patients that are difficult to treat. These are the causes of bone loss, that in rare, but in some cases, may in the long-term lead to periimplantitis, but in most cases not.



Fig. 2



Fig. 3

Holst: So what can we, as dental implant professionals, do to prevent the proliferation of misinformation about periimplantitis?

Albrektsson: I'm increasingly irritated with people calling benign bone loss a disease. Those who are doing so have to read the new research that's out and realise they are wrong.

And the profession must, in a united manner, protest against alarming reports in a much stronger manner than we have done to date. But at the same time we must of course continue to take patients very seriously. We cannot ignore bone loss, even if it proves to be benign. We have to be active all the time and work to the best of our knowledge for our patients.

More to explore! For more to read about this and related topics—such as findings about screw vs. cement retention—please visit: nobelbiocare.com/news.

contact

Nobel Biocare Services AG

P.O. Box
8058 Zurich-Airport, Switzerland
www.nobelbiocare.com

Fig. 2: Stick with the original.

"Implant systems that say they are similar to other documented implants, and therefore need no documentation of their own, are not to be trusted."

Fig. 3: Dr Holst: "What can we do to prevent the proliferation of misinformation about periimplantitis?"

Prof. Albrektsson: "We must protest against alarming reports in a much stronger manner than we have done to date."

NucleOSS

Smart designs—brave smiles

T6 bone level implant provides a safe surgical procedure for the dentist as well as the comfortable surgery process it presents to the patient. The wide range of superstructures brings brave smiles. T6 refreshes your confidence with smiling designs and advanced strength. Pure titanium (GR-4) sandblasted with Al_2O_3 subjected to surface treatment with double thermal acid. By means of this method, the implant bodies obtain hydrophilic features.

The Tpure implant has performed 97.2 per cent success in ten years of clinical application practice. Unique and proven Maxicell surface provides full integration to the bone with macro surface anatomy. That no residue is found on the surface has been proven by an independent science institution in Germany. The new T6 implant is made of reinforced (Gr-4) titanium with a



BONE LEVEL IMPLANT

Maxicell surface and thus provides confident and long-term treatment consolidated by an efficient design.

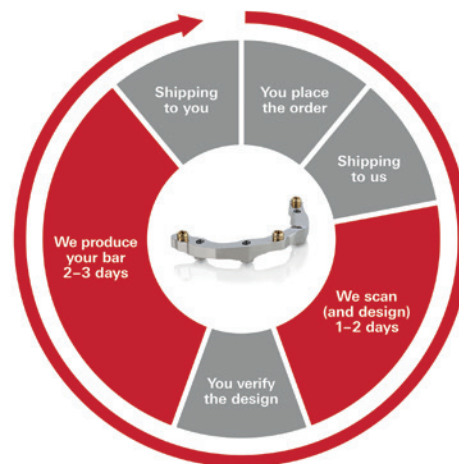Nucleoss Europe GmbH
Floßhafenstr. 6
41460 Neuss, Germany
www.nucleoss.com



Nobel Biocare

CAD/CAM implant bars on demand

As a result of growing demand, dental laboratories that can provide high-quality implant bars to support overdentures will find new business knocking at their doors. Ramping up implant bar production, however, can require a significant investment in equipment, time and staff training, which many labs simply cannot afford. Labs can instead receive a range of high-quality, precision-milled implant bars, simply by sending a model to NobelProcera. This flexible approach to outsourcing offers many benefits for labs. Primarily, it means they can offer precision-fitting bars in NobelProcera's renowned high quality without needing to invest in a Nobel-Procera CAD system or purchase and maintain expensive production technology.



This is how it works. NobelProcera's Scan and Design Service makes it possible for labs to take advantage of requests for high-quality implant bars that they might otherwise be forced to pass up.

By removing the need for investments and offering unrivaled results, NobelProcera's Scan and Design Service lets labs take advantage of requests for high-quality implant bars that they might otherwise be forced to pass up. In other words, it affords labs the flexibility to take opportunities that they can't afford to miss.

Nobel Biocare Services AG
P.O. Box
8058 Zurich-Airport, Switzerland
www.nobelbiocare.com

MIS

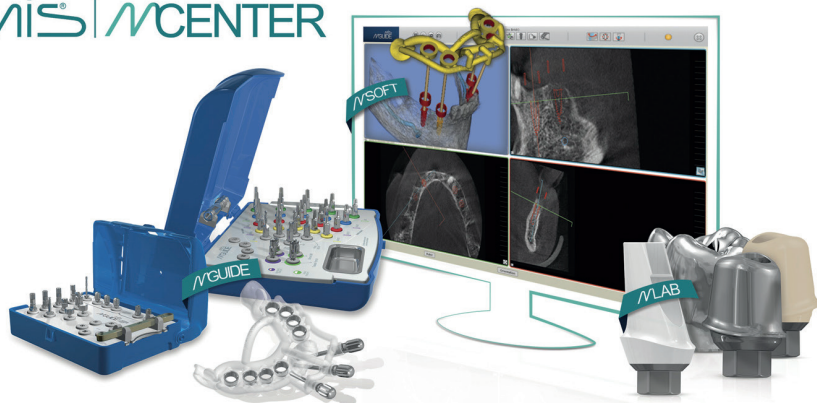New digital guided surgery solution

The new Conical Connection MGUIDE Surgical Kits include all the drills and tools necessary for a simpler surgical procedure. These new kits are compatible with both C1 and V3 conical connection implants and complete the existing line of surgical kits, which includes MGUIDE Internal Hex. Surgical Set for standard sleeve as well as the Narrow Sleeve MGUIDE Kit. Unlike all other guided surgery services offered by other manufacturers, MIS workflow is created and followed by only one provider. All steps in the procedure are handled by one source. MIS MCENTERS around the world

take the patient information sent to them and transform it into all that is necessary for the dental practitioners to perform implant surgery and provide patients with a "full smile solution". Having all components of the process and workflow in one place, enables the MCENTER team to view each case in a "top down design".

MIS Implants Technologies GmbH
Simeons carré 2
32423 Minden, Germany
www.mis-implants.com

MIS | MCENTER



2ND ANNUAL MEETING OF

ISMI

INT. SOCIETY
OF METAL FREE
IMPLANTOLOGY



Ceramic implants — practical experiences and recent trends

JUNE 10 – 11, 2016 IN BERLIN, GERMANY
STEIGENBERGER HOTEL AM KANZLERAMT

Speaker:

Prof. Dr. Joseph Choukroun/Nice (FR)
Prof. Dr. Matthias Heiliger/Kreuzlingen (DE)
Prof. Dr. Marcel Wainwright/Düsseldorf (DE)
Prof. Dr. Jose Mendonça-Caridad/Santiago di Compostela (ES)
Dr. Dr. Johann Lechner/Munich (DE)
Dr. Tilmann Fritsch/Bayerisch Gmain (DE)
Dr. Stefan König/Bochum (DE)
Dr. Dominik Nischwitz/Tübingen (DE)
Dr. Sammy Noubissi/Silver Spring, MD (US)
Dr. Jens Schug/Zug (CH)
Dr. Karl Ulrich Volz/Konstanz (DE)

Scientific Director:

Dr. Karl Ulrich Volz/Konstanz (DE)

Venue:

Steigenberger Hotel Am Kanzleramt
Ella-Trebe-Straße 5, 10557 Berlin, Germany
www.steigenberger.com

Organization/Registration:

OEMUS MEDIA AG
Holbeinstraße 29
04229 Leipzig, Germany
Tel.: +49 341 48474-308
Fax: +49 341 48474-290
event@oemus-media.de
www.oemus.com
www.ismi-meeting.com



Organizer:

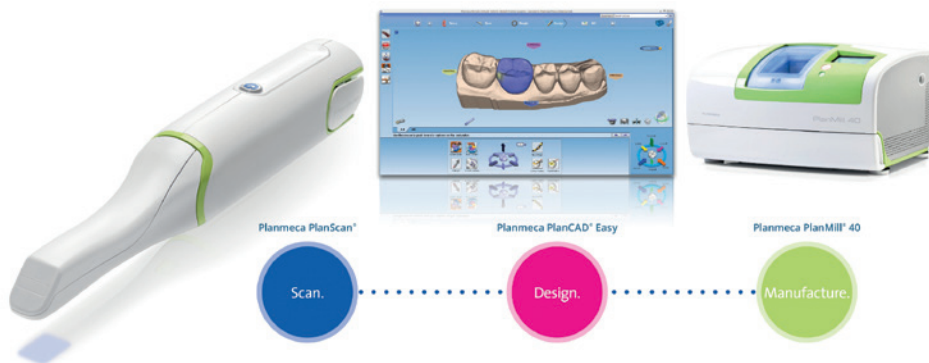
ISMI – International Society of
Metal Free Implantology
Lohnerhofstraße 2
78467 Konstanz, Germany
Tel.: 0800 4764-000
Fax: 0800 4764-100
office@ismi.me
www.ismi.me



www.ismi-meeting.com

Planmeca

Fast scanning – also in colour



The Planmeca FIT™ system for chairside CAD/CAM dentistry provides clinics with a completely digital workflow from start to finish. It seamlessly integrates intraoral scanning, 3-D designing and on-site milling into one software platform, allowing clinics to produce restorations in a single visit. Scanning with the system is now 40% faster than before, with colour scanning also offered.

The Planmeca FIT system is all about integrated efficiency. Comprised of the Planmeca PlanScan[®] scanner, the Planmeca PlanCAD[®] Easy

software and the Planmeca PlanMill[®] 40 milling unit, the system enables dental clinics to create high-quality restorations that fit perfectly. Clinics can either choose to perform the entire CAD/CAM workflow in-house with the system, or flexibly outsource parts of it.

Planmeca Oy
Asentajankatu 6
00880 Helsinki, Finland
www.planmeca.com

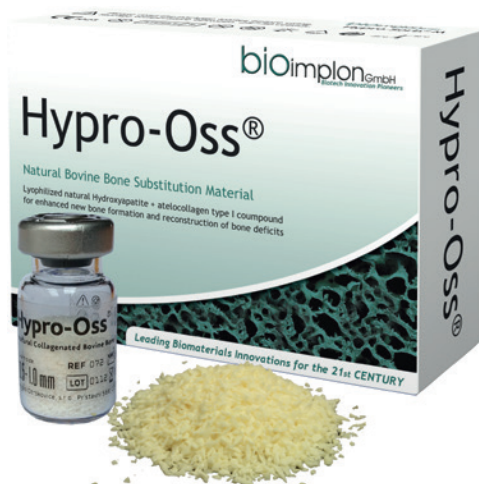Bioimplon

The unique bone graft material

Hypro-Oss[®] is an innovative lyophilised natural bovine bone graft with integrated Atelo-Collagen Type I. It is the result of a six-year research and development with a prime concept—to create an ideal bone graft material. Each single granule of Hypro-Oss[®] is a composite of 30% Atelo-Collagen Type I and 70% hydroxyapatite of bovine origin. Thanks to our patented atelo-peptidation technology, we create a modified collagen (Atelo-Collagen) where the immunogenic telopeptides have been biochemically eliminated. This ensures maximum biocompatibility and safety. The process of dry freezing instead of other standard-heating technologies preserves the native bio-elements of collagen. Furthermore, Atelo-Collagen's powerful hydrophilic and haemostatic properties promote cell adhesion and avert haematoma formation. During the bone formation process Hypro-Oss[®] is not simply integrated, but it is completely remodelled into the patient's own new bone—

which makes it the optimal bone graft material. Hypro-Oss[®] is sterile and 100% BSE-free.

Bioimplon GmbH
Friedrich-List-Str. 27
35398 Gießen, Germany
www.bioimplon.de

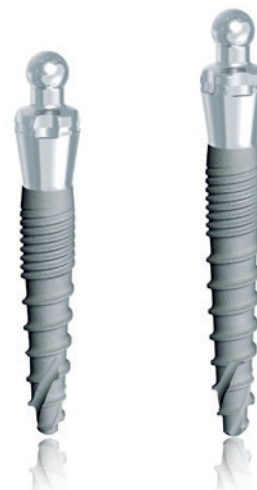

Dentaurum Implants

Three steps to success

The new CITO mini[®] line is a system of one-piece implants that allows minimally-invasive insertion in only three steps. As many implant cases can be loaded immediately, patients can enjoy their new quality of life a lot sooner. The line consists of six implants, with three drills in the instrument set. Users can regulate the drilling depth individually to achieve maximum primary stability. CITO mini[®] implants are provided with the scientifically proven¹⁻³ self-tapping thread geometry known from the tioLogic[®] ST implant system.

CITO mini[®]

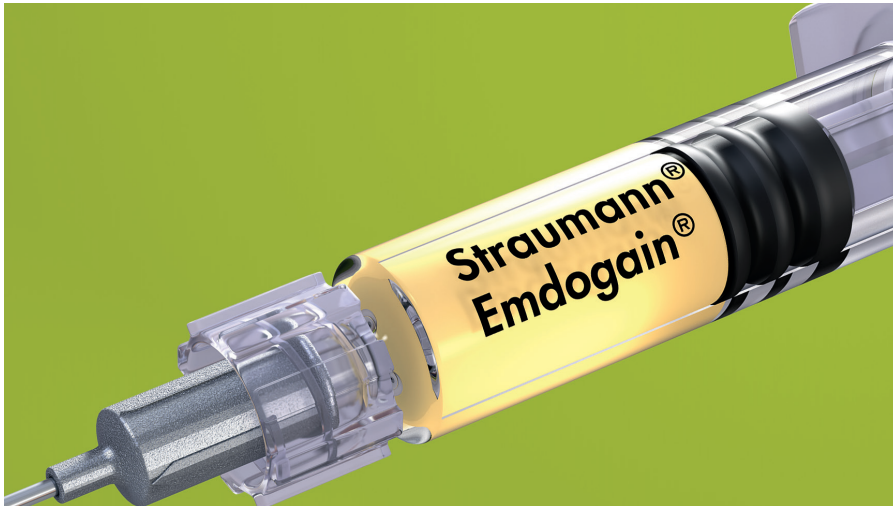

- [1] I. Hasan, H. Stark, C. Bourauel: Biomechanische Untersuchungen des Einflusses von Geometrievarianten des tioLogic[®] ST Implantats [Biomechanical analyses of the influence of tioLogic[®] ST implant geometry variations]; University of Bonn 2012.
- [2] A. Rahimi, F. Heinemann, A. Jäger, C. Bourauel: Biomechanische Untersuchungen des Einflusses von Gewindevarianten des tioLogic[®] ST Implantats [Biomechanical analyses of the influence of tioLogic[®] ST thread variations]; University of Bonn 2006.
- [3] I. Hasan, C. Bourauel: Biomechanische Untersuchungen des Einflusses von Geometrievarianten des CITO mini[®] Implantats [Biomechanical analyses of the influence of CITO mini[®] implant geometry variations]; University of Bonn 2014.

Dentaurum Implants GmbH
Turnstr. 31
75228 Ispringen, Germany
www.dentaurum-implants.com

Straumann

Orchestrating wound healing and oral regeneration



Straumann® Emdogain® is one of the best documented products in oral tissue regeneration. Its excellent clinical tolerability has been demonstrated in over two million surgical applications. Emdogain® contains enamel matrix proteins (amelogenins).

When applied to the wound, these proteins form an extracellular matrix that stimulates cells and processes that are fundamental for wound healing. This makes it a unique solution to stimulate and accelerate the healing of wounds and regen-

eration of tissues. Straumann is now setting new milestones in the area of oral tissue regeneration by extending the use of Emdogain® to improve soft tissue wound healing in oral surgical procedures and dental implantation procedures in general. The properties of Emdogain® have the potential to render procedures less prone to complications and to increase patient satisfaction by a. allowing faster healing and recovery, b. reducing the level of post-surgical discomfort (pain and swelling) and c. increasing the quality of the outcomes of esthetic procedures in implant dentistry. As the first dental implant company to do so, Straumann is incorporating a biologic in the surgical procedure of implant placement as a standard step in order to improve Wound healing with Straumann® Emdogain®. More information: bit.ly/emdogain-woundhealing.

Institut Straumann AG
Peter-Merian-Weg 12
4002 Basel, Switzerland
www.straumann.com

CAMLOG

Attractive implant sets offer even more options

iSy® is the inexpensive quality system from CAMLOG. As of September 2015, CAMLOG has extended the iSy® Implant system and thus complies with the requests of many users wishing to use the iSy® Implants in even more cases. The 7.3 mm short iSy® Implants have been added to the product range. These are suitable for cases with limited bone volume and extend the

indication spectrum of the system. Also new are the Esthomic® gingiva formers, which can be screwed directly in the implant, as well as the option of impression taking at the implant level through open and closed impression posts, plus numerous prosthetic components and instruments. At the same time, the manufacturer has also released the iSy® Implant base for

final restorations. Further information on the iSy® Implant system is available on the web at www.isy-implant.com.

CAMLOG Biotechnologies AG
Margarethenstrasse 38
4053 Basel, Switzerland
www.camlog.com

© CAMLOG





6th International CAMLOG Congress in Krakow

Practice-oriented continuous education

Source: CAMLOG Foundation

The 6th International CAMLOG Congress will take place from June 9 to 11, 2016, in Krakow under the motto "Tackling everyday challenges". Renowned experts from Europe and America will be presenting

current results from their research and clinical experience. A ground-breaking digital dentistry pre-congress on Thursday provides fascinating insights on the entire digital workflow. Experienced specialists

Fig. 1: Prof. Dr. Piotr Majewski, Congress President.

Fig. 2: Prof. Dr. Frank Schwarz, Congress President.

Fig. 3: Prof. Dr. Jürgen Becker, President CAMLOG Foundation.



Fig. 1




Fig. 2



Fig. 3



will convey the latest technologies and treatment methods in five—already almost booked out—practical workshops.

Since the first congress in 2006 and the founding of the CAMLOG Foundation, the international CAMLOG congresses have established themselves as important communication and education events in implant dentistry. Top-level speakers, practise-oriented workshops and an attractive location highlight the 6th CAMLOG Congress: the international elite in implant dentistry meets in Europe's award-winning and most modern congress center. The scientific committee, chaired by Prof. Frank Schwarz and Prof. Piotr Majewski, is responsible for the program.

Digital dentistry pre-congress

The influence of digital technologies in both the clinic and the laboratory can no longer be disputed. The full-day symposium illustrates opportunities and options, discusses problematic treatments and gives practical advice. Experienced speakers present an up-to-date, comprehensive interdisciplinary view together with an outlook into the future. An event you should not miss with the added benefit of a combined discount when booking the symposium.

High practical relevance coupled with interaction

The relevance for dental practice has always been a focal point for the CAMLOG Foundation. With this in mind, the speakers have been asked to focus their presentations on the benefits in daily practice. Abstracts of the presentations can be viewed at any time at www.camlogcongress.com. Using an app created specifically for the congress, delegates are given the opportunity of asking the speakers questions. Should

you prefer personal to digital contact, the delegates are available for discussions during the breaks in the Network Lounge.

A visit by Mickey Mouse

One highlight of the congress will no doubt be guest speaker Prof. Markus Gross. He is Director of Disney Research in Zurich and will guide delegates through the digital world of 3-D facial modeling and demonstrate the potential for medical applications. The overview on 20 years of working with digital human faces will certainly be an eye-opener for the audience.

The debate: heated discussions on controversial topics

At the end of the congress, delegates from the panel will be heading for confrontation. Convinced users will be holding an open discussion using concrete examples to underline their position and will answer questions from the audience. Should implants be treated or removed in case of periimplantitis? Is a parallel or conical implant-abutment connection preferable? Discussions you should not miss and where active participation is desired.

Krakow: a UNESCO World Heritage site

A compact historical center with more than 5,000 historic buildings and cultural monuments make Krakow Poland's most beautiful city. The city center features Europe's largest historical market square and also houses an impressive museum and numerous churches. Hundreds of clubs, bars and galleries in the immediate vicinity and the Kazimierz district invite visitors for an evening stroll. Not to forget, of course, the legendary congress party which will be held under the motto "Hard Rock CAMLOG".

All the information on the congress is available at www.camlogcongress.com. Register now. We look forward to welcoming you in Krakow.

contact

CAMLOG Foundation
Margarethenstrasse 38
4053 Basel, Switzerland
Tel.: +41 61 565 41 00
Fax: +41 61 565 41 01
info@camlogfoundation.org
www.camlogfoundation.org

Membership Application Form

IM 2/16

I hereby to apply for membership of the DGZI – German Association of Dental Implantology (Deutschen Gesellschaft für Zahnärztliche Implantologie e.V.).
Please send this form via FAX to +49 211 16970-66.

Do you have experience in implantology? (mandatory)

Yes No

I hereby agree to have my personal data processed for all purposes of the DGZI.

Full membership (outside Germany) Assistant doctors (outside Germany) Students/auxiliaries (outside Germany)
⇒ 125 Euro p.a. ⇒ 60 Euro p.a. ⇒ 60 Euro p.a.

I have transferred the annual fee to the DGZI bank account c/o Dr Rolf Vollmer:
IBAN: DE33 5735 1030 0050 0304 36 | KSK Altenkirchen | SWIFT/BIC: MALADE51AKI

Personal Data

Name	First name	Date of birth
Title	Citizenship	
Street	City, ZIP code	Country
Phone, Country and Area code	Fax	
E-Mail	Homepage	
Special qualification	Spoken languages	

Payment (by credit card)

Please use your: (Please mark as appropriate)

Visa MasterCard

Card holder's name	Card number
Expiry date	
Signature	Place, Date

Please complete this application form in block letters.

FOR FURTHER INFORMATION PLEASE CONTACT



Deutsche Gesellschaft für Zahnärztliche Implantologie e.V.
Central Office: Paulusstraße 1, 40237 Düsseldorf, Germany
Phone: +49 211 16970-77 | FAX: +49 211 16970-66 | office@dgzi-info.de | www.dgzi.de

46TH



DGZI INTERNATIONAL ANNUAL CONGRESS

How much aesthetic is required in the implantology?

Scientific Director:

Prof. Dr Herbert Deppe/DE

Prof. (CAI) Dr Roland Hille/DE

30 September and
1 October, 2016
Munich | The Westin Grand Munich


Only a limited number of seats
and hotel capacities!

Online
Congress Programme



www.dgzi-jahreskongress.de

Gold Sponsor



Silver Sponsor



Bronze Sponsor



FAX REPLY | +49 341 48474-290

I would like to receive further information on the
46TH DGZI INTERNATIONAL ANNUAL CONGRESS
on 30 September and 1 October, 2016, in Munich, Germany.

Practise Stamp

Key factors for

Global dental diagnostic market

In its latest market report, global research firm Technavio forecasts that the global dental diagnostic and surgical equipment market will exceed US\$7.5 billion (€6,7 billion) by 2020. According to the analysts, key factors underlying this prediction are the rising demand for oral care, an increasing number of dentists, and the growing edentulous population and incidence of oral disease.



According to the analysts, efficient oral care, such as minimally invasive procedures, early detection of caries with new laser equipment, treatment of periodontal disease and professional tooth cleaning, will increase the number of patients and dental visits, thereby driving the growth of the field.

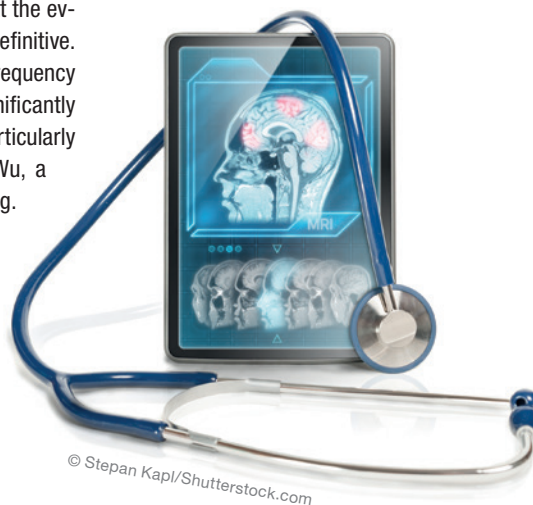Advancing this trend is increasing oral health awareness reinforced through oral health campaigns by governments and private organisations. Furthermore, the demand for budget oral care is likely to boost the dental market globally, states Technavio lead analyst Barath Palada. "Countries like Turkey, Hungary, India, and South Korea are gaining popularity as medical tourism destinations among people seeking low-cost dental care procedures." The complete report, titled Global dental diagnostics and surgical equipment market 2016–2020, can be purchased at www.technavio.com.

Unclear link between

Oral health & cognitive status

A number of studies have suggested that oral hygiene and regular dental visits may play a role in slowing cognitive decline as people age. However, the association between oral health and cognition is not fully understood. A recently published systematic review conducted at Duke University in the US has now shown that the evidence that one causes the other is not definitive. "Clinical evidence suggests that the frequency of oral health problems increases significantly in cognitively impaired older people, particularly those with dementia," said Prof. Bei Wu, a gerontologist at Duke's School of Nursing. "In addition, many of the factors associated with poor oral health, such as poor nutrition and systemic diseases like diabetes and cardiovascular disease, are also associated with poor cognitive function." Wu and her colleagues analysed 56 relevant cross-sectional and longi-

tudinal studies published between 1993 and 2013. The study, titled "Association between oral health and cognitive status: A systematic review," was published online on April 1 in the *Journal of the American Geriatrics Society* ahead of print.



Fundamental misconceptions about

Dental implants among patients

Investigating patients' knowledge and perceptions regarding implant therapy, a Chinese study has found that an alarming number of participants had inaccurate and unrealistic expectations about dental implants. Moreover, the study determined that only 18 per cent felt con-

fident about the information they had about the treatment. In the study, the researchers investigated preoperative information levels, perceptions and expectations regarding implant therapy via a questionnaire. Responses from 277 patients were obtained during 2014 and 2015

in three different locations in China (Hong Kong, Sichuan and Jiangsu). The analyses established that about one-third of the participants had mistaken assumptions about dental implants.

The study, titled "What do patients expect from treatment with dental implants? Perceptions, expectations and misconceptions: A multicenter study", was published online ahead of print on 23 March in the *Clinical Oral Implants Research* journal.



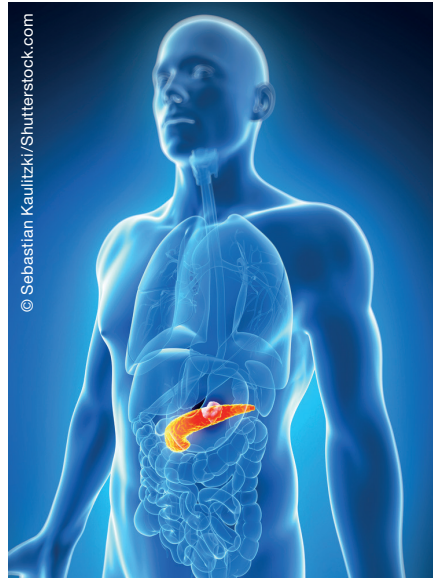
Oral bacteria may indicate

Increased pancreatic cancer risk

Researchers have found that the risk of developing pancreatic cancer is associated with specific bacteria in the mouth. They hope that the findings could enable earlier and more precise treatment of the disease, which is one of the most common causes of cancer death in both men and women and results in more than 40,000 deaths annually in the US alone.

The researchers compared bacterial contents in mouthwash samples from 361 American men and women who had developed pancreatic cancer with samples from 371 people of matched age, sex and ethnic origin who did not. They found that men and women whose oral microbiome included *Porphyromonas gingivalis*, a major contributor to periodontal disease, had an overall 59 per cent greater risk of developing pancreatic cancer than those whose microbiome did not contain the bacterium. Similarly, people with oral microbiomes containing *Aggregatibacter actinomycetemcomitans*, which has been associated

with severe periodontitis, were at least 50 per cent more likely overall to develop the disease.



Antidepressant use could increase

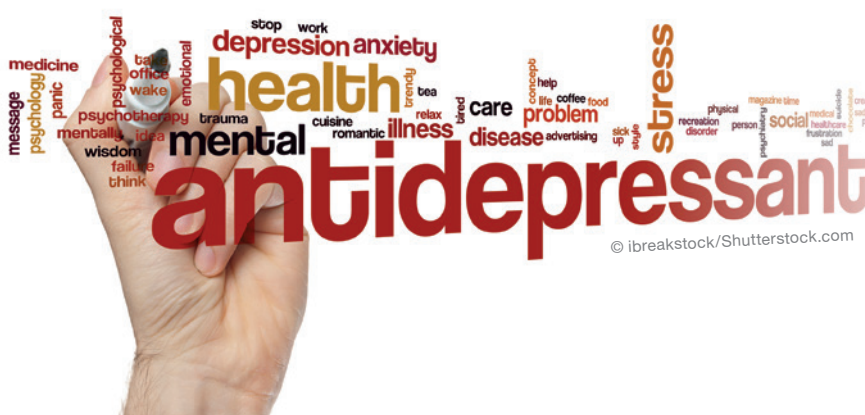Implant failure risk

New research has linked antidepressants to dental implant failure. The pilot study conducted at the University at Buffalo found that antidepressants could affect the regulation of bone metabolism, a crucial factor for the healing process and implant success.

In the study, the researchers analysed data from the medical charts of the university's dental clinic patients in 2014. They found that of the few patients who experienced implant failures, 33 per cent used antidepressants. For patients who did not experience failures, only 11 per cent took the drug. Overall, the analysis showed that use

of antidepressants increased the odds of implant failure fourfold. Each year of antidepressant use doubled the odds of failure, the researchers stated. Therefore, they advise patients using antidepressants to consult with their physician about the drug's side effects and alternative methods of managing depression, anxiety or pain.

Antidepressant use has been associated with a number of side effects, including osteoporosis, akathisia, bruxism and dry mouth, all of which affect the implant healing process and are of concern for dentists with regard to oral and bone health, the investigators noted.



Further Education at the

DGZI International Annual Congress in Munich

As the most traditional European society for dental implantology, DGZI is going to hold its 46th Annual Congress in Munich, Germany from 30 September to 1 October 2016. Renowned speakers from Germany and abroad, representatives of associated societies and, of course, participants from Europe, the USA, Asia and the Arabic countries will once more contribute to and profit from an exceptional further-education event. This year, the congress will take place parallel to the annual congress of the German Society for Laser Dentistry (DGL), the Munich Forum of Innovative Implantology and the Oral Hygiene Day, resulting in additional pools of information for our participants.



The congress aims at providing first-rank, practice-oriented further education and building a bridge to the latest scientific findings via introducing industrial innovations and their implementation in the daily practice. Lectures will cover the complete spectrum of modern implantology, furthermore illustrating significant interfaces with other relevant areas of expertise. The congress programme is completed by workshops by manufacturers of implants, membranes and bone substitutes as well as separate topics on the dental assistance in implantology.

As the congress will be held on the Oktoberfest's final weekend, all interested colleagues are encouraged to plan their participation in time.

Source: DGZI e.V.

USA to expect

Growing dentist shortage

The demand for dental care services in the US is projected to grow on a national level, mainly owing to demographic changes. However, a new report has forecast that all 50 US states will have a shortage of dental professionals in the near future. Based on dental workforce data from 2012, it is predicted that the excess growth in demand in relation to dentist supply will result in a national shortage of approximately 15,600 dentists in 2025.

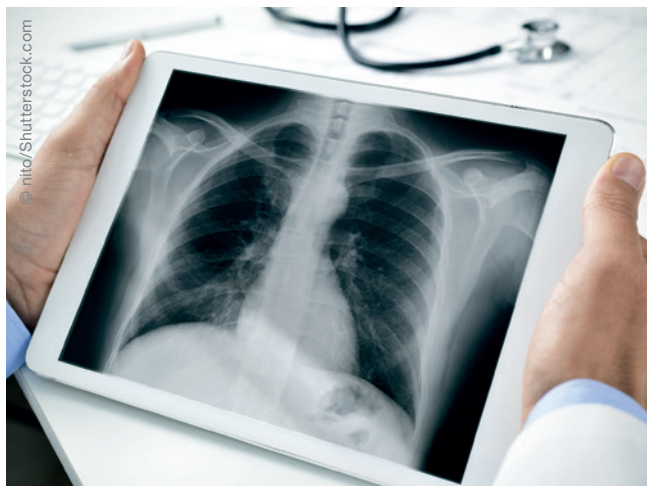

© tai11/Shutterstock.com

According to the Health Resources and Services Administration (HRSA), an agency of the US Department of Health and Human Services, which issued the report in February, over 46 million people in the US currently live in areas with a shortage of dental health professionals, and thus lack basic access to dental care. It is estimated that a total of about 15,600 additional dentists may be required to meet the actual demand in 2025. The report, titled "National and state-level projections of dentists and dental hygienists in the US, 2012–2025," was published online on the HRSA website.

Caries treatment may prevent

Pneumonia in Parkinson's patients



Pneumonia is a common condition in patients with Parkinson's disease. A new study that explored risk factors for pneumonia development has now found that patients treated for dental caries had a reduced risk of pneumonia compared with patients who had not been treated. The study included 2,001 participants newly diagnosed with Parkinson's disease between 2000 and 2009. Over a mean follow-up period of about six years, 19 per cent of the patients were hos-

pitalised for pneumonia. With regard to oral health status, the researchers observed that dental diseases were among the most common co-morbidities. About 48 per cent of the patients in the study had dental caries and over 44 per cent periodontitis. Moreover, the data analysis showed that the incidence of pneumonia in patients who had received treatment for dental caries

was lower. They thus concluded that maintenance of good oral hygiene and control of oral biofilm formation reduce the number of potential respiratory pathogens, thereby lowering the risk of pneumonia, especially in elderly men. The study, titled "Risk factors for pneumonia among patients with Parkinson's disease: A Taiwan nationwide population-based study", was published on 27 April in the *Neuropsychiatric Disease and Treatment* journal.

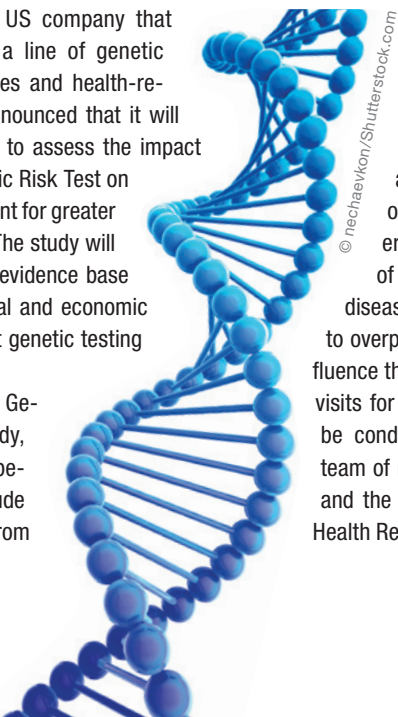
US company to study

Genetic test for periodontal disease

Interleukin Genetics, a US company that develops and markets a line of genetic tests for chronic diseases and health-related conditions, has announced that it will conduct a clinical study to assess the impact of its PerioPredict Genetic Risk Test on dental patient engagement for greater preventive dental care. The study will build on the company's evidence base in support of the medical and economic value of the PerioPredict genetic testing platform.

According to Interleukin Genetics, the clinical study, which was expected to begin on May 1, will include 800 dental patients from

20–30 general dentistry clinics who routinely visit their dentist only once a year although they are entitled to two visits a year by their insurance coverage. The overall aim of the study is to assess whether knowing their increased risk of developing severe periodontal disease owing to a genetic tendency to overproduce inflammation might influence the frequency of preventive care visits for these patients. The study will be conducted in collaboration with a team of researchers at Duke University and the Kaiser Permanente Center for Health Research in the US.



18-year-old suffers from

Inexplicable tooth loss

Smiling has become a difficult task for 18-year-old Linzi Grant from England: the teenager has



been suffering for years from a dental nightmare. Starting when she was 14 years old, her teeth have become so unstable that even sneezing can cause them to fracture. In addition to the constant pain, blood and puss often occur in the resulting gaps, prompting nausea, continuous discomfort and repeated infections as well as frequent stays in hospital.

Doctors assume the reason for this is her diabetes type 1 and recommend complete extraction. To finance the expensive surgical treatment which may cost up to 20,000 BP, Linzi has reached out to the public and contacted the media. In addition, she is looking for an alternative diagnosis and treatments. Find out more via www.gofundme.com/letlinzismileagain.

Source: ZWP online

PETA urges orthodontic society to

Move event from SeaWorld

People for the Ethical Treatment of Animals (PETA), the world's largest animal rights organisation, has called upon its followers to join a campaign urging the American Association of Orthodontists (AAO) to relocate the opening ceremony of its 2016 Annual Session from SeaWorld Orlando. According to PETA, SeaWorld, which owns all but one of the orcas held captive in the US, has a long history of mistreating animals and forcing them to perform unnecessary tricks for entertainment. As part of the campaign, PETA further highlighted that at least 38 orcas have died to date on SeaWorld's watch. In addition, nearly all the

orcas at SeaWorld are suffering from advanced dental trauma as a result of biting the metal gates and concrete sides of their small tanks. In order to prevent orcas from dying of infection owing to fractured teeth, marine parks often drill holes into the pulp cavity of broken or worn teeth to open the cavity enough to be flushed and cleaned daily, for the rest of the animal's life. This is often done without anaesthetics. Therefore, the animal advocacy organisation has called upon its members and followers to ask the AAO to move its event away from SeaWorld, by writing e-mails or posting to AAO's social media accounts.



Increase in caries rates after

Fluoridation cessation

Community water fluoridation is a matter of debate around the globe. While it is used widely in North America, many European countries have stopped the practice. Owing to a lack of contemporary research on fluoridation cessation, however, researchers in Canada have now investigated its impact on dental caries experience.

In Canada, community water fluoridation has been in place since 1945. In a recently published study, researchers at the University of Calgary therefore compared changes in caries experience in schoolchildren in Calgary with those in Edmonton, which has fluoridated its community water since 1967. In examining datasets from the school years of 2004/2005 and 2013/2014, the researchers observed an overall increase in



primary tooth decay in both cities, but the absolute magnitude of the increase was greater in Calgary. In their analysis, the researchers focused on smooth tooth surfaces, where fluoride is most likely to have an impact. The study, titled "Measuring the short-term impact of fluoridation cessation on dental caries in Grade 2 children using tooth surface indices," was published online on Feb. 17 in the *Community Dentistry and Oral Epidemiology* journal ahead of print.

Congresses, courses and symposia



Third MIS Global Conference: 360° Implantology

26–28 May 2016
Venue: Barcelona, Spain
www.mis-events.com



6th International CAMLOG Congress

9–11 June 2016
Venue: Krakow, Poland
www.camlogcongress.com



2nd Annual Meeting of ISMI

10–11 June 2016
Venue: Berlin, Germany
www.ismi-meeting.com



Nobel Biocare Global Symposium 2016

23–25 June 2016
Venue: New York, USA
[www.nobelbiocare.com/
global-symposium-2016](http://www.nobelbiocare.com/global-symposium-2016)



46th International Annual DGZI Congress

30 September–1 October 2016
Venue: Munich, Germany
www.dgzi-jahreskongress.de

implants

international magazine of oral implantology



Imprint

Publisher

Torsten R. Oemus
oemus@oemus-media.de

CEO

Ingolf Döbbecke
doebbecke@oemus-media.de

Members of the Board

Jürgen Isbaner
isbaner@oemus-media.de

Lutz V. Hiller
hiller@oemus-media.de

Chief Editorial Manager

Dr Torsten Hartmann (V. i. S. d. P.)
hartmann@dentalnet.de

Editorial Council

Dr Rolf Vollmer
info.vollmer@t-online.de

Dr Georg Bach
doc.bach@t-online.de

Prof (CAI) Dr Roland Hille
dr-hille@t-online.de

Dr Suheil Boutros
SMBoutros@aol.com

Editorial Office

Georg Isbaner
g.isbaner@oemus-media.de

Claudia Jahn
c.jahn@oemus-media.de

Executive Producer

Gernot Meyer
meyer@oemus-media.de

Product Manager

Timo Krause
t.krause@oemus-media.de

Designer

Sandra Ehnert
s.ehnert@oemus-media.de

Theresa Weise
t.weise@oemus-media.de

Customer Service

Marius Mezger
m.mezger@oemus-media.de

Published by

OEMUS MEDIA AG
Holbeinstraße 29
04229 Leipzig, Germany
Tel.: +49 341 48474-0
Fax: +49 341 48474-290
kontakt@oemus-media.de

Printed by

Silber Druck oHG
Am Waldstrauch 1
34266 Niestetal, Germany

implants

international magazine of oral implantology is published in cooperation with the German Association of Dental Implantology (DGZI).

DGZI

DGZI Central Office
Paulusstraße 1
40237 Düsseldorf, Germany
Tel.: +49 211 16970-77
Fax: +49 211 16970-66
office@dgzi-info.de

www.dgzi.de
www.oemus.com
www.implants.de

Copyright Regulations

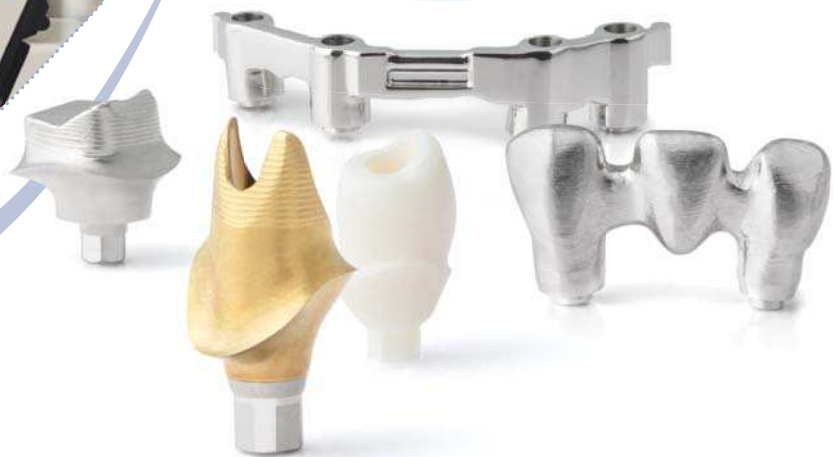implants international magazine of oral implantology is published by OEMUS MEDIA AG and will appear in 2016 with one issue every quarter. The magazine and all articles and illustrations therein are protected by copyright. Any utilization without the prior consent of editor and publisher is inadmissible and liable to prosecution. This applies in particular to duplicate copies, translations, microfilms, and storage and processing in electronic systems. Reproductions, including extracts, may only be made with the permission of the publisher. Given no statement to the contrary, any submissions to the editorial department are understood to be in agreement with a full or partial publishing of said submission. The editorial department reserves the right to check all submitted articles for formal errors and factual authority, and to make amendments if necessary. No responsibility shall be taken for unsolicited books and manuscripts. Articles bearing symbols other than that of the editorial department, or which are distinguished by the name of the author, represent the opinion of the afore-mentioned, and do not have to comply with the views of OEMUS MEDIA AG. Responsibility for such articles shall be borne by the author. Responsibility for advertisements and other specially labeled items shall not be borne by the editorial department. Likewise, no responsibility shall be assumed for information published about associations, companies and commercial markets. All cases of consequential liability arising from inaccurate or faulty representation are excluded. General terms and conditions apply, legal venue is Leipzig, Germany.

ATLANTIS™

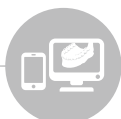Beyond CAD/CAM

Patient-specific prosthetic solutions
for all major implant systems

In order to provide truly ideal solutions, you need restorative versatility, flexibility within your workflow and design options that are as individual as each patient. By choosing ATLANTIS, you get the freedom, esthetics, simplicity and reliability that go beyond CAD/CAM.



STEPPS™



SIMPLANT™



SYMBIOS™



ANKYLOS™

ASTRA TECH
IMPLANT SYSTEM

XiVE™



ATLANTIS™

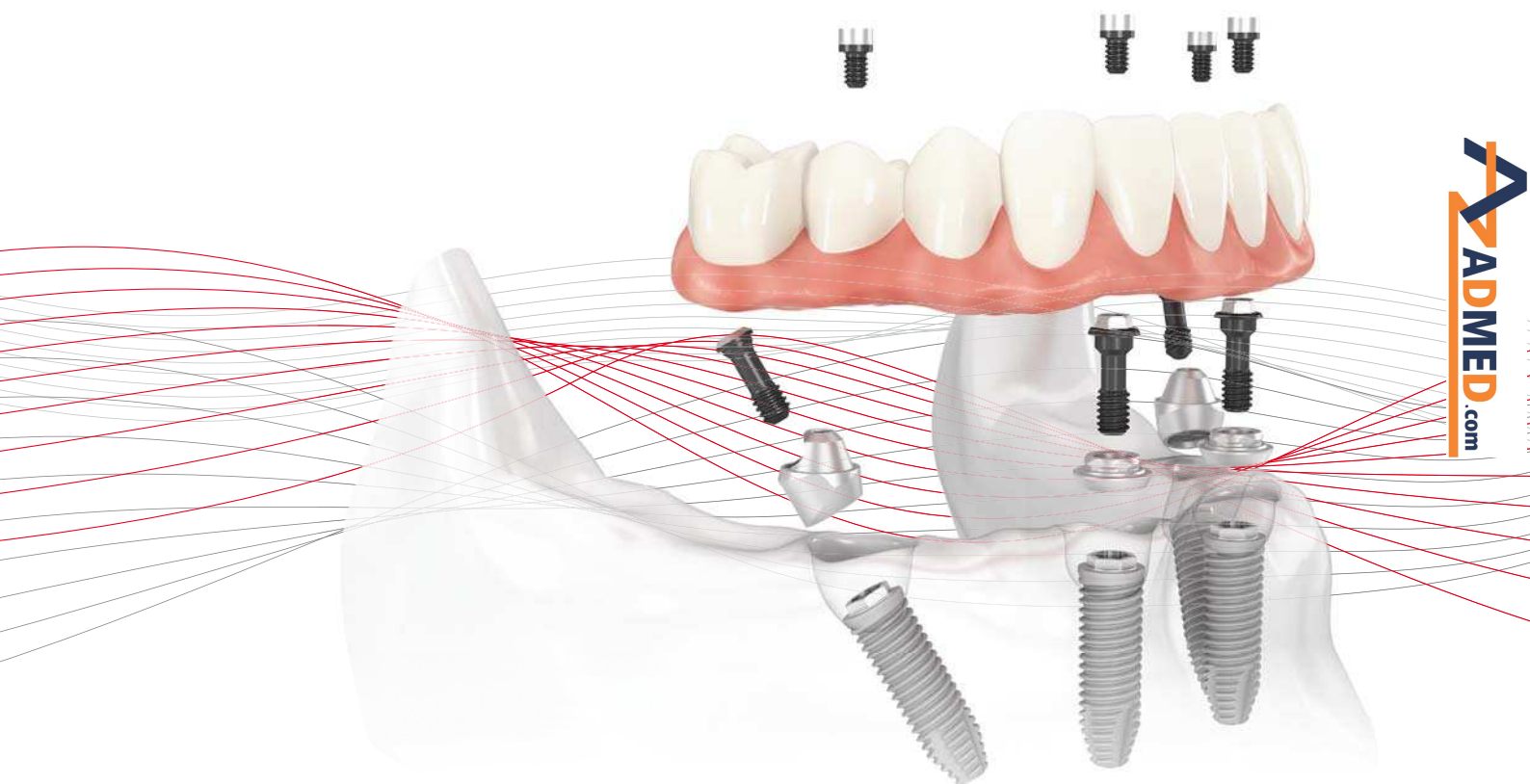
Follow DENTSPLY Implants



www.dentsplyimplants.com



Best in class



All-on-4[®] treatment concept

The All-on-4[®] treatment concept is the best in its class of solutions. But only when Nobel Biocare products are combined. Many have tried to mirror this groundbreaking concept, but only we have the scientifically documented success to back it up. The All-on-4[®] treatment concept provides edentulous and soon-to-be edentulous patients with a fixed full-arch prosthesis on four implants on the day of surgery. Start treating more patients better.

Visit nobelbiocare.com/all-on-4



• Base it

بیس و لاینر (دایکال نوری)



- حاوی کلسیم هیدروکساید آپاتیت (دارای خاصیت رادیوآپسیتی)
- شیرینکیچ پائین ، چسبندگی بالا و استحکام در برابر پوسیدگی
- دارای مقاومت بیشتر از گلاس آینومر
- ایجاد بهترین عایق • ۴ سرنگ ۲ گرمی
- قابلیت ایجاد دنتین ثانویه با آزاد کردن یون های کلسیم هیدروکسی و فسفات

You're
the Artist

SPIDENT
Made in Korea



AZAD TEJARAT
PARS.LTD

• Es Flow

نانو کامپوزیت فلو



- مناسب برای ترمیم حفره های کلاس ۱ تا ۳ و کلاس عمیقی
- قابل استفاده در ارتودنسی
- دارای مقاومت و پولیش پذیری بالا
- با خاصیت افت پلیمریزاسیون اندک و ضریب ارتجاعی مشابه عاج دندان
- فلو پذیری مناسب
- ۲ سرنگ ۲ گرمی

Web: www.befrest.com
Email: info@azadmed.com
Tel: +98 21 88 98 80 63 - 6 Fax: +98 21 88 98 75 72

تهران، خیابان فاطمی، خیابان کاج جنوبی، ساختمان آوا، شماره ۳۴
Add: Ava Building, No 34, Kaj St, Fatemi Ave, tehran, Iran