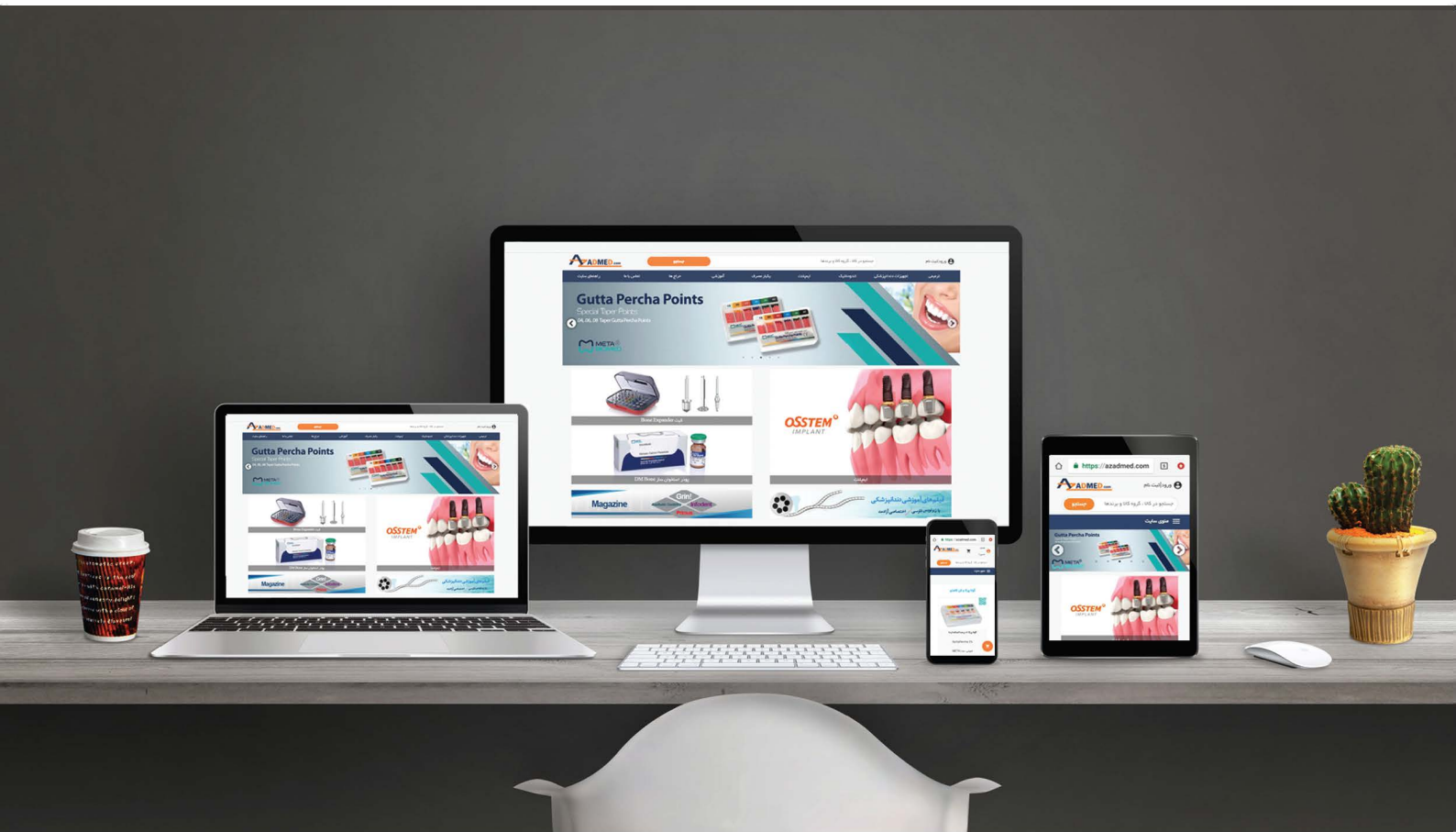




آزاد تجارت پارس
AZAD TEJARAT PARS.LTD

AZADMED.com



www.azadmed.com



 azaadtejaratpars

 @azadmed2

 88 98 80 63 - 6

implants

international magazine of oral implantology

4 2017

ADMED.com

research

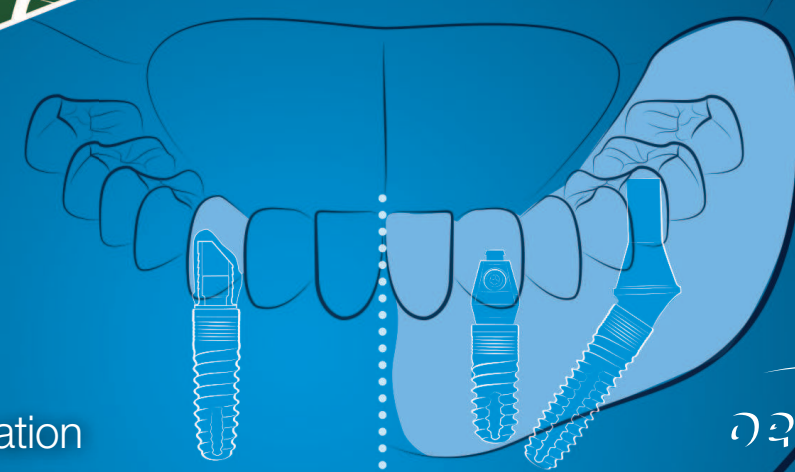
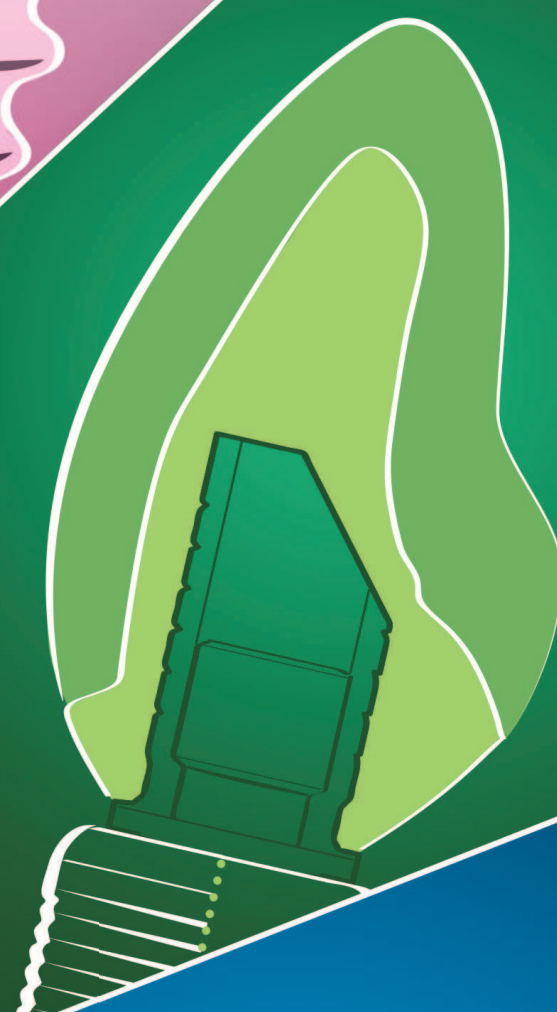
Titanium and its alloys
in dental implantology

case report

Rehabilitation of
edentulous patients

industry

Digital workflow:
From planning to restoration



ADMED

axiom[®]

MULTI LEVEL

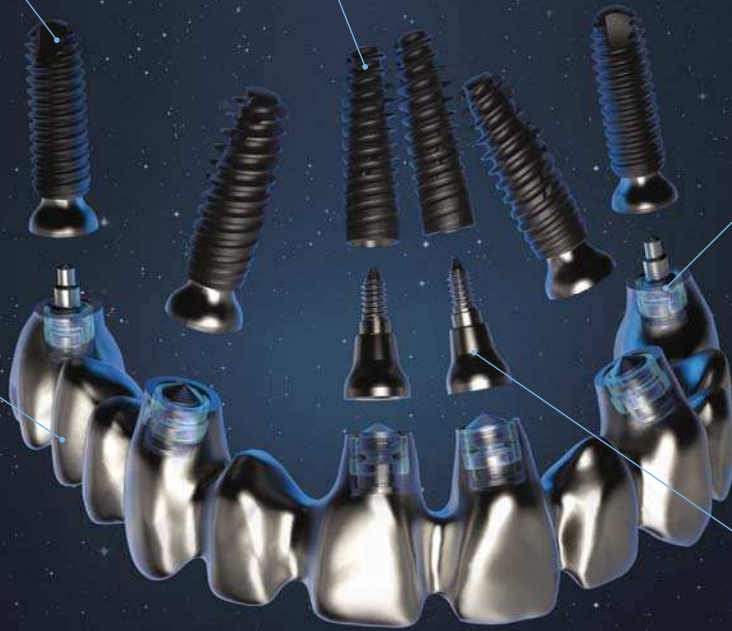NEW Axiom[®] TL,
Tissue Level **IMPLANT**

Axiom[®] BL,
Bone Level

CAD-CAM **Simeda[®]**
prosthesis

INNOVATIVE
inLink[®] connection

inLink[®]
abutment



YOUR NEW POWER

The **Axiom[®] Multi Level[®]** range opens the way to a new total compatibility between the **Bone Level** and **Tissue Level** philosophies. The new **Axiom[®] Tissue Level** implant promotes biological safety and prosthetic manipulation with the comfort of a screw-retained prosthesis. Thanks to the **inLink[®]** innovation, available on **Axiom[®] Tissue Level** and **Axiom[®] Bone Level** through a dedicated abutment, **Anthogyr** introduces the first connection with integral screw system in a **CAD-CAM Simeda[®]** prosthesis. **The Axiom[®] Multi Level[®]** range provides new flexibility to your implantology practice.



www.axiom-multilevel.com

Anthogyr
PRIME MOVER IN IMPLANTOLOGY

How can we make it better?



Dr Rolf Vollmer

Dear colleagues,

The German Association of Dental Implantology (DGZI) is one of the most traditional European dental implantology associations. From the very beginning, as practitioners, we have provided decisive impulses without which modern implantology would not be conceivable today as one of the absolute trend disciplines of modern dentistry.

In 2017, the DGZI again had (also) a lot of international activities. Visits were made to the USA, Japan, and also to the Maghreb countries. Insights into the dental training structures and into the current market developments of the respective countries often showed interesting aspects. One German attendee said: "Without adequate training you will not be successful. And we definitely have to bring more experience and knowledge from continent to continent."

One of the experiences I personally have made was that not only treatment concepts but also the mentality in other countries can be very different. A US friend and colleague with Japanese roots and a Japanese wife discussed with me the differences between Japan, Germany and the USA. He said: "My sons are Americanised. Whether privately as in their hobbies or when they do their jobs, I very often hear: 'It's good enough!' But the Japanese or Germans ask: How can we make it better?" My own experience has shown that there is some truth behind this.

Future congress in dental implantology

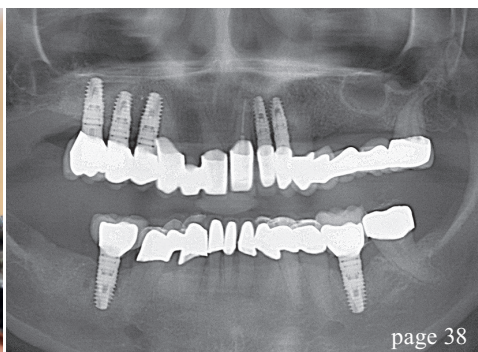

For the next years, the DGZI has set herself the demanding task and vision to adapt both the training structures with regard to curricula, dental technician training, and the congress design to the most modern possibilities and conditions in order to remain on top in the future.

Thus, in 2018, the 1st Future Congress for Dental Implantology of the DGZI will raise new questions under the motto "Visions in Implantology". The congress will address the question of what implantology will look like in five or maybe ten years. Renowned speakers from Germany and abroad, representatives of friendly international professional societies, industry partners and, of course, participants from Europe, the USA, Asia and the Arab countries will design and experience an outstanding innovative training event. The DGZI board cordially invites you to this new congress on 28 and 29 September 2018 at the Hilton Hotel in Düsseldorf, Germany. Save the date, keep curious and let yourself be surprised.

I wish you a pleasant Christmas time and a relaxed New Year,

Yours

Dr Rolf Vollmer
First Vice President and Treasurer of the German Association of Dental Implantology



| **editorial**

- 03 **How can we make it better?**
Dr Rolf Vollmer

| **research**

- 06 **Titanium and its alloys in dental implantology**
Drs Roland Masa & Gábor Braunitzer

| **case report**

- 12 **Rehabilitation of edentulous patients**
Dr Nikolaos Papagiannoulis

| **industry**

- 20 **Rehabilitation of edentulous arches**
Dr Marco Montanari, Claudio Sassatelli & Davide Nadalini
- 32 **Digital workflow: From planning to restoration**
Jan Kielhorn, Siegfried Hoelzer & Björn Roland
- 38 **A clinical comparison**
Private lecturer Dr Dr Arwed Ludwig & Dr Gregor Thomas

| **interview**

- 48 **“Implantology is a field of opportunities”**
- 50 **Putting TiUnite to the test**

| **events**

- 52 **47th DGZI International Annual Congress**
Dr Georg Bach
- 56 **AAID congress in San Diego**
Dr Rolf Vollmer
- 60 **Hot programme for EAIO meeting in Madrid**
Dental Tribune International
- 62 **“Science meets Practice”**

| **news**

- 42 **manufacturer news**
- 63 **news**

| **about the publisher**

- 66 **imprint**



Cover image courtesy of bredent medical GmbH & Co. KG
www.bredent-medical.com

a perfect fit™

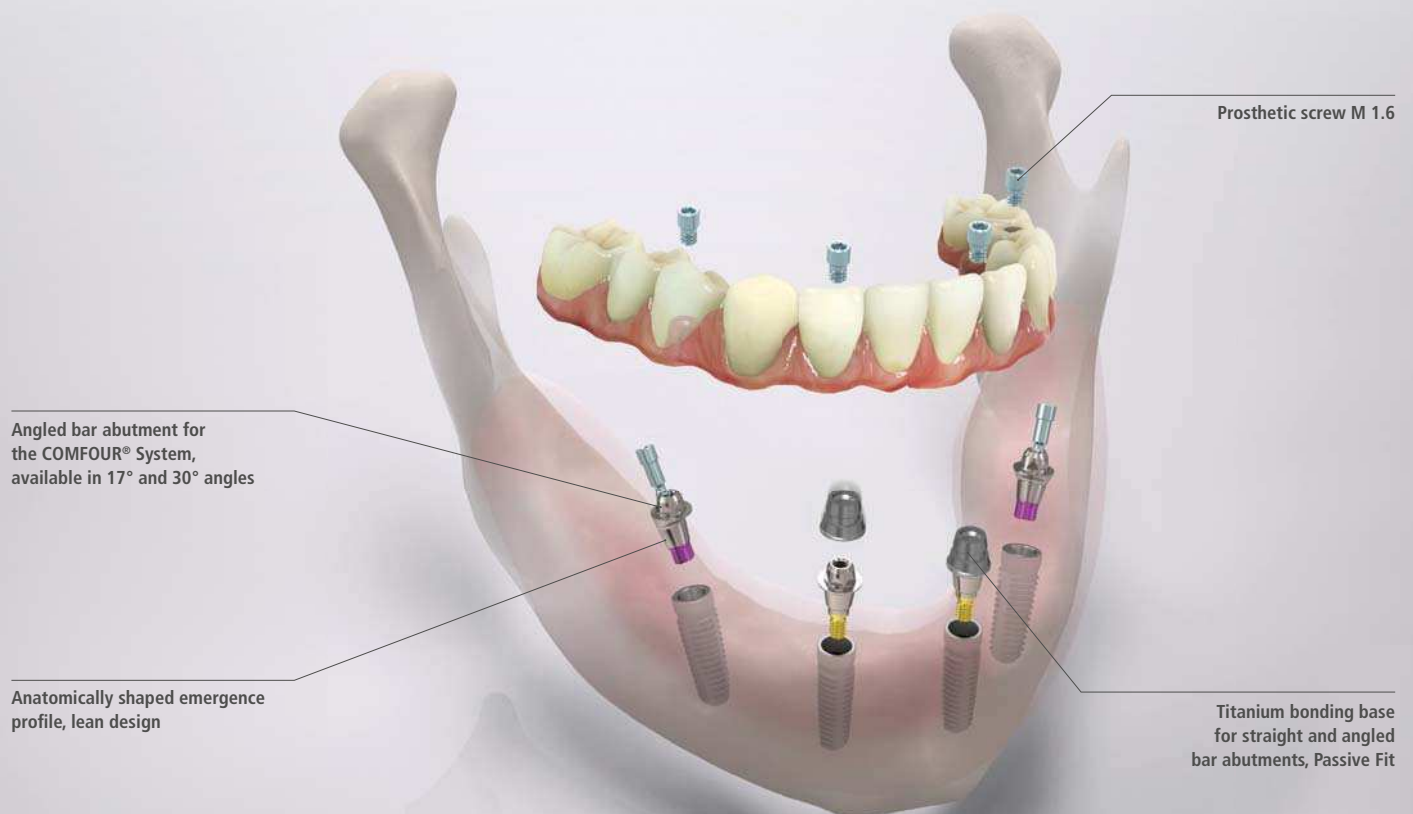camlog

THE NEW COMFORT CLASS.

The COMFOUR® Abutment System for occlusal screw-retained restorations is an ideal addition to the CAMLOG® and the CONELOG® Implant System. With the COMFOUR® System, you can offer your edentulous patients the option of an immediate, comfortable and permanent denture on four or six implants – and thus a considerable gain in quality of life. www.camlog.com

CAMLOG®
SYSTEM

CONELOG®
SYSTEM

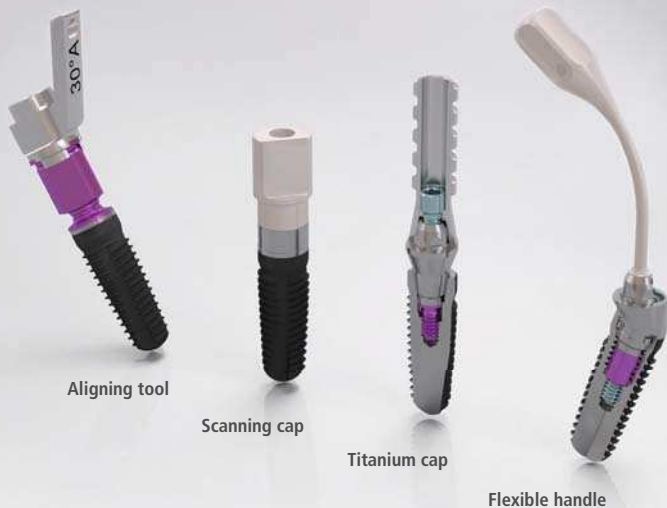

Prosthetic screw M 1.6

Angled bar abutment for the COMFOUR® System, available in 17° and 30° angles

Anatomically shaped emergence profile, lean design

Titanium bonding base for straight and angled bar abutments, Passive Fit



Aligning tool

Scanning cap

Titanium cap

Flexible handle

COMFOUR® offers you a range of options to overcome the challenges you face in your implant practice, making them easier while saving time.

Titanium and its alloys in dental implantology

Authors: Drs Roland Masa & Gábor Braunitzer, Hungary

Pure titanium and titanium alloys for dental purposes

In contemporary prosthodontics, the use of dental implants is as self-evident as any other established method. Titanium (Ti) and its alloys are still the most widely used materials for dental and orthopaedic applications.^{1,2} Titanium has good mechanical stability, low density (4.5 g/cm³), a high strength-to-weight ratio and favourable biocompatibility.³ Titanium and its alloys have excellent corrosion resistance owing to the thick, insoluble titanium dioxide (TiO₂) layer that forms on the surface within nanoseconds. This layer can restore itself immediately in the presence of water or air should damage occur.⁴

Four grades of unalloyed, commercially pure (CP) Ti are available for dental applications, designated as Grades 1 to 4. These grades are defined by their oxygen and iron content, as these elements have a substantial effect on the mechanical and physical properties of the metal, even in very small concentrations. As the concentration of oxygen or iron increases, the mechanical strength increases in parallel, while ductility decreases.⁵ The Ti-6Al-4V alloy (described later) is also referred to as Grade 5. Grades over 5 are not used in dentistry. A comparison of the mechanical properties of CP Ti and its alloys is given in Table 1.

Grades 1 to 4

As already mentioned, the physical characteristics of CP Ti are predominantly influenced by the oxygen and iron content of the material. The increasing grade number expresses a decreasing amount of these "impurities". Therefore, Grade 1 is the softest and most ductile type of CP Ti, while Grade 4 is significantly stronger and less malleable than the lower grades.⁵ Of the unalloyed CP Ti grades, Grade 4 has the highest tensile strength and yield strength. Some disadvantages that Grades 1 to 4 have are relatively low mechanical strength, a high Young's modulus and poor wear resistance. Improving the mechanical

properties without reducing biocompatibility is still a challenge.⁶

Grade 5 (Ti-6Al-4V)

CPTi is not preferable when high stress tolerance is required. Mechanical properties such as implant strength, creep resistance and formability can be improved by alloying Ti with a wide range of elements (e.g. aluminium, Al; vanadium, V; tantalum, Ta; zirconium, Zr). As shown in Table 1, the mechanical properties of Ti alloys are superior to those of Grades 1 to 4, and therefore it comes as no surprise that Grade 5 is the most widely used Ti alloy for biomedical applications.³

In spite of its good mechanical features, corrosion wear and ion release (Al, V) initially raised concerns about its applicability in implant dentistry. De Morais et al. investigated the level of these ions released from orthodontic mini-implants and the potential toxicity of these elements.⁷ They concluded that, despite the detectable amounts of Ti, Al and V ions, these values remained below the average nutrition uptake of these ions and did not reach the level of toxicity.⁷

A high Young's modulus is also a problem with Grade 5, but the exact value (115 GPa) does not significantly differ from that of the CP grades. Therefore, this should not raise specific concerns regarding this alloy. Different alloying elements have been used to replace Al and V in the Ti-6Al-4V alloy. One example is the use of niobium (Nb) and Zr in the alloy Ti-13Nb-13Zr. This offers the highest strength-to-weight ratio and a reduced Young's modulus (77 GPa), making Ti-13Nb-13Zr optimal for orthopaedic implants.⁸ Ti-13Nb-13Zr's possible dental applicability is still under investigation.^{9,10}

Adverse reactions to titanium and titanium alloys

Since Ti is a transition metal, allergy or metal hypersensitivity may be a matter of concern.¹¹⁻¹³ In

Properties	Grade 1	Grade 2	Grade 3	Grade 4	Grade 5 (Ti-6Al-4V)	Ti-13Nb-13Zr	
Tensile strength (MPa)	240	345	450	550	860	1,030	
Yield strength (0.2% offset; MPa)	170	275	380	485	795	900	
Elongation (%)	24	20	18	15	10	15	
Reduction of area (%)	30	30	30	25	25	45	Table 1

spite of Ti's excellent biocompatibility, allergy to this metal can still be observed in dental implant patients, although its prevalence is very low (0.6%).¹⁴ Some authors still recommend a metal allergy test for patients with previous hypersensitivity of any kind.^{15,16} While we have no gold standard test for detecting Ti allergy, dermal patch tests or *in vitro* blood tests such as the lymphocyte transformation test or the memory lymphocyte immunostimulation assay (MELISA®) are frequently used methods, even if the results are often ambiguous.¹⁷ It must be added that Ti exposure from personal care products and biomedical implants is common, and still there is no reliable evidence for actual toxicity or true allergic reactions.

Furthermore, according to a review by Javed et al., Ti per se cannot be identified as a cause of allergic reactions in patients with dental implants.¹⁸ In their opinion, it is the occasional and otherwise negligible impurities (i.e. additional elements besides Ti) that trigger hypersensitivity reactions.¹⁸ Harloff et al. examined common dental implant materials (Grade 1 Ti and Ti alloys, including Grade 5) by spectral analysis.¹⁹ Their results showed that all the investigated materials contained low but detectable amounts of various other elements (nickel, chromium, copper, palladium, manganese) that may induce allergic reactions, especially in people with existing metal sensitivity.

Since it is quite rare for a patient's metal allergy to be diagnosed first upon implant placement, failure due to hypersensitivity can be avoided by careful history taking. However, it can happen that the patient denies knowledge of any metal allergy and an allergic reaction occurs nevertheless. The appearance of a rash, urticaria, oedema, mucosal erythema, swelling, or hyperplastic lesions of the soft tissue after implant placement indicates an allergic reaction.²⁰ In these cases, a corrosion process is occurring in which ions released from the surface form active complexes with proteins and trigger the characteristic reactions.²¹ Such cases, however, are rare, and Ti implants for prosthodontic purposes can be considered safe and reliable for the general population.

Dental implant surface modifications


Bulk properties, such as corrosion resistance and modulus of elasticity, which determine the selection of the appropriate biomaterial for the relevant biomedical application, are important for implant success. However, surface properties also play a significant role. First of all, the geometric configuration of the implant should be designed to achieve an extensive bone-implant contact area for faster osseointegration. This in itself, however, is not sufficient. During osseointegration, the outermost layers of the implant interact with the host tissues and cells. Therefore, developing surfaces that enable a shorter healing time and optimal connection between the biomaterial and the surrounding bone is a major focus of research.

In order to achieve that goal, various surface treatments have been developed, generally classified into two major categories: physicochemical and biochemical. A common feature of these treatments is that they leave the bulk properties unchanged and modify only certain target properties of the surface, such as its roughness or chemical composition.²²⁻²⁴ Here, we give a brief summary of these methods and their resulting surfaces and discuss the sandblasted, large-grit, acid-etched (SLA) method that combines two physicochemical methods.

Physicochemical methods

Physicochemical methods are usually used to increase the implant's surface roughness. Rougher surfaces yield better bone response and higher bone quality than machined/turned surfaces, as demonstrated by histomorphometric studies.²⁵⁻²⁷ Wennerberg and Albrektsson classified surfaces according to their roughness (Sa) as follows: smooth (Sa < 0.5 µm), minimally rough (Sa = 0.5–1 µm), moderately rough (Sa > 1–2 µm) and rough (Sa > 2 µm); and concluded that moderately rough surfaces (such as SLA, detailed later) show the most favourable bone responses.²⁸ The most widely used physicochemical surface treatments are sandblasting, ion implantation, laser ablation, covering with inorganic calcium phosphates and purely chemical methods, like oxidation and acid etching.²⁴

Tab. 1: Mechanical properties of titanium and its alloys.⁵



Figs. 1a & b: Scanning electron microscopy images of Alpha-Bio Tec's SLA surface at x1,000 (a) and x2,500 (b) magnification.

Biochemical methods

These methods augment the physicochemical processes based on the latest knowledge in biology and biochemistry. The aim is to immobilise various proteins, enzymes and molecules to better control the specific bone-implant interface.²⁹⁻³¹ These molecules can interact with or promote the adsorption of desired proteins to enhance osseointegration. Proteins and/or steroid growth factors have been shown to promote the proliferation of different connective tissue and inflammatory cells.^{32,33} Besides promoting the attachment of host cells, the inhibition of bacterial colonisation is desirable and is the focus of intensive research.³⁴

In order to prevent the initial attachment of bacteria and biofilm formation, anti-biofouling and bactericidal surfaces have been developed. Anti-biofouling surfaces prevent the initial attachment with specific surface topography or chemistry.³⁵ In addition, bactericidal surfaces cause the death of the bacterial cell typically on contact.³⁶ Coatings that release nanosilver, photocatalytic TiO₂ or nitric oxide have been shown to be bactericidal.^{37,38}

Sandblasting with large-grit corundum and acid etching

SLA is one of the most widely studied and well-documented Ti implant surface modifiers³⁹⁻⁴² and was originally introduced by Buser et al.⁴³ As the name suggests, the surface is first sandblasted with large-grit corundum (aluminium oxide) particles, then acid-

etched with hydrochloric acid and sulphuric acid. The result is a moderately rough surface ($S_a \approx 1.5 \mu\text{m}$) characterised by rapid osseointegration and is therefore optimal even for early implant loading.²⁸ The surface is composed predominantly of TiO₂ with residual Al from the sandblasting process.^{44,45} Some studies have reported as high as a 97-100% success rate with this surface at the five-year follow-up, after early loading at six weeks (Figs. 1a & b).^{46,47}


Biocompatibility and clinical applicability of SLA

In vitro studies

Aybar et al. performed an immunohistochemical study of osteoblast-like cells on four different types of Ti discs: SLA1 (Grade 4, Straumann), SLA2 (Grade 5, Alpha-Bio Tec), acid-etched (Grade 5, Alpha-Bio Tec) and machined (Grade 5, Alpha-Bio Tec).⁴⁸ Proliferation and DNA synthesis of primary rat calvarial cells were evaluated after one and seven days of incubation. After 24 hours, the highest level of DNA synthesis was observed on SLA1, but after one week, the proliferation of osteoblast-like cells decreased significantly on this surface, while a significant increase of DNA production was observed on the Grade 5 surfaces. In another *in vitro* study, the adsorption of different human plasma proteins to three different implant surfaces (SLA, machined, acid-etched, Alpha-Bio Tec) was examined. Singh compared polished and SLA surfaces in terms of osteogenetic potential, and found SLA significantly superior (Figs. 2a & b).⁵⁵ The quantity and quality of adsorbed plasma proteins (albumin, fibronectin and fibrinogen) was the highest in the SLA group, as demonstrated by enzyme-linked immunosorbent assay and confocal scanning laser microscopy.⁴⁹ Implant removal torque testing also resulted in better bone anchorage and higher stiffness values of the SLA surface compared with the machined and acid-etched surfaces.⁵⁰

Clinical studies

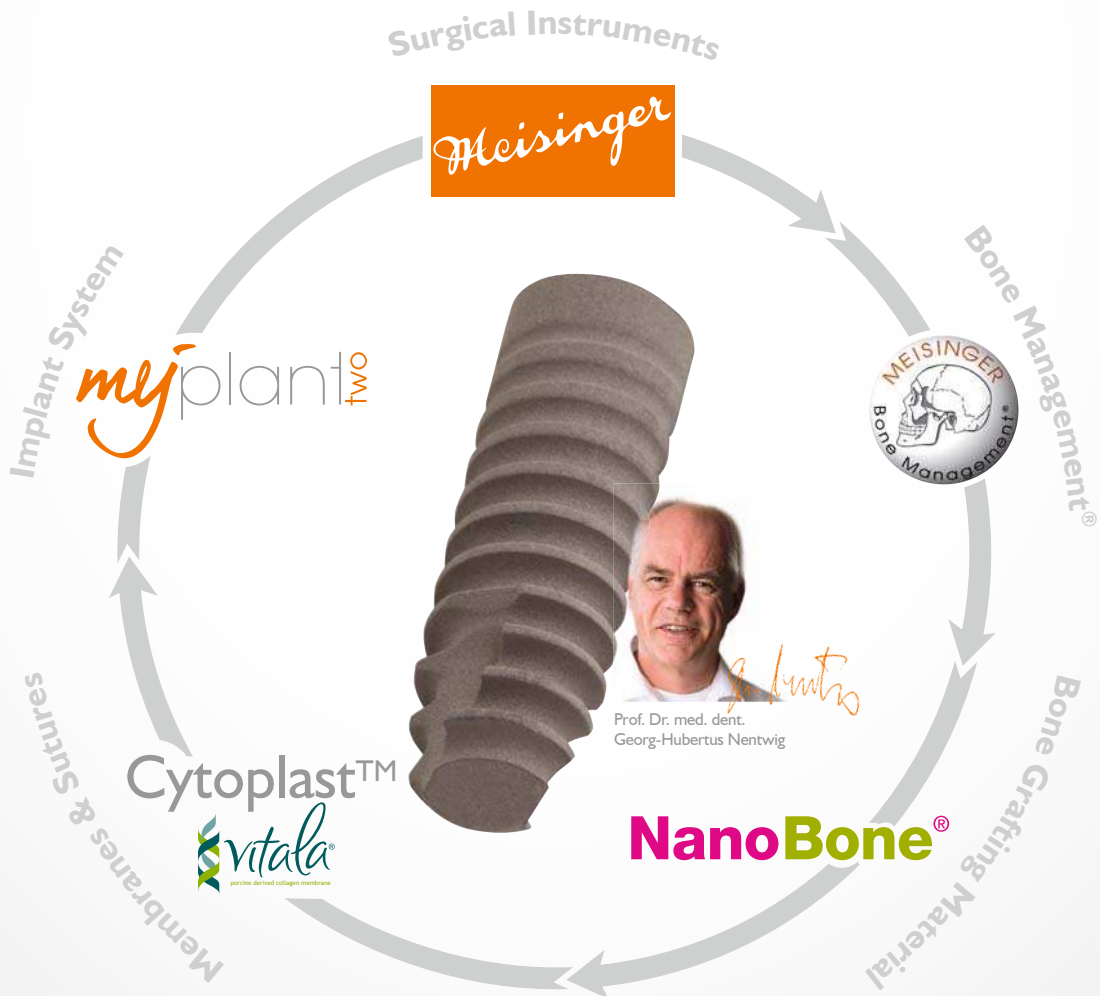
Roccuzzo et al. examined 106 implants (53 SLA, 53 control TPS) in 27 patients and found no implant loss after five years' follow-up (100% success rate).⁴⁶ No significant differences were seen in the basic periodontal indices (bleeding on probing, probing pocket depth, bone loss) between the two surfaces,⁴⁶ indicating superior biocompatibility. Van Velzen et al. evaluated the ten-year survival of 374 SLA-modified dental implants in 177 patients with special attention to peri-implantitis. The success rate was 99.7% at the implant level and 99.4% at the patient level, with 7% prevalence of symptoms specific to peri-implantitis.⁴⁰ In the clinical study of Strietzel et al., the survival of 283 immediately loaded screw-type Alpha-Bio Tec SLA implants was assessed.⁴⁷ It was found that,



Figs. 2a & b: Scanning electron microscopy images of smooth (a) and SLA (b) surfaces after attachment of human osteosarcoma osteoblast cells.⁵⁵

MEISINGER

PERFECT SURGICAL SOLUTIONS



Authors (year)	Aims of the study	Survival rate (%)	Company	Follow-up
Roccuzzo et al. (2008)	Assessment of the peri-implant condition, early loading	100	Straumann	5 years
Van Velzen et al. (2015)	Long-term survival and incidence of peri-implant disease	99.7	Straumann	10 years
Strietzel et al. (2011)	Comparison of immediately loaded implants (different implant insertion times)	98.2	Alpha-Bio Tec	2.5 years (median)
Artzi et al. (2010)	Success rate of implants loaded immediately after implantation (post-extraction or healed alveoli)	96.9	Alpha-Bio Tec	3 years
Ormianer et al. (2016)	Comparison of long-term bone loss around dental implants with three different thread designs	96.3	Alpha-Bio Tec	107 months (mean)
Kohen et al. (2016)	Comparison of different insertion and loading protocols	95.6	Alpha-Bio Tec, Zimmer Dental, BioHorizons IPH	107 months (mean)

Table 2

Tab. 2: Clinical success rate of SLA-treated dental implants.

regardless of the time of insertion (immediate or delayed), the general survival of these rough-surfaced implants was 98.2% at follow-up after a median of 2.5 years.

Artzi et al. reported high success rates with immediately loaded, fixed provisional prostheses supported by root form or spiral-shaped Alpha-Bio Tec implants.⁵¹ Of the 676 implants, only 21 (3.1%) were removed owing to failed osseointegration. The effect of three different implant macrostructure designs on marginal bone loss was compared by Ormianer et al.⁵² They investigated 1,361 implants and found the survival rate to be 96.3%. In their study, one-piece V-thread design implants were associated with the least bone loss and the highest survival rate, probably owing to the absence of micro-gaps between the implant and the abutment. Finally, Kohen et al. reported high implant survival (95.6%) and minimal bone loss (2.03 mm) in a sample of 1,688 implants, 75% of which were manufactured by Alpha-Bio Tec.⁵³ These success rates suggest that the biocompatibility of SLA implants is superior (Tab. 2).

Conclusion

The excellent biocompatibility and physicochemical properties of Ti dental implants position Ti as the gold standard in implant dentistry. While the safety and success of Grade 4 Ti is well documented, Grade 5 offers better physical properties and similarly outstanding biocompatibility and survival. As for the various surface modifications, SLA appears to combine the advantages of the physical and chemical methods successfully, making it a favourable alternative. High levels of osseointegration and favourable

long-term survival of SLA dental implants were confirmed by several *in vitro* and clinical studies. Based on the current literature, we can conclude that Grade 5 Ti with SLA-modified surfaces assures the best dental implantation outcomes. Hypersensitivity or allergic reactions to Ti or other alloy ingredients are extremely rare but still occur, necessitating that the implant dentist be aware of this possibility and pay special attention to the patient's history.



contact

Dr Roland Masa

Department of Oral Biology and Experimental Dental Research
Faculty of Dentistry
University of Szeged
Tisza Lajos körút 64–66
6720 Szeged, Hungary
Tel.: +36 62 545283

Author details




Dr Gábor Braunitzer

dicomLAB Ltd.
Pulz utca 46/b.
6724 Szeged, Hungary
Tel.: +36 62 737304

Author details





Dentsply Sirona does not waive any right to its trademarks by not using the symbols or 3267114-USX1610 © 2016 Dentsply Sirona. All rights reserved.

Astra Tech Implant System®

Our world is not flat

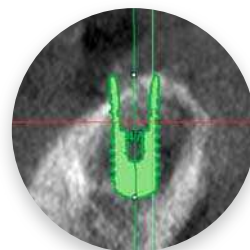
Neither is the anatomy of your implant patients

Your world is already full of clinical challenges so why work harder because of conventional thinking? Instead of augmenting sloped ridges to accommodate flat-top implants, it's time to discover a simpler solution by using an implant that follows the bone. Because sloped-ridge situations call for anatomically designed sloped implants.

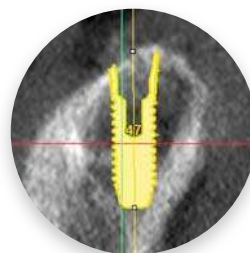
OsseoSpeed® Profile EV - It's time to challenge conventional thinking



www.profiledentalimplants.com



Conventional vs innovative approach



 **Dentsply
Sirona**
Implants

Rehabilitation of edentulous patients

Author: Dr Nikolaos Papagiannoulis, Germany



The prosthetic rehabilitation is the last step in implant therapy. The ageing of the population, the demand for aesthetics and functionality at advanced ages, and the establishment of implants as a regular therapy increase the edentulous situations that must be treated yearly. In this study, we examine full-arch treatments with screw-retained fixed prostheses. In Table 1 (see QR Code Tables), a decision tree for deciding whether fixed or removable prostheses are the appropriate solution for the patient is shown. While fixed prostheses are more favourable in the case of sufficient bone volume or only minor bony defects and good patient compliance, removable ones are preferable in the case of major vertical defects or insufficient soft-tissue support (in addition to a lack of compliance). In this study, we treated 23 edentulous jaws. In total, 133 implants were placed, 94 in the maxilla and 39 in the mandible. All of our patients fulfilled the criteria shown in Table 1 (see QR Code Tables): no or low vertical and lateral bone defects, replacement of the teeth was sufficient for soft-tissue support, hygiene was ensured in every case, and implants were placed in the proper prosthetic position.

Manufacturing and implantation

Three jaws received cast frameworks milled at the laboratory, whereas 12 were CAD/CAM-milled at multi-unit abutment level. The remaining eight frameworks were milled at implant level (either with internal geometry or on a scan base abutment). The major implant types used were anonymised into B, I and M, while implant Types Z, C and two others refer to older implants integrated into the new prostheses. Three implants were lost during healing owing to low primary stability and lack of osseointegration. All three implants were replaced immediately with slightly wider ones, since no signs of inflammation were evident.

The All-on-4 protocol (Nobel Biocare) was deliberately avoided, since its limitations influence long-term therapy success. Nevertheless, two patients (both maxilla) received only four implants. Both patients were over 80 years old and in neither of the cases were implants angulated more than 15°. Generally, we tried to avoid angulated implants. In contrast to the All-on-4 concept, we chose to insert the im-

Figs. 1a–h: Multi-unit abutments.
a) Type B straight. **b)** Type B angled.
c) Type C snap-in. **d)** Type C straight.
e) Type T straight. **f)** Type T angled.
g) Type M straight. **h)** Type M angled.



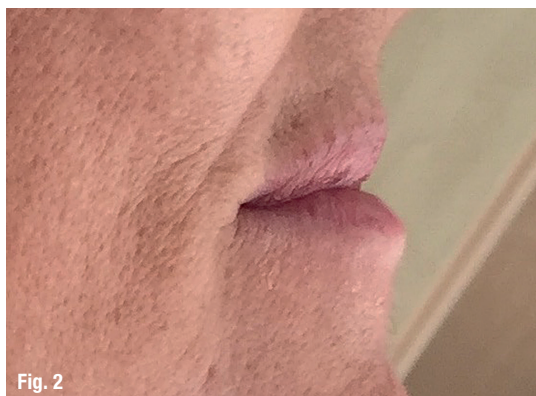


Fig. 2

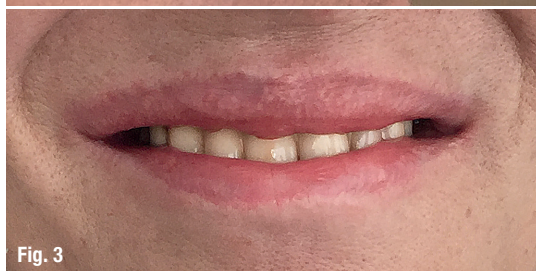

Fig. 3

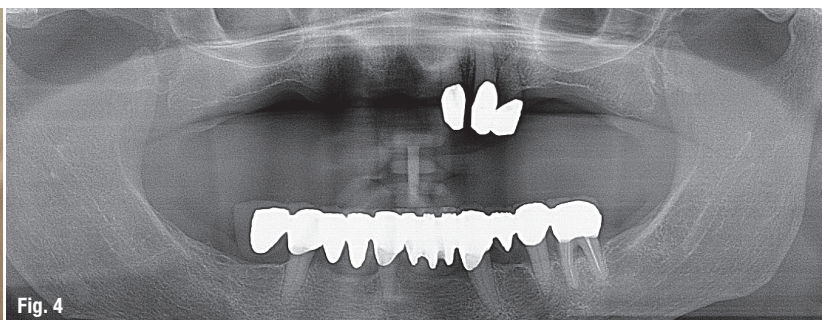


Fig. 4

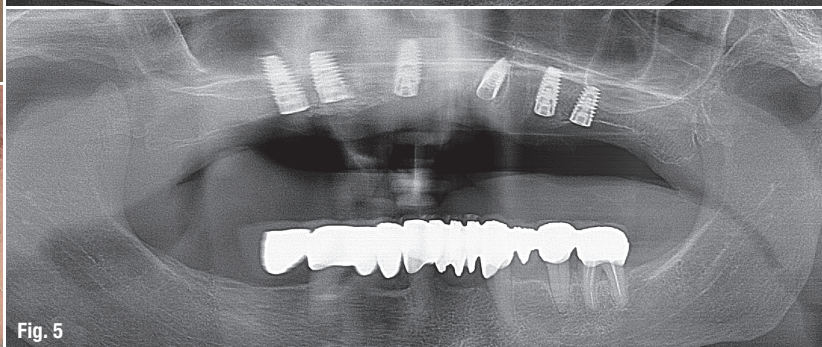


Fig. 5

plants parallel. As a result, only four jaws and eight implants needed angled multi-unit abutments. No second molar was replaced in any case, but one patient received restoration up to the second premolar, since the molars were retained and received regular full-ceramic crowns (Table 2, see QR Code Tables).

Prosthetic components

All of the angled multi-unit abutments were two-piece abutments. The B and C systems offered one- and two-piece straight abutments. System C components had a snap-on function that often simplified their insertion—though not in all cases. All of the systems offered components with anti-rotation between the multi-unit abutment and implant. If components without anti-rotation to the implant were used, they needed to remain inserted after the initial probing. Components with an anti-rotation function between the multi-unit abutment and framework or titanium sleeve were very useful. The insertion of angled abutments was time-consuming without a jig. Angled abutments were inserted with customised titanium sleeves, since no abutment carrier was sufficient for insertion. Special insertion adapters were necessary for almost all manufacturers (apart from Type D implants).

A very practical abutment design was determined for Type I and M implants. Combining platform switching and a concave abutment design offers much space for crestal bone and soft tissue to build a ring around the implant neck, protecting it in the long term. Type M implants offer even more space for crestal bone and soft tissue through the triangular design of the implant neck. Together

with the gold-anodised prosthetic components and emergence profile, aesthetics is realised more easily than with other systems (Figs. 1a–h; Table 3, see QR Code Tables).

Manufacturing and milling

Screw-retained full-arch constructions show many advantages over cemented ones. They are easy to realise and repair. From re-entry until final loading of the implants takes three to four appointments and three weeks. Especially in combination with digital impressions and 3-D-printed models, the manufacturing time and costs can be reduced to a minimum. Apart from the re-entry, all other appointments are short, only up to 30 minutes. Cast frameworks (non-milled) are quite expensive and subject to tension. In contrast, milled frameworks showed no tension at all and no steps had to be repeated.

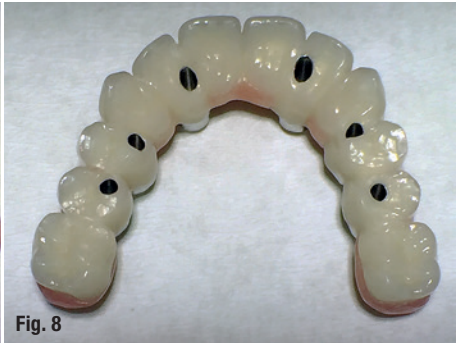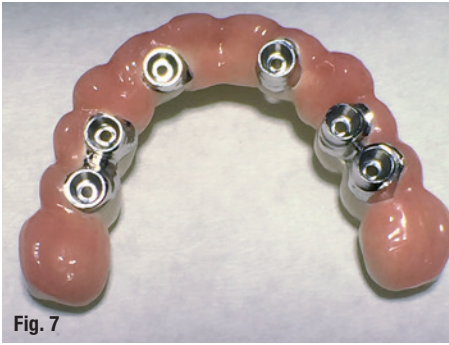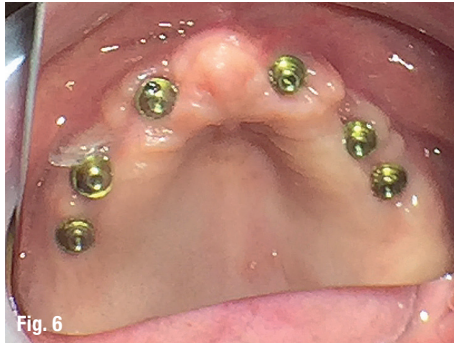The mandibles were treated with multi-unit abutments. There was only one exception of a mandible being treated with a framework at the implant level, because no milling centre that we worked with was able to mill an internal hexagon geometry of 3 mm. The maxillae were treated with scan bases or directly at the implant level. The maxilla is not mobile and therefore is not subject to torsional forces as the mandible is. Through this solution, we reduced potential weak points to a minimum, having only one, the screw fixing the framework to the implant. In the mandible, there are two potential weak points: the screw to the implant and the screw to the multi-unit abutment. Nevertheless, in this study, two maxillae were treated with multi-unit abutments because either the milling centres were not able to

Case 1—Fig. 2: Lateral view of the face with the patient wearing the provisional prosthesis.

Fig. 3: Frontal view of the face with the patient wearing the provisional prosthesis.

Fig. 4: Radiograph before implant placement.

Fig. 5: Radiograph after implant placement.



Case 1—Fig. 6: Maxilla with multi-unit abutments.

Fig. 7: Basal view of the screw-retained bridge.

Fig. 8: Coronal view of the screw-retained bridge.

mill the required geometry or there was an insufficient conical connection surface between the framework and implant to eliminate transversal forces leading to screw loosening (Table 4, see QR Code Tables).

CAD/CAM-milled superstructure

The digital era of dentistry has reached our practice. A digital workflow is not possible without compromises. Nevertheless, new materials, manufacturers and systems are easily integrated into any workflow or milling system. Also, anatomical findings can often avoid techniques like intraoral scanning.

In this case series, only six cases were performed with intraoral scanning. Owing to the very high soft-tissue quantity that we saw in many cases, scan bodies were not always sufficient for the scanners to perform digital impressions. The matching of an edentulous jaw with a non-edentulous one is possible with additional aid. Even in cases that were scanned intraorally, we manufactured 3-D models to proceed with the jaw matching.

Case 1

In the first case, a female patient with a partially edentulous maxilla was treated. All of the remaining teeth had to be extracted. One implant was an immediate implantation. The patient received a removable provisional prosthesis for two months. Owing to the implant surface of the manufacturer, we decided to re-enter after eight weeks. The final loading took place 12 weeks after implant placement. Although one implant had no optimal angulation, a screw-retained bridge was possible. The prosthesis received a resin layer facing the ceramic bridges in the mandible.

The replacement of the missing teeth with a prosthesis was sufficient for optimal support of the lower face soft tissue. Furthermore, a welcome side effect of such treatment is the decrease of wrinkles through the soft-tissue support. With this, the patient looked ten years younger. A very important focus of the prosthetic rehabilitation was hygiene maintenance.

The patient needed to be able to brush and floss each implant easily, giving consideration to the fact that all of the patients in this series were over 60 years old, with an average age of 65 to 70, and some were already in their 80s.

The prostheses were loaded on multi-unit abutments. Although we generally load maxillae at the implant level, the implant system used in this case was very new and milling centres were not able to mill the internal geometry or use other cast scan bases. Nevertheless, loading maxillae at the implant level reduces weak points at the superstructure level. Here, we would have six screws that could loosen. Since the maxilla is not mobile, there are no torsional forces on the implants or the superstructure (Figs. 2–12).

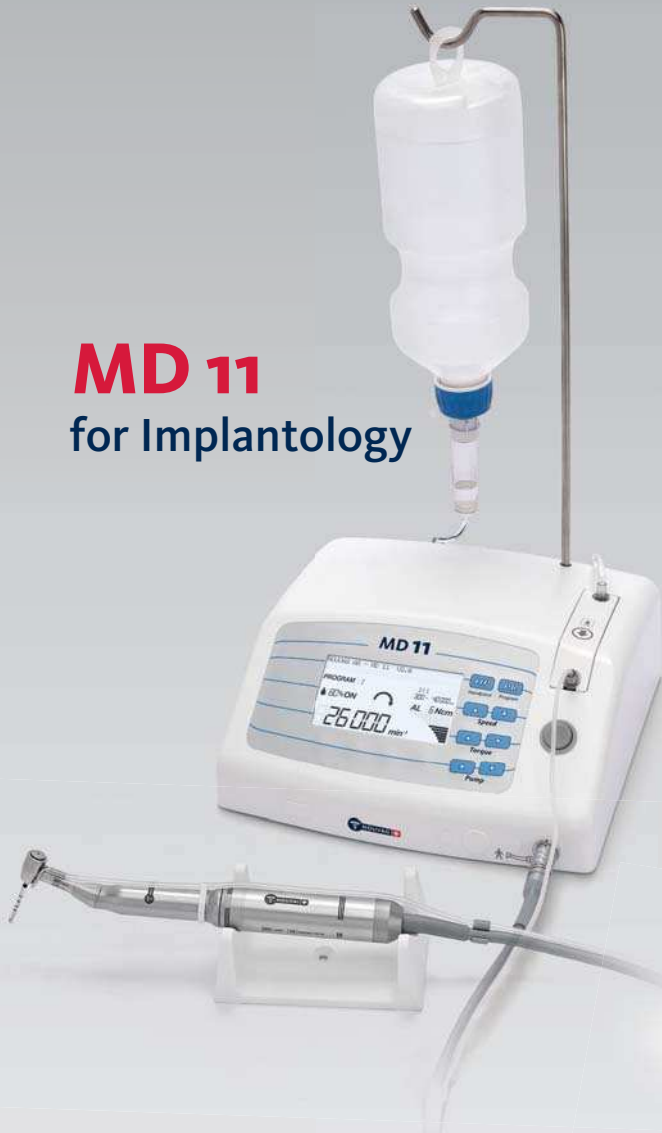Case 2

In the second case, treatment of a mandible was performed. All of the teeth needed to be extracted; however, initially, three molars were retained for the stability of the provisional prosthesis. Owing to emotional reasons, the last two molars were extracted some months after loading the implants. Four of the five implants were placed immediately. The fifth one, placed in region #46, was a late implantation. We could clearly see that, at the point of loading, there was slight vertical bone resorption at #46. This was not true resorption, but more the establishment of a new biological width. This new biological width is inevitable.

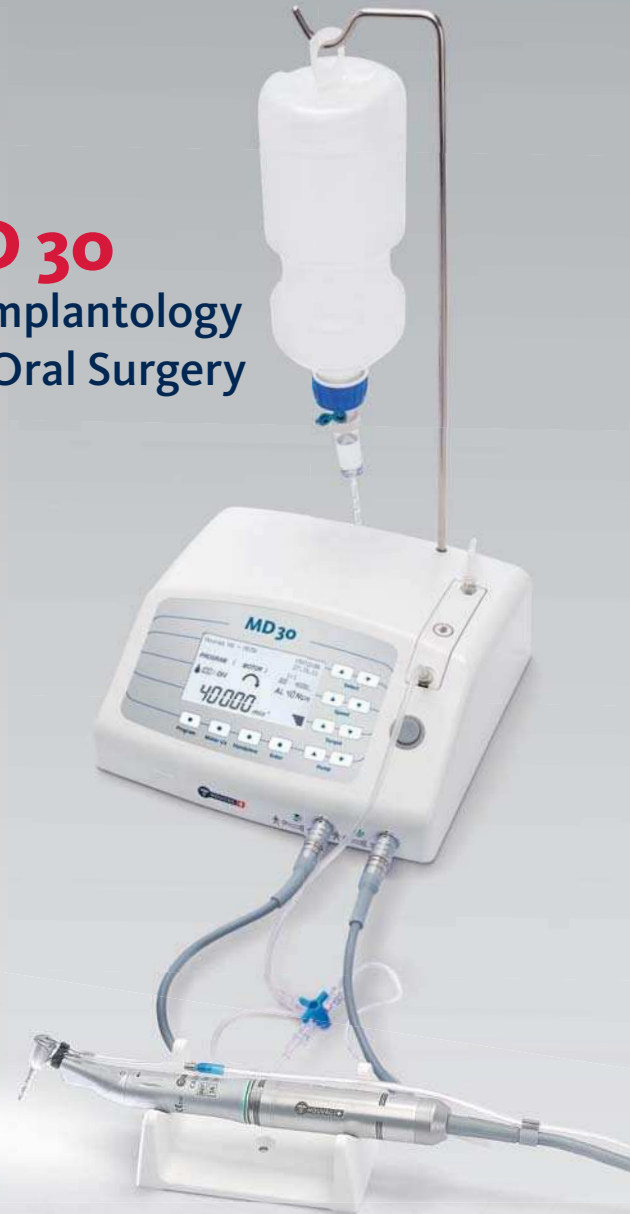In late defects, biological width is lower if platform-switched implants are used and placed correctly and higher if other platforms are used. Immediate implantations seem to behave more predictably: the transformation of the socket begins with the implant placement and not after the re-entry. With this, we see no vertical bone loss in the first weeks or months after loading the implants. The long-term stability is not affected by the new biological width. The main factors for long-term stability are bone quantity, soft-tissue quantity and quality, prosthetic and masticatory forces, as well as proper oral hygiene at home (Figs. 13–19).

We talk implantology

MD 11
for Implantology



MD 30
for Implantology
and Oral Surgery



- **Easy** | Simple device setup
- **Strong** | Powerful and smooth motor
- **Reliable** | High quality finish



Scan me to be linked to the Nouvag contact form. ▶



NOUVAG AG · Switzerland
info@nouvag.com · www.nouvag.com

In this case, we loaded the implants as prescribed in our protocol. We prefer to always load the mandible at the multi-unit abutment level. The reason for this is that the mandible is long bone that experiences torsional forces through mastication. Loading at implant level would transfer these transversal forces to the implants, thereby influencing long-term stability. With multi-unit abutments, the weak point is placed higher, at the connection of the superstructure to the multi-unit abutments. In this way, such forces would cause screw loosening at the superstructure level. This has been seen at recall appointments, where in approximately 5 per cent of the implants placed, screw retention has loosen insertion torque, not 100 per cent but almost 10Ncm. We also have to consider that these screws are inserted at a torque of 15 to 20Ncm, while superstructures are directly screwed at implant level at 35Ncm. Thus, there was no mobility felt at the superstructure level and no patient had such complaints.

Discussion

Digital dentistry

Modern digital dentistry offers various services to the practitioner. Computer-assisted implantology has been a reality for many years. The digital impression (precision of up to 7–12 μ) is evolving rapidly, allowing additional services, such as the complete planning of the prosthesis, shade matching, mock-ups and fast communication with the laboratory. 3-D printers offer precise (up to 30–50 μ) models and

minimise time wastage such as in conventional dentistry. Milling centres are fast in production and use new systems and techniques. The intraoral scanner used in this study needs no powder and is able to scan even in the humid environment of the mouth.

Data communication

Yet, there are problems to overcome. Often, it is difficult to implement new data formats in old workflows and convert it into STL format, and this may result in the loss of information. Though not in all cases, the practitioner can avoid master models for manufacturing full-arch frameworks. At the same time, screw-retained full-arch solutions are less favoured in some countries, although implant manufacturers and the industry react very quickly to the needs of the practitioner.

Full-arch frameworks and materials

Full-arch frameworks, according to this protocol, are to be loaded on multi-unit abutments when treating the mandible. Owing to the torsional forces, a too-rigid connection of the implants can lead to screw loosening although the framework is free of tension. Such torsional forces occur during mastication or parafunction and can result in overloading of the implants. The maxilla can bear practically any type of framework.

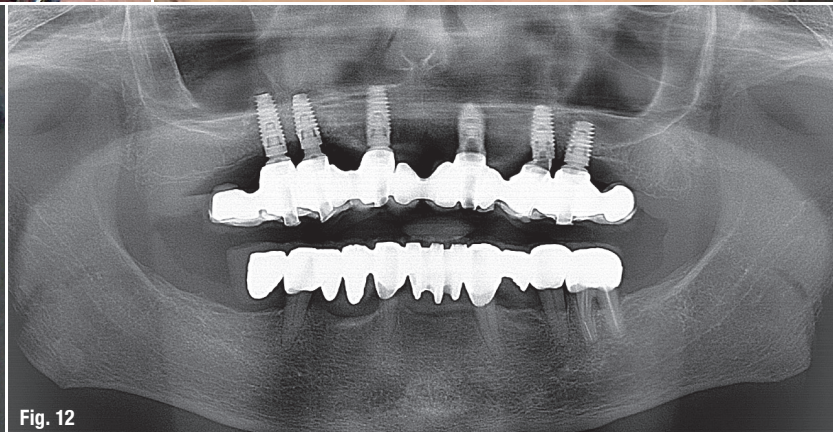
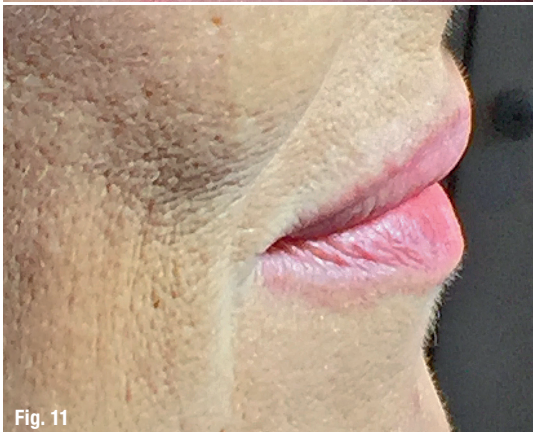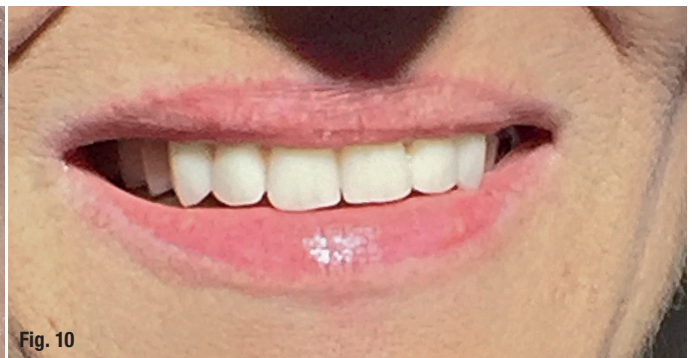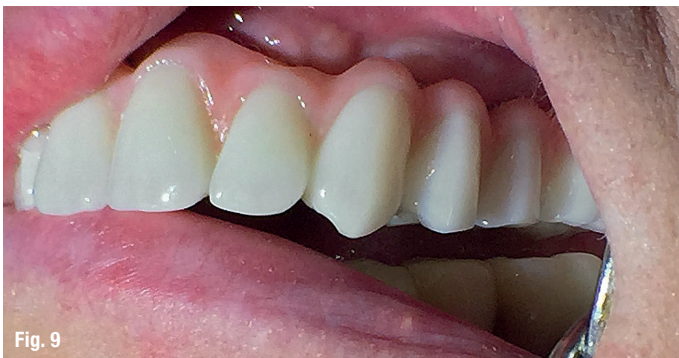A very interesting alternative to this protocol is frameworks of PEEK or PEEK variants, such as BioHPP (bredent), especially in removable prostheses and in

Case 1—Fig. 9: Implants loaded.

Fig. 10: New lower face aesthetics and lip support.

Fig. 11: New smile and face soft-tissue support.

Fig. 12: Radiograph after loading.



THE SELF-ALIGNING OT EQUATOR HOUSING

Metal to metal rotational core

Titanium anodized housing

Titanium liner

Elastic Cap

Passive insertion
reduces trauma

Correct divergency
up to 50°

25°

50°

25°

RHEIN83

Case 2—Fig. 13: Radiograph before implant placement.

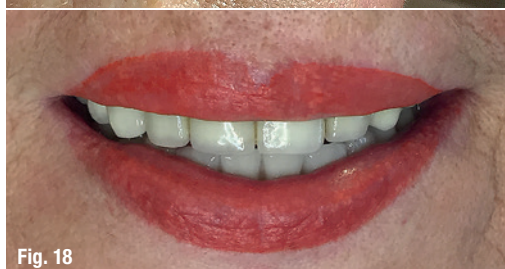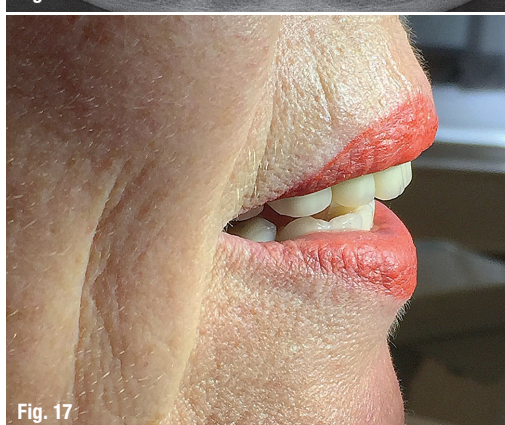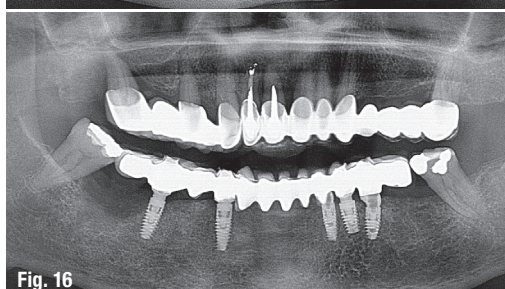
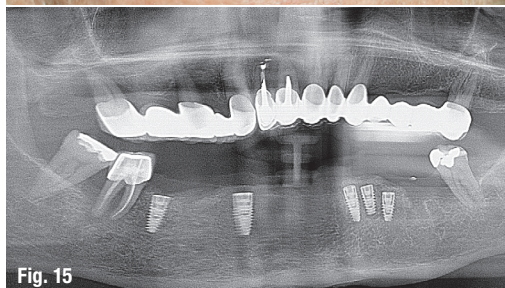
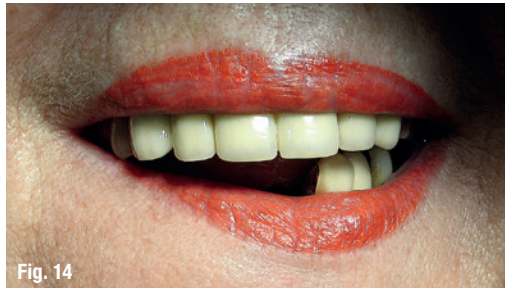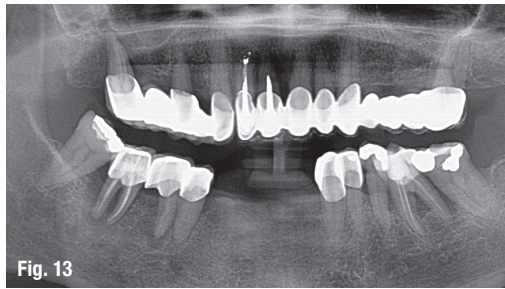
Fig. 14: Patient smiling before implant treatment.

Fig. 15: Radiograph of the implants placed in the mandible.

Fig. 16: Radiograph of the screw-retained bridge in the mandible.

Fig. 17: Lateral view of the patient showing soft-tissue support of the lower face.

Fig. 18: Frontal view of the patient smiling.



the mandible. They are elastic, can be milled thinly and are comfortable to wear. Also, full-zirconia frameworks on scan bases are experiencing a revival. Nowadays, we can overcome early childhood diseases like framework fracture by removing the weak points coronally by using a zirconia framework prepared like teeth and IPS e.max crowns (Ivoclar Vivadent) on them. In this way, if fractures occur, they instead affect the IPS e.max crown, which can easily be milled and applied in only a few hours.

Complications

In order to eliminate complications, all patients were put on a four- to six-month recall programme. The passive fit of the framework was elementary. Complications were only observed in one case of a mandibular construction at the implant level through screw loosening or framework detachment from the scan base. The prostheses were rebuilt with multi-unit abutments or internal geometry this time. Loosening of the screws retaining a superstructure on multi-unit abutments was not seen as complication and occurred only in mandibles.

Another important issue is the communication between dentist and dental technician. The framework, especially regarding milling at the implant level, must be planned thoroughly. The technician needs exact instructions on how to mill the emergence profile. If, for example, the soft tissue after re-entry is sufficient, but when it comes to the final loading, the emergence profile and the framework are too bulky, gingival recession can occur. This is not true gingival recession, but arises because the part of the framework engaged with the implant is too convex. Reducing this part or even giving it a concave form solves the aesthetic problem through lower pressure on the buccal gingiva.

Prosthetic components and aesthetics

Another important issue is the soft-tissue aesthetics. Concave abutments are preferable. They offer space for the soft tissue to build a ring around the abutment, protecting the crestal bone. The more delicate the abutment, the better the aesthetic outcome. Manipulating soft tissue through implant components is a smart way to optimise prostheses, but leads to recessions if components are too bulky. Angled abutments especially tend to be too bulky. Additionally, they cause pain when inserted because of their pressure on the gingiva.

A proper surgery results in sufficient soft-tissue quantity and quality. However, too much soft tissue can be a hindrance in some prosthetic steps. If, for instance, the amount of soft tissue prohibits an intraoral scan because scan bodies are not long enough, conventional methods must be followed.

All-on-4 or all-on-five to -six?

The follow-up, which was up to six years later, showed a stable hard- and soft-tissue situation with no implant failure. The aesthetic outcome was also stable. These results are similar to those of All-on-4 procedures. The insertion of five to six implants better distributes forces and enables the extension of the prosthesis in case of future complications.

Angled implants were not an issue. We saw no need for long implants of more than 13 mm or angulated ones to enlarge the support polygon distally or the bone-to-implant contact. Since we also do not favour immediate function, regular lengths of at least 8 mm, even with sinus procedures, allowed us to easily reach and impress distal implants, relinquish or reduce counter levers. Implants of 8 mm in length do not show significant differences in long-term stability compared with longer implants. At the same time, very long implants, when extracted, lead to major defects, and if loaded under function immediately, can fail, requiring a re-do of all the planning and a re-make of the prostheses. Immediate loading requires at least a 40 Ncm insertion torque.

In such cases, co-axial implants are an interesting alternative, since abutments can be screwed on ortho-radially and aid prosthetic treatment. Yet, there are few manufacturers with such an implant-abutment connection, and the implants are of greater diameter. Our patients have lacked functionality and aesthetics for many years; waiting for another three months to receive the final prostheses has never been an issue. Modern implant surfaces such as the Type M implant seem to offer better and faster osseointegration (owing to the B+ surface; MIS Implants Technologies, which provides higher bone-to-implant contact), which allowed us to load them after eight weeks, compared with regular surfaces that are to be loaded after 12 to 16 weeks.

Implant design

Interesting findings were made on the radiographs after loading implants. Whereas implants with machined collars and no platform switching (Type B, Z and C implants) inserted in late defects tended to show a slight vertical bone loss after six to 12 months (establishment of a new biological width), bone level implants with platform switching (Type I and M implants) showed no similar findings, especially when inserted immediately or early.

A further difficulty encountered was the integration of older implants. These implants were often inserted to support removable prostheses carrying locator or telescopic crowns and were of small diameter or misplaced. All of these implants had to receive customised abutments.




Fig. 19: Example of a modern implant with platform switching and additional space for hard tissue.

Fig. 19

Conclusion

The use of screw-retained full-arch prostheses is fully integrated in everyday practice. They offer fixed solutions that are fast and economical compared with bars or cemented prostheses. The premises for treatment success are mainly that the replacement of the missing teeth must support lower face soft tissue and the hard-tissue defect vertically should not be major. The patient then receives a highly aesthetic full-arch reconstruction, with high functionality and long-term stability of the hard- and soft-tissue, in four to five appointments and within three to four months without the risks that accompany early or immediate loading. Combined with CAD treatment planning and intraoral scanning, the comfort of the treatment is enormous.

Materials used in this case report:

MIS Implants

V3 and C1 Implant Systems

Conical connection, multi-unit abutments

contact

Dr Nikolaos Papagiannoulis

Dental Esthetics
Hans-Böckler-Straße 2A
69115 Heidelberg, Germany
info@dentaesthetics.de
www.dentaesthetics.de

Author details



Rehabilitation of edentulous arches

The Double FiRe Bridge

Authors: Dr Marco Montanari, Claudio Sassatelli & Davide Nadalini, Italy

Implantology allows the restoration of missing or lost teeth by supporting fixed prostheses or anchoring removable prostheses. This has considerably expanded the possibilities of treatment and has allowed the patient to gain functional and psychological benefits and improved comfort, especially compared with conventional removable prostheses.¹ Every prosthetic rehabilitation aims to restore the stomatognathic apparatus, achieve satisfactory aesthetics—in harmony with the patient's face—and support soft tissue or compensate for loss.²⁻⁴ In this situation, it is of great importance to choose the type of prosthesis (fixed or removable) and the means of realising it.^{5,6}

The support of perioral tissue, lip mobility and the smile line are important parameters to take into account, because they affect the choice of the most appropriate prosthesis for the patient. Specifically, the relationship between the tooth profile and the volume of hard- and soft-tissue, which the prostheses must compensate for, gains particular significance in developing a treatment plan.^{2,5} For this reason, a complete patient analysis, which is not limited to intraoral examination, but includes extraoral (frontal and profile) aspects, such as the smile line, perioral tissue, muscu-

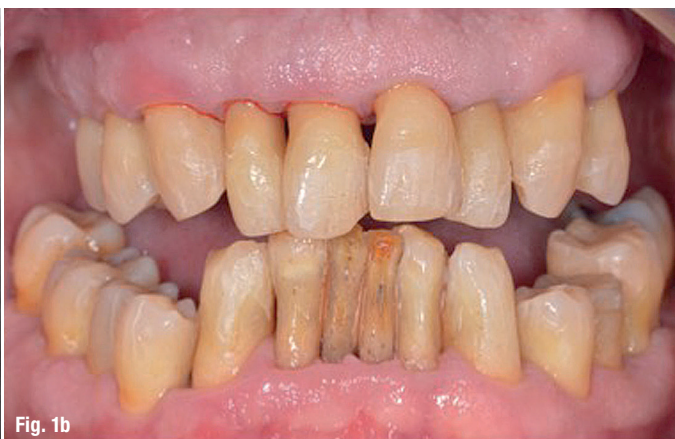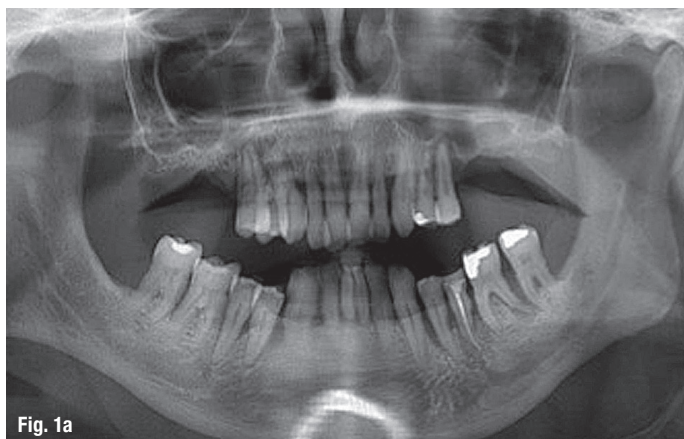loskeletal conformation, phonetics and hygiene habits, is of fundamental importance.

In cases of high crestal bone and gingival resorption, an implant-supported removable prosthesis is the obvious solution, since lost volumes can be supported by a prosthetic flange. This kind of prosthesis has the advantage of facilitating the patient's home oral hygiene, both of the framework and of the removable prosthesis itself, and gives the patient the feeling of wearing a fixed prosthesis.⁷ However, in cases in which there is good maintenance of hard- and soft-tissue and the profile appears correct, with good support of perioral tissue, a fixed prosthesis appears to be the best option.^{2,5}

Loss of hard tissue can be due to trauma, but it is more often due to periodontal problems that may lead to spontaneous tooth loss. Periodontitis is an infectious pathology that causes progressive resorption of the dental supporting structures (alveolar bone, periodontal ligament and root cementum), resulting in recession, deep periodontal pockets, tooth mobility, spontaneous gingival bleeding or bleeding on probing, and apical abscesses, ultimately resulting

Fig. 1a: Dental panoramic tomogram showing periodontal problems on both arches.

Fig. 1b: Intraoral photograph showing signs of generalised chronic periodontitis.



in loss of the teeth involved.⁸ In periodontitis, the normal balance between bacterial plaque and the immune defence is altered and this leads to imperfect regulation of the inflammatory response, resulting in increased marginal periodontal destruction.⁹⁻¹¹

When bone loss is consistent and makes it difficult or even impossible to place straight implants, it is possible to opt for tilted implants. The use of tilted implants allows the reduction of the distal cantilever and a better distribution of the forces.¹² In addition, the angle allows the use of longer implants, insertion of the implant into a better bone structure, and the preservation of noble anatomical structures, such as the mandible and the maxillary sinus.^{13,14}

When a masticatory load is applied to a cantilever, compression forces are exerted on the distal implants and traction forces on the anterior implants. The magnitude of these forces is directly proportional to the length of the cantilever.¹⁵ It has been shown that, with the insertion of four or six implants of the same length as the cantilever, forces acting on the most distal and anterior implants are comparable, allowing the simplification of the surgical procedures.¹⁵⁻¹⁷ The implant angle also reduces the compression load in the connective area between abutment and bar and does not induce bone crest abnormalities compared with straight implants.^{15,18}

In this article, the clinical situation of two male patients aged 66 and 67, respectively, are described, both of whom complained of mobility of residual teeth, periodontal problems, caries and poor aesthetics. The purpose of this article is to describe a new prosthetic protocol called DoubleFiRe (Fixed/Removable) Bridge, highlighting its functional, aesthetic and hygiene advantages. This protocol provides fixed rehabilitation of edentulous arches by the insertion of four tilted implants.

Case 1

The patient showed signs of generalised chronic periodontitis that involved most teeth in both the upper and lower arches (Figs. 1a & b). Since the maxillary sinus was greatly pneumatised, there was increased difficulty of implant placement and proper prosthetic design. The extraoral examination found a convex, divergent profile with good masticatory muscle trophism. The perioral tissue was maintained and the nasolabial angle was around 90°. After careful diagnosis and clinical data collection, a treatment plan was developed that would involve a fixed maxillary implant prosthesis and a mandibular overdenture attached to the canine roots (#33 and #43), and two implants inserted into the interforaminal area (#32 and #42).

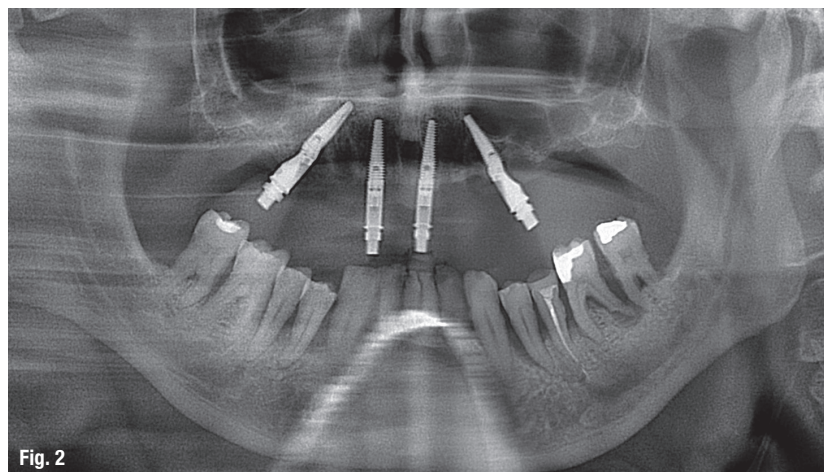


Fig. 2

Fig. 2: Post-op dental panoramic tomogram showing the positioning of the maxillary implants.

Surgical protocol

The surgical protocol entailed anaesthesia at the level of the entire upper arch with articaine with 1:100,000 adrenaline, and antibacterial prophylaxis was administered in the form of 875 mg of amoxicillin plus 125 mg of clavulanic acid provided one hour before surgery and continued every 12 hours for six days. The teeth were extracted as carefully as possible not to damage the postextraction sites. Subsequently, a full-thickness flap was performed to achieve better visual access to the surgical area. Four exterior hexagonal implants (4 × 13 mm; Co-Axis 12 and 24°, Southern Implants) were placed in regions #15, 12, 21 and 24 (Fig. 2). Distal implants were angled to minimise the distal cantilever and to improve transmission of the masticatory load. The maxillary implants were placed at a torque reaching over 40 Ncm in order to follow an immediate loading protocol. At the end of the surgical procedure, suturing was performed using 4/0 silk.

Prosthetic protocol

At the end of the operation, a polyether polyurethane impression (Impregum Penta, 3M ESPE) was taken, after bounding the impression copings with dual composite for greater precision. After 24 hours, the patient was provided with a fixed maxillary provisional prosthesis in acrylic resin with a cobalt-chromium internal reinforcement to have greater rigidity of the structure and better distribution of the load between the implants. The provisional was screwed directly to the fixture without the interposition of a multi-unit abutment owing to the geometry of the implants used. They have an angled prosthetic connection from the longitudinal axis, and this provides the possibility of correcting divergences. A lateral cephalometric radiograph confirmed the exact position of the prosthetic incisors from the alveolar crest, highlighting that the fixed rehabilitation was the best choice in this case (Fig. 3).

Owing to the marked angulation of the distal implants, it was possible to reduce the cantilever and

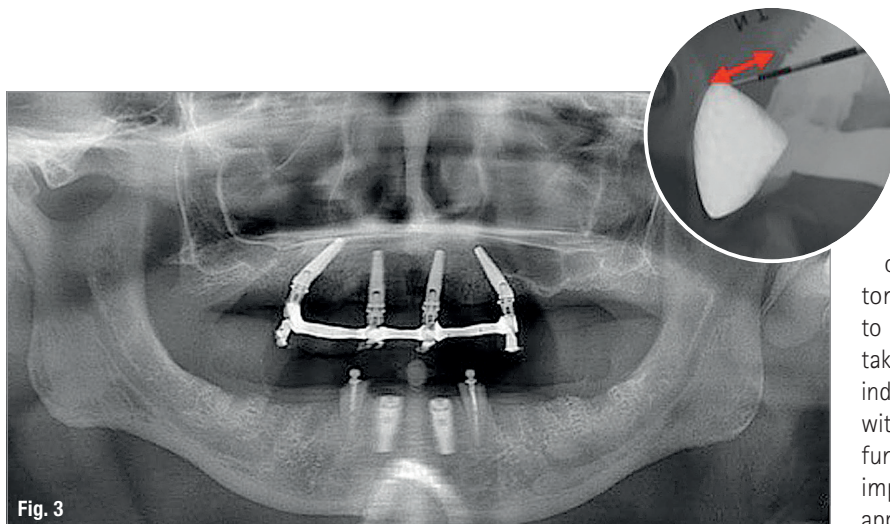


Fig. 3

Fig. 3: Dental panoramic tomogram after seating of the temporary prosthesis.

avoid a regenerative maxillary sinus lift. Furthermore, owing to the peculiar connection of the Co-Axis implants, it was possible to handle the prostheses as if these implants were placed parallel. On the same day of the provisional prosthesis delivery, the mandibular teeth were extracted. Only #33 and #43 were preserved because they were found to be stable and to exhibit no caries or periodontal pathologies (Fig. 4).

A removable prosthesis, anchored with wire hooks to the mandibular canines, was delivered to the patient as a temporary prosthesis during osseointegration time and healing of the hard- and soft-tissue. After a few weeks, two cylindrical implants were inserted in regions #32 and 42 (PrimaConnex, Keystone Dental) and were left covered by the soft tissue for four months. During this period, the two mandibular canines were endodontically treated, sectioned at the gingival level to reduce the crown-root ratio, and two titanium pivots with normal-size spheres (Pivot Block, Rhein'83) were cemented in order to improve retention of the temporary prosthesis and, later, of the definitive prosthesis.

Fig. 4: All teeth except for #33 and #43 were removed.

Fig. 5: Two implants were inserted in regions #32 and 42 and two spherical attachments were inserted to support and anchor a removable prosthesis.

Fig. 6: At the upper arch level, the cuff height was evaluated and the correct OT Equator low-profile attachments were screwed on.

Definitive prosthetic rehabilitation

Four months after surgery, the mandibular implants were uncovered and, after evaluation of the cuff height, two Sphero Blocks with normal-size spheres (Rhein'83) were screwed on (Fig. 5). At the upper arch level, four OT Equator attachments (Rhein'83, Fig. 6) were screwed on to the implants, and an alginate impression was taken to produce the individual impression trays. The individual impression tray was adequately edged with thermoplastic paste (ISO FUNCTIONAL, GC) and functionalised. Subsequently, polyether precision impressions (3M ESPE) were taken, using the appropriate pick-up impression coping for the maxillary OT Equator attachments and for the mandibular spheres.

After pouring of the pink silicone into the impressions to reproduce the gingival portions, the master model was poured in extra-hard plaster (Class IV). The dental technician then made a wax rim with a resin base in order to determine the maxillary relationship with the facial arch (Artex, Amann Girrbach). The correct height of the maxillary wax rim in the frontal area and the parallelism with the ala-tragal line (corresponding to the occlusal plane) and with the bi-pupillary plane were determined using the Fox plane (Candulor). The wax rim was held firmly by three retentive caps that were connected to the low-profile attachments in order to facilitate masticatory detection, median line recording, smile show and canine position without using an adhesive paste. The rim, once returned to the laboratory, allowed setting up of the models in the articulator. After the references had been taken with the wax rims, the tooth set-up was done (Acry Plus EVO, Ruthinium). An aesthetic try-in was then done, paying particular attention to phonetics.

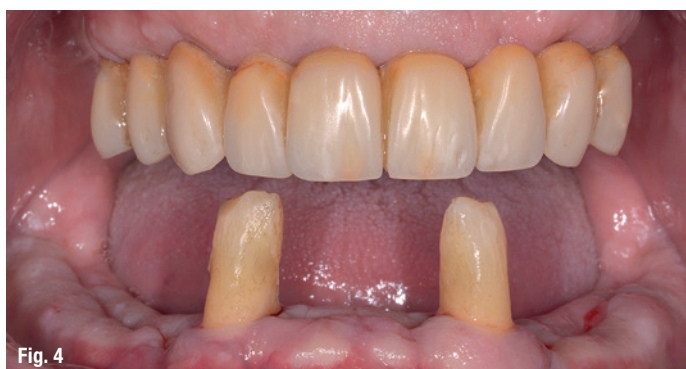

Fig. 4

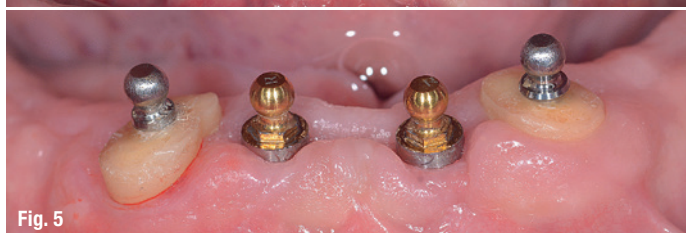

Fig. 5

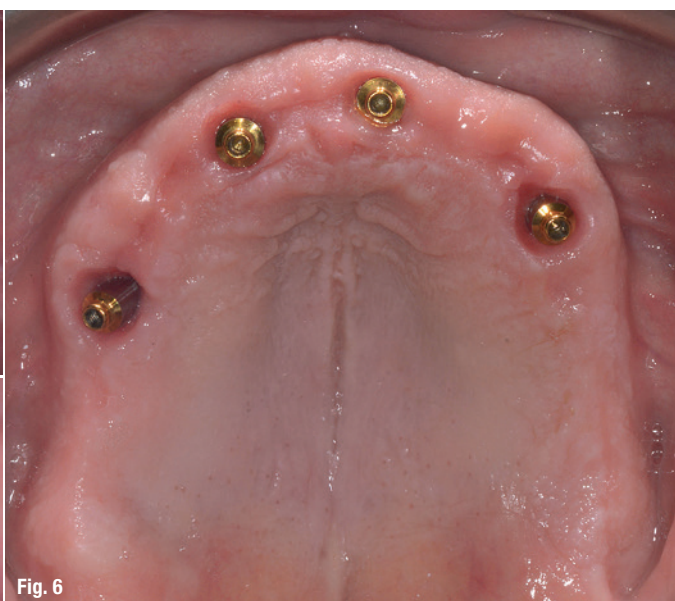

Fig. 6



neo

THE NEXT SENSATION

by Alpha-Bio Tec.

 | www.alpha-bio.net/neo



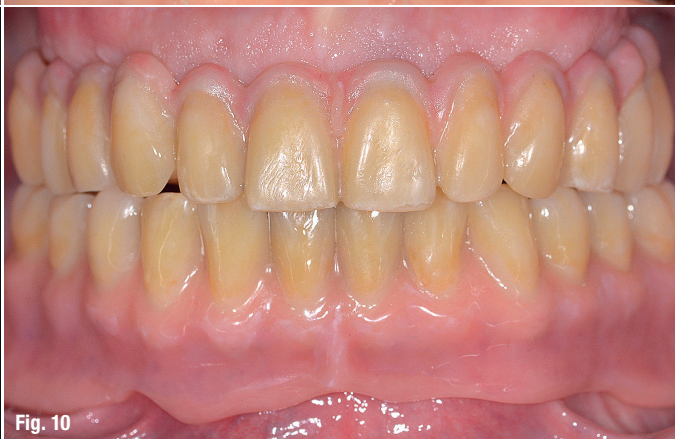
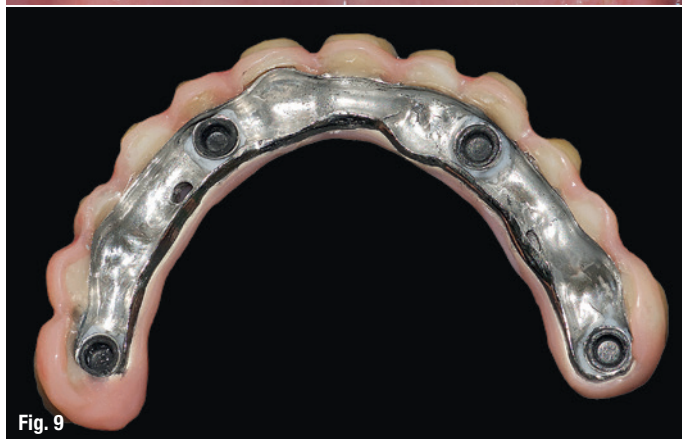
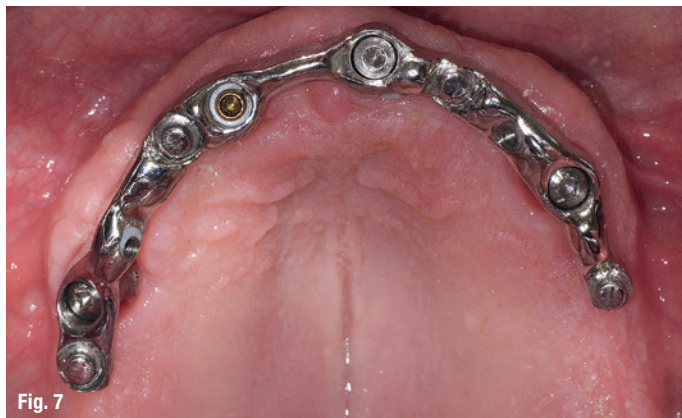
Fig. 7

Fig. 8

Fig. 9

Fig. 10

Fig. 7: Primary bar anchored to low-profile OT Equator attachments by means of Elastic Seeger rings, whose function is to anchor the structure passively.

Fig. 8: The primary bar was assembled with castable material and subsequently cast in cobalt-chromium.

Fig. 9: Secondary structure anchored on the primary structure via OT Equator attachments and palatine screws.

Fig. 10: Delivery of the prostheses, which showed good harmonisation with the surrounding tissue and good aesthetics.

The assembly try-in provided a general appearance that harmonised well with the physiognomy of the patient by providing a proper profile and aesthetics. After the assembly had been correctly done, the prosthetic volumes were evaluated while searching the available spaces for the reinforcement structure, both for the maxillary fixed prosthesis and the removable mandibular prosthesis. The Double FiRe Bridge protocol implemented in the present study entailed the construction of a primary bar anchored to low-profile OT Equator attachments using acetal rings called Elastic Seeger (Rhein'83), capable of blocking the whole structure by creating a functional and solid connection with guaranteed passivity.¹⁹ Above each attachment, a cover screw was placed to increase the contact of the Elastic Seeger rings on the walls of the bar by improving the anchorage (Fig. 7).

On the occlusal surface, the bar had some OT Equator attachments that would allow a superstructure to be anchored if the clinician decided to turn the fixed prosthesis into a removable one. The primary bar, once cast, had two threads at the palatine level to which it was possible to attach the fixing screws for the secondary structure positioned above, thereby transforming the prosthesis into a fixed one (Fig. 8). The overlying secondary structure was precisely fitted on the primary bar and assembled according to the dentition tested during aesthetic and phonetic testing (Fig. 9). For the mandible, a cobalt-chromium

reinforcement structure was cast, which had to be applied inside the containers on the spherical attachments for the retentive caps.

The definitive prosthesis was completed and characterised with colour stains to mimic the keratinised gingiva and dental discolorations to improve mimicry. In addition, the medial frenulum and the alveolar nerve were formed for a more natural look. The maxillary and mandibular prostheses were then delivered and showed proper harmony with the surrounding tissue and good aesthetics provided both by the features of the teeth and flange and by the absence of occlusal access holes for the screws, commonly present in fixed screw-retained prostheses (Fig. 10). The final dental panoramic tomogram showed correct fitting of the prostheses, correct adjustment of the maxillary bar and excellent maintenance of the peri-implant bone. The lateral cephalometric radiograph showed the close relationship between the base of the prosthetic central incisor and the implant neck to indicate how, in this case, fixed restoration was the best possible solution from an aesthetic and functional point of view (Figs. 11a & b).^{2,5}

Case 2

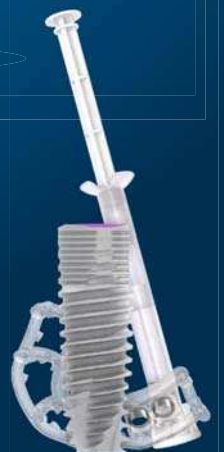In the second case, a 67-year-old patient with multiple caries and periapical lesions of both maxillary and mandibular teeth was treated. The patient had a



INSPIRING SPEAKERS. BREATHTAKING VIEWS MAKE IT SIMPLE

MIS is proud to introduce the Global Conference Speakers Team: • Yuval Jacoby • Ignacio Sanz Sánchez • Vincent Fehmer • Emilio Arguello • Eric Van Dooren • Galip Gürel • Mauro Fradeani • Christian Stappert • Myron Nevins • Joseph Kan • Edward P. Allen • German O. Gallucci • Lesley David • Stefan Koubi • Leila Jahangiri • Carlo Marinello • Ariel J. Raigrodski • Mirela Feraru • Tali Chackartchi • Tommie Van De Velde • Pablo Galindo-Moreno • Stavros Pelekanos • Juan Arias Romero • Víctor Clavijo • Anas Aloum • Gustavo Giordani. To learn more about the conference visit: www.mis-implants.com/bahamas

MIS[®]



skeletal Class III malocclusion with an inverse relationship of the arches, as evidenced in a lateral cephalometric radiograph (Fig. 12). After careful diagnosis and clinical data collection, it was decided on a treatment plan that included a removable implant-supported maxillary prosthesis and a fixed implant-supported mandibular prosthesis. On the day of surgery, anaesthesia was performed with articaine with 1:100,000 adrenaline, and all of the maxillary and mandibular teeth were extracted. In the maxilla, four tilted implants (M-Series [Internal Hex], Southern Implants) were inserted to reduce the distal cantilever and improve distribution of the masticatory load. Four tilted implants (M-Series [Internal Hex], Co-Axis 12°) were inserted in the mandible, with the most distal ones having an angled connection of 12° from the main axis of the fixture (Fig. 13).

Since implant stability exceeded 50 Ncm, it was decided to apply an immediate loading protocol. Standard spherical attachments (Sphero Flex, Rhein'83) were screwed on the implants, and two temporary removable prostheses were provided. As a result of the divergence in the upper arch, the prosthesis was anchored only to the two most mesial fixtures, while in the lower arch, where Co-Axis implants were used, it was possible to anchor the prosthesis to all of the implants, because the connections, and consequently the spherical attachments, were almost parallel to each other.

Definitive prosthetic rehabilitation

After four months, the maxillary distal implants were uncovered and OT Equator attachments were mounted on all fixtures (Fig. 14). Subsequently, alginate and polyether impressions were taken to complete the master model as described in the first case of this article. The maxillary relationship was recorded with the wax rim and the teeth were set up (Acry Plus EVO) to perform the aesthetic and phonetic tests. After the set-up had been checked, a cast bar with OT Equator attachments was designed to support the definitive removable maxillary prosthesis (Fig. 15). The bar was anchored to the OT Equator attachments by interposing Elastic Seeger rings, which guaranteed the passivity of the entire structure and the creation of a stable connection.¹⁹

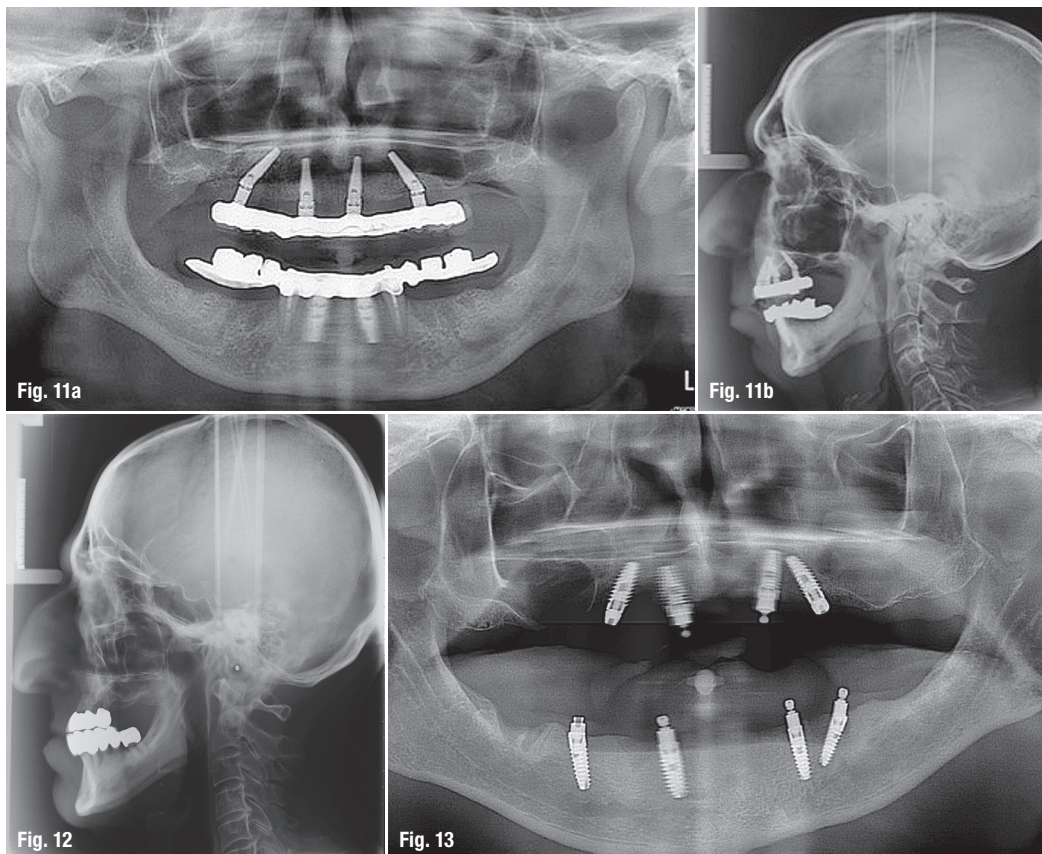
A fixed prosthesis was realised in the mandible, consisting of a double structure (primary and secondary) anchored to the underlying implants, using OT Equator abutments and inserting Elastic Seeger rings for guaranteed passivity (Fig. 16). Four cast OT Equator attachments were located on the occlusal surface of the bar to allow a superstructure anchor should the clinician decide later to turn the fixed prosthesis into a removable one. On the lingual surface, however, there were two fixing screws, which enabled the prosthesis to be transformed into a fixed device by screwing on the overlying secondary structure, in which the teeth were present (Fig. 17). A radiograph

Fig. 11a: Final dental panoramic tomogram.

Fig. 11b: Lateral cephalometric radiograph.

Fig. 12: Lateral cephalometric radiograph showing a skeletal Class III malocclusion with an inverse relationship between the arches. The poor support of the perioral soft tissue can be observed.

Fig. 13: Post-op dental panoramic tomogram showing the positioning of the maxillary implants, with the distal ones tilted to reduce the cantilever.



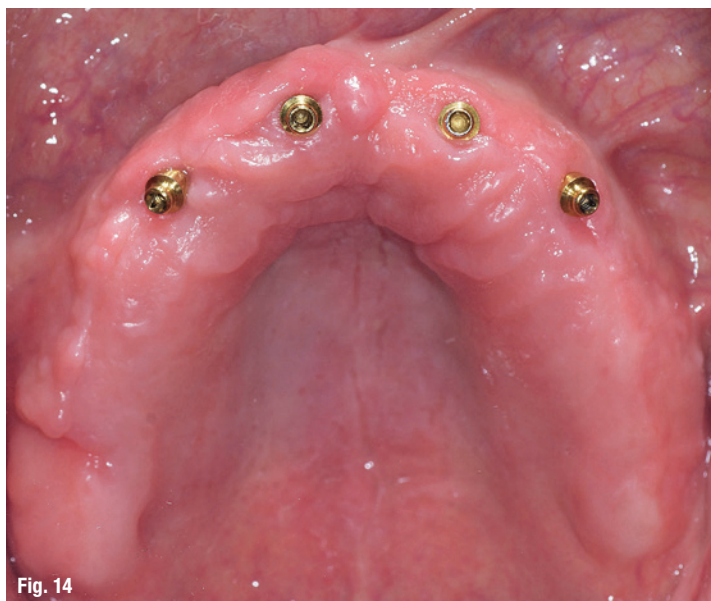


Fig. 14

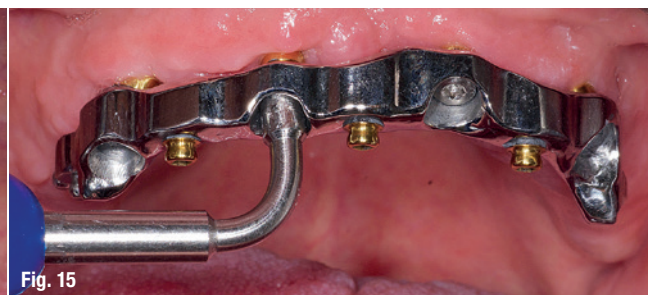

Fig. 15

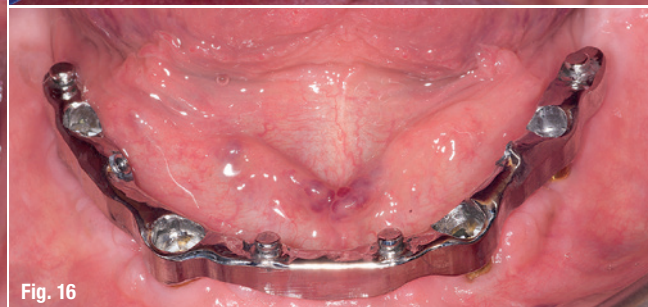


Fig. 16

of the sagittal plane (Fig. 18) confirmed the position of the central incisor of the definitive prosthesis in relation to the alveolar ridge, highlighting that removable rehabilitation was the best choice in this case.

Owing to bone resorption in the maxilla, typical of patients with a skeletal Class III malocclusion, it was necessary to place the anterior teeth further in order to provide a Class I ratio. The final result (Fig. 19) confirmed the excellent aesthetics achieved in both the maxilla and the mandible and the harmonisation with the surrounding tissue. It can also be noted that choosing a higher and lower fixed-removable prosthesis associated with proper assembly made it possible to restore occlusion by creating an occlusal Class I. A fixed maxillary prosthesis would have resulted in the creation of a non-harmonious profile, owing to poor lip support and a retracted maxilla. Additionally, we would have created a very difficult area for the patient to clean; indeed, food residues would have easily accumulated in such an area. The insertion of a flange, however, allowed the restoration of a correct Class I profile with good support of perioral tissue and proper occlusion.

Discussion

Loss of teeth and, consequently, of the supportive tissue necessitates restoration with a prosthesis to restore masticatory function and satisfactory aesthetics. Implantology, in this sense, has considerably expanded therapeutic possibilities by allowing fixed or removable prostheses based on the patient's need.^{1,20} Since in the pathogenesis of periodontitis, there is poor hygiene control, it is important to educate the patient on following a good home hygiene routine and perhaps to propose a therapeutic solution for easy maintenance from a hygiene point of view.²¹

Preserving some roots and using them as anchorage allows the reduction of treatment costs, and provides a number of benefits. The maintenance of the periodontal ligament plays an important role in reducing maxillary resorption. In addition, the maintenance of proprioceptors and mechanoreceptors allows the masticatory system to safeguard the sensory feedback that regulates motor response. Sectioning the remaining teeth at the level of the gingival margins decreases the crown-root ratio, stabilises the tooth and improves the prognosis.²²

Bone loss caused by periodontitis may not allow the insertion of implants in some sites. In order to overcome this disadvantage, a viable therapeutic possibility is the insertion of tilted implants as an alternative to complex regenerative surgeries, which are expensive and not immune to morbidity.^{23,24} In fact, distal angled positioning allows the insertion of longer implants in areas with better bone quality, respects the noble structures (such as the inferior alveolar nerve or maxillary sinus) and reduces the cantilevers by better distributing occlusal forces.^{15,16} The cantilever reduction is responsible for lower flexion of the load-bearing bar and less stress in the abutment-bar connective area.¹⁴ In order to design the cantilever measurement, it is important to evaluate the distribution of the implants in the arches.

An anterior-posterior spread (AP spread) is defined as the distance between the line joining the distal edges of two rear implants with the centre of the more mesial implant. The AP spread is influenced by the shape of the arch: a triangular or elongated shape is associated with a favourable AP spread, while a square shape is unfavourable. A restoration on multiple implants to which a load is applied can be considered a Class I lever, in which the extension of the pros-

Fig. 14: At the upper and lower arch level, peri-implant cuff height was evaluated and the low-profile OT Equator attachments were screwed on.

Fig. 15: Maxillary cast bar with OT Equator attachments to anchor the definitive removable maxillary prosthesis.

Fig. 16: Fixed prosthesis consisting of a double structure.

thesis from the last pillar represents the power arm, the last implant acts as a fulcrum, and the AP spread represents the strength arm. When a force acts on a cantilever zone, force transmission occurs in the underlying systems in two different ways: compression on the most distal implants and traction on the more mesial ones.²⁵

The literature demonstrates how, by applying a load to a prosthetic arch supported by four or six implants, there are no stress differences at the fixtures if the more mesial and more distal implants are placed in the same respective locations.^{12,15} Although tilted implants show a higher concentration of stress at the bone-implant interface, the literature shows that there are no statistically significant differences in peri-implant bone loss when compared with vertical implants.^{13,24} In the present study, the insertion of tilted implants enabled implanting of the implant neck in a more distal position compared with an implant positioned vertically.

With Co-Axis implants, the angled connection from the longitudinal axis represents a valuable aid in correcting divergences and allowing more appropriate prosthetic positioning for the case. The ability to insert low-profile OT Equator attachments from the beginning without having to remove these during subsequent prosthetic phases is of remarkable biological benefit because it avoids damage to the epithelial ligament and the circumferential connective fibres around the implant neck. This achieves a biological seal and plays a key role in preventing and avoiding propagation of infections to the deep supportive tissue.²⁶

When connecting the implants through a bar, passivity of the structure is a problem, since tension can be transmitted to the implants and lead, in par-

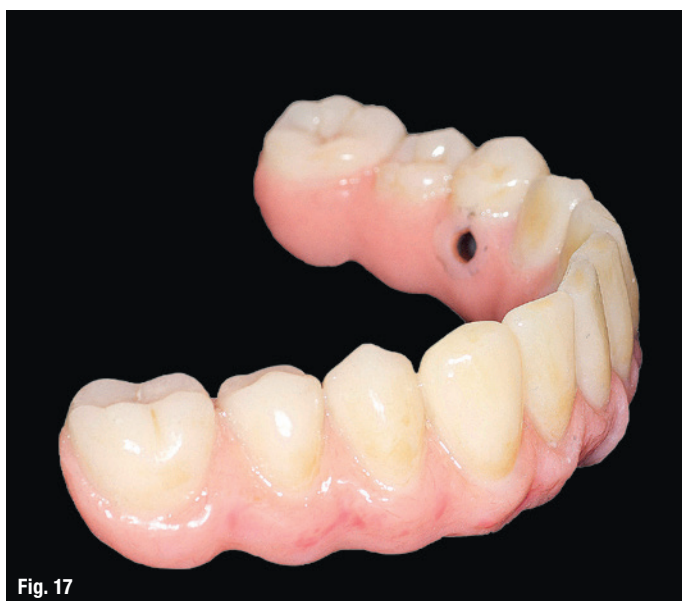ticular, to incorrect fitting of the prosthesis and implant failure.²⁷ In order to achieve a bar with good passivity, several try-in tests with the patient are required, and corrections are not always easy. In the present study, the passivity of the bar was obtained by inserting Elastic Seeger rings between the bar and the OT Equator attachments. This device overcomes the equator of the attachment and compensates for the space between the bar and the attachment itself, creating a solid connection with the guarantee of absolute passivity.¹⁹

The tolerance between the bar and OT Equator attachments is intended to compensate for the small inaccuracies that can arise between impression taking and plaster casting. The function of the screw is to improve the contact of the Elastic Seeger rings on the walls of the bar by improving its anchorage. Musculoskeletal analysis showed that the patients treated did not fall into the brachycephalic class in which the masticatory load is very high. This analysis appears to be very important during the prosthetic design because it is directly related to the occlusal load exerted on the implant-prosthesis structure.²⁸

In Case 2, it was possible to perform immediate loading of the two maxillary anterior implants by inserting retentive caps with a gummy consistency and capable of anchoring the prosthesis to the spherical attachments and acting as a shock absorber. This allowed the distribution of the masticatory forces to the ridges, avoiding the overload of the two implants. In order to achieve this, however, the temporary prosthesis had a full palatal flange in order to have all the possible support on the palate, a non-compressible area, that provides support in the distribution of the occlusal load and improves retention and prosthetic stability.

Fig. 17: Lingual surface of the prosthesis; screw holes allowed the prosthesis to be transformed into a fixed device by screwing on the overlying structure bearing the teeth.

Fig. 18: The lateral cephalometric radiograph confirmed the position of the central incisor of the definitive prosthesis in relation to the alveolar ridge.



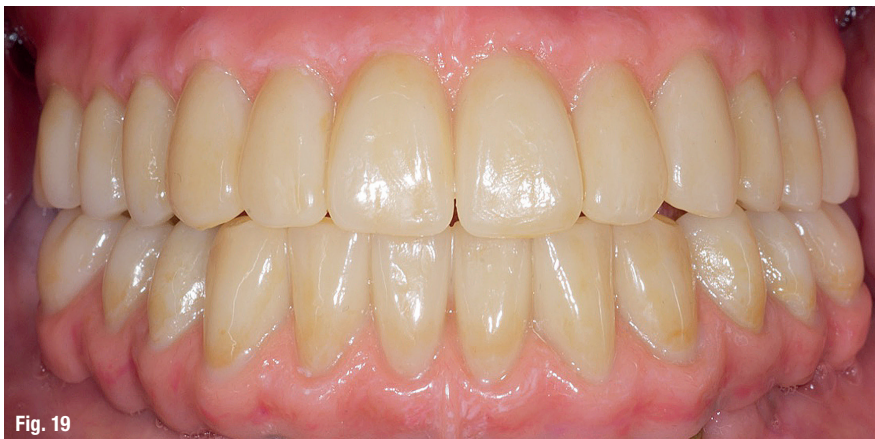


Fig. 19

Fig. 19: Final result.

The Double FiRe Bridge protocol

The Double FiRe Bridge protocol implemented has several advantages:

- an aesthetic advantage, because there are no holes in the occlusal surface for screws;
- a functional advantage, because the clinician can decide at any time to switch from a fixed prosthesis to a removable one (or vice versa);
- a hygiene advantage, because the structure offers good maintenance and can be checked with greater simplicity.

By using the Double FiRe Bridge protocol, it was possible to combine aesthetics, structural passivity, hygiene and functionality in one prosthetic rehabilitation by solving some problems that may be encountered with conventional full-arch fixed restoration. Furthermore, the use of tilted implants allowed the reduction of the cantilever of the structure, despite the greatly pneumatized maxillary sinuses, and allowed improved transmission of the masticatory load. The characteristic of having an angled connection from the implant's main axis enabled the divergence to be solved immediately, giving the freedom to tilt the implants even more. In this way, it is possible to apply the cantilever protocol in a simpler and faster way without the interposition of additional prosthetic components.

In the Double FiRe Bridge protocol, the prosthesis consists of two structures (a primary structure and a secondary superstructure), solidly joined together owing to the insertion of two palatine locking screws. Following this workflow, it is possible to provide the patient with a fixed solution that can be converted into a removable device if neces-

sary by simply removing the palatine/lingual fixing screws, if the patient's hygiene maintenance is poor or if better support of the soft perioral tissue is necessary. This protocol is also helpful for the case in which the patient asks to first try a fixed prosthesis and then to eventually switch to a removable one (or vice versa). Having two structures locked together by lingual fixing screws also eliminates occlusal access holes, providing obvious aesthetic and structural advantages. In addition, the ability to quickly and easily remove the prosthesis during check-ups allows for more careful and accurate follow-up of the patient and therefore provides a longer-lasting rehabilitation through it being more easily inspected.

The protocol implemented in the present study proved to be a successful therapy and its association with the use of OT Equator and Elastic Seeger technology simplified the clinical and dental engineering procedures by reducing the treatment time and combining the benefits of a fixed prosthesis and a removable prosthesis within the same rehabilitation.

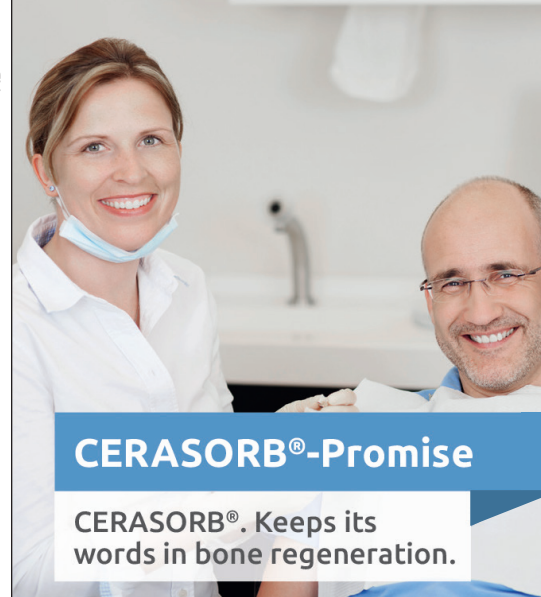contact

Dr Marco Montanari
Viale Risorgimento, 244/A
47121 Forlì, Italy
Tel.: +39 0543 68910

Author details



Literature



CERASORB®-Promise

CERASORB®. Keeps its words in bone regeneration.



CERASORB® M

- + big and microporous surface increases osteoconductivity
- + shortened duration of resorption by fast penetration with body own bone supporting structure



CERASORB® Foam

- + easy handling thanks to defect-adapted modelling and comfortable positioning

CERASORB® – Always First Choice.

Manufacturer:
curasan AG
Lindigstrasse 4
63801 Kleinostheim
Germany
cerasorb@curasan.de
www.curasan.de

curasan
Regenerative Medicine

Trefoil™ the next full-arch revolution

A revolutionary fixed solution to treat more patients better.


Leading in immediate solutions

By challenging existing treatment methods we aim to drive efficiency and make high-quality treatment a viable choice for more patients.

THE FIRST PRE-MANUFACTURED BAR WITH PASSIVE FIT

The ingenious fixation mechanism is a breakthrough in treating the edentulous mandible.

Anatomically designed for the natural arch of the lower jaw, the standardized bar contains adaptive joints that adjust to compensate for horizontal, vertical and angular deviations from the ideal implant position.



Angular deviation
 $\pm 4.0^\circ$

Horizontal deviation
 $\pm 0.4 \text{ mm}$

Vertical deviation
 $\pm 0.5 \text{ mm}$

PATENT PENDING FOR FIXATION MECHANISM

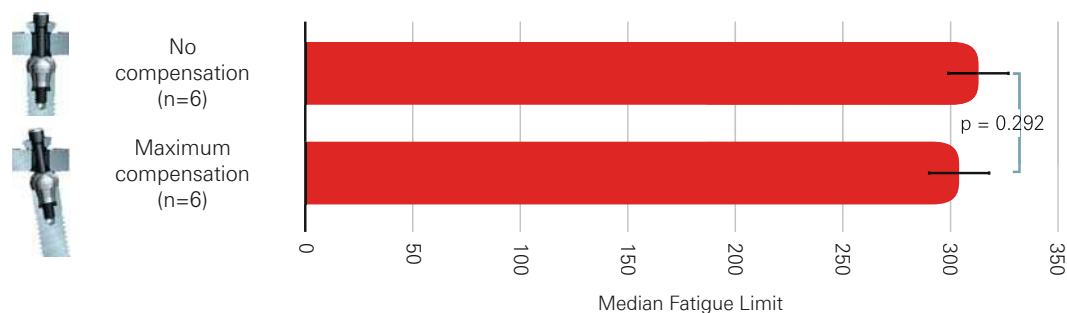
Each mechanism has five self-adjusting joints that help correct the position of the pre-manufactured bar, enabling the passive fit of the definitive prosthesis.



PATENT PENDING for fixation mechanism

PROVEN STRENGTH WHEN PUSHED TO THE LIMIT

The Trefoil system maintains its strength when pushed to the extreme of its compensation capability. In fact, tests¹ prove almost no difference in fatigue limit between the maximum compensation configuration and the configuration without compensation.



1. Carretta R, Geisendorff M, Spinnler A, Heuberger P, Higuchi KW, Brunski JB. A Novel Prefabricated, Final Fixed Solution for the Edentulous Mandible. J Dent Res 96(Spec Iss A):3348, 2017 (www.iadr.org).
2. Clinicaltrials.gov. The TREFOIL concept 5-year clinical investigation (NCT02940353). <https://clinicaltrials.gov/ct2/show/NCT02940353>. Accessed June 22, 2017.

DEFINITIVE TEETH IN ONE DAY*

The Trefoil system is a cost-efficient solution that allows Immediate Function and makes fixed and definitive teeth on the day of implant surgery* an option for more patients.

Shorter time-to-teeth:

The Trefoil system enables a fixed and definitive prosthesis to be placed up to six months earlier than conventional treatments with provisional prosthetics.

Trefoil™

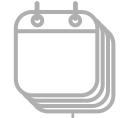
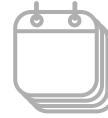
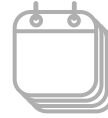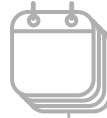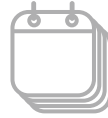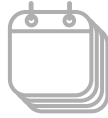Implant placement and fixed definitive restoration in one visit*.

FIND OUT MORE

Discover the detail behind this revolutionary full-arch solution:
nobelbiocare.com/trefoil

Conventional treatment



Implant placement: implant and provisional denture are placed.

3-6 MONTHS

Fixed and definitive restoration is placed

*Depending on clinician preference and close cooperation with the laboratory.

STRAIGHTFORWARD PROSTHETIC WORKFLOW

Substantial time savings for the restorative clinician and the lab.

The restorative workflow is simplified thanks to the use of the pre-manufactured bar. An experienced clinician and lab will require approximately six hours of active working time to do the treatment.**

LAB
3 hours



PROTHODONTIST

1 hour

**6
HOURS**



SURGEON

2 hours

**The comparison above demonstrates possible treatment methods with approximate treatment times.

ALREADY BACKED BY CLINICAL RESEARCH²

The Trefoil system is the focus of an ongoing five-year, multi-center study², taking place across four continents, that began in 2015. Positive results are already being reported for implant and prosthetic survival rates.

**5
YEARS**

**4
CONTINENTS**

**110
PATIENTS**



Dr. Kenji Higuchi,
United States



Dr. Rubén Rosenberg,
Chile



Prof. Dr. Massimo Albanese,
Italy



Dr. Glen Liddell,
Australia



Dr. Rubén Davó,
Spain

Digital workflow: From planning to restoration

Authors: Jan Kielhorn, Siegfried Hoelzer & Björn Roland, Germany

High-quality treatment results that are individual to each patient can be drawn up for the edentulous jaw in the combination of innovative procedures for implant surgery and reasoned prosthetic concepts. In this article, the authors describe the digital workflow for the tried-and-tested immediate restoration concept SKY fast & fixed and discuss the possibilities of transverse screwing, amongst others.

of accuracy. High-precision results can be achieved in an efficient manner by combining the digital production of the superstructure. In addition to digital know-how, proven fundamentals are promising factors. This includes patient compliance, a sound dental and dental technical knowledge, surgical and manual skills, the perfect materials and products and close consultation within the treatment team. On the basis of this, modern computer-guided procedures offer an optimum basis for re-interpreting tried-and-tested implant prosthetic concepts such as the SKY fast & fixed (bredent medical). This article shows the digital workflow using a patient case as an example.

Introduction

Digital technologies help simplify the process involved in implantology and often accelerate the process, whilst at the same time offering a high level

Fig. 1: Transverse screwing: the thread for the bolt screw is located in the bridge framework. The bolt screw (A) and the cylindrical surfaces (B and C) form a unit. The prosthetic coping is fixed as a three-point fixation using the bolt screw and the short cylindrical surfaces. Due to the short cylindrical surfaces, the coping locks itself once attached.

Figs. 2 & 3: Initial situation: conventional X-ray measurement (two-dimensional) and situation model.

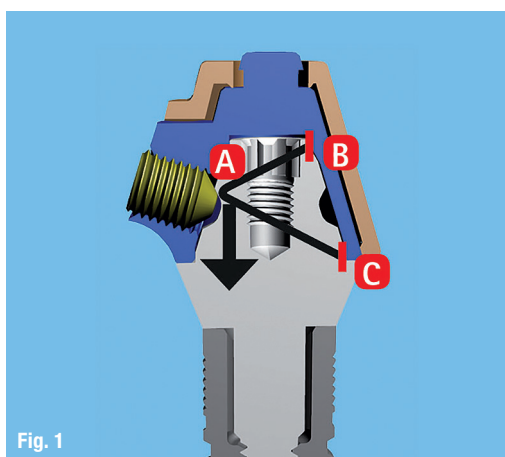


Fig. 1

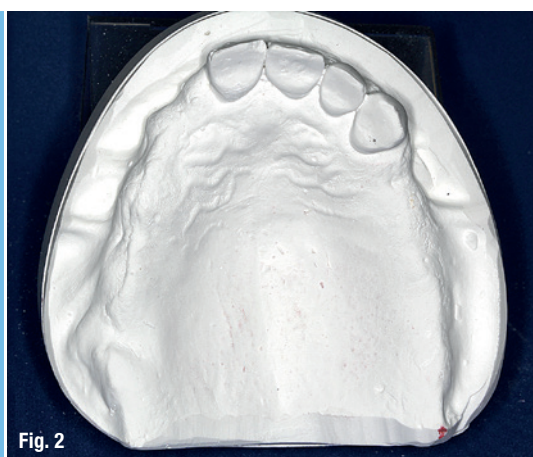

Fig. 2

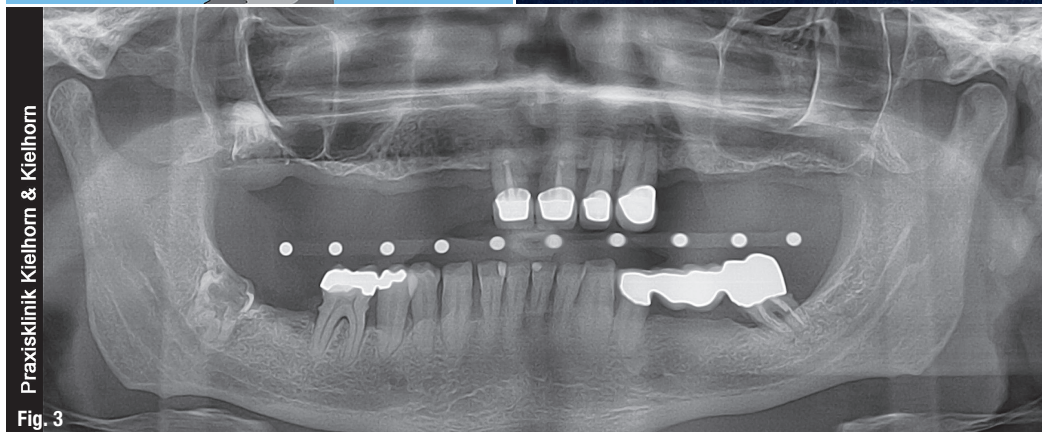


Fig. 3

Praxisklinik Kielhorn & Kielhorn

Anchoring

The “fixed” treatment option has become important for edentulous jaws and jaws that are becoming edentulous. Many patients state that they are not satisfied with the classic removable total prosthesis; in particular, if they lose the last few teeth they still have. They want an aesthetic, functional implant prosthetic restoration. However, areas of limitation, such as sub-optimal anatomical circumstances, are often encountered. In order to be able to avoid bone augmentation, measures where possible in these cases, as well as problematic implant positions and limited aesthetics, suitable implant prosthetic solutions are sought. The SKY fast & fixed concept is one of those.

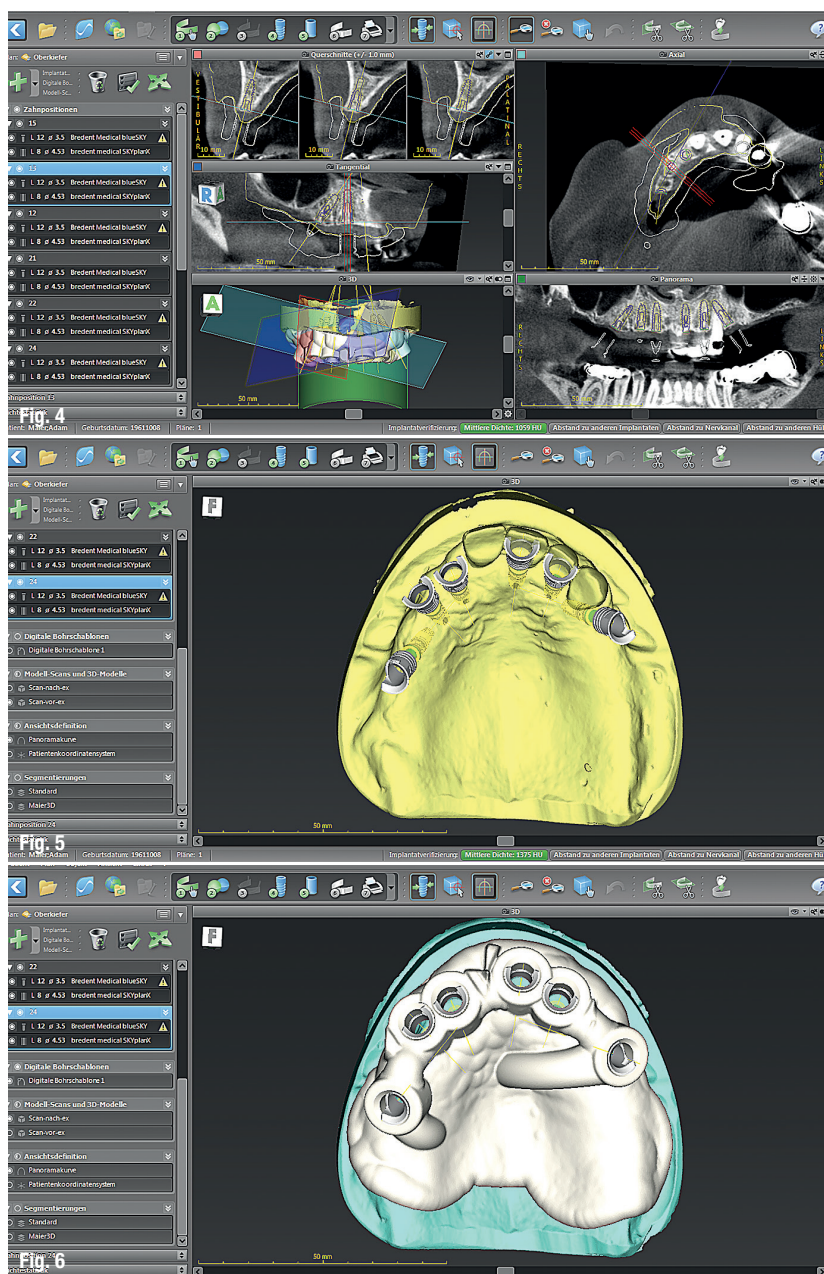
In principle, a distinction is made between screwed and cemented prostheses in fixed implant prosthesis. In an edentulous jaw, we generally prefer a screwed reconstruction. In contrast to cementing, the main benefit is the fact that the restoration can be removed from the implants without problems. For example, if an abutment were to loosen or a repair be required, the restoration can be carried out with ease. What is more, hygiene measures are simplified, which is an important aspect, particularly with regard to professional implant aftercare.

The treatment concept

In the SKY fast & fixed therapy, the implants are inserted in the local bone in such a way that they can be restored immediately after insertion with a fixed temporary bridge. Osseointegration is supported by means of primary interlocking. In order to be able to insert the implants into the jaw without augmentation measures where possible, meticulous preoperative investigations and an implant component especially designed for use in this situation are pre-requisites. This objective can generally be achieved by means of angled insertion of the posterior implants. The immediate temporary restoration is guaranteed by means of screwing onto the implants, resulting in stable interlocking. The pre-fabricated interim restoration is made from plastic. Due to the relatively low elasticity module, the load application on the implants can be cushioned during the healing phase. Following successful osseointegration, several prosthetic configurations lead to the desired result. The primary requirement of the restoration is the tension-free fit on the implants.

Transverse screwing

Due to the type of screwing of the dental prosthesis, a choice can be made between two variants in the described concept. In addition to occlusal screwing, a bonding element is also offered for the transverse (horizontal) screwing. This offers an aesthetic benefit



in many situations. Orthograde screwing—screw channel emerging occlusally, often especially means a compromising solution in the anterior region in terms of aesthetics. The seal of the screw channel in the visible region of the front teeth limits the dental technician with regard to the aesthetic design. Adequate alternatives include normal bonding elements in the region that is not visible.

The SKY fast & fixed abutment with horizontal circumferential groove is available for this and is restored using a pre-fabricated transverse screwed coping. This type of screwing involves bolting in the true sense of the word. The thread for the bolt screw is located in the bridge framework. The bolt screw and the cylindrical surfaces form a unit (Fig. 1). Fixation is carried out as three-point fixation, which prevents tilting. Thanks to

Fig. 4: Three-dimensional planning of six implants, based on a DVT.

Figs. 5 & 6: Digitalised situation model (STL): determining the drill template design.

Figs. 7 & 8: The drilling template and the pre-fabricated temporary restoration with palate for optimum positioning.

Fig. 9: Inserted implants with the corresponding superstructures for the SKY fast & fixed concept.

Fig. 10: Long-term temporary restoration with target fracture sites in front of the intraoral adhesion and lining.

Fig. 11: Bridges screwed onto the implants (long-term temporary restoration following removal of the palate) for immediate restoration.

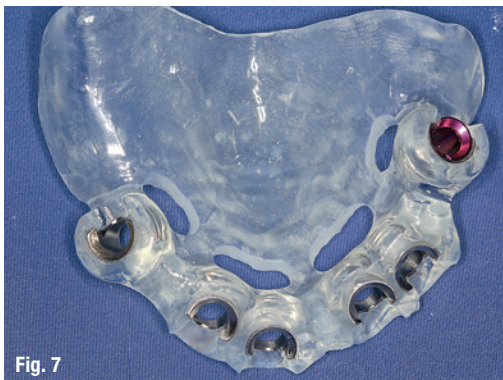


Fig. 7

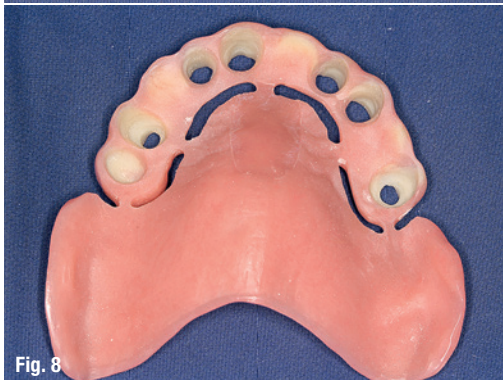

Fig. 8

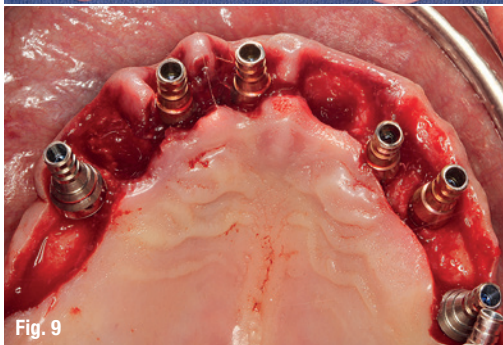


Fig. 9

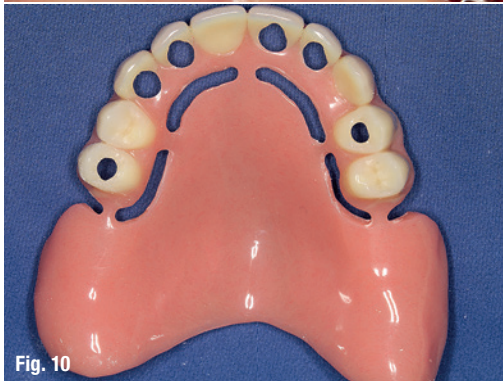

Fig. 10

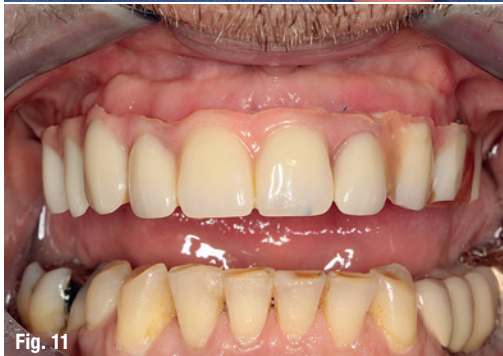

Fig. 11

the slightly inclined position of the bolt screw, the prosthetic coping is “pressed” onto the abutment platform without showing a gap once it is tightened. The treatment team benefits from the transverse bonding of the dental prosthesis with the implants with excellent aesthetics and a complete lack of tension.

Patient case

The 48-year-old patient came for a consultation in the practice due to an unsatisfactory removable dental prosthesis in the maxilla. Teeth 11 to 23 were still present, but severely damaged periodontally. A fixed restoration was requested. The high mobility grade of the teeth would not permit a stable anchoring of a new dental prosthesis. Therefore, following a discussion with the patient, extraction of the teeth and immediate implant prosthetic restoration was planned in accordance with the SKY fast & fixed concept.

Planning

As a planning base, a situation model was initially produced (Fig. 2). This was digitalised in the laboratory scanner (D800, 3Shape) and an STL data set was created. In order to validate the implant positions, the two-dimensional X-ray image only yielded limited information about the available bone (Fig. 3). A three-dimensional image (DVT) was therefore compiled, without a scan template being required for this.

Thanks to the allocation of space for the anatomical structures, a detailed analysis of the jaw was now possible. Using the planning software (coDiagnostiX, Dental Wings), six implants were planned in the local bone based on the visualisation of the anatomical structures and the digital set-up (ideal position of the prosthesis; Fig. 4). By angling the distal implants, anatomically vital structures were circumvented and augmentation measures avoided.

The angle of the implants is between 30 and 45 degrees for the SKY fast & fixed concept. In addition to the individual surgical components, special prosthetic superstructures are integrated in the complete concept. A drilling template for the navigated implant insertion and a temporary restoration were created from the planning software for the immediate restoration (Figs. 5 & 6). In order to guarantee accurate positioning in the mouth, both objects were designed with a palate, whereby the temporary dental prosthesis is produced with target fracture sites, in order to guarantee a palate-free design of the screwed bridges (Figs. 7 & 8).

Implantation and immediate restoration

At the time of the surgical procedure, the existing teeth were extracted atraumatically and six implants (blueSKY, bredent medical) were inserted with the help of the drilling templates. The implants were in-

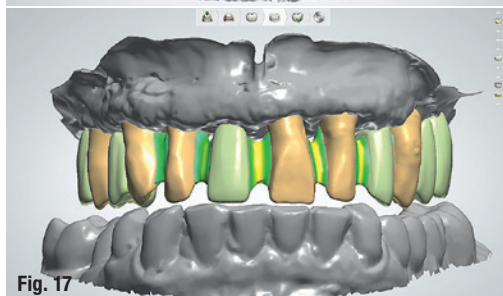
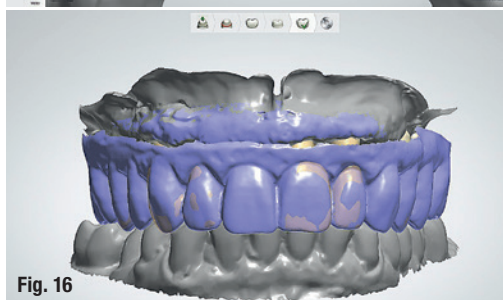
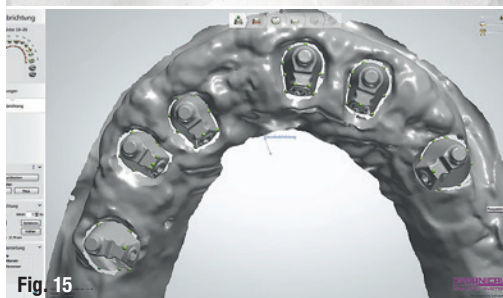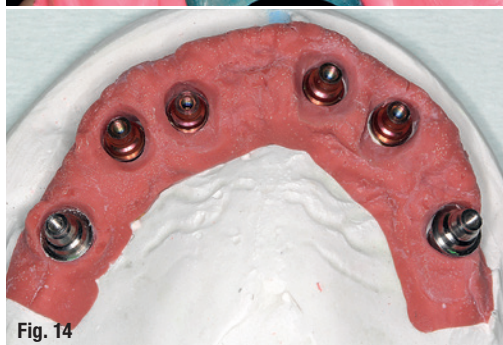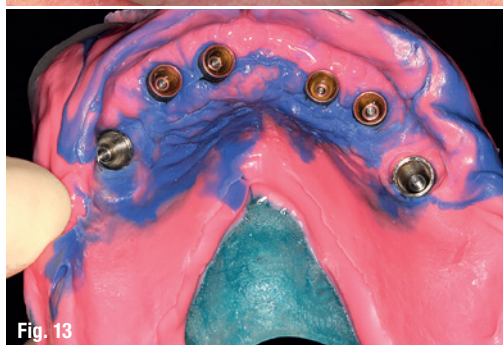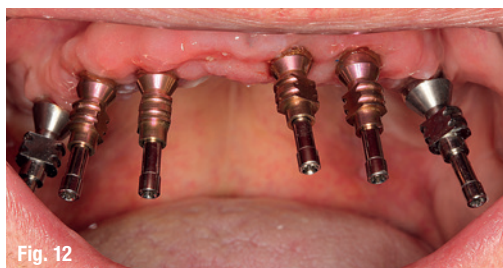serted in a primary stable manner with a torque of between 30 to 45 Ncm (Fig. 9). The abutments were applied and the area sutured. The pre-fabricated temporary restoration was inserted without an impression needed. The palate provided support in order to ensure the reliable referencing of the mouth. The temporary restoration was bonded with the abutment for a tension-free intraoral fit (Qu-resin, bredent medical), lined and the bridge was then processed and produced (Figs. 10 & 11).

Manufacture of the final restoration

The postoperative progress was free of problems. The patient was able to participate in social activities without restriction during the healing phase. Osseointegrated implants and stable hard- and soft-tissue conditions were seen after three months. Following a pick-up impression, the temporary restoration was removed and the implant situations were modelled using an individual tray (Figs. 12–14). A screwed restoration was also planned for the final dental prosthesis. The framework made from non-precious-metal alloy (NEM) should be veneered using a high-quality composite material. In order to give the aesthetic design ample space, transverse screwing (bolting) of the dental prosthesis with the implants was considered. In principle, a restoration screwed onto implants places a high demand on the framework fit. In complex restorations of this type, this involves a considerable challenge in the production procedure. Due to the implant's rigid bond with the bone, even a low amount of force can cause considerable displacement of the implants.

The highest level of precision is required from both the dentist and the dental technician. Digital manufacturing technologies come into play here. These offer a perfect framework fit and a high material quality—the icing on the cake is that production is also efficient. In the CAD software, the data relating to the pick-up impression is superimposed on the data relating to the implant master model (matching) and a framework is constructed in a smaller anatomical crown shape. In the software, the bonding elements for the transverse bolting were integrated in the framework (Figs. 15–17). CAM milling of the NEM framework was carried out in the laboratory's own high-performance milling machine. The thread for the transverse bolting was then incorporated within the cavity incorporated in the bridge framework (Fig. 18).

A framework try-in in the mouth confirmed that this was the perfect fit. The individual veneering of the restoration was carried out using pre-fabricated veneers (novo.lign, bredent medical). The veneers were fixed to the framework with a dual-hardening adhesive and the individual fine touches were added with a veneer plastic (crea.lign, bredent medical). The



Figs. 12–14: The implant model for manufacturing the final restoration (transverse screwed bridge).

Fig. 15: CAD construction with the bonding elements for the transverse bolting.

Fig. 16: Digitalised set-up.
Fig. 17: Construction of the framework in a smaller, anatomical crown shape.

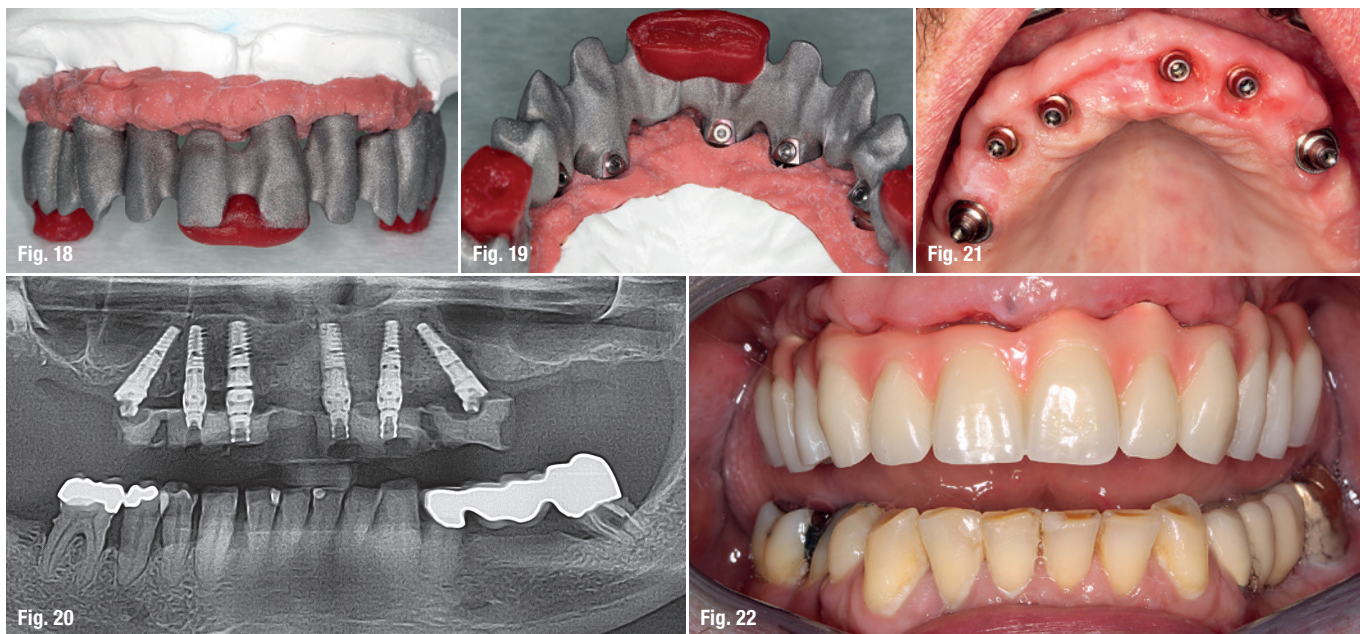


Fig. 18: CAD/CAM-manufactured framework before the try-in in the mouth: the transverse bolting in the cervical-palatine area is easily recognisable.

Fig. 19: The final restoration is fixed to the implants by means of transverse bolting.

Fig. 20: Final X-ray image.

The posterior implants were positioned obliquely in the local bone in accordance with the SKY fast & fixed concept.

Fig. 21: Wonderfully healed soft tissue on recall (continuous hygiene phase).

Fig. 22: The final restoration is fixed to the implants by means of transverse bolting.

multiple-layer veneers (high-impact PMMA composite) and the light-curing composites support the simple manufacture and the individual, aesthetic characterisation. In order to achieve efficient progress, the cushioning properties against chewing pressure of the composite are combined, which are important to consider, particularly in implant prostheses.

Insertion and aftercare

The bridge was fixed using the prosthetic copings (SKY uni.cone transverse prosthetic coping) and bolting in the practice. As this was carried out as three-point fixation, tilting or rotation of the dental prosthesis can be ruled out. Thanks to the slightly inclined position of the bolt screw, the prosthetic coping is "pressed" onto the abutment platform without showing a gap once it is tightened. This elegant type of fixation combines high-quality aesthetics with a tension-free position. The "screw channels" are located in the palatine region of the cervical area, which does not lead to any aesthetic or functional impairments. Following final fitting, the functional, aesthetic and periodontal hygiene factors were subjected to a final check and the patient was discharged from the practice with an aesthetic, fixed restoration (Figs. 19 & 20). The superstructure was designed in such a way as to ensure optimal hygiene was guaranteed.

The patient was given comprehensive instructions in this regard. An important pre-requisite for the long-term success and therefore for a stable periodontal situation is aftercare in the practice. For the first year after treatment with an implant, in particular, a continuous, specific recall system is recommended. The patient had a consultation in the practice every three months. Once the superstructure was

removed, professional cleaning and disinfection of the components of the dental prosthesis bearing the implant were carried out. The peri-implant soft tissue remains exemplary to date (Fig. 21).

Summary

The success of a total concept such as SKY fast & fixed is based on a coherent procedure. From the surgical components to the prosthetic materials—the philosophy is to combine the components in an optimal manner. This requires a high level of cooperation between the practice and laboratory, which can be experienced more intensively and effectively in the digital workflow. Various concepts are offered for the final prosthetic restoration and the individual details are therefore taken into consideration. In order to rule out an aesthetically compromising solution, in this case orthograde screwing of the dental prosthesis—screw channel emerging occlusally—was avoided. A normal bond was achieved in the region that was not visible by means of transverse bolting. The access to the bolting, which was easily achieved, made it possible to easily remove the dental prosthesis in the practice.

contact

Jan Kielhorn
Specialist in Oral Surgery
Private practice
Verrenberger Weg 15
74613 Öhringen, Germany
info@praxisklinik-kielhorn.de
www.praxisklinik-kielhorn.de

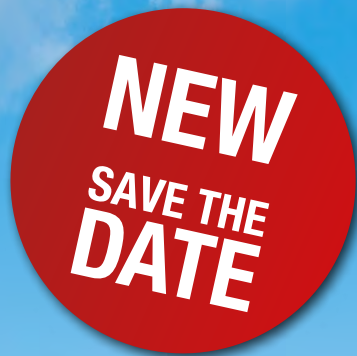Author details



VISIONS IN IMPLANTOLOGY

1ST FUTURE CONGRESS
FOR DENTAL IMPLANTOLOGY

28 + 29 SEPTEMBER 2018



Senior Premium Partner



Premium Partner



48TH DGZI INTERNATIONAL ANNUAL CONGRESS
HILTON HOTEL DÜSSELDORF, GERMANY

WWW.OEMUS.COM

OEMUS MEDIA AG · Holbeinstraße 29 · 04229 Leipzig, Germany · Tel.: +49 341 48474-308 · Fax: +49 341 48474-290 · event@oemus-media.de



A clinical comparison

β -tricalcium phosphate vs hydroxyapatite ceramics

Authors: Private lecturer Dr Dr Arwed Ludwig & Dr Gregor Thomas, Germany



The topic of **bone substitution** or bone regeneration, xenografts, allografts or biomimetic materials are discussed very controversially in the OMF surgery at times. However, the progress and good clinical experiences made with biomimetic materials during the last two decades are undisputed. The present observational study compares two established bone augmentation materials of different chemistry and structure in a direct, indication-related way. The mentioned study cases show that both material types are able to support the surgical work substantially, considering the respective task.

The essential questions related to the product group of the biomimetic materials are about the structure preserving its volume without resorption, or complete degradation of the applied material. The restructuring into vital new bone tissue holds the inevitable side effect of a controlled, yet existing volume loss. The materials used for the comparison are manufactured and distributed by the company curasan (Kleinostheim, Germany) under the names CERASORB® M and Osbone®. CERASORB® M is a β -tricalcium phosphate (β -TCP) with a phase purity of 99% in spongy, polygonal broken form. The open-celled structure with interconnected micro-, meso- and macropores allows a fast ingrowth of osteoblasts and a complete transformation into new vital bone tissue. Due to the lack of any biological and organic content the material can be safely used. The manufacturing process guarantees complete sterility and absence of pyrogens. Osbone® is a purely biomimetic hydroxyapatite with a porosity of 80% and a likewise polygonal broken granular form with interconnected

pores. This leads to a very spongy-like structure of the product. The hydroxyapatite is resorbed extremely slow and therefore guarantees a high volume stability over time and early mechanical endurance.

Both products have a clear advantage over xenogenic materials with the early osteoblastic colonisation and therefore an early bone formation, as the examination of Bernard A. et al. of 2010 shows (Figs. 1a–c). Further important parameters for the evaluation of bone augmentation and bone regeneration materials are:


Primary particle size

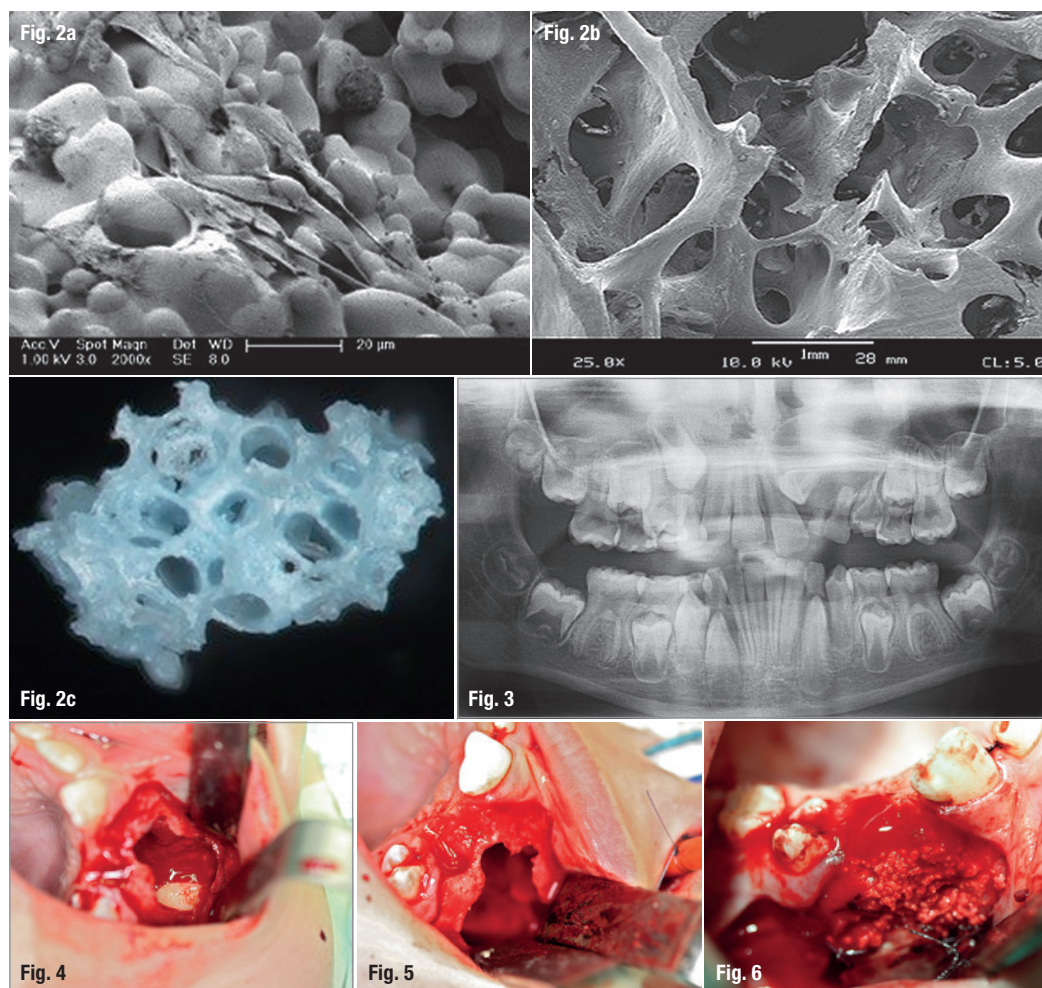
A bone augmentation material with a particle size higher than $10\ \mu\text{m}$ is ideal to avoid cellular decomposition and phagocytosis. It ensures the mechanical stability of the fabric as well as the interconnecting microporosity. A particle size of less than $10\ \mu\text{m}$ stimulates the phagocytosis by macrophages. This leads to an unwanted and premature loss of the bone augmentation material in the defect and a complete biological bone regeneration cannot take place.

Scaffold stability

The granules must not dissolve and disintegrate into small particles or lose stability due to the solution process when the product is applied. A premature disintegration into microparticles provokes an activity of phagocytizing macrophages and polymorphic polynuclear cells. Thereby increased unspecific immunoreaction interferes with the regeneration process. In some cases this can lead to an exuberant inflammatory reaction.

Figs. 1a–c: Comparative tests of different ceramic bone-substitute materials with the human osteoblast-cell line SAOS-2: morphological differences after 24 hours of osteoblast cultivation.





Figs. 2a–c: Structural comparison of CERASORB® M (a), natural bone spongiosa (b) and Osbone® (c).

Fig. 3: Extensive follicular cyst region 23.

Fig. 4: Removal of the retained and extremely displaced tooth 23.

Fig. 5: Extensive bone defect.

Fig. 6: Mixing β -TCP with blood from the defect.

Interconnecting, spongy–open–celled pore structure and continuous structuring with blood vessels

Pores increase the surface and are vascularised in case of sufficient diameter. The pore diameter should at least be 100 μm for the ingrowth of vascularised, mineralised tissue. This enables a complete structuring. The pore size of the synthetic hydroxyapatite is mostly between 250 and 450 μm which supports vascularisation and osseointegration.

Biocompatibility

28 days after the beginning of the cell cultivation, a very good cellular proliferation is clearly visible in the wide extension and clustering of the osteoblasts on Osbone®. The biocompatibility of the bone augmentation material is already visible *in vitro*, due to good cell population properties. Due to its high similarity to a natural bone form, the hydroxyapatite could be confirmed to have a very good biocompatibility. Comparisons of *in vitro* studies with an osteoblast cell line show the reliable, very good cell population properties.

Case studies—indications and usage

Both of the two described products are qualified for the treatment and reconstruction of complex

three-dimensional bone defects. However, after extirpation of cysts, size, localisation, cyst-type and the age of the patient play a major role as well. The β -TCP (CERASORB® M) is preferred because the goal is a complete regeneration from defect to the natural bone tissue (Figs. 2a–c).

Filling of bone defects

A 9-year-old patient came with an extensive follicular cyst in the region 23. Due to an extensive cyst growth, a massive bone resorption of the maxillary bone was noticed. The cyst growth completely decomposed the alveolar ridge bone up to the maxillary sinus (Fig. 3). After removal of the retained and extremely displaced tooth 23 (Fig. 4) as well as extirpation of the cyst and the surrounding tissue, a considerable bone defect remained (Fig. 5). The β -TCP was mixed with blood from the defect and applied without pressure (Fig. 6). Additionally, the graft material was covered with a resorbable membrane. The postoperative radiograph after six months (Fig. 7) and after six years (Fig. 8) shows a perfect bone regeneration in the treated area. This creates a foundation for a good future for implantological treatment after the bone maturity is complete.

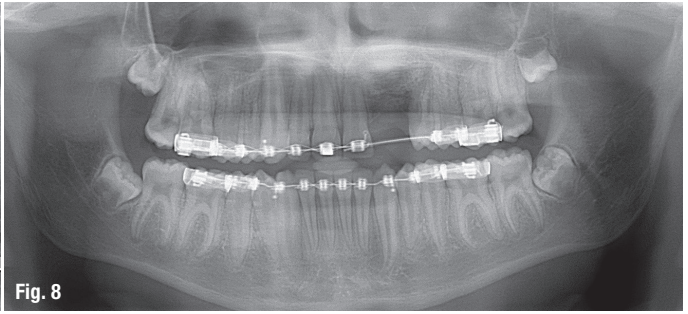
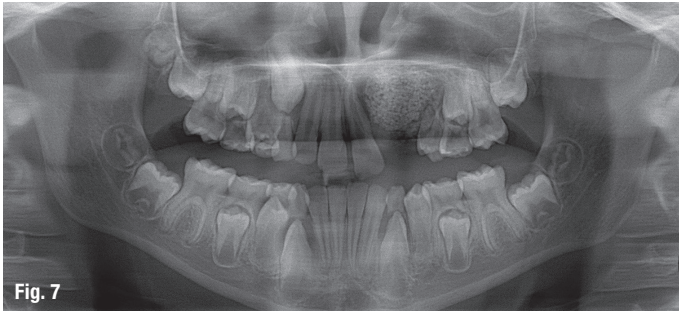


Fig. 7: Postoperative X-ray after six months.

Fig. 8: Postoperative X-ray after six years.

Reconstruction of a lateral wall

A 52-year-old patient had a follicular cyst in region 23 with a retained and displaced tooth 23 (Fig. 9). Because the patient wanted to replace the gap with an implant later on, a ridge preservation had to be performed. After osteotomy of tooth 23 and cystectomy an extensive bone defect was visible, with a missing vestibular wall. The cover and reconstruction of the vestibular bone was done with resorbable (PDLLA) pins and a resorbable (PDLLA) membrane. This created a possibility to fill the defect with β -TCP granules soaked in blood (Figs. 10 & 11). Afterwards, the wound was closed with interrupted sutures (Fig. 12). The postoperative panoramic scan shows the filling of the defect radiographically (Fig. 13).

Fig. 9: Follicular cyst region 23 at the retained and extremely removed tooth 23.

Figs. 10 & 11: Filling of the defect with β -TCP granules soaked in blood.

Fig. 12: Closing of the wound with interrupted sutures.

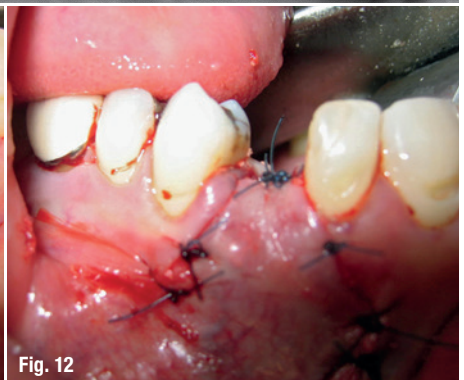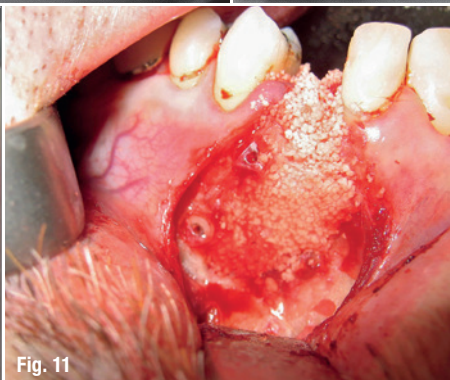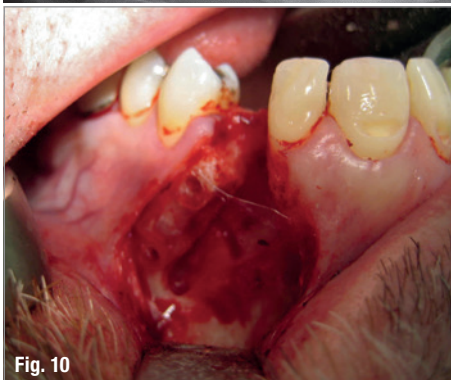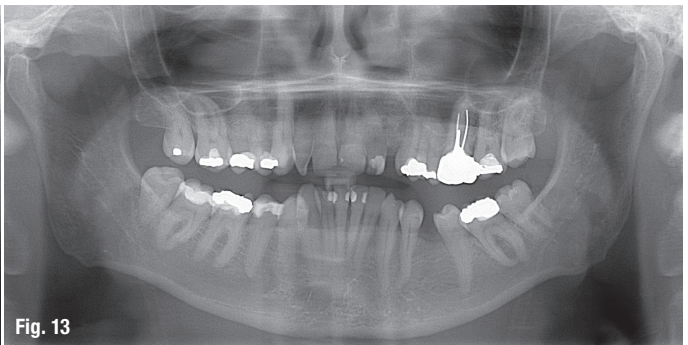
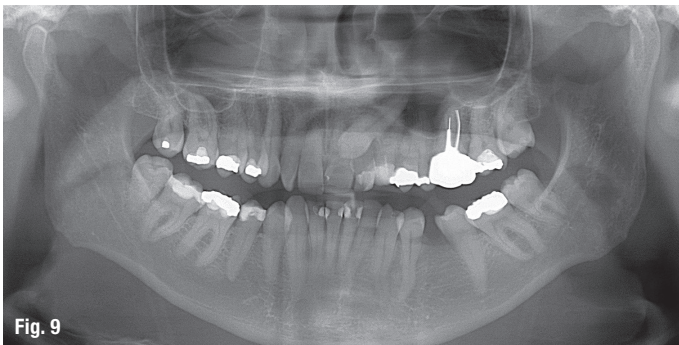
Fig. 13: Postoperative panoramic scan showing the filling of the defect.

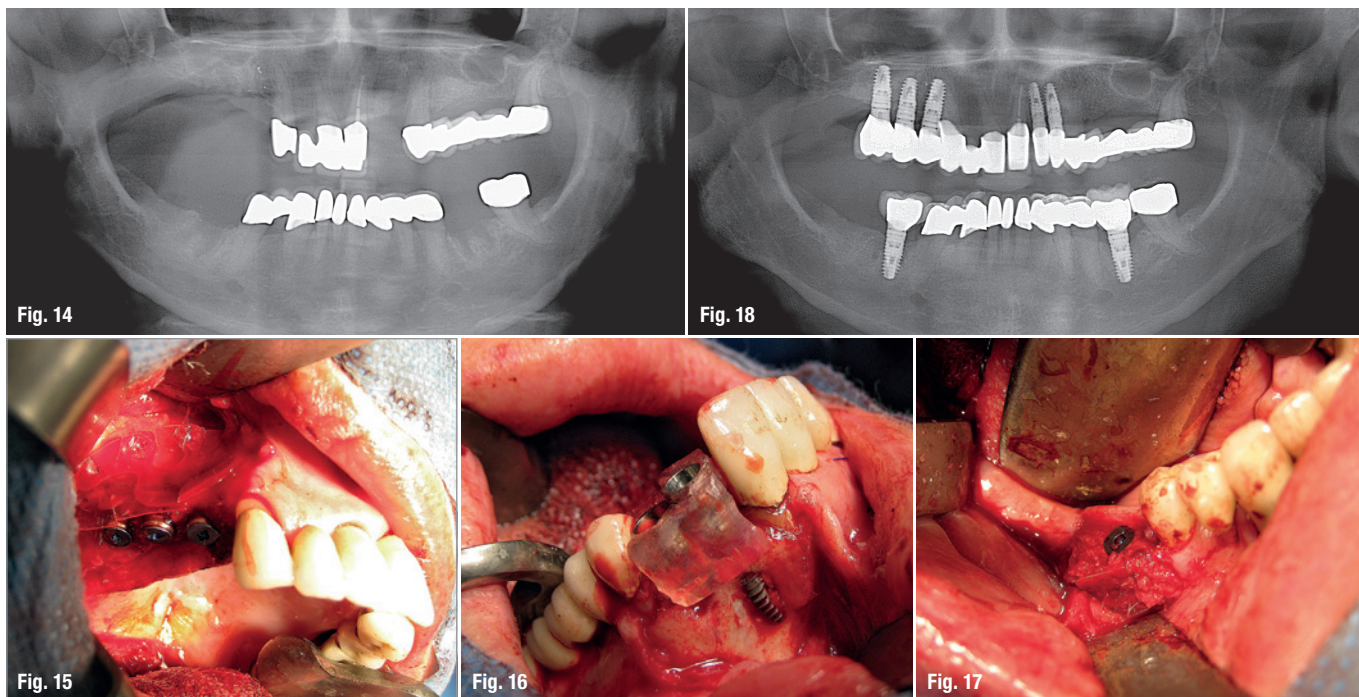
Augmentation of atrophied maxillary ridge

Both materials are suitable for the internal and external sinus floor elevation, however β -TCP is preferred for sinus lift procedures. When the bone defect is vestibular or the bone quality is poor, the application of hydroxyapatite is more advantageous.

A 65-year-old patient presented with an extensive maxillary bone atrophy with loss of the teeth #14 to #16, #21, #22, #36 and #46 (Fig. 14). Firstly, a 3-D CT presentation of the jaws was made to determine the necessary bone augmentation. Afterwards, a sinus floor elevation on the right side was performed by means of balloon lifting technique. A sinus floor augmentation with combination of β -tricalcium phosphate and autologous bone was performed on the right side. Simultaneously, three implants were placed in the first quadrant with the help of a prefabricated guided-implant surgery template (Fig. 15).

In the second quadrant, a massive lateral bone augmentation had to be performed, otherwise, the implants in the vestibular cranial direction would not have been covered by bone tissue. For prosthetic reasons, no other position could be chosen for the implants. After implant insertion with CT templates in region 21 and 22, the lateral bone augmentation was effected with a compound of β -TCP and autologous bone and a resorbable membrane was used for coverage (Fig. 16).





A simultaneous implant insertion was performed in the third and fourth quadrant in region 36 and 46 (Fig. 17). After a six-month healing phase, the implants were exposed and a prosthetic solution was fabricated (Fig. 18).

Summary

Today, different bone grafting materials with different properties and approaches are available for preservation, augmentation and reconstruction of the dental bone ridge. The systematic purpose of this study was to compare CERASORB® M and Osbone®. The products were evaluated regarding their chemical and biological properties and the following clinical applications:

1. Filling and reconstruction of complex three dimensional bone defects.
2. Ridge augmentation in atrophied bone regions (sinus floor elevation and subantral augmentation).
3. Filling of alveolar defects after tooth extraction for the purpose of alveolar ridge preservation and creation of an implant bed, or filling of defects after operative removal of retained teeth—as well as corrective osteotomies or multisided bone defects of the alveolar processes and the facial skull.
4. Filling of two- or multisided bone pockets and bi- as well as trifurcation defects.
5. Supporting function for a membrane with the Guided Tissue Regeneration (GTR).

The comparison showed the following results: Both materials are of biomimetic origin and therefore free of foreign materials or allergens. A good biocom-

patibility is guaranteed by the interconnecting, open-celled and porous structure. The β -TCP offers advantages for cyst defect filling, as the goal is a physiological bone regeneration. Both materials are suitable for the sinus lift; however, the thickness of the Schneiderian Membrane has to be considered. If the membrane is thin, β -TCP has to be applied because of its polygonal structure.

The hydroxyapatite should be preferred for lateral bone augmentation. In case of poor bone quality (D3/D4) and/or two-sided procedure, the hydroxyapatite should also be used due to its higher volume stability. CERASORB® M should be preferred for the filling of alveolar defects without a subsequent implant insertion or for single tooth defects; Osbone® should be chosen for multisided defects. For the purpose of two- or multisided bone pockets as well as bi- and trifurcation defects, and for the supporting function of a membrane both materials are suitable. Because of its constant volume, the hydroxyapatite should be preferred for vertical and lateral augmentation as well as for peri-implantitis.

contact

Dr Dr Arwed Ludwig
MGK Medizinische und
Gesichtschirurgische Klinik
Neue Fahrt 12
34117 Kassel, Germany
Tel.: +49 561 9985990
aludwig@gwdg.de
www.mgk-chirurgie.de

Author details



Fig. 14: Extensive maxillary bone atrophy.

Fig. 15: Implantation via guided-implant surgery template.

Fig. 16: Lateral bone augmentation.

Fig. 17: Simultaneous implant insertion.

Fig. 18: Prosthetic restoration.



© Corepics VOF/Shutterstock.com

CAMLOG

Oral Reconstruction Global Symposium

The Oral Reconstruction Foundation drives progress in implant dentistry and related areas, for the benefit of the patients. Education and training are the Foundation's utmost priorities and are realised through the organisation of top-class events. With the Oral Reconstruction Global Symposium 2018, formerly International CAMLOG Congress, the foundation intends to build on its successes in April next year.

In Rotterdam, implant dentistry topics will be presented and discussed in theory and practice through practical workshops, scientific lectures, and podium and audience discussions. Under the theme "The Future of the Art of Implant Dentistry", a diversity of education and training will be offered thanks to the

combination of instructive workshops, an informative scientific programme with top-class speakers, an innovative event concept, and a high-end evening event for networking with opinion leaders and colleagues.

Register now for the Oral Reconstruction Global Symposium 2018: www.orfoundation.org/globalsymposium.

Oral Reconstruction Foundation
Margarethenstr. 38
4053 Basel, Switzerland
www.orfoundation.org

Alpha-Bio Tec

Implant system with new design



Recently, Alpha-Bio Tec launched a new one-piece design for its AlphaUniverse Multi Unit restoration system, which enhances effectiveness and long-lasting aesthetic results. In line with Alpha-Bio Tec's core value of simplicity, the improved design is launched after a meticulous research and development, along with a comprehensive user feedback. The one-piece abutments are available in 0°, 17° and 30° angles with six cuff heights for the straight abutments and three cuff heights for the angled abutments (1.5 – 3.5mm). The angled abutments come with a bendable metal holder for easier handling and delivery. The abutment's design includes a concaved tulip shape, which promotes soft

tissue healing and adaptation, connecting above the abutments. All restoration parts connecting above the abutments remain the same as well as the classic protocol and CAD/CAM workflow.

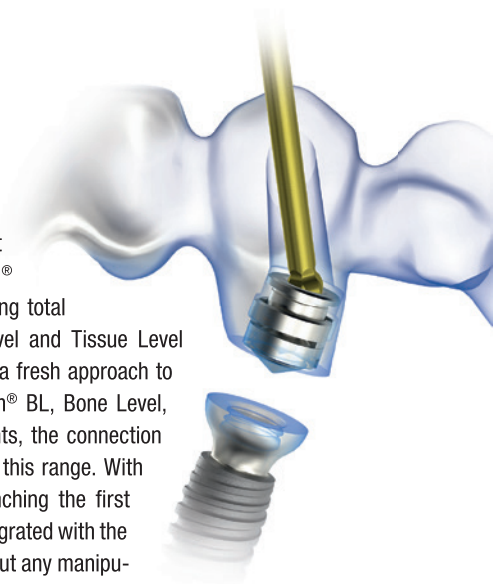
Alpha-Bio Tec
4 Hatnufa St. P.O. Box 3936
Kiryat Arye, Petah Tikva
49510 Israel
www.alpha-bio.net

Anthogyr

Total compatibility

As a natural extension of Concept Axiom®, the new Axiom® Multi Level® range forges a new path by proposing total compatibility between the Bone Level and Tissue Level philosophies. This new range offers a fresh approach to implantology. Available on the Axiom® BL, Bone Level, and Axiom® TL, Tissue Level implants, the connection inLink® illustrates the intelligence of this range. With inLink®, Anthogyr innovates by launching the first locking system that is completely integrated with the prosthesis CAD/CAM Simeda®, without any manipulation, or transport of screws. It consists of a fixation lock and a retaining ring that are integrated within the prosthesis. The system offers compensation for the divergence of implant axes without an intermediary abutment, and angulated access of screw channels to 25°. Thanks to the inLink® connection, it is possible to combine the use of Axiom® TL, Tissue Level, and Axiom® BL, Bone Level implants for a single prosthesis.

Anthogyr Group
2237 Avenue André Lasquin
74700 Sallanches, France
www.anthogyr.com



Integration Diagnostics Sweden

Measuring dental implant stability

PenguinRFA measures implant stability and osseointegration to enhance decisions about when to load. This is especially important when using protocols with shorter treatment time or treating risk patients. The concept is affordable and uncomplicated. It is now available in more than 40 countries by 20 distributors, currently covering more than 50 implant systems with MultiTiegs. The reusable MultiTiegs are made from durable and tissue friendly titanium. Sealed magnets make it possible to autoclave them at least 20 times.

In addition, the company has made the RFA technique even more accurate by creating an ISQ Calibration System, which means minimised variance between different MultiTiegs. Thank's to the reference system, physical misfit between components can also be detected and eliminated in the design phase. This strives to give different implants, with the same stability, the same ISQ.

The company will continue to build its distributor network globally and also intensify the research around implant diagnostics.

Integration Diagnostics Sweden AB
Nedergårdsgatan 5
416 54 Göteborg, Sweden
www.penguinrfa.com



**Shortest Implants –
 Longest History.**

Think Short!

For more than 30 years Bicon® short implants are unchanged in clinical use.

According to the 11th European Consensus Conference (EuCC) 2016 in Cologne, provided the specific treatment parameters are observed, the use of short, angulated or diameter-reduced implants in sites with reduced bone volume can be a reliable treatment option, given the risks associated with the use of standard-dimension implants in combination with augmentation procedures.

For more Information:

Bicon Europe Ltd.

Hauptstr. 1

55491 Buechenbeuren

Germany

Phone +49 (0)6543 818200

germany@bicon.com

www.bicon.de.com

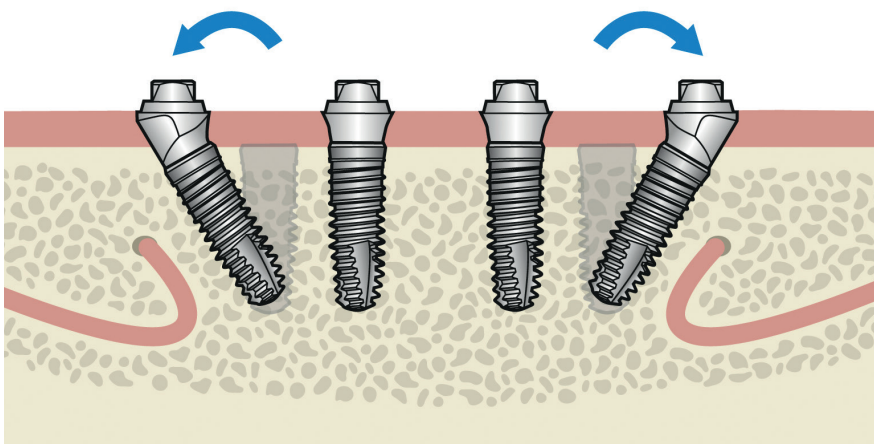
Dentsply Sirona

Immediate restoration of edentulous patients

SmartFix offers an affordable and reliable solution for the immediate restoration without augmentation of edentulous patients when space is restricted. This concept has made a name for itself as a simple implant prosthetic procedure for the immediate restoration of edentulous patients with screw-retained bridges or bar dentures. The suprastructure is supported by four implants that anatomically bypass critical areas due to their angled positioning. The new retention caps are ideal for taking impressions and transferring the implant position. In addition, they can be used to create long-term temporaries and also

be integrated into modified existing prostheses. SmartFix is currently available for the Ankylos and Xive implant systems. It is characterised by a very stable denture placement, the angled abutments in turn allow optimal results in terms of aesthetics and function and the short and flexible insertion aid facilitates handling.

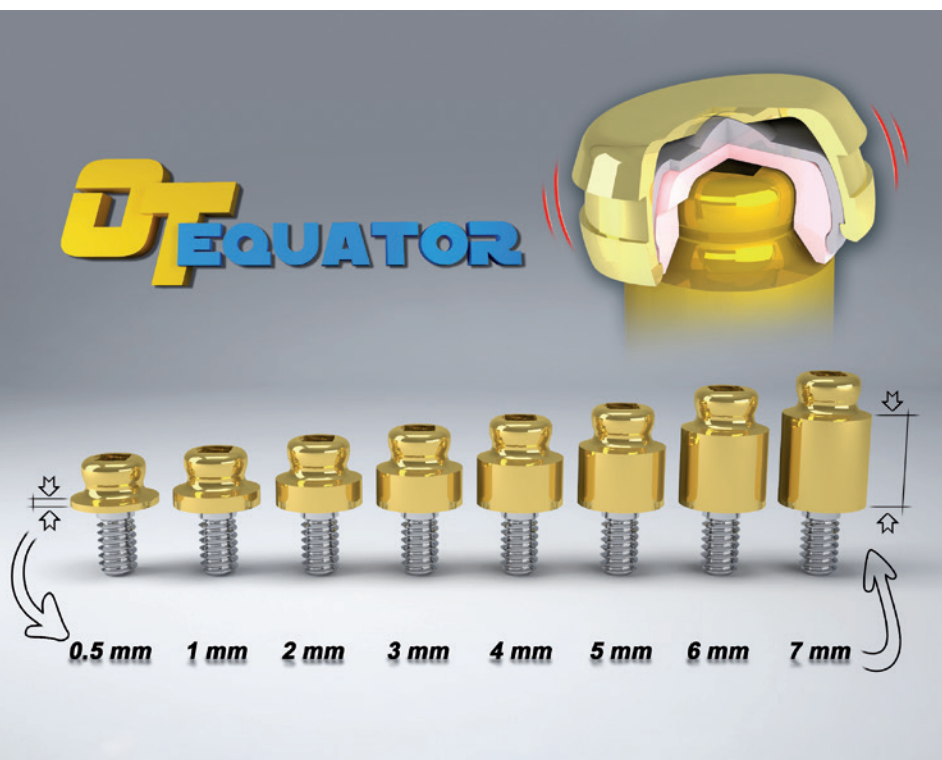
**Dentsply Sirona –
 The Dental Solutions Company™**
Sirona Straße 1
5071 Wals/Salzburg, Austria
www.dentsplysirona.com/implants



bicon
 DENTAL IMPLANTS

Rhein'83

Dimensional attachment system



OT Equator by the company Rhein'83 is the smallest dimensional attachment system in the market counting on a reduced vertical profile of 2.1 mm with a 4.4 mm diameter. The system is compatible with all implant systems and brands, and available in eight different gingival heights. The innovative design of the Equator attachment provides a superior stability and retention to the prosthesis.

The TiN-coating procedure increases the hardness and duration in time the product obtained FDA and CE certification for Russia, Canada, Japan, Korea and more countries.

In case of extreme divergencies between the implants with the OT Equator, the so-called Smart Box can be used. The Smart Box thanks to an inner tilting mechanism allows a passive insertion with divergent implants up to 50°. For more information please contact: marketing@rhein83.it.

Rhein'83
Via E. Zago, 10
40128 Bologna, Italy
www.rhein83.com

Straumann

Insights into clinical performance

More than ten years ago, Straumann® pioneered accelerated osseointegration with the innovative hydrophilic SLActive® surface, reducing the healing period from six to eight, down to three to four weeks for most indications. Since then SLActive® implants have made faster treatment and better outcomes a reality. The extensive healing potential of this product can now be seen even in severely compromised patients and with challenging treatment protocols. Leading researchers worldwide are looking at what's behind the outstanding clinical performance of SLActive®. As new insights

emerge, recently discovered nano-structures explain why the implant surface goes beyond hydrophilicity. Discover the science of high performance at <http://slactive.straumann.com>.

Institut Straumann AG
Peter Merian-Weg 12
4052 Basel, Switzerland
www.straumann.com



Hager & Meisinger

Back to the roots

The concept of a two-phase titanium implant with a special expansion thread and a self-locking cone as an abutment connection was developed by Prof. Dr Georg-Hubertus Nentwig und Dr Ing. Walter Moser over 30 years ago and established to clinical maturity. Creating a design that offered high primary stability, minimum construction height, and deep platform switching in addition to a micro-movement free and bacteria-proof implant abutment connection soon proved to be superior components in terms of achievable bone and soft tissue stability, and thus providing exceptional long-term success. The MyPlant II system is based on the proven principles in terms of progressive thread design and has been optimised with regard to



achievable primary stability and mechanical safety under functional loading. Where adequate vertical bone volume exists, the MyPlant II implant can be inserted subcrestally by approximately 1 mm promoting stable bony incorporation supporting soft tissue.

The reinforced and extended inner cone allows for greater fatigue strength and a higher level of mechanical loading. The self-locking internal cone connection can be oriented freely, is absolutely rotation-stable and also seals practically bacteria-proof.

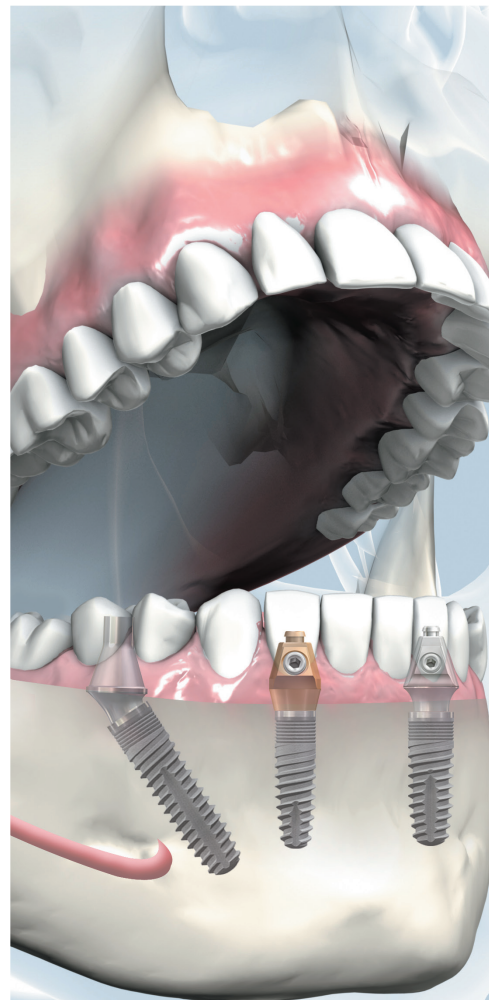
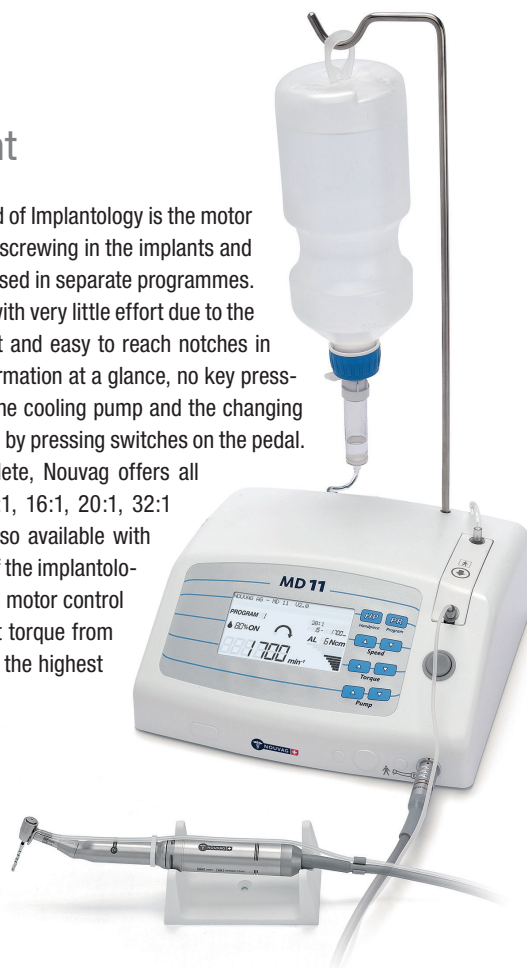
Hager & Meisinger GmbH
Hansemannstraße 10
41468 Neuss, Germany
www.meisinger.de

Nouvag

Sophisticated motor management

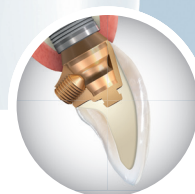Nouvag's latest development in the field of Implantology is the motor system MD 11. Drilling, thread cutting, screwing in the implants and placing the cover screw are now organised in separate programmes. The insertion of the tubing set is done with very little effort due to the great visibility of the mounting bracket and easy to reach notches in the bracket. The display shows all information at a glance, no key pressing necessary. Even the activation of the cooling pump and the changing of the pump speed is conveniently done by pressing switches on the pedal. To make the set of the MD 11 complete, Nouvag offers all required contra angles such as the 1:1, 16:1, 20:1, 32:1 and a 70:1. The 20:1 contra angle, also available with LED spotlight, covers the largest field of the implantologists tasks, thanks to the sophisticated motor control of the MD 11 which provides sufficient torque from the lowest possible speed of 15rpm to the highest speed of 1,700rpm.

Nouvag AG
St. Gallerstr. 23-25
9403 Goldach
Switzerland
www.nouvag.com



SKYonics
 IMPLANTOLOGY MEETS BIONICS

The SKY® fast & fixed
 Therapy



Train the bone –
 save the tissue with
 Bionic framework and
 veneering materials.
 10 years success in immediate
 full arch restoration.

- Easy to use
- Aesthetic results
- Increase profit

Call (+49) 0 73 09 / 8 72-4 41
 to get more information about
 the indications and the versa-
 tility of the SKY® fast & fixed
 therapy.

SKY
 IMPLANT SYSTEM



DENTAL INNOVATIONS
 SINCE 1974

bredent
 group

Nobel Biocare

Introducing the Trefoil™ system

At EAO congress 2017, Nobel Biocare launched the Trefoil system—the latest addition to the company's proven assortment of full-arch solutions for patients in most need.



The Trefoil system has been developed for treating edentulous patients and patients with failing dentition, enabling the fixed, definitive, full-arch restoration of the mandible in one day. These significant efficiency gains are the result of an optimised workflow and componentry, which enable shorter time-to-teeth and reduced chair time in comparison with conventional treatments that require provisional restorations.

The cost-effective Trefoil system features a pre-manufactured titanium bar. Passive fit is made possible by a fixation mechanism that compensates for deviations in implant placement. The bar is retained on three implants featuring the

TiUnite surface, which is proven to support immediate function.¹

At launch, the Trefoil system was already backed by a year of scientific evidence showing successful early clinical outcomes. Preliminary findings show high implant and prosthetic survival rates, minor marginal bone remodelling and short time-to-teeth.² Patients and clinicians reported excellent functional and aesthetic satisfaction at all follow-up assessments, with patients also experiencing notable improvements in quality of life following restoration.

Nobel Biocare Services AG
P.O. Box
8058 Zurich-Airport, Switzerland
www.nobelbiocare.com/Trefoil



MIS

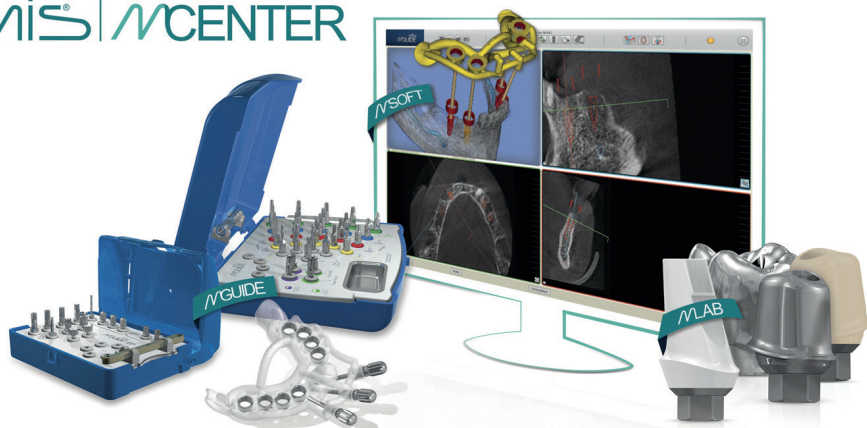
Digital guided surgery solution

The Conical Connection MGUIDE Surgical Kits include all the drills and tools necessary for a simpler surgical procedure. These kits are compatible with both C1 and V3 conical connection implants and complete the existing line of surgical kits, which includes MGUIDE Internal Hex. Surgical Set for standard sleeve as well as the Narrow Sleeve MGUIDE Kit. Unlike all other guided surgery services offered by other manufacturers, MIS workflow is created and followed by only one provider. All steps in the procedure are handled by one source. MIS MCENTERS around the world

take the patient information sent to them and transform it into all that is necessary for the dental practitioners to perform implant surgery and provide patients with a “full smile solution”. Having all components of the process and workflow in one place, enables the MCENTER team to view each case in a “top down design”.

MIS Implants Technologies GmbH
Simeonscarré 2
32423 Minden, Germany
www.mis-implants.com

MIS | MCENTER



Bicon

Time-proven design

The Bicon SHORT® Implant is an example of a time-proven geometric design that successfully transfers the occlusal forces on its prosthesis to its surrounding bone by appropriately integrating the following features: a bacterially-sealed, 1.5 degree locking taper abutment to implant connection and a subcrestally placed, sloping shouldered implant with a plateaued tapered root form body. Additionally, these integrated features compensate for the implant's ankylosed nature by successfully transforming occlusal forces to acceptable strains within the bone, provide for healthy and gingivally aesthetic peri-implant tissues, as well as for the callus formation of cortical like bone with central vascular systems.



Bicon Europe Ltd.
Hauptstraße 1
55491 Büchenbeuren
Germany
www.bicon.com

bredent medical

Implantology meets bionics

SKYonics comprises the disciplines of the so-called “Tissue Related Implant Management”, the solutions for “implant prosthesis with bionic high-performance polymers” as well as innovative “implant therapies for the immediate restoration”. The tried-and-tested SKY® implant family offers primary stability and is the basis for this concept from the bredent group—the specialist procedure for implantology and physiological prosthetics—with optimum use of the local bone.

With the visio.lign® aesthetic and functional system, the bredent group also offers in the truest sense of the word, multi-layer possibilities for a physiological veneering, which represents optimal bonding to all scaffolding materials. These elements provide the basis for the successful use of a variety of immediate restoration therapies from a single tooth, to a jaw which is losing teeth or even a completely toothless jaw.

SKYonics
IMPLANTOLOGY MEETS BIONICS

Tissue Related Implant Management (TRIM)

TRIM, the “Tissue Related Implant Management”, is a tissue-oriented implant management that takes into account the individual tissue condition of the patient during the planning of the surgical protocol and the selection of components for the healing phase and soft tissue management. The aim is to minimise major surgical procedures under all circumstances and to avoid complex augmentations. This method provides maximum safety for patient and practitioner, while ensuring an efficient process that reduces the time and costs of treatment and enables more patients to be treated.

Implant therapy for the immediate restoration

The bredent group is a powerful partner for dentists and surgeons, especially in the immediate restoration of implant-supported therapies. With more than ten years of experience and nearly 50,000 treated and satisfied patients, the company is one of the world leaders in the provision and development of immediate restoration therapies such as “SKY fast & fixed” for toothless jaws and SKY elegance abutments for bridges and single tooth restoration.

Implant prosthesis with bionic high-performance polymers

The bredent group is an expert in the field of high-performance plastics. BioHPP®, for example, a PEEK-based, ceramic-reinforced high-performance polymer with bone-like elasticity, reduces chewing force peaks, thus avoiding permanent misalignment and protects the implants even during osseointegration. In this way, a long-term successful implant is ensured. Thus, bredent provides implant-preserving and natural restorations fixed and removable and promotes patient health and satisfaction.

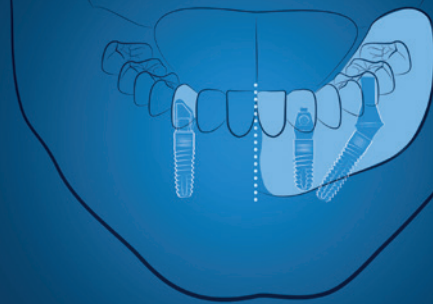
bredent medical GmbH & Co. KG

Weißenhornstraße 2

89250 Senden, Germany

www.bredent-medical.com

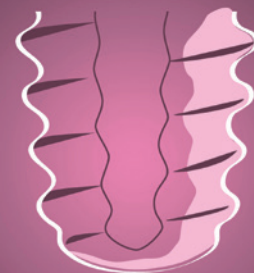
IMPLANT THERAPIES FOR IMMEDIATE RESTORATION



IMPLANT PROSTHETICS WITH BIONIC HIGH-PERFORMANCE POLYMERS



TISSUE RELATED IMPLANT MANAGEMENT



“Implantology is a field of opportunities”

Lately, Anthogyr introduced its newest product to the dental audience, the Axiom® Multi Level® system. At this year’s EAO congress in Madrid, Spain, *implants* spoke to Anthogyr CEO Éric Genève about the new system, the company’s collaboration with Straumann, and future plans.

How did you experience this year’s EAO, and on which product did you lay your main focus?

Anthogyr had been exhibiting at many EAO congresses now—meanwhile, we have become a gold sponsor. At this year’s EAO, we presented our newly developed Axiom® Multi Level® concept which was already revealed in Paris last year. In Madrid, we wanted to introduce this product to the Spanish market before it will be fully launched in the beginning of 2018.

What is special about the Axiom® Multi Level® concept?

The speciality of this concept is the very unique inLink® connection. With this, practitioners have an

implant connection for both Axiom® BL, Bone Level, and Axiom® TL, Tissue Level. Axiom® Multi Level® offers a great variety of surgical and prosthetic treatment possibilities with a clear focus on CAD/CAM solutions.

The real added value of the new inLink® connection contains two key aspects. On the one hand, the retaining screw is already fixed to the structure so that practitioners merely have to tighten the screw. On the other hand, due to the CAD/CAM structure angulations of the implants can be compensated by the implant prosthetics. Thus, there is no further need for specially angulated superstructures. Due to the connection geometry, any implant axis can be compensated without affecting functionality. This is a very cost-efficient and simple solution, proving the innovative force of Anthogyr.

Furthermore, this new system also facilitates the dental technician’s work a lot. Due to the very low structure height of the retaining screw, the technician is able to position the angulation for a transverse screwing channel at an early point.

Is this system primary meant for full prosthetic solutions?

The Axiom® Multi Level® system can be used for both full prosthetic and bridge restorations. Although, the system’s added value comes to its best effect in full prosthetic restorations. For bridge restorations there are other very good options. Beyond that, the system can also be applied for immediate restorations, since it offers the possibility to work with angulated temporary superstructures made from titanium.

Is the concept fully integrated into a digital workflow?

To date, the concept is not yet integrated into a digital workflow, but it will be in the future. At the moment, we are in an evaluation process in order to make sure an effective and fully integration of the Axiom® Multi Level® concept from camera to manufacturing.

Fig. 1: Interview with Anthogyr CEO Éric Genève (middle), Georg Isbaner (right), editorial manager of *implants*, and Laetitia Martin-Berne, Anthogyr communication manager.



Fig. 1

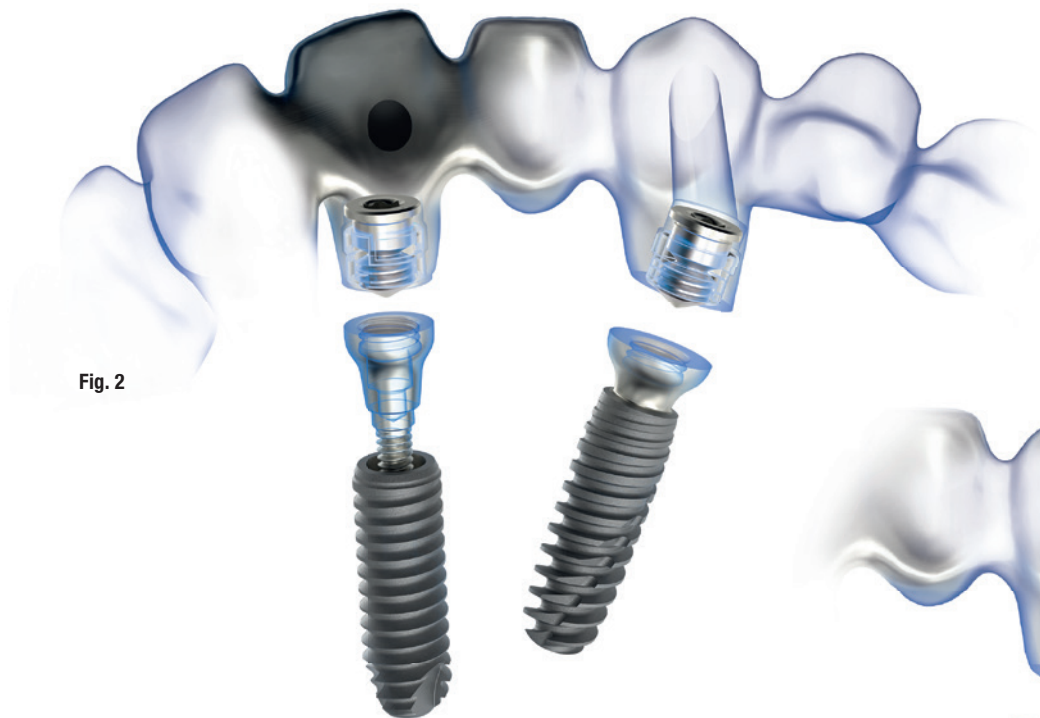

Fig. 2

Fig. 2: The Axiom® Multi Level® implants system offers an innovative solution to the practitioner.

Fig. 3: The inLink® connection.

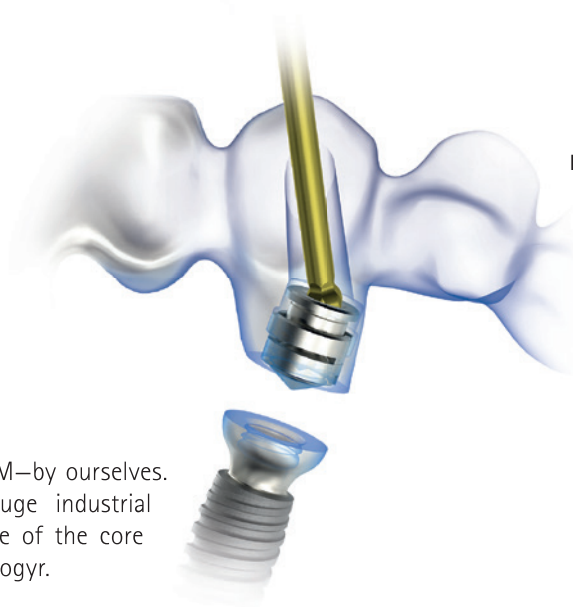


Fig. 3

What is the overall reaction towards your new concept?

We obtained the patent for this new concept six years ago, and then started clinical evaluation. By now, we have collected a lot of data on this technology with very good results. Axiom® Multi Level® is a quite disruptive solution that needs a lot of support and training. Therefore, our decision was to launch this product very carefully.

It is a totally new system and we are a rather small company. With this in mind, we have to keep attention of the people's reactions to ensure that everyone in the "chain" is willing and able to successfully manage this new solution. It takes time to train and accompany them accordingly. Until now, the overall feedback of the practitioners is very good, they are totally satisfied.

Where is the manufacturing made?

All our implant solutions are manufactured in Sallanches in France at our company's headquarter. All customised solutions in terms of prosthesis are made in Luxembourg, in the centre of Europe. With this, we are able to supply our customers within the European market—Spain, Italy, Benelux, Germany, France, UK—fast and easy.

Where do you think the dental implantology market will develop to in the next years?

Implantology is definitely a growing market, and at the same time a very interesting market. There are a lot of countries lacking adequate treatment options to date. For a relatively small player as we are, implantology is a field of opportunities, and yet a great challenge, since we are managing the whole workflow of marketing, design and manufacturing within our entire portfolio—from implantol-

ogy to CAD/CAM—by ourselves. Thereby, our huge industrial facilities are one of the core strength of Anthogyr.

However, to succeed in this exciting and rapidly developing field we need to grow very fast, because there is a lot of competition and consolidation at the international and global dental implantology market.

In view of this challenges, what are your future plans?

Two years ago, we entered in a collaboration with Straumann for the Chinese dental market. With this very close and unique partnership, we aim to increase our activities in the Asian market. With Straumann managing our Chinese businesses, Anthogyr is able to refocus more on the European market. For example, one year ago Christian Grau has taken over the lead as General Manager for Germany, which is a very tough market. But we are sure that Anthogyr will succeed in gaining a place amongst the top players in the area of dental implantology. With our decision to open our door to Straumann we made a huge step to reach this goal also at a global level.

Many thanks for this interview. _

contact

Anthogyr Group
 2237 Avenue André Lasquin
 74700 Sallanches, France
 Tel.: +33 450 580237
 contact@anthogyr.com
 www.anthogyr.com

Putting **TiUnite** to the test

Having been involved with dental implantology from the very beginning, Prof. Tomas Albrektsson was a keen observer when Nobel Biocare launched its moderately rough TiUnite surface in 2000. Now, 17 years on, he is the co-author of a landmark meta-analysis analysing all prospective studies since published on the surface—106 papers in total, featuring over 12,000 TiUnite implants.¹ Here, he explains the significance of the findings.

Prof. Albrektsson, the meta-analysis assessing TiUnite implants that you co-authored with Prof. Matthias Karl is perhaps the most extensive assessment of a single brand of dental implants. What is the relevance of looking at research on the TiUnite surface in such detail?

It is always relevant to have proper clinical studies conducted. But it is the sheer wealth of evidence on TiUnite implants that made this meta-analysis possible. Nobel Biocare is definitely leading the way here. There are some other systematic reviews on a single implant surface or brand, but not many.

And the more we know, of course, the better it is for dental professionals and for patients.

Research of this nature highlights the stark contrast between high-quality implants and the copycat versions that are likely not backed by documentation. Even if they seemingly look like the implant that they are trying to imitate, this does not mean they will work in the same way. So this is really the most important thing—that a dental implant really works as planned and that there is high-quality evidence to prove it.

What were the key findings of this TiUnite meta-analysis and why are they important?

It was reported, not to any great surprise, that there is a very high implant survival rate for implants with the TiUnite surface. We know today that TiUnite has a very good clinical record with maintained bone levels in the great majority of cases. There are actually five different ten-year studies on TiUnite that demonstrate well-maintained bone levels.

What does your study tell us about rates of peri-implantitis with TiUnite implants?

The publications assessing biological complications revealed a low prevalence of peri-implantitis with TiUnite implants. This is also no big surprise. The figures we have seen widely reported in the literature are exaggerated. They say that any bone loss after the first year is disease which is, to put it mildly, incorrect.

We see maintained bone levels in this study and in other ten-year follow-up studies with TiUnite. If peri-implantitis is a disease, which is something widely discussed at this time, it may affect one per cent of implants at ten years. So, if by “disease” we mean bone loss that threatens the survival of the implant, it’s in the order of one per cent.

Nobel Biocare’s implant systems are not the only ones showing good results with respect to peri-implantitis but if I were to choose an implant today I would look at the documented research, which is so much better with Nobel Biocare. The TiUnite im-

Fig. 1: Prof. Tomas Albrektsson, co-author of a meta-analysis assessing TiUnite implants.



Fig. 1

plant surface is backed by more five- and ten-year studies than implant surfaces from the majority of competitors. When it comes to supporting evidence, Nobel Biocare implants have the advantage.

How can the findings of this meta-analysis be used to optimise clinical practice?

I think that we have to strive for continuous improvement. In the 1800s if you had 19 per cent mortality with appendicitis cases you were better than the average doctor. Today such a mortality rate would see you lose your license because we have new techniques. It is a similar story with dental implants—we have to constantly challenge what we think of now as the ultimate implant solution in order to have even better solutions for patients in future.

It is a continuing mission and I know that Nobel Biocare is involved in a number of studies with a view to making further improvements. I think this is exactly the right approach because the ideal situation is that we have 100 per cent survival and success rate at ten years. We are not there yet, but that is the goal.

You have been involved with research evaluating Nobel Biocare implants for many years. Have the findings of your analysis changed your perception of the TiUnite surface in any way?

The meta-analysis is another validation of TiUnite's efficacy, but there is confirmation of its high performance also in other types of clinical studies. Meta-analysis offers high-quality insight, but you need a wide range of supporting evidence, and TiUnite is backed not just by prospective studies, as we examined, but by retrospective research and other study types as well. The statements we make about TiUnite implants today can therefore be made with great confidence.

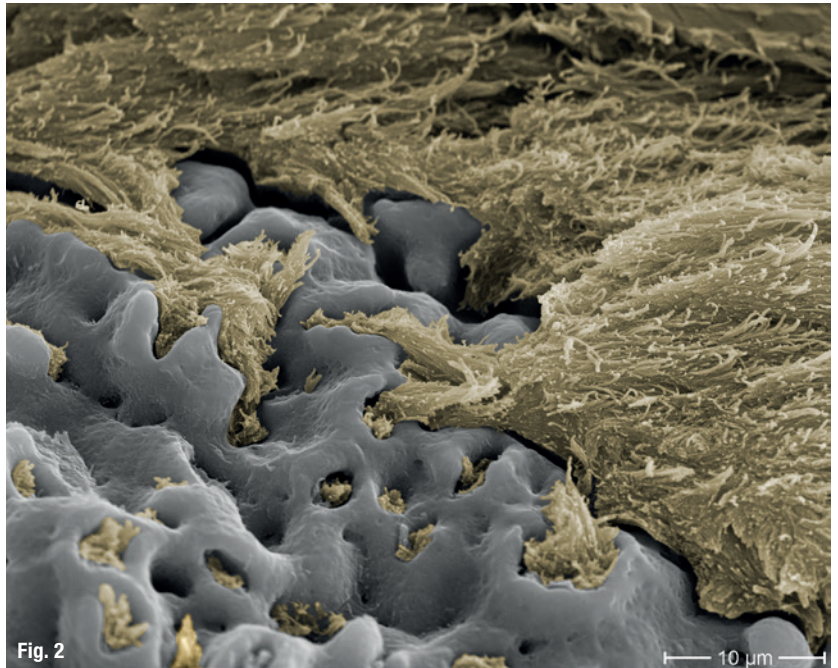


Fig. 2

10 µm

I observed TiUnite being launched in the year 2000. I believed in it then and now I know that my beliefs were correct. It is a superb implant surface.

Fig. 2: Osseointegrative bone formation—human histology six months after implant insertion with bone anchored in the TiUnite pores. (© Dr Peter Schüpbach)

Literature

- 1 Karl, M and Albrektsson, T. Clinical performance of dental implants with a moderately rough (TiUnite) surface: Int J Oral Maxillofac Implants. 2017 Jul/Aug;32(4):717–734. doi: 10.11607/jomi.5699.

contact

Nobel Biocare Services AG

P.O. Box
8058 Zurich-Airport, Switzerland
Tel.: +41 43 21142-00
info.switzerland@nobelbiocare.com
www.nobelbiocare.com/TiUnite

AD

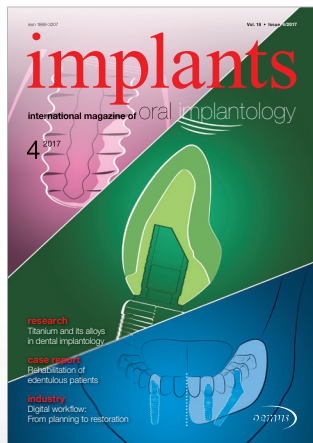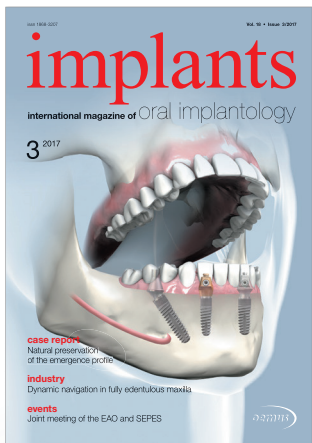BECOME AN AUTHOR

for implants—international magazine of oral implantology

Interdisciplinary, transparent & market orientated



www.oemus.com



Become part of a successful network and benefit from a wide reach and high level of awareness

Your benefits:

- author's profile at ZWP online
- specimen copies
- offprints
- speaking engagement*

Please send back your fax form or contact Mr. Georg Isbaner: g.isbaner@oemus-media.de Phone: +49 341 48474-123

*according to the required profile





Fig. 1

47th DGZI International Annual Congress

Author: Dr Georg Bach, Germany

On 29 and 30 September 2017, the 47th DGZI International Annual Congress was held in Berlin, Germany. 60 speakers from eight countries had been invited to discuss the rather provocative question of "Does biology still matter?" taking a closer look at the controversial topic from all its facets. The scientific board was chaired by DGZI President Prof. Dr Herbert Deppe and DGZI Vice President Dr Roland Hille.

Congress opening

The congress opened on Friday in presence of numerous associated professional societies in the area of dental implantology. Delegates from Japan, the Eastern Europe, North America and the Arabian region joined the event.

In their welcome speech, Prof. Dr Herbert Deppe and Dr Roland Hille referred to one of the main topics of the congress which was conventional vs digital workflow. They posed the question of whether the conventional workflow is still contemporary or has the digital workflow already taken over the lead.

However, there were still some problems to solve, as they concluded. Another important point of discussion was the multi-morbidity of patients with regards to extensive medication prescription. In this context, the scientific committee pointed out the importance of dentists' to consciously look at the oftentimes complex pathology of their patients. Considering this, they would be better able to estimate individual risks regarding planned surgeries.

Subsequently, Prof. Dr Stefan Wolfart and Dr Christian Mehl gave a closer insight into the dispute of conventional vs digital workflow. Using impressive images and well-documented case examples, they discussed advantages and disadvantages of both practices. Each speaker concluded in his lecture that dentists can feel at home in both worlds—depending on the availability of equipment and material, and their individual educational level. "What is significant is the improvement of the treatment quality," Prof. Dr Wolfart stated, and simultaneously advised his colleagues: "Don't let the industry fool you that you necessarily need to buy this or that!"

DGZI past President Dr Friedhelm Heinemann spoke about fixed restorations made from full-ceramics—tension-free and efficient. "There is a lot that works, however, you have to do it in the right way," with this initial statement Dr Heinemann had the auditorium on his side. Oftentimes, dentists have to decide between a tension-free cementation that may be fraught with biological difficulties (cementitis), and screwing that comprises aesthetic disadvantages and may cause tensions. He proposed a solution using both procedures: fabrication of the crown with a hole, cementing, and screwing.

Dr Victor Clavijo who had been travelling from Brazil to the German capital, divided his lecture into three parts: experiences, evidence, and reproducibility. In his lecture, he focused on the maxillary anterior teeth which are an aesthetically relevant zone. Thereby, he pointed out differences in the prosthetic treatment. His first take-home message was: "Keep the maxillary anterior teeth as long as possible!" If implants cannot be avoided any longer, he suggested to use diameter reduced implants preceded by a soft- and hard-tissue augmentation. His second take-home message was: "Always change an unfavourable initial situation to a favourable one, and only afterwards talk about implants!"

After the opening session, the congress participants had ample opportunities to visit different podiums; they could choose between the main podium, the international podium, and the corporate podium.

Biology and medication

In the afternoon of the first congress day, one of the first lectures was presented by DGZI President Prof. Dr Deppe. He referred on benefits and limitations of dental implants in patients with systemic diseases. Thereby, he concentrated on cardiovascular diseases, diabetes, and immunodeficiency diseases. Despite inconsistent guidelines and advices, Prof. Deppe concluded that patients with these diseases may be well treated with dental



Fig. 2



Fig. 3

implants given the respective disease is under control. The same applies to old patients in a good overall condition.

Prof. Dr Weischer perfectly rounded off the lecture of his previous speaker by emphasising the meaning of biology in implant treatment of patients having pre-existing diseases. In case of patients undergoing an antiresorptive therapy, the individual risk potential limits the decision of inserting dental implants—especially in long-term and intravenous administration. Another risk for implant treatment is caused by long-term and high administration of cortisone. Thus, a careful anamnesis, well-balanced indication, and pre-operative antibiosis is crucial for the implant

Fig. 1: View into the main podium of the 47th DGZI International Annual Congress.

Fig. 2: (from left) Congress President Dr Roland Hille, Dr Stefan Wolfart and DGZI President Prof. Dr Herbert Deppe.

Fig. 3: At the booth of the DGZI gold sponsor OT medical.



Fig. 4

success, Prof. Dr Weischer concluded. Taking into account these factors, implants could be a therapeutic alternative even in tumour patients.

In the following, Dr Dr Frank Halling talked about relevant side effects and interactions of the 50 frequently prescribed medications in Germany. In his thoroughly researched presentation, he pointed out that an over 65-year-old patient averagely takes four different agents. In view of this fact, polypharmacy and polymorbidity are also a relevant issue and considerable challenge for dentists. Thus, dentists are obliged to consult the respective general physician or internist before they carry out a complex surgery.

After having heard a lot of interesting lectures, congress participants concluded the day with a special event. During the live show "Stars in Concert", DGZI guests enjoyed a memorable time from best seats, and meet a lot of stars, amongst them Elvis Presley, the Blues Brothers, and Elton John.



Fig. 5

Biological aspects in implantology

The second congress day was opened by a presentation of Prof. Dr Siegfried Heckmann. He introduced a study on immediate implants and immediate restoration in the aesthetically relevant zone. Thereby, he clearly stated: "One has to decide either for a consequent immediate implantation and restoration, or for a delayed implantation and restoration. Do not mix these procedures! Do not use mixed procedures!"

Subsequently, Prof. Dr Constantin von See addressed the question of how implants that are currently available, still make sense under a biological point of view. Following years of stagnation, a new variety in terms of implant design and form has been developed, as Prof. Dr von See stated. Thereby, a great importance is attached to the crown-implant ratio and implant stability. DGZI board member Prof. Dr Kai-Olaf Henkel followed this topic in a perfect manner by talking about the force flux at the implant that



Fig. 6



Fig. 7



Fig. 8

Fig. 4: Members of the Japan delegation with Dr Rolf Vollmer.

Fig. 5: Dr Yoshie Minoru, Japanese board member, during his welcome speech.

Fig. 6: Members of the Georgian delegation with Dr Rainer Valentin.

Fig. 7: Prof. Dr. Mazen Tamimi and guest.

Fig. 8: Prof Dr Robert Sader, Dr Georg Bach und Prof. Dr Wilfried Wagner at the podiums discussion "DGZI controversy".

are crucial for implant success. He concluded that it has to be of highest priority to consider the surface, and pressure and tension forces.

As an expert in the field of ceramic implantology, Dr Michael Gahlert referred on biological aspects of ceramic dental implants. Ceramic implants are not merely a passing trend but a real alternative to titanium implants, he stated. Especially, with a view to biological aspects in dentistry. The following speaker Prof. Dr Max Heiland dealt with pre-implantological augmentation in the maxilla. Thereby, he focused on bone regeneration in the edentulous maxilla—based on options in the single-tooth replacement, and to avoid removable dentures. In his presentation, he specifically concentrated on the possibilities of 3-D diagnostic and 3-D support in such augmentation procedures.

Dr Daniel Thoma referred on biomaterials as alternative to autologous soft tissue implants. In his explanations he followed the credo: Biomaterials are worthwhile, and have been established as alternative to conventional procedures using autologous materials. Subsequently, Prof. Dr Thorsten Auschill focused on a both relevant and demanding topic under the headline "Update peri-implantitis therapy according to changed guidelines". After having thoroughly described important definitions and addressed nomenclatorial questions, he concentrated on the latest therapy options in the treatment of peri-implantitis.

Different ways—DGZI controversy

Besides scientific lectures, the second day of the DGZI annual congress is traditionally dedicated to a controversial exchange and discussion. For this year's podiums discussion, the scientific board succeeded to win two German top-class experts in the area

of maxillofacial surgery: Prof. Dr Robert Sader and Prof. Dr Wilfried Wagner. The speakers discussed the question: "Are shorties the all-purpose weapon in implantology?" In their initial statement, both experts confessed that they as patients would agree to short implants, if the appropriate conditions were met.

During the debate it became evident that previous differences on the subject, which seemed in part irreconcilable, have ceased. Oral surgeons do not longer insist on bone blocks as the ultimate solution, and sceptics of augmentative procedures are more and more aware that their preferred procedures have their limits. Both experts agreed that today the following factors are crucial: a clear analysis of the individual patient conditions, a good pre-implantological diagnosis, a reliable command of the insertion technique used in each case, and, last but not least, implantological troubleshooting.

Closing the two-day event, participants, speakers and all those responsible looked back on a highly informative congress. In view of this successful event, those interested can look forward to 2018 and the 48th DGZI International Annual Congress which will be held on 28 and 29 September 2018 in Düsseldorf, Germany.

contact

Dr Georg Bach
Zahnarzt für Oralchirurgie
Rathausgasse 36
79098 Freiburg im Breisgau
doc.bach@t-online.de

Author details





© Dancestrokes/Shutterstock.com

AAID congress in San Diego

Author: Dr Rolf Vollmer, Germany

From 11 to 14 October 2017, the 66th Annual Educational Conference of the AAID (American Academy of Implant Dentistry) was held in San Diego, USA. More than 1,000 implant dentistry professionals came from across the globe to attend the event. As AAID representatives stated, this was a record number. The many international attendees gathered to learn from fellow practitioners and the industry's most renowned experts. The German Association of Dental Implantology (DGZI) was also present with its 1st Vice President Dr Rolf Vollmer, the international representative Dr Mazen Tamimi and the DGZI US representative Prof. Dr Suheil Boutros.

Dr Frank Liebaug, who also came from Germany, visited the AAID Annual Conference for the first time. "I came here to get some new ideas, and I've been able to confirm that over the past 20 years I've been on the right track", Dr Liebaug said. "You cannot find success without education. And, we especially need to transfer more knowledge from one continent to the other." He also said that he was looking forward to seeing

some of the latest high-tech devices and instruments at the exhibition hall.

More than 130 companies attended the exhibition in the Hilton San Diego Bayfront Conference Center. They offered hands-on opportunities for practitioners to examine some of the industry's most advanced and innovative tools and techniques. The attendees were able to learn through didactic and hands-on sessions, and through interaction with peers and at the social events.

Impressive presentations

During the four-day event, congress participants had the possibility to hear a lot of interesting lectures by renowned experts. Amongst others, impressive presentations were held by Dr Michael Pikos ("The use of rhBMP-2 for alveolar ridge augmentation") and Dr O. Hilt Tatum ("Predictable restoration of alveolar bone"). Corporate-supported courses offered the opportunity to learn about latest innovations in implant

dentistry directly from those who are developing the newest techniques and technologies. One of those courses was given by DGZI member and specialist Prof. Dr Suheil Boutros on "Narrow diameter implants for narrow ridges in the aesthetic zone". In his presentation, Dr Boutros demonstrated the placement of narrow diameter implants (NDI) in a narrow ridge to avoid the need for a large ridge augmentation.

In another workshop, Dr Boutros showed that bone management is one of the key elements for achieving success in implant dentistry. Implant site development at the time of tooth extraction should be considered to prevent bone loss and allow for ideal implant placement. The presentation demonstrated how to perform an atraumatic tooth extraction and how to do socket preservation/ridge augmentation. Afterwards, the decision tree in selecting the appropriate grafting materials was discussed. The second part of the presentation discussed how to successfully grow bone through Guided Bone Regeneration (GBR) as well as ridge expansion by bone splitting with especially developed chisels and wedges.

Dr Paulo Malo, founder and president of the Malo Clinic, reported about "Recent advancements in graftless solutions, zygomatic, and tilted implants". In his lecture, he discussed the goals in surgical and prosthetic therapy when using the All-on-4 treatment concept to restore the fully-edentulous and failed-dentition patient. The most recent advancements of this graftless solution to approach the severely resorbed maxilla and mandible were covered. Clinical management of patients were presented by demonstrating data gathering process, diagnosis, treatment planning, surgical protocols, fabrication of both provisional, and definitive implant-retained prostheses. The indications for the use of the modi-

fied technique using zygomatic implants to manage the severely resorbed maxilla cases were impressively demonstrated.

Another topic that was discussed by Prof. Dr Boutros was "Trabecular Metal™ Technology from orthopaedics to dental implantology". Hereby, he explained the indications for this new mix of two materials. Trabecular Metal™, a porous (80%) tantalum biomaterial with a trabecular like structure for three-dimensional bone in-growth, has been used for more than a decade in orthopaedic surgery. As a result of great success in orthopaedics, a new tapered, threaded titanium dental implant with a trabecular metal midsection has been developed and tested in animal models followed by human cases for over five years. Clinical cases presenting the trabecular metal dental implant for enhanced secondary stability in poor bone quality and its indication in compromised sites in addition to medically compromised patients were presented.

Scientific joint lecture

Another highlight of the meeting was the scientific joint lecture of Dr Elisabeth Jacobi-Gresser, DGZI specialist with 38 years of experience in oral surgery, implantology and environmental medicine, and Prof. Dr Daniel Gustavo Olmedo, specialist and head professor in oral pathology at the University of Buenos Aires, Argentina. The lecture was titled "Risk factors in titanium implantology: Reasons to consider zirconia implants". Prof. Dr Olmedo and Dr Jacobi-Gresser stated that over the past 50 years, oral implants fundamentally influenced reconstructive concepts in dental medicine. Due to its excellent biocompatibility titanium is still the preferred metal not only in dental implantology but also in orthopaedic joint replacement.

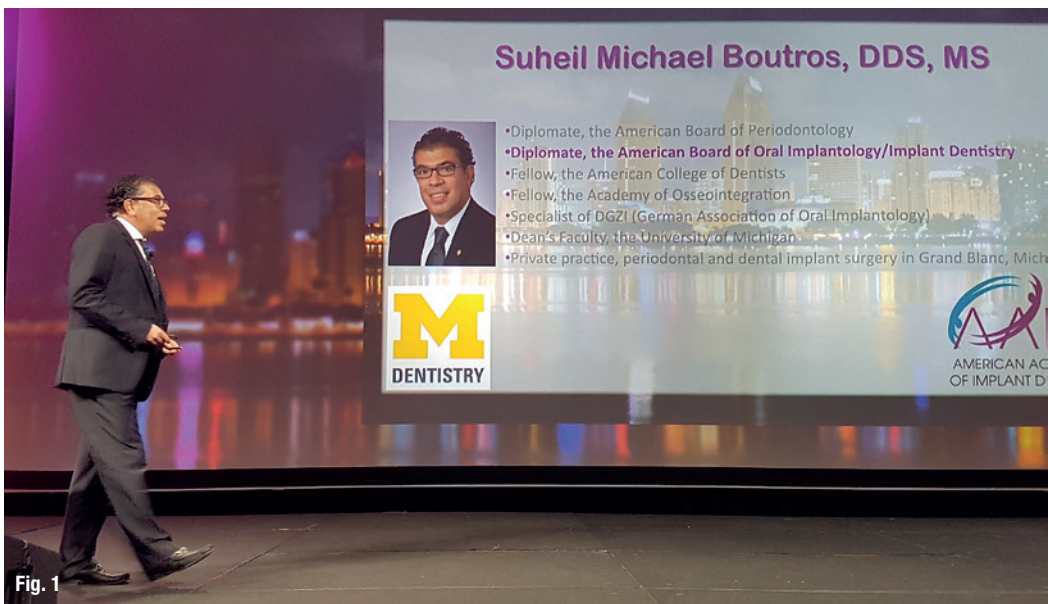

Fig. 1: Dr Suheil Boutros referred on "Narrow diameter implants for narrow ridges in the aesthetic zone" and the Trabecular Metal™ Technology.

Fig. 1



Fig. 2



Fig. 3

Fig. 2: During the exhibition, participants could examine some of the industry's most advanced and innovative tools and techniques.

Fig. 3: In another workshop, Dr Boutros offered practical exercises in implant bone management.

However, it seems that the risks of inserted titanium implants still remain underestimated. Titanium debris from the implant surface as result of frictional wear and corrosion (tribocorrosion) has been known for decades. Side effects from the incorporation of micro- and nanoparticles in biological systems has been mostly ignored, as titanium is widely considered to be inert. The chemically active metal ions or particles released from an implant surface, may bind to the surrounding tissues but may also bind to proteins, and be disseminated to distant organs in the vascular and lymphatic systems.

In this regard, research in human samples has shown the presence of titanium particles in:

- peri-implant tissue around failed human dental implants
- oral mucosa in contact with implant cover screws
- cells exfoliated from peri-implant oral mucosa around titanium dental implants
- reactive lesions in the peri-implant mucosa

In addition, the lecturers' studies in experimental animal models demonstrated a deposition of titanium microparticles (MPs) and nanoparticles (NPs) and the presence of a tissue response to these particle deposits. The development of special immune assays in the past ten years gave an insight into previously unknown immunological effects resulting from titanium wear debris. Histoimmunological stainings of peri-implant hard- and soft-tissue impressively confirm the presence of immune cells like macrophages, T- and B-lymphocytes reacting to disseminated titanium particles.

Local, as well as systemic immunological responses, by proliferation of phagocytosing cells and subsequent liberation of proinflammatory cytokines have been verified through specific laboratory immune assays. In this regard, results obtained in the clinical study confirmed a statistically significant higher amount of pro-inflammatory cytokine release in patients with failed implants than in those with

Fig. 4: Dr Alessandro Pozzi talked about "How to maximise function and aesthetics with a tilted minimally-invasive approach".

PROSTHETIC DESIGN	CONFIGURATION	AXIAL IMPLANT	ASW IMPLANT	PSW IMPLANT
TYPE 1 N°5		5	5	5
TYPE 2 N°2		4		2
TYPE 3 N°10		10	10	
TYPE 4 N°20				
	TOT			
AVERAGE TILTING DEGREE (SD)				

MINIMALLY INVASIVE TREATMENT OF THE ATROPHIC POSTERIOR MAXILLA: A PROOF-OF-CONCEPT PROSPECTIVE STUDY WITH A FOLLOW-UP OF BETWEEN 36 AND 54 MONTHS

Alessandro Pozzi, DDS, PhD, Giuseppe Sennino, DDS, and Alberto Barlattani, MD, MSc, PhD

University of Rome Tor Vergata, School of Dentistry, Rome, Italy

FOLLOW UP UP 3-5 YEARS > 10-YEAR
37 ATROPHIC POSTERIOR MAXILLA
81 IMPLANTS MINIMAL INVASIVE SURGERY
IMMEDIATE FUNCTION
IMPLANT SURVIVAL RATE 96.3%
PROSTHESIS SURVIVAL RATE 100%

Fig. 4





Fig. 5

Fig. 5: DGZI 1st Vice President Dr Rolf Vollmer, Prof. Dr Daniel Gustavo Olmedo, DGZI specialist Dr Elisabeth Jacobi-Gresser, Dr Frank Liebaug and DGZI international representative Dr Mazen Tamimi (from left).

long-term implant success. Moreover, multiple worldwide gene association studies have shown that individual genetic risk profiles, in respect to inflammatory high-responder reactions, influence long-term implant success. An adequate individual risk assessment should be considered before insertion of titanium devices or application of ceramic implants should be preferred.

Dr Jacobi-Gresser showed well-documented clinical case reports with immunological, genetic and histological findings and summarised: In respect to a specific immune reaction, titanium is—compared to other metals—well tolerated and does not induce allergies. Titanium, however can induce adverse signs of inflammation and lead to mucositis, peri-implantitis and peri-implant bone loss due to particle debris, mostly associated with bacterial adhesion. The reason of an individual titanium intolerance is an excessive, genetically determined proinflammatory reactivity of macrophages to corrosion particles. The microbiological risk is less on zirconia surface because the biofilm adhesion is less compared to titanium.

Lasting memories

Dr Alessandro Pozzi from Rome, Italy, presented the topic "How to maximise function and aesthetics with a tilted minimally-invasive approach". The computer-guided implant surgery introduced a minimally invasive concept in the treatment of partially or totally edentulous patients, with new perspectives based on bone graft-free rehabilitation and low morbidity implant surgery. Diagnostic data obtained from CBCT and extra- and intraoral optical surface scanning showed a different digital pathway based on facially driven virtual diagnostic waxing, prosthetically driven surgical plan, digitally printed surgical template, and prefabricated implant-supported screw-retained interim restorations. The challenging interplay with the surrounding gingival framework supported by tilted implants were emphasised through a step by step clinical protocol to deliver a

natural gingival architecture, a direct pink-free prosthetic emergence profile and learning to differentiate when immediate loading is feasible.

Dr Istvan Urban was the highlight of Saturday morning explaining "Vertical and Horizontal Ridge Augmentation". Dr Urban explained that vertical and horizontal augmentation presents one of the greatest challenges of bone regeneration in implant dentistry. Dr Urban recognised patient selection, patient preparation for surgery, precise surgical techniques, and postoperative management as the key factors in reducing the rate of bone graft complications. The detailed surgical anatomy of the floor of the mouth, the modified lingual flap, as well as the technique for protecting the mental nerve, was presented in detail. Recent research of the "Sausage Technique™" as well as minimally invasive soft tissue reconstruction were presented. Utilising these procedures may reduce the need of harvested autogenous bone and may generally lead to decreased morbidity, and therefore increased patient comfort and satisfaction associated with these regenerative procedures and keratinised tissue after ridge augmentation.

The participants liked wandering around not only at the welcome reception on Wednesday at sunset on the Hilton Bayfront's Promenade Plaza. They also enjoyed the reception and celebration of the leaving AAID President. It was easy to hear a wide variety of languages and accents engaged in lively discussions about implants, football, shopping, dining and everything else, with remaining memories for all.

contact

DGZI Central Office

Paulusstraße 1
40237 Düsseldorf, Germany
Tel.: 0211 16970-77
sekretariat@dgzi-info.de
www.dgzi.de

Hot programme for EAO meeting in Madrid

Source: Dental Tribune International



Under a blue Spanish sky and with temperatures soaring above 30 degrees, the 26th Annual Scientific Meeting of the European Association for Osseointegration (EAO) was held at the Feria de Madrid fairgrounds. Attendees had little time to enjoy the sun, however, as the event had plenty to offer from 5 to 7 October. With over 600 papers, guests could learn more about the latest concepts and clinical techniques in dental implantology and oral rehabilitation.

More than 50 clinical experts from all over the world were speaking at this year's event. Among them were prominent figures in dentistry, such as Prof. Mariano Sanz from Spain, Dr Christian Coachman from Brazil and Dr Christoph Hämmerle from Switzerland. In the guest country session, that was held on Saturday, clinicians from Latin America presented their research to a professional audience for the first time. While most of the papers had been delivered in English, they were simultaneous interpreted into Spanish for some of the sessions.

At the opening ceremony, EAO President Prof. Alberto Sicilia Felechosa welcomed everyone to this year's congress and thanked the Spanish society of

prosthodontic and aesthetic dentistry (Sociedad Española de Prótesis Estomatológica y Estética; SEPES) for co-organising the event. Over 4,000 dental professionals had registered for the three-day conference, which was in Spain for the second time since the first edition took place in 1992. Spanish attendees were then addressed by SEPES President and congress chair Dr Nacho Rodríguez Ruiz. Also during the ceremony, several members of the EAO were awarded honorary membership of the EAO, including past President Dr Franck Renouard from France.

In addition to the educational offering, attendees could try out the latest products and technologies in their field at the trade exhibition. Over 130 manufacturers and dealers, including international heavyweights like Nobel Biocare, Straumann and Dentsply Sirona, showcased their latest innovations. Attendees could also learn about products and clinical solutions at industry symposia running concurrently with the main programme.

Founded in 1991 by leading dentists interested in osseointegration, the EAO is now a worldwide authority in the fields of reconstructive surgery and prosthetic rehabilitation. In addition to its large annual event, the association holds master clinical courses throughout the year. It furthermore offers members and non-members the opportunity to obtain a post-graduate diploma in implant dentistry.

contact

EAO Office

38 rue de Croix des Petits Champs
75001 Paris, France
Tel.: +33 1 42366220
info@eao.org
www.eao.org

SUBSCRIBE NOW!

ceramic implants—international magazine of ceramic implant technology

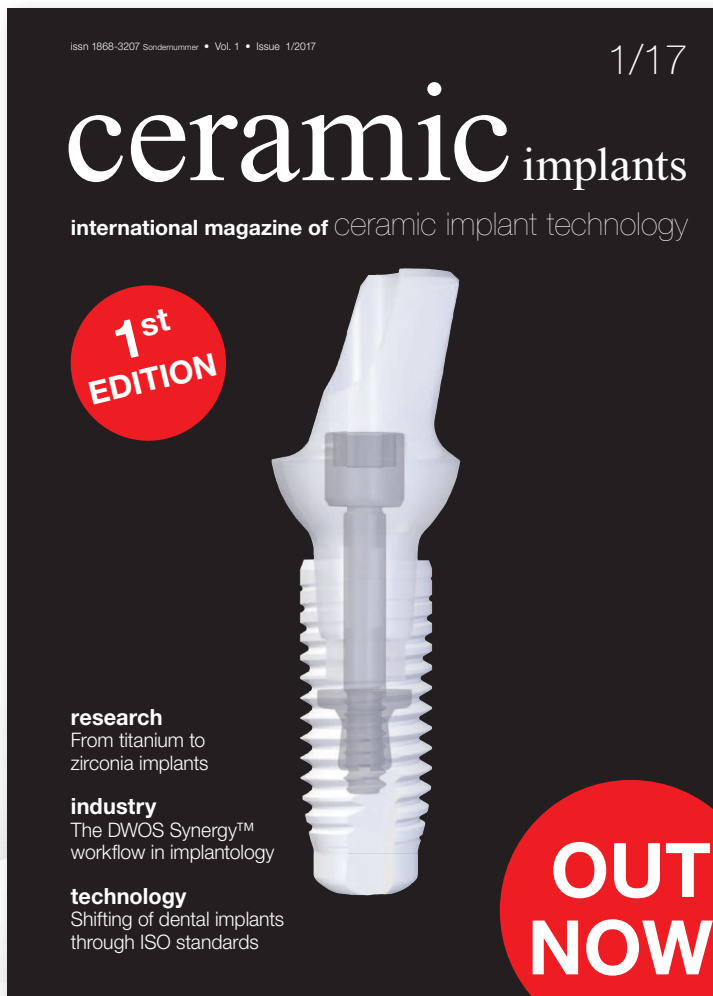Interdisciplinary, transparent & market orientated

ONLINE
SUBSCRIPTION HERE



www.oemus-shop.de

implants 4/17



stay updated:

research
From titanium to zirconia implants

industry
The DWOS Synergy™ workflow in implantology

technology
Shifting of dental implants through ISO standards



Fax: **+49 341 48474-290**

I would like to subscribe for the following journals:

- ceramic implants—international magazine of ceramic implant technology 2 issues p.a. € 30*
- implants—international magazine of oral implantology 4 issues p.a. € 44*

Terms & Conditions: The subscription may be cancelled in written form without due justification within 14 days of order by contacting OEMUS MEDIA AG, Holbeinstraße 29, 04229 Leipzig, Germany. Dispatching notification in good time will suffice. The subscription is automatically extended by another twelve months if it is not cancelled in written form 6 weeks prior to the end of the reference period.

* All prices include VAT, shipping and handling (within Germany).

Last Name, First Name

Company

Street

ZIP/City/Country

E-Mail

Signature

Credit Card Number

Expiration Date

Security Code



© ESB Professional/Shutterstock.com

“Science **meets** Practice”

Frankfurt Implantology Days 2018

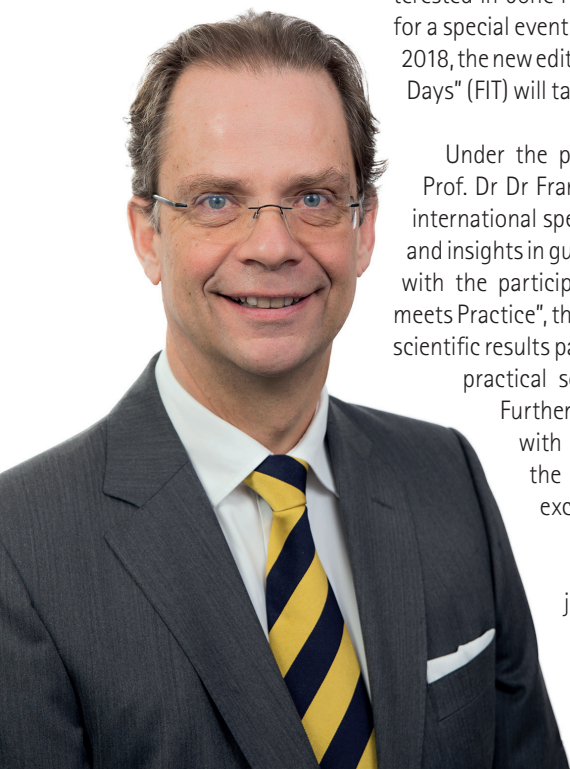Implantologists, maxillofacial or oral surgeons interested in bone regeneration should save the date for a special event in the upcoming year: On 28 April 2018, the new edition of the “Frankfurt Implantology Days” (FIT) will take place in Frankfurt/Main.



Under the proven scientific chairmanship of Prof. Dr Dr Frank Palm, Constance, Germany, 15 international speakers will share their experiences and insights in guided tissue and bone regeneration with the participants. Under the motto “Science meets Practice”, they are going to present their latest scientific results paired with clinical case reports and practical solutions for daily surgical work.

Furthermore, participants can network with like-minded colleagues and take the opportunity for an international exchange of experiences.

This CME-certified top-class event is supported by curasan AG, Germany. The full agenda and registration details can be found on the website www.curasan.com.



All interested can register and join an exciting educational event within international atmosphere where science meets practice.

Fig. 1: Prof. Dr Dr Frank Palm, scientific chairman of FIT.

contact

curasan AG
Lindigstraße 4
63801 Kleinostheim, Germany
Tel.: +49 6027 40900-51
ir@curasan.de
www.curasan.de

Info and registration



National and international colleagues could

Exchange at the DGZI Presidents Reception

At the eve of the 47th DGZI International Annual Congress, DGZI President Prof. Dr Herbert Deppe and the DGZI board invited more than 50 national and international partners to their "Presidents Reception". Participants from more than 15 countries followed this invitation. On Thursday evening, one day before congress opening, they gathered to meet colleagues from all over the world in a relaxed atmosphere. Representatives, speakers and participants had the unique opportunity to exchange experiences and discuss about current topics and the upcoming congress in a very special ambience. Many guests also took the chance for personal encounters, since they had been knowing each other for many years already. At the end of the reception, everyone agreed that this was a successful beginning of the DGZI Annual Congress 2017 in the German capital Berlin.



The Japanese delegation during the 47th DGZI Annual Congress.

Become a member of the DGZI!

Become a member of the German Association of Dental Implantology (DGZI) under www.dgzi.de/ueber-uns/mitgliedschaft or scan the adjacent QR code.

Application form



Study details poor

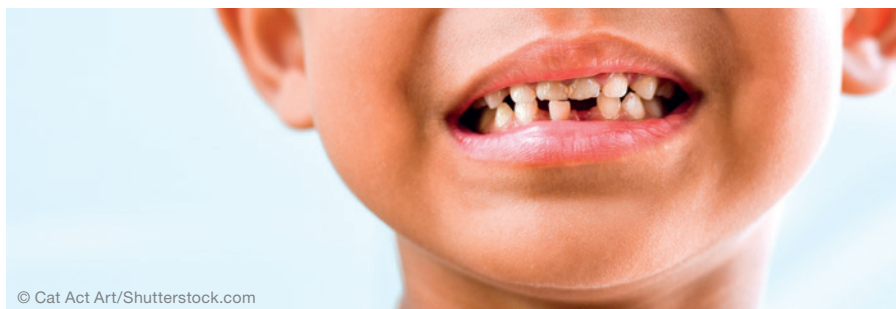Oral health status of refugees

Since 2015, a large number of refugees have made their way to Europe. Coming from countries in which public dental care is often not freely accessible and where oral healthcare is not as much of a focus as it is in most parts

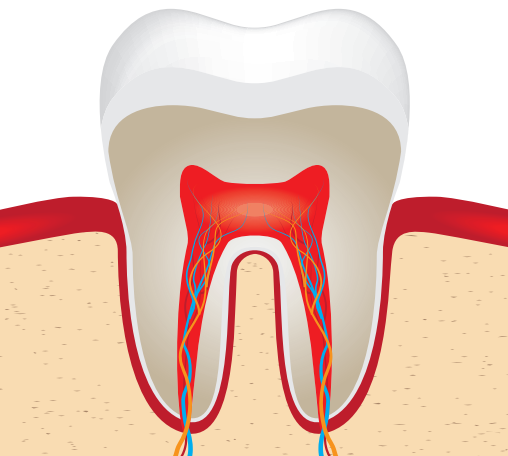
of western Europe, the majority of them are in significant need of information and treatment. Researchers at the University of Greifswald in Germany have examined more than 540 refugees and found that the overall oral health sta-

tus of children and adolescents was comparable to that of Germans 30 years ago. In adults, several untreated carious defects were found. Only 35 per cent of the 12-year-olds still had a healthy natural permanent dentition, while this was the case for 80 per cent of this age group in Germany.

With reference to the study data, the researchers estimated that the cost of treatment for full oral rehabilitation, including all dental specialties, would be between 178 and 1,759 Euro per refugee. To address prevention gaps and to counteract the high caries rates, the researchers advised, among other things, the expansion of prophylactic measures under the German Asylum Seekers Benefits Act.



© Cat Act Art/Shutterstock.com



© OrelPhoto/Shutterstock.com

Dentists successfully extract

Stem cells from third molars

Few discoveries hold as much promise of single-handedly expanding medical treatment options as stem cells do. Now, researchers from the University of Nevada, Las Vegas, (UNLV) have developed a new method for extracting tooth root pulp from the third molars that quadruples the number of stem cells that can be harvested and replicated to treat a variety of medical conditions.

Having solved the challenge of accessing the root pulp, the researchers sought to determine how many viable stem cells they could recover from the fractured teeth. They dyed 31 fractured teeth pulp samples to highlight any viable stem cells the teeth contained. Dead cells would turn blue when exposed to the dye and living cells would appear clear. Under the microscope, 80 per cent of their extracted cells remained clear after the dye was introduced.

Next, the team isolated the stem cells from the rest of the root pulp. The researchers harvested cells from the pulp and cultured them on a petri dish. Once the cells had covered the dish, they split the culture in half and repeated the process between ten and 20 times. By the end of the culturing, all non-stem cells had expired. The researchers captured the remaining stem cells and collected their RNA, which is converted into proteins that become biomarkers the team could use to characterise each stem cell type and its respective rate of replication.

The next logical step in this research would be to test stem cells in humans to treat chronic illnesses such as Alzheimer's or Parkinson's disease.

Little clinical benefit through untargeted


Provision of vitamin D supplements

An international study of older adults has found that mass, untargeted provision of vitamin D supplements provides little clinical benefit to many when it comes to the common bone disease, osteoporosis. Instead, the study recommends targeting vitamin D supplements at individuals whose levels of this vitamin are markedly reduced. The study was carried out by researchers at the University of Auckland, New Zealand, and Harvard Medical School, Boston, USA.

The study was part of a bigger trial among community-resident adults aged 50–84 years, and followed 418 participants for two years, who were randomised to receive, monthly, either high oral doses of vitamin D or a placebo. The researchers were looking at changes over time to bone density in their lower spines, primarily, and in other

commonly tested sites on the body. They were also testing thresholds in the levels of vitamin D already present in the participants and found that that level was significant when it came to the effect of the vitamin D treatment.

The researcher concluded that future trials of vitamin D supplements in older adults should focus on those who have baseline vitamin D levels equal to or below 30 nmol per litre.



© Aleksandra Gigowska/Shutterstock.com

Nobel Biocare and Dentalpoint AG

Entering into a partnership

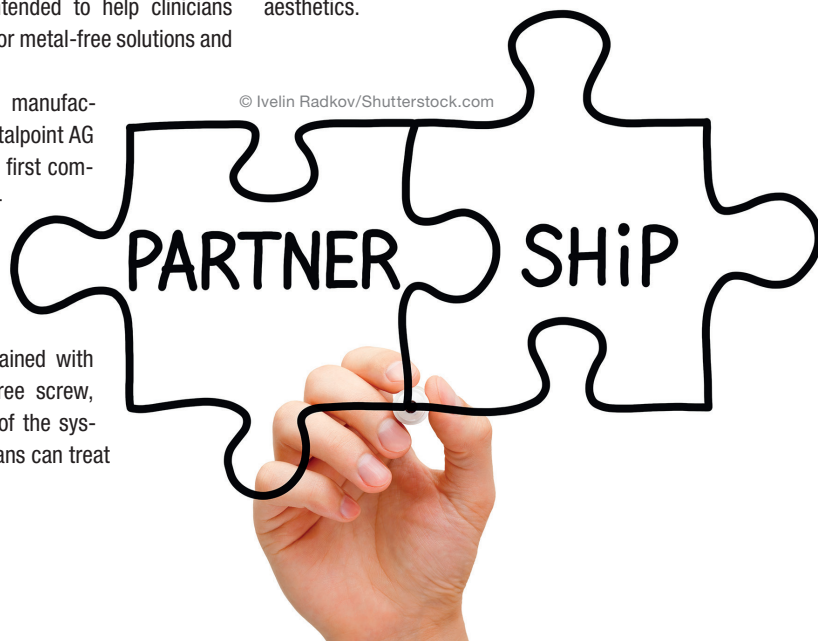At the 2017 European Association of Osseointegration (EAO) Congress in Madrid, Spain, Nobel Biocare announced it has entered into a partnership agreement with Dentalpoint AG, a leader in ceramic dental implants, to add a zirconia implant solution to its portfolio.

The partnership with Dentalpoint AG will add a new implant option to Nobel Biocare's leading range of titanium dental implants with the clinically proven TiUnite surface. The innovations from Dentalpoint AG, known for its ZERAMEX® implant brand, are intended to help clinicians meet patient demand for metal-free solutions and high-end aesthetics.

Utilising breakthrough manufacturing technology, Dentalpoint AG is the developer of the first completely metal-free two-piece bone level implant system with internal connection that is not dependent on cement. Screw-retained with an innovative metal-free screw, the two-piece nature of the system means that clinicians can treat

patients with a zirconia implant using protocols similar to those they are familiar with for traditional implants. It also offers greater restorative flexibility compared with existing one-piece or cement-retained ceramic implant options.

A solution featuring this first-of-a-kind technology will be available from Nobel Biocare in early 2018. The introduction of a ceramic implant further extends Nobel Biocare's comprehensive range of innovative solutions for immediate function and excellent aesthetics.




© Ivelin Radkov/Shutterstock.com

New technique aims to

Simplify dental bone graft procedures

It is a common issue that, when performing a bone graft, the graft material will lose its shape during the suturing of the soft tissue. This complication can be prevented with the use of “tenting” screws or tacks to help keep the graft in place. To avoid additional surgeries and increased treatment costs, researchers from the University of Minnesota, Minneapolis, along with the Implant Cosmetic Dental Center in Silver Spring, have introduced a new surgical technique for closing the grafted area.



© AleksKey/Shutterstock.com

Termed the Continuous Periosteal Strapping Suture (CPSS) technique, this method uses resorbable sutures and membrane, materials that can be resorbed and assimilated into the body. If implemented correctly, CPSS requires a less complex surgical procedure than currently available techniques. This simpler procedure leads to lower overall treatment costs.

The technique used by the researchers relies on resorbable sutures and membrane and does not include any surgical screws or tacks to help keep the graft in place. Instead, a series of intricate knots made with resorbable sutures surrounding the membrane are used. The knots help to maintain the strength of the sutures, creating a firmer hold on the wound closure area. With the use of resorbable materials, the need for a separate surgery to remove “tenting” screws or tacks can be eliminated.

Dental Wings becomes

A fully-owned Straumann Group

The shareholders of Dental Wings Inc. (Montreal, Canada) have signed an agreement to sell their remaining shares in the company to Straumann Holding AG (Basel, Switzerland). As a result, Dental Wings will become a fully-owned Straumann Group company.

Group. The energy and passion for digital dentistry has never been stronger at Straumann, so the future is very bright for Dental Wings,” said Dental Wings’ Founder, Naoum Araj.

Dental Wings will be a core component in the new Digital Business Unit that Straumann is establish-



Dental Wings products and services will be sold under the Dental Wings, Straumann, and other brands—as they are today—by Straumann and the Dental Wings network of distribution partners around the world.

“Our long-term partnership with Straumann has been exceptional on every level and we are both proud and pleased to become part of the Straumann

ing under the leadership of Michael Rynerson, who is transitioning from his role as CEO of Dental Wings. This will be one of the most dynamic digital dental teams worldwide, incorporating all aspects of the business: software, scanners, information systems, milling equipment, materials, design services, and production centres active on a global scale.

Intake of caffeine may

Trigger sugar cravings

Caffeine is a powerful antagonist of adenosine receptors, which promote relaxation and sleepiness. Depressing the effect of the receptors may make people feel more awake, but research has found that it also decreases their ability to taste sweetness—making food and drink seem less sweet, resulting in an increased temptation for sweets.

The study, conducted at Cornell University, demonstrates taste modulation in the real world, said senior author Dr Robin Dando, from the Department of Food Science. “When you drink caffeinated coffee, it will change how you perceive taste. So if you eat food directly after drinking a caffeinated coffee or other caffeinated drinks, you will likely perceive food differently.”

In the blind study, one group sampled decaffeinated coffee with 200 mg of caffeine added in a



© Scorpp/Shutterstock.com

laboratory to make the beverage equivalent to a strong cup of coffee and thus consistent with real-life amounts of caffeine. The other group drank decaffeinated coffee containing an equally bitter concentration of quinine. Both groups had sugar added. In a second session on a separate day, the groups were alternated. Panelists rated the caffeinated brew as less sweet but didn’t report on the effect on bitter, sour, salty or umami perception.

Congresses, courses and symposia



MIS Global Conference 2018

8–11 February 2018
Venue: Nassau, Paradise Island, Bahamas
bahamas.mis-implants.com



4th BEGO Implant Systems Global Conference

9–10 February 2018
Venue: Dubai, UAE
www.art-of-implantology.com



Oral Reconstruction Global Symposium 2018

26–28 April 2018
Venue: Rotterdam, Netherlands
symposium2018.orfoundation.org



EuroPerio9

20–23 June 2018
Venue: Amsterdam, Netherlands
www.efp.org/europerio9



4th Annual Meeting of ISMI

22–23 June 2018
Venue: Hamburg, Germany
www.ismi.me

implants

international magazine of oral implantology



Deutsche Gesellschaft für
Zahnärztliche Implantologie e.V.



Imprint

Publisher

Torsten R. Oemus
oemus@oemus-media.de

CEO

Ingolf Döbbecke
doebbecke@oemus-media.de

Members of the Board

Jürgen Isbaner
isbaner@oemus-media.de

Lutz V. Hiller

hiller@oemus-media.de

Chief Editorial Manager

Dr Torsten Hartmann (V. i. S. d. P.)
hartmann@dentalnet.de

Editorial Council

Dr Rolf Vollmer
info.vollmer@t-online.de

Dr Georg Bach

doc.bach@t-online.de

Dr Roland Hille

dr-hille@t-online.de

Dr Suheil Boutros

SMBoutros@aol.com

Editorial Office

Georg Isbaner
g.isbaner@oemus-media.de

Katrin Maiterth

k.maiterth@oemus-media.de

Executive Producer

Gernot Meyer
meyer@oemus-media.de

Product Manager

Timo Krause
t.krause@oemus-media.de

Designer

Sandra Ehnert
s.ehnert@oemus-media.de

Theresa Weise

t.weise@oemus-media.de

Customer Service

Marius Mezger
m.mezger@oemus-media.de

Published by

OEMUS MEDIA AG
Holbeinstraße 29
04229 Leipzig, Germany
Tel.: +49 341 48474-0
Fax: +49 341 48474-290
kontakt@oemus-media.de

Printed by

Silber Druck oHG
Am Waldstrauch 1
34266 Niestetal, Germany

implants

international magazine of oral implantology is published in cooperation with the German Association of Dental Implantology (DGZI).

DGZI

DGZI Central Office
Paulusstraße 1
40237 Düsseldorf, Germany
Tel.: +49 211 16970-77
Fax: +49 211 16970-66
office@dgzi-info.de

www.dgzi.de

www.oemus.com

www.implants.de

Copyright Regulations

implants international magazine of oral implantology is published by OEMUS MEDIA AG and will appear in 2017 with one issue every quarter. The magazine and all articles and illustrations therein are protected by copyright. Any utilization without the prior consent of editor and publisher is inadmissible and liable to prosecution. This applies in particular to duplicate copies, translations, microfilms, and storage and processing in electronic systems. Reproductions, including extracts, may only be made with the permission of the publisher. Given no statement to the contrary, any submissions to the editorial department are understood to be in agreement with a full or partial publishing of said submission. The editorial department reserves the right to check all submitted articles for formal errors and factual authority, and to make amendments if necessary. No responsibility shall be taken for unsolicited books and manuscripts. Articles bearing symbols other than that of the editorial department, or which are distinguished by the name of the author, represent the opinion of the afore-mentioned, and do not have to comply with the views of OEMUS MEDIA AG. Responsibility for such articles shall be borne by the author. Responsibility for advertisements and other specially labeled items shall not be borne by the editorial department. Likewise, no responsibility shall be assumed for information published about associations, companies and commercial markets. All cases of consequential liability arising from inaccurate or faulty representation are excluded. General terms and conditions apply, legal venue is Leipzig, Germany.



Straumann® BLT Ø 2.9 mm – the SmallOne
Another legend is born:
Small, strong and enduring.



LESS INVASIVE*

A perfect combination of shape, strength and healing power.



NATURAL LOOKING ESTHETICS

Novel prosthetic design that closely matches the anatomy of teeth.



FULL STRENGTH

A strong and reliable treatment option thanks to Roxolid®.



Contact your local Straumann® representative today to find out more about the SmallOne. Or visit smallone.straumann.com.

*if GBR can be avoided



Redefine possibilities

Trefoil™ – the next full-arch revolution

The new Trefoil system makes definitive teeth possible in just one day.*

Discover groundbreaking engineering, created with the needs of the many in mind, that enables passive fit with a pre-manufactured bar and unique adjustable fixation mechanism.

nobelbiocare.com/trefoil



*Depending on clinician preference and close cooperation with the laboratory.
GMT 53206. Disclaimer of liability: This product is part of an overall concept and may only be used in conjunction with the associated original products according to the instructions and recommendation of Nobel Biocare. Non-recommended use of products made by third parties in conjunction with Nobel Biocare products will void any warranty or other obligation, express or implied, of Nobel Biocare. The user of Nobel Biocare products has the duty to determine whether or not any product is suitable for the particular patient and circumstances. Nobel Biocare disclaims any liability, express or implied, and shall have no responsibility for any direct, indirect, punitive or other damages, arising out of or in connection with any errors in professional judgment or practice in the use of Nobel Biocare products. The user is also obliged to study the latest developments in regard to this Nobel Biocare product and its applications regularly. In cases of doubt, the user has to contact Nobel Biocare. Since the utilization of this product is under the control of the user, it is his/her responsibility. Nobel Biocare does not assume any liability whatsoever for damage arising thereof. Please note that some products detailed in this Instructions for Use may not be regulatory cleared, released or licensed for sale in all markets. As such, provided patient criteria are met and adequate primary stability is achieved, Nobel Biocare implants allow a fixed provisional restoration to be loaded on the day of surgery.



- ISO: 8, 10, 15, 20, 25, 30, 35, 40, 45, 50, 55, 60, 70, 80, 90, 100, 110, 120, 130, 140
- Non-Standardized (Accessory sizes): XF, FF, MF, F, FM, M, ML, L, XL
- Special Taper Points: 04, 06

گوتا فقط متا

✓ انعطاف پذیری بسیار بالا در حین کار

✓ پرفروش ترین در جهان

✓ رادیو اپستی عالی

✓ بی رقیب در قیمت و کیفیت

✓ مناسب جهت پر کردن کانال به روش تراکم جانبی و عمودی

✓ با بهترین بسته بندی ضد ریزش برای کاربری آسان



کن کاغذی

موجود در انواع سایزها با قدرت جذب بالا، استریل و فاقد لینت
در بسته بندی ۲۰۰ عددی گشویی ضد ریزش