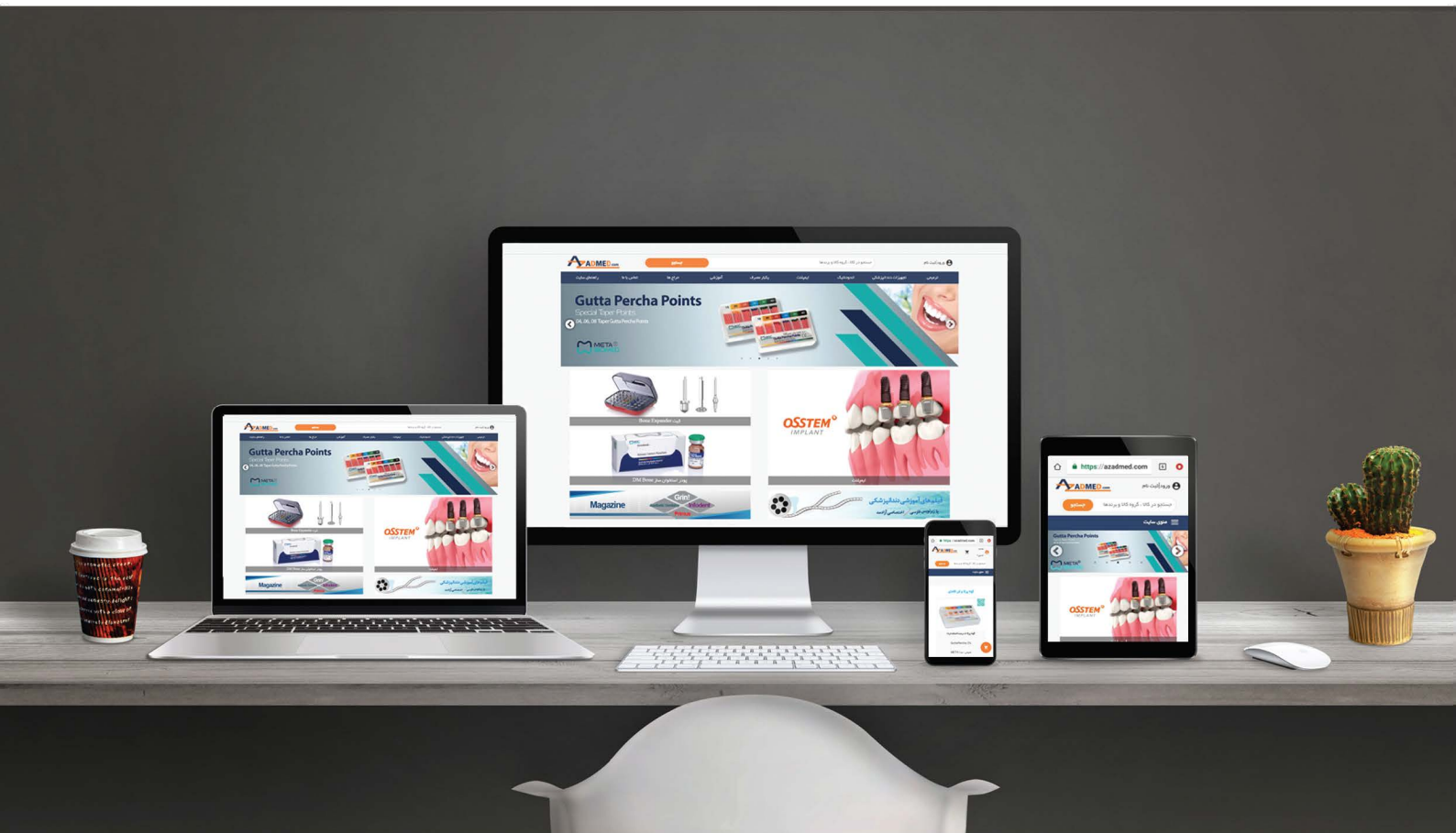




آزاد تجارت پارس  
AZAD TEJARAT PARS.LTD

**AZADMED.com**



[www.azadmed.com](http://www.azadmed.com)



 azaadtejaratpars

 @azadmed2

 88 98 80 63 - 6

# laser

international magazine of laser dentistry

3<sup>2010</sup>




| **research**  
Frenectomy review

| **interview**  
“A man alone cannot do anything”

| **social news**  
AALZ Greece successfully established

0277113





When I bought my Fidelis my colleagues told me Fotona never stops innovating. They never stop pushing the boundaries of laser dentistry. How right they were! I've just started working with my new set of **Preciso endodontic and Varian periodontic** fiber tips. Both are fully compatible with the **AT/HT Fidelis Er:YAG laser**. I can now choose from almost 20 fiber tips to make my hard and soft tissue treatments less invasive, more effective and to reduce my patients' chair time.



Fotona user since 2000

**NEW**

**Fotona**  
choose perfection

## AT Fidelis Highest Performance in Dental Care

### Revolutionizing Dentistry

The AT Fidelis is Fotona's newest generation in dental laser systems. With dentistry's two best lasers in one system, you can provide the ultimate in dental care! AT Fidelis' Er:YAG, the world's fastest drilling, hard tissue laser, features broadened soft tissue surgery capabilities with the finest low pulse, high repetition rates. Its top-of-the-line Nd:YAG laser provides trouble-free endodontic, surgical and aesthetic procedures. Both lasers feature VSP technology, enabling controlled and constant laser intensities, in an unprecedented five, selectable pulse duration modes.

### Convenience and Safety First

The AT Fidelis includes the newest Comfort Mode touch screen navigation system. Its pre-set treatment programs and data storage facility offer ultimate treatment management. Selecting the right treatment settings has never been easier!

Its Advanced Mode enables users to quickly fine-tune procedures through its all-encompassing interface. The AT Fidelis offers the industry's only Tissue effect Graphical Interface (TeGI) which provides precise graphical representations of laser-tissue effects as treatment settings are changed. For improved user comfort, the AT Fidelis features a wireless footswitch. While ESC Technology allows you to perfect water and air spray mixes, the AT Fidelis does not require external air or water sources, making it uniquely mobile.

### Unlimited Possibilities!

Apart from providing the widest range of hard and soft tissue dental treatments, you can also upgrade your system with aesthetic upgrade packages. This enables you to provide aesthetic treatments ranging from facial laser hair removal and rejuvenation treatments to facial vascular treatments.



**The Highest Performance, Best Made Laser Systems in the World**

Put a smile on your patients' faces!  
Visit [www.fotona.com](http://www.fotona.com) now!



Prof Dr Norbert Gutknecht  
WFLD President  
Editor-in-Chief

# Laser—useful and reasonable

„Laser is not only an expert medical or dental discipline, but also a technology which, thanks to its versatility, can be applied on its own or in addition to other treatments for a variety of different medical and dental purposes. Moreover, there is not just "the one and only laser", but lasers of different wavelengths. Since students do not learn anything about laser application during their studies, e.g. that laser application is based on biophysical light-tissue interactions, it is highly important for every responsible dentist to acquire the necessary knowledge about lasers.

Integrative laser technology, applied in responsible dentistry, is a useful and reasonable complement to treatment of patients in most other disciplines, and it often leads to a less painful, minimally invasive and all-round more successful treatment.

Prof. Dr. Norbert Gutknecht  
-President of DGL-

AD



**LASER...INNOVATION**  
MADE IN GERMANY

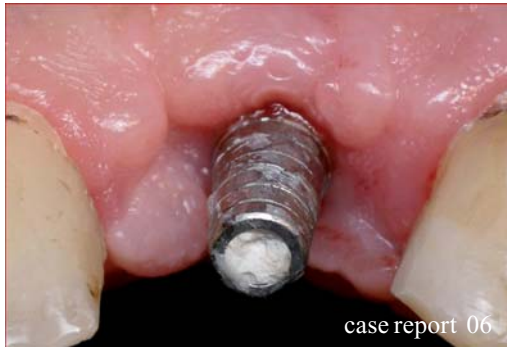The new **FOX**

- > Endodontics
- > Periodontics
- > Implantology
- > Surgery
- > Whitening
- > Biostimulation

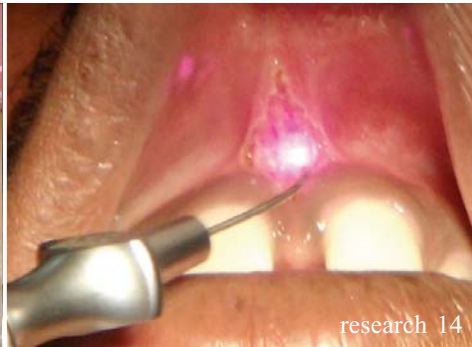

[www.arclaser.de](http://www.arclaser.de)

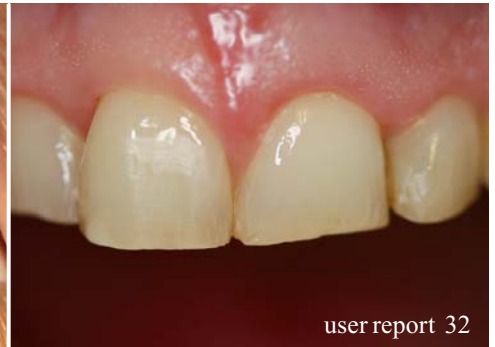



case report 06



research 14



user report 32

| editorial

- 03 **Laser**—useful and reasonable  
| Prof Dr Norbert Gutknecht

| laser

- 32 “A man alone cannot do **anything**”  
| Kristin Urban

| case report

- 06 **The use of the Er:YAG in laser-assisted broken abutment screw treatment**  
| Avi Reyhanian, Steven Parker, Joshua Moshonov, Natan Fuhrman
- 12 **Laser phototherapy in Bell’s palsy**  
| Prof Aparecida Maria Cordeiro Marques, Luiz Guilherme Pinheiro Soares, Dr Cristina Maria do Nascimento, Alberto de Aguiar Pires Valença Neto, Roberta Cordeiro Marques, Dr Antonio Luiz Barbosa Pinheiro

| social news

- 34 **2010—A breakthrough for Laser Supported Dentistry in Sweden**  
| Dr Peter Fahlstedt
- 36 **AALZ Greece successfully established**  
| Dimitris Strakas, Dominique Vanweersch

| research

- 14 **Frenectomy review**  
| Dr M. L. V. Prabhuji, Prof Dr Madhu Preetha, Dr Ameya G. Moghe

| meetings

- 38 **International events 2010–2012**
- 40 **XII<sup>th</sup> International Congress of the WFLD in Dubai**  
| Prof Toni Zeinoun
- 44 **Laser dentistry and Implantology Symposium in Gaziantep a great success!**  
| Leon Vanweersch
- 46 **“Tomorrow’s dentistry today”**  
| Ralf Borchert

| user report

- 20 **The minimalinvasive laser surgical crown lengthening**  
| Dr Thorsten Kuypers
- 24 **The clinical use of the Er,Cr:YSGG laser in endodontic therapy**  
| Justin Kolnick
- 28 **Er,Cr:YSGG laser assisted GTR in periodontal surgery**  
| Dr Elena Speranza Moll

| news

- 48 **Manufacturer News**

| about the publisher

- 49 | submissions
- 50 | imprint



social news 38



meetings 44



meetings 46



Just 115 x 90 x 28 mm: the claros pico®

“elexxion’s latest development is absolutely brilliant.

It’s exactly what practitioners like us need!”

It’s here! elexxion, the global technology leader for high-quality dental lasers, is presenting the claros pico® for professionals.

The claros pico® is an absolutely full-featured, professional-standard dental laser that comfortably fits in one hand. With its lithium ion technology, it offers all the mobility that modern practices demand.

What does that mean for you on the front line? With the claros pico® you’ll be getting a diode laser that opens up new treatment possibilities in endodontics, periodontics and soft tissue surgery at the “push of a button”. You’ll be able to treat numerous indications more effectively - and give your practice a new competitive edge in the process. And, needless to say it boasts a laser bleaching function that your assistants can use on their own.

For more information about the brand new claros pico® please visit our website.

elexxion AG  
Schützenstrasse 84  
78315 Radolfzell  
Germany

[www.elexxion.com](http://www.elexxion.com)

**elexxion AG**

Dental-Laser

# The use of the Er:YAG in laser-assisted **broken** abutment screw treatment

**Authors** \_Avi Reyhanian, Israel, Steven Parker, United Kingdom, Joshua Moshonov, Israel, Natan Fuhrman, Israel

## Abstract

Dental implants are a functional and aesthetic solution to partial and total edentulism. Although the overall success rate of implant dentistry is very high, over 90% of the treatment modality is not free of complications and dental implants occasionally fail. The chronic loosening or fracturing of implant screws continue to be a problem in restorative practices and generally are challenging to remove. This report describes and demonstrates the management and technique used for the removal of fractured screw fragments and the successful utilization of the Er:YAG laser as an important auxiliary tool.

## Introduction—the problem

Success in implant-supported prosthetic replacement of teeth will be due to a combination of appropriate placement criteria (receptor site quality, implant stability, osseointegration), appropriate (non-excessive) loading and prevention of bacterial contamination. The failure of dental implants is due not only to biological factors, such as unsuccessful osseointegration or the development of peri-implantitis, but it may also result from technical complications.<sup>1,2</sup> Den-

tal implant complications may be considered under the following main categories:

### *Early*

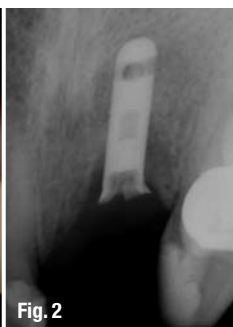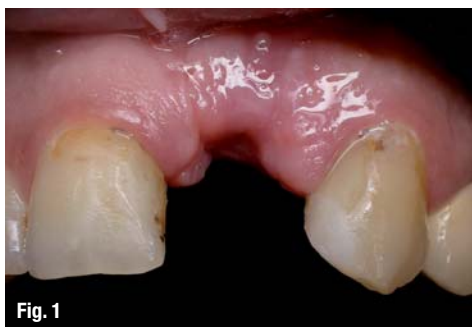- \_ Failure/inadequate surgical preparation.
- \_ Failure of osseointegration.
- \_ Peri-surgical infection.

### *Late*

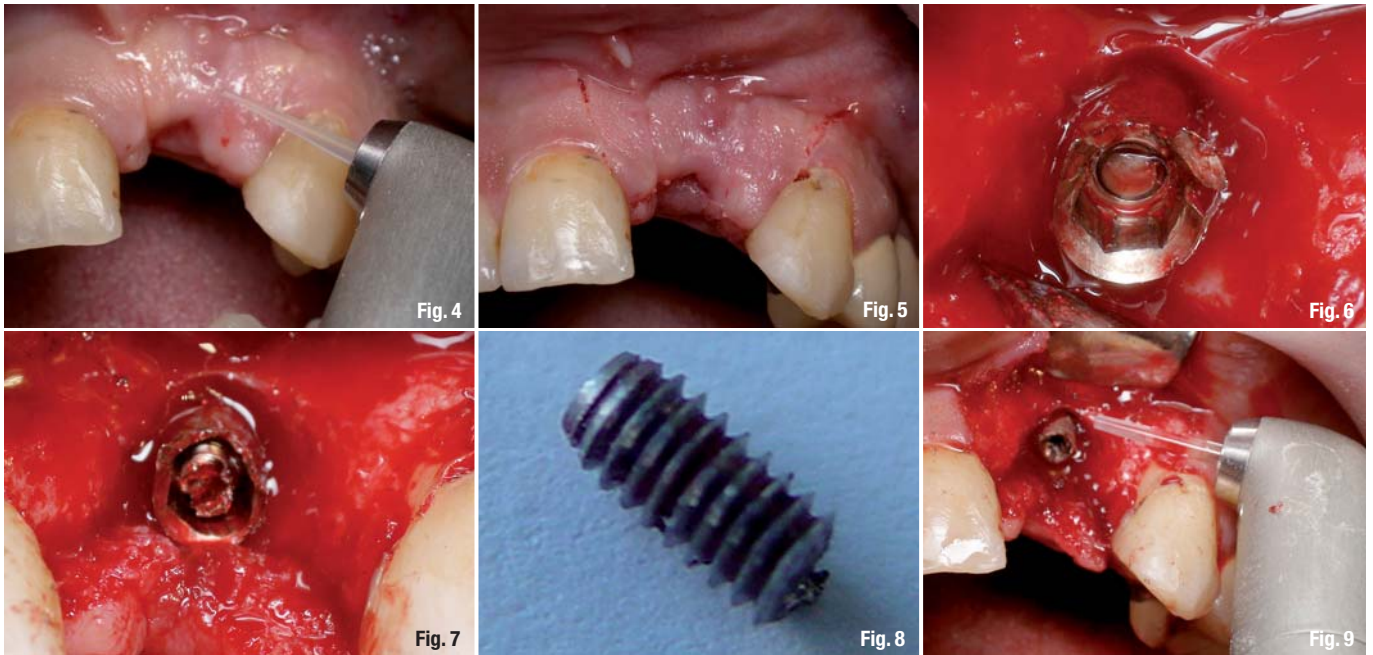
- \_ Implant overloading, leading to bone loss.
- \_ Peri-implantitis.
- \_ Soft tissue complications.
- \_ Fracture of mechanical components and aesthetic/phonetic considerations.

Failures of implant-supported restorations result from technical problems and can be divided into two groups: those relating to implant components, and those relating to the prosthesis.<sup>3,4,5,6,7,8,9,10,11</sup> Technical problems related to implant components include abutment screw fracture.<sup>8,12</sup>

The abutment screw fracture presents a rare, but quite unpleasant failure and can be a serious problem<sup>13,14</sup>, as the fragment remaining inside the implant may prevent the implant from functioning efficiently







as an anchor.<sup>15</sup> The primary reason for screw fracture is undetected screw loosening which can be due to bruxism, an unfavorable superstructure, overloading<sup>16,17</sup> or malfunction.<sup>10,11,18,19</sup> Fractures of the implant abutment or of the abutment screw have been observed as a consequence of screw loosening and undetected micro-movements of the abutment under functional loading<sup>20</sup> and consequently, it is advised that the repeated loosening of an abutment screw should alert the clinician to possible significant contributing causes.

However, the behavior of the implant/abutment joint components with respect to critical bending force is still unclear.<sup>20,21</sup> Studies show that implant abutment failure occurs when lateral forces exceed 370 Newtons for abutment with a joint depth of at least 2.1 mm and 530 Newtons with a joint depth of at least 5.5 mm.<sup>7</sup>

### Preventive recommendations

- The number, position, dimension and design of implants, as well as the design of the prosthesis are critical factors to be considered during the treatment planning phase.<sup>11,12,13,22,23</sup> To withstand high bending stresses, implants should be as long and as wide as possible, used in adequate numbers, and be positioned such as to allow axial loading.<sup>13,20,24,27</sup> Implant components are known to fracture more frequently in the posterior region and in partially dentate patients compared to completely edentulous patients.<sup>5,6,9,11,12,19,23,25</sup>
- Retightening an abutment screw ten minutes after the initial torque applications should be routinely performed, and increasing the torque value for abut-

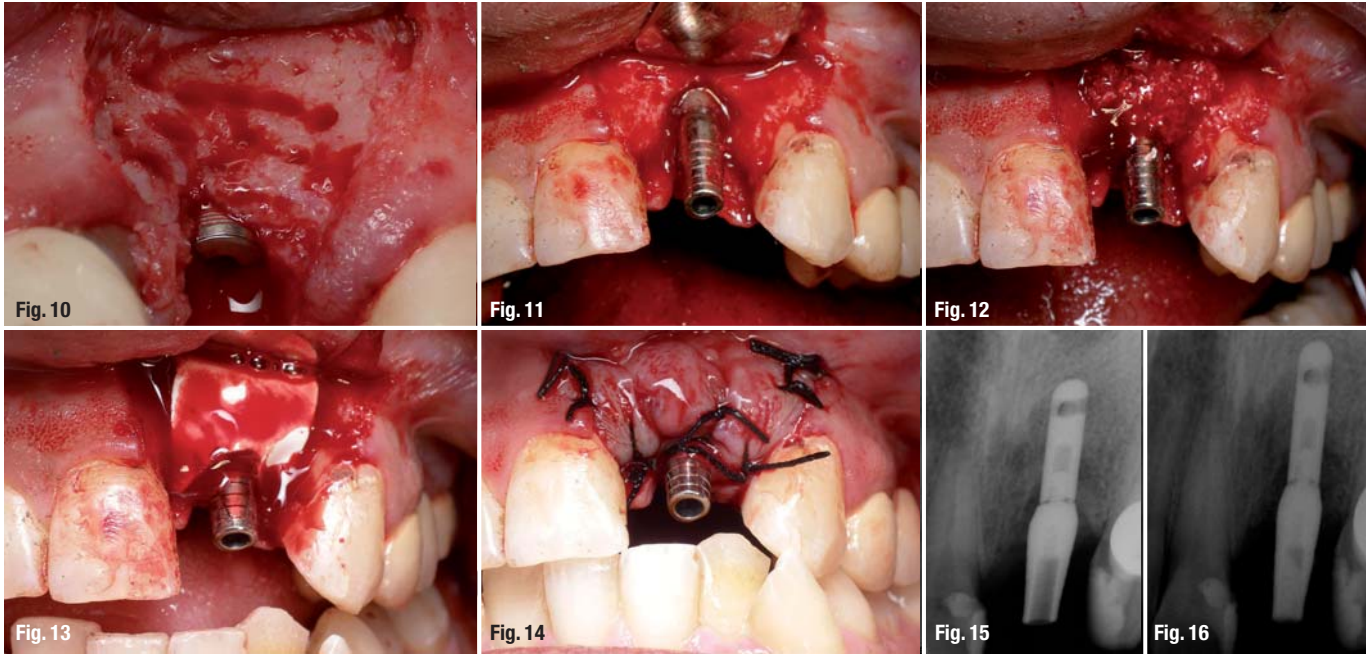
ment screws above 30 Newtons can be beneficial for the abutment, implant stability and to decrease the possibility of the screw becoming loose.<sup>25</sup>

- Proper case selection, excellent surgical technique, placing an adequate restoration on the implant, educating the implant patient as to the importance of maintaining meticulous oral hygiene, and evaluating the implant both clinically and radio-graphically at frequent recall visits<sup>26</sup>; reinforcing periodic maintenance.
- A procedure for using dimples inside the abutment screw cylinder above the screw, and filling the holes with elastomeric impression material will prevent the screw-retained prosthesis from loosening.<sup>27</sup>
- Using the correct fixation screw.
- Replacing loose screws instead of retightening them.
- Immediate investigation; looseness of the prosthesis is detected by the clinician or patient.<sup>28,29</sup>

### Fragment retrieval methodology

The methods employed to grasp the broken fragments or screw are determined according to the location of the fracture abutment—above or below the head of the implant. If an abutment screw fractures above the head of the implant, an explorer, a straight probe or haemostats<sup>30</sup> might be successful. The tip of the instrument is moved carefully in a counter-clockwise direction over the surface of the screw segment until it loosens.<sup>1</sup> If the screw fracture occurs below the head of the implant, other methods are required. There are several available implant repair kits:

- ITI® Dental Implant System (Institut Straumann AG, Switzerland), consists of drills, two drill guides and six manual tapping instruments.<sup>8</sup>



- \_ IMZ®TwinPlus Implant System<sup>1</sup> (DENTSPLY Friadent, Germany)
- \_ Screw Removal Kit Replace (Nobel Biocare™, Yorba Linda, California, USA)
- \_ Certain®-Screw Removal Kit (Biomet 37™, Florida, USA<sup>3</sup>)

The application of these systems is to permit a hole to be drilled into the centre of the broken screw and drive a removal wedge into the hole that engages the broken screw when reverse torque is applied by removing the instrument.

If no thread damage has occurred and the screw has not "bottomed out" or torqued into a seating stop, then the force necessary to remove the screw may be minimal.<sup>8</sup> If none of these systems is available, another method for broken screw retrieval involves the following procedure: after the prosthesis or abutment is removed, the screw hole is vigorously flushed with an air/water spray from a 3-way syringe. Pressurized air is applied to dry the screw hole, and a drop of mineral oil (delivered on the tip of an explorer) is introduced into the screw hole. A sharp 1/4-round bur in a high-speed handpiece is activated and lightly applied to the exposed side of the fractured screw. The objective is to have the spinning bur's blades contact the metal surface of the screw so that the screw will spin itself out of the hole. When repeated several times, the screw can be backed out and retrieved easily with forceps.<sup>8</sup>

If this technique fails, a slot can be created using a surgical drill, on the head of the fractured screw, and then a screwdriver is used to back out the broken abutment screw. Sometimes just a gentle touch with

the drill to the head of the broken screw will be enough to back it out. If the hexagonal head of the screw is stripped, it should be filed away completely using a round carbide bur or heatless stone, the head of the implant should be straightened, and a new abutment may be rotated into the implant.

### Case study

This clinical report describes a situation in which a fractured implant abutment screw was successfully retrieved by using the Er:YAG laser as an auxiliary tool, and the advantages of this 2,940 nm wavelength versus conventional methods.

### Examination

A 36-years-old male presented for treatment, reporting the detachment of an implant-supported crown in the region of the upper left central incisor. The patient stated that the implant and crown had been placed four years earlier and that looseness of the crown had occurred on two occasions during this period. On both occasions, the screw had been re-tightened with no further investigation.

Clinical examination of the patient revealed a missing tooth at the location of #9 with no sign of an implant (Fig. 1). The patient brought the abutment, crown and broken screw with him (Fig. 3). Radiographic examination of the area showed the presence of a root-form cylindrical implant, consistent in appearance with a 13 mm long, 3.75 mm diameter abutment with an internal hex. The apical part of the screw remained threaded into the implant, but had fractured at the level of the hexagonal lock. Although

# Introducing iLase™

The next instrument for your tray.



Powerful.  
Affordable.  
**Beyond Portable.**



Actual Size

*iLase™ gives Biolase the most complete family of dental laser solutions, to match the needs of you and your patients perfectly as you expand your laser applications:*



## *iLase*™

The Personal Laser, for everyday soft-tissue procedures.



## *ezlase*™

The Total Diode Laser Solution, including whitening and pain relief.



## *waterlase*™ MD TURBO

Best-of class soft and hard tissue laser for common and advanced restorative, periodontics, endodontics, cosmetic, surgical and pediatric procedures.



the implant was osseointegrated, there were radiographic signs of peri-implantitis with some crestal bone loss having occurred (Fig. 2).

### \_ Treatment options

The treatment options available were: 1) retrieve the fractured screw, or 2) remove the old implant and insert a new implant in one sitting. Following discussion with the patient and evaluation of the possibilities for success, it was decided to try and retrieve the fractured screw. Treatment would involve the use of the Er:YAG laser to perform the following, based upon accepted research:

- \_ The flap incision.<sup>31,32,33</sup>
- \_ Ablation of granulation tissue around the implant.<sup>34,35,36</sup>
- \_ Remodelling, shaping and ablating of the bone.<sup>32,34,37,38</sup>
- \_ Detoxification of the infected surfaces of the implant.<sup>36,39,40,41,42</sup>
- \_ An associated osteogenic (GBR) procedure to prevent soft tissue in-growth and maintain the form of the alveolus treatment alternatives, using a more conventional approach, would include the use of traditional scalpel, curettage, and rotary instruments.

### \_ Treatment

A dual-wave laser system with operating wavelengths of 2,940 nm and 10,600 nm (OpusDuo™ AquaLite™, Lumenis, Ltd. Yokneam, Israel) was employed for this procedure. The laser operating parameters employed for the various surgical stages were as follows:

- \_ Flap Access: Wavelength: 2,940 nm (Er:YAG), 200-micron sapphire tip, in contact mode; 450 mJ per pulse at 20 Hz. Total power: 9 Watts.
- \_ Granulation Tissue Removal: Wavelength: 2,940 nm (Er:YAG), 1,300-micron sapphire tip, in non-contact mode; 700 mJ per pulse at 12 Hz. Total power: 8.4 Watts.
- \_ Bone Surgery: Wavelength: 2,940 nm (Er:YAG),

1,300-micron sapphire tip, in non-contact mode; 450 mJ per pulse at 20 Hz. Total power: 9 Watts.

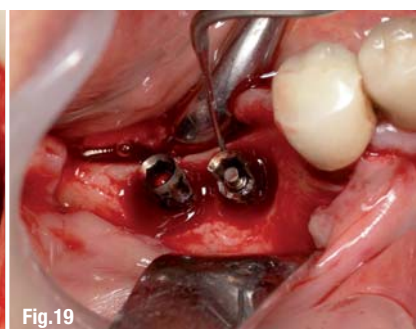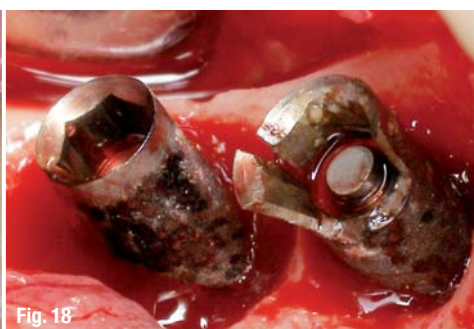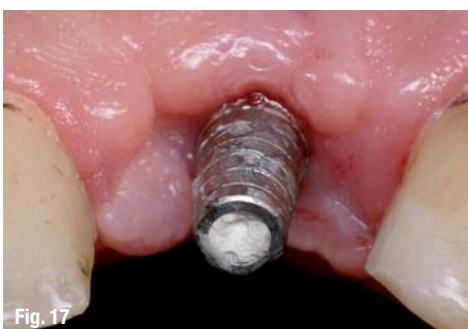\_ Detoxification of the implant: Wavelength: 2,940 nm (Er:YAG), 1,300-micron sapphire tip, in non-contact mode; 150 mJ per pulse at 20 Hz. Total power: 3 W.

\_ Decortication for GBR technique: Wavelength: 2,940 nm (Er:YAG), 1,300-micron sapphire tip, in non-contact mode; 500 mJ per pulse at 17 Hz. Total power: 8.5 Watts.

A "V" shape incision was made with the Er:YAG laser. An intrasulcular incision was made (after anaesthesia) at the buccal and palatal side of the implant, together with two vertical relieving incisions: one at the mesial side of tooth # 8 and the second at the mesial side of tooth # 11 (Figs. 4 and 5).

The buccal and palatal flaps were lifted and the area explored (Fig. 6); there was granulation tissue around the neck of the implant. The granulation tissue was ablated using the laser (Fig. 9). Vaporization of granulation tissue (if any exists) after raising a flap is efficient with the Er:YAG laser, offering a lower risk of overheating the bone than that posed by the current diode or CO<sub>2</sub> lasers.<sup>43</sup> And often obviates the need for hand instruments. Results from both controlled clinical and basic studies have pointed to the high potential of the Er:YAG laser and its excellent ability to effectively ablate soft tissue without producing major thermal side-effects to adjacent tissue has been demonstrated in numerous studies.<sup>35,36,37</sup>

The broken hexagon slot was straightened, using a round diamond bur and the head of the implant was rendered smooth. A slot was created with a surgical drill on the head of the fractured screw, and a screwdriver was successfully used to unscrew the broken abutment screw (Figs. 7 and 8). The Er:YAG laser was aimed at the surface of the exposed implant for the purpose of decontaminating the infected exposed surfaces, without damaging them.<sup>36,40,41,42,43</sup> Studies have shown that Er:YAG laser energy effects on bone include bacterial reduction.<sup>43,44</sup> Following this, all accessible bone surfaces were exposed to laser energy to ablate necrotic bone and to shape and remodel the surface, in accordance with established clinical proto-



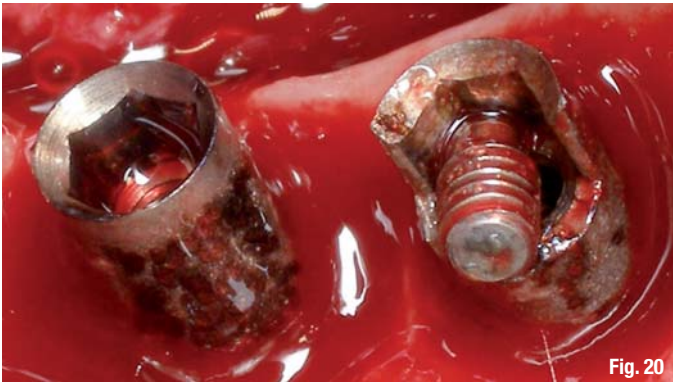


Fig. 20

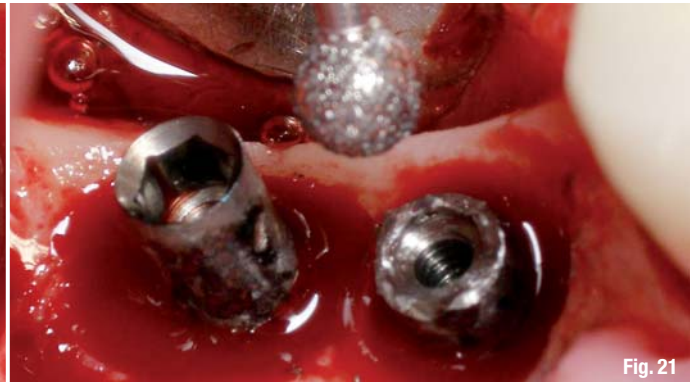


Fig. 21

cols.<sup>32,34,38,39</sup> Decortication of the buccal bone was then performed (Fig. 10). The purpose of decortication is to encourage bleeding, providing progenitor cells to the site. A new abutment was then inserted into the implant (Fig. 11). All spaces between implant and existing osteotomy site were filled with a xenograft bone substitute (Bio-Oss®, Geistlich Biomaterials) and covered with an absorbent bilayer membrane (Bio-Gide®, Geistlich Biomaterials), (Figs. 12 and 13). The mucoperiosteal flap was re-positioned and sutured with silk 3-0, paying particular attention to primary closure of the flap (Fig. 14).

### Post-operative instructions

The patient was prescribed Clindamycin 150mg x 50 tabs to avoid infection. He was also given Motrin 800 mg x 15 tabs for pain. Instructions were given to rinse with Chlorhexidine 0.2 %, starting the next day for 2 weeks x 3 per day.

### Management of complications and follow-up care

The following day the patient reported moderate pain and moderate swelling. There was no tissue bleeding and the site was closed. The flap was showing signs of attachment and was healing nicely. At ten days post-op the patient returned for inspection and removal of sutures. The swelling had resolved, there were no signs of fistula and healing was progressing well. After five months the soft tissue was completely healed without complications (Figs. 16 Et 17). The soft issue had healed over the bone and there were no bony projections observed under the soft tissue. The prognosis is excellent.

### Conclusion

The use of osseo-integrated implant-supported prostheses in the replacement of missing natural teeth has become an accepted clinical protocol in dentistry. Success in this area is enhanced through correct diagnosis, treatment planning and maintenance; however, complications often occur, which may be significant

and compromise the long-term success of the implant abutment and associated prosthesis. The management of such complications has given rise to several techniques to address failings, such as component fracture and bacterial contamination.

The Er:YAG (2,940 nm) laser can be employed as an auxiliary tool for the purpose of decontamination of infected implant surfaces and it has been shown to be effective and safe. The use of the 2,940 nm wavelength for these procedures presents many advantages vs. conventional methods, including enhancing the surgical site and less bleeding during the operation, providing the practitioner a better field of visibility and reducing patient discomfort during its use. In addition, anecdotal claims have been made that post-operative effects such as pain and swelling are less pronounced. A summary of possible serious complications associated with implant placement has been given, together with a report of a clinical case in which the use of the Er:YAG laser has been shown to be beneficial in the management of the consequences of a fractured abutment screw.

*Editorial note: The literature list can be requested from the Editorial Office.*

_contact	laser
<p><b>Avi Reyhanian, DDS</b> 1 Shaar Haemek Street, Netanya 42292, Israel</p>	
<p><b>Steven Parker, BDS, LDS, RCS, MFGDP (Harrogate, UK)</b> 30, East Parade, Harrogate HG1 5LT, United Kingdom</p>	
<p><b>Joshua Moshonov, DMD</b> 25 Habanai Street, Jerusalem 96264, Israel</p>	
<p><b>Natan Fuhrman, DDS</b> Institute of Advanced Dental Education Haifa, Israel</p>	

# Laser phototherapy in Bell's palsy

## A case report

**Authors** \_Profa Aparecida Maria Cordeiro Marques\*, Luiz Guilherme Pinheiro Soares\*, Dr Cristina Maria do Nascimento\*, Alberto de Aguiar Pires Valença Neto\*, Roberta Cordeiro Marques\*, Dr Antonio Luiz Barbosa Pinheiro\*, Brazil

### \_Introduction

Bell's palsy is a sudden idiopathic peripheral palsy of the facial nerve. This condition is caused by some kind of damage to the VII cranial nerve that causes either complete or partial of the facial mimics.<sup>3</sup> It may be associated or not to gustative disturbance, hyper salivation, and of eye and ear disturbances.<sup>8</sup> Its diagnosis is by the exclusion of any other causes that may cause the palsy of the facial nerve as its etiology remains unclear.<sup>2,11</sup> It has been demonstrated that herpes virus may cause this type of palsy due to reactivation of the virus or by immunomediated post-viral nerve demyelination.<sup>12,13</sup> Most cases of Bells' palsy recover without treatment. Besides the unbalance of the facial esthetic and some sensorial symptoms, the acute phase of this disease is not associated to severe disturbances.<sup>16</sup> The condition has a annual incidence estimated of 20–30:100.000 people<sup>2,12</sup> and has a good prognosis, with spontaneous resolution in 95% of the cases within 6–8 weeks.

One common symptom reported by suffers is pain around the ear prior to the clinical appearance of the facial palsy. This pain is caused by sensorial distur-

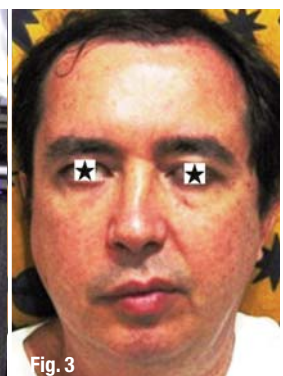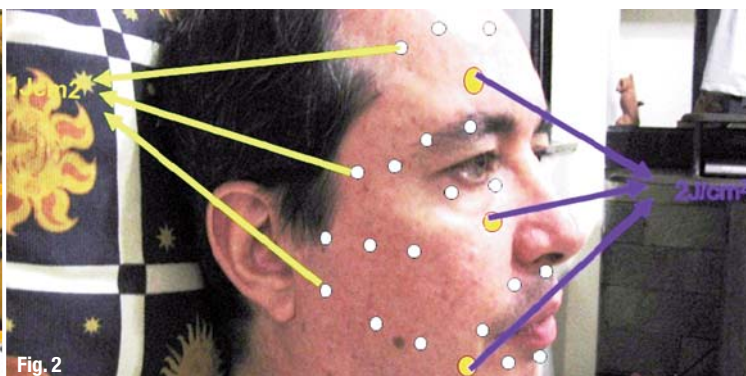
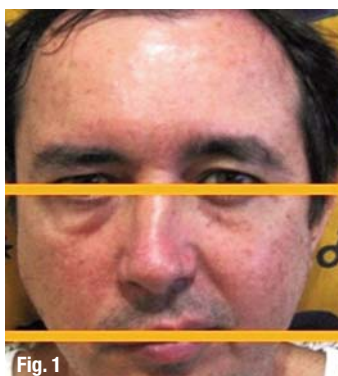bance of the facial nerve.<sup>18</sup> The muscular spasm and sensitivity around the ear is an alert, an early sign, and it is due to hyper excitability of the facial nerve that causes the spasm of the facial muscles of the mimic and that may be provoked by centripetal impulses generated by the contact of the axons of the nerve with the Nervi nervorum.<sup>5</sup>

Clinical examination evidences the lost of facial expression on the affected side. The patient is not able, for example, of closing the eye as the eyelid does not respond to the order to close due to the palsy of the facial nerve. The eyeball rotates itself up. This is known as Bell's sign.<sup>13</sup> Ru Lan et al. (2009) suggested that ageing increases the severity of the condition due to a reduced capacity of neural regeneration. This may be attributed to a hyperactivity of glial cells and increased activity of cerebral cytokines that impair the repair of nerve cells.<sup>8</sup> There is also some evidence that Bell's palsy may be associated to bacterial infection Liu et al. (2009) suggested on their study that the use of penicillin on suffers showing normal counts of leukocytes and increased number of neutrophils resulted in Best results than when anti-viral agents were used. These aspects are indicative of a multi-fac-

**Fig. 1** \_Initial aspect of the patient showing limitation of the facial expression.

**Fig. 2** \_Diagram showing the sites of application of the Laser and amount of energy delivered to each point.

**Fig. 3** \_Aspect of the patient lips of the affected site during the treatment (30 days).





torial etiology and that it may require different treatments according to the etiological agent.

The success of the treatment of Bell's palsy by using laser phototherapy isolated or in association with other therapeutic approach has been reported on the literature.<sup>1,16,20</sup> The ability to increase the amplitude of the action potential and increased regeneration of nerves are probably related to the efficacy of the protocol used on cases of Bell's palsy.<sup>7</sup> A previous report by Shamir et al. (2001) on a rodent model used applications of  $\lambda=780\text{nm}$  laser light applied daily and transcutaneously (30 min, 21 consecutive days), to corresponding segments of the spinal cord and to the injured sciatic nerve. Their results showed positive somato-sensorial response on 69.2% of the animals that were irradiated with the laser. Controls showed only 18.2% of positive responses. Immunohistochemical analysis evidenced both increased number of total axons and improved quality of nerve repair on irradiated animals.

The treatment of Bell's palsy aims mainly to prevent corneal damage usually by physiotherapy and steroids.<sup>13</sup> Physiotherapy, steroids and retroviral agents are now widely accepted for treating Bell's palsy. Laser phototherapy is able to stimulate the metabolism of the damaged nerve stimulating the production of proteins associated to its growth and improved recovery capacity of the facial nerve.<sup>20</sup> Ailioaie, Chiran, (2004) studied nerve regeneration on 31 children using Laser light ( $\lambda=670/830\text{nm}$ ) and found complete regeneration on 87.5% of the cases. Controls showed only 60% of recovery. This work reports the treatment of a case of Bell's palsy with laser phototherapy, electrotherapy and physiotherapy.

## \_Case report

A 52-years-old white male complaining of hemifacial palsy was seen at the Laser Center of the Center of Biophotonics of the School of Dentistry of the Federal University of Bahia (Fig. 1). Laser phototherapy was carried out during two months. A diode laser ( $\lambda=790\text{nm}/40\text{mW}/26\text{-}29\text{J}/\text{cm}^2$  - Kondortech®, São Carlos, São Paulo, Brazil) was used and treatment started 48h after the onset of the palsy. During the first week the treatment was carried out on daily basis ( $26\text{J}/\text{cm}^2$ ) on the following weeks treatment was carried out three times a week ( $29\text{J}/\text{cm}^2$ ). The number of total sessions was 21. Laser light was delivered on extra-oral contact points on the affected hemiface and was carried out along the five branches of the facial nerve and at the infraorbital and mental foramina (Fig. 2). Besides Laser phototherapy the patient was also submitted to TENS and physiotherapy three times a week. The palsy weakened along the time of treatment as seen on Figures 3 and 4.

## \_Discussion

Bell's palsy may be uni or bilateral disturbance of the conduction of the Facial nerve with non-specific etiology.<sup>2</sup> Treatment of this pathology is carried out using antiviral drugs<sup>2,12,17</sup>, steroids<sup>4,6,14,15</sup>, physiotherapy<sup>3</sup>, and acupuncture.<sup>11</sup> The use of steroids has been shown effective on the treatment of Bell's palsy due to its strong anti-inflammatory effect that reduces the damage to the nerve resulting in a better prognosis.<sup>2,15</sup>

Over the last 10 years the use of Laser phototherapy has been suggested as an associated treatment to other types of therapeutic approaches.<sup>5,9,16,20</sup> This positive effect has been attributed to the effect of the light on nerve regeneration and consequent recovery of normal nerve physiology. Khullar et al. (1996) suggested that Laser light might stimulate reinnervation of the tissues by either the penetration of the axons or on adjacent Schwann's cells inducing the compromised tissue to secrete proteins related to nerve growth or the releasing of mediator of nerve growth that will affect non-damaged adjacent nerves. These aspects were reflected on the treatment of the patient. Despite the positive result of the treatment, further studies are needed to elucidate the effect of the laser light on nerve as well as on the etiology of Bell's palsy.

## \_Conclusion

Laser phototherapy seems to positively affect the outcome of the treatment of Bell's palsy carried out with other therapeutic approaches causing mainly quicker sensorial recovery and improved quality of life of the patients.

## \_Abstracts

Bell's palsy is defined as a peripheral facial nerve palsy, idiopathic, and sudden onset and is considered the most common cause of this pathology. It is caused by damage to cranial nerves VII, resulting in complete or partial paralysis of the facial mimic. May be associated with taste disturbances, salivation, tearing and hyperacusis. It is diagnosed after ruling out all possible etiologies, because its cause is not fully understood. Physical therapy, corticosteroids and antiviral therapy have become the most widely accepted treatments for Bell's palsy. Therapy with low-level laser (LLL) may induce the metabolism of injured nerve tissue for the production of proteins associated with its growth and to improve nerve regeneration. In most cases, the recovery occurs without uneventfully (complications), the acute illness is not associated with serious disorder. This paper reports a successful treatment of Bell's palsy treated with Laser phototherapy, electrotherapy and physiotherapy.



**Fig. 4** Aspect of the patient at the end of the treatment showing the recovery of the facial mimics (60 days).

_contact	laser
<p><b>Profa Aparecida Maria Cordeiro Marques</b>          Center of Biophotonics          School of Dentistry          Federal University of Bahia          Av. Araújo Pinho,          62, Canela          Salvador, BA,          CEP 40140-110, Brazil          Tel./Fax:          +55 71 32839010          E-mail:          amarques@ufba.br,          cidamarques77@hotmail.com</p>	
<p>*Center of Biophotonics,          School of Dentistry,          Federal University of Bahia,          Av. Araújo Pinho, 62,          Canela, Salvador, BA, CEP          40140-110, Brazil</p>	

# Frenectomy review

## Comparison of conventional techniques with diode laser

**Authors** Dr M.L.V. Prabhuji, Prof Dr S.S. Madhu Preetha, Dr Ameya G. Moghe, India

### Introduction

The word frenum is derived from the Latin word "fraenum". Frena, are triangle-shaped folds found in the maxillary and mandibular alveolar mucosa, and are located between the central incisors and canine premolar area.

Frenum may be classified depending upon its morphology as:

- \_ Long and thin
- \_ Short and broad.

Depending upon the attachment level, frenum has been classified as: (Placek et al. 1974)

- \_ Mucosal
- \_ Gingival
- \_ Papillary
- \_ Papillary penetrating.

When the insertion point of the frena is at the gingival margin it may pose a problem (Corn 1964). This kind of abnormal insertion of the frenum may cause marginal recession of the gingiva. Abnormal frenal insertion can distend and retract the marginal gingiva or papilla away from the tooth when the lip is stretched. A frenum that encroaches on the margin of the gingiva may interfere with plaque removal, and tension on this frenum may tend to open the sulcus.

This condition may be more conducive to plaque accumulation and inhibit proper oral hygiene.

Aberrant frenum can be treated by frenectomy or frenotomy procedures. The terms frenectomy and frenotomy signify operations that differ in degree of surgical approach. Frenectomy is a complete removal of the frenum, including its attachment to the underlying bone, and may be required for correction of abnormal diastema between maxillary central incisors (Friedman 1957). Frenotomy is the incision and relocation of the frenal attachment.

### Indications

- \_ The indications for frenectomy procedure include
- \_ Tension on the gingival margin (frenal-pull concomitant with or without gingival recession)
- \_ Facilitate orthodontic treatment
- \_ Facilitate home care.

### Techniques for frenectomy

- \_ Conventional technique
- \_ Using soft tissue lasers.

### Conventional technique

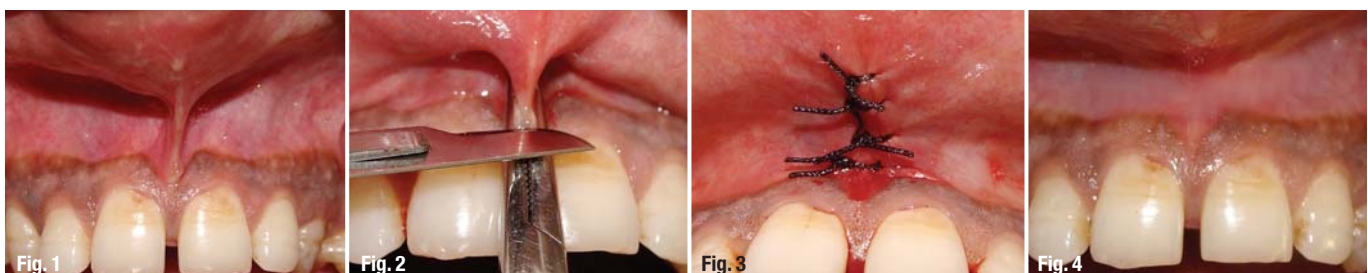
Conventional technique utilises traditional instruments like the scalpels and periodontal knives. Different procedures have been mentioned under the conventional frenectomy technique. These include

Fig. 1\_Abnormal frenal attachment.

Fig. 2\_Haemostat in place & incision made.

Fig. 3\_Sutures placed.

Fig. 4\_Post-op two months.



Dieffenbach, Schuchardt, & Mathis. The most common being Dieffenbach V-plasty & Schuchardt Z-plasty.

**\_Armamentarium**

Bard-Parker handles no. 3, No. 15 blade, mosquito haemostat, suture material.

**\_Procedure**

*Dieffenbach V-plasty*

Surgical steps: The area is anesthetized by giving local anesthetic injection (2% lignocaine with 1:200,000 adrenaline). After anesthesia is achieved, the frenum is held with the mosquito haemostat to its full depth. With the No. 15 blade mounted on a Bard-Parker handle, an incision is made along the upper surface of the haemostat till the entire depth of the frenum extending into the vestibule. A similar incision is repeated on the under-surface of the haemostat so that the haemostat is detached along with the frenal tissue within its beaks. Once this is achieved, a rhomboid area exposing the deeper connective tissue fibers becomes visible. With the help of fine scissors, the deeper fibers are detached from the underlying periosteum. Periosteal scoring is done with the help of surgical blade so as to prevent the reattachment of fibers. The labial mucosa is un-

dermined so as to permit the approximation of the edges. The bleeding is controlled by applying pressure packs.

Suturing: The diamond shaped wound is sutured using either a 4-0 or 5-0 silk sutures in simple interrupted fashion. Proper approximation of the margins is ensured. A periodontal dressing is placed to cover the surgical area.

Frenectomy by V-plasty may result in scar formation that could prevent the mesial movement of the central incisors (West 1968). However, it is typically a safe surgical procedure with no notable complications.

*Schuchardt Z-plasty*

The main advantage of this method over the V-plasty method was minimal scar tissue formation. The method requires a skilled operator as it is tedious to perform.

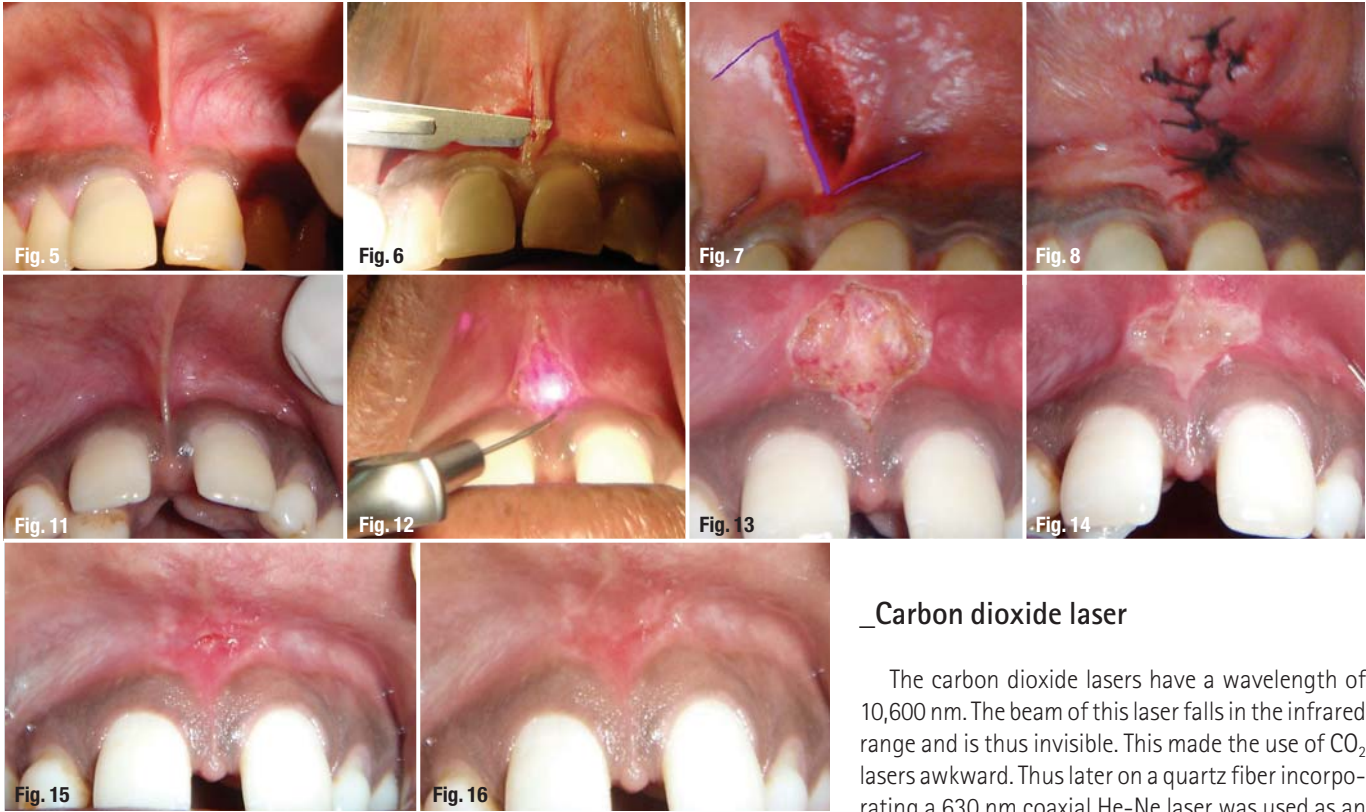
**\_Frenectomy using soft tissue lasers**

LASER (Light Amplification by Stimulated Emission of Radiation) is based on Albert Einstein's theory of spontaneous and stimulated emission of radiation. It was Maiman in 1960 who gave the first laser prototype using ruby crystal. Shortly there-

Laser Type		Wavelength	Colour
Excimer laser	Argon fluoride (ArF) Xenon chloride (XeCl)	193 nm 308 nm	Ultraviolet Ultraviolet
Gas laser	Argon Helium-Neon (HeNe) Carbon dioxide (CO <sub>2</sub> )	488 nm 514 nm 637 nm 10,600 nm	Blue Blue green Red Infrared
Diode laser	Indium Gallium Arsenide Phosphorus (InGaAsP) Gallium Aluminium Arsenide (GaAlAs) Galium Arsenide (GaAs) Indium Galium Arsenide (InGaAs)	655 nm 677-830 nm 840 nm 980 nm	Red Red-Infrared Infrared Infrared
Solid state	Frequency doubled Alexandrite Potassium Titanyl Phosphate (KTP)	337 nm 532 nm	Ultraviolet Green
Lasers	Neodymium:YAG (Nd:YAG) Holmium:YAG (Ho:YAG) Erbium, Chromium (Er,Cr: YSGG) Erbium:YSGG (Er:YSGG) Erbium:YAG (Er:YAG)	1,064 nm 2,100 nm 2,780 nm 2,790 nm 2,940 nm	Infrared Infrared Infrared Infrared Infrared







**Fig. 5**\_Papillary frenal attachment.  
**Fig. 6**\_Horizontal incision made.  
**Fig. 7**\_Outline for Z-plasty.  
**Fig. 8**\_Sutures placed.  
**Fig. 11**\_Papillary penetrating frenum.  
**Fig. 12**\_Diode laser applied.  
**Fig. 13**\_Immediate Post-operative view.  
**Fig. 14**\_Post-op 2 days.  
**Fig. 15**\_Post-op 1 week.  
**Fig. 16**\_Post-op 2 months.

after, in 1961, Snitzer published the prototype for the Nd:YAG laser. The first application of a laser to dental tissue was reported by Goldman et al. and Stern and Sognnaes, each article describing the effects of the ruby laser on enamel and dentin. Lasers designed for surgery deliver concentrated and controllable energy to the tissue. For the laser to have effect the energy must be absorbed. The degree of absorption in the tissue varies as a function of wavelength and characteristics of target tissue. As the temperature increases at surgical site, the soft tissues are subjected to:

- \_Warming (37 °C to 60 °C)
- \_Welding (60 °C to 65 °C)
- \_Coagulation (65 °C to 90 °C)
- \_Protein denaturation (90 °C to 100 °C)
- \_Drying (100 °C)
- \_Carbonization (above 100 °C)

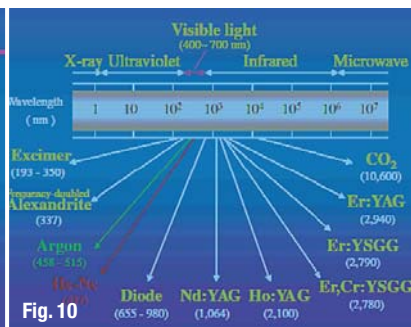
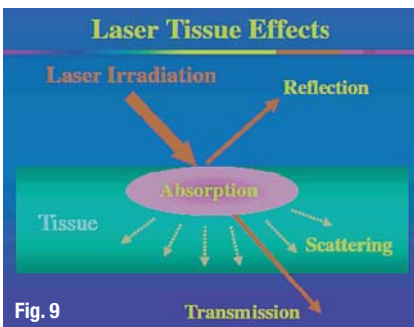
### \_Carbon dioxide laser

The carbon dioxide lasers have a wavelength of 10,600 nm. The beam of this laser falls in the infrared range and is thus invisible. This made the use of CO<sub>2</sub> lasers awkward. Thus later on a quartz fiber incorporating a 630 nm coaxial He-Ne laser was used as an aiming beam in the handpiece. The CO<sub>2</sub> laser received safety clearance from FDA in 1976 for use in soft tissue surgery. With the CO<sub>2</sub> laser there is rapid intracellular rise of temperature and pressure leading to cellular rupture and release of 'laser plume' (vapour and cellular debris).

The CO<sub>2</sub> laser is readily absorbed by water. Soft tissue consists of 75 % to 90 % water, 98 % of the incident energy is converted into heat and absorbed at the tissue surface with very little scatter or penetration. Thus moist surface is essential for maximal effect. With CO<sub>2</sub> laser no contact is made with the tissue, and no tactile feedback occurs.

### \_Neodymium:YAG laser

The Nd:YAG laser has a wavelength of 1,064 nm and lies in the infrared zone like the CO<sub>2</sub> laser. The Nd:YAG laser penetrates water upto 60 mm after which it is attenuated 10 % of its original strength. Thus energy is scattered in soft tissue rather than being absorbed onto the surface. The wavelength of Nd:YAG laser is attracted to colours and as a result its scattering in heavily pigmented soft tissues like skin is almost double its absorption. This heating effect of the Nd:YAG laser is ideal for the ablation of potentially haemorrhagic abnormal tissue and for haemostasis of small capillaries and venules. In 1990, the FDA approved soft tissue removal by means of a pulsed Nd:YAG laser. In 1997, the FDA approved sulcular debridement by means of a pulsed Nd:YAG laser.



## \_Erbium:YAG laser

The Er:YAG laser was introduced in 1974 by Zharikov et al. as a solid-state laser that generates a light with a wavelength of 2,940 nm. Of all lasers emitting in the near- and mid-infrared spectral range, the absorption of the Er:YAG laser in water is the greatest because its 2,940 nm wavelength coincides with the large absorption band for water. The absorption coefficient of water of the Er:YAG laser is theoretically 10,000 and 15,000–20,000 times higher than that of the CO<sub>2</sub> and the Nd:YAG lasers, respectively. Since the Er:YAG laser is well absorbed by all biological tissues that contain water molecules, this laser is indicated not only for the treatment of soft tissues but also for ablation of hard tissues. The FDA approved the pulsed Er:YAG laser for hard tissue treatment such as caries removal and cavity preparation in 1997, unchanged for soft tissue surgery and sulcular debridement in 1999 and for osseous surgery in 2004.

## \_Diode lasers

The diode laser is a solid-state semiconductor laser that typically uses a combination of Gallium (Ga), Arsenide (Ar), and other elements such as Aluminum (Al) and Indium (In) to change electrical energy into light energy. The wavelength range is about 800–980 nm. The laser is emitted in continuous-wave and gated-pulsed modes, and is usually operated in a contact method using a flexible fiber optic delivery system. Laser light at 800–980 nm is poorly absorbed in water, but highly absorbed in hemoglobin and other pigments (ALD 2000). Since the diode basically does not interact with dental hard tissues, the laser is an excellent soft tissue surgical laser (Romanos G, 1999), indicated for cutting and coagulating gingiva and oral mucosa, and for soft tissue curettage or sulcular debridement.

The FDA approved oral soft tissue surgery in 1995 and sulcular debridement in 1998 by means of a diode laser (GaAlAs 810 nm). The diode laser exhibits thermal effects using the 'hot-tip' effect caused by heat accumulation at the end of the fiber, and produces a relatively thick coagulation layer on the treated surface (ALD 2000). The usage is quite similar to electrocauterization. Tissue penetration of a diode laser is less than that of the Nd:YAG laser, while the rate of heat generation is higher (Rastegar S 1992), resulting in deeper coagulation and more charring on the surface compared to the Nd:YAG laser. The width of the coagulation layer was reported to be in excess of 1.0 mm in an incision of bovine oral soft tissue in vitro (White JM 2002). The advantages of diode lasers are the smaller size of the units as well as the lower financial costs.

# cosmetic dentistry

\_ beauty & science



## One issue free of charge!

You can also subscribe via  
[www.oemus.com/abo](http://www.oemus.com/abo)

 **Subscribe now!**

I hereby agree to receive a free trial subscription of **cosmetic dentistry** (4 issues per year). I would like to subscribe to **cosmetic dentistry** for € 44 including shipping and VAT for German customers, € 46 including shipping and VAT for customers outside Germany, unless a written cancellation is sent within 14 days of the receipt of the trial subscription. The subscription will be renewed automatically every year until a written cancellation is sent to OEMUS MEDIA AG, Holbeinstr. 29, 04229 Leipzig, Germany, six weeks prior to the renewal date.

▶ **Reply** per Fax +49 341 48474-290 to OEMUS MEDIA AG or per E-mail to [grasse@oemus-media.de](mailto:grasse@oemus-media.de)

Last Name, First Name

Company

Street

ZIP/City/Country

E-mail

Signature

Notice of revocation: I am able to revoke the subscription within 14 days after my order by sending a written cancellation to OEMUS MEDIA AG, Holbeinstr. 29, 04229 Leipzig, Germany.

Signature



Lasers type	Current/Potential dental application
Excimer lasers	Argon Fluoride (ArF) Xenon Chloride (XeCl)
Gas lasers	Argon (Ar)  Helium Neon (HeNe) Carbon Dioxide (CO <sub>2</sub> )
Diode lasers	Indium Gallium Arsenide Phosphorus (InGaAsP) Gallium Aluminum Arsenide (GaAlAs) and Gallium Arsenide (GaAs)
Solid state lasers	Frequency-doubled Alexandrite Neodymium:YAG (Nd:YAG)  Erbium group Erbium:YAG (Er:YAG), Erbium:YSGG (Er:YSGG), Erbium:chromium:YSGG (Er,Cr:YSGG)

### Argon laser

The argon laser uses argon ion gas as an active medium and is fiber optically delivered in continuous wave and gated pulsed modes. This laser has two wavelengths, 488 nm (blue) and 514 nm (blue-green), in the spectrum of visible light. The argon laser is poorly absorbed in water and therefore does not interact with dental hard tissues. However, it is well absorbed in pigmented tissues, including haemoglobin and melanin, and in pigmented bacteria.

The argon laser was approved by the FDA for oral soft tissue surgery and curing of composite materials in 1991 and for tooth whitening in 1995. Considering the advantages of eradication of pigmented bacteria, this laser may be useful for the treatment of periodontal pockets.

### Alexandrite laser

The Alexandrite laser is a solid-state laser employing a gemstone called Alexandrite, which is chromium doped: Beryllium-Aluminum-Oxide chrysoberyl (Cr+3; BeAl<sub>2</sub>O<sub>4</sub>) and is one of the few trichroic minerals. Rechmann & Henning first reported that the frequency-doubled Alexandrite laser (wavelength 337 nm, pulse duration 100 ns, double spikes, q-switched) could remove dental calculus in a completely selective mode without ablating the underlying enamel or cementum.

The development of this laser for clinical use is widely expected due to its excellent ability for selective calculus removal from the tooth or root surface without ablating the tooth structure.

### Excimer laser

Excimer lasers are lasers that use a noble-gas halide, which is unstable, to generate radiation, usually in the ultraviolet region of the spectrum. Frentzen et al. demonstrated that the ArF excimer laser, wavelength 193 nm, could effectively remove dental calculus without causing any damage to the underlying surface. The cementum surface was clean, and only a slight roughness could be observed after irradiation, supporting the use of excimer lasers for laser scaling. Folwaczny et al. have reported that the 308 nm wavelength XeCl excimer laser could effectively ablate dental calculus without thermal damages or smear layer production.

### Frenectomy procedure using diode lasers

Diode laser (A.R.C. Fox™) with wavelength of 810nm was selected for the procedure. No local anaesthesia was given to the patient. The frenum was stretched to visualize its extent. The diode laser was applied in a contact mode with focused beam for excision of the tissue. The ablated tissue was continuously mopped using wet gauze piece. This takes care of the charred tissue and prevents excessive thermal damage to underlying soft tissue. The tissue was lased until all the underlying muscle fibers were dissected. No sutures were placed at the end of this procedure. Patients were asked to take analgesics only if needed.

Advantages of Laser over Conventional technique:

- No need of local anaesthesia. Hence it's a painless procedure. As a result there is less patient apprehension.
- Bloodless operative field, thus better visibility.
- No need of periodontal dressing, therefore no patient discomfort as a result of irritation from the dressing.
- Better healing and less scarring.
- Less time consuming.

<b>_contact</b>	<b>laser</b>
<p><b>Dr M.L.V. Prabhujji MDS</b>                  Department of Periodontics                  Krishnadevaraya College of Dental Sciences                  Hunasamaranhalli, Via Yelahanka                  Bangalore, 562157, India                  E-mail: prabhujimlv@gmail.com</p>	



# 19th ANNUAL CONGRESS OF THE DGL



## LASER START UP 2010

OCTOBER 29–30, 2010, BERLIN, GERMANY



» Please fax this form  
**+49 341 48474-390**

More information:

- LASER START UP 2010
  - 19th ANNUAL CONGRESS OF THE DGL
- October 29–30, 2010, Berlin, Germany

office stamp

# The minimalinvasive laser surgical crown lengthening

Author\_Dr Thorsten Kuypers, Germany

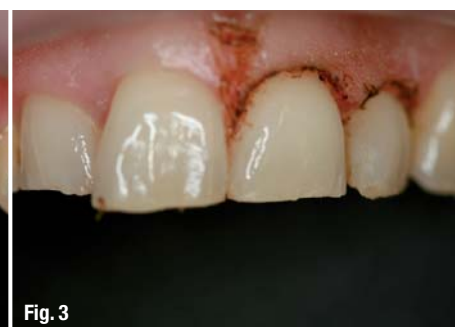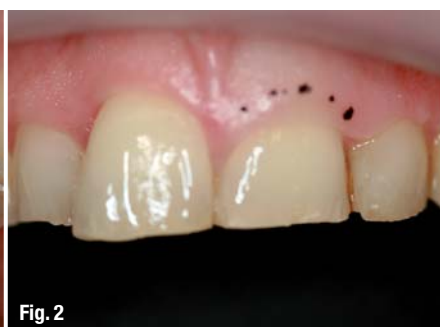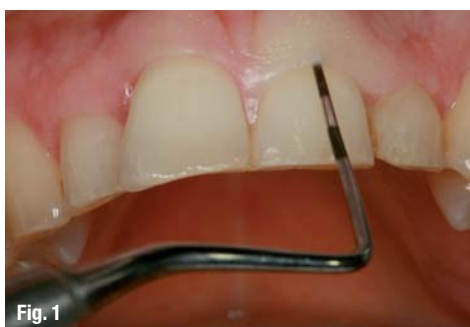**\_The surgical crown lengthening** is a procedure, which is probably not performed as often as it should be. There are multiple medical indications for this operation. Not only do we need it for example to modify the red-white aesthetics, but this operation should be done in many other cases. If a patient has too short clinical crowns, which would give not enough retention for restorations we should prepare a more suitable situation by surgical intervention. Especially with ceramic-restorations, which need adhesive attachment, we often have problems. The preparation margin should be supra- or paragingival. This is often not the case, so it is more difficult to have a clean and dry operation area, while attaching the restoration. If we would perform a surgical crown lengthening before preparation, things would be a lot easier afterwards. Last but not least we often have to distort the biological width. This will result in chronically inflamed areas around the restoration. If we know that the defect of the tooth is going to force us to damage the biological width, we have to perform a surgical crown lengthening before starting with the planned treatment. So why is it, that this operation is performed so rarely? The answer is easy to give. The conventional treatment

with scalpel, bone milling cutter, needle and thread is not easy, is bloody and risky and often associated with pain for our patients. In addition, we have to wait several weeks for the healing process to end, which will retard the actual treatment. Therefore it is obvious, that many dentists and patients will look for a compromise and will risk functional and/or aesthetic degradation.

To solve this problem we would need a possibility to perform a surgical crown lengthening fast, save, painless and with shorter healing time. This is where it comes to laser dentistry. The right lasers, used in the right way, will serve us all these benefits.

The right treatment will now be shown by the author in a case presentation. The crown lengthening was done with a combination of an 810 nm diode laser and an Er,Cr:YSGG laser.

Intentionally we wanted to show a case of the upper jaw front. In those cases we need a high amount of predictability, which is given in the laser surgery. As well as we can present a nice documentation.



# implants

international magazine of oral implantology

## Clinical procedure

The following case report should show the clinical guidelines how to use different wavelengths in this treatment. It would be possible of course to perform a crown lengthening with just an erbium laser, as it absorbs mostly in water and therefore works on gingival and on bone. But under clinical aspects it is our opinion, that the combination of diode and erbium laser is very useful. Because of the gingivectomy with a diode laser—in this case the laser "Q 810" by ARC lasers—the operation field is not bleeding and shows good clarity. With good clarity it is no problem to measure the new biological width by ablating the bone with an erbium laser.

At first it must be ascertained how much tissue we have to remove and how much space exists from the limbus alveolaris to the top of the gingiva. This is carried out by means of measurement with a PA probe under anaesthesia. If the measurement is concluded, we are able to mark the tissue, which is to be removed. This is helpful for the following reshaping of the gingiva (Figs. 1, 2 & 3). Then we can begin with the excision of the soft tissue. In this case we used 2.8 watts in the cw mode. In this setting a speedy work is reached under excellent coagulation (Figs. 4 & 5). If the modelation of the gingiva is concluded, we immediately can begin with the ablation of the bone. If we remove 2–2.5 mm of bone, the basis for a new biological width is created.

The ablation with an erbium laser is carried out without thermal damage under good visibility. In this case the "Waterlase MD" Cr:YSGG laser with 2,780 nm wavelength by the company "Biolase" was used. The Ablation of the bone is possible without a flap, minimum-invasive and without thermal damage. These were important factors for the patient to decide positive for this intervention. The bone-ablation is checked within the treatment by means of using a PA probe (Fig. 6 & 7).

In this case after the surgical steps were carried out we did a shaping of the incisors. Veneers are planned for a nice aesthetical result. But a functional pre-treatment is necessary. The final situation directly at the end of the crown lengthening is nice and already gives an improved aesthetic result (Fig. 8) to the patient. After one week there is hardly something to be seen (Fig. 9). The healing was without complications; there were no scars, no swelling or pain. Merely during the day of the treatment, the patient took a painkiller. This was purely prophylactic on our advising. In the fol-



You can also subscribe via  
[www.oemus.com/abo](http://www.oemus.com/abo)

 **Subscribe now!**

I hereby agree to receive a free trial subscription of **implants international magazine of oral implantology** (4 issues per year). I would like to subscribe to **implants** for € 44 including shipping and VAT for German customers, € 46 including shipping and VAT for customers outside of Germany, unless a written cancellation is sent within 14 days of the receipt of the trial subscription. The subscription will be renewed automatically every year until a written cancellation is sent to OEMUS MEDIA AG, Holbeinstr. 29, 04229 Leipzig, Germany, six weeks prior to the renewal date.

▶ Reply via Fax +49 341 48474-290 to OEMUS MEDIA AG or per E-mail to: [grasse@oemus-media.de](mailto:grasse@oemus-media.de)



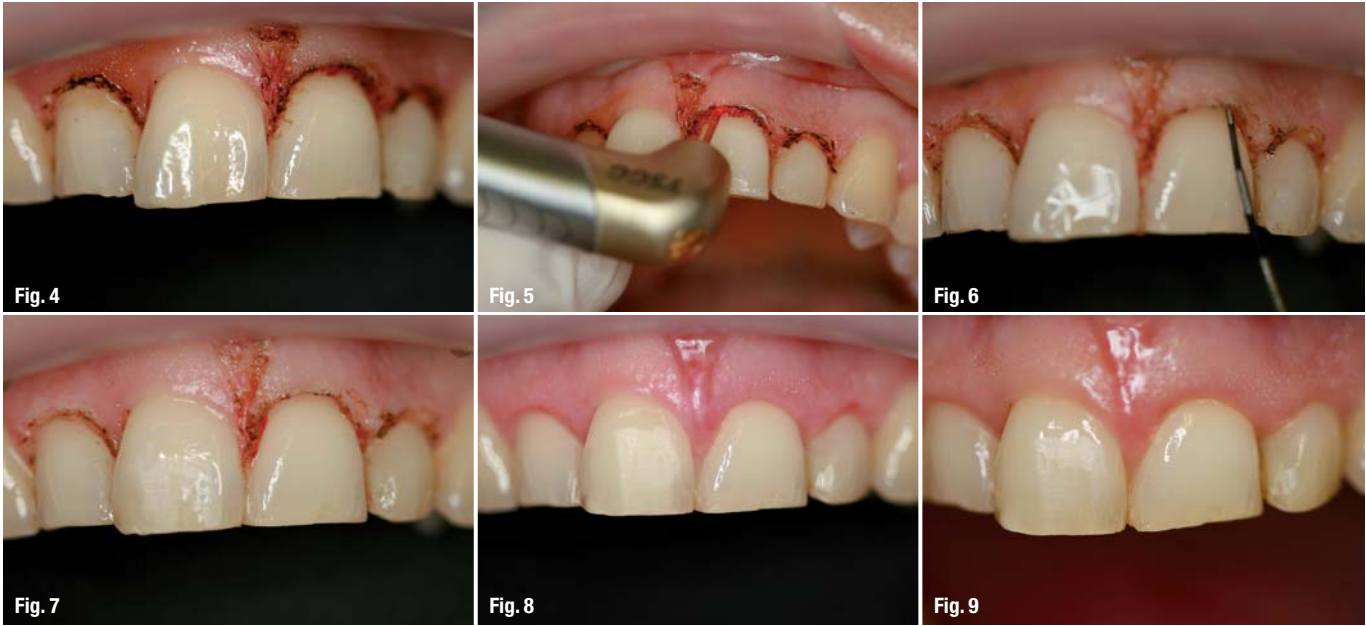




Notice of revocation: I am able to revoke the subscription within 14 days after my order by sending a written cancellation to OEMUS MEDIA AG, Holbeinstr. 29, 04229 Leipzig, Germany.

OEMUS MEDIA AG  
 Holbeinstraße 29, 04229 Leipzig  
 Tel.: +49 341 48474-0  
 Fax: +49 341 48474-290  
 E-Mail: [grasse@oemus-media.de](mailto:grasse@oemus-media.de)





lowing no more medication was necessary. The normal oral hygiene was taken up again after four days. Before that, the area of the crown lengthening should be left out of the brushing procedure. Only oral rinse was used adjuvant in the first days after surgery. After two to three weeks the healing is concluded solidly. The patient is contented and other therapeutic measures—in this case the construction of the canine guidance and veneers—can be begun. This approach is only because we are working in the front tooth area. If we are working for example on molars and the aesthetics are not too important, we can do our further treatment after six to ten days.

### Benefits

The advantages for the dentist are obvious. A time needing, bleeding surgical approach with flaps, stitches and the risk of afterwards appearing scars can be avoided. Also a solidly healed result is to be realised in short time. This means that we can begin earlier with the next restorative treatments.

By the non-invasive approach the dentist can achieve an increased compliance for a treatment, which no patient wants to have. We can expand our methods in aesthetic surgery, pre prosthetic surgery and simplify our work. Also the financial benefits and the positive propaganda offer unmistakable advantages. For our patients the advantages are also evident. A bloody, surgical intervention of this kind is substantially more pleasant by the application of laser light, than in the conventional approach. Also the post surgical healing is generally without any complications. A

shorter duration of the surgery and good healing also gives the opportunity for the patient to have this procedure done without changing his normal everyday life. To sum up, one can say that for "laser dentists" possibilities come up which are not to be reached conventionally. Own therapy can be improved, expanded and one can treat his patients non-invasive, careful and with good predictability. A classic „win win situation“.

### Summary

There are many Indications for a surgical crown lengthening. Even though the indication-list is long, this treatment is not very often done. This is probably, because it is difficult and demanding to perform and often painful for our Patients. To solve this Problem, we have the opportunity to use lasers instead of the conventional technique. The laser surgical crown lengthening is done fast, not very difficult and gives a great amount of safety and comfort to our patients.

<u>contact</u>	<b>laser</b>
<p><b>Dr Thorsten Kuypers, MSc</b>                  Private Practice                  Neusser Straße 600                  50737 Cologne, Germany                  E-mail: info@laserzahnarzt-koeln.de</p>	

**Lay the Foundations to your  
successful Future now!**

*The next master course starts on September 2011*



## **Master of Science (M.Sc.) in Lasers in Dentistry**

*Would you also like to be part of the International Dentists' Elite?*

- *The first accredited M.Sc. programme in dentistry in Germany*
- *Career-accompanying postgraduate programme of two years at the University of Excellence RWTH Aachen*
- *Double degree: European M.Sc. in „Oral Laser Applications“ (EMDOLA)*
- *Internationally accepted and accredited by the German Government, the European Union, the Washington Accord and the Bologna Process*
- *Science-based and practice-orientated on highest national and international level*
- *Bronze Award of the European Union for „Life-Long Learning programmes“*



Aachen Dental Laser Center

**More information:**

AALZ GmbH · Pauwelsstrasse 19 · 52074 Aachen · Germany  
Tel. +49 - 2 41 - 9 63 26 70 · Fax +49 - 2 41 - 9 63 26 71  
[www.aalz.de](http://www.aalz.de) · [info@aalz.de](mailto:info@aalz.de)

In cooperation with the University  
of Excellence RWTH Aachen

**RWTHAACHEN  
UNIVERSITY**

# The clinical use of the Er,Cr:YSGG laser in endodontic therapy

Author\_Justin Kolnick, USA

**Total elimination of bacteria** from infected root canal systems remains the most important objective of endodontic therapy. However, in spite of a plethora of new products and techniques, achieving this objective continues to elude our profession. Historically, endodontic treatment has focused on root canal disinfection with "entombment" of remaining bacteria within dentinal tubules and inaccessible areas of the root canal system. Although many factors have been implicated in the etiology of endodontic failures, it has become evident that these "entombed" bacteria play a pivotal role in the persistence of endodontic disease (Siqueira & Rocas 2008).

to sterilize root canal systems. In addition, many clinical obstacles exist that further complicates the clinician's ability to achieve this goal. These include, but are not limited to: restricted endodontic

access, complex root canal anatomy, limitations of irrigation and instrumentation techniques, inability to entomb bacteria and the inability to reach and eliminate bacteria deep within the tooth structure. While the purpose of this article is to focus on the clinical use of the Er,Cr:YSGG laser with radial-firing tips, a definitive treatment protocol needs to be in place to reduce the intracanal bacterial load prior to laser usage and also to facilitate delivery of the laser energy to the most critical part of the root canal, the apical third.

The erbium,chromium:yttrium-scandium-gallium-garnet (Er,Cr:YSGG) laser emits at a wavelength of 2,780 nm and is highly absorbed by water. The lower the penetration depth in water

**Fig. 1** Comparison of different wavelengths used by lasers and their penetration depth in water/tissue.

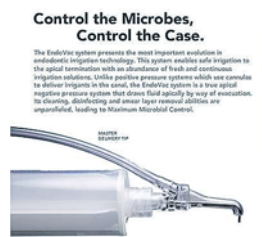
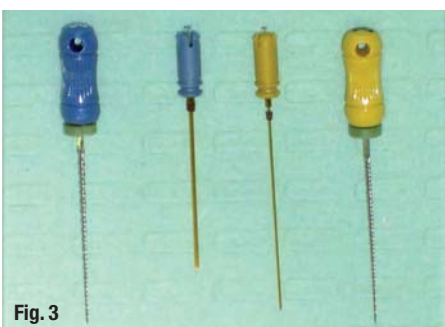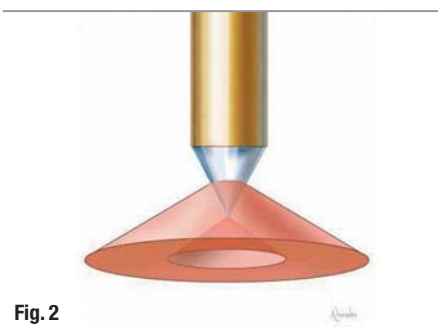
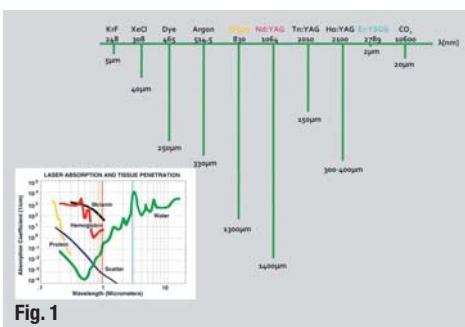
The higher the absorption, the greater is the ability of the laser to cut or ablate tissue.

**Fig. 2** Laser energy is emitted as a broad cone providing better coverage of root canal walls.

**Fig. 3** RFT2 (yellow) and RFT3 (blue) laser tips compared to hand files.

**Fig. 4** Master delivery tip delivers irrigant to the pulp chamber and evacuates any overflow.

**Fig. 5** True negative pressure apical irrigation and evacuation provided by macro- and microannuluses.





or tissue (or the higher the absorption), the greater is the ability of the laser to cut or ablate tissue (Fig. 1). Since this wavelength is very similar to the absorption maximum of water in hydroxyapatite, photo-ablation occurs where water evaporates instantaneously, thereby ablating the surrounding tissue. Gordon et al (2007) found that it was possible to achieve expansion and collapse of intratubular water as deep as 1,000  $\mu\text{m}$  or more. This micropulse-induced absorption was capable of producing acoustic waves strong enough to disrupt and kill intratubular bacteria. These findings are significant as bacteria have been identified at depths of 1,000  $\mu\text{m}$  (Kouchi et al. 1980), with *E. faecalis* at depths of 800  $\mu\text{m}$  (Haapasalo and Orstavik 1987). Irrigants such as sodium hypochlorite have a limited effect on these bacteria with penetration depths of only 100  $\mu\text{m}$  (Berrutti et al. 1997). Increasing concentration, exposure time and temperature was recently found to improve NaOCl penetration (Zou et al. 2010). Promising bacterial kill rates using the Er,Cr:YSGG laser with radial-firing tips have been reported in extracted teeth. A disinfection reduction of 99.7% was obtained for *E. faecalis* at depths of 200  $\mu\text{m}$  into dentin (Gordon et al. 2007) and 94.1% (1 log) at depths of 1,000  $\mu\text{m}$  (Schoop et al. 2007).

The development of the radial-firing laser tip (Biolase Technology, Inc.) with a tip shape that emits the laser energy as a broad cone, allows better coverage of the root canal walls than end-firing tips (Fig. 2). This facilitates entry of the emitted laser energy into the dentinal tubules reaching bacteria that have penetrated deep into the dentin.

## \_ Treatment protocol

Current techniques incorporating hand and/or rotary instrumentation, positive pressure irrigation, with or without sonic and ultrasonic agitation, fall short of total canal disinfection. The treatment protocol presented in this article incorporates three main components: management of the working width of the root canal, negative pressure apical irrigation and intracanal laser therapy.

### *Working width management*

The working width (WW) of a root canal is the diameter of the canal immediately before reaching its apical constriction. Allen (2007) found that 97% of canals not cleaned to their WW had residual debris in the critical apical region, while 100% of those cleaned to their WW were free of debris 1 mm from the apical constriction. Studies have shown that we need to clean to larger sizes to re-

move bacteria and debris (Kerekes 1977, Wu 2000). Conventional tapered files cannot accomplish this without transporting the canal, creating strip perforations, weakening the tooth or separating instruments. The LightSpeed LSX (Discus Dental) file is a unique, extremely flexible, taperless, nickel titanium instrument capable of cleaning to the WW. The final apical size (FAS) is the instrument size that completes WW preparation and is determined when the LSX file binds 4 mm (or more) from the working length and requires a firm push to reach WL. The customized apical preparations created are critical for predictably successful endodontics and provide significant advantages:


- \_ Effective removal of infected material, debris, inflamed and necrotic tissue from the apical region.
- \_ Allows placement of irrigating needle to WL for negative pressure apical irrigation.
- \_ Facilitates placement of intracanal medication deeper within the canal.
- \_ Facilitates placement of radial-firing laser tip within 1mm of WL.

### *Negative pressure apical irrigation*

There are two main reasons why irrigants fail to reach the critical last 3 mm of a root canal. Firstly, using positive pressure irrigation with a side-vented needle there is little flushing beyond the depth of the needle (Chow 1983). Most of the irrigant follows the path of least resistance and backs out of the canal with apical flushing penetrating only 1–2 mm apical to the end of the needle. To achieve effective apical flushing, the needle tip needs to be placed 1mm from working length which dramatically increases the risk of a sodium hypochlorite accident.

Secondly, the presence of apical vapor lock from air trapped in the canal as well as ammonia and carbon dioxide released from the dissolving action of sodium hypochlorite on pulp tissue prevents penetration of irrigants into the apical third. This vapor lock cannot be removed with hand or rotary files, sonic or ultrasonic activation. In a recent study, vapor lock resulted in "gross retention of debris and smear layer remnants" in the apical 0.5–1.0 mm of closed root canal systems (Tay et al. 2010).

The EndoVac (Discus Dental) is a true apical negative pressure irrigating system that provides continuous, high volume irrigation of fresh fluids to the canal terminus with simultaneous evacuation. It is comprised of a master delivery tip (Fig. 4) that delivers fluid to the pulp chamber and a macro- and microcannula (Fig. 5) that draw the fluid from the chamber to the canal terminus by way of evacua-



**Fig. 6** Laser removal of smear layer in apical third of canal (Biolase Technology. Unpublished data).

**Fig. 7** Single dentinal tubule after laser ablation (Biolase Technology. Unpublished data).

**Fig. 8** Accessory canal after laser ablation (Biolase Technology. Unpublished data).

**Fig. 9** Technique for laser tip positioning in canal.

**Fig. 10** Upper premolar treated with laser protocol.

**Fig. 11** Lower molar treated with laser protocol.

**Fig. 12** Lower premolar treated with laser protocol.

**Fig. 13** Lower molar treated with laser protocol.

This system eliminates vapor lock and provides superior cleaning, disinfecting and smear layer removal while virtually eliminating the threat of sodium hypochlorite accident (Schoeffel 2008). When compared to positive pressure irrigation with a ProRinse needle, EndoVac produced canals that were 366% and 671% cleaner 1 mm and 3 mm respectively from WL (Nielsen & Baumgartner 2007).

When EndoVac was used in combination with LightSpeed LSX instrumentation, canals were 99% and 99.5% free of debris 1 mm and 3 mm respectively from WL (Prashanth & Shivanna 2008).

*Intracanal laser therapy*

The final stage of root canal preparation and disinfection is completed with the Waterlase MD laser (Er,Cr:YSGG) using radial-firing tips (Biolase Technology Inc.).

The laser tips are available in two sizes: RFT2 and RFT3 with diameters of 275 μm and 415 μm respectively (Fig. 3). The RFT2 tip is inserted 1 mm short of WL, requiring canal preparation sizes of ISO 30 or more while the RFT3 tip is inserted to the junction of middle and apical thirds, requiring canal sizes of ISO 45 or more. These sizes fall well within typical working width preparation sizes prepared with LSX files. Intracanal laser therapy is performed in two phases, the Cleaning Phase for smear layer and debris removal and the Disinfection Phase for tissue ablation and bacterial elimination.

*Cleaning phase (1.25 W; 50 Hz; 24% air; 30% water):*

This phase uses water and removes smear layer and debris without using chemical irrigants. It takes 2–3 minutes per canal and uses Hydrophotonics™ to create a powerful micro-agitation effect throughout the canal system.

It is generally accepted that smear layer removal facilitates the cleaning and disinfecting of the dentinal tubules and improves the sealing of the root canal. When merging results of two studies, the Er,Cr:YSGG with radial-firing tips produced significantly better smear layer removal in the apical, middle and coronal thirds than two rotary techniques (Sung et al. 2007, Peters & Barbakow 2000). This extremely efficient action opens the dentinal tubules, lateral canals and isthmuses in preparation for disinfection (Fig. 6, 7 & 8).

Technique for cleaning phase: after completion of access, working width preparation and negative-pressure irrigation:

- \_Use the RFT2 to perform apical and partial coronal 2/3 cleaning.
- \_Select the recommended laser settings in the wet mode.
- \_Fill canal with sterile solution.
- \_Insert RFT2 tip 1 mm short of working length (WL).
- \_Activate laser on withdrawal of tip coronally at approximately 1 mm/s. Maintain tip in contact with the side surface of the canal wall during the entire apical to coronal pass.
- \_Repeat steps 4 and 5 one or two more times to ensure that the entire inner canal has been cleaned (Fig. 9).
- \_Place the RFT3 tip in handpiece to perform final

- cleaning of the coronal 2/3.
- \_ Fill canal with sterile solution.
- \_ Insert the tip to the junction of apical and middle third of the root canal.
- \_ Repeat steps 5 and 6.

#### *Disinfection phase (.75 W; 20 Hz; 10% air; 0% water)*

As stated previously, the laser energy emitted from the Er,Cr:YSGG laser is highly absorbed by water in tissue and micro-organisms resulting in instantaneous photo-ablation. In addition, the resulting micro-pulse expansion and collapse of intratubular water produce acoustic waves strong enough to disrupt and kill intratubular bacteria.

This effect is most effective in a dry mode as the laser energy is not absorbed by the water spray and can exert its full effect on the bacteria. This was confirmed by Gordon et al (2007) who achieved a 99.7% kill rate for *E. faecalis* in the dry mode. Technique for the disinfection phase is the same as the cleaning phase but with different laser settings in the dry mode.

### **\_Clinical applications**

While this protocol is recommended for all endodontic treatments (Fig. 10, 11 12 & 13), it is most valuable in the following clinical situations:

- \_ Infected cases with apical, lateral and/or furcal radiolucencies.
- \_ Retreatments with periapical periodontitis.
- \_ Acutely inflamed cases, especially those diagnosed with Cracked Tooth Syndrome.
- \_ Internal and external resorption.
- \_ Persistent infections not responding to conventional endodontic treatment.
- \_ Unexplained, prolonged post-operative discomfort.

### **\_Summary**

A root canal cleaning, shaping and disinfection protocol has been described that maximizes the removal of tissue, debris, smear layer and bacteria from root canal systems. Utilizing a combination of working width management with LightSpeed LSX instruments, high volume apical negative pressure irrigation and evacuation with the EndoVac system and intracanal laser therapy with radial-firing tips using the WaterlaseMD laser, the ability to totally eliminate bacteria from infected root canal systems may soon be within our grasp.\_

### **\_Bibliography**

Allen F: In vivo study of apical cleaning. *General Dentistry* 449–456 (2007).

- Berutti E, Marini R, Angeretti A: Penetration ability of different irrigants into dentinal tubules. *J Endod* 23:725–727 (1997).
- Chow TW: Mechanical effectiveness of root canal irrigation. *J Endod* 9:11:475–478 (1983).
- Gordon W, Atabakhsh VA, Meza F, Doms A, Nissan R, Rizoju I, Stevens R: The antimicrobial efficacy of the erbium,chromium:yttrium-scandium-gallium-garnet laser with radial emitting tips on root canal dentin walls infected with *Enterococcus faecalis*. *JADA* 138:7:992–1002 (2007).
- Haapasalo M, Orstavik D: In vitro infection and disinfection of dentinal tubules. *J Dent Res* 66:8:1375–9 (1987).
- Kerekes K, Tronstad L: Morphometric observations on root canals of human molars. *J Endod* 3: 114–8 (1977).
- Kouchi Y, Ninomiya J, Yasuda H, Fukui K, Moriyama T, Okamoto H: Location of streptococcus mutans in the dentinal tubules of open infected root canals. *J Dent Res* 59:2038–2046 (1980).
- Nielsen BA, Baumgartner JC: Comparison of the EndoVac System to Needle Irrigation of Root Canals. *J Endod* 33:5:611–615 (2007).
- Peters O, Barbakow F: Effects of Irrigation on Debris and Smear Layer on Canal Walls: A Scanning Electron Microscopic Study. *J Endod* 26:1:6–10 (2000).
- Prashanth, Shivanna V: Evaluation of New System for Root Canal Irrigation to Conventional: An Ex Vivo Study. *Discus Dental, Culver City, CA: The EndoFiles Newsletter* (2008).
- Schoeffel J: The EndoVac Method of Endodontic Irrigation, Part 2 – Efficacy. *Dentistry Today* 27:1 (2008).
- Schoop U, Barylyak A, Goharkhay K, Beer F, Wernisch J, Georgopoulos A, Sperr W, Moritz A: The impact of an erbium,chromium:yttrium-scandium-gallium-garnet laser with radial-firing tips on endodontic treatment. *Lasers Med Sci* 24:1:59–65 (2007).
- Siqueira JF, Rocas IN: Clinical Implications and Microbiology of Bacterial Persistence after Treatment Procedures. *J Endod* 34:11: 1291–1301 (2008).
- Sung E, Rankin DD, Rizoju I, Chueh P: Biolase Technology, unpublished study (2008).
- Tay FR, Gu L, Schoeffel GL, Wimmer C, Susin L, Zhang K, Arun SN, Kim J, Looney JW, Pashley DJ: Effect of Vapor Lock on Root Canal Debridement by using a Side-vented Needle for Positive-pressure Irrigant Delivery. *J Endod* 36:4:745–750 (2010).
- Wu MK, R'oris A, Barkis D, Wesselink P: Prevalence and extent of long oval canals in the apical third. *Oral Surgery, Oral Medicine, Oral Pathology* 89:6:739–743 (2000).
- Zou L, Shen Y, Li W, Haapasalo M: Penetration of Sodium Hypochlorite into Dentin. *J Endod* 36:5:793–796 (2010).

#### **\_contact**

#### **laser**

#### **Justin Kolnick DDS**

222 Westchester Avenue, Suite 402,  
White Plains, NY 10604, USA  
Tel.: + 1 914 946 2218  
Fax: + 1 914 946 2232  
E-mail: info@westchesterendo.com



# Er,Cr:YSGG laser assisted GTR in periodontal surgery

Author\_Dr Elena Speranza Moll, Italy

## Abstract

*Objectives:* This case report describes the application of an Er,Cr:YSGG laser in regenerative periodontal surgical therapy.

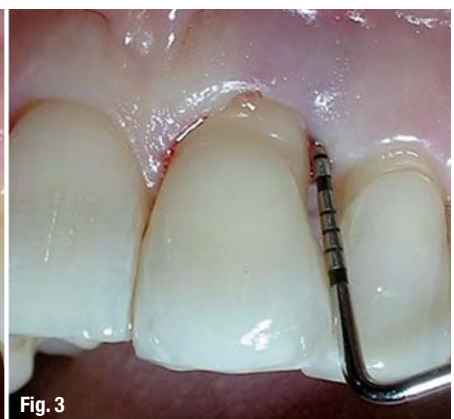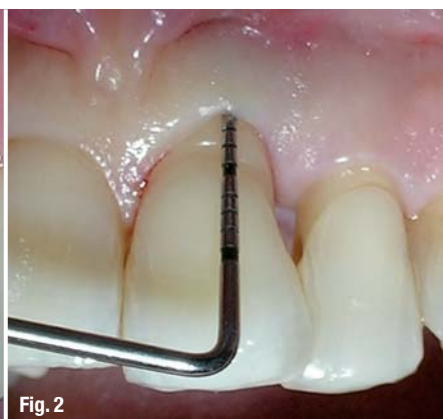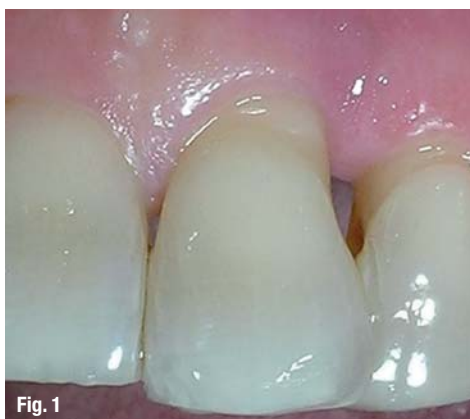*Materials and methods:* A patient with extensive periodontal tissue breakdown is treated with an Er,Cr:YSGG laser for granulation tissue removal, bone decorticalization and root decontamination. In the regenerative procedure demineralised bovine bone mineral and collagen membranes were used. Following clinical parameters were recorded at baseline, at 3 months, 6 months, 1 year, and at 2 years and 5 years: Plaque Index (PI), Bleeding On Probing (BOP), Periodontal Pocket Probing Depth (PPD), Recession (REC), Clinical Attachment Level (CAL).

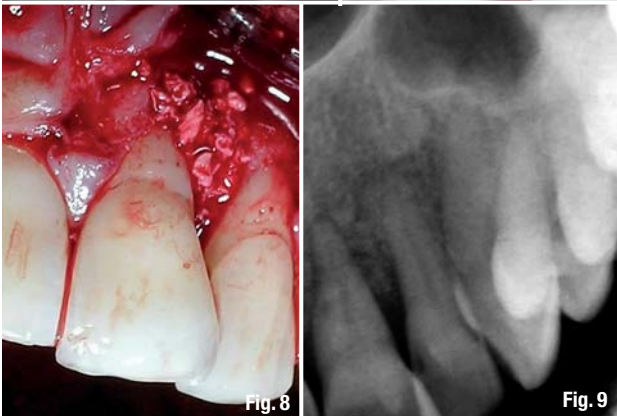
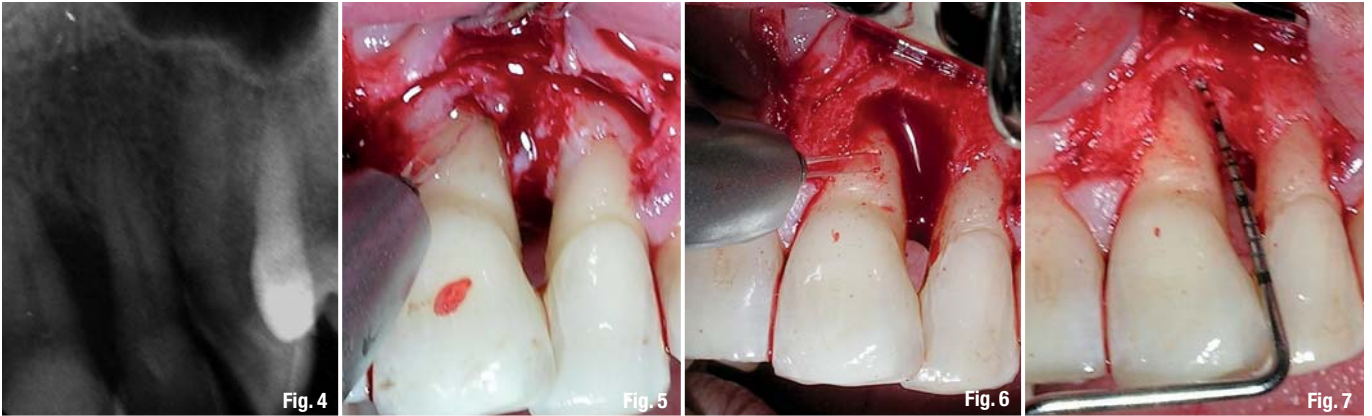
*Results:* The operated sites demonstrated uneventful healing. Radiographically remineralisation was observed at six months. At one year follow up, significant periodontal pocket reductions and clinical attachment level gains were registered.

*Conclusion:* In this case reports it may be acknowledged that the Er,Cr:YSGG laser could be applied for debridement and decontamination of both the root and the bone defect in guided tissue regeneration procedures. Further investigation is needed to identify in which treatment protocol in periodontology the Er,Cr:YSGG laser can be integrated and with what benefits.

## Background

The application of laser in periodontology is widely discussed especially as the several laser systems with their specific wavelength have a different impact on periodontal tissues. Excellent knowledge of laser applications is essential, which requires the operator to go through a learning curve to avoid adverse effects. During laser irradiation the power settings play a significant role and must be regulated appropriately in order to avoid detrimental effects to the irradiated tissues (Ishikawa I. 2002). Periodontal tissue destruction is treated according to the type of defect and the location, posterior or an-





frared spectrum, is a class 4 laser, with a pulse repetition rate of 10 Hz to 50 Hz and power output from 0.25 to 8 Watt, and pulse energy of 300 mJ. The flexible optical trunk fibre is connected to a straight or angled hand piece. The laser beam is accompanied by a water and air spray. The water/air spray represents a hydrating and cooling agent reducing thermal effects. Both Air and Water settings can be modified from 0-100%. Radiation of the Er,Cr:YSGG laser is absorbed mainly by water and calcium hydroxyapatite. With a pulse duration of 90 or 150  $\mu$ sec the Er,Cr:YSGG laser has a high ablation efficiency and low thermal impact on the surrounding tissues (StraBl, 2004) "Comparison of the emission characteristics of three Erbium laser systems—a physicals case report." (JOLA 2004).

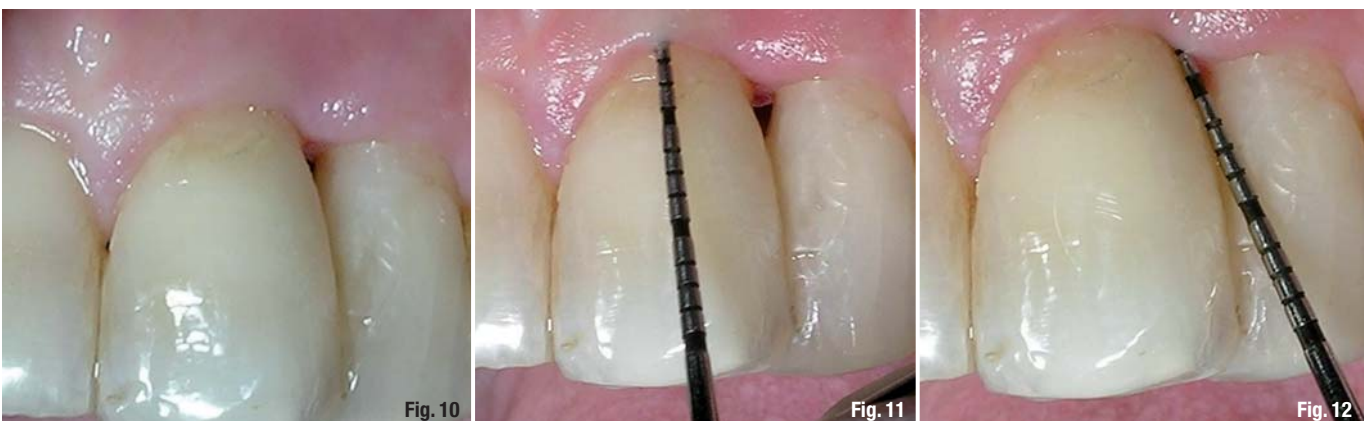terior, in the mouth. Regenerative therapy is indicated in case of intraosseous defects of which the radiographic angle and number of walls determine which kind of procedure needs to be applied and which kind of materials need to be used. The difficulty of guided tissue regeneration and other treatments of the periodontium lies in the fact that we are dealing with roots, which have an avascular surface in which, both the multiple specialized cell types and the microbial environment are involved in all healing processes.

**\_Materials and methods**

The Er,Cr:YSGG laser (Biolase Inc. San Clemente, CA) with a 2,780 nm wavelength, in the far-in-

frared spectrum, is a class 4 laser, with a pulse repetition rate of 10 Hz to 50 Hz and power output from 0.25 to 8 Watt, and pulse energy of 300 mJ. The flexible optical trunk fibre is connected to a straight or angled hand piece. The laser beam is accompanied by a water and air spray. The water/air spray represents a hydrating and cooling agent reducing thermal effects. Both Air and Water settings can be modified from 0-100%. Radiation of the Er,Cr:YSGG laser is absorbed mainly by water and calcium hydroxyapatite. With a pulse duration of 90 or 150  $\mu$ sec the Er,Cr:YSGG laser has a high ablation efficiency and low thermal impact on the surrounding tissues (StraBl, 2004) "Comparison of the emission characteristics of three Erbium laser systems—a physicals case report." (JOLA 2004).

A 44 year, female, with incidental, severe adult periodontitis (Vd Velden U., 2005). As far as medical conditions and life style concerned: the patient was negative for tobacco but she suffered from severe II grade obesity (BMI 35–39.9) and stress. Family history resulted positive for periodontitis. Intra-oral exams (Fig.1) demonstrated the central upper left incisor with extensive bone-loss on the distal, resulting in a black triangle at the soft tissue out-



mesial	baseline	12 mnts	24 mnts	60 mnts
PPD	3 mm	3 mm	4 mm	3mm
REC	0 mm	1 mm	0 mm	1 mm
CAL	3 mm	4 mm	4 mm	4 mm

**Tab. 1**

buccal	baseline	12 mnts	24 mnts	60 mnts
PPD	7 mm	2 mm	2 mm	2 mm
REC	3 mm	2 mm	2 mm	2 mm
CAL	10 mm	4 mm	4 mm	4 mm

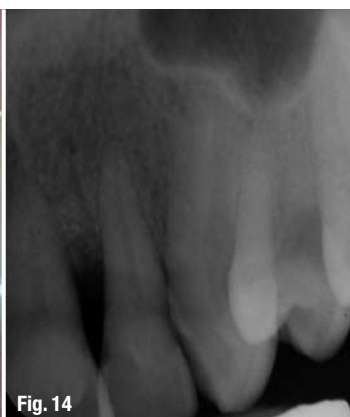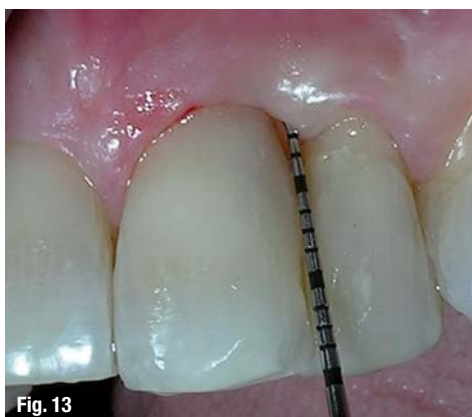**Tab. 2**

line. Second grade mobility, probably due to occlusal trauma was evident. Periodontal pocket probing depths were buccal 7 mm (Fig. 2), distal 9 mm (Fig. 3), mesial 3 mm and lingual 3 mm.

The plaque index (PI) and bleeding on probing (BOP) < 15% and the patient demonstrated high standards of oral hygiene. Radiographic exams (Fig. 4) showed a vital tooth with a normal root length. A wide angled non supportive bone defect was present at the distal side of the root.

Follow up was monitored with radiographs, with BOP- and PI-indexes and PPD, REC, CAL were registered. The occlusion was corrected by elimination of the pre-contact, no splint was placed.

After infiltration anaesthetics, the soft tissue incisions are made with a by Takei in 1995 proposed papilla preserve technique reflecting the lingual papilla to the buccal. The laser's angled handpiece mounts a chisel shaped tip, with which in contact mode the flapdesign is made. Laser power settings on 2.0 Watt, 30% Air, 10% Water, and 30 Hz.



Granulation tissues were removed (Fig. 5) with laser power settings on 2,5 Watt, 40% Air, 20% Water, and 25 Hz. Root-conditioning (Fig. 6) is performed holding the tip in a 1,5–2 mm distance from the root, in overlapping vertical and horizontal strokes, until the root-surface has a whitish etched aspect, with laser settings 1,5 Watt, 30% Air, 20% Water, and 20 Hz. The wide non-sustaining defect (Fig. 7) was filled with the demineralised bovine bone mineral (Fig. 8) to avoid collapse of the soft tissue into the defect. The bone substitute (Bio-Oss, Geistlich Biomaterials) was then covered with a resorbable collagen membrane (Bio-Gide, Geistlich Biomaterials) to avoid fibroblast in-growth. After releasing the buccal flap, the papilla is repositioned and sutures are placed and the wound is perfectly closed without tension. Patient received post-operative instructions.

### \_Results

Initial healing was uneventful although the tooth demonstrated I-grade mobility, which diminished in the first three months to zero. After two weeks sutures were removed and oral hygiene was resumed with brushing carefully the operated site. At six months remineralisation of the defect was evident on radiographic exam (Fig. 9). At one year significant CAL gains have been found, both on the buccal as on the distal. To further close the black triangle a composite filling was made on the mesial side of tooth 22 (Fig. 10). The PPD on the buccal went from 7 mm at baseline to 2 mm and had a CAL-gain of 6 mm which remained stable (Fig. 11). The PPD on the distal went from 9 mm to 4 mm in the first 12 months (Fig. 12). and measured at 60 months 3 mm (Fig. 13), with a final CAL-gain of 9 mm Radiographic follow-up showed regular alveolar bone outline with lamina dura at 60 months (Fig. 14).

### \_Discussion

According to evidence based therapy, a combination of barrier membranes and bone substitutes, is a standardized approach to treat wide non supportive bone defects (Camelo M. 1998). To be able to introduce the laser treatment in regenerative periodontal surgery, for debriding and decontaminating the bone defect , it needs to be taken in consideration that much knowledge in laser-dentistry is still experience based and widely discussed. Especially because there are many kinds of wavelengths, as well as very little evidence based research (Ishikawa I. 2008). In periodontal regenerative surgery the conditioning of rootsurfaces appropriately, is likely to be important for enhancing predictability of regenerative therapies (AAP, 2005). The introduction of the Er,Cr laser to debride the defect and decontaminate



the root is based on several findings. It is reported that this laser is suitable for the disinfection of even the deeper layers of dentin, because of its bactericidal effect (Schoop U. 2004). With the appropriate settings, an Er,Cr:YSGG laser is capable of performing scaling and root planing to remove calculus, and because of its short pulse, it may be especially suitable for the micro-morphology of the root surface (Hakki SS. 2010). Due to high absorption in water of laser energy, an effective ablation with a very thin surface interaction occurs on the irradiated tissues, and without any major thermal damage to the irradiated and surrounding tissues (Straßl M. 2004, Wang X. 2005). To avoid smearlayer caused by hand-instruments or detrimental effects of chemical root-conditioning (Blomlof J. & Lindskog S. 1995), the Er,Cr laser is used to clean and etch the exposed rootsurface. Furthermore the Er-wavelength seems to give comparable results to ultra sonic devices (Crespi R. 2007), without leaving a smearlayer however.

The AAP consensus statement declared, that research should be focused on identifying factors that can detoxify roots and also influence appropriate cell attachment (AAP 2005). Regeneration of periodontal tissues is reported in studies, where laser's decontaminative capacity created right circumstances for fibroblast attachment on root-surfaces (Feist IS. 2003), and in case reports this might have induced to clinical improvements in periodontal healing (Schwarz F. 2003). Er-laserwavelength is capable to ablate periodontopathic bacteria with thermal vaporization, and its bacteriacidal effect on the diseased root surfaces appears to be superior to that of the ultrasonic scaler (Akiyama F. 2010). Furthermore, the Er,Cr laser irradiation to perforate the alveolar bone of the defect to release blood, containing growth factors, could be advantageous for wound healing of bone tissues as comparative studies on bone healing suggested (Pourzarandian A. 2004). The application of Er-wavelength seem to be slightly more effective when platelet derived growth factors are involved for regeneration purposes and therefore a promising treatment alternative (Belal M.H. 2007).

**\_Clinical relevance statement & conclusions**

The application of an Er,Cr:YSGG laser with 2,780 nm wavelength, which substitutes the scalpel blade, root conditioning agents and hand- or ultrasonic instruments, demonstrate the possibility to integrate laser treatment successfully in various stages of advanced periodontal therapy. Clinically the Er,Cr:YSGG laser seems to contribute with its decontaminative capacities to create ideal circumstances for regenerative procedures which resulted in significant CAL-gain in this case report.

distal	baseline	12 mnts	24 mnts	60 mnts
PPD	9 mm	4 mm	3 mm	3 mm
REC	4 mm	2 mm	2 mm	1 mm
CAL	13 mm	6 mm	5 mm	4 mm

**Tab. 3**

mesial	baseline	12 mnts	24 mnts	60 mnts
PPD	5 mm	2 mm	2 mm	2 mm
REC	2 mm	3 mm	3 mm	3 mm
CAL	7 mm	5 mm	5 mm	5 mm

**Tab. 4**

Randomized controlled clinical trials and more basic studies have to be encouraged and performed to confirm the status of Er,Cr:YSGG laser treatment as an adjunct in traditional periodontal surgical therapy.

**\_About the author**

Dr Elena Speranza Moll graduated in Dentistry at the University of Amsterdam, The Netherlands. She established herself opening her office in the outskirts of Florence in Italy. She specialized mainly in Periodontology and Implantology. In 2003 she completed the post-graduate course on Laser Dentistry at the University of Florence. In 2004 on Laser Oral Surgery held by the L'Istituto Nazionale Tumori in Milan. She is since 1995 member of the SIdP, Italian Society of Periodontology and since 2003 of the International Society for Oral Laser Applications. She has participated to mod I and II of the Academy of Oral Laser Applications based in Vienna. She has lectured in national and international congresses and has given courses on the integration of laser techniques in evidence based treatment approaches in advanced periodontal and basic implantology treatments.

*Editorial note: The literature list can be requested from the editorial office.*

<b>_contact</b>	<b>laser</b>
<p><b>Dr Elena Speranza Moll</b>                  Private practice                  Via Amilcare Ponchielli, 21 B                  50018 Scandicci FI                  Italy                  E-mail: esmoll@tiscali.it                  odontoatria-laser@libero.it                  Tel.: +39 055 755347 / +39 335 625-0092</p>	

# “A man alone cannot do anything”

Author\_Kristin Urban, Germany

The World Federation of Laser Dentistry (WFLD) recently elected a new president. Prof Jean-Paul Rocca will take over the position from Prof Norbert Gutknecht, who has served a two years mandate. Our Editorial Office spoke with Prof Rocca about what he would like to achieve during his term.

**Prof Rocca, you were elected as President of the WFLD. Could you tell us some on your person?**

I consider myself as a discreet person and your question is awkward. I'm a full time professor in the Nice Sophia Antipolis University and university hospital. I have been the Dean of this Faculty and I'm actually in charge of clinical research unit. I passed two PhD (a long time ago): one in endodontics and one in human biology (bacteriology). I'm also the director for the European Master degree in Oral Laser Applications in Nice and a laboratory so-called laser technology and oral applications. I love my children, I like smiling and I'm crazy about classical music. Is it OK?

**WFLD is a well-known scientific society. As new President, what will be your role?**

WFLD is the first scientific society in the field of oral laser applications. WFLD being a federation of scientific associations my role, as you say, consists first of all to entertain good relationship with those national scientific associations and enhance their number as WFLD partners. Moreover individual members are welcomed; they join our society because they know perfectly that they will get the opportunity to hear at international opinion leaders'

experience in the field of oral lasers' applications and subsequently to improve standards on this technology. I observed, with a non masked satisfaction, that this number is increasing year after year.

The second role consists in opening our society to an increasing number of young clinicians and searchers. As you can imagine, future successes in oral laser medicine and surgery depends on exchanges, advancement and dissemination of basic and clinical research. Subsequently, we have a duty: they have to be considered as our future and they are the key for new progresses.

The third role consists in developing our five divisions (North America, South America, Middle-East-Africa, Asian-Pacific and Europe).

**Do you think WFLD can pretend to manage a leadership all over the world?**

This question is surprising but the answer could be very short: yes!

I saw in your eyes that "yes" was not sufficient and I will explain why and how.

Once again dissemination pass threw meetings, communications and therefore exchanges. Divisions were created five years ago by Prof. Namour and it's a nice surprise to see their activities are growing up in a significant mode and cover each two years the whole continents.



Divisions' activities are not in competition with National activities. National scientific associations are also acting seriously and many WFLD members are involved in those diligences too.

Moreover publications serve this objective. I observe that a lot of WFLD members publish high level scientific publications in referenced journals. Lasers in Medical Science and your journal, laser—International Magazine of Laser Dentistry are official journals of our society. One is dedicated to basic research and the second one to clinical observations. Thanks to Prof Gutknecht who was and is so much involved in that great mission. So, yes: WFLD can pretend!

**How WFLD could play a role in scientific dissemination?**

I think I answered clearly previously. General meetings, Division meetings, National scientific associations activities affiliated with WFLD, publications aim at this objective.

**With whom do you collaborate? Is the President a powerful person working alone?**

I'm convinced, since a very long period, that a man alone cannot do anything. A team represents a laboratory producing ideas to be discussed and eventually adopted.

WFLD is composed of an executive committee (ExCo) of ten persons. The executive board includes an immediate past-president (Norbert Gutknecht), the president, the president elect (Aldo Brugnera), the secretary (Kenji Yoshida), the treasurer (Carlo Fornaini) and a colleague in charge of the website and newsletter (Mathias Frentzen). Members are represented by the chairpersons of the five divisions (Carlos de Paula Eduardo, Loh Hong Sai, Toni Zeinoun, Georgios Romanos, Adam Stabholz). That means ten persons, nine countries represented. Since March 2010 were joined two co-chairpersons (Norbert Gutknecht and Samir Nammour): their mission consists in controlling the legal compartment of our society.

In those conditions, do you still think the President works alone?

**So, you consider WFLD to be a democratic association?**

Once again the answer is: yes, without any doubt.

Democracy is strictly observed. The ExCo is elected (general assembly) for a two years long mandate. Re-election of the President is possible but I observe that the tradition is a two years long

mandate. I agree with that kind of attitude. Democracy, respecting this turn-over of responsibilities, must be respected even if it's true that a two years long mandate is a very short one. In fact, efficacy is not disturbed due to the role of the past-president acting as a counsellor, if needed. Moreover, responsibilities are moving on also in the five divisions.

Finally, all continents are involved in the decisions and in WFLD Divisions all countries of each continents are, mandate after mandate, represented.

**You told that WFLD is a non-profit association. But members have to pay fees. Is there any contradiction?**

Of course, no!!!! Annual fees in WFLD are very low: 20 euros for students, 80 euros for members, 150 euros for members with the journal, 250 euros for national associations and it's more than four years we did not ask for increasing amounts!

There are no contradictions in paying dues, each year, and a non-profit scientific society!! Expenses do exist and may I tell you that a financial report is produced and submitted for approval by the ExCo and by members during the general assembly. In any case, if a President forget to present this report, the two legal co-chairmen would, at once, interfere.

**What are your next meetings?**

May I first congratulate the persons in charge of the last meeting, held in Dubai on March 2010. The Chairman of the congress: Toni Zeinoun as well as Samir Nammour in charge of the excellent scientific programme and Norbert Gutknecht acting as WFLD President.

The future is composed of a general meeting to be held in Barcelona (2012). Next year the ExCo will propose for 2014 (at the moment we have two candidates but it's a secret!!!). Moreover don't forget that we have our five Division meetings each uneven year. You are invited to look at our website ([www.wfld.org](http://www.wfld.org)) and you will get details.

**Do you have a wish?**

I hope, WFLD to continue on that way: to stimulate the research and coordinate clinical studies.

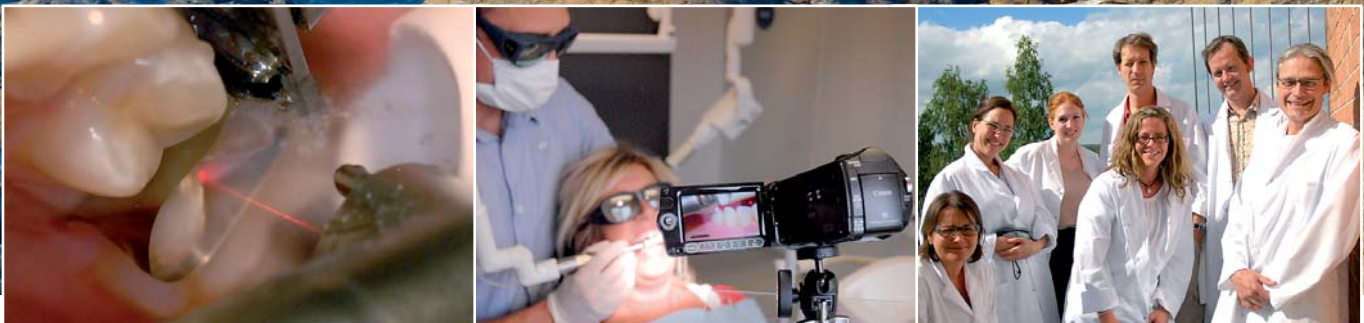Due to the fact I'm neither a magician nor a fakir, acting close with the WFLD team, I hope to be able to demonstrate my personal engagement and serve efficiently this scientific association.

**Prof Rocca, thank you very much.**



# 2010—A breakthrough for **Laser Supported Dentistry** in Sweden

**Author**\_Dr Peter Fahlstedt, Sweden



**\_The Opening of the ILSD/AALZ Educational Center in Akersberga outside Stockholm, Sweden, represents a breakthrough for the development of Lasers in Dentistry in this northern area of Europe.**

The co-operation between the world leading educational Institute in this field, AALZ, the Aachen Dental Laser Center at RWTH Aachen University, and ILSD, The Institute for Laser Supported Dentistry, Sweden, underline the need of an international network for evidence based knowledge. After a time when the first boom of lasers in Swedish Dental Clinics had declined due to the absence of qualified education, dentists in the Nordic Countries can now receive University level education in a wide range of individually designed courses.

Nordic dentists with non or little experience from lasers are now implementing new treatment proto-

cols in there daily practice. Diagnostics, cariology, periodontology, endodontics, surgery, pediatrics are some of the specialities in dentistry where patients and operator experience obvious benefits from this knowledge. In workshops at ILSD the dental staff are trained in different wavelengths and parameters for each specific indication. Live-demonstrations transferred via intranet along with instructive videos/foto documentation, accompanies the scientifically based lecture material.

In addition, the first days in sunny June 2010 the first workshop "Lasers in Periodontics" for Dental Hygienists was carried out. This group of dental care specialists responded very well and a new era in Prophylactics for Hygienists may be born.

To ensure a remained high quality, DDS, MSc Peter Fahlstedt at ILSD Sweden is, together with other



international co-workers of AALZ, continually updated at RWTH University by the Scientific leader Professor Norbert Gutknecht. New research results are penetrated and if accepted taking the place of "out to date" material in the lectures. One of the main goals for ILSD is to encourage and support different national research projects, constituting a reference for needed objective facts. A number of projects are initiated and will hopefully contribute to higher knowledge and acceptance of laser as a primary choice of safe, precise and predictable treatment methods when discomfort, infections and inflammations are unwanted.

In January 6–9, 2011, the second international Scandinavian Mastership Course will starting up with participants traveling from around the globe. The leading lecture team from AALZ will during four days perform the first part of this one-year-certifi-

cation course in this english spoken practical Fellowship Course. We welcome international dentists to participate in order to build up a long lasting world wide network of well educated dentists in Laser Supported Dentistry.

For extensive information, please go into our web-site: [www.ilsd.se](http://www.ilsd.se)

**\_contact**

**laser**

**ILSD/AALZ Educational Center Sweden**

Dr Peter Fahlstedt

**Co-operator**

AnnCharlotte Fahlstedt

E-mail: [peter.fahlstedt@ilsd.se](mailto:peter.fahlstedt@ilsd.se) or

[annchas.fahlstedt@ilsd.se](mailto:annchas.fahlstedt@ilsd.se)



# AALZ Greece successfully established

Authors\_Dimitris Strakas, Greece, Dominique Vanweersch, Germany



**\_Laser assisted dentistry** is already a reality for dentists worldwide. The possibilities for successful treatments using a laser as stand alone or supplementary to conventional techniques equipment are increased. Simultaneously the dentists realize that apart from a modern tool for every day practice, laser is a technology that involves a biophysical background and scientific knowledge that is not provided by the standard academic studies in dentistry.

AALZ has been since 1991 the leader in this field. In cooperation with the Clinic for Conservative Dentistry, Periodontology and Preventive Dentistry at the University of Excellence RWTH Aachen, the Aachen Dental Laser (AALZ) has created the first dental laser education institute in Germany. Known for its research in laser-assisted dentistry, it cooperates nationally and internationally with major research facilities. Recognized from dentists globally for its education system AALZ had already been the obvious choice for the Greek dentist who wants to keep up with future-oriented dental surgery.

AALZ Greece was founded in Greece for that reason and the Greek dental community welcomed it highly. The local scientific co-Workers of AALZ in charge are Dr Antonis Kallis MSc and Dr Dimitris Strakas MSc. The training courses that are offered by AALZ Greece are:

## **\_Laser Safety Officer Course**

One-day course with official certification as a Laser Safety Officer (LSO). The innovative treatment methods of laser therapy include risks for both practitioners and their teams as well as for patients if fundamental technical, biological and physical information about the application and laser safety measures are not or insufficiently known. Dentists will be prepared for safely using lasers by giving them an in-depth understanding of laser physics and laser-tissue interaction. After completing successfully the examination they will receive the "Laser Safety Officer" certificate. Our laser safety courses meet the requirements of the trade associations for obtaining expertise as a Laser Safety Of-





ficer. They are officially recognized according to the guidelines of BGV B2 (orientated to EN 60825-1 and ANSI Z136.1) and State Radiation Protection Office.

### **\_"Introduction to Laser Dentistry" Course**

Over the course of three hours, we inform you neutrally and objectively about how the various laser systems work and are applied. Using practical demonstrations, we show the effect that different laser systems have on various types of tissue. A therapeutic overview of the individual wavelengths aims to help participants to decide on the appropriate system for their treatment emphasis.

### **\_Workshops on specific wavelengths**

Dentists gain in an one-day clinical workshop on a specific wavelength an official certificate from the RWTH Aachen University Hospital. Lasers function with diverse wavelengths that have distinctive effects on tissue. Depending on the tissue to be treated, there are specific types of lasers for optimal use in the diverse fields of application. Each wavelength-specific workshop gives you scientific-based knowledge on possible treatments using the appropriate laser:

Solid-state lasers: Nd:YAG, Er:YAG, Er,Cr:YSGG

Gas laser: CO<sub>2</sub>

Diode lasers: 655 nm, 810 nm, 940 nm, 980 nm

### **\_Mastership Course „Lasers in Dentistry"**

"One-year clinical specialization course for selected wavelengths"—This offer is geared towards dentists who would like to specialize in certain wavelengths. In this one-year certification course participants are taught to fundamental physical and technical knowledge and how to recognize primary, secondary, and tertiary indications on ten attendance days split into modules. After successful completion of the course, participants acquire a certificate from RWTH Aachen University, identifying them as a "Lasers in Dentistry"

specialist. On January 30, 2010, the first LSO Course took place in Athens. The first ten participants from all over Greece had a long but fruitful day of laser safety lectures and of course the normal anxiety of the written exam at the end of the day. After successfully completing the multiple choice test the participants received their Laser Safety Officer certificates from RWTH Aachen University.

On June 18, the second LSO Course, organized by AALZ Greece took place in Loutraki, Athens, with 13 participants. In the venue facilities of a five-star Hotel, the participants received the fundamental knowledge on laser physics and laser safety in order to successfully answer the test on the end of the day.

### **\_Upcoming Events and Courses**

AALZ Greece has already planned the following activities:

\_Exhibitor on the Panhellenic Congress in Athens  
22–24 October 2010

\_Laser Safety Officer Course—15 November 2010

\_One-year Mastership Course. Module 1 starting date  
—15,16 November 2010

\_Workshop on diode lasers—January 2011

AALZ Greece is a pioneer in laser education in Greece. It is another corner of the world in which AALZ provides recognized and accredited training and helps you meet your goal of becoming a laser specialist.

\_contact

laser

**Dr Antonis Kallis**

**Dr Dimitris Strakas**

Tel.: +30 21 06251577

Fax: +30 21 06254856

E-mail: aalzgreece@gmail.com

Website: www.aalz.gr

# International events

## 2010

### 19<sup>th</sup> Annual Scientific Meeting of EAO

Where: Glasgow, Scotland  
Date: 06–09 October 2010  
Website: [www.eao.org](http://www.eao.org)

### 13<sup>th</sup> Congress of APALMS

Where: Nagano, Japan  
Date: 08 & 09 October 2010  
E-mail: [asagai@shinano-iryo.or.jp](mailto:asagai@shinano-iryo.or.jp)

### Annual Congress of DGL

Where: Berlin, Germany  
Date: 29 & 30 October 2010  
Website: [www.dgl-online.de](http://www.dgl-online.de)

### LASER START UP 2010

Where: Berlin, Germany  
Date: 29 & 30 October 2010  
Website: [www.startup-laser.de](http://www.startup-laser.de)

### International Laser Dentistry Symposium

Where: Sydney, Australia  
Date: 1 & 2 November 2010  
Website: [www.wfld-org.info](http://www.wfld-org.info)

### Start Mastership Course „Lasers in Dentistry“ Greece

Where: Athens, Greece  
Date: 15 & 16 November 2010  
Websites: [www.aalz.gr](http://www.aalz.gr), [www.aalz.de](http://www.aalz.de)

### Greater New York Dental Meeting

Where: New York, NY, USA  
Date: 26 November–1 December 2010  
Website: [www.gnydm.org](http://www.gnydm.org)

## 2011

### Start Mastership Course „Lasers in Dentistry“ Scandinavia—Batch 2

Where: Akersberga/Stockholm, Sweden  
Date: 07–10 January, 2011  
Websites: [www.ilsd.se](http://www.ilsd.se), [www.aalz.de](http://www.aalz.de)

### 34<sup>th</sup> International Dental Show

Where: Cologne, Germany  
Date: 22–26 March 2011  
E-mail: [ids@koelnmesse.de](mailto:ids@koelnmesse.de)  
Website: [www.ids-cologne.de](http://www.ids-cologne.de)

### 3<sup>rd</sup> European Congress World Federation for Laser Dentistry (WFLD)

Where: Rome, Italy  
Date: 10 & 11 June 2011  
Website: [www.wfld-org.info](http://www.wfld-org.info)

## 2012

### LaserOptics Berlin

Where: Berlin, Germany  
Date: 19–21 March 2012  
Website: [www.laser-optics-berlin.de](http://www.laser-optics-berlin.de)







# 2010

# GREATER NEW YORK DENTAL MEETING

86<sup>th</sup>  
Annual Session

## FREE REGISTRATION\*

MEETING DATES:  
NOVEMBER 26 -  
DECEMBER 1

EXHIBIT DATES:  
NOVEMBER 28 -  
DECEMBER 1

The  
Largest  
Dental  
Convention/  
Exhibition/  
Congress  
in the  
United  
States



*\*Free registration  
before November 26*

Please send me more information about...

- Attending the Greater New York Dental Meeting
- Participating as a guest host and receiving free CE
- I speak \_\_\_\_\_ and am willing to assist international guests  
enter language



Name \_\_\_\_\_

Address \_\_\_\_\_

City, State, Zip/Country Code \_\_\_\_\_

Telephone \_\_\_\_\_ E-mail \_\_\_\_\_

Fax or mail this to:  
Greater New York Dental Meeting or  
visit our website: [www.gnydm.com](http://www.gnydm.com) for more information.



For More Information:  
Greater New York Dental Meeting™  
570 Seventh Avenue - Suite 800  
New York, NY 10018 USA  
Tel: +1 (212) 398-6922  
Fax: +1 (212) 398-6934  
E-mail: [info@gnydm.com](mailto:info@gnydm.com)  
Website: [www.gnydm.com](http://www.gnydm.com)



# XII<sup>th</sup> International Congress of the WFLD in Dubai

Author\_Prof Toni Zeinoun, Lebanon

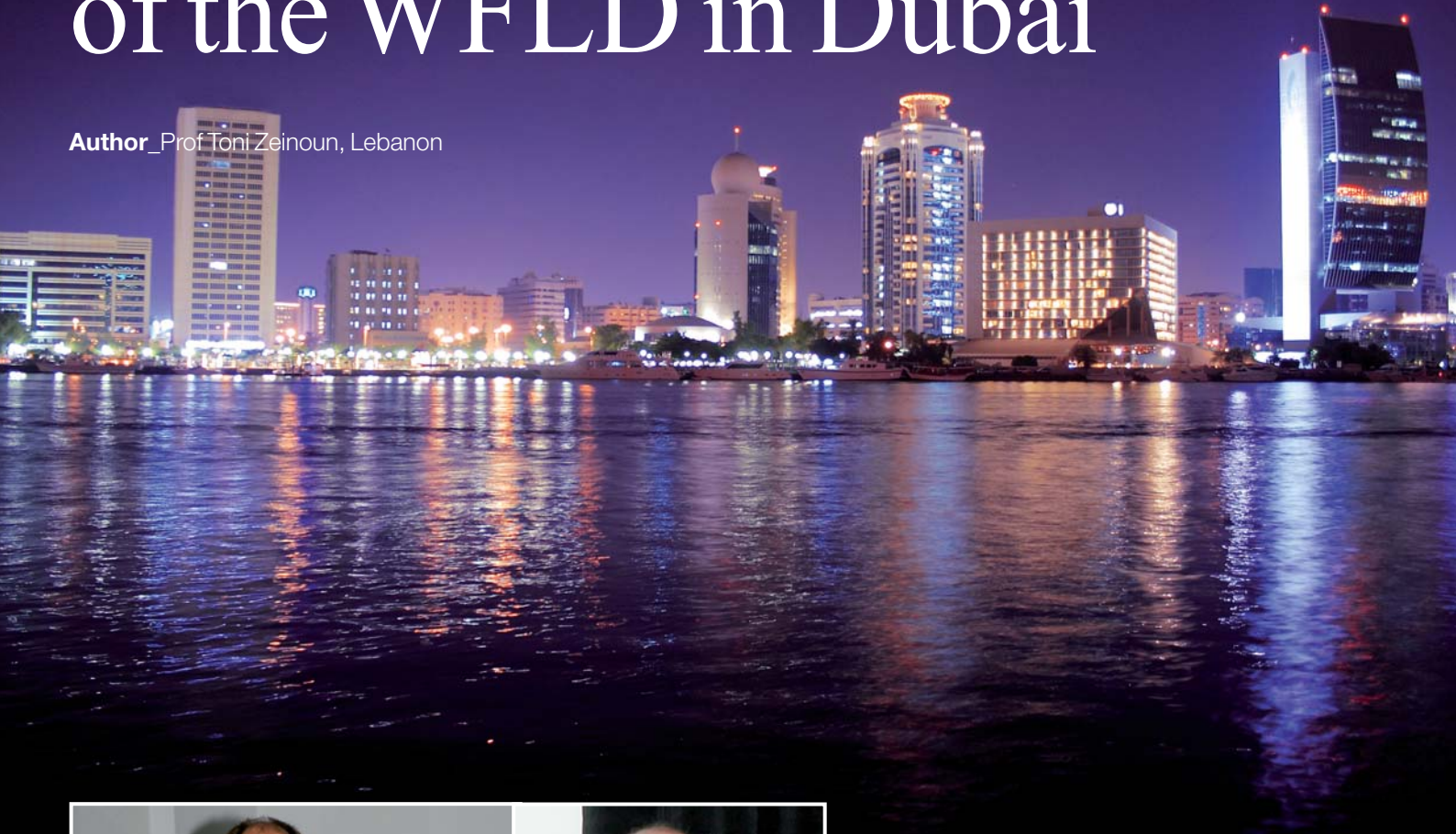

Fig. 1



Fig. 2

**Fig. 1** \_President of WFLD, Prof Dr Norbert Gutknecht.

**Fig. 2** \_Organizing Chairman, Prof Toni Zeinoun.

The annual meeting and the activities of the WFLD Executive Committee was held in Dubai from 7 to 8 March 2010 two days a head of the Dubai Congress. The agenda was then discussed; important decisions were made and prepared to be presented to the general assembly in the closing ceremony. The report of the Executive Committee will be presented in the Gen-

eral Assembly by the General Secretary of the WFLD Professor Aldo Brugnera.

The WFLD congress in Dubai was characterized by the participation of 144 speakers and researchers coming from 27 countries discussing for three days all the scientific issues in two halls: WFLD I and WFLD II. In addition to that, a poster session was organized with the participation of 80 poster presenters. Many dental faculties from Europe and South America were exposing their researches and developments in the laser field. This congress was held with the conjunction of the AEEDC Congress in Dubai in the Convention and Exhibition Center.

On the 9<sup>th</sup> of March, the congress started at 8:30 with an opening ceremony. The chairman of the Organizing Committee as well of the Middle East and Africa division, Professor Toni Zeinoun inaugurated the Congress by thanking all the speakers and the WFLD Divisions for their involvement in the Dubai Congress.



Fig. 3



Fig. 4

Professor Zeinoun specifically thanked President Gutknecht for all his efforts in contributing to the progress of the WFLD, the official society for laser in dentistry in the world. He additionally thanked Mr Abdul Salam Al Madani from Index for hosting the XII<sup>th</sup> International Congress in Dubai. Following on, Prof Zeinoun presented the chairperson of the Scientific Committee of the AEEDC Dr Nasser Malik. Dr Malik underlined the strong involvement of WFLD during this two years represented by Professor Norbert Gutknecht, the President of WFLD, and Professor Toni Zeinoun, the Organizing Chairman, and thanked them for all their efforts in contributing to the success of the scientific meeting in the region. Afterwards Prof Gutknecht thanked in his speech all the participants in the congress and the AEEDC for her collaboration in hosting the XII<sup>th</sup> International Congress of WFLD.

The Organizing Chairman commented on the film showing the history and developments of the WFLD. Simultaneously, this film introduced and showed the countries and all the speakers participating in the Congress. The film was prepared by Mme Carla Zeinoun and Dr Théophile Rahall and got a good review from the audience.

According to the Executive Committee decisions, A plaque of appreciation was presented by the Organizing Chairman and the President of WFLD to Index Holding represented by General Manager Mr Anas Al Madani and Dr Nasser Malik representing the Scientific

Committee of AEEDC for their contribution and major efforts in hosting this congress. In addition to that, the Organizing Chairman and Prof Gutknecht awarded a plaque of appreciation representing a life membership to the Past Presidents of WFLD: Prof Samir Nammour, Prof Loh Hong Sai and Prof Isao Ishikawa.

All the badges and files of the speakers were taken from the WFLD Desk Office which was situated in the exhibition center. The Organizing Committee was delivering all the documents to the participants in the congress.




Fig. 5

This first day was characterized by the meeting of the country representatives and the affiliated associations. The decisions of the Executive Committee were discussed and, the congress of Barcelona 2012 was introduced by Prof Toni Espana and Prof Joseph Arnabat. A meeting of the European and South America division took also place.

For the first day, the Organizing Committee prepared a touristic program which included a dinner on the deck of the Sundibad boat for all the WFLD participants and their accompanists. In the same time, the Executive Committee of WFLD was invited to a VIP Gala dinner in the Rotana Hotel, where President Gutknecht and Prof Zeinoun were decorated by Mr Abdul Salam Al Madani the President of Index Holding. Also, President Gutknecht and the Chairman Prof Zeinoun presented two plaques of appreciation to the representatives of the Dubai health authority Dr Tareq Koory, and to Mr

Fig. 3\_WFLD Executive Board.

Fig. 4\_Prof Dr Norbert Gutknecht and Prof Toni Zeinoun together with Abdul Salam Al Madani (middle), President of Index Holding.

Fig. 5\_Scientific Chairman, Prof Samir Nammour.



**Fig. 6** WFLD members celebrated the XXII<sup>th</sup> anniversary of the society and where the spouses of the executive committees Mme Gutknecht, Nammour, Brugnera, Loh Hong Sai and Zeinoun cut the cake of the event with the new President of WFLD Prof Jean Paul Rocca.



**Fig. 6**

Abdul Salam Al Madani for their hosting, cooperation and collaboration in the success of the WFLD congress.

The second day was characterized by the scientific poster sessions. The jury of the Scientific Committee viewed and discussed the posters with their presenters in two sessions. The meeting of the North American division and Asian division took place on the 10<sup>th</sup> of March. The AEEDC Gala dinner was held in the Hayat Regency Hotel in the presence of the Prince of Dubai. The Executive Committees were presented by Prof Norbert Gutknecht, Aldo Brugnera and Toni Zeinoun. A table of honor was reserved for the Executive Committees of WFLD and special attention from Mr Al Madani to his guest.

On the third day, the meeting of the Middle East and African division took place; as well as the meeting of the jury of the Scientific Committee which designated the best poster and best oral presentation. The first award of oral presentation was designed to Dr Ambrose Chan from Australia and the first award for poster presentation was designed for Dr V. Aleksic from Japan. During his final statement, at the closure ceremony, the Organizing Chairman thanked all the participants and invited the Chairman of the Scientific Committee Prof Samir Nammour to reward the best oral and best poster presenter. According to WFLD Executive Committee, the best oral and poster presenter were rewarded by the Chairman of Scientific Committee Prof Nammour. A plaque of appreciation were delivered by the President Prof Norbert Gutknecht and Prof Zeinoun according to the Executive Committee decision.

*The TOP 3 in the poster presentation*

- 1<sup>st</sup> Dr V. Aleksic (Japan)
- 2<sup>nd</sup> Dr Sheila C.Gouw Soares (Brazil)
- 3<sup>rd</sup> Dr Alyne Simoes (Brazil)

*The TOP 3 in the best oral presentation*

- 1<sup>st</sup> Dr Ambrose Chan (Australia)
- 2<sup>nd</sup> Dr Marina Stella Bello Silva (Brazil)
- 3<sup>rd</sup> Dr Lahmouzi Jamila (Belgium)

The General assembly began with the participation of Mr Abdul Salam Al Madani. He congratulated the WFLD Executive Committee especially Prof Toni Zeinoun and the President Prof Norbert Gutknecht for the excellent organization and the success of the congress. Then he presented trophies to the organizing committee members and the invited speakers. A photo with the executive members was taken to commemorate the moment.

The General assembly of WFLD continued giving the approval for the report of Executive Committees and the decision of the divisions of WFLD. Prof Gutknecht present the executive committees decisions:

- The creation of legal affairs posts. Prof Norbert Gutknecht and Prof Samir Nammour were voted for these posts for a period of six years.
- The election of president elect Prof Aldo Brugnera.
- The election of Carlo Fornaini from Italia as a treasurer of WFLD.
- The election of Kenji Yushida from Japan as a general secretary of WFLD.
- The election of Adam Stabholz as a new chairman for the European division.

Prof Aldo Brugnera and Prof Abiko report to the General secretary and Treasurer. And the general assembly approved the two reports. Prof Gutknecht invited his team to present a report about the new modalities of our website where members can enter and paid their duties by pay pal directly. Then the president invited the Spanish team to present the WFLD congress 2012 in Barcelona. A film for the occasion was exposed. The Organizing Chairman announced the finishing of the general assembly and invited the Spanish team (Dr Toni Espana and Dr Joseph Arnabat) to come to the stadium where he presents the flag of WFLD to the team and where the XIII<sup>th</sup> International Congress of WFLD will take place in Barcelona at may 2012.

Finally, the last social activities of the congress was the Gala dinner who was held in restaurant Al Tannour in Dubai were Lebanese food and Arabic musical program were presented.

WFLD members celebrated the XXII<sup>th</sup> anniversary of the society and where the spouses of the executive committees Mme Gutknecht, Nammour, Brugnera, Loh Hong Sai and Zeinoun cut the cake of the event with the new President of WFLD Prof Jean Paul Rocca.

A plaque of appreciation was delivered to the Past President of WFLD Prof Norbert Gutknecht and for the Chairman of Scientific Committee Prof Samir Nammour for all their efforts contributing to the success of the congress by the WFLD Organizing Chairman Prof Toni Zeinoun.





ANNUAL DENTAL TRIBUNE STUDY CLUB

# SYMPOSIA AT THE GNYDM

NOVEMBER 28 – DECEMBER 1, 2010, 10:00 AM DAILY



For the third year in a row, the DTSC hosts its annual CE Symposia at the GNYDM, offering four days of focused lectures in various areas of dentistry. Find us on the Exhibition Floor in Aisle 6000, Room # 3.

Each day will feature a variety of presentations on topics, which will be led by experts in that field. Participants will earn ADA CERP CE credits for each lecture they attend. DTSC is the official online education partner of GNYDM.



PLEASE SEE PROGRAM DETAILS UNDER [WWW.DTSTUDYCLUB.COM/GNYDM](http://WWW.DTSTUDYCLUB.COM/GNYDM)

REGISTER NOW: [WWW.GNYDM.COM](http://WWW.GNYDM.COM)

FREE FOR REGISTERED GNYDM ATTENDEES, BUT PRE-REGISTRATION IS RECOMMENDED.

For more information, please contact Julia E. Wehkamp, C.E. Director, Dental Tribune Study Club  
Phone: (416) 907-9836, Fax: (212) 244-7185, E-mail: [j.wehkamp@DTStudyClub.com](mailto:j.wehkamp@DTStudyClub.com)

## SUNDAY, NOVEMBER 28

10:00 - 11:00 Howard Glazer, DDS, FAGD

**BEAUTIFIL: GO WITH THE FLOW - COURSE: 3020**

11:20 - 12:20 John Flucke, DDS

**LIGHT CURED ADHESIVE DENTISTRY - SCIENCE AND SUBSTANCE - COURSE: 3030**

1:20 - 2:20 Martin Goldstein, DMD

**A SIMPLIFIED APPROACH TO MULTI-LAYER DIRECT COMPOSITE BONDING - COURSE: 3040**

2:40 - 3:40 Jay Reznick, DMD, MD

**3D IMAGING AND CT-GUIDED DENTAL IMPLANT SURGERY - 3050**

4:00 - 5:00 Louis Malcmacher, DDS, MAGD

**TOTAL FACIAL ESTHETICS FOR EVERY DENTAL PRACTICE - COURSE: 3060**

## MONDAY, NOVEMBER 29

10:00 - 11:00 Mrs. Noel Brandon-Kelsch

**ECO-FRIENDLY INFECTION CONTROL-UNDERSTANDING THE BALANCE - COURSE: 4120**

11:20 - 12:20 Gregori Kurtzman, DDS

**INCORPORATING NEW ADVANCES IN DENTAL MATERIALS AND TECHNIQUES INTO YOUR RESTORATIVE PRACTICE - COURSE: 4130**

1:20 - 2:20 Damien Mulvany, DDS

**OPTIMIZING YOUR PRACTICE WITH 3D CONE-BEAM TECHNOLOGY - COURSE: 4140**

2:40 - 3:40 Edward Katz, DDS

**IMPROVING PATIENT CARE WITH 3D CONE BEAM COMPUTERIZED TOMOGRAPHY - COURSE: 4150**

4:00 - 5:00 George Freedman, Fay Goldstep and Edward Lynch

**SOFT TISSUE LASERS AND CARIES DIAGNOSIS - COURSE: 4160**

## TUESDAY, NOVEMBER 30

10:00 - 11:00 George Freedman, Fay Goldstep and Edward Lynch

**SOFT TISSUE LASERS AND CARIES DIAGNOSIS - COURSE: 5110**

11:20 - 12:20 Greg Diamond, DDS

**LASERS IN PERIODONTAL THERAPY - COURSE: 5120**

1:20 - 2:20 Dov Almog, DMD

**INTRODUCTION TO CONE BEAM CT (CBCT), ESPECIALLY AS IT PERTAINS TO PREVENTION OF FAILURES IN ORAL IMPLANTOLOGY - COURSE: 5130**

2:30 - 3:30 Maria Ryan, DDS, PhD

**DETECTING CORONARY HEART THROUGH PERIODONTITIS AND PERIIMPLANTITIS - COURSE: 5140**

4:00 - 5:00 Dwayne Karateew, DDS

**CONTEMPORARY CONCEPTS IN TOOTH RELACEMENT: PARADIGM SHIFT - COURSE: 5150**

## WEDNESDAY, DECEMBER 1

10:00 - 11:00 Mr. Al Dube

**BEST MANAGEMENT PRACTICE, WASTE MANAGEMENT FOR THE DENTAL OFFICE, AND OSHA COMPLIANCE - COURSE: 6060**

11:20 - 12:20 Glenn van As, DMD

**HARD AND SOFT TISSUE LASERS - COURSE: 6070**

12:45 - 4:45 Dr. Benedict Bachstein, Dr. David Hoexter, Dr. Jeffery Hoos, Dr. Dwayne Karateew, Dr. Enrique Merino, Dr. Ethan Pansick

**THE FIRST ANNUAL OSSEO UNIVERSITY SUMMIT: IMPLANT DRIVEN DENTISTRY - COURSE: 6080**

THIS PROGRAM IS SUBJECT TO CHANGE





# Laser dentistry and Implantology Symposium in Gaziantep a great success!

Author Leon Vanweersch, Germany



**The first Idealclub Knowledge Sharing Days** and Gaziantep Implantology and Laser symposium, in cooperation with Aachen Dental Laser Center (AALZ) and International Implant Education Center (IFZI), from June 4–6 in Gaziantep was a great success. Due to the timeless efforts of Hülya Kazak (President of Idealclub, founded by AALZ and IFZI) and her organizing team the symposium hall was with 250 participants from Turkey, Syria and other border countries fully booked, and many more interested dentists had to be disappointed because the congress was sold out! The symposium was held in the brand new hotel Novotel in the center of Gaziantep.

The symposium program was focused on the up-to-date and fascinating combination of oral implantology and the support of laser dentistry in daily clinical practice, and the participants got their money's worth with the excellent scientific program, the national and international outstanding presentations and the execution of after-congress postgraduate courses in laser dentistry and oral implantology. The industrial exhibition was very well attended and the companies were leaving very satisfied at the end of the event.

Under the presidency of Prof Dr Aslihan Üsümez and Dr Zafer Kazak MSc the first day was more focused on oral implantology with presentations from well known lecturers, like Prof Dr Manfred Lang, Prof Dr Aslan Gökbuğet, Prof Dr Selim Pamuk, Prof Dr Cetin Sevük and Dr Gassan Yücel. The importance of state-of-the-art oral implantology in daily practice was demonstrated in the presentations, where the auditorium appreciated the clinical integration of the different in the implantology market represented systems.

The second day was focused on the use of laser dentistry in daily practice and the mountain of advantages by using the several laser wavelengths in the right way. Prof Dr Norbert Gutknecht, Executive Director of the WFLD and President of the DGL, started this day with his—as usual—outstanding presentation about evidence based laser dentistry in daily practice. The fully packed auditorium appreciated highly his clear message concerning the evidence based use of the different wavelengths in the several fields of laser supported dentistry. Also the other presentations from Prof Dr Aslan Üsümez, Prof Dr Serhat Yalcin, Prof Dr Hakan Ozyuvaci and Dr Ilay Maden MSc showed the advantages of the supporting use of





lasers in the several fields of dentistry against classical treatment methods. The big amount of questions after the presentations and the lively discussions showed the interest of the auditorium in the topics and the intention to learn more about this exiting therapy technology.

The big advantage of having two different main topics in this symposium was certainly the introduction of a new therapy to those dentists who were interested in the "other" subject. Furthermore the presentations, which showed laser supported oral implantology cases were very much appreciated, especially when showing not only the medical advantages but also the financial advantages for the business of a dentist.

Another benefit for the audience was certainly the possibility to have discussions with two pioneers of implant and laser therapy, Prof Gutknecht and Prof Lang, especially for those dentists, which use these therapies in their practice having the possibility to share their experiences with them of these outstanding scientists.

The hotel venue was perfectly suited for the symposium because the convenient location in the center

of Gaziantep provided all possibilities for short excursions to the old town and his historical sites during the breaks and after the programs. Also the cultural program was exiting.

After a visit to the Gaziantep national mosaic museum the organizers invited on Saturday for a dinner party in a historical venue of the old town with the, especially in Turkey, very famous Gaziantep food specialties and traditional Turkish dances. During this evening we saw "one" big implantology and laser family enjoying the excellent food and dancing.

On the days after the symposium Idealclub and AALZ executed the modules 3 and 4 of the mastership course "Laser Therapy in Dentistry" certificated by RWTH Aachen University. This mastership course is a one-year clinical specialisation course in laser dentistry, running in different countries around the world by AALZ. The second version of this successful Turkish Mastership Course will start on Friday, October 1, 2010 in Istanbul.

*We thank the organizers and the symposium presidents for offering such a highly professional symposium in the beautiful city of Gaziantep.*



# “Tomorrow’s dentistry today”

Author\_Ralf Borchers, DDS, M.Sc.



From 2–4 April 2010, the Indian Academy of Laser Dentistry (IALD) held its 4<sup>th</sup> International Conference in Mumbai, India. This event was perfectly operated by the organizing committee under the leadership of Dr Suchetan Pradhan, MSc, President of the IALD and Director of Pradhan Dental Centre, Mumbai (India).

Location of the conference was the brand new “Courtyard Marriot” hotel near Airport Mumbai, which had opened its doors just one day before the congress started. This was certainly a good choice by the organizers because service and catering were excellent.

The pre-conference course on 2<sup>nd</sup> April, under the topic “Fun with Lasers”, was a promising lead up with already 75 participants. After a general introduction of laser history, laser physics and an overview of indications, a wide spectrum of treatment cases was shown and discussed. Afterwards a couple of workstations were waiting for the participants to get a picture of practical laser treatment by hands-on experiences with different types of lasers. The demand on the workstations and booths of the additionally held dental exhibition remained high the following two days and was accepted by the exhibitors with great pleasure.

On 3<sup>rd</sup> and 4<sup>th</sup> April the main conference offered a wide range of lectures covering scientific reports, case studies, facial rejuvenation and marketing of all laser systems used in dentistry. To ensure a great va-

riety the lectures were held by international presenters and professors from India, Israel, Canada, USA and Germany.

The audience, at least more than 250 dentists per day, followed the lectures highly interested and a whole bunch of questions was waiting for every speaker after he ended his/her lecture. The atmosphere was very good and familiar and everybody was very active to help the beginners in laser dentistry making their way in becoming specialists in this unique and extraordinary field of dentistry.

As a consequence of the conference a large part of the audience requested further education in laser dentistry. Many of them were informed by Dr Ralf Borchers, MSc (Germany) about the postgraduate master program “Lasers in Dentistry”, which is offered in Dubai (UAE) and Aachen (Germany) by the worldwide well known AALZ Aachen Laser Center (Germany) with its Scientific Director Professor Dr Norbert Gutknecht, President of the German Society for Lasers in Dentistry (DGL) and Executive Director of the World Federation for Laser Dentistry (WFLD).

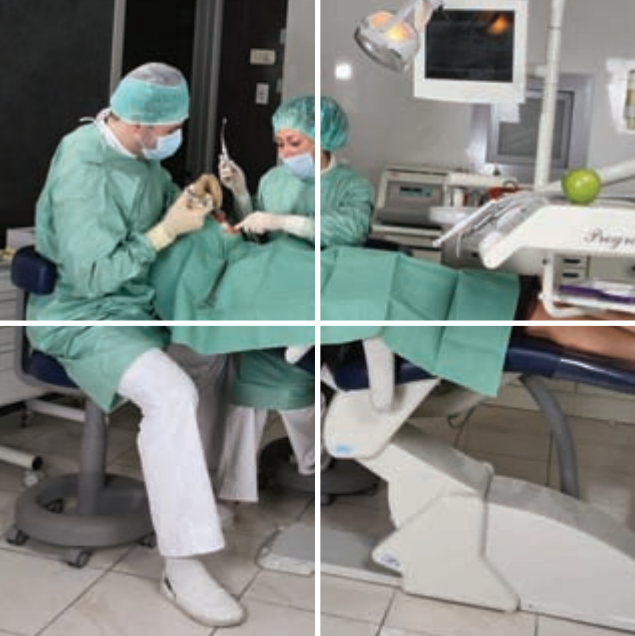

Additionally, the Pradhan Dental Centre, Mumbai (India) is offering a laser education program of constitutive modules in cooperation with the AALZ Aachen and experienced laser dentists from Germany. It was a successful conference which made every participant leaving with a smile and an improvement of knowledge in laser dentistry.

# DENTISTRY 2010



CME Accreditation

9 - 11 November 2010 • Abu Dhabi National Exhibition Centre, UAE



## The Definitive Dentistry Event in the Middle East

The conference will feature the most up-to-date information on the diagnosis and treatments available from international experts including:



**Renowned Dental Personality**  
 Prof Nasser Barghi,  
 Professor and Head of Division – Esthetic Dentistry,  
 University of Texas, San Antonio, USA



**Diplomate of the American Board of Oral Medicine**  
 Prof Juan Yepes,  
 Associate Professor and Director of Radiology,  
 University of Kentucky, USA



**Award Winner: Excellence in Dental Education**  
 Prof Patricia Reynolds,  
 Director of Flexible Learning – Dental Institute,  
 King's College, UK

Register your delegate place today  
[www.dentistryme.com](http://www.dentistryme.com)

Supported By



Organised By



Member Of



Media Partners



+971 4 336 7334

+971 4 336 4021

[dentistry@iirme.com](mailto:dentistry@iirme.com)

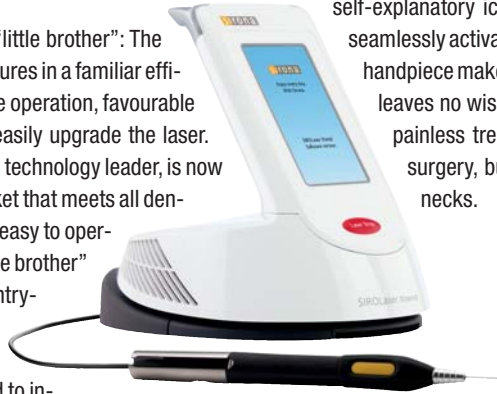
[www.dentistryme.com](http://www.dentistryme.com)

# Manufacturer News

## Sirona

### New laser makes entry into the premium class even easier

The successful SIROLaser Advance gets a "little brother": The SIROLaser Xtend offers all the important features in a familiar efficient form. Newcomers benefit from intuitive operation, favourable price-performance ratio and the ability to easily upgrade the laser. With the SIROLaser Xtend, Sirona, the dental technology leader, is now able to bring another diode laser on the market that meets all dental requirements for lasers, but is especially easy to operate and goes easy on the budget. As the "little brother" of the successful SIROLaser Advance, the entry-level model provides complete investment protection despite leaner technology because the SIROLaser Xtend can be upgraded to in-



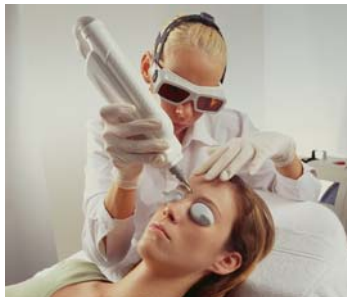
clude all the functionality of Advance with the exception of the wireless foot control. In regards to operation, users of the SIROLaser Xtend do not have to compromise because like the Advance professional model with colour touch-screen, the "little" diode laser features clearly structured menu navigation and self-explanatory icons for intuitive and straightforward ease of use. The seamlessly activated finger switch integrated in the ergonomically shaped handpiece makes activating the laser easy. Also the range of applications leaves no wish unmet: Preset therapy programmes ensure quick and painless treatment of patients in periodontology, endodontics and surgery, but also for herpes, aphthous ulcers and sensitive tooth necks.

**Sirona Dental Systems GmbH**  
 Fabrikstraße 31  
 64625 Bensheim, Germany  
 E-mail: [contact@sirona.de](mailto:contact@sirona.de)  
 Website: [www.sirona.com](http://www.sirona.com)

## Laservision

### New multi-use laser safety eyecaps for patients

During medical laser treatment eye protection of the patients is extremely important. By offering the completely novel laser safety eyecaps "CAP2PROTECT" LASERVISION takes care of this challenge and provides patients excellent eye protection for laser treatment in the facial



area. Present eye caps are made in most cases out of rigid material like metal or plastics. They are typically connected together with a nose bridge and hold in position by an additional head strap. In contrast to that the new LASERVISION eye caps feature a unique self-adhesive effect. This effect is a basic material characteristic and doesn't become lost even after multiple reuses. The adhesive part of the cap keeps it securely in a position which protects the

eye of the patient against incident laser radiation and stray light from all directions. As designed for the medical market, the caps are of course suitable for sterilisation. In order to increase laser protection and mechanical stability the eye caps feature an additional metal insert on the top side. Due to its small size and thickness the wearing comfort is not affected at all.

**LASERVISION GmbH & Co. KG**  
 Siemensstr. 6  
 90766 Fuerth, Germany  
 E-mail: [info@lv.com](mailto:info@lv.com)  
 Website: [www.uvex-laservision.com](http://www.uvex-laservision.com)

## KaVo

### Greater performance for more efficiency

The KaVo KEY 3 LASER with its gentle, effective and low-pain application in periodontics, conservative dentistry, endodontics and surgery has been established in dental practices for years. Together with a new periodontic handpiece, KaVo presented the KEY 3 plus LASER with greater performance than its predecessors and variable pulse lengths at IDS 2009. Through greater ablation speed in hard dental tissue and bone, treatment length is significantly reduced compared to conventional LASERs. Fine ablation with variable pulse length also permits finishing the cavity margins. As a result, better aesthetics can be achieved than with conventional technologies. KEY 3 LASERs already in the market can be easily upgraded, with a very positive effect upon value preservation of existing systems.



In periodontics, the unique feedback system of the KEY 3 LASER allows the selective, complete and low-pain removal of calculus, with excellent protection of the root support structures. Bacteria are killed and any biofilm on the tooth surface is dehydrated and deactivated. The new periodontic handpiece 2261 is small and features an impressively easy exchange of application tips.

In conservative therapy, the Er:YAG LASER is suitable for caries preparation, enamel/dentine conditioning and fissure sealing. With the aid of the special, caries contact handpiece, the diseased tissue may be removed with direct intimate contact of the tooth surface, while using the feedback system.

Furthermore, the KEY 3 plus LASER is suitable for numerous other indications in endodontics and surgery, such as drying and sterilising the root canal, implant exposure and root tip resection.

**KaVo Dental GmbH**  
 Bismarckring 39  
 88400 Biberach/Riss, Germany  
 E-mail: [info@kavo.com](mailto:info@kavo.com)  
 Website: [www.kavo.com](http://www.kavo.com)



## submission guidelines:

Please note that all the textual components of your submission must be combined into one MS Word document. Please do not submit multiple files for each of these items:

- \_ the complete article;
- \_ all the image (tables, charts, photographs, etc.) captions;
- \_ the complete list of sources consulted; and
- \_ the author or contact information (biographical sketch, mailing address, e-mail address, etc.).

In addition, images must not be embedded into the MS Word document. All images must be submitted separately, and details about such submission follow below under image requirements.

### Text length

Article lengths can vary greatly—from 1,500 to 5,500 words—depending on the subject matter. Our approach is that if you need more or less words to do the topic justice, then please make the article as long or as short as necessary.

We can run an unusually long article in multiple parts, but this usually entails a topic for which each part can stand alone because it contains so much information.

In short, we do not want to limit you in terms of article length, so please use the word count above as a general guideline and if you have specific questions, please do not hesitate to contact us.

### Text formatting

We also ask that you forego any special formatting beyond the use of italics and boldface. If you would like to emphasise certain words within the text, please only use italics (do not use underlining or a larger font size). Boldface is reserved for article headers. Please do not use underlining.

Please use single spacing and make sure that the text is left justified. Please do not centre text on the page. Do not indent paragraphs, rather place a blank line between paragraphs. Please do not add tab stops.

Should you require a special layout, please let the word processing programme you are using help you do this formatting automatically. Similarly, should you need to make a list, or add footnotes or endnotes, please let the word processing programme do it for you automatically. There are menus in every programme that will enable you to do so. The fact is that no matter how carefully done, errors can creep in when you try to number footnotes yourself.

Any formatting contrary to stated above will require us to remove such formatting before layout, which is very time-consuming. Please consider this when formatting your document.

### Image requirements

Please number images consecutively throughout the article by using a new number for each image. If it is imperative that certain images are grouped together, then use lowercase letters to designate these in a group (for example, 2a, 2b, 2c).

Please place image references in your article wherever they are appropriate, whether in the middle or at the end of a sentence. If you do not directly refer to the image, place the reference at the end of the sentence to which it relates enclosed within brackets and before the period.

In addition, please note:

- \_ We require images in TIF or JPEG format.
- \_ These images must be no smaller than 6x6 cm in size at 300 DPI.
- \_ These image files must be no smaller than 80 KB in size (or they will print the size of a postage stamp!).

Larger image files are always better, and those approximately the size of 1 MB are best. Thus, do not size large image files down to meet our requirements but send us the largest files available. (The larger the starting image is in terms of bytes, the more leeway the designer has for resizing the image in order to fill up more space should there be room available).

Also, please remember that images must not be embedded into the body of the article submitted. Images must be submitted separately to the textual submission.

You may submit images via e-mail, via our FTP server or post a CD containing your images directly to us (please contact us for the mailing address, as this will depend upon the country from which you will be mailing).

Please also send us a head shot of yourself that is in accordance with the requirements stated above so that it can be printed with your article.

### Abstracts

An abstract of your article is not required.

### Author or contact information

The author's contact information and a head shot of the author are included at the end of every article. Please note the exact information you would like to appear in this section and format it according to the requirements stated above. A short biographical sketch may precede the contact information if you provide us with the necessary information (60 words or less).

### Questions?

Eva Kretzschmann  
e.kretzschmann@oemus-media.de

# laser

international magazine of laser dentistry



#### Publisher

Torsten R. Oemus  
[oemus@oemus-media.de](mailto:oemus@oemus-media.de)

#### CEO

Ingolf Döbbecke  
[doebbecke@oemus-media.de](mailto:doebbecke@oemus-media.de)

#### Members of the Board

Jürgen Isbaner  
[isbaner@oemus-media.de](mailto:isbaner@oemus-media.de)

Lutz V. Hiller  
[hiller@oemus-media.de](mailto:hiller@oemus-media.de)

#### Chief Editorial Manager

Norbert Gutknecht  
[ngutknecht@ukaachen.de](mailto:ngutknecht@ukaachen.de)

#### Co-Editors-in-Chief

Samir Nammour  
Jean Paul Rocca

#### Managing Editors

Georg Bach  
Leon Vanweersch

#### Division Editors

Matthias Frenzen  
*European Division*

George Romanos  
*North America Division*

Carlos de Paula Eduardo  
*South America Division*

Toni Zeinoun  
*Middle East & Africa Division*

Loh Hong Sai  
*Asia & Pacific Division*

#### Senior Editors

Aldo Brugneira Junior  
Yoshimitsu Abiko  
Lynn Powell  
John Featherstone  
Adam Stabholz  
Jan Tuner  
Anton Sculean

#### Editorial Board

Marcia Martins Marques, Leonardo Silberman, Emna Ibrahim, Igor Cernavin, Daniel Heyselaer, Roeland de Moor, Julia Kamenova, T. Dostalova, Christliebe Pasini, Peter Steen Hansen, Aisha Sultan, Ahmed A Hassan, Marita Luomanen, Patrick Maher, Marie France Bertrand, Frederic Gaultier, Antonis Kallis, Dimitris Strakas, Kenneth Luk, Mukul Jain, Reza Fekrazad, Sharonit Sahar-Helft, Lajos Gaspar, Paolo Vescovi, Marina Vitale, Carlo Fornaini, Kenji Yoshida, Hideaki Suda, Ki-Suk Kim, Liang Ling Seow, Shaymant Singh Makhan, Enrique Trevino, Ahmed Kabir, Blanca de Grande, José Correia de Campos, Carmen Todea, Saleh Ghabban Stephen Hsu, Antoni Espana Tost, Josep Arnabat, Ahmed Abdullah, Boris Gaspirc, Peter Fahlstedt, Claes Larsson, Michel Vock, Hsin-Cheng Liu, Sajee Sattayut, Ferda Tasar, Sevil Gurgan, Cem Sener, Christopher Mercer, Valentin Preve, Ali Obeidi, Anna-Maria Yannikou, Suchetan Pradhan, Ryan Seto, Joyce Fong, Ingmar Ingenegeren, Peter Klee- mann, Iris Brader, Masoud Mojahedi, Gerd Voll- and, Gabriele Schindler, Ralf Borchers, Stefan Grümer, Joachim Schiffer, Detlef Klotz, Herbert Deppe, Friedrich Lampert, Jörg Meister, Rene Franzen, Andreas Braun, Sabine Sennhenn-Kirchner, Siegfried Jänicke, Olaf Oberhofer, Thorsten Kleinert

#### Executive Producer

Gernot Meyer  
[meyer@oemus-media.de](mailto:meyer@oemus-media.de)

#### Designer

Sarah Fuhrmann  
[s.fuhrmann@oemus-media.de](mailto:s.fuhrmann@oemus-media.de)

#### Customer Service

Marius Mezger  
[m.mezger@oemus-media.de](mailto:m.mezger@oemus-media.de)

#### Published by

Oemus Media AG  
Holbeinstraße 29  
04229 Leipzig, Germany  
Tel.: +49 341 48474-0  
Fax: +49 341 48474-290  
[kontakt@oemus-media.de](mailto:kontakt@oemus-media.de)  
[www.oemus.com](http://www.oemus.com)

#### Printed by

Messedruck Leipzig GmbH  
An der Hebemärchte 6  
04316 Leipzig, Germany

#### laser

international magazine of laser dentistry  
is published in cooperation with the World Federa-  
tion for Laser Dentistry (WFLD).

#### WFLD President

University of Aachen Medical Faculty  
Clinic of Conservative Dentistry  
Pauwelsstr. 30  
52074 Aachen, Germany  
Tel.: +49 241 808964  
Fax: +49 241 803389644  
[ngutknecht@ukaachen.de](mailto:ngutknecht@ukaachen.de)  
[www.wfld-org.info](http://www.wfld-org.info)

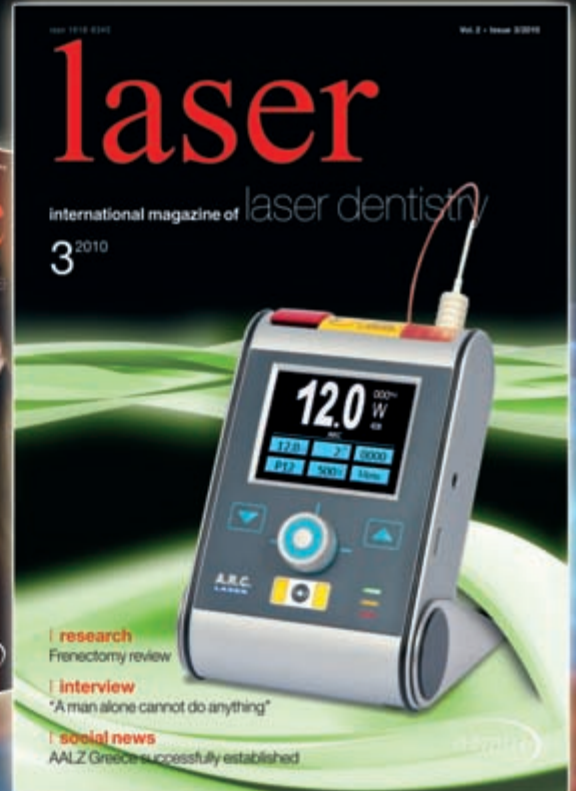
#### Copyright Regulations

\_laser international magazine of laser dentistry is published by Oemus Media AG and will appear in 2010 with one issue every quarter. The magazine and all articles and illustrations therein are protected by copyright. Any utilization without the prior consent of editor and publisher is inadmissible and liable to prosecution. This applies in particular to duplicate copies, translations, microfilms, and storage and processing in electronic systems.

Reproductions, including extracts, may only be made with the permission of the publisher. Given no statement to the contrary, any submissions to the editorial department are understood to be in agreement with a full or partial publishing of said submission. The editorial department reserves the right to check all submitted articles for formal errors and factual authority, and to make amendments if necessary. No responsibility shall be taken for unsolicited books and manuscripts. Articles bearing symbols other than that of the editorial department, or which are distinguished by the name of the author, represent the opinion of the afore-mentioned, and do not have to comply with the views of Oemus Media AG. Responsibility for such articles shall be borne by the author. Responsibility for advertisements and other specially labeled items shall not be borne by the editorial department. Likewise, no responsibility shall be assumed for information published about associations, companies and commercial markets. All cases of consequential liability arising from inaccurate or faulty representation are excluded. General terms and conditions apply, legal venue is Leipzig, Germany.

# laser

international magazine of laser dentistry



You can also subscribe via  
[www.oemus.com/abo](http://www.oemus.com/abo)



Subscribe now!

## One issue free of charge!

I hereby agree to receive a free trial subscription of **laser international magazine of laser dentistry** (4 issues per year).

I would like to subscribe to cosmetic dentistry for € 44 including shipping and VAT for German customers, € 46 including shipping and VAT for customers outside Germany, unless a written cancellation is sent within 14 days of the receipt of the trial subscription. The subscription will be renewed automatically every year until a written cancellation is sent to OEMUS MEDIA AG, Holbeinstr. 29, 04229 Leipzig, Germany, six weeks prior to the renewal date.

▶ Reply per Fax +49 341 48474-290 to OEMUS MEDIA AG or per E-mail to [grasse@oemus-media.de](mailto:grasse@oemus-media.de)

Last Name, First Name

Company

Street

ZIP/City/County

E-mail

Signature

Notice of revocation: I am able to revoke the subscription within 14 days after my order by sending a written cancellation to OEMUS MEDIA AG, Holbeinstr. 29, 04229 Leipzig, Germany.

Signature



sirona.

Notice:

Say goodbye  
to stress!

Laser dentistry  
with Sirona.

OK

Newcomers welcome.  
The new SIROLaser Xtend

Relaxed patients. Easy treatment. Improved post-operative healing. Is this all just wishful thinking? Actually, it's stress-free – and at your fingertips. Both the SIROLaser Advance and the upgrade-ready SIROLaser Xtend offer you all the benefits of modern laser dentistry. For periodontology, endodontics, surgery ... the list goes on! **Enjoy every day. With Sirona.**

www.sirona.com

Laser Stop

ADMED.com

The Dental Company

sirona.



- ISO: 8, 10, 15, 20, 25, 30, 35, 40, 45, 50, 55, 60, 70, 80, 90, 100, 110, 120, 130, 140
- Non-Standardized (Accessory sizes): XF, FF, MF, F, FM, M, ML, L, XL
- Special Taper Points: 04, 06

## گوتا فقط متا

✓ انعطاف پذیری بسیار بالا در حین کار

✓ پرفروش ترین در جهان

✓ رادیو اپستی عالی

✓ بی رقیب در قیمت و کیفیت

✓ مناسب جهت پر کردن کانال به روش تراکم جانبی و عمودی

✓ با بهترین بسته بندی ضد ریزش برای کاربری آسان



## کن کاغذی

موجود در انواع سایزها با قدرت جذب بالا، استریل و فاقد لایت در بسته بندی ۲۰۰ عددی کشویی ضد ریزش