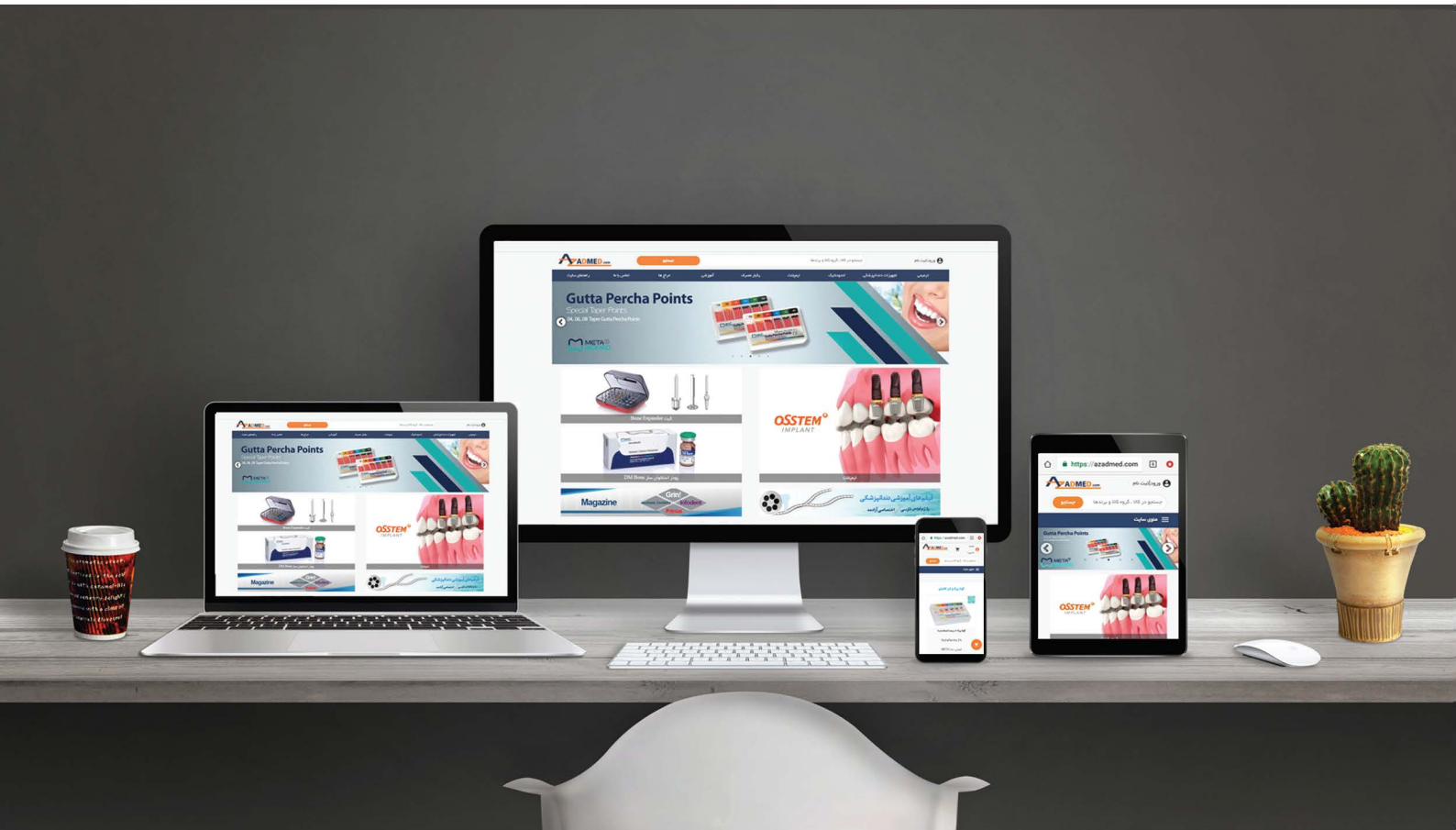




آزاد تجارات پارس
AZAD TEJARAT PARS.LTD

AZADMED.com



www.azadmed.com



 azaadtejaratpars

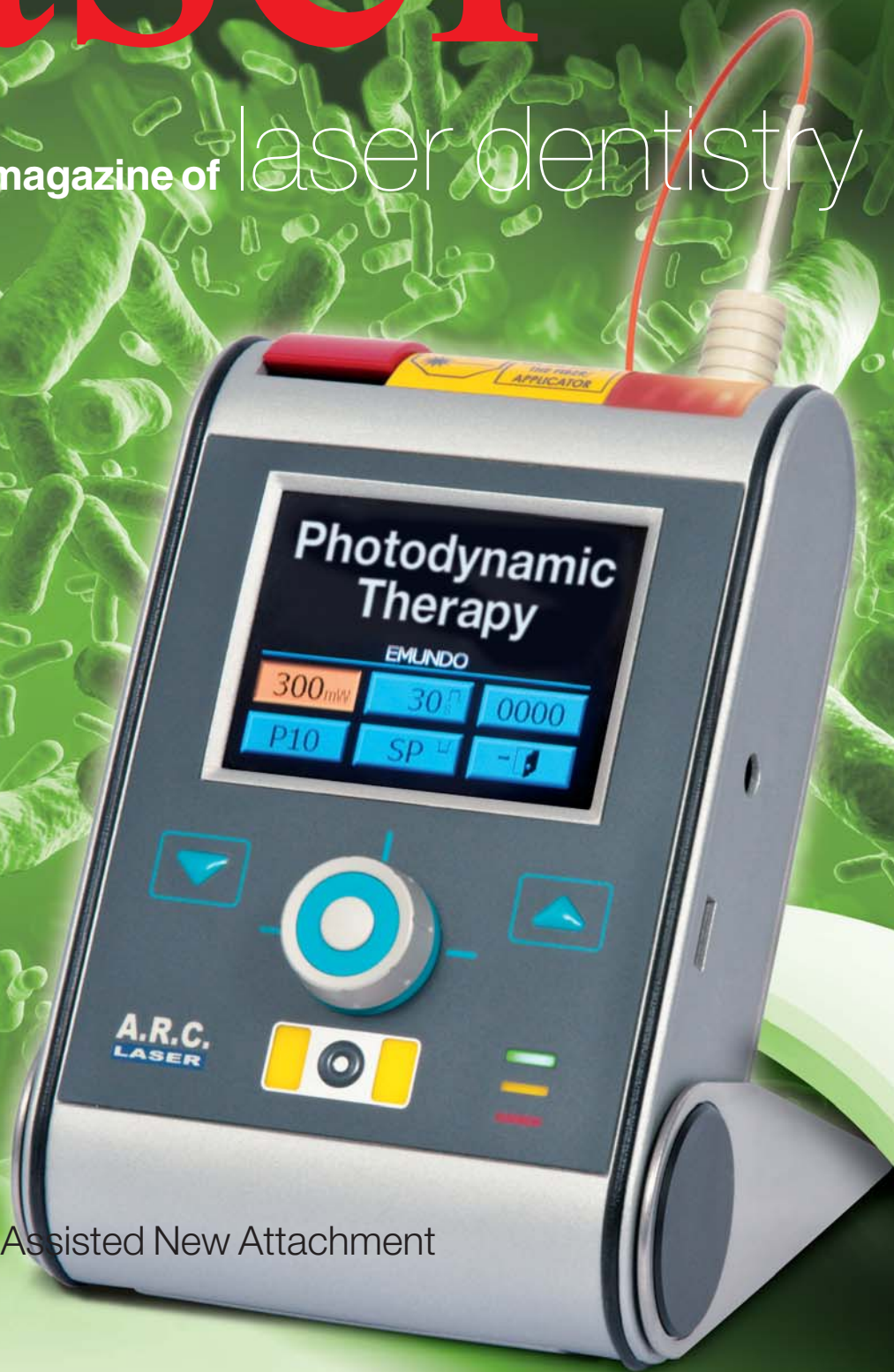
 @azadmed2

 88 98 80 63 - 6

laser

international magazine of laser dentistry

3 2011



| **overview**

LANAP — Laser-Assisted New Attachment Procedure

| **research**

Swap Drills for Light Energy

| **meetings**

3rd European Congress of the WFLD in Rome

0277113

After endodontic laser treatment there is no smear layer around the opening of the lateral canal.

The universe at your fingertips.



LightWalker[®]

Introducing the highest technology dental laser system

Supreme clinical results in:

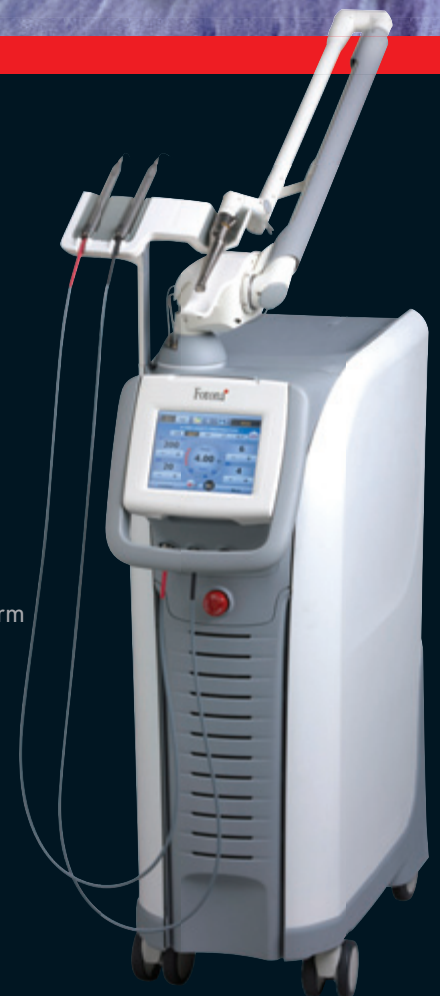- TwinLight™ Perio Treatments (TPT)
- TwinLight™ Endo Treatments (TET)
- No-sutures soft tissue surgery
- Gentle TouchWhite™ bleaching
- Patient-friendly conservative dentistry

Unmatched simplicity of use:

- Pre-sets for over 40 applications
- Intuitive user navigation
- Balanced and weightless OPTOflex arm
- Nd:YAG handpiece detection system
- Er:YAG scanner ready

Journey into a new dental experience with speed, precision and great results.
Visit www.lightwalkerlaser.com today!

Fotona
choose perfection



Happy Birthday DGL!



Prof Dr Norbert Gutknecht
WFLD President
Editor-in-Chief

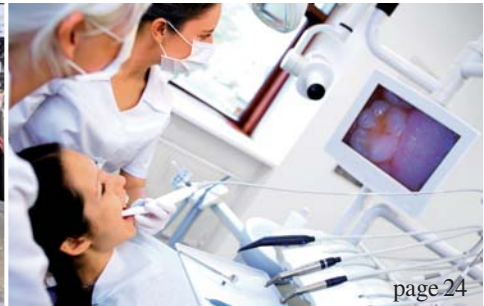
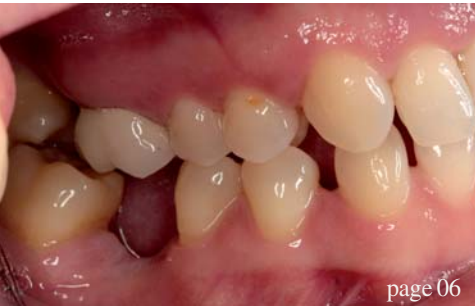Twenty years ago, the DGL (German Society for Laser Dentistry) was founded in Stuttgart, Germany. The DGL was the third laser society to be founded following the foundation of the ISLD (International Society for Lasers in Dentistry) in 1988 in Japan and the ALD (Academy for Laser Dentistry) in 1990 in the US.

In addition to the formation of international and regional societies, the establishment of national societies is one of the most important promotion activities in the field of laser dentistry in order to explain and promote the use of lasers in the daily dental office. Furthermore, national laser societies can establish positive relationships with national dental associations in order to dispel long-existing prejudices resulting from a lack of information.

The integration of the DGL into the German Dental Association (DGZMK) might prove to encourage all the other laser societies worldwide to continue developing a network with the dental associations and universities in their respective regions.

A handwritten signature in black ink, appearing to read 'Norbert Gutknecht', written in a cursive style.

Prof Norbert Gutknecht
Editor-in-Chief



| editorial

03 Happy Birthday **DGL!**
| Prof Dr Norbert Gutknecht

| overview

06 **LANAP**—Laser-Assisted New Attachment Procedure
| Dr David Kimmel

| research

10 Swap Drills for **Light Energy**
| Prof Matthias Frentzen

| case report

12 **Lase to amaze**
| Dr Kirpa Johar

16 **Treatment of epulis** using the 980 nm diode laser
| Dr Merita Bardhoshi

18 Novel technique for using the diode laser
to treat refractory erosive **oral lichen planus**
| Prof Dr Sajee Sattayut

| user report

22 **Laser ridge preservation**
| Dr Darius Moghtader

24 **Optical imaging** in the oral cavity
| Danielle Le *et al.*

30 **Morphological changes** in hard dental tissue
prepared using Er:YAG laser
| Dr Snejana Ts. Tsanova *et al.*

36 Efficient and ergonomic **apical resection** using the
Kaiserswerth algorithm
| Prof Marcel Wainwright

| feature

40 “The Scanner mode is going to **revolutionise dentistry**”
| An interview with Dr Ladislav Grad & Dr Matjaz Lukac

| meetings

42 **International events 2011 & 2012**

44 3rd European Congress of the **WFLD** in Rome
| Umberto Romeo

46 Basic **Laser Certification** Course in Malaysia

| news

48 **Manufacturer News**

| about the publisher

50 | Imprint



Cover image courtesy of A.R.C. Laser GmbH,
www.arclaser.de



Photodynamic breakthrough

**A.R.C.
LASER**

EmunDo[®]  **FOX**

- Extreme effective against Gram-positive and Gram-negative bacteria
- The reliable PDT-therapy – designed for the treatment of periodontitis



www.arclaser.de

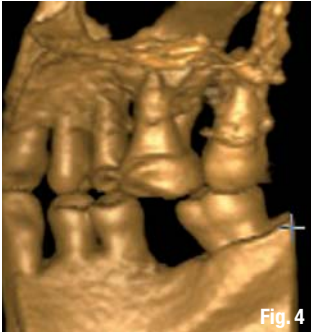


Fig. 4

DATE:	8/3/10																
EXAM TYPE:	Comprehensive <input type="checkbox"/> Limited <input type="checkbox"/> Screening <input type="checkbox"/> Reevaluation <input type="checkbox"/> Post-Operative Evaluation <input checked="" type="checkbox"/>																
TOOTH #	1	2	3	4	5	6	7	8	9	10	11	12	13	14	15	16	17
Pockets:	F 333	333	333	312	333	333	333	333	333	333	333	333	333	333	333	333	333
Recession:	F 2	3															
Na.AG:	F																
Ma.AG:	F																
Mobility:																	
Function:	F																
Codes:																	
Other:																	
H & N Exam:	Class: Malocclusion																
POS / NEG:	Fremittus in Sliding Movements: # in C.O.:																

Fig. 5

periodontal disease. Regeneration is a rather complex event and, as seen with guided tissue regeneration or scaling and root planning alone, can be very unpredictable. LANAP is predictable. Clinically, those clinicians who have been using the LANAP protocol for some time know this, and its predictability was reinforced when new attachment was found on all the LANAP-treated teeth in the initial histology studies done by Dr Ray Yukna. LANAP is also a very safe protocol. The use of the Nd:YAG laser has often been of concern by some owing to possible damage to root surfaces and the tissue attachment but, with a basic understanding of laser physics, laser-tissue interaction parameters were developed that enabled the use of an Nd:YAG in a very safe and effective manner. LANAP is also standardised. That is, before a doctor can obtain his laser he goes through three days of training: one day of laser physics and laser-tissue interaction and then two days of hands-on training with patients. This is then followed up by two more separate days of treating patients to refine techniques and add other treatment modalities utilising the Nd:YAG. Because of the simplicity, predictability and standardisation of LANAP, it has become a very safe and effective way to treat periodontal disease.

The simplicity of the LANAP protocol can be seen in Table I.

The LANAP protocol

Step A

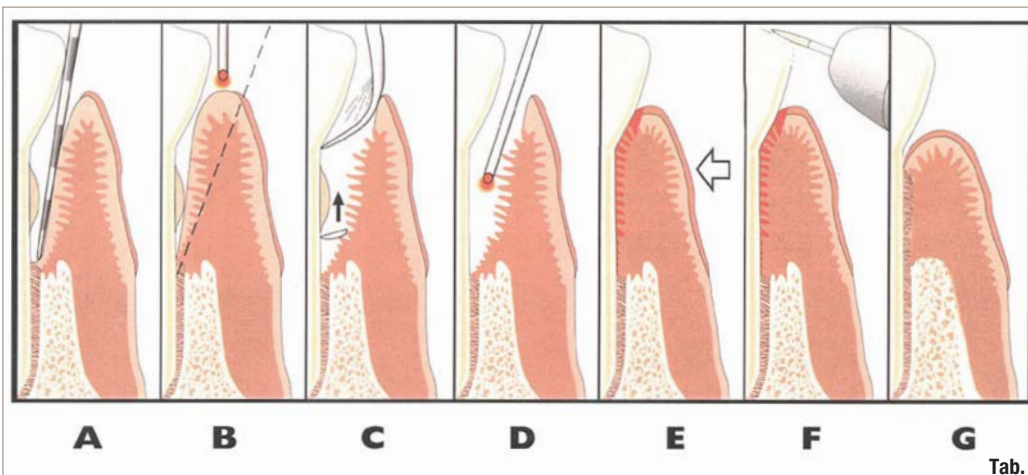
Patients undergo a full dental examination and treatment plan—as with all dentistry. If they have an appropriate diagnosis of Type III or greater periodontal disease, all treatment options are presented to the patient. The initial step of the LANAP protocol, after anaesthesia has been administered, is bone sounding around each tooth. The objective is to determine areas of osseous defects that cannot be seen radiographically.

Step B

This is the first time the laser is used. The objective of this step is to remove only diseased epithelium, to affect selectively bacteria associated with periodontal disease, to affect the calculus present, and to affect thermolabile toxins. The bacteria that are associated with periodontal diseases are pigmented and are found in the sulcus, within the root surface and within the epithelial cells. One of the reasons for the predictability of this step is in the selection of a free-running pulsed Nd:YAG laser with a wavelength of 1,064 nm and pulsed in a range of seven different microseconds. The shorter 1,064 nm wavelength was selected for its affinity for melanin or dark pigmentation, unlike the longer wavelengths that are highly absorbed in water and would have a shallow depth of

Fig. 4 Pre-op CBT scan.

Fig. 5 Post-op periodontal probing at 15 months.



Tab. I

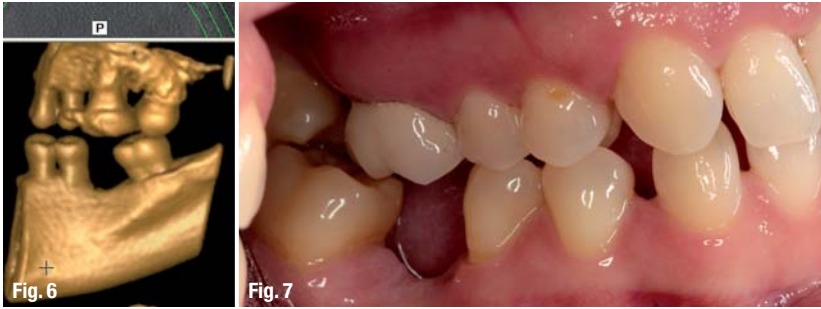

Fig. 6_CBT scan 15 months post-op LANAP.

Fig. 7_Pre-op photograph.

penetration. This ability to increase the depth of penetration of the laser energy with minimal collateral damage is the reason that the diseased epithelium can be selectively removed without damage to the underlying tissue, leaving intact rete pegs. The diode lasers are also known for this selective absorption in pigmented tissues, but the free-running, pulsed Nd:YAG lasers differ in their ability to operate at very high peak powers in very short time-frames, which allows the Nd:YAG to have the greater depth of penetration and the lack of collateral damage (Fig. 1).

Step C

This step in the LANAP protocol is straightforward; it is just a matter of using the piezo-scalers to remove the calculus present on the root surfaces. The removal of calculus is believed to be easier after the interaction of the laser energy with the calculus. The first interaction of the laser results in the initial formation of a mini-flap, thereby further assisting in the removal of calculus because of increased visibility and access to the calculus.

Step D

The next step again utilises the laser. This time the parameters are varied to enhance the ability to form a fibrin clot to close the mini-flap and to disinfect the site again. The formation of the stable fibrin clot is significant, as it is stable for approximately 14 days. The role of the fibrin clot is to keep the sulcus sealed against bacterial infiltration and to prevent the growth of epithelium down into the sulcus. Other laser wavelengths not only lack the ability to form this stable fibrin clot, but also require repeated

treatments to prevent epithelium growth down into the sulcus. The ability to select the laser-tissue interaction specifically is unique to the PeriLase MVP-7 (Millennium Dental Technologies). Through the use of specific fibre sizes, energy, repetition rates, pulse durations and standardisation of the energy at the fibre tip, this protocol can be followed in a predictable and reproducible manner. The high standard of training that each LANAP doctor receives also contributes to the predictability of this protocol and to its safety. Patients often present with different tissue types along with different degrees of disease. One of the purposes of the hands-on training is learning to recognise these differences and how to change the laser parameters accordingly so that the desired laser-tissue interactions are achieved. (Fig. 2)

Step E

The fifth step in LANAP is the compression of the fibrin clot to enhance the healing process. Because laser wounds heal by secondary intention, closer approximation enhances the healing time.

Step F

Following the compression and stabilisation of the clot, the last step of LANAP is refining the occlusion. Occlusion has been considered a greater co-factor in the progression of periodontal disease than smoking. In order to minimise this role, extensive adjustments are made to the dentition.

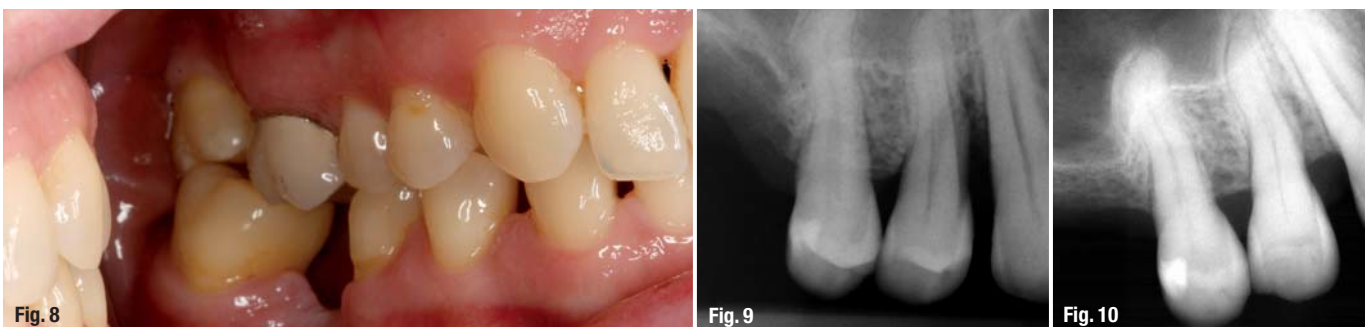
The patients are then followed for nine to 12 months with routine supra-gingival cleanings and occlusal refinements. No sub-gingival restorative or periodontal probing is done during this time. Only during the final post-operative visit is a periodontal probing done.

The results that are seen from LANAP treatment are very similar to the following cases, where new bone fill can be seen in vertical osseous defects. The bone fill ranges from simple proximal defects to the more complex furcation defects. The hallmark of LANAP is pocket reduction, new tissue attachment and a lack of tissue recession.

Fig. 8_Post-op photograph.

Fig. 9_Pre-op X-ray.

Fig. 10_Post-LANAP X-ray at 36 months.



_LANAP case 1

The patient in this case was a 40-year-old female patient with a history of lupus, rheumatoid arthritis and Sjögren's syndrome. She was also a smoker. There was generalised deep pocketing as seen in her periodontal charting (Fig. 3). The extent of the osseous defect is shown on the lingual view of the right quadrant preoperative CBT scan (Fig. 4). The initial post-LANAP evaluation was done at 15 months. Post-operative probing is shown in Figure 5. The CBT from the lingual view of the right quadrant at 15 months post-operatively is shown in Figure 6. The change in the osseous defects is apparent. Minimal to no recession is shown in the preoperative clinical photograph in Figure 7 and the post-operative in Figure 8.

_LANAP case 2

The patient in this case was a 59-year-old male patient, with Type 1 diabetes and a smoker. His periodontal pocketing was 7 mm on the mesial second premolar. The preoperative X-ray is shown in Figure 9 and the 36-month post-LANAP X-ray in Figure 10. The 7 mm pocket had been stable and maintained at 3 mm for the last 36 months. The LANAP protocol will be 21 years old this year. It is coming of age. It has stood

the test of time. There are over 1,000 trained clinicians applying LANAP. They have all been standardised. The uniqueness of the protocol is that whether the doctor is new to LANAP or a veteran "LANAP'er", his results are similar. During its early stages, early adopters accepted LANAP with anecdotal evidence alone, which was reinforced by the individual successes seen clinically. It was further validated by Dr Ray Yukna's histological studies in 2003. As the LANAP multicentre clinical studies move to completion, it would be reasonable to expect to see LANAP become the conventional manner or the standard for the treatment of periodontal disease. It is a very simple but eloquent protocol, one in which the patient has no to minimal discomfort and treatment acceptance is high.

_contact**laser****Dr David Kimmel**


12124 Cobble Stone Dr
Bayonet Point, Florida 34667
USA

E-Mail: dskimmel@mac.com
Tel.: +1 727 862 8513

AD

LaserHF®

Laser meets Radio Frequency

**LaserHF®****Worldwide first combined Laser plus HF unit**

- Pre-adjusted programs for all dental soft tissue treatments, with individual programming
- Easy handling by dual operating concept: touch-screen and automatic starting system
- Modern radio frequency surgery (2.2 MHz) allows easy, fast and precise cutting
- Diode laser (975 nm) for periodontology, endodontology and implant exposure
- Therapeutic laser (650 nm) for Low Level Laser Therapy (LLLT) and antimicrobial Photodynamic Therapy (aPDT)
- Good value of money

www.hagerwerken.de

Tel. +49 (203) 99269-26 · Fax +49 (203) 299283

Swap Drills for **Light** Energy

An interdisciplinary collaborative research project

Author_Prof Matthias Frentzen, Germany



The overall aim of prevention-oriented dentistry is to offer (laser) light-based diagnosis and treatment with outstanding capabilities. An example of this is the early detection of hidden carious lesions, which are clinically and radiographically barely detectable, using light-induced fluorescence. Through a combination of photosensitisers and light, bacteria-contaminated gingival pockets can be disinfected. Laser light is even capable of replacing the scalpel, allowing incisions resulting in reduced blood loss and benign alterations of the mucous membrane. These are just a few of the many new possibilities and developments in the clinical diagnosis and treatment of oral and dental disease through laser-based technology.

For 20 years, the Laser in Dentistry working group at the University of Bonn's Dental and Oral Health Centre has collaborated on research, directed by Prof M. Frentzen, and participated in a number of national and international development projects. This includes the collaborative MiLaDi (Minimally Invasive Laser Ablation and Diagnosis of Oral Hard Tissue) project for researching ultra-short pulse laser technology. The Federal Ministry of Education and Research-funded project involves a research collaboration between the Lasers in Dentistry working group and two industrial

companies: Sirona Dental Systems GmbH and Lumera Laser GmbH, a medium-sized business with many years of experience in manufacturing ultra-short pulse lasers in science and industrial material machining. The main goal of the MiLaDi project is to develop new laser therapy systems based on ultra-short pulse laser technology through the dental biological and medical research and testing of a laser diagnostic and treatment device with a large range of applications. The project has a total current budget of €6.8 million.

During the last few years, ultra-short pulse laser has been introduced to fundamental research in dentistry. This technology offers the prospect of treating oral hard and soft tissues efficiently and with minimal damage. The highly precise removal of biological tissues is expected to be associated with reduced pain as well.

The first experience of this technology was in the 1990's with the nanosecond, pulsed excimer laser, which radiated in the ultraviolet area of the spectrum. The newly developed ultra-short pulse laser technology is based on laser devices with wavelengths of around 1 µm (e.g. Nd:YAG lasers), and pulse durations of picoseconds to femtoseconds. Tissue ablation with this type of laser is not based upon the physical principle of absorption, but on non-linear optical effects with changes to plasma generation.

In the near future, short pulse laser therapy should enable users to:

- remove hard tooth substance (enamel, dentine, as well as caries) and mineralised concretions (such as tartar or concretions) in a minimally invasive manner with little or no pain, and allow an objective analysis of the material removed (Fig. 1);
- carefully handle surrounding tissue when treating bone (when performing orthopaedic surgery or implantology, for instance);

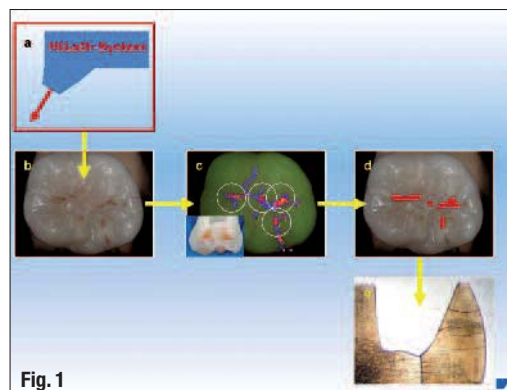


Fig. 1_Selected, fluorescence controlled caries removal.




Fig. 2




Fig. 3

Fig. 2_Fundamental examination of test samples on an optical bench.

Fig. 3_SEM of a laser drilled cavity.

- perform surgical procedures on healthy and diseased oral soft tissue, and carry out analysis of the material removed;
- perform biofilm management of plaque-associated diseases in the areas of cariology, endodontology and periodontology.

As a part of ongoing research, a fundamental examination is performed to examine the effect of ultra-short pulse radiation on biological tissue and restorative materials (Fig. 2). The detection procedure can then be tested, based on fluorescence and plasma spectroscopy.

To test clinical relevance in the treatment of dental hard tissue, the processing speed of enamel and dentine must be determined. The ablation volume of dentine, without air or spray filling, is approximately 10 mm³/min. The efficiency seems to improve significantly due to optimisation and in particular due to the scan parameter. Carious dentine can be ablated four times faster than healthy dentine.

The cavities do not show any histological indications of thermal damage but a smooth and extremely sharp-edged contour. It seems as though no smear layer forms (Fig. 3). Consequently, it is possible to prepare cavities with laser. In order to ensure a sufficient width of the therapy spectrum with ultra-short pulse laser technology, restorative materials were also tested with this technology to demonstrate the extent to which they could be handled. Clinically relevant ablation rates, by the usual tested materials, indicate the possibility of effective laser treatment of restorative materials (Fig. 4).

The basis for the surgical application of ultra-short pulse laser is the efficient and careful ablation of oral soft and hard tissue. As histological studies demonstrate, bone can be handled without spray and air cooling with no detectable side-effects (Fig. 5). The clinical efficiency is, according to available results, comparable to traditional methods.

The collaborative project is currently focusing on systematic examination relevant to laser parameters, as well as the development of a suitable radiative transfer system, including adequate detection systems. The results achieved so far are very promising and make patient-oriented advancement a possibility.




Fig. 4

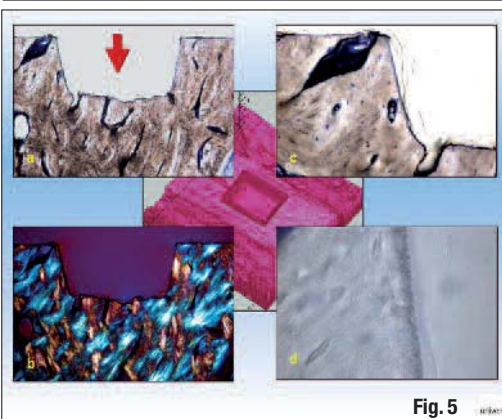


Fig. 5

_contact	laser
<p>AG Laser in der Zahnheilkunde Zentrum für Zahn-, Mund- und Kieferheilkunde der Rheinischen Friedrich-Wilhelms-Universität Bonn Welschnonnenstr. 17, 53111 Bonn, Germany</p> <p>Tel.: +49 228 287-22470 Fax: +49 228 287-22146</p> <p>frentzen@uni-bonn.de www.miladi.uni-bonn.de</p>	

Fig. 4_Photomicrograph of laser cavity in composite. The 3-D display of the same cavity appears on the right. The defined edges of the cavity are particularly distinguishable here.

Fig. 5_Histological section of a laser cavity in bone showing no side-effects.



Lase to amaze

Author_Dr Kirpa Johar, India

Today's patients expect restorations that are both functional and aesthetic. Unlike yesteryear's, today's patients have better knowledge of the advanced materials available and state-of-art equipment. Consequently, they have high expectations when designing their smile and other procedures to achieve optimum results. The specialist's main aim is to achieve complete oral rehabilitation in the most conservative manner.

When choosing a treatment option, dentists and technicians must satisfy both the clinical criteria and the patient's expectations. To design the optimal outcome for a patient during aesthetic enhancement, the dentist must seek to create a symmetrical and harmonious relationship between the lips, gingival architecture and the positions of the natural dentition.

Case report

A 27-year-old patient visited our practice with the chief complaint of attrition in the lower front teeth and generalised discoloration of all the teeth. He also complained of reduced visibility of the lower anterior teeth along with blackish discoloration of the gingiva.

Examination and treatment plan

Clinical examination revealed attrition of the lower anteriors up to the level of the middle third of the coronal tooth structure in relation to teeth #31, 32, 41 and 42. All the teeth were discoloured and extrinsic stains due to the patient's seven-year history of tobacco chewing (as reported by the patient) were present. Overall gingival asymmetry was observed. Generalised pigmentation of the gingiva was also observed (Figs. 1, 2). It was decided to treat the patient in four phases.

Phase 1: Preliminary phase

Impressions were taken and study models were prepared. An OPG was taken. Oral prophylaxis was done. The patient was recalled after two days for further treatment.

Phase 2: Surgical phase

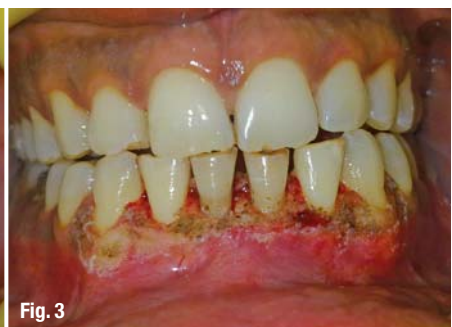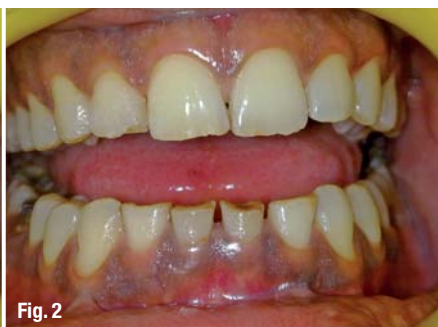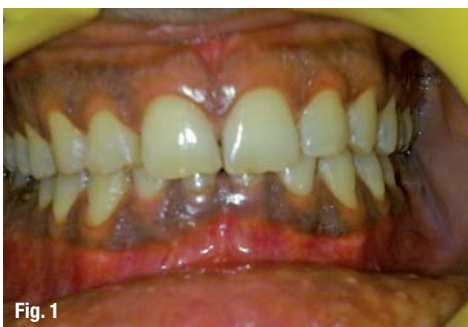The second phase entailed a laser-assisted gingivectomy and laser-assisted endodontic sterilisation.

Gingivectomy

Lasers offer increased operator control and minimal collateral tissue damage. The fine tip of the diode laser can be manipulated easily to create the gingival margin contours required to perform the aesthetic crown-lengthening procedure. The surgical site was anaesthetised and the biological width was determined. A 980 nm diode laser with a 400 µ cable was used for the surgical procedure. The amount of gingival tissue to be incised was outlined. Initial incision for the laser-assisted gingivectomy was similar to that of using a blade with an external bevel approach. The distance of the incision from the coronal marginal gingiva is based on the pocket depth and the amount of attached gingiva. The gingival chamfer is achieved and the initial cut is made slightly apical to the pocket depth measurement. A slow, unidirectional hand motion is used, moving the tip at an external bevel towards the tooth structure. Caution is necessary, especially near the root structure, because of a possible laser-hard tissue interaction, which could harm the tissue. During the course of surgery, care was taken to maintain the biological width and to preserve the attached gingiva (Figs. 3, 4, 5). The access cavity was prepared according to the traditional method. The rotary instruments were used along with the ProTaper files for cleaning and shaping the root canals.

Fig. 1 & 2_Initial clinical examination showing attrition and depigmentation of the mandibular anteriors.

Fig. 3_Immediately post operative.



*Express
your mastery*

Join the fast growing success of Syneron Dental Lasers

Presenting

LITETOUCH™

The unique fiber-free Er:YAG laser

Dentists' **1st** Choice
for hard and soft tissue procedures

To explore cooperation opportunities please contact dental@syneron.com
W W W . S Y N E R O N D E N T A L . C O M



Syneron™
DENTAL LASERS

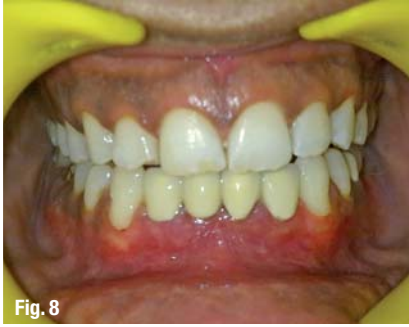
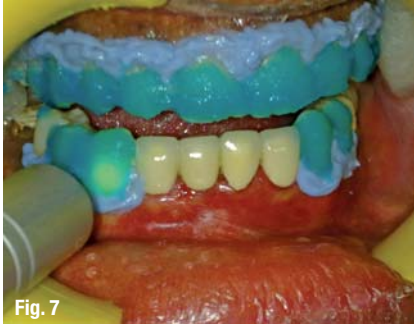
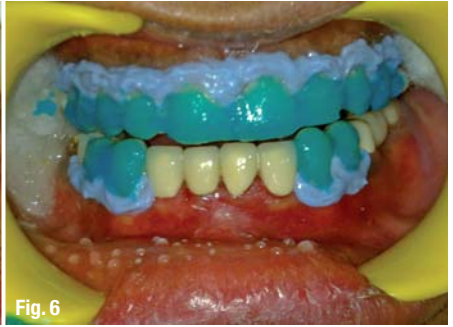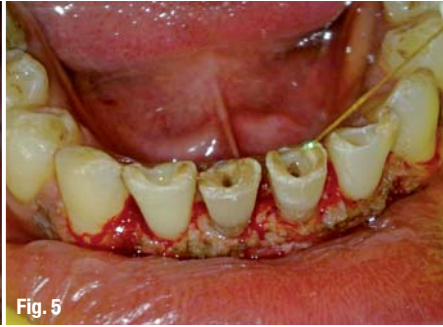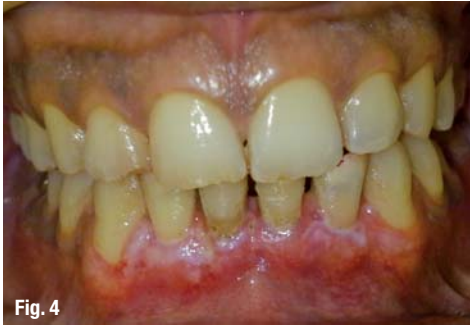Fig. 4 _ One week post operative.
Fig. 5 _ Laser assisted sterilization of the root canals in relation to 31, 32, 41 & 42.
Fig. 6 & 7 _ Laser assisted bleaching.
Fig. 8 _ Post operative intraoral view.

Sterilisation

A 980 nm diode laser with a 200 µ cable was used for sterilisation of the canals along with regular chemical disinfectants. The advantage of laser sterilisation to a conventional irrigant regime to provide sterilisation is that while irrigating solutions have a limited depth of penetration, the laser beam transmitted through the tip of a fibre is emitted in a lateral direction and has an effective penetration depth of more than 1,000 µm. This was followed by obturation and coronal access restoration with composites. The patient was recalled after one week for further treatment.

Phase 3: Aesthetic phase

The third phase entailed laser-assisted depigmentation and laser-assisted bleaching.

Depigmentation

The diode laser was used at 2 W, continuous wave in a defocused mode. This causes a reduced depth of penetration, ablating only the superficial epithelium, which primarily contains the melanin pigments, leaving behind a carbonised layer. Only a surface anaesthetic spray was used for this procedure.

Bleaching

Laser light has the unique property of being absorbed by the chromospheres. These emulsions can be added to the bleaching gel, which are capable of absorbing laser energy and thus inducing and promoting a fast, safe and effective reaction. Cheek and tongue retractors were positioned and a dry operatory was maintained. The gingival protection material was applied along the margin of the gingival covering approximately 1 mm from the tooth surface in the cervical region. The bleaching gel was applied to teeth #11, 21, 12

and 22. Each tooth was then irradiated for 30 seconds in the same sequence, constantly moving the tip of the laser, so that the laser energy was not directed at one place (at 1 W). Fluoride gel was applied to each tooth and irradiated with the laser for 15 seconds to provide resistance to acid attacks on enamel and dentine. The patient was recalled after two weeks.

Phase 4: Prosthetic phase

Crown preparation of teeth #42, 41, 32 and 31 was done. Elastomeric impressions were taken. Bite registration records were taken and the appropriate shade was sent to the laboratory for the fabrication of the crowns. Temporary restorations were fabricated using temporisation material. The patient was recalled after six days for the cementation of the crowns. Excess cement was removed, the occlusion was adjusted and contours were checked.

Inference

The final result showed that the definitive restorations and the soft-tissue procedures had restored the normal form, function and harmony of the oral cavity, while keeping the patient's functional and aesthetic concerns in mind.

_ Conclusion

Dental lasers promote patient compliance through the non-invasive nature of treatment, faster recovery time and reduced post-operative discomfort. The use of laser reduces chairside time and improves operator efficiency and thereby reduces fatigue.

_contact	laser
<p>Dr Kirpa Johar FF-3, Business Point, 137, Brigade Road, Bangalore 560004, India</p> <p>drkirpajohar@ldrr.org www.ldrr.org/home.html www.joharslaserdental.com/</p>	

**Lay the Foundations to your
successful Future now!**

Next master course starts: Aachen 26.09.11, Dubai 17.10.11



Master of Science (M.Sc.) in Lasers in Dentistry

Would you also like to be part of the International Dentists' Elite?

- The first accredited M.Sc. programme in dentistry in Germany
- Career-accompanying postgraduate programme of two years at the University of Excellence RWTH Aachen
- Internationally accepted and accredited by the German Government, the European Union, the Washington Accord and the Bologna Process
- Science-based and practice-orientated on highest national and international level
- Bronze Award of the European Union for „Life-Long Learning programmes“



Aachen Dental Laser Center

More information:

AALZ GmbH · Pauwelsstrasse 19 · 52074 Aachen · Germany
Tel. +49 - 2 41 - 9 63 26 70 · Fax +49 - 2 41 - 9 63 26 71
www.aalz.de · info@aalz.de

In cooperation with the University
of Excellence RWTH Aachen

**RWTHAACHEN
UNIVERSITY**

Treatment of epulis using the 980 nm diode laser

Author_Dr Merita Bardhoshi, Albania

Abstract

Fibromatous epulis is treated through surgical removal and a good treatment modality is the 980 nm diode laser. This article reports on the treatment of eleven patients with fibromatous epulis at the University of Tirana's Dental School. Diagnosis was confirmed by biopsy. The laser was used with a power setting of 4 to 6 W, 300 µm optical fibre, set at continuous wave and in focused mode. The patients were examined at one week, four weeks and six months to one year after surgery. Post-operatively, no bleeding, swelling or oedema was observed. The laser surgery was well accepted by all patients. Use of the 980 nm diode laser in the treatment of fibromatous epulis offers advantages for both the patient and surgeon.

envelop one or more teeth. The cause is unknown. An epulis is treated by surgical removal. A good treatment modality is laser surgery. Many different laser wavelengths have been used in the field of oral surgery and offer many advantages especially because of laser's high coagulation property and bactericidal effect.

The 980 nm diode laser is portable, compact, efficient and of benefit in the treatment of epulis. It can be used with infiltration anaesthesia, set at continuous wave (cw) and in focused mode. The short duration of surgery is an advantage of this method because it reduces the fear and anxiety that patients have during dental procedures. The aim of this report is to present the clinical effects of the 980 nm diode laser in the management of epulis and to demonstrate wound-healing characteristics after laser surgery.

Introduction

Fibromatous epulis refers to any benign lesion situated on the gingiva. Firm, pink tumours develop along the gums and while they are benign, non-invasive growths, they may become quite large and completely

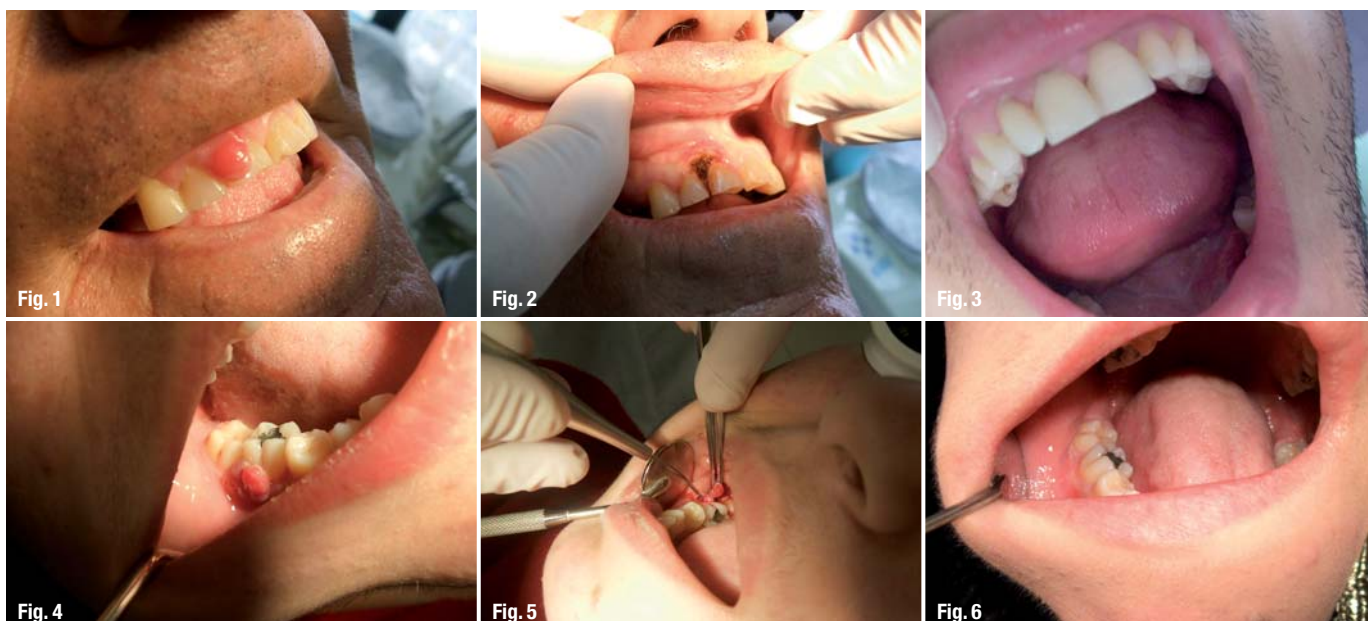
Material and methods

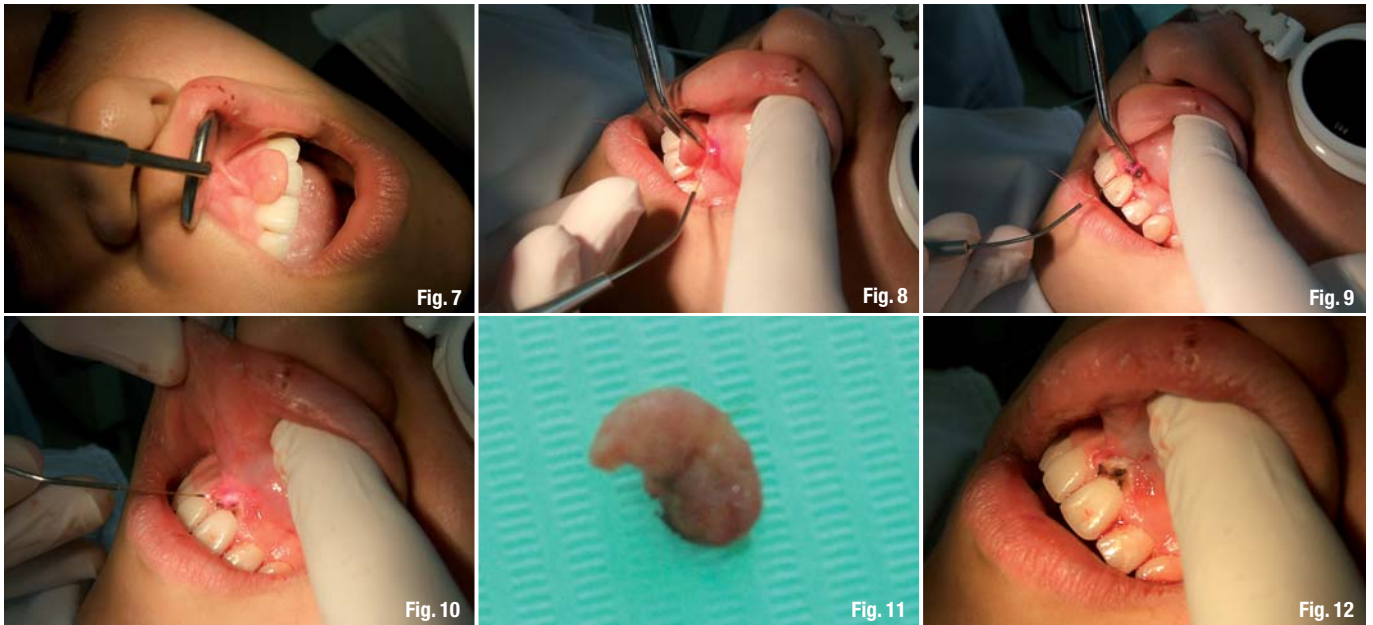Eleven patients aged between 14 and 50 with epulis participated in this study. Diagnosis was confirmed by biopsy. All clinical cases were treated as outpatients at

Figs. 1–3 Initial situation showing fibromatous epulis.

Fig. 4 During treatment: the lased area appears bloodless.

Figs. 5–7 Laser treatment of the lesions.





the Department of Oral Surgery at the University of Tirana's Dental School using the 980 nm diode laser. The laser parameters were as follows: 4 to 6 W power setting, 300 µm optical fibre, cw, focused mode. The specimens were histologically examined. All patients were examined at one week, four weeks and six months to one year after surgery for evaluation of early and long-term results. Written informed consent was obtained from all patients before treatment commenced.

Diode laser treatment

Before treatment, all precautions were taken for the safety of the patients, operator and assistant. Preoperative photographs were taken to document progress (Figs. 1, 2 & 3). Infiltration anaesthesia (lidocaine 2%, 1 cc) was used before each treatment. The diode laser was calibrated. The surgical technique was excision. Traction was applied to the lesion using forceps and it was excised along its base (Figs. 4, 5, 6 & 7). No sutures were placed (Fig. 8) and all specimens were histologically examined (Fig. 10). The histopathological examinations confirmed fibromatous epulis. No bone problems were revealed by X-rays and neither the teeth adjacent to the epulis nor any part of the jawbone had to be removed. The surgery took four to six minutes. The patients were advised to put ice on the lesion to prevent oedema and given instructions regarding follow-up.

Results

The patients were followed up at one week, four weeks and six months to one year after surgery. At one week, the patients were examined for pain, bleeding and swelling. In post-operative clinical observations (eleven clinical cases), no pain, swelling or bleeding was reported. All patients resumed their normal activities

(school, job) immediately after surgery. No analgesics or antibiotics were prescribed. At four weeks, the wound-healing characteristics were evaluated. All patients reported good, comfortable healing without complications or functional disturbance (Figs. 11 & 12). At six months to one year, there was no recurrence (Fig. 13). In general, patient acceptance of laser treatment was high.

Conclusion

Laser surgery is a treatment modality for epulis that offers beneficial effects and advantages. An intra-operative advantage is the high coagulation property of the 980 nm diode laser, owing to its good absorption by haemoglobin, which allows the surgeon a good view of the operating field. As post-operative advantages, wound-healing was without complication and there was no pain, bleeding or swelling one week after surgery. The short duration of surgery minimises patients' fear and anxiety during the procedure. Laser surgery was well accepted by all the patients. In conclusion, the treatment of epulis with laser offers advantages for both the patient and surgeon.

Figs. 8 & 9 Immediately after treatment.

Fig. 10 The specimen excised.
Fig. 11 Wound-healing after four weeks.

Fig. 12 Four weeks after surgery, the wound has healed completely.

contact

laser

Dr Merita Bardhoshi

Department of Oral Surgery
Dental School
University of Tirana
Tirana, Albania

meritabardhoshi@yahoo.com

Novel technique for using the diode laser to treat refractory erosive oral lichen planus

Author_Prof Dr Sajee Sattayut, Thailand

Refractory erosive oral lichen planus (OLP) is a common oral disease and treatment thereof poses a considerable problem in oral medicine. Conventional surgery, cryosurgery and CO₂ evaporation can offer temporary pain relief without promising healing of the ulcer. This article presents a case report of erosive OLP that did not respond to a topical steroid and only partial symptomatic pain relief by low intensity laser and CO₂ laser irradiation was obtained. Complete healing of the ulcer was achieved two weeks after treatment according to the laser welding technique using an 830 nm diode laser (continuous wave) for two treatment episodes. The three-month follow-up showed no ulceration or symptoms.

Introduction

Oral lichen planus (OLP) is a common autoimmune disease resulting from auto-cytotoxic T lymphocytes triggering apoptosis of epithelial cells, leading to chronic inflammation of oral mucosa. Regarding the symptoms, atrophic and erosive OLP are generally painful for sufferers.¹ The management of OLP is still symptomatic relief by reduction of inflammation, aiming for pain control. There is a range of treatment options, such as avoiding initiating factors, applying a topical steroid, or taking an immune-suppressive drug or systemic steroid.¹ Low intensity laser therapy is an additional therapy for conservative treatment of OLP.² For refractory OLP, particularly erosive OLP, treatment

choices are surgical methods such as surgical removal with a free soft tissue graft, cryosurgery and CO₂ laser evaporation.^{1,3} The results of these surgical methods appear to be satisfactory in terms of pain relief, but not promising in terms of healing of the lesion, particularly in the case of erosive OLP and recurrence overall. Concerning the risk of malignant transformation of long-term OLP, especially the erosive type,^{1,4} an innovative therapy for recovery from OLP ulceration is still under consideration. Regarding the laser technique for treating OLP, the welding technique with the benefit of promoting closure of the surgical wound margins in large vessels and skin⁵ has not been applied to treatment of this oral lesion. This report introduces the novel technique of using the diode laser to treat an erosive OLP case with no response to a topical steroid and only partial pain relief from refractory to low intensity laser therapy and CO₂ laser irradiation.

Case report

A 55-year-old male patient was referred by his general dentist for treatment of refractory erosive OLP with spontaneous moderate pain and severe pain when drinking and eating.

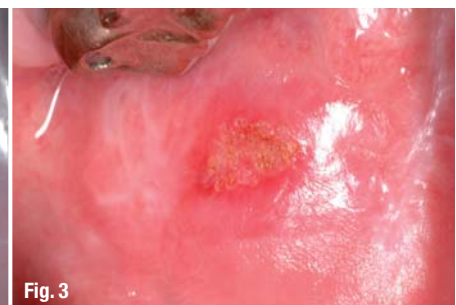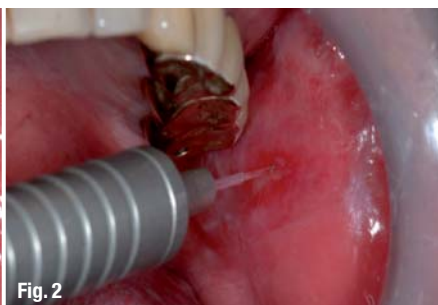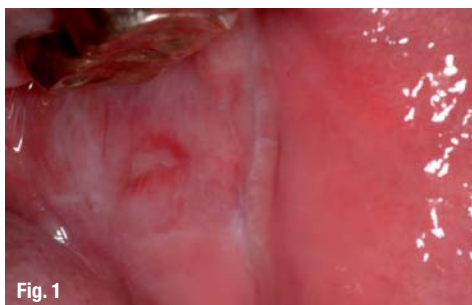Past history of treatment

The diagnosis was confirmed by histopathological investigation. The patient had no response to treatment

Fig. 1_The erosive OLP lesion before laser welding.

Fig. 2_The laser welding procedure for treating OLP using an 830 nm diode laser.

Fig. 3_Immediate post-laser welding of the OLP lesion.

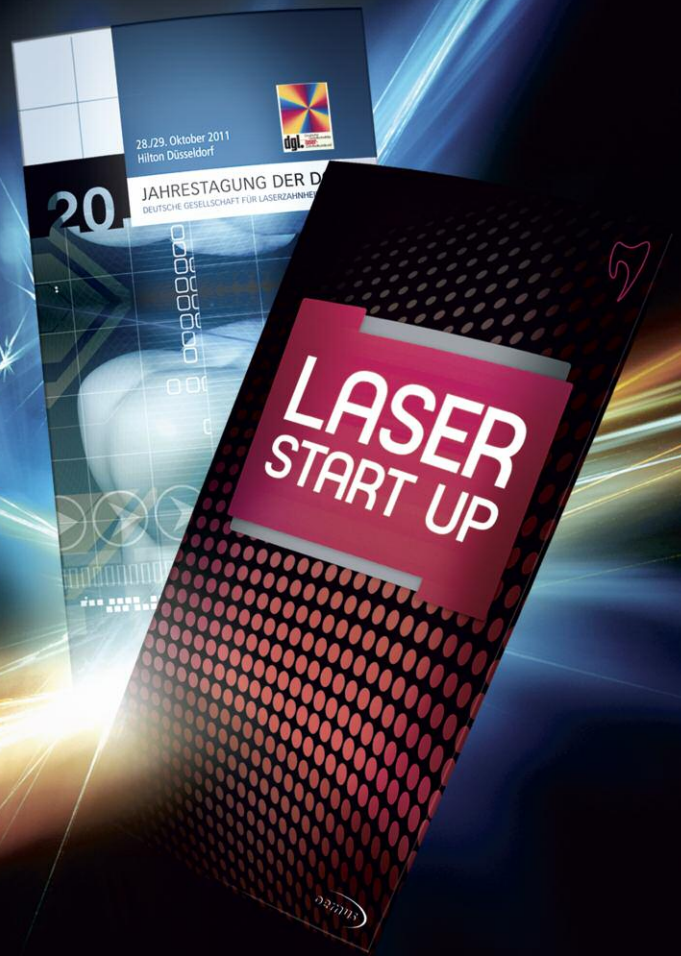

fascination of laser dentistry

20th ANNUAL CONGRESS OF THE DGL e. V.
LASER START UP 2011

October 28–29, 2011

Düsseldorf, Hotel Hilton Düsseldorf, Germany



Please fax this form
+49 341 48474-390

More information:

20th ANNUAL CONGRESS OF THE DGL e. V.

LASER START UP 2011

October 28–29, 2011, Düsseldorf, Germany

NAME

E-MAIL

OFFICE STAMP

laser 3/11

Fig. 4_ Recovery of the buccal mucosa from OLP one week after the first laser welding.

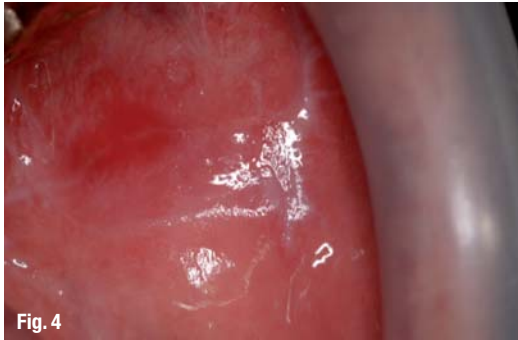

Fig. 4

Fig. 5_ Recovery of the buccal mucosa from OLP one week after the second laser welding.

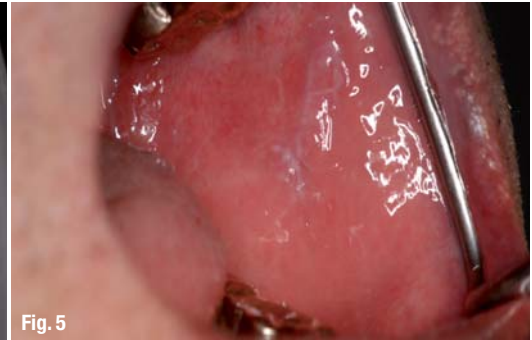


Fig. 5

with a topical steroid for three months and could not tolerate the side-effects of severely oily skin and generalised acne from the systemic steroid. He had no known allergies or systemic disease.

The patient had then been treated with low intensity laser therapy (830 nm, continuous wave, 100 mW, 4 J) once a week for four treatment episodes and defocused CO₂ laser (continuous wave, 1 W) irradiation with a high water content absorbing gel once a week for two treatment episodes. These laser treatments partially relieved pain and offered some temporary reduction in the size of the ulcer but did not bring complete recovery. The patient continued to complain of pain in the region of the ulcer, stimulated by drinking and consuming spicy foods.

Oral examination

The extra-oral examination showed no palpable superficial cervical lymph nodes or other significant abnormality. From the intra-oral examination, there was a 2 x 4 mm ulcer covered with a yellowish slough and surrounded by a 1 to 2 mm band of erythematous mucosa (Fig. 1).

Laser welding technique and result

A novel laser technique, laser welding, was undertaken using an 830 nm diode laser (continuous wave, 2 W) under topical anaesthesia. The laser was applied with light touch contact at the ulcerated area and with near contact at the peripheral reddened area (Fig. 2). Post-operatively, the surface of the area treated appeared dry and brownish without any carbonisation and with a reduction in the reddened mucosa of the peripheral area (Fig. 3).

The results at the one-week follow-up showed remarkable pain relief and a decrease in the size of the ulcer to 1 x 4 mm (Fig. 4). Laser welding was then repeated using the same technique mentioned above. One week after the second treatment, there was no ulceration only a few white striae on the buccal mucosa (Fig. 5). The patient occasionally felt a mild burning sensation in this area when eating spicy food. He was advised to avoid

hot and spicy foods. At the three-month follow-up after the second laser welding treatment, there was no evidence of ulceration or the previously inflamed buccal mucosa.

Discussion

The results of this novel technique suggest that it has the ability to achieve complete recovery of erosive OLP, in terms of both symptoms and mucosal healing, while the low intensity laser and CO₂ laser irradiation, at least the methods used in this case, were able to relieve the spontaneous pain only partially. The reason for this is that this technique has a bio-modulation effect as always observed when using 830 nm low intensity therapy,² together with minor changes in tissue structure in the welding mode, 70 to 80 °C, producing helical unfolding collagen in a favour of healing⁶ and wound closure.⁵

Conclusion

The novel technique used here (we have called it the "laser welding technique for oral mucosa"), using an 830 nm diode laser (continuous wave, 2 W), was able to gain complete recovery from ulceration clinically in a case of refractory erosive OLP. Therefore, the laser welding technique is worth further study with regard to exploring basic tissue reaction and clinical efficacy.

Editorial note: A list of references is available from the publisher.

contact

laser

Assoc Prof Dr Sajee Sattayut
(Chairman of Lasers in Dentistry Research Group)

Khon Kaen University
Khon Kaen City, 40002
Thailand

sajee@kku.ac.th
Tel.: +66 8 1544 2460
Fax: +66 4334 8153

Dental South China 2012

International Expo 华南国际口腔展



Visitor Pre-register now
www.dentalsouthchina.com




Top Dental Show | March 7-10, 2012
in China

17th Dental South China International Expo

www.dentalsouthchina.com

Venue: China Import and Export Fair Pazhou Complex, Guangzhou, China

Organizer: Guangdong Int'l Science & Technology Exhibition Company 

Exhibitor Service Tel: 0086-20-83549150

Email: dental@ste.cn

Visitor Service Tel: 0086-20-83561589

Email: dentalvisit@ste.cn

Fax: 0086-20-83549078

Laser ridge preservation

Author_Dr Darius Moghtader, Germany

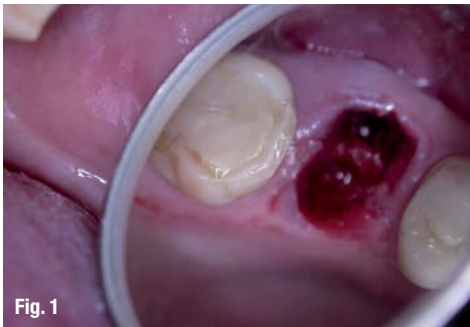

Fig. 1

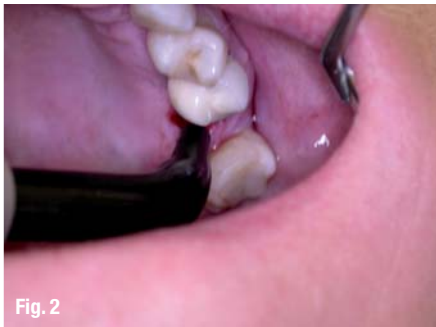

Fig. 2

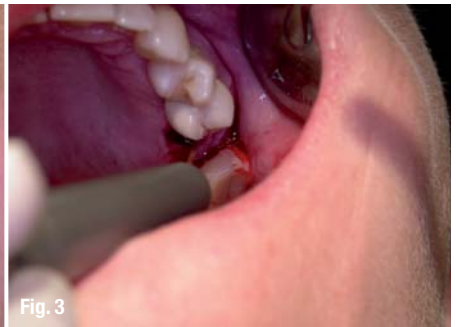

Fig. 3

Fig. 1 _Condition after extraction.

Fig. 2 _Launch of glass rod from laser.

Fig. 3 _Membranisation.

Abstract

The following article describes an alternative treatment option to reduce bone resorption post-tooth extraction with the help of laser technology and autologous materials, thereby creating the optimal conditions for implantation.

Many prosthodontic dentists are familiar with the problem of the crucial buccal lamella being partially or completely resorbed within six weeks post-tooth extraction. This resorption then leads to subsequent implantation problems. Treatment of insufficient bone is attempted via expensive and cumbersome bone augmentation procedures either during or before implantation. Numerous procedures have already been introduced to prevent this bone resorption: from direct implantation to filling the alveole with materials of different origins and frequently additional membranes to cover the introduced material.

This costly bone graft procedure, usually using foreign materials, can unfortunately lead to unforeseeable results, ranging from very good to very poor. Aside from the often-mentioned risks related to bone substitutes of human or animal origin, it is very disagreeable to find non-osseointegrated bone replacement material instead of the desired newly formed bone during implantation and being worse off than without the procedure. Amongst some surgical colleagues, the phrase "party crasher"¹ is used, i.e. the bone formation party fails to happen. Unfortunately, even immediate implantation, which would help in most cases, is often no solution, because infection, insufficient treatment time, unsuited implant systems, and especially the legally uninformed patient are obstacles to an immediate implantation. Even if immediate implantation is a success, the results are not reliably predictable, especially with regard to aesthetics. For these reasons, I searched for an alternative, affordable, fast and non-cumbersome procedure using autologous materials to reduce bone resorption

Fig. 4 _Elap-rp membrane.

Fig. 5 _Situation after three days.

Fig. 6 _Recall after four weeks.

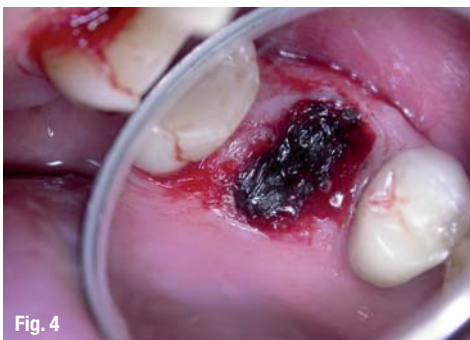

Fig. 4

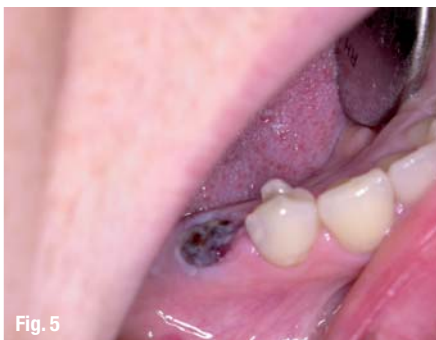

Fig. 5

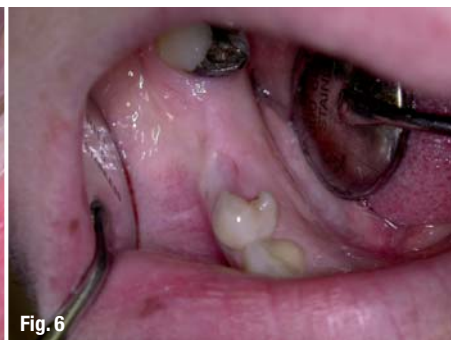
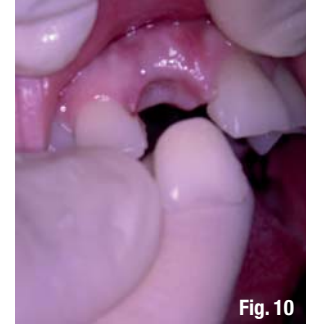
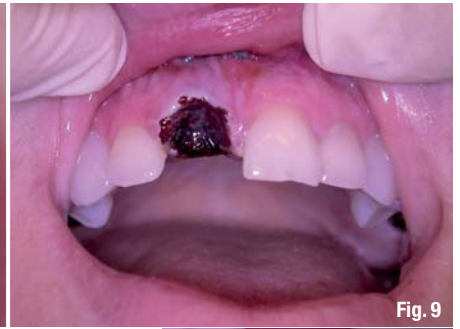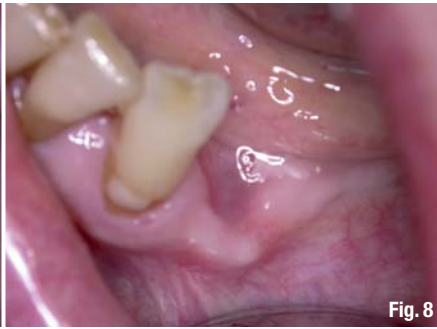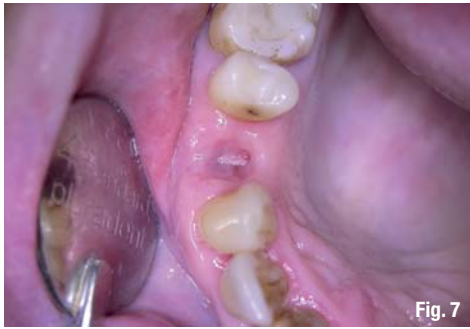Fig. 6



and create optimal conditions for subsequent implantation. This procedure, elap-rp (elexxion laser-assisted protocol-ridge preservation), will be presented in this article.

_Theoretical reflections

Romanos² demonstrated in his study with a high-performance Nd:YAG laser that a laser cut heals distinctly slower than a scalpel cut, but therefore scar free. After three weeks, at the earliest, the laser cut is completely healed. It is assumed that thermal damage to the external epithelial layer slows the healing process. This undesired result occurs with every thermal laser and therefore with an undesired, related tissue carbonation.

_Effectively slowing healing

The effect described is of use to the experienced laser operator during de-epithelialisation of movable mucoperiosteal membranes for controlled reproduction of attached gingiva. The de-epithelialisation area acts as the barrier that slows the healing process. In brief, the area treated with the high-performance laser acts as a natural, resorbable, highly effective membrane with all known and desired effects. The way in which the laser-created autologous membrane can be optimally used for ridge preservation will be illustrated later. The second important factor for optimal bone regeneration is blood, as already conclusively presented and practised by Schulte³ with autologous blood coagulum of cysts. If the vestibular lamella can be retained during tooth removal, when compared to a hexagonal cube, it is about a defect in five of the sides and a missing "lid". This can be compared to a cyst defect; the sole difference being that no primary wound closure can be achieved without otherwise unnecessary additional surgical intervention.

_Retaining vestibular lamella

Accompanying the elap-rp procedure, a whole bleeding of the alveole is absolutely necessary post-extraction (Fig. 1). The bleeding can be achieved conventionally via alveole planing or preferably via laser application. Generally, a claros soft laser (elexxion) in the healing programme with a pulse of 75 mW with

8,000Hz for 120 seconds or with 100 mW for 60 seconds, i.e. approx. 6 J per alveole, is sufficient in such cases. The T4 soft laser glass rod should be inserted to the base of the alveole and all exposed bone surfaces should be collected on a grid without contact (Fig. 2). Sometimes, a second or third procedure is necessary, and of course possible, to achieve sufficient bleeding.

The alveole filled with blood is then membranised (Fig. 3) grid-wise with the claros in the haemostasis programme with 30 W with 20,000 Hz and a pulse duration of 10 seconds with the non-initialised 600 fibre, beginning distally at an unfocused distance of 1 to 2 mm (Fig. 3). This procedure initially requires some practice, but is then simple, fast and reproducibly successful. Afterwards, the patient leaves the clinic with instructions not to brush or rinse too thoroughly (Fig. 4). The three-day (Fig. 5) and four-week (Fig. 6) follow-ups of a different case showed a successful, almost complete retention of the vestibular lamella. In the following illustrative examples (Figs. 7–10), further results are shown that were also achieved with this new, systematic elap-rp procedure. Please note the almost completely retained vestibular lamella that invites each implant surgeon to a simple and safe implantation at a prosthetically sensible location. With the elap-rp procedure, ideal conditions for implantation or an ovate pontic can be created quickly and affordably without additional material costs. Use it to offer you patients an optimal and affordable laser treatment.

Editorial note: A list of references is available from the publisher.

_contact	laser
<p>Dr Darius Moghtader</p> <p>In den Weingärten 47 55276 Oppenheim Germany</p> <p>dr-moghtader@hotmail.de www.oppenheim-zahnarzt.de www.laser-zahn-arzt.de</p>	

Fig. 7_ Four weeks after elap-rp.
Fig. 8_ Six weeks after elap-rp.
Fig. 9_ Directly after x and elap-rp.
Fig. 10_ Situation after twelve weeks.

Optical imaging in the oral cavity

Innovative and emergent imaging techniques

Author _Danielle Le, Anh Le, Jennifer Holtzman, Joel Epstein & Petra Wilder-Smith, USA

_As the emphasis shifts from damage mitigation to disease prevention or reversal of early disease in the oral cavity, the need for sensitive and accurate detection and diagnostic tools becomes more important. Many novel and emergent optical diagnostic modalities for the oral cavity are becoming available to clinicians with a variety of desirable attributes, including: (a) non-invasiveness; (b) absence of ionising radiation; (c) patient friendly; (d) real-time information; (e) repeatability; and (f) high-resolution surface and subsurface images. In this article, the principles behind optical diagnostic approaches, their feasibility and applicability to imaging soft and hard tissue, and their potential usefulness as a tool in the diagnosis of oral mucosal lesions, dental pathologies, and for other dental applications will be reviewed.

_Introduction

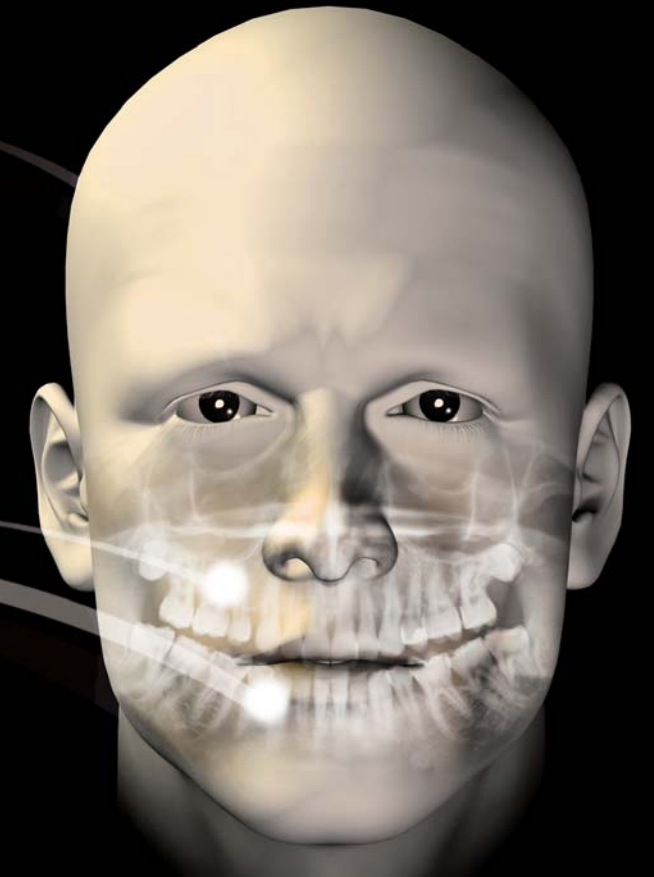Light-based imaging of tissue detects minimal changes, such as: (a) cell microanatomy (e.g. nuclear/cytoplasmic ratio); (b) redox status; (c) expression of specific biomarkers; (d) tissue architecture and composition; (e) chemical changes (e.g. mineralisation); and (f) vascularity/angiogenesis and perfusion. These properties are ideal for the detection of minimal (early) changes, for assessing the margins of lesions and potentially the presence of subclinical abnormalities beyond the clinical margins, for re-

peated non-invasive monitoring of existing lesions, and for rapidly examining at-risk populations.

_Oral cancer

A. Chemiluminescence: ViziLite

This imaging device has been used in the oral cavity since 2001. After rinsing with an acetic acid mixed solution, the oral cavity is examined under chemiluminescent illumination at 430, 540 and 580 nm wavelengths. This method allows increased visual distinctions between normal mucosa and oral white lesions (Huber *et al.* 2004; Kerr *et al.* 2006; Epstein *et al.* 2006; Epstein *et al.* 2008). The detected signals may be related to the altered thickness of the epithelium, or to the presence of a higher density of nuclear content and mitochondrial matrix that preferentially reflect light. Hyper-keratinised or dysplastic lesions appear distinctly white when viewed under a diffuse low-energy wavelength light. In contrast, normal epithelium will absorb light and appear dark (Lingen *et al.* 2008). Since the majority of studies investigating chemiluminescence reported subjective perceptions of intra-oral lesions in terms of brightness, sharpness and texture versus routine clinical examination, data interpretation may vary significantly between examiners (Huber *et al.* 2004; Kerr *et al.* 2006). In January 2005, a combination of both toluidine blue and ViziLite systems (ViziLite Plus with



TBlue system) received FDA clearance as an adjunct to visual examination of the oral cavity in populations at increased risk for oral cancer. In a multicenter study of high-risk patients, it was reported that the majority of lesions with a histological diagnosis of dysplasia or carcinoma in situ were detected and mapped using ViziLite and toluidine blue (Epstein *et al.* 2008). Recently, a new chemiluminescence device (Microlux/DL, AdDent) has been introduced as an adjunct tool for oral lesion identification (McIntosh & Farah 2009).

B. Spectroscopy and autofluorescence

Tissue autofluorescence has been applied in the screening and diagnosis of pre-cancer and early cancer of the lung, uterine cervix, skin and, more recently, of the oral cavity. During the disease process, the altered cellular structure (e.g. hyperkeratosis, hyperchromatin and increased cellular/nuclear pleomorphism) and/or metabolism (e.g. concentration of flavin adenine dinucleotide and nicotinamide adenine dinucleotide) affect tissue interaction with light. Spectroscopy or autofluorescence imaging can provide information about these altered light interaction properties.

In the last decade, several forms of autofluorescence technology have been developed for inspection of the oral mucosa. LED Medical Diagnostics Inc

in partnership with the British Columbia Cancer Agency has marketed the VELscope system (Lingen *et al.* 2008; Patton *et al.* 2008; De Veld *et al.* 2005). When viewed through the instrument eyepiece, normal oral mucosa emits a pale green autofluorescence upon stimulation with intense blue excitation at 400 to 460 nm wavelength, whilst dysplastic lesions exhibit decreased autofluorescence and appear darker with respect to the surrounding healthy tissue. Several studies have investigated the effectiveness of the VELscope system as an adjunct to visual examination, and determined an improvement in the ability to distinguish between oral lesions and healthy mucosa, and between different lesion types (De Veld *et al.* 2005). Overall, the technique appears to show high sensitivity, but low specificity (De Veld *et al.* 2005). Using histology as the comparative gold standard, VELscope demonstrated high sensitivity and specificity in identifying areas of dysplasia and malignancy that extended beyond the clinically evident tumours (Lingen *et al.* 2008; Patton *et al.* 2008; De Veld *et al.* 2005; Onizawa *et al.* 1996; Schantz *et al.* 1998). A direct clinical application entails assessing pathology margins in patients with potentially malignant oral lesions, thereby assisting in guiding surgical management (Poh *et al.* 2007; Rosin *et al.* 2007). However, reported evaluations of the VELscope system are from case series and case reports rather than clinical trials, and no published studies have assessed the VELscope system as a diagnostic adjunct in screening patient populations (including patients with or without a history of dysplasia/oral squamous cell carcinoma).

In another study using quantitative fluorescence imaging in 56 patients with oral lesions and 11 normal volunteers, healthy tissue could be discriminated from dysplasia and invasive cancer with a sensitivity of 95.9% and specificity of 96.2% in the training set, and with a sensitivity of 100% and specificity of 91.4% in the validation set. Lesion probability maps qualitatively agreed with both clinical assessment and histology (Roblyer *et al.* 2009). Further clinical studies are needed in diverse populations to evaluate fully the clinical usefulness of this promising technology. Other devices using a range of spectroscopic techniques are under development, often combined with other technologies. These include the FastEEM4 System, the Identafi (Remicalm) and the PS2-oral (Schwarz *et al.* 2009; McGee *et al.* 2008; Lane *et al.* 2006; De Veld *et al.* 2005; Wagnieres *et al.* 1998; Ramanujam *et al.* 2000; Culha *et al.* 2003; Choo-Smith *et al.* 2002; Bigio *et al.* 1997; Farrell *et al.* 1992). Clinical studies are still at a relatively early stage, but preliminary results are encouraging. The Identafi technology combines anatomical imaging with fluorescence, fibre optics and confocal microscopy to map and delineate precisely the lesion in

the area being screened. In a screening of 124 subjects, a sensitivity of 82% and specificity of 87% were determined for differentiating between neoplastic and non-neoplastic sites in the oral cavity. Results appeared to vary between sampling depths, and keratinised versus non-keratinised tissue (Schwarz *et al.* 2009). Major challenges to diagnostic spectroscopy include the often low signal-to-noise ratio, difficulty in identifying the precise source of signals, data quantification, and difficulty in establishing definitive diagnostic milestones and endpoints, especially given the wide range of tissue types within the oral cavity. The depth of tissue penetration is an inherent limitation of the technology. Additional concerns relate to the potential mutagenicity induced by UV light in the clinical setting.

C. Photosensitisers

When topical or systemic photosensitisers are administered, their ability to accumulate in cancer cells and to fluoresce under specific wavelengths can be used to identify and delineate areas of microscopic changes (Kennedy *et al.* 1992; Cassas *et al.* 2002). This approach permits 3-D mapping of the epithelial surface and subepithelial boundary, screening of large surface areas and offers the option of subsequent photodestruction of the photosensitised lesion. Some promising agents for photodetection include aminolevulinic acid (Levulan), hexyl aminolevulinate (Hexvix), methyl aminolevulinate (Metvix), tetra(meta-hydroxyphenyl)chlorin, as well as porfimer sodium (Photofrin; Ebihara *et al.* 2003; Leunig *et al.* 1996, 2000, 2001; Chang & Wilder-Smith, 2005). In a blinded clinical study of 20 patients with oral neoplasms, diagnostic sensitivity using unaided visual fluorescence diagnosis or fluorescence microscopy approximated 93%. Diagnostic specificity was 95% for visual diagnosis, improving to 97% using fluorescence microscopy (Chang & Wilder-Smith, 2005). A recent study using epidermal growth factor-targeted fluorescent agents by topical application to oral mucosal lesions, combined with *in vivo* imaging, demonstrated encouraging results with regard to lesion detection, margin delineation and as an adjunct guiding tool for biopsy (Nitin *et al.* 2009). Depending on the photosensitiser and its mode of application (systemic versus topical), limitations include systemic photosensitisation over prolonged periods, penetration-related issues, the need for specialised fluorescence detection and mapping equipment, and lack of specificity when inflammation or scar tissue is present.

D. Optical coherence tomography

Optical coherence tomography (OCT) was first introduced as an imaging technique in biological systems in 1991 (Huang *et al.* 1991). The non-invasive nature of this imaging modality, coupled with a pen-

etration depth of 2 to 3 mm, high resolution (5–15 μm), real-time image viewing and capability for cross-sectional, as well as 3-D tomographic images, provides excellent prerequisites for *in vivo* oral screening and diagnosis. OCT has frequently been compared to ultrasound imaging. Both technologies employ back-scattered signals reflected from different layers within the tissue to reconstruct structural images, with the latter measuring sound rather than light. The resulting OCT image is a 2-D representation of the optical reflection within a tissue sample. Cross-sectional images of tissue are constructed in real time, at near histological resolution (approximately 5–15 μm with current technology). These images can be stacked to generate a 3-D reconstruction of the target tissue. This permits *in vivo* non-invasive imaging of epithelial and subepithelial structures, including depth and thickness, histopathological appearance and peripheral margins of the lesions.

Several OCT systems have received US FDA approval for clinical use, and OCT is deemed by many as an essential imaging modality in ophthalmology. *In vivo* image acquisition is facilitated through the use of a flexible fibre-optic OCT probe. The probe is simply placed on the surface of the tissue to generate real-time, immediate surface and subsurface images of tissue microanatomy and cellular structure, whilst avoiding the discomfort, delay and expense of biopsies. Several studies have sought to investigate the diagnostic utility of *in vivo* OCT to detect and diagnose oral pre-malignancy and malignancy (Tsai *et al.* 2008; Wilder-Smith *et al.* 2009). In a blinded study involving 50 patients with suspicious lesions, including oral leukoplakia and erythroplakia, the effectiveness of OCT for detecting oral dysplasia and malignancy was evaluated (Wilder-Smith *et al.* 2009). OCT images of dysplastic lesions revealed visible epithelial thickening, loss of epithelial stratification, and epithelial downgrowth. Areas of oral squamous cell carcinoma of the buccal mucosa were identified in the OCT images by the absence or disruption of the basement membrane, an epithelial layer that was highly variable in thickness, with areas of erosion and extensive epithelial downgrowth and invasion into the subepithelial layers. Statistical analysis of the data gathered in this study substantiated the ability of *in vivo* OCT to detect and diagnose pre-malignancy and malignancy in the oral cavity with excellent diagnostic accuracy. For detecting carcinoma *in situ* or squamous cell carcinoma (SCC) versus non-cancer, sensitivity was 0.931 and specificity was 0.931; for detecting SCC versus all other pathologies, sensitivity was 0.931 and specificity was 0.973.

In another study of 97 patients using OCT imaging to detect neoplasia in the oral cavity (Tsai *et al.* 2009), the results revealed that the main diagnostic criterion

for high-grade dysplasia/carcinoma in situ was the lack of a layered structural pattern. Diagnosis based on this criterion for dysplastic/malignant versus benign/reactive conditions achieved a sensitivity of 83% and specificity of 98% with an inter-observer agreement value of 0.76. This study concluded that OCT, with high sensitivity and specificity combined with good inter-observer agreement, is a promising imaging modality for non-invasive evaluation of tissue sites suspicious for high-grade dysplasia or cancer. Other studies have utilised direct analysis of OCT scan profiles, rather than image-based criteria, as a means of delineating the site and margins of oral cancer lesions (Tsai *et al.* 2008). Using numerical parameters from A-scan profiles as diagnostic criteria, the decay constant in the exponential fitting of the OCT signal intensity along the tissue depth decreased as the A-scan point moved laterally across the margin of a lesion. Additionally, the standard deviation of the OCT signal intensity fluctuation increased significantly across the transition region between the normal and abnormal portions. The authors concluded that such parameters may well be useful for establishing an algorithm for detecting and mapping the margins of oral cancer lesions. Such a capability has huge clinical significance because of the need to better define excisional margins during surgical removal of oral pre-malignant and malignant lesions.

Dental pathologies and other applications

Light scattering, reflection, absorption and laser-induced fluorescence can provide much information regarding hard-tissue structure and pathology. The techniques described below—OCT, polarisation-sensitive OCT (PS-OCT), laser fluorescence (DIAGNOdent, KaVo), quantitative laser fluorescence (QLF), fibre-optic transillumination—exploit this concept, achieving varying degrees of specificity and sensitivity for detecting demineralisation and decay of the dental matrices, the anatomical structure of the tooth organ, as well as the attached microbial biofilms and calculus.

Dental caries

A. Optical coherence tomography

As described above, OCT measures the intensity of back-scattered light to create images. Light does not travel at a constant velocity when it passes through different structures, travelling faster in material with a low refractive index and slower in media with a high refractive index. Additionally, when the light hits a sharp change in refraction, the wave is reflected either externally or internally. The amount of reflection depends on the amount of change in refraction, the angle the light is travelling at and the polarisation of the light. If the change of refraction between the me-

dia is gradual, the reflection will be minimal (Brezinski *et al.* 2006; Colston *et al.* 1998; Feldchtein *et al.* 1998; Otis *et al.* 2000). The changes between the hard tissues such as enamel and dentine and between healthy and demineralised or carious states can then be interpreted to create 2-D and 3-D images of the hard tissues. As such, various optical properties are under investigation as potential quantifiers of the mineralisation changes to detect dental caries (Li *et al.* 2009). In the relatively early days of OCT, two groups of researchers investigated the feasibility of using OCT *in vivo* to image sound and demineralised tissue, and even monitored restorative procedures (Colston *et al.* 1998). A recent publication described the use of *in vivo* OCT to determine the effectiveness of a proton pump inhibitor in treating gastro-oesophageal reflux by monitoring dental erosion with OCT (Wilder-Smith *et al.* 2009). The study was significant in that the researchers were able to identify an association between the medication and a reduction in enamel erosion.

B. Polarisation-sensitive OCT

Since both enamel and dentine have strong polarising effects, changes in polarisation provide more structural information than conventional OCT (Brezinski, 2006). Light is delivered in one polarisation, and the reflection is read in both polarisations. Although we were unable to find clinical studies that used PS-OCT, extensive research has been conducted by Fried and others that demonstrates that this technology has the potential to monitor demineralisation/remineralisation and quantify demineralised tooth structure, even below dental sealant (Manesh *et al.* 2009; Chen *et al.* 2005; Jones *et al.* 2006; Jones & Fried 2006; Ngaotheppitak *et al.* 2005; Chong *et al.* 2007; Jones *et al.* 2004). Unfortunately, PS-OCT technology has not been as effective in identifying root caries (Lee *et al.* 2009).

C. Laser fluorescence

Back-scattered light from laser-induced fluores-

Fig. 1 Indispensable part of a successful therapy: optical diagnostic.

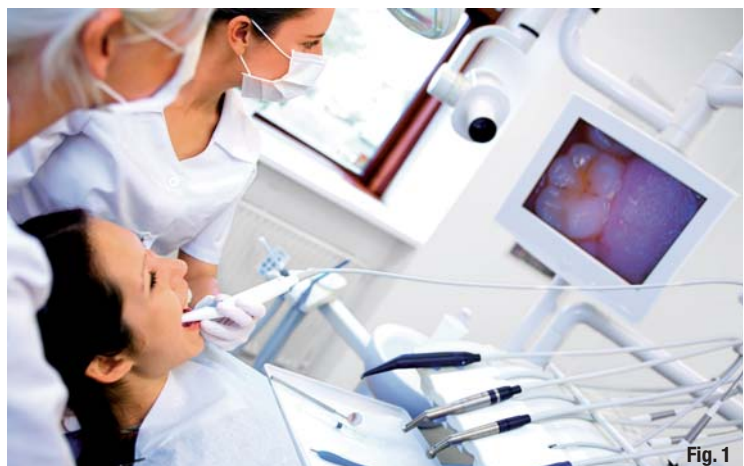

Fig. 1

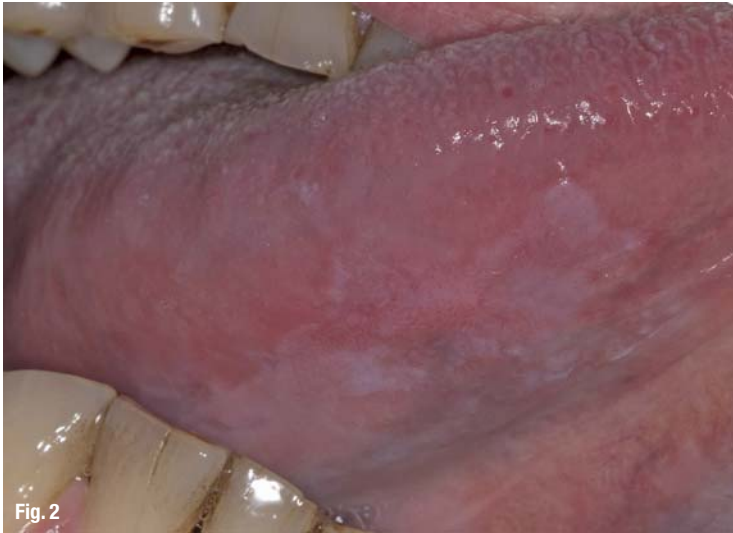

Fig. 2

Fig. 2 Severe dysplasia under white light. (With kind permission of 14th Floor Solutions; VELscope®)

cence has been reported as a tool to detect and quantify caries activity (Zandona & Zero 2006). A red laser light (655 nm wavelength) is absorbed by organic and inorganic matter in the tooth and then re-emitted from the organic material as near-infrared fluorescent light. The device provides a numerical printout and an audible signal when decay is detected. The results of studies investigating diagnostic usefulness of DIAGNOdent vary considerably (Chong *et al.* 2003; Kuhnisch *et al.* 2008). The lack of diagnostic consistency may reflect: (a) the need for clinicians to learn how to use the correct position for the unit; (b) staining and/or calculus affecting the readings; and (c) difficulty in determining the numerical value at which surgical intervention is indicated (Shi *et al.* 2000). However, the literature appears to be consistent in describing DIAGNOdent as a better tool for detecting dentinal caries than enamel caries. Additional benefits of the DIAGNOdent may be its ability to identify completed removal of infected tooth structure during excavation (Lussi *et al.* 2004). While DIAGNOdent's high rate of false-positive results may be a limitation in some clinical practices, in a high-risk population with limited access to dental care, this tool may be quite predictive in caries screening.

D. Quantitative light fluorescence

QLF uses fluorescence induced by multi-wavelength excitation at 290 to 450 nm to measure mineral loss in enamel and dentine (Hall & Girkin 2004). Unlike the DIAGNOdent system, this device provides colour-coded images of the target tissue. Sound tooth structure fluoresces and carious tooth structure appears dark. As the caries scatters the light, mapping the carious lesion can be difficult. Interestingly, the predictive nature of this technology depends on the population (Hall *et al.* 2004). In a high-risk population, QLF is highly predictive (.90–.98) of future caries (Zandon & Zero 2006). In a low-risk population, it is much less predictive, and stains, plaque,

and fluorosis can affect QLF accuracy (Zandona & Zero 2006). High-intensity UV light can generate free radicals, potentially resulting in toxicity to live tissue.

E. Fibre-optic transillumination

This approach uses changes in the scattering and absorption of photons by structural characteristics to detect caries in real time. Advantages of this technology include safety, as UV light is not used. In digital-imaging fibre-optic transillumination (DIFOTI), the light that passes through the tooth is interpreted by a digital device on the other side of the tooth. DIFOTI seems to perform well for early surface lesions; however, it seems to have low specificity, which can result in overtreatment and is also unable to determine lesion depth, which limits potential sites of use (Young *et al.* 2005; Bin-Shuwaish *et al.* 2008; Schneiderman *et al.* 1997). Recently, Wu and Fried used near infra-red (NIR) transillumination to image dental caries (Wu & Fried 2009). This technology takes advantage of the transparency of sound enamel at 1310 nm, which decreases considerably in unhealthy tooth structure. Demineralised areas on the enamel surface appear lighter, while deeper lesions appear darker. However, low contrast as compared to the high reflectance signal and decreasing effectiveness with increasing tooth thickness are important clinical challenges. Although we were unable to identify clinical studies using NIR transillumination, the concept holds great promise, for example, allowing clinicians to monitor remineralisation of enamel.

_ Other dental applications

Periodontics

A. Fluorescence using the periodontal probe for DIAGNOdent

Because calculus fluoresces differently than healthy tissue, the use of laser fluorescence has been proposed as an aid to detect residual calculus following root planing and scaling. The DIAGNOdent periodontal probe may aid in clinical detection of sub-gingival calculus deposits far better than conventional methods (Kasaj *et al.* 2008; Krause *et al.* 2003; Krause *et al.* 2005). Audible sounds and measurable values as signals for presence of calculus during screening may increase patients' awareness of their calculus levels, leading to increased patient compliance with the recommended treatment.

B. Optical coherence tomography

Several *in vitro* studies have demonstrated the potential use of OCT as an adjunct tool for diagnosis of periodontal disease. Studies in a porcine model showed high-resolution images of periodontal tissue, the enamel–cementum and the gingiva–tooth interfaces (Colston *et al.* 1998). While results of early *in vivo* studies were promising, consistent imaging of

the periodontal tissue remains challenging owing to the limited penetration depth and scan sizes of OCT (Colston *et al.* 1998). In another study by Baek *et al.* the successful use of OCT for monitoring periodontal ligament changes during orthodontic tooth movements in rats was reported (Baek *et al.* 2009).

Endodontics

A. Fluorescence using the DIAGNOdent perio probe

Real-time assessment of the microbial status of the root canal system would be useful in clinical endodontic practice for determining endpoints of biomechanical treatment. In an *ex vivo* study using extracted teeth, the DIAGNOdent, in combination with a prototype sapphire tip designed for periodontal assessment, was used to evaluate the pulp chamber and coronal third of the root canal system. The fluorescence properties of bacterial colonies, biofilms in root canals, pulpal soft tissue and sound dentine were evaluated in 50 extracted teeth with known endodontic pathology. Sound dentine and healthy pulpal soft tissue gave an average fluorescence reading of 5 (on a scale of 100), whereas biofilms of *Enterococcus faecalis* and *Streptococcus mutans* colonising the root canals showed a progressive increase in fluorescence signals over time. Fluorescence readings reduced to the "healthy" threshold range when root canals were endodontically treated, and the experimentally created bacterial biofilms were removed completely. High fluorescence readings were recorded in the root canals and pulp chambers of extracted teeth with radiographic evidence of peri-apical pathology and scanning electron microscopy evidence of bacterial infection (Sainsbury *et al.* 2009).

B. Optical coherence tomography

In a study on extracted teeth, the diagnostic accuracy of high-resolution OCT using a 0.5 mm diameter intra-canal probe for mapping oval canals, uncleaned fins, risk zones and root perforations approached that provided by histology (Shemesh *et al.* 2007). The probe easily fitted into a prepared root canal and its flexibility allowed penetration and advancement through curvatures. The optical probe rotated within a probe sheath so that adjacent lines in each rotation could be stacked to generate a frame showing a cross-section of the tissue architecture in the wall. The scan was quick, about 15 seconds for a 15 mm-long root. The authors concluded that fibre-optic OCT probing holds promise for full *in vivo* endodontic imaging.

Another *ex vivo* study assessed apical micro-leakage following endodontic treatment using OCT (Todea *et al.* 2009). OCT imaging was found to be effective in identifying the apical seal. However, in the real clinical situation, OCT use for peri-apical diagnostics is limited by its short penetration depth into the bone in which the tooth is embedded.

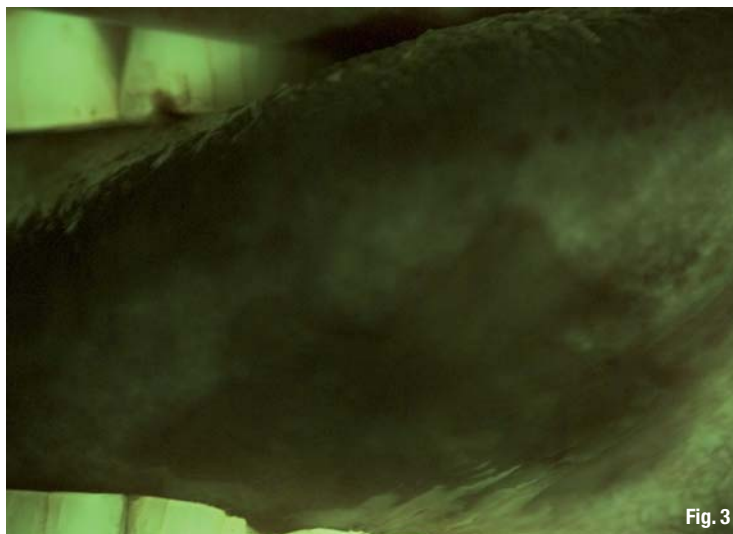

Fig. 3

Conclusion

Emergent optical technologies show promise for a wide range of oral diagnostic applications with capabilities for high-resolution, cross-sectional tomographic imaging of microstructure in several biological systems. OCT can achieve image resolution one to two orders of magnitude finer than standard ultrasound. As such, OCT functions more effectively as a unique "optical biopsy" to delineate the cross-sectional images of tissue structure at the micro-scale. This promising biomedical optical imaging technology provides images of tissue *in situ* and in real time, without the need for surgical biopsy and multiple-specimen processing. OCT imaging allows detection and diagnosis of early stages of disease in teeth, periodontal tissue and mucosa, and facilitates large-scale screening for high-risk populations. Because of the rapid pace of innovation in this field, the cost and ease of use of such modalities are improving rapidly, such that many such devices are becoming available to dental clinicians. We envisage many benefits to patients and clinicians from the use of these devices.

Fig. 3 The lesion viewed using VELscope's fluorescence visualization. (With kind permission of 14th Floor Solutions; VELscope®)

_contact

laser

Dr Petra Wilder-Smith

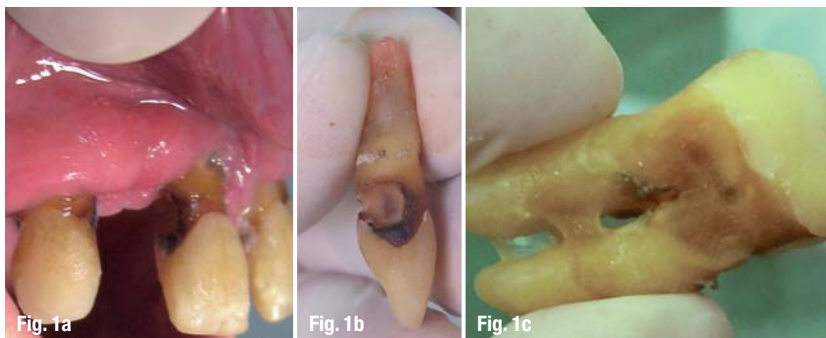
Beckman Laser Institute
University of California, Irvine
1002 Health Sciences Rd.
Irvine, CA 92612, USA

Tel.: +1 949 824 7632
Fax: +1 949 824 8413

pwsmith@uci.edu

Morphological changes in hard dental tissue prepared using the Er:YAG laser

Author_Drs Snejana Ts. Tsanova & Georgi T. Tomov, Bulgaria



Figs. 1a–c _Extracted teeth with carious lesions.

_In recent years, prevention and early caries detection, as well as shifts in the understanding of the chemical and biological basis of the demineralisation process in hard dental tissue and the possibility of carious lesions undergoing remineralisation, have superseded the classical operative approach to caries treatment postulated by Black and promoted minimally invasive preparation (MIP). The main categories of MIP techniques include rotary handpieces and burs, chemomechanical cleaning with Carisolv gel, air abrasion and dental lasers.^{1,2} The trend for alternatives to the conventional method of preparation led to a focus on the impact of alternative techniques on hard dental tissue and underlying dental pulp. MIP techniques claim to be able to achieve controlled removal of infected and softened dentine while preserving the healthy, hard dental tissue and do so with minimal discomfort to the patient. However, current data provides contradictory evidence of the impact of MIP techniques on hard dental tissue compared with conventional preparation. Possible reasons for this are the variety of experimental studies and difficulties in standardising the results of clinical

research. It is worth noting that the studies that have given the most positive evaluation of the alternative methods of preparation (Carisolv, laser) use mainly clinical criteria for evaluation (patient's perception and tolerance, noise, atraumatic work, colour and texture of the dentine when probing, etc.), which are all rather subjective. While new, improved versions of alternative systems for preparation on the market claim to be highly clinically efficient, there is still little information about them (the modified Carisolv colourless gel, multi-frequency, high-energy lasers, air-abrasion). This makes it necessary for research in this rapidly developing, promising field of dentistry to be updated periodically. The objective of the present *in vitro* study was to evaluate by SEM the ultrastructural changes in hard dental tissue treated with several alternative systems for caries removal and preparation.

_Materials and methods

The study used 20 human teeth, freshly extracted because of advanced periodontal disease. The preparations involved natural carious lesions on tooth surface (Figs. 1a–c). The teeth were divided into four groups of five teeth ($n = 5$) according to the preparation technique:

- Group 1:** Mechanical rotary preparation with steel burs/micromotor;
- Group 2:** Mechanical rotary preparation with diamond burs/air turbine;
- Group 3:** Chemomechanical preparation with Carisolv colourless gel (MediTeam AB; Figs. 2a–c);
- Group 4:** Laser preparation by Er:YAG laser (Lite-

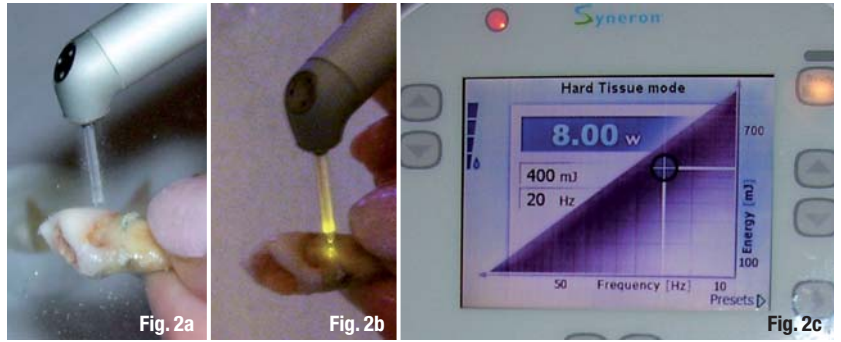
Touch, Syneron; Figs. 3a–c). Preparation was done strictly according to the manufacturers' instructions. The removal of caries was confirmed clinically through observation and probing. After preparation, the teeth were immersed in a 4% buffered glutaraldehyde fixative solution (0.075 M, pH 7.3) for one hour. They were then rinsed in distilled water and placed in a cold sodium cacodylate buffer (0.02 M, pH 7.2, 660 mosm) for 90 minutes for fixation of the organic matter. Subsequent dehydration was carried out through an ascending series of ethanol concentrations (30, 50, 70, 80, 95 and 100%) for one hour per series. The teeth were critical point dried in a desiccator. The dried specimens were then mounted on a metal stand and gold-coated (200–250 nm) by cathode atomisation under vacuum.

Scanning microscopy was performed using an electron microscope (515SEM model, Philips), with accelerating voltage of 25 kV in secondary emission mode. For each specimen, we took five photographs of randomly chosen areas with the same magnification (x 2,000) and various photographs at a different magnification. Using the SEM photomicrographs, we evaluated, described and compared the morphological findings and differences in the enamel and dentine tissues after treating the teeth using alternative methods for caries removal and cavity preparation.

Results

When analysing the SEM photomicrographs of the specimens examined, we found that the conventional method of cavity preparation with steel burs and micromotors at low speed without water-cooling (group 1) resulted in a contaminated surface with a thick smear layer of dentine debris without visible dentinal tubule orifices on all treated surfaces (Figs. 4a & b). The walls of the cavities were smooth and rounded and the border between enamel and dentine hardly noticeable.

Preparation with diamond burs, an air turbine and water-cooling (group 2) yielded a thin,



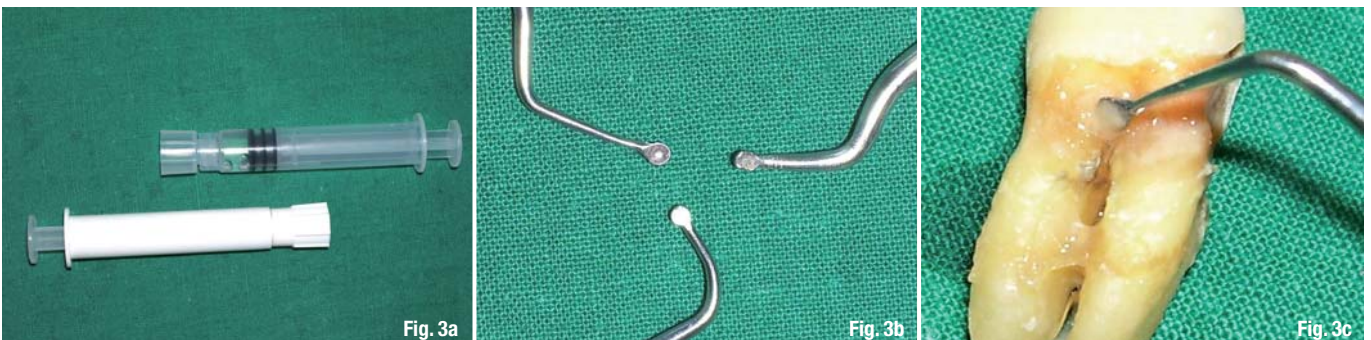Figs. 2a–c Laser preparation with the LiteTouch Er:YAG laser in hard tissue mode (400 mJ/20 Hz, 8 W).


smooth, and in some places absent, smear layer (Fig. 5a). In the area of water turbulence, there were patent dentinal tubule orifices, but without a clear outline of tubule lumens or peri- and intertubular dentine (Fig. 5b). The boundary between enamel and dentine was unclear, and the cavity had smooth contours.

The dental surface topography after chemomechanical preparation with Carisolv gel (group 3) was clearly rougher compared with that of groups 1 and 2. The dentinal tubule orifices were visible and there was almost no smear layer (Fig. 6a). Preparation of the organic matrix using chemomechanical preparation with Carisolv while preserving mineralised dental tissue resulted in a rough appearance of the treated surfaces and considerable micro-retention (Figs. 6b & c). Denatured collagen fibres and surface contamination occurred in some places, blocking the dentinal tubule orifices (Fig. 6d). The cavity form in group 3 followed the initial carious lesions' forms without going beyond their boundaries.

Cavity forms prepared with the Er:YAG laser (group 4) were characterised by a lack of definite geometric configuration and outlined cavity elements (Fig. 7a). There was a rough and irregular surface with no smear layer (Fig. 7b). Dentinal tubules were clearly exposed. Intertubular dentine was more ablated than peri-tubular dentine and this made the appearance of dentinal tubules more prominent (Fig. 7c). In the enamel, the typical architectonics of enamel prisms grouped in bundles

Figs. 3a–c Chemomechanical preparation with Carisolv colourless gel and hand excavators.





Figs. 4a & b SEM photomicrographs of tooth surfaces prepared with steel burs (x 500; 2,000 magnification). The surface is covered with a layer of debris and dentinal tubule orifices are not visible.

Figs. 5a & b A smooth, thin smear layer covers tooth surfaces prepared with diamond burs and an air turbine. In the area of water turbulence, partially removed contaminants and single dentinal tubule lumens were observed (x 500; 2,000 magnification).

was observed. Laser ablation of part of the enamel rendered the surfaces highly retentive (Figs. 7d & e).

Discussion

The MIP approach is based on several principles: remove only irreversibly damaged dental tissue and avoid macro-retention preparation in healthy tissue.¹ Additionally, MIP techniques should protect the underlying pulp and leave the treated surface suitable for adhesive bonding.¹ The antibacterial effects of the alternative preparation techniques must not be lower than those of standard necrotomy with rotary instruments and should excel them rather.¹

Nowadays the laser devices available for clinical use are capable of effective, controlled ablation of hard dental tissue.² Some clinical trials have suggested that Carisolv gel is highly efficient in caries removal, leaving clean and retentive dentinal surfaces.² However, not all researchers agree with these conclusions. Therefore, such studies should be periodically updated owing to the constant introduction of new technologies.

The experimental results of the present study revealed significant differences in the surface morphology of the samples studied, which would affect the ability to perform effective adhesive bonding. These morphological differences are highly dependent on the mechanism of action of the specific preparation systems.

Laser devices use a variety of physical media as sources for generating different wavelengths that are absorbed and interact with specific molecules in human tissues. The explanation for the hard tissue ablation is that the water content evaporates when exposed to laser irradiation, creating high in-

ternal pressure and subsequent micro-explosions. Inadequate water-cooling in this interaction of laser irradiation with tissue will lead to undesirable thermal effects.³ Depending on parameters such as pulse energy and frequency, CO₂ lasers, Nd:YAG and Er:YAG lasers cause changes in enamel and dentine in the form of roughing, craters, cracking, slicing, carbonification, melting and recrystallisation as described in many previous studies.⁴⁻⁶ These changes depend on the laser type, mode of operation, system for water-cooling and proper operation.³ Additionally, the ability to ablate carious dentine and enamel varies greatly according to different experimental studies.⁴⁻⁶ There is insufficient data that demonstrates the ability of the argon-fluoride and excimer lasers to remove dental caries.⁵ The krypton fluoride excimer laser, which emits in the ultraviolet range, has been shown to remove dentine, but enamel resists ablation.⁵

The high-power and high-frequency Er:YAG laser (LiteTouch) used in the present study has an advanced hydrokinetic system that is claimed to be capable of effective and safe ablation of hard dental tissue. The LiteTouch laser uses unique software that allows for the broadest range of energy and frequency settings. Its unique handpiece prevents loss of energy and, along with precision control over pulse duration, pulse energy and the optimal repetition rate, allows for a wide range of hard tissue procedures. LiteTouch is the first laser in to undesirable thermal effects.³ LiteTouch is the first laser in yet fully explored as a possible opportunity to eliminate acid etching of hard dental tissue and its related adverse effects on the underlying dentine and pulp.

Carisolv is a chemomechanical, minimally invasive method for selective softening of caries in

THE BUSINESS OF DENTISTRY



**INTERNATIONAL DENTAL
EXHIBITION AND MEETING
APRIL 20 - 22, 2012**

Limited space available. Secure your booth now!

We Bring the Asia Pacific Markets to You. IDEM Singapore connects you with over 6,000 dental traders, distributors and practitioners from the Asia Pacific region. Enriched with opportunities from the trading and showcasing of high-quality dental equipment to learning and development in the field of dental practice, this event is a "must-attend" for every dental and associated professional.

Endorsed By



Supported By



Held In



In Co-operation With



Co-organiser




North America

Franz Balve
Koelnmesse Inc
Tel: +1 732 933 1117
Fax: +1 732 741 6437
f.balve@koelnmessenafra.com

International

Stephanie Sim
Koelnmesse Pte Ltd
Tel: +65 6500 6723
Fax: +65 6296 2771
s.sim@koelnmesse.com.sg



Figs. 6a & b Dentine surfaces treated with Carisolv gel are clean and highly retentive, with many exposed, open dentinal tubules (x 500; 2,000 magnification).

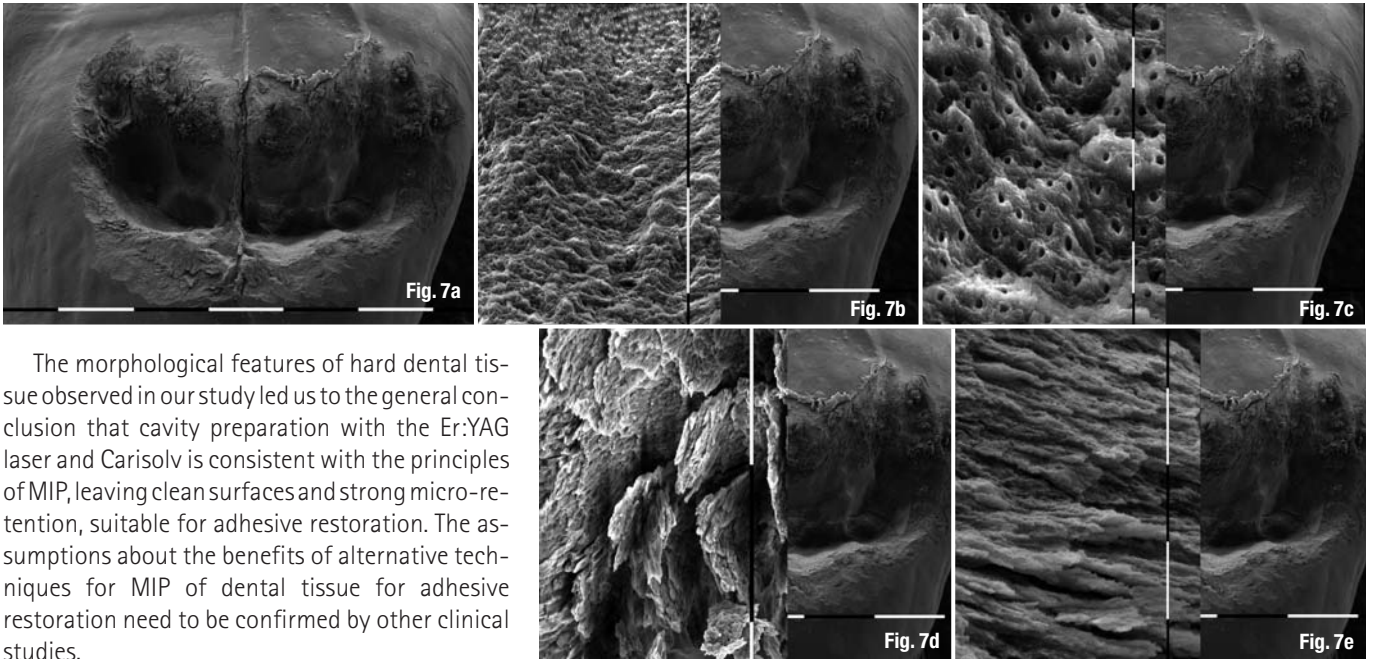
Figs. 6c & d Dentine surfaces treated with Carisolv gel are rough, granular and highly retentive. In some areas, single collagen fibrils are evident (x 3,000 magnification).

dentine and its subsequent removal with hand excavators.¹⁶ The system consists of gel containing three amino acids (glutamine, lysine and leucine) and a transparent liquid (0.5% NaOCl), which are mixed immediately before application. The chlorinated amino acids obtained selectively tear the damaged collagen fibres in carious dentine without damaging the underlying demineralised but not denaturated collagen. The macerated, infected dentine is removed manually using excavators. Carisolv gel is colourless and its amino acid concentration is twice as small, while the sodium hypochlorite concentration is increased twofold. The mechanism of action of Carisolv gel is based primarily on the proteolytic effect of NaOCl, which dissolves the denaturated collagen in the carious lesion.¹⁶ It is thought that the three amino acids enhance the effect of NaOCl on the collagen and reduce the involvement of healthy dental tissue. Carisolv chemical effects on the underlying pulp have been assessed as safe, and the alkaline pH (~11) of the gel neutralises acids and has a bactericidal effect on cariogenic flora.^{1,16} The presence of NaOCl in Carisolv is problematic, however, because of the danger of NaOCl inhibiting the bonding agent's polymerisation. Another clinical problem is the inability of Carisolv to affect the enamel and that requires combination with rotary instruments to excavate caries.¹⁶ Additionally, the results reported by studies on Carisolv's capacity to remove the smear layer are conflicting. According to some studies, Carisolv almost completely removes the smear layer, leaving visible and patent dentinal tubules.^{15,17} According to another study, however, Carisolv is unable to eliminate the smear layer and no patent dentinal tubules result.¹⁸ The latter study was conducted on a non-carious dentine surface and the researchers observed an irregular smear layer over enamel and dentine, and all dentinal

tubule orifices filled with debris. A third group of researchers found results that lay in between the findings of the other two: Carisolv does not eliminate the smear layer entirely. They observed partially patent dentinal tubules and residue of a contaminant smear layer covering the dentinal surface.²

The dentine surfaces treated with Carisolv and observed by SEM in the present study were clean, free of a smear layer, with some remnants of denaturated collagen fibres. Conventional rotating burs formed a smear layer on the dental surface, while Carisolv increased the surface roughness, leaving a relatively clean area. The dentine topography following Carisolv application was granular and rough compared with preparation with rotating instruments and exhibited roughness similar to that observed after laser preparation. The marked structural changes in the dental tissue and the surface roughness observed in our study may play a crucial role in composite material adhesion, possibly without requiring the use of etching agents. However, data in the literature on structural changes following Carisolv preparation varies considerably and we can conclude that this system for the chemomechanical removal of dental caries is likely sensitive to the application technique, mineralisation and other dentine characteristics.^{2,19}

The results of some contemporary studies have demonstrated that despite the differences between individual studies, in general the amount of smear layer after treatment with the Er:YAG laser and Carisolv in all cases is less than that after preparation with conventional rotating instruments, and surface changes are characterised by markedly rugged topography.^{2,3,12,15}



The morphological features of hard dental tissue observed in our study led us to the general conclusion that cavity preparation with the Er:YAG laser and Carisolv is consistent with the principles of MIP, leaving clean surfaces and strong micro-retention, suitable for adhesive restoration. The assumptions about the benefits of alternative techniques for MIP of dental tissue for adhesive restoration need to be confirmed by other clinical studies.

Conclusion

SEM analysis of hard dental tissue treated with steel and diamond burs showed surfaces covered with a thick layer of debris, which could compromise adhesion of filling materials. Dental tubule orifices were obturated with debris, with the exception of the areas under water turbulence, where the debris was partially removed.

Carisolv gel does not affect the enamel or healthy dentine. The surface topography of the dentine remaining after complete caries removal with Carisolv was rougher than that after conventional preparation with rotating burs. No typical smear layer was observed, but thin patches of contaminants, much less prominent than after drilling, were visible.

All laser-treated samples showed no evidence of thermal damage or signs of carbonification or melting. The SEM examination revealed characteristic micro-irregularities of the laser-prepared dentine surface without any smear layer and with

open dentinal tubules. Intertubular dentine was ablated more than peri-tubular dentine and that made the dentinal tubules appear to be better exposed. The Er:YAG laser ablated enamel effectively, leaving well-exposed enamel prisms without debris. The surfaces were very retentive.

This article was first published in Folia Medica 52/3 (2010): 46–55 (doi: 10.2478/v10153-010-0006-1; Copyright © 2010 Medical University Plovdiv).

Editorial note: A list of references is available from the publisher.

Fig. 7a A cavity prepared with the Er:YAG laser shows unclear cavity outlines and craters shading into one another (x 20 magnification). There are no precise outlined cavity elements.

Figs. 7b & c Laser-treated dentine surfaces are clean and free from debris, and all dentinal tubules are open. The surfaces are also irregular and rough, and therefore highly retentive. At greater magnification, the more effective removal of intertubular dentine is seen and this makes dentinal tubule orifices appear convex (x 500; 2000 magnification).

Figs. 7d & e Enamel surfaces treated with the Er:YAG laser revealed characteristic architectures of bundles of enamel prisms with different orientation. The surface is highly retentive and free from contaminants and a smear layer (x 2,000; 500 magnification).

_contact

laser

Dr Georgi Tomov

Department of Operative Dentistry and Endodontics
Faculty of Dental Medicine
Medical University of Plovdiv
Bulgaria

AD

”Action is the foundational key to all success.”

Pablo Picasso

become an

AUTHOR
for “laser”

► Contact Dajana Mischke.
d.mischke@oemus-media.de

Efficient and ergonomic apical resection using the Kaiserswerth algorithm

Author_Prof Marcel Wainwright, Germany




Fig. 1_The MAP system.

Fig. 1

ago. Apical resection is a challenging surgical procedure—not least because of the limited accessibility of the surgical field. Instrumentation of an apical resection case therefore requires a surgical technique that is as simple as it is safe and ergonomic.

This report presents two clinical cases that illustrate a system for applying retrograde endodontic filling materials that has proven a consistently viable option in our clinical practice.

_Introduction

Thanks to minimally invasive techniques, such as ultrasonic surgery and the availability of reliable restorative materials, the surgical revision and rehabilitation of endodontically treated teeth have a significantly better prognosis than only ten years

_Case I

The first case is that of a 34-year-old male patient who presented at our clinic for the first time. The orthopantomogram (OPG) yielded an accidental finding of apical translucencies at teeth #14, 36

Fig. 2_Autoclavable box with syringe, mixing cup and tips.

Fig. 3_Tips with different angulations.

Fig. 4_OPG showing active infection at sites 16, 36, and 46

Fig. 5_Surgical site after removing a bone block and performing apical resections on tooth #36.

Fig. 6_Bone block, stored in Ringer's solution.




Fig. 2




Fig. 3

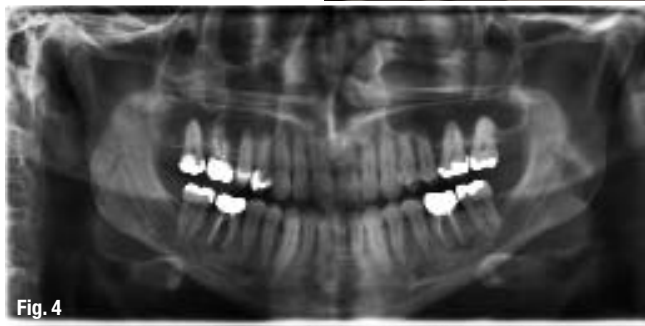

Fig. 4

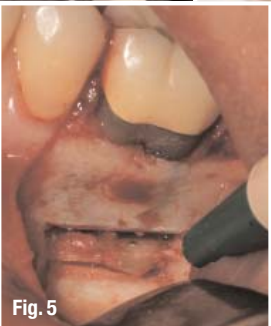

Fig. 5

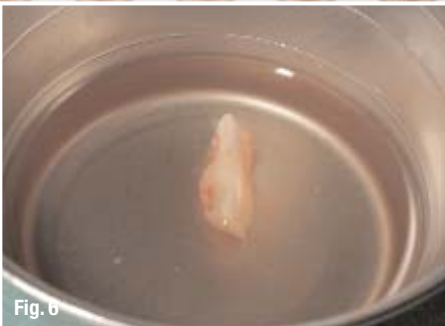

Fig. 6

and 46, which had been insufficiently treated endodontically. Clinically, these translucencies were asymptomatic and diagnosed as instances of chronic apical periodontitis or apical osteitis (Fig. 1).

Together with the patient, we planned for an apical resection of tooth #36 in conjunction with a retrograde root-canal filling with subsequent removal of the non-salvageable teeth #16 and 46.

Following extensive consultation and patient education, surgery was performed under local infiltration anaesthesia. With our protocol, block anaesthesia is unnecessary in 98% of all surgical interventions in the mandible, and dispensing with it minimises the risk of iatrogenic nerve damage.

An incision was performed in the marginal gingiva, with a mesiodistal relief incision, followed by preparation of a full flap for adequate access to the surgical site. Using the Piezotome II (Acteon), a buccal bone window of adequate depth was prepared to gain access to the apical region at tooth #36 in order to perform the apical resection. It is helpful for the preparation to provide for undercuts in order to facilitate subsequent removal of the bone block. As no rotary instruments were used and because ultrasonic surgical instruments have a vaso-constrictor effect, the surgical field remained impressively free of bleeding and afforded a clear view of the site. The bone block was stored in Ringer's solution to facilitate subsequent repositioning (Fig. 2). The root apices were then exposed and ultrasonically removed (Fig. 4).

After apical resection, our protocol called for thorough removal of all soft tissue using instruments, followed by complete decontamination of the cyst lumen using a diode laser. Care had to be taken to ensure that the laser tip did not make direct contact with the bone.

Retrograde preparation of the root canals was also performed ultrasonically, which only takes a few seconds when using the Piezotome II.

Following chlorhexidine digluconate and sodium-hypochlorite rinses, the retro-prepared root canals were dried with paper points. In our clinic, we have had excellent success with the MAP (Micro-Apical Placement) retro system (PDSA), which has been on the market for many years (Fig. 5). The system comes in a sterilisable metal container. The triple-angled endo tips greatly simplify the uptake and application of the material, with the syringe facilitating "injection" (retrograde obturation) of the root canal to a depth of several millimetres (Fig. 6). This well-targeted application of the restorative material keeps the surgical field clear (Fig. 7).

On application of ProRoot MTA (DENTSPLY Maillefer), the material was allowed to set, the cross-section surface of the resected area was smoothed and polished, the resection lumen was filled with a quick-hardening bone cement (VitalOs, PDSA), and the bone block was returned to its place (Fig. 8). The post-operative radiograph shows the site following apical resection and retrograde root filling (Fig. 9).

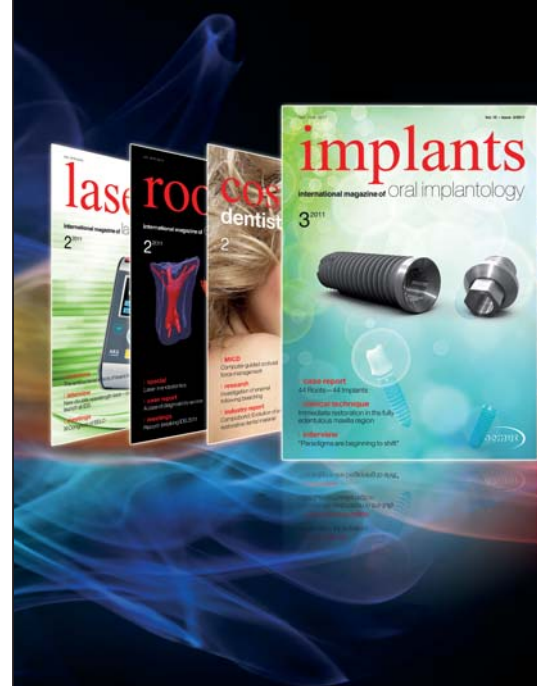The patient was prescribed Amoxicillin 750 mg and Ibuprofen 600 mg post-operatively, as well as Arnica C30 to prevent swelling. Post-operative healing was uncomplicated, and the sutures were removed after eight days. Swelling was minimal, and the patient reported virtually no post-operative pain.

Case II

The second case is that of a 65-year-old female patient who presented with an apical resection on tooth #14 that had been performed in alio loco five years before. The patient presented at our clinic because the site had become reinfected.

implants

international magazine of oral implantology



You can also subscribe via
www.oemus.com/abo

 **Subscribe now!**

I hereby agree to receive a free trial subscription of **implants international magazine of oral implantology** (4 issues per year). I would like to subscribe to **implants** for € 44 including shipping and VAT for German customers, € 46 including shipping and VAT for customers outside of Germany, unless a written cancellation is sent within 14 days of the receipt of the trial subscription. The subscription will be renewed automatically every year until a written cancellation is sent to OEMUS MEDIA AG, Holbeinstr. 29, 04229 Leipzig, Germany, six weeks prior to the renewal date.


Reply via Fax +49 341 48474-290 to OEMUS MEDIA AG or per E-mail to grasse@oemus-media.de

Last Name
First Name
Company
Street
ZIP/City/County
E-Mail
Signature

Notice of revocation: I am able to revoke the subscription within 14 days after my order by sending a written cancellation to OEMUS MEDIA AG, Holbeinstr. 29, 04229 Leipzig, Germany.

Unterschrift

OEMUS MEDIA AG
Holbeinstr. 29, 04229 Leipzig
Tel.: +49 341 48474-0
Fax: +49 341 48474-290
E-Mail: grasse@oemus-media.de



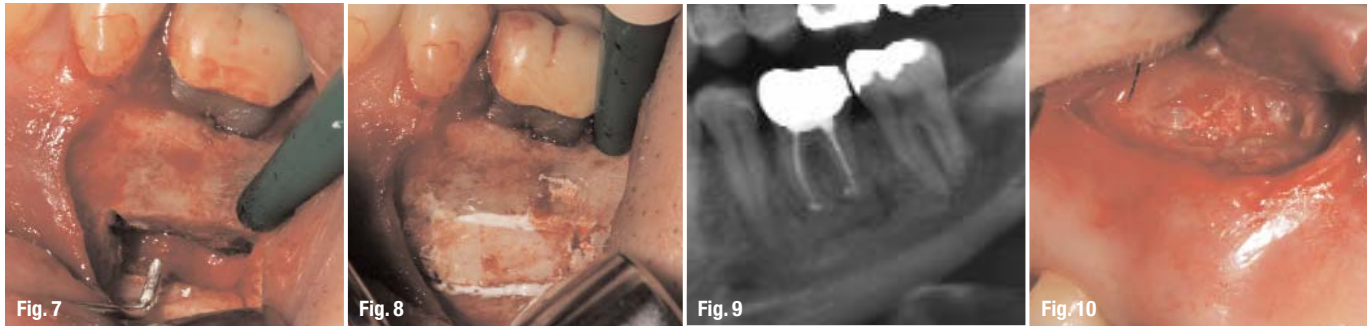


Fig. 7 Applying MTA using the MAP system.
Fig. 8 The bone block is repositioned and secured with bone cement (VitalOs).
Fig. 9 Postoperative OPG detail following apical resection of tooth #36.
Fig. 10 Surgical site 14 following the semilunar incision.
Fig. 11 Retrograde ultrasonic preparation (Piezotome II, Acteon)
Fig. 12 Mixed Pro-Root MTA prior to application.
Fig. 13 Applying the MTA using the MAP system.
Fig. 14 Resected and retro-filled tooth #14.
Fig. 15 Baseline status of tooth #14 following apical resection alio loco and reinfection.
Fig. 16 Revision treatment outcome for tooth #14.

She reported pain at tooth # 14 on occlusal contact and percussion. A local digital radiograph clearly showed the area of apical resection, the two root-canal fillings and a cystic peri-apical radiolucency (Fig. 10). Since this was a surgical re-entry case, the same incision technique was used as chosen by the primary treatment provider, i.e. a crescent-shaped incision as described by Pichler (Fig. 11). The procedure was otherwise the same as in case I. Following retrograde ultrasonic preparation (Fig. 12), ProRoot MTA was mixed to a working consistency and applied using the MAP system (Figs. 13 & 14). This clean and efficient application mode and controlled handling shortened the surgical procedure and reduced post-operative complaints (Fig. 15). The post-operative radiograph shows an efficient retrograde filling of both root canals following revision of tooth # 14. Owing to a projection artefact, the restorative appears beside the canals, when it is in fact located clinically exactly within.

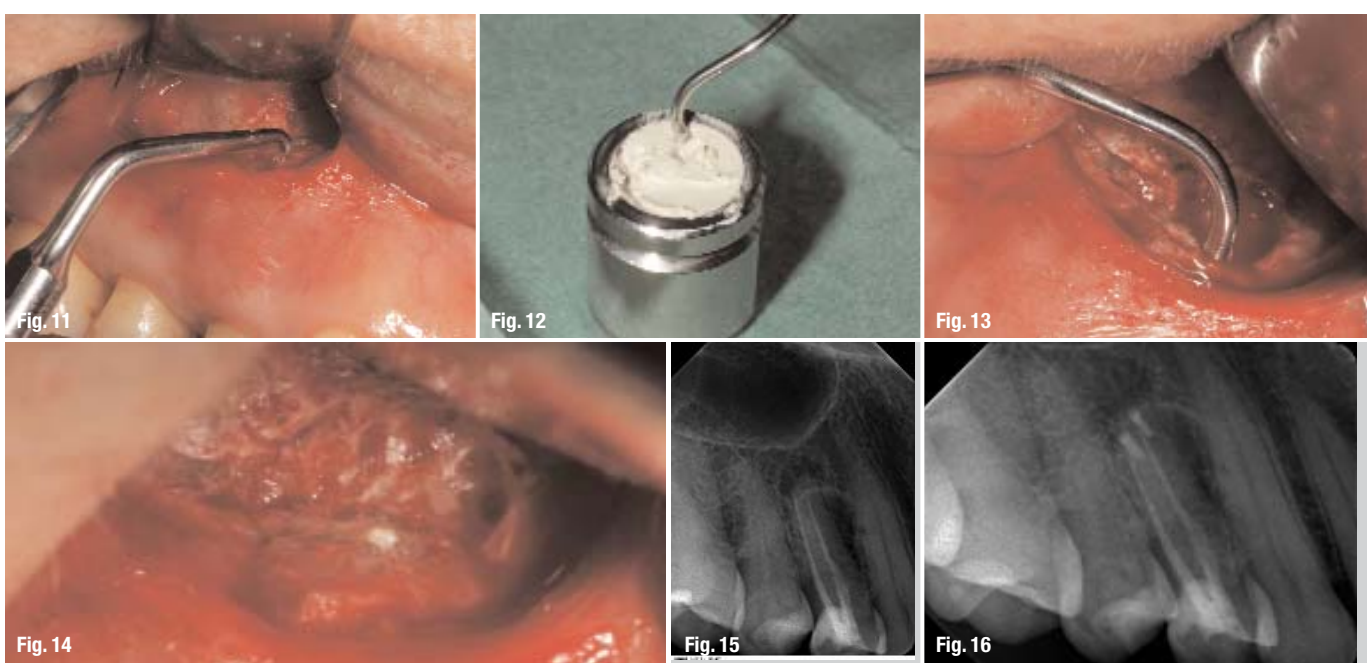
_Conclusion

Apical resection is a routine procedure in our clinic. Thanks to the use of ultrasonic surgery, the

surgical laser, and the MAP system, this procedure is reliable, predictable and simple, and we have preserved the natural teeth of many patients. Being an oral implantologist myself, I do not perceive anything contradictory in looking at these treatment methods; rather, apical resection is a complementary treatment mode and an attempt to preserve teeth over the longer term that would otherwise be considered lost.

The list of references is available from the author on request.

_contact	laser
Prof Marcel Wainwright	
Dental Specialists and White Lounge Kaiserswerth Kaiserswerther Markt 25–27 40489 Düsseldorf, Germany	
www.dentalspecialists.de	



The 31st Moscow International Dental Forum

Moscow 2012



The 31st Moscow International Dental Forum

Dental Salon international dental fair

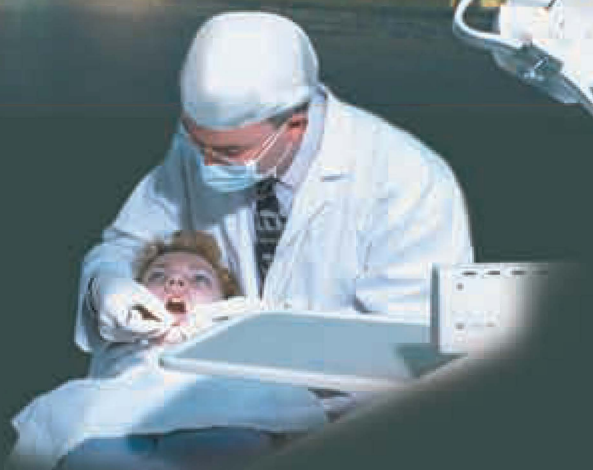April 23-26

Crocus Expo exhibition grounds

more than 450 exhibitors	more than 25000 attendees	more than 35 countries
---------------------------------------	--	-------------------------------------

www.dental-expo.com

DENTALEXPO®



“The Scanner mode is going to revolutionise dentistry”

An interview with Dr Ladislav Grad & Dr Matjaz Lukac, Fotona d.d.



Dr Ladislav Grad & Dr Matjaz Lukac

_The new LightWalker hard- and soft-tissue dental laser system from Fotona was introduced at IDS 2011. The system offers a wide range of dental applications and, according to the manufacturer, will revolutionise dentistry in the coming years. **laser** had the opportunity to speak to Drs Ladislav Grad and Matjaz Lukac about the benefits of the system for general dentists, as well as specialists.

_laser: *Dr Grad, Dr Lukac, congratulations on the launch of LightWalker! Would you please tell us about its applications and how dentists can benefit from using it?*

Dr Grad: LightWalker has two laser sources, offering a wide range of dental applications. The laser can be used in all different dental specialties—endodontics, periodontics, conservative dentistry, tooth whitening, etc.—but there is more. Fotona is a manufacturer of medical lasers and well known in the field of surgical and dermatological lasers. Owing to our background, we were able to include additional indications. You see, in some countries, dentists can perform aesthetic treatments, such as facial hair removal or removal of vascular lesions.

Our system is also perfect for surgical procedures. For example, treating leukoplakia was a very invasive procedure traditionally. With our laser, the lesions can be vaporised with almost no bleeding or trauma, which is a big advantage for patients and doctors. We know of some clinics, where one laser is shared by different departments: three days a week, it is used in the dental department; two days a week, the aesthetic doctors and dermatologists use it for their patients.

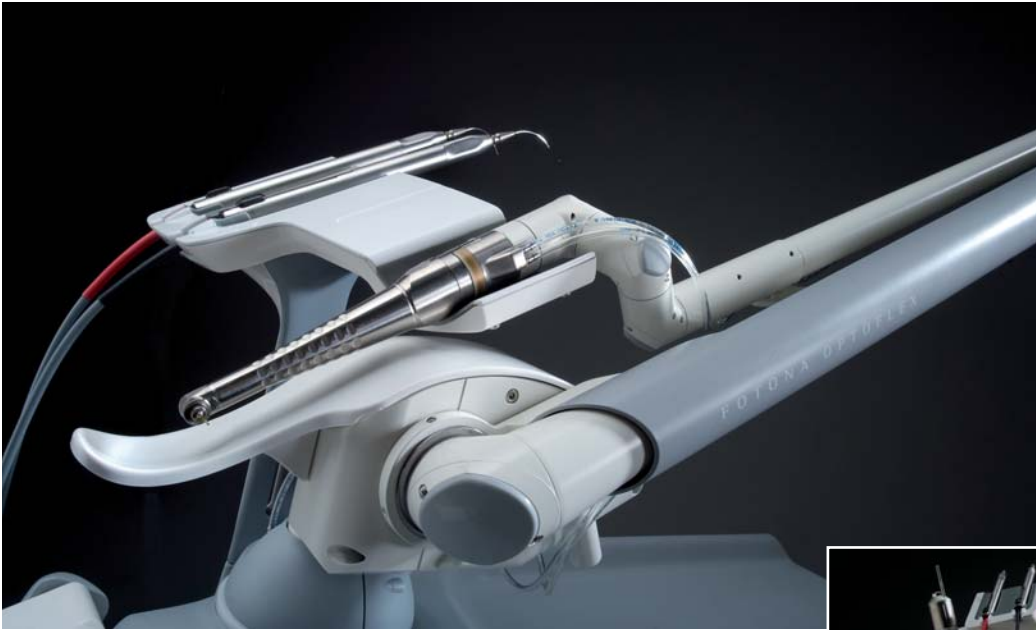_What was the impetus for developing the new laser?

Dr Lukac: We have been in dental lasers since the early '90s, and wanted to pool all of our experience—in terms of use and technology—into a new system without having to make any compromises. Amongst the most exciting applications of LightWalker is the photon-induced root-canal therapy that makes treating even posterior teeth a simple procedure for every general dentist. There is also a combined laser wavelength procedure, the TwinLight, for periodontal disease treatment. With TwinLight, hard-tissue calculus and soft-tissue epithelial lining can be removed. General dentists can now treat perio patients' disease comprehensively, without scalpels or sutures, right in their own practice. Amongst the aesthetic treatments, our patented TouchWhite tooth-whitening method should be mentioned. It is extremely gentle, yet shortens the whitening time by a factor of five.

Our patented quantum square pulse (QSP) technology allows the laser to ablate more efficiently and with greater precision because the laser beam is not affected by hard-tissue debris. We created this technology especially for this laser. By being able to ablate more efficiently, the edges of individual craters are virtually straight, creating a perfect cut and resulting in higher levels of precision and maximum tooth preservation in hard-tissue treatments.

_Where are your biggest markets at the moment and which markets are you approaching?

Dr Grad: Currently, the biggest market for our lasers is Europe. However, with LightWalker we plan on becoming a global market leader.



What additional features are you offering with the laser?

Dr Lukac: There is one feature, the scanner mode, which we think is going to revolutionise dentistry. LightWalker is the first dental laser system in the world that can accommodate laser scanning technology. The scanner-ready Er:YAG laser will be able to provide consistent and even ablation in hard and soft tissue. The speed and consistency of ablation performed with a scanner is virtually impossible to achieve with any other tool. It is the "weightlessness" of the laser light that makes this possible. Our goal now is to guide dentists in using the scanning ability of the laser.

We also believe that one of the first fields that is going to be revolutionised will be implantology. Now, it is finally possible to drill larger diameter holes with laser. Currently, mechanical drills are used, which cause thermal damage and a smear layer, which can lead to problems later on, such as infections. We are currently conducting clinical research on this and we don't have FDA clearance yet, but that's where we are going.

What effect do you foresee lasers are going to have on dentistry?

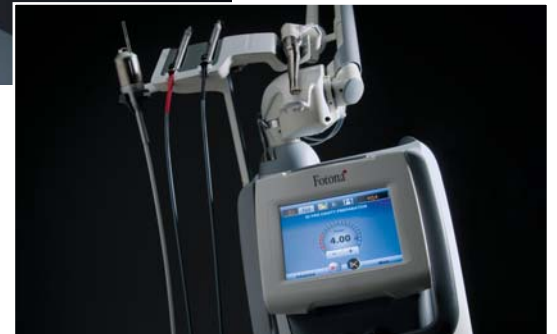Dr Lukac: The big selling point for this unit is its wide range of applications. This is what is drawing customers. As I said, this technology evolves so that it is easy to use. It is a tool that can be used for a variety of indications. I am predicting that soon there will be no more laser-specific dental meetings because the laser is becoming part of the regular dental practice, thus laser will become part of general meetings. Soon, lasers will be just another dependable tool that dentists use without hesitation.

How can dentists learn about how to use this laser effectively? Are you offering courses?

Dr Grad: Yes. Laser dentistry is currently not part of the dental curriculum taught at most universities.

There are, however, many possibilities for postgraduate dental education. We have reference doctors in different states who offer local training courses. We collaborate a great deal with Aachen University in Germany, which is the leading educational and research institution for lasers in dentistry. There are specific dates reserved on which practitioners can attend a training seminar at the university. It is very important for users to establish a safe and confident handling of this technology and education is the way to go about establishing that. There is no turning back. Without laser technology, there is no modern dentistry.

For information on Fotona laser workshops please go to www.fotona.com/en/dentistry/workshops/.



_contact

laser

Fotona d.d.

Stegne 7
1210 Ljubljana
Slovenia

info@fotona.com
www.fotona.com

International events

2011

20th Annual Scientific Congress of the EAO

Athens, Greece

12–15 October 2011

www.eao-congress.com

Annual Congress of DGL

Düsseldorf, Germany

28–29 October 2011

www.startup-laser.de

Dentistry 2011

Abu Dhabi, United Arab Emirates

1–3 November 2011

www.dentistryme.com

Greater New York Dental Meeting

New York, NY, USA

25–30 November 2011

www.gnydm.org

2012

LaserOptics Berlin

Berlin, Germany

19–21 March 2012

www.laser-optics-berlin.de

IDEX Istanbul

Istanbul, Turkey

5–8 April 2012

www.cnridex.com

IDEM International Dental Exhibition

Singapore

20–22 April 2012

www.idem-singapore.com

13th WFLD World Congress

Barcelona, Spain

26–28 April 2012

www.wfld-barcelona2012.com

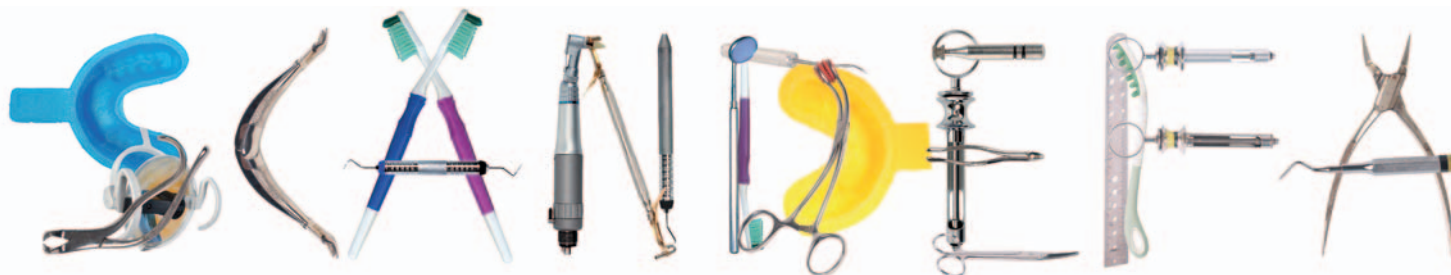90th General Session & Exhibition of the IADR

Rio de Janeiro, Brazil

20–23 June 2012

www.iadr.org





APRIL 26- 28, 2012 • BELLA CENTER • COPENHAGEN • DENMARK

Welcome to the 45th Scandinavian Dental Fair
The leading annual dental fair in Scandinavia

SCANDEFA 2012



The 45th SCANDEFA invites you to exquisitely meet the Scandinavian dental market and sales partners from all over the world in springtime in wonderful Copenhagen

SCANDEFA 2012

Is organized by Bella Center and is being held in conjunction with the Annual Scientific Meeting, organized by the Danish Dental Association (www.tandlaegeforeningen.dk).

175 exhibitors and 11.422 visitors participated at SCANDEFA 2011 on 14,220 m² of exhibition space.

Exhibit at Scandefa

Book online at www.scandefa.dk
Sales and Project Manager, Christian Olrik
col@bellacenter.dk, T +45 32 47 21 25

Travel information

Bella Center is located just a 10 minute taxi drive from Copenhagen Airport. A regional train runs from the airport to Orestad Station, only 15 minutes drive.

Check in at Bella Center's newly built hotel

Bella Sky Comwell is Scandinavia's largest design hotel. The hotel is an integral part of Bella Center and has direct access to Scandefa. Book your stay on www.bellasky.dk

3rd European Congress of the WFLD in Rome

Author_Umberto Romeo, Italy



The Third European Congress of World Federation of Laser Dentistry (WFLD-ED) was held from 9–11 June 2011, in the Department of Stomatology and Maxillo-Facial Surgery of Sapienza University of Rome. The choice to organize the Congress in a university is a testimony of ever closer bond between the realities of professional and academic world.

The greatest scientific event at the continental level Laser Dentistry has been chaired by the Director of the Department, Antonella Polimeni who welcomed with warmth and affection the many colleagues, both Italian and foreign (represented more than 21 countries around the world), that

have made with their presence and their scientific contributions, the success of the Roman event.

Among the speakers at the event, were numbered of Dentistry International big names such as: Nam-mour, Cantatore, Rocca, Stabholz, Parma Benfenati, Baraldini, Gutknecht, Esapana, Sculean, Sibbet, Wilder Smith, etc. which have enriched the conference program with their much followed reports.

That the union between University and WFLD has been a happy intuition, have confirmed the numbers, absolutely amazing, that characterized Rome 2011: 450 participants, 70 posters and 63 oral communication. The data are, really flattering,





which have rewarded the efforts and the work of the Scientific and the Organizing Committee chaired respectively by Umberto Romeo and Roly Kornblit.

Considerable interest has also received scientific events on the sidelines of the main program, starting from the Certification Course, the basic course of a day that can be certified by the WFLD, which had as speakers: Rocca, Nammour, Vescovi, Romeo, Kornblit, Fornaini and Del Vecchio gave the participants an introduction to laser dentistry at the highest level. Similar courses have attracted acclaim single issue of Dermatology and Aesthetic Surgery. The Congress was also framed by mo-

ments of great cultural and social, from the inauguration took place in the prestigious Great Hall of the Rectorate in the presence of the Rector, Luigi Frati, and concludes with the popular Gala Dinner which took place elegant Caffarelli Terrace in the heart of the eternal city where foreign guests were able to admire a truly unique and exclusive view.

The Congress was closed by a closing address by Professor Polimeni, who emphasized the important work done by all the Department with a special plaudits to Professor Romeo and Dr Kornblit, and the taking over of the banner of WFLD from the colleagues of Barcelona for the next edition of WFLD Congress 2012.



Basic Laser Certification Course in Malaysia



Fig. 1

Fig. 2

Fig. 1 Group photo after certificate presentation
Fig. 2 Hands-on practical session (Dr K. Luk surrounded by his participants)

Basic Laser Certification Course (BLCC) was organized in conjunction with the 68th Malaysian Dental Association (MDA)-AGM/Federation Dental International (FDI) scientific convention and trade exhibition and supported by the Malaysian Dental Association. This year the theme for this FDI world Dental Federation Congress is "Current Perspectives in Dentistry". It was most appropriate for us to begin this Congress by presenting the "Current perspectives in Laser Dentistry" in this pre-congress workshop, on the 8-9 June 2011. The workshop venue was the Faculty of Dentistry, at The National University of Malaysia.

one and a half day lecture, including a hands-on and examination laser course, passed with an examination mark of above 75%.

In deed, the participant who scored the highest was from Malaysia. The learning atmosphere and the eagerness of learning from the audients were so vibrant. Furthermore, the quality of question was of a high standard and evidently everybody had a good time. We all agree that we had run another successful laser course.

Thanked for the tremendous supported from Dr Muzafar Bin Hamirudin (Chair, LOC), Dr Roberto Vianna (Chair, FDI ExCo) and Dr How Kim Chuan (Past President, MDA) with their team (Dr S. Kanagasigam, Dr K. Penriasamy, Dr T. Palany and others) and the Speakers from our Asian Pacific Division, included Prof Steven Loh (Chair, WFLD- APD), Prof Kenji Yosida (General Secretary, WFLD), A/Prof Sajee Sattayut, Dr Kenneth Luk, Dr Shigeyuki Nagai and Dr Ambrose Chan who made this laser course so educational as well as so enjoyable that it left everyone with an wonderful experience that will be remembered for a long, long time.

The maximum number of participants was kept to thirty who came locally as well as internationally and ranged from PhD students to dental specialist. All who took part in this



submission guidelines:

Please note that all the textual components of your submission must be combined into one MS Word document. Please do not submit multiple files for each of these items:

- _ the complete article;
- _ all the image (tables, charts, photographs, etc.) captions;
- _ the complete list of sources consulted; and
- _ the author or contact information (biographical sketch, mailing address, e-mail address, etc.).

In addition, images must not be embedded into the MS Word document. All images must be submitted separately, and details about such submission follow below under image requirements.

Text length

Article lengths can vary greatly—from 1,500 to 5,500 words—depending on the subject matter. Our approach is that if you need more or less words to do the topic justice, then please make the article as long or as short as necessary.

We can run an unusually long article in multiple parts, but this usually entails a topic for which each part can stand alone because it contains so much information.

In short, we do not want to limit you in terms of article length, so please use the word count above as a general guideline and if you have specific questions, please do not hesitate to contact us.

Text formatting

We also ask that you forego any special formatting beyond the use of italics and boldface. If you would like to emphasise certain words within the text, please only use italics (do not use underlining or a larger font size). Boldface is reserved for article headers. Please do not use underlining.

Please use single spacing and make sure that the text is left justified. Please do not centre text on the page. Do not indent paragraphs, rather place a blank line between paragraphs. Please do not add tab stops.

Should you require a special layout, please let the word processing programme you are using help you do this formatting automatically. Similarly, should you need to make a list, or add footnotes or endnotes, please let the word processing programme do it for you automatically. There are menus in every programme that will enable you to do so. The fact is that no matter how carefully done, errors can creep in when you try to number footnotes yourself.

Any formatting contrary to stated above will require us to remove such formatting before layout, which is very time-consuming. Please consider this when formatting your document.

Image requirements

Please number images consecutively throughout the article by using a new number for each image. If it is imperative that certain images are grouped together, then use lowercase letters to designate these in a group (for example, 2a, 2b, 2c).

Please place image references in your article wherever they are appropriate, whether in the middle or at the end of a sentence. If you do not directly refer to the image, place the reference at the end of the sentence to which it relates enclosed within brackets and before the period.

In addition, please note:

- _ We require images in TIF or JPEG format.
- _ These images must be no smaller than 6x6 cm in size at 300 DPI.
- _ These image files must be no smaller than 80 KB in size (or they will print the size of a postage stamp!).

Larger image files are always better, and those approximately the size of 1 MB are best. Thus, do not size large image files down to meet our requirements but send us the largest files available. (The larger the starting image is in terms of bytes, the more leeway the designer has for resizing the image in order to fill up more space should there be room available).

Also, please remember that images must not be embedded into the body of the article submitted. Images must be submitted separately to the textual submission.

You may submit images via e-mail, via our FTP server or post a CD containing your images directly to us (please contact us for the mailing address, as this will depend upon the country from which you will be mailing).

Please also send us a head shot of yourself that is in accordance with the requirements stated above so that it can be printed with your article.

Abstracts

An abstract of your article is not required.

Author or contact information

The author's contact information and a head shot of the author are included at the end of every article. Please note the exact information you would like to appear in this section and format it according to the requirements stated above. A short biographical sketch may precede the contact information if you provide us with the necessary information (60 words or less).

Questions?

Dajana Mischke
d.mischke@oemus-media.de

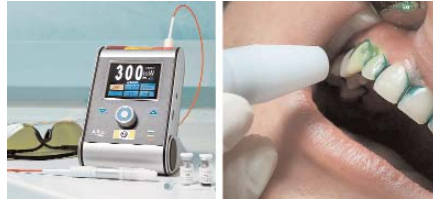Manufacturer News

A.R.C. Laser

A.R.C. Laser convinces with EmunDo®

An increasing number of users speak on their enthusiasm concerning the positive impact of the entirely new Photodynamic Therapy. They are reporting of the simple and gentle laser-method to treat periodontitis.

For the first time in dental history, PDT is considered to achieve consistently effective and predictable outcomes in combination with a normal FOX diode laser.



The colorant EmunDo®—stimulated through the laser—generates aggressive singulett oxygen. As a consequence EmunDo® kills effectively all gram-positive and all gram-negative bacteria particularly in the periodontal therapy. Patients which have had problems with antibiotics and its side effects in the past, can be relieved now. EmunDo® is not only any kind of PDT agent—it is a acknowl-

edged therapy concept based on wide-range studies and the direct cooperation with AALZ Aachen, Germany.

- Unique selling point for your office:
- 100 % anti-bacterial impact
 - even germs in tissue are accessible
 - Reliable therapy concept

A.R.C. Laser

Bessemerstraße 14
90411 Nürnberg, Germany

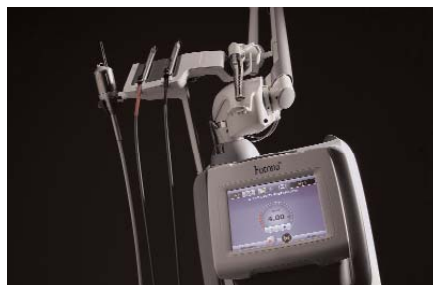info@arclaser.de
www.arclaser.de

Fotona

LightWalker AT—Award-winning Dental Laser

Fotona's new laser system, LightWalker AT, has been recognized in the dental community by key opinion leaders. It has recently received the Pride Institute's Best of Class Technology Award for 2011 and was selected as one of Dentistry Today's TOP 100 Products of 2011.

A panel of dental technology experts, organized by the Pride Institute, a dental practice management consulting firm based in Novato, California, selected this year's winning products through a rigorous assessment selection process. The aim of the award is



to provide an unbiased, non-profit assessment of available technologies in the dental space. LightWalker AT was an honoree in the Therapeutic category.

What is more, Dentistry Today, America's leading clinical news magazine for dentists, featured the LightWalker as one of the TOP 100 dental products

of the year. According to the magazine, LightWalker was selected on the basis of reader response and represents what is new and innovative in the profession today. LightWalker is the latest dental laser to be introduced by Fotona. The system is designed for high-speed cavity preparations, virtually all soft-tissue surgical procedures, as well as minimally invasive TwinLight (Er:YAG and Nd:YAG) endodontic and periodontal treatments. It is the only dental laser system on the market that includes built-in scanner-ready technology.

Fotona d.d.

Stegne 7
1210 Ljubljana, Slovenia

info@lightwalkerlaser.com
www.lightwalkerlaser.com

Hager & Werken

LaserHF—Radio frequency and laser combined for the first time

LaserHF® from Hager & Werken is a combined unit which for the first time offers two technologies in one device: laser and radio frequency. While tissue can be perfectly cut, resected and coagulated with radio frequency, the laser offers additional, fascinating applications in endodontics, periodontics as well as in implant surgery. On top of that, new approaches, such as the tissue treatment

in therapeutic terms (Low Level Laser Therapy) and antimicrobial photodynamic therapy (aPDT) can be carried out. LaserHF includes two types of laser: A



diode laser with 975nm/6W and a diode soft laser with 650nm/100mW for LLLT and aPDT.

An easy to use touch-screen offers 15 pre-set programs in the laser unit (10x diode laser, 5x diode soft laser). The radio frequency-unit offers various pre-set programs. Additionally the user can save individual programs. Further information is available at:

Hager & Werken GmbH & Co.KG

PF 10 06 54
47006 Duisburg, Germany
info@hagerwerken.de
www.hagerwerken.de

KaVo Dental

5-star light for your dental practice

Ideal working conditions in the dental practice, begin with the best possible view of the treatment site. The KaVoLUX 540 LED light, with its unique optical system and four different coloured LEDs, supplies natural white light of the highest quality, at up to 40,000 LUX at every point in the illuminated field. Thus the user always has the best view, ensuring optimum treatment results. With outstanding color rendering index values and the natural daylight-like, full spectrum of light, it is possible to accurately compare tooth and composite colors, directly at the dental chair.

The innovative COMPOsave mode, filters out all blue components of the light and thus slows down undesirable polymerization of composites. It is thus possible to adapt light-cured materials at a relaxed pace, without having to dim the light.

Even, illuminated field

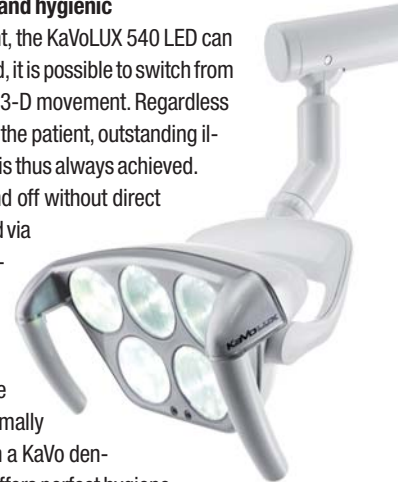The KaVoLUX 540 LED light delivers the ideal light-field, for a perfectly illuminated treatment area: homogenous, precisely delineated and with reduced shadow formation. The colour-temperature can be individually adjusted in five steps, e.g. for higher contrast on soft tissue. Even the most inaccessible parts of the mouth are clearly illuminated, thanks to the impressive, light penetration properties. The detailed structures thus can be seen in sharper focus and can be optimally identified, without eye-strain.

Ergonomic, practical, flexible and hygienic

With its unique, lockable 3D-joint, the KaVoLUX 540 LED can be variably positioned: if required, it is possible to switch from the fixed 2-D mode, to a flexible 3-D movement. Regardless of the position of the dentist and the patient, outstanding illumination of the treatment site, is thus always achieved.

The light can be switched on and off without direct contact, or be intuitively operated via the treatment centre's dentist element controls. Removable handles and smooth surfaces, enable rapid and thorough disinfection, thus supporting simple and fast hygiene regimes. Optimally

coordinated in combination with a KaVo dental chair, the KaVoLUX 540 LED offers perfect hygiene, high illumination quality, long service-life and maximum operating comfort.



KaVo Dental GmbH

Bismarckring 39, 88400 Biberach/Riß, Germany
Tel.: +49 7351 56-0
Fax: +49 7351 56-71104

info@kavo.com
www.kavo.com

Syneron Dental Lasers

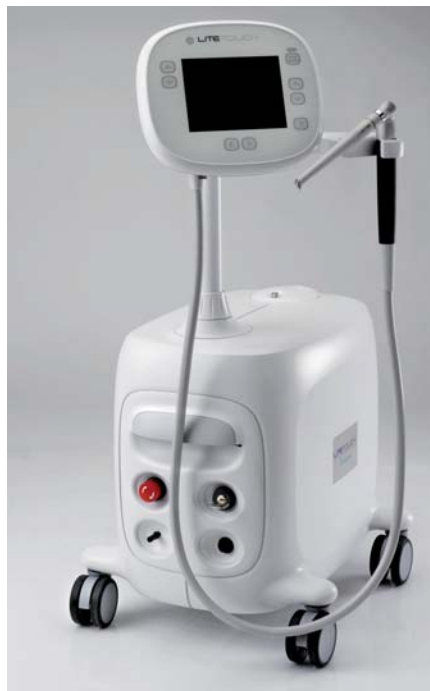Syneron Dental Lasers

Partnerships will bring the LiteTouch™ and Laser-in-Handpiece™ technologies to Poland, the Netherlands, the Czech Republic and Serbia Dental Markets.

Syneron Dental Lasers, the inventor of the Lite-Touch™ and Laser-in-Handpiece™ technology announced the signing of four distribution agreements in Europe.

The company has solidified partnerships with Shar-Pol in Poland, International Equipment Center (IEC) in the Netherlands, and B.P.C. Ltd. in the Czech Republic and Serbia. The new distributor agreements follow Syneron Dental's existing strong partnerships with other European distributors such as Dentacon, its Balkan region distributor, and Swiss distributor Orcos Medical, among other international distributors.

Under these agreements, the distributors will sell Syneron Dental's LiteTouch™ and D-Touch™ as well as promote, educate and train the customers. Syneron Dental Lasers plans to expand



into additional countries within Europe and Asia during the second half of 2011.

"We are very excited about the opportunities these partnerships present to Syneron Dental Lasers," said Ira Prigat, Syneron Dental's President.

"Our business operations are rapidly expanding while our close-knit synergy with the existing dis-



tributors is further empowering the Syneron Dental family worldwide, thus contributing to the company's ongoing success. As an emerging, fast-growing market leader, Syneron Dental Lasers is strategically aspired to continue establishing its global footprint and alongside with its steadily increasing market share, is already changing the shape of the laser dentistry market.

Syneron Dental Lasers is committed to promoting technology innovations, cross-continent clinical research collaborations, laser dentistry education and long-term support and services to Lite-Touch™ customers worldwide."

Syneron Dental Lasers

POB 223
Yokneam 20692, Israel

dental@syneron.com
www.synerondental.com.

laser

international magazine of laser dentistry



Publisher

Torsten R. Oemus
oemus@oemus-media.de

CEO

Ingolf Döbbecke
doebbecke@oemus-media.de

Members of the Board

Jürgen Isbaner
isbaner@oemus-media.de

Lutz V. Hiller
hiller@oemus-media.de

Chief Editorial Manager

Norbert Gutknecht
ngutknecht@ukaachen.de

Co-Editors-in-Chief

Samir Nammour
Jean Paul Rocca

Managing Editors

Georg Bach
Leon Vanweersch

Division Editors

Matthias Frenzen
European Division

George Romanos
North America Division

Carlos de Paula Eduardo
South America Division

Toni Zeinoun
Middle East & Africa Division

Loh Hong Sai
Asia & Pacific Division

Senior Editors

Aldo Brugneira Junior
Yoshimitsu Abiko
Lynn Powell
John Featherstone
Adam Stabholz
Jan Tuner
Anton Sculean

Editorial Board

Marcia Martins Marques, Leonardo Silberman, Emna Ibrahim, Igor Cernavin, Daniel Heyselaer, Roeland de Moor, Julia Kamenova, T. Dostalova, Christliebe Pasini, Peter Steen Hansen, Aisha Sultan, Ahmed A Hassan, Marita Luomanen, Patrick Maher, Marie France Bertrand, Frederic Gaultier, Antonis Kallis, Dimitris Strakas, Kenneth Luk, Mukul Jain, Reza Fekrazad, Sharonit Sahar-Helft, Lajos Gaspar, Paolo Vescovi, Marina Vitale, Carlo Fornaini, Kenji Yoshida, Hideaki Suda, Ki-Suk Kim, Liang Ling Seow, Shaymant Singh Makhan, Enrique Trevino, Ahmed Kabir, Blanca de Grande, José Correia de Campos, Carmen Todea, Saleh Ghabban Stephen Hsu, Antoni Espana Tost, Josep Arnabat, Ahmed Abdullah, Boris Gaspirc, Peter Fahlstedt, Claes Larsson, Michel Vock, Hsin-Cheng Liu, Sajee Sattayut, Ferda Tasar, Sevil Gurgan, Cem Sener, Christopher Mercer, Valentin Preve, Ali Obeidi, Anna-Maria Yannikou, Suchetan Pradhan, Ryan Seto, Joyce Fong, Ingmar Ingenegeren, Peter Kleeemann, Iris Brader, Masoud Mojahedi, Gerd Volland, Gabriele Schindler, Ralf Borchers, Stefan Grümer, Joachim Schiffer, Detlef Klotz, Herbert Deppe, Friedrich Lampert, Jörg Meister, Rene Franzen, Andreas Braun, Sabine Sennhenn-Kirchner, Siegfried Jänicke, Olaf Oberhofer, Thorsten Kleinert

Executive Producer

Gernot Meyer
meyer@oemus-media.de

Designer

Sarah Fuhrmann
s.fuhrmann@oemus-media.de

Customer Service

Marius Mezger
m.mezger@oemus-media.de

Editorial Office

Dajana Mischke
d.mischke@oemus-media.de

Published by

OEMUS MEDIA AG
Holbeinstraße 29
04229 Leipzig, Germany
Tel.: +49 341 48474-0
Fax: +49 341 48474-290
kontakt@oemus-media.de
www.oemus.com

Printed by

Messedruck Leipzig GmbH
An der Hebemärchte 6
04316 Leipzig, Germany

laser

international magazine of laser dentistry
is published in cooperation with the World Federation for Laser Dentistry (WFLD).

WFLD President

University of Aachen Medical Faculty
Clinic of Conservative Dentistry
Pauwelsstr. 30
52074 Aachen, Germany
Tel.: +49 241 808964
Fax: +49 241 803389644
ngutknecht@ukaachen.de
www.wfld-org.info

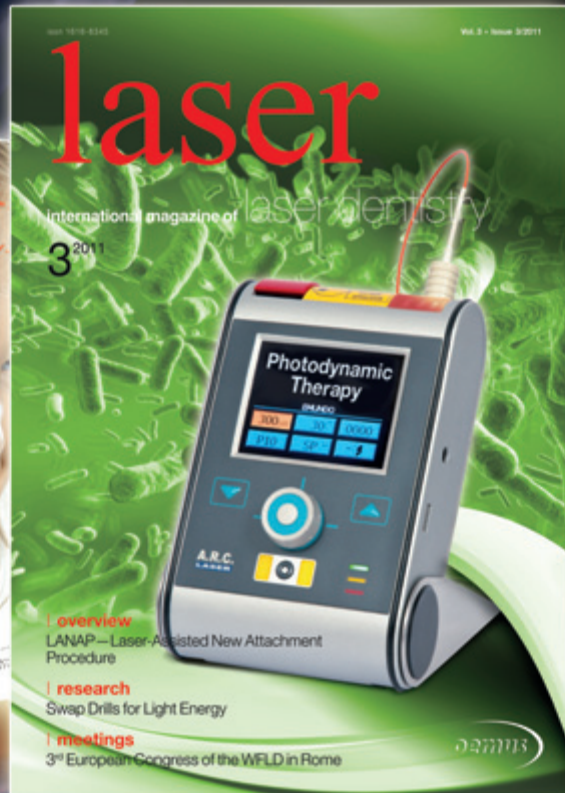Copyright Regulations

The **laser international magazine of laser dentistry** is published by Oemus Media AG and will appear in 2010 with one issue every quarter. The magazine and all articles and illustrations therein are protected by copyright. Any utilization without the prior consent of editor and publisher is inadmissible and liable to prosecution. This applies in particular to duplicate copies, translations, microfilms, and storage and processing in electronic systems.

Reproductions, including extracts, may only be made with the permission of the publisher. Given no statement to the contrary, any submissions to the editorial department are understood to be in agreement with a full or partial publishing of said submission. The editorial department reserves the right to check all submitted articles for formal errors and factual authority, and to make amendments if necessary. No responsibility shall be taken for unsolicited books and manuscripts. Articles bearing symbols other than that of the editorial department, or which are distinguished by the name of the author, represent the opinion of the afore-mentioned, and do not have to comply with the views of Oemus Media AG. Responsibility for such articles shall be borne by the author. Responsibility for advertisements and other specially labeled items shall not be borne by the editorial department. Likewise, no responsibility shall be assumed for information published about associations, companies and commercial markets. All cases of consequential liability arising from inaccurate or faulty representation are excluded. General terms and conditions apply, legal venue is Leipzig, Germany.

laser

international magazine of laser dentistry



You can also subscribe via
www.oemus.com/abo

 **Subscribe now!**

I would like to subscribe to **laser** international magazine of laser dentistry (4 issues per year) for €44 including shipping and VAT for German customers; €46 including shipping and VAT for customers outside of Germany unless a written cancellation is sent within 14 days of the receipt of the trial subscription. The subscription will be renewed automatically every year until a written cancellation is sent to OEMUS MEDIA AG, Holbeinstr. 29, 04229 Leipzig, Germany, six weeks prior to the renewal date.

▶ **Reply** via Fax to +49 341 48474-290 to OEMUS MEDIA AG or via E-mail to grasse@oemus-media.de

Last Name, First Name

Company

Street

ZIP/City/County

E-mail

Signature


Notice of revocation: I am able to revoke the subscription within 14 days after my order by sending a written cancellation to OEMUS MEDIA AG, Holbeinstr. 29, 04229 Leipzig, Germany.

Signature

The Dual Wavelength *waterlase***iPlus*™

Advancing Laser Technology to Its Ultimate

*i*NCOMPARABLE ACCESS & FIELD OF VISION



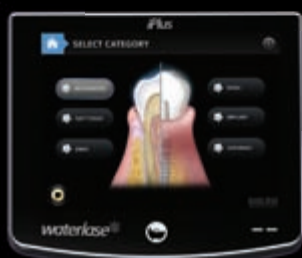- ⊕ No Pain, Therefore No Shot Necessary
- ⊕ No Micro-fractures or Thermal Damage
- ⊕ No Cross Contamination as with Burr
- ⊕ Best Ergonomic & Smallest Design

*i*NCREDIBLE POWER



- ⊕ Cutting Speed that Surpasses the High Speed Handpiece and Any Other Dental Laser on the Market
- ⊕ Cuts Faster and More Efficiently than Lasers with More Power Watts
- ⊕ Combines 0.5-10 Watts Power with 100 Hz & Short Pulse for 600 mJ of Laser Energy
- ⊕ Patented Laser Technology

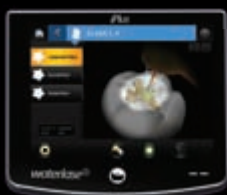*i*NTUITIVE GRAPHICAL USER INTERFACE



- ⊕ Step 1: Application

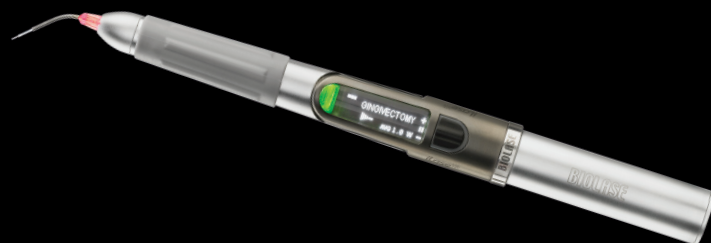

- ⊕ Step 2: Procedure



- ⊕ Step 3: No Shot/No Drill

*i*LASE 940nm DIODE LASER

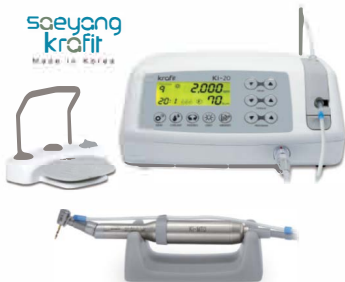

- ⊕ 5 Watts of Power with ComfortPulse
- ⊕ Handheld & Ergonomic
- ⊕ Battery Operated with Finger Switch Activation
- ⊕ Proprietary Multi-diameter/Length Bendable Tips
- ⊕ Single Use for NO Cross Contamination

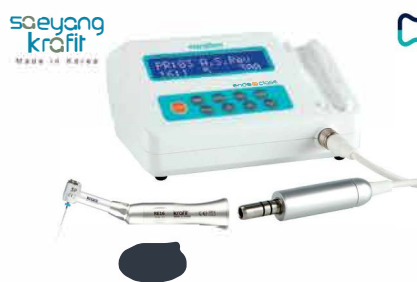



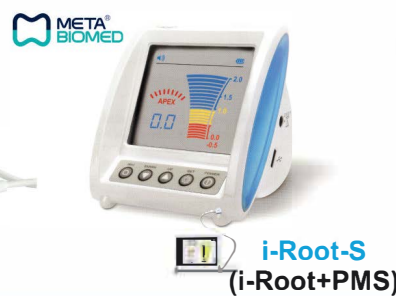KI-20 (Optic)



Endo E Class



i-ROOTS



EQ-V

