





www.azadmed.com



 azaadtejaratpars

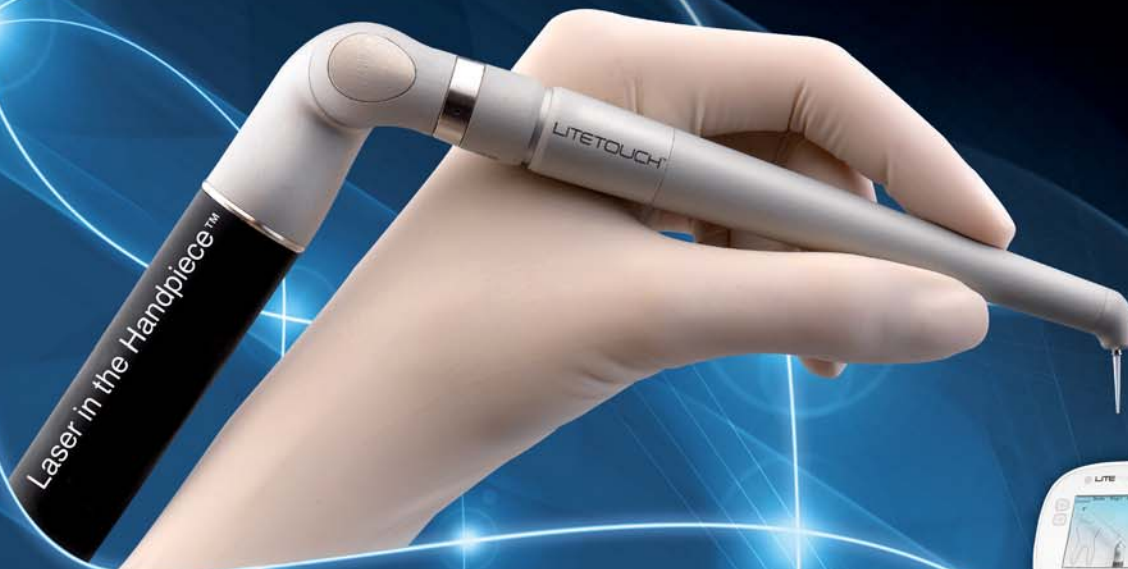 @azadmed2

 88 98 80 63 - 6

laser

international magazine of laser dentistry

4²⁰¹¹



| research

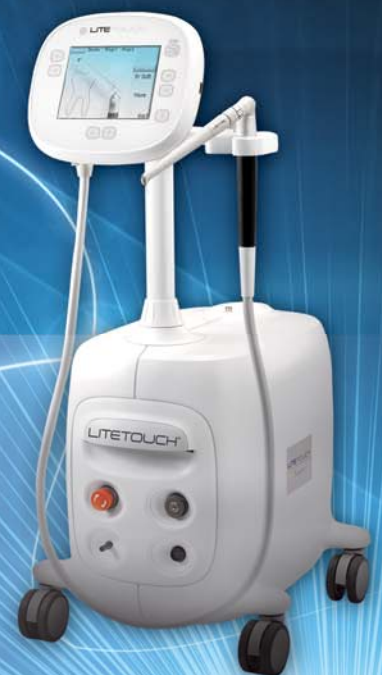Treatment of gingival hyper-pigmentation with the Er,Cr:YSGG laser

| case report

Smile enhancement with laser technology — Predictable and esthetic

| education

Start of the new Master of Science course Lasers in Dentistry at RWTH Aachen University



د ٤٧٧١١٣

Preserved collagen fibrils
of the intertubular dentin
at the entrances to the
dentinal tubules.

The universe at your fingertips.



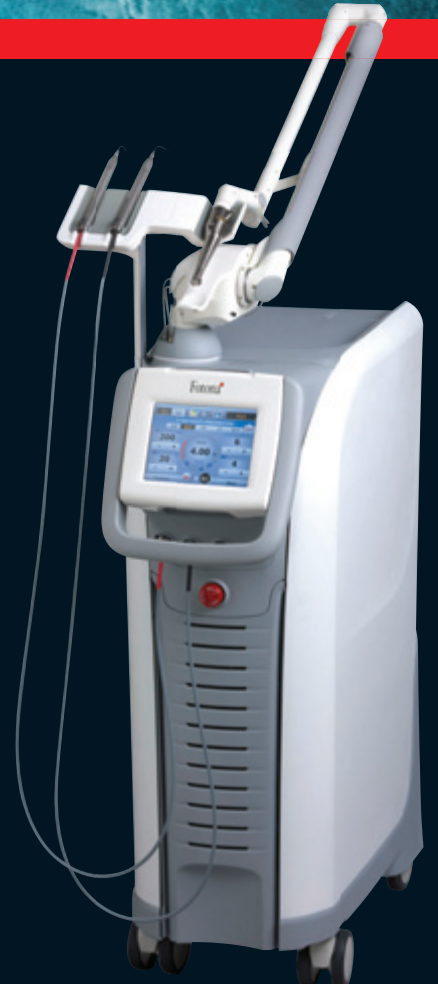LightWalker®

LightWalker TwinLight™ Treatment Concept

- Dentistry's two best wavelengths in one system: Nd:YAG and Er:YAG
- Optimum use of the unique laser-tissue interaction characteristics of each wavelength
- Nd:YAG is superior for coagulation and deep disinfection
- Er:YAG is uniquely efficient at ablating hard and soft tissues
- Dual wavelength procedures dramatically improve the outcome of treatments
- Maximum safety and efficacy

Fotona
choose perfection

Visit www.lightwalkerlaser.com today!



www.fotona.com

88897100

Under the **laser** **light tree!**



Prof Dr Norbert Gutknecht
WFLD President
Editor-in-Chief

_The year 2011 was full with a numerous of highlights.

Depending on the regional cultures and customs, the christmas trees are differently adorned. A big variation of different light sources are found all around it, generating varying pleasant impressions of all kinds.

Looking at our "Laser Light Tree", the year 2011 generated a number of new laser light sources and laser light combination in medical and dental devices generating varying pleasant treatment methods. Presents under the Christmas trees can be compared with the different conference meetings, exhibitions, and congresses such as IDS, WFLD-ED and a number of national meetings.

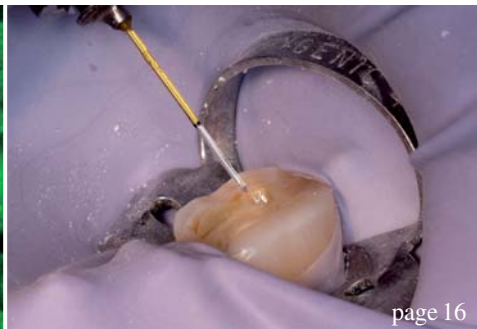
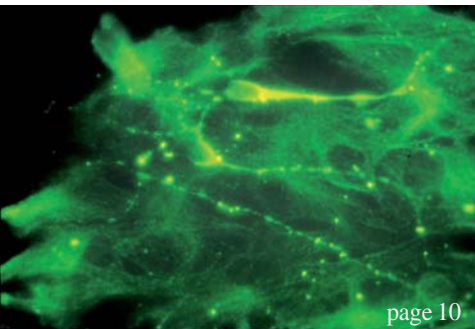
All we can say—it was a rich and enlightening year.

Now, the year 2012 is just around the corner, triggering special expectations. For sure, the WFLD congress in Barcelona will be the highlight in laser dentistry in the upcoming year 2012, where participants from all around the world will share their experiences and knowledge in their fields of expertise.

Looking forward to meet you in Barcelona I wish you all a Merry Christmas and a Happy New Year.

A handwritten signature in black ink, appearing to read 'Gutknecht', written in a cursive style.

Prof Dr Norbert Gutknecht
Editor-in-Chief



| editorial

- 03 Under the **laser light tree!**
| Prof Dr Norbert Gutknecht

| research

- 06 Treatment of gingival **hyper-pigmentation** with the Er,Cr:YSGG laser
| Dr Gizem Berk *et al.*
- 10 **Some aspects** of the use of the Nd:YAG laser in periodontal therapy
| Dr Talat Qadri *et al.*

| overview

- 16 Laser-assisted dentistry in the **daily office routine:** A “multi-wave” concept
| Dr Kresimir Simunovic *et al.*

| case report

- 22 Smile enhancement with laser technology—**Predictable and esthetic**
| Dr Hugh Flax
- 26 **Papillon-Lefèvre** syndrome
| Dr Maziar Mir *et al.*

| user report

- 30 Er,Cr:YSGG laser for **cavity** preparation
| Dr Ralf Borchers

| industry report

- 32 The use of the Er:YAG in laser-assisted **periodontal surgery**
| Dr Avi Reyhanian

- 36 Laser in **daily practice** use
| Prof Dr Frank Liebaug *et al.*

| meetings

- 39 **International** events 2012
- 40 Laser’s rightful place in **modern dentistry**
| Jürgen Isbaner

| education

- 42 Fascination of **Laser Dentistry**
- 44 **Graduation** of the first Mastership Course of AALZ Greece
| Dr Dimitris Strakas
- 46 Start of the new **Master of Science** course in Aachen
| Dajana Klöckner

| news

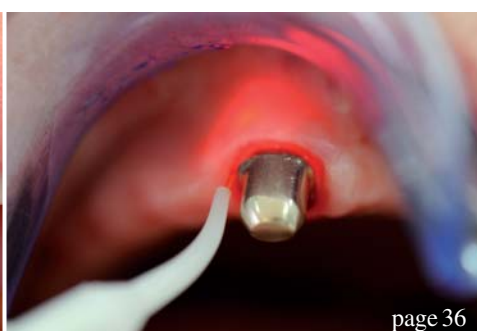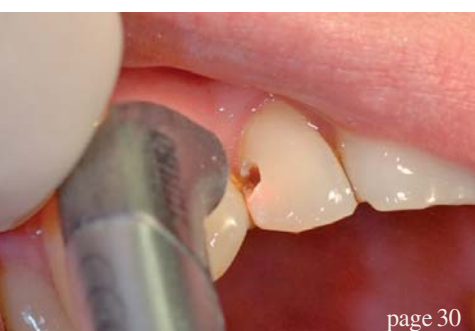- 48 **Manufacturer** News

| about the publisher

- 50 | imprint



Cover image courtesy of Syneron Dental Lasers, www.synerondental.com.
Artwork by Sarah Fuhrmann, Oemus Media AG.



*Express
your mastery*

Join the fast growing success of Syneron Dental Lasers

Presenting

LITETOUCH™

The unique fiber-free Er:YAG laser

Dentists' **1st** Choice
for hard and soft tissue procedures

To explore cooperation opportunities please contact dental@syneron.com
W W W . S Y N E R O N D E N T A L . C O M



Syneron™
DENTAL LASERS

Treatment of gingival hyper-pigmentation with the Er,Cr:YSGG laser

Clinical observation and one-year follow-up

Authors_Drs Gizem Berk, Kubra Atici & Nuket Berk, Turkey

Introduction

The colour of the gingiva is determined by several factors, including the number and size of blood vessels, epithelial thickness, quantity of keratinisation and pigments within the epithelium. Melanin, carotene, reduced haemoglobin and oxyhaemoglobin are main pigments contributing to the normal colour of the oral mucosa.¹ Frequently, the gingival hyper-pigmentation is caused by excessive melanin deposits mainly located in the basal and supra-basal cell layers of the epithelium.²

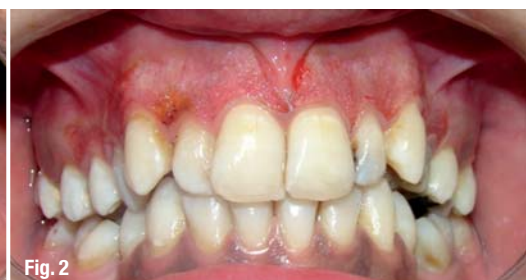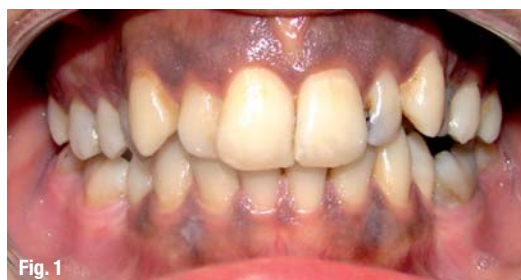Melanin is produced by specific cells—melanocytes residing in the basal layer—and is transferred to the basal cells, where it is stored in the form of melanosomes. It can also be found in keratinocytes of gingival epithelium.³

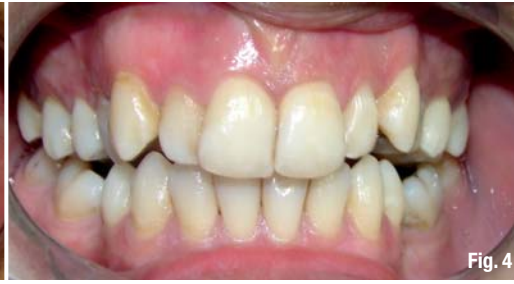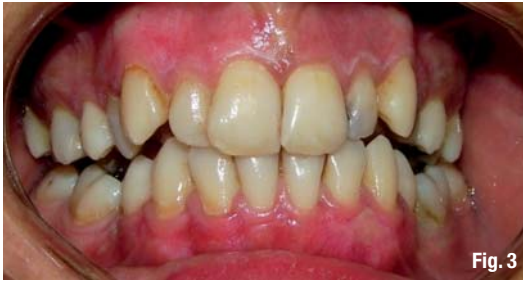Melanin hyper-pigmented gingiva is an aesthetic problem for many individuals, particularly if the hyper-pigmentation is on the facial aspect of gingiva and visible during smiling and speech, es-

pecially those with gummy smiles.² The degree of pigmentation depends on a variety of factors, particularly the activity of melanocytes. Fair-skinned individuals are very likely to have non-pigmented gingival, but in darker-skinned persons, the chance of having pigmented gingiva is extremely high. The highest rate of gingival pigmentation has been observed in the area of incisors. The rate decreases considerably in the posterior regions.⁴

Gingival depigmentation has been carried out using surgical, chemical, electrosurgical and cryosurgical procedures.^{2, 5} Recently, laser ablation has been recognised as one of the most effective, pleasant and reliable techniques.⁵ Many laser systems such as Q-switched ruby laser, flash-lamp pumped-dye laser, argon laser, CO₂ laser, Nd:YAG laser and Er:YAG laser have been used for skin pigmentation.^{1, 2, 5}

In the late 1990s, the Er,Cr:YSGG laser with a wavelength of 2,780 nm, frequency of 10 to 50 Hz, and pulse energy between 0 and 300 mJ was introduced as a safe and efficient wavelength to be





used on hard and soft periodontal tissues, supported by several published studies regarding its beneficial effect in periodontal treatment.^{6,7}

Re-pigmentation after gingival depigmentation is an important point of which clinicians should be aware. Reports of re-pigmentation are quite limited and varied.¹

The following case shows successful depigmentation using an Er,Cr:YSGG laser and results regarding re-pigmentation obtained after a one-year follow-up period.

Case report

A 29-year-old female, Turkish patient presented to our clinic who was not happy with her smile and aesthetic appearance owing to the pigmented regions, most pronounced in the anterior region. She had extensive pigmentation on her maxillary gingiva and moderate pigmentation on her mandibular gingiva (Fig. 1). The colour of the gingiva was dark to black. There was no contributory medical problem. The patient was very fearful of dental injections.

Preoperative pictures were taken and topical anaesthetic gel applied to the operatory field. In compliance with FDA rules, patient and staff used special eyeglasses for protection.

Er,Cr:YSGG laser application started with 600 sapphire tips (MG6, 6 mm) with 20 Hz, 140 μ s pulse duration (H mode) and 1.5 W, 20% air and 15% water in non-contact mode, about 1.5 mm away from

the tissue and with a sweeping motion localised only on the pigmented regions. The procedure was performed in a cervico-apical direction on all pigmented areas. After slight removal of the connective tissue, the setting was changed to 1.75 W, 40% air and 5% water in order to obtain more rapid ablation with less haemorrhaging but without thermal damage to the tissue.

Every five minutes, the operation field was wiped with sterile gauze soaked in 1% normal saline solution. The depigmentation procedure continued until no visible pigments remained. The complete treatment was performed in 30 min.

After wiping of the operative fields for the last time, there was slight bleeding (Fig. 2).

No periodontal pack or additional material was applied to support the healing procedure.

The patient was recalled 24 hours, four days and seven days later and intra-oral pictures were taken (Fig. 3).

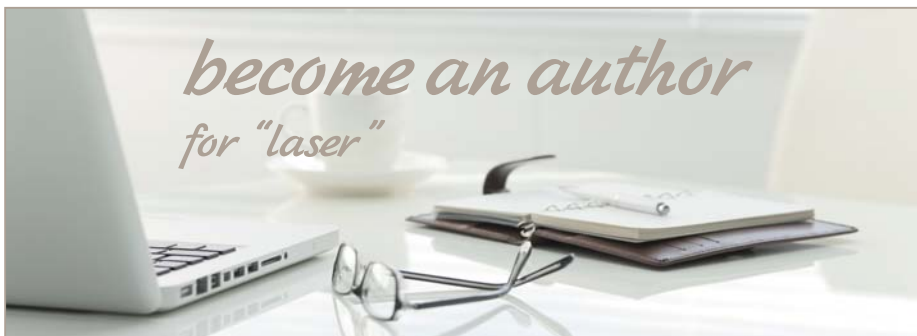The patient was instructed to avoid smoking, alcohol, acidic beverages, and hot and spicy foods. He was advised to keep his wound area clean by brushing with a soft brush for the first week. No analgesic was prescribed.

Clinical results

After 24 hours, the lased gingiva was partly covered with a thin layer of fibrin, which exfoliated during the first week after treatment. The ablated



AD



Please contact Dajana Mischke
 ✉ d.mischke@oemus-media.de

wound was healed almost completely after four days. The colour of ablated gingiva was pink and healthy four days after ablation. The gingiva was visually similar to the normal untreated gingiva, completely without melanin pigmentation.

On the fourth day post-operatively, the patient was asked whether she had had any pain or discomfort within the past four days. She revealed that she had had a slight sensitivity on her maxilla about twelve hours post-operatively but did not need any medications and this did not cause any change in her usual routine. The patient was recalled six months and one year later, and intra-oral pictures were taken again (Fig. 4).

Discussion

Numerous authors have reported successful results for the use of the lasers in hard and soft tissue applications. They include procedures common to oral surgery, oral pathology, restorative dentistry and periodontics.⁶⁻⁹ There is abundant evidence that confirms markedly less bleeding, particularly of highly vascular oral tissues with laser surgery. Anecdotal reports that incising oral soft tissue with a laser is less painful than using a scalpel and therefore requires less oral aesthetic have no scientific confirmation to date.¹⁰ In our study, topical aesthetic gel was applied, but no infiltration anaesthetic was used and we observed less bleeding during laser therapy compared with conventional surgical techniques. Post-operative pain from oral and otolaryngological surgical procedures has been claimed to be reduced in laser surgery. It is theorised that this may be due to protein coagulum that is formed on the wound surface, thereby acting as a biological wound dressing^{10,11} and sealing the ends of the sensory nerves.¹² In the present study, patient satisfaction was high. There was no complaint of pain during treatment or post-operatively.

Some reports suggest that laser-created wounds heal more quickly and produce less scar tissue than conventional scalpel surgery.^{13,14} In contrast, some studies have shown the delay of re-epithelisation of the laser wound compared with conventional wounds.^{15,16} In our report about depigmentation treatment with the Er,Cr:YSGG laser, re-epithelisation was completed after seven days and the gingiva was similar to the normal untreated gingiva.

Re-pigmentation after depigmentation has been reported following the use of different techniques. The mechanism of re-pigmentation is not understood but according to the migration theory, active melanocytes from the adjacent pigmented

tissues migrate to treated areas, causing re-pigmentation.¹⁷ Dummett and Bolden¹⁸ observed partial recurrence of hyper-pigmentation in six out of eight patients after gingivectomy at one to four months, whereas Perlmutter and Tal¹⁷ described partial recurrence after seven to eight years. Tal *et al.*¹⁹ and Tal²⁰ did not observe re-pigmentation until 20 months after cryosurgical depigmentation. No recurrence of hyper-pigmentation was found in any of the four patients treated by Atsawasuwana *et al.*² at 11 to 13 months after gingival depigmentation using the Nd:YAG laser. Nakamura *et al.*²¹ reported depigmentation with the CO₂ laser in ten patients. No re-pigmentation was seen in the first year, but four patients showed re-pigmentation at 24 months. Tal *et al.*¹ observed no re-pigmentation in any of the patients treated with the Er:YAG laser after six months.

In the present study, re-pigmentation was not observed during a one-year follow-up period. However, long-term observations are required to determine the efficiency of the Er,Cr:YSGG laser in hyper-pigmentation treatment.

Conclusion

Treatment of gingival hyper-pigmentation by Er,Cr:YSGG laser radiation in a defocused mode was found to be a safe and effective procedure. Post-operative patient satisfaction in terms of aesthetic and pain was impressive. The gingiva healed uneventfully and completely regenerated with no infection, pain, swelling or scarring. No re-pigmentation had occurred after one year post-surgery. Based on these observations, the Er,Cr:YSGG laser is a good treatment choice for gingival hyper-pigmentation.

Editorial note: A list of references is available from the publisher.

_contact	laser
<p>Dr Gizem Berk Denta Form Health Center Mahatma Gandhi Cad. No. 34 06700 G.O.P. Ankara, Turkey</p> <p>Tel.: +90 312 4476090 Fax: +90 312 4462782</p> <p>gizemberk@yahoo.com www.dentaform.com.tr</p>	

**Lay the Foundations to your
successful Future now!**

New course: 17-22 February 2012, Aachen Dental University College, Dubai



Mastership Curriculum Laser Therapy in Dentistry

- One year clinical Certification Course
- Use of different laser systems in skilltraining and practical sessions.
Practical instruction on laser handling and their subsequent practical use
- Live operations on patients or via direct monitor transfer
- Training to become a certified Laser Safety Officer is part of the course
- An internet based e-learning environment supports the participants for the home study

Module I

Laser Safety (LSO)
Laser Construction

2 Days

Module II

Diode-Lasers
Photo-Dynamic Therapy

4 Days

Module III

Er:YAG-Lasers
Er,Cr:YSGG-Lasers

4 Days

Module IV

Written Exam,
Presentation of clinical cases

2 Days



Aachen Dental Laser Center

More information:

AALZ GmbH · Pauwelsstrasse 17 · 52074 Aachen · Germany
Tel. +49 - 2 41 - 47 57 13 10 · Fax +49 - 2 41 - 47 57 13 29
www.aalz.de · info@aalz.de



Some aspects of the use of the Nd:YAG laser in periodontal therapy

Authors_Drs Talat Qadri & Jan Tunér, Sweden

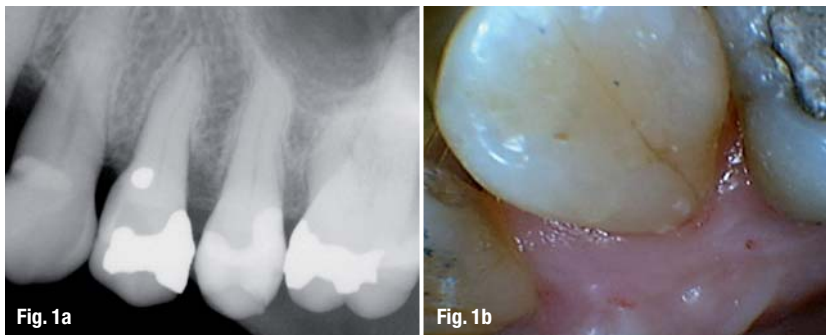

Fig. 1a

Fig. 1b

Fig. 1a_X-ray.

Fig. 1b_The situation before treatment.

Introduction

Moderate forms of periodontitis are demonstrated in 50 to 90% of adults with regional and age-based differences. Periodontitis destroys the integrity of oral mucous membranes and is one of the main reasons for tooth loss, especially amongst people aged 40 and older. Aggressive forms of periodontitis may result in advanced loss of periodontal attachment and alveolar bone, resulting in urgent need for prosthetic treatment for those individuals within a very short time. The presence of bacteria in the gingival sulcus and periodontal tissues is a determining factor of the development of periodontal disease. The

Fig. 1c_After creating the funnel.

Fig. 1d_The post-op situation.

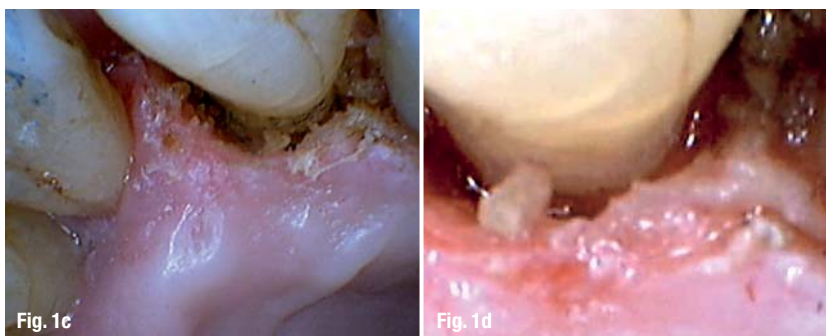


Fig. 1c

Fig. 1d

conventional periodontal therapy aims to suppress inflammatory signs and pathogenic bacteria. This therapy consists of root scaling and planing, whether associated with antibiotic chemotherapy or not. In areas of different access such as the furcations, invaginations and concavities, the use of manual curettes or ultrasound does not ensure the eradication of periopathogenic bacteria and the success of treatment. Moreover, the increase of strains capable of resisting antibiotic chemotherapy may also damage the efficacy of conventional periodontal treatment. Based on these facts, alternative methods are being studied with the aim of achieving a more efficient therapy with more predictable prognosis. In this regard, lasers have become an interesting adjuvant therapy with promising results. The scientific base for this approach to treating periodontitis is still not entirely evidence based and more studies are needed to determine its effectiveness and optimal parameters. The present article will provide a summary of our experiences and the outcome of four clinical studies.

The dental Nd:YAG laser

Modern dental Nd:YAG lasers are free running and pulsed as opposed to other continuous wave lasers with gated pulse options. The ablation ability is set either by increasing the output power or the pulse repetition rate. The therapy is performed in tissue contact and in constant motion.

For pulsed lasers, peak power has an order of magnitude higher than an average power. There are very high spikes, with peak power being 1,000 times higher than average power, and relatively long rest periods. Pulse width (the amount of time for each pulse) varies from 90 to 1,200 microseconds in different pulsed Nd:YAG lasers and is an important component of this




Fig. 2




Fig. 3a



Fig. 3b

technology. The short duration allows for a long resting time, which sometimes obviates the need for local anaesthesia. The number of pulses (frequency, pulse repetition rate) per second is one of the crucial factors in pulsed Nd:YAG lasers. With a high repetition rate of 10 to 100 Hz in different devices, one can achieve smoother cutting at a very low power setting because the peak power in each pulse can be very high (White *et al.* 1994).

The 1,064 nm wavelength is invisible, which makes the evaluation of the actual effected area difficult. Seen through an infra-red camera, it is obvious that the light is spread like a small ball over a rather large area and not just around the fibre tip.

The Nd:YAG laser energy is absorbed by tissue and it is this absorbance that allows surgical excision and coagulation of tissue. The absorption in different dental tissues shows a low absorption and a moderate absorption for hydroxyapatite. The ablative effect of this wavelength on hard dental tissue is obviously rather low. Its wavelength has a particular affinity for melanin or other dark pigments. Therefore, microbes with dark pigment are more sensitive to this laser. These microbes can be eliminated at rather low power settings at which there will be no collateral damage to the adjacent tissue. The choice of wavelength is important when it comes to bactericidal effect.

Harris (2004) aimed to develop a method for quantifying the efficacy of ablation of *Porphyromonas gingivalis* *in vitro* with two different lasers. The ablation thresholds for the two lasers were compared in the following manner. "The energy density was measured as a function of distance from the output of the fibre-optic delivery system. *P. gingivalis* cultures were grown on blood agar plates under standard anaerobic conditions. Blood agar provides an approximation of gingival tissue for the wavelengths tested in having haemoglobin as a primary absorber. Single pulses of laser energy were delivered to *P. gingivalis* colonies and the energy density was increased until the appearance of a small plume was observed coincident with a laser pulse. The energy density at this point de-

fines the ablation threshold. Ablation thresholds for a single pulse were determined for both *P. gingivalis* and for blood agar alone. The large difference in ablation thresholds between the pigmented pathogen and the host matrix for pulsed-Nd:YAG indicated a significant therapeutic ratio and *P. gingivalis* was ablated without visible effect on the blood agar. Near threshold, the 810 nm diode laser destroyed both the pathogen and the gel. The pulsed Nd:YAG, however, may selectively destroy pigmented pathogens, leaving the surrounding tissue intact. The 810 nm diode laser may not demonstrate this selectivity owing to its longer pulse length and greater absorption by haemoglobin" (Harris 2004).

Which microbes are eliminated?

It is postulated that the Nd:YAG laser eliminates primarily the dark-pigmented microbes, such as *P. gingivalis*, whereas *Aggregatibacter actinomycetemcomitans*, having no pigments, would not be similarly reduced. However, in Andrade *et al.* (2008) *A. actinomycetemcomitans* was eliminated directly after irradiation, but regained approximately 50% of the baseline level after six weeks. Such recurrence is reported in several studies and is attributed to cross-contamination from non-treated pockets and/or saliva (Teughels *et al.* 2000). *A. actinomycetemcomitans* is found in 90% of all cases of juvenile periodontitis but only in 50% of adult chronic periodontitis (Slots *et al.* 1980). *P. gingivalis* is reported to be aggregated with other periodontal pathogens, such as *Prevotella intermedia* so light absorption into the dark pigment of *P. gingivalis* is likely to cause consid-

Fig. 2 Lateral distribution of the light.

Figs. 3a-d The fibre with water cooling, easy to clean (3a-b) and without water cooling (3c-d).

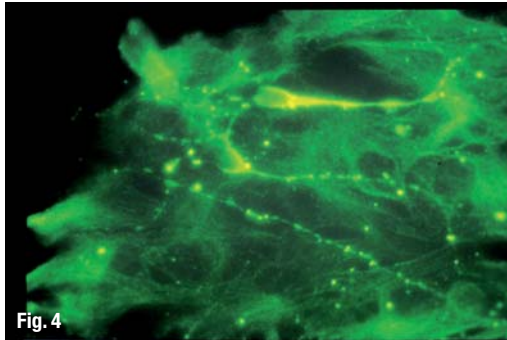


Fig. 3c



Fig. 3d

Fig. 4 Varicosity formation in the axons. (Courtesy of Ambrose Chan, Australia)



erable collateral damage to other microbes. Therefore, it appears that the Nd:YAG laser has a promising potential in eliminating the majority of the microbes in the pocket's soft tissue.

The use of water-cooling

Negative thermal effects of the Nd:YAG laser have been reported in *in vitro* studies (Liu *et al.* 1999; Israel *et al.* 1997). However, *in vivo* effects on the root surface and the pulp are not well documented (Gaspirc & Skaleric 2001; Schwarz *et al.* 2008). The effect of laser irradiation on the surrounding tissues is influenced by parameters such as power, pulse, fibre size, fibre angulations and cooling/no cooling. White *et al.* (1994) suggest that powers between 0.3 and 3.0 W should not cause a damaging rise in intrapulpal temperature. Likewise, Gold and Vilardi (1994) and Spencer *et al.* (1996) also report that the use of laser at 4 W is safe and does not damage the root surface. The use of water-cooling is not standard in dentistry. In our experience, the cooling further reduces the risk of local carbonisation with the following increased absorption and unwanted tissue destruction. In spite of the use of 3 W in our studies, the speed of operation was still satisfactory and no carbonisation was observed. The advantage of using water is also relevant as described above for the accumulation of carbonised tissue on the probe, as described below.

Fig. 5a Example of the use of Nd:YAG tissue ablation using only Xylocaine ointment immediately before treatment.

Fig. 5b The post-op situation.

Fig. 5c One week post-op.

It is essential to understand that the effect of the Nd:YAG is not based upon heating, but upon selective absorption in the tissue. Electrocautery, on the

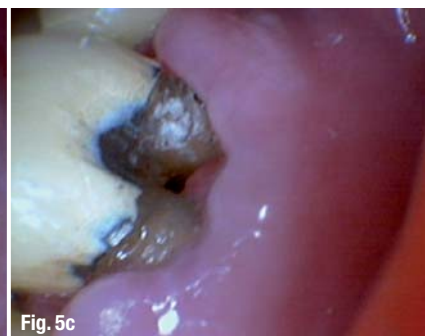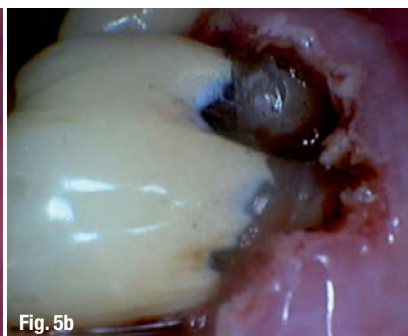
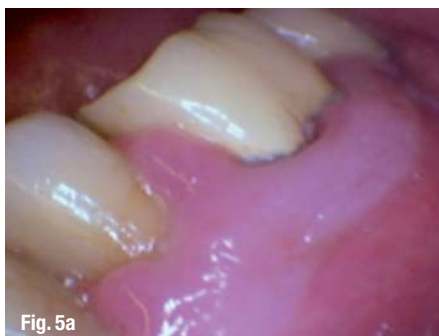other hand, causes uncontrolled tissue necrosis and non-selective effects on microbes. Adding water-cooling to the electrocauter is not standard procedure, but by doing so, the cutting effect is slower but carbonisation is reduced and post-operative healing is improved.

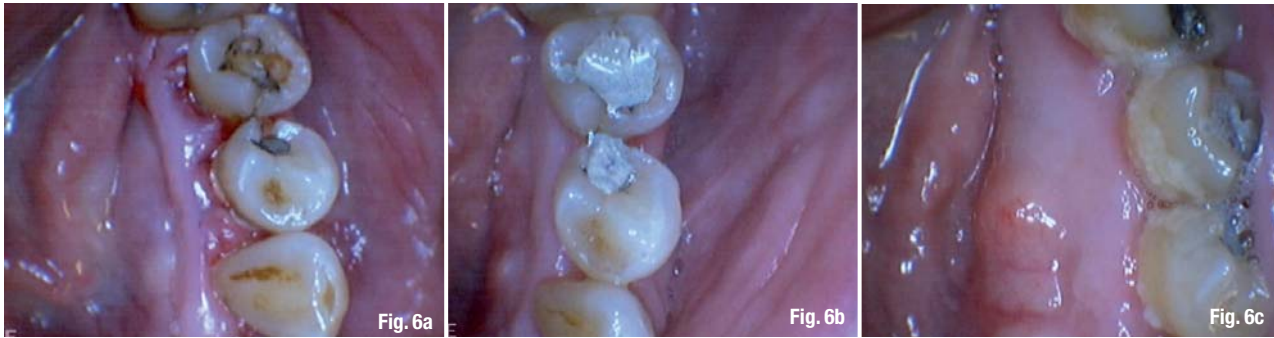Dental calculus

It has been postulated that the use of Nd:YAG laser prior to SRP softens the calculus deposits and makes conventional SRP easier. However, the marginal benefit of this procedure probably does not compensate for the potential damage to the root surface. On the other hand, the use of the Nd:YAG laser can be compared to open flap surgery. By removing the epithelial lining and widening the access to the root surface, calculus deposits are made visible and can therefore be removed conventionally with greater accuracy. The photographs above illustrate this possibility (Figs. 1a & d). The advantage of this technique is obvious, since there is no need for anaesthesia other than topical anaesthesia occasionally, there is no bleeding, and no need for sutures or re-appointment to remove the sutures. In addition, there is less post-operative pain and oedema. The laser irradiation itself creates an anaesthetic period of up to 24 hours, after which the patient experiences some tenderness in the area. In short, this is a cost-effective procedure with benefits for the operator and the patient.

The technique

Several techniques have been proposed. In our own studies (Qadri *et al.* 2008, 2010), a 600 µm fibre was used in contact with the soft tissue only, in constant motion and with water-cooling. To be able to compare the effect with SRP, both sides of the mouth were treated by SRP before the Nd:YAG was used as an adjunct treatment. Clinically, we prefer a different approach. The pocket epithelial lining is first removed with the fibre at an angle of approximately 30°, avoiding contact with the root. This approach creates a funnel-like shape of the pocket with a reduction of the pocket depth by a few mil-





limetres. Once this has been done, the pocket is open for inspection, with no or little bleeding, and SRP can be performed with excellent visual control.

The characteristics of different Nd:YAG fibres

Most bare fibres consist of a glass rod core made of silica quartz with an outer surface cladding that has a different refractive index from that of the silica-quartz fibre, and an outer protective vinyl jacket. The standard options are diameters ranging from 200 to 600 μm . As the fibre diameter decreases, the energy densities increase and fibre flexibility increases. Thin fibres are popular for non-contact irradiation because of the high power density but less than ideal for closed curettage, because they are too prone to fracture and the energy density is too high. The energy density of a 300 μm fibre is four times as high as that of a 600 μm fibre. Thus, the use of a thin fibre in a closed area has disadvantages. The high power densities will easily cause charred areas in the pocket and sticking of carbonised tissue to the tip. In the dark carbonised areas, absorption of the light increases, and so does heat. The aim of the laser treatment is not to use the instrument as a thermo-cauter but to take advantage of the interaction between the light and the specific tissue targeted. Further to that, a thicker diameter makes the fibre stronger and difficult-to-reach areas can more comfortably be accessed.

Figure 2 shows the distribution of the light at the fibre tip. As can be seen, the light is not only distributed along the axis of the fibre, but also to a considerable degree to the lateral sides. This is illustrated by the plume of smoke caused by the lateral spread of the beam and only occurring in pigmented (dark) structures.

During treatment, the fibre has to be cleaned and cut frequently. The output at the tip can be reduced by more than 50% after being used around a single tooth. By using water-cooling, there will be less carbonised tissue in the pocket epithelium and less on the fibre as well. The debris sticking to the fibre will

also be easier to remove (Figs. 3a & b). Further to that, the fibre should be kept in constant motion during therapy. The cutting capacity of the fibre is greater when in motion than in a stationary position.

Nd:YAG, which has little absorption in water, may be effectively cooled with simultaneous air and water spray. Several studies have confirmed that application of an air and water spray provides adequate heat protection of the pulp, comparable with cooling of the conventional rotary bur (Miserendino *et al.* 1994).

Nd:YAG laser and pain perception

A major advantage of Nd:YAG laser periodontal therapy is that the procedure is more or less pain free. From the patient's point of view, this is certainly the major aspect. The degree of pain is largely related to the skill of the operator. Still, an anaesthetic gel is required in some cases during the initial phase of the surgery. After a while, it seems that the laser in itself provides an anaesthetic effect. The prolonged anaesthetic effect and the reduced trauma make compliance with post-operative home care easier.

When performing sulcular debridement with the laser around hypersensitive teeth, there is sometimes a pain reaction. In these cases, the tooth crown can be irradiated from a short distance without water until the pulp has been anaesthetised. For the same obvious reason, no water should be used when conventional hypersensitive tooth necks are treated with Nd:YAG laser. In combination with water, the area will be cleaned and the tubules will be even more open. Without water, they may be sealed.

The anaesthetic effect of the Nd:YAG laser is not fully understood, but *in vitro* studies have shown that Nd:YAG and 808 nm therapeutic lasers give rise to transient nodules along the axons, possibly slowing down nerve conduction. Figure 4 shows these varicosities after Nd:YAG irradiation of axons *in vitro*.

In general, it can be stated that the lasers themselves are not dangerous or damaging. It is the lack

Fig. 6a–c Nd:YAG treatment without anaesthesia (day of treatment, at seven weeks and at three months). Note the good condition of the gingiva at three months in spite of poor oral hygiene.

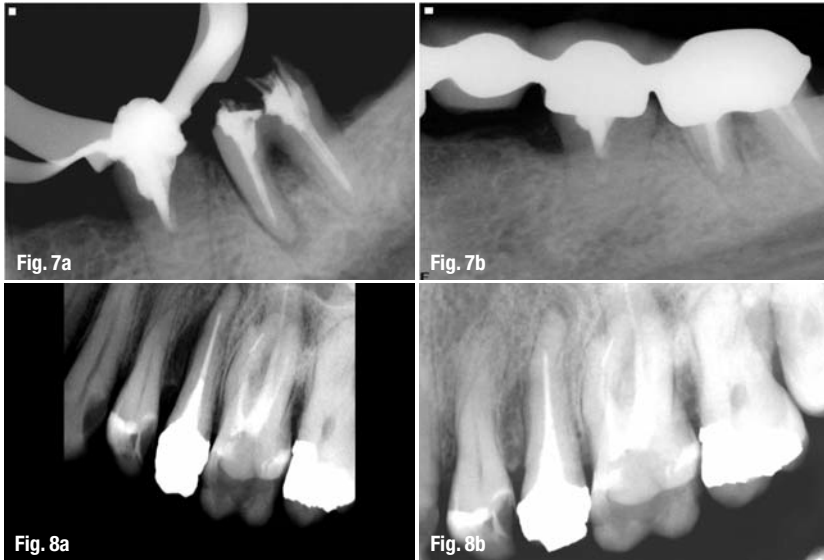

Fig. 7a_Furcation one day of treatment.
Fig. 7b_Furcation at two years.
Fig. 8a_Mesial pocket before therapy.
Fig. 8b_Mesial pocket at one year.

of knowledge that results in damage. The undesirable side effects can vary firstly with power and energy density and secondly with the type of laser used.

In summary, the advantages of the Nd:YAG laser in periodontal therapy are:

1. reduced need for local anaesthesia;
2. reduced bleeding and better visual control of the pocket;
3. local reduction of microbes in the pocket;
4. reduction of post-operative discomfort; and
5. reduction of the need for pharmaceuticals.

Nd:YAG and bone regeneration

In our long-term study (Qadri 2010), some new bone was gained. In many clinical cases, much more bone regeneration has been seen, but typically in these cases the condition has been worse than the 4+ mm pockets treated in our study. Another difference in the more successful cases is that there were several therapy sessions, while the two Nd:YAG studies that are the subject of the present article only used one single irradiation. One single session may therefore not be optimal, even though it may be quite useful. Figures 7 & 8 show some examples of bone regeneration using the Nd:YAG laser.

The therapeutic laser connection—Low-level laser therapy

While dental lasers such as the Nd:YAG and the Er:YAG are used for removal of tissue, the therapeutic lasers (also called low-level lasers and the therapy itself low-level laser therapy—LLLT) are non-thermal and cause cellular modifications through absorption in specific cellular photoreceptors, such as the cytochrome c oxidase, the terminal enzyme in the mitochondrial respiratory system. Such absorption causes a cascade of primary and secondary effects on conditions such as wound healing, oedema, inflammation, cellular proliferation and pain.

The first commercially available therapeutic laser was a helium-neon (HeNe) laser of 1 mW. The wavelength is 632.8 nm. This is a gas laser and it is rather large and fragile, and the light is distributed through a fragile optical fibre. The narrow bandwidth of this laser is believed to be an advantage, since the length of coherence increases with the narrowness of the wavelength. HeNe lasers are today not very common on the market. In the late 1990s, they were being replaced by diode lasers. This technology allowed for smaller machines and gradually also higher power. The gallium-arsenide laser has a wavelength of 904 nm and is a pulsed laser with a high peak power but an average power between 10 and 100 mW. The gallium-aluminium-arsenide laser has a wavelength of between 780 and 980 nm. Since the electrical driving system is less complicated, these lasers can be small and still offer high outputs, typically between 5 and 500 mW. Recently, HeNe lasers have begun to be replaced by semiconductor lasers containing indium gallium aluminium phosphate. Wavelengths are typically between 630 and 680 nm in the red part of the spectrum. Unlike the HeNe laser, these lasers can be small and handy and are typically in the 10 to 300 mW range.

LLLT follows the Arndt-Schultz law, which stipulates that for every substance, small doses stimulate, moderate doses inhibit, large doses kill. Here, the "killers" are the surgical lasers. There are specific dose

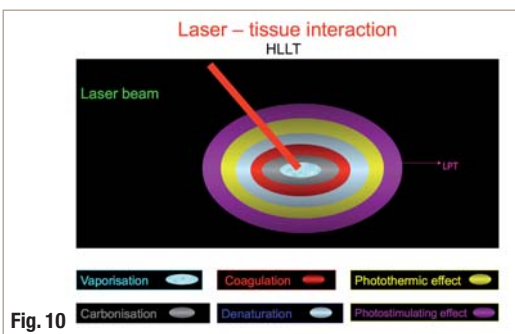
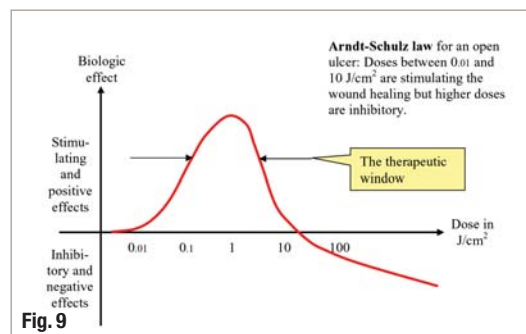


Fig. 9_The Arndt-Schultz law (Tunér & Hode 2004).
Fig. 10_Schematic illustration of the different light intensity zones. LPT is other term for LLLT. (Courtesy of Edson Nagib, Brazil)

intervals in LLLT: wound healing requires a low dose, anti-inflammatory effects 50 to 100% higher and pain-relieving effects much higher, because here an inhibition is needed. But it should be born in mind that a medium dosage aimed at the inflammatory process is also pain relieving but not immediate. A high dose will inhibit pain but will also prolong the inflammatory phase, which in itself is painful (Tunér & Hode 1998; Huang *et al.* 2009). LLLT is probably most efficient during the first week following surgery (Gerbi *et al.* 2005; Fig. 9).

_Additional bio-stimulatory effect

Bio-stimulatory effects have been confirmed using the Nd:YAG and the Er:YAG at low fluences. Thus, the Nd:YAG laser has a certain bio-stimulatory effect and this contributes to enhanced post-operative healing (Abergel *et al.* 1984; Herman & Khosla 1989; Fortuna *et al.* 2002; Vescovi *et al.* 2008). The energy densities in the most peripheral zone fall within the bio-stimulatory range, as illustrated in Figure 10. The clinical effects in periodontal therapy are described by Qadri *et al.* (2005, 2007). The current literature on the use of LLLT in periodontal therapy has been reviewed by Eduardo *et al.* (2010).

_Summary

The different parameters and techniques used in Nd:YAG periodontal work contribute to the lack of a firm evidence-based conclusion regarding the usefulness of this therapeutic modality. This article summarises our own experiences. The use of water-cooling can, in our opinion, offer several advantages. The size and colour of the fibre also affect the outcome. Further clinical studies are needed to determine the optimal parameters for each indication._

_contact

laser

Dr Talat Qadri

Department of Periodontology
Karolinska Institutet
171 77 Huddinge
Sweden


Dr Jan Tunér

Spjutvägen 11
772 32 Grängesberg
Sweden

AD

LaserHF®

Laser meets Radio Frequency



LaserHF®

Worldwide first combined Laser plus HF unit

- Pre-adjusted programs for all dental soft tissue treatments, with individual programming
- Easy handling by dual operating concept: touch-screen and automatic starting system
- Modern radio frequency surgery (2.2 MHz) allows easy, fast and precise cutting
- Diode laser (975 nm) for periodontology, endodontology and implant exposure
- Therapeutic laser (650 nm) for Low Level Laser Therapy (LLLT) and antimicrobial Photodynamic Therapy (aPDT)
- Good value of money

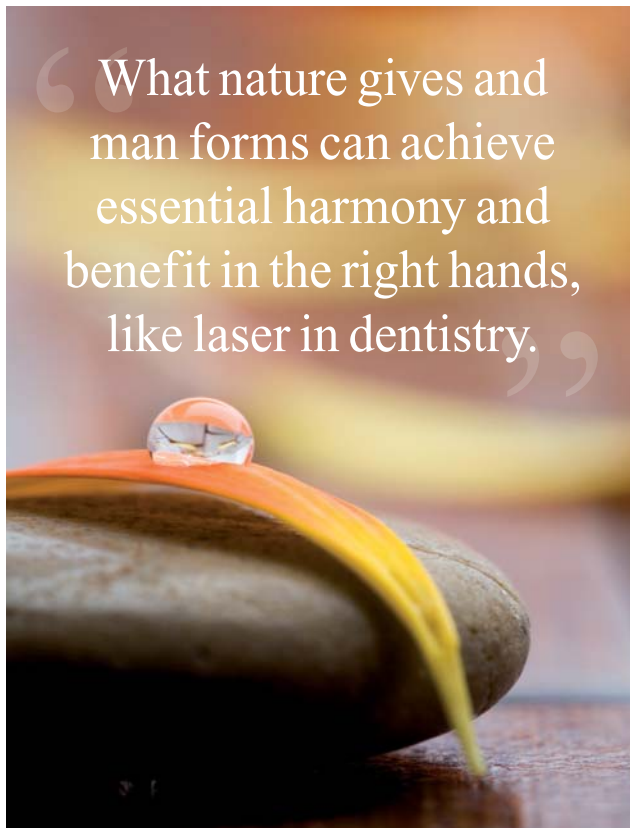
www.hagerwerken.de

Tel. +49 (203) 99269-26 · Fax +49 (203) 299283

HÄGER
WERKEN

Laser-assisted dentistry in the daily office routine: A “multi-wave” concept

Authors_Dr Kresimir Simunovic, André Scholtz, Switzerland



“What nature gives and man forms can achieve essential harmony and benefit in the right hands, like laser in dentistry.”

_Since Einstein pictured the nature of light and therefore postulated the basics of the concept of laser over almost a century ago, a long and sometimes rebellious time of experimentation elapsed before we finally witnessed a rapide and wide expansion of this instrument of light across all fields of dentistry in the new century.

At the beginning of the 1960s, Maiman developed the first laser, a ruby laser. Thus, a “solution looking for a problem” was born, then with no concrete indica-

tions. Only at the dawn of our millennium a vast range of wavelengths, pulse durations and power settings was achieved, to support safe and efficient clinical applications of lasers in dentistry today. Thus we have the privilege to be able to use the laser as an assistive or completely independent evidence-based tool in almost every field of dentistry, in terms of a multi-wave concept. In our office we classify laser-assisted dentistry into three categories, based on the focused main effect:

1. Ablation: mostly in aesthetic and operative dentistry and surgery;
2. Decontamination: mainly in endodontics, periodontology and surgery;
3. Photobiomodulation PBM as additional effect for the applications mentioned above, or as a therapy on its own, like essential bio-modulation or photodynamic therapy.

In this multi-wave concept, all three function together, unifying their basic features. We use following wavelengths in our office: 810 nm, 980 nm, 1,064 nm and 2,940 nm. This choice resulted gradually from increasing knowledge and need to expand the laser-assisted indications in our practice, based on the chart of laser-assisted dentistry by Prof Dr N. Gutknecht from the RWTH Aachen University. In dependency of the target tissue and the corresponding coefficient of absorption, we evaluate and select along the horizontal line the wavelength with the most efficient tissue interaction.

Our patients involved are given a folder of fact sheets, with a short description of any laser-assisted therapy and its benefits, which is accompanied by an individual consultation with our team on any scheduled laser therapy.

About searching and finding

Any therapy is based on diagnostics and laser-assisted diagnostics is often a patient's first exposure to laser light at a first visit, a recall check-up or during an emergency consultation.

Laser-assisted detection tools for plaque, decay, calculus and concretions are based on the direct analysis of different qualities of fluorescence on the target (DIAGNOdent pen, KaVo; VisaProof, Dürr Dental; Figs. 1 & 2). Additional laser-based diagnostic tools for objective vitality tests are based on Laser Doppler Flowmetry or the intra-oral fluorescence visualisation for detection and prevention of early mucosal alteration through reduced fluorescence from the target tissue.

The DIAGNOdent pen, VistaProof and similar detection tools are based on the spectral analysis between the quality of light emission in the green/blue wavelength area of sound enamel/dentine and the red wavelength area infected by bacterial metabolic products. The numerical and/or visual result distinguishes between the necessity of therapy or just long term monitoring of the detected spot.

Ablation

Applications in conservative/operative dentistry

Since the new generation of Er:YAG lasers allows very subtle settings for pulse duration, frequency and energy, the array of indications covers almost every possible treatment of dental hard tissue from simple fissure sealing through extended onlays, overlays, veneers to complex cases using CAD/CAM and CEREC. It is important to point out the positive and preventive side-effect

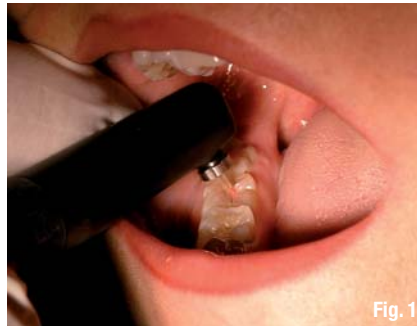

Fig. 1

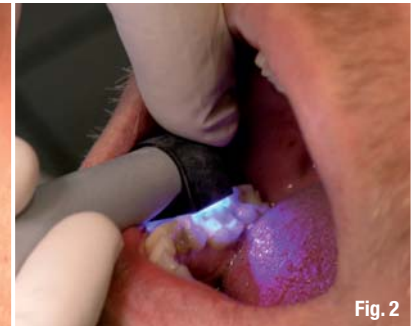

Fig. 2

of the resulting micropores after lasing, as being collecting tanks for fluoride, calcium and phosphate ions. This phenomenon optimises the enamel crystal structure, modifying carbon apatite versus hydroxyapatite and finally the stronger and essentially more resistant fluor-apatite. The removal of metal and porcelain fillings is still not an application of laser.

New pulse qualities, like the QSP (Fotona, Slovenija) allows us through an additional sophisticated tuning of each single pulse, a very precise and even more efficient ablation with very specific structural changes in the tissue and on its surfaces and borders.

Laser-assisted aesthetic dentistry

This field includes tooth bleaching, management of hard and soft tissue and lasing dental hard tissue for CAD/CAM, different ceramic crowns and any kind of resins and porcelain veneers.

Our in-office power bleaching entails laser activation of a wavelength-specific activator, developed at the University of Vienna. The powder is mixed with 25% H₂O₂ and applied to each buccal tooth surface. The ir-

Fig. 1 Detection of caries and concretions through spectral analysis and numerical differentiation between sound dental tissue, concretions and bacterial metabolic products with the DIAGNOdent pen.

Fig. 2 Imaging of plaque and caries through laser- and computer-assisted differentiation between sound enamel and contaminated dental hard tissue by bacterial by-products. In the photograph shown with the LED intra-oral camera is VistaProof.

Figs. 3-8 Partial ablation with the Er:YAG laser after earlier biopsy, removal of the second part after one week, subsequent monitoring after two to three weeks and at every recall. In the meantime, instructed self-monitoring by the patient.

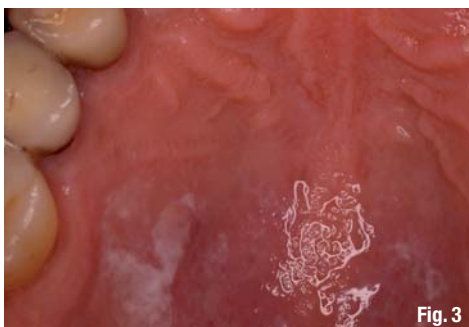

Fig. 3

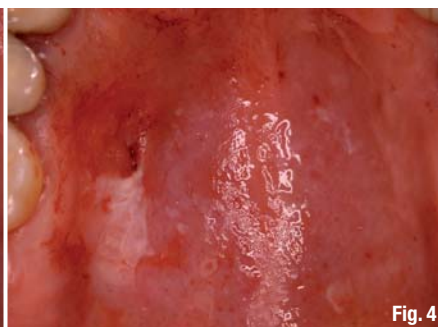


Fig. 4

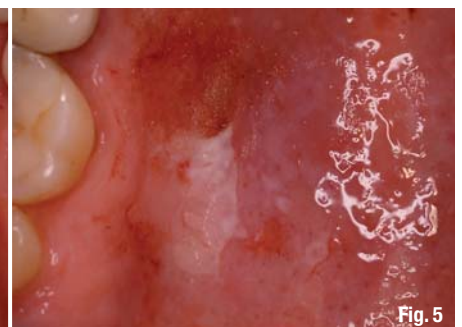

Fig. 5

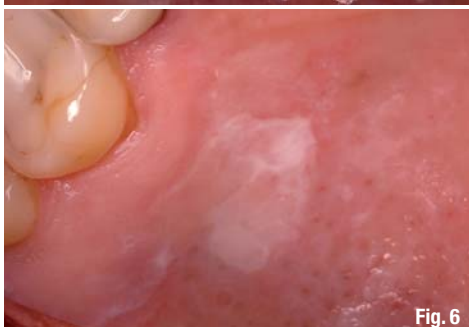

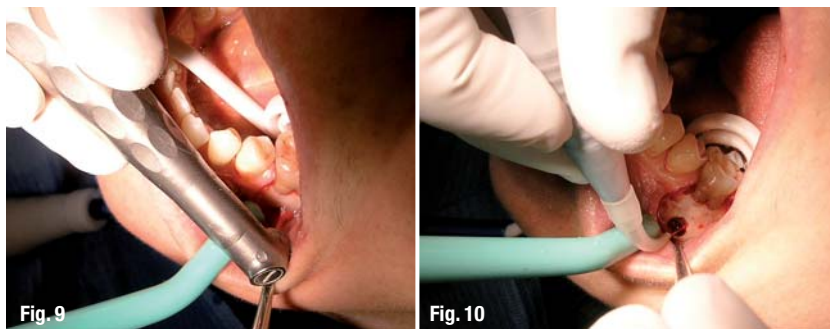
Fig. 6

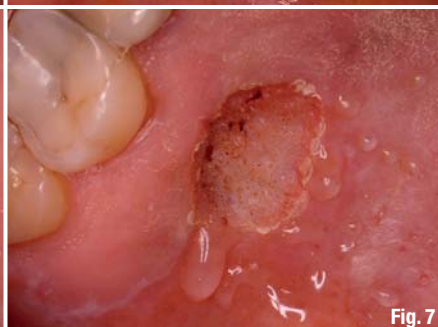

Fig. 7

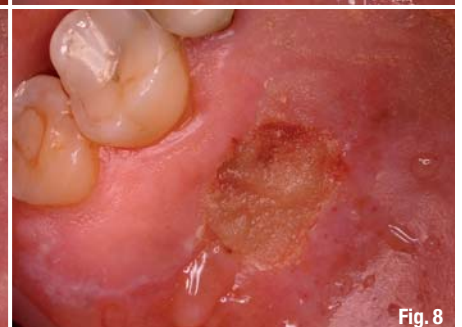

Fig. 8



Figs. 9 & 10 Buccal opening, root resection and surface modification of the peri-apical lesion on the lower left first molar with the Er:YAG laser, decontamination with the Nd:YAG laser and LLLT immediately post-op with the diode laser.

radiation time is 30 seconds, with up to three cycles per session. The redox reaction is primarily related to the specific activator and not to heat, and the presence of TiO₂ keeps the temperature rising in a medium range of 1 to 1.5 °C. No enamel surface alteration was shown on the SEM before or directly after the treatments with different wavelengths.

Modelling of soft gingival and hard bone tissue is often necessary to ensure the biological width and in aesthetic surgery as a first step to the right smile harmony.

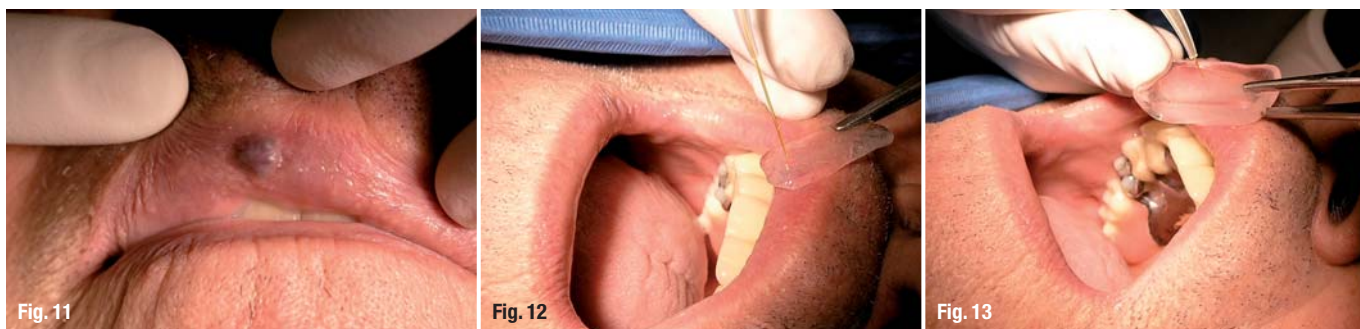Owing to the new settings, mostly of shorter or longer pulse durations, the erbium wavelength allows us to manage soft, hard and dental tissues with only one laser type and one handpiece.

Laser-assisted surgery

Oral surgery offers the widest range of indications for treatment by laser. The Er:YAG laser is the gold standard in our office for excellent handling of soft and hard tissue (Figs. 3–10), thanks to an efficient modulation of pulse duration, frequency, energy and water/air ratio.

The wavelengths of the 810 nm and 980 nm diode lasers extend the range to bio-modulation and a different laser approach to soft tissue modelling, decontamination and photodynamic therapy. The Nd:YAG laser completes the team as the wavelength for vascular lesions (Figs. 11–13), for deep decontamination, soft tissue surgery and as an alternative for the treatment of herpes and aphthae.

Figs. 11–13 Step-by-step removal of the vascular lesion on the upper lip with the Nd:YAG laser using the ice cube technique: no invasive opening, but slow inner lasing of the lesion, initiated by non-contact Nd:YAG surface scanning through ice (five-minute weekly sessions).



The Er:YAG laser is the laser of choice for a selective biological bone ablation and does not result in any classical thermal or mechanical trauma. The laser treatment results in a native, original and stress-free bone structure, allowing immediate revascularisation and initiating biological processes almost during surgery already and excellent tissue healing.

_Decontamination

Laser-assisted endodontics

Endodontics is certainly one of the most rewarding and best-investigated areas of laser-assisted evidence-based dentistry. The classic and highly efficient wavelengths of 810 nm and even stronger 1,064 nm enable a deep decontamination of the main root-canal system and the very important mosaic of lateral tubules and other anatomical variations, seen as obstacles to a successful traditional root-canal treatment or retreatment. The Nd:YAG laser decontaminates the complex anatomical root system also over the main canals, spreading its effect approximately 1.1 mm into the system, the distance of bacterial migration, allowing around 95% of effectiveness. No other wavelength and no other rinsing of any nature can attain this phenomenon of decontamination.

Owing to the pigmentation of the involved bacteria (*Enterococcus faecalis* detected as the problem germ), the bactericidal effect focuses exactly on its target, with no collateral damage to the surrounding tissue, if settings are correct. The only resulting side-effect during lasing is the scattering to lower energy levels by means of bio-modulation of the neighbourhood tissue for faster cell regeneration and good wound healing.

Our in-office protocol includes usually two to three sessions of a combined Er:YAG/Nd:YAG laser use, known actually as Twinlight Endodontic Treatment.

Thanks to new erbium quartz fibres (Preciso tip, Fotona), which allow side-firing in any area of the root walls at different depths, we are able to remove smear layer and debris selectively in combination with saline solution, to perform an initial decontamination of

42ND

INTERNATIONAL ANNUAL CONGRESS OF THE DGZI



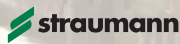
October 5–6, 2012
Hamburg//Elysee Hotel



Gold Sponsor:



Silver Sponsor:



Bronze Sponsor:



FAX REPLY

+49 341 48474-390

Please send me further information on the
42ND INTERNATIONAL ANNUAL CONGRESS
OF THE DGZI October 5–6, 2012, in Hamburg, Germany.



Office Stamp

about 0.4 mm from the main canal into the lateral root system, to bio-stimulate (fibroblasts) and to leave an ideal microstructure on the walls for a 3-D filling.

The alternative erbium quartz fibre Pips (Photon Induced Photoacoustic Streaming by M. Colonna, E. Di Vito and G. Olivi) System replaces even a part of the mechanical root canal treatment, in adjunct to all the effects already mentioned above. The Pips fibre (Fotona) is placed in the pulp chamber filled alternatively with 15 to 17% EDTA and saline solution. It entails by laser activation the production of shockwaves in direction to each root canal separately, along the anatomy from cervical to apical at very low energy settings, converting thermal energy into an athermal mechanical precise and complete debridement (Fig. 14). Both protocols are completed in our office by a final deep decontamination laterally up to 1.1 mm with the Nd:YAG laser, perform-

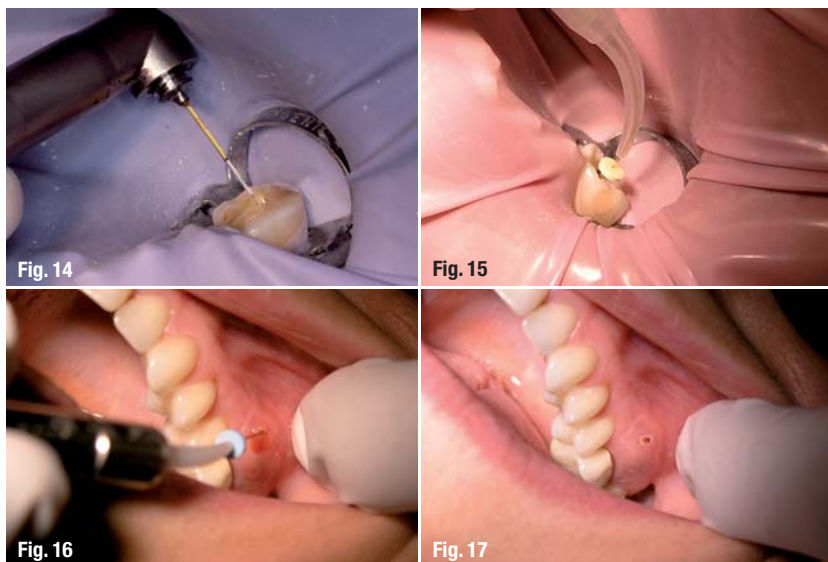
close debridement or open flap surgery, with a surface reactivation and bio-modulation of the remaining wound, are the pillars of modern periodontal therapy.

The corresponding laser assistance is highly efficient, as demonstrated with success during the last decade by various methods, such as LANAP. There are still some questions regarding the major benefits compared with the classic protocol, even if the combined use of laser-assisted and classic methods has been demonstrated as more advantageous and efficient by various studies. We set the perio chart in our office with the Florida probe, as an objective and hand-independent system, allowing direct comparisons of results in time and place.

During a closed periodontal treatment into pockets to a depth of 6 mm (or even more) the protocol suggests the assisting applications of Er:YAG, diode and/or Nd:YAG wavelengths. Periodontal open flap surgery is the primary action area of the Er:YAG laser, combined with a diode or an Nd:YAG laser for supplementary decontamination, bio-modulation and de-epithelialisation. The de-epithelialisation of the cervical tissue border and the upper buccal soft tissue area allows a discrete reattachment at the bottom of the pocket, before the faster re-epithelialisation of lesser quality from cervical starts growing down to the bottom. The laser-assisted perio protocol includes also peri-mucositis and/or peri-implantitis, often first with a closed debridement, as an emergency treatment to manage mainly the symptoms, and subsequently as open flap surgery to eliminate the cause.

Even if longer pulse durations are available, the closed decontamination of peri-implant areas with the Nd:YAG laser is still not included in our office protocol, because of its affinity to titanium and therefore more risky handling. In cases of closed decontamination, we switch to the 810 nm diode laser.

The regular office protocol is based on three steps (Figs. 18–23). Independent of the pocket anatomy, we start with an initial sterilisation with the diode, Nd:YAG or Er:YAG laser, to minimize the bacteria spreading into the body system. It is a medical sensible measure for all patients, but mandatory for the immune-compromised risk patients of any type. The second step entails classical closed debridement with ultrasound or piezo, supported by an Er:YAG-assisted concrement ablation on the hard root surface, and the elimination of granulomatous tissue on the soft gingival side, followed by a root surface modification and decontamination, to improve a local regeneration. The mandatory third step involves the final deep decontamination with the Nd:YAG laser in three to five cycles with a constant 2 mm/sec movement from apical to cervical along the soft tissue side of the pocket. The last cycle of more superficial



Figs. 14 & 15 PIPS protocol, with the additional final dry and deep decontamination using the Nd:YAG laser.

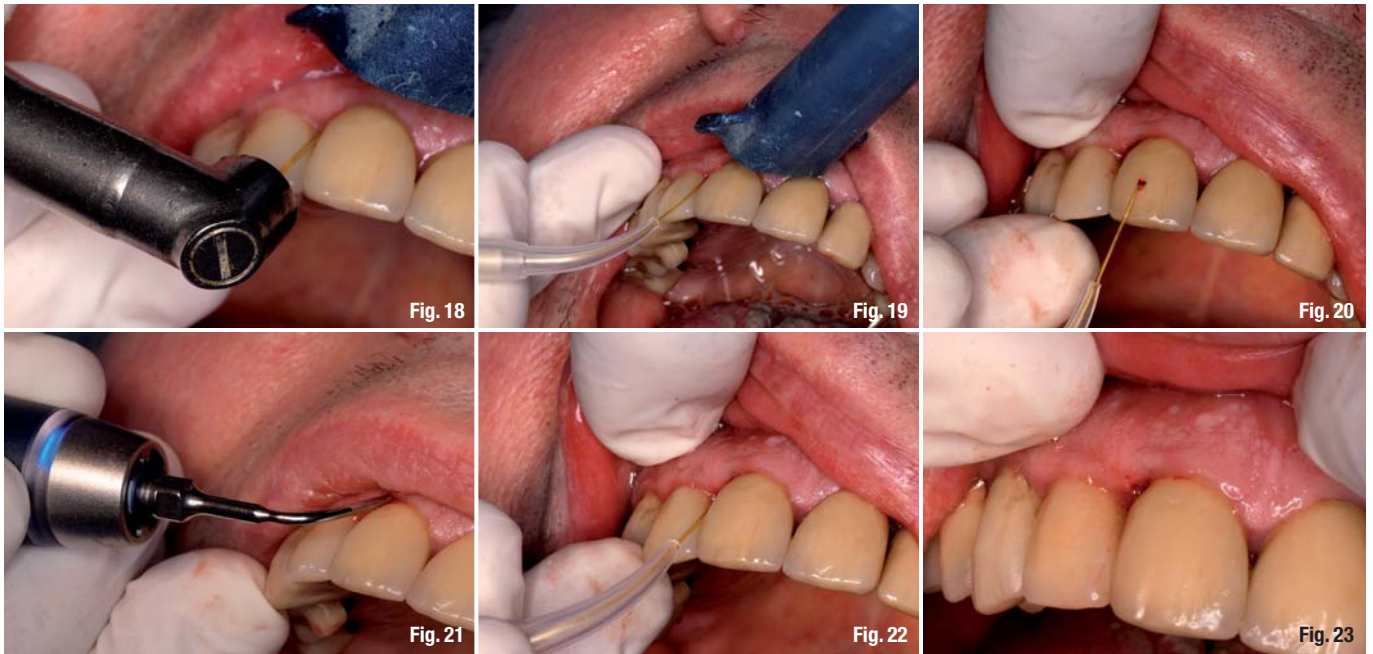
Figs. 16 & 17 Laser-assisted treatment of the fistula to manage the symptoms and preserve the first upper left molar until the scheduled surgery, depending on patient's work schedule: rinsing, decontamination, de-epithelialisation and sloughing of the tunnel, followed by a bio-modulation with the 810 nm diode laser or Nd:YAG laser.

ing three to five cycles of constant circuiting movement at 2 mm/sec from apical to coronal, allowing an interval of 30 seconds of down-cooling between the actions (Fig. 15). An equivalent office protocol is followed to manage the prepared root canal before pin cementation, after a provisional time elapse. Besides the decontamination, it allows a stronger adhesive cementation, changing the root-canal anatomy by a precise 3-D superficial modification.

Fistulas are often a side-effect in active peri-apical or periodontal lesions. The decontamination of the bone lesion, the de-epithelialisation of the tunnel and the sloughing of the entrance are performed efficiently with a diode or Nd:YAG laser (Figs. 16 & 17). A scattered bio-modulation is always included.

Laser-assisted periodontology

The bactericidal effect and the systematic removal of granulomatous soft and infected hard tissue during



movements at wider pulse durations entails the formation of a stable fibrin clot (Fig. 23), to close the cervical entrance by means of a biological wound dressing and in the de-epithelialisation versus buccal.

Photobiomodulation PBM or Laser Photo Therapy LPT

Photobiomodulation is one essential biological quality of laser-assisted therapy. Photobiomodulative radiations as a result of scattering are the positive side effect of a laser-assisted therapy. But they are also stand alone indications for LPT: the photodynamic therapy PDT (often part of the recall) and the specific photobiomodulation on cellular level. This one to optimise a high level wound healing in all kind of oral surgery, in cases of myoarthropathies, in laser acupuncture, local or systemic pain control, neuralgias, ghost pain, damage of specific neural areas and more. The new EmunDo PDT protocol (by Prof N. Gutknecht, University of Aachen, Germany), is the only one permitting the most efficient and complete decontamination of gram+ and gram-bacterias, allowing an immediate initialisation and activation trough a very low energetic level output of the diode 810 nm (by ARC).

Photobiomodulation enjoys finally its long deserved renaissance, rising up from the shade of uncertain anecdotal evidence to the sunny side of scientific evidence. The range of indications and the protocols are quite complex and mostly based on chemical effects in the cell or between cells, interactions, which need more space of discussion than the basic aim of this publication is. The motto is "similis similibus curantur" or in another words "using the body natural resources to provide". Those phenomenons explain PBM acting as the third pillar of our multi-wave in-office concept.

_Conclusion

We have purposely not mentioned any concrete settings for the therapies and their protocols reviewed in this article. The aim was not to be instructive, but to give some inspiration for the daily office using laser-assisted dentistry. The parameters and settings, scientifically verified, are given by the manufacturers, to ensure safe use of the laser-assisted therapy. The essential requirements are basic knowledge about physics, physiology, wavelengths, their tissue interactions and their applications and the evidence-based background, and self confidence. The study of a range of evidence-based literature, including medical websites, and the participation at theoretical and practical CE courses and workshops are mandatory for a safe, conscious and productive laser use.

I would like to thank particularly my father Zlatko as one of the early pionieers of LLLT/PBM. He gave me the strength, a profound credo and the fundamental knowledge to understand the spirit of healing light and its unique biological benefits.

Figs. 18–23 Protocol for a laser-assisted closed perio debridement: initial superficial decontamination and ablation of granulomatous tissue with the Er:YAG laser and Varian 600 µm fibre (Fotona), supported by one cycle of the 810 nm diode laser or Nd:YAG laser. Chlorhexidine rinsing and debridement with concrement-detecting piezo (PerioScan, Sirona). Final deep decontamination and bio-modulation with the Nd:YAG and 810 nm diode lasers. A stable fibrin clot as biological wound dressing was achieved by longer Nd:YAG pulse durations.

_contact	laser
<p>Dr Kresimir Simunovic, MSc André Scholtz, DDS Praxis für laserunterstützte Zahnmedizin Seefeldstr. 128 8008 Zurich, Switzerland</p> <p>ksimunovic@smile.ch www.simident.ch</p>	

Smile enhancement with laser technology— Predictable and esthetic

A case report

Author_Dr Hugh Flax, USA



Fig. 1_Visualizing the entire oral-facial composition helps to diagnose less harmonious features of the smile.

_Introduction

With the esthetic zone being absolutely critical to a patient's external appearance and inner emotions, orchestrating a bioesthetic result is mandatory. Too often, this is complicated when esthetic desires infringe on the health of the periodontal complex. This is often true when biologic width violations have occurred iatrogenically. Many factors may contribute to these failures, the two main culprits being intracrevicular margin location and overcontoured restorations. Not only is plaque accumulation problematic, but the

supracrestal fibers also become interrupted, causing the tissues to become further inflamed and esthetically unmanageable. Kois' landmark study defined the total dentogingival complex (DGC) as clinically predictable at 3.0 mm on the direct facial aspect, and at 3.0–5.0 mm interproximally when measured from the free gingival margin to the osseous crest. It is critical anteriorly that the gingival margin mimics the osseous scallop while maintaining the DGC.¹ Further complicating these complex situations is the degree of inflammation in the soft tissue, affecting the clinical development of health and esthetic symmetry.

Dental lasers have evolved considerably as an adjunctive and alternative treatment to safely, conservatively, and reliably decrease bacterial levels and improve the hard and soft tissue contours. Often the patient is frustrated with his or her previous poor cosmetic results.

However, to improve the periodontal framework in order to create an ideal result, they must be referred to yet another doctor. Even more challenging is the extended healing time created by reflective mucoperiosteal surgery. This not only affects the

chronology of final restorative care, but also delays the patient's ultimate satisfaction and happiness for a minimum of two to three months. Fortunately, dental lasers have evolved considerably as an adjunctive and alternative treatment to safely, conservatively, and reliably decrease bacterial levels and improve the hard and soft tissue contours. Studies of Er:YSGG lasers by Rizioiu and others have shown that thermal coagulative results, as

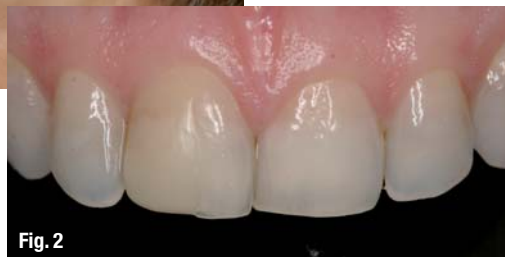
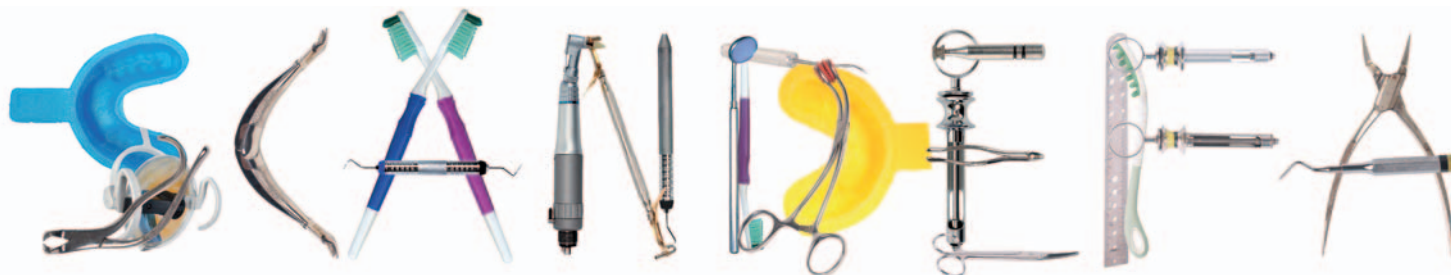
Fig. 2_Close-up photography is essential to planning peri-restorative care.



APRIL 26- 28, 2012 • BELLA CENTER • COPENHAGEN • DENMARK

Welcome to the 45th Scandinavian Dental Fair
The leading annual dental fair in Scandinavia

SCANDEFA 2012



The 45th SCANDEFA invites you to exquisitely meet the Scandinavian dental market and sales partners from all over the world in springtime in wonderful Copenhagen

SCANDEFA 2012

Is organized by Bella Center and is being held in conjunction with the Annual Scientific Meeting, organized by the Danish Dental Association (www.tandlaegeforeningen.dk).

175 exhibitors and 11.422 visitors participated at SCANDEFA 2011 on 14,220 m² of exhibition space.

Exhibit at Scandefa

Book online at www.scandefa.dk
Sales and Project Manager, Christian Olrik
col@bellacenter.dk, T +45 32 47 21 25

Travel information

Bella Center is located just a 10 minute taxi drive from Copenhagen Airport. A regional train runs from the airport to Orestad Station, only 15 minutes drive.

Check in at Bella Center's newly built hotel

Bella Sky Comwell is Scandinavia's largest design hotel. The hotel is an integral part of Bella Center and has direct access to Scandefa. Book your stay on www.bellasky.dk

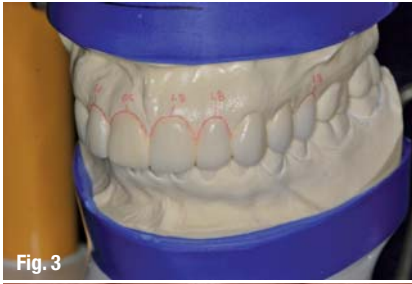

Fig. 3

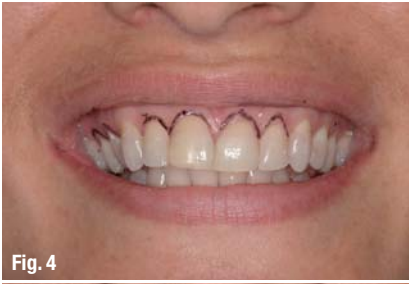

Fig. 4

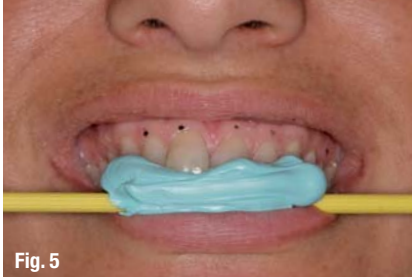

Fig. 5

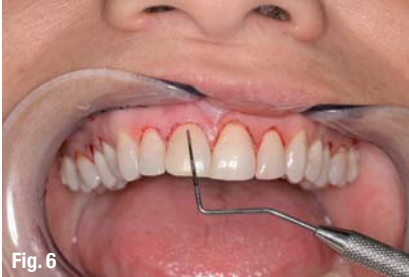

Fig. 6

Fig. 3 A mounted diagnostic wax-up is a critical roadmap to planning a realistic result.

Fig. 4 Outlining the desired gingival margins, prior to anesthesia, communicates a blueprint to the patient and restorative team.

Fig. 5 A stick-bite helps to verify that incisal and gingival planes will be parallel.

Fig. 6 The tissues are treated in a very nontraumatic manner with the Waterlase.

Fig. 7 To modify the bone, a very tight up-and-down movement is performed, using the black mark as a reference following the gingival scallop.

Fig. 8 A curette helps clean and smooth the sulcus of any debris.

well as bony ablation characteristics are similar to a dental bur.² From a patient-friendly standpoint, less need for suturing and shorter healing times improves case acceptance for doing ideal dentistry. In selected cases, such as the one presented in this article, minimally invasive laser procedures, with precise restorative planning and technique, can satisfy esthetic and functional parameters. Furthermore, patients can enjoy optimal results more comfortably and efficiently.

A conservative strategy was devised that would allow us to correct the problems and causes in a "multi-tasking" manner.

_Case Presentation

A 38-year-old female patient presented for correction of what she termed her "tilted smile" (Fig. 1). Given that she was starting a new sales career, she also wanted to make her teeth brighter and her smile much broader.

The patient shared her frustration about previous dental consultations that had focused solely on orthodontic or surgical solutions without considering a more practical approach that would fit her busy life. Her smile analysis established a collapse of the bicuspids in the buccal corridor. Furthermore, the axial inclinations, irregular gingival margins, and incisal edges created a downward tilt to the patient's right due to tooth positioning. Close-up imaging showed healthy gingival tissues as well as a weakened right central incisor from a large composite (Fig. 2).

_Findings

A full clinical examination with radiographs and mounted models revealed the following:

- Biomechanically, the majority of her teeth remained strong despite previous dental care.
- Periodontally, soft and hard tissues were healthy.
- Occlusally, load testing was normal (after muscle relaxation) and there was obvious CR-CO anterior-vertically slide due to a premature contact at tooth #30.
- Esthetically, the width-to-length ratio of the upper centrals was 1:2, far from the ideal range of 0.75:1.0. Tooth shade was a VITA A2.

_Treatment plan

Given the patient's previous history and her desire for minimally invasive dental care, a conservative strategy was devised that would allow us to correct the problems and causes in a "multi-tasking" manner:

- muscle and bite therapy with a Tanner appliance, followed by careful equilibration aided by the T-scan (Tekscan System; South Boston, MA)
- three-dimensional wax-up on a Stratos articulator (Ivoclar Vivadent; Amherst, NY) (Fig. 3)
- home bleaching of the lower teeth with Opalescence 15% (Ultradent; South Jordan, UT)
- "closed flap" periodontal modification with the Waterlase ErCr:YSGG (Biolase Technology; San Clemente, CA) while the first three items were being accomplished (the combination of these four steps was a tremendous time saver and also allowed us to carefully monitor progress on a weekly basis)
- definitive restorative care with porcelain veneers and a crown on tooth #8.

No tissue necrosis or significant bleeding occurred as a result of using the laser's relatively lower settings.

_Treatment

At the initial closed periodontal lift, the ErCr:YSGG laser was used in three modes (gingival sculpting, osseous recontouring, and bio-stimulation). Prior to anesthesia, the desired framework was planned and outlined using a fine marker (Fig. 4). Furthermore, a

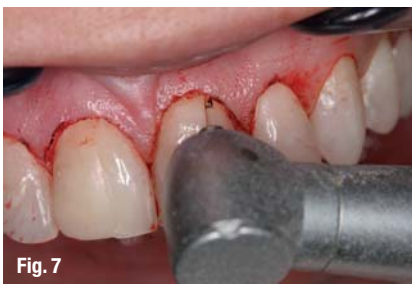

Fig. 7

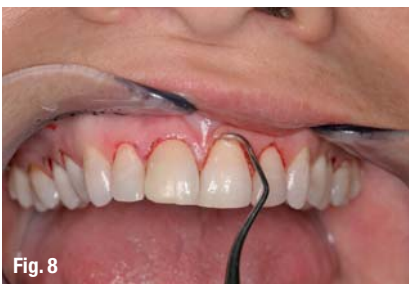

Fig. 8

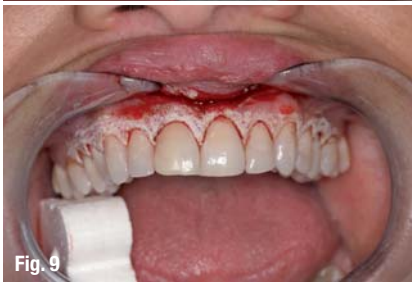

Fig. 9

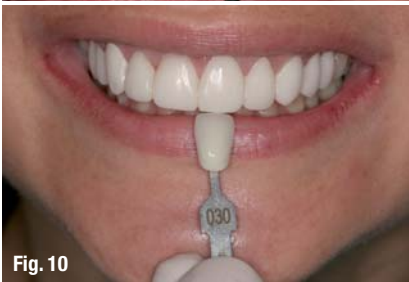

Fig. 10

stick-bite was used, not only to establish an ideal incisal plane, but also to properly align the gingival margins (Fig. 5).

With the settings at 2.0 Watts (W), 20 pulses per second, 20% air, and 20% water, a G-6 tip (600 μ in diameter) was used to shape the labial gingival region. No tissue necrosis or significant bleeding occurred as a result of using the laser's relatively lower settings. All areas were "sounded" using a periodontal probe (Fig. 6). At the facial margins, osseous sculpting required great precision in order to maintain a 3-mm DGC. A specially tapered T4 tip (400 μ in diameter) was used at a 25% higher wattage of 2.5W. Prior to usage, the tip was measured and marked to 3 mm in order to maintain controlled adjustments within the gingival sulcus during perio probing movement of the tip (Fig. 7). The resection was smoothed with a 7/8 curette (Fig. 8). Using low-level laser therapy at a setting of 0.25 W, a decrease in the release of inflammatory histamine and increased fibroblasts for junctional epithelial growth was achieved by "frosting" the outer epithelium and injection sites (Fig. 9). The patient was placed on a vigorous home-care regimen (Oxygel, Oxyfresh; Coeur d'Alene, ID) and closely monitored for a month while occlusal therapy and bleaching procedures were performed.

Four weeks after surgery, the tissues had healed and restorative care could be initiated. The patient's teeth were prepared for veneers and a crown with mild soft tissue reshaping, to fine-tune our previous treatment. After taking impressions and bite registrations, prototype provisionals (Luxatemp Plus, Zenith DMG; Englewood, NJ) were fabricated using the "shrink-wrap" technique. The patient was sent home with the same home-care regimen as mentioned previously, and instructed to "test-drive" her new smile for esthetics and function. She returned in a week to perfect the prototype's occlusion, color, and morphology. Photographs and models were sent to the laboratory, providing a final blueprint for the porcelain restorations (Fig. 10).

Four weeks later, the provisionals and cement were carefully removed from the teeth. All restorations were tried in individually and as a group to verify fit and esthetics. After the patient's enthusiastic approval, the porcelain was bonded using the two-by-two technique and isolation. Margins were smoothed and polished and occlusion balanced with the T-scan. A protective night-time appliance was created to add longevity to the rehabilitation. Our very satisfied patient said that we had exceeded her expectations.



Fig. 11

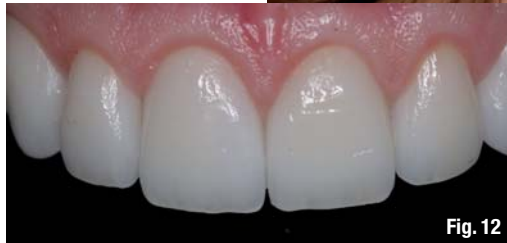

Fig. 12

Fig. 9 A "laser bandage" is placed along the treated area to improve the healing time and decrease the patient's discomfort. Note the immediate improvement of the geometric progression of gingival embrasures.

Fig. 10 Detailed information helps the laboratory to translate clinical results to the porcelain restorations.

Fig. 11 The great improvement in esthetics boosted the patient's self-confidence and pride in her dental care.

Fig. 12 Ideal proportions and emergence profiles will create long-term healthy tissues and bioesthetics.

Conclusions

The use of a hard/soft tissue laser is a wonderful adjunctive tool for cosmetic and restorative dentistry. The case discussed here demonstrates that this type of laser technology gives dentists the ability to make significant soft and hard tissue changes while being minimally invasive. These changes not only improve the final esthetic outcome of the case but also provide the physiologic functional parameters required for successful dentistry.

Acknowledgments

The author thanks his office team and laboratory technician, Mr. Wayne Payne (Payne Dental Lab, San Clemente, CA), for continually enhancing the lives of many patients like the one presented here. He also is thankful to his family, who allow him to contribute to the education of other dentists and their teams.

Contact

laser

Hugh Flax DDS
 1100 Lake Hearn Dr. NE
 Suite 440
 Atlanta, Georgia 30342
 Tel.: +1-404-255-9080
 Fax: +1-404-255-2936
 smile@flaxdental.com
 www.flaxdental.com

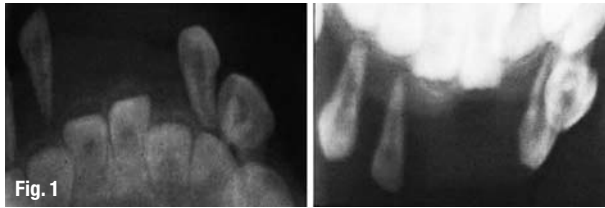
Editorial note: A list of references is available from the publisher.

Editor's Note: This article was reprinted with permission of Journal of Cosmetic Dentistry®, 2011 American Academy of Cosmetic Dentistry, All Rights Reserved. 608.222.8583; www.aacd.com

Papillon-Lefèvre syndrome

New laser-assisted treatment method

Authors _ Dr Maziar Mir, Dr Surena Vahabi, Dr Shahrzad Jalali, Dr Bahram Kazemi, Dr Susanne F. de Haar, Dr Gholam Hossein Ramezani, Prof Dr Friedrich Lampert and Prof Dr Norbert Gutknecht



*spp.*⁵ In a PCR study, *Bacteroides*, in particular, *Bacteroides forsythus*, were associated with different types of periodontitis.⁷ It was mentioned by Kabashima *et al.*⁸ that IL-8, IL-1 alpha and IL-1 beta cytokines may be responsible for modulating the process of rapidly progressive periodontitis in a patient with PLS.⁸

Fig. 1 _ Maxillary and mandibular occlusal view radiographs taken on April 1998: Bone loss around the primary teeth shows a very poor diagnosis for saving the teeth. Therefore, all primary teeth were extracted.

_Introduction

Papillon-Lefèvre syndrome (PLS) is a rare autosomal recessive disorder. Its reported incidence is one to four per million and both the sexes are equally affected.¹ PLS is characterised by palmo-plantar hyperkeratosis, periodontopathy and premature loss of deciduous, as well as permanent dentition.² Plaque and calculus deposits may be present, along with significant halitosis.³ It manifests between one to five years of age and the patient becomes edentulous in the early teens. Another component of PLS is asymptomatic ectopic calcification in the choroids plexus and tentorium,² hearing loss, follicular hyperkeratosis and nail abnormalities.⁴ About 20% of these patients also show an increased susceptibility to infection, probably due to dysfunction of lymphocytes and leukocytes.² PLS is diagnosed mainly clinically.⁵ It needs to be differentiated from other conditions that show similar oral and cutaneous clinical features, such as acrodynia, hypophosphatasia, histiocytosis X, leukaemia, cyclic neutropenia and Takahara syndrome, which are also associated with periodontitis and premature loss of teeth.⁶ The risk of developing periodontal disease decreases with age because of the immune response to antigenic challenge.³ PLS patients usually have very complex subgingival flora, which includes the presence of *Actinobacillus actinomycetemcomitans*, capnophilic bacteria and *Capnocytophaga*

PLS is caused by mutations in the gene that encodes cathepsin C (CTSC),⁹ as well as the related condition Haim-Munk syndrome and some cases of prepubertal periodontitis.¹⁰ This gene encodes a lysosomal cysteine protease or dipeptidyl aminopeptidase I (DPPI) necessary for the activation of serine proteinases in polymorphonuclear leukocytes (PMNs). It has also been suggested that DPPI is involved in a wide variety of immune responses, such as the activation of phagocytes and T lymphocytes. If the protein is truncated, it may not be transported to the organelle and may be not able to activate protein kinases. In addition, it will not be able to activate phagocytes and T lymphocytes, thereby leading to disease phenotype. Therefore, any typical mutation may result in either truncation or alteration in the conformation of CTSC-encoded enzyme DPPI.⁴ This gene is located on chromosome 11. Codon seven of this chromosome shows the exact mutation. This mutation has been registered as Hm040133 and directly affects one of the amino-acid residues at the active site of the enzyme.⁹ Up to now, 50 different mutations have been described in PLS patients.¹¹ The most common class of point mutation is a transition involving substitution of a G-C (guanine-cytosine) pair with an A-T (adenine-thymine) pair or vice versa. Variations at the site harbouring such changes have recently been termed "single nucleotide polymorphisms".⁶ In patients with PLS, loss-of-function mutations in CTSC do not affect lym-

phokine-activated killer cell function. Natural killer (NK) cells from affected patients contain inactive granzyme B, indicating that CTSC is required for granzyme B activation in unstimulated human NK cells.¹² However, according to the existing data, CTSC gene mutations are only responsible for 70 to 80% of PLS cases.¹³ De Haar *et al.* demonstrated that PLS patients lack the activity of the PMN-derived serine proteinases elastase, cathepsin G and proteinase 3. They found that the PMNs of PLS patients released lower levels of IL-37. Furthermore, because of their deficiency in serine proteases, the PMNs of PLS patients were incapable of neutralising the leukotoxin produced by this pathogen, which resulted in increased cell damage.¹⁴

The goal of periodontal therapy is to eliminate bacteria in the pockets, to remove hard- and soft-tissue deposits, to remove the granulation tissue and pocket epithelium in the periodontal lesions, to do root planing and, later, to enhance the attachment gain.¹⁵ The conventional mechanical treatment of periodontitis in a patient with PLS has a poor prognosis. Almost no treatment that saved the permanent dentition in PLS patients has been described so far. The most optimistic papers have described an extraction of all the deciduous teeth six months before eruption of permanent molars # 16 and 17 followed by a period of edentulism. The edentulous period may explain there being no recurrent attachment loss in the permanent teeth up to age 17.¹⁶ After this age, treatment shifts to the use of dental implants and complete dentures as the best solutions to this problem.¹⁸ Also, regular bacteriological tests may help to prevent or control the risk of infection.³ Several studies have demonstrated that additional irradiation with low-level and diode lasers is better than scaling and root planing alone.^{19–22}

Relatively recently, Cobb concluded some clinical evidence from the literature that demonstrates that certain laser wavelengths could be helpful for the decontamination of periodontal sockets.²³ Qadri *et al.* demonstrated that additional treatment with low-level laser reduced gingival inflammation after non-surgical treatment. Plaque index, gingival index and probing depth declined more on the side given such treatment. Another marker of inflammation, gingival crevicular fluid volume, has been also reported to be greater on the treated side.¹⁹ Ishikawa and Sculean published a review article in 2007 that demonstrated the successful results of diode laser assistance in de-epithelialising and sulcus decontamination therapies.²⁴

In this study, additional to complete clinical, radiological, pathological and genetic diagnosis, a laser-assisted periodontal therapy was performed on a PLS

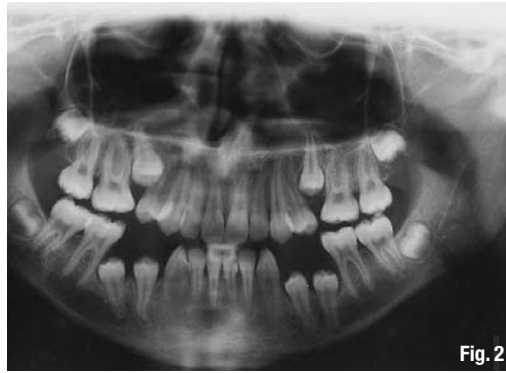

Fig. 2 Panoramic view taken on December 2008: The bone-level and soft-tissue lines are all normal. There is no pathological finding reportable.

patient. Following the accurate evaluations of the studies noted earlier, a 980 nm diode laser was selected to treat this particular patient, who lived in a village with no access to well-equipped laser clinics. Diode lasers are semiconductors that use solid-state elements to change electrical energy into light energy, and are smaller and more easily transported to areas far from medical centres. These lasers with wavelengths of 810 to 980 nm approximate the absorption coefficient of soft-tissue pigmentation. Therefore, light energy from diode lasers is well absorbed by the soft tissue and poorly absorbed by teeth and bone.²⁵

Review of a case with a new laser-assisted treatment plan

A three-and-a-half-year-old female patient was referred to the clinic with ten missing and six mobile primary teeth in April 1998. Physical examination revealed palmar and plantar hyperkeratosis. No other physical, mental or laboratory disorders were found. Dental examinations showed severe generalised gingival loss of attachment in both dental arches. There was a root exposure all around the existing teeth. Periodontitis as a manifestation of systemic disease is concluded as diagnosis.

Radiographic findings

Severe bone loss was evident in occlusal view radiographs (Fig. 1). The permanent teeth were found healthy inside the bone.

Microbiological and histopathological findings

The early antibiogram detection showed cephalixin as the antibiotic of choice for the disease. The result of the cultures revealed the predominant presence of *Bacteroides*. Hypercementosis and inflammatory reactive hyperplasia (fibrosis) were observed in the slides of the teeth involved and surrounding tissues, respectively.

Genetic analysis

By use of polymerase chain reaction (PCR), we amplified the seven exons of cathepsin C using the

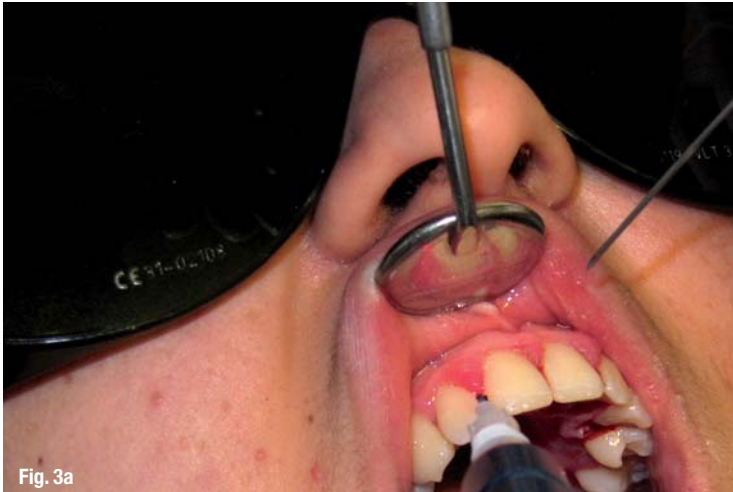


Fig. 3a

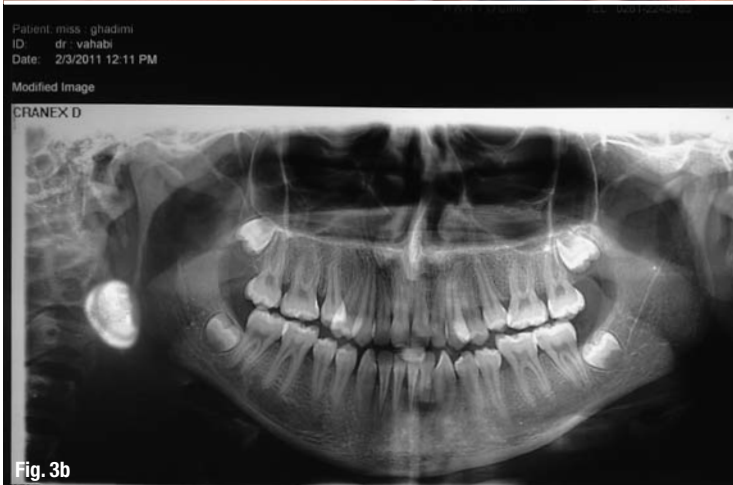

Fig. 3b

Fig. 3a & b Final clinical and radiograph condition of patient is shown as was registered in February 2011. This is the first time that a 12-year follow-up of a case of PLS has reported success in complete teeth eruption without any tooth mobility until the age of 16.

primers described in other studies. After the PCR process, we confirmed the presence of the PCR product by 2% agarose gel electrophoresis. The PCR products were purified using columns and the concentration of the DNA was determined spectrophotometrically. For the sequence reaction, we used the same primers as for the PCR reaction and the reaction was carried out using the BigDye Terminator mix (Applied Biosciences). The data was automatically collected and analysed by the software of the Sequencer. The sequences were compared with the published cathepsin C sequence. A nucleotide 1212 A>G mutation in the cathepsin C gene was found, which was predicted to result in an amino acid 405 His>Arg mutation. The mutation was confirmed by the use of restriction enzyme analysis performed on exon seven. The nucleotide mutation has not been reported previously.

Treatment

The patient was treated with a daily chlorhexidine mouth rinse. To eliminate the source of infection, all the primary teeth were extracted in June 1998. An early anti-biogram test has reported cephalixin to be recommended after extraction of the teeth. This selective antibiotic therapy elimi-

nated the need for antibiotic therapy before eruption of the permanent teeth, which was recommended by some earlier studies.

Follow-ups and laser-assisted therapy

The infection was successfully controlled. The patient was re-evaluated clinically and para-clinically and no future antibiotic therapy was needed. The permanent incisors and first molars erupted under good oral hygiene care. A recall on November 2003 showed no significant finding on the panoramic X-ray either.

In July 2007, gingivitis and the start of new contamination were reported. Therefore, laser treatment using a diode laser (970+/-10 nm wavelength, K-laser, Eltech S.R.L.) was selected in addition to routine hand instrumentation and curettage. This laser irradiated a beam with a diameter of 300 µm and 2.5 to 3 W output power around free gingival margins and inside the pockets after removing the necrotised parts of tissue. The full mouth procedure took approximately 15 minutes and the entire operation was documented using a professional video camera. The exact output power was 2 W during treatment and a reputation rate of 20 was selected.

The patient was re-evaluated after 1.5 years due to the relocation of her parents and difficult access to them. Although no treatment was done in this time, gingival tissue colour was normal in December 2008, and there were no evidences of deep periodontal pockets or loss of attachments, except slight inflammation around the gingival margins. No significant pathological finding was reported from the panoramic radiograph either (Fig. 2). Orthodontic treatment was proposed by a related department, but as the orthodontic wire and brackets are a source of plaque accumulation, diode laser therapy is done at the same time as each orthodontic visit to maintain the good condition of teeth until the age of 18. On February 2011, all teeth were still healthy and the patient was still undergoing periodical laser therapy additional to scaling and root planing. The final radiograph and clinical condition are presented in Figure 3.

_Discussion

The aetiology of the periodontal component is not entirely clear. The gene abnormality that causes PLS is found on chromosome 11q14, which involves mutations of cathepsin C.²⁶ This mutation was shown as in this case. The enzyme cathepsin C is active in skin, gingival tissue and immunologically active cells;²⁷ it is possible that the absence of functional cathepsin C affects the immune response to microbial infection. Thus, periodontal pathogens

are enabled, secondary to the impaired local immune response. Periodontal treatment included extraction of all the deciduous teeth and mechanical therapy with the concomitant use of systemic antibiotics.

In case reports, both mechanical debridement alone and mechanical therapy plus a single antibiotic have failed to eradicate *A. actinomycetem-comitans* and improve the periodontal condition in PLS.^{16,28} In this case, microbiological studies showed *Bacteroides* as the predominant bacterial species and cephalexin as the antibiotic of choice which has been resulted.

Numerous studies have demonstrated that the period of edentulism following the extraction of all deciduous teeth prevented involvement in later erupting permanent teeth. In these studies, extraction was followed by other treatment, such as mechanical therapy, systemic antibiotics and surgical treatment.^{16, 29–33} So, early diagnosis to extract the deciduous teeth before eruption of permanent teeth is very important, which was done in this case. Success in retaining the permanent teeth seems to depend on the timing of these therapies. If any teeth erupt after the period (edentulism) into a mouth that is free of periodontal disease, patients have a good chance of remaining periodontally healthy, even if oral hygiene and maintenance are not optimal, as happened in this case.

Several lasers have been used to decontaminate periodontal pockets.¹⁹ Some authors have reported proliferation of gingival fibroblasts after using low-level laser and have shown that the stimulated fibroblasts are better organised in parallel bundles.¹⁹ Low-level laser therapy may play an important role in periodontal wound-healing and regeneration by enhancing the production of the growth factors.³⁴ Application of the diode laser can reduce bacteria²⁰ in gingival crevices, which may reduce bacteraemia following ultrasonic scaling.²² Thermal and photo-disruptive laser effects result in the elimination of periodonto-pathogenic bacteria, regardless of laser wavelength.^{21, 35} Some studies have demonstrated that instrumentation of soft periodontal tissues with a diode laser (980 nm) leads to complete epithelial removal as compared with conventional treatment methods with hand instruments.¹⁵

Periodontitis in PLS is a multifactorial process believed to have genetic, bacterial and immunological aetiologies, making it difficult to diagnose and treat. Early diagnosis and administering appropriate systemic antibiotic therapy in patients with PLS might preserve all permanent teeth that otherwise would exfoliate spontaneously or be extracted. We con-

clude that microbiological tests may be a powerful tool to select the proper antibiotic for the successful treatment of a PLS patient. Decontamination of sockets after de-epithelialisation of gingival soft tissue in inflamed margins with a diode laser is a successful aid to the previous hand instrumentation and medicament therapies. This fact has been clinically proven by a ten-year follow-up of a case that has a healthy periodontal condition. Similar cases reported in the literature mostly resulted in loosened permanent teeth. This success, while partly due to the correct antibiotic selection, is mostly the result of sufficient laser therapy. More studies are needed to establish this finding. As PLS is a very rare syndrome, no randomised clinical trial could be done. Therefore, collaboration between several medical universities could be the key to conducting a long-term cohort study entailing laser treatment.

_References

1. W.A.D. Griffiths, M.R. Judge and I.M. Leigh, "Disorders of Keratinisation", in R.H. Champion, J.L. Burton, D.A. Burns and S.M. Breathnach (eds.), Textbook of Dermatology, 6th edn. (Oxford: Blackwell Scientific Publications, 1998), 1569–71.
2. R. Bergman and R. Friedman-Burnham, Papillon–Lefèvre syndrome: A study of the long-term clinical course of recurrent pyogenic infections and the effects of etretinate treatment, British Journal of Dermatology, 119/6 (1998): 731–6.
3. H.U. Toygar, C. Kircelli, E. Firat, et al., Combined therapy in a patient with Papillon–Lefèvre syndrome: A 13-year follow-up, Journal of Periodontology, 78/9 (2007): 1819–24.
4. A.A. Wani, N. Devkar, M.S. Patole, et al., Description of two new cathepsin C gene mutations in patients with Papillon–Lefèvre syndrome, Journal of Periodontology, 77/2 (2006): 233–7.

Editorial note: The whole list of references is available from the publisher.

_contact	laser
<p>Dr Maziar Mir</p> <p>British Lasik and Cosmetic Surgery Center, Dubai, UAE</p> <p>Department of Preventive and Conservative Dentistry University Hospital Aachen and Aachen Dental Laser Center RWTH Aachen University Pauwelsstr. 19 52074 Aachen Germany</p> <p>mmir@ukaachen.de</p>	

Er,Cr:YSGG laser for cavity preparation

A case presentation

Author_Dr Ralf Borchers, Germany

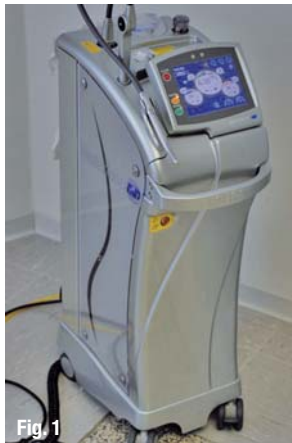

Fig. 1

Fig. 1_BIOLASE Waterlase MD Turbo.

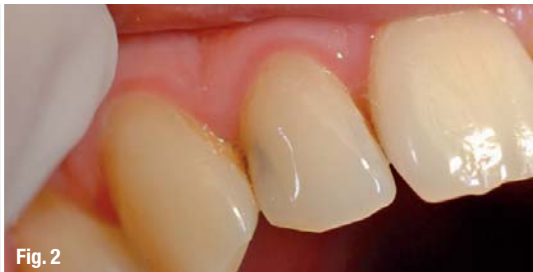

Fig. 2

Fig. 2_Upper right lateral incisor with caries.

Fig. 3_Turbo handpiece with MX7 tip.

Fig. 4_Preparation of enamel.

_Introduction

In the early 1990s, cavity preparation by Er:YAG laser was an exercise in patience. Owing to the low peak power of the pulse and a slow frequency the cavity was finished in what felt like hours after starting the laser treatment. Today, short pulse length, high power and increased frequency lead to short treatment times, comparable with conventional mechanical treatment by burs. Nearly all kinds of preparation and caries excavation can be done without any anaesthesia if the dentist is familiar with his laser and the correct treatment options. The procedure itself is more comfortable for the patient because there is no pressure or vibration on the tooth owing to the non-contact mode of the treatment. Additionally, the bactericidal effect of the laser results in a nearly sterile cavity without any smear layer, which in the case of direct or indirect pulp capping speeds up healing and helps to avoid eventual endodontic treat-

ment of the tooth. Laser treatment of cavities can be done minimally invasively with maximum preservation of sound tissue and even selective removal of caries is possible if the dentist is well versed. Subsequently, a cavity and caries treatment will be explained to demonstrate the procedure.

_Case presentation

The patient was a 28-year-old man with a carious lesion at the upper lateral incisor on the right side (Fig. 2). Laser treatment was done with a Waterlase MD Turbo (BIOLASE), an Er,Cr:YSGG laser with a wavelength of 2,780 nm (Fig. 1) and a turbo handpiece with a MX7 fibre tip (Fig. 3). The treatment was done without any anaesthesia and began with the preparation of the cavity. In case of interdental cavities the use of the „gold handpiece“ with longer tips would be preferable. Using the longer tips increases the ability to reach deeper zones in the mesial or distal part of the cavity and prevents from harming the adjacent tooth. Because of the different form of the tip and handpiece the speed of ablation will drop down slightly in this case.

Enamel treatment was done with the following parameters: 6.25 W, 30 Hz, 140 µs pulse, 75% water, 90% air (Fig. 4). Treatment of caries and dentine was done with the following parameters: 3 W, 30 Hz, 140 µs pulse, 35% water, 45% air (Fig. 5). During the procedure, the treated area was marked by the ablated enamel, a white surface looking nearly already etched (Fig. 6). The complete procedure was done in non-contact mode; therefore, the cavity had to be probed occasionally to ensure caries removal because the usual tactile feeling is absent during hard-tissue laser treatment. After cavity preparation and caries removal, the lased surface was treated with an excavator to remove the loosened enamel particles and thereby avoid a white area shining through the filling surface. The tooth was subsequently etched



Fig. 3

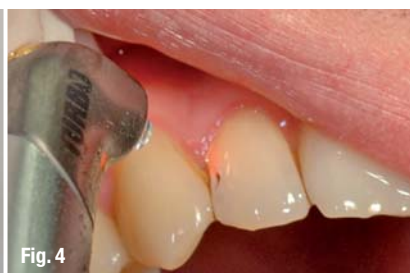

Fig. 4

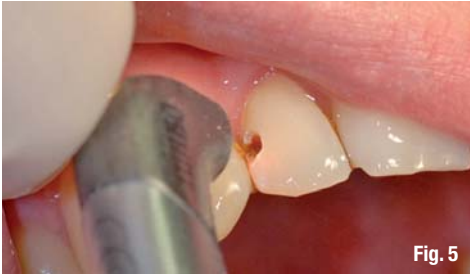

Fig. 5

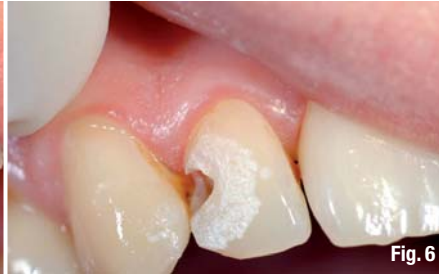

Fig. 6

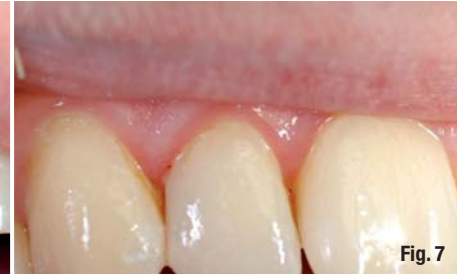

Fig. 7

and bonded as with conventional treatment. The finished filling after polishing is shown in Figure 7.

Summary

The entire procedure was done in ten minutes. No change of instruments was necessary, so as in classical treatment and therefore only a minimum of instruments have to be cleaned and sterilised. Due to laser preparation and additional etching the long term prognosis for such fillings is very high, which could be proved already by clinical studies and dye penetration tests. Patients compliance is very high for laser treatment because the entire procedure is more comfortable and mostly painfree. There is no vibration or pressure on the tooth, no injection for anesthesia is needed and treatment is accomplished in a short time. Sometimes its

possible to finish the complete procedure in the time another conventional treated patient is still waiting for anesthesia success. Last but not least it has to be mentioned that more than 90% of the already laser treated patients are asking for laser treatment the next time although they know about the additional charging of the laser treatment.

_contact

laser

Dr Ralf Borchers, MSc

Bahnhofstraße 14, 32257 Bünde, Germany
Tel: +49 5223 10222

Dr.Borchers@praxis-borchers.de
www.laserdentistry-germany.de

AD

implants

international magazine of oral implantology



You can also subscribe via
www.oemus.com/abo

 **Subscribe now!**

I would like to subscribe to **implants** for € 44 including shipping and VAT for German customers, € 46 including shipping and VAT for customers outside of Germany, unless a written cancellation is sent within 14 days of the receipt of the trial subscription. The subscription will be renewed automatically every year until a written cancellation is sent to OEMUS MEDIA AG, Holbeinstr. 29, 04229 Leipzig, Germany, six weeks prior to the renewal date.

Reply via Fax +49 341 48474-290 to OEMUS MEDIA AG or per E-mail to grasse@oemus-media.de

Last Name, First Name

Company

Street

ZIP/City/Country

E-mail

Signature

Notice of revocation: I am able to revoke the subscription within 14 days after my order by sending a written cancellation to OEMUS MEDIA AG, Holbeinstr. 29, 04229 Leipzig, Germany.

Signature

laser 4/11



The use of the Er:YAG in laser-assisted periodontal surgery

Author_Dr Avi Reyhanian, Israel

_Introduction

Periodontal diseases are some of the most widespread of oral pathologies. Chronic periodontitis, characterised by local inflammation owing to infection with pathogenic bacteria, destroys the supporting structures of the teeth including periodontal ligaments, cementum and alveolar bone. Untreated periodontal disease then leads to tooth loss because the attachment apparatus and tooth-supporting structures are destroyed. The goals of periodontal therapy are to arrest the progression of periodontal disease and regenerate those structures lost to disease. Since periodontal diseases are considered both chronic and destructive, the sooner diagnosis and treatment begin, the better the prognosis is for the patient.

Periodontal inflammation is reversible when limited to soft tissue areas (gingivitis), but when supportive bone tissue becomes involved (periodontitis), the situation does not reverse if left untreated. To accomplish these goals, it is essential to eliminate etiological factors such as adherent plaque, dental calculus, and diseased cementum

from the root surface and infected connective tissue within intra-bony defects around the teeth. Recently, various regenerative therapies in conjunction with flap surgery have come into use for the treatment of advanced periodontitis. Basically, however, the success of these therapies still depends on thorough debridement of the contaminated root surface and removal of infected granulation tissue. The aim is to preserve the natural teeth. Many variables are considered to determine whether surgically reducing the depths of the pockets will benefit the patient's oral hygiene.

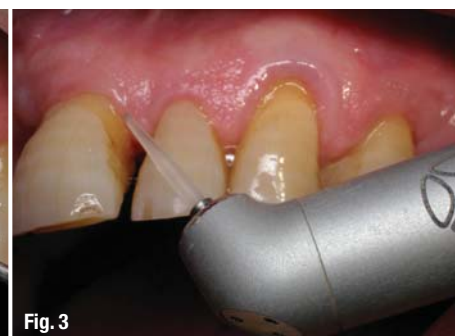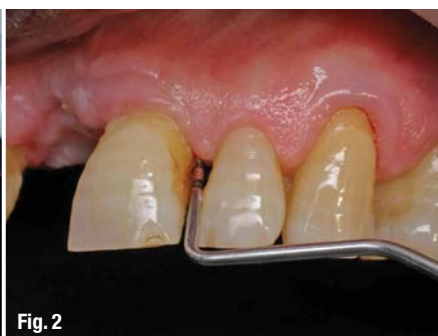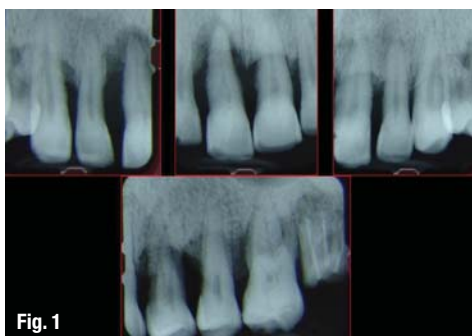
_Periodontal surgery with the Er:YAG laser

Usually, the removal of calculus and diseased soft tissue is performed with mechanical instruments. However, conventional mechanical instrumentation using curettes is still technique dependent, time consuming and occasionally ineffective, and power scalers are a source of uncomfortable stress such as noise and vibration for the patient. Laser-assisted periodontal therapy has attracted attention recently as a potential alternative to conventional mechanical treatment.

Fig. 1_X-ray image at presentation.

Fig. 2_Periodontal probe indicate pockets around 8 to 7 mm.

Fig. 3_Er:YAG laser incision with 600 μ sapphire tip, contact mode, power 200 mJ, 35 Hz.



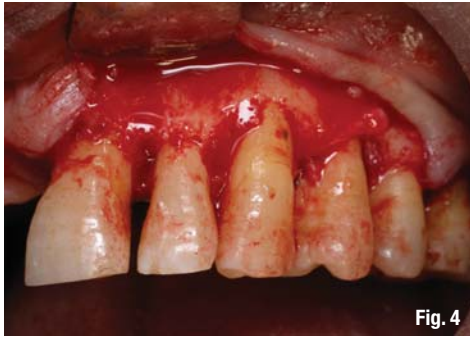


Fig. 4

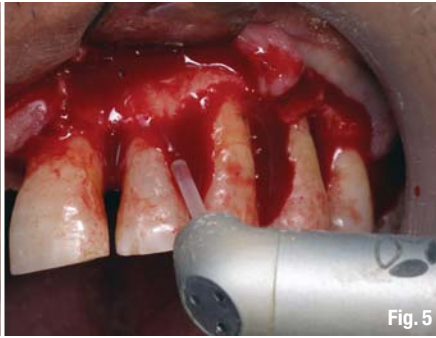

Fig. 5

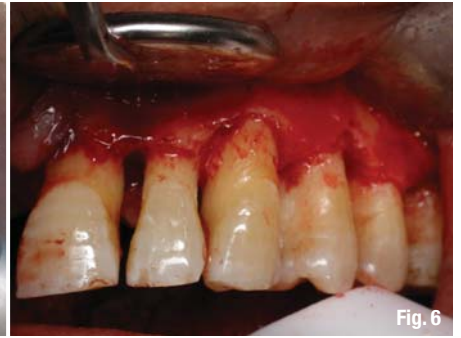

Fig. 6

Various types of lasers have been investigated as an adjunct to periodontal therapy. The Er:YAG laser, which emits at a wavelength of 2.94μ , has been demonstrated to be useful for both hard and soft tissue. The Er:YAG laser has produced the most promising results³² and has come to be one of the most promising lasers used in periodontics with a wide range of applications such as:

- incision for flap lifting;^{2, 4, 26}
- calculus removal;¹⁸
- high bactericidal capacity;⁹
- granulation tissue ablation;^{1, 27}
- detoxification effect on lipopolysaccharides of the diseased root surface;^{7, 30, 31}
- bone ablation: remodelling and shaping, without major thermal side-effects; and
- favourable root conditioning for the adherence of fibroblasts.^{20, 2, 26, 1, 28, 29}

A controlled clinical trial was performed by Schwarz *et al.*²³ They demonstrated that periodontal pocket therapy with an Er:YAG laser obtained equivalent or better results compared with conventional mechanical therapy with Gracey type curettes. Also, Sculean *et al.*²⁴ have reported that Er:YAG laser debridement of granulation tissue within intra-bony defects during periodontal flap surgery was as effective as with conventional mechanical instruments. Therefore, the clinical safety and effectiveness of the Er:YAG laser have been demonstrated for both non-surgical and surgical periodontal therapy, and this laser has become one of the most promising lasers used in periodontics.^{2, 24}

The purpose of this case study is to demonstrate the effectiveness of using an Er:YAG laser for periodontal surgery. The conventional approach is to make an incision with a scalpel and then use a periosteal elevator to lift a flap, then to remove the granulation tissue with mechanical tools. Bone reshaping and remodelling are then performed with rotary instruments and assorted chisels. The use of an Er:YAG laser for periodontal surgery is faster and more comfortable for the pa-

tient. This case study demonstrates the use of the LiteTouch Er:YAG laser system (Syneron Dental) for the entire procedure, both hard and soft tissue.^{4, 8, 9} This article will demonstrate that the Er:YAG laser may be used as a treatment alternative when working with bone.^{8, 14}

_Surgical case study

A 55-year-old healthy male patient presented with complaints of halitosis and recurrent bleeding. Clinical examination showed bleeding on probing with pocket probing depths of 5 to 6 mm (Fig. 1), stable teeth with no mobility, and exudation. An X-ray revealed vertical and horizontal bone loss (Fig. 2). Therefore, this case was classified as severe periodontitis. The dental hygienist initiated treatment through plaque removal and scaling and root planing, and then instructed the patient in more aggressive oral hygiene. Six weeks later, the situation was re-evaluated: there was no significant clinical improvement in pocket depth and bleeding on probing. A surgical procedure was decided that involved lifting a flap.

_Laser apparatus

The laser apparatus used was the LiteTouch Er:YAG laser system. The features of this system are a wavelength of 2.94μ , an output energy range of 50 to 700 mJ/pulse, a pulse frequency range of 11 to 50 pulse/second (Hz) and pulse duration of 200 microseconds. The system does not employ a fibre delivery system; the laser medium is in the applicator. The system also uses a special water spray system to cool the irradiated area. Air-mixed water is released coaxially to the contact tip, covering the target area during irradiation, providing precise and adequate water delivery. An optional feed bottle system is integrated into the system for sterile saline water supply during surgery. Intra-sulcular palatal and buccal incisions were performed with a 600μ tip 4 under local anaesthesia (Fig. 3). Water spray was used for tissue cooling throughout the entire laser procedure. The 600μ sapphire tip was used at settings of 200 mJ/35 Hz

Fig. 4 Immediately after raising the flap.

Fig. 5 Granulation tissue ablation with $1,300 \mu$ sapphire tip, non-contact, 400 mJ, 20 Hz.

Fig. 6 Immediately after ablation.

(= 7 W) in contact mode at intrasulcular depth. After the flap had been lifted (Fig. 4), the granulated tissue was removed by ablation and vaporisation using a 1,300 μ tip, in non-contact mode, at a distance of 1 to 1.5 mm from the target tissue (Fig. 5). The energy used for this procedure was 400 mJ/20 Hz (= 8 W). In narrow embrasures where the tip was too wide, the 1,300 μ tip was replaced with a narrower conical tip (800 μ) and the energy was decreased. Since the laser fires from the end of the tip and not from its sides, even when the side of the tip is touching another tooth while firing, no damage occurs to the adjacent tooth. After ablating the soft tissue,² the hard tissue was treated: for bone remodelling the power set was 300 mJ/20 Hz^{1, 2, 8} (= 7 W). The tip of choice is a 1,300 μ sapphire tip applied in non-contact mode.^{8, 14} For bone smoothing, the energy applied is 150 mJ/50 Hz (= 7.5 W), 1,300 μ sapphire tip in non-contact mode. Before closing the flap, laser energy should be applied to the exposed roots in non-contact mode on the buccal, palatal and interproximal sites at a very low energy of 100 mJ/35 Hz (= 3.5 W), using a 1,300 μ sapphire tip in non-contact mode (Fig. 6).

This step is important because it improved the attachment of the soft tissue to the root and greatly reduced bacterial endotoxin from the root's surface.^{5, 7, 9, 10, 12, 13, 15, 18, 19} A vertical release incision was not necessary because flap reflection was adequate. This particular procedure was performed without the assistance of curettes, rotary equipment or chisels. Were sub-gingival calculus present, however, I would have removed it with a chisel tip sapphire (Fig. 11).

Studies show that sub-gingival calculus can be removed with an Er:YAG laser.¹⁵⁻¹⁹ The patient returned the following day and reported that he was no longer in pain. No swelling was observed.^{3, 9} The patient was scheduled for maintenance therapy at three-month intervals for a period of three years. Fifteen months after the interventions, clinical attachment levels, pocket probing depths, recession, full-mouth plaque scores and full-mouth bleeding scores were assessed. No pocket depths ex-

ceeded 3 mm. The photographs and X-rays presented in Figures 1 to 11 show the various stages of this case study.

Several observed advantages of using lasers in periodontal surgery

The following are observed advantages of using lasers in periodontal surgery:

- less bleeding during the procedure;
- surgical site decontamination—the laser is bactericidal¹⁸ (no antibiotics necessary after surgery);
- comfortable post-operative outcome—less swelling and less pain (studies show this may be partly due to the closure of smaller blood vessels, lymphatic vessels, and exposed nerve endings);³
- more effective bone cleaning;^{1, 2, 14}
- faster completion of the surgical procedure³ and easy handling;²
- no rotary tool vibrations—patient comfort;³
- the Er:YAG laser produces no smear layer, leaving a bone surface that is absolutely clean, thus reducing the possibility of secondary infection.

Many studies have shown that when Er:YAG and other lasers are applied to bone, growth factors are released that enhance bone regeneration:¹ faster bone repair after irradiation than conventional bur drilling. Implants inserted into Er:YAG laser-placed holes can exhibit greater bone contact than those prepared by conventional methods.¹⁴

Particular points of attention

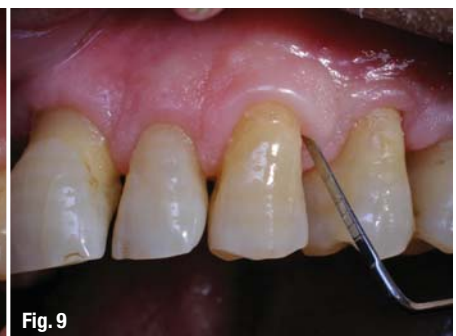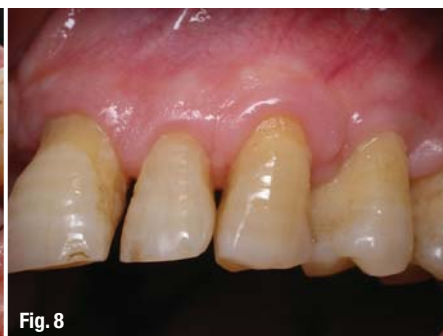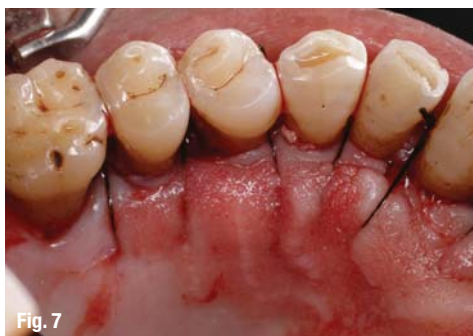There are particular points that require attention when using lasers for bone tissue:

- constant hand motion during laser emission—avoid applying the laser beam on any one spot longer than necessary (dental lasers are thermal devices by nature; therefore, long interaction between the laser and target tissue raises the temperature of the tissue—studies show, how-

Fig. 7 _Immediately post-op.

Fig. 8 _Six months post-op.

Fig. 9 _Fifteen months post-op.



ever, that when properly used the temperature generated by a laser beam is no higher than that generated by rotary tools);^{6,8}

- the use of saline solution as opposed to distilled water as a cooling liquid; this is to provide the bone tissue with an isotonic environment;
- the Er:YAG laser energy setting should stay below 400 mJ (8 W), keeping the applicator in constant motion;
- laser application to bone tissue should be in non-contact mode at a distance of 1 to 2 mm between the applicator tip and the target tissue—when the overlying tissue incisions are performed, operating in contact mode until you feel contact with the bone it is recommended;
- tissue-cooling water spray should be used throughout the entire Er:YAG laser procedure.

Discussion

Surgery with the Er:YAG laser takes less chair time, and invariably delivers better results than conventional approaches, making for an all-around happier patient. The definition of a well-rounded dental laser surgeon is the one who knows how to match the wavelength to the procedure, but that is not enough! The energy of the wavelength and the motion and position of the beam must be suited to the procedure as well (power energy, energy density and duration of irradiation). The surgeon should be well trained and skilled. A higher quality level of granulation tissue removal was achieved with the laser,^{2,4,8} the bone was free of a smear layer, the tissue healed faster, and the patient felt better after laser-assisted periodontal surgery.³

Conclusion

In conclusion, the LiteTouch Er:YAG laser can be safely and effectively utilised for degranulation and root debridement in periodontal flap surgery, without causing major thermal side-effects on the root and bone surfaces, and pulpal damage. The LiteTouch laser possesses characteristics particularly suitable for periodontal treatment, owing to its dual ability to ablate soft and hard tissue with minimal damage. The LiteTouch Er:YAG laser has proven itself to be an effective and promising tool for periodontal therapy and surgery, and has a sterilising effect upon dental structures.

References

1. K.M. Sasaki, A. Aoki, S. Ichinose, et al., Scanning electron microscopy and Fourier transformed infrared spectroscopy analysis of bone removal using Er:YAG and CO₂ lasers, *Journal of Periodontology*, 73/6 (2002): 643–52.

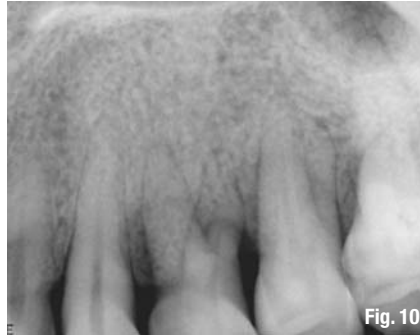


Fig. 10

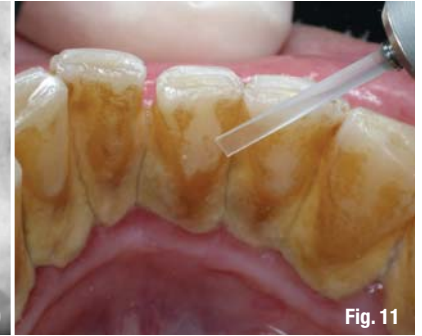

Fig. 11

2. I. Ishikawa, A. Aoki & A.A. Takasaki, Potential applications of Er:YAG laser in periodontics, *Journal of Periodontal Research*, 39/4 (2004): 275–85.

3. N. Lioubavina-Hack, Lasers in dentistry. The use of lasers in periodontology, *Ned Tijdschr Tandheelkd*, 109/8 (2002): 286–92. Errata in: *Ned Tijdschr Tandheelkd*, 109/10 (2002): 415.

4. H. Watanabe, I. Ishikawa, M. Suzuki, et al., Clinical assessments of the Er:YAG laser for soft tissue surgery and scaling, *Journal of Clinical Laser Medicine and Surgery*, 14/2 (1996): 67–75.

5. M. Folwaczny, H. Aggstaller, A. Mehl, et al., Removal of bacterial endotoxin from root surface with Er:YAG laser, *American Journal of Dentistry*, 16/1 (2003): 3–5.

6. V. Armengol, A. Jean & D. Marion, Temperature rise during Er:YAG and Nd:YAG laser ablation of dentin, *Journal of Endodontics*, 26/3 (2000): 138–41.

7. H. Yamaguchi, K. Kobayashi, R. Osada, et al., Effects of irradiation of an Er:YAG laser on root surfaces, *Journal of Periodontology*, 68/12 (1997): 1151–5.

8. Institute for Laser Dentistry, "Use of the dental Er:YAG laser (2940nm) for contouring and resection of osseous tissue (bone) and the preparation of endodontic canals" <<http://www.laserdentistry.ca/Er:YAG.html>>, accessed 30 Oct. 2006.

9. Y. Ando, A. Aoki, H. Watanabe, et al., Bactericidal effect of Er:YAG laser on periodontopathic bacteria, *Lasers in Surgery and Medicine*, 19/2 (1996): 190–200.

10. A. Pourzarandian, H. Watanabe, A. Aoki, et al., Histological and TEM examination of early stages of bone healing after Er:YAG laser irradiation, *Photomedicine and Laser Surgery*, 22/4 (2004): 342–50.

Editorial note: The whole list of references is available from the publisher.

_contact

laser

Avi Reyhanian, DDS

Shaar Haemek Street
Netanya 42292, Israel

avi5000rey@gmail.com
<http://www.avidentallaser.com/>

dental@syneron.com
<http://www.synerondental.com>

Laser in daily practice use

The key to therapeutic and economic success

Authors _ Prof Dr Frank Liebaug & Dr Ning Wu, Germany

_Laser dentistry went through a rapid development within the last years. Today, the use of laser devices enhances the whole dental treatment range valuably and supports conventional as well as conservative therapies. So the practitioner achieves more safety and a better clinical result can be obtained for the patient in a gentle way. In the following, the authors show different alternatives based on clinical case studies.

Especially for the colleagues with their own practice it is important to study the possibilities, but also the limitations of modern laser dentistry and to get an idea about the possible introduction in their practice.

_Practical indication for lasers in dentistry

Today, application fields of laser devices in oral therapy are to be found in diagnostics, caries and hard tissue removal, periodontology, antimicrobial, photodynamic therapy of mucosa diseases, en-

doodontics, implantology and preparation of suprastructures, periimplantitis therapy (Fig. 2), high-quality prosthetics, laser-supported pediatric dentistry, prophylaxis, bleaching and—last but not least—in esthetic dentistry.

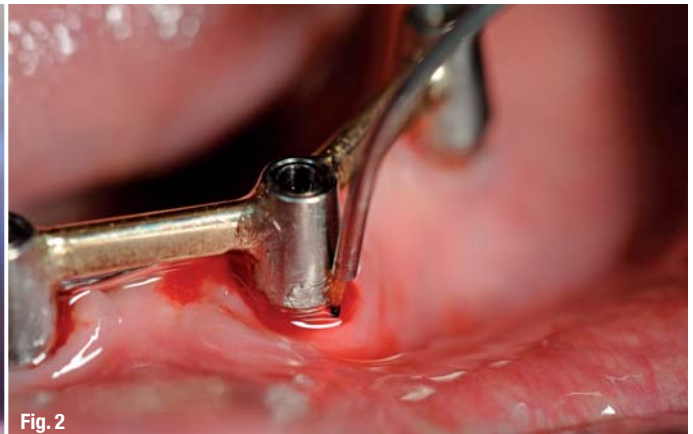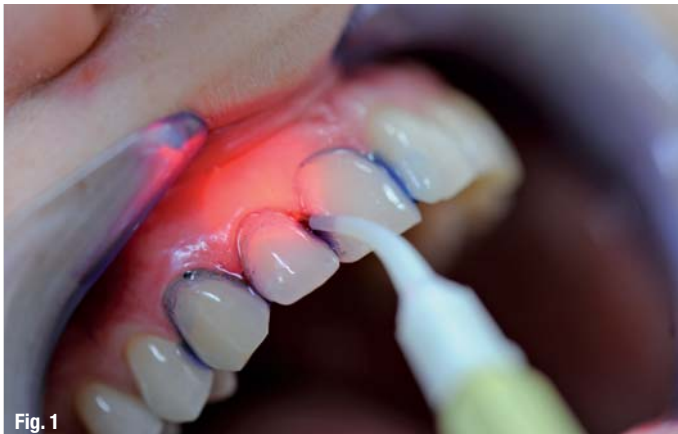_Wavelengths determine indication of use

However, there is not just one device for all applications and indications, in fact the indication is determined by the respective wavelength of the laser. Caries and hard tissue removal are treated with the Er:YAG device. As these devices are high-end developments, they are connected with high investment costs for the dental practice. If appropriately used by the dentist and integrated into the daily treatment concept, the use of such devices is reasonable midterm, therapeutically as well as economically.

Within the last years, various dental laser systems have gained importance in the therapy of pe-

Fig. 1 _Antimicrobial, photodynamic therapy in marginal periodontitis.

Fig. 2 _Laser for periimplantitis therapy, 17 years post implantation and dental bar provision.



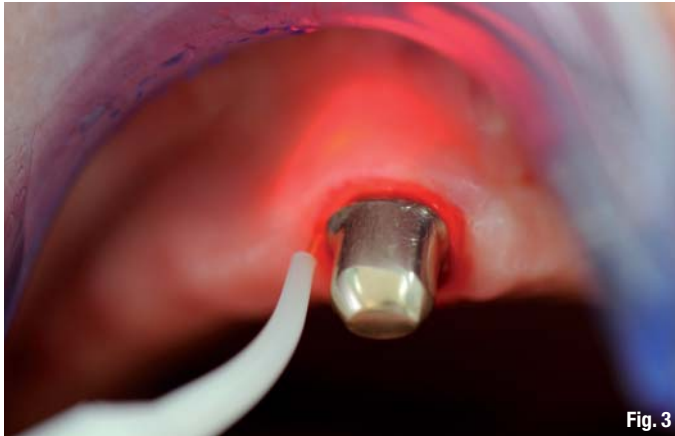

Fig. 3

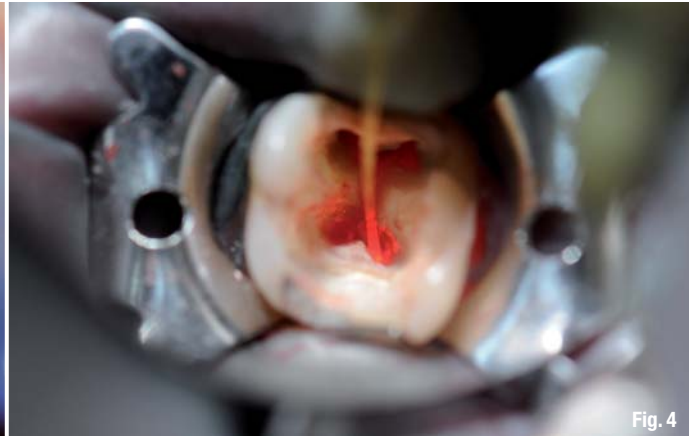


Fig. 4

riodontitis. In principle, the use of laser can only be seen as completion of the conventional, systematic therapy even though the field of non-surgical periodontal therapies could have been expanded by laser application meanwhile.

Before using laser devices, the patient must be prepared in terms of a completed initial therapy. Due to the latest developments in the field of laser technology, it seems to be conceivable that even the removal of concretions can be done by means of a laser.

Usage of laser creates a bactericidal environment and supports healing

Primarily, however, the dentist takes advantage of the bactericidal effect of a certain wavelength. Numerous studies and publications in various fields of dentistry have proved that laser shows an excellent antibacterial effect in the infrared area and that it is able to deactivate bacterial toxins. This effect starts developing at an output power clearly underneath the limit for a thermal damage of soft and hard tissue. Thin and flexible light conductor

Fig. 3 _ Pocket decontamination at telescopic tooth with a laser.

Fig. 4 _ Laser decontamination of root canals at a molar under Rubberdam.

AD

cosmetic dentistry

_ beauty & science

One issue free of charge!

You can also subscribe via www.oemus.com/abo

 **Subscribe now!**

I hereby agree to receive a free trial subscription of **cosmetic dentistry** (4 issues per year). I would like to subscribe to **cosmetic dentistry** for € 44 including shipping and VAT for German customers, € 46 including shipping and VAT for customers outside of Germany, unless a written cancellation is sent within 14 days of the receipt of the trial subscription. The subscription will be renewed automatically every year until a written cancellation is sent to OEMUS MEDIA AG, Holbeinstr. 29, 04229 Leipzig, Germany, six weeks prior to the renewal date.

▶ **Reply** via Fax +49 341 48474-290 to OEMUS MEDIA AG or per E-mail to grasse@oemus-media.de

Last Name, First Name

Company

Street

ZIP/City/Country

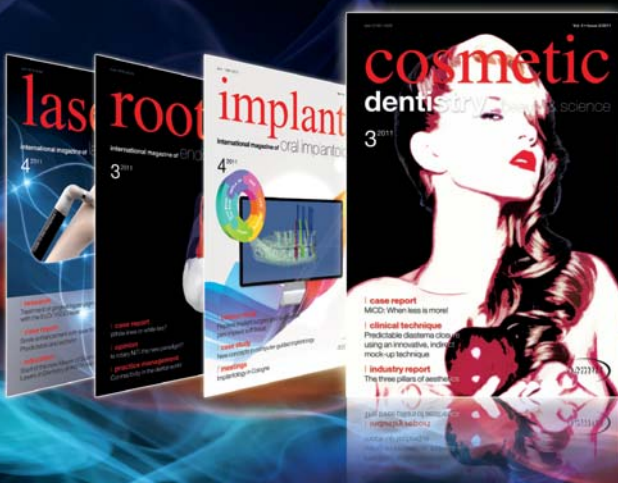E-mail

Signature

Notice of revocation: I am able to revoke the subscription within 14 days after my order by sending a written cancellation to OEMUS MEDIA AG, Holbeinstr. 29, 04229 Leipzig, Germany.

Signature

laser 4/11



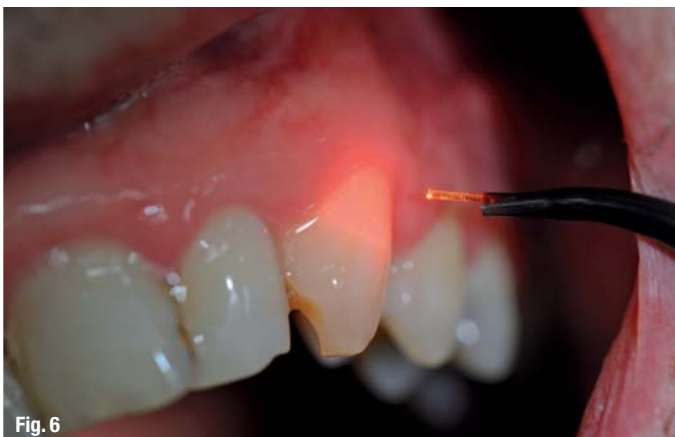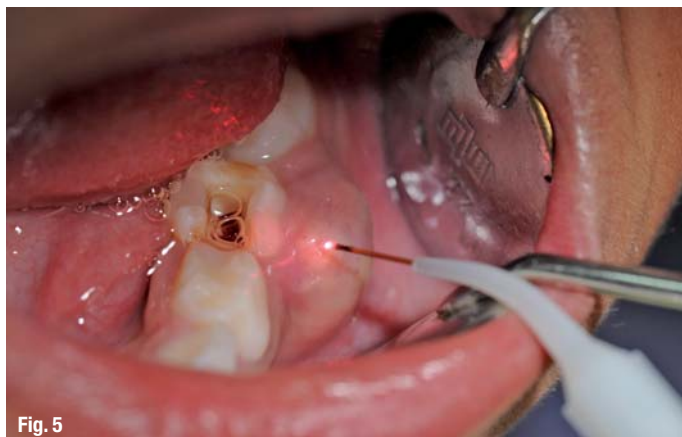


Fig. 5 Laser incision at acute, submucous abscess in primary dentition.

Fig. 6 Laser application for desensitization of hypersensitive tooth surfaces.

systems bring the laser radiation to nearly any desired place and can be well used even in the bifurcation area of molars. So it seems to be obvious to profit from these advantages in connection with a systematic periodontal therapy. If the output power is increased, also pocket epitheliums in terms of a closed curettage can be removed with an Nd:YAG or diode laser. Therefore, pocket decontamination with the laser is very effective, even in case of an acute local periodontitis.

Advantages of laser-supported periodontal therapy

Most dentists as well as patients will quickly realize the advantages especially in the fields of periodontology and laser-supported endodontics. For the field of laser-supported* periodontal therapy this means:

- no bleeding after treatment, even in patients suffering from a bloodclotting disorder or taking anticoagulants*
- significantly less anesthesia demand
- agreeable and easier treatment
- better healing process without complications
- considerably less postoperative pain
- drinking and eating possible after subsiding of anesthesia
- less postoperative hypersensitivities of tooth necks by sealing of dentin tubuli
- germ reduction in periodontal pockets (Fig. 3).

Advantages of laser-supported endodontic treatment

The success rate in endodontic therapy can be significantly increased by a consequent use of the laser device, too, thus avoiding surgical interventions to the point of necessary tooth extraction in case of clinical failures (Fig. 4). A major advantage is the 99% germ reduction* in the root canal immediately after exposure to laser light resulting in:

- possibly no medicamentous insert
- time saving, often whole treatment in just one appointment
- sealing of the apical dentin tubuli
- avoiding of apicectomy.

Clinical examples

The following case studies show just a small selection of treatment possibilities, without claim to be complete, to encourage interested colleagues to integrate innovative methods into the daily practice in the interest of their patients. It is not to be underestimated that especially children and anxious, sensitive patients are very open to this treatment method. One example should be the incision of an acute submucous abscess in the primary dentition (Fig. 5). But also the relatively many patients with herpes labialis or sore stomatitis aphthosa respond positively to the oral laser therapy. Hypersensitive tooth surfaces can be treated effectively with the non-contact procedure (Fig. 6).

The newcomer might have difficulties to find the appropriate device on the current dental market. Aside from devices with just one laser of a certain wavelength, the combination unit LaserHF, which we use in our practice, has been available for more than a year now. Apart from a diode laser with a wavelength of 975 nm, this device includes a low-level-laser with 660 nm and an additional high frequency surgery unit for cutting and coagulation.

_contact	laser
<p>Prof Dr med Frank Liebaug Professor Hangzhou Normal University, China Guestprofessor Shandong University, China Praxis für Laserzahnheilkunde und Implantologie Arzbergstraße 30 98587 Steinbach-Hallenberg Tel.: +49 36847 31788</p>	

International events

2012

Midwinter Meeting

23–25 February 2012

Chicago, USA

www.cds.org

Expodental 2012

Madrid, Spain

23–25 February 2012

www.expodental.ifema.es

Laser Optics Berlin

Berlin, Germany

19–21 March 2012

www.laser-optics-berlin.de

IDEX Istanbul

Istanbul, Turkey

5–8 April 2012

www.cnridex.com

IDEM International Dental Exhibition

Singapore

20–22 April 2012

www.idem-singapore.com

Dental Salon

Moscow, Russia

23–26 April 2012

www.dental-expo.com

SCANDEFA

Copenhagen, Denmark

26–28 April 2012

www.scandefa.dk

13th WFLD World Congress

Barcelona, Spain

26–28 April 2012

www.wfld-barcelona2012.com

**90th General Session & Exhibition
of the IADR**

Rio de Janeiro, Brazil

20–23 June 2012

www.iadr.org



Laser's rightful place in modern dentistry

Author: Jürgen Isbaner, Germany

The LASER START UP 2011 and 20th annual congress of the German Society for Laser Dentistry (DGL) took place in Düsseldorf, Germany, from 28 until 29 October 2011. The attending 250 laser beginners and proficient users were fully rewarded by the scientific and experience driven program.

In many respects the laser market developed extremely well in the past. Not least, this is reflected in a wide range of modern and very effective lasers. Due to the effort to integrate the laser dentistry more and more into individual areas such as implantology, periodontics and endodontics, it becomes increasingly easy to fight for the laser's rightful place in modern dentistry. Significant contributions for achieving this goal are the two laser-related conventions in Germany, the annual conference of the German Society for Laser Dentistry (DGL) and the LASER START UP congress.

The annual congress of the DGL builds on existing skills and provides a versatile program for continuing education regarding new applications of lasers in the dental office. The LASER START UP offers the ideal opportunity to make beginners familiar with the basics of laser dentistry and the latest laser technology.

Undisputed advantages of laser treatment

For more than 30 years the laser is used as a tool for therapy and diagnosis in medicine and dentistry. Its advantages over conventional methods, such as touch-free and sterile working or the reduced tissue trauma, are mostly undisputed. In addition, the specificity of laser light allows the development of completely new treatment and surgical techniques.

Laser is worth it

In the past there were mainly two reasons why the almost unlimited spectrum of indications of lasers in dental practices has not kept the unbroken triumph: First, there were not any universal lasers in the past and secondly, using the laser compared to conventional





instruments was relatively expensive. However, things have changed. The latest generation of lasers is flexible, powerful and ultimately economic. Still, the laser is not superior to conventional therapies. But, and this is crucial, the laser can be much simpler, faster, and in the relationship between effort and result more efficient. In times of cost pressure there is a significant opportunity for the laser: In regard of the technical level and the diversity of applications, dental lasers have never been as good as today. It has been proved, for example, that the laser reaches excellent results in dental surgery or endodontic and periodontal therapy, especially in the treatment of peri-implantitis.

Education and training for beginners and users

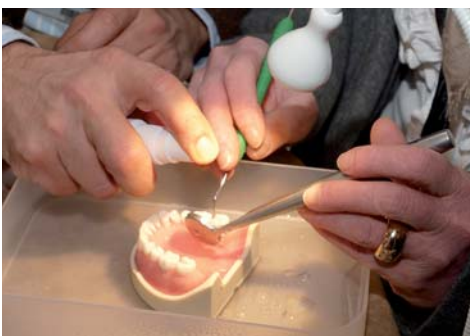Under the scientific leadership of Prof Dr Norbert Gutknecht (Aachen, Germany) Prof Dr Herbert

Deppe (Munich, Germany) and Dr George Bach (Freiburg/Breisgau, Germany) both, the DGL-annual conference and the LASER START UP offered first-class speakers that covered all aspects of laser use in daily practice in a comprehensive scientific program, hands-on courses and workshops of the leading laser manufacturers.

Thus, the joined conference in Düsseldorf was a valuable training event for both, experienced laser users and beginners.

In the upcoming year, both the LASER START UP 2012 and the annual congress of the DGL will be held in the city of Leipzig, Germany, on the 7 and 8 September 2012.

For booking information please contact OEMUS MEDIA AG via e-mail: events@oemus-media.de



Fascination of Laser Dentistry



From 28 October until 29 October 2011 both the 20th annual congress of the German Association of Laser Dentistry (DGL) as well as the congress for laser beginners, LASER START UP, were held in Düsseldorf, Germany. Over the two congress days we welcomed up to 200 participants from all over Germany, Europe and Middle East. Here you can read the abstracts of some lectures given during the congresses.

Laser-supported reduction of specific microorganisms in the periodontal pocket with the aid of an Er,Cr:YSGG laser: A pilot study

Author_Dr Constanze van Betteray, Msc/Germany

Aim of the study: This study evaluates the capability of the Er,Cr:YSGG laser with a wavelength of 2,780 nm and the new 360° firing elastic Radial Firing Perio Tip (RFPT; 14 mm length, 500 µm diameter; BIOLASE) to reduce pathogenic microorganisms in the periodontal pocket and to eliminate the biofilm and the diseased gingiva as a non-surgical conservative periodontal treatment that offers effectiveness for the dentist and comfort for the patient.

Material and method: Twelve patients with chronic or aggressive periodontitis were examined and treated. In the second dental hygienist session, a microbial smear as a pool probe from the deepest pocket in each quadrant was taken and the pocket depth of all teeth were measured. Following, a conservative periodontal treatment with ultrasonic devices and hand instruments followed in all quadrants within 24 hours. Afterwards, two randomly chosen quadrants were laser treated three times in a seven-day period using the Waterlase (BIOLASE) and the RFPT (output power of 1.5 W, 30 Hz, 11% air, 20% water and a pulse duration of 140 µs). After the last

lasing session, another microbial smear was taken from the laser sites. This was repeated after three and six months. After six months, the pocket depths were also measured again.

Results: The number of all bacteria in the pockets was reduced to -88.72% after six months. All bacteria, *Aggregatibacter actinomycetemcomitans*, *Porphyromonas gingivalis*, *Prevotella intermedia*, *T.f.*, *Treponema denticola* and *Fusobacterium nucleatum*, were reduced continuously throughout the whole examination period. The pocket depth showed a slightly higher reduction in the laser treated quadrants than in the non-laser treated ones. These results were found to be consistent and in some cases improved after six months post-treatment.

Conclusion: The results demonstrate that the use of the Er,Cr:YSGG laser with the new 360° RFPT in periodontal treatment is able to reduce pathogenic microorganisms in periodontal pockets significantly.

Basics of laser-assisted diagnostic procedures

Authors_Priv.-Doz. Dr J. Meister, Dipl.-Phys. F. Schelle, Dr O. Brede, Priv.-Doz. Dr A. Braun, Prof Dr M. Frentzen/Germany

Diagnosis, in the broadest sense, describes the assignment of findings to a term of illness, in which the discovery methods are grouped under the term "diagnosis". In dentistry and in oral and maxillo-facial surgery, numerous optical methods of assessment are used. These primarily include visual examination and imaging techniques such as X-rays or MRI scans. With the help of more modern LED and laser technologies, the field of optical diagnosis has been expanded. The selective excitation of fluorophores through monochromatic light and the consequent detection of carious lesions, for example, have made these technologies an integral part of the dental practice. A brief functional description is given and the current state of fluorescence technology is discussed.

The development of ultrashort-pulse laser (USPL) systems has opened another diagnostic window. For a variety of detection procedures, very specific properties of the USPL are exploited, e.g. its short coherence length or its very high intensities. The resulting technologies, for example, are optical coherence tomography and terahertz imaging. They allow not only superficial, but also deeper tissue layers to be analysed. Their function and practicality are discussed in this article.

In the future, the combination of therapy and diagnosis (theragnostics) could be of particular importance. This is explained using USPL and OCT as examples.

Possibility of calculus removal with an ultrashort-pulse laser system

Authors_Prof Dr M. Frentzen, ZÄ P. Pourfarid, Dipl.-Phys. F. Schelle/Germany

The selective and careful removal of biofilm and mineral deposits in periodontal therapy is a clinical challenge. As an alternative to conventional techniques, laser technologies hold significant potential regarding the selective removal of calculus and disinfection of the root surface. In the present study, the potential of ultrashort-pulse laser technology was investigated in this therapeutic field.

The aim was to determine the ablation thresholds of calculus and cementum. The ability to remove calculus selectively and the side-effects of this were assessed. The root surface of

freshly extracted teeth with and without calculus deposits were treated with an Nd:YVO4 laser (1,064 nm, pulse energy of 6–8 μ J, pulse duration of 8 ps, repetition rate of 500 kHz, focus \emptyset : 30 μ m, scan parameter: line spacing 12.5 μ m with a scanning speed of 2 m/s).

The study's results demonstrate that biofilm and calculus can be safely removed at 4 W average output power without damaging the dental hard tissue. The result is a smooth surface area. The results are the basis for further development of a clinical application system.

Material processing with ultrashort-pulse laser technology

Authors_Dipl.-Phys. F. Schelle, Dr B. Oehme, Dr O. Brede, Priv.-Doz. Dr A. Braun, Priv.-Doz. Dr J. Meister, Prof Dr M. Frentzen/Germany

Ultrashort-pulse lasers (USPL) are a well-known and proven radiation source for industrial material processing. The benefits of this technology include its high precision, versatility and efficiency of processing. The aim of this study was to determine how these properties can be transferred to application in dentistry. In particular, ablation thresholds and ablation rates for oral hard and soft tissue, and restorative materials were determined.

A 1,064 nm Nd:YVO4 laser (with a pulse duration of 8 ps, emitting at a repetition rate of 500 kHz) served as beam source. The experiments were performed on dentine, enamel, cortical bone, bone marrow, trabecular bone, titanium, amalgam, composites and ceramics. The resulting cavities were measured with

an optical profilometer. All materials investigated could be ablated. Ablation rates and thresholds were determined for all materials. Selectivity of material removal could be assessed from the data obtained. Promising results regarding selectivity of removal were obtained with composite materials, which have the highest ablation rate, as well as a remarkably low ablation threshold.

Regarding material processing properties, the use of USPL in dentistry appears promising. However, no realistic treatment situations could be simulated with the laboratory system utilised. Further studies are needed to examine and assess possible side-effects and risks for patients.

Evaluation of the efficiency of the diode laser for the treatment of pyogenic granuloma

Author_Dr Merita Bardhoshi/Albania

I report my experience in the treatment of two clinical cases of pyogenic granuloma with a 980 nm diode laser in the University Hospital, Department of Oral Surgery, Tirane, Albania. You will be treated as an outpatient under infiltration anesthesia lidocaine 2% 1cc, laser parameters: 6 W, continuous wave, optical fiber 300 micrometer after surgery no sutures were required.

Patients are following up after one week, four weeks, six months and one year after surgery to evaluate the early and long-term results. No analgesics and antibiotics were prescribed. The diagnosis was confirmed by biopsy. The laser surgery is well accepted by patients.

Patient reported no pain, swelling or bleeding a week after the operation. Four weeks after surgery, the wound was completely healed without complications. No scarring occurred and lips were normal in consistency. Aesthetic result was perfect. One year after surgery no recurrence occurred. The patients were satisfied with the result.

Laser surgery is a good modality for treatment of Granuloma pyogene. It is easy to perform, well accepted by the patients and the wounds were healed without complication. The big advantage is the lack of scars and a perfect aesthetic result. The application of 980 nm diode laser for the treatment of pyogenic granuloma seems to be with good beneficence.

Graduation of the first Mastership Course of AALZ Greece

Author_Dr Dimitris Strakas, Greece

Participants of the first Mastership/Fellowship Course offered by AALZ Greece have graduated. AALZ's course is a one-year clinical specialisation course for laser treatment at selected wavelengths. This offering is geared towards dentists who would like to specialise in certain wavelengths. Over the course of ten days spread over one year, participants are taught fundamental physical and technical knowledge and how to recognise primary, secondary, and tertiary indications.

The course, which is split into four modules, started on 14 November 2010. AALZ's Director and Mastership Course Director Prof Norbert Gutknecht and General Manager Mr Leon Vanweersch initiated and welcomed the participants by giving them the first guidelines to support them in their studies.

The first day of the course was dedicated to the Laser Safety Officer Course. This is a one-day course that offers official certification as a Laser Safety Officer (LSO; this course is a prerequisite for laser use). The innovative treatment methods of laser therapy pose risks for both practitioners and their teams, as well as for patients, if fundamental technical, biological and physical infor-

mation about the application and laser safety measures is not or insufficiently known. Dr René Franzen gave the participants an in-depth understanding of laser physics and laser-tissue interaction, preparing them for using lasers safely. This was followed by an examination for the LSO certificate. Our laser safety courses meet trade association requirements for obtaining expertise as an LSO. They are officially recognised according to the guidelines of BGV B2 (follows EN 60825-1 and ANSI Z136.1) and the State Radiation Protection Office.

On the second day, laser structure, function and handling of laser systems and laser-tissue interaction were taught. In addition, participants were introduced to AALZ's exclusive e-learning platform (ILIAS). Each participant was required to use the system, interacting with the lecturers and with the other participants and participating in the ILIAS forum, where questions and answers on lasers were posted and discussed.

The second module was presented from 28 February to 1 March 2011. Nd:YAG, diode low and high power, and CO₂ lasers were covered in this module and Prof Gutknecht explained the theoretical and biophysical





background, clinical indications and clinical importance in various fields of dentistry (e.g. periodontics, implantology, endodontics and soft-tissue surgery) to the participants.

The third module was presented from 8 to 10 May 2011. The erbium laser family (Er:YAG and Er,Cr:YSGG) was the subject of Prof Gutknecht's lectures over these three days. Every aspect of erbium lasers was analysed in detail and the participants had the opportunity to answer the vast number of questions they had.

We were then finally at the point at which our participants were preparing for the examinations at RWTH Aachen University. Apart from the written exam, the presentation of five clinical cases is essential. Guidelines and protocols were given to the dentists so they could prepare and demonstrate the laser treatments that they offer to their patients. The two months until the exams in Aachen were precious in order for them to prepare adequately.

On 13 July 2011, we flew to RWTH University in the beautiful city of Aachen. The written examination was held on the next day and the clinical presentations were delivered to the committee by the dentists the day after. Prof Gutknecht headed the four-member evaluation committee, which included Drs Franzen, Antonis Kallis and Dimitris Strakas.

In the afternoon, a reception and gala dinner hosted by AALZ was held in the exceptional Hotel Kasteel Bloemendaal. The graduation ceremony for awarding diplomas to successful participants was well planned and afterwards everyone enjoyed dinner in a friendly and pleasant environment.

Invaluable are the remarks by participants that characterised their experience of AALZ's course. This is what participants said about our programme:

"Starting the Mastership Course on November, I did not expect to meet such a serious and simultaneously

pleasant experience with exceptional organisation and high level of scientific-based lectures. Practically, the help of the Greek 'pioneer' colleagues Antonis and Dimitris and the German professors, especially Prof Gutknecht, which I thank, made me change the philosophy of my dental clinic in terms of modern technological innovations. The comprehension and usage of different wavelengths made it easier for me to implement lasers in my everyday dental treatments."

Dr Evangelos Dimitriou, Athens

"Before the Mastership Course Lasers in Dentistry, I felt like a blind man, using a laser. Now I feel stronger, owing to the high level of education of AALZ, of the great team working in this programme in Greece and Germany and of course to Prof Gutknecht, a real teacher and leader."

Dr Pantelis Mavridis, Drama

"Great experience: A must-do programme for anyone who wants to work with dental lasers. It has helped me to use 100% of the capabilities of my laser and not just by following given guidelines. It helps you understand how lasers work so that you can work with them effectively. Also for those who do not have any laser equipment but want to start working with laser, it will help them choose what is right for them and choose the right machine with the correct capabilities."

Dr Cristos Tzimogiannis, Ioannina

The second Mastership Course will start on 3 December 2011 in Athens:

Module I: 3–4 December 2011 (two days);
 Module II: 5–8 February 2012 (four days);
 Module III: 6–9 May 2012 (four days);
 Module IV: 10–11 September 2012 (two days).

The programme is presented in English and the exams are held at RWTH Aachen University in Germany. For more information, you can visit our website at www.aalz.gr or e-mail us at aalzgreece@gmail.com.

Start of the new **Master of Science** course in Aachen

Author _ Dajana Klöckner, Germany

_On 26 September 2011 the 14th master course "Lasers in Dentistry" started in Aachen, Germany. This postgraduate Master of Science programme has been offered since 2004 at the RWTH Aachen University.

The Rector of RWTH Aachen University, Prof Dr Schmachtenberg, welcomed the 24 curious dentists who will get a taste of student's life again. He introduced the University of Excellence where they will study extra-occupational for the next two years.

The participants come from 12 Nations: Germany, the European countries, Turkey, Iran and Saudi Arabia but also from Hong Kong. Some of them have already

been working for decades as successful dentists in their countries. They have come to Aachen because they are persuaded that laser dentistry is the future in dental medicine. After the official enrolment at the RWTH Aachen University the students got to know their new study place by a bus tour. Already in the afternoon, the serious students life started with the first lecture.

During the last seven years more than 120 dentists could take their Master of Science degrees.

Dr Peter Fahlstedt, M.Sc., graduate from 2008, reports: "I will start the first Institute for Laser-sup-





ported Dentistry in the Nordic Countries with the aim to offer the highest achievable level of education in this field to dentists in Sweden and other neighbour countries. This is only possible with the extraordinary support and professionalism."

The conclusion from Dr Dimitris Strakas, M.Sc., who started his studies in 2004: "The quality of the program and its elaborate structure will certainly give you the boost that you need while using and successfully treating with lasers. I am grateful for all the things I gained and for the security I feel having a great team of colleagues beside me, as we all walk with confident steps towards the new era of dentistry."

All important theories and application options pertaining to laser use in dentistry are taught. Participants obtain sound theoretical knowledge in lectures and seminars led by renowned, competent and experienced international scientists and practitioners. Skill training sessions, exercises, practical applications, live operations and workshops with intensive assistance from scientific associates with doctorates guide participants towards using lasers successfully and professionally in their own surgeries. During the ten modules, students remain in steady contact with the RWTH Aachen University and the

lecturers between attendance days via the e-learning system. This kind of segmentation allows established dentists to remain active in their clinics while getting their Master degree.

The Master course "Lasers in Dentistry" is the first accredited dentistry laser Master program in Germany and indeed the world, recognized in the EU and all countries of the Washington Accord (USA and Anglo-American nations) and of the Bologna Reform as an internationally valid academic degree.

The next course in English starts on 24 September 2012 and the upcoming course in German Language begins on 1 October 2012.

_contact

laser

AALZ – Aachen Dental Laser Center

Dajana Klöckner
 Pauwelsstr. 17
 52074 Aachen
 Tel.: 0241/47571311

klöckner@aalz.de



Manufacturer News

FOTONA

Fotona Gets Patent for its TouchWhite Tooth Bleaching Tx

Fotona, a leading developer and manufacturer of dental laser systems, has received a patent for its TouchWhite™ minimally-invasive laser tooth bleaching procedure.

TouchWhite™ utilizes the Er:YAG laser to activate the bleaching gel on the tooth's surface using Fotona's VLP pulse mode. The benefits of using the Er:YAG wavelength's high absorption in water means that, unlike with Nd:YAG or diode lasers, any




Fig. 1_ With TouchWhite™ only the gel is heated (a), while with standard laser whitening the entire tooth is heated (b).

bleaching gel color can be used because bleaching gels primarily consist of water. With TouchWhite™ patient safety and comfort are not a concern.

The Er:YAG laser power in the TouchWhite™ technique, is utilized more effectively, and the gel can

be heated to higher temperatures without compromising the safety of the tooth or pulp because laser light is fully absorbed in the gel.

As a consequence, the TouchWhite™ procedure is extremely gentle and the tooth whitening speed can be safely increased by 5–10 times.

Fotona d.d.

Stegne 7

1210 Ljubljana, Slovenia

www.lightwalkerlaser.com

info@lightwalkerlaser.com

KAVO

Greater performance for more efficiency

The KaVo KEY 3 plus LASER with its gentle, effective and low-pain application in periodontics, conservative dentistry, endodontics and surgery has been well established in dental practices since 2009.

Through greater ablation speed in hard dental tissue and bone, treatment length is significantly reduced compared to conventional LASERs. Fine ablation with variable pulse length also permits finishing the cavity margins. As a result, better aesthetics can be achieved than with conventional technologies. In periodontics, the unique feedback system of the KEY 3 plus LASER allows the selective, complete and low-pain removal of calculus, with excellent protection of the root support structures. Bacteria are killed and any biofilm on the tooth surface is dehy-



drated and deactivated. The periodontic handpiece 2261 is small and features an impressively easy exchange of application tips.

In conservative therapy, the Er:YAG LASER is suitable for caries preparation, enamel/dentine conditioning and fissure sealing. With the aid of the special, caries contact handpiece, the diseased tissue may be removed with direct intimate contact of the tooth surface, while using the feedback system.

Furthermore, the KEY 3 plus LASER is suitable for numerous other indications in endodontics and surgery, such as drying and sterilising the root canal, implant exposure and root tip resection.

KaVo Dental GmbH

Bismarckring 39

88400 Biberach/Riß, Germany


info@kavo.com

www.kavo.com

HAGER & WERKEN

Radio frequency and laser combined for the first time

LaserHF® from Hager & Werken is a combined unit which for the first time offers two technologies in one device: laser and radio frequency. While tissue can be perfectly cut, resected and coagulated with radio frequency, the laser offers additional, fascinating applications in endodontics, periodontics as well as in implant surgery. On top of that, new approaches, such as the tissue treatment in therapeutic terms (Low Level Laser Therapy) and antimicrobial



photodynamic therapy (aPDT) can be carried out. LaserHF includes two types of laser: A diode laser with 975 nm/6 W and a diode soft laser with 650 nm/100 mW for LLLT and aPDT. An easy to use touch-screen offers 15 pre-set programs in the laser unit (10 x diode laser, 5 x diode soft laser). The radio frequency-unit offers various pre-set programs. Additionally the user can save individual programs. Further information is available at www.hagerwerken.de.

Hager & Werken GmbH & Co. KG

PF 10 06 54

47006 Duisburg, Germany

info@hagerwerken.de

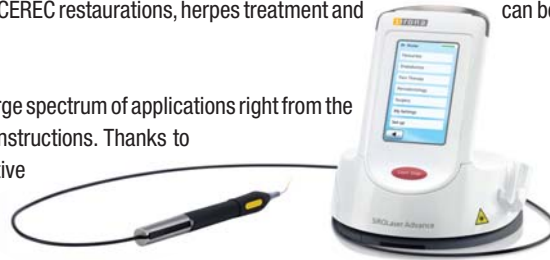www.hagerwerken.de

SIRONA

SIROLaser Advance & Xtend: intuitive, intelligent, universal

Laser therapy combines modern dentistry and up to date patient treatment. By using a diode laser, dentists fulfill the wishes of their patients: having an alternative or an addition to a conventional treatment. Sirona, the dental technology leader, offers two options for less experienced users and experts: SIROLaser Xtend with the up-grade-ready option and SIROLaser Advance. Both dental lasers offer a universal treatment spectrum: effective germ reduction, minimal invasive surgery, support during CEREC restorations, herpes treatment and bleaching.

Dentists are able to handle the large spectrum of applications right from the start—even without operating instructions. Thanks to the intelligent software and intuitive user navigation, they can get the application programme



they need quickly via touchscreen—and they will also find their way quickly back to the main menu.

The use of SIROLaser Advance and SIROLaser Xtend will result in happier patients. The stress-free treatment is efficient, causes hardly any pain and achieves stable good clinical results. Countless users and patients around the world agree. With these diode lasers Sirona offers dentist state-of-the-art devices and product quality that stands the tests of the time; along with a complete range of accessories, easy-to-use consumables and the expertise of the company located in Bensheim. All this means treatment with SIROLaser Advance and SIROLaser Xtend is treatment without stress. Further information about lasers can be found under: www.sirona.com.

Sirona Dental Systems GmbH

Fabrikstraße 31
64625 Bensheim, Germany

contact@sirona.de
www.sirona.de

SYNERON DENTAL LASERS

Amongst top ten fastest growing companies in Israel

Syneron Dental Lasers, inventor of the LiteTouch and Laser-in-Handpiece technology has been ranked 9th in the prestigious 2011 Deloitte Technology Fast 50 competition in Israel. Deloitte's Technology Fast 50 is a global program that recognizes the 50 fastest growing public or private technology companies in each region. To determine the fastest growing companies, Deloitte reviewed fiscal year revenues over five years (2006–2010), calculated the revenue growth percentage over five years, and compared the growth of technology companies.

"It is an honor to be recognized as one of the top ten fastest growing technology companies in Israel by



a respected organization such as Deloitte," said Ira Prigat, President and General Manager at Syneron Dental Lasers. "Our company's Laser-in-Handpiece innovation has played a pivotal role in transforming the way practitioners perform dental treatments today. Just as the mobile phone freed our world from wires, so has the LiteTouch freed dentists from the use of traditional tools and bulky optic fibers, making laser dentistry completely portable."

According to the manufacturer, LiteTouch is the world's smallest versatile Er:YAG dental laser for both hard and soft tissue dental treatments. The unique Laser-in-Handpiece technology incorporated in the LiteTouch offers a fiber-free laser delivery mechanism that mimics the feel of the turbine drill but with all the benefits of laser. The laser energy is swiftly delivered to the tissue, providing supreme cutting power and precise incision for soft tissue and bone. On November 24th, Syneron Dental Lasers ranked 119th in the Deloitte Technology Fast 500 EMEA program, and 8th among the 32 companies in the Biotech/Pharmaceuticals/Medical Device Equipment sector in Europe.

Syneron Dental Lasers

POB 223
Yokneam 20692, Israel

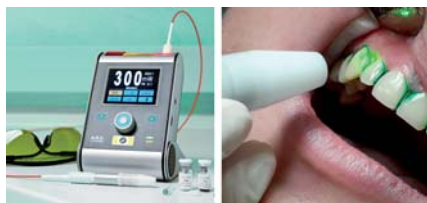dental@syneron.com
www.syneron.com

A.R.C. Laser

A.R.C. Laser convinces with EmunDo®

An increasing number of users speak on their enthusiasm concerning the positive impact of the entirely new Photodynamic Therapy. They are reporting of the simple and gentle laser-method to treat periodontitis.

For the first time in dental history, PDT is considered to achieve consistently effective and predictable outcomes in combination with a normal FOX diode laser.



The colorant EmunDo®—stimulated through the laser—generates aggressive singulett oxygen. As a consequence EmunDo® kills effectively all gram-positive and all gram-negative bacteria particularly in the periodontal therapy. Patients which have had problems with antibiotics and its side effects in the past, can be relieved now. EmunDo® is not only any kind of PDT agent—it is a acknowl-

edged therapy concept based on wide-range studies and the direct cooperation with AALZ Aachen, Germany.

- Unique selling point for your office:
- 100 % anti-bacterial impact
 - even germs in tissue are accessible
 - Reliable therapy concept.

A.R.C. Laser

Bessemersstraße 14
90411 Nuremberg, Germany

info@arclaser.de
www.arclaser.de

laser

international magazine of laser dentistry



Publisher

Torsten R. Oemus
oemus@oemus-media.de

CEO

Ingolf Döbbecke
doebbecke@oemus-media.de

Members of the Board

Jürgen Isbaner
isbaner@oemus-media.de

Lutz V. Hiller
hiller@oemus-media.de

Chief Editorial Manager

Norbert Gutknecht
ngutknecht@ukaachen.de

Co-Editors-in-Chief

Samir Nammour
Jean Paul Rocca

Managing Editors

Georg Bach
Leon Vanweersch

Division Editors

Matthias Frenzen
European Division

George Romanos
North America Division

Carlos de Paula Eduardo
South America Division

Toni Zeinoun
Middle East & Africa Division

Loh Hong Sai
Asia & Pacific Division

Senior Editors

Aldo Brugneira Junior
Yoshimitsu Abiko
Lynn Powell
John Featherstone
Adam Stabholz
Jan Tuner
Anton Sculean

Editorial Board

Marcia Martins Marques, Leonardo Silberman, Emna Ibrahim, Igor Cernavin, Daniel Heyselaer, Roeland de Moor, Julia Kamenova, T. Dostalova, Christliebe Pasini, Peter Steen Hansen, Aisha Sultan, Ahmed A Hassan, Marita Luomanen, Patrick Maher, Marie France Bertrand, Frederic Gaultier, Antonis Kallis, Dimitris Strakas, Kenneth Luk, Mukul Jain, Reza Fekrazad, Sharonit Sahar-Helft, Lajos Gaspar, Paolo Vescovi, Marina Vitale, Carlo Fornaini, Kenji Yoshida, Hideaki Suda, Ki-Suk Kim, Liang Ling Seow, Shaymant Singh Makhan, Enrique Trevino, Ahmed Kabir, Blanca de Grande, José Correia de Campos, Carmen Todea, Saleh Ghabban, Stephen Hsu, Antoni Espana Tost, Josep Arnabat, Ahmed Abdullah, Boris Gaspirc, Peter Fahlstedt, Claes Larsson, Michel Vock, Hsin-Cheng Liu, Sajee Sattayut, Ferda Tasar, Sevil Gurgan, Cem Sener, Christopher Mercer, Valentin Preve, Ali Obeidi, Anna-Maria Yannikou, Suchetan Pradhan, Ryan Seto, Joyce Fong, Ingmar Ingenegeren, Peter Kleeemann, Iris Brader, Masoud Mojahedi, Gerd Volland, Gabriele Schindler, Ralf Borchers, Stefan Grümer, Joachim Schiffer, Detlef Klotz, Herbert Deppe, Friedrich Lampert, Jörg Meister, Rene Franzen, Andreas Braun, Sabine Sennhenn-Kirchner, Siegfried Jänicke, Olaf Oberhofer, Thorsten Kleinert

Executive Producer

Gernot Meyer
meyer@oemus-media.de

Designer

Sarah Fuhrmann
s.fuhrmann@oemus-media.de

Customer Service

Marius Mezger
m.mezger@oemus-media.de

Editorial Office

Dajana Mischke
d.mischke@oemus-media.de

Published by

Oemus Media AG
Holbeinstraße 29
04229 Leipzig, Germany
Tel.: +49 341 48474-0
Fax: +49 341 48474-290
kontakt@oemus-media.de
www.oemus.com

Printed by

Messedruck Leipzig GmbH
An der Hebemärchte 6
04316 Leipzig, Germany

laser

international magazine of laser dentistry
is published in cooperation with the World Federation for Laser Dentistry (WFLD).

WFLD President

University of Aachen Medical Faculty
Clinic of Conservative Dentistry
Pauwelsstr. 30
52074 Aachen, Germany
Tel.: +49 241 808964
Fax: +49 241 803389644
ngutknecht@ukaachen.de
www.wfld-org.info


Copyright Regulations

_laser international magazine of laser dentistry is published by Oemus Media AG and will appear in 2011 with one issue every quarter. The magazine and all articles and illustrations therein are protected by copyright. Any utilization without the prior consent of editor and publisher is inadmissible and liable to prosecution. This applies in particular to duplicate copies, translations, microfilms, and storage and processing in electronic systems.

Reproductions, including extracts, may only be made with the permission of the publisher. Given no statement to the contrary, any submissions to the editorial department are understood to be in agreement with a full or partial publishing of said submission. The editorial department reserves the right to check all submitted articles for formal errors and factual authority, and to make amendments if necessary. No responsibility shall be taken for unsolicited books and manuscripts. Articles bearing symbols other than that of the editorial department, or which are distinguished by the name of the author, represent the opinion of the afore-mentioned, and do not have to comply with the views of Oemus Media AG. Responsibility for such articles shall be borne by the author. Responsibility for advertisements and other specially labeled items shall not be borne by the editorial department. Likewise, no responsibility shall be assumed for information published about associations, companies and commercial markets. All cases of consequential liability arising from inaccurate or faulty representation are excluded. General terms and conditions apply, legal venue is Leipzig, Germany.

laser

international magazine of laser dentistry



You can also subscribe via
www.oemus.com/abo

 **Subscribe now!**

I would like to subscribe to **laser** international magazine of laser dentistry (4 issues per year) for € 44 including shipping and VAT for German customers, € 46 including shipping and VAT for customers outside Germany, unless a written cancellation is sent within 14 days of the receipt of the trial subscription. The subscription will be renewed automatically every year until a written cancellation is sent to OEMUS MEDIA AG, Holbeinstr. 29, 04229 Leipzig, Germany, six weeks prior to the renewal date.

▶ **Reply** via Fax +49 341 48474-290 to OEMUS MEDIA AG or per E-mail to grasse@oemus-media.de

Last Name, First Name	
Company	
Street	
ZIP/City/County	
E-mail	Signature

Notice of revocation: I am able to revoke the subscription within 14 days after my order by sending a written cancellation to OEMUS MEDIA AG, Holbeinstr. 29, 04229 Leipzig, Germany.


Signature



The Dual Wavelength *waterlase***iPlus*™

Advancing Laser Technology to Its Ultimate

*i*NCOMPARABLE ACCESS & FIELD OF VISION



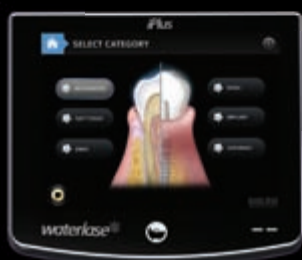- ⊕ No Pain, Therefore No Shot Necessary
- ⊕ No Micro-fractures or Thermal Damage
- ⊕ No Cross Contamination as with Burr
- ⊕ Best Ergonomic & Smallest Design

*i*NCREDIBLE POWER



- ⊕ Cutting Speed that Surpasses the High Speed Handpiece and Any Other Dental Laser on the Market
- ⊕ Cuts Faster and More Efficiently than Lasers with More Power Watts
- ⊕ Combines 0.5-10 Watts Power with 100 Hz & Short Pulse for 600 mJ of Laser Energy
- ⊕ Patented Laser Technology

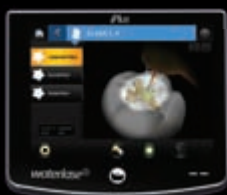*i*NTUITIVE GRAPHICAL USER INTERFACE



- ⊕ Step 1: Application

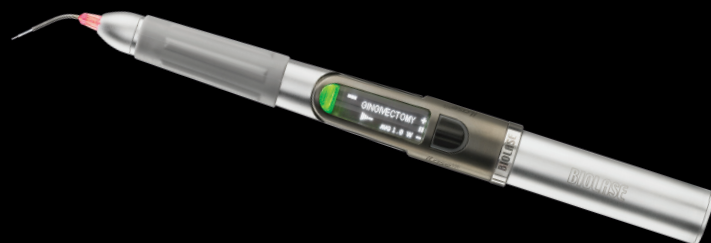

- ⊕ Step 2: Procedure



- ⊕ Step 3: No Shot/No Drill

*i*LASE 940nm DIODE LASER



- ⊕ 5 Watts of Power with ComfortPulse
- ⊕ Handheld & Ergonomic
- ⊕ Battery Operated with Finger Switch Activation
- ⊕ Proprietary Multi-diameter/Length Bendable Tips
- ⊕ Single Use for NO Cross Contamination



Standard World
Leader



This is
the First

TSIII SA

OSSTEM[®]
IMPLANT



Tel: +98 21 88 98 80 63 - 6

Web: Azadmed.com