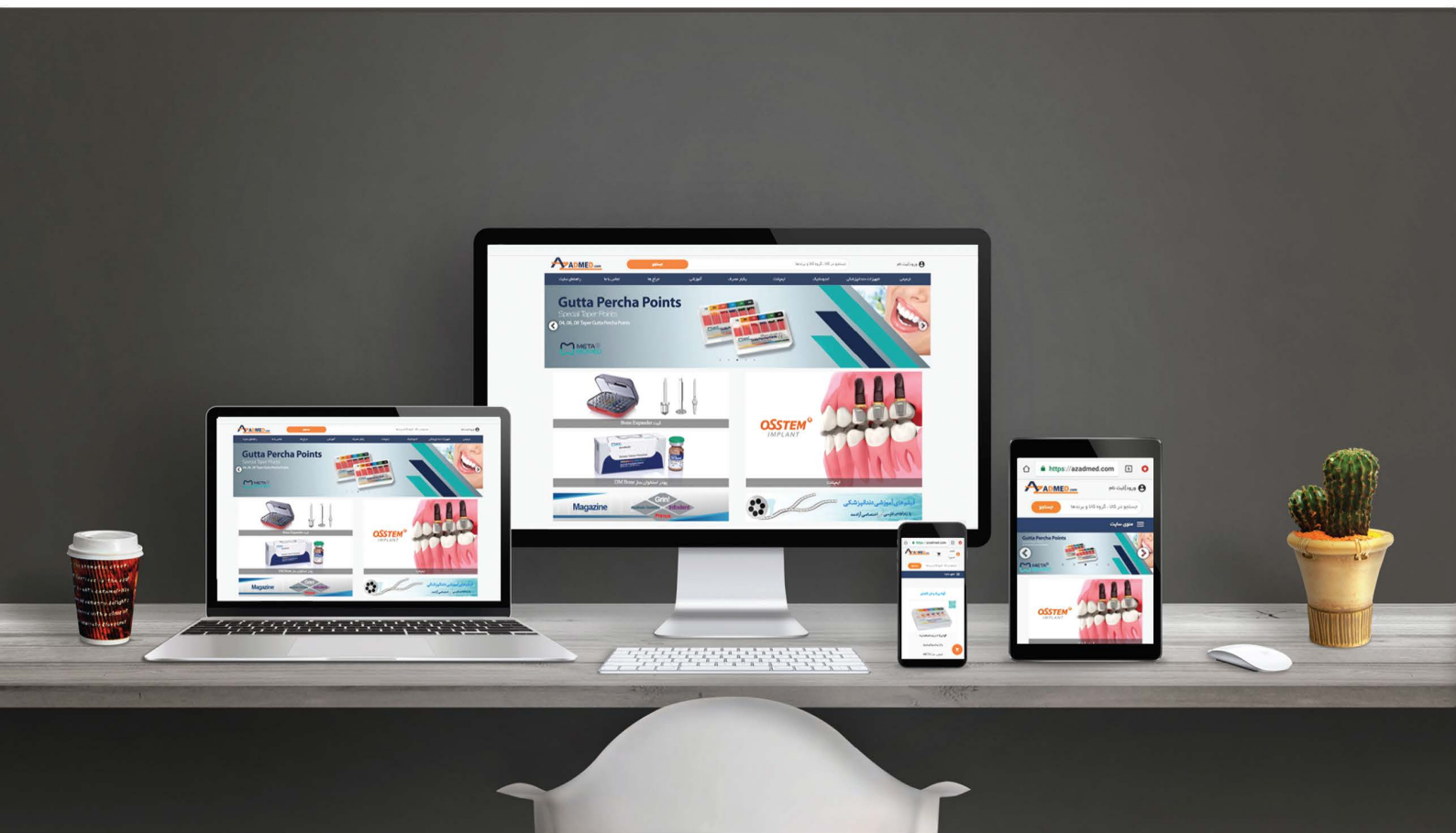







AZADMED.com



www.azadmed.com

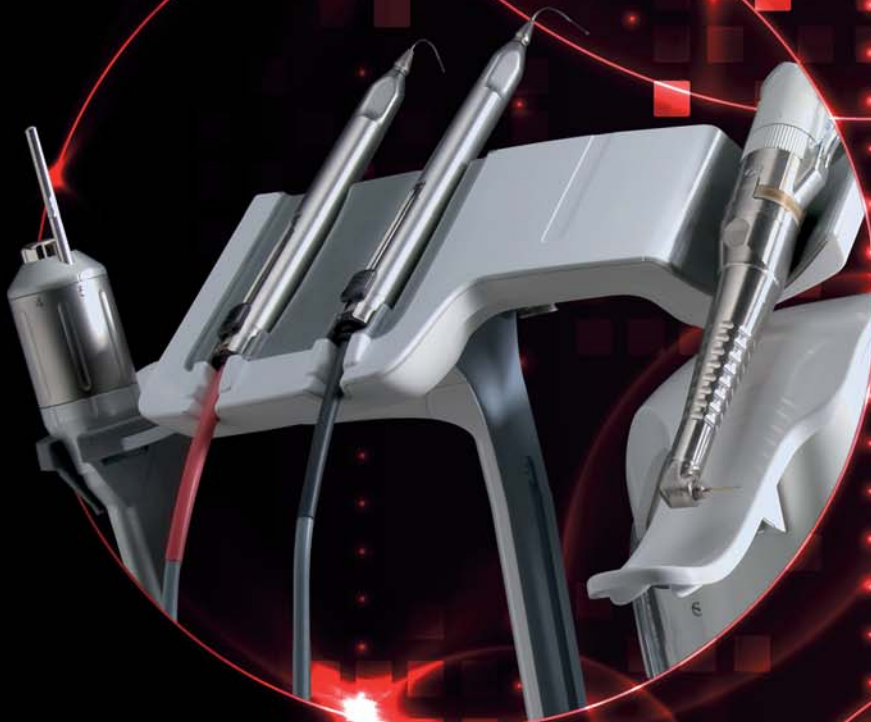

 azaadtejaratpars
 @azadmed2
 88 98 80 63 - 6

laser

international magazine of laser dentistry

1 2012



| **overview**

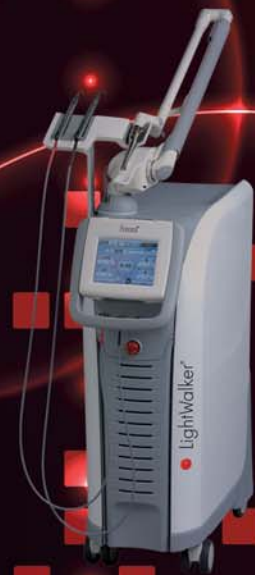Laser treatment of dentine hypersensitivity

| **industry report**

Bleaching: New approaches to a traditional minimally invasive therapy

| **meeting**

13th WFLD World Congress in Barcelona



دكتور

Fotona[®]
choose perfection

The universe at your fingertips.

TouchWhite™ Laser Assisted Tooth Whitening

A perfect white smile now faster and safer than ever before

- Utilizing the unique laser tissue interaction of the Er:YAG laser wavelength and Fotona's VSP pulse mode
- Up to 10 times shorter treatment times
- Safer - no unnecessary thermal burden on the tooth or pulp
- More comfortable for patients while achieving the same or better whitening efficacy
- Any bleaching gel color can be used
- Perfect, natural looking results after one single treatment

Available only with



LightWalker[®]



www.fotona.com

www.lightwalkerlaser.com

90812/1.0

Welcome to the **WFLD World** **Congress** in Barcelona



Prof Dr Norbert Gutknecht
Editor-in-Chief

It's hard to believe that already two years have passed since we said Goodbye in Dubai. It seems time has passed faster and faster, maybe because more and more dental events are on display. Today, hardly anybody is able to visit all the conferences and congresses which are offered.

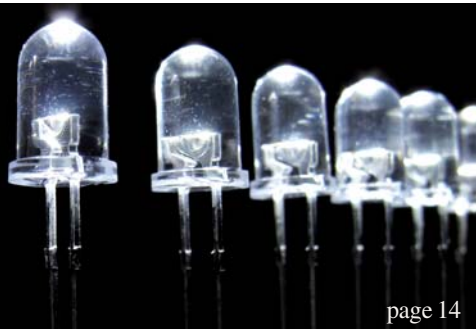
It's all the more pleasing to know that certain conferences like the WFLD congress have maintained a permanent place in your agenda. Looking at the high numbers of poster and abstract submissions, one can estimate that lasers in dentistry are a topic more relevant than ever.

The active participation of the largest manufactures of dental lasers as sponsors and exhibitors, along with the high number of laser manufacturers in general who partake in the exhibition, also has a high impact on the congress: visitors and participants benefit from the opportunity to see different laser systems in exhibitions, workshops or live demonstrations.

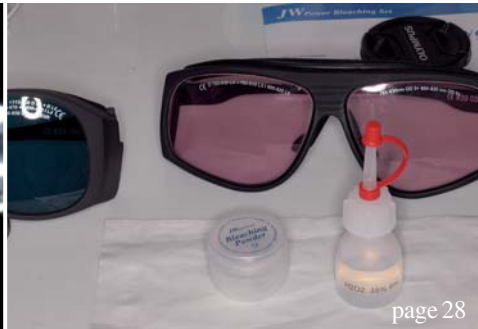Last but not least, the cultural aspects of the congress venue, the city of Barcelona, are worth undertaking a trip to the upcoming WFLD Congress. Springtime in the streets of Barcelona, a sunset dinner with friends on the shore of the Mediterranean Sea, the visit of historical museums, all combined with lectures, workshops and seminars of the congress, will make this event unforgettable.

On part of the *Laser Journal* I send my best wishes to the organizers, the board of the WFLD, the speakers and all participants for an inspiring and successful conference.

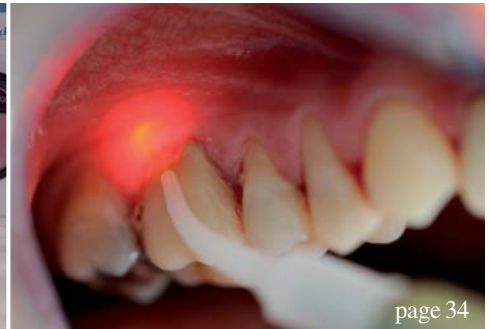Prof Dr Norbert Gutknecht
Editor-in-Chief



page 14



page 28



page 34

| editorial

03 Welcome to the **WFLD World Congress** in Barcelona
| Prof Dr Norbert Gutknecht

| research

06 Laser in **oral surgery** and medicine
| Antonio Batista-Cruzado et al.

10 Influences on the treatment of **recurrent aphthous ulcers**
with the Nd:YAG laser
| Dr Iris Brader

14 Treatment of **chronic periodontitis**
by laser and LED-PDT light
| Dr G. Karakitsos

| overview

20 Laser treatment of **dentine hypersensitivity**
| Dr Ute Botzenhart et al.

| case report

26 The management of **pyogenic granuloma**
with the 980 nm diode laser
| Dr Merita Bardhoshi

| industry report

28 **Bleaching**: New approaches to a traditional minimally
invasive therapy
| Dr Kresimir Simunovic et al.

34 **Effective** treatment of **periodontal** problem areas
| Prof Frank Liebaug

| education

38 Laser-assisted Pediatric Dentistry
| Dr Gabriele Schindler-Hultsch

44 The Mundus ACP Program: aiming for a **brighter future**
| Prof Dr Norbert Gutknecht

46 **11th “MSc in Lasers in Dentistry” class graduates**
at RWTH Aachen University
| Dajana Klöckner

| meetings

42 **13th WFLD World Congress in Barcelona**
| Dr Antoni España

47 **International** events 2012


| news

40 **Manufacturer** News

48 **News**

| about the publisher

50 | imprint



Cover image courtesy of Fotona d.d.,
www.fotona.com.
Artwork by Sarah Fuhrmann, OEMUS MEDIA AG.



page 38



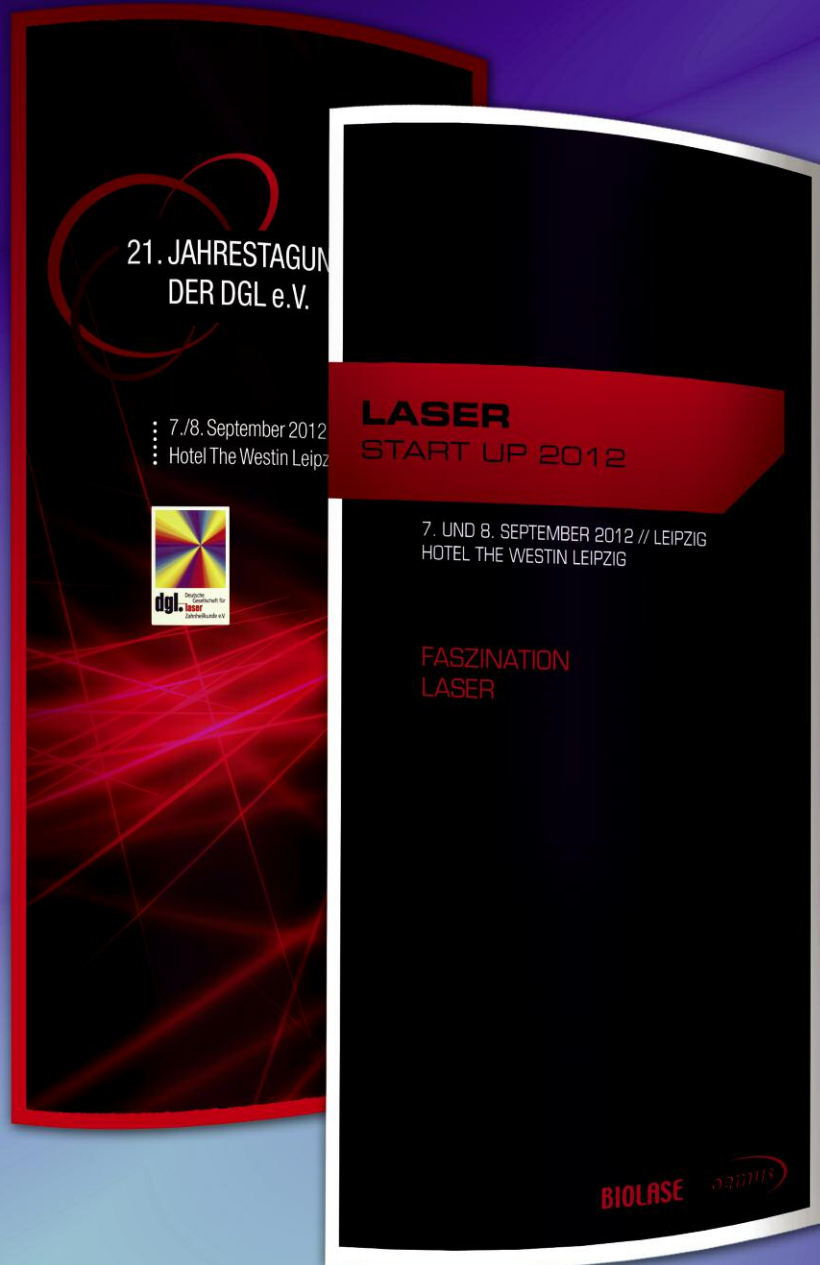page 42



page 44

» FASCINATION OF LASER DENTISTRY

FOR EXPERTS AND BEGINNERS



SEPTEMBER 7–8, 2012//
LEIPZIG//HOTEL THE WESTIN
LEIPZIG, GERMANY

MAIN SPONSOR

BIOLASE

ORGANIZATION/
REGISTRATION

OEMUS MEDIA AG
Holbeinstraße 29
04229 Leipzig
Tel.: +49 341 48474-308
Fax: +49 341 48474-390
event@oemus-media.de
www.dgl-jahrestagung.de
www.startup-laser.de



FURTHER INFORMATION

PLEASE FAX THIS FORM

+49 341 48474-390

Further information about:

LASER START UP 2012 21st ANNUAL CONGRESS OF THE DGL e.V

September 7–8, 2012, Leipzig, Germany

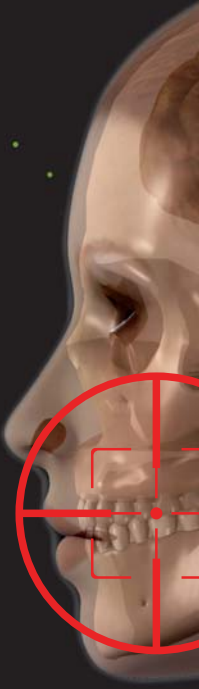NAME/E-MAIL

OFFICE STAMP

laser 1/12

Laser in oral surgery and medicine

Authors Antonio Batista-Cruzado, Daniel Torres-Lagares, Blanca Moreno-Manteca, Gerd Volland, Patricia Bargiela-Perez, Martin Jorgen & Jose-Luis Gutierrez-Perez, Spain



Introduction

The laser has been used in the field of oral surgery for a wide range of indications. In this article, we focus on its surgical uses. The success of the surgical treatment of lesions in the oral cavity depends greatly on knowledge of the aetiology and histology of the lesion. There are pathologies that can be treated with laser, such as cancer sores and hyperkeratosis. Others, like candidiasis, cannot be treated with laser. Furthermore, laser has quickly become a predictable and favourable treatment modality for leukoplakia, haemangioma and epulis.

In vitro studies

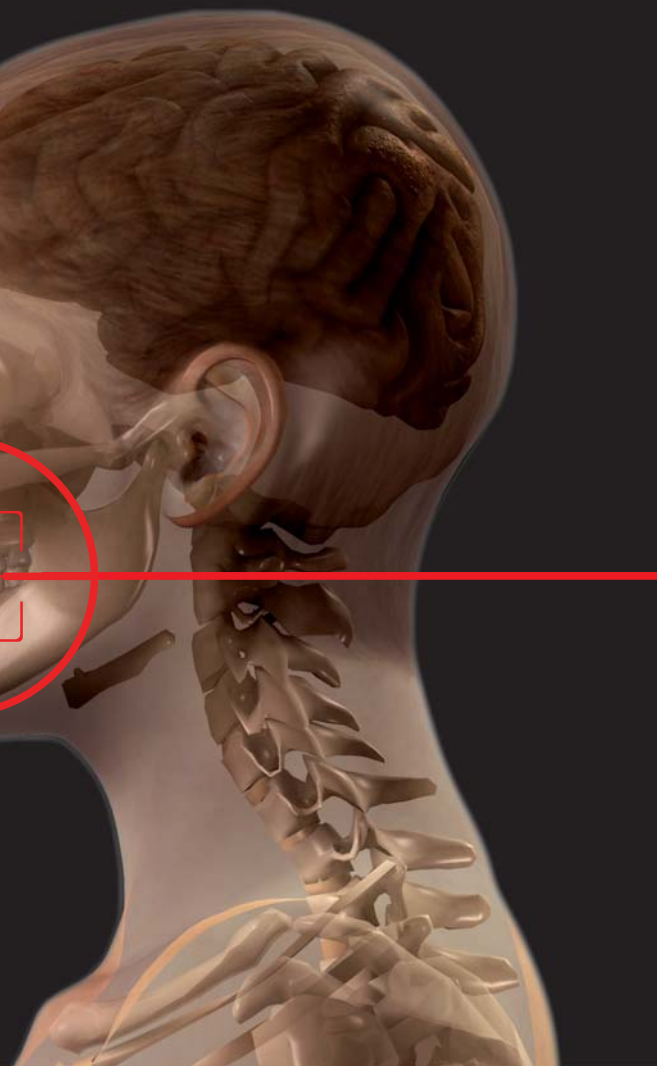There have been only few in vitro studies on the application of laser in oral surgery. For example, the study by Leco Berrocal et al.¹ explored the power of Er:YAG laser sterilisation on dental structures and dental roots in particular. Microbiological cultures indicated lower growth of bacteria after increased

energy irradiation, correlating higher energy irradiation with a greater sterilising effect of the Er:YAG laser.

In vivo studies on animals

One of the most important contributions to research in the period studied is that by Silvestri et al.² It describes the possibility of avoiding the development of a third molar via laser treatment. The use of a diode laser (20 W) in the development area of the third molar in newborn rats was able to halt the development of the tooth by 80% with only few side-effects.

Silvestri et al.² also applied this model to dogs. They employed a diode laser at either 20 W or 100 W in the formation area of the molar at the age of six to seven weeks when it begins to form. In those places where 20 W was applied, the molar continued its development, but this development was halted at 100 W. These findings indicate new



cal perspective. During the healing process, they detected similar changes in the two groups in the study overall. However, they identified TGF- β 1 as lower in the scalpel wounds on the first post-operative day than in the laser wounds. At seven days, the TGF- β 1 level was high in the scalpel group only. Therefore, they concluded that the highest tissue damage occurred in the wounds made by the diode laser, although they considered it a good cutting device for oral mucosa.

Yamasaki et al.⁶ studied coagulative necrosis in the gingiva of rats produced by irradiation with a CO₂ laser in pulsed mode and at low power. The structural characteristics of the injury and the subsequent healing process were examined in terms of histology, immunohistochemistry and

electron microscopy. The study suggested that coagulative necrosis produced by the CO₂ laser does not alter healing, but it promotes its steady progress and subsequent tissue remodelling.

A similar study was conducted by D'Arcangelo et al.,⁷ who examined the effects of scalpel versus diode laser treatment (808 nm, 4 and 6 W) with regard to the expression of eNOS and iNOS from an immunohistochemical perspective. At the histological level, the results partly agreed with the results of Jin et al.⁵ and partly with Yamasaki et al.,⁶ given that the group with the worst healing was that treated with the diode laser (6 W). The results, however, were also similar to those of the scalpel and the diode (4 W) group. Immunohistochemically, the concentrations of eNOS and iNOS were greater initially than seven days after the treatment in the laser group.

Demir et al.⁸ studied the influence of low-level laser therapy (LLLT) on the healing of the oral mucosa. They applied LLLT to wounds inflicted by scalpel and laser, noting improved clinical scarring in both of the groups when using LLLT. A histological analysis showed an improvement in epithelisation when LLLT was applied.

Finally, the study by Seoane et al.⁹ is noteworthy, in which the thermal damage and the histological types resulting from the use of laser are relevant to decision-making regarding biopsies. This study examined the wounds caused by the CO₂ laser in 25 Sprague rats, assigned randomly to five groups: four pilot groups in which glossectomies were performed using a CO₂ laser (3, 6, 9 and 12 W); and one control group treated with a scalpel. Samples were prepared, then stained and

avenues to be investigated with application to humans.

Lasers have already been used satisfactorily for the treatment of various diseases in animals. For example, Lewis et al.³ addressed stomatitis in a cat with a CO₂ laser. Kovács et al.⁴ removed proliferative inflammatory eosinophilic granulomatosis from a cat's tongue with a diode laser. This helped them to control bleeding, which had been impossible before owing to the high number of blood vessels in the area.

***In vivo* studies on humans**

Wound healing

Several new studies have added to the body of recent research on surgical scarring owing to laser treatment. Jin et al.,⁵ for example, analysed the healing of incisions made by scalpels and diode and Er,Cr:YSGG lasers in the mucosa of guinea pigs from both a histological and immunohistochemi-

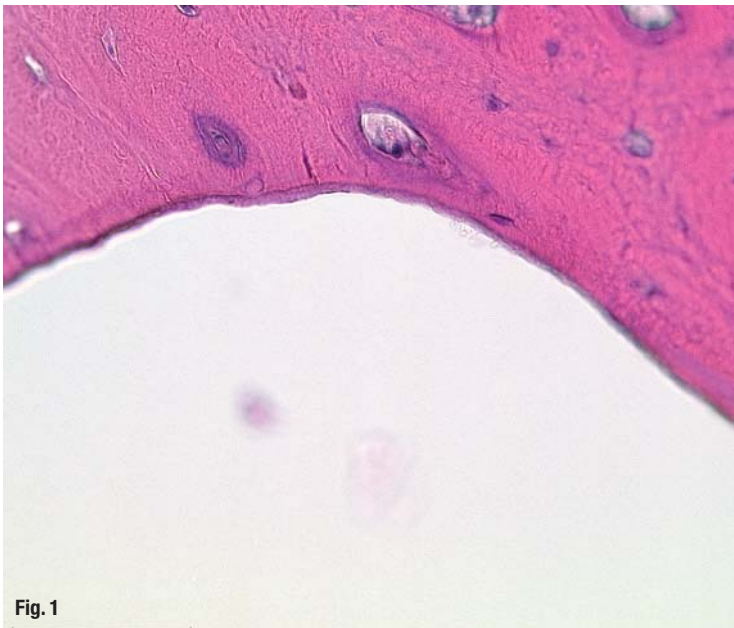

Fig. 1

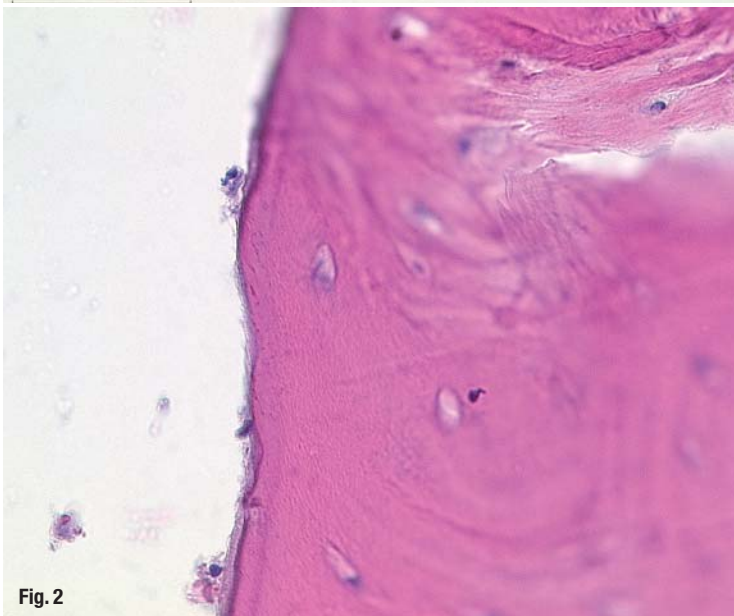


Fig. 2

Fig. 1 Histological section of the bone: very small zone of necrosis, approximately 12 µm. Er:YAG application (200 mJ, 10 Hz, 400 µs, pulse, with spray).

Fig. 2 Histological section of the bone: very small zone of necrosis, approximately 11 µm, osteoblasts are not altered. Er:YAG treatment (200 mJ, 10 Hz, 100 µs, pulse, with spray).

a double-blind study conducted on them by two pathologists. Cellular and nuclear polymorphism, nuclear aberration and the loss of intercellular adhesion were identified, especially in the basal and supra-basal layers of the oral epithelium, but no differences between the experimental groups were observed. No histological or structural changes were observed in the control group. For all these reasons, the CO₂ laser (3–12 W) should be considered to generate epithelial damage which can simulate dysplasia. This, in turn, can lead to an unsuccessful therapy.

Bone studies

There are no larger studies that provide new evidence for the results already mentioned in the previous section. Pourzarandian et al.¹⁰ confirmed that osteotomies carried out with Er:YAG laser, CO₂

laser or a surgical bur resulted in greater revitalisation of osteoblasts and fibroblasts and more pronounced revascularisation in the tissue treated with the Er:YAG laser. The study by Martins et al.¹¹ found that the healing of an osteotomy in the jaw is improved after Er:YAG laser treatment compared with wounds inflicted by a mechanical bur or CO₂ laser. For this reason, long-term studies of 60 to 90 days are needed in order to provide more evidence to support these findings. Accordingly, many studies on these issues have been published in recent years. Other studies, such as Rochkind et al.,¹² have confirmed the positive effect of LLLT on the healing of bone tissue (see histological sections, Figs. 1-3).

Clinical studies

Soft-tissue surgery

Studies on soft-tissue surgery have investigated heat damage in biopsies, the need for anaesthetic, post-operative pain, as well as intra- and post-operative complications with regard to scalpel versus laser treatment. Tuncer et al.¹³ confirmed that the CO₂ laser produces less damage in soft-tissue surgery than the scalpel. In particular, they found a 50% reduction in the need for use of anaesthetic, as well as a 60% reduction in the number of patients who needed analgesic medication post-operatively. No complications were observed for either of the two groups, and the authors suggested that thermal changes had not affected the histopathological results. The findings are in agreement with other studies published recently, for example Stübinger et al.¹⁴

The study by Matsumoto et al.¹⁵ provides further findings concerning soft-tissue surgery. It compared the emergence and importance of changes at the margins of the biopsies taken by CO₂ laser (in continuous wave and pulsed mode) and through electrocautery. Thermal changes associated with the biopsy instrument were found in all of the samples, but these changes were more significant in the electrocautery group and continuous-wave laser group. Therefore, the authors recommend the use of the CO₂ laser in pulsed mode in order to minimise changes caused by thermal effects.

Vescovi et al.¹⁶ further explored the suitability of various laser types for biopsies. They studied thermal changes that can alter the pathological diagnosis and assessed resection margins in three groups. Group I consisted of six specimens of human oral mucosa removed using an Nd:YAG laser at a power of 3.5 W and frequency of 60 Hz. Group II consisted of nine specimens removed via an Nd:YAG laser at a power of 5 W and frequency of

30 Hz. Lastly, group III consisted of 11 specimens removed using a #15c Bard-Parker scalpel blade. Their results indicated that the thermal effect of laser on biopsies introduced slight changes at the edges of the specimen. When the laser was used for incisions exceeding 7 mm and at a lower power and high frequency, these results were improved (group I, Nd:YAG—3.5 W, 60 Hz).

Kafka et al.¹⁷ explored the application of diode lasers in the treatment of soft-tissue conditions such as epulis fissuratum. These study found that this kind of laser operates optimally. Similarly, studies that evaluate the treatment of tongue lesions by diode laser, for example the study by Saleh and Saafan,¹⁸ come to the same conclusion.

Cancer treatment via CO₂ laser

Although mucoepidermoid carcinoma is painless and usually does not produce metastases or recur, it must be treated both surgically and with post-operative radiotherapy. The study by Leong et al.¹⁹ advanced the research done so far on the use of laser for the treatment of cancer. They report on the case of a patient with mucoepidermoid carcinoma at the base of the tongue. The authors applied CO₂ laser and achieved very good results.

The changes produced by laser during the surgical excision of precancerous lesions and their possible influence on accurate diagnosis have been widely discussed. Goodson and Thomson present²⁰ 169 cases of oral premalignant lesions removed via CO₂ laser and their subsequent monitoring over several years. A positive correlation was found between the results of the biopsies and those of the histological studies of the tissue removed by laser. Furthermore, hidden invasive carcinoma was identified in 15 patients and removed by laser.

In seeking to determine the recurrence of lesions removed by laser, Hamadah and Thomson²¹ followed 78 patients whose precancerous or dysplastic lesions were treated with a CO₂ laser over a period of at least two years. By the end of this period, 64% of the patients were free of the disease, 32% developed recurrent local dysplasia or dysplasia in new sites and 4% developed squamous cell carcinoma at sites different from their initial disease. The margins of the excisions were clear in 55% of the cases. However, 19% showed mild, 21% moderate and 5% severe dysplasia in the histopathological examination. The authors recommend the CO₂ laser for the excision of lesions, stating that in their study it allowed for complete histopathological evaluation and resulted in minimal post-operative morbidity and 64% of patients free of the disease.

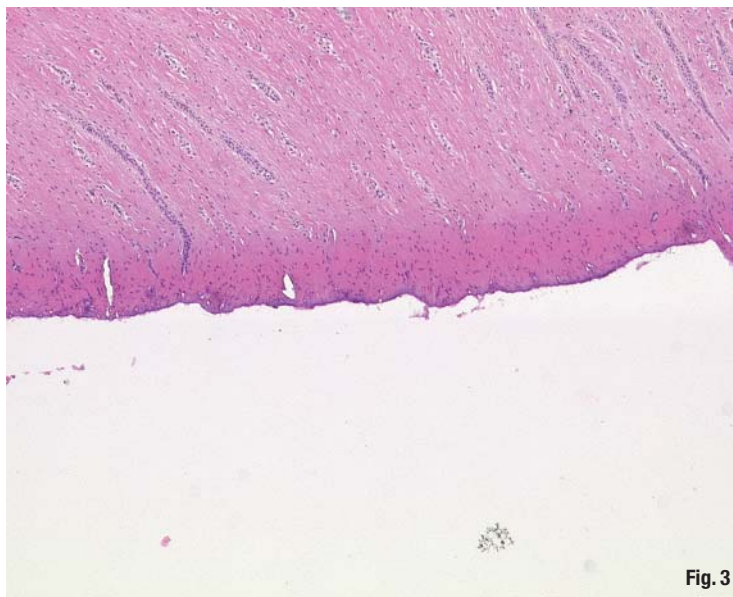


Fig. 3 Histological section of the gingiva: effect of heat accumulation at the surface, necrosis of about 45 µm. Er:YAG treatment (200 mJ, 10 Hz, 1000 µs, pulse with no spray).

Cancer treatment via photodynamic therapy

Photodynamic therapy (PDT) has demonstrated efficacy in the treatment of dysplasia and early forms of microinvasive oral cancer. Clinical studies such as the study by Mang et al.²² support this view. Mang et al.²² present a case of squamous cell carcinoma of the maxillary gingiva, which was successfully treated with PDT, sparing the patient surgery and radiation therapy.

Similarly, Schweitzer and Somers²³ evaluated the efficacy of the Photofrin-mediated PDT for the treatment of diffuse field cancerisation in 30 patients for whom conventional treatment had failed. In 80% of the patients, there was complete remission, and the remaining 20% showed partial remission. After two years, 11 of the 24 patients with complete remission were cancer free. PDT is also a form of cancer treatment suitable for the treatment of oropharyngeal tumours, either primarily or in patients whose previous surgeries or radiotherapies have failed.

Editorial note: To be continued with more treatment options and the final conclusion in the next issue of laser.

| | |
|--------------------------------------------------------------------------------------------------------------------------------------------------------------------------------------------------------------------------------------------|-------|
| _contact | laser |
| <p>Prof Dr MSc mult Gerd Volland</p> <p>Facultad de Odontología Cirugía bucal Universidad de Sevilla C/ Avicena s/n Sevilla, Spain</p> <p>dr.volland@t-online.de</p> | |

Influences on the treatment of recurrent aphthous ulcers with the Nd:YAG laser

An initial first clinical investigation—Part I

Author_Dr Iris Brader, Germany

_Introduction

The Greek word aphthi, which means "burning, to set on fire or to inflame", was first used by Hippocrates for the clinical symptoms of recurrent aphthous stomatitis (Ship 2000; Scully 2002). These ulcerations affect 5 to 25% of the general population and in select groups, for example students at examination time, prevalence can be more than 50% (Reichardt 2000; Scully 2002). The typical lesion involves self-limited, painful, clearly defined, shallow, round or oval 1 to 3 mm ulcers, each with a shallow necrotic centre. They are covered with a yellow-greyish pseudomembrane and are surrounded by minimally raised margins and an erythematous halo, and they tend to heal within ten to 14 days. We differentiate between three forms: minor, major and herpetiform aphthae (Ship 2000; Scully 2002; Scully 2003).

The diagnosis is almost entirely made on the basis of clinical criteria and the history of an otherwise usually healthy person. The aetiology is still unclear and it

is probable that it is multifactorial, resulting in a variety of predisposing and immunological factors. These may be provoked by one or several different contributing factors and associated conditions. Recurrent aphthae can also be associated with systemic disorders (such as Behçet's disease, Reiter's syndrome, gastro-intestinal diseases), drug reactions or immune disturbances (Scully 2002; Porter 2005). Since there is no conclusive evidence for the aetiology, the therapy is non-specific and attempts to treat symptoms (Scully 2002). This can be achieved through:

- exclusion of triggers;
- physical methods (surgery, laser ablation, cauterisation);
- topical agents (local anaesthetics), antimicrobials (chlorhexidine), corticosteroids, immunomodulatory agents (prostaglandin E2);
- systemic treatments (corticosteroids, thalidomide);
- laser treatment (low-level laser, Nd:YAG in non-contact mode).

Fig. 1a In this case we see a five year-old girl. Her grandmother brought her into our praxis, because she had been suffering from acute ulcer pain for five days.

Fig. 1b The aphthous ulcer was treated with the described parameters. On the next day, the girl was free of pain and the ulcer was smaller.

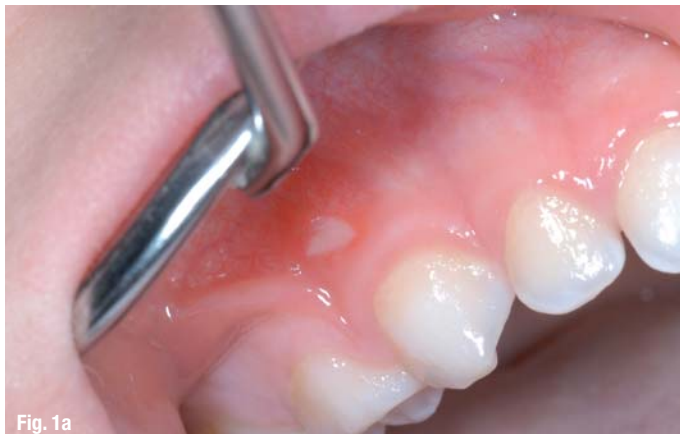

Fig. 1a

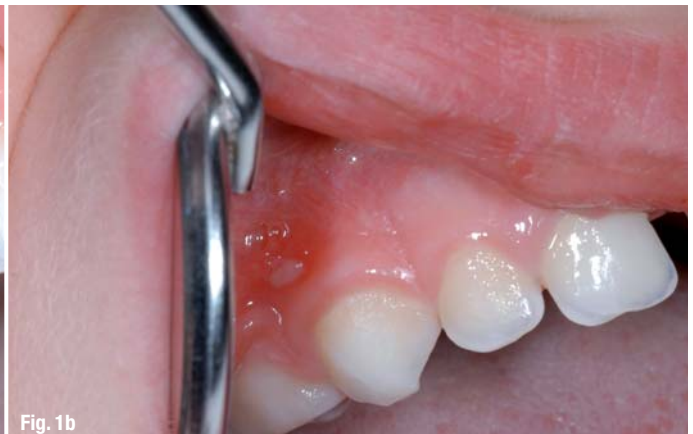

Fig. 1b

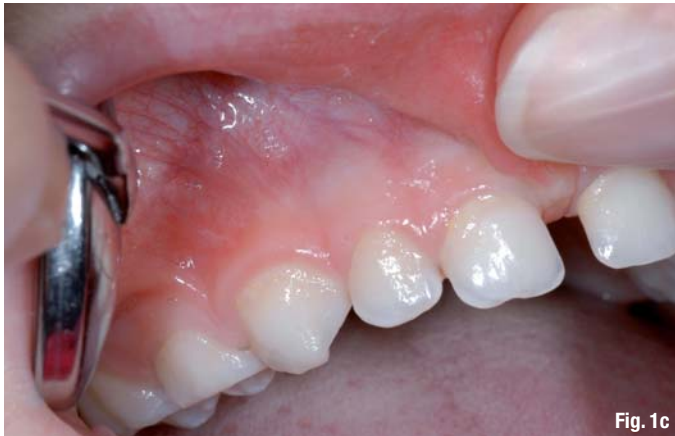

Fig. 1c

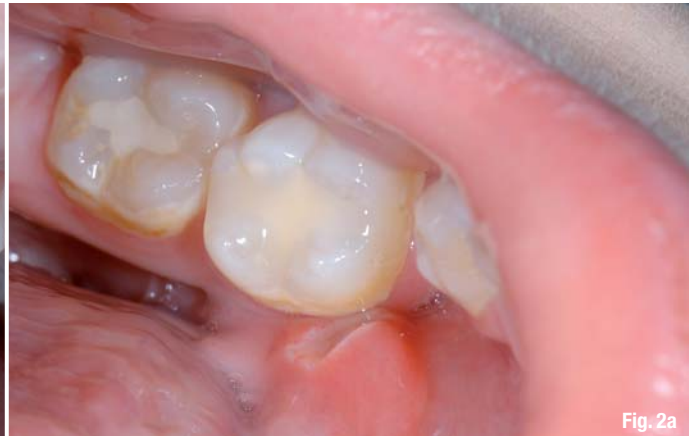

Fig. 2a

Systemic treatment should be warranted only in patients with severe and frequent ulcerations because they may have many severe adverse side-effects.

Aim of the investigation

Treatment with the Nd:YAG laser may reduce or stop ulcer pain and promote healing, but not in all cases. The aim of this investigation is to determine the extent to which certain factors influence treatment with the Nd:YAG laser.

Method and materials

A total of 61 aphthous ulcers were treated, but only 45 could be documented completely. Patients suffering from a painful aphthous ulcer at the time were

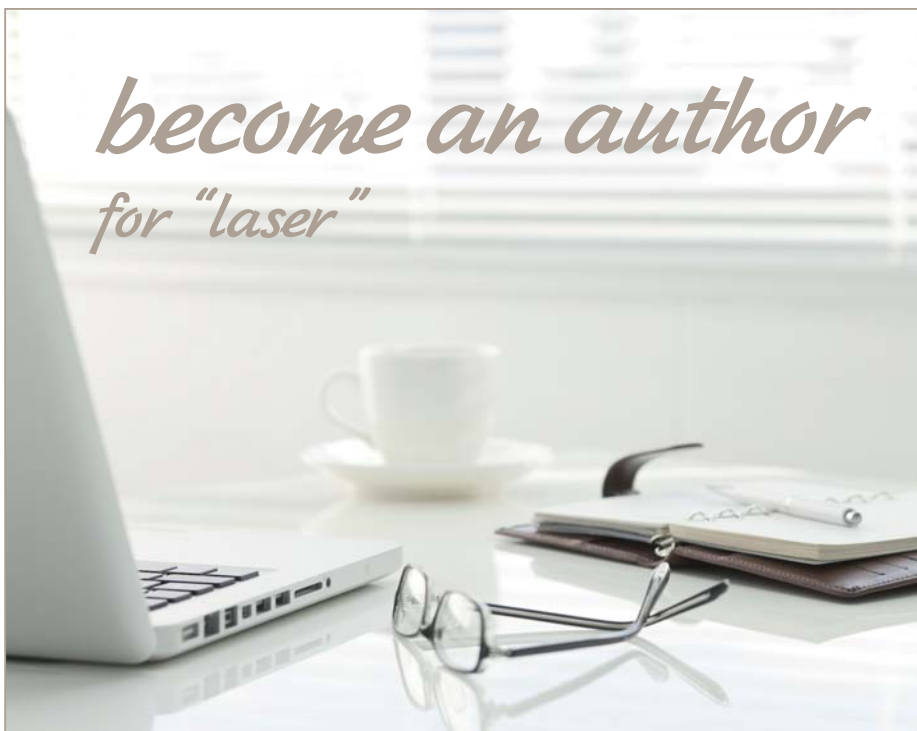chosen to participate in clinical trials. Informed consent was obtained. In documenting the cases, we first took a complete and detailed patient history using a standardised form, followed by the specific history and diagnostic investigations of the aphthous ulcer, especially with regard to the following: day of formation; size; location; morphological description; intensity of the pain (intense/moderate/none).

In addition, two pictures of the ulcer were taken at each session. We used an Nd:YAG laser (Pulsmaster 1000, ADT) with a 300 µm fibre for treatment. Following Gutknecht (1999), the applied physical parameters were a pulse energy of 80 mJ and a frequency of 30 Hz (power setting 2.4 W). The pulse width was 100 µs and the effective energy density amounted to 113 J/cm². The irradiation was done in non-contact mode from 10 to 2 mm towards the ulcer at a rate of approximately

Fig. 1c Three days after the treatment with the Nd:YAG laser the ulcer had healed.

Fig. 2a 11/05/05: extremely painful ulcer with a size of 8x5 mm.

AD



Please contact Dajana Mischke
 ✉ d.mischke@oemus-media.de

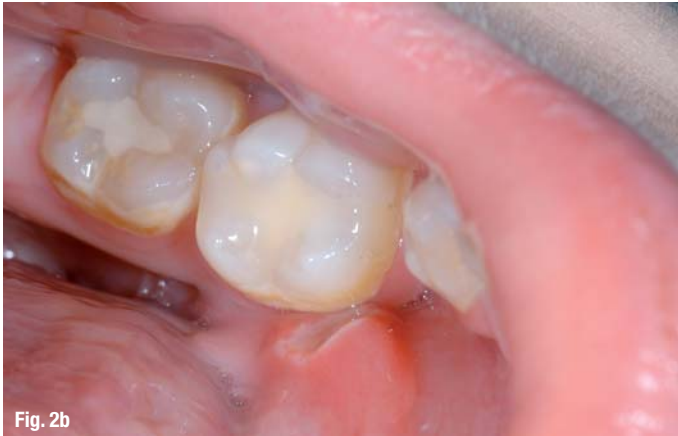

Fig. 2b

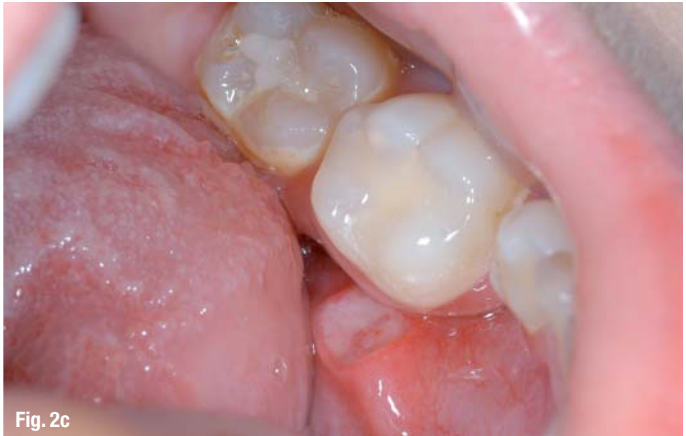

Fig. 2c

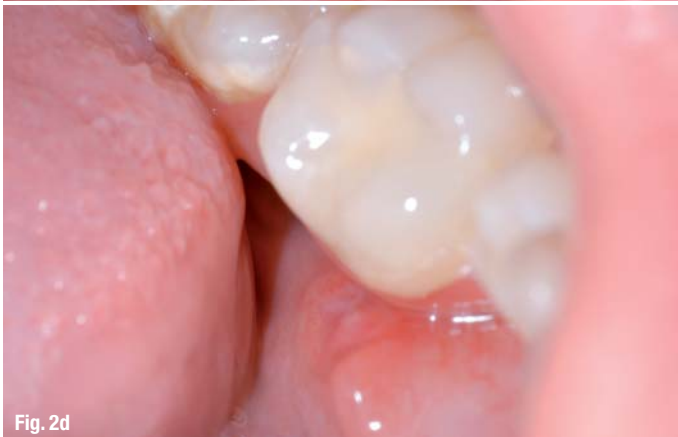

Fig. 2d

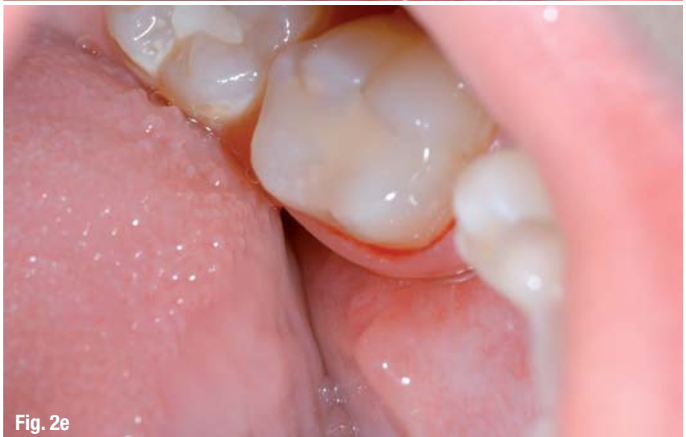

Fig. 2e

Fig. 2b & c_12/05/05 and 13/05/05: no change in size or pain relief.

Fig. 2d_Ulcer four days after treatment.

Fig. 2e_Six days after treatment: scar-like impression.

30 s/cm². We examined and documented the ulcers every one and three days (Figs. 1a–c). The effectiveness of the treatment was evaluated according to whether patients experienced no or reduced pain and the healing time.

Case report

A 24-year-old female patient came to us on 11 May 2005 with an extremely painful ulcer in the base of her mouth. The patient had no systemic disorders but had compromised general health because ingestion had been nearly impossible for days. The patient was a non-smoker.

The aphthae appeared ten days before and she had suffered from acute and intense pain for five days (Fig. 2a). Swallowing, speaking and even rinsing her mouth with water caused an intense burning sensation. The patient had occasionally had ulcers of this kind in the past, but normally they healed within three to four days. The patient had tried to treat the ulcer with chlorhexidine, but the pain was too intense. Our first treatment was the smoothing of the distolingual cusp and application of a topical local anaesthetic (Dynexan, Kreussler). Since there was no change in either pain or size (Figs. 2b & c), we decided to modify the treatment and use laser. The irradiation was done as described for 50 seconds. The patient told us by phone

that as early as the afternoon of the same day the pain was reduced. On the next day, she felt no pain at all. Four days later, the re-epithelisation was nearly complete (Fig. 2d). Six days after the laser treatment, the tissue appeared to be rough and scarred (Fig. 2e).

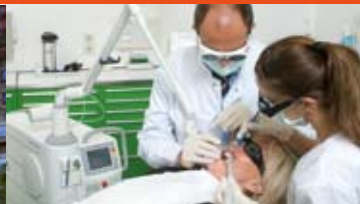The topical drugs used initially (chlorhexidine) had no or only a limited pain-relieving effect for some minutes (local anaesthetics) and resulted in no changes in size. After the laser treatment, we obtained symptomatic relief almost immediately and the patient did not feel any further pain the following day. Symptomatic relief is possible also in aphthous ulcers that persist for longer periods.

Editorial note: To be continued in our next issue of Laser. A list of references is available from the publisher.

| | |
|----------------------------------------------------------------------------------------------------------------|--------------|
| _contact | laser |
| <p>Dr Iris Brader Bernhardtstr.1 98617 Meiningen Germany</p> <p>Iris.Brader@t-online.de</p> | |

**Lay the Foundations to your
successful Future now!**

The next Master programme starts on **24 September 2012** in Aachen



Master of Science (M.Sc.) in Lasers in Dentistry

Become a part of the International Dentists' Elite!

- The first accredited M.Sc. programme in dentistry in Germany
- Career-accompanying postgraduate programme of two years at the University of Excellence RWTH Aachen
- Combination of lectures, skill training sessions, live ops, tutorials, and practical workshops
- Internationally accepted and accredited by the German Government, the European Union, the Washington Accord and the Bologna Process
- Science-based and practice-orientated on highest national and international level



Aachen Dental Laser Center

More information:

AALZ GmbH · Pauwelsstrasse 17 · 52074 Aachen · Germany
Tel. +49 - 2 41 - 47 57 13 10 · Fax +49 - 2 41 - 47 57 13 29
www.aalz.de · info@aalz.de

**RWTHAACHEN
UNIVERSITY**

Treatment of chronic periodontitis by laser and LED-PDT light

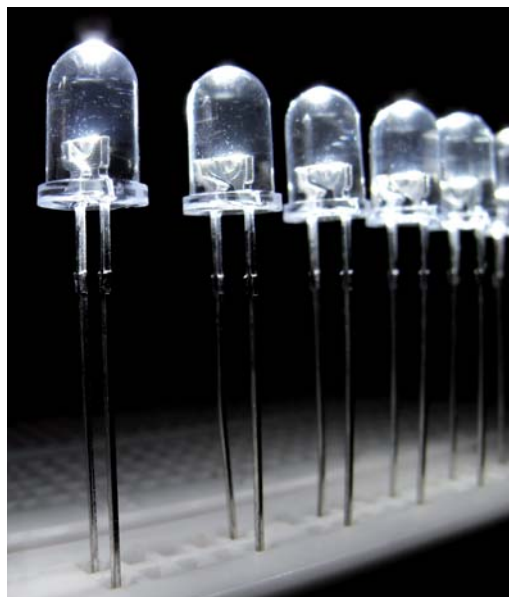
An *in vivo* study

Authors_Dr G. Karakitsos & Dr J. Karakitsos-Kurz, Greece

_Introduction

Periodontitis is a very common disease among adults, with approximately 80% having gingivitis and periodontitis, and 65% showing signs of periodontitis.¹ It is a major cause of tooth loss in adults and primarily considered an anaerobic bacterial infection, caused by the red complex species. Bacteria within a biofilm community, as well as enzymes, endotoxins, and other cytotoxic factors from these bacteria, lead to tissue destruction and the initiation of chronic inflammation.²

The conventional treatment entails the mechanical removal of calculus and the micro-organisms through scaling and root planning (SRP). Antimicrobial agents, used systemically or via local drug deliv-



ery, further suppress the periodontal pathogens, thus increasing the benefits of conventional mechanical therapy. However, this conventional mechanical treatment of periodontitis is not always sufficient. Moreover, the emergence of resistant micro-organisms and a shift in the microflora after extended antimicrobial application limits their effect. Other approaches to the local delivery of antimicrobial agents have been investigated, including the use of high-energy pulsed lasers and photodynamic therapy (PDT).³

The Nd:YAG laser has been used in dentistry for nearly 20 years, primarily in minor surgery and endodontics. Nd:YAG laser energy is absorbed by tissues and it is this absorbance that allows surgical excision and coagulation of tissue.⁴ The 1,064 nm wavelength has a particular affinity towards melanin or other dark pigments. Therefore, darkly pigmented microbes are more sensitive to this laser and can be eliminated at very low power settings with no collateral damage to the adjacent tissue. Harris and Yessik⁵ developed a method for quantifying the efficacy of ablation of *Porphyromonas gingivalis* *in vitro*, using two different lasers.

Free-running pulsed Nd:YAG laser systems can generate high peak powers, at which the individual pulse power can reach several thousand watts. It allows this type of laser to deliver the required energy to the target tissue before the absorbed heat can dissipate from the treated area.

_Water-spray cooling

Although no comparative studies have been conducted on the need for water-spray cooling in both

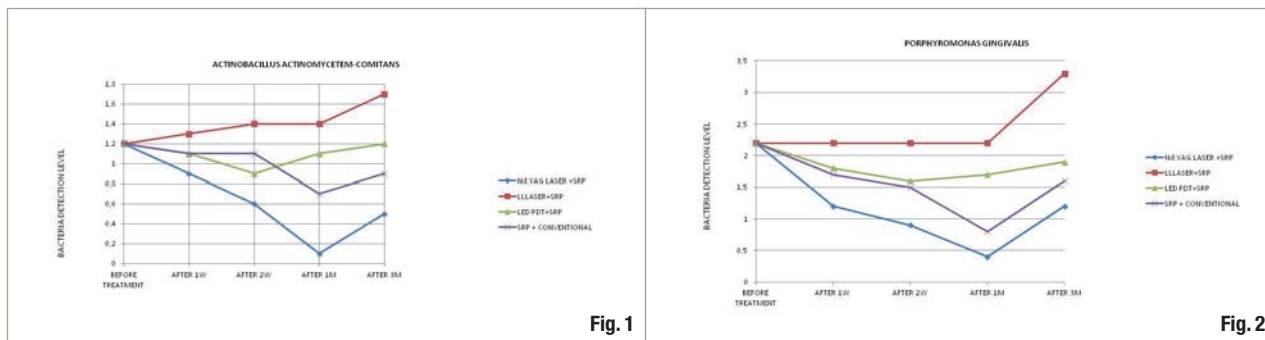


Fig. 1

Fig. 2

diode and Nd:YAG laser procedures, water-spray can be said to be counter-productive from a biophysical point of view. Water is a good heat conductor and removes heat, whereas a thermal effect is desired. Cooling at the tissue surface is associated with the risk of deeper tissue necrosis. Therefore, water-spray should not be used in diode laser procedures.

For this reason, this study made use of an Nd:YAG laser without water and only with air spray.³

LLLT lasers

The treatment of periodontitis with low-level laser therapy (LLLT) has not been common to date, and only a limited amount of literature exists. In a blind study by Qadri et al.,⁶ the clinical parameters, such as probing of the pocket depth, plaque index and gingival index, were more strongly reduced on the laser side than on the placebo side, with $p < 0.01$. The wavelengths used for LLLT have poor absorption in water, allowing for a penetration depth in soft and hard tissue ranging from 3 to 15 mm. As the energy penetrates tissues, it is scattered by both erythrocytes and micro-vessels. Because of this, both blood distribution and the network of micro-vessels in the tissue influence how the laser-light works, much like a bio-laser. LLLT lasers do not cut or ablate, but they use a photobiological process, which can have positive effects on periodontal healing and pain relief. LLLT is optimal for cells in a reduced oxygen environment.⁷

Photodynamic therapy

PDT protocols use diode lasers or LED light with wavelengths that range from 635 to 690 nm, combined with a photosensitiser to eradicate sub-gingival microbes. PDT, which is also known as photo-radiation therapy, phototherapy or photochemotherapy, involves the use of a photoactive dye (photosensitiser), which is activated by exposure to light of a specific wavelength in the presence of oxygen. The transfer of energy from the activated photosensitiser to available oxygen results in the formation of toxic oxygen species, such as singlet oxygen and free

radicals. The oral cavity is especially suitable for photodynamic antimicrobial chemotherapy (PACT) because it is relatively accessible for illumination.⁸

Dye concentration is a very important factor to be taken into consideration, since it results in a limited production of reactive oxygen (ROS) and requires a longer irradiation time. A high dye concentration works as an optical filter because of the resulting high absorption effect. The present study made use of a toluidine blue photosensitiser with a low concentration of 0.01 %, ensuring that soft-tissue irradiation and hard-tissue staining do not occur.

A semiconductor laser, such as the GaAlAs laser used in this study, has a coherence length of a few millimetres. This is very important, since the laser light produces constructive interference in tissue and consequent speckle formation. In contrast, LED light does not create speckles. These LED-light sources have a spectral width of 30 to 100 nm. LED reacts with cytochromes in the body. When cytochromes are activated, their energy levels increase, which stimulates tissue growth and regeneration.⁹

Materials and methods

In January 2011, in Thessaloniki, Greece, 12 adults (seven women and five men), with an average age of 47 years (ranging from 29 to 68 years) were randomly assigned for treatment of the left or right side of the mouth. After the second week of the treatment, two patients had to leave the study because they had used antibiotics. The study was continued with ten patients, six women and four men. The patients were questioned about their systemic health status, their use of medication and smoking habits. In all of these cases, the inclusion criteria were periodontal pockets with probing depths deeper than 5 mm, with haemorrhagic findings and clinical signs of inflammation (swelling, secretion, etc.). Those individuals with a medical history of systemic disease requiring medication, those who had undergone antibiotic therapy within a three-month

Figs. 1 & 2 Change in detection levels of five bacteria from baseline (0) to one week and two weeks, to one month, and from one month to three months post-treatment.

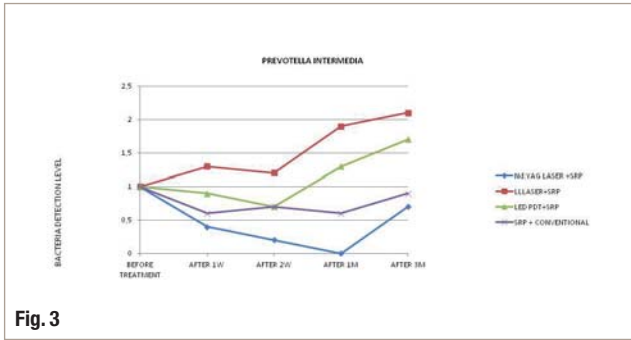


Fig. 3

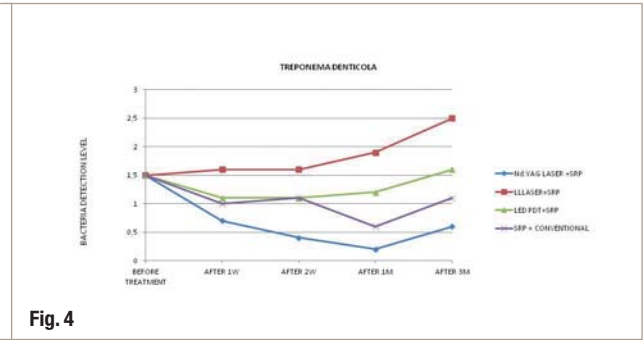


Fig. 4

Figs. 3–5 Change in detection levels of five bacteria from baseline (0) to one week and two weeks, to one month, and from one month to three months post-treatment.

period preceding the study, and those with contagious diseases, as well as pregnant women and nursing mothers, were excluded.

Periodontal examination

At baseline, one trained examiner, who was masked to the test and control groups, measured the clinical periodontal parameters, including BOP (bleeding on probing) and PPD (probing pocket depth). These were measured with a graded periodontal probe (PerioWise, Premier Dental) at six sites. All teeth, except for the third molars, were registered.

Treatment protocols

The patients were randomly divided into four groups, which represented four different treatment modalities. At baseline (day 0), the patients assigned to group I received a one-hour session of full-mouth sub-gingival debridement, using a piezoceramic ultrasonic instrument (Piezon Master 400 with A+ PerioSlim tips, water coolant and power setting at 75%; EMS). The patients in group II received SRP with ultrasonic full-mouth debridement and then irradiation with a GaAlAs low-level laser at 830 nm (DIOBEAM, CMS Dental). The patients in group III received SRP with ultrasonic full-mouth debridement and then irradiation with a pulsed Nd:YAG laser at 1,064 nm (Genius). Finally, the patients in group IV received SRP with ultrasonic full-mouth debridement and then irradiation with the LED-PDT laser (FotoSan, CMS Dental).

Clinical parameter measurements

The PPD and BOP were measured for each group before the treatment, as well as one and three months post-treatment. Five clinical samples of gingival crevicular fluid were obtained from each patient and analysed with the DNA reverse-hybridisation laboratory process in the following order: (i) pre-treatment; (ii) one week after the first laser or LED-light session; (iii) one week after the second laser or LED-light session; (iv) one month post-treatment; and (v) three months post-treatment. A total of 200 microbiological samples were taken during the study period.

Laser parameters and lasers

The laser equipment used in this study was an Nd:YAG laser (1,064 nm), a GaAlAs low-level laser (830 nm) and a LED light (625–635 nm). The laser treatment was performed by inserting the optical fibre into the periodontal pocket, almost parallel to the tooth.

The Nd:YAG laser was used with the following settings: an average output of 4 W energy per pulse of 80 mJ; pulse width of 350 μs and pulse repetition rate of 50 Hz; pulse peak power of 228 W; average power density at the fibre end of 1,415 W/cm²; and peak power density of 80,600 W/cm². Laser energy per treated tooth was 240 J. The fibre diameter was 600 μm (0.002826 cm²). Only air cooling (+5 scale) was used during irradiation. The time spent on each tooth was 60 seconds.

The GaAlAs laser was used with the following power-intensity settings: the 8 J button was utilised and energy intensity was 63.5 J/cm². The buccal, palatal and lingual papillae were treated for 53.3 seconds per surface. The irradiated area was 0.25 cm².

The LED light used in this study had an output power of 2,000 mW/cm². The energy density (J/cm²) was not calculated because the energy was emitted not only from the tip, but also with considerable lateral emission. The sites were irradiated from both the buccal and lingual aspects.

Microbiological examination

Sterile paper points (ISO 40) were used for 30 seconds each to harvest sub-gingival plaque. The plaque was taken from the same site as the gingival crevicular fluid samples. After the paper point were collected from each quadrant, they were placed in sterile transport vials and sent to the laboratory for a thorough analysis. The sub-gingival microbiota were analysed using the checkerboard DNA-DNA hybridisation technique.³ Furthermore, the frequencies of positive sites and of sites with colony-forming units ≥10³ were recorded. The following five micro-organisms were analysed: *Aggregatibacter actinomycetemcomitans*, *P. gingivalis*, *Prevotella interme-*

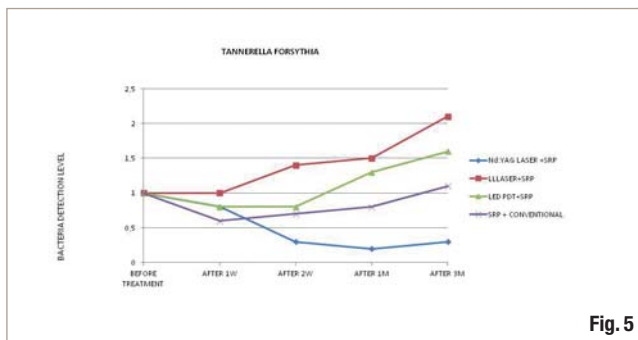


Fig. 5

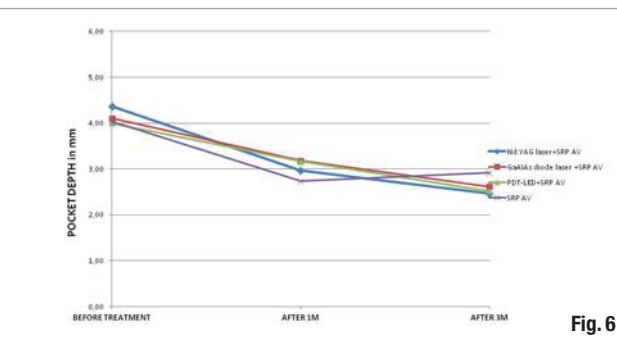


Fig. 6

dia, *Tannerella forsythensis* and *Treponema denticola* ((AID Diagnostika GmbH, Periodontitis++).

Statistical methods

Commercially available software, such as GraphPad Prism 5 by GraphPad Software, was used for the statistical analysis. PPD and BOP were the primary clinical-outcome variables. Mean values and standard deviations (mean ± SDs) for the clinical variables were calculated for each treatment, based on the subject as the statistical unit. The student's t-test was employed for continuous variables (clinical measurements), after the normality of the data distribution had been confirmed.

Similarly, the significance of the difference within each group, pre- and post-treatment, was evaluated with the paired-samples t-test. Differences were considered statistically significant when the p-value was less than 0.05.

The post-therapeutic data in each quadrant was checked against the initial data, using the paired t-test for statistically significant differences. Finally, the data of the quadrants additionally treated with laser was compared to the data of the conventionally treated quadrant as part of an unpaired t-test.

Results

Microbiological results

All of the ten patients attended the baseline examination and the follow-up appointments. In the Nd:YAG laser- and SRP-treated group, it must be emphasised that *A. actinomycetemcomitans* (*A.a.*) levels were significantly reduced over the entire study period. It should also be noted that *A.a.* was reduced during the second week of treatment in the LED PDT- and SRP-treated group. Furthermore, the Gram-negative anaerobic bacteria were significantly reduced in the course of the study in the Nd:YAG laser group, in contrast with a lack of reduction for the other treatment groups. In the GaAlAs laser treated group, the microbiological samples showed an increase from moderate to higher detection levels. This result is in accordance

with evidence in the literature that the low-level laser produces bacterial growth.¹⁰

Clinical results

All treatment groups showed significant decreases in PPD and BOP over the three-month post-treatment period. Baseline PPD was 4.37 (0.7) mm in the Nd:YAG quadrant, 4.10 (0.37) mm in the GaAlAs laser quadrant, 4.00 (0.4) mm in the LED-PDT quadrant and 4.03 (0.35) mm in the SRP quadrant. After three months of treatment, PPD was 2.47 (0.32) mm in the Nd:YAG quadrant, 2.62 (0.16) mm in the GaAlAs laser quadrant, 2.52 (0.29) mm in the LED-PDT quadrant and 2.92 (0.18) mm in the SRP quadrant. The reduction in PPD was significantly greater in the test group than the control group.

Baseline BOP for the Nd:YAG laser quadrant was 12.4. It decreased to five after one month and to zero after three months. For the GaAlAs laser quadrant, the baseline was 11.9, and BOP was 2.4 after one month and 0.5 after three months. In the LED-PDT quadrant, the baseline was 11.7, and BOP was 3.7 after one month and 0.8 after three months. For the SRP quadrant, the baseline was 12.3, and BOP was 4.9 after one month and 2.3 after three months.

For the PPD parameter, no significant difference could be established when comparing the four treatment methods used in this study directly. For the BOP index, the number of the haemorrhagic points clearly decreased in the quadrants treated with laser (Nd:YAG or GaAlAs laser) and with LED PDT, as compared with the one treated conventionally (Figs. 1–9).

Discussion

The results in this study demonstrated that, when compared with the inflammation seen after non-surgical treatment, additional treatment with the Nd:YAG laser, GaAlAs laser and LED-PDT light led to further reduction in gingival inflammation. Both the PPD and the number of BOP findings declined more

Fig. 6 Change in PPD from baseline to one month and from one month to three months post-treatment in test and control teeth.

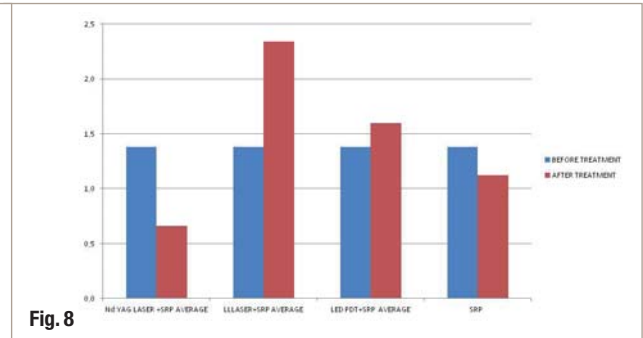
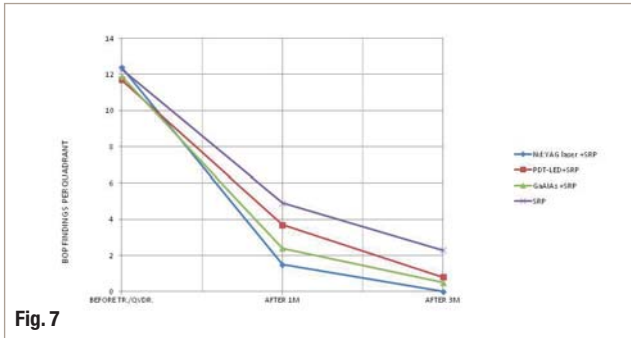


Fig. 7 Change in BOP findings per quadrant from baseline to one month and from one month to three months post-treatment in test and control teeth.

Fig. 8 The post-therapeutically established data in each treated quadrant was checked with the initial data for statistically significant differences with the help of a paired t-test.

in the quadrant in which these additional treatments were performed.

The average values of the five microbial species that were investigated in this study were lower in the quadrants treated with Nd:YAG laser and SRP than in the quadrants that had been treated with GaAlAs laser and SRP, LED PDT and SRP, and conventional SRP. There were statistically significant differences in favour of the Nd:YAG laser method, especially in the first seven weeks. These findings confirm the findings from the study by Gutknecht et al.,¹¹ which demonstrated a reduction of specific micro-organisms in periodontal pockets when conventional treatment was supported by the use of an Nd:YAG laser.

Recurrence is reported in several studies and is attributed to cross-contamination from non-treated pockets and/or saliva.¹² In the present study, the Nd:YAG laser group was found to have a significant reduction in the levels of *A.a*.

The LED-PDT group also showed a reduction in *A.a* levels, although this short-term decline was followed by a reappearance of the *A.a*. Both the GaAlAs laser and the LED-PDT groups, with toluidine blue as an adjunct to conventional SRP treatment, showed beneficial effects in clinical parameters like PPD and BOP, in comparison with the conventional SRP treatment.⁶ One explanation may be that laser irradiation reduces prostaglandin E₂, or that it causes stimulation of cellular ATP. The GaAlAs laser also seems to have a stimulating effect on bacterial

growth, confirming similar findings in the scientific literature.¹³

However, certain pathogens, such as *A. actinomycetemcomitans* and *P. gingivalis*, are particularly resistant to the effects of sub-gingival debridement. This has been linked to their ability to invade the pocket epithelium and underlying connective tissue.¹⁴

Conclusion

The results of this study prove the positive role of coherent or non-coherent light irradiation as adjuncts to SRP in the non-surgical treatment of periodontitis. The ability of the Nd:YAG laser to reduce the levels of oral bacterial pathogens is much higher than that of LED PDT. Possibly one very important factor for the success of laser treatment is the regeneration of periodontal tissue, and it is best achieved by initially reducing the bacterial load.

LED PDT could be used as an alternative periodontal treatment after an initial treatment phase with the Nd:YAG laser. It should be limited to periods between treatment recalls. The short-term effect of LED PDT is sufficient to prevent a quick bacterial recolonisation of affected sites, especially in high-risk patients.

Editorial note: A complete list of references is available from the publisher.

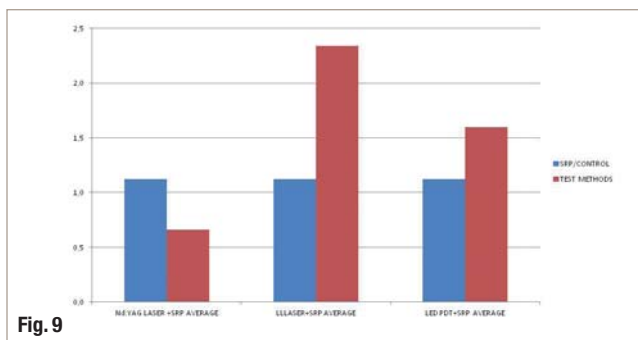
_contact
laser

Dr G. Karakitsos and Dr J. Karakitsos-Kurz
 Private Dental Clinic
 Krithia 1, Dimos Lagada
 57200 Thessaloniki
 Greece

Tel.: +30 69 3 666 0135
 Fax: +30 23 9 405 4458

georgekaraki@yahoo.gr

Fig. 9 The data gathered in those quadrants that were additionally treated conventionally with the Nd:YAG laser, GaAlAs laser and LED PDT was compared with the data of the conventionally treated quadrant as a part of an unpaired t-test.



42ND

October 5-6, 2012//Hamburg, Germany//Elysee Hotel

Congress President//Prof. Dr. Dr. Frank Palm/DE

Scientific Director//Dr. Roland Hille/DE

INTERNATIONAL ANNUAL CONGRESS OF THE DGZI



Quality driven implantology –
On the way to long term success

Speakers


Prof. Dr. Dr. Kai-Olaf Henkel/DE
Prof. Dr. Dr. George Khoury/DE
Prof. Dr. Dr. Albert Mehl/CH
Prof. Dr. Herbert Deppe/DE
Prof. Dr. Werner Götz/DE
Prof. Dr. Shoji Hayashi/JP
Prof. Dr. Andrea Mombelli/CH
Prof. Dr. Dr. Frank Palm/DE
Prof. Dr. Suheil Boutros/US
Prof. Dr. Peter Rammelsberg/DE
Prof. Dr. Anton Sculean/CH
Prof. Dr. Dr. Jörg R. Strub/DE
Prof. Dr. Hans-Peter Weber/US

Prof. Dr. Thomas Weischer/DE
Priv.-Doz. Dr. Andreas Bindl/CH
Dr. Tomohiro Ezaki/JP
Dr. Daniel Ferrari, MSc/DE
Dr. Sami Jade/LB
Dr. Ramy Fahmy Rezkallah/EG
Dr. Rolf Vollmer/DE
Dr. Osamu Yamashita/JP
ZTM Andreas Kunz/DE
ZTM Tom Lassen/DE
ZTM Christian Müller/DE
Mohamed Moataz M. Khamis
B.D.S., M.S., Ph.D./EG

Gold Sponsor:



Silver Sponsor:



Bronze Sponsor:



FAX REPLY

+49 341 48474-390

Please send me further information on the
42ND INTERNATIONAL ANNUAL CONGRESS
OF THE DGZI October 5-6, 2012, in Hamburg, Germany.



Office Stamp

Laser treatment of dentine hypersensitivity

An overview Part I

Authors Dr Ute Botzenhart, Dr Andreas Braun & Prof Matthias Frentzen, Germany

Introduction

More than two decades ago, laser applications in the treatment of dentine hypersensitivity were introduced to dentistry. Many clinical studies using different laser types have been published since. This overview summarises the basic and clinical aspects, including treatment protocols.

The hypersensitive dental neck

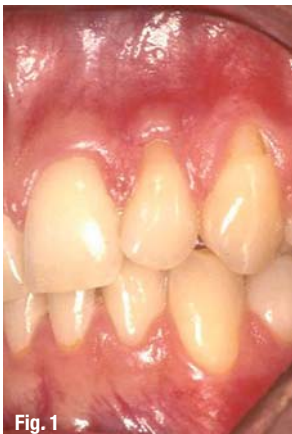Dentine hypersensitivity is a widespread painful condition in dentistry (Orchardson et al. 2006; Schwarz et al. 2002). Unfortunately, this clinical condition is often poorly understood (Pesevska et al. 2010). It is important to understand this condition in light of dental therapy because the need for treatment is increasing (Gerschman et al. 1994; Miglani et al. 2010). Hypersensitivity occurs when tooth necks are exposed. Brannström's hydrodynamic theory describes these mechanisms. Chemical, osmotic, physical or mechanical stimuli induce movement of fluid in dental tubules, which activates pain fibres—mainly A- δ fibres—at the pulp-dentine border (Brannström 1992). Afflicted patients describe an intense and sharp pain of short duration that cannot be ascribed to any other form of dental defect or disease (Canadian Advisory Board on Dentin Hypersensitivity 2003). In a huge number of cases, these symptoms are triggered by cold and are not related to restorative or caries therapy. The well-being of patients who suffer from dentine hypersensitivity is often affected. Daily stimulation, for example eating or teeth brushing, could induce considerable pain (Rösing et al. 2009; Tengrungsun et al. 2008).

Today, more than 30% of the adult population of industrialised nations is thought to be affected (Ritter et al. 2006; Gillam et al. 1997), but the actual

prevalence is still unknown (Rösing et al. 2009). The reported incidence mainly depends on the population under examination and the methodology of the studies, which vary a lot. Middle-aged patients are most often affected (Al Sabbagh et al. 2004), but a growing number of young persons are affected by dentine hypersensitivity (Sykes 2007). The higher frequency of hypersensitivity, even in middle-aged adults, could be explained by increasing exposure of tooth necks, which occurs increasingly early on in young people (Dowell et al. 1983). The main reasons for exposure are erosion, abrasion and attrition. However, erosion is most likely to be the main factor (Addy et al. 1994; Gillam et al. 1997). This comes from an increasing awareness of dental hygiene, which has resulted in well-intentioned but incorrect brushing (Fig. 1). For these reasons, sensitive tooth necks frequently occur opposite the hand that is brushing. The loss of the thin cementum layer in the tooth-neck area is responsible for more than 90% of the hypersensitive surfaces (Orchardson et al. 1987). As a result, dentine hypersensitivity can be characterised as a tooth-wear phenomenon (Bamise et al. 2008). Restorations, functional overload and bleaching of vital teeth are also causes of dentine hypersensitivity (Brannström 1992; Jacobsen et al. 2001; Haywood 2002). Nowadays, one therefore speaks of a multifactorial genesis of dentine hypersensitivity associated with tooth wear.

Despite intensive research, the precise physiological mechanisms of pain production and transmission in the dental pulp have not been sufficiently determined (He et al. 2011; Bal et al. 1999; Zhang et al. 1998). The surface texture of dentine, that is the number of open tubules at the root neck, is of great relevance to the process of dentine hypersensitivity (Absi et al. 1987; Markowitz 1993; Fig. 2). The extent of hypersensitivity depends on

Fig. 1 Clinical situation of a patient with gingival recession. The occurrence of gingival recession is a precursor to the loss of cement, owing to poor oral hygiene, the exposure of tooth necks and dentine hypersensitivity.



the number of exposed tubules (Ngassapa 1996). Clinical studies (Narhi et al. 1992) and SEM examinations (Absi et al. 1987) have demonstrated that the dentine of hypersensitive teeth has a considerably higher number of exposed dental tubules (eight times the number) with a considerably greater aperture (twice the size) compared with teeth with no hypersensitivity symptoms (Absi et al. 1987). Since dentine hypersensitivity can occur even after the closure of most of the dental tubules, other factors, like inflammatory mediators, are assumed to be involved in nerve stimulation and pain (Narhi et al. 1992; Ngassapa 1996) in addition to the hydrodynamic theory.

Conventional therapy

Currently, a multitude of desensitising agents are available on the market. Normally, the therapeutic mechanism is based upon the hydrodynamic theory. By occluding dentinal tubules, movement of fluid should be reduced. Furthermore, the reduction of pulpal pain-nerve fibre firing should contribute to reduced sensitivity.

The spectrum of applications ranges from agents for topical application, dentine adhesives, light-curing primer systems, mucogingival surgery for soft-tissue management, conventional fillings, to endodontics as ultima ratio. Topical applications are the most important for desensitisation; among them are fluorides, potassium and calcium compounds, hydroxyapatite, bioactive glass and glass-ceramics, oxalates, glutaraldehyde, formalin and chlorhexidine. These ingredients are mostly found in toothpastes, mouth rinses, gels, suspensions, varnishes or pastes for topical application. They can also be applied via chewing gum or iontophoresis. Today, the application of nano-sized particles of different mixtures is also very popular.

In 1935, Grossman formulated a set of criteria that desensitising agents are to fulfil. These criteria are still valid today (Renton-Harper et al. 1992):

- no irritation of pulp tissue;
- painless application;
- easy to apply;
- rapid in effect;
- sufficient efficiency;
- no side-effects; and
- long-term effectiveness.

The predominant number of compounds lead to a rapid resolution of symptoms, but often they are only short-lived. In most cases, a long-term occlusion of dentinal tubules cannot be attained. Thus far, no desensitising substance or method of appli-




Fig. 2 SEM examination of a human cervical dentinal surface with open tubules, after experimental removal of the smear layer with 50 % citric acid for one minute (1,000x magnification).

cation has fulfilled all the criteria Grossmann postulated in 1935. There has been a constant improvement in terms of the available means of treatment and active substances, but the reports still demonstrate difficulty in relieving the pain (Romano et al. 2011). Until recently, no universally applicable substance was available (Mitchell et al. 2011; Tirapelli et al. 2010; Dabahne et al. 1999).

Laser application

Precipitates and surface coverings disintegrate after some time, for example owing to the influence of acid or toothbrush abrasion (Addy et al. 1983). Conventional desensitising treatments had to be applied repeatedly at regular intervals to ensure a durable analgesia (Gillam et al. 1992; Cuenin et al. 1991). The application of laser beams of different wavelengths and energy levels, alone or in combination with topical application, for example fluoride, is an alternative method for the treatment of dentine hypersensitivity.

Studies on the effects of laser application

In vitro and *in vivo* studies document high effectiveness rates and comparatively long-lasting pain relief. The most commonly used types of lasers for the treatment of dentine hypersensitivity already determined *in vivo* can be divided into two groups. Those lasers with a lower output power, low-level lasers (He-Ne and GaAlAs diode lasers), are applied to biostimulation and are distinguishable from laser types with a middle-output power, middle-output power lasers, which have the ability to morphologically alter dental hard tissue.

The middle-output power lasers include the Nd:YAG, Er:YAG laser and CO₂ lasers (Dederich et al. 1984; Melcer et al. 1985; Featherstone et al. 1987). The effect of these laser types can probably be attributed to the sealing of the dentinal tubules, nerve analgesia and placebo effects. The sealing has been observed to be of long-lasting effect, whereas in

the case of nerve analgesia and placebo effects, the effects are not durable (Kimura et al. 2000a). Despite the precise mechanisms of laser action, the long-term value of laser therapy in treating dentine hypersensitivity is uncertain; current evidence is based upon a slight superiority compared with conventional topical applications (He et al. 2011).

Laser therapy with low-output power has been applied to humans since the 1970s and was originally used for wound healing (Kimura et al. 1991, 1993, 1997). In the 1980s, the inhibition of inflammation (Karu 1988, 1989) and the stimulation of nerve cells were demonstrated (Kimura et al. 1993; Jarvis et al. 1990).

Low-level lasers: GaAlAs laser

Thus far, GaAlAs diode lasers of three wavelengths have been used clinically to treat dentine hypersensitivity: 780, 830 and 900 nm. The 780 nm wavelength has been used with good clinical success (30 mW in continuous wave mode [cw] and an application time of about 0.5 to three minutes; Matsumoto et al. 1985a). The 830 nm wavelength for the treatment of dentine hypersensitivity was first described by Matsumoto in 1990. With an energy setting of 20 to 60 mW in cw mode and an application time of 0.5 to three minutes, the effectiveness of therapy was 30 to 100%, depending on the energy level (Matsumoto et al. 1990). The effectiveness of therapy using the 900 nm wavelength and an output power of 2.4 mW at 1.2 Hz for 2.5 minutes was approximately 73 to 100% (Kimura et al. 2000b). Yamaguchi et al. (1990) compared the application of a GaAlAs diode laser of a wavelength of 790 nm and an output power of 30 mW and a placebo in vivo. Significant differences between laser application and the placebo group were found. At two hours, one day and five days after laser application, a significant improvement was detected (Yamaguchi et al. 1990). Overall, compared with the placebo, an improvement of 60 to 22% was achieved. GaAlAs laser application with a maximal energy output of 60 mW did not damage enamel or dentine surfaces morphologically (Watanabe et al. 1991).

According to another in vitro study, the application of GaAlAs laser diodes with energy levels of 30 mW (cw, 780 nm), 60 mW (cw, 830 nm) and 10 W (pulsed, 900 nm) did not lead to a significant increase in the temperature in the dental pulp (Arrastia et al. 1994). Gerschman et al. (1994) accomplished a clinical double-blind study with GaAlAs lasers compared with a placebo. During the therapy, the apical and cervical regions of the tooth

were irradiated for one minute; this procedure was repeated in one-week, two-week and eight-week intervals. Dentine hypersensitivity evoked by tactile and thermal stimuli was measured at each control and compared with the placebo group. A significant difference concerning dentine hypersensitivity was detected during the analysis. It was therefore deduced that the GaAlAs laser is an effective method for dentine desensitisation (Gerschman et al. 1994).

Combined application of GaAlAs laser and fluoride

In another clinical study, a laser with an energy density of 3 and 5 J/cm² was applied up to six times in an interval of 72 hours after each application (Marsilio et al. 2003). Dentine hypersensitivity was measured initially after each application, and at 15 and 60 days after application. In more than 85% of the teeth treated, an improvement was detected. Side-effects were not observed (Marsilio et al. 2003). In a comparative study of GaAlAs laser application (630–670 nm) at energy levels of 15 mW in contact mode for 20 seconds and fluoride application (Fluor Protector, Ivoclar Vivadent), significant and complete relief from pain after three sessions was achieved in 86.6% of the cases compared with 26.6% after fluoridation only (Pesevska et al. 2010). The clinical findings of Noya et al. (2004) proved that just a single application of GaAlAs laser (670 nm, 15 mW, 5 J/cm²) yields a statistically significant reduction in sensitivity to mechanical and thermal stimuli and that two applications are enough to reduce sensitivity to air. No other application led to any additional benefit (Noya et al. 2004).

A significant reduction in VAS scores was also detected with laser application for 160 seconds at an energy density of 4 J/cm² per dental element at 24 hours and seven days after application compared with a placebo application (Orhan et al. 2010). All teeth remained vital and no adverse effects were found radiographically, but the results were not significantly different from any conventional desensitiser (Gluma Desensitizer, Heraeus Kulzer; Orhan et al. 2010).

A combined application of GaAlAs laser light with sodium fluoride (NaF) at an energy output of 15 mW and density of 4 J/cm² led to no statistically significant differences between laser application and combined laser and fluoridation treatment (Corona et al. 2003).

Whether a combined application of GaAlAs laser and fluoride is effective in treating dentine hyper-



No Pre-Registration Fee

**The Largest
Dental Meeting/
Exhibition/Congress
in the United States**

MARK YOUR CALENDAR

**Scientific Meeting:
Friday - Wednesday,
November 23 - 28**

**Exhibit Dates:
Sunday - Wednesday,
November 25 - 28**

ATTEND AT NO COST
Never a pre-registration fee at the
Greater New York Dental Meeting

MORE THAN 600 EXHIBITORS
Jacob K. Javits Convention Center 11th Ave.
between 34-39th Streets (Manhattan)

HEADQUARTERS HOTEL
New York Marriott Marquis Hotel

LIVE DENTISTRY ARENA - NO TUITION

**LATEST DENTAL TECHNOLOGY
& SCIENTIFIC ADVANCES**

MORE THAN 350 SCIENTIFIC PROGRAMS
Seminars, Hands-on Workshops, Essays
& Scientific Poster Sessions as well as
Specialty and Auxiliary Programs

**EDUCATIONAL PROGRAMS
IN VARIOUS LANGUAGES**

SOCIAL PROGRAMS FOR THE ENTIRE FAMILY

**ENJOY NEW YORK CITY AT ITS BEST
DURING THE MOST FESTIVE TIME
OF THE YEAR!**

FOR MORE INFORMATION:
Greater New York Dental Meeting®
570 Seventh Avenue - Suite 800
New York, NY 10018 USA
Tel: (212) 398-6922 / Fax: (212) 398-6934
E-mail: victoria@gnydm.com

**GREATER
NEW YORK
DENTAL MEETING**

WWW.GNYDM.COM

Sponsored by the New York County Dental Society and the Second District Dental Society

2 0 1 2

sensitivity is questionable. Results are contradictory, often masked by placebo effects and highly dependent on laser parameters and the given circumstances for each patient. Both methods of treatment, GaAlAs laser application and fluoridation, are suitable for dentine hypersensitivity therapy.

Biostimulative mechanisms of GaAlAs lasers

The GaAlAs laser mechanism is thought to be biostimulative rather than effecting morphological changes in dentine. It is assumed that the laser energy is transmitted to the dentine–pulp complex, interacts with the pulp tissue and causes a photobiomodulating effect, increasing the cellular metabolic activity of the odontoblasts and obliterating the dentinal tubules by means of tertiary dentine production (Ladalaro et al. 2004; Walsh 1997).

Tengrungsun et al. (2008) compared the efficiency of a GaAlAs laser (790 nm, 30 mW, 1 min) with a dentine bonding agent (Scotchbond, 3M ESPE) and found a statistically significant reduction immediately and 15 days after treatment in both of the two groups. No additional reduction in the level of hypersensitivity 30 days after treatment was observed. The dentine bonding agent was significantly superior to the GaAlAs laser within all measuring periods, thus confirming the assumption that laser light may act in a different way from occluding dentinal tubules (Tengrungsun et al. 2008).

The immediate laser effect is assumed to be triggered by placebo effects as a result of endorphin release induced by the activation of the pain inhibition system of the organism. This leads to the release of endorphins by the central nervous system, possibly controlling the painful stimulus at the periphery, and causing biostimulative effects that happen gradually within a few days (Tuner et al. 2002; Kimura et al. 2000b; Trowgridge et al. 1990). Another assumption is the blocking of the depolarisation of C-fibre afferences (Wakabayashi et al. 1993). The exact mechanism of action of low-intensity lasers in dentine hypersensitivity is not thoroughly understood (Orhan et al. 2010).

Infra-red wavelengths and high-power density

Laser diodes, some of which have already been tested *in vitro* and *in vivo*, with wavelengths in the infra-red area and a high-power density are easily available on the market. Because of the laser–tissue interaction of this laser type with high energy per

surface density, its results are comparable to that of an Nd:YAG laser. The sealing ability of this laser type was observed with the parameters 810 nm, 2 W and 30 ms, and was found to be less than that of CO₂, Er,Cr:YSGG lasers and Nd:YAG lasers (Gholami et al. 2011).

Clinical findings with the use of a GaAlAs laser of a wavelength of 810 nm at 1.5 to 2.5 mW for one minute resulted in a rapid reduction of discomfort, 15 minutes and 30 minutes after laser irradiation (37 % after 15 minutes and 41 % after 30 minutes) compared with placebo laser application with a reduction of 9 %. The improvement remained stable until two weeks (72 %) and two months (66 %) after application compared with placebo laser application (a 28 % reduction at two weeks and 26 % at two months) and the application of 10 % potassium nitrate gel (a 36 % reduction at two weeks and 30 % at two months; Sicilia et al. 2009).

Different effects in different age groups

Ladalaro et al. (2004) evaluated the clinical desensitising effect of red and infra-red GaAlAs laser light application (660 nm and 830 nm, 4 J/cm², cw, 114 seconds, contact mode) in adult patients of different age groups (25–35 years and 36–45 years) as an immediate (15 minutes and 30 minutes after application; four sessions with intervals of seven days between each session) and late therapeutic effect (15, 30 and 60 days after the conclusion of treatment). Significant desensitising levels were only found in patients aged between 25 to 35 with the 660 nm red laser, which was found to be more effective than the 830 nm infra-red laser immediately after and in the follow-up periods at 15, 30 and 60 days after the conclusion of treatment.

In the group of 36- to 45-year-old patients, the effect of the red laser was only moderate, with recurrence of sensitivity, and the infra-red laser was ineffective. The authors concluded that the desensitising effects immediately after laser irradiation resulted from a suppression of evoked potential of the pulp nociceptive nerve fibres, with a better tissue response in the younger group. Pathological processes, regressive or atrophic alterations of the odontoblasts and the dentine pulp complex may lower the reaction potential in older patients, with reduced effectiveness of the laser biostimulation (Ladalaro et al. 2004).

A significant clinical improvement was also observed after the combined application of GaAlAs laser (808 nm, cw, contact mode, 25 seconds) and

desensitiser toothpaste compared with the toothpaste alone (Dilsiz et al. 2010a).

_GaAlAs laser and acid resistance

Recently, the GaAlAs diode laser was tested to establish enhancement of the acid resistance of dentine surfaces as a preventive method for hypersensitivity. A degree of improvement in the acid resistance of dentine specimens after laser irradiation (808 nm, cw, 60 J/cm²) and erosive challenge (1 M hypochlorous acid for five minutes) was found without creating thermal or structural damage (De-Melo et al. 2010). However, the exact mechanism of action remains unclear. Laser treatment can be a useful tool for rapid reduction in pain, and possibly in the improvement of acid resistance of dentine. Nevertheless, more basic research and long-term clinical trials are needed to evaluate the long-term efficiency of this method and to explain the exact mechanism of action.

_Low-level lasers: He-Ne laser

The He-Ne laser has a wavelength of 633 nm (Moritz et al. 2006) and is a low-level laser. The first application of the He-Ne laser in the therapy of dentine hypersensitivity was described by Senda et al. (1985), who used an output power of 6 mW and chose two different modes (cw and pulsed, 5 Hz). Effectiveness ranged from 5 to 100%. In another study, an effectiveness of 5 to 18% was achieved (Wilder-Smith 1988). To date, the mechanism of action of the He-Ne laser has not been explained completely (Moritz et al. 2006). An energy level of 6 mW does not alter the enamel or dentinal surface structure morphologically; however, laser energy transmits through enamel and dentine and reaches the pulp tissue (Watanabe 1993). Physiological experiments have shown that the He-Ne laser application does not influence nociceptors of circumferential A- δ - or C-fibres (Jarvis et al. 1990), but it does influence electrical activity (action potential), which in healthy nerves is enhanced by about 33% after application (Rochkind et al. 1986). The effect is long-lasting and leads to an increase in the action potential of nerve fibres for more than eight months after laser application (Rochkind et al. 1986).

_He-Ne laser compared to Nd:YAG laser

In a clinical study (Gelsky et al. 1992), which was aimed at testing the effectiveness and confidence of the Nd:YAG laser in the therapy of dentine hypersensitivity in vivo (see below), the He-Ne laser was applied to one group and the He-Ne laser and the Nd:YAG laser were applied to the other group

(30–100 mJ, 10 pps increments of ten to 40 seconds, total application time < two minutes, without local anaesthesia). Dentine hypersensitivity was measured mechanically (dental probe) and thermally (stream of cold air) with the aid of a VAS. Additionally, the pulpal sensibility was evoked electrically. Initially and after three months, X-rays were taken to identify possible side-effects of the laser application. Directly after laser application and three months later, a reduction in the level of discomfort was observed. After three months, dentine hypersensitivity evoked by thermal stimuli was scaled back to 63% and hypersensitivity evoked by mechanical stimulation was scaled back to 61%. Compared with the combined application of He-Ne and Nd:YAG lasers, there was not much difference (reduction of dentine hypersensitivity evoked by thermal stimulation to 58%; evoked by mechanical stimulation to 61%). All of the teeth were vital after application and no side-effects or complications could be detected.

If dentine hypersensitivity is conditioned by the hydrodynamic mechanism exclusively, (thermal) effects of Nd:YAG laser application should reduce dentine hypersensitivity primarily (Gelsky et al. 1992). In contrast, He-Ne laser application should not lead to important effects. Thus, it is assumed that a surficial modification is not the only desensitising factor, but that there is apparently also a neurophysiological component (Gelsky et al. 1992), which is affected by biostimulative effects.

In a study with a similar design, the reduction of dentine hypersensitivity after He-Ne laser application alone, as well as after combined He-Ne laser and Nd:YAG laser application, was detected. It remained stable for six weeks (Halket et al. 1996).

Editorial note: To be continued in our next issue of Laser. A list of references is available from the publisher.

_contact

laser

Dr Ute Botzenhart

Department of Orthodontics
Centre of Dentistry and Oral Health
Ernst Moritz Arndt University of Greifswald
Germany

Dr Andreas Braun/Prof Matthias Frentzen

Department of Periodontology, Operative and Preventive Dentistry
University of Bonn
Germany

The management of pyogenic granuloma with the 980 nm diode laser

A case report

Author_Dr Merita Bardhoshi, Albania

_Introduction

Pyogenic granuloma (PG) is a benign non-neoplastic mucocutaneous lesion. It is a reactional response to constant minor trauma and can be related to hormonal changes. In the mouth, PG is manifested as a sessile or pedunculated, resilient, erythematous, exophytic papule or nodule with a smooth or lobulated surface that bleeds easily.^{1, 2, 3} The size of PG varies from 2 mm to 2 cm in diameter. Occasionally, the lesions may reach a diameter of up to 5 cm.^{7, 9} PG preferentially affects the gingiva, but may also occur on the lips, tongue, oral mucosa and palate.

The appearance of PG usually ranges in colour from red/pink to purple. Younger lesions are more likely to be red because of the high number of blood vessels. Older lesions become pink.^{5, 6} The exact cause of PG is unknown; trauma is usually a precipitating factor.

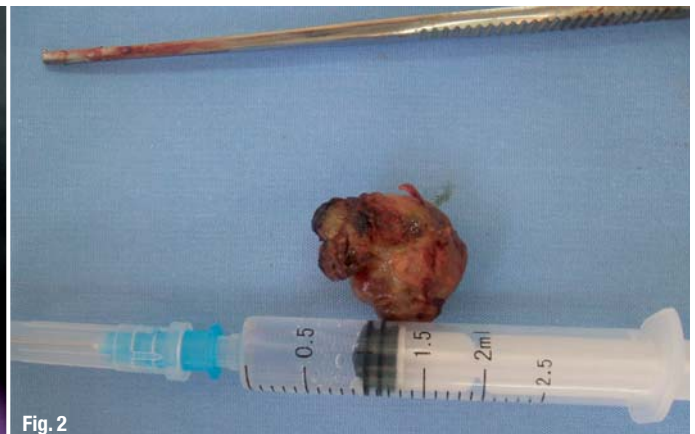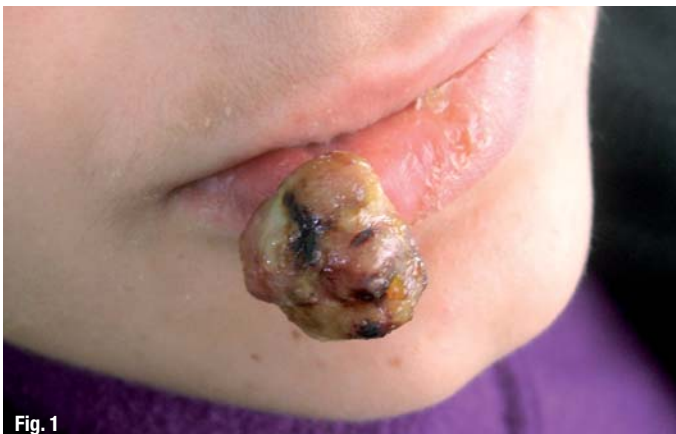Several methods can be applied to remove PG, like surgery, electrocauterisation and laser treatment. The argon laser has long been used to treat PG, but it is claimed to result in an increased risk of scarring. There are several reports about treatment with the pulsed dye laser, although it has only been successfully employed in removing very small granuloma. In the past few years, the continuous-wave carbon dioxide laser has proved to be an effective treatment option.^{2, 3} In this study, I report on a new experience in the treatment of PG with the 980 nm diode laser.

_Patients and method

Two patients with PG were examined in this study. They were treated with the 980 nm diode laser at the University of Tirana's Dental School in Albania. An initial clinical examination consisting of the medical and dental history and a thorough extra- and intra-oral examination was performed. A complementary blood

Fig. 1_Initial photograph.

Fig. 2_Immediately after surgery.



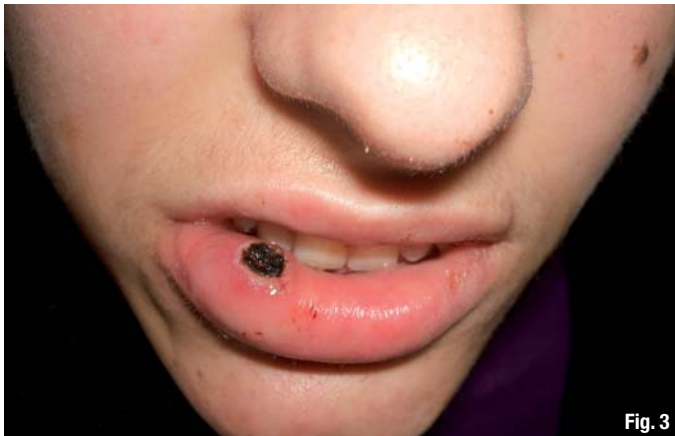

Fig. 3

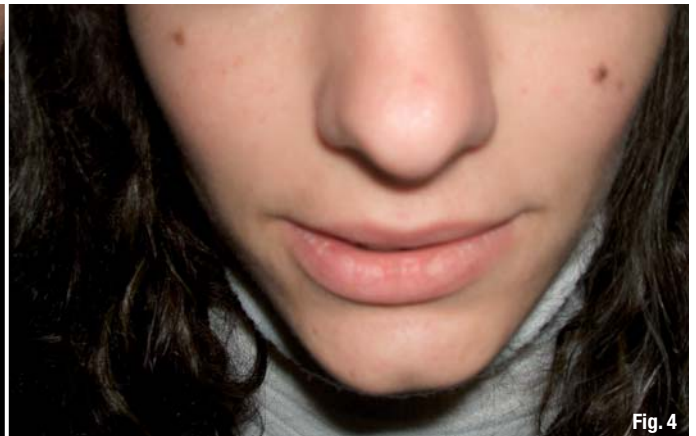

Fig. 4

test, complete blood count, and erythrocyte sedimentation rate test made it possible to exclude infectious diseases. The patients had no systemic complaints. The data collected was evaluated and a clinical diagnosis for the type of lesion was established (Fig. 1). Incisional biopsies were taken pre- and post-operatively, and the specimens were histologically examined (Fig. 2). Patients were given written and verbal information on the nature of laser treatment and the signed informed consent forms were obtained prior to the treatment. The 980 nm diode laser was applied using the following parameters: continuous wave, 300 μ m optical fibre and 6 W power. The treatment was conducted under infiltration anaesthesia (2% lidocaine, 1 cc). The treatment area was cooled by the application of ice for two to five minutes post-operatively. All wounds were left open to heal by granulation and secondary epithelisation; therefore, no sutures were required (Fig. 3). After the treatment, analgesic medication was prescribed to be taken as required, but no antibiotics were prescribed. The follow-up visits were scheduled at ten days, one month, six months, and one year after surgery. All of the lesions were photographically documented at all stages of treatment and healing.

Results

Post-operatively, there was no bleeding or pain. The power setting of 6 W in continuous wave mode and focused contact handpiece appeared to lead to some superficial tissue necrosis associated with delayed wound healing. The wounds were completely healed after four to five weeks without scar formation or pigmentary changes. The cosmetic effect of the laser therapy was evident (Fig. 4). No recurrence was observed in the patients who were followed up one year after the surgery.

Discussion

Aesthetic Treatment of PG consists of the removal of the lesion. Current treatment modalities include

chemical cauterisation and surgical excision. However, these methods do not exclude the risk of complications, such as scarring or pigmentary changes. These complications may lead to aesthetic problems for patients, who accept the surgical removal of PG only with great difficulty. The conventional lip-shave procedure is often painful, results in significant bleeding and poses cosmetic concerns. Laser treatment of the lips does not compromise the importance of the lip, its discrete anatomic borders such as the vermilion border, or its functional functionality.

Various laser devices have been successfully used to treat PG, including the 585 and 595 nm pulsed dye laser, the 1,064 nm Nd:YAG and the dioxide carbon laser. The pulsed dye laser is safe, but it can only be used for small PG lesions. The carbon-dioxide laser has proved to be an effective treatment option. Its use permits rapid, minimally invasive surgical treatment, but the non-specific coagulation it results in may lead to scarring.

Treatment with the 980 nm diode laser is a viable treatment option. The 980 nm diode laser beam is well absorbed by haemoglobin. The excision was well performed and suturing after surgery was not necessary because of the good coagulation. The surgical period was significantly reduced. From the good results obtained, it was concluded that the application of the 980 nm diode laser in the treatment of PG appears to be of beneficial effect.

Editorial note: A complete list of references is available from the publisher.

contact

laser

Dr Merita Bardhoshi

Oral Surgeon

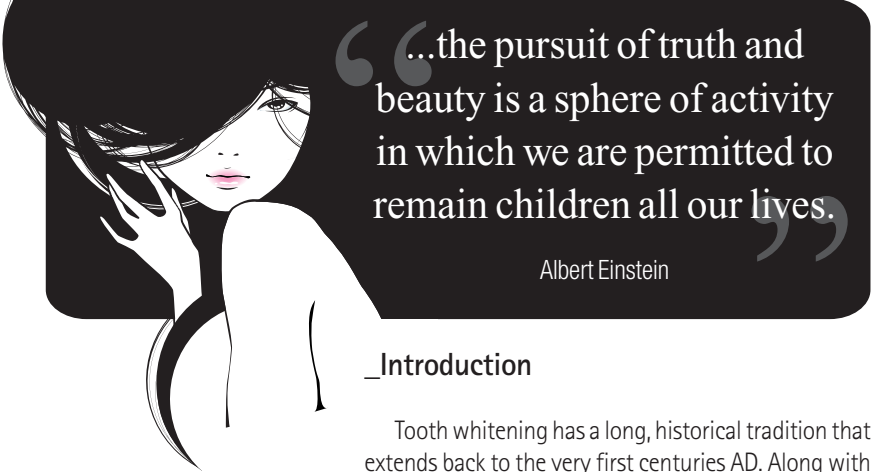
Dental School, University of Tirana, Albania

meritabardhoshi@yahoo.com

Bleaching: New approaches to a traditional minimally invasive therapy

CosmEt(h)ics vs. aesthEt(h)ics

Authors_Dr Kresimir Simunovic & Monica Tuzza, Switzerland



“...the pursuit of truth and beauty is a sphere of activity in which we are permitted to remain children all our lives.”

Albert Einstein

_Introduction

Tooth whitening has a long, historical tradition that extends back to the very first centuries AD. Along with tooth extractions, it was an accepted practice already in medieval times, performed by applying aqua fortis (a solution of nitric acid) after a simple rough polishing of the enamel surface. The procedure was performed by the “dental surgeons” on duty in those days, known as barbers.

In the 19th century, new methods were developed with oxalic acid (Chappel 1887) and super-peroxide, which is thus the first documented use of hydrogen peroxide (H₂O₂; Harlan 1884). In 1918, Abbot discovered a fundamental formula for tooth bleaching, entailing a combination of light, heat production and the chemical interactions of stabilised H₂O₂ at 35% (superoxol). Since then, the formula has been refined continuously, but not changed in essence.

Studies in the late sixties by Zach and Cohen, and Nyborg and Brännstorm determined the safety settings to control heat influence on the pulp, and in 1970 the effectiveness of H₂O₂ on dentine was established. During the sixties and seventies, carbamide peroxide was used

as an oral antiseptic, with an additional whitening effect discovered during treatment. This phenomenon was subsequently analysed (Klusmier 1960), and Haywood and Heymann later developed the original home-bleaching process. The first commercial products were launched on the market as White&Brite by Omni (1989) and Opalescence by Dent Mat (1991), among many others.

The current home-bleaching process entails the chemical decomposition of carbamide peroxide into H₂O₂, among others, but with an effect that is six times weaker in comparison to the original protocol. In the late sixties, Nutting and Poe developed the walking bleach method for non-vital teeth, which involved placing a mixture of superoxol and sodium perborate into the pulp chamber for a week, a protocol that was further adapted without altering the basics.

An entirely new series of heat sources like plasma and LED lamps, combined with corresponding bleaching gels, paved the way to the new millennium with names like BriteSmile (Discus Dental) and the various generations of Zoom.

Professional literature on bleaching and cosmetics emerged at the beginning of the nineties, with the first publications by the pioneers Goldstein and Garber, followed by many others.

_Thermocatalytic or photocatalytic?

The two principles are not mutually exclusive. The bleaching procedure was described step by step in 1991 in Albers' ADEPT report. It involves a redox process in which complex, dark-pigmented carbon rings are reduced through oxidation to more simple chains that ab-

The 32nd Moscow International Dental Forum

Moscow 2012

The 32nd Moscow International Dental Forum



Dental-Expo
international dental fair

September 17-20

Crocus Expo exhibition grounds

more than
450
exhibitors

more than
25000
attendees

more than
35
countries

www.dental-expo.com

DENTALEXPO®





Fig. 1

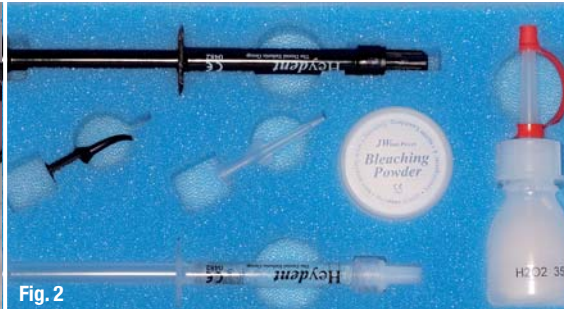

Fig. 2

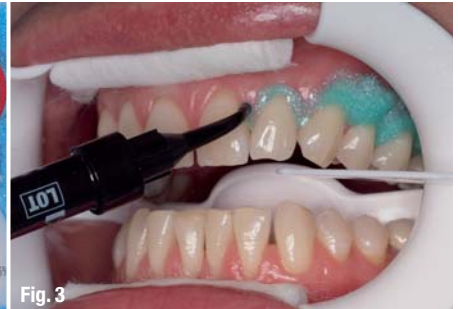

Fig. 3

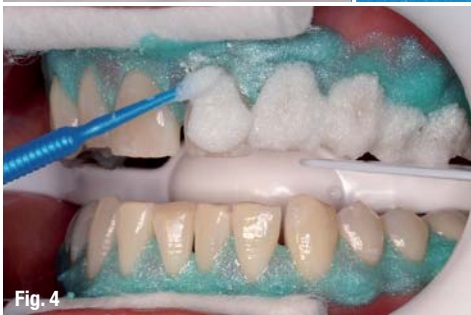

Fig. 4

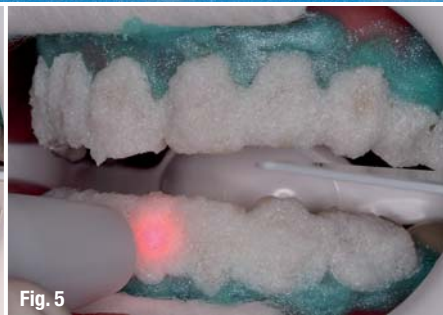

Fig. 5

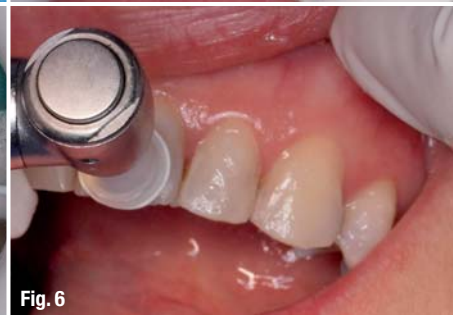

Fig. 6

sorb less light, reflecting light more intensively and appearing brighter. The redox process continues until the saturation point is reached. Thus, it functions as an absolute emergency stop to avoid any fatal decomposition of the tooth structure to CO₂ and H₂O through ruptures of the molecular structures, which would result in noxious complete oxidation.

Laser-assisted or laser-activated?

Since November 2009, dental practitioners have had the choice of a new innovative laser-activated whitening method, initiated by a wavelength-specific chromophore or activator as an essential part of the bleaching powder. Additional TiO₂ limits the thermal side-effects, allowing a maximal increase of 1.5 to 2°C at the delicate border between the bleaching gel and the enamel surface.

A corresponding large series of ESEM analyses from the University of Vienna (Prof Andreas Moritz and Prof Johann Wernisch) provided no evidence of any change in the enamel-surface morphology before and immediately after bleaching. Consequently, there is no longer any need for specific 48-hour post-operative instructions about smoking or food and drink consumption, a

conclusion supported by several basic studies. There is no risk either of any kind of pigment staining the teeth during the first two days.

From our clinical experience, we have concluded that post-operative complaints or sensitivities are very rare and limited to the day of treatment. In addition, the whitening process continues for about two more days post-operatively and the final result is often a natural-looking aesthetic whitening of several shades. This protocol even improves grey tones: a revolutionary outcome, since those shades are very challenging for any external whitening process.

The protocol of this new method of laser-activated tooth whitening includes protective glasses and a bleaching set, with a wavelength-dependent activator in the bleaching powder and H₂O₂ liquid (about 25%). They are mixed to a creamy consistency and then left to rest for two minutes. Pumice (no prophylaxis paste) is used to remove biofilm from the teeth, and the gingiva is covered by the liquid dental dam (Figs. 1–3). After the dental dam set, the mixture is applied to the buccal tooth surfaces (Fig. 4) and then irradiated at the chosen wavelength, scanning each surface for 30 seconds. Three or four cycles per session are allowed and a final applica-

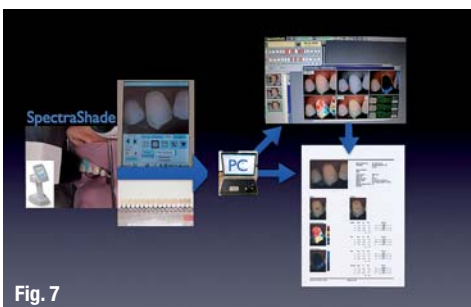

Fig. 7

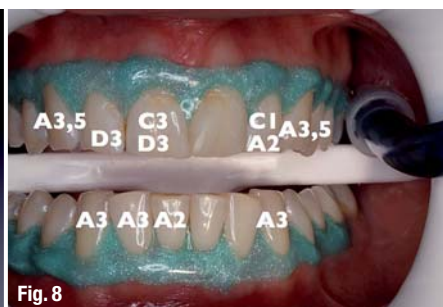


Fig. 8

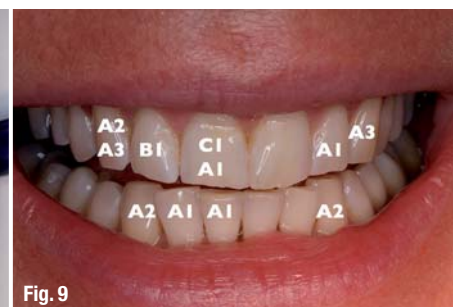
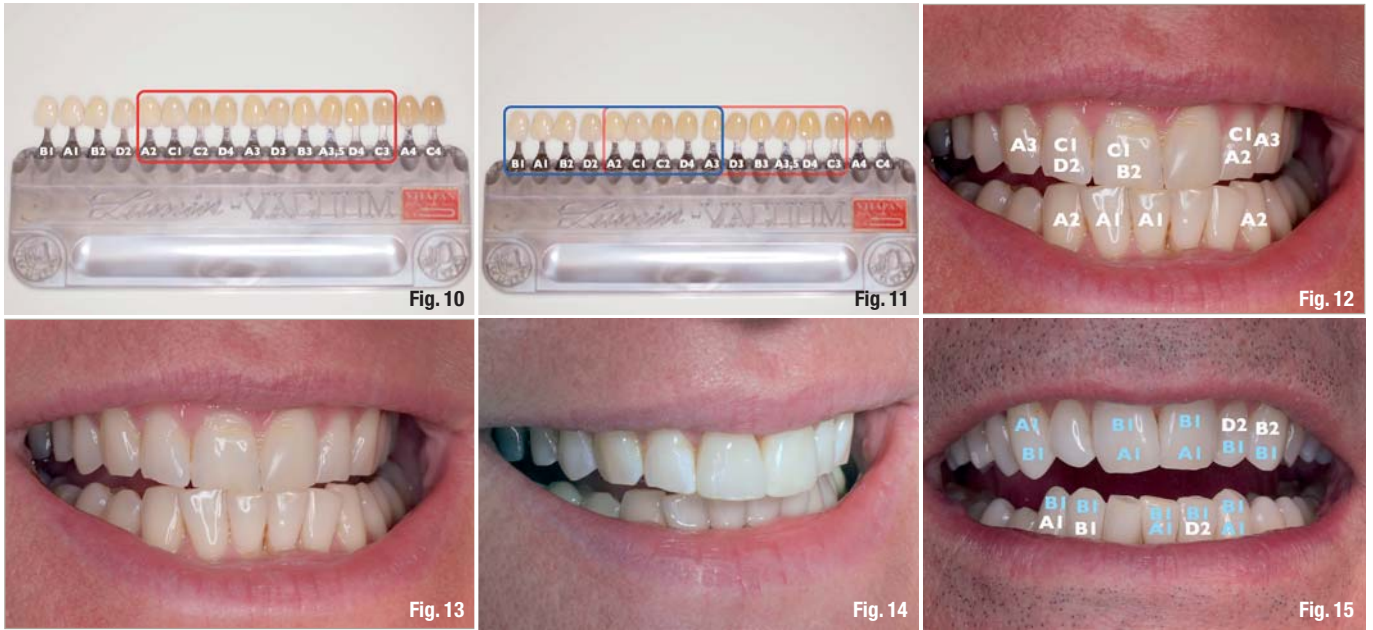


Fig. 9



tion can be done after two weeks at the earliest. A final polish and fluoride application concluded the bleaching session (Figs. 5 & 6). The patient is then given basic instructions for post-operative care. A shade comparison should be done after a minimum of two days.

**Laser-activated whitening:
Three cases from our office**

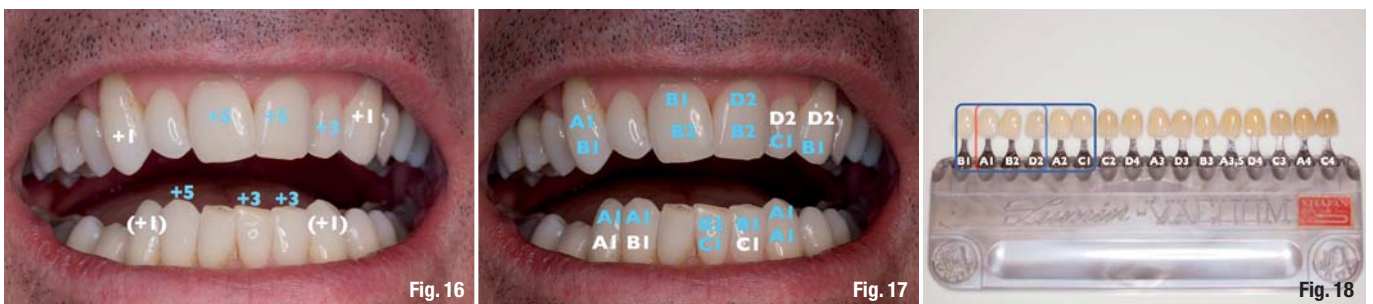Case 1

The first case was a cosmetic pre-treatment before veneer placement. A detailed spectrometric analysis (SpectraShade by MS.ch as a clinical application, simulated on Fig. 7) before (Fig. 8), immediately post-op (Fig. 9), and not earlier than two days on six tooth surfaces accompanied the whitening process. The results were registered and validated by using the original Spectra Shade software. For this purpose, the results of the complete analysis before the first bleaching cycle and the graphical translation of the shade variations were compared to the classical VITA parameters (red frame, Fig. 10). The dark blue frame shows the evident shift to brighter shades (Fig. 11) just before and immediately after the complete bleaching on the day of treatment. Another spectrometric analysis was carried out eleven days after the operation (Fig. 12).

Bleaching (Fig. 13) was followed by surface conditioning with Er:YAG/Fidelis Plus III by Fotona and cementation with Variolink Veneer and Syntac Classic by Ivoclar Vivadent. Minimally invasive veneering (Fig. 14) completed the treatment.

Case 2

The second case demonstrates a retreatment of an earlier different bleaching with an already high shade as a challenging starting point. The protocol of this case entailed laser irradiation of three cycles of 30 seconds each using an Nd:YAG laser (Fidelis Plus III, Fotona) with the corresponding R24 bleaching hand-piece. A complete analysis was made before the first bleaching, with a translation of the shade variations to the VITA parameters. In addition, a spectrometric analysis was carried out immediately after the three bleaching cycles by Nd:YAG/Fidelis plus III (Fotona) with the bleaching hand piece R24 and the corresponding shade variations (Fig. 15). One week later, another spectrometric analysis followed (Fig. 16: numerical translation of the shade variations (Fig. 17: final result). Fig. 18 gives a comparison between the initial parameters before the bleaching (red frame), immediately after the bleaching (blue frame) and the final results (darker blue frame).



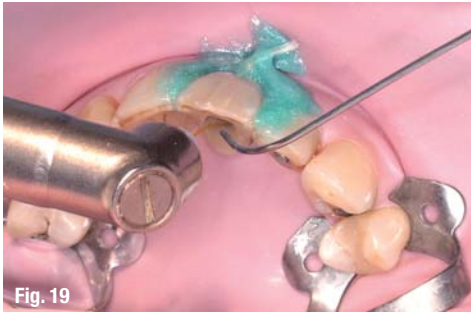

Fig. 19

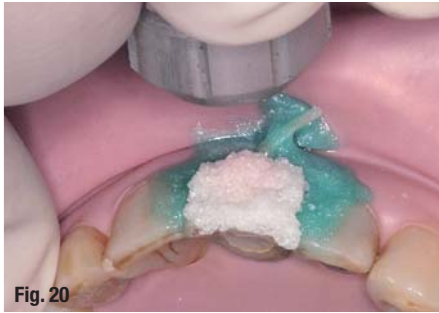


Fig. 20

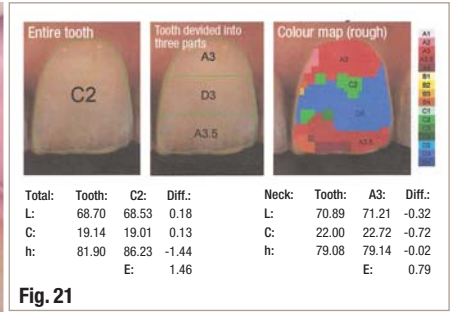


Fig. 21

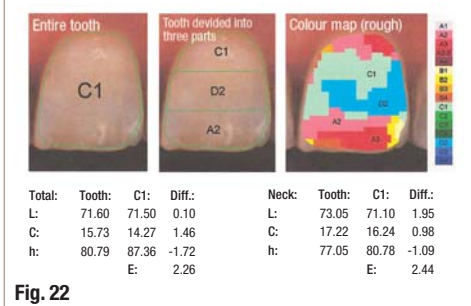


Fig. 22

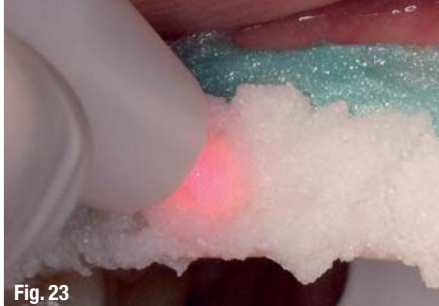

Fig. 23

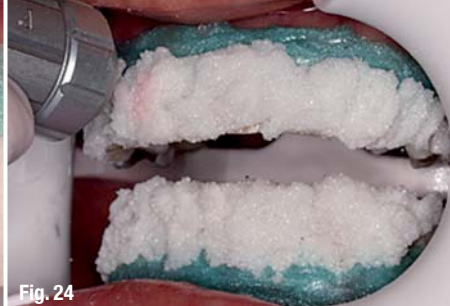

Fig. 24

Case 3

The third case was treated using combined two-step whitening before the definitive aesthetic restoration. The first step entailed combined laser-assisted endodontic revision of the non-vital left maxillary central incisor using Er:YAG and Nd:YAG lasers (Fidelis Plus III, Fotona), followed by selective external bleaching using an Nd:YAG laser with the R24 hand piece for four cycles of 60 seconds each (Figs. 19 & 20). In addition, Figs. 21 & 22 show the final results of the spectrometric analysis of the central left incisor (after selective external bleaching of this surface only). The second step involved complete combined bleaching of both arches using an 810 nm diode laser (ARC) with a photo-bi modulation (PBM) hand piece for two cycles of 30 seconds each and an Nd:YAG laser with the R24 hand piece (Fotona) for one cycle of 30 seconds (Figs. 23–24). Figs. 25 & 26 offer a comparison between the situation before any treatment and after the final bleaching (before definitive restorations).

Conclusion

This new and innovative addition to the field of laser-assisted tooth whitening is a precious enrichment to minimally invasive therapies that are part of the daily

office routine. Tooth bleaching is a prudent evidence-based choice in cases of aesthetic imbalance, often because tooth-shade variation is an evident social, private and professional obstacle, and the clinician's professional knowledge and the patient's treatment needs are the focus. For the laser user, tooth bleaching is a safe and cost-saving alternative because the bleaching powder can be adapted to the in-office laser wavelength(s) via specific activators. Handling is easy and can be carried out by assistants as part of a low-level energy laser treatment.

| | |
|--------------------------------------------------------------------------------------------------------------------------------------------------------------------------------------------------------------------------------------------------------------------------------------|-------|
| _contact | laser |
| <p>Dr Kresimir Simunovic and Monica Tuzza Office for Laser-Assisted Dentistry Seefeldstr. 128 8008 Zurich Switzerland</p> <p>ksimunovic@smile.ch www.simident.ch</p> | |

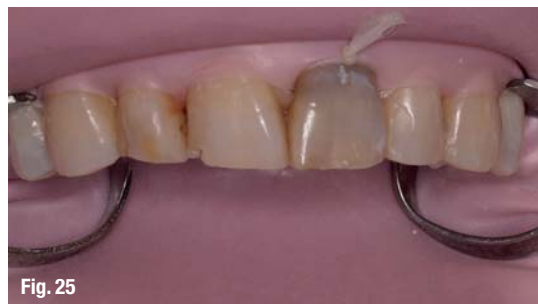

Fig. 25

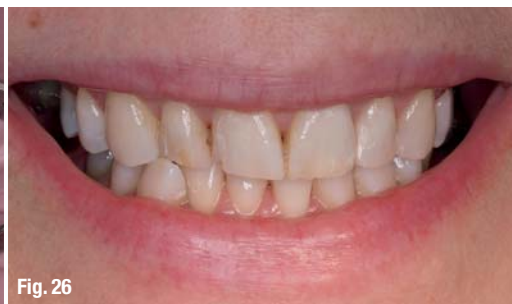

Fig. 26

تحت رعاية
سمو الشيخ حمدان بن راشد آل مكتوم
نائب حاكم دبي، وزير المالية
رئيس هيئة الصحة بدبي

Under the Patronage of
H. H. Sheikh Hamdan Bin Rashid Al Maktoum
Deputy Ruler of Dubai, Minister of Finance
President of the Dubai Health Authority

مؤتمر الإمارات الدولي لطب الأسنان ومعرض طب الأسنان العربي
UAE INTERNATIONAL DENTAL CONFERENCE & ARAB DENTAL EXHIBITION

إيكد AEEEDC DUBAI

Delivering Science & Technology

5 - 7 February, 2013 | مركز دبي الدولي للمؤتمرات والمعارض
Dubai International Convention & Exhibition Centre

www.aeedc.com

Organised by



In Cooperation with



Strategic Partner



Supported by



Strategic Sports Club Partner



INDEX® Conferences & Exhibitions Organisation Est.

Dubai Healthcare City, Ibn Sina Medical Complex #27, Block B, Office 203, P.O. Box: 13636, Dubai, United Arab Emirates
Tel: +971 4 3624717, Fax: +971 4 3624718, E-mail: info@aeedc.com, Website: www.index.ae

Effective treatment of periodontal problem areas

Combined therapy

Authors Prof Frank Liebaug & Dr Ning Wu, Germany & China

_Introduction

In systematic periodontal therapy, furcation treatment is still quite a challenge for the dentist. Because of the difficulties in the handling of this special treatment area, various therapy approaches have been discussed over the past few years. For instance, the combined use of laser and gradually released chlorhexidine xanthan gel supports the remission of inflammation considerably.

Periodontal disease has become an endemic disease in countries with a Western way of life. Over 50% of adults in Germany between 35 and 45 years of age suffer from moderately severe periodontitis. Today, periodontal disease poses the highest threat to general dental health and is responsible for premature loss of teeth in affected patients (Renggli 2010), which certainly implicates a substantial loss of quality of life.

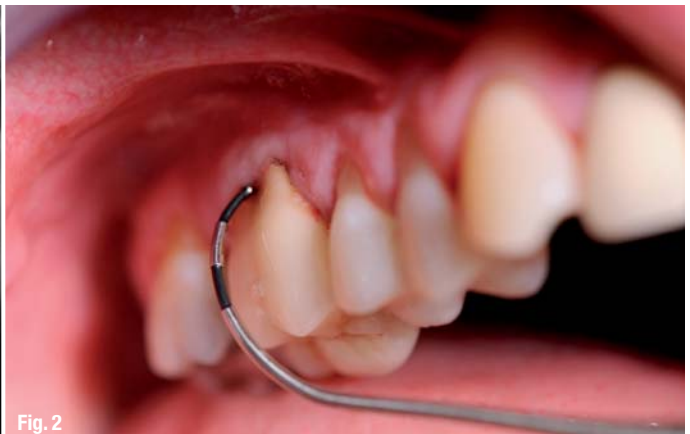In the afore-mentioned age group, the periodontal bone resorption usually extends to more than one-third of the total root length and spreads evenly horizontally. Therefore, an orthopantomogram or X-ray can be used for initial diagnosis. A detailed patient anamnesis and a corresponding patient-oriented prevention and therapy plan are essential prior to periodontal treatment. Periodontal treatment represents a wide field in daily dentistry, and can only be completed successfully if the dentist, the patient and the dental assistants cooperate.

_The role of oral micro-organisms

In the multifactorial aetiopathogenesis of periodontopathies, a decisive role is attributed to oral micro-organisms. The oral flora features a natural balance between various micro-organisms, and each patient has an individual oral flora. Therefore,

Fig. 1 Generalised horizontal and vertical premature bone resorption in a 37-year-old patient.

Fig. 2 Probing and pocket depth measurement.

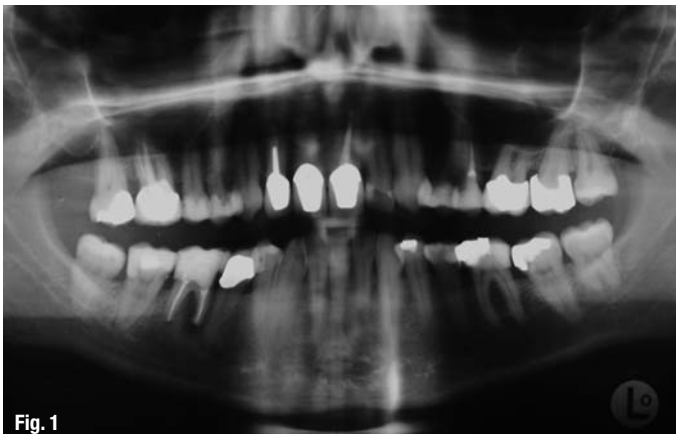

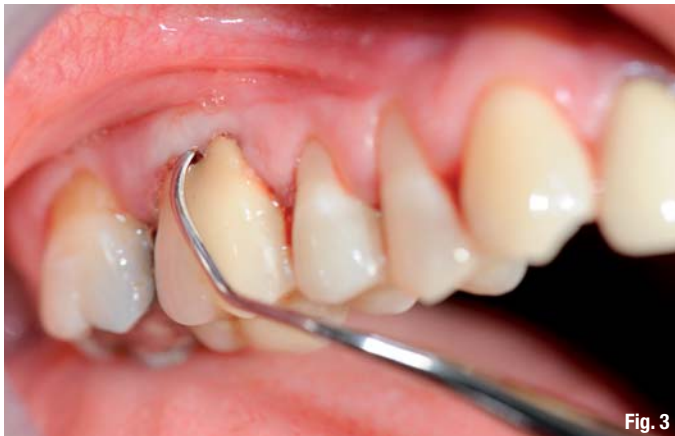


Fig. 3

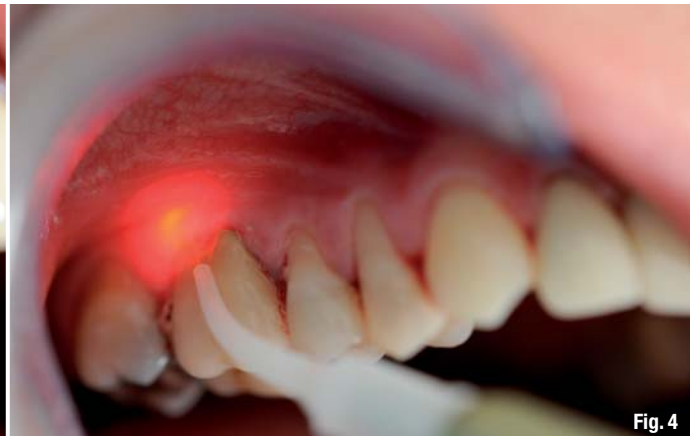

Fig. 4

the existence of periodontal pathogenic micro-organisms alone is not likely to lead to an outbreak of periodontopathies. As a result, its therapy concentrates on the reduction of pathogenic bacteria through mechanical therapy (Renggli 2011).

However, bacteria such as *Porphyromonas gingivalis*, *Tannerella forsythia*, *Fusobacterium species*, *Aggregatibacter actinomycetemcomitans*, *Prevotella intermedia* and *Prevotella oralis* cannot be eliminated by initial treatment or surgical therapy alone: deep pockets with a complex root anatomy can complicate the access of periodontal instruments to all diseased areas. Even the wide selection of slim and anatomically shaped curettes and scalers often does not allow an efficient therapy in the bi- and trifurcation areas of molars, since various pathogenic micro-organisms penetrate into the tissue and thus cannot be removed by mechanical cleaning. The persistency of periodontal pathogenic species especially, such as *A. actinomycetemcomitans* and *P. gingivalis*, appears to be an important factor for the progress of chronic periodontitis.

—New opportunities: Non-surgical treatment

A paradigm shift in periodontal treatment in recent years resulted in the prioritisation of non-surgical treatment of pockets with a medium depth (4–5 mm). This characterises the majority of patients suffering from periodontal disease. In this regard, the introduction of laser techniques into periodontology offers interesting new perspectives and should form part of the treatment spectrum of today's practitioner. Dental laser devices demonstrate clear advantages, especially in combination with scaling and root planing.

Sub-gingival plaque is the main factor for the development of periodontitis: tartar plays an important role as a retention area for the colonisation

of micro-organisms. Loose bacterial deposits—non-adhesive plaque (swimmer's calculus)—nearly exclusively consisting of Gram-negative anaerobes, colonise the soft tissue of the pockets. Their number rapidly increases in acute phases, which appears to be an important factor for the progress of periodontitis.

Chlorhexidine can be of help in fighting periodontitis (Lundergan 1992). Every dentist knows the extremely advantageous bactericidal effect of chlorhexidine bis-gluconate from his or her years of study. Local delivery devices for improving application in deep pockets through longer exposure were tested years ago already. These are used with great success in treating periodontal disease (Sellmann 2011).

—Chlorhexidine xanthan gel

In patients with furcation involvement, I use a chlorhexidine xanthan gel (ChloSite Periodontal Treatment Gel by Ghimas), which is a typical example of a local delivery device. According to the manufacturer, ChloSite consists of 1.5% chlorhexidine bonded in a xanthan carrier substance. It contains chlorhexidine in two different forms. The first form is 0.5% highly soluble chlorhexidine digluconate, also called chlorhexidine-bis(D-gluconate). This is the form of chlorhexidine used as an antiseptic agent mainly in dentistry. The second form is slow-release 1% chlorhexidine dihydrochloride (a bis-biguanide with bacteriostatic characteristics). Chlorhexidine digluconate in this composition has an immediate bactericidal effect, while chlorhexidine dihydrochloride provides controlled delayed disinfection.

Substantivity is the ability of an agent to build a reservoir by bonding to the adjacent hard- or soft-tissue walls of a gingival pocket. For achieving the desired substantivity using a local delivery device with a high sulcus fluid flow rate of 40 ml/hour to

Fig. 3 Scaling and root planing.

Fig. 4 Flexible laser fibre in the pocket area, ensuring diffuse dispersion of laser light in the surrounding tissue.

renew the content of a periodontal pocket, carriers which guarantee maximum retention time in the pocket are required. For this purpose, ChloSite uses xanthan gel as the carrier. Xanthan is a natural thickening and gelling agent. It is extracted from sugar-containing substrates by means of bacteria of the *Xanthomonas* species. Xanthan usually cannot be metabolised, or it is metabolised only to a very low level. For this reason, it belongs to the category of fibres and represents no health hazard. It swells in a watery solution, thus increasing the viscosity of the substance dissolved in it, in our case the two forms of chlorhexidine. It is used as a thickening agent in food, for example in dairy products, gravies, ketchup, etc. A special feature of xanthan solutions is their pseudo-yield point.

When exposed to fluids, xanthan forms a 3-D, pseudo-elastic net (reticulum), in which bactericidal substances can be embedded. This is followed by a controlled release, depending on the specific physical and chemical characteristics. According to the manufacturer, xanthan in ChloSite provides good sub-gingival bonding of the local delivery device, while the high chlorhexidine content guarantees a safe bactericidal effect. Special galenics secure the controlled delayed release into the biofilm.

ChloSite's composition has been scientifically proven to allow the chlorhexidine to remain in the treated pocket area for two to three weeks (Sellmann 2011). In this period, chlorhexidine is released as the gel degrades, thus continuously and efficiently fighting bacteria.

Dental laser systems

Within the past few years, various dental laser systems have gained prominence in the therapy of periodontitis (Bach 2007). Although laser can only be viewed as complementary to conventional systematic therapy, it has expanded the range of non-surgical periodontal therapies. Before laser can be

applied, the patient has to be prepared by comprehensive initial therapy. The latest developments in the field of laser techniques have made the removal of calculus with the help of a laser conceivable, since the choice of a particular wavelength can result in a favourable bactericidal effect. Numerous studies and publications in various fields of dentistry have proven that lasers have an excellent antibacterial effect in the infra-red area and that they are able to deactivate bacterial toxins. This effect is achieved already at a power output clearly below the limit of thermal damage to soft and hard tissue. Thin and flexible light conductor systems allow the laser radiation to be applied in almost any area, even the bifurcation area of molars. Therefore, the use of laser for systematic periodontal therapy can be recommended. If the power output is increased, even infected pocket epithelium can be removed by means of an Er:YAG, Nd:YAG or diode laser. Therefore, pocket decontamination by laser is very effective, even in cases of acute local periodontitis.

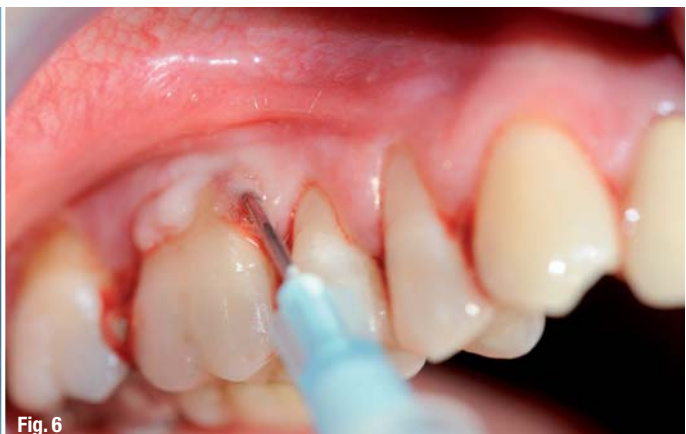Clinical treatment procedure

The clinical treatment procedure in my dental practice is as follows:

- use of ultrasonic devices on enamel surfaces to remove mineralised plaque (tartar) and sub-gingival calculus;
- use of ultrasonic scalers on root dentine for systematic treatment of the root surface;
- mechanical root planing with hand instruments;
- finishing, scaling and root planing with hand instruments with fine tactility;
- final rinsing with chlorhexidine;
- pocket decontamination with laser, for which flexible fibres are indispensable in the furcation area;
- in few individual clinical cases, external gingivectomy and removal of gingival hyperplasia to reduce extremely deep periodontal pockets;

Fig. 5 ChloSite Perio Protection Gel package.

Fig. 6 Atraumatic instillation of ChloSite in the bifurcation area with a rounded and laterally open cannula.



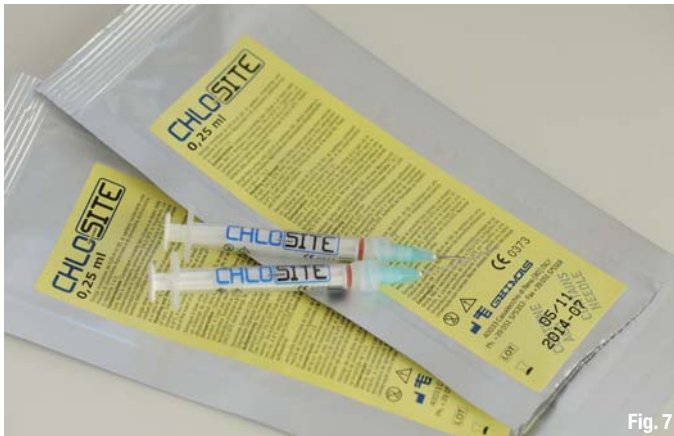

Fig. 7




Fig. 8

– application of ChloSite gel via the rounded and laterally open cannula included, without traumatization of the soft tissue surrounding the pocket.

On the one hand, the immediate bactericidal effect of laser application guarantees optimal wound healing. On the other hand, the release of chlorhexidine in the pocket allows both bacterial reduction for a minimum of 15 to 20 days and the prevention of new bacterial growth. The effectiveness of this treatment method is evident in the pain-free wound healing without irritation or bleeding, which is very positively evaluated by the patient. In my experience, a single treatment reduces the depths of the diseased pockets by approximately 2 to 2.5 mm per pocket. Another important clinical advantage of applying chlorhexidine xanthan gel in the periodontal pockets compared with full-mouth disinfection or pocket rinsing with chlorhexidine is that such side-effects as a black hairy tongue, the deactivation of fibroblasts in regeneration treatment, dysgeusia and chlorhexidine staining on composite fillings do not occur.

Conclusion

Using chlorhexidine xanthan gel in the form of ChloSite gel and laser in combination with systematic periodontal treatment can increase treatment success and improve the clinical healing process for the patient. Especially in the difficult-to-access bi- and trifurcation areas of the molars, the gel can be applied in a pain-free manner for the patient and without difficulty for the dentist. An adjuvant administration of antibiotics with the corresponding systemic side-effects becomes obsolete in nearly all cases. From my point of view, this supportive therapy alternative is an up-to-date periodontal treatment method, featuring a reduction in treatment time, an uncomplicated healing process and the prevention of undesirable side-effects. The prevention of premature administration of antibiotics has to be taken into consideration in particular, espe-

cially in light of the development of increasing resistance to antibiotics worldwide.

Furthermore, it is of great importance for the dentist to use therapy methods that promote the regeneration of periodontal soft and hard tissue. It also has to be pointed out that the therapy may be repeated several times without any problems in the case of persistent furcation infection and very deep pockets, thus slowly and successively obtaining a measurable reduction of the clinical pocket depth.

Editorial note: A complete list of references is available from the author.

Fig. 7 Application syringes containing chlorhexidine xanthan gel.
Fig. 8 LaserHF (Hager & Werken): the only combination device in the world with two laser units (975 nm/6 W and 660 nm/25–100 W) and a high-frequency surgery component (2.2 MHz) for easy, fast and precise cutting of soft tissue.

| _contact | laser |
|------------------------------------------------------------------------------------------------------------------------------------------------------------------------------------------------------------------------------------------------------------------------------------------------------------------------|-------|
| <p>Prof Frank Liebaug Praxis für Laserzahnheilkunde und Implantologie Arzbergstr. 30 98587 Steinbach-Hallenberg Germany</p> <p>Phone: +49 368 4731788 frankliebaug@hotmail.com</p> | |

Fig. 9 Logically arranged colour touch-screen display.



Fig. 9

Fascination of Laser Dentistry



From 28 October until 29 October 2011 both the 20th annual congress of the German Association of Laser Dentistry (DGL) as well as the congress for laser beginners, LASER START UP, were held in Düsseldorf, Germany. Over the two congress days we welcomed up to 200 participants from all over Germany, Europe and Middle East. Here you can read another abstract of the lectures given during the congresses.

Laser-assisted Pediatric Dentistry

Author_Dr Gabriele Schindler-Hultsch, MSc/Germany

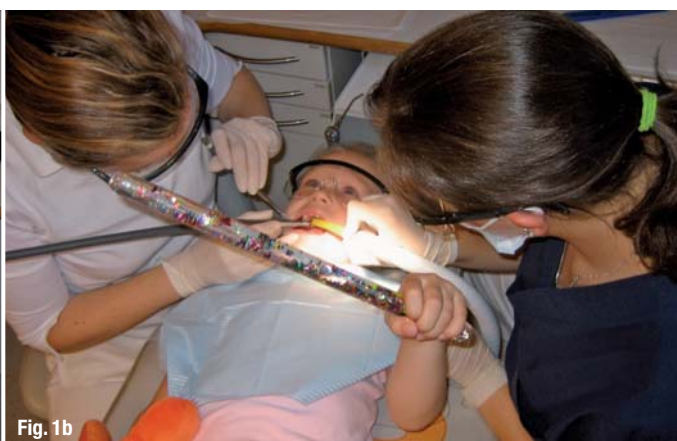
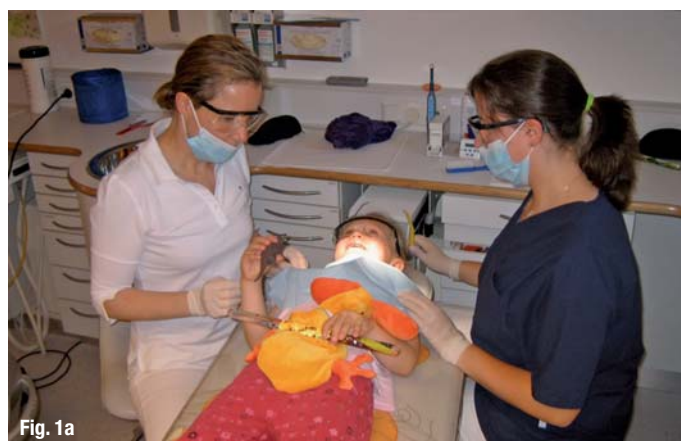
Fig. 1a-c First laser treatment of a four-year old girl. Treatment protocol followed the Laserkids® concept using behavioral management method (here with the help of magic bag and wand). The child was very cooperative during treatment and happy after her successful laser treatment.

Introduction

A clear indication for the application of different laser wavelengths is a prerequisite for a successful therapy in pediatric dentistry. Erbium lasers (Er,Cr:YSGG 2,780 nm, Er:YAG 2,940 nm) mainly find their application in operating on dental hard tissue, such as in cavity preparation for fillings, fissure sealing, minimally invasive preparation, and the creation of a micro-retentive

surface structure which is also useful in orthodontic treatments. Erbium lasers are also used for caries removal and for pulpotomy. In the field of pediatric oral surgery, frenectomy, uncovering or the removal of retained and impacted teeth as well as the treatment of pericoronitis and gingivectomy are the main indications for laser use, for which either diode lasers (wavelengths around 810 nm) or erbium lasers are suitable.

Material and methods

Using the Laserkids® Concept (Schindler RWTH Aachen University 2008) as guideline for laser-assisted pediatric dentistry, the operational sequences for the small patients are shown step by step and clinical examples illustrate this approach and the clinical proceeding. The Laserkids® Concept consists of four pillars: setting, desensitizing with the tell-show-show-do method, behavioral management, and laser application (indications, special pediatric laser settings and parameters, treatment plan and proceedings), and shows the requirements for a successful implementation of laser technology in the dental treatment standards. The laser-assisted treatment protocol includes eight steps:



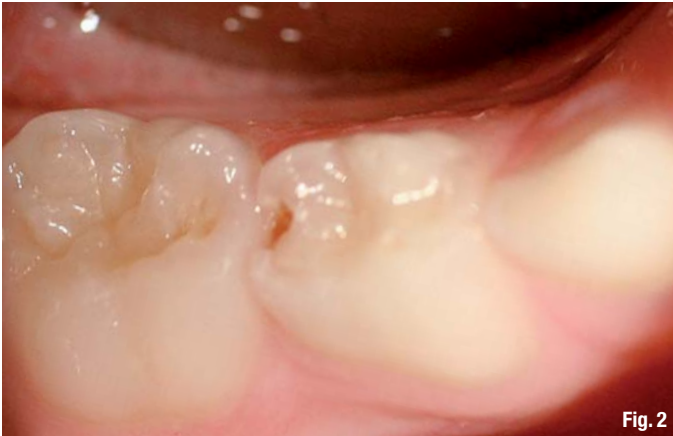


Fig. 2

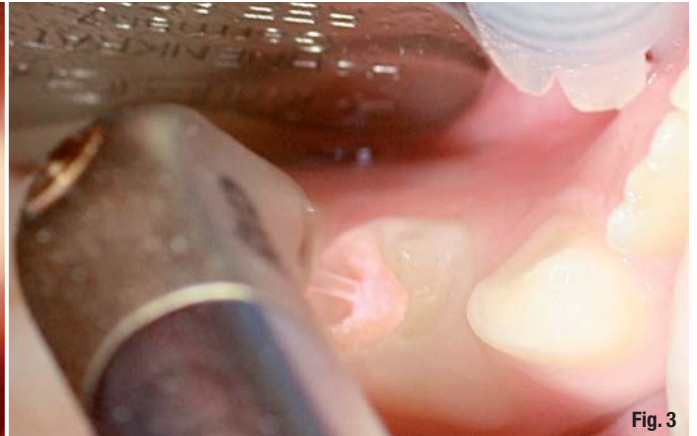


Fig. 3

- laser-assisted caries removal (with Er,Cr:YSGG laser [Biolase Inc., Waterlase MD™ turbo]: 2,780 nm: 3,5W, 35 Hz, water: 35%, air: 45%)
- laser-assisted cavity preparation (Er,Cr:YSGG laser: 2,780 nm: 5 W, 30 Hz, water: 75%, air: 90%)
- laser-assisted enamel conditioning (with Er,Cr:YSGG laser: 2,780 nm: 2 W, 30 Hz, water: 75%, air: 90%)
- etching with Ultraetch 35% phosphoric acid (Ultradent Products, Inc., USA)
- application of resin-based dental adhesive system bond Clearfil™ SE Bond (Kuraray Europe GmbH);
- filling layer by layer with restorative material X-flow™ and Dyract® eXtra (Dentsply De Trey GmbH, Konstanz, Germany);
- curing with bluephase lamp (Ivoclar Vivadent AG, Liechtenstein);
- polish

On the basis of clinical cases, various laser treatments are demonstrated and presented with their short-term and long-term results.

Discussion and final conclusion

Advantages of laser-assisted pediatric dentistry are an opportunity for minimally invasive cavity preparation and the selective removal of caries tissue. The resulting good micro-retentive surface structure

plays an important role for subsequent adhesive techniques for composites. Further advantages are the bactericidal effect, the biostimulation of the tissue and accelerated wound healing.

Due to the reduced pain sensation of laser treatment, local anesthesia often is not needed and resulting lip bite injuries especially in very small children, can be avoided. Also, because of the fact that the application of laser light has a coagulating effect with the positive consequence of less bleeding in the operating field during the surgery and post-operatively, no sutures are needed and a second appointment for suture removal is not required in many cases.

The good compliance of children and adolescents under the precondition of a good clinical approach and appropriate use of laser technology opens an additional field of pediatric dental treatments and in some cases helps reducing the necessity of general anesthesia.

In summary, laser-assisted treatment methods show considerable advantages compared to conventional treatment methods and constitute an important step in extending the pediatric treatment options available.

Fig. 2 First right primary molar and second primary molar with caries lesion.

Fig. 3 Laser treatment with Er,Cr:YSGG laser: 2,780 nm, gold handpiece, Tip: MGG6, 2–5 W, 30 Hz, 140 μs, water: 40–75% and air: 60–90%.

Fig. 4 After treatment.

Fig. 5 Final result.

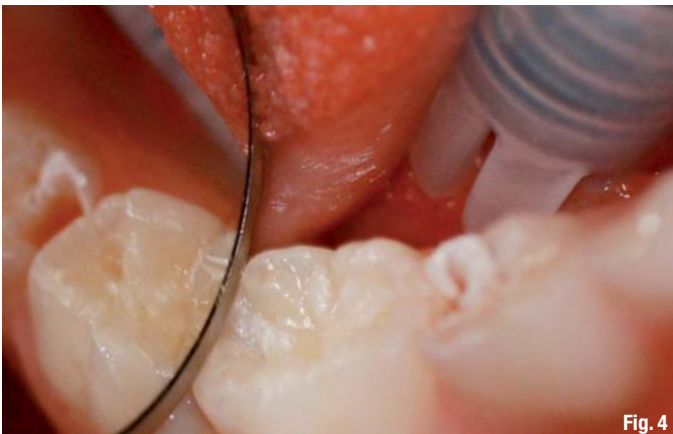


Fig. 4

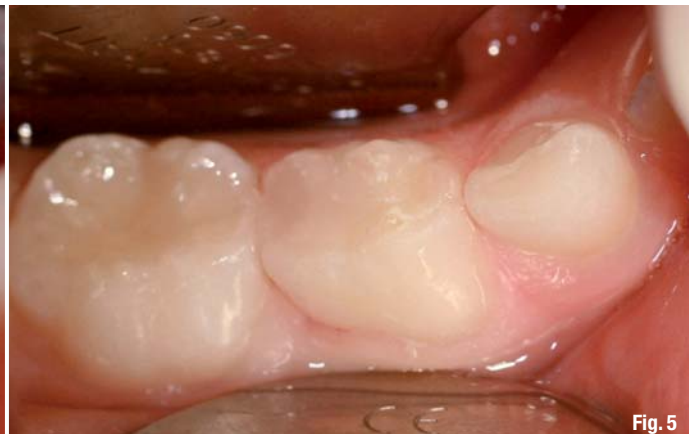

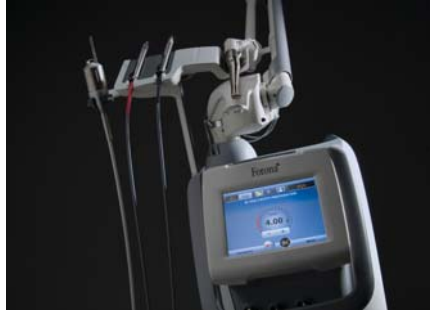Fig. 5

Manufacturer News

Fotona

TwinLight™ by Fotona

It is a well-established fact that different dental procedures require different laser wavelengths. Wavelength is important because specific body tissues interact in unique ways depending on the particular laser source. With the choice of two complementary wavelengths (in terms of their effect on tissues) Fotona's award-winning dental laser, the LightWalker, comes very close to being a "universal" laser. Laser-assisted dental treatments can be performed with either the most highly absorbed Er:YAG laser wavelength or the most homogeneously absorbed Nd:YAG laser wavelength.



LightWalker's TwinLight™ Treatment Concept combines these two premium wavelengths in one laser system, enabling practitioners to perform not only single-wavelength but also dual-wavelength (TwinLight™) treatments. Utilizing both of the two wave-

lengths in a single treatment makes optimum use of the unique laser-tissue interaction characteristics of each wavelength. For example, Nd:YAG laser energy is superior for coagulation and deep disinfection, while Er:YAG is uniquely efficient in ablating hard and soft tissues. Combined, they can dramatically improve the outcome of endodontic, periodontal and surgical treatments, guaranteeing maximum safety and efficacy.

Fotona d.d.

Stegne 7

1000 Ljubljana, Slovenia

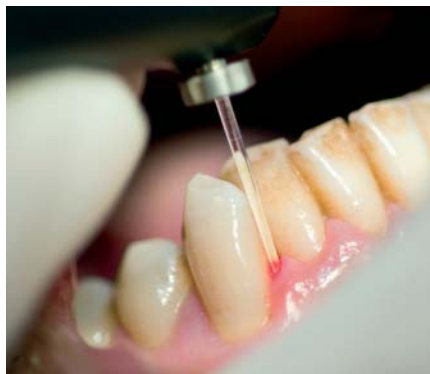info@lightwalkerlaser.com

www.lightwalkerlaser.com

KaVo

KaVo DIAGNOdent Perio probe: reliable and comfortable detector of calculus

The KaVo DIAGNOdent pen is well-known to be a unique instrument for the detection of caries. It can identify healthy and unhealthy tooth substance quickly and reliably by means of varying fluorescence. In addition to caries detection, the DIAGNOdent system can be used with a special Perio probe for the reliable and comfortable detection of periodontitis. The Perio probe detects concretions in the deepest pockets reliably and without pain, despite the presence of saliva or blood. It is therefore



an ideal control instrument after root cleaning. A gentler, more thorough cleaning of the pockets can thereby be achieved with a substantially enhanced healing. The readings of the DIAGNOdent pen are

communicated as digital and acoustic signals which communicate the need for treatment and increased compliance to the patient.

Clinical studies confirm that the use of the DIAGNOdent Perio probe for the detection of calculus and an increased control of the treatment improves the postoperative bleeding index and noticeably reduces pocket depth in comparison to a conventional probe.

KaVo Dental GmbH

Bismarckring 39

88400 Biberach/Riss, Germany


info@kavo.com

www.kavo.com

Hager & Werken

LaserHF—Radio frequency and laser combined for the first time

LaserHF® from Hager & Werken is a combined unit which for the first time offers two technologies in one device: laser and radio frequency. While tissue can be perfectly cut, resected and coagulated with radio frequency, the laser offers additional, fascinating applications in endodontics, periodontics as well as in implant surgery. On top of that, new approaches, such as the tissue treat-



ment in therapeutic terms (Low Level Laser Therapy) and antimicrobial photodynamic therapy (aPDT) can be carried out. LaserHF includes two types of laser: a diode laser with 975 nm/6 W and a diode soft laser with 650 nm/100 mW for LLLT and aPDT. An easy to use touch-screen offers 15 pre-set programs in the laser unit (10 x diode laser, 5 x diode soft laser). The radio frequency-unit offers various pre-set programs. Additionally, the user can save individual programs. Further information is available at www.hagerwerken.de.

Hager & Werken GmbH & Co. KG

Ackerstraße 1

47269 Duisburg, Germany

info@hagerwerken.de

www.hagerwerken.de

A.R.C. Laser

Soft tissue treatment with diode laser

A.R.C. Laser is known as the embodiment of soft tissue treatment with diode laser, and A.R.C. laser Q810/FOX is primarily applied in endodontics and periodontics. The compact high-performance instrument is battery-powered and has gained worldwide reputation for its cost efficiency.

A.R.C. Laser's JAZZ sapphire laser scalpel is the perfect complement to the diode laser: cutting and coagulation can be performed at the same time and the handling of JAZZ is similar to that of any regular surgical scalpel.



EmunDO® is a photodynamic colorant specifically designed for Q810. It was introduced at the IDS 2011 (International Dental Show, Cologne, 2011). EmunDO® allows the therapist to achieve germi-

cidal effects without using antibiotics. Since the colorant only accumulates at inflamed areas, it can be applied selectively. Stimulated by laser, singlet oxygen effectively destroys both gram-positive and gram-negative bacteria in the course of periodontal therapy.

EmunDO® is an approved therapy concept based on extensive research and created in cooperation with AALZ (Aachen Dental Laser Center, Germany).

A.R.C. Laser GmbH

Bessemerstr. 14
90411 Nuremberg, Germany

info@arclaser.de
www.arclaser.de

Biolase

25th Anniversary in 2012

Biolase, one of the world's leading manufacturers of dental lasers with nearly 20,000 units installed all over the world, is celebrating its 25th anniversary in 2012.

With the new diode laser Waterlase iPlus, Biolase takes the development of dental lasers to the next level and offers faster cutting and an economical design for infinite productivity. Waterlase iPlus has the highest, most flexible trunk fiber in the history of Biolase and also brings a graphical user interface which opens a new world of clinical capabilities. Biolase's 25 years of experience show in the large variety of tips, accessories and upgrades, and make Waterlase iPlus a superior system of dental lasers. Combined with i-lase, the smallest personal laser system, Waterlase iPlus supports a broad spectrum of laser-assisted treatments by



offering dual wavelengths. As a result, both versatility and convenience are increased.

Aside from technical solutions, Biolase and its international partners offer a wide range of postgraduate-training courses as well as permanent technical, scientific and economic support. With this objective in mind, Biolase also is one of the sponsors of this year's WFLD World Congress in Barcelona. Moreover, Biolase has only recently formed a new partnership named Biolase Germany with NMT Munich GmbH. Together with NMT Munich, whose experience with high-tech and state-of-the-art laser systems also dates back 25 years, Biolase plans to offer number-one support now for its German costumers.

Biolase Europe GmbH

Paintweg 10
92685 Floss, Germany

info@nmt-muc.de
www.biolase.com

Philips

Dental Hygienists would recommend Sonicare DiamondClean to each other

Members of the German Society of Dental Hygienists (Deutsche Gesellschaft für Dentalhygieniker/-innen, DGDH e.V.) have put Philips Sonicare DiamondClean through its paces under day-to-day clinical conditions. "Afterwards, 85% of the users wanted to recommend this sonic toothbrush to their colleagues", reports Sylvia Fresman, chairman of the DGDH.

The dental hygienists especially liked the new brush head: having 44% more bristles than the head of a ProResults brush, as well as a diamond-shaped arrangement of the bristles, the brush head plays a cru-



cial role in Sonicare's cleansing performance. A total of 89% of the testers described an intense cleansing experience, with 87% stating that Sonicare DiamondClean was "pleasantly powerful and effective".

This model of the Philips Sonicare line can clean even hard-to-reach areas, 74% of the test group confirmed. Moreover, 30% of the testers stated that they perceived a whitening effect after using Sonicare DiamondClean.

"Most impressive to me was the fact that 65% of the group said that Sonicare DiamondClean was one of the most remarkable new products in the past IDS year", Sylvia Fresmann adds.

Philips GmbH

Lübeckertordamm 5
20099 Hamburg, Germany

sonicare.deutschland@philips.com
www.philips.de/sonicare

13th WFLD World Congress in Barcelona

Author_Dr Antoni España



Fig. 1



Fig. 2

Fig. 1 _Dr Carlos Eduardo de Paula (President of the Scientific Committee), Dr Antoni España (President of the Congress), Dr Aldo Brugnera (Elect President of the WFLD) and Dr Josep Arnabat (SELO's President).

Fig. 2 _Dr Josep Arnabat, Dr Antoni España.

_From 26 to 28 April 2012 the 13th WFLD (World Federation for Laser Dentistry) World Congress will be held in Barcelona. The Hesperia Tower hotel is the conference venue, placed near the international airport of Barcelona. Specialists and speakers are invited to meet in Barcelona and talk about lasers in dentistry. More than 40 speakers from more than 20 different countries will give more than 150 lectures to show the latest advances in this field.

The WFLD will take place in two main rooms of the hotel: firstly, the most general lectures will be held in the "Auditorium", where a simultaneous translation from English to Spanish is given. These lectures have been selected for providing the listeners with all necessary information to include this new technology into their daily practice. The lectures will be also useful for those who want to know about the current situation of laser technology in everyday dentistry. Advanced aspects about the use of different types of laser will be exposed in the "Jupiter" room. These sessions will have a

highly scientific content, dealing with the latest advances of laser and taught by the internationally renowned scientists. Besides, there will be two additional rooms, which are going to be used for oral presentations and posters illustrating each speech.


The organization has furthermore proposed a scientific committee to evaluate the various oral presentations and posters, with the purpose of rewarding the best oral presentations and posters exhibited at the Congress. The committee has selected the lecturers with the aim of showing a wide range of topics, scientifically as well as clinically. The Congress programme has then been meticulously organized and the sessions have been divided into six specialities in order to avoid overlaps: periodontology, endodontics, oral surgery, implantology, restorative dentistry and low-level laser. Another important part of the Congress is the commercial exposition, which is going to be one of the most extensive of the WFLD so far because of the generous support by the Congress' sponsors.

implants

international magazine of oral implantology



You can also subscribe via
www.oemus.com/abo

 **Subscribe now! One issue free of charge!**



Social events will also be a decisive aspect of the Congress' success. Barcelona is a city with a vast cultural, artistic and culinary richness. Gaudi's architecture with the Sagrada Familia and Parc Güell, as well as the different museums and the best restaurants and culinary offers make Barcelona a special city. More than 20 restaurants in Barcelona are currently awarded with a Michelin star.

The Gala dinner is expected to be in the old bullring of the Arenas in Barcelona, which has recently been remodelled into a shopping centre. On its top floor, you can find the "Cupula de las Arenas", a fantastic stage where you can enjoy the beautiful view of Barcelona and the splendid fountains of Montjuïc. The dinner brings the WFLD Congress to a closure with an extensive programme consisting of different shows.

We encourage everybody to participate in this great experience of the World Federation Laser of Dentistry Congress: we hope to see you in Barcelona!_

I hereby agree to receive a free trial subscription of **implants international magazine of oral implantology** (4 issues per year). I would like to subscribe to **implants** for € 44 including shipping and VAT for German customers, € 46 including shipping and VAT for customers outside of Germany, unless a written cancellation is sent within 14 days of the receipt of the trial subscription. The subscription will be renewed automatically every year until a written cancellation is sent to OEMUS MEDIA AG, Holbeinstr. 29, 04229 Leipzig, Germany, six weeks prior to the renewal date.

▶ Reply via Fax +49 341 48474-290 to OEMUS MEDIA AG or per E-mail to: grasse@oemus-media.de

Last Name

First Name

Company

Street

ZIP/City/County

E-Mail

Signature

Notice of revocation: I am able to revoke the subscription within 14 days after my order by sending a written cancellation to OEMUS MEDIA AG, Holbeinstr. 29, 04229 Leipzig, Germany.

Unterschrift

OEMUS MEDIA AG
 Holbeinstr. 29, 04229 Leipzig
 Tel.: +49 341 48474-0
 Fax: +49 341 48474-290
 E-Mail: grasse@oemus-media.de



The Mundus ACP Program: aiming for a brighter future

Author: Prof Dr Norbert Gutknecht, Germany



Under the auspices of the Mundus ACP Program, the Portuguese representative of the World Federation of Laser Dentistry, and the MSc from RWTH Aachen University, Dr Miguel Rodrigues Martins from the Endodontic Department of Oporto University, Portugal, was recently selected to spend one month as an international lecturer at the School of Dental Sciences of the Nairobi University in Kenya.

The Mundus ACP Program belongs to the larger framework of the Erasmus Mundus Programme "Action 2" and consists of a partnership of 20 Higher Education Institutions from the European Union and several ACP Countries (Africa, Caribbean and Pacific). Its main goal is to enhance the cooperation in the area of higher education between the European

Union and the ACP Countries, by supporting master and doctorate students' mobility (from the ACP Countries to Europe) as well as teaching and administrative staff mobility (in both directions).

"These thirty days of lecturing in a completely different environment and an institution which has had several budget containments was definitely a magnificent experience: what might be considered a lack of material at first turns out to be easily made up for by human capabilities, personal interest and professional dedication."

In fact, the Kenyan experience has overcome initial suspects which mainly regarded the past requests for laser education to be part of the technological developments in Dentistry.

Fig. 1 & 2_Kenyan Association Congress Annual Conference and Exhibition. Nairobi, October 2011.



Fig. 1



Fig. 2





tion can afford to attend it. They know that proper education can lead to an improved lifestyle for both themselves and their families. Therefore, the commitment to learn and the respect for the institution are elevated to an uncommonly high level."

The School of Dental Sciences received the lecturer with enthusiasm and on a friendly basis. They had gathered all the necessary resources to not only provide the opportunity to perform theoretical lectures for undergraduates, but they also organized a full-day "Laser's in Dentistry" Symposium for postgraduate students and general practitioners, "Despite the short notice, the participation and the interest for the topic itself were unexpectedly high. Everyone was thrilled by the therapeutic possibilities and the advantages for laser applications in dentistry."

The question, "How much does it cost?" emerged more than once in the course of the presentations. To this simple question, Dr Miguel R. Martins offered a simple answer, "Laser technology may sometimes seem to cost too much, but knowledge can always be shared and taken for free."

"It was truly a coincidence, but during this teaching period, the opportunity emerged to lecture at the Kenyan Dental Association Congress, Nairobi, through the invitation of the Conservative Dentistry Department. Initially, the conference was meant to have a duration of 30 min, but the enthusiasm of the audience and the support from the chairman was so intense that the presentation finally took more than two hours of lecturing about vast applications of lasers."

The interest from the congress participants and the pre- and postgraduate students in the university was another reference point, "In most of the European countries, we give higher education a granted value. Students commonly associate university with something regular and given. In Kenya, university education is hard to achieve and just a small part of the popula-

In conclusion, the following remark can be seen as the predominant lesson of this lecture, "No matter if we are able to apply the knowledge immediately, learning and understanding other concepts and ideas are properties of a wise clinician. To be aware of new treatment strategies can push people forward, guide them on a quest for education and, finally, aim for a brighter future."

| | |
|------------------------------------------------------------------------------------------------------------------------------------------------------------------------------------------------------|-------|
| _contact | laser |
| <p>Prof Dr Norbert Gutknecht Aachen Dental Laser Center Pauwelsstr. 17 52074 Aachen, Germany</p> <p>Tel.: +49 241 47571314</p> | |

Fig. 3 Final meeting and balance of activities (from left to right): Dr Tom Dienya (Chief of Endodontic Department), Dr Miguel R. Martins, Prof Dr Wagaiu (Dean of School of Dental Sciences, Nairobi University), Prof Dr Eric Mitema (Mundus ACP Program and International Relationships Office Director), Dr Kisumbi (Department of Conservative Dentistry Chairman). **Fig. 4** Undergraduate Students at School of Dental Sciences, Nairobi University.



Fig. 3



Fig. 4

11th “MSc in Lasers in Dentistry” class graduates at RWTH Aachen University

Author_Dajana Klöckner, AALZ, Germany

In September 2011, another group of international dentists graduated from the RWTH Aachen University with a Master of Science in “Lasers in Dentistry” and is now officially certified to use laser applications correctly and successfully in their daily practices and for therapeutic purposes.

It takes a lot of courage, discipline and perseverance to manage attending MSc courses for two years on the one hand whilst practising dentistry and caring for patients on the other. But for dentists who want to offer innovative treatment to their patients, the success of applying new technologies seems undeniable. Two years ago, the now successful graduates had this line of thought on their minds when they signed up for their Master’s studies.

Since 2004, more than 110 dentists have successfully passed this accredited Master’s programme. Including the current graduates, the programme now has over 130 alumni from all over the

world, hailing from the European Union, Canada, China, Japan, India, Iran, Iraq, Pakistan, Saudi Arabia, Turkey, and many other countries.

Participating dentists recognize that dental laser systems have become more and more important: well-informed and discerning patients have increasingly inquired alternative treatments and expect their dentist to be able to inform them about new medical and technological developments. Hence, today laser has become one of the most important medical instruments and forms a foundation for successful and state-of-the-art dental clinics.

To meet these expectations, participants obtain sound theoretical knowledge in lectures and seminars led by renowned, competent and experienced international scientists and practitioners. Participants are guided towards using lasers successfully and professionally in their own practices by skill training sessions, exercises, practical applications, live operations and workshops with intensive assistance from scientific associates with doctorates.

The “Lasers in Dentistry” Master’s programme is the first accredited Master’s programme for laser dentistry in Germany. Indeed, it is recognized internationally as a valid academic degree by the EU and all countries of the Washington Accord (USA and Anglo-American nations), as well as by the Bologna Reform. The European Commission awarded it with the Bronze Medal for Lifelong Learning.

The next master course starts on 24 September 2012 at RWTH Aachen University. For more information about the programme and registration, please see www.aalz.de or contact Ms Dajana Klöckner (Tel.: +49 241 47571311, E-mail: kloeckner@aalz.de).



International events

2012

IDEX Istanbul

Istanbul, Turkey
5–8 April 2012
www.cnridex.com

IDEM International Dental Exhibition

Singapore
20–22 April 2012
www.idem-singapore.com

Dental Salon

Moscow, Russia
23–26 April 2012
www.dental-expo.com

SCANDEFA

Copenhagen, Denmark
26–28 April 2012
www.scandefa.dk

13th WFLD World Congress

Barcelona, Spain
26–28 April 2012
www.wfld-barcelona2012.com

4th international CAMLOG Congress

Lucerne, Switzerland
3–5 May 2012
www.camlogcongress.com

ITI Congress Switzerland

Biel, Switzerland
5 May 2012
www.iti.org/events

**90th General Session & Exhibition
of the IADR**

Rio de Janeiro, Brazil
20–23 June 2012
www.iadr.org

OSSTEM Europe Meeting 2012 Lisbon

Lisbon, Portugal
22–23 September 2012
en.osstem.com



Silver nanoparticles could help

Fight against oral infections

Yeasts that cause mouth infections can be killed using silver nanoparticles in the laboratory, scientists in Portugal have found. The researchers hope to test silver nanoparticles in mouthwash and dentures as a potential preventative measure against the infections, which are caused by *Candida albicans* and *Candida glabrata* and target the young, old and immunocompromised.

The study was conducted by Prof Mariana Henriques and her colleagues from the University of Minho in Largo do Paço, who investigated the anti-fungal properties of silver nanoparticles of different sizes to determine their effect against *C. albicans* and *C. glabrata*. These two yeasts cause various infections, including oral thrush and dental stomatitis, a painful infection that affects around seven out of ten denture wearers. Infections like these are particularly difficult to treat because the micro-organisms involved form biofilms.

The scientists used artificial biofilms in conditions that mimicked those of saliva as closely as possible. They then added different sizes and concentrations of silver nanoparticles and found that nanoparticles of different sizes were equally effective at killing the yeasts. Owing to the range of sizes of nanoparticles with anti-fungal properties, the researchers hope this will enable the nanoparticles to be used in many different applications.



Some researchers have expressed concerns regarding the safety of nanoparticle use but the Portuguese scientists stressed that this research is at an early stage and extensive safety trials will be carried out before any product reaches the market.

“With the emergence of candida infections, which are frequently resistant to the traditional anti-fungal therapies, there is an increasing need for alternative approaches. So, silver nanoparticles appear to be a new potential strategy to combat these infections,” Henriques said. “As the nanoparticles are relatively stable in a liquid medium they could be developed into a mouthwash solution in the near future.”

Moving forward, Henriques hopes to integrate silver nanoparticles into dentures, which could prevent infections from taking hold.

The study was published online in the Society for Applied Microbiology's Letters in Applied Microbiology journal.

Nobel Biocare appoints

New Head of Global Operations

Nobel Biocare announced that Frank Mengis will be appointed Senior Vice President Global Operations and member of the Executive Committee, effective 1 July 2012. He will replace Ernst Zaengerle, who will be retiring. Frank Mengis has extensive senior



management experience in operations and manufacturing in the life sciences field including the dental industry. Most recently, he held senior management positions in Project Management and Development, Global Manufacturing, Operations and Quality Management at Straumann Institute. Prior to that, Frank Mengis was Head of Pharma Capital Investment Projects at Karl Steiner, Switzerland, after having held various management positions at F. Hoffmann-La Roche, Switzerland, in areas including galenic engineering and pharmaceutical manufacturing. Frank Mengis obtained a degree in Mechanical Engineering from the University of Karlsruhe, and completed the Advanced Management Program at Harvard Business School. Nobel Biocare would like to thank Ernst Zaengerle for his commitment and contribution to Nobel Biocare, and wishes him all the best for his future.

Increase until 2030

German dental sector to grow considerably

While the dental sector in some countries may be facing hard times, German dental professionals and dental suppliers can look forward to the future. According to a recent study, about 76,000 jobs will be created in dental offices, dental laboratories and through dental retail sales until 2030. This represents an increase of 19 per cent compared with current figures. The study was conducted by the Institute of German Dentists (Institut der Deutschen Zahnärzte—IDZ) and WifOR Darmstadt, an independent economic research insti-

tute, upon the instruction of the National Association of Statutory Health Insurance Dentists (Kassenzahnärztliche Bundesvereinigung—KZBV) and the German Dental Association (Bundeszahnärztekammer—BZÄK). “The dental sector must not only be discussed as a cost factor. It's an economic factor and part of the health-care job machinery. Already, 400,000 people are working in the German dental sector,” said Dr Jürgen Fedderwitz, Chairman of the BZÄK Board. Prof Christoph Benz, Vice-President of BZÄK, commented:

“The job training rate in dental professions is traditionally high. Additionally, demographic developments will probably lead to a further employment stimulus.”

Both dental organisations pointed out that the positive forecast for the German dental sector depends on health policy representatives being willing to set stable conditions

References: KZBV/DTI

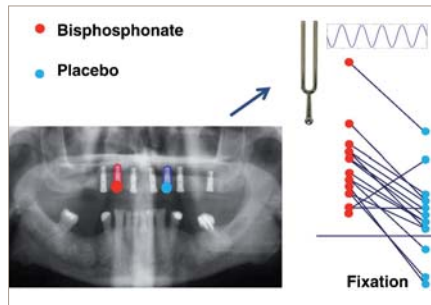
Study shows success

New coating accelerates fixation of dental implants

Researchers from Linköping University in Sweden have successfully tested a new drug coating on humans that allows titanium implants to adhere to the bone better and more rapidly. The findings could benefit patients with difficulty chewing following dental treatment.

Millions of people have bad teeth replaced with dental implants, which are embedded into the jawbone and provide retention for artificial teeth. After the procedure, many patients are unable to chew food. Using the current technology, it may take four to six months before the bone surrounding the implant has healed and is strong enough for the patient to begin to benefit from surgery.

The new coating consists of a nanometre-thin layer of protein that adheres to the metal surface. At-



tached to the protein is a drug belonging to the class of bisphosphonates, usually used to treat osteoporosis.

Now, for the first time, this method has been tested on humans. The study involved 16 patients. Each of them received two implants—one ordinary im-


plant and a similar surface-treated implant as described above. Neither the patient nor the dental surgeon knew which was which. After six months, it was noted that for 15 of the 16 patients the surface-treated screw was markedly much better established. Already after two months, X-ray images showed positive changes in the tissue surrounding the surface-treated implants. According to the researchers, no complications occurred.

“It is the first time ever anyone has succeeded in reinforcing the bone around an implant with localised medication,” said study leader Per Aspenberg, Professor of Orthopaedics, who devised the method of using bisphosphonates in this way. The study was published online in the Bone journal.

Reference: DTI

Most efficient way explored

Researchers investigate efficiency of bladed tooth shape



Using a combination of guillotine-based experiments and cutting-edge computer modelling, researchers at the University of Bristol have explored the most efficient ways for teeth to cut food. Their results demonstrate how precisely the shape of an animal's teeth is optimised to suit the type of food it eats. There is massive variety in tooth shapes in the natural world, from long, serrated teeth in Tyrannosaurus rex to triangular teeth in sharks and our own complex molars. Teeth can enable animals to crush, chop, grind or even cut food into pieces small enough to swallow. Such cutting instru-

ments, however, are not restricted to toothed animals. Bird beaks, insect mouth parts and even the roughened tongue of snails can also be used to break down food. Nevertheless, how teeth are able to cut and break down food has not been extensively examined. Now, two researchers at the University of Bristol's School of Earth Sciences have investigated this problem. In their study, research fellow Dr Philip Anderson and lecturer Dr Emily Rayfield used a unique double-bladed guillotine and measured the force needed by different tooth shapes to compress food materials. Finite-element analysis, a computational engineering technique, was then used to mimic these experiments and measure different variables, such as the total energy required. The researchers found that different shaped bladed teeth are optimised for different types of food.

“The actual hardness or toughness of the food item has a strong effect on what type of tooth shape is most efficient for cutting it,” Anderson said. “We looked specifically at V-shaped bladed edges,

which are similar to tooth shapes found in some sharks and the cheek teeth of many carnivorous mammals, and found that the angle of the V could be optimised for different foods.” According to Anderson, this sort of analysis is only possible with a computer model, which the researchers created to mimic the physical experiments. With the validated model, they were able to alter aspects of the tooth shape until they found a specific shape that used the least energy. “These results might seem rather obvious,” said Rayfield, “because we know tooth shape is adapted to diet. But we were surprised at the precision and predictability of the fit of tooth shape to dietary item.”

The researchers hope this new integrated methodology will create a new framework for exploring the evolutionary history of dental shape and how it relates to diet. Their study, “Virtual experiments, physical validation: Dental morphology at the intersection of experiment and theory”, was published ahead of print on 7 March in the Journal of the Royal Society Interface.

Reference: DTI

laser
international magazine of laser dentistry



Publisher

Torsten R. Oemus
oemus@oemus-media.de

CEO

Ingolf Döbbecke
doebbecke@oemus-media.de

Members of the Board

Jürgen Isbaner
isbaner@oemus-media.de

Lutz V. Hiller

hiller@oemus-media.de

Chief Editorial Manager

Norbert Gutknecht
ngutknecht@ukaachen.de

Co-Editors-in-Chief

Samir Nammour
Jean Paul Rocca

Managing Editors

Georg Bach
Leon Vanweersch

Division Editors

Matthias Frenzen
European Division

George Romanos
North America Division

Carlos de Paula Eduardo
South America Division

Toni Zeinoun
Middle East & Africa Division

Loh Hong Sai
Asia & Pacific Division

Senior Editors

Aldo Brugneira Junior
Yoshimitsu Abiko
Lynn Powell
John Featherstone
Adam Stabholz
Jan Tuner
Anton Sculean

Editorial Board

Marcia Martins Marques, Leonardo Silberman, Emina Ibrahim, Igor Cernavin, Daniel Heyselaer, Roeland de Moor, Julia Kamenova, T. Dostalova, Christliebe Pasini, Peter Steen Hansen, Aisha Sultan, Ahmed A Hassan, Marita Luomanen, Patrick Maher, Marie France Bertrand, Frederic Gaultier, Antonis Kallis, Dimitris Strakas, Kenneth Luk, Mukul Jain, Reza Fekrazad, Sharonit Sahar-Helft, Lajos Gaspar, Paolo Vescovi, Marina Vitale, Carlo Fornaini, Kenji Yoshida, Hideaki Suda, Ki-Suk Kim, Liang Ling Seow, Shaymant Singh Makhan, Enrique Trevino, Ahmed Kabir, Blanca de Grande, José Correia de Campos, Carmen Todea, Saleh Ghabban Stephen Hsu, Antoni Espana Tost, Josep Arnabat, Ahmed Abdullah, Boris Gaspirc, Peter Fahlstedt, Claes Larsson, Michel Vock, Hsin-Cheng Liu, Sajee Sattayut, Ferda Tasar, Sevil Gurgan, Cem Sener, Christopher Mercer, Valentin Preve, Ali Obeidi, Anna-Maria Yannikou, Suchetan Pradhan, Ryan Seto, Joyce Fong, Ingmar Ingenegeren, Peter Kleemann, Iris Brader, Masoud Mojahedi, Gerd Volland, Gabriele Schindler, Ralf Borchers, Stefan Grümer, Joachim Schiffer, Detlef Klotz, Herbert Deppe, Friedrich Lampert, Jörg Meister, Rene Franzen, Andreas Braun, Sabine Sennhenn-Kirchner, Siegfried Jänicke, Olaf Oberhofer, Thorsten Kleinert

Editorial Office

Dajana Mischke
d.mischke@oemus-media.de

Claudia Jahn

c.jahn@oemus-media.de

Executive Producer

Gernot Meyer
meyer@oemus-media.de

Designer

Sarah Fuhrmann
s.fuhrmann@oemus-media.de

Customer Service

Marius Mezger
m.mezger@oemus-media.de

Published by

OEMUS MEDIA AG
Holbeinstraße 29
04229 Leipzig, Germany
Tel.: +49 341 48474-0
Fax: +49 341 48474-290
kontakt@oemus-media.de
www.oemus.com

Printed by

Messedruck Leipzig GmbH
An der Hebemärchte 6
04316 Leipzig, Germany

laser

international magazine of laser dentistry
is published in cooperation with the World Federation for Laser Dentistry (WFLD).

Copyright Regulations


_laser international magazine of laser dentistry is published by OEMUS MEDIA AG and will appear in 2012 with one issue every quarter. The magazine and all articles and illustrations therein are protected by copyright. Any utilization without the prior consent of editor and publisher is inadmissible and liable to prosecution. This applies in particular to duplicate copies, translations, microfilms, and storage and processing in electronic systems.

Reproductions, including extracts, may only be made with the permission of the publisher. Given no statement to the contrary, any submissions to the editorial department are understood to be in agreement with a full or partial publishing of said submission. The editorial department reserves the right to check all submitted articles for formal errors and factual authority, and to make amendments if necessary. No responsibility shall be taken for unsolicited books and manuscripts. Articles bearing symbols other than that of the editorial department, or which are distinguished by the name of the author, represent the opinion of the afore-mentioned, and do not have to comply with the views of OEMUS MEDIA AG. Responsibility for such articles shall be borne by the author. Responsibility for advertisements and other specially labeled items shall not be borne by the editorial department. Likewise, no responsibility shall be assumed for information published about associations, companies and commercial markets. All cases of consequential liability arising from inaccurate or faulty representation are excluded. General terms and conditions apply, legal venue is Leipzig, Germany.



laser

international magazine of laser dentistry



 **Subscribe now!**

You can also subscribe via
www.oemus.com/abo

I would like to subscribe to **laser** international magazine of laser dentistry (4 issues per year) for € 44 including shipping and VAT for German customers, € 46 including shipping and VAT for customers outside Germany, unless a written cancellation is sent within 14 days of the receipt of the trial subscription. The subscription will be renewed automatically every year until a written cancellation is sent to OEMUS MEDIA AG, Holbeinstr. 29, 04229 Leipzig, Germany, six weeks prior to the renewal date.

▶ **Reply** via Fax +49 341 48474-290 to OEMUS MEDIA AG or per E-mail to grasse@oemus-media.de

Last Name, First Name

Company

Street

ZIP/City/County

E-mail

Signature

Notice of revocation: I am able to revoke the subscription within 14 days after my order by sending a written cancellation to OEMUS MEDIA AG, Holbeinstr. 29, 04229 Leipzig, Germany.

Signature

The Dual Wavelength *waterlase**iPlus™

Advancing Laser Technology to Its Ultimate

INTUITIVE & INTELLIGENT GRAPHICAL USER INTERFACE

For example, performing a Class I Cavity Prep with the iPlus™ is as easy as 1,2,3...

- Step 1** Select "Restorative" from the first screen
- Step 2** Choose "Class I" from the next screen that appears automatically
- Step 3** Specify any other concerns such as patient sensitivity or bond strength
That's it! Step on the foot pedal, and start working.


iLASE™ 940nm DIODE LASER DOCKING STATION

- + Adds dual wavelength versatility and convenience
- + First totally wireless dental laser
- + 5 Watts peak power with ComfortPulse™
- + Battery operated with finger switch activation
- + Exclusive bendable tips in many diameters & lengths



BREAKS THE SPEED BARRIER

- + RR™ powered laser delivers 100 pulses/sec. for superior soft-tissue cutting
- + Patented laser technology delivers 10 watts of power
- + Enables multi-quadrant same-day procedures



ENABLES BIOLOGICALLY FRIENDLY DENTISTRY

- + No micro-fractures or thermal damage
- + More precise, minimally invasive

PROVIDES GREAT RETURN ON INVESTMENT

- + Increases treatment acceptance of day-to-day restorative cases
- + Attracts new patients
- + Increases productivity and enables new procedures



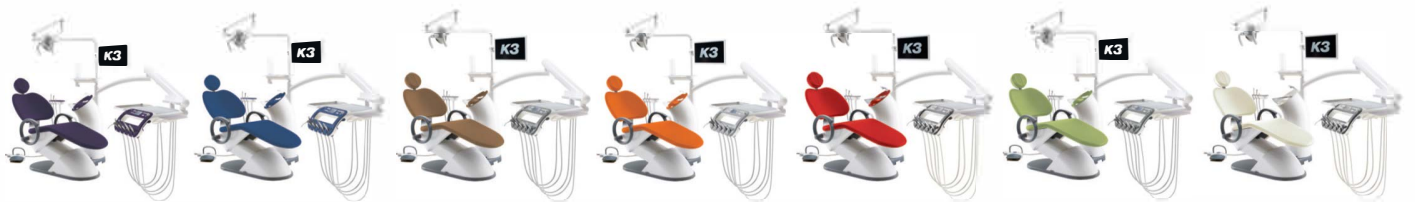©2012

K3™ Unit Chair



OSSTEM[®]
IMPLANT

آزاد تجارت پارس
AZAD TEJARAT PARS.LTD



پنل عملکرد

عملکردهای متنوع با دکمه برای تنظیمات دستی، کراشوار از جنس شیشه نشکن و دکمه On/Off چراغ که بر روی پنل در Side Table قرار داده شده است.



Rotating double-jointed table arm

تیبل آرم دو مصله چرخشی
تیبل آرم چرخشی دو مصله باعث استفاده بهتر از فضا برای دستیار پزشک و کاربرد دوستی می شود.



Water supply system with double sensor / Glass spittoon container

سیستم لیوان بر کن هوشمند / محتوی اسپتون شیشه ای
تغذیه آب و کراشوار از جنس شیشه نشکن طراحی شده با شکل و ارتفاع مناسب، برای بیماران در تمامی سنین و افزایش آرامش و راحتی بیمار می باشد. علاوه بر آن سیستم لیوان بر کن هوشمند حجم آب مورد نیاز را کنترل می کند و شیشه ی شفاف و بزرگ کراشوار نظافت آن را دقیق تر و بهتر خواهد کرد.



With adjustable water supply / Switch for hot water

مخزن آب قابل تنظیم / مجهز به سیستم آبگرمکن
دکمه کنترل ذخیره آب و زیر آب On/Off برای آب داغ، تهیه شده در قسمت جلوی یونیت که باعث راحتی کلر کاربران می شود.



USB Port & 220V power socket

خروجی USB و سوکت ۲۲۰ ولت



Suction filter & side rack

فیلتر ساکشن و میز ابزار
فیلتر ساکشن با قابلیت شستنوی آسان نظافت و نگهداری را آسان می کند و میز ابزار قابل جدا شدن قابلیت نگهداری ابزار گوناگون در طول درمان را دارد.

