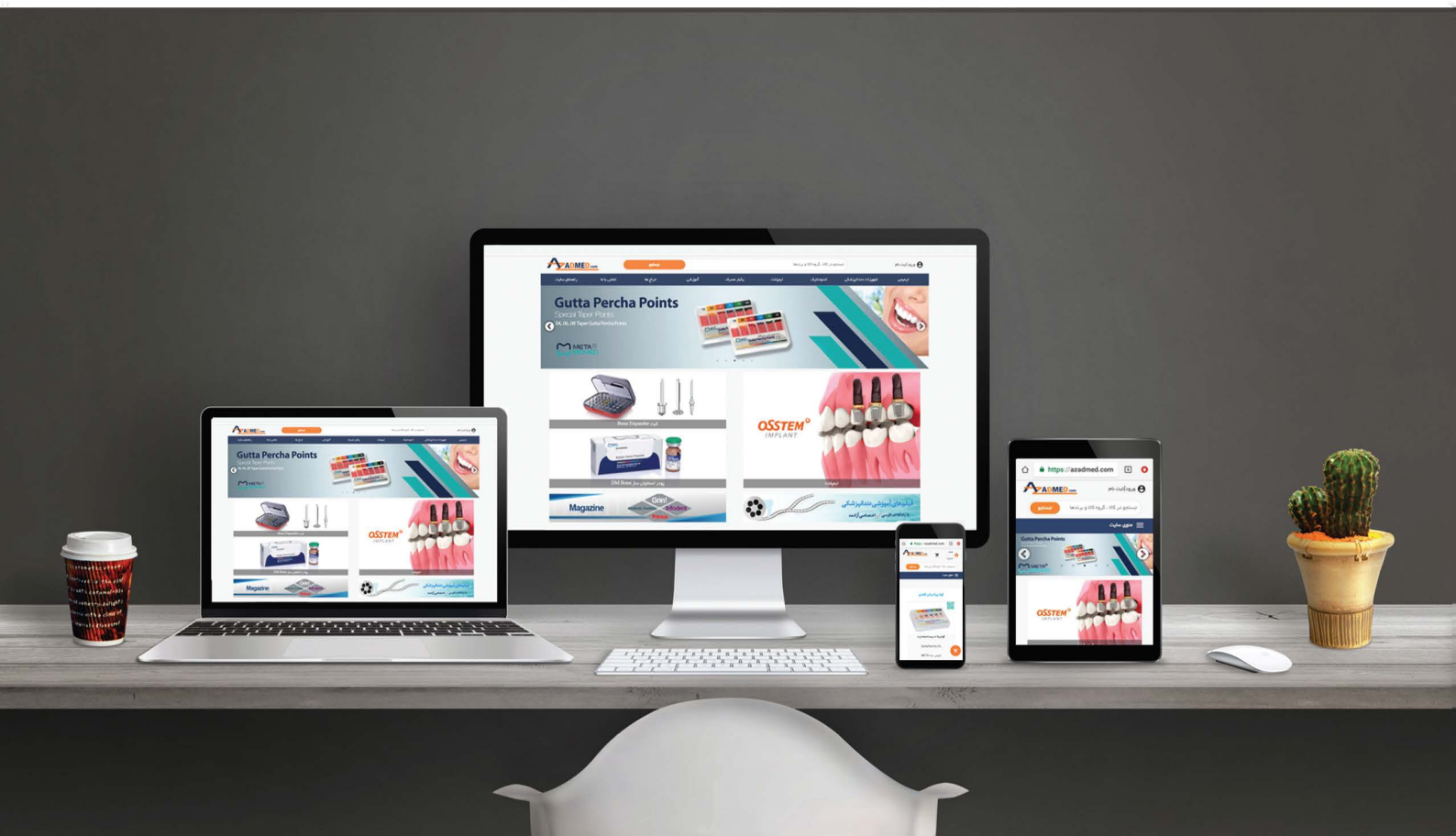




آزاد تجارت پارس
AZAD TEJARAT PARS.LTD

AZADMED.com



www.azadmed.com



 azaadtejaratpars

 @azadmed2

 88 98 80 63 - 6

laser

international magazine of laser dentistry

2²⁰¹²



| **research**

The antibacterial effects of lasers in endodontics

| **overview**

Laser treatment of dentine hypersensitivity

| **case report**

A novel technique of Er:YAG laser-enhanced early implant stability



The Dual Wavelength *waterlase**iPlus™

Advancing Laser Technology to Its Ultimate

INTUITIVE & INTELLIGENT GRAPHICAL USER INTERFACE

For example, performing a Class I Cavity Prep with the iPlus™ is as easy as 1,2,3...

- Step 1** Select "Restorative" from the first screen
 - Step 2** Choose "Class I" from the next screen that appears automatically
 - Step 3** Specify any other concerns such as patient sensitivity or bond strength
- That's it! Step on the foot pedal, and start working.*


iLASE™ 940nm DIODE LASER DOCKING STATION

- + Adds dual wavelength versatility and convenience
- + First totally wireless dental laser
- + 5 Watts peak power with ComfortPulse™
- + Battery operated with finger switch activation
- + Exclusive bendable tips in many diameters & lengths



BREAKS THE SPEED BARRIER

- + RR™ powered laser delivers 100 pulses/sec. for superior soft-tissue cutting
- + Patented laser technology delivers 10 watts of power
- + Enables multi-quadrant same-day procedures



ENABLES BIOLOGICALLY FRIENDLY DENTISTRY

- + No micro-fractures or thermal damage
- + More precise, minimally invasive

PROVIDES GREAT RETURN ON INVESTMENT

- + Increases treatment acceptance of day-to-day restorative cases
- + Attracts new patients
- + Increases productivity and enables new procedures



©2012

Laser (in)dispensable in dentistry?



Dr Georg Bach

Have you been following the coverage of dental congresses in the past few weeks? If so, you might have felt just the same positive sensation as I have when I came across the fact that scientific contributions on laser applications in implantology have gained a high rank in the past congress season. By the way, the same holds true for scientific texts on implantology in dental specialist publications.

The growing impact of laser applications on both congresses and scientific literature does indeed pose a snapshot of the current status of laser in dental therapies and might even express a recent trend. This trend, in my view, bears various notable facets:

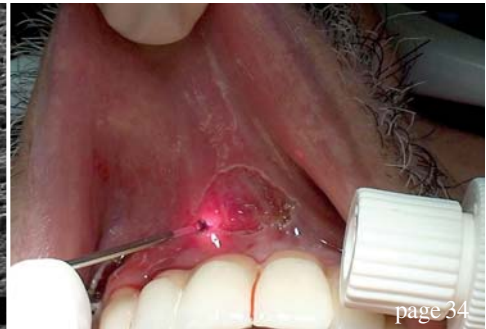
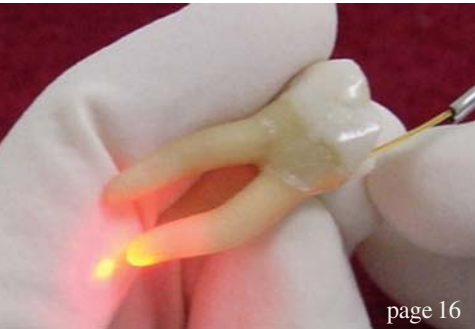
Many of the numerous implantological congresses and symposia intersecting with laser dentistry have included reports on the application of monochromatic light into their programs. Moreover, whole sessions are dedicated to laser in both implantological and periodontal congresses and symposia. On such occasions, the high value of atraumatic laser incisions with significantly reduced hemorrhage is highlighted, along with the lack of alternatives to laser surface decontamination in the treatment of periimplantitis.

The antibacterial effects of lasers in endodontics and the advantages of laser therapy of oral haemangiomas contribute to the wide range of applications of laser in dentistry.

As you can see, we are provided with a sufficient (and evidence-based) number of opportunities to pursue our passion for monochromatic light in dental therapy. It follows that our résumé be "No (more) dentistry without laser"!

With best regards,

Dr. Georg Bach



| editorial

- 03 **Laser (in)dispensable in dentistry?**
| Dr Georg Bach

| research

- 06 **Laser in oral surgery** and medicine—Part II
| Antonio Batista-Cruzado *et al.*
- 12 **Evaluation of combined Nd:YAG laser treatment of moderate periodontitis**
| Dr Anna-Maria Yiannikou-Loucaidou
- 16 **The antibacterial effects of lasers** in endodontics
| Dr Selma Cristina Cury Camargo

| overview

- 24 **Laser treatment of dentine hypersensitivity**
| Dr Ute Botzenhart *et al.*

| case report

- 28 **A novel technique of Er:YAG laser-enhanced early implant stability**
| Dr Kenneth Luk *et al.*
- 32 **Laser therapy of oral haemangiomas**
| Friedrich Müller *et al.*

| industry report

- 34 **Lasers in oral Implantology**
| Dr Ilay Maden *et al.*

| education

- 40 **“Laser Supported Dentistry”** in Turkey
| Prof Dr Aslihan Usumez *et al.*
- 42 **Innovation and information at IDS 2013**
| VDDI

| meetings


- 43 **International events 2012**
- 44 **DGL annual conference** in Leipzig, Germany
| Jürgen Isbaner
- 46 **“Scientifically, laser has now reached its highest standard”**
| Dajana Mischke

| news

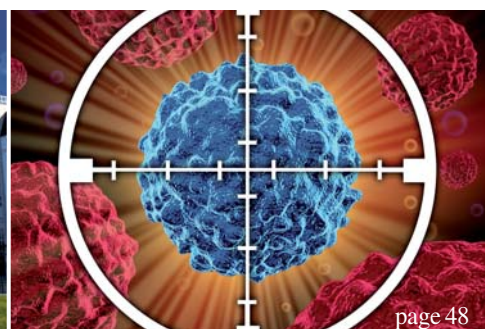
- 38 **Manufacturer News**
- 48 **News**

| about the publisher

- 50 | imprint



Cover image courtesy of Biolase Technology Inc., www.biolase.com.
Original Background: ©Excellent backgrounds
Artwork by Sarah Fuhrmann, OEMUS MEDIA AG.



FASCINATION OF LASER DENTISTRY

FOR EXPERTS AND BEGINNERS

SEPTEMBER 7-8, 2012
LEIPZIG
HOTEL THE WESTIN
LEIPZIG, GERMANY

16
JAHRESTAGUNG DER DGL e.V.
LASER START UP 2012

LASER
START UP

7. UND 8. SEPTEMBER
HOTEL THE WESTIN LEIPZIG

FASCINATION OF
LASER DENTISTRY

21. JAHRESTAGUNG DER DGL e.V.

LASER START UP 2012



- 7./8. September 2012
- Hotel THE WESTIN LEIPZIG

HAUPTSPONSOR
BIOLASE

oemus

ORGANIZATION/ REGISTRATION

Deutsche Gesellschaft für Laserzahnheilkunde e.V.
(German Society for Laserdentistry)

Klinik für Zahnerhaltung, Parodontologie und Präventive
Zahnheilkunde Universitätsklinikum der RWTH Aachen,
Pauwelsstraße 30, 52074 Aachen, Germany

Fon: +49 241 8088-164

Fax: +49 241 803388-164

sekretariat@dgl-online.de

www.dgl-online.de

OEMUS MEDIA AG

Holbeinstraße 29

04229 Leipzig, Germany

Fon: +49 341 48474-308

Fax: +49 341 48474-390

event@oemus-media.de

www.oemus.com

www.dgl-jahrestagung.de

www.startup-laser.de

MAIN SPONSOR

BIOLASE

FURTHER INFORMATION

oemus

PLEASE FAX THIS FORM

+49 341 48474-390

Further information about:

LASER START UP 2012

21st ANNUAL CONGRESS OF THE DGL e.V.

September 7-8, 2012, Leipzig, Germany

NAME/E-MAIL

OFFICE STAMP

laser 2/12

Laser in oral surgery and medicine—Part II

Authors Antonio Batista-Cruzado, Daniel Torres-Lagares, Blanca Moreno-Manteca, Gerd Volland, Patricia Bargiela-Perez, Martin Jorgén & Jose-Luis Gutierrez-Perez, Spain

The laser has been used in the field of oral surgery for a wide range of indications. In this article, we focus on its surgical uses. The success of the surgical treatment of lesions in the oral cavity depends greatly on knowledge of the aetiology and histology of the lesion. There are pathologies that can be treated with laser, such as cancer sores and hyperkeratosis. Others, like candidiasis, cannot be treated with laser. Furthermore, laser has quickly become a predictable and favourable treatment modality for leukoplakia, haemangioma and epulis.

In the last issue of laser, the authors gave an overview on in vitro studies and in vivo animal studies in this field. They continued by giving examples of in vivo studies on humans on the subjects of wound and bone healing supported by laser treatment. Finally, the authors analysed soft-tissue surgery and examples of cancer treatment via CO₂ laser and photodynamic therapy under the headline of "clinical studies". They continue this chapter in the present issue of laser by discussing, among others, leukoplakia treatment, benign diseases and frenectomy. In the conclusion, they sum up the positive effects of laser on oral surgery.

Leukoplakia treatment

Leukoplakia is a premalignant lesion associated with excessive consumption of alcohol and tobacco.

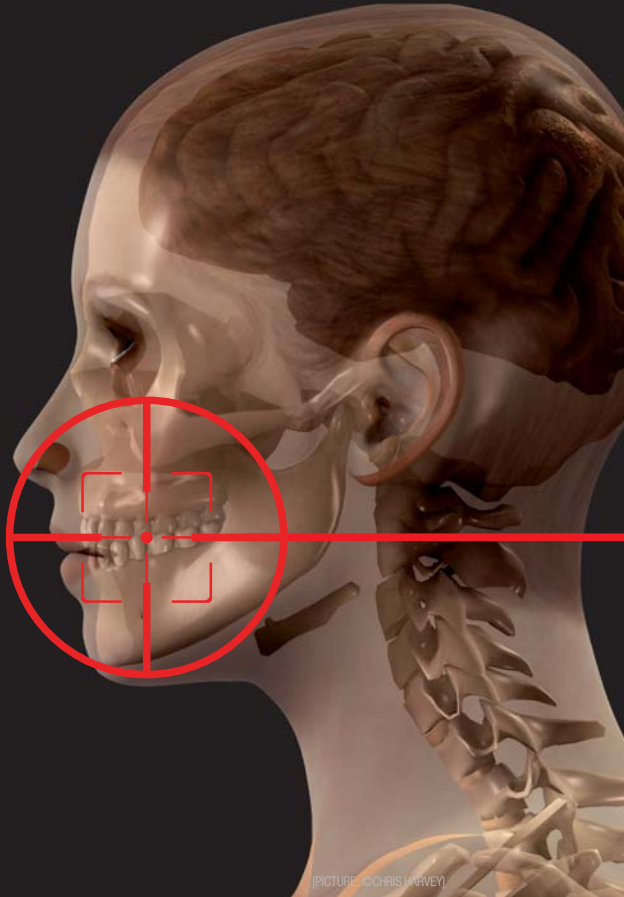
Although there is no specific treatment to prevent its recurrence, abandoning these habits can decrease the probability of recurrence, as well as the transformation into malignant tumours.

Vivek et al.²⁴ treated 28 patients with histologically diagnosed leukoplakia in order to study efficacy, safety and acceptability of lasers, particularly the Nd:YAG laser. After laser treatment, post-operative complications associated with ablation were assessed. They recorded only mild to moderate pain, with slight swelling up to 72 hours post-treatment. A follow-up study was initiated three years later. Approximately 92 per cent of the patients were found to have been cured. Therefore, the authors regarded Nd:YAG laser as an effective tool for the treatment of this pathology.

There are also studies that recommend CO₂ laser for the excision of leukoplakia. For example, Reddi and Shafer²⁵ found the CO₂ laser to be of great success in the excision of leukoplakia in their study. They also applied laser to the treatment of erythroplasia and lichen planus.

Treatment of lichen planus

Owing to its inflammatory effects, lichen planus can be painful both in atrophic and erosive forms.



Benign diseases

In this section, pathological entities treated with laser in recent years are discussed. Attention is paid to the technique applied, as well as frequency and impact of the laser used for the respective oral surgery.

Owing to the high frequency of pyogenic granuloma in the oral cavity, especially during pregnancy, Jafarzadeh et al.²⁸ reviewed this disease and considered treatments and new approaches. Possible treatment options are, among others, resection by means of a scalpel, cryotherapy, the use of corticosteroids, or the use of an Nd:YAG or CO₂ laser. The authors state that laser treatment can help control bleeding, does not result in adverse effects and is therefore consid-

ered a successful treatment method with high acceptance by patients.

Actinic cheilitis is another medical condition that can be treated with laser, since results show a high clinical resolution and low recurrence. Its successful treatment is based on the removal of epithelium while avoiding the resulting scarred tissue. De Godoy Peres et al.²⁹ compared two protocols of low morbidity clinico-histologically in which CO₂ laser was used with different parameters. A biopsy was done before and after laser treatment. In both groups, a significant reduction in epithelial dysplasia was achieved. Therefore, the authors recommend the use of lasers in cases of mild to moderate dysplasia.

Adipose tissue tumours are found frequently in the maxillo-facial region, for example on the lips and buccal mucosa. Although these tumours have traditionally been treated with a scalpel, laser can be a valid alternative. Suture is not necessary, and there is only minimal tissue scarring. Capodiferro et al.³⁰ is an insightful study on this topic.

Hyperkeratosis

Abnormal thickening of the stratum corneum caused by an increase of keratin is known as hyperkeratosis. The biological behaviour of this lesion is related to different histopathological changes. Various therapies, such as the use of scalpel, electrocautery, cryotherapy, PDT and topical medications have been proposed for its removal. Owing to advances in the use of laser in the oral environment, laser therapy appears a promising method for treating hyperkeratosis.

Santos et al.³¹ sought to verify the advantages of CO₂ lasers (10,600 nm) and removed lesions by focusing the beam of light around each lesion. The removed tissue was then sent for histopathological ex-

The traditional treatment, therefore, makes use of topical corticosteroids.

Cafaro et al.²⁶ conducted a prospective cohort study of 13 patients with lichen planus in order to investigate the effectiveness of LLLT. Patients were given biostimulation by diode laser (904 nm, pulsed mode). In general, a decrease in the size of the lesions and pain, and overall stable results were observed. The authors therefore recommend LLLT as a possible treatment for patients with lichen planus, but recommend that future studies be done with a larger group of patients in order to corroborate their results.

Aphthous stomatitis

LLLT has also been used in the treatment of recurrent aphthous stomatitis. The study by De Souza et al.²⁷ employed LLLT not as an inhibitor of the process, but for its modulating and healing effect on tissues. The authors assessed the effect of LLLT on aphthous stomatitis in 20 patients divided into two groups. Group I was treated with topical corticoids (triamcinolone acetonide) and group II was treated via diode laser (670 nm, 50 mW). Patients reported a decrease in pain already directly after laser treatment. Four days post-treatment, the lesion had receded completely in group I, compared with complete recession seven days post-treatment in group II.

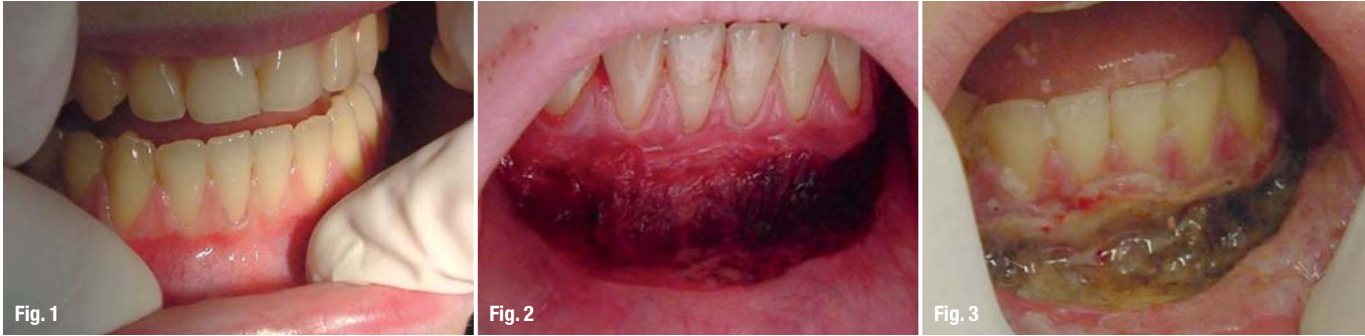

Fig. 1 Long-term case of vestibuloplasty. Situation on 15th of June, 2003: no gingiva attached at the lower jaw front.

Fig. 2 Long-term case of vestibuloplasty. ER:YAG treatment (1,000 μ s, 15 Hz, 400 mJ, no water, no air). Very low bleeding, periosteum not damaged. Gain of 10 mm.

Fig. 3 Long-term case of vestibuloplasty. Removal of peripac periodontal dressing, three days after the surgery.

amination. An improvement in haemostasis was achieved by defocusing the laser beam. The authors assert that this technique is easily applied and without post-operative complications.

Treatment of vascular lesions

Large vascular lesions in the orofacial region are often very difficult to remove. Therefore, the use of laser has been suggested as an effective way to remove major vascular lesions through photocoagulation. Angiero et al.³² investigated the effectiveness of photocoagulation and treated 136 patients with a diode laser. More than 98 % of these cases displayed complete remission. The study therefore demonstrated that diode laser treatment can prevent recurrence and complication, while the healing time is shortened.

Ostectomy

Stübinger et al.³³⁻³⁶ closely studied the use of Er:YAG laser on bone tissue and its biological effects. Applications range from different kinds of ostectomy, taking grafts from a tubercle and the chin, as well as tooth extraction. Among the benefits of Er:YAG laser treatment are high accuracy without wasting bone, along with a low risk of traumatising soft tissue or tissue charring, or of any complications in the healing of wounds. In order to achieve the best results, Stübinger et al.³³⁻³⁶ advocate the use of planning software. The amount of time needed for the surgery and the lack of depth control are among the disadvantages of the Er:YAG laser.

Third molar

Post-operative pain and oedema are common after the surgical removal of the lower third molar. Traditionally, non-steroidal anti-inflammatory drugs and steroids have been used to treat these symptoms. LLLT has only recently been considered as a possible analgesic agent to control post-operative pain, lock-jaw or inflammation. Markovic and Todorovic³⁷ compared the analgesic effects of two anaesthetics, the use of LLLT and the administration of diclofenac in their study. Compared with the control group, who only received regular post-operative recommendations, participants treated with

laser showed significantly reduced post-operative pain.

One year later, Markovic and Todorovic³⁸ studied the effectiveness of dexamethasone and the use of LLLT in reducing post-operative swelling. The study was conducted in 30 patients divided into four groups. Group I was irradiated immediately after the surgery. In addition to laser, an intramuscular injection of 4 mg dexamethasone was administered to group II in the internal pterygoid muscle. Group III was given 4 mg of systemic dexamethasone (intramuscular injection in the deltoid region) in addition to LLLT, which was followed by 4 mg dexamethasone intra-orally six hours after surgery. Group IV was the control group and received only the usual post-operative recommendations. Group II showed the lowest incidence of oedema. The authors concluded that LLLT can be recommended for the reduction of inflammation, an effect that can be increased by topical corticoids.

Amarillas-Escobar et al.³⁹ conducted a similar study on the extraction of wisdom teeth. Their study employed 15 patients who were treated with a diode laser (810 nm, 100 mW) intra-orally and extra-orally, and a control group of 15 patients who were not irradiated. The experimental group showed no statistically significant differences compared with the control group, although a reduction in post-operative pain, swelling and lock-jaw was detected.

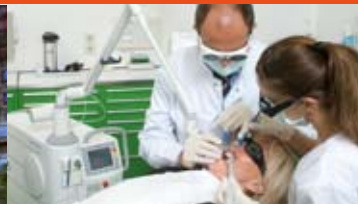Frenectomy

The term "frenectomy" refers to the complete removal of the frenulum from either the lip or the tongue. This can be done by either conventional surgery using a scalpel or laser. Recently, possible post-operative discomfort for the patient has been widely discussed.

Haytac and Ozcelik⁴⁰ randomly selected 40 patients for their study who had originally been intended to undergo another form of treatment. Each patient was asked to rate functional complications and pain according to a scale from one to seven. All of the patients perceived laser application positively

**Lay the Foundations to your
successful Future now!**

The next Master programme starts on **24 September 2012** in Aachen



Master of Science (M.Sc.) in Lasers in Dentistry

Become a part of the International Dentists' Elite!

- The first accredited M.Sc. programme in dentistry in Germany
- Career-accompanying postgraduate programme of two years at the University of Excellence RWTH Aachen
- Combination of lectures, skill training sessions, live ops, tutorials, and practical workshops
- Internationally accepted and accredited by the German Government, the European Union, the Washington Accord and the Bologna Process
- Science-based and practice-orientated on highest national and international level



Aachen Dental Laser Center

More information:

AALZ GmbH · Pauwelsstrasse 17 · 52074 Aachen · Germany
Tel. +49 - 2 41 - 47 57 13 10 · Fax +49 - 2 41 - 47 57 13 29
www.aalz.de · info@aalz.de

**RWTHAACHEN
UNIVERSITY**

and experienced reduced discomfort with laser. See for example a long-term case of vestibuloplasty from 2003 by Prof. Dr. Gerd Volland, where no gingiva was attached at the lower jaw front (Fig. 1). After treatment with Er:YAG laser (1,000 μ s, 15 Hz, 400 mJ, no water, no air), only very low bleeding occurred and a gain of 10 mm was noted (Fig. 2). Three days after the surgery, the periodontal dressing was removed (Fig. 3), and the patient was free of pain seven days after the surgery (Fig. 4). The healing was completed six weeks after the surgery and a gain of 7 mm was observed (Fig. 5). Three years later, the final gain was set at 5,5 mm and no scarring occurred (Fig. 6). A follow-up in 2009 showed no recessions and stable results (Fig. 7).

Pathology of the salivary glands

Mucoceles, ranulas or sialolithiasis can result in obstructive salivary-gland pathologies. Mucoceles are produced by an accumulation of mucin from a ruptured salivary-gland duct, usually caused by local trauma. They are characterised by a high percentage of relapse. Two approaches to removing mucoceles have been suggested in the literature: resection by either scalpel or CO₂ laser. Yagüe-García et al.⁴¹ compared the effectiveness of using a scalpel with that of a CO₂ laser in removing mucoceles in their study. They treated 38 patients using a scalpel and 30 patients using a CO₂ laser (5–7 W). The results showed a repetition rate of 8.8% for the conventional scalpel ablation. In 13.2% of the cases, complications such as fibrous scars arose. In the laser group, a follow-up study at 12 months showed no complications or recurrence. The authors therefore recommend laser treatment, since its results are more predictable and its recurrence rate is lower than that of the traditional treatment. Furthermore, fewer complications occur. Huang et al.⁴³ contributed to this line of argumentation in reporting on laser vaporisation, a procedure that they recommend for children and non-cooperative patients especially.

Ranulas are due to an accumulation of mucin caused by the obstruction of a salivary-gland duct (generally that of the sublingual and submandibular

glands), which is usually the result of previous local trauma. Marsupialisation, the removal of the ranula with or without the sublingual gland, laser splitting, and vaporisation of the ranula have been proposed as possible treatments. Lai and Poon⁴⁴ present a series of three cases in which ranulas were removed and the injuries vaporised using CO₂ laser. The authors state that this treatment can be recommended because of the precision of excision, a clear and sterilised operating field and the low risk of damage to the Wharton's duct and the gingival nerve. Furthermore, CO₂ laser treatment results only in minimal or no recurrence. Zola et al.⁴⁵ present an alternative method for removing ranulas. They used an Er,Cr:YSGG laser (1.5 W). The authors found their treatment to offer advantages similar to those found by Lai and Poon.⁴⁴

Sialolithiasis is the mechanical obstruction of salivary glands or their excretory ducts owing to the formation of concretions. It accounts for 30% of salivary gland pathologies and mainly affects the submaxillary glands (83–94%), followed by the parotid (4–10%) and sublingual glands (1–7%). Yang and Chen⁴⁶ present 19 clinical cases entailing the removal of stones from the Wharton's duct in their article. All of the patients were treated with a CO₂ laser (4–6 W). Their success rate was 95% and only very few complications occurred. For this reason, the authors advocate CO₂ laser treatment as the first technique to be used to treat this pathology.

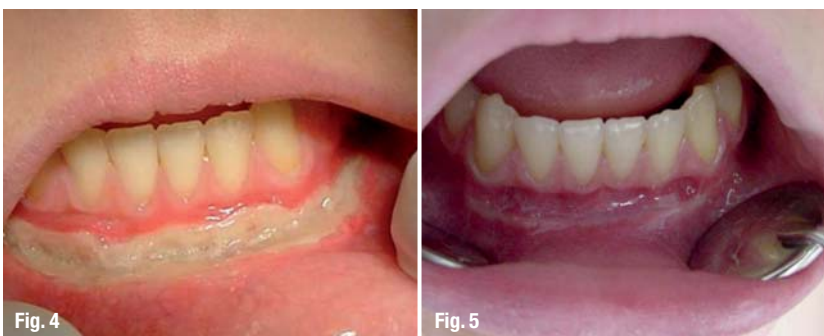Bisphosphonates

The clinical scope of avascular necrosis caused by bisphosphonates ranges from a single fistula to large areas of exposed necrotic bone tissue. Additional symptoms are paraesthesia, pus, swelling, pain and even fracture. The treatment and management of avascular necrosis resulting from bisphosphonates has proven to be challenging, as no treatments have been effective in the long term. Depending on the patient's health, possible treatments are the temporary or permanent suspension of bisphosphonate use, use of local or systemic antibiotics or hyperbaric oxygen, and surgical debridement of the lesions. The combination of these therapies may bring about more predictable results.

The use of LLLT has been increasingly favoured as an alternative for treating this type of pathology. In their 2010 review of the treatment of avascular necrosis by LLLT, Vescovi and Nammour⁴⁷ explain the effects of the laser on the healing process. Laser stimulation increases organic bone matrix, osteoblast proliferation and capillary growth. Owing to its strong affinity to water and hydroxyapatite, the Er:YAG laser can be easily applied to both soft and bone tissue. Necrotic bone is vaporised in the course

Fig. 4 Long-term case of vestibuloplasty. Fibrin cover seven days after surgery. Patient free of pain.

Fig. 5 Long-term case of vestibuloplasty. Situation on 28th of July, 2003: healing complete. Gain of 7 mm.

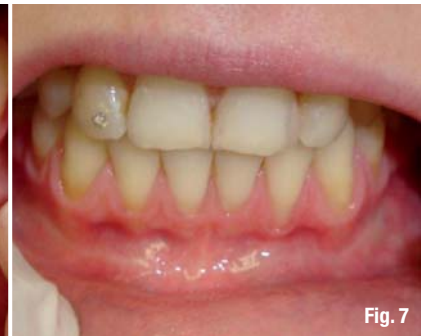
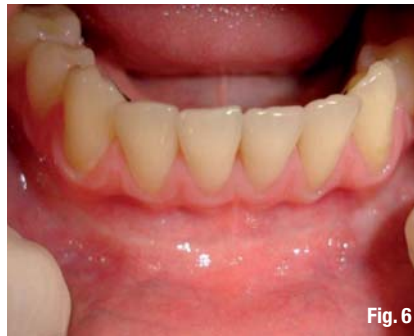
of conservative surgery until healthy bone is reached. Another advantage of Er:YAG laser treatment is its bactericidal action, which increases the healing of bone tissue. Er:YAG laser treatment therefore appears to be a promising technique, since it is regarded as safe, well tolerated by patients and allows minimally invasive treatment of the disease in the early stages.

In a study in 2008, Vescovi et al.⁴⁸ present their clinical results of the treatment of 28 patients affected by osteonecrosis. They treated the four groups of patients with an Nd:YAG laser in combination with medical and surgical treatment. Group I was treated medically only, for example via antibiotics and anti-septics. Group II was treated medically and surgically. Group III was treated medically and via LLLT. Finally, group IV was treated medically, surgically and using LLLT. Twelve of the 14 patients treated with LLLT showed significant clinical improvement and reduction in symptoms, nine patients exhibited complete clinical success. The authors state that while the results of their study were not conclusive, the results indicate that Nd:YAG laser treatment has significant potential to treat lesions caused by bisphosphonate-associated osteonecrosis.

In 2010, Vescovi et al.⁴⁹ published the results of a similar study. Between 2004 and 2008, 91 patients underwent stomatological observation and 55 sites affected by osteonecrosis were examined. These were divided into four groups and different therapeutic modalities were studied. Group I comprised 13 lesions that were treated medically (1 g amoxicillin three times a day and 250 mg metronidazole twice a day, orally) for a minimum of two weeks. Group II consisted of 17 lesions that were treated medically and via LLLT using an Nd:YAG laser (1,064 nm) once a week for two months. Group III consisted of 13 cases of avascular necrosis treated surgically by the removal of necrotic bone, debridement, alveolar removal and corticotomy. Finally, group IV comprised 12 lesions treated using an Er:YAG laser (2,040 nm) in combination with LLLT using an Nd:YAG laser.

All of the lesions treated with the Er:YAG laser showed a clinical improvement of 100% and complete healing in 87.5% of the cases. The group IV results differed significantly from those of the other groups. The authors suggest that the reason for this is increased accessibility to both soft and bone tissue using the Er:YAG laser. They therefore highlight the role of the Er:YAG laser in the treatment of osteonecrosis and conservative surgery. Consequently, a surgical approach combined with LLLT can be considered the most efficient treatment method for bisphosphonate-associated osteonecrosis.



Conclusion

In the last 20 years, lasers have become an excellent tool in oral surgery. Especially in soft-tissue surgery, laser enables the practitioner to excise tumors of different types in a safer and more precise manner than with conventional techniques using a scalpel or electrotome.

Modern laser application is based on our knowledge about absorption and other aspects of working with a laser beam. Over the past ten years, 980 nm and 810 nm diode lasers have evolved in particular. They are relatively inexpensive and provide a good compromise between superficial visible absorption and penetration, in favor of achieving optimal coagulation without necrosis in the depths of the tissue.

As a consequence, fibromas, papillomas or lipomas can be removed even from sites like the lips and the cheek with a clear operating field and predictable results. In addition, sutures can be reduced to a minimum and scar formation is also reduced. For hard tissues, erbium lasers appear to be the best choice because of their high absorption in water. Their effect is based on thermomechanical principles, unlike diode lasers, which interact thermally. Therefore, water spray is essential. This way, bone can be removed without inhibiting healing owing to thermal necrosis. Thus applied, laser can increase the positive effects of oral surgery by providing reliability for the surgeon and comfort for the patient.

Fig. 6 Long-term case of vestibuloplasty. Situation on 15th of May, 2006: no scars. Final gain of 5,5 mm.
Fig. 7 Long-term case of vestibuloplasty. Situation on 25th of November, 2009. Stable results, no recessions.

| | |
|--|-------|
| _contact | laser |
| <p>Prof Dr MSc mult Gerd Volland Facultad de Odontología Cirugía bucal Universidad de Sevilla C/ Avicena s/n Sevilla, Spain dr.volland@t-online.de</p> | |

Evaluation of combined Nd:YAG laser treatment of moderate periodontitis

A randomised controlled clinical study

Author_Dr Anna-Maria Yiannikou-Loucaidou

_Introduction

One of the main goals of dentistry is the prevention of disease. Minimally invasive methods of treatment are preferred. For this reason, the concept of treatment in periodontology has radically changed over the past decades. While in the early days, extensive surgical interventions used to be the centre of attention, today more conservative treatment is the focus.

Treatment procedures recently transitioned from surgical to non-surgical, after the potential of scaling and root planning (SRP) to eliminate inflammation and arrest progression of periodontal disease was successfully demonstrated in a number of clinical trials (Axelsson & Lindhe 1978; Badersten et al. 1984; Hirschfeld & Wasserman 1978; Lovdal et al. 1961). Researchers debate whether there is a significant reduction in the depth of the periodontal pocket when the Nd:YAG laser is applied as an adjuvant therapy.

The balance of evidence seems to favour the improvement of the pocket depth with the use of Nd:YAG as an additional tool for the periodontal treatment, but more research still is needed in this area in order to evaluate the effectiveness of laser treatment with different settings.

_Aims of the present study

The objective of this study is to examine whether the use of Nd:YAG laser as an adjunct to traditional SRP improves the results of traditional therapy, especially concerning the bleeding index and the depth of the periodontal pocket. Furthermore, the present study is

aimed at providing insight into the existing debate in scientific literature regarding the bleeding index and the depth of the periodontal pocket.

The hypothesis of this study is that the application of the Nd:YAG laser as an adjunct tool to local, non-surgical SRP therapy will result in a significantly greater reduction of the bleeding index and the periodontal pocket depth than the traditional mechanical treatment of periodontitis alone. Consequently, the null hypothesis states that there will be no significant differences between the two test groups on the two clinical parameters of bleeding index and pocket depth.

_Materials and methods

A total of 20 healthy patients (twelve women, eight men), aged between 35 and 55, with mild periodontitis (pockets of a depth of 4 to 6 mm) participated in this study. Patients were excluded from this study according to the following criteria: smokers, pregnant women or nursing mothers, type I and type II diabetics, patients currently under antibiotic treatment and patients who had taken antibiotics within three months prior to their selection for the study, patients suffering from cardiovascular disease (high-risk heart disorder) and patients with contagious diseases (El Yazami et al. 2004).

The patients were randomly selected to be divided into two groups of ten persons each. Group 1 was chosen to be the test group. Patients were treated according to the protocol of AALZ (Aachen Dental Laser Center) with SRP, using manual instruments combined with the Nd:YAG laser. Group 2 was assigned to be the

control group and the patients were treated with SRP using manual instruments. Additionally, all of the patients were given instructions for oral hygiene routines and methods.

Clinical assessments of the BOP (bleeding on probing) index and mean PD (periodontal pocket depth) were recorded prior to phase 1, immediately after phase 2 and three months after phase 3.

Pre-treatment examination

Every patient was initially assessed by taking his or her medical history (Armitage 2004; Raffetto 2004). The patients underwent a clinical and radiographical examination prior to the treatment. Their X-rays were taken with the bitewing technique with the Planmeca dixi 3 digital intra-oral digital imaging system. Two periodontal parameters were registered and charted: BOP and PD. Measurements were taken for six aspects of each tooth: mesiobuccal (mb), buccal (b), distobuccal (db), mesiolingual (ml), lingual (l), and distolingual (dl) using calibrated periodontal probes.

Initial therapy

Initial therapy entailed removing plaque and polishing the teeth, as well as giving instructions and encouraging the patients.

Closed curettage

Closed curettage was carried out with mechanical root planning using hand instruments—Gracey curettes # 1/2, 3/4, 7/8, 11/12, and 13/14 for both of the groups (Schwarz et al. 2003). The average amount of instrumentation in each group was nine minutes for single-rooted teeth and ten minutes for multi-rooted teeth.

Laser treatment

De-epithelisation of the sulcus was performed in one session, one week after the cleaning of the last quadrant with a 2,940 nm Er:YAG laser. The following settings were applied: frequency 20 Hz, energy 100 mJ, average output 2 W, with the aid of an R07 handpiece, without water, only with the use of air, and pulse duration 750–950 μs. The laser was used for the de-epithelisation of the sulcus, effectively removing the epithelium of the sulcus. This treatment was executed by continuously moving the tip of the R07 handpiece back and forth from the gingival crest.

During this procedure, the surface of the sulcus appeared to be a whitish colour and the tip of the R07 handpiece became covered in the removable epithelium cells. These cells on the handpiece and the sur-

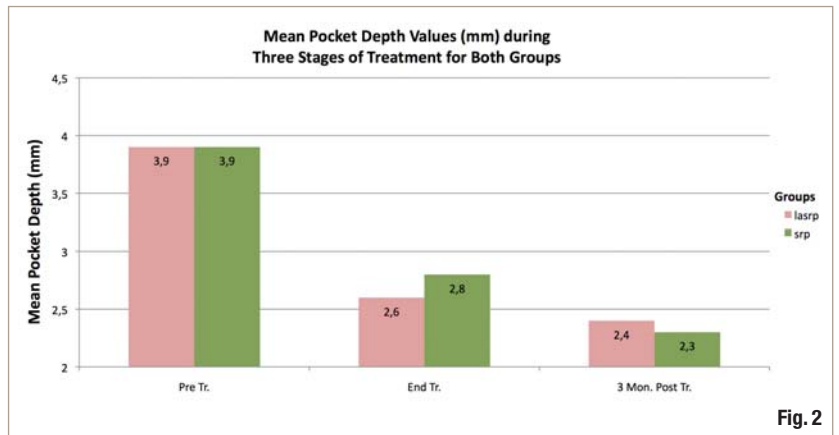


Fig. 2

face of the sulcus were frequently wiped off with a cotton roll or wet gauze (Harris et al. 2002). Scientific literature shows that the concept of de-epithelisation encompasses the promotion of reattachment and the formation of new connective tissue.

One week after the de-epithelisation of the sulcus, pocket sterilisation (Fig. 1) was performed with a 1,064 nm Nd:YAG (output power 2 W, frequency 20 Hz, with the aid of a 300 μm fibre, pulse duration 75 to 100 μs). Before the use of the Nd:YAG laser in the pockets, the area was dried with air. With the aid of a 300 μm thick quartz fibre placed on the bottom of the pocket, the pocket was irradiated circularly for 30 to 40 seconds parallel to the surface of the root, maintaining contact with the tissue. This procedure was performed in the entire mouth without anaesthesia, only with the application of topical anaesthetic gel. When signs of bleeding occurred, the fibre was applied to the next pocket. The procedure was repeated three times in intervals of four to seven days.

It is important to note that this interval time between the treatments must be strictly kept. If the patients are treated earlier than four days, more tissue will be removed, the wound will be larger and shrinking will occur. A treatment later than seven days can result in recolonisation of the periodontal bacteria.

Fig. 1 Mean PD values (mm) during the three phases of treatment for both groups.

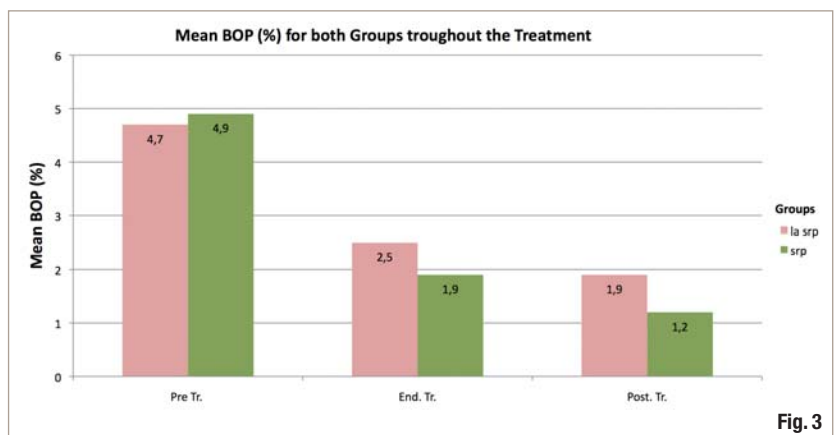


Fig. 3

The researcher chose the setting parameters above because it was reported that Nd:YAG laser irradiation with a setting of 100 mJ, 20 Hz, 2 W for 30 seconds only inhibits the DNA metabolism and the cell division rate (Gutknecht et al. 1998). In this case, a safe soft-tissue laser treatment can be performed. White et al. (1994) examined in vitro the changes of intra-pulpal temperatures during Nd:YAG laser irradiation of root surfaces at 0.3 to 3.0 W (30 to 150 mJ/pulse, 10 or 20 Hz). They reported that within the parameters outlined in their study, pulsed Nd:YAG laser energy should not cause any devitalising rise in the intra-pulpal temperature when it is applied to root surfaces with adequate remaining dentine thickness (Aoki et al. 2004).

Statistical analysis

The data collected was tested for normality by Q-Q plots and Kolmogorov–Smirnov tests. The data was found to be normally distributed and parametric tests were conducted to examine significant differences between the mean values. Dependent t-tests were used to check for significant differences between the same subjects before, during and at the end of the treatment, and three months post-treatment. This procedure was carried out in both groups. In addition, independent t-tests were used to check for significant differences between the two groups at each phase, that is, pre-treatment, at the end of the treatment and three months post-treatment.

Results

According to the statistical analysis, there were significant differences ($p < 0.05$) for each group between phases 1 to 2 and phases 2 to 3 for BOP and PD. More specifically, the mean PD value decreased in the laser-combined SRP therapy group from 1.28 ± 0.54 mm ($p < 0.05$) at the end of the therapy, to 0.25 ± 0.32 mm ($p < 0.05$) after three months and in the SRP group from 1.03 ± 0.81 mm ($p < 0.05$) at the end of the treatment, to 0.54 ± 0.38 mm ($p < 0.05$) three months post-treatment (Fig. 2).

Furthermore, the BOP mean value decreased in the group under laser-combined SRP therapy from $21.6 \pm 9.5\%$ ($p < 0.05$) at the end of the therapy to $7.3 \pm 6.03\%$ ($p < 0.05$) three months post-treatment and in the SRP group from $30.07 \pm 20.65\%$ ($p < 0.05$) at the end of the treatment to $7.06 \pm 8.66\%$ ($p < 0.05$) three months post-treatment, showing a statistically significant decrease ($p < 0.05$) between phases 1 and 2 and phases 2 and 3 (Fig. 3).

No significant difference ($p > 0.05$) in the PD mean values occurred in the comparisons of the two groups (pre-treatment: $t = 0.2$, $p = 0.845$; end of treatment: $t = -0.6$, $p = 0.56$; three months post-treatment:

$t = 0.4$, $p = 0.72$). When the two treatment groups were compared for mean differences in BOP values (%), no statistically significant differences emerged ($p > 0.05$) at any phase of the treatment.

Discussion

Two parameters of periodontal disease were investigated in this randomised controlled study, the probing depth and the sulcus haemorrhage. The aim of the present study was to compare the clinical results of these parameters after non-surgical periodontal treatment to those of SRP via hand instruments or Nd:YAG laser as an adjunct tool to the conventional mechanical instrumentation. The results have demonstrated that non-surgical periodontal treatment with both of the two treatment modalities leads to a significant reduction in PD and BOP. However, when the two treatment groups—test and control—were compared for mean differences in BOP values and in PD values at each phase of the treatment, there were no significant differences.

Conclusion

At this stage and within the framework of the present study, it appears that the use of Nd:YAG combined with non-surgical periodontal treatment improves the clinical outcome of an initial periodontal therapy. The findings should be confirmed by a study of a larger number of patients, a longer follow-up period, different treatment-planning protocols and different energy settings. Furthermore, basic and clinical studies are required in order to clarify the application of the Nd:YAG laser as a complementary therapy in periodontal therapy.

A bright future lies ahead for laser applications in periodontal procedures. Laser-assisted therapy is a successful treatment option that can effectively help the patient to maintain optimal periodontal health.

Editorial note: A complete list of references is available from the publisher.

contact

laser

Dr Anna-Maria Yiannikou-Loucaidou

RWTH Aachen University
Yiannikou Dental Polyclinic
8 Alkeous and Pindarou St.
1060 Nicosia, Cyprus

Tel.: +357 22 764765

Fax: +357 22 756160

annamariadentist@yahoo.com



Live, Interactive Webinars and On Demand Courses

A growing education platform where you can find more than 400 dental courses, live Webinars, live Education Symposia.

Interested in C.E. credits and quality learning?

Learn from the experts:

Richard Niederman
 Louis Malcmacher
 Eduardo Mahn
 Robert Horowitz
 Paul Weigl
 Shamshudin Kherani
 Christian Coachman
 Ron Kaminer
 Edgar Garcia Hurtado
 Glenn van As
 Marc Gottlieb
 John Fluke

Marius Steigmann
 David Hoexter
 Dwayne Karateew
 Fotinos S. Panagakos
 George Freedman
 Howard S. Glazer
 Lynn Mortilla
 Maria Emanuel Ryan
 Michael Glick
 Peter Barry
 Barry Levin
 Fay Goldstep

Interested in sponsoring education?

Some of our partners:



"83% of the dentists visited the exhibiting sponsors as a result of attending the Symposia."

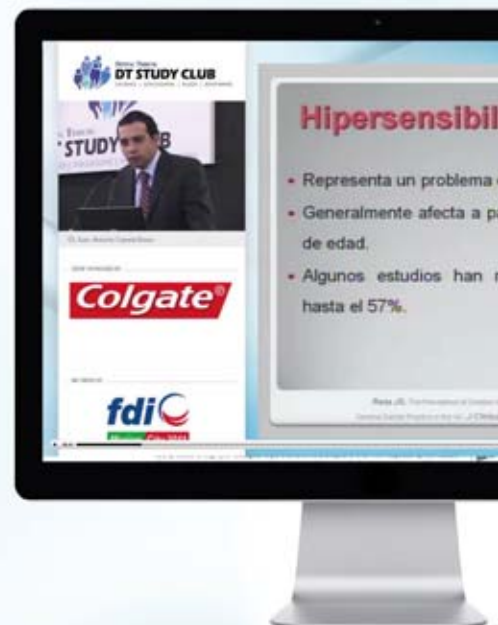this is what we've learned from our customers

Register for FREE on www.DTStudyClub.com



How to receive your C.E. Credits?

1. Go to www.DTStudyClub.com and log in.
2. Not a member yet? Register for a free account.
3. Find the courses you're interested in and register to access them.
4. Watch the course.
5. Take the Quiz and print the C.E. certificate.



The antibacterial effects of lasers in endodontics

Author_ Dr Selma Cristina Cury Camargo, Brazil

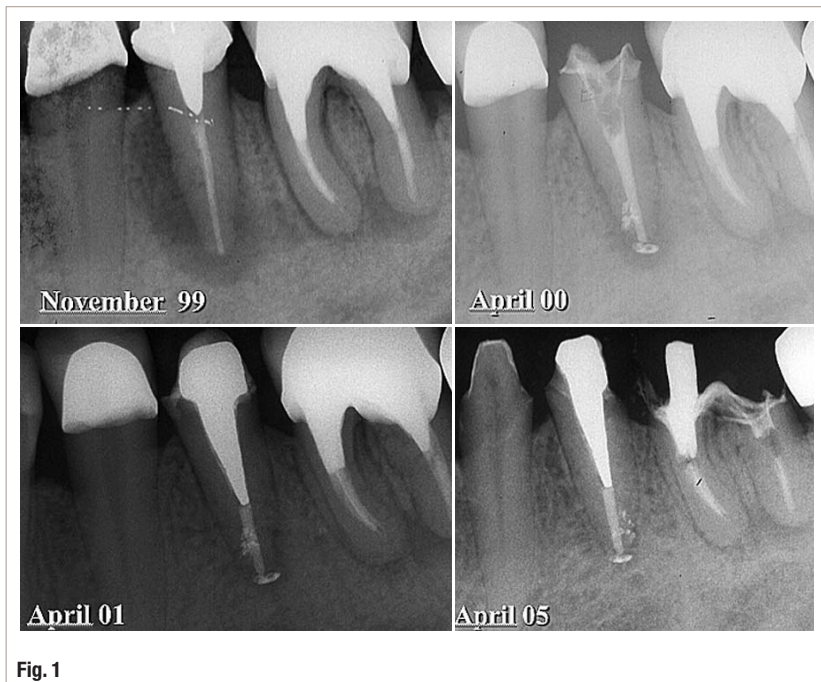


Fig. 1

Fig. 1 _Success in endodontic treatment: apical radiolucency repair.

_Endodontic infection

Endodontic treatment can attain success rates of between 85 and 97%.¹ Adequate treatment protocols, knowledge and infection control are essential to achieving such rates (Figs. 1a–d).² It is well known that apical periodontitis is caused by the communication of root-canal micro-organisms and their by-products to the surrounding periodontal structures. Exposure of dental pulp directly to the oral cavity or via accessory canals, open dentinal tubules or periodontal pockets is the most probable route of the endodontic infection.^{2,3}

Clinically, apical periodontitis is not evident as long as the necrotic tissue is not infected with micro-organisms.^{4–6} There are up to 40 isolated species of bacteria present in the root canal. Cocci, rods, filaments, spirochaetes, anaerobic and facultative anaerobic microorganisms are frequently identified in primary infections. Fungus can also be isolated.^{2,7} Endodontic microbiota can be found suspended in the main root canal, attached to the canal walls and deep in the dentinal tubules at a depth of up to 300µm (Figs. 2a–c). The absence of cementum dramatically increases bacterial penetration into dentinal tubules.^{8–11}

It has been shown that bacteria can also be found outside the root-canal system, located at the apical cementum and as an external biofilm on the apex.^{12–15} Following conventional endodontic treatment, 15 to 20% of non-vital teeth with apical periodontitis fail.^{16–18} The presence of bacteria after the decontamination phase or the inability to seal root canals after treatment are reasons for failure.² The remaining contamination in endodontically treated teeth continues the infectious disease process in the periapical tissue.

Retreatments are the first choice for failed root canals. The microbiota found in persistent infections differ from that in primary infection (Figs. 3a–c). Facultative anaerobic Gram-positive (G+) and -negative (G-) micro-organisms and fungi are common.^{19–21} Special attention is given to *Enterococcus faecalis*, a resistant facultative anaerobic G+ cocci, identified in a much higher incidence in failed root canals.^{22–25} Bacterial control plays a significant role in endodontic success. Adequate and effective disinfection of the root-canal system is necessary.

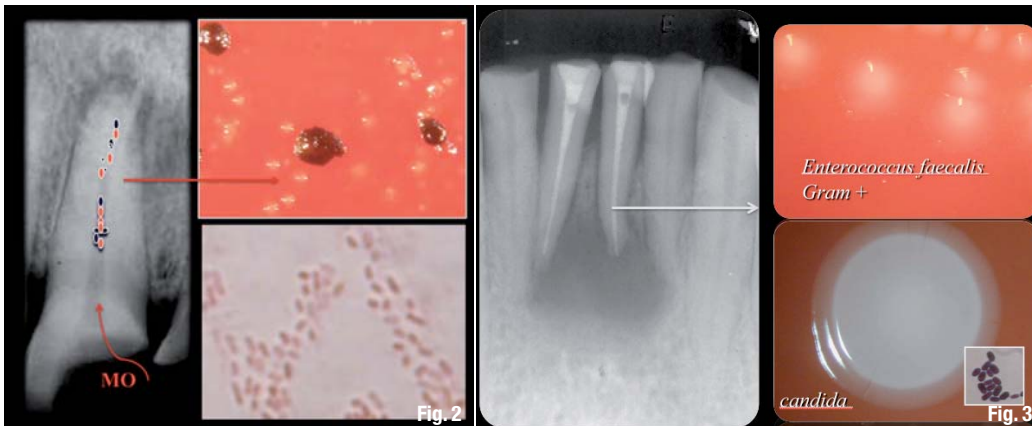


Fig. 2_Primary infection: black pigmented strains and G-rods.

Fig. 3_Persistent infection.

Endodontic therapy

The bacterial flora of the root canal must be actively eliminated through a combination of debridement and antimicrobial chemical treatment. Mechanical instrumentation eliminates more than 90% of the microbial amount.²⁶ An important point to note is the adequate shaping of the root canal. Evaluating the antibacterial efficacy of mechanical preparation itself, Dalton et al.²⁷ conclude that instrumentation to an apical size of #25 resulted in 20% of canals free of cultivable bacteria. When shaped to a size of #35, 60% showed negative results.

An irrigating solution has been used with mechanical instrumentation to facilitate an instrument's cutting efficiency, remove debris and the smear layer, dissolve organic matter, clean inaccessible areas and act against micro-organisms. Sodium hypochlorite is the most common irrigant used in endodontics.²⁸ It has an excellent cleansing ability, dissolves necrotic tissue, has a potential antibacterial effect and, depending on the concentration, is well tolerated by biological tissues. When accompanied by mechanical instrumentation, it reduces the number of infected canals by 40 to 50%.

Other irrigating solutions can also be used during endodontic preparation. EDTA, a chelating agent used primarily to remove the smear layer and facilitate the removal of debris from the canal, has no antibacterial effect.²⁹ Chlorhexidine gluconate has a strong antibacterial effect on an extensive number of bacterial species, even the resistant *E. faecalis*, but it does not break down proteins and necrotic tissue as sodium hypochlorite does.³⁰

As mechanical instrumentation and irrigating solutions are not able to eliminate bacteria from the canal system totally—a requirement for root-canal filling—additional substances and medicaments have been tested in order to address the gap in standard endodontic protocols. The principal goal of dressing the root canal between appointments is to ensure safe antibacterial action with long-lasting effects.³¹ A great number of medicaments have been used as dressing material, such as formocresol, camphorated parachlorophenol, eugenol, iodine-potassium iodide, antibiotics, calcium hydroxide and chlorhexidine.

Calcium hydroxide has been used in endodontic therapy since 1920.³¹ With a high pH at saturation (pH above 11), it induces mineralisation, reduces bacteria

Figs. 4a & b_Nd:YAG laser intra-canal irradiation.

Fig. 5_Nd:YAG laser irradiation, deep penetration.

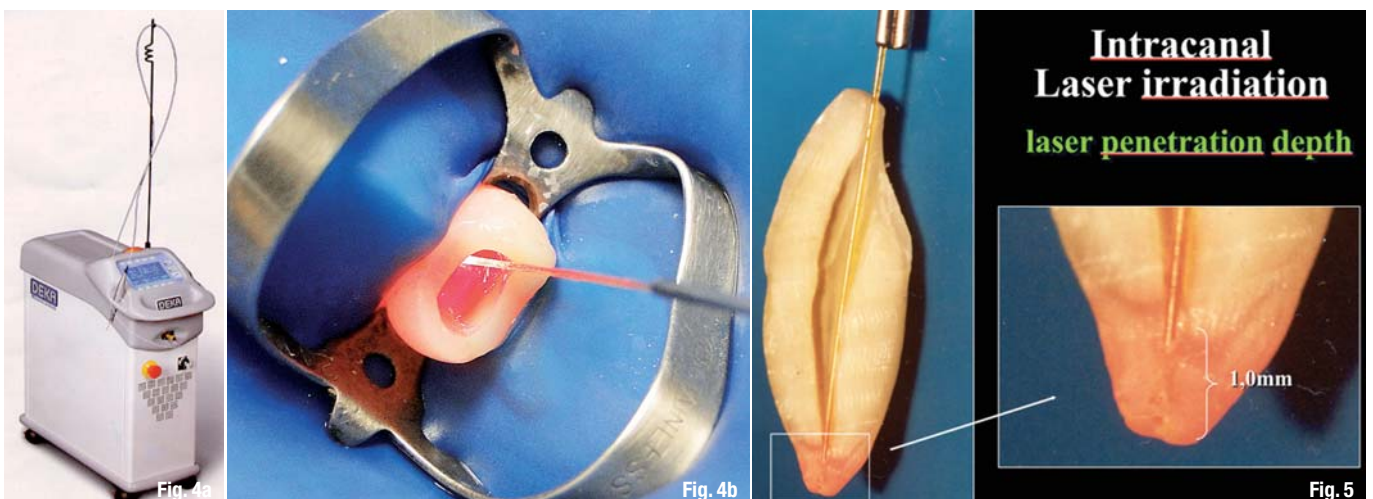

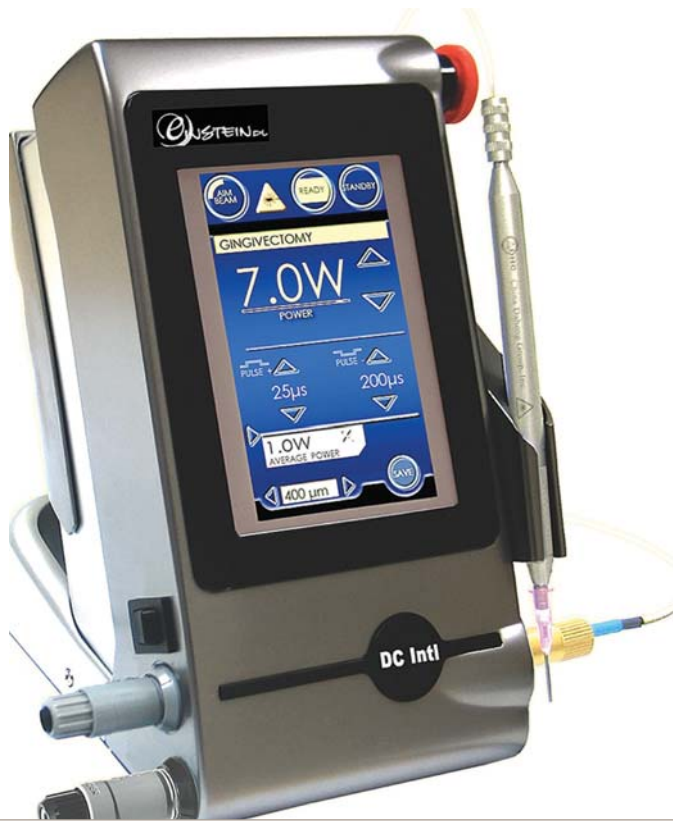


Fig. 6a

Figs. 6a & b Diode 980 nm intra-canal irradiation.

and dissolves tissue. For extended antibacterial effectiveness, the pH must be kept high in the canal and in the dentine as well. Sustaining the pH depends on the diffusion through dentinal tubules.³²

Although most micro-organisms are destroyed at pH of 9.5, a few can survive a pH of 11 or higher, such as *E. faecalis* and *Candida*.²¹ Because of the resistance of some micro-organisms to conventional treatment protocols—and the direct relation between the presence of viable bacteria in the canal system and the reduced rate of treatment success—additional effort has to be made to control canal system infection.

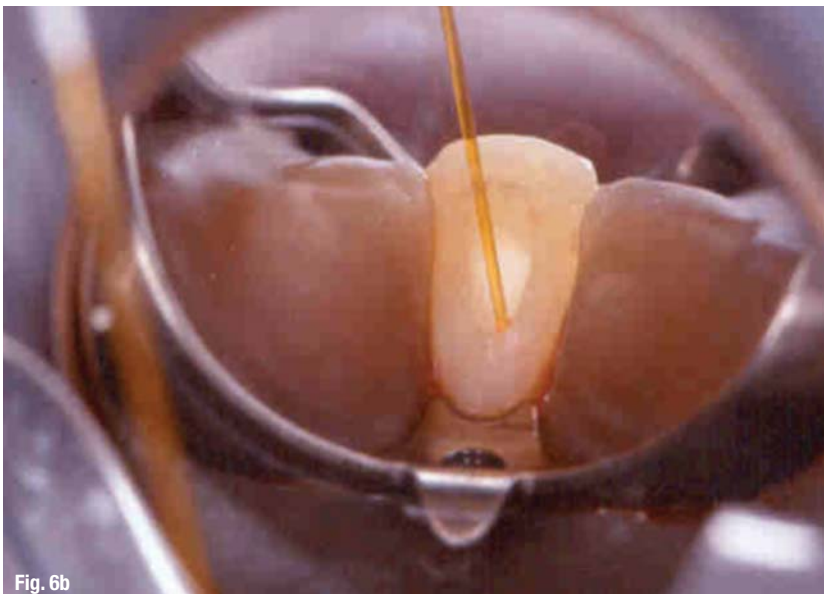

Fig. 6b

Lasers in endodontics

Lasers were introduced to endodontics as a complementary therapy to conventional antibacterial treatment. The antibacterial action of Nd:YAG, diodes, Er:YAG and photoactivated disinfection (PAD) have been explored by a number of investigators. In the following section, each laser is evaluated with the aim of selecting an adequate protocol with a high probability of success in teeth with apical periodontitis.

Nd:YAG laser

The Nd:YAG laser was one of the first lasers tested in endodontics. It is a solid-state laser. The active medium is usually yttrium aluminium garnet ($Y_3Al_5O_{12}$), where some Y^{3+} ions are replaced by Nd^{3+} ions. It is a four-level energy system operating in a continuous wave or pulsed mode. It emits a 1,064 nm infra-red wavelength. Thus, this laser needs a guide light for clinical application. Flexible fibres with a diameter between 200 and 400 μm are used as delivery systems. The laser can be used on intra-canal surfaces, in contact mode (Figs. 4a & b).

The typical morphology of root-canal walls treated with the Nd:YAG laser shows melted dentine with a globular and glassy appearance, and few areas are covered by a smear layer. Some areas show dentinal tubules sealed by fusion of the dentine and deposits of mineral components.^{33,34} This morphological modification reduces dentine permeability significantly.^{35,36} However, because the emission of the laser beam from the optical fibre is directed along the root canal and not laterally, not all root-canal walls are irradiated, which gives more effective action at the apical areas of the root.³⁷ Undesirable morphological changes, such as carbonisation and cracks, are seen only when high energy parameters are used.

One of the major problems regarding intra-canal laser irradiation is the temperature increase at the external surface of the root. Laser light exerts a thermal effect when it reaches tissue. The heat is directly associated with the energy used as well as time and irradiation mode. An increase in temperature levels above 10°C per minute can cause damage to periodontal tissues, such as necrosis and ankylosis.

Lan³⁸ evaluated *in vitro* the temperature increase on the external surface of the root after irradiation with a Nd:YAG laser under the following energy parameters: 50, 80 and 100 mJ at 10, 20 and 30 pulses per second. The increase of temperature was less than 10°C. The same results were obtained by Bachman et al.³⁹, Kimura et al.⁴⁰ and Gutknecht et al.⁴¹ In contrast to the external surface, the intra-canal temperature rises dramatically at the apical area,

The 32nd Moscow International Dental Forum

Moscow 2012

The 32nd Moscow International Dental Forum



Dental-Expo
international dental fair

September 17-20

Crocus Expo exhibition grounds

more than
450
exhibitors

more than
25000
attendees

more than
35
countries

www.dental-expo.com

DENTALEXPO®



promoting effective action against bacterial contamination. For the Nd:YAG laser, 1.5 W and 15 Hz, are safe energy parameters for temperature and morphological changes.^{33,41}



Fig. 7_Er:YAG laser.

The primary use of the Nd:YAG laser in endodontics is focused on elimination of micro-organisms in the root-canal system. Rooney et al.⁴² evaluated the antibacterial effect of Nd:YAG lasers *in vitro*. Bacterial reduction was obtained considering energy parameters. The researchers developed different *in-vitro* models simulating the organisms expected in non-vital, contaminated teeth. Nd:YAG irradiation was effective for *Bacillus stearothermophilus*,^{43,44} *Streptococcus faecalis*, *Escherichia coli*,⁴⁵ *Streptococcus mutans*,⁴⁶ *Streptococcus sanguis*, *Prevotella intermedia*⁴⁷ and a specific micro-organism resistant to conventional endodontic treatment, *E. faecalis*.⁴⁸⁻⁵⁰ Nd:YAG has an antibacterial effect in dentine at a depth of 1,000 μm (Fig. 5).⁵⁰

Histological models were also developed in order to evaluate periapical tissue response after intra-canal Nd:YAG laser irradiation. Suda et al.⁵¹ demonstrated in dog models that Nd:YAG irradiation at

100 mJ/30 pulses per second for 30 seconds was safe to surrounding root tissues. Maresca et al.,⁵² using human teeth indicated for apical surgery, corroborated Suda et al.'s⁵¹ and Ianamoto et al.'s⁵³ results. Koba et al.⁵⁴ analysed histopathological inflammatory response after Nd:YAG irradiation in dogs at 1 and 2 W. Results showed significant inflammatory reduction at four and eight weeks compared with the non-irradiated group.

Clinical reports published in the literature confirm the benefits of intra-canal Nd:YAG irradiation. In 1993, Eduardo et al.⁵⁵ published a successful clinical case that combined conventional endodontic treatment with Nd:YAG irradiation for retreatment, apical periodontitis, acute abscess and perforation. Clinical and radiographic follow-up showed complete healing after six months.

Similar results were shown by Camargo et al.⁵⁶ Gutknecht et al.⁵⁷ reported a significant improvement in the healing of laser-treated infected canals, when compared with non-irradiated cases.

Camargo et al.⁵⁸ compared *in vivo* the antibacterial effects of conventional endodontic treatment and the conventional protocol associated with the Nd:YAG laser. Asymptomatic teeth with apical radiolucency and necrotic pulps were selected and divided into two groups: conventional treatment and laser-irradiated. Microbiological samples were taken before canal instrumentation, after canal preparation and/or laser irradiation and one week after treatment. The results showed a significant antibacterial effect in the laser group compared to conventional treatment. When no other bactericidal agent was used, it was assumed that the Nd:YAG laser played a specific role in the bacterial reduction for endodontic treatment in patients.

Diodes

The diode laser is a solid-state semiconductor laser that uses a combination of gallium, arsenide, aluminium and/or indium as the active medium. The available wavelength for dental use ranges between 800 and 1,064 nm and emits in continuous wave and gated pulsed mode using an optical fibre as the delivery system (Figs. 6a & b). Diode lasers have gained increasing importance in dentistry owing to their compactness and affordable cost. A combination of smear layer removal, bacterial reduction and reduced apical leakage are advantages of this laser and make it viable for endodontic treatment. The principal laser action is photo-thermal.

The thermal effect on tissue depends on the irradiation mode and settings. Wang et al.⁵⁹ irradiated root canals *in vitro* and demonstrated a maximum

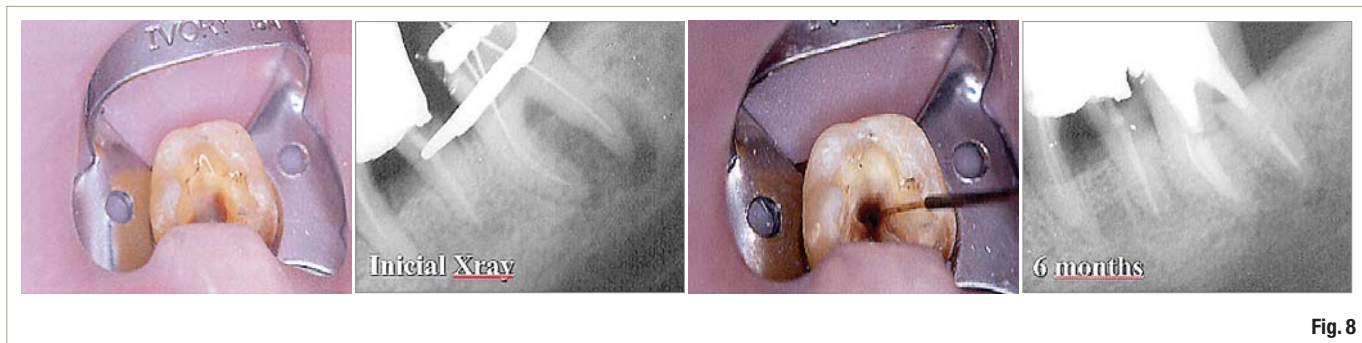


Fig. 8

temperature increase of 8.1°C using 5W for seven seconds. Similar results were obtained by Da Costa Ribeiro.⁶⁰ Gutknecht et al.⁶¹ evaluated intra-canal diode irradiation with an output of 1.5W and observed a temperature increase of 7°C in the external surface of the root using a 980nm diode laser at a power setting of 2.5W at a continuous and chopped mode, and found that the temperature increase never exceeded 47°C, which is considered safe for periodontal structures.⁴¹

Morphological changes at the apical portion of the root after intra-canal diode irradiation were observed in clean intra-canal dentinal surfaces with sealed dentinal tubules, indicating melting and recrystallisation.⁶² In general, near infra-red wavelengths, such as 1,064 and 980nm, promote fusion and recrystallisation on the dentinal surface, sealing dentinal tubules.

The apparent consensus is that diode laser irradiation has a potential antibacterial effect. In most cases, the effect is directly related to the amount of energy delivered. In a comparative study by Gutknecht et al.,⁶³ an 810nm diode was able to reduce bacterial contamination by up to 88.38% with a distal output of 0.6W in continuous wave mode. A 980nm diode laser has an efficient antibacterial effect of an average of between 77 to 97% in root canals contaminated with *E. faecalis*. Energy outputs of 1.7, 2.3 and 2.8W were tested. Efficiency was directly related to the amount of energy and dentine thickness.⁶⁴

Er:YAG laser

Er:YAG lasers are solid-state lasers with a lasing medium of erbium-doped yttrium aluminium garnet (Er:Y₃Al₅O₁₂). Er:YAG lasers typically emit light with a wavelength of 2,940nm, which is infra-red light. Unlike Nd:YAG lasers, the output of an Er:YAG laser is strongly absorbed by water because of atomic resonances. The Er:YAG wavelength is well absorbed by hard dental tissue. This laser was approved for dental procedures in 1997. Smear layer removal, canal preparation and apicoectomy are indications for endodontic use (Fig. 7).

The morphology of a dentinal surface irradiated with an Er:YAG laser is characterised by clean areas, showing open dentinal tubules free of a smear layer, in a globular surface. Bacterial reduction using the Er:YAG was observed by Moritz et al.⁶⁵

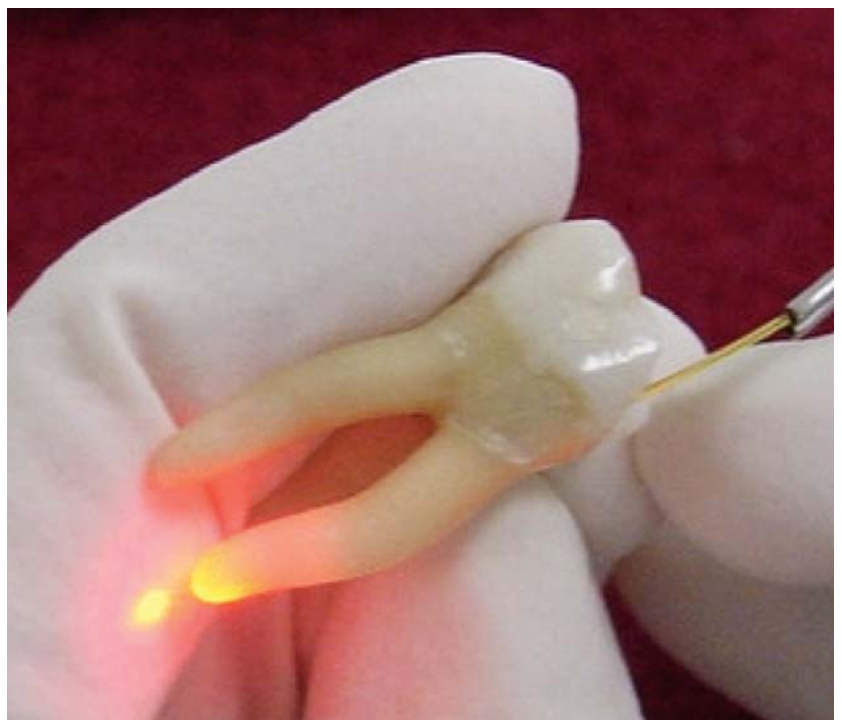Stabholz et al.³⁷ describe a new endodontic tip that can be used with an Er:YAG laser system. The tip allows lateral emission of the radiation rather than direct emission through a single opening at the far end. It emits through a spiral tip located along the length of the tip. Examining the efficacy of the spiral tip in removing the smear layer, Stabholz et al.⁶⁶ found clean intra-canal dentinal walls free of a smear layer and debris under SEM evaluation.

Photoactivated disinfection

PAD is another method of disinfection in endodontics and is based on the principle that photoactivated substances, which are activated by light of a particular wavelength, bind to target cells. Free radicals are formed, producing a toxic effect to bacteria.

Fig. 8_Therapeutic plan.

Fig. 9_Intra-canal laser irradiation, molar.



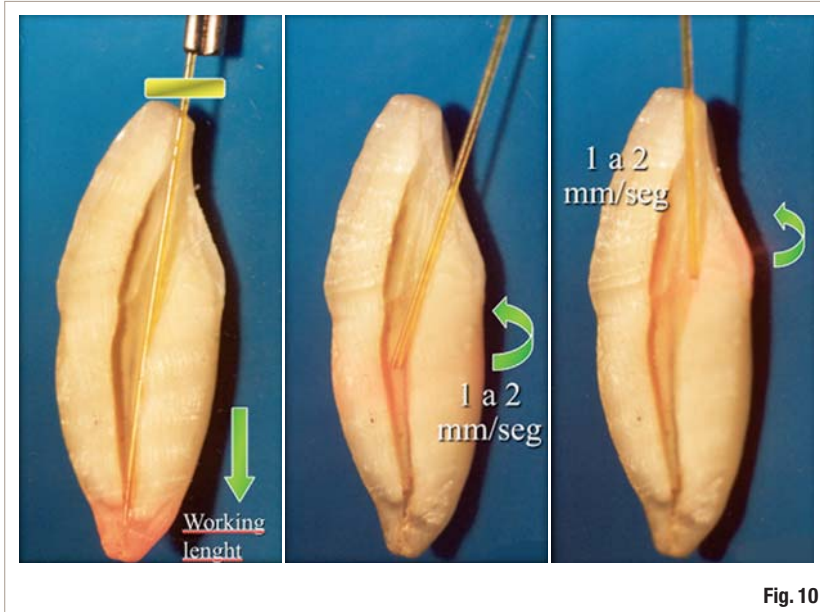


Fig. 10

Fig. 10_Intra-canal laser irradiation, technique.

Toluidine blue and methylene blue are examples of photoactivated substances. Toluidine blue is able to kill most oral bacteria. In *in vitro* studies, PAD has an effective action against photosensitive bacteria such as *E. faecalis*, *Fusobacterium nucleatum*, *P. intermedia*, *Peptostreptococcus micros* and *Actinomyces comitans*.^{67,68} On the other hand, Souza et al.,⁶⁹ evaluating PAD antibacterial effects as a supplement to instrumentation/irrigation of canals infected with *E. faecalis*, did not prove a significant effect regarding intra-canal disinfection. Further adjustments to the PAD protocols and comparative research models may be required before recommendations can be made regarding clinical usage.

Discussion and conclusion

There are good reasons to focus the treatment of non-vital contaminated teeth on the destruction of bacteria in the root canal. The possibility of a favourable treatment outcome is significantly higher if the canal is free from bacteria when it is obturated. If, on the other hand, bacteria persist at the time of root filling, there is a higher risk of treatment failure. Therefore, the prime objective of treatment is to achieve complete elimination of all bacteria from the root-canal system.^{2,31}

Today, the potential antibacterial effect of laser irradiation associated with the bio-stimulation action and accelerated healing process is well known. Research has supported the improvement of endodontic protocol. Laser therapy in endodontic treatment offers benefits to conventional treatment, such as minimal apical leakage, effective action against resistant micro-organisms and external apical biofilm, and an increase in periapical tissue repair.

For this reason, laser procedures have been incorporated into conventional therapeutic concepts to improve endodontic therapy (Figs. 8a–d).

Clinical studies have proven the benefits of an endodontic laser protocol in apical periodontitis treatment. For endodontic treatment, the protocol entails standard treatment strategies for cleaning and shaping the root canal to a minimum of #35, irrigating solutions with antibacterial properties and intra-canal laser irradiation using controlled energy parameters. Ideal sealing of the root canal and adequate coronal restoration are needed for an optimal result.

In practice, little additional time is required for laser treatment. Irradiation is simple when flexible optical fibres of 200µm in diameter are used. The fibre can easily reach the apical third of the root canal, even in curved molars (Fig. 9). The released laser energy has an effect in dentine layers and beyond the apex in the periapical region. The laser's effect extends to inaccessible areas, such as external biofilm at the root apex.

The irradiation technique must adhere to the following basic principles. A humid root canal is required and rotary movements from the coronal portion to the apex should be carried out, as well as scanning the root canal walls in contact mode (Figs. 10a–c). The power settings and irradiation mode depend on one's choice of a specific wavelength.

Nd:YAG, diodes of different wavelengths, Er:YAG, and low-power lasers can be used for different procedures with acceptable results. Laser technology in dentistry is a reality. The development of specific delivery systems and the evolution of lasers combined with a better understanding of laser–tissue interaction increase the opportunities and indications in the endodontic field.

Editorial note: A complete list of references is available from the publisher.

| | |
|---|-------|
| _contact | laser |
| <p>Dr Selma Camargo University of São Paulo Rua Pinto Gonçalves, 85/54 Perdizes São Paulo, SP 05005-010 Brazil</p> <p>selmacris@me.com</p> | |



No Pre-Registration Fee

**The Largest
Dental Meeting/
Exhibition/Congress
in the United States**

MARK YOUR CALENDAR

**Scientific Meeting:
Friday - Wednesday,
November 23 - 28**

**Exhibit Dates:
Sunday - Wednesday,
November 25 - 28**

ATTEND AT NO COST
Never a pre-registration fee at the
Greater New York Dental Meeting

MORE THAN 600 EXHIBITORS
Jacob K. Javits Convention Center 11th Ave.
between 34-39th Streets (Manhattan)

HEADQUARTERS HOTEL
New York Marriott Marquis Hotel

LIVE DENTISTRY ARENA - NO TUITION

**LATEST DENTAL TECHNOLOGY
& SCIENTIFIC ADVANCES**

MORE THAN 350 SCIENTIFIC PROGRAMS
Seminars, Hands-on Workshops, Essays
& Scientific Poster Sessions as well as
Specialty and Auxiliary Programs

**EDUCATIONAL PROGRAMS
IN VARIOUS LANGUAGES**

SOCIAL PROGRAMS FOR THE ENTIRE FAMILY

**ENJOY NEW YORK CITY AT ITS BEST
DURING THE MOST FESTIVE TIME
OF THE YEAR!**

FOR MORE INFORMATION:
Greater New York Dental Meeting®
570 Seventh Avenue - Suite 800
New York, NY 10018 USA
Tel: (212) 398-6922 / Fax: (212) 398-6934
E-mail: victoria@gnydm.com

**GREATER
N.Y.**

DENTAL MEETING

WWW.GNYDM.COM

Sponsored by the New York County Dental Society and the Second District Dental Society

2 0 1 2

Laser treatment of dentine hypersensitivity

An overview Part II

Author_Dr Ute Botzenhart, Dr Andreas Braun & Prof Matthias Frentzen, Germany

Introduction

More than two decades ago, laser applications in the treatment of dentine hypersensitivity were introduced to dentistry. Many clinical studies using different laser types have been published since. This overview summarises the basic and clinical aspects, including treatment protocols.

In the last issue of laser, conventional approaches towards the treatment of dentine hypersensitivity were discussed with regard to a set of criteria for a successful treatment as proposed by L. I. Grossman (1935). The authors came to the conclusion that, so far, no conventional therapy has been able to meet all the criteria. The authors then moved on to studies on laser treatment. Studies on GaAlAs laser and He-Ne lasers were introduced and analysed. Part I of this article was finished by a comparison between He-Ne lasers and Nd:YAG lasers.

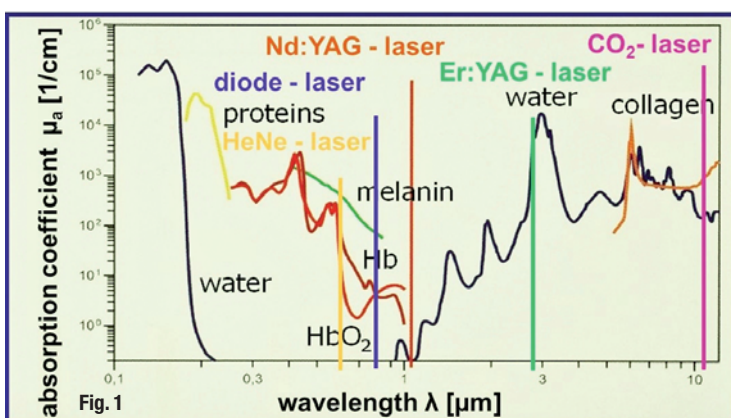
Part II in this issue of laser continues with studies on the application of Nd:YAG lasers in dental therapies as well as an overview on Er:YAG lasers.

Middle-output power lasers: Nd:YAG laser

The Nd:YAG laser with a wavelength of 1,064 nm belongs to the group of middle-output power lasers. Matsumoto et al. (1985b) referred to the application of this laser type in the therapy of dentine hypersensitivity. Since then, it has been established for the therapy of dentine hypersensitivity in a number of studies (Dilsiz et al. 2009; Yonaga et al. 1999; Kobayashi et al. 1999; Gutknecht et al. 1997; Lan et al. 1996; Renton-Harper et al. 1992; Gelsky et al. 1992; White et al. 1990; Goodis et al. 1989; Matsumoto et al. 1985b).

The energy level used ranges from 0.3 to 10 W, with the most frequent use of 1 or 2 W (Kimura et al. 2000b). The methods of application are highly dependent on the laser energy used and vary according to this, from 0.3 W for 90 seconds in non-contact mode up to 2 W for 0.5 seconds with the application of an absorber in contact mode (Kimura et al. 2000b). In different studies, the efficiency of therapy ranges from 5 to 100% (Kimura et al. 2000b). Among the middle-output power lasers, the Nd:YAG laser is regarded as exceedingly effective (Dilsiz et al. 2010b; Birang et al. 2007; De Magalhaes et al. 2004; Yonaga et al. 1999). In a comparative *in vitro* study of the ability of Er,Cr:YSGG, Nd:YAG, CO₂ and diode lasers to melt dentinal tubules, all laser types had a statistically significant ability to seal perpendicular dentine and occlude dentinal tubules partially or totally, but the highest reduction in mean tubule diameter resulted from the Nd:YAG laser with 53% effectiveness (Gholami et al. 2011). Comparable results were also found by Dilsiz et al. (2009), comparing immediate and late therapeutic effects after Nd:YAG (1 W, 10 Hz, 60 seconds, non-contact mode, without cooling) and diode-laser application (25 mW, 9 Hz, 100 seconds). Both were effective in reducing dentine hypersensitivity, but there was a higher suc-

Fig. 1 Laser wavelength and absorption spectrum of the different laser types used for desensitization in human tissues.



cess rate after Nd:YAG laser application, especially after immediate application and 60 days after concluding the treatment.

Abed et al. (2011) compared the sealing ability of Nd:YAG laser application (1 W, 10 Hz, 60 seconds, non-contact mode without cooling) to that of a resin (Seal & Protect®, DENTSPLY DeTrey) applied to exposed human dentinal tubules *in vitro*. Compared with the control group, laser application showed a homogeneous dentinal surface with less exposed tubules and a reduction in the diameter of the exposed tubules of 50%. Nevertheless, in this study, the resin was much better, with a 90% sealing ability compared with the control group (Abed et al. 2011).

Effects of Nd:YAG laser application

When using Nd:YAG laser light and black ink as an absorption amplifier, it is recommended that deep penetration of laser light through enamel and dentine be evaded so that excessive harmful effects on the pulpal tissue can be avoided (Launay et al. 1987) and superficial sealing effects can be enhanced (Morioka et al. 1984; Gelsky et al. 1993; Yonaga et al. 1999; Kobayashi et al. 1999). The closure or narrowing of dentinal tubules (Lan & Liu 1995, 1996) and direct nerve analgesia are assumed to be mechanisms of Nd:YAG laser light action (Whitters et al. 1995). In an *in vitro* SEM examination, the melting of dentinal tubule openings and the solidification of the dentine surface with a penetration depth varying between 1 to 7 μm were observed, depending on irradiation parameters (30 mJ, 0.3 W, 7 Hz; 40 mJ, 0.4 W, 7 Hz for 43 seconds with a ten-second interval; De Magalhaes et al. 2004).

In a study by Moriyama et al. (2004), morphological and chemical changes in human dentine surfaces resulting from Nd:YAG laser irradiation with different pulse durations were observed. SEM analysis confirmed a melting and resolidification with larger resolidification structures and a smoother surface after using long pulses. An increased concentration of calcium and phosphorous was also found in all irradiated samples compared with the control group, possibly making it less susceptible to acid dissolution (Moriyama et al. 2004). Laser of a wavelength of 1,064 nm also demonstrates effects upon microcirculation (Funato et al. 1991; Zennyu et al. 1996).

Causes of the analgesic effects of Nd:YAG lasers

A multitude of theories on the way in which the Nd:YAG laser induces its analgesic effect have been suggested (Kimura et al. 2000b). For example, laser energy is thought to interfere with the sodium pump and alter the cell membrane permeability and/or affect the endings of sensory axons (Myers et al. 1991). Not only can Nd:YAG laser application block off the depolarisation of very slow C-fibre afferences, but it can also af-




Fig. 2

fect fast-conducting A- β -fibres (Orchardson et al. 1997). It is also thought that a desensitising effect can be achieved by denaturing the odontoblast process and by overheating dentinal fluid (White et al. 1990; Goodis et al. 1989).

A glazing of the dentine was described after the application of Nd:YAG laser light to the exposed tooth neck (Birang et al. 2007; Lan et al. 2004; Dederich et al. 1984; Halket et al. 1996). The result was a glazed, non-cavernous surface with closure of the exposed tubules and without surface cracks. When using an Nd:YAG laser, the sealing depth is dependent on the chosen parameters and the optical properties of dentine. With the use of 30 mJ/pulse and 10 Hz, the sealing depth is less than 4 μm (Liu et al. 1997). In an *in vivo* study by Gutknecht et al. (1997), different laser parameters for Nd:YAG laser application were tested. Roughly the same success rates were detected in each case. It was concluded that Nd:YAG laser light must have been effective even with a low-energy dose. Manton et al. (1992) compared the effect of the Nd:YAG laser with that of an untreated control group. Directly before and after laser application, as well as after three and 28 days, the time it took for teeth to become painful after cold stimuli was measured. Nd:YAG laser light application showed a statistically significant clinical improvement over a period of 28 days. These results were confirmed by a study by Yonaga et al. (1999). Recrudescence occurred after more than two months. After a follow-up period of one year, the effectiveness of Nd:YAG laser application was 85.4% effective compared with 90% immediately after the application (Zhang 1990).

Hu (2004) analysed the effect of a pulsed Nd:YAG laser in the therapy of dentine hypersensitivity compared with a control group treated with NaF. The effectiveness immediately after laser application, and one month and six months after was significantly better compared with the control group (Hu 2004). Cia-

Fig. 2 SEM examination of a human cervical dentinal surface after removal of the smear layer with 50% citric acid for one minute to open up the dentinal tubules and simulate hypersensitive dentine and application of Bifluorid 12® (combination of sodium fluoride and calcium fluoride, 1,000 x-magnification). Dentinal tubules are totally or partially closed by fluoride-containing covering layer.

ramicoli et al. (2003) also confirmed the results of the studies described above. The effect of Nd:YAG laser irradiation (2 W, 100 mJ, 20 Hz, 60 seconds, with air cooling) compared with conventional fluoridation (Bifluorid 12®, VOCO, Fig. 2) immediately after and one, two, three and four weeks after application showed a significant improvement in VAS scores to air blast immediately after and one week after laser treatment (Kara et al. 2009). Whereas at weeks two, three and four in the fluoridated group, VAS scores decreased up to nearly 75 to 85% of the baseline scores, VAS scores remained nearly unchanged in the laser group. Fluoride was applied in three consecutive visits in this study, but laser was only applied once. Nd:YAG laser irradiation thus appears to be a suitable tool for the immediate and successful reduction of pain within a shorter treatment time.

Recurring dentine hypersensitivity

The mechanism of the recurrence of dentine hypersensitivity is unknown (Yonaga et al. 1999), but it is assumed that after laser treatment, a reappearance of symptoms depends on the initial intensity of the dentine hypersensitivity before the application (Yonaga et al. 1999). The irradiation of the cervical region with Nd:YAG laser light under the use of an absorber enhances the efficiency—with this method, a recurrence of the symptoms can be delayed (Yonaga et al. 1999). According to this study, morphological aspects, in addition to analgesic effects, are assumed to be important for the sustainability of treatment effects (Yonaga et al. 1999).

Side-effects

The thermal impacts of laser light on the pulpal tissue constitute a problem for using Nd:YAG laser *in vivo*. Compared with other laser types, the Nd:YAG laser beam has deep penetration into dentine, bone and soft tissue (Dederich 1993; Zennyu et al. 1996). Exposure of dentine beyond the safety threshold can cause thermal damage to the pulpal tissue (Yonaga et al. 1999; Zhang 1990; Matsumoto et al. 1988; Zach et al. 1965). However, clinical studies state that despite the danger of thermal damage, no side-effects were found (Yonaga et al. 1999).

Other clinical studies examined a partial oxygen saturation of pulpal blood in anterior hypersensitive teeth after Nd:YAG laser irradiation (1 W, 10 Hz, 60 seconds, non-contact mode, without cooling) as a possible indicator of pulpal damage. A slight but significant increase in the oxygen saturation of the pulpal blood was observed immediately and one week after laser application compared with the control group. However, partial oxygen saturation of pulpal blood in laser-treated teeth had gained its pretreatment level at follow-up measurement after one month, thus maintaining the teeth vitality and indicating no irreversible

damage in the dental pulp after laser application within the limit of desensitisation parameters (Birang et al. 2008).

The additional use of an absorber defines the depth effect of Nd:YAG laser light and reduces the possibility of side-effects. Zapletalova et al. (2007) tested different dye solutions for topical application in combination with Nd:YAG laser energy and found erythrosin to be the best agent to avoid damage to the dentinal structure. Sealing of tubules occurred after four doses of 30 mJ pulses (total energy density 33 J/cm²).

Concerning efficiency and simplicity, the application of Nd:YAG laser light is a relevant treatment method for clinical practice (Yonaga et al. 1999). The great variances in the different studies can be explained by morphological differences that inevitably occur on account of intra- and inter-individual variation of the dentine structure and depend, among others, on the age and clinical history of the teeth (Moriyama et al. 2004). For example, in their SEM examination of the occluding ability of Nd:YAG laser on exposed human dentine compared with a resin, Abed et al. (2011) discovered that the number and diameter of dentinal tubules vary significantly from tooth to tooth even for different sections of the same tooth. This confirms most of the clinical findings morphologically.

Combined treatment with Nd:YAG laser and fluoride

The clinical application of the Nd:YAG laser and NaF varnish, as well as Nd:YAG laser light alone, showed significant improvement in dentine hypersensitivity in each case (Kumar et al. 2005). However, the combination of the Nd:YAG laser and NaF varnish showed a greater efficiency compared with either of these used alone (Kumar et al. 2005). SEM examinations confirm the clinical results. A reduction in the number of open tubules was combined with an improvement in the efficiency of the therapy (Kumar et al. 2005). The study by Ciaramicoli et al. (2003) supports the above results. Hsu et al. (2006) also hypothesised the improved desensitising effect of a combined treatment. A fluoride-containing dentine desensitiser was first applied and this was followed by Nd:YAG laser irradiation (1,062 nm, 33 mJ, 50 pulses/second [pps] for two minutes in slight contact) resulted in long-lasting acid and brushing resistance. The posttreatment was carried out very briefly and the integration of fluoride into the dentinal surface was not confirmed by structural analysis. This confines the validity of this study. Qualitative microanalysis of ions and ultrastructural changes in dentine exposed to Nd:YAG laser (1.5 W, 100 mJ, 15 Hz, 60 seconds, energy density 125 mJ/cm², with black ink as dye solution) and fluoride solutions (10% SnF₂ for 30 minutes; 10% SrCl₂ for 30 minutes) proved the capability of the Nd:YAG laser to alter the

dentinal structure by melting and resolidification of the surface with an occluding effect on exposed dentine and additionally altering the absorption of ions, leading to a better infiltration into the dentinal structure (Glauche et al. 2005). After the combined use of the Nd:YAG laser and 10% SnF₂, Sn₂₊ could be detected up to 250 µm in EDX analysis compared with 100 µm without laser application. The combined use of the Nd:YAG laser and 10% SrCl₂ resulted in an uptake of Sr₂₊ up to 500 µm compared with 23 µm without laser irradiation (Glauche et al. 2005).

—Middle-output power lasers: Er:YAG laser

Today, there are only a few clinical studies on the application of the Er:YAG laser (2,940 nm) in the therapy of dentine hypersensitivity. A possible explanation for the desensitising effect of the Er:YAG laser is its high absorption in water; thereby an evaporation of dentinal fluid and the retention of the smear layer with a deposition of insoluble salts in the exposed dentinal tubules are assumed (Moritz et al. 2006). Another possible explanation for the Er:YAG laser effects in the treatment of dentine hypersensitivity is an analgesic effect on the pulpal nerves, which would explain the immediate effect and the progressive increase of symptoms after irradiation over time (Badran et al. 2011).

SEM analysis of human dentine after Er:YAG laser irradiation (300 mJ, 10 pps, ten seconds; up to 700 mJ, 10 pps, ten seconds, with and without water cooling) demonstrated that laser energy of 500 mJ/pulse at 10 pps for ten seconds was sufficient for inducing melting and recrystallisation of dentine crystals (Lee et al. 2004). At irradiation parameters of 60 mJ, 2 Hz, without air/water-cooling on human dentine *in vitro* for 30, 60 or 120 seconds, a partial reduction in tubule diameter (30 seconds), an almost complete obliteration of exposed tubules with visible signs of melting (60 seconds) and complete occlusion with a rugous melted dentinal surface were observed (Badran et al. 2011). A decrease in dentine permeability in 26.05% was also achieved at 60 mJ and 2 Hz for four applications of 20 seconds *in vitro* (Aranha et al. 2005). The use of water-cooling is important for the reduction of thermal effects (Lee et al. 2004). Firoozmand et al. (2008) proved that the *in vitro* use of an Er:YAG laser (250 mJ, 4 Hz, 80 s, 19 mJ/cm², non-contact mode, with constant water-cooling) for cavity preparation on bovine dentine did not exceed the critical temperature of 5.5 °C.

Clinical investigations of Er:YAG laser application (100 mJ, 3 Hz, two applications of 60 seconds) have found an acceptable therapeutic effect with reduction in pain over a period of up to six months (Birang et al. 2007).

Comparative studies of Er:YAG lasers

Schwarz et al. (2002) compared the efficiency of Er:YAG laser application (80 mJ/pulse and 3 Hz) and a conventional treatment and observed a significant improvement in symptoms directly after the application of both of the two treatments and after six months compared with the control group. However, at two and six months, the group treated with fluoride varnish showed an increase in dentine hypersensitivity compared with the group treated with laser. The latter had the same level as directly after the laser treatment.

Another comparative *in vivo* study evaluating the effect of the Er:YAG and CO₂ lasers and the combination of these laser types with fluoride application (NaF) proved the efficiency of the two treatment options. With the use of Er:YAG laser light at energy levels of 60 mJ at 30 Hz for 10 seconds without water/air spray alone or in combination with fluoride, the clinical improvement in discomfort determined by a cold-air blast and VAS score was significantly reduced one week, one month and six months after treatment compared with a control group treated solely with fluoridation. No significant differences between Er:YAG laser application and CO₂ laser application as a single dose or as a combined treatment were observed (Ipci et al. 2009).

Similar results in an *in vitro* study that compared the occluding ability of the Er:YAG laser (60 mJ, 30 Hz, ten seconds) and CO₂ laser (1 W, cw, one second) application alone or in combination with 2% NaF gel corroborated the clinical findings mentioned above. A melted appearance along with the occlusion of the dentinal tubules could be found in all irradiated groups, but in terms of number and diameter of open tubules, no significant differences between the laser only and the combination group were found (Cakar et al. 2008).

Editorial note: To be continued in our next issue of laser. A complete list of references is available from the publisher.

—contact

laser

Dr Ute Botzenhart

Department of Orthodontics
Centre of Dentistry and Oral Health
Ernst Moritz Arndt University of Greifswald
Germany

Dr Andreas Braun/Prof Matthias Frentzen

Department of Periodontology, Operative
and Preventive Dentistry
University of Bonn
Germany



A novel technique of Er:YAG laser-enhanced early implant stability

Author_Dr Kenneth Luk & Dr Ryan S. K. Seto, China

_Introduction

Over the years, developments in implant dentistry have concentrated on implant design and surface treatment of titanium,¹⁻¹¹ and successful osseointegration¹² is now considered the minimum standard for all implants.

To avoid bone necrosis, preparation of the osteotomy site is commonly achieved with a series of drills and copious water irrigation. Studies show that erbium lasers with water spray can also be used to prepare the site.¹³⁻¹⁷ However, little attention has been paid to the possibilities of laser conditioning after drill preparation of the implant site.

The Er:YAG laser has a wavelength of 2,940 nm. It falls within the mid-infra-red region (invisible to the human eye) and is well absorbed by water molecules and hydroxyapatite. Since water is one of the main constituents of all oral hard and soft tissues, the Er:YAG laser is therefore used in the ablation of tooth, bone and dental soft tissue.¹⁸⁻³³

Er:YAG laser osteotomy and drill osteotomy have been compared in animal studies.^{16, 17, 34, 35} In these in-

vestigations, laser osteotomy yielded comparable or better results than drill osteotomy in terms of bone healing, and some of these studies^{14, 16, 35} showed favourable laser results for bone-to-implant contact. Romanos et al.¹³ demonstrate that Er:YAG laser irradiation appears to stimulate the secretion of platelet-derived growth factor when preparing osteotomy sites in a rat model. The study postulates that laser irradiation could improve the healing of those sites. Aleksic et al.³⁶ demonstrate the low-level laser effect of Er:YAG laser irradiation with the enhancement of osteoblast proliferation.


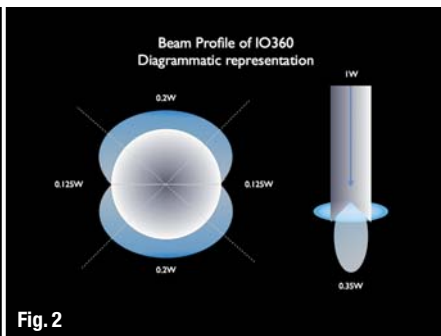

_Objective

The authors thus instituted a study to investigate the possibility of using an Er:YAG laser to condition an osteotomy site prepared according to a standard drilling sequence (SDS). They utilised a newly designed tip, performed a simple in vitro experiment, and then proceeded to test the technique with two clinical cases. The aim of this study was to compare the stability values of implant placement with and without Er:YAG laser conditioning of the bone surface following an SDS. The maxillary region was chosen for both patients.

Fig. 1_IO360 tip. (Courtesy of elexxion AG)

Fig. 2_Representation of the beam profile of the IO360 tip at 1 W emission. (Courtesy of elexxion AG)

Fig. 3_SEM image of sample 1, the SDS-prepared site, showing smear layer in bovine bone.



implants

international magazine of oral implantology

Materials and methods

Tip design

A modified wedge-shaped design, 1,200 μ m diameter IO360 sapphire tip was used (elexxion AG; Fig. 1). A 1 W emission of Er:YAG laser energy was analysed. The beam profile (Fig. 2) demonstrates both side- and end-firing components, although the power is not evenly dispersed. Ideally, the tip should provide an even 360-degree emission to allow complete irradiation of the osseous surface, but such a tip is not currently available from the company.

In vitro experiment

Three samples of bovine bone were used. Sample 1 was prepared according to an SDS to produce an osteotomy site (4 mm x 9 mm), and served as the control. Sample 2 was prepared by Er:YAG laser (elexxion Duros) using a 1,000 μ m conventional tip with parameters of 200 mJ, 10 Hz, 2 W, 100 μ s pulse duration, with water spray, irradiated for approximately 15 minutes. Sample 3 was prepared according to an SDS, similar to sample 1, followed by Er:YAG irradiation with parameters of 100 mJ, 20 Hz, 2 W, 100 μ s pulse duration, with water spray, and with a vertical movement of the IO360 tip along the entire length of the site for 30 seconds. Scanning electron microscope images of the samples were taken at 1,000x magnification by Prof. W.K. Leung at the University of Hong Kong (Figs. 3–5).

Clinical cases


Two patients were selected for this pilot study, and each was to have four implants (BioHorizons) placed in the maxillary posterior region. Osteotomies were prepared according to an SDS. One site was used as a control and the other three sites were conditioned according to the same Er:YAG laser protocol described above for sample 3 (100 mJ, 20 Hz, 2 W, 100 μ s pulse duration, with water spray). The authors have named their technique the Laser-enhanced Early Implant Stability Technique (LEIST), which uses two different movements for conditioning.

The first technique, termed LEIST-v (Fig. 6), entails a 15-second vertical withdrawal movement of the IO360 tip, placed in the centre of the osteotomy site, starting 1 mm above the apical floor and finishing at the ridge surface of the site. Then the tip is rotated one-quarter turn, placed 1 mm above the apical floor, and again withdrawn vertically over a 15-second period.

The other technique, termed LEIST-s (Fig. 7), entails a spiral withdrawal movement of the IO360 tip, starting 1 mm away from the apical floor and finishing at the ridge surface of the site. As the tip is withdrawn, it passes very close to the wall of the preparation, but does not touch it. The movement takes 30 seconds.



You can also subscribe via
www.oemus.com/abo

 **Subscribe now! One issue free of charge!**

I hereby agree to receive a free trial subscription of **implants international magazine of oral implantology** (4 issues per year). I would like to subscribe to **implants** for € 44 including shipping and VAT for German customers, € 46 including shipping and VAT for customers outside of Germany, unless a written cancellation is sent within 14 days of the receipt of the trial subscription. The subscription will be renewed automatically every year until a written cancellation is sent to OEMUS MEDIA AG, Holbeinstr. 29, 04229 Leipzig, Germany, six weeks prior to the renewal date.

▶ Reply via Fax +49 341 48474-290 to OEMUS MEDIA AG or per E-mail to: grasse@oemus-media.de

Last Name

First Name

Company

Street

ZIP/City/County

E-Mail

Signature

Notice of revocation: I am able to revoke the subscription within 14 days after my order by sending a written cancellation to OEMUS MEDIA AG, Holbeinstr. 29, 04229 Leipzig, Germany.

Unterschrift

OEMUS MEDIA AG
Holbeinstr. 29, 04229 Leipzig
Tel.: +49 341 48474-0
Fax: +49 341 48474-290
E-Mail: grasse@oemus-media.de




Fig. 4




Fig. 5

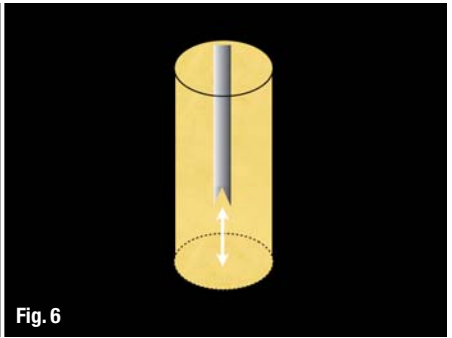


Fig. 6

Fig. 4 SEM image of sample 2, the Er:YAG laser-prepared site with conventional tip, showing minimal smear layer.

Fig. 5 SEM image of sample 3, the SDS-prepared site followed by Er:YAG laser irradiation using the IO360 tip, showing minimal smear layer.

Fig. 6 Diagram of the LEIST-v withdrawal movement of the IO360 tip.

Implant Stability Quotient (ISQ) values were recorded immediately after implant placement and subsequently at one-week intervals for 12 weeks, using the Osstell Mentor. This instrument measures resistance to lateral movement of the implant by using resonance frequency analysis, which employs the principles of a tuning fork. The stiffer the interface between the bone and implant, the higher the resultant frequency, which is converted into a number from 1 to 100 (ISQ value). The higher the stability, the larger the ISQ value. This type of device has a mean ISQ value in the range of 60 to 75.³⁷ As shown in Figure 8, initial mechanical stability is supplemented and then replaced by biological stability as osseointegration progresses.

Case I

The first patient was a 57-year-old male patient with a long-standing history of diabetes and heart disease. He had been taking various medications including aspirin, metformin HCl, simvastatin, metoprolol and gliclazide for the past ten years. He presented with a type 3 bone quality, which is described as thin cortical bone with underlying dense trabecular bone.³⁸ All of the implant fixtures were internal hex and the implant for site #27 also had the Laser-Lok feature, which is the manufacturer's proprietary implant surface treatment. Site #27 was prepared according to an SDS and LEIST-s, and an implant of 5.8 mm x 9 mm was placed. Site #26 was prepared according to an SDS and LEIST-v, and an implant of 4.0 mm x 10.5 mm was placed. Site #14 was prepared according to an SDS and LEIST-v, and an implant of 4.0 mm x 12 mm was placed. Site #15 was prepared according to an SDS only, and an implant of 4 mm x 10.5 mm was placed.

Figure 9 shows a graphic representation of the ISQ values. Implant #15, the control, showed a decrease in ISQ value from week 2 but gradually returned to initial stability at week 9. Implants #14 and 26, conditioned with LEIST-v, showed a very small decrease in ISQ value. Unlike other sites, implant #27, conditioned with LEIST-s, demonstrated an increase in ISQ value from week 1. The actual numerical readings from the device are given in Figure 10.

Case II

The second patient was a 69-year-old male patient with a non-contributory medical history who also had a type 3 bone quality. However, because of the location of the maxillary sinuses, three of the four sites required sinus floor elevation by osteotome. All of the implant fixtures were internal hex with Laser-Lok.

Site #27 was prepared through sinus elevation, an SDS and LEIST-s, and an implant of 5.8 mm x 7.5 mm was placed. Site #26 was prepared through sinus elevation, an SDS and LEIST-s, and an implant of 4.5 mm x 7.5 mm implant was placed. Site #15 was prepared according to an SDS and LEIST-v, and an implant of 4.5 mm x 7.5 mm was placed. Site #17 was prepared through sinus elevation and an SDS, and an implant of 5.8 mm x 7.5 mm was placed. This also served as the control.

Figure 11 shows a graphic representation of the ISQ values. Implant #17, the control, showed a 20% increase from the initial ISQ value. Implant #26, conditioned with LEIST-v, maintained an ISQ value above initial stability throughout the period. Implant #27 showed a minimal dip in ISQ value between weeks 2 and

Fig. 7 Diagram of the LEIST-s withdrawal movement of the IO360 tip.

Fig. 8 Graphic representation of ISQ values over time as osseointegration progresses. Note the initial decrease in stability, followed by an increase as the implant becomes biologically stable. (Courtesy of Osstell AB)

Fig. 9 Graphic plot of the ISQ values of each implant in Case I over a 12-week period.

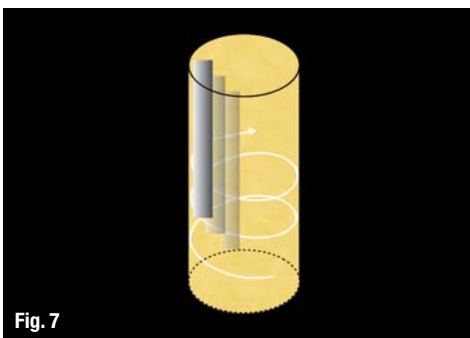


Fig. 7

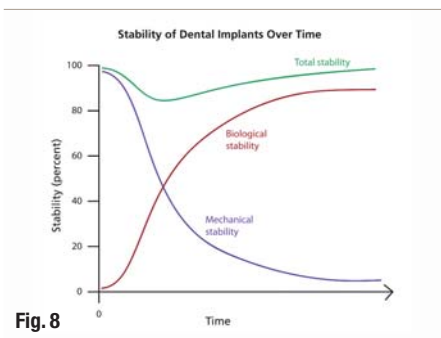


Fig. 8

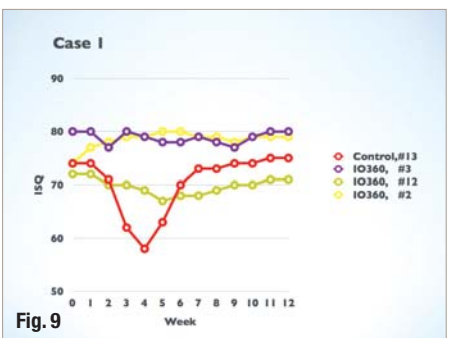


Fig. 9

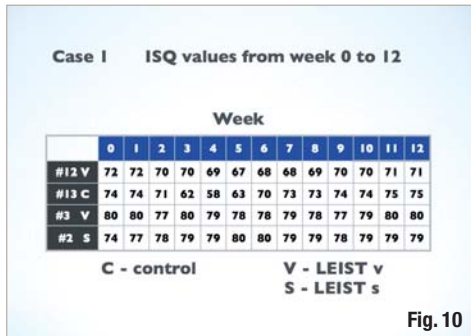

Fig. 10

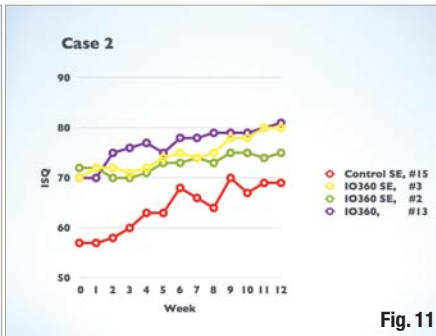


Fig. 11

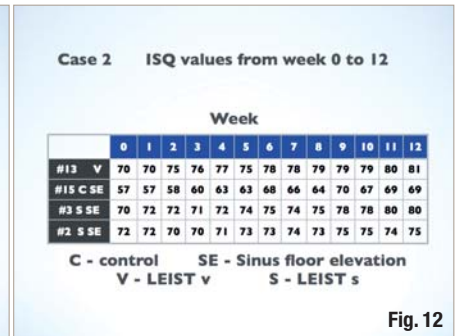


Fig. 12

4, but had recovered by week 5. Implant #15, conditioned with LEIST-v, but without sinus elevation achieved a 10% steady rise in ISQ value by week 4, while implants #26 and 27 required nine weeks or more to reach the 10% increase in ISQ value. The actual numerical readings from the device are given in Figure 12.

Discussion

In Case I, the control showed an expected ISQ progression with a decrease in week 2 and a re-establishment of initial stability by week 9. The 20% drop in ISQ value was most severe at week 4, which may be related to the patient's diabetic condition. Implants conditioned with LEIST-v did not show a significant drop in ISQ value, and the LEIST-s-treated site showed a constant rise in ISQ value from the first day.

In Case II, the control started with an ISQ value of 57 at week 1 and the stability gradually increased by 20% over six weeks. Implant #26 showed an immediate increase in ISQ value, while implant #27 showed a 3% dip at week 2 and returned to above the initial ISQ value at week 5. Lai et al.³⁹ reported good initial primary stability with sinus floor elevation and a decrease in stability between weeks 2 and 6, but ultimately a high stability at week 20. The authors had similar but slightly higher values in their smaller study.

Barewal et al.⁴⁰ found that the greatest change in stability was between weeks 3 and 10. The control in Case I showed similar findings, but the sites conditioned with LEIST showed very small drops in ISQ value between weeks 3 and 10 or immediate increases in ISQ value. Bornstein et al.⁴¹ demonstrated successful early loading with provisional prostheses 21 days after implant placement using modified-surface implants. The authors would be interested to see whether adding the LEIST protocol to these modified-surface implants could achieve any improvement in stability and early loading.

Conclusion

The results of this very small clinical study indicate that the Er:YAG laser with a special tip design and the LEIST protocol could improve the early stability of im-

plants. The ISQ results are promising but not statistically significant. Animal and histological studies with this technique will be the next step to confirming the progressive level of osseointegration, and more clinical cases utilising LEIST are underway.

Acknowledgements

The authors would like to thank ellexion AG for their support and the design of the IO360 tip. Prof. W. K. Leung at the Prince Philip Dental Hospital, University of Hong Kong, is acknowledged for his support with the *in vitro* study. The authors would also like to thank Dr Douglas Chong, who performed the implant surgery for Case II. Lastly, they would like to thank Drs Frank Yung and Don Coluzzi for their guidance.

Disclosures

The authors received no financial support from ellexion AG, BioHorizons or Osstell AB for this study. Dr Luk is a presenter for ellexion and receives honoraria for his services. Dr Seto has no relationships to disclose.

Editorial note: The article was first published as K. Luk & R.S.K. Seto, A novel technique of Er:YAG laser-enhanced early implant stability for implant dentistry: A pilot clinical case report, Journal of Laser Dentistry, 19/1 (2011): 162-167, and is reprinted here with kind permission of the Academy of Laser Dentistry. Copyright 2011 by the Academy of Laser Dentistry. All rights reserved.

A complete list of references is available from the publisher.

| | |
|--|-------|
| _contact | laser |
| <p>Kenneth Luk 301, No.50 Queen's Rd Central, Hong Kong China</p> <p>drkluk@mac.com</p> | |

Fig. 10_Numerical values of each implant in Case I over a 12-week period.

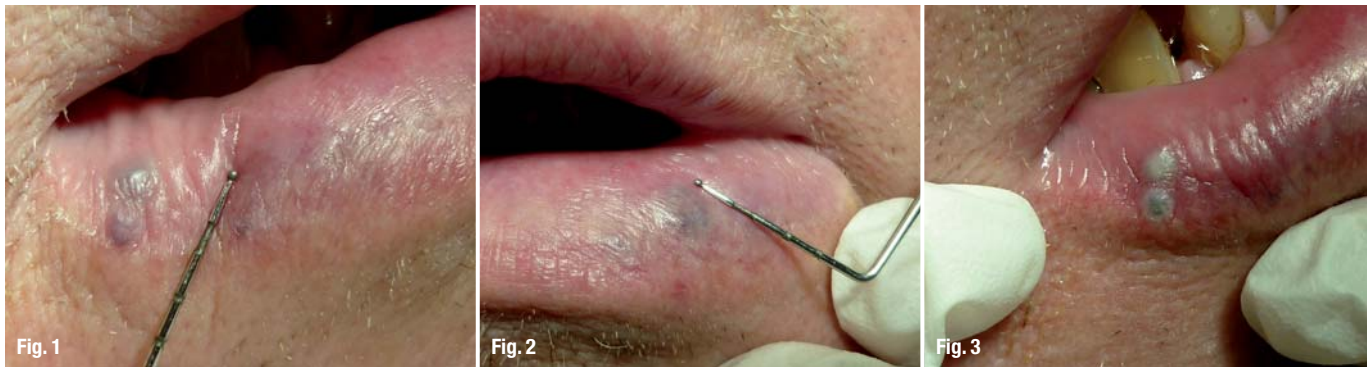Fig. 11_Graphic plot of the ISQ values of each implant in Case II over a 12-week period.

Fig. 12_Numerical values of each implant in Case II over a 12-week period.

Laser therapy of oral haemangiomas

A case report

Author_Friedrich Müller & Dr Maximilian Schmidt-Breitung, Germany



Figs. 1 & 2_Haemangiomas prior to treatment.

Figs. 3 & 4_Immediately after treatment.

_Introduction

Owing to demographic changes, eruptive or so-called senile haemangiomas have become more frequent among our patients. Haemangiomas are benign endothelial tumours found more often in women than men. Congenital capillary or cavernous haemangiomas are characterised by remission in more than 50%. Eruptive haemangiomas occur spontaneously in patients of 60 or older, especially on the lips, but they can also be found elsewhere. Remission of eruptive haemangiomas is observed more seldom than in capillary or cavernous haemangiomas. Owing to their localisation and the fact that older patients have more serious general health problems, non-surgical and non-invasive modalities for haemangioma treatments are favoured in order to minimise the risk of prolonged bleeding and scarring. Therefore, the use of lasers is nowadays the best option for removing haemangiomas easily. This article demonstrates the removal of three oral eruptive haemangiomas using an Nd:YAG laser with a wavelength of 1,064 nm.

_Case presentation

Prior to treatment, differential diagnostic aspects must be investigated. Lymphangiomas, retentions,

cysts and tumours of the salivary glands sometimes have a similar appearance to haemangiomas. Even haematomas can be mistaken for haemangiomas. The diagnosis is based on clinical parameters and can be confirmed by the use of a small glass plate that renders the haemangioma anaemic. Aspiration can also be helpful. Angiographic investigations have no clinical relevance in dentistry because of their poor benefit–cost ratio.

A 67-year-old male patient presented with three eruptive haemangiomas. He was treated with an Nd:YAG laser with a wavelength of 1,064 nm. The irradiation time applied was two minutes and the power output was 1.75 W and 15 Hz in non-contact mode. Three eruptive haemangiomas in the lower lip regions 34 and 45 with a diameter of 3 mm were treated in one appointment. The treatment was stopped when the surface of the haemangiomas turned whitish.

Figures 1 & 2 show the haemangiomas in regions 34 and 45 before the treatment. In order to enhance patient comfort, a local anaesthetic was administered. Figures 3 & 4 give an impression of the three haemangiomas immediately after laser treatment. One week after laser irradiation, a central induration with a marginal bulge was observed. This can be seen

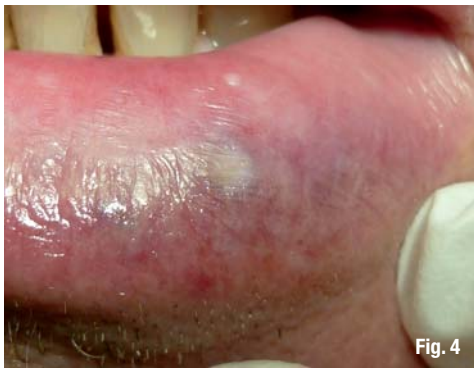

Fig. 4

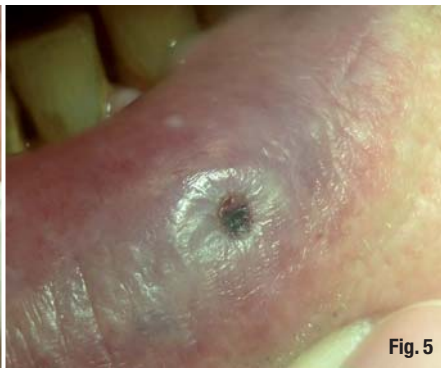


Fig. 5

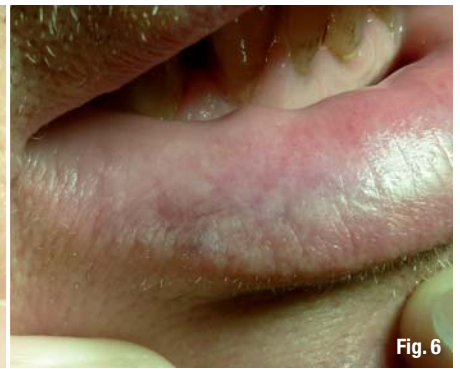

Fig. 6

from figure 5. The complete removal of the haemangiomas was followed up 11 weeks after treatment. As can be seen from figure 6, neither differences in the colour of the lip mucosa occurred, nor in its texture. Although our patient reported stinging pain during laser irradiation, no complications or pain arose during the healing process.

Conclusion

This case report demonstrates that the removal of haemangiomas can be done with very little effort even in the dental practice. We suggest that this procedure can also be used for coagulation of intra-oral lesions of hereditary telangiectasis like morbus Osler-

Rendu-Weber to reduce the risk of spontaneous bleeding.

The authors declare no conflict of interest.

Fig. 5 One week after laser irradiation.

Fig. 6 11 weeks after laser irradiation.

_contact

laser

Friedrich Müller

Tannenring 76
65207 Wiesbaden (Auringen)
Germany

praxis@muellerzahnarzte.de
www.muellerzahnarzte.de

AD

*become an author
for "laser"*



Please contact Claudia Jahn
✉ c.jahn@oemus-media.de

Lasers in oral implantology

Author_Drs Ilay Maden & Zafer Kazak, Turkey

(BACKGROUND: ©EW; FEMALE DENTIST: ©FRANCK BOSTON)

_Introduction

Both lasers and implantology are considered to be the fashionable treatments of modern dentistry, and combining them seems to represent best practice from a number of perspectives. Implantology is one of the many dental indications for the use of lasers, and it is one from which patients can benefit significantly.

_The ideal scenario

Ideally, the soft tissue surrounding the implant should be prepared before starting an implant procedure. The vestibular sulcus depth and frenulum should be examined and prepared accordingly. This can also be performed during the second stage of surgery (Fig. 1). Different laser wavelengths can be used for this kind of surgery. Er:YAG lasers cause less pain, as they do not heat the tissue surface, unlike diode, Nd:YAG and CO₂ lasers, and the patient heals more quickly for the same reason.^{1,2}

_Removal of granulation tissue

One of the most important uses of lasers in implantology is the removal of granulation tissue and disinfection of the surgical area after extraction.

Erbium lasers can be used for this purpose, especially if there was chronic infection before the extraction, regardless of whether implants or bone grafts are being placed (Fig. 2). It has even been suggested that implants can be placed at pre-infected sites, although the site has to be cleaned thoroughly.³ Owing to significant differences in water content, the erbium laser can be used to only remove soft tissue by setting the parameters correctly (energy density, pulse duration, etc.). This is done without thermal side-effects on the bone,⁴ and with greater comfort to the patient while disinfecting the surface,⁵ since no force is applied, unlike with curettes. The non-contact or pseudo-contact procedure enables safe cleaning of very fragile bone that may even be in a bridge form if there is a fenestration.⁶

_Laser ablation

If the coronal part of the crest is too thin, and a plateau is desired, ablating the bone in order to achieve the desired thickness is advantageous, since, without a thermal effect, exposure of the implant neck can be avoided. This same safety benefit also applies when angulated implants are placed and distal neighbouring bone needs to be removed. Also, a laser can be used to make an indent to mark the location of the first drilling site because it will not slip and cause iatrogenic damage (especially helpful for novice implantologists). Lasers can also be used when the procedure involves an osteotomy sinus lift, obtaining a bone block or bone splitting (Figs. 3a & b).^{9,10}

_Preparation of the implant bed

The Er:YAG laser can be used for the preparation of an implant bed in special cases, such as when the bone is very thin and soft. Thin contact tips can be used to remove the minimum amount of bone (Fig. 4), as they are thinner than pilot drills. Then the implant bed can be prepared using bone condensers. For other cases, it may also be beneficial to prepare the implant bed with a laser to achieve longer stability.¹¹ Ultimately, if scanner systems are combined with high-powered lasers for the purpose of shaping cavities of predetermined dimensions in the bone without the thermal side-effects of drills, it could be speculated that the results would improve even further: in addition to the disinfection of the site, the smear layer would be re-

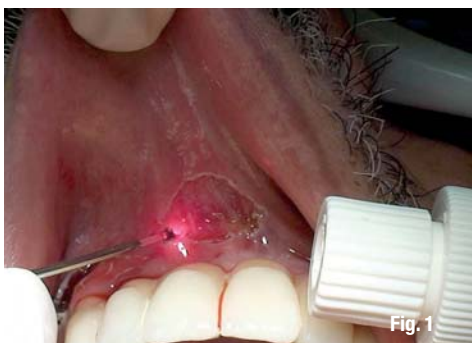


Fig. 1

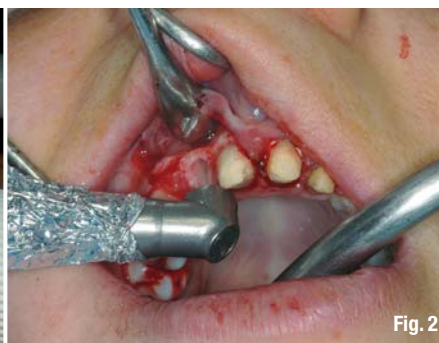

Fig. 2

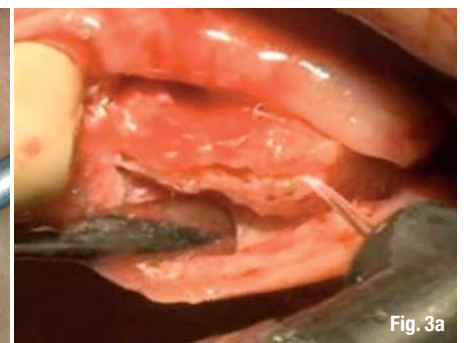


Fig. 3a

_Bio-modulation

After the removal of granulation tissue and superficial disinfection, a diode or Nd:YAG laser can be used for deep disinfection. The penetration of laser energy of these wavelengths in hydroxyapatite and absorption by bacterial pigments are advantageous in this case.⁷ These wavelengths also have a bio-modulation effect, which aids healing, leading to less oedema and pain.⁸ Bio-modulation is mostly effective during the initial healing phase, which is why it should be repeated every second day for the first few weeks.⁸

moved from the surface, activating osteoblastic activity.¹²

_Uncovering the implant

The most comfortable, patient-friendly use of the Er:YAG laser is during the second stage of implant placement: uncovering the implant (Fig. 5). Using a reduced water spray in order to decrease bleeding, it is possible to uncover the implant with diminished pain, even if bone is covering the implant. Using longer pulses causes haemostasis in the soft tissue, while shorter pulses enable the removal of bone without

Fig. 1 Frenectomy with a diode laser after placement of full-arch implant-supported prostheses.

Fig. 2 Cleaning and disinfecting the socket with an Er:YAG laser after extraction.

Figs. 3a & b Bone splitting (a). Sinus window preparation (b).

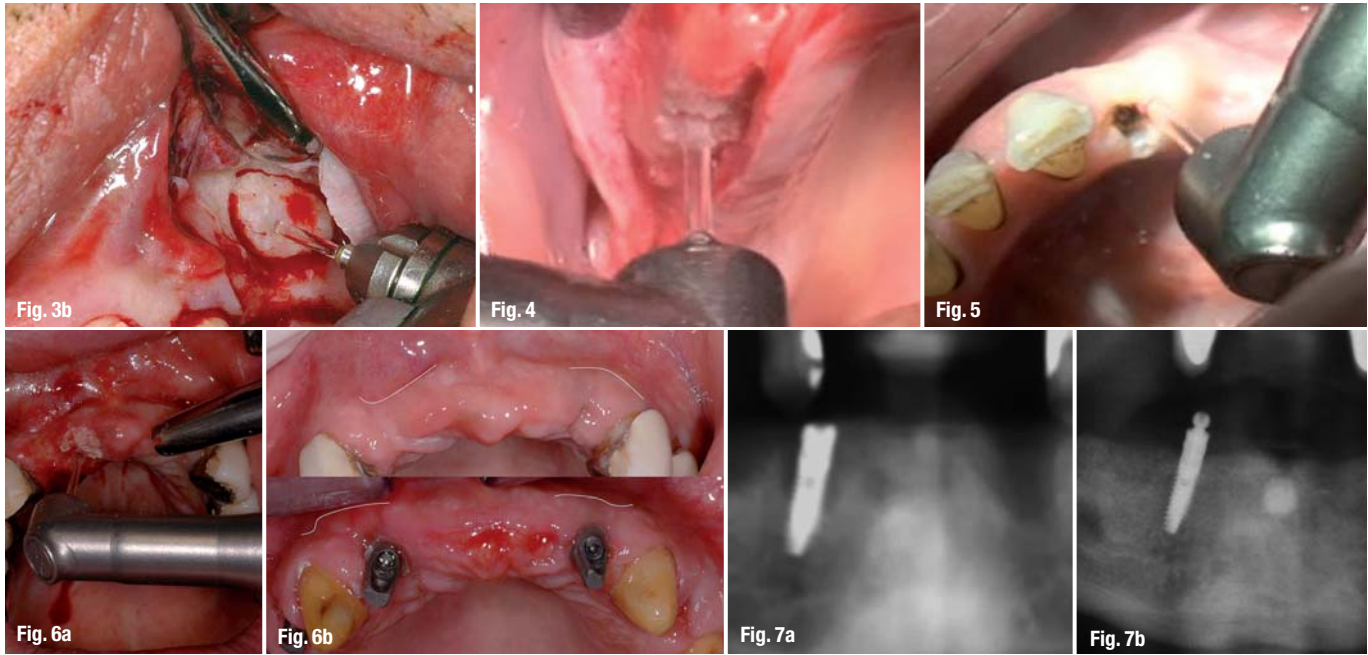


Fig. 4_ Bone ablation for the implant bed.
Fig. 5_Uncovering the implant.
Figs. 6 a & b_De-epithelialisation of the crestal gingival to make a roll flap.
Figs. 7a & b_Peri-implantitis before treatment (a). After cleaning, disinfection and augmentation (b).

thermal side-effects. This is achieved without causing pain to the patient and without raising a flap. This is possible, of course, if there is sufficient attached gingiva and the crestal attached gingiva does not need to be replaced apically. When there is no harmful heating of the soft tissue, there is no retraction of tissue, so the impressions can be taken as soon as possible without delay. Another use is the de-epithelialisation of the crestal gingiva to make a roll flap in order to optimise vestibular soft-tissue thickness (Fig. 6).

_Peri-implantitis

The most efficient use of the Er:YAG laser is in the treatment of peri-implantitis.¹⁴ With Er:YAG, it is possible to clean the granulation tissue both on the bone surface and implant surface (Figs. 7a & b). This is done through decontamination of the site, which is the main purpose of peri-implantitis treatment.^{15,16} Similar to the cleaning of the surgical area after extraction, it is possible to leave the highly fragile surrounding bone intact. The effect of the laser energy on the implant surface is dependent on the amount of energy density, power and possibly also pulse duration.^{17, 18} The parameters should be chosen cautiously, however. Lowering the settings may make the procedure slower but safer for re-osseointegration. Non-surgical use of Er:YAG and diode lasers is also possible if the problem is not extensive.

The most prevalent reason for peri-implantitis appears to be poor occlusal load distribution, with either primary contacts or cantilever bridges in implant-supported prostheses. Good oral hygiene on the patient's part is mandatory. The position and design of prostheses that are difficult to manage may limit the

effectiveness of mechanical cleaning. Once the underlying reason has been determined and recurrence is prevented, the Er:YAG laser can help treat peri-implantitis. Finally, lasers are also used to enhance the aesthetics of implant-supported prostheses. Gingival levelling by crown lengthening and depigmentation are the most common procedures performed for this purpose.

_Conclusion

From this range of laser applications, it is evident that the use of lasers in modern dentistry is only limited by the dentist's imagination. Ultimately, lasers are not miracle machines that can improve the quality of implantology overnight in cases in which the practitioner has limited knowledge and experience in implantology. However, they are indeed a major aid in doing what is needed, always enabling increased comfort, both for the operator and the patient. Education is certainly the key in implantology and laser dentistry in general.

Editorial note: The complete list of references is available from the author.

| | |
|---|--------------|
| _contact | laser |
| <p>Dr İlay Maden PhD, MSc, BDS Mühürdar Caddesi 69 34710 Istanbul, Turkey</p> <p>ilaymaden@gmail.com</p> | |

42ND

October 5-6, 2012 // Hamburg, Germany // Elysee Hotel

Congress President // Prof. Dr. Dr. Frank Palm/DE

Scientific Director // Dr. Roland Hille/DE

INTERNATIONAL ANNUAL CONGRESS OF THE DGZI



Quality driven implantology –
On the way to long term success

Speakers

Prof. Dr. Dr. Kai-Olaf Henkel/DE
Prof. Dr. Dr. George Khoury/DE
Prof. Dr. Dr. Albert Mehl/CH
Prof. Dr. Herbert Deppe/DE
Prof. Dr. Werner Götz/DE
Prof. Dr. Shoji Hayashi/JP
Prof. Dr. Andrea Mombelli/CH
Prof. Dr. Dr. Frank Palm/DE
Prof. Dr. Suheil Boutros/US
Prof. Dr. Peter Rammelsberg/DE
Prof. Dr. Anton Sculean/CH
Prof. Dr. Dr. Jörg R. Strub/DE

Prof. Dr. Hans-Peter Weber/US
Prof. Dr. Thomas Weischer/DE
Priv.-Doz. Dr. Andreas Bindl/CH
Dr. Tomohiro Ezaki/JP
Dr. Daniel Ferrari, M.Sc./DE
Dr. Sami Jade/LB
Dr. Ramy Fahmy Rezkallah/EG
Dr. Osamu Yamashita/JP
ZTM Andreas Kunz/DE
ZTM Tom Lassen/DE
ZTM Christian Müller/DE
Mohamed Moataz M. Khamis
B.D.S., M.S., Ph.D./EG

Gold Sponsor:



Silver Sponsor:



Bronze Sponsor:



FAX REPLY

+49 341 48474-390

Please send me further information on the
42ND INTERNATIONAL ANNUAL CONGRESS
OF THE DGZI October 5-6, 2012, in Hamburg, Germany.



Office Stamp

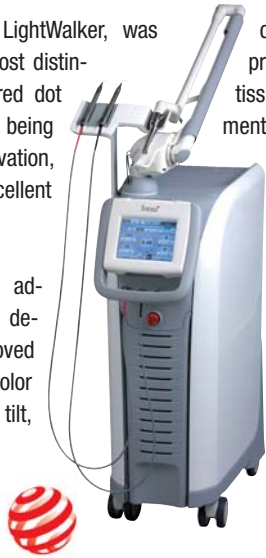Manufacturer News

FOTONA

"red dot design award 2012" for LightWalker

Fotona's latest dental laser, LightWalker, was awarded one of the world's most distinguished design awards, the "red dot award: product design 2012", being recognized for combining innovation, technological perfection and excellent design.

LightWalker's technologically advanced, modern and functional design offers ease-of-use and improved ergonomics: A state of the art color touch screen with an adjustable tilt, interchangeable optics for new technologically advanced hand pieces, and a modern, durable and lightweight system housing allow user-friendly handling. An easy-to-access water reservoir and the unique and patented OPTOflex articulated arm, which allows a full range of motion, provide further



reddot design award winner 2012

comfort. The system enables gentle and precise cavity preparation, sutureless soft-tissue surgery, effective periodontal treatments, safe and efficient endodontic treatment and numerous cosmetic procedures.

The red dot award is LightWalker's third prestigious international quality recognition. In 2011, the Pride Institute awarded the laser system the "Best of Class Technology Award", and *Dentistry Today*, America's leading clinical news magazine for dentists, recognized LightWalker as one of the "TOP 100 dental products of the year".

Fotona d.d.

Stegne 7
1000 Ljubljana, Slovenia

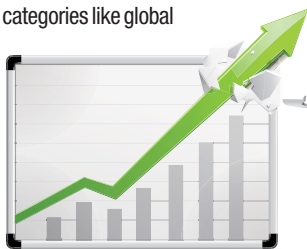
www.lightwalklaser.com
info@lightwalklaser.com

Henry Schein

Henry Schein regains top position on Fortune companies list

Henry Schein is once again No. 1 on *Fortune* magazine's 2012 list of the most admired companies in the wholesale healthcare sector. This is the first time since 2011 that the company has ranked first in this category. In the two previous years, the top position was held by McKesson, a pharmaceutical corporation based in San Francisco.

According to *Fortune*, Henry Schein not only outdid competitors in business-related categories like global competitiveness and long-term investment but also scored best in the social responsibility category, driven by Henry Schein Cares, a program launched in 2001 with the aim of providing medical



supplies and logistic support to underserved communities around the world. In 2011, the program provided medical relief to the victims of Hurricane Irene in North America and the New Zealand earthquake, among others. Nasdaq-listed Henry Schein scored record sales of \$8.5 billion worldwide last year. In addition to its US businesses, the company currently maintains operations in 25 countries.

Henry Schein Dental Deutschland GmbH

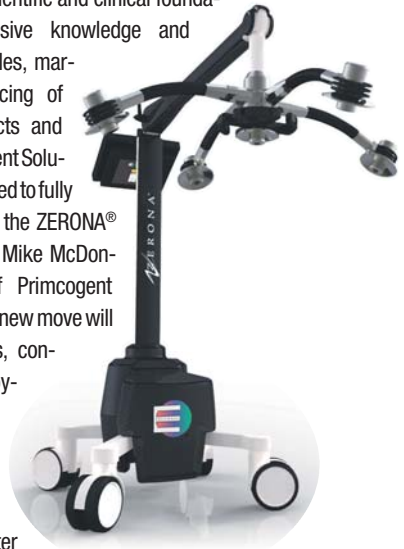Monzastraße 2a
63225 Langen, Germany

info@henryschein.de
www.henryschein-dental.de

Primcogent Solutions

Erchonia Europe renamed as Primcogent Solutions

Erchonia Europe, the provider of Low Level Laser Technology (LLLT) for medical applications, has been renamed Primcogent Solutions, and now holds exclusive North American and Western European distribution rights to the ZERONA® non-invasive body contouring laser. Primcogent Solutions is a privately-held medical company with offices strategically located in New York City, Dallas, the United Kingdom and Germany, whose products and services are backed by a clear, logical and convincing scientific and clinical foundation. With extensive knowledge and success in the sales, marketing and financing of healthcare products and services, Primcogent Solutions is ideally placed to fully support and grow the ZERONA® provider network. Mike McDonald, President of Primcogent Solutions, said the new move will benefit physicians, consumers and employees alike: "Our primary goal has always been to continuously evolve and provide better products and services to



our customers. We are proud to have taken the next step in the evolution of our company." David Boris, Chairman of Primcogent Solutions, added: "We are extremely excited to be able to provide the Erchonia Europe management team with the resources needed to help them grow the ZERONA provider network and add new products into the North American and Western European portfolios."

Primcogent Solutions

The Innovation Centre
99 Milton Park, Abingdon,
Oxon, OX14 4RY, United Kingdom

sales@primcogent.com
www.primcogent.com



Biolase

Biolase concludes transaction with Henry Schein

Biolase Technology, Californian-based dental laser manufacturer and distributor,

has repurchased 159 of its

Waterlase MD Turbo laser systems from Henry Schein, supplier of dental and medical equipment. The equipment is expected to be used primarily as a source of parts to service the large number of installed MD Turbo laser systems and for dental schools in order to promote Waterlase technology in the academic sector.

According to the manufacturer, the Waterlase MD Turbo, first launched in 2006, is the most successful all-tissue laser in the history of dental lasers, with approximately 6,500 units sold worldwide.

Biolase purchased the MD Turbos at a very advantageous price and the entire purchase price was offset by monies owed by Henry Schein to Biolase from sales made in the normal course of business mainly during the first quarter of 2012 and, to a much lesser

extent, the year ended Dec. 31, 2011. None of the monies used to offset the purchase price were related to the original sales of the MD Turbos to Schein.

Federico Pignatelli, Chairman and CEO of Biolase, commented, "Closing this transaction is a very important step for Biolase, as it eliminates the overhang in the marketplace that equaled approximately 440 units at the end of 2010 and significantly impacted our sales in 2011, releases all liens on our patent and intellectual properties portfolio and frees us of any present and future obligations to Schein. It is also a very advantageous transaction, as the remaining inventory was purchased at a very convenient price and will mainly be used as parts to service our vast install base of MD Turbos."

Biolase Europe GmbH

Paintweg 10
92685 Floss, Germany

info@biolase-europe.com
www.biolase.de

elexxion

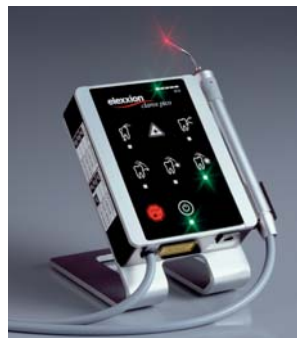elexxion signs distributor for Asian markets

Dental laser specialist elexxion has reported that it has signed a new distribution agreement with Global Dental Supplies in Hong Kong. The five-year contract will give the dental distributor the exclusive rights to distribute elexxion's laser technology for use in dentistry in several Asian countries.

Currently, the German company sells its products through its subsidiaries and dealers in selected

markets, such as India and Japan. The distribution rights for Hong Kong and Macau were previously held by Healthcare Dental, which did not renew its contract with elexxion after 2009, company officials told Dental Tribune Asia Pacific. Besides elexxion dental lasers, Global Dental Supplies also distributes products from the German implant company

BEGO, Sunstar, Bisco and GC, among others. "With Global Dental Supplies we have a strong partner that gives us the opportunity to systematically ex-



pand our sales and marketing activities in Asia," commented elexxion CEO Per Liljenqvist. He said that his company could particularly benefit from the agreement in terms of product registration and exhausting new distribution channels in the region.

The latest elexxion product offering includes the delos 3.0, a novel combined Er:YAG/diode laser indicated for a wide range of dental

applications. In addition, the company distributes the pico mobile diode laser and duros, an Er:YAG dental laser claimed to facilitate efficient hard-tissue preparation and bone ablation tasks.

elexxion AG

Schützenstraße 84
78315 Radolfzell, Germany

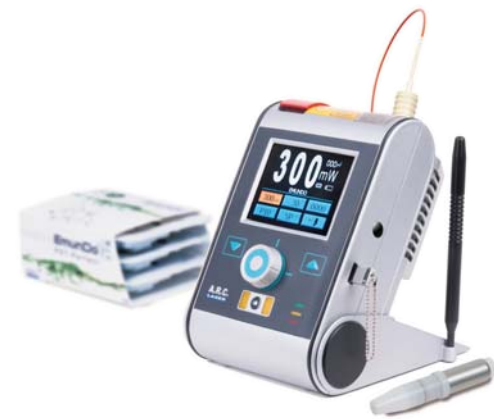info@elexxion.com
www.elexxion.de

A.R.C. Laser

Healthy teeth = Healthy patients

Bacterial inflammation in periodontal pockets can lead to bleeding gums, pocket formation, reformation of gums with loosening and eventual loss of teeth. Furthermore, scientific evidence indicates that there is an increased risk of infections developing in the rest of the body, eventually resulting in vascular diseases in the heart and arteries.

EmunDo® PDT therapy is safe and effective for removing harmful bacteria, regardless of the Gram stain and including Gram-positive/-negative bacteria, as well as Gram-variable and Gram-undetermined species. By comparison, mechanical cleaning cannot reach and remove bacteria in all areas. Other laser-based therapies cannot be said to be clinically effective on all types of germs.



PDT has the ability to treat exposed areas without thermal effect. EmunDo® has a selective, localized effect because it accumulates only in the inflamed areas and can be irradiated immediately without waiting period. Furthermore, the bacteria contained in plaque or biofilm is less affected by antibiotics, because they are shielded by the organic matrix in the film and may be absorbed by or adhere to the tooth and epithel cells. While PDT has the advantage of achieving excellent cosmetic results with minimal risk of scarring, it is also a welcome alternative treatment for periimplantitis to save the implant by maintaining the protective function of the mucosa.

A.R.C. Laser GmbH

Bessemerstraße 14
90411 Nuremberg, Germany

info@arclaser.de
www.arclaser.de

“Laser Supported Dentistry” in Turkey

AALZ and Bezmialem Vakif University Istanbul cooperate

Author Prof Dr Aslihan Usumez, DDS, PhD/Turkey, Leon Vanweersch, MBA/Germany

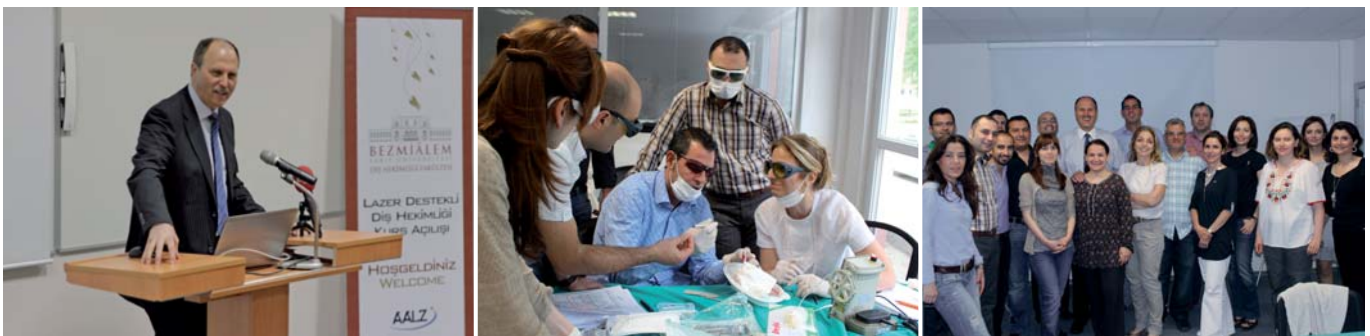“**Laser Supported Dentistry**” attracts more attention in dentistry, day by day. Dental laser training and education are necessary to start laser-assisted dental therapy in order to execute dental laser applications in the most accurate and safe way.

On 5 December 2011, in accordance to a collaboration protocol for post-graduation education, signed by AALZ and Bezmialem Vakif University, the first one-year mastership certification course “Laser Supported Dentistry” was started at Istanbul Bezmialem Vakif University.

A well-attended opening ceremony was arranged in the university on 3 February 2012, which was also the starting date of the first course. University Director Prof Dr Adnan Yüksel, AALZ Director Prof Dr Norbert Gutknecht, the Bezmialem Vakif University Dental Faculty Dean Prof Dr Serdar Üsümez, other deans of the university and university academicians, dental laser distributors in Turkey, agents of visual and print media, mastership students and university students attended the ceremony. Bezmialem Vakif University Rector Prof Dr Adnan Yüksel was the first to address the audience. Rector Yüksel emphasized that the University is open for innovations and highlighted the importance of the collaboration with AALZ in his speech. AALZ Director Prof Dr Norbert Gutknecht expressed in his speech that the AALZ network is growing every day and that AALZ has

cooperations with lots of universities all over the world. Prof Gutknecht also introduced the scientific co-worker group for the courses at Bezmialem, formed by Prof Dr Usumez, PhD Dr Maden, Dr Kazak, and Dr Berk, who hold Master of Science degrees and mastership certificates from RWTH Aachen University. Dentistry Faculty Dean Prof Dr Serdar Üsümez introduced the young academic permanent staff of the Dentistry Faculty, expressing that the aims of the new Bezmialem Dental Faculty are a rapid growth and to become an important scientific and academic institution.

The first module of the first mastership course started with 18 participants and took place on 4 to 5 February 2012 at Bezmialem Vakif University. Prof Dr Jörg Meister lectured the Laser Safety Officer training on the first day. On 5 February, a lecture and skill training about the construction and properties of lasers were conducted. The second mastership module was executed from 16 to 19 May 2012. The lecturer here was Prof Gutknecht himself, assisted by Dr Maden, Dr Kazak and Prof Usumez. Because of the high interest in this mastership program, a second batch will already start their first module from 28 to 29 June 2012. The “Master of Science in Lasers in Dentistry” course, which will start after receiving the approval of the Turkish Council of Higher Education, is being planned to start in September 2013. *Detailed information can be found at <http://aalz.bezmialem.edu.tr>.*



تحت رعاية
سمو الشيخ حمدان بن راشد آل مكتوم
نائب حاكم دبي، وزير المالية
رئيس هيئة الصحة بدبي

Under the Patronage of
H. H. Sheikh Hamdan Bin Rashid Al Maktoum
Deputy Ruler of Dubai, Minister of Finance
President of the Dubai Health Authority

مؤتمر الإمارات الدولي لطب الأسنان ومعرض طب الأسنان العربي
UAE INTERNATIONAL DENTAL CONFERENCE & ARAB DENTAL EXHIBITION

إيكد
AEEEDC
DUBAI

Delivering Science & Technology

5 - 7 February, 2013 | مركز دبي الدولي للمؤتمرات والمعارض
Dubai International Convention & Exhibition Centre

www.aeedc.com

Organised by



In Cooperation with



Strategic Partner



Supported by



Strategic Sports Club Partner



INDEX® Conferences & Exhibitions Organisation Est.

Dubai Healthcare City, Ibn Sina Medical Complex #27, Block B, Office 203, P.O. Box: 13636, Dubai, United Arab Emirates
Tel: +971 4 3624717, Fax: +971 4 3624718, E-mail: info@aeedc.com, Website: www.index.ae

Innovation and information at IDS 2013

Laser technology in the spotlight

Author_VDDI



There is no such thing as a universal laser that covers all indications equally well in the field of laser dentistry. Instead, the sector offers a wide range of different units for specific areas of application. Differentiating features include the respective characteristic wavelength, the medium and the form of signal produced by the laser. As far as wavelength is concerned, the spectrum of light emissions extends from the ultraviolet over the visible region all the way into the far infrared. When it comes to the search for the right laser, interested dentists will find the concentrated expertise of the innovative dental industry and the associated trading companies presented at IDS 2013 in Cologne.

The CO₂ laser, a gas laser, opens up completely new possibilities in soft-tissue surgery. Its applications include frenectomies, vestibuloplasties and hyperplasia removals, where it is used as a minimally invasive scalpel replacement. Furthermore, it can also be used to smooth scars resulting from an apicectomy. Dentists looking for a laser for hard-tissue applications will turn to an Er:YAG laser. This can be used both for caries removal and enamel conditioning and for oral surgery procedures. Such applications include, for example, incisal ridge defects, lesions due to cleaning and multilayer constructions of dentin adhesives. The erbium laser also represents a worthwhile investment for a practice that is active in the field of paediatric

dentistry, as it can be used for minimally invasive therapy of an incipient caries. What's more, the laser works without physical contact and with minimal discomfort to the patient.

Diode lasers can be used to carry out both gingival surgical procedures and endodontic treatments. Multimorbid patients in particular profit from this form of therapy, which is why this technique provides an additional benefit for a practice, especially in the light of ongoing demographic change. Patients suffering from diabetes are much less frequently affected by wound-healing impairments after laser therapy, and the majority of patients receiving Marcumar can also be treated without the need for the internist to make changes to the blood-thinning medication.

IDS takes place in Cologne every two years and is organized by the Gesellschaft zur Förderung der Dental-Industrie mbH (GFDI), the commercial enterprise of the Association of German Dental Manufacturers (VDDI), and is staged by Koelnmesse GmbH, Cologne. "Trade visitors from practices and laboratories will have a unique opportunity during the International Dental Show, the world's largest trade fair for dental medicine and dental technology, in Cologne from 12 to 16 March 2013," said Dr. Markus Heibach, Executive Director of the VDDI.



International events

2012

Europerio 7

Vienna, Austria
6–12 June
www.europerio7.com

FDI Annual World Dental Conference

Hong Kong, China
29 August–1 September
www.fdiworldental.org

21st DGL Annual Conference

Leipzig, Germany
7–8 September
www.dgl2012.de

China Dental Show

Xi'an Qujiang, China
13–15 September
www.ChinaDentalShow.com

32nd Dental-Expo

Moscow, Russia
17–20 September
www.dental-expo.com

22nd Central European Dental Exhibition

Poznan, Poland
20–22 September
www.cede.pl

13th Slovak Dental Days

Bratislava, Slovakia
27–29 September
www.incheba.sk

42nd International Congress of DGZI

Hamburg, Germany
5–6 October
www.dgzi-jahreskongress.de

20th Pragodent Dental Fair

Prague, Czech Republic
11–13 October
www.pragodent.eu

DenTech China

Shanghai, China
24–27 October
www.dentech.com.cn



DGL annual conference in Leipzig, Germany

Author_Jürgen Isbaner, Germany

Translated by_Claudia Jahn, Germany

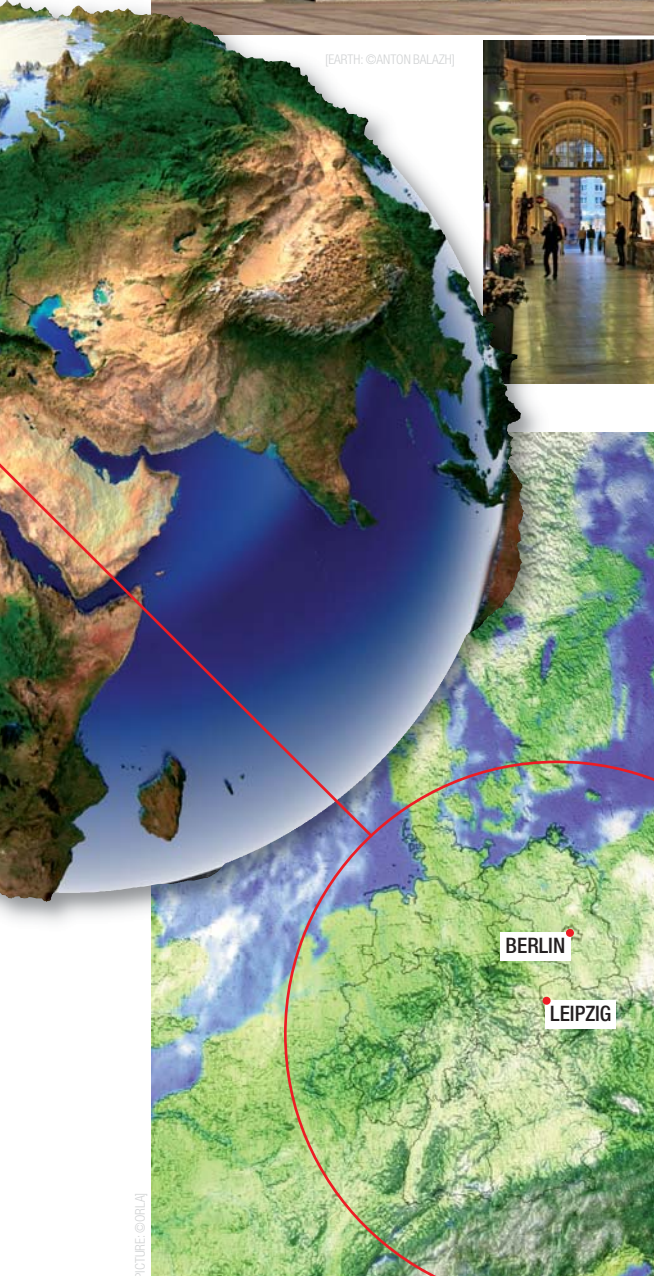

The 21st annual conference of the German Society for Laser Dentistry (Deutsche Gesellschaft für Laserzahnheilkunde e.V., DGL) will take place from 7 to 8 September, 2012, in Leipzig, Germany. Particular focus is placed on laser as an integrative technology in dentistry.

Only a few scientific events in dentistry pay as much attention to laser and its various fields of clinical application as do the DGL annual conferences. The facts that various lasers make soft tissue surgery possible, free of hemorrhage or with only little bleeding, and that caries excavation and the preparation of cavities can be conducted free of pain via erbium lasers have become standard knowledge, at least among the members of the DGL. Other than the direct, visible and demonstrable effects of various kinds of lasers, however, secondary reactions and tissue changes are another interesting and impressive fact to note when it comes to laser dentistry. It is especially those interactions which are scientifically hard to follow and impossible to measure which have had a highly positive impact on the success of laser-supported therapy.

One of the internationally leading scientists, Prof Dr Chukuka S. Enwemeka from Milwaukee (USA) is going to give a speech on this phenomenon at the upcoming DGL annual conference. Under the topic "Biomodulation and Biostimulation", Prof Dr Enwemeka is going to illustrate how visible infrared laser beams can have a positive influence on the surrounding tissues and especially single cells even in small doses.

In addition to photodynamic therapy, almost every field of laser application is put into focus at the conference, reaching from endodontology over periodontology to surgery. After all, laser applications have undergone a significant reevaluation in recent years. Compared to conventional methods in dentistry, laser application often proves to be easier, faster and thus more efficient. Participants of the DGL annual conference will have the opportunity to catch up on the latest developments on the laser market on



the occasion of the accompanying dental trade fair in Leipzig. Parallel to the annual conference, Laser Start Up is designed to enable beginners in laser dentistry to acquire a professional knowledge base in order to enter this new field of expertise. In addition, workshops and hands-on courses will provide practical training in getting to know the various kinds of lasers.

The DGL party is the festive occasion concluding the DGL annual conference Saturday night at THE WESTIN LEIPZIG hotel. The accomplished combination of professional exchange and friendly gathering makes this year's DGL annual conference an exceptional educational event.

_contact

laser

OEMUS MEDIA AG

Holbeinstraße 29
04229 Leipzig, Germany

Tel.: +49 341 48474-308
Fax: +49 341 48474-390

event@oemus-media.de
www.oemus.com

“Scientifically, laser has now reached its highest standard”

Author_Dajana Mischke, Germany

On the occasion of the German Society for Laser Dentistry (Deutsche Gesellschaft für Laserzahnheilkunde e.V.) annual conference 2012 in September in Leipzig, Germany, Prof Dr Norbert Gutknecht of the University Hospital of RWTH Aachen, Germany, commented on the current situation of laser dentistry, the key issues of the upcoming DGL annual conference as well as the future of laser therapy in dentistry and the activities of the DGL.



Prof Dr Norbert Gutknecht

_laser: Prof Dr Gutknecht, this year's DGL annual conference takes place in early September in Leipzig, Germany. Can you tell us what the participants can expect from this event? What are the highlights of the conference?

You can roughly attribute four key points to our upcoming congress in Leipzig. Firstly, we want to present the latest scientific discoveries to our audience in an easily accessible way. Secondly, we aim at emphasising the significance of laser for a successful dental therapy by pointing out how laser technology has been integrated in various medical and dental therapies.

Thirdly, economic efficiency plays a crucial role in any laser application. Therefore, another important aspect of this year's congress is the new German Scale of Fees for Dentists (Gebührenordnung für Zahnärzte, GOZ). And last but not least, there is the social aspect. The success of last year's DGL anniversary party has shown once more how important social values and friendships are nowadays. Our DGL party on Saturday is dedicated to combining the scientific interest we all have in common with a friendly and relaxed atmosphere.

_How would you assess the current situation of laser dentistry? What are the main directions its development is going to take? What do you think will be the status of laser dentistry in five years?

Scientifically, laser dentistry has now reached its highest and most substantiated standard. Furthermore, laser is an integrative technology highly accepted by the professional organisations in medicine and dentistry. In my opinion, this shows how laser technology can take a decisive influence on the success of various therapies. Speaking of the main directions of the development of laser dentistry, we have to take three essential aspects into account: Firstly, there is the advancement of pico-second and femto-second lasers with regard to hard tissue applications. Secondly, laser-activated photodynamic therapy has become both more specialised and developed. Thirdly, therapy concepts for already existing laser systems are constantly being developed, which will lead to a significant growth in the sector of laser technology within the coming five years. This perspective is especially relevant for periodontology, endodontology, cariology, surgery, implantology and pedodontics.

_DGL maintains a high profile, both nationally and internationally. Can you name current activities initiated or supported by the DGL?



Nationally, the DGL boards are intensively engaged in establishing statements and clinical treatment guidelines for the German Society for Dental and Oral Medicine (Deutsche Gesellschaft für Zahn-, Mund- und Kieferheilkunde, DGZMK). Furthermore, subgroups of the executive board and advisory boards are currently discussing the problem of interpreting and billing certain laser treatment options according to the new GOZ. Internationally, DGL is represented both in European and international laser societies. Moreover, not only are members of the DGL much sought-for speakers, but they also are entrusted with different additional tasks in their respective organisations.

Photodynamic therapy is going to be among the key topics of this year's DGL conference. What is the current status of photodynamic therapy in laser dentistry and how relevant is it for the daily dental practice?

In the past, photodynamic therapy only played a secondary role or the role of the outsider, both in scientific research and in clinical applications. However, we have noticed a grown interest in this therapeutic branch since 2006, which has even more increased

within the past two years. By now we can rely on different wavelengths and photosensitisers which have been scientifically tested and applied in clinical therapies. Nevertheless, the range of possible dental applications of lasers is still very limited, with the highest clinical relevance in periodontology: photodynamic therapy has proven a successful integrative method for the standardised procedures of periodontological treatment.

Prof Dr Gutknecht, thank you very much for this interview!

_contact

laser

Prof Dr Norbert Gutknecht

DGL—Deutsche Gesellschaft für
Laserzahnheilkunde e.V.
Pauwelsstraße 30
52074 Aachen, Germany

speck@dgl-online.de
www.dgl-online.de



From the use of lasers to aesthetic implants

by Javier Martínez de Pisón

The third day of lectures of the Dental Tribune Study Club Symposia introduced on Tuesday a good variety of speakers and topics at the Greater New York Dental Meeting. A total of six speakers of different backgrounds spoke at these well-known series of lectures, which are part of the educational arm of Dental Tribune International. Among them were Dr Gregori Kurtzman,



who talked about "Core Buildups, Post & Cores and Understanding Ferrule"; Dr Paul Goodman, who disserted on how to "Capitalize on the Hidden Implant Production in Your Practice";

Dr George Freedman and Dr Fay Goldstep, who gave an explanation of the clinical advantages of the now affordable laser therapy, entitled "The Diode Laser: The Essential Soft Tissue Handpiece".

The 4-day series of lectures of Dental Tribune Study Club attracted a large number of dentists interested in learning about these topics. The Tuesday lectures offered six hours of ADA-CEP Continuing Education credits.

Dr Pedro Lázaro, a Spain-based specialist in periodontics and dental implants, said that what is really difficult is to get results that are perfect from an aesthetic point of view, or as close to perfect as possible.

"It's like when you see a professional tennis player and the game looks very easy, but you know that there are only a few real top level champions like Rafa Nadal or Roger Federer," said Lázaro in an interview after his lecture. "Not using the appropriate technique could worsen the results of treatment," he warned.

Australian survey finds

Dental mid-life crisis in women

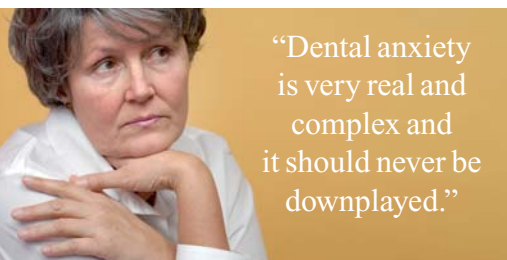Middle-aged women are most likely to suffer from fear of the dentist, a new study found. Clinical observation of patients taking part in a multi-year clinical trial conducted at the Dental Phobia Clinic in Westmead, Sydney, has indicated that the level of dental anxiety is highest among women in their forties.

According to the researchers, this demographic was also found to have perceived a traumatic dental experience, including orofacial trauma, in the past and to be more prone to stress or mental disorders like depression. The results are intended to help investigate the relationship between dental anxiety and the

perception of and coping with pain, as well as to develop strategies for managing the condition successfully.

In addition, the study could confirm findings of earlier research that found that cognitive processing of dental phobia in women differs significantly from that in men.

Forty per cent of people in the developed world are estimated to have some form of dental anxiety. Surveys have shown that compared with the general population, phobic patients wait more than five times longer to make a dental appointment, co-ordinator of the study and special needs dentist Dr Avanti Karve said. She added that the key strategy for managing dental phobia is to help the patient develop the skills for coping with or overcoming the condition. "Dental anxiety is very real and complex and it should never be downplayed," she said. The anxiety study has been running in association with clinical psychologists for five years.



"Dental anxiety is very real and complex and it should never be downplayed."

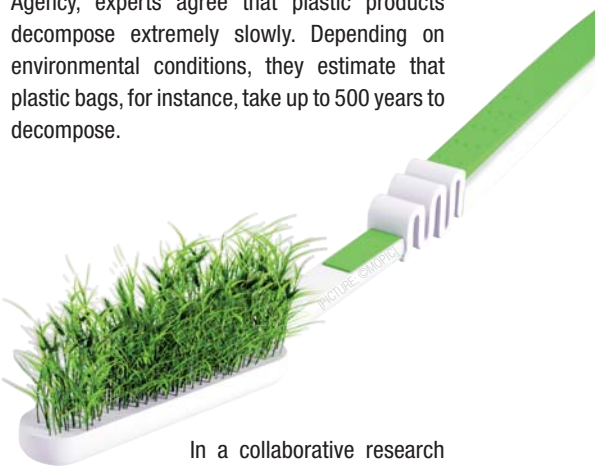[PICTURE: ©JUNIAL ENTERPRISES]

Compostable toothbrush

Produced by German manufacturer

Engineers have developed a cardboard toothbrush that could replace not only disposable toothbrushes in hotels and aeroplanes but also conventional household toothbrushes. The materials used in manufacturing this toothbrush are bio-based, renewable and fully recyclable.

According to the German Federal Environmental Agency, experts agree that plastic products decompose extremely slowly. Depending on environmental conditions, they estimate that plastic bags, for instance, take up to 500 years to decompose.



In a collaborative research project, the Zahoransky engineering corporation and the West Saxon University of Applied Sciences of Zwickau developed an innovative injection-moulding process, which made it possible to produce a toothbrush using renewable raw materials. This invention could be an alternative to disposable toothbrushes, which are also given regularly to patients at dental practices.

According to Zahoransky, the new toothbrush is manufactured from a biodegradable, fibre-filled composite, which is made by first pressing waste paper fibre into free-flowing bulk solids and thereafter processing the solids into injectable granulate using a biopolymer matrix.

Given the rising oil price, which affects the price of synthetic oil-based plastics, and increasing public awareness of ecologically safe products and processes, the designers wanted to create a disposable toothbrush that is environmentally friendly at the same time. The production of the newly developed toothbrush does not involve any fossil fuel because it is made solely from bio-based synthetic materials. After use, the toothbrush can be disposed of in the composting bin.

Survey finds

Most unattractive oral problems

A survey conducted by the British Dental Health Foundation (BDHF) ahead of its annual oral health campaign, National Smile Month, demonstrated that an imperfect smile usually makes a bad impression. National Smile Month from 20 May to 20 June, is the largest oral health campaign in the UK. The survey of more than 1,000 people aimed to determine which oral health problems are generally considered the least desirable to one's appearance. Missing teeth was considered to be the least desirable problem by 57 per cent of respondents, and stained teeth turned off nearly one in five respondents (18 per cent). Surprisingly, only six per cent of the respondents were most put off by braces, and only two per cent of people thought fillings were the least desirable feature. Opinions


were also sought on cracked teeth, uneven teeth and receding gums, problems that put off a combined total of roughly one in five respondents (18 per cent).

According to Dr Nigel Carter, Chief Executive of the BDHF, the findings do not come as a great surprise: "Images portrayed in



the media of celebrities have led to a society where image and the way we look is an important facet of daily life. Young people particularly associate celebrities with attractiveness, achievement and affluence, so it is only natural they will seek to mimic what they see on TV and in print."

Carter added, "It is great to see oral health in the country improving over the years of the campaign, but there are still improvements to be made. By taking responsibility for your oral health, your teeth and your mouth, it's clear from the survey desirability can improve too."



Researchers investigating YouTube have suggested that the potential of the online video-sharing platform and similar social media sites as means of dental education is highly underdeveloped. In a study, they found that it could hold important implications for dental professionals, as well as dental education staff.

Owing to an increasing integration of multimedia sources into professional and academic education, Dr Michael Knösel, an orthodontic specialist, and his team from the University of Göttingen, assessed the value of videos on YouTube related to dentistry. Two assessors with an academic background evaluated 60 videos in the general category "All" and 60 videos in the "Education" category. The results were first sorted "by relevance" and later by "most viewed". Videos in the educational category were mostly uploaded by practitioners but also by academic institutions and dental companies. The majority of videos in the general category, which were aimed at entertainment generally, were mostly posted by patients and laypersons, but there was also a significant percentage of

videos with a commercial purpose and posted by dental manufacturers. The assessors said that videos in the educational category depicted an optimistic view on dentistry, whereas those in the general category tended to be rather negative. They found that between 68 and 93 per cent of the videos represented dentistry accurately, and videos in the general category were inaccurate in this regard.

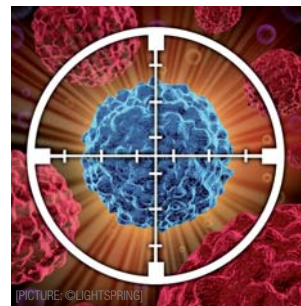
The researchers recommended that more academic institutions acknowledge YouTube as an effective supplementary medium for education: "YouTube and similar social media websites offer new educational possibilities for dentistry, but are currently both underdeveloped and underestimated regarding their potential value. Dentists should also recognise the importance of such websites in relation to the formation of public opinion about their profession," the researchers stated. "We would therefore like to encourage educators to make greater use of this medium, to work to improve the quality of videos, and to demand that contents are updated on a regular basis."

Novel portable probe

Detects early oral cancer

In order to reduce the time taken to diagnose oral cancer, researchers have developed the first prototype of a handheld detection device capable of fast imaging with a large field of view.

"To achieve a higher survival rate, early and on-site diagnostic methods are much needed in oral health programs. The compact handheld confocal imaging system shows great promise for clinical early oral cancer diagnosis and treatment," the researchers from the University of Texas at Austin's Department of Biomedical Engineering concluded. The probe uses a laser to illuminate the examination area and a micro-mirror, an instrument also used in barcode scanners. The micro-mirror is controlled by micro-electromechanical systems, enabling the laser beam to scan the area as programmed. Preclinical trials showed good correspondence with control images from conventional laboratory microscopes and clinical trials are currently being planned. The paper was published online on April 27 in the *Journal of Micromechanics and Microengineering* ahead of print.



(PICTURE: ©LIGHTSPRING)

laser
international magazine of laser dentistry



Publisher

Torsten R. Oemus
oemus@oemus-media.de

CEO

Ingolf Döbbecke
doebbecke@oemus-media.de

Members of the Board

Jürgen Isbaner
isbaner@oemus-media.de

Lutz V. Hiller

hiller@oemus-media.de

Chief Editorial Manager

Norbert Gutknecht
ngutknecht@ukaachen.de

Co-Editors-in-Chief

Samir Nammour
Jean Paul Rocca

Managing Editors

Georg Bach
Leon Vanweersch

Division Editors

Matthias Frenzen
European Division

George Romanos
North America Division

Carlos de Paula Eduardo
South America Division

Toni Zeinoun
Middle East & Africa Division

Loh Hong Sai
Asia & Pacific Division

Senior Editors

Aldo Brugneira Junior
Yoshimitsu Abiko
Lynn Powell
John Featherstone
Adam Stabholz
Jan Tuner
Anton Sculean

Editorial Board

Marcia Martins Marques, Leonardo Silberman, Emina Ibrahim, Igor Cernavin, Daniel Heyselaer, Roeland de Moor, Julia Kamenova, T. Dostalova, Christliebe Pasini, Peter Steen Hansen, Aisha Sultan, Ahmed A Hassan, Marita Luomanen, Patrick Maher, Marie France Bertrand, Frederic Gaultier, Antonis Kallis, Dimitris Strakas, Kenneth Luk, Mukul Jain, Reza Fekrazad, Sharonit Sahar-Helft, Lajos Gaspar, Paolo Vescovi, Marina Vitale, Carlo Fornaini, Kenji Yoshida, Hideaki Suda, Ki-Suk Kim, Liang Ling Seow, Shaymant Singh Makhan, Enrique Trevino, Ahmed Kabir, Blanca de Grande, José Correia de Campos, Carmen Todea, Saleh Ghabban Stephen Hsu, Antoni Espana Tost, Josep Arnabat, Ahmed Abdullah, Boris Gaspirc, Peter Fahlstedt, Claes Larsson, Michel Vock, Hsin-Cheng Liu, Sajee Sattayut, Ferda Tasar, Sevil Gurgan, Cem Sener, Christopher Mercer, Valentin Preve, Ali Obeidi, Anna-Maria Yannikou, Suchetan Pradhan, Ryan Seto, Joyce Fong, Ingmar Ingenegeren, Peter Kleemann, Iris Brader, Masoud Mojahedi, Gerd Volland, Gabriele Schindler, Ralf Borchers, Stefan Grümer, Joachim Schiffer, Detlef Klotz, Herbert Deppe, Friedrich Lampert, Jörg Meister, Rene Franzen, Andreas Braun, Sabine Sennhenn-Kirchner, Siegfried Jänicke, Olaf Oberhofer, Thorsten Kleinert

Editorial Office

Dajana Mischke
d.mischke@oemus-media.de

Claudia Jahn
c.jahn@oemus-media.de

Executive Producer

Gernot Meyer
meyer@oemus-media.de

Designer

Sarah Fuhrmann
s.fuhrmann@oemus-media.de

Customer Service

Marius Mezger
m.mezger@oemus-media.de

Published by

OEMUS MEDIA AG
Holbeinstr. 29
04229 Leipzig, Germany
Tel.: +49 341 48474-0
Fax: +49 341 48474-290
kontakt@oemus-media.de
www.oemus.com

Printed by

Messedruck Leipzig GmbH
An der Hebemärchte 6
04316 Leipzig, Germany

laser

international magazine of laser dentistry
is published in cooperation with the World Federation for Laser Dentistry (WFLD).


Copyright Regulations

The **laser international magazine of laser dentistry** is published by Oemus Media AG and will appear in 2012 with one issue every quarter. The magazine and all articles and illustrations therein are protected by copyright. Any utilization without the prior consent of editor and publisher is inadmissible and liable to prosecution. This applies in particular to duplicate copies, translations, microfilms, and storage and processing in electronic systems.

Reproductions, including extracts, may only be made with the permission of the publisher. Given no statement to the contrary, any submissions to the editorial department are understood to be in agreement with a full or partial publishing of said submission. The editorial department reserves the right to check all submitted articles for formal errors and factual authority, and to make amendments if necessary. No responsibility shall be taken for unsolicited books and manuscripts. Articles bearing symbols other than that of the editorial department, or which are distinguished by the name of the author, represent the opinion of the afore-mentioned, and do not have to comply with the views of Oemus Media AG. Responsibility for such articles shall be borne by the author. Responsibility for advertisements and other specially labeled items shall not be borne by the editorial department. Likewise, no responsibility shall be assumed for information published about associations, companies and commercial markets. All cases of consequential liability arising from inaccurate or faulty representation are excluded. General terms and conditions apply, legal venue is Leipzig, Germany.

laser

international magazine of laser dentistry



Subscribe now!

You can also subscribe via
www.oemus.com/abo

I would like to subscribe to **laser** international magazine of laser dentistry (4 issues per year) for € 44 including shipping and VAT for German customers, € 46 including shipping and VAT for customers outside Germany, unless a written cancellation is sent within 14 days of the receipt of the trial subscription. The subscription will be renewed automatically every year until a written cancellation is sent to OEMUS MEDIA AG, Holbeinstr. 29, 04229 Leipzig, Germany, six weeks prior to the renewal date.

Reply via Fax +49 341 48474-290 to OEMUS MEDIA AG or per E-mail to grasse@oemus-media.de

| | |
|-----------------------|-----------|
| Last Name, First Name | |
| Company | |
| Street | |
| ZIP/City/County | |
| E-mail | Signature |

Notice of revocation: I am able to revoke the subscription within 14 days after my order by sending a written cancellation to OEMUS MEDIA AG, Holbeinstr. 29, 04229 Leipzig, Germany.

| |
|-----------|
| Signature |
|-----------|





After endodontic laser treatment there is no smear layer around the opening of the lateral canal.

The universe at your fingertips.

LightWalker®

Introducing the highest technology dental laser system

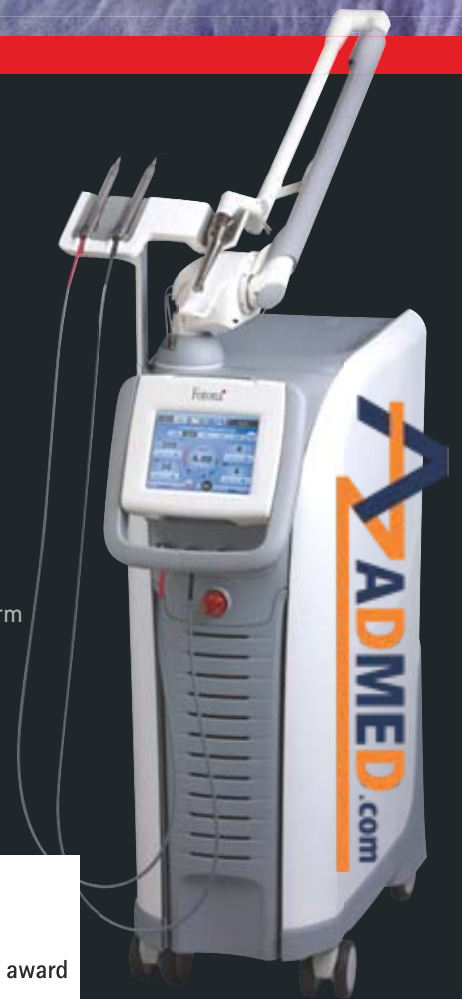Supreme clinical results in:

- TwinLight™ Perio Treatments (TPT)
- TwinLight™ Endo Treatments (TET)
- Effective oral implant surgery
- Gentle TouchWhite™ bleaching
- Patient-friendly conservative dentistry

Unmatched simplicity of use:

- Pre-sets for over 40 applications
- Intuitive user navigation
- Balanced and weightless OPTOflex arm
- Nd:YAG handpiece detection system
- Er:YAG scanner ready

Journey into a new dental experience with speed, precision and great results.
Visit www.lightwalkerlaser.com today!

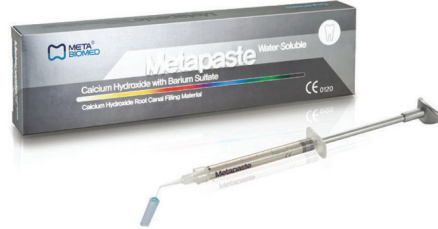



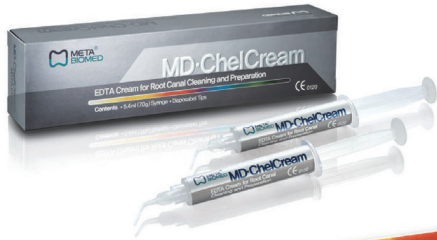• سیلر بیس رزینی
ADSEAL



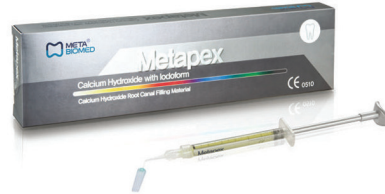• هیدروکسید کلسیم + سولفات باریم
Metapaste



• ژل آرسی پرپ ۱۹٪
MD.ChelCream



• هیدروکسید کلسیم + ید
Metapex



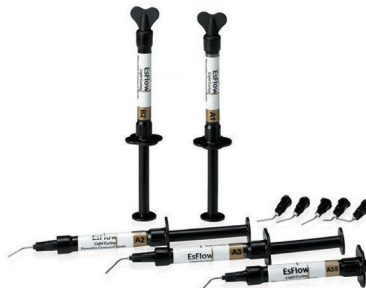• گوتا پرکا
Gutta Percha Point

- ISO sizes : 10, 15, 20, 25, 30, 35, 40, 45, 50, 55, 60, 70, 80, 90, 100, 110, 120, 130, 140
- Non-Standardized (Accessory sizes): XF, FF, MF, F, FM, M, ML, L, XL
- Special Taper Points : .04, .06, .08

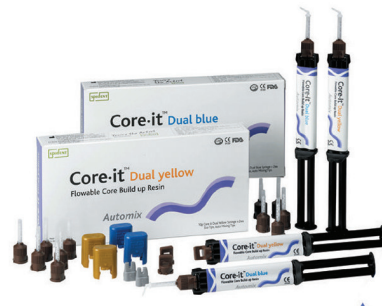protaper : F1, F2, F3



Base.It
(بیس و لاینر) دایکال نوری



EsFlow
کامپوزیت نانو فلو لایت کیور



Core.it
کریبلد آپ دوآل کیور