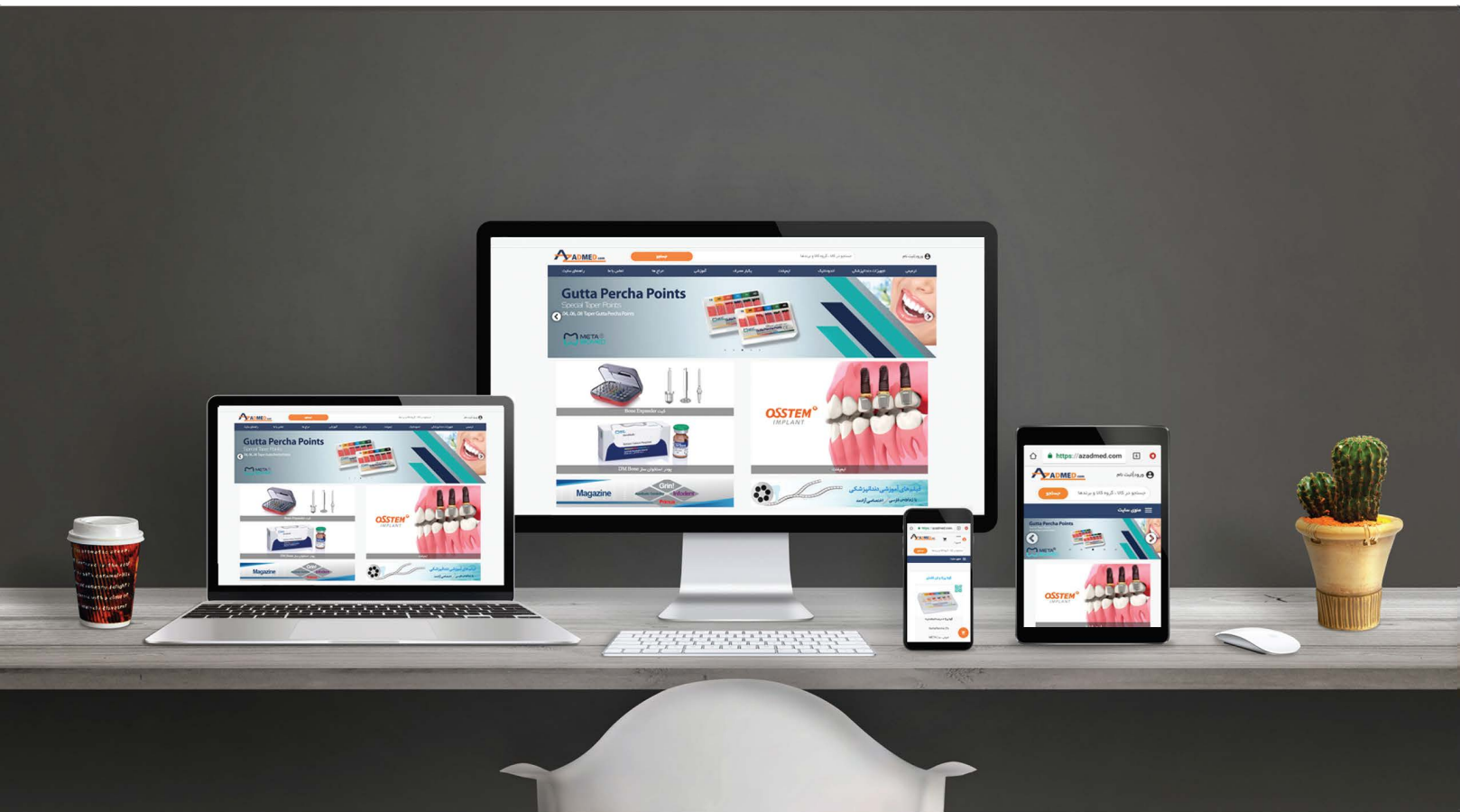




آزاد تجاروت پارس  
AZAD TEJARAT PARS.LTD

**AZADMED.com**



[www.azadmed.com](http://www.azadmed.com)



 azaadtejaratpars

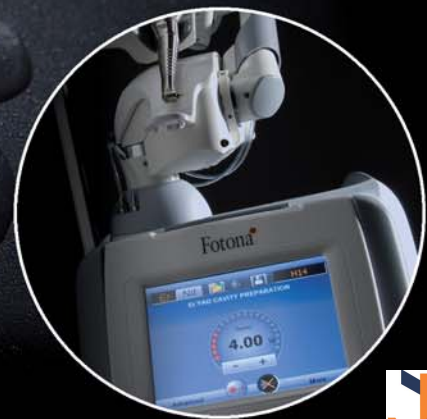 @azadmed2

 88 98 80 63 - 6

# laser

international magazine of laser dentistry

1 2013



| **overview**

Laser versus conventional therapies

| **research**

Photodynamic therapies – Blue versus Green

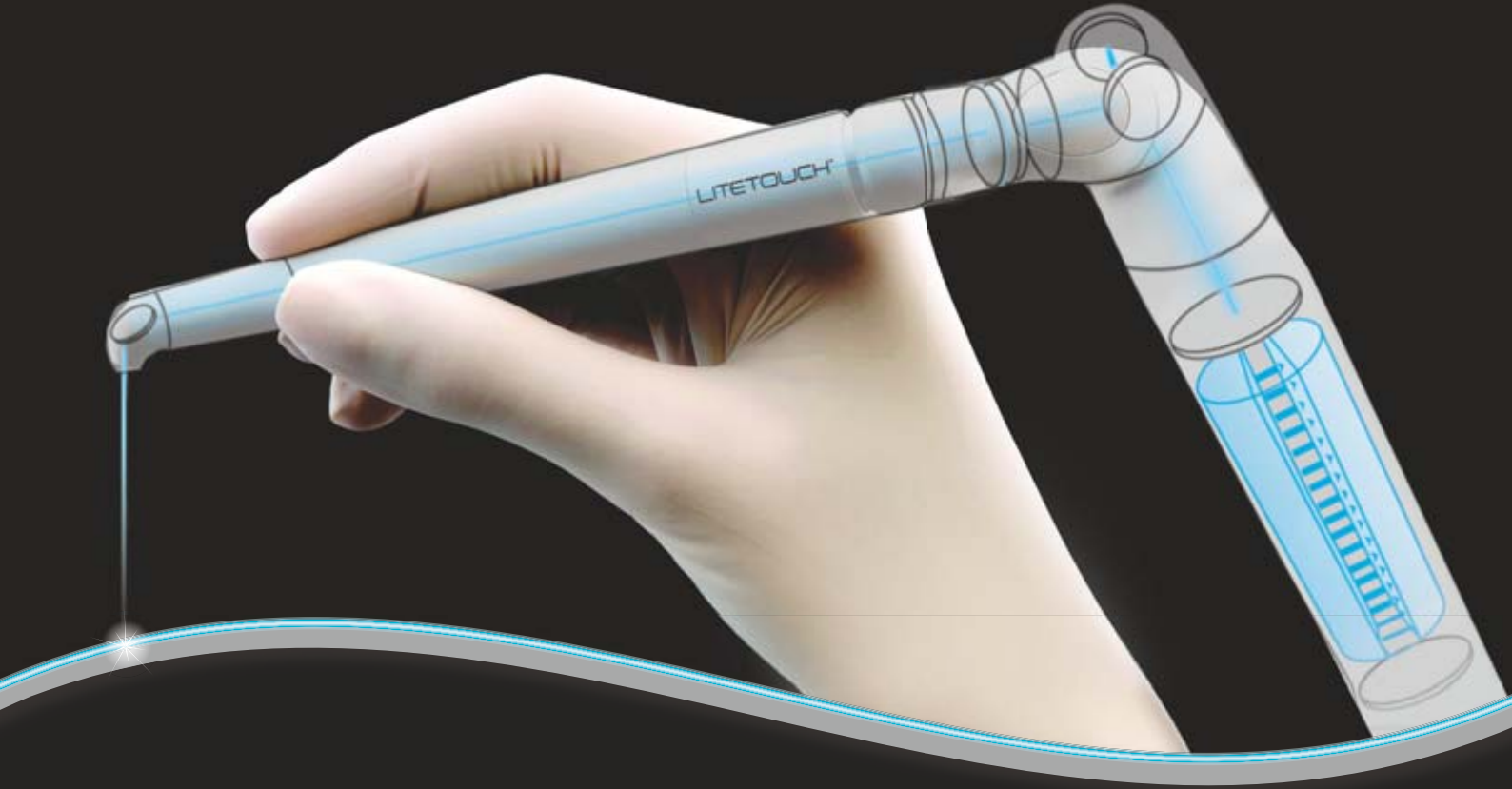
| **industry report**

Long-term treatment of peri-implant lesions in geriatric dentistry



**Syneron™**  
DENTAL LASERS

*Express  
your mastery*



Education. Technology. Family.

Join the Syneron Dental Lasers Family at IDS 2013

**Come and see the LiteTouch™ in action**

The unique Er:YAG laser that has changed the face of laser dentistry

**IDS  
2013**

Live presentations every hour, Booth N050, Hall 4.2, March 12-16, 2013, Cologne, Germany.  
Reserve your personal consultation at [dental@syneron.com](mailto:dental@syneron.com)

WWW.SYNERONDENTAL.COM

# Cologne in the eyes of laser dentistry



Dr Georg Bach

Dear readers of **laser** international magazine of laser dentistry,

I must confess that the headline of this editorial is a little presumptuous—and of course, not only is Cologne in the focus of the dental community, but the whole dental family is watching the city on the Rhine. This time, for sure, it is not because of the carnival, but because of IDS, International Dental Show, which starts only shortly after.

Although we have experienced this dental trade show for decades, it still radiates a hard-to-describe mixture of curiosity, thirst for knowledge and fascination.

IDS has always been a special event for laser dentistry, if not even the motor of this incredible and sometimes turbulent development this dental specialty has undergone since the early 1990s.

Judging from the hype triggered by the first Nd:YAG lasers presented in Cologne as well as the "all new" area of laser-supported hard tissue therapies and photodynamic therapy, laser dentistry has brought about a multitude of both new and aspiring laser users: IDS has always proved to be the perfect place for laser dentistry!

As the dental laser industry is well aware of this fact, all important manufacturers and distributors are represented with stands, staff and equipment and even with an entertaining programme.


Of course, dear reader, I am not yet able to predict if the time-honoured Cologne exhibition halls will witness a new laser hype, but you will certainly encounter state-of-the-art dental lasers at IDS. Therefore, I wish you as well as our editorial team much fun at IDS 2013!

Independently from whether or not you will be able to visit Cologne, I hope that all readers of **laser** international magazine of laser dentistry will enjoy this issue!

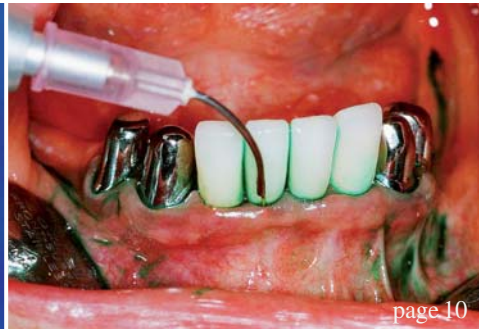Warm regards,

Georg Bach





page 06



page 10



page 26

| editorial

03 **Cologne** in the eyes of **laser dentistry**  
| Dr Georg Bach

| overview

06 **Laser versus** conventional therapies  
| Cristiane Meira Assunção *et al.*

| research

10 **Photodynamic** therapies – **Blue** versus **Green**  
| Dr Michael Hopp *et al.*

| case report

26 **Becoming kissable:**  
**Laser-assisted haemangioma** removal  
| Dr Darius Moghtader

| industry report

30 **Er:YAG Garnet** in laser-assisted **crown lengthening**  
| Dr Avi Reyhanian

34 **Long-term treatment of peri-implant lesions in geriatric dentistry**  
| Dr Georg Bach

38 **X-Runner Er:YAG dental laser** application  
| Prof. Dr Carlo Fornaini

| education

44 **1<sup>st</sup> International Congress of WALED and GLOBAL 2013 in Istanbul**  
| AALZ Germany

| meetings

46 **The next chapter in the IDS success story**  
| Koelnmesse

| news

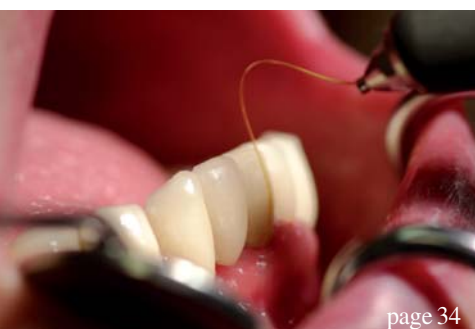42 **Manufacturer News**  
48 **News**

| about the publisher

50 | imprint



Cover image courtesy of Fotona, [www.fotona.com](http://www.fotona.com)



page 34



page 44



page 46



After endodontic laser treatment there is no smear layer around the opening of the lateral canal.

# The universe at your fingertips.



## LightWalker®

Introducing the highest technology dental laser system

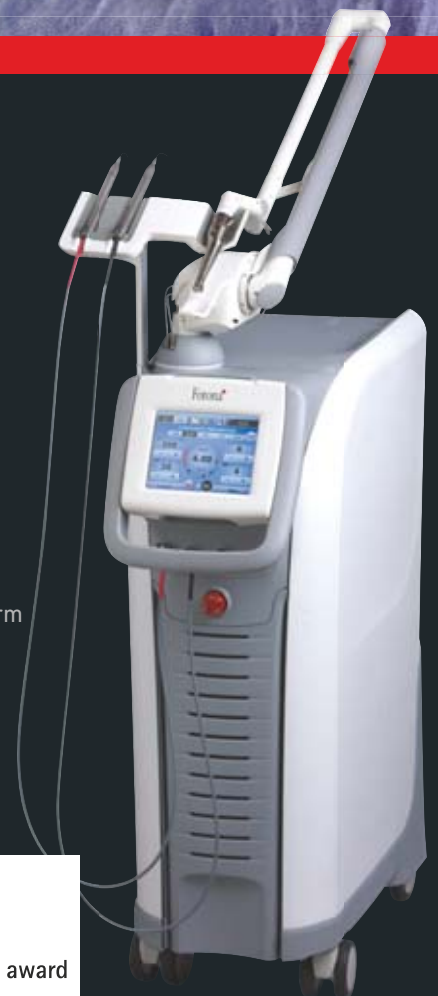**Supreme clinical results in:**

- TwinLight™ Perio Treatments (TPT)
- TwinLight™ Endo Treatments (TET)
- Effective oral implant surgery
- Gentle TouchWhite™ bleaching
- Patient-friendly conservative dentistry

**Unmatched simplicity of use:**

- Pre-sets for over 40 applications
- Intuitive user navigation
- Balanced and weightless OPTOflex arm
- Nd:YAG handpiece detection system
- Er:YAG scanner ready

Journey into a new dental experience with speed, precision and great results.  
Visit [www.lightwalkerlaser.com](http://www.lightwalkerlaser.com) today!





# Laser **versus** conventional therapies

**Authors** Cristiane Meira Assunção, Joanna Tatith Pereira, Renata Schlesner Oliveira & Dr Jonas de Almeida Rodrigues, Brazil



Fig. 1a

Fig. 1a DIAGNOdent 2095.

## \_Introduction

In recent years, several studies have been conducted on the clinical applications of laser in dentistry. At the same time, there has been a marked emergence of organisations in support of the use of laser in dentistry. In the last decades, laser therapy has been used in dentistry as an adjunct or alternative to conventional approaches. In this paper, the following topics will be reviewed: the application of laser in caries prevention and diagnosis, hard- and soft-tissue treatments, and periodontal and endodontic procedures. There is a large research effort into new indications for laser in dentistry. It is expected that laser will become an essential component of the dentist's armamentarium.

While the technology was regarded as complex and of limited use in clinical dentistry in the past, a growing awareness of the usefulness of laser in the modern dental practice has been observed. Laser can be used as an adjunct or alternative to conventional approaches.<sup>1</sup> When comparing the use of laser with conventional therapies, three important areas must

be considered: safety, efficacy and effectiveness. From an ethical standpoint, it is important to use the best available evidence when making clinical decisions.<sup>2</sup>

## \_Diagnostic laser applications

The most common methods for caries detection are visual and radiographic examination.<sup>3</sup> However, visual examination is a subjective method that depends on the knowledge and clinical experience of the examiner.<sup>3-6</sup> Several studies have demonstrated that radiographic examination demonstrates poor sensitivity to non-cavitated lesions.<sup>3,7-9</sup> For this reason, fluorescence-based methods have been developed, aiming at the detection of occlusal and approximal carious lesions, for example DIAGNOdent 2095 (KaVo; LF; Figs. 1a-c) and DIAGNOdent 2190 (LF pen; Figs. 2a & b). They rely on the same principle: a laser diode emits red light at 655 nm and a photodetector quantifies the reflected fluorescence from bacterial metabolites (fluorophores) in carious lesions, showing values ranging from 0 to 99.<sup>3,9</sup>

A study that assessed the performance of a visual method, radiographic examination and fluorescence-based methods in detecting occlusal caries in primary teeth found that the visual method and VistaProof fluorescence camera (Dürr Dental; FC) exhibited better accuracy in detecting enamel and dentine carious lesions, whereas the visual method combined with LF, LF pen and FC better detected dentine lesions on occlusal surfaces in primary teeth, with no statistically significant difference among them.<sup>3</sup>

Another study compared the performance of fluorescence-based methods (FC, LF and LF pen), radiographic examination, and another visual

The logo for WFLD (The World Federation for Laser Dentistry) is located in the top left corner. It consists of the letters 'WFLD' in a bold, white, sans-serif font, with a red horizontal line underneath. Below the line, the full name 'The World Federation for Laser Dentistry' is written in a smaller, white, sans-serif font.

The World Federation  
for Laser Dentistry

## 4<sup>th</sup> Congress of the European Division

# Let there be light!

Brussels, July 11–12, 2013  
[www.wfldbrussels2013.com](http://www.wfldbrussels2013.com)

You are cordially invited to participate  
For information, please visit our website

### **Congress President:**

Pr S. Nammour

### **International Organizing Committee**

**Chairman:** Pr Roly Kornblit

Dr Boris Gaspirc (Slovenia)  
Dr Peter Fahlstedt (Sweden)  
Pr Anton Sculean (Switzerland)  
Dr Miguel Vock (Switzerland)  
Pr Ferda Tasar (Turkey)  
Pr Sevil Gurgan (Turkey)  
Pr Christopher Mercer (UK)  
Dr Miguel Martins (Portugal)  
Dr Marina Vitale (Italy)  
Dr Sharonit Sahar-Helft (Israel)  
Pr Lajos Gaspar (Hungary)  
Dr Dimitris Strakas (Greece)  
Dr Kallis Antonis (Greece)  
Pr Matthias Frentzen (Germany)  
Dr Frederick Gaultier (France)  
Dr Gérard Navarro (France)  
Pr Marita Luomanen (Finland)  
Dr Peter Steen Hansen (Denmark)  
Pr Julia Kamenova (Bulgaria)  
Dr Emina Ibrahimimi (Austria)  
Dr Anna Maria Yiannikou (Cyprus)  
Pr Igor Shugailov (Russia)  
Dr. Oleg Tysoma (Ukraine)  
Pr Assem Soueidan (France)

### **Honorary Presidents:**

Pr Lynn Powel; Pr Isao Ishikawa ,  
Pr Hong Sai Loh, Pr Jean Paul Rocca,  
Pr Norbert Gutknecht

### **International Scientific Committee**

**Chairman:** Pr Carlo Fornaini (Italy)

Pr Jean Paul Rocca (France)  
Pr Norbert Gutknecht (Germany)  
Pr Paolo Vescovi (Italy)  
Pr Umberto Romeo (Italy)  
Pr Antoni J. Espana Tost (Spain)  
Pr Josep Arnabat (Spain)  
Pr Carmen Todea (Romania)  
Pr Adam Stabholz (Israel)  
Dr Thierry Selli (France)

### **Local Organizing Committee:**

**Chairman:** Pr Roeland De Moor

Marc Tielemans  
Daniel Heysselaer  
Amaury Namour

**Secretariat:** Cristina Barrella Penna

**Chairman for commercial relations & Promotion:**  
Pr Roly Kornblit

[www.wfldbrussels2013.com](http://www.wfldbrussels2013.com)



method called the International Caries Detection and Assessment System (ICDAS) II on occlusal surfaces. This study demonstrated that the combination of ICDAS and bite-wing radiographs yielded the best performance for detecting caries on occlusal surfaces.<sup>9</sup>

**Caries prevention:  
Enhancing enamel resistance**

In the past, several *in vitro* studies have shown that enhancing enamel demineralisation resistance can be achieved by irradiation with lasers. In a blind *in vitro* study, Ana et al. 2012<sup>1</sup> compared the effect of professional fluoride application with that of laser irradiation with regard to the demineralisation of enamel and fluoride formation and retention. The study found that both methods enhanced enamel resistance, and no side-effects were found. A greater concentration of retained calcium fluoride-like material was found in the laser group. Formation and retention of calcium fluoride were also improved with laser irradiation.

The wavelengths absorbed most strongly by dental enamel are the 9.3 and 9.6 µm carbon dioxide laser wavelengths. The reduction in acid dissolution of enamel is said to be caused by a loss of the carbonate phase of enamel crystals due to the heat of irradiation. Rechmann et al. 2011<sup>10</sup> demonstrated that short-pulsed 9.6 µm carbon dioxide laser irradiation successfully inhibited enamel caries without any harm to the pulpal tissue of the teeth irradiated. The efficacy of carbon CO<sub>2</sub> laser irradiation regarding its long-term effect on caries resistances can be verified by further studies.

**Hard-tissue applications:  
Caries removal**

There is limited evidence to support the effectiveness of dental lasers in the removal of caries compared with rotary burs. In order to evaluate this, a systematic review of seven studies with adequate methodologies was performed.<sup>8</sup> Two of the studies

found that there was no difference with regard to time taken for caries removal and cavity preparation. Four of the studies found that the laser took up to three times longer to perform these procedures. Four of the studies found that there were no differences between lasers and rotary burs with regard to pulpal effects. One of the studies found that dentists preferred the bur to the laser, and all the studies found that patients favoured the laser with respect to comfort. The studies found that adult patients prefer the laser, although the response from children was inconclusive. The results are not surprising, considering that local anaesthesia is often not needed when using a laser, making the overall dental experience more pleasant for the patient.<sup>10</sup>

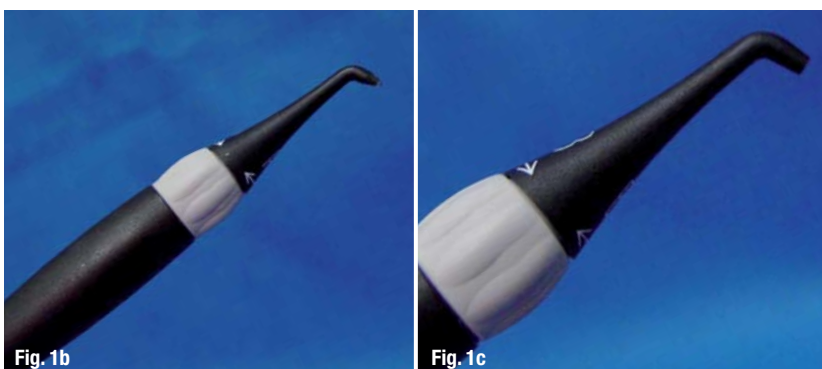
**Endodontic laser procedures  
(disinfection)**

The main causes of endodontic treatment failure are the presence of persistent micro-organisms and recontamination of the root canal owing to inadequate sealing.<sup>11</sup> The long-term success rate of conventional endodontic treatment depends on several factors, such as the diverse and complex anatomy of the root-canal system that consists of small canals diverging from the main canal. This complex system does not allow direct access during biomechanical preparation because of the canals' positioning and diameter.<sup>6</sup> New antimicrobial approaches to disinfecting root canals have been proposed; these include the use of high-power lasers and photodynamic therapy, which works by dose-dependent heat generation. However, in addition to killing bacteria, they have the potential to cause collateral damage such as charred dentine, ankylosed roots, melted cementum, root resorption and periradicular necrosis.<sup>2</sup>

In order to compare the effectiveness of antimicrobial photodynamic therapy with standard endodontic treatment and combined treatment to eliminate bacterial biofilms present in infected root canals, a study was conducted on ten single-rooted freshly extracted human teeth inoculated with stable bioluminescent Gram-negative bacteria. It found that endodontic therapy alone reduced bacterial bioluminescence by 90%, while photodynamic therapy alone reduced bioluminescence by 95%. The combination reduced bioluminescence by up to 98%, and, importantly, the bacterial regrowth observed 24 hours after treatment was much less for the combination group than for the treatment groups individually.<sup>12</sup>

Alternatives to conventional therapies to improve the disinfection of root canals are Nd:YAG and Er:YAG lasers. One study evaluated the bactericidal

Fig. 1b\_Tip A for occlusal surfaces.  
Fig. 1c\_Tip B for smooth surfaces.



efficacy of Nd:YAG and Er:YAG lasers in experimentally infected curved root canals and concluded that in the straight root canals the Er:YAG laser had a bactericidal effect of 6.4 to 10.8 % higher than that of the Nd:YAG laser. Conversely, the bactericidal effect of the Er:YAG laser in the curved root canals was 1.5 to 3.1 % higher than that of the Nd:YAG laser.<sup>13</sup> These results suggest that further development of the endodontic laser tip and techniques are required to ensure its success.

### **\_Periodontal laser procedures (disinfection)**

Conventional periodontal therapy procedures include mechanical scaling and root planing, which has some limitations, especially in reducing bacteria inside deep pockets. In order to overcome the limitations of conventional mechanical therapy, several adjunctive protocols have been developed. Among these, laser has been proposed for its bactericidal and detoxification effects and for its ability to reach sites that conventional mechanical instrumentation cannot.<sup>14</sup>

Different lasers could be used in periodontal therapy for calculus removal, periodontal pocket disinfection, photoactivated dye disinfection of pockets and de-epithelialisation to assist regeneration.<sup>15</sup>

Several studies have indicated that the diode laser, with a wavelength of between 655 and 980 nm, can accelerate wound healing through the facilitation of collagen synthesis, promotion of angiogenesis, and augmentation of growth factor release. Furthermore, the diode laser has in vitro bactericidal and detoxification effects and can prevent ablation of the root surface, which theoretically reduces the risk of removal of normal root tissue.<sup>13</sup>

Sgolastra et al. 2012<sup>14</sup> did not observe significant differences for any investigated outcome (clinical attachment level, probing depth, and changes in the plaque and gingival indices) in their systematic review. These findings suggest that the use of the diode laser as an adjunctive therapy to conventional non-surgical periodontal therapy did not provide additional clinical benefit. However, given that few studies were included in the analysis, the results should be interpreted with caution. Important issues that remain to be clarified include the influence of smoking on clinical outcomes, the effectiveness of the adjunctive use of the diode laser on microbiological outcomes, and the effect of adverse events. Future studies are required to assess the effectiveness of the adjunctive use of the diode laser, as well as the appropriate dosimetry and laser settings.



Fig. 2a



Fig. 2b

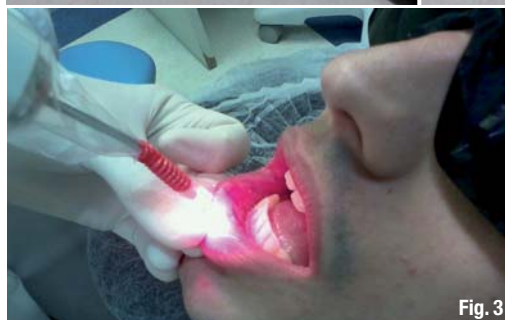

Fig. 3

**Fig. 2a**\_Cylindrical tip for occlusal surfaces.

**Fig. 2b**\_Wedge-shaped tip for proximal surfaces.

**Fig. 3**\_Intra-red laser therapy for treatment of a primary herpetic infection in an adolescent patient undergoing chemotherapy (Therapy XT, DMC).

### **\_Soft-tissue applications**

There are numerous soft-tissue procedures that can be performed with laser. Two key advantages of this are reduced intra-operative bleeding and less post-operative pain compared with conventional techniques, such as electrosurgery. Certain procedures in patients with bleeding disorders are better suited to lasers with greater haemostatic capabilities.<sup>5</sup>

### **\_Conclusion**

Although the results of laser therapy are similar (in safety, efficacy and effectiveness) to those obtained with conventional methods, new techniques and devices have been developed. Laser could thus be an evidence-based and well-supported treatment option for the dentist in daily dental practice.

*Editorial note: A list of references is available from the publisher.*

<b>_contact</b>	<b>laser</b>
<p><b>Dr Jonas de Almeida Rodrigues</b>                  School of Dentistry                  Federal University of Rio Grande do Sul                  Av. Paulo Gama, 110                  Porto Alegre – RGS                  90000-000                  Brazil                    jorodrigues@hotmail.com</p>	

# Photodynamic therapies – Blue versus Green

Author\_Dr Michael Hopp & Prof. Dr Reiner Biffar, Germany

## Introduction

After the successful introduction of antimicrobial photodynamic therapy based on methylene and toluidine blue, a green medical colouring agent which is activated at 810 nm has become available. The following article illustrates its indication, range of effects and therapy efficiency in comparison to the classical blue agents. Photodynamic therapy (PDT) as a minimally invasive oncological method performed with injected photosensitisers has been advanced to a non-invasive, surface-oriented therapy in dentistry. Its main indications are bacteria, which is why it has been marked "antibacterial": antimicrobial photodynamic therapy (aPDT). aPDT entails a light-induced inactivation of cells, microorganisms or molecules without destroying the tissue. Therefore, aPDT or PDT in periodontology, endodontology, professional tooth cleaning, as well as periimplantitis and mucosa treatment must be differentiated from invasive therapies such as hard-tissue treatments in enamel, dentine and bone, surgery, periodontal treatment, endodontology and invasive periimplantitis therapy.

In aPDT, two effects are brought together: the low-level, highly pervasive laser energy with the photodynamic effect resulting in high tissue efficiency and the colouring agent activation resulting in a bactericidal effect via singlet and triplet oxygen, which harms the unsaturated fatty acids in the colour-marked membranes and their organelles. In addition, they initiate the disintegration of the bacterial membranes and therefore cause the bacteria to die. These two effects are linked inseparably in aPDT. Parallely to reducing bacteria, laser light which has not been absorbed promotes healing. Even the application of laser light alone will reduce dental plaque<sup>1</sup>, thus leading to a reduced healing time. In previous years, aPDT has been associated with a multitude of synonyms: PACT—photoactivated chemotherapy, PDD—photodynamic disinfection, LAD—light-activated disinfection, PAD—photoactivated disinfection, among others. These terms signify a principle rather than actually contributing to an enhanced insight into the concept. They can therefore be seen as marketing-oriented neologisms.

Laser-, LED- und colouring agent systems have become available in larger quantities and can be integrated to other therapies. Possible combinations are:

- LED 630 nm—toluidine blue O—Fotosan/Fotosan 630
- Laser 635—toluidine blue O—PACT system, R+J, Two in one, MDL 10, among others
- Laser 670 nm—methylene blue, HELBO system, Periowave, among others
- Laser 810 nm—methylene blue derivative—Photolase system
- Laser 810 nm—indocyanine green—EmunDo, PerioGreen

## aPDT/PDT application in dentistry

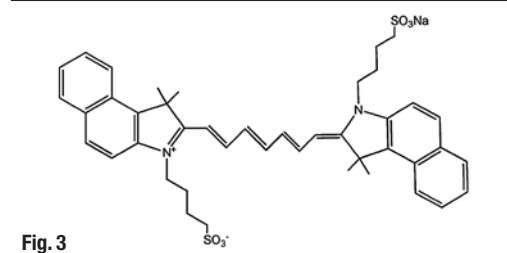
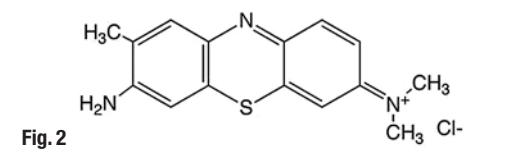
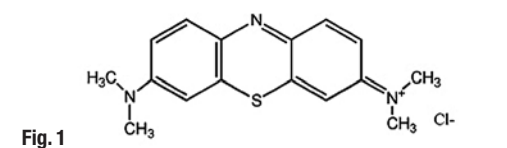
### Periodontology

Periodontology is the most prominent field of application for aPDT/PDT in dentistry to date. aPDT can be applied specifically to target infected and contaminated tissues or organic structures (periodontitis, periimplan-

Fig. 1 Structural formula of methylene blue (MB).

Fig. 2 Structural formula of toluidine blue (TBO).

Fig. 3 Structural formula of indocyanine green (ICG).







# Master of Science (M.Sc.) in Lasers in Dentistry

Next Start: **23 September 2013**  
Aachen, Germany  
4 semesters

## Become part of the International Dental Elite

- Create new economic potential for your practice
- Two year career-accompanying postgraduate programme at the University of Excellence RWTH Aachen
- Combination of lectures, skill training sessions, live ops, tutorials, and practical workshops
- Internationally accepted and accredited by the German Government, the European Union, the Washington Accord and the Bologna Process
- Science-based and practice-orientated on highest national and international level
- Increased patient satisfaction: minimal contact reduced vibration and pain



**RWTH INTERNATIONAL ACADEMY**  
**AACHEN UNIVERSITY**

RWTH International Academy  
Kackertstraße 10 | 52072 Aachen | Germany  
phone +49 241 80 23543 | fax +49 241 80 92525  
info@academy.rwth-aachen.de  
www.academy.rwth-aachen.de

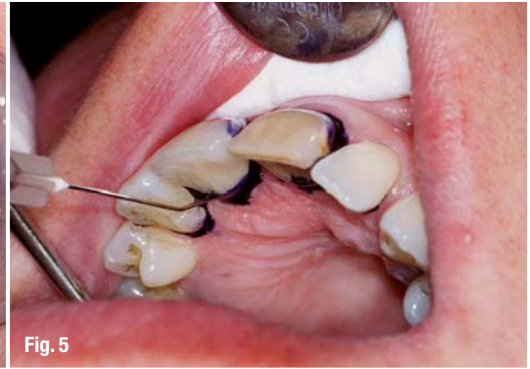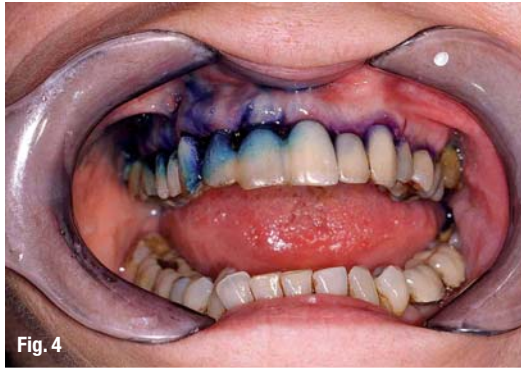
**PROFESSIONAL EDUCATION PROGRAMMES**

**AALZ**

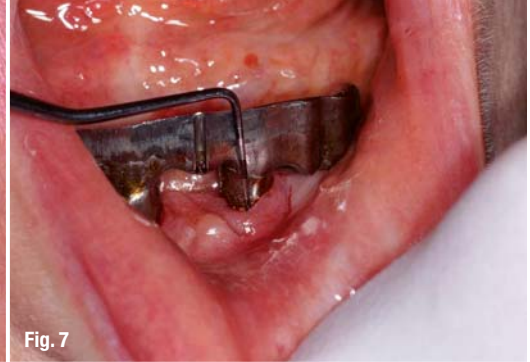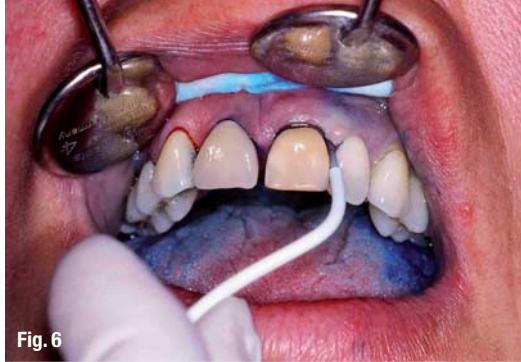Aachen Dental Laser Center

AALZ GmbH  
Pauwelsstraße 17 | 52074 Aachen | Germany  
phone +49 241 47 57 13 10 | fax +49 241 47 57 13 29  
info@aalz.de  
www.aalz.de

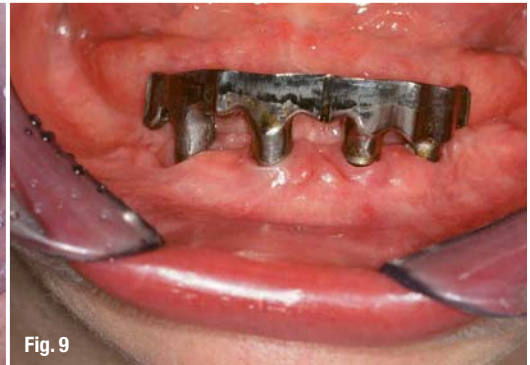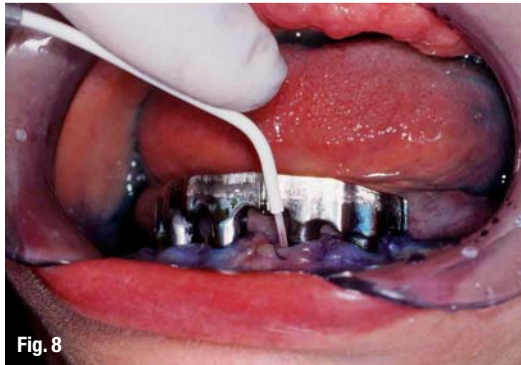**Fig. 4** Intensity differences between methylene blue (Blue Sensitizer, HELBO, on the left) and toluidine blue O (PACT, Cumdente, on the right).



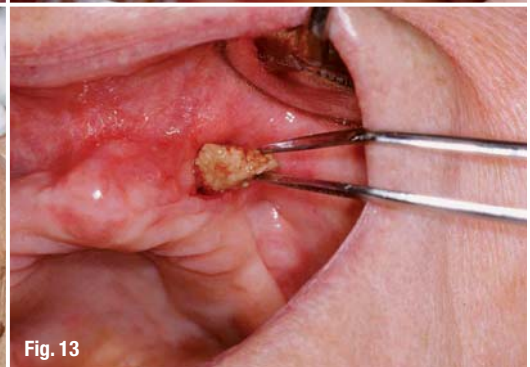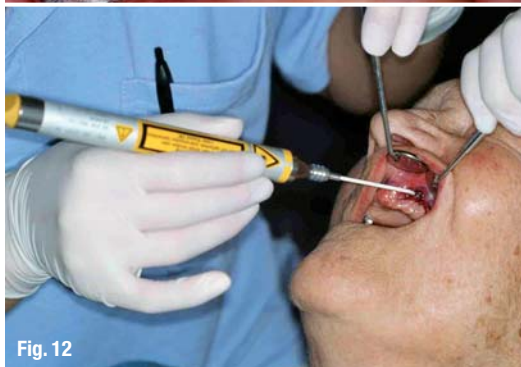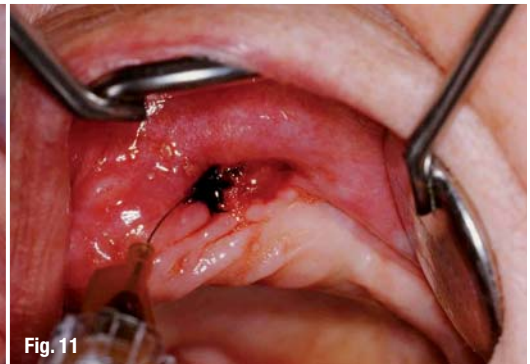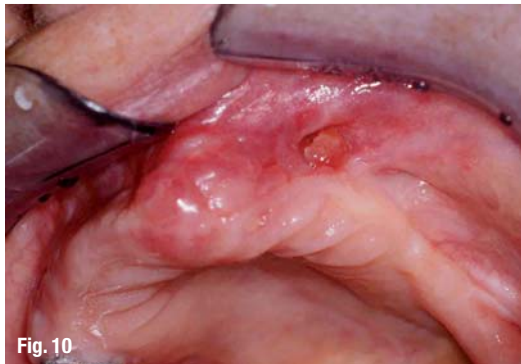
**Case 1**  
**Fig. 5** Blue Sensitizer (HELBO) applied to the sulcus.  
**Fig. 6** Laser light application to the sulcus.



**Case 2**  
**Fig. 7** Measuring of progressing bone resorption.  
**Fig. 8** Selective laser application according to protocol.  
**Fig. 9** Inflammation-free condition after 30 days.



**Case 3**  
**Fig. 10** Entrance to the inflamed bone cavity after pus removal.  
**Fig. 11** Application of Blue Sensitizer to the cavity.  
**Fig. 12** TeraLite laser application.  
**Fig. 13** Removal of a bone sequestrum from a bone cavity which is almost completely epithelialised.





titis, infected mucosa or other areas of the patient's skin).<sup>2-4</sup> De Olivera et al.<sup>5</sup> have reached comparable clinical results in their split-mouth investigations of aPDT in comparison to scaling and root planing (SRP). Wilson et al.<sup>6,7</sup> have introduced the basics of low-level laser application with photosensitive substances in bacteria.

PDT treatment can be applied in dentition damaged by periodontitis:

1. As an immediate measure in acute gingivitis or periodontitis.
2. As a consecutive conventional periodontitis therapy in intervals of three days up to two weeks.
3. In unspecific prophylactic bacterial reduction in extended professional tooth cleaning in intervals of one to two years.<sup>3,8</sup>

aPDT applications have provided good results and a significant reduction of the microbial load.<sup>9</sup> In periodontitis caused by *Porphyromonas gingivalis*, a reduced bone resorption in comparison to the control group was observed in animal studies after colouring agent-activated laser treatment with toluidine blue.<sup>10</sup> Comparing different laser systems with regard to their adjuvant application, Brink and Romanos<sup>11,12</sup> showed that mechanical cleansing combined with aPDT resulted in the highest possible reduction of microbes in the dental pockets. The highest reduction was verified after three months. *Actinobacillus actinomycetemcomitans*, now named *Aggregatibacter actinomycetemcomitans*, was eliminated after treatment with one of the systems (aPDT, 1,064 nm laser, 980 nm laser). Investigations in patients of an open dental practice showed a microbial reduction of 80,11 % after four weeks and 91,37 % after twelve weeks compared to the initial findings of aPDT in comparison to the above-mentioned laser systems. Sulcus bleeding index, pocket depths and mobility of the teeth were significantly reduced after treatment. In cases of minimal pocket depths of three to four millimetres, aPDT can be the sole therapy. A fast recolonisation of the periodontic tissue was minimised by PDT after two days.<sup>13</sup> They showed in their study that roughly 95 % of *A. actinomycetemcomitans* and *F. nucleatum* and 99–100 % of the black-pigmented bacteria, such as *P. gingivalis* and *P. intermedius* and *S. sanguis* were eliminated. Rühling et al.<sup>14</sup> did not note any advantages in PDT with regard to conventional treatment, but they admit that it can be an alternative. The initial treatment of periodontitis with amoxicillin and metronidazole (Winckelhoff cocktail) is favoured by Griffiths et al.<sup>15</sup> over an invasive treatment. An initial administration of antibiotics achieved better results than did subsequent treatment. A critical discussion on the administration of metronidazole was conducted only reluctantly. Procedures which are specifically tropical (aPDT) and of a high selectivity are more favourable in the aftercare of periodontally dam-

aged patients than broad-spectrum antibiotic treatments, which have various side effects and are often accompanied with a limited compliance of the patients.<sup>16</sup> Hägi & Sculean<sup>17</sup> do not consider aPDT which is free from side effects and bactericidal a significant improvement over antibiotic therapies, with the exception of severe and aggressive periodontitis.

The importance of pulpal temperature rise in periodontal treatments is described by El Yazami et al.<sup>18</sup> with an average temperature rise of roughly 0,5°C at 5,46 J/cm<sup>2</sup> for 60 s with a diode laser of 660 nm (output: 20 mW). Another advantage of aPDT is that it can be performed by a trained assistant if the patient has been treated accordingly before. This kind of laser treatment (class 3B) is a physical, non-invasive therapy<sup>19</sup> which can be delegated. Whereas the doctor is in charge of supervision, control and overall responsibility of delegated tasks with respect to a commission with single allocation defined in concrete terms, he does not have to execute the delegated tasks. Treatment is free of pain and non-destructive on the tissues. However, its application in the bleeding dental pocket would neutralise its effect almost completely. Therefore, a time-shift is recommended in this treatment. The activation of epithelia and bone growth, vascularisation and an increase in phosphorylation are important for the production of ATP in the healing phase and their effects on mitochondria and enzymes of the respiratory chain have long been assumed.<sup>20,21</sup> Bosatra<sup>22</sup> showed that low-energy laser light induces the synthesis of fibres in the tissue in 1984. Tocco et al.<sup>23</sup> and Boulton et al.<sup>24</sup> proved an increase in fibroblast growth by HeNe (630 nm) and IR laser application.

#### Implantology

In implantology, aPDT is applied in mucositis or manifested periimplantitis as a closed therapy or as an open therapy in combination with surgical measures. An important advantage of athermal laser applications is the lack of superficial changes of the titan and of ruptures.

#### Oral and maxillofacial surgery

In oral and maxillofacial surgery, photodynamic disinfection of bone or soft tissue defects during the final surgical phase is an additional means of prevention. Local or systemic toxicity of the photosensitiser as well as damage by the source of light can be excluded because of the low energy level. Lingohr et al.<sup>25</sup> have described advantages with regard to apicoectomies. Neugebauer et al.<sup>26</sup> have observed positive effects on the prevention of alveolar osteitis and the dolor post extractionem and Conrad<sup>27</sup> on the augmentation of infected alveoli. Nagayoshi et al.<sup>28</sup> have proved a complete sterilisation of the bone cavity via ICG with radiation for more than 60 seconds at 810 nm in the periapical defect model. PDT can be an alternative to lengthy and highly-dosed antibiotic therapies in the treatment and post treatment



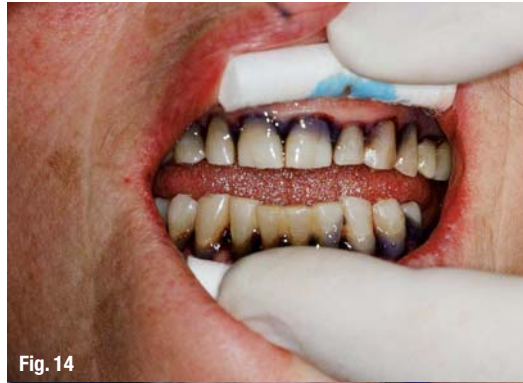

Fig. 14

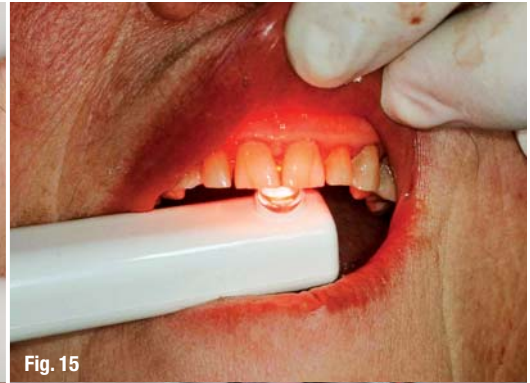

Fig. 15

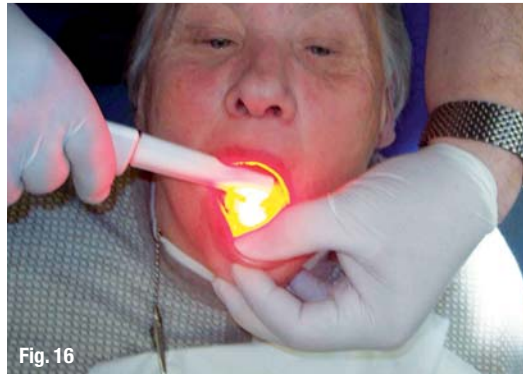

Fig. 16

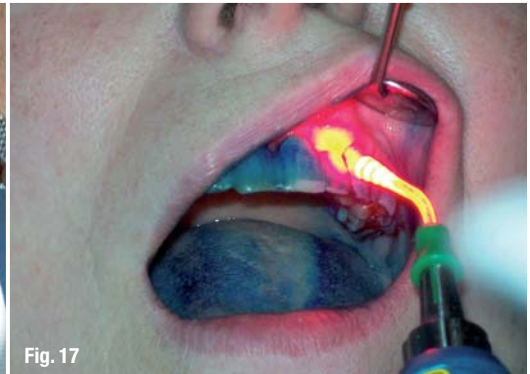

Fig. 17

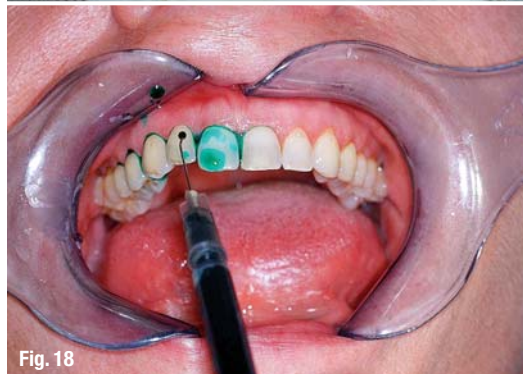

Fig. 18

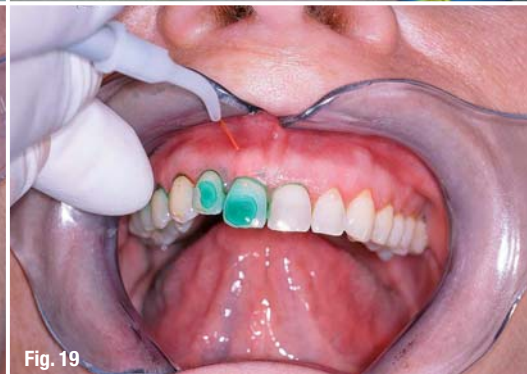

Fig. 19

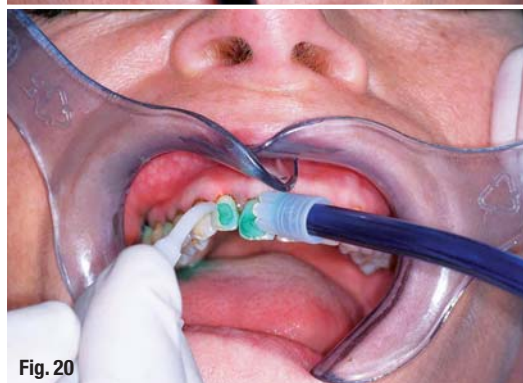

Fig. 20

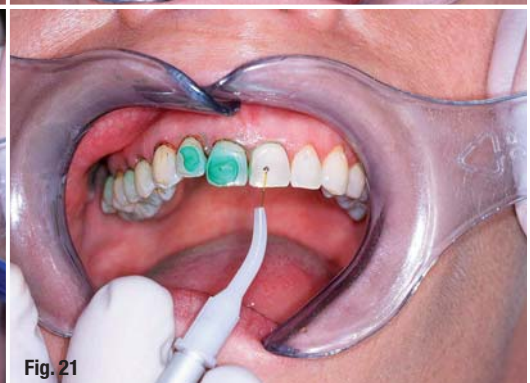

Fig. 21

**Case 4**

**Fig. 14**\_Injection of a surplus of TBO (Fotosan) in the periodontal pockets.

**Fig. 15**\_High transillumination in palatal laser application.

**Fig. 16**\_Laser light application in the mandible.

**Case 5**

**Fig. 17**\_PDT disinfection of the tissue surfaces after periodontal surgery.

**Case 6**

**Fig. 18**\_Application of ICG solution.

**Fig. 19**\_Transgingival laser application with bare fibre.

**Fig. 20**\_Laser application of the periodontal pockets with bulb fibre.

**Fig. 21**\_Removal of the inflamed pocket epithelium at 300 mW.

of bone defects induced by diphosphate. It can also be combined with surgery in the open operating site. A crucial side effect in laser therapy, however, is the stimulation of bone healing by photobiological effects of the laser radiation. Guzzardella et al.<sup>29</sup> have shown a significant effect on bone defect healing by laser light of a wavelength of 780 nm in their experiments. Laser irradiation resulted in bone growth twice or three times the amount as compared to conventional treatment. These findings have been confirmed by other studies<sup>30</sup>, which have also been published on red wavelengths of HeNe lasers of low performance.<sup>31,32</sup>

#### Endodontics

Various low-consistent sensitizers and long slim applicators are offered for the disinfection of the root canal. In addition to a possible discolouration of the root dentine, there is the danger of a lack in in-depth moistening of the dentinal tubuli, which would limit the effect on the prepared pulp cavity. The application of type-4 lasers must be considered with regard to safety as well as material and time saving.

#### Cariology (dentine hardening)

In cariology, PDT procedures for dentine hardening usually are time-dependent processes with blue colouring agents. Multiple applications are sensible and gen-

tle on the dentine, since carious dentine is disinfected and removed layer-by-layer. Disinfection of the occlusal fissures is another possibility. A pulpal increase in temperature in the photodynamic treatment of deep carious lesions results in a rise in temperature of 0,8 – 1°C after 30 seconds of irradiation.<sup>33</sup> While a blue colouring agent only permits a disinfection of the carious dentine, ICG can also result in dentine removal. ICG-based caries removal was examined by Rodrigues de Sant'anna et al.<sup>34</sup>, who proved significant removal on the hard tissue. McNally et al.<sup>35</sup> also describe erosive processes without any ruptures in the substance, whereas the temperature rise in the pulpal area of extracted teeth depends on the ICG concentration as well as the laser performance. Caries removal via ICG is more invasive and has hardly been examined to date. However, it suffices with one single application. It remains to be seen whether it poses a real alternative to Er:YAG and Er,Cr:YSGG lasers.

#### Skin und mucosa infections

Infections of mucosa or skin are a common oral or periodontal phenomenon, resulting from bacterial or viral infections. Here, PDT can be performed by the dentist as well as the dermatologist and other specialists. Zolfaghari et al.<sup>36</sup> have proved a photodynamic effect on Staph. aureus by the combination of methylene blue and laser light. In recent years, mycoses of the oral cav-

AD

**IDS  
2013**

Please visit us at:  
trade fair hall 10.1  
booth J030/K031

**elexxion AG**  
Dental Laser

**1. Bodensee-  
Laser-Symposium**  
7–8 June 2013 |  
Überlingen

Now that's  
something  
to get my  
teeth into.

**PERIO GREEN®**  
Periodontal therapy greenlighted

Perio Green® effectively destroys bacteria in biofilm, periodontal pockets and dental implants, using photodynamic therapy (PDT).

For more information: [www.periogreen.com](http://www.periogreen.com)



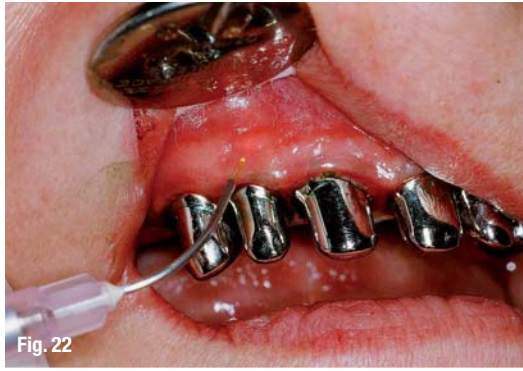

Fig. 22

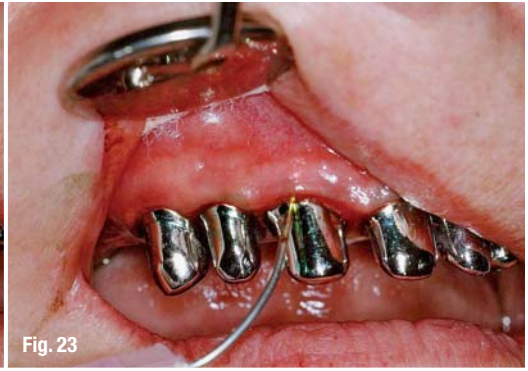

Fig. 23

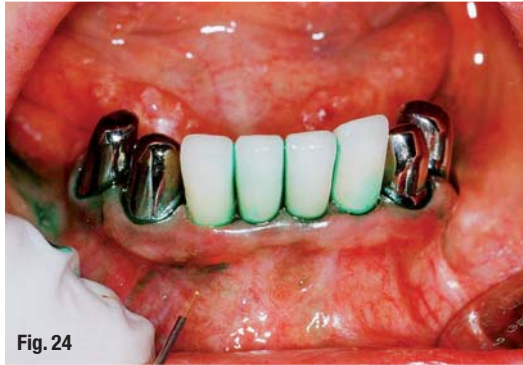

Fig. 24

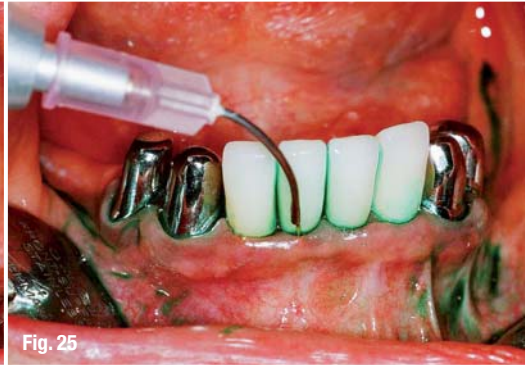

Fig. 25

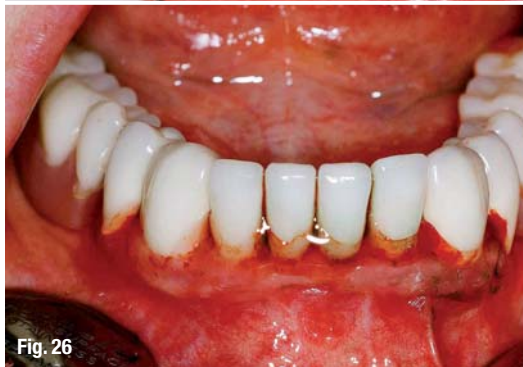

Fig. 26

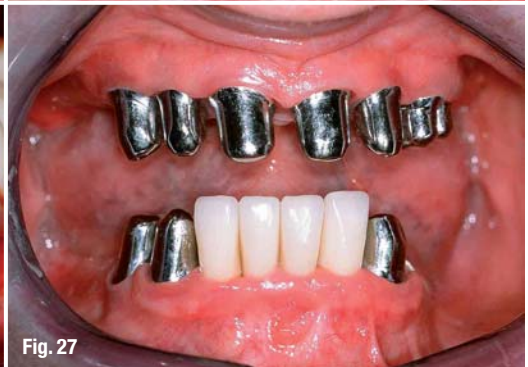

Fig. 27

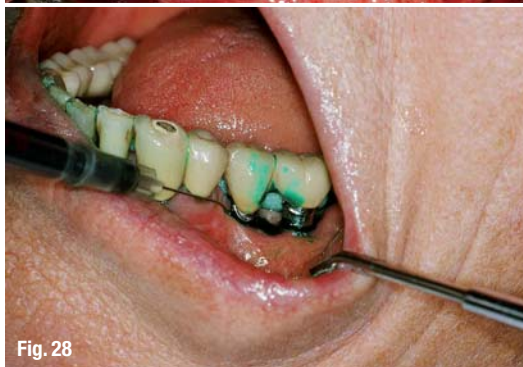

Fig. 28

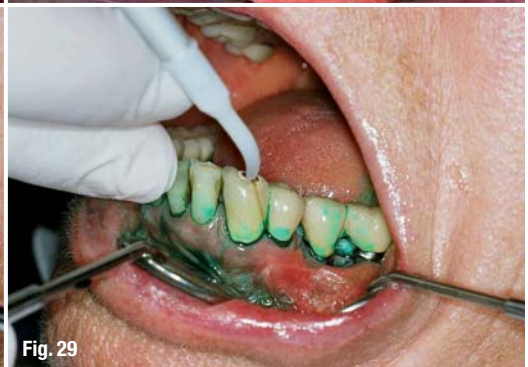

Fig. 29

**Case 7**

- Fig. 22**\_Transgingival laser application.
- Fig. 23**\_Laser application in the dental pockets with bulb fibre.
- Fig. 24**\_Application of the ICG solution in the periodontal pockets.
- Fig. 25**\_Intrasulcular laser application in the mandible.
- Fig. 26**\_PDT/PTT treatment.

- Fig. 27**\_Condition free from inflammation and swelling after two weeks.

**Case 8**

- Fig. 28**\_Insertion of the ICG colouring agent (EminDo, ARC).
- Fig. 29**\_Laser application with bulb fibre.
- Fig. 30**\_Healing of the acute episode after three weeks.

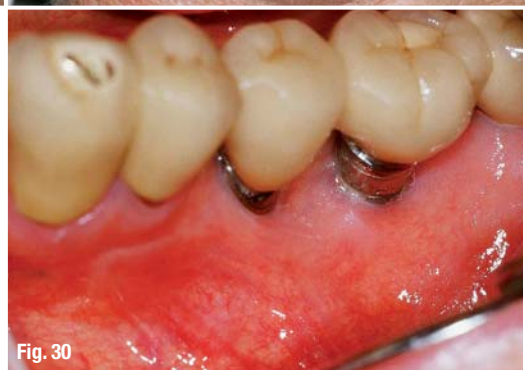

Fig. 30



ity have become a focal point of dental treatment. Here, photodynamic therapies are a new aspect in treating superficial mycotic infections. The target, which is the mycotic cell, as well as other microorganisms are eliminated, since the colouring agents are unspecific. In dermatology and mycotic therapy, activation via conventional or LED light systems have been favoured so far, since they are simple, reasonably priced and easy to apply on extensive surfaces. Malachite green, which is a triphenylmethan-based colouring agent activated at 810 nm, has been used against *Candida spp.*, whereas blue photosensitisers have been successfully applied in mycoses of mice in animal studies.<sup>37</sup> The colouring agent Green 2W, activated at 630 nm, has provided good results in an *in vitro* study on *Aspergillus fumigatus*.<sup>38</sup>

#### *Mucosa changes*

The selective treatment of malign or semi-malign mucosa changes is often bound to special photosensitisers which are activated by differing wavelengths. Porphyrin and its derivatives are often used for PDT in cancer cells. 5-aminolaevulinic acid (5-ALA) is applied in fluorescence diagnostics in urology, gynaecology and dermatology as well as in the therapy of malign degenerations, such as urethral carcinomas in their initial stage. Methylene blue is applied as well, but its low insertion depth of less than 20 µm minimizes its effect.

#### *Extended prophylaxis*

PDT can prove an effective measure for an extensive prophylaxis to maintain healthy, but reduced gingiva which is unresponsive to further treatment after periodontitis.<sup>8</sup> Generally speaking, low-level lasers are applied more and more by trained assistants, especially in the area of prophylaxis. If required, prophylaxis assistants can inform the patient on their own and perform the relevant tasks according to the therapy chosen by the dentist. In addition to an increase in treatment efficiency, delegating these tasks will result in a motivation boost for the assistant, who can now work more autonomously.

### **\_Photodynamic disinfection**

Photodynamic disinfection auf prosthetics and impressions has been investigated in experiments. Vlahova et al.<sup>39</sup> have tested various Phthalocyanine photosensitisers, activated with an LED light at 635 nm, with regard to their performance in disinfection of MRSA, *Staph. aeruginosa* and *C. albicans*. The disinfection of silicones and composites by Ga-Phthalocyanine was 100% and 40% in Alginates. Therefore, Phthalocyanine can be seen as an alternative to other, specialised disinfection methods.

#### *Veterinary Medicine*

In addition to human medicine and dentistry, veterinary medicine is another field in which photodynamic

therapies have proved to be successful treatment methods. Toth et al.<sup>40</sup> have given convincing results for the gentle treatment of infected extensive surface wounds, for instance eosinophil ulcerated dermatitis in horses.

### **\_Photosensitisers in dentistry**

In dental procedures, four photosensitisers are currently applied. These are indocyanine green and three kinds of phenothiazines: methylene blue, toluidine blue, methylene blue derivatives. Whereas the effect of these colouring agents on bacteria can vary, their charge—anionic or cationic—seems to play a vital role in their binding to bacteria (gram positive or negative), as do preparatory medications or trypsinisation.<sup>41</sup>

#### *1. Methylene blue*

Methylene blue (MB), 3,7-bis(Dimethylamino)-phenothiazin-5-ium chloride (Fig. 1), was synthesised by chemist Henrich Caro (BASF, Germany) in 1876. Already in 1885 did Paul Ehrlich realise its advantages with regard to selective colouring in histology. Methylene blue can be applied as a vital colouring agent in the vital staining of live tissues. In the past, it was seen as an important antidote in nitrite or aniline poisoning. Its application as an antiseptic, for example in malaria, enteritis and pyelitis cases, has become obsolete. Methylene blue today is used as an antirheumatic and as a means of diagnosis. It has been considered a treatment option for Alzheimer's disease for some time and several investigations were conducted. Its low toxicity makes it an unproblematic substance in medicine, which can be seen from its MAC (maximum workplace concentration) value of 1,180 mg/kg (rat, perorally). If larger quantities (0.5 ml and above) of methylene blue are swallowed, urine will assume a green colour.<sup>42</sup> Its absorption of max 661 nm makes this cationic colouring agent an ideal sensitiser for red laser applications.

#### *2. Toluidine blue O*

Toluidine blue O (TBO), also known as tolonium chloride (Fig. 2), is a blue colouring agent (3-amino-7-[dimethylamino]-2-methylphenothiazine) which is used for histological and intravital dyeing or as an antidote in methemoglobin generator poisonings. In dentistry and maxillofacial medicine, it is used as a test to differentiate between benign and malign precancerous leukoplakia. However, the specificity of this test is too low.

Similarly to methylene blue, toluidine blue has a low antiseptic effect. Its low toxicity renders it an unproblematic medical substance: its LD50 in rats when administered intraperitoneally is 215 mg kg<sup>-1</sup>. If larger quantities of toluidine blue O are swallowed, urine will assume a green colour. An absorption of max 635 nm makes this colouring agent ideal for red lasers of this wavelength.<sup>43</sup>

### 3. Methylene blue derivatives

Methylene blue derivatives are applied with wavelengths of 810 nm. There are only a few case descriptions in the literature. Balboaca et al.<sup>44</sup> have proved a shift in the activation wavelength to 810 nm in methylene blue derivatives. However, no exact description of the molecule applied in the Photolase system (Photolase Europe, Ltd., Hamburg), based on 810 nm lasers, was found. There was an attempt to explain the process by "changes in the colouring agent molecules based on phenothiazine causing a 'long-waved flank' which results in optical activation and irradiation of 810 nm". Since the necessary light dose can be achieved faster, treatment time is said to be shortened considerably. In addition, an increase in the output of reactive oxygen radicals (ROS) is said to result from the undiluted solution.<sup>45</sup> Other derivatives, such as New Methylene blue (NMB, 556416-1G; Sigma) can reduce the activation wavelength similarly to toluidine blue O.<sup>37</sup>

### 4. Indocyanine green

Indocyanine green (ICG, Fig. 3), 1,7-Bis(1,1-dimethyl-3-[4-sulfobutyl]-1H-benz[e]indol-2-yl)heptamethinium-betain-Na, well-known in liver function tests, ophthalmology and oncology<sup>46</sup>, is new in dentistry but seems promising for periodontology.

Indocyanine green is an anionic photosensitiser which is activated at 810 nm and leads to photo-oxidation. Here, the intra- and extracellular ICG concentration is vital and must comprise a temporal component.<sup>47</sup> Its absorption depends on the dissolving medium, bonds to the plasma proteins and its concentration.<sup>48</sup> The overall effect of indocyanine green consists of 20 per cent photodynamics (PDT) as well as fluorescence and, mainly, of its photothermal effect (PTT).<sup>49</sup> The thresholds in tissue coagulation are employed to make use of photothermal effects free from side effects in therapies of the ciliary body, which is a highly sensitive tissue.<sup>50</sup> For this, the dose-effect graph must be taken into account precisely. ICG in the form of sodium salt is combined with sodium iodide of up to 5% to improve solutions for medical treatment.<sup>51</sup> In dentistry, the material used is free from iodide (EmunDo, ARC) or contains normal quantities of iodide (PerioGreen, ellexion). There are no findings on how far material containing iodide can trigger allergies or anaphylactic reactions in dentistry. Most of the medical treatments consider an injection of ICG and its concentration in the target cells.

The photothermal effect of injected ICG has been applied in the therapy of telangiectatic leg veins in order to obliterate tissue changes subcutaneously in an elegant manner.<sup>52</sup> Laser energies of 100 – 110 J/cm<sup>2</sup> are applied. Mathematical Modelling and comparison with the results of scientific experiments, ICG concentration and laser performance can be optimised with regard to the tissue. Thus, excessive heating of the tissue can be

prevented.<sup>53</sup> The lethal but selective effect of ICG on bacteria is a well-established fact. While *Staphylococcus aureus* and *Strep. pyogenes* are eliminated by the photodynamic effect, *P. aeruginosa* remains intact. The energy density applied was 411 J/cm<sup>2</sup>. An effective concentration was reached already at 25 µg/ml.<sup>54</sup> ICG laser systems can advance acne treatments significantly in substituting or accompanying conventional therapies, since the agents applied did not show any serious side effects.<sup>55</sup>

Szeimies et al.<sup>56</sup> observed excellent effects in the treatment of AIDS-associated Kaposi sarcomas on the outer skin, resulting in an almost complete remission of the sarcomas. Laser welding of wounds as described by Khosroshahi et al.<sup>57</sup> can be performed with a relatively low energy, avoiding in-depth tissues by topically applied ICG. The future will show if this technique can be involved in welding neural tissue. An effective impact of ICG on squamous cancer of the oral mucosa was proved by Lim & Oh.<sup>58</sup> The percentage of apoptotic cells increased to 84 % six hours after ICG-PDT with 20 µM ICG. The percentage of dead cells rose to 65 % in three hours of applying a solution of 200 µM ICG. Contrarily to other studies, they activated ICG via LED of a wavelength of 785 nm. This procedure can advance minimally invasive cancer therapy in the oral cavity significantly. Urbanska et al.<sup>59</sup> observed a high effectiveness of ICG in the pre-treatment of melanoma cells which was five to ten times higher than the effects of conventional laser treatment with diode lasers of a wavelength of 700 – 800 nm. Experts are currently working on the implementation of polyurethane composites in the production of intravenous catheters, since the antimicrobial activity against gram-positive bacteria results in a reduction of 2 log<sub>10</sub> units, such as methicillin-resistant *Staphylococcus aureus* (MRSA) and *Staphylococcus epidermidis* after 15 minutes of exposure at an energy density of 31,83 J/cm<sup>2</sup>. Gram-negative bacteria (*Escherichia coli* and *Pseudomonas aeruginosa*) showed only little reaction under the same conditions: they were reduced by 0.5 log<sub>10</sub>-units.<sup>60</sup>

ICG is not resorbed by the intestinal mucosa, which is why the danger of uncontrolled swallowing of the material is non-existent. The metabolism of indocyanine green occurs microsomal in the liver and is excreted only via liver and the pancreatic ducts.<sup>61</sup> ICG is of a low toxicity. LD<sub>50</sub> values in animals were 60 mg/kg in mice and 87 mg/kg in rats.<sup>51</sup> Restrictions of the visual field with regard to the visual sense after intraocular ICG application have further enhanced the discussion about the toxicity of the material. Engel et al.<sup>49</sup> proved in cellular experiments that the material which disintegrates during photo oxidation obtains a cell-inhibiting effect caused by its fission and decomposition products. ICG is suitable for liver function diagnostics because of its complete metabolism and excretion by the liver. In

addition, it can help differentiate between a normal, healthy liver, liver dysfunctions and drug- or medicine related liver anomalies because of its specific clearance rate.<sup>62</sup> ICG which is administered intravenously has a half-life of three to four minutes, depending on the liver performance. During pregnancy, its administration is not risk-free. Only few allergic reactions on ICG containing iodine have been described in the literature.<sup>63</sup>

### Indocyanine green in dentistry

Only little published data is available on indocyanine green in dentistry, mostly *in vitro* studies, figures based on experience and case studies. Its application in periodontology has been postulated after successful *in vitro* tests with regard to periodontally pathogen germs by Boehm & Ciancio.<sup>64</sup> This however has not yet been proved by patient studies. More extensive studies are currently being conducted.

From the practitioner's point of view, the integration of PDT and ICG in aftercare and the long-term stabilisation of periodontitis/periimplantitis have proved of value.<sup>8</sup> Combined with ICG photosensitisers, low laser performance has a good effect on various bacteria of the biofilm as well as the periodontal pockets. Therefore,

it can be used in support of conventional mechanical methods.

McNally et al.<sup>35</sup> evaluate the reduced hardware in colourant-based laser ablation of carious enamel and dentine as an advantage over Er:YAG lasers. In this regard, advantages postulated with respect to heat development, in-depth irradiation, pulpal damage, consumption of consumables and time must be discussed critically, even if the authors conclude that the dentine treated has no fissures and shows hardness similar to healthy material. With regard to the colouring agent, it can be argued that, in addition to various chemical properties, a differing quality and highly varying concentration of active substances are currently being offered. Figure 4 gives a split-mouth depiction of MB (Helbo) and TBO (Cumdente) photosensitisers. Some manufacturers do not declare the concentration of active substances in their colouring agents. The consistency of the solution has to match its application. Low consistencies are recommended for areas which are hard to moisten, such as root canals, while high viscosities are more appropriate for surface defects or areas of a long retention time such as the periodontal pockets. Each package is of a different user-friendliness and applicability. While blue dyes are provided in a dissolved form for direct application, the crystalline ICG has to be

# Dental diode laser system

## Dentist's Good Assistant!



CHEESE™ 4/7/10W

GBOX™ 15W

- 810nm, 940nm, 980nm for choice
- All dental soft tissue treatments
- Small size and handheld System
- User-friendly interface
- Customized programs
- Full accessories
- Golden service with high level technical support

[www.gigalaser.com](http://www.gigalaser.com)

Tel: +86 27 67848871 Fax: +86 27 67848873



**GIGAA**  
**LASER**



dissolved in a puncture vial first. The reason for this is its short shelf life of roughly four hours.<sup>48</sup>

Since photosensitisers are designed for one application (ICG) or one patient and thus are of a short shelf life (blue colouring agents), the packing quantities are decisive. Packages of 0.5 to 1 ml are optimal, while quantities of more than 1 ml are too large and result in a high proportion of waste and high costs. In addition, prices differ significantly between the various providers and active ingredients.

### Photoactivation

Light sources based on laser, LED or plasma lamps are appropriate for photoactivation. Conversely, the physical and therapeutical differences resulting from the variation in light sources are hardly known. Clinically, there are no differences in the results of identical procedures, wavelengths and powers of the light sources. There are no experiments with regard to the possible differences of the photobiological effects on healing and stimulation of the tissues in the various light sources (laser or LED). It seemed more important to find out about optical fibres and applicators appropriate to lead the light to its site of action effectively and without loss. For this, the material of the optical fibre as well as the quality of the optical coupling points play an important role, as they decide about power losses and, finally, the price. From a hygienic point of view, disposable applicators are preferable to permanent fibres.

In intrasulcular applications, the laser light reaches the colouring agent immediately and thus is applied directly to its site of action. A small percentage of the light is emitted to the depths where it can trigger photobiological effects. Mucosal thickness, blood circulation, mucosal pigmentation, absorption in the tissue, light parameters, remains of blood, secretions and colouring agents as well as absorption variations during treatment influence transgingival irradiation. It remains to be discussed whether the concentration of the sensitizer and exposure time are corresponding with the irradiation parameters and whether the graphs of the action time are extrapolated with regard to unfavourable anatomic cases. Light plays a vital role in the photobiological effect. Fotosan (LOSER & CO, Leverkusen, Germany) is a system which works exclusively transgingivally. Due to the many still unknown components, the current trend is directed towards intrasulcular light applications or combined intrasulcular transgingival applications.

### Clinical cases

Therapies based on blue colouring agents are relatively simple. The sensitizer is applied to the periodontal pocket which must be free from bleeding after dis-

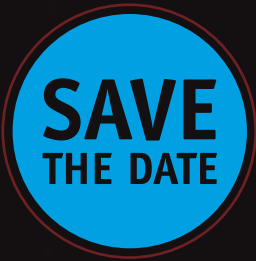infection. It is then put to effect by diffusion for a consistent colouration of the aquatic space and is finally activated by laser. Most of these systems work with applicators which are injected in the periodontal pocket. Transgingival activation has become more and more prominent, in which case laser parameters must be in accordance with anatomical and physiological properties.

#### *Case 1: Consecutive periodontitis therapy*

In the following case, a 49-year-old female patient is treated by the PDT system HELBO (Bredent, Senden, Germany). During her regular dental cleaning, a new periodontal episode was noted after a successful laser periodontitis treatment four years earlier. The system used for this periodontal treatment included the TheraLite laser (660 nm, 100 mW), HELBO® 3-D pocket probe and the light absorbing colouring agents HELBO® Blue Photosensitizer (methylene blue). A time controller was used for an easy and controllable application of dye exposure and application times of the laser light on the treatment site. aPDT should succeed the professional dental cleansing after three to 14 days with respect to the degree of inflammation and latent bleeding tendency. A bleeding sulcus might have a reductive effect on the colouring agent penetration into the pockets and thus on the final treatment result. However, immediate treatment is still an option. Treatment starts with the application of the colouring agent solution (Fig. 5) circular around the teeth. The distribution of the intensely blue colouring agent can be well controlled. Exposure time is a minimum of three minutes, since this step is determined by diffusion and the molecules of the colouring agent penetrate into the biofilm, where they adsorb unspecifically and specifically to the bacteria via forces of attraction caused by electric charges. After the exposure, the colouring agent is sprayed off (Fig. 6) and the periodontal pockets are rinsed in order to avoid an unnecessary absorption loss of the laser light in the free colouring agents. All steps of the procedure which depend on time are paced by the time controller (Fig. 7). The tapered fibre applicator of the activated laser can be injected easily in the pockets and the activation energy (laser light) can be applied (Fig. 8). Depending on the individual tooth, four to six points of the pockets are irradiated. The treatment success was monitored after about three weeks, which showed a reduction in the depth of the periodontal pockets of a minimum of three millimetres (Fig. 9). In severe and therapy-resistant cases, treatment can be repeated on a weekly basis.

#### *Case 2: Periimplantitis therapy in the acute phase*

An acute periimplant inflammation can be a dramatic experience for the patient and a challenge for his dentist. Inflammation, bleeding, pain, pocket formation and loss of the periimplant attachment defined the clinical picture of the 56-year old female pa-



NOVEMBER 15-16,  
2013// BERLIN,  
GERMANY//MARITIM HOTEL

# LASER START UP 2013



# 22nd ANNUAL CONGRESS OF THE DGL e.V.

**SCAN MICH**



impressions  
DGL // LASER  
START UP 2013

Scan QR-Code with  
your Smartphone  
(Quick Scan, etc.)

**PLEASE FAX THIS FORM**

+49 341 48474-390

Further information about:

- LASER START UP 2013
- 22nd ANNUAL CONGRESS OF THE DGL e.V

November 15-16, 2013, Berlin, Germany

NAME/E-MAIL

OFFICE STAMP





tient (Fig. 10) who presented 10 years post-op with iliac crest bone which was applied via onlay procedure after resorption. Probing depth (Fig. 11) and radiological bone loss are decisive parameters of the diagnosis. In order to assess the severity of the damage and treatment options, the CIST system by Lang et al.<sup>65</sup> is an appropriate measure. The overall treatment procedure is conducted according to protocol: rinsing of the periodontal pockets, injection of the colouring agents (Fig. 12) and laser application according to the perimeters for single-rooted teeth for 20 seconds in all four sites (Fig. 13). Here, the applicator is placed on the base of the pockets. After laser treatment, the pockets are rinsed and then dried to instill the CHX gel (Fig. 14) and insert the prosthesis. This procedure is repeated weekly. Home care includes cleansing of the prosthesis and reciprocal instillation of CHX gel and Durimplant. After only a short amount of time, an inflammation-free result was reached (Fig. 15).

#### *Case 3: Osteonecrosis treatment after bisphosphonate therapy*

The dramatic event of multiple osteonecrosis of the maxilla occurred in a 86-year-old male patient after long-term bisphosphonate therapy. Bisphosphonates have been administered for more than 20 years in multiple myelomas (plasmacytoma), mammary carcinoma, kidney tumours, prostate carcinoma, osteoporosis and rheumatism. In this case, a multiple myeloma was diagnosed, but it was not confirmed later. The initial OPG of the patient (Fig. 16) showed a remaining dentition in the maxilla, teeth 17, 22, were situated in the devitalised bone and had to be removed. Markers of the devitalised bone are the lack in bleeding and hardly any resistance against extraction due to the destruction of the periodontium. A surgical revision of the maxilla was conducted INT with loss of the alveolar ridge and the maxillary sinus. After healing, the maxilla was fitted with a telescope obturator prosthesis (Fig. 17). Resulting from the following osteonecrosis episode, tooth 21 was lost and left an persisting ulcerating defect in regio 22/23 (Fig. 18). After deciding against another surgical therapy, a conservative long-term treatment via PDT was preferred over highly dosed antibiotics. Upon pus removal and rinsing, the entrance to an inflamed bone cavity with surrounding, highly reactive granulation became visible (Fig. 19). Blue Sensitiser (HELBO) was applied (Fig. 20) and left to take effect over a relatively long amount of time of roughly ten minutes. The remains of the colouring agent were rinsed (Fig. 21) and laser application (TeraLite laser, Fig. 22) followed. After several PDT applications during the following two weeks and the reduction of inflammatory complications, exposed bone became visible. This was removed as a bone sequestrum from an almost completely epithelialized bone cavity (Fig. 23). The defect was again lased via PDT (Fig. 24) and then healed autonomously

(Fig. 25). Even three years later, an irritation-free alveolar ridge without any signs of a relapse was diagnosed (Fig. 26).

#### *Case 4: Transgingival periodontitis treatment*

A 68-year-old female patient presented with dentures in urgent need for restoration. Periodontal treatment was conducted in the form of PDT with TBO in the transgingival activation mode via the FotoSan system. The special feature of this device is the light source with a 15-Watts LED. Photosensitiser was inserted in the dental pockets after disinfection (Fig. 27) and left to take effect. The surplus of photosensitiser was removed before laser application. Since only a shortened row of teeth existed, including the second premolars, the photosensitiser was applied in one step at all teeth. The laminar applicator of the device is placed directly on the mucosa. The light is applied segmentally and tooth-by-tooth for activation. Figures 28 and 29 show the high transillumination of the tissue, which is why there is sufficient activation energy for the photosensitiser within the pockets. After irradiation, the remains of the sensitiser are sprayed of and CHX gel is placed in the pockets.

#### *Case 5: Photodynamic Post treatment after periodontal surgery*

In the days following a surgical periodontal procedure, oral hygiene is limited. Pain, swelling, tendency towards bleeding and the danger of damage to the soft tissue structures are significant restraints to mechanical cleansing. Some regenerative and augmentative procedures, such as the application of enamel matrix proteins (Emdogain, Straumann) requires only chemical cleaning via a disinfecting rinsing in the first few days after surgery. An efficient bactericidal method without any mechanical intervention is the application of PDT on the surfaces of mucosa, teeth and interdentially. Already in the year 2000 did Frentzen et al.<sup>66</sup> point out the possibility of a "laser tooth brush". This principle was applied successfully in the following case of a female patient with progressed aggressive periodontitis after surgical periodontal treatment via Emdogain. At the first follow-up two days after surgery, the postoperative condition corresponded with the healing process and a photodynamic cleaning of the teeth was conducted. Figure 30 depicts the activation of the blue colouring agent with a laser by R+J (Berlin, Germany) and a therapeutic approach which allows light application on the surface.

#### *Case 6: Treatment of chronic periodontitis*

A 46-year-old patient presented with chronic periodontitis caused by insufficient care. Bone loss and crater-like irruptions became visible in the OPG. After cleaning the tooth necks (SRP), a combined PDT and PTT treatment was conducted in a separate session. Superficial anaesthesia with Oraqix is sufficient for light cases of periodontitis. After rinsing the pockets with physio-

logical saline, an ICG solution (EmuDo, ARC) is applied and the first laser application is performed transgingivally with bare fibre (400 mW, 810 nm, Q 810, Henry Schein, Germany) for ten seconds per periodontal unit from vestibular to palatal/lingual. Alternatively to bare fibres, the therapy, transgingival or bleaching hand piece can be used. The second step consists of laser application at and in the dental pockets with bulb fibres and, depending on the condition of the mucosa, with 200 up to 300 mW. Depending on size and undercut, eight to twelve seconds of irradiation are estimated time frames. Constant movement is necessary since the photothermal effect is significant already in low powers and excessive burns must be avoided. The inflamed inner epithelium of the periodontal pocket can only be removed efficiently with a power of 300 mW. The same procedure is conducted via a palatal approach. Because of the therapeutic character of the minimally invasive approach, the same principles that are applied to operative laser-surgical procedures are adopted to PDT/PTT with extended hygienic demands. For example, protective glasses have to be worn in any applications of type-4 lasers of a wavelength of 810 nm. When the PDT/PTT treatment is finished, the sulcus is rinsed and the treatment result will show that a minimally invasive procedure was performed. After treating all five quadrants, and after the periodontium has finished healing, only slight discolourations by the CHX rinsing solution were visible after four weeks. The development of the clinical parameters and the pocket depths indicate good final results.

#### *Case 7: Acute gingivitis/periodontitis treatment*

Other than PDT with blue colouring agents, which can be applied without any tissue damage, ICG-based methods allow the selective removal of the inner epithelia of the periodontal pocket from the sulcus at 300 mW and via bulb fibre. This is usually the standard in photothermal therapy (PTT).

The 64-year-old female patient presented with an acute inflamed periodontitis episode and a massive mycotic infection by *Candida albicans* (CFU ++++) in the oral cavity and on the lips five years after restoration of the dentures. The mycosis was treated with a combination of Amphotericin B and Miconazol. The periodontal treatment was conducted after surface anaesthesia with Oraqix by successive mechanical cleansing followed by PDT/PTT. Laser application was conducted with the Q810 laser (Henry Schein) with universal fibre and disposable bare and bulb fibre attachments. After rinsing and application of the EmunDo photosensitizer, transgingival laser application with the bare fibre at 400 mW was performed. Afterwards, the periodontal pockets were lasered with bulb fibre at 300 mW according to protocol. A light de-epithelialisation of the marginal periodontium at 400 mW and rinsing ensued. Since only anterior dentures have remained, this case is

treated jaw-by-jaw and not quadrant-by-quadrant. After rising, the ICG solution is inserted in the periodontal pockets of the mandible. In addition, transgingival and intrasulcular laser application and de-epithelialisation are conducted. Finally, CHX gel is applied to the pockets and the cone prosthesis as a reservoir. Only shortly after PTT, the patient appears free from inflammation and swelling. The periodontal pockets depths showed convincing results and there are no periodontal inflammations when the prosthesis is worn. Bleeding cannot be provoked.

#### *Case 8: Therapy of advanced periimplantitis*

A 79-year-old patient presented with advanced periimplantitis. In agreement with the patient, conservative, non-invasive maintenance measures are taken, preferably without any antibiotics. Home care involves mechanical tooth cleaning, rinsing for disinfection, instillation of CHX gel in the periimplant sulcus and Durimplant application. Advanced bone loss became visible on the X-ray and was proved by the measured pocket depths. There was neither block nor infiltration anaesthesia, but an intrasulcular surface anaesthesia via Oraqix. After careful cleansing, the ICG photosensitizer (EmunDo, ARC) is inserted and activated transgingivally via bare fibre at 400 mW and 810 nm (Q810, Henry Schein) as well as bulb fibre at 300 mW. A single treatment already resulted in immediate remission of the inflammation. A stable condition was achieved after healing. However, this success should not blind us to the fact that this is only a symptomatic treatment which hardly contributes to the formation of new bone and must be evaluated clinically as a dormant state of periimplantitis.

### **\_Economic aspects of PDT application**

From an economic point of view, PDT methods are more costly than laser treatments exclusively with type-4 lasers, due to the fact the colouring agents (photosensitizers) and sometimes disposable applicators have to be used. Therefore, possible applications have to be examined with regard to more efficient methods which can be used instead of photodynamic caries hardening, which has to be repeated on consecutive treatment days. Periodontal treatment of singular teeth which is based solely on laser or selective caries removal via Er:YAG laser is one possible alternative.

### **\_Conclusion**

The integration of PDT has proved itself in the treatment and post-treatment with long-term stabilisation of periodontitis/periimplantitis.<sup>8</sup> Low laser power combined with photosensitizers on various bacteria of the biofilm and in the periodontal pocket showed good results and can therefore be used in addition to conventional mechanical cleansing. Thus, PDT can already

be found in a compilation of evidence-based laser-supported treatment methods.<sup>67</sup>

All light-activated procedures have been viewed as comparable to PDT treatment and were said to differ only in their colouring agents, their intrinsic effect and the wavelength used for activation. This assessment, however, cannot be supported when the real modes of action are taken in consideration. Because of the good adhesiveness of the colouring agents, depending on exposure time, photodynamic therapies with blue colouring agents encompass a photodynamic effect as well as solely disinfecting properties of the dyes along with an efficacy which exceeds the treatment. There is however no intrinsic disinfecting effect in photodynamic therapies based on indocyanine green. The therapeutical effect is limited to the treatment time, which is the amount of time in which the colouring agent is activated by laser. This effect consists of photodynamics (PDT) with a percentage of 20 %, fluorescence and, mainly, photothermal effects (PTT).<sup>49</sup> These components of the therapeutical effect explain the limited destruction of the pocket epithelium and minimised bleeding. Another sensible application of the wavelength of 810 nm was added when ICG was introduced. In both of the two applications, a strict protocol which includes the abidance to the exposure and activation times of the colouring agents as well as rinsing and drying procedures and the level of laser energy applied is vital. While an extension of the activation time does not result in tissue damages in PDT based on methylene or toluidine blue, the specified treatment time must not exceed in ICG. Moreover, the intrinsic effect of the photosensitiser seems to be a philosophical problem, since the treatment success does not depend on the question if the effect of the photosensitiser occurs when activated or without activation. Both PDT and combined PDT/PTT are gentle, yet efficient therapy methods for acute and chronic periodontal and periimplant defects. A separation between PDT und treatments with extensive bleeding are recommended, since the colouring agent could be rinsed or diluted in an invalid level by the bleeding. In addition, binding to plasma proteins or blood cells can also minimize the effect of the photosensitisers. PDT and PDT/PTT have increased the range of treatment modalities for bisphosphonate-reduced necrosis of the jaw and a multitude of infections. Economic aspects have to be taken into account in PDT or PDT/PTT application in single teeth, endodontics, caries hardening, and disinfection of the surgical site, among others. Because of the high efficiency of PTT when ICG is applied, a singular therapy per cycle will be sufficient, whereas phenothiazine-based colouring agents will necessitate the repetition of the treatment within short intervals. Both of the two procedures cannot necessarily substitute antibiotics, but they can contribute significantly to reduced antibiotic applications. The bacterial load in the periodontal pockets can be reduced consid-

erably, which is an advantage with regard to sluicing bacteria in immediately following periodontal surgeries. ICG is more efficient because of its proved in-depth effects which include PTT effects on microorganisms in bordering tissues. PTT is followed by healing of the defect in case of laser light applications beyond a threshold level causing tissue damages. This healing usually processes fast and does not cause retractions since the defect is limited in size.

PDT and combined PDT/PTT cannot be compared with or replace each other. Although both of the two procedures can be applied equally, the wishes of patient and dentist as well as therapy goals determine their usage. PDT alone cannot be applied in non-invasive delegation procedures, the treatment of tissue defects or pain-free conservational therapies. A maximum power of 0.2 Watts must not be exceeded in ICG-based therapies. Further investigations with regard to these treatment areas are necessary. If the treatment can be of an invasive character or more extensive, combined PDT/PTT treatment must be preferred. In most cases, this will be performed by the dentist. Combined PDT/PTT indocyanine-green based treatment constitutes a new instrument for the dentist, which offers laser treatment at low laser energy levels of 200 up to 400 mW as well as a low photodynamic component for the sterilisation of periodontal pockets via oxygen radicals and a photobiological component to support the healing process. Therefore, PTT can result in an improved performance in modified mechanisms of action in periodontal treatment when compared to blue-based PDT procedures.

*Editorial note: A complete list of references is available from the publisher.*

## \_contact

## laser

### Dr Michael Hopp

Zahnarztpraxis am Kranoldplatz  
Kranoldplatz 5  
12209 Berlin-Lichterfelde, Germany

mdr.hopp@t-online.de  
www.dr-michael-hopp.de

### Prof. Dr Reiner Biffar

Ernst-Moritz-Arndt-Universität Greifswald  
Zentrum für Zahn-, Mund- und Kieferheilkunde  
Abteilung für Zahnärztliche Prothetik und  
Werkstoffkunde  
Direktor: Professor Dr. Reiner Biffar  
Rotgerberstraße 8  
17489 Greifswald, Germany

Tel.: +49 3834 865000  
biffar@uni-greifswald.de



Scan for the German version of this article, including a more extensive image gallery.



# Becoming kissable: Laser-assisted haemangioma removal

Author\_Dr Darius Moghtader, Germany

(PICTURE: ©DIEGO CERVO)

**Figs. 1a & b**\_ Treatment example with the 980 nm diode laser at 2.5 W (continuous wave);  
(a) Typical presentation of a haemangioma;  
(b) Six weeks after the third session.

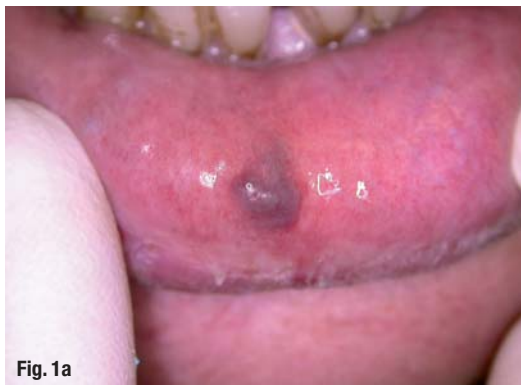

Fig. 1a

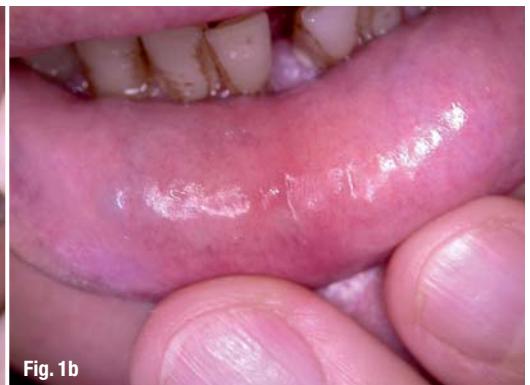

Fig. 1b

## \_Introduction

This is the story of how an attractive young woman became kissable once again, thanks to laser therapy.

There are a surprisingly high number of patients with growths mostly in the area of the lip vermillion, and virtually every person affected by this condition reports suffering under it. Strangely, we dentists are hardly ever asked by patients what these growths could be or how they can be treated. The reasons for this will be discussed later on in this article—I can certainly promise that it will be worth your while to read on.

The lesion has a bluish colour, occurs in differing sizes and especially on the lip, but also on the mucosa of the cheek or on the tongue and—as you al-

ready guessed—goes by the name of haemangioma. Haemangiomas are benign blood-vessel tumours that are usually prominent and localised, and range from crimson to greyish-blue in colour. The blood filling can often be pressed out (spatula test).

In this article, I will discuss the various non-invasive, minimally invasive and invasive laser treatment methods for haemangiomas and how a rather rare exophytic haemangioma can be treated quickly, painlessly and aesthetically.

## \_The proper addressee

We should first address the interesting issue of why dentists are rarely asked about treatment options for these unsightly lip spots. The answer is as simple as it is surprising: the patients have already asked someone else: their GP. Generally their fam-



## The methods— From non-invasive to invasive

### *Non-invasive therapy*

First, let's talk about the non-invasive haemangioma therapy developed by the laser pioneer, Prof. Georgios E. Romanos. The haemangioma is treated by means of a contact-free diode laser through a very thin ice wafer. The cooling effect of the ice preserves the texture of the lip.

Place an extremely thin ice wafer on the vascular tumour (Fig. 1a) and, after administering local anaesthetic, irradiate the tumour through the ice using the preset haemangioma programme of the ellexion claros or 2.5 W (continuous wave) until coagulation is achieved. As the ice wafer melts, the laser must constantly be moved in order to prevent direct contact between laser and tissue.

The blue spot shrinks and success of the therapy is evident by the greyish-white colour of the tissue. The constant cooling protects the surface of the tissue, and the lip structure is fully preserved. As a rule, this therapy must be repeated several times until the haemangioma has been completely eliminated (Fig. 1b).

ily doctor, or perhaps their dermatologist, or another doctor who does not normally work with lasers will, correctly, tell the patient that it is a benign tumour and that he or she would recommend leaving it well alone, as removal can lead to copious bleeding and potentially to ugly and disfiguring scars after removal of the sutures. And of course, the doctor is right. It is better to leave the scalpel alone and refer the patient to a specialised colleague, who ideally also has experience in plastic surgery, or even better to a laser specialist!

If this last description applies to you anyway, first obtain the patient's informed consent, then furnish the patient with a quotation and—after the statutorily prescribed reflection period—perform the treatment using your diode laser in less than five minutes. The next section will detail this method and other more invasive methods.

Romanos originally described this procedure in the Atlas of Laser Applications in Dentistry<sup>1</sup> with reference to the Nd:YAG laser, which is the ideal wavelength for this method owing to its greater depth of penetration compared with the diode laser.

How does it work? Laser light of the above-mentioned wavelengths has a high selective absorption in haemoglobin and in certain pigments. This results in energy bundling in the tumour tissue and leads to coagulation and destruction of the vascular tumour.

What laser types are suitable? Lasers with a greater depth of penetration and high haemoglobin absorption are more advantageous for this application: argon, Nd:YAG, 980 nm diode and 810 nm diode lasers.

**Figs. 2a–d** Minimally invasive therapy (Photographs courtesy of Dr Bach).

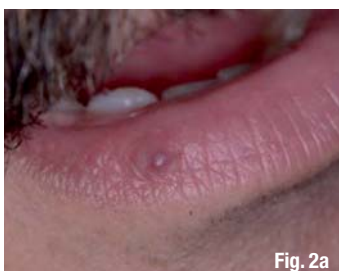

Fig. 2a

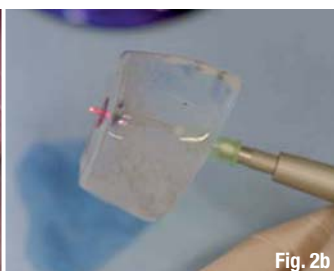


Fig. 2b

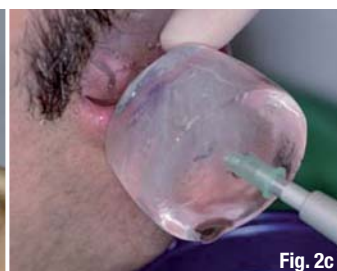

Fig. 2c

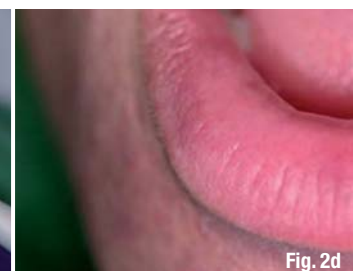
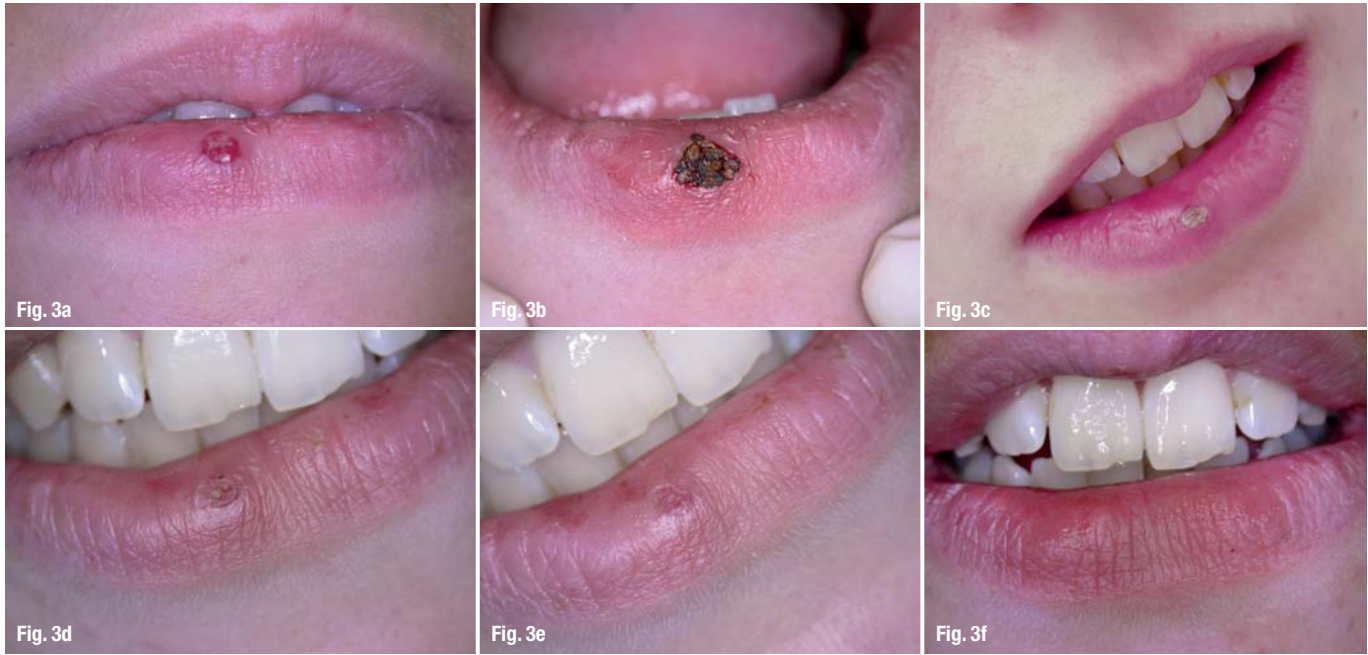

Fig. 2d



**Figs. 3a–f** (a & b) Invasive therapy, (c) one, (d) two, (e) six and (f) twelve weeks post-op.

*Minimally invasive therapy*

In Laser (German edition), Dr Georg Bach<sup>2</sup> presented a modified method to optimise this procedure for the 810 nm diode laser. With the new method, the haemangioma is treated directly and in a minimally invasive manner (Fig. 2a) using a cannula embedded in an ice block (Figs. 2b & c). The advantages of this method are good results while protecting the lip structure by means of cooling with ice, as well as the possibility of completing the treatment in just one session (Fig. 2d).

*Invasive therapy*

This female patient consulted me about her lip problem. She told me how unhappy she was that she was no longer being kissed because of the growth on her lip. Her lip texture and structure had been affected (Fig. 3a). In this case, invasive therapy was able to provide a good aesthetic result for the exophytic haemangioma on her lip.

After administration of local anaesthetic, one-time, direct, contact-free irradiation was performed with the preset haemangioma programme of the elxxion claros with the 600 µm fibre up to complete coagulation (Fig. 3b). In this programme, the elxxion claros operates at 25 W high peak power with pulses of 15,000 Hz and a duration of 10 µs and an average output of 3.75 W.

After one week (Fig. 3c), we saw wound healing without any complications. At every follow-up visit, the elxxion claros was applied using the low-level laser programme for one minute at 100 mW with the glass rod in order to optimise wound healing. A distinct improvement in the sit-

uation was seen after just two weeks (Fig. 3d). Slow and constant self-optimisation was observed in the further wound-healing process after six weeks (Fig. 3e) up to the desired final result at the end of 12 weeks (Fig. 3f).

If one has performed the treatment correctly, there will be no bleeding, and the patient will have no pain or discomfort. Only two weeks later, this patient was kissable once again as she reported with a big smile on her lips.

This case report has demonstrated that invasive laser therapy can, in selected indications, lead to good aesthetic results with exophytic haemangiomas of the lip quickly, safely and efficiently.

*Editorial note: A complete list of references is available from the publisher.*

_contact	laser
<p><b>Dr Darius Moghtader</b>                  In den Weingärten 47                  55276 Oppenheim                  Germany</p> <p>dr-moghtader@hotmail.de                  www.oppenheim-zahnarzt.de</p>	



# 1<sup>st</sup> International Congress of WALED and GLOBAL

June 14-15, 2013

Istanbul, Turkey, Point Hotel Taksim

Fees: 250 EUR, inclusive full day catering and 2 evening events

Congress Presidents: Prof Norbert Gutknecht, Dr Zafer Kazak

**Enjoy dental science and fun in Istanbul!**

Copyright © Sadik Gulec

More Information: [info@aalz.de](mailto:info@aalz.de)

## Preliminary List of Speakers:

Prof Norbert Gutknecht  
Ass.-Prof Ilay Maden  
Dr Miguel Martins  
Dr Stefan Grümer  
Dr Dimitris Strakas

Prof Aslihan Üsümez  
Ass.-Prof Jörg Meister  
Dr Peter Fahlstedt  
Dr René Franzen  
Dr Gabriele Schindler-Hultzs

Prof Matthias Frentzen  
Dr Iris Brader  
Dr Zafer Kazak  
Dr Nasrin Kianimanesh

Prof Gerd Volland  
Dr Masoud Mojahedi  
Dr Merita Bardoshi  
Dr Alireza Fallah

# Er:YAG Garnet in laser-assisted crown lengthening

Author\_Dr Avi Reyhanian, Israel

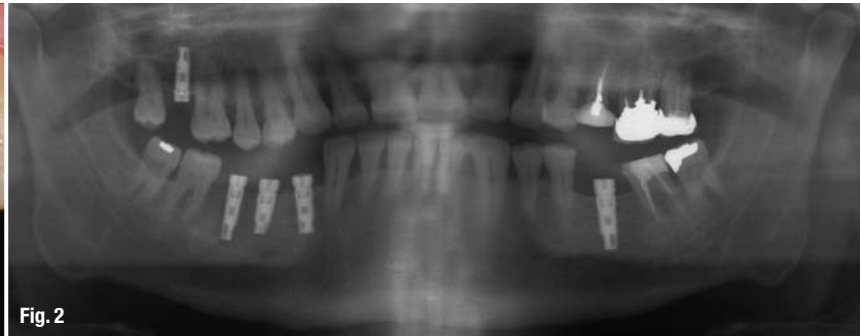
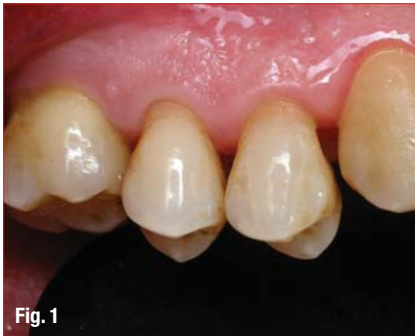
Fig. 1\_Patient presentation.  
Fig. 2\_Insertion of five implants.

## \_Introduction

This article describes and demonstrates the use of the Erbium:YAG 2,940nm laser system (Lite-Touch, Syneron Medical Ltd.) as a central tool in the treatment of osseous crown lengthening, and the advantages this wavelength offers versus the use of conventional methods.

## \_Objectives and methods

Crown lengthening is a surgical procedure employed for the removal of periodontal tissue, in order to increase the clinical crown height. It is the

most frequently used and valuable periodontal surgical procedure related to restorative treatment.<sup>1-4</sup>

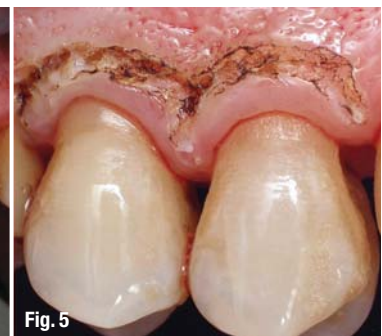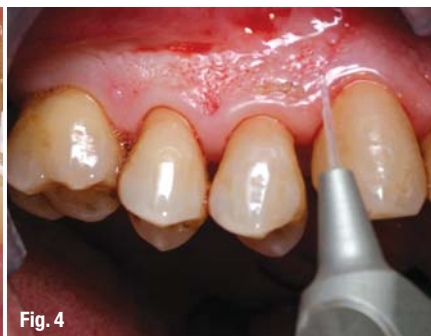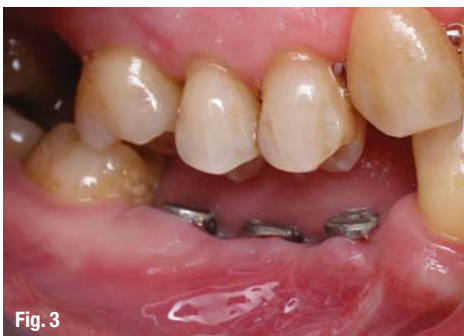*The objectives of clinical crown lengthening include*

- Removal of subgingival caries
- Preservation and maintenance of restorations
- Cosmetic improvement
- Enabling restorative treatment without impinging on biologic width
- Correction of the occlusal plane
- Facilitation of improved oral hygiene

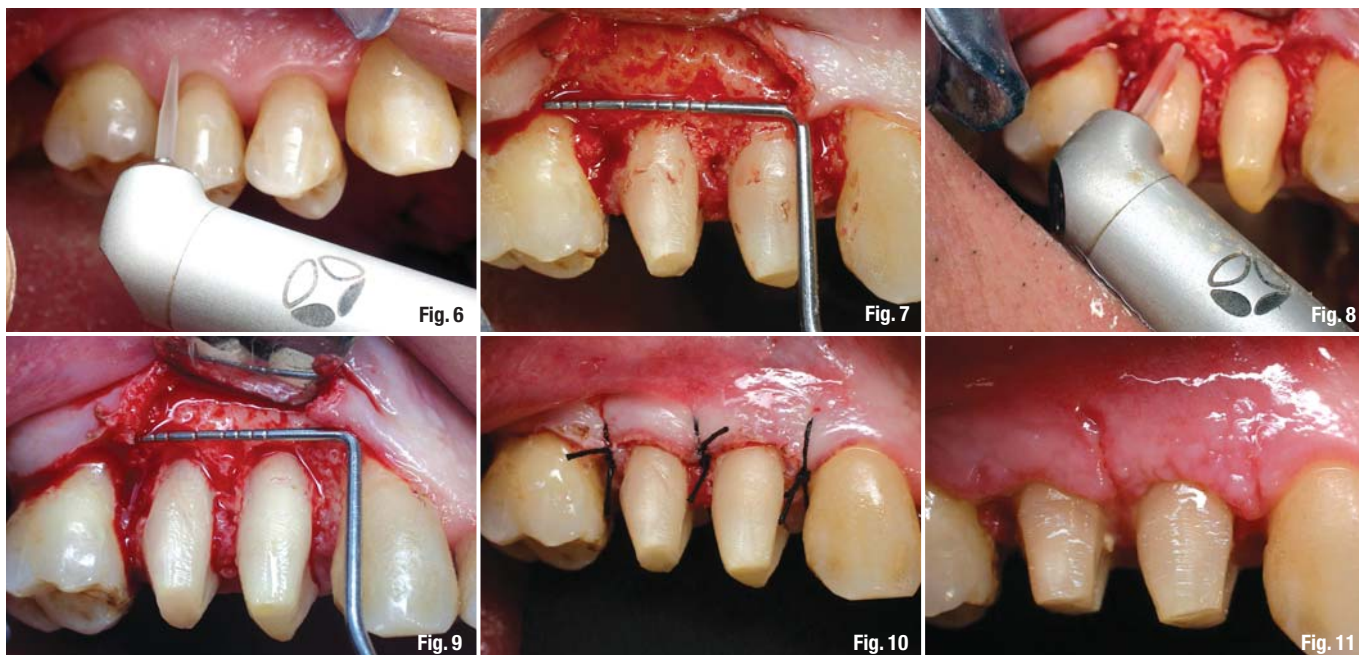
Fig. 3\_Teeth #14 and 15 in occlusion.

Fig. 4\_Use of the diode laser to mark the border for incision of the soft tissue.

Fig. 5\_Incision border.







There are two methods of crown lengthening:

- Orthodontic—coronal extension
- Surgical—apical extension.

#### Clinical considerations

- Importance of the tooth
- Subgingival caries
- Clinical crown/root ratio
- Root length and morphology
- Residual amount of bone support
- Furcation involvement
- Tooth mobility
- Aesthetic demands
- Post-op maintenance and plaque control.

#### Biologic width and aesthetic dentistry

The clinician must create a symmetrical and harmonious relationship between lips, gingival architecture and positions of the natural dentate forms. Spear et al.<sup>5</sup> have referred to this diagnostic methodology as facially generated treatment planning, where the maxillary central incisal edges determine where the soft tissue, i.e., gingiva, and bone should be positioned.<sup>6</sup>

To utilize crown lengthening, it is important for the restorative dentist to understand the concept of biologic width, indications, technique and other principles.<sup>7-9</sup> To maintain healthy periodontal tissue, the attached gingival and biologic width must be considered. Biologic width is measured from the bottom of the gingival sulcus to the alveolar crest and is maintained by homeostasis.<sup>10,11</sup> This width consists of the epithelial attachment to the tooth

surface and its connective tissue. The average width is 2.04 mm. Impinging biologic width may cause periodontal tissue destruction; therefore, in crown lengthening, the position of the margin is important.

#### Methods of clinical crown lengthening

As mentioned above, there are two methods to lengthen a crown: coronal extension and apical extension. Apical extension of the crown is achieved by surgery, with or without osseous resection. In apical extension there are two methods:

- Open technique—patients who exhibit asymmetrical gingival levels, those with greater than 3 to 5 mm of maxillary gingival display, or both may be candidates for surgical gingival and/or alveolar bone repositioning to improve their aesthetics.
- Closed technique—for minor localized biologic width and/or aesthetic gingival zenith corrections. Can be used in lieu of a flap procedure to make the correction and complete the restorative process without the necessary healing time required for open crown lengthening surgeries.<sup>12</sup>

#### Case presentation

This clinical report describes a situation in which a crown lengthening procedure was successfully performed with the Er:YAG laser (Lite-Touch, Syneron Medical Ltd.) as a principal auxiliary tool, and the advantages of the 2,940 nm wavelength versus conventional methods.

**Fig. 6**\_Incision.

**Fig. 7**\_Lifting the mucoperiosteal.

**Fig. 8**\_Bone ablation.

**Fig. 9**\_Bone level after ablation.

**Fig. 10**\_Immediately post-op.

**Fig. 11**\_One week post-op.



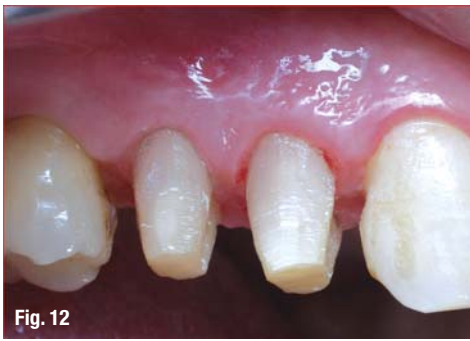

Fig. 12

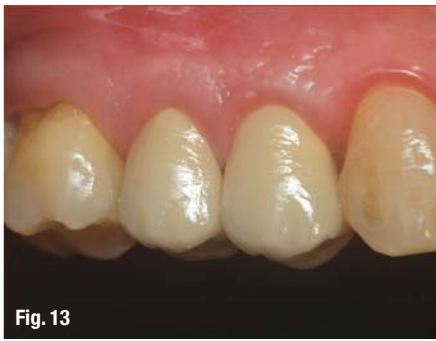

Fig. 13

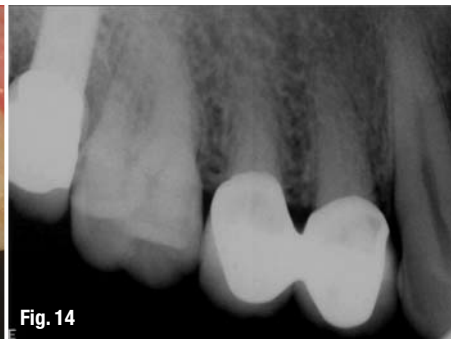

Fig. 14

Fig. 12\_Four months post-op.

Fig. 13\_Nine months post-op.

Fig. 14\_Nine months post-op X-ray image.

*Examination*

Clinical examination of a 57-year-old male revealed missing teeth at the locations #17, 36, 44, 45 and 46 with overeruption of teeth # 14 and 15 (Fig. 1). Radiographic examination of the area showed overeruption of teeth 14 and 15 with the alveolar bone.

*Treatment options*

The treatment options available in this case were:

- Insertion of implants and metal-ceramic crowns at the locations of teeth #17, 36, 44, 45 and 46.
- In addition to option one above: crown lengthening for teeth #14 and 15 and covering them with metal-ceramic crowns.

Following discussion with the patient and evaluation of the possibilities for success, it was decided to perform crown lengthening. Treatment would involve the use of the Er:YAG laser to perform the following steps, based upon accepted research:

- Flap incision<sup>13-15</sup>
- Ablation of soft tissue around the teeth after raising a flap<sup>16-18</sup>
- Remodelling, shaping and ablating of the bone.<sup>13,15,19,20</sup>

*Treatment*

All five implants were placed in one sitting (Fig. 2). Crown lengthening was performed three weeks postop (Fig. 3). Laser operating parameters employed for the various surgical stages were as follows:

- Flap Access: Wavelength: 2,940 nm (Er:YAG), 600-micron sapphire tip, contact mode; 200 mJ per pulse at 35 Hz. Total power: 7 Watts.
- Soft Tissue Removal: Wavelength: 2,940 nm (Er:YAG), 1,300-micron sapphire tip, non-contact mode; 400 mJ per pulse at 20 Hz. Total power: 8 Watts.
- Bone Surgery: Wavelength: 2,940 nm (Er:YAG),

1,300-micron sapphire tip, non-contact mode; 300 mJ per pulse at 20 Hz. Total power: 6 Watts.

With the assistance of a diode laser operating at a power setting of 2.4 W in contact mode, the location of the incision was marked (Figs. 4 and 5). An incision was made with the laser (after anaesthesia) at the buccal and palatal side of teeth # 14 and 15 (Fig. 6) and a vertical incision was not required. The buccal and palatal flaps were lifted and the area was explored (Fig. 7); there was soft tissue around the neck of the teeth. The soft tissue was ablated using the laser. Vaporization of soft/granulation tissue (if any exists) after raising a flap is efficient with the Er:YAG laser, offering a lower risk of overheating the bone than that posed by the diode or CO<sub>2</sub> lasers<sup>23</sup> and often obviates the need for hand instruments. Results from both controlled clinical and basic studies have pointed to the high potential of the Er:YAG laser and its excellent ability to effectively ablate soft tissue without producing major thermal side effects to adjacent tissue have been demonstrated in numerous studies.<sup>16-18</sup>

The Er:YAG laser was aimed at the surface of the exposed bone which was ablated in non-contact mode (Fig. 8). Studies have shown that Er:YAG laser energy effects on bone include bacterial reduction.<sup>22</sup> Following this, all accessible bone surfaces were exposed to laser energy to ablate necrotic bone and to shape and remodel the surface in accordance with established clinical protocols.<sup>13,15,20</sup>

The bone level around teeth #14 and 15 fits to the bone level of teeth #13 and 16 (Fig.9). The mucoperiosteal flap was re-positioned and sutured with silk 3-0, paying particular attention to primary closure of the flap (Fig. 10).

*Postoperative instructions*

The patient was prescribed antibiotics to avoid infection and painkillers for pain. Instructions were given to rinse with Chlorhexidine 0.2 %, starting the next day for two weeks, three times per day.

# implants

international magazine of oral implantology

## Management of complications and follow-up

The following day the patient reported moderate pain and moderate swelling. There was no tissue bleeding and the site was closed. The flap was showing signs of attachment and was healing nicely. At seven days post-op, the patient returned for inspection and removal of sutures. The swelling had resolved and healing was progressing well (Fig. 11). After five months, the soft tissue was healed completely without complications (Fig. 12). The soft tissue had healed over the bone and there were no bony projections observed under the soft tissue. The prognosis is excellent. An impression for two metal-ceramic crowns was taken five months post-op (Fig. 10). An aesthetic result was achieved (Figs. 13 & 14).

## Conclusion

The Er:YAG laser system (LiteTouch, Syneron Medical, 2,940 nm) can be employed as an auxiliary tool for the purpose of crown lengthening and has been shown to be effective and safe. The use of the LiteTouch wavelength for these procedures presents many advantages as opposed to conventional methods, including enhancement of the surgical site and less bleeding during the operation, providing the surgeon with a better field of visibility and reducing patient discomfort during use. In addition, anecdotal claims have been made that post-operative effects such as pain and swelling are less pronounced. Finally, the laser offers the dental surgeon enhanced ease of use with the hand piece's 360° swivel capability.

*Editorial note: A complete list of references is available from the publisher.*

## \_contact

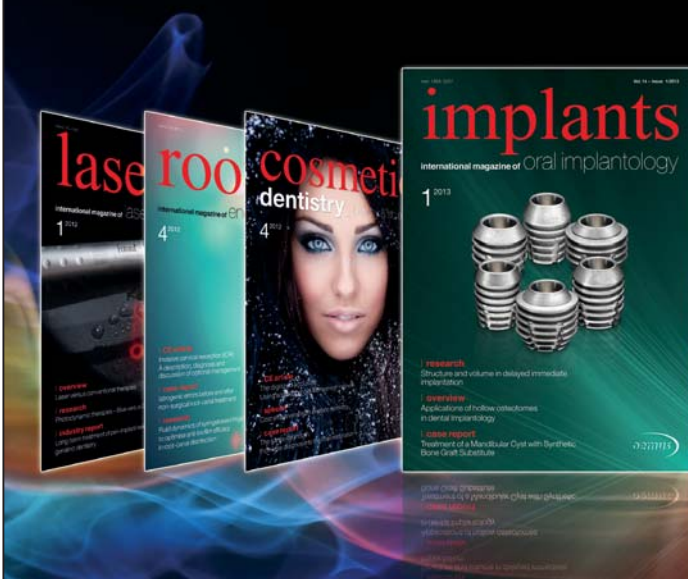laser

### Dr Avi Reyhanian


Private Clinic  
1 Shaar Haemek St.  
Netanya 42292, Israel

Tel.: +972 9 8338825  
Fax: +972 9 8339890

avi5000rey@gmail.com  
www.dentallaser.co



You can also subscribe via  
[www.oemus.com/abo](http://www.oemus.com/abo)

 **Subscribe now! One issue free of charge!**

I hereby agree to receive a free trial subscription of **implants international magazine of oral implantology** (4 issues per year). I would like to subscribe to **implants** for € 44 including shipping and VAT for German customers, € 46 including shipping and VAT for customers outside of Germany, unless a written cancellation is sent within 14 days of the receipt of the trial subscription. The subscription will be renewed automatically every year until a written cancellation is sent to OEMUS MEDIA AG, Holbeinstr. 29, 04229 Leipzig, Germany, six weeks prior to the renewal date.

▶ Reply via Fax +49 341 48474-290 to OEMUS MEDIA AG or per E-mail to: [grasse@oemus-media.de](mailto:grasse@oemus-media.de)

Last Name

First Name

Company

Street

ZIP/City/County

E-Mail

Signature

Notice of revocation: I am able to revoke the subscription within 14 days after my order by sending a written cancellation to OEMUS MEDIA AG, Holbeinstr. 29, 04229 Leipzig, Germany.

Unterschrift

OEMUS MEDIA AG  
Holbeinstr. 29, 04229 Leipzig  
Tel.: +49 341 48474-0  
Fax: +49 341 48474-290  
E-Mail: [grasse@oemus-media.de](mailto:grasse@oemus-media.de)

# Long-term treatment of peri-implant lesions in geriatric dentistry

**Author** \_Dr Georg Bach, Germany

[PICTURE: ©PRIVILEGE]

## \_Introduction

In recent years, photodynamic therapy has gained many new users in laser dentistry, giving it an enormous push forward. This therapy is minimally invasive and long-lasting. A multitude of scientific studies on the therapy have been conducted and it has a uniform nomenclature, established during the last meeting of the DGL (German Association for Laser Dentistry). During this meeting, the difference between "real" photodynamic therapy and one whose sensitiser has its own (antibacterial) properties was established. The following case report describes the minimally invasive use of a photodynamic therapy system with a green sensitiser in geriatric dentistry (treatment of peri-implant lesions).

## \_Real photodynamic therapy: Sensitiser with intrinsic effect

In treatments with real photodynamic therapy, cell death of the pathogenic bacteria is achieved exclusively by the interaction between sensitiser and laser light, which generates oxygen, resulting in destruction of the pathogenic cell. A further differentiation can be made with regard to sensitisers that use blue (usually with antibacterial properties) and those that use green (usually without antibacterial properties) dyes. Systems with green sensitisers are undoubtedly the focal point of current interest. They are generally indocyanine green (ICG) based and activated with an 810 nm (diode) laser (near infrared).

## \_Indocyanine green-based sensitisers for photodynamic therapy

ICG is a recognised active substance that has been standard in ophthalmology, as well as in oncology, dermatology and veterinary medicine, for years. If irradiated with a low-energy laser of a wavelength of 810 nm, it promises a successful therapy for periodontitis and peri-implantitis.

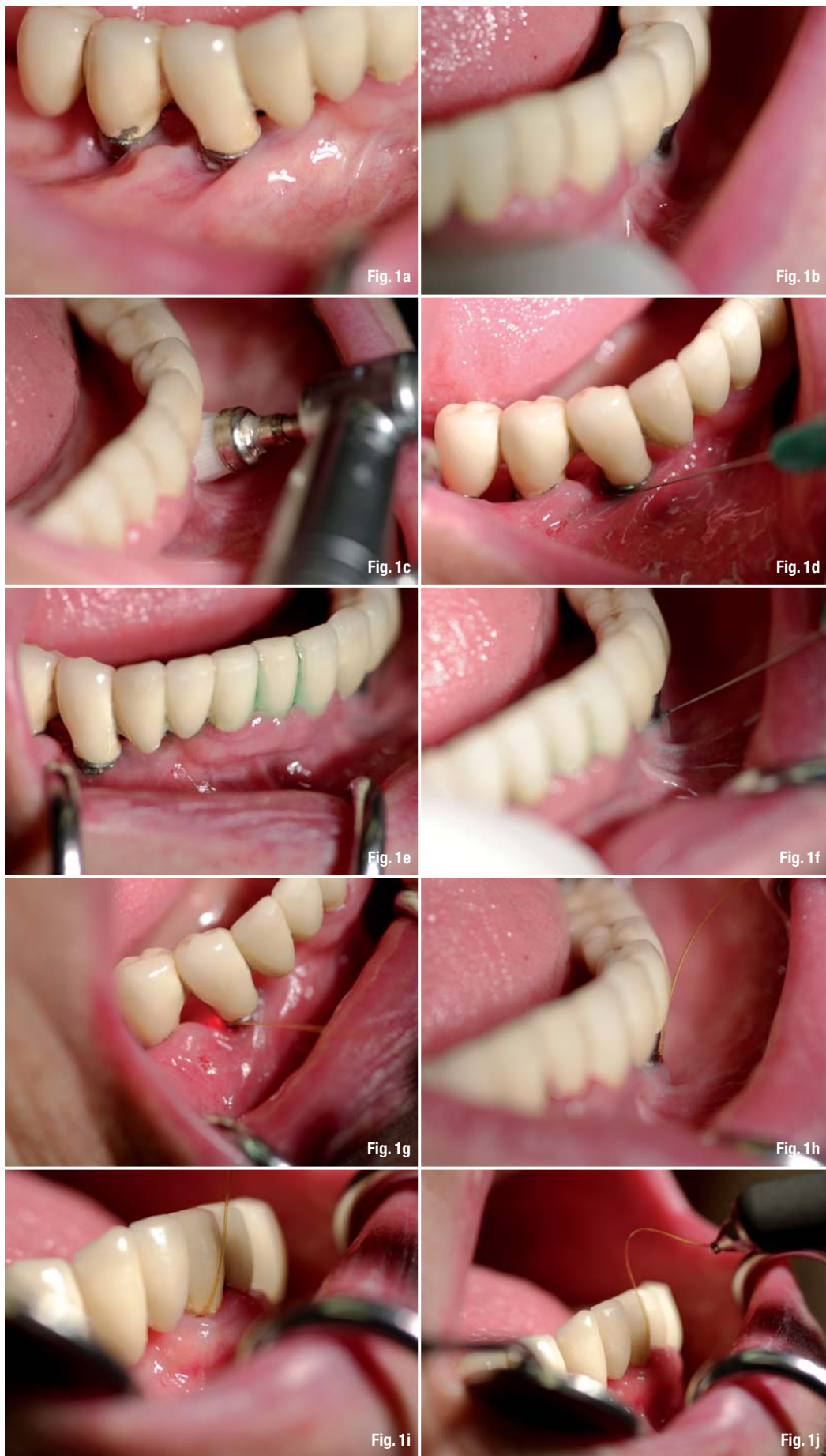## \_Case report

Eleven years ago, the now 79-year-old female patient had received implants in the mandible. After several years of total satisfaction with the implant provision, she experienced the first complications. While initially limited to the superstructure (small chips on the ceramic and loosening of the superstructure), problems with the actual implants had increased in the past three years and recurring infections, sometimes painful, and bleeding when brushing her teeth, etc. arose. Local and systemic antibiotics only yielded short-lived improvement, and she was then referred to our practice.

The first superficial intra-oral examination revealed clinical findings clearly indicative of a diagnosis of peri-implantitis:

- massive peri-implant bone loss;
- bowl-shaped defect; and
- pain on probing the soft-tissue sleeve.





**Fig. 1** Within the scope of a full-mouth disinfection, both of the implants affected by peri-implantitis and the remaining teeth of the mandible were treated with ICG-based photodynamic therapy.

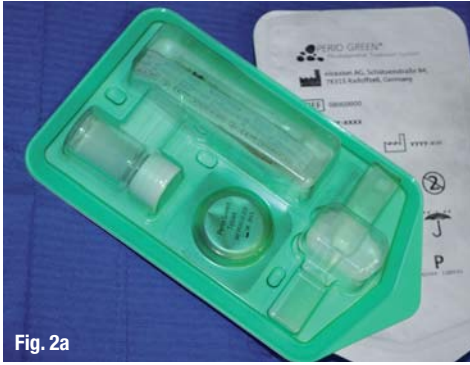

Fig. 2a



Fig. 2b

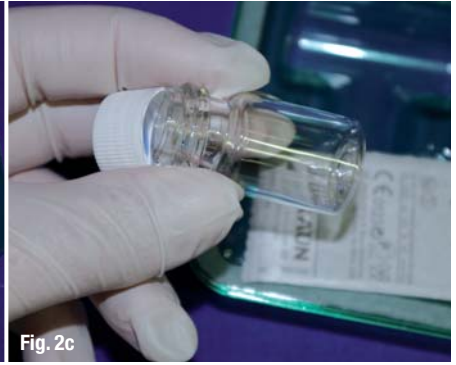


Fig. 2c

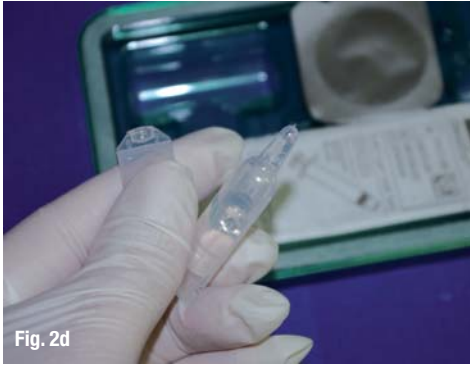

Fig. 2d

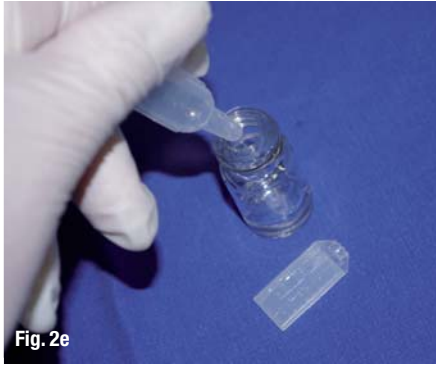

Fig. 2e

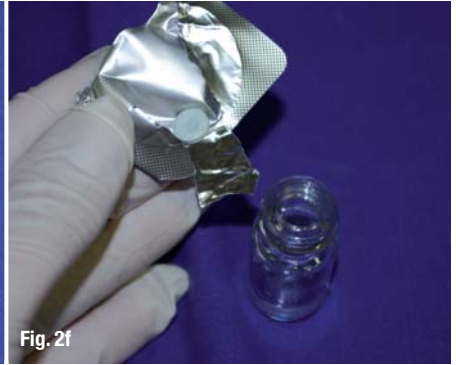

Fig. 2f

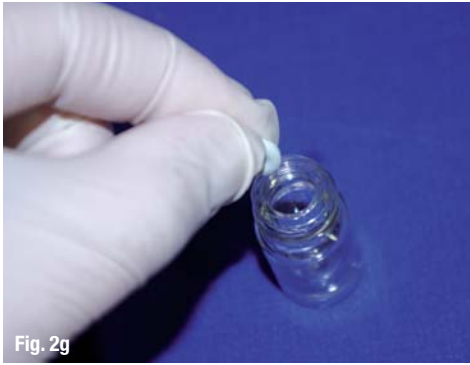

Fig. 2g



Fig. 2h

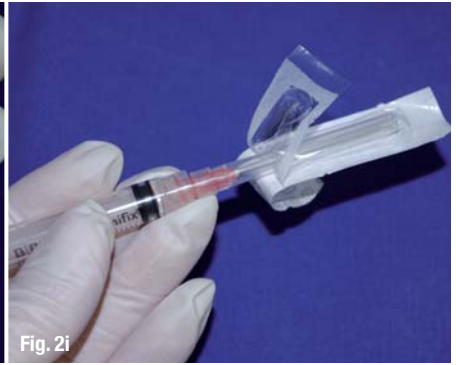


Fig. 2i

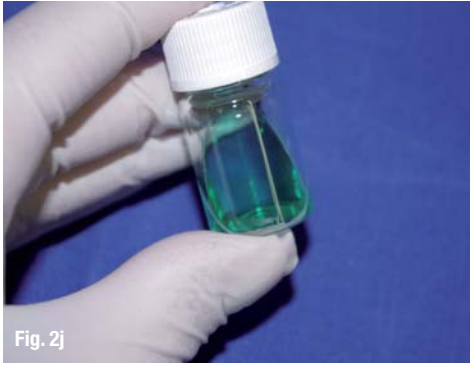


Fig. 2j

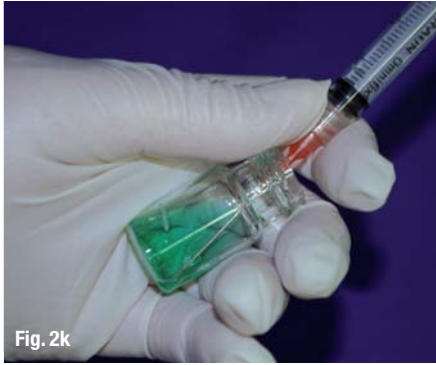

Fig. 2k

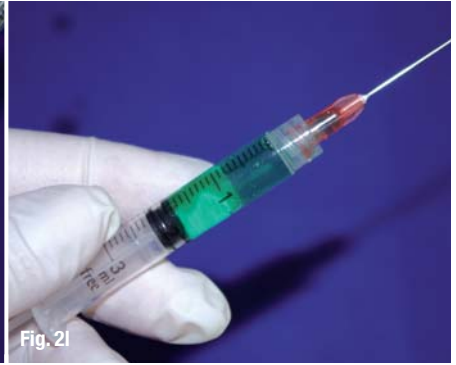

Fig. 2l

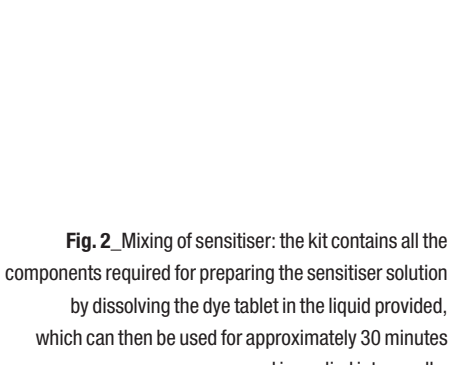


Fig. 2m

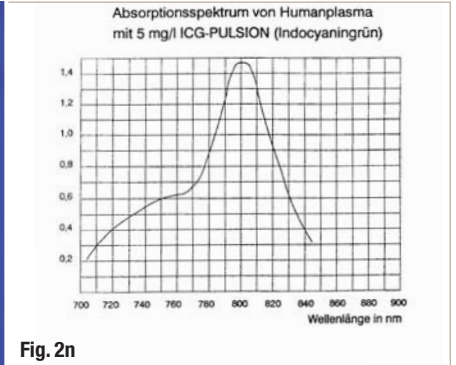


Fig. 2n

**Fig. 2\_Mixing of sensitizer:** the kit contains all the components required for preparing the sensitizer solution by dissolving the dye tablet in the liquid provided, which can then be used for approximately 30 minutes and is applied intra-orally.



The X-ray confirmed the initial clinical diagnosis: it was a case of full peri-implantitis. One implant in the left half of the mandible had loosened from the bone to the extent that no more than half of the titanium surface that had originally been covered by the implant was still osseointegrated. An explantation with subsequent augmentation and re-implantation later could have been considered for this artificial abutment tooth.

Already at this early stage of decision-making, the family doctor and internal medicine specialist vetoed any procedures with increased risk of bleeding, increased risk of bacteraemia and a high degree of invasiveness owing to the patient's highly compromised physical condition. With these justified restrictions, photodynamic therapy was the obvious choice for treatment.

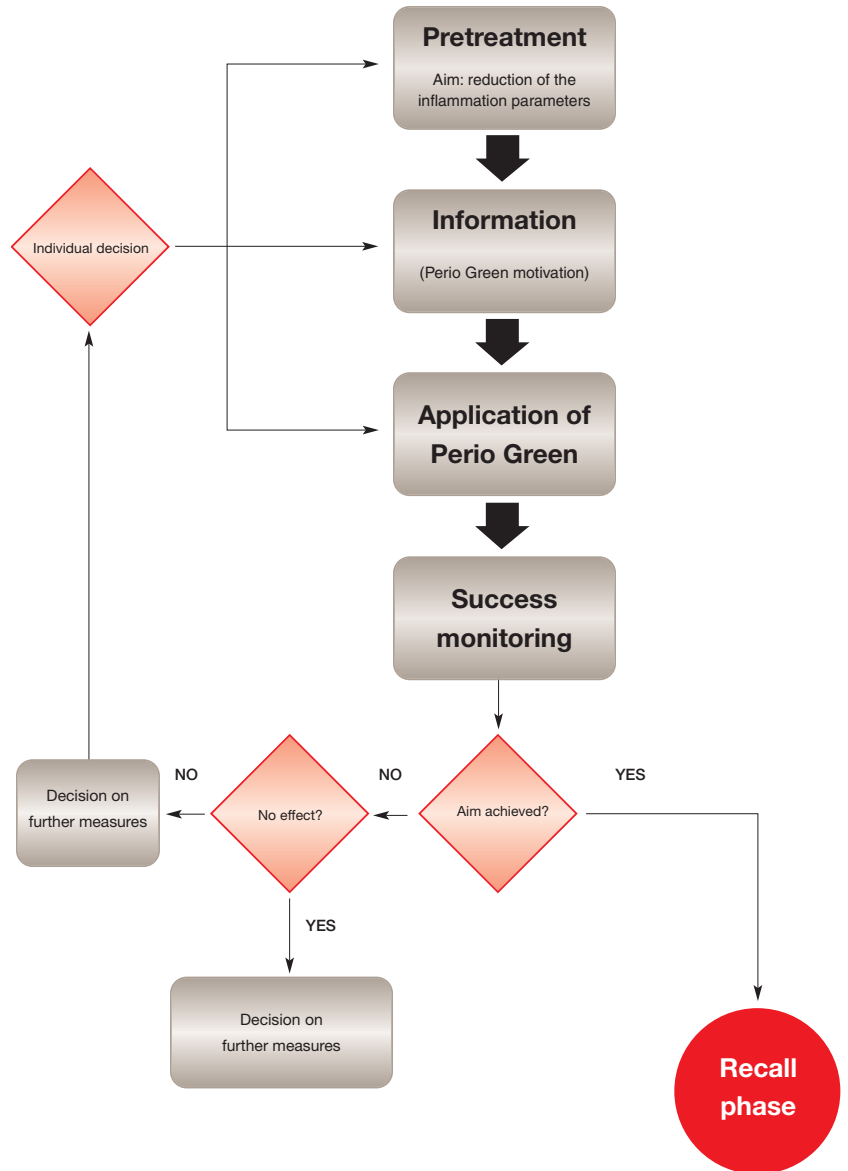
An ICG-based sensitiser (Perio Green, elexxion) in combination with an 810 nm diode laser (100 mW, pulsed) was used (Fig. 1). This is a photodynamic therapy system with matched components. The sensitiser is made up immediately prior to treatment by dissolving a dye tablet in the liquid included in the kit and then applied intra-orally (Fig. 2). The application of a low-viscosity light-green sensitiser, which requires a directed droplet-flow technique, is quite demanding compared with high-viscosity blue sensitisers. After application and a period of exposure, the laser fibre is inserted into the target area and the tissue is then irradiated with a low-energy diode laser (810 nm). The persistent colouring of the gingiva that is often observed when using other sensitisers does not occur after completion of treatment. No residue of the dye is visible intra-orally after rinsing several times.

An intra-oral follow-up examination was carried out at one and four weeks. The patient was, and is to date, without any symptoms. To maintain this situation, she is scheduled for recalls every three months, with every recall entailing a professional cleaning and photodynamic therapy for every second recall (Fig. 3).

Since, the patient is now almost completely without symptoms for the first time in years, but no improvement is to be expected with regard to her general health, we decided on this minimally invasive maintenance therapy. Regarding the commitments associated with it, the patient concluded very matter-of-factly, "To me, it is worth it".

**Conclusion**

In my opinion, photodynamic therapy is a minimally invasive option compared with conventional



methods. It is ideally and most effectively used with a verified treatment protocol and a sensitiser without an intrinsic effect. Photodynamic therapy has become my treatment of choice for patients with compromised health, for whom more invasive therapy options would be more difficult or impossible to implement, and for patients with a risk of bacteraemia.

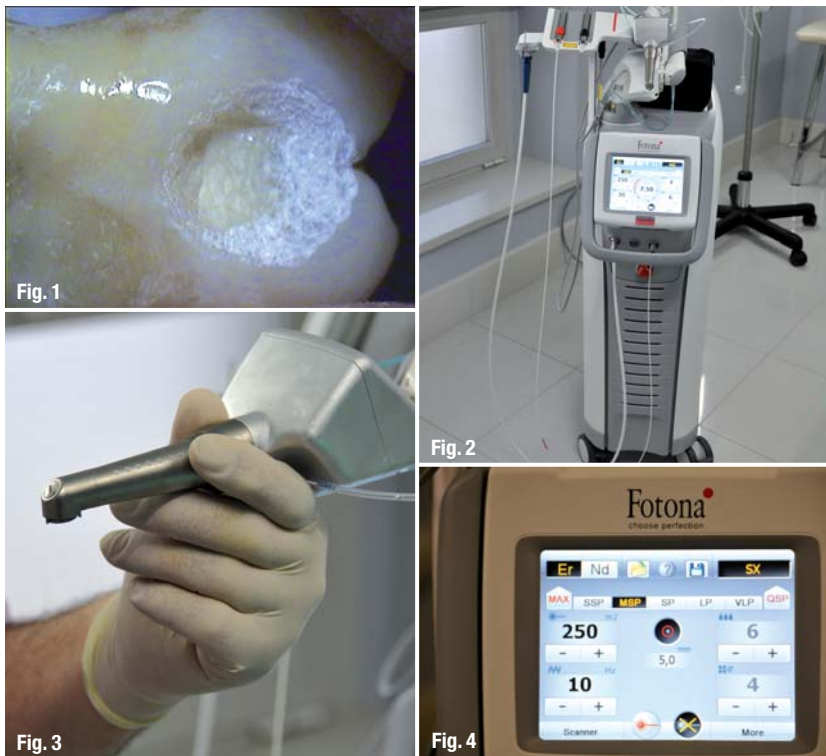**Fig. 3** Treatment regimen of ICG-based photodynamic therapy using Perio Green.

_contact	laser
<p><b>Dr Georg Bach</b>                  Rathausgasse 36                  79098 Freiburg/Breisgau                  Germany</p> <p>doc.bach@t-online.de</p>	



# X-Runner Er:YAG dental laser application

Author\_Prof. Dr Carlo Fornaini, Italy



**Fig. 1** \_Tooth sample for optical microscope and SEM observation.

**Fig. 2** \_LightWalker AT dental laser.

**Fig. 3** \_X-Runner handpiece.

**Fig. 4** \_X-Runner settings screen.

## \_Introduction

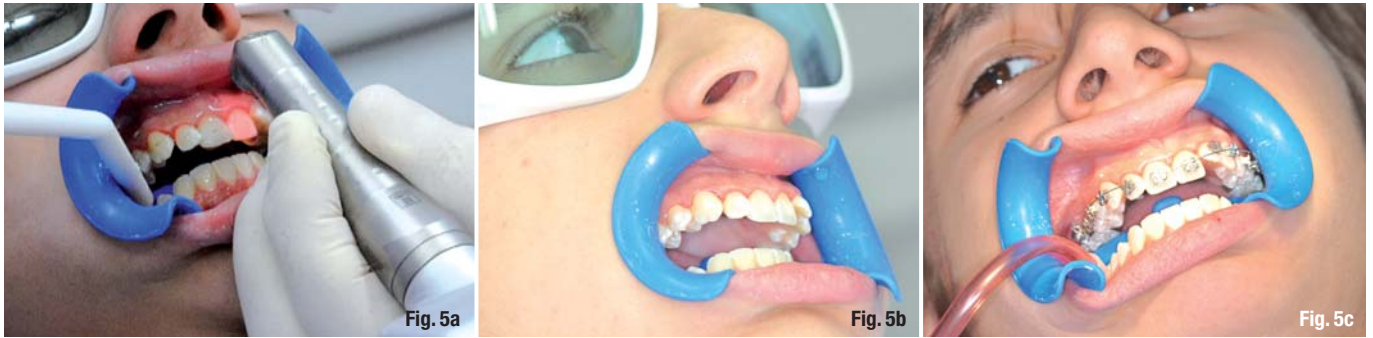The notion of utilising laser technology in conservative dentistry was proposed in 1990 by Hibst and Keller, who introduced the possibility of using an Er:YAG laser as alternative to conventional instruments such as the turbine and micro-motor.<sup>1,2</sup> Widespread interest in employing this new technology stems from a number of significant advantages, as described in several scientific studies. Thanks to the affinity of the Er:YAG laser wavelength to water and hydroxyapatite, laser technology allows for efficient ablation of hard dental tissues without the risk of micro- and macro-fractures, as have been observed with

the use of conventional rotating instruments.<sup>3-5</sup> The dentin surface treated by laser appears clean, without a smear-layer, and with the tubules open and clear.<sup>6</sup>

Thermal elevation in the pulp, recorded during Er:YAG laser irradiation, is lower than that recorded by using a turbine and micro-motor with the same conditions of air/water spray.<sup>7,8</sup> This wavelength also has an antimicrobial decontamination effect on the treated tissue, which destroys both aerobic and anaerobic bacteria.<sup>9</sup> The most interesting aspects of this new technology are related to the goals of modern conservative dentistry, i.e. minimally invasive treatments and adhesive dentistry. Er:YAG lasers can reach spot dimensions smaller than 1 mm, which enables a selective ablation of the affected dentin while preserving the surrounding sound tissue to produce highly efficient restorations.<sup>10</sup> Several *in vitro* studies have demonstrated that the preparation of enamel and dentine by Er:YAG laser, followed by orthophosphoric acid-etching, enhances the effectiveness in terms of reduced microleakage and increased bond strength.<sup>11</sup>

To understand the role that a scanner can perform in dental treatments, it is useful to take a comparative look at the field of aesthetic medicine. The Er:YAG laser has been used for many years in the field of dermatology, where it is employed for the vaporisation of lesions such as condyloma, naevi, warts, mollusca contagiosa, as well as for the treatment of keloid scars and wrinkles with so-called laser "resurfacing".<sup>12</sup> For many years, scanners have proven highly effective in dermatological treatments, enabling high-precision surface treatments without overlapping or under-coverage of the laser treatment area.

The aim of our study, which began several years ago, has been to evaluate the possibility of transferring the same type of scanner technology that is widely utilised



in dermatology to the dental field. The first *in vitro* tests were performed on extracted teeth by using a scanner and a dermatological Er:YAG laser. Because of the fact that this particular dermatological device operates without water, it was necessary to modify it by adding a double external pipeline in order to deliver an air/water spray at the point of the laser's impact on the tooth.

The results of this first sequence of tests were very promising and convinced the manufacturer Fotona to invest in a major research and development effort to construct a scanner handpiece of reduced size, able to be employed intra-orally. Once developed, the new dental-optimised scanner was given another series of "*in vitro*" tests, and after the safety of its utilisation was demonstrated via K-thermocouple records, optical microscope (Fig. 1) and SEM observation, it was subsequently applied to *in vivo* tests on human subjects.

**Material and method**

The laser appliance used was a LightWalker (Fotona, Fig. 2). The scanner handpiece is similar to the usual non-contact Er:YAG laser handpiece. The scanning mechanism is integrated inside an ergonomic box that lies on the operator's hand, with a supplementary electrical cable delivering the digital information from the laser device to the scanning mirrors (Fig. 3). Its application is the same as with the usual non-contact handpiece; the only difference is that it covers a bigger area than the standard handpiece. However, it is useful because it can cover a larger area, or, by pressing the button on the screen, it can be used as a classical one-spot laser handpiece. The scanner handpiece can thus be used for all kinds of treatments by switching from the scanner modality to classic handpiece modality, without swapping handpieces.

The following settings are available for the scanner handpiece on the touch screen (Fig. 4):

- scanning of the area shape (circular, rectangular, hexagonal),
- size of the scanning area (width and length of the rectangle, diameter of circle and hexagon),
- number of scan passages (a function of the requested ablation depth),

- delay between consecutive scans (duration of the pause between scans).

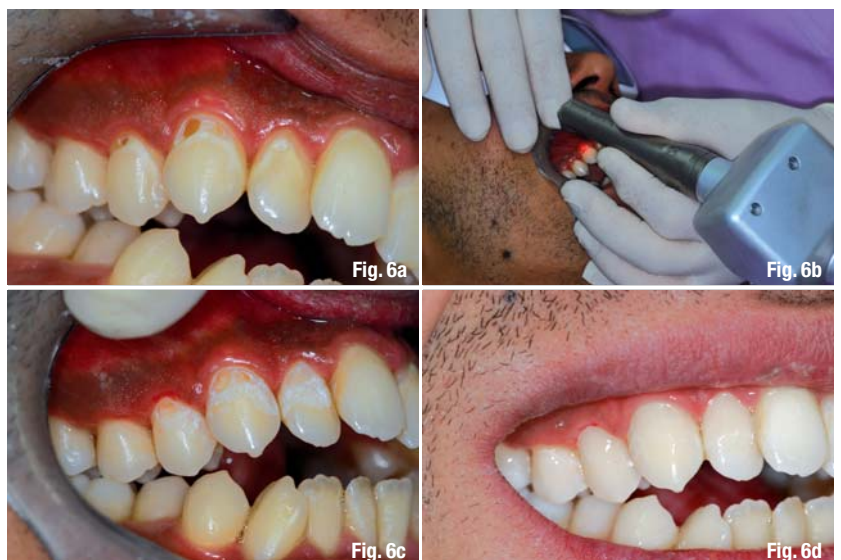Moreover, all parameters available with the classic handpiece (energy, frequency, mode, spray) are also used with the scanner handpiece. By reducing one of the sides of the rectangular shape, it is possible to obtain a linear cut without moving the handpiece, for instance to cut the root apex during endodontic surgery or to perform an incision in soft tissues surgery.

In this preliminary study, clinical applications are shown below which illustrate this new Er:YAG laser technology.

**Case 1: Enamel laser conditioning for orthodontic bracket bonding**

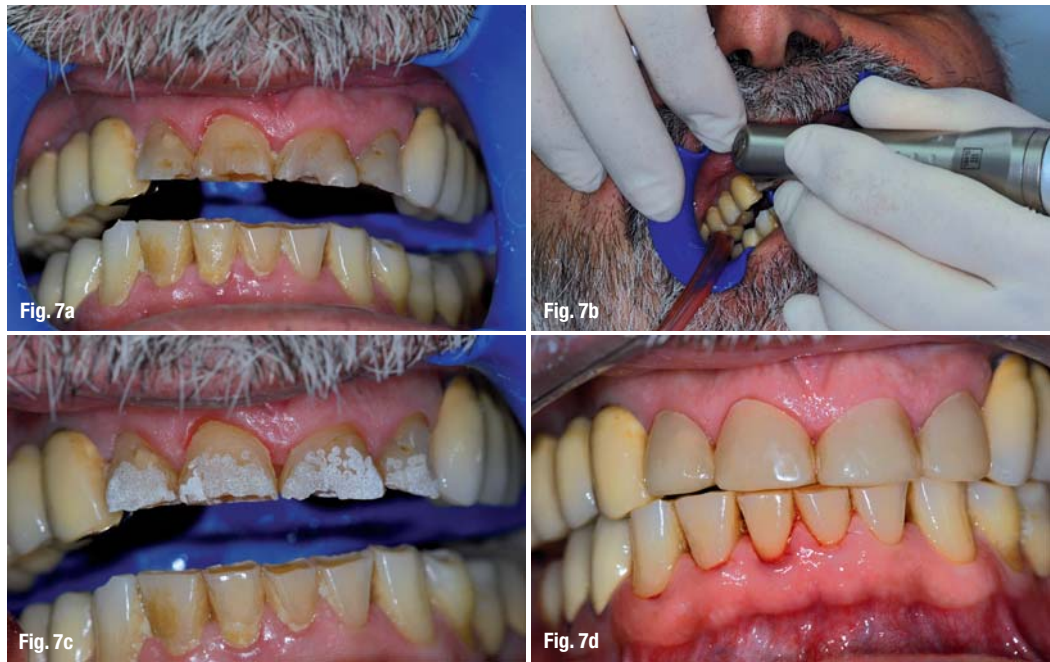The employment of an Er:YAG laser to prepare the enamel for improving the strength of adhesion of composite resins has been proposed by several authors in conservative dentistry as well as for bracket bonding in orthodontics.<sup>13</sup> Several studies, based both on traction and microleakage tests, have shown that the best values were obtained with samples irradiated by an Er:YAG beam before acid etching.<sup>14</sup> Additionally, an "*in vitro*" study on extracted human teeth demon-

**Fig. 5** a) During laser-scanner conditioning; b) After the enamel preparation for brackets with the scanner; c) Brackets bonding completed.



**Fig. 6** a) Enamel lesions in the right upper lateral incisor, canine, and the first premolar; b) During scanner treatment; c) After the scanner ablation of enamel lesions; d) After the complete treatment.

**Fig. 7** a) Damaged frontal teeth crowns; b) During scanner ablation of enamel; c) After the scanner ablation of dental tissue; d) After bonding a coat of composite resin.



strated that preparation by Er:YAG laser alone also gives a stronger adhesion than orthophosphoric acid alone.<sup>15</sup> Moreover, other authors have underscored these results when using lasers to prepare enamel surfaces to make them more resistant to decay.<sup>16</sup> This is possible because of the modification of hydroxyapatite crystals, which is important in the prevention of decalcification zones around brackets, particularly in patients with scanty oral hygiene.<sup>17</sup> Another advantage of laser utilisation is the ability to prepare a very small surface area of enamel, exactly of the same dimension of the bracket. We initially proposed a technique based on the use of a plastic template with rectangular windows designed to limit the irradiated area. Now, by using the scanner handpiece, the procedure is faster, easier and more precise.

The case described presents a 14-year-old female receiving orthodontic fixed treatment of the upper arch. The parameters used were determined by SEM observation in order to give the best enamel conditioning coupled with the minimal ablation: 55 mJ, 8 Hz, MSP mode, 4/6 air/water spray. The dimension of the ablation area was 2.5x3 mm and the number of passes was 10, once for each tooth.

### Case 2: Treatment of amelogenesis imperfecta spots on permanent incisors

The term amelogenesis imperfecta is defined as a diverse group of hereditary disorders that primarily affects the quantity, structure, and composition of enamel.<sup>18</sup> In the hypomature type, the affected teeth exhibit mottled, opaque white-brown or yellowish discoloured enamel, which is softer than normal. The hypocalcified type shows pigmented, softened, and

easily detachable enamel, while in the hypoplastic type, the enamel is well mineralised but the amount is reduced.<sup>19</sup>

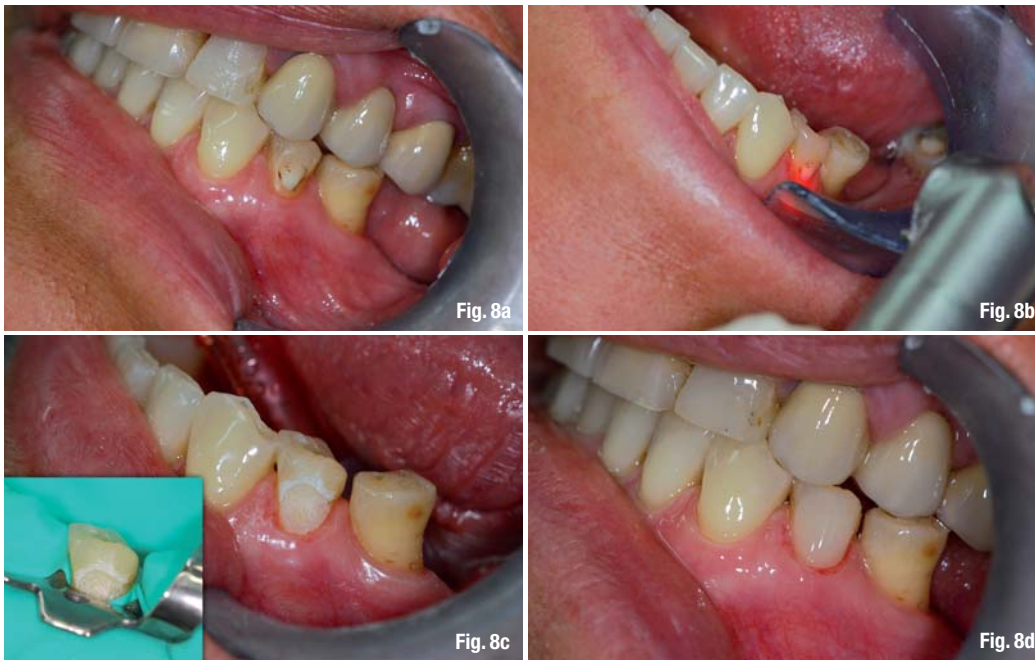In our daily practice, we have worked with several young patients exhibiting zones of discoloration in their frontal teeth and who needed treatment to improve the aesthetics of their smile. Due to the impossibility of treating these cases with classical bleaching techniques, it was necessary to ablate the affected zones and to fill the cavities produced with composite resins. We have already described the use of the Er:YAG laser in this type of case as a good example of minimally invasive dentistry<sup>20</sup> but the use of the scanner improves the precision of the ablation even further by programming the extent and depth of the zone in advance.

The case presented concerns an 18-year-old male who had enamel lesions in the right upper lateral incisor, canine, and the first premolar. The treatment was performed without anaesthetics, with a total laser irradiation time of 186 sec. For this case we used the following parameters: 250 mJ, 10 Hz, MSP mode, 4/6 air/water spray. The ablation area was a 3.5 mm diameter circle and the number of passes was 15.

### Case 3: Direct composite veneering of permanent incisors

In cases concerning damage to the frontal teeth crowns from a number of possible causes, i.e. traumas or bruxism, and if the patient does not wish to choose a prosthetic option, the solution is to ablate a portion of the enamel and to directly bond a coat of composite resin. The role of the Er:YAG laser in improving the





**Fig. 8** a) Old composite on tooth 34; b) During scanner ablation; c) Immediately after scanner treatment; d) After the complete treatment.

adhesion of resin to enamel has been well demonstrated<sup>21,22</sup> and the advantage with the use of a scanner handpiece is the possibility to limit the volume of ablated dental tissue. The case presented regards a 64-year-old male who needed repair of his upper incisors. The treatment was performed without anaesthetics, with a total laser irradiation time of 253 sec. The parameters used were: 300 mJ, 10 Hz, MSP mode, 4/6 air/water spray. The ablation area was a 4.5 mm diameter circle, the number of passes was 15.

#### **Case 4: Aesthetic re-treatment of an aging composite restoration**

In some cases, composite restorations may present discolorations and spots after a number of years, particularly in patients who do not observe an adequate level of oral hygiene. The vestibular face of the frontal teeth or the cervical area of the premolars may pose a problem, from an aesthetical point of view, and this is the reason why several patients have come to our offices to regain a pleasant smile. The Er:YAG laser may be very helpful in this situation; in fact, because of its wavelength (2,940 nm) it is well absorbed by Glycidyl methacrylate (GMA) and Silicon Dioxide, two important components of composite. It is very effective in the ablation of old restorations without thermal elevation<sup>23</sup> and can produce a rough surface, very difficult to obtain with orthophosphoric acid, which is able to bond the new coat of resin.

The case presented here involves a 55-year-old female with an aging infiltrated and spotted cervical restoration on tooth 34. The treatment was performed without anaesthetic. The parameters used were: 250 mJ, 10 HZ, MSP mode, 4/6 air/water spray. The ab-

lation area was a 4 mm diameter circle and the number of passes was 15 for two times.

#### **Discussion and Conclusion**

Laser technology was introduced in dentistry by Goldman in 1967.<sup>24</sup> Since that time, a continuing effort has been made by clinicians, researchers and companies to improve the results of clinical treatments. The introduction of Er:YAG in 1990 provided the option to also treat hard tissues, and this technology was further improved through greater control of pulse duration (VSP—variable square pulse technology).

The recent introduction of a scanner handpiece enabled a higher precision of irradiation and depth of ablation as well as reduced treatment time, allowing laser technology to more fully realise the vision of "minimally invasive" conservative dentistry.

*Editorial note: A list of references is available from the author.*

**\_contact**

**laser**

**Prof. Dr Carlo Fornaini**

MD DMD MSc

Via Varini, 10

29017 Fiorenzuola d'Arda, PC, Italy

Tel.: +39 0523 982667

Fax: +39 0523 242109

info@fornainident.it

www.fornainident.it

# Manufacturer News

## GIGAA LASER

### Professional medical diode laser systems supplier

CHEESE dental laser is a good assistance for dentists in the treatment of periodontics, conservative dentistry, endodontics, oral surgery as well as teeth whitening. The good performance of laser technology comprising with conventional treatments makes the patients smile, it sounds like "CHEESE". With the advantage of battery-operated design, the fully charged battery can support about three hours of treatment in CW mode.

GBOX dental laser with repetition rate up to 20 kHz makes the pulse-pause-ratio (PPR technology) available. PPR technology is a treatment for soft tissue cutting and coagulation in a high repetition rate with less or no carbonization. As a result, the patients will feel less pain and recover quickly. Gigaa is a leading developer and manu-

facturer of diode laser systems for the dental area as well as other surgery areas, such as vascular surgery, ENT surgery, lipolysis, and urology surgery and laser therapy. It is our mission to provide reliable diode laser systems to increase patients' health.



#### Wuhan Gigaa Optonics Technology Co., Ltd

5-6/F, Unit A-B, Building B8, Hi-Tech Medical Device Industrial Park, #818 Gaoxin Avenue, East Lake Development Zone, Wuhan 430206, China

info@gigaa.com  
www.gigaa.com

## Biolase

### Laser training and new diode laser

Informing themselves about the latest developments and methods in laser applications and taking part in the respective trainings is mandatory for all laser users. Therefore, Biolase has been supporting WCLI (World Clinical Laser Institute) for many years, thus operating in laser education on an international scale. In order to be able to offer certified high-level courses worldwide, Biolase has also recently started a new cooperation with AALZ (Aachen Dental Laser Center) in Aachen, Germany, presided by Prof. Norbert Gutknecht.

In addition, train-the-trainer seminars will be held for international training practices. For the first time, a workshop will be conducted which combines periodontology and aesthetic surgery/dentistry. Every laser user can gain further qualification in a certification course starting January 2013.

Moreover, the release of the new 10-Watts diode laser Epic is eagerly awaited by laser users. A good price-performance ratio, its appealing design and easy handling have already led to such a high demand that it has become hard

keep pace with on the production side, resulting in delivery delays. Now, finally, the modern diode-laser system Epic with 25 years of Biolase experience in development is made available worldwide.

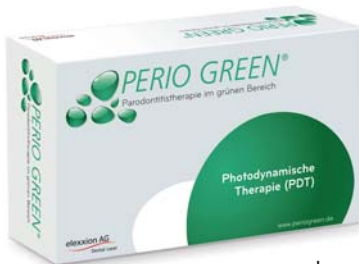

All training activities in the German-speaking countries can be found at [www.nmt-muc.de](http://www.nmt-muc.de).

## elexxion

### Antimicrobial periodontal and peri-implantitis treatment

With the new photodynamic active ingredient Perio Green, elexxion AG based in Radolfzell, Germany, is bringing colour into laser-assisted periodontal and peri-implantitis treatment. The new class IIa medical device, which is based on the clinically proven PDT dye indocyanine green and reacts specifically to the light frequency of elexxion lasers, provides highly effective and painless adjuvant treatment of periodontitis and peri-implantitis – with no risk to hard dental and soft tissue and without causing discolouration or systemic effects.



or mechanical effects; anaesthesia is usually unnecessary.

The actual Perio Green treatment, which can be repeated any time in recall appointments, takes about an hour. If the method is used during a professional oral hygiene session, the time is reduced to only about 30 minutes. Furthermore, as this type of laser-assisted therapy is non-invasive, it can be delegated to a suitably trained dental nurse.

#### elexxion AG

Schützenstraße 84  
78315 Radolfzell, Germany

info@elexxion.com  
www.periogreen.com/en

#### Biolase Europe GmbH

Paintweg 10  
92685 Floss, Germany

info@biolase-europe.com  
www.biolase.de

IDS: Hall 10.1, booths J030-K031

IDS: Hall 4.2, booth N060

## Henry's Angels brighten EllenorLions Hospices' charity shop

A team of office workers from Henry Schein UK, subsidiary of the US-based Henry Schein, Inc. (NASDAQ: HSIC), the world's largest provider of health care products and services to office-based dental, medical and animal health practitioners, swapped their pens for paintbrushes to give one of EllenorLions Hospices' local charity shops a make-over.



(PICTURE: ©BOULE)

Henry's Angels—a troupe of volunteers from Henry Schein in Gillingham, UK—took time out of their busy schedules to give Gravesend's Kings Street store a face life. Armed with paint pots and oodles of enthusiasm, the dedicated team set to work on Thursday, 23 August 2012. The Angels brightened the walls with lashings of white emulsion and gave the woodwork a beautiful glossy finish. All of the materials were also paid for donations raised by the Angels at a car-wash project held at a local car wash centre in July. The team also brought in donations of pre-loved clothes, household

items and other goodies, to be sold in the shop. Henry's Angels was formed in January 2011 with the goal of providing Henry Schein employees an opportunity to help local causes in practical ways. Henry Schein's global corporate social responsibility programme, Henry Schein Cares, stands on four pillars: engaging Team Schein Members to reach their potential, ensuring accountability by extending ethical business practices to all levels, promoting environmental sustainability, and expanding access to health care for underserved and at-risk communities.

### Henry Schein UK

Centurion Close  
Gillingham Business Park  
Gillingham ME8 0SB, England

[www.henryschein.co.uk](http://www.henryschein.co.uk)

IDS: Hall 10.2, booths M048-N049

## Syneron Dental Lasers

### LiteTouch™ Training Academy Goes Global

Syneron Dental Lasers, provider of innovative dental laser technologies, is pleased to announce the launch of its global LiteTouch™ Training Academy, with a new concept that opens more than eight academic institutions around the globe offering practical LiteTouch™ training and insight into the Laser-in-the-Handpiece™ technology.



**Syneron Dental Lasers Global Training Academy**  
BARCELONA NICE TAIPEI VIENNA PLOVDIV SKOPJE GENEVA JERUSALEM  
R.S.V.P. at [dental@syneron.com](mailto:dental@syneron.com) - [WWW.SYNERONDENTAL.COM](http://WWW.SYNERONDENTAL.COM)

Syneron Dental Lasers has partnered in education with world-class leading laser dentistry institutions, including the International Society for Oral Laser Applications (SOLA) in Vienna, the University of Barcelona, the Hebrew University and Hadassah Medical Center in Jerusalem, the University of Nice-Sophia Antipolis, the University of Plovdiv, the faculty of Medical Sciences, General Stomatology Univer-

sity "Goce Delcev" Stip, R. Macedonia, the University of Geneva and the Asia Pacific Laser Institute. The LiteTouch™ training programs include instructor-led classroom lectures as well as hands-on sessions. The Academy offers training programs led by key opinion leaders and targets two main groups: new entrants to laser dentistry and practitioners looking to extend their clinical knowledge. In addition, the program will provide a first-of-its-kind education program for specialists seeking to understand best practices and clinical solutions for specific procedures in their area of specialty (e.g., endodontics, periodontics, paediatric dentistry, restorative and oral Surgery, aesthetic dentistry).

### Syneron Dental Lasers

Tavor Building, Industrial Zone  
20692 Yokneam Illit, Israel

[dental@syneron.com](mailto:dental@syneron.com)  
[www.synerondental.com](http://www.synerondental.com)

IDS: Hall 4.2, booth N050

*become  
an  
author  
for "laser"*



Please contact Claudia Jahn  
[c.jahn@oemus-media.de](mailto:c.jahn@oemus-media.de)



# 1<sup>st</sup> International Congress of WALED and GLOBAL 2013 in Istanbul

Source\_AALZ Germany

[PICTURE: ©ILKER CANIKLIGIL]

From 14–15 June 2013, the 1<sup>st</sup> International Congress of WALED and GLOBAL 2013 will be held at Point Hotel Taksim in Istanbul, Turkey. We are planning an exciting programme with evidence-based and state-of-the-art laser dentistry. Meet international experts in their fields, e.g. laser diagnostics, paediatric dentistry, aesthetics and oral surgery.

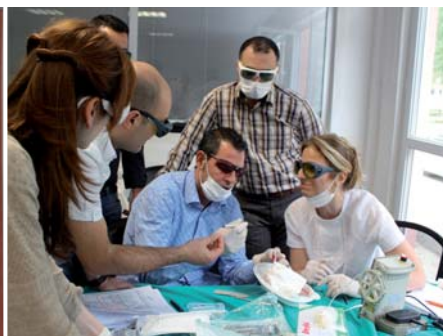The programme is separated between the two organisers on the first day. The WALED programme is reserved only for WALED members. Members of this academy are Master of Science and Mastership/ Fellowship graduates from the Aachen Dental Laser Center (AALZ) and RWTH Aachen University. WALED (World Academy for Laser Education in Dentistry) is the academic and educational worldwide network of AALZ and has been established to realise an international academy of excellence for postgraduate education and research in laser dentistry. The goal of WALED is to standardise education concepts based on evidence-based research as well as

treatment protocols based on evidence-based preclinical and clinical research.

On the second day, the programme is open for everybody. Simultaneous translation in Turkish will be provided. Workshops will complete the lecture and the congress will be closed by the great "International Night". The Congress Fees are 250 Euro and include, in addition to the scientific sessions, the full day catering as well as the evening events!

We also established a WALED page on [www.facebook.com/groups/123005997774948/](http://www.facebook.com/groups/123005997774948/)

Please have a look from time to time for any updates and news. We sincerely hope you will be able to attend our congress, that your visit will be an enriching experience both academically and culturally, and that, above all, you will have fun! We look forward to welcoming you at our congress and to Istanbul. \_



Under the Patronage of  
**H. H. Sheikh Hamdan Bin Rashid Al Maktoum**  
Deputy Ruler of Dubai, Minister of Finance  
President of the Dubai Health Authority

تحت رعاية  
سمو الشيخ حمدان بن راشد آل مكتوم  
نائب حاكم دبي، وزير المالية  
رئيس هيئة الصحة بدبي

## مؤتمر الإمارات الدولي لطب الأسنان ومعرض طب الأسنان العربي UAE INTERNATIONAL DENTAL CONFERENCE & ARAB DENTAL EXHIBITION

# إيكد AEEEDC DUBAI

Delivering Science & Technology

4 - 6 February, 2014

مركز دبي الدولي للمؤتمرات والمعارض  
Dubai International Convention & Exhibition Centre

[www.aeedc.com](http://www.aeedc.com)

Organised by



In Cooperation with



Strategic Partner



Supported by



**INDEX® Conferences & Exhibitions Organisation Est.**

Dubai Healthcare City, Ibn Sina Medical Complex #27, Block B, Office 203 | P.O. Box: 13636, Dubai, United Arab Emirates  
Tel: +971 4 3624717, Fax: +971 4 3624718 | E-mail: [info@aeedc.com](mailto:info@aeedc.com), Website: [www.index.ae](http://www.index.ae)



# The next chapter in the IDS success story

Source\_Koelnmesse



[PICTURES: © KOELNMESSE GMBH]

IDS 2013 will continue a positive tradition that began 90 years ago, when the first dental show took place in Germany.

More than 1,900 exhibitors from over 55 countries are expected to be in Cologne from 12–16 March 2013 for the world's largest trade show for dentistry and dental technology. Thanks to the tremendous demand for space, the fair will also occupy Hall 2.2 in addition to Halls 3, 4, 10 and 11. Altogether, 150,000 m<sup>2</sup> of gross exhibition space will be covered.

The International Dental Show will once again be the global meeting point for the international dental sector in 2013. Around 68 per cent of the exhibiting companies will come to Cologne from abroad. Following Germany, the nations that will be the most strongly represented include Italy, the USA, the Republic of Korea, the People's Republic of China, Switzerland, France and Great Britain. In addition, there will again be a large number of joint participa-

tions from abroad in March 2013. These are organised in conjunction with state or private export promotion organisations and associations. At present, 13 joint participation groups have registered. These come from Argentina, Brazil, Bulgaria, The People's Republic of China, Great Britain, Israel, Italy, Japan, the Republic of Korea, Pakistan, Russia, Taiwan and the USA.

Once again in 2013, the International Dental Show will stick to its time-tested recipe for success. The concept of the event will continue to focus on business at the stands and product information provided by the exhibitors. Correspondingly and according to tradition, 12 March 2013, the first day of the show—also referred to as Dealer's Day—will concentrate on dental trade and importers. This special focus will provide participants with an appropriate atmosphere for undisturbed and intensive sales negotiations.

Another well-established part of the IDS programme—the Speakers' Corner—will take place in Hall 3.1, right next to the Entrance South. Here, IDS exhibitors will present new product information, services and process techniques every day. In addition, speakers will report on the latest findings from the worlds of science and research.

A number of digital services are available to help visitors plan the optimal trade show visit. These services contribute to goal-oriented trade show preparations and help make the visit more effective. In order to ensure optimal support, the update for the trade show's own IDS app for iPhone, Blackberry and other operating systems is available since December. The app can be downloaded free of charge from the IDS website.

Travel arrangements, hotels and admission tickets for the trade fair can be booked quickly and easily online, thanks to a number of services on the IDS website. Registration and ticket sales are available now through the online ticket shop.



**laser** wishes you  
a successful **IDS 2013!**



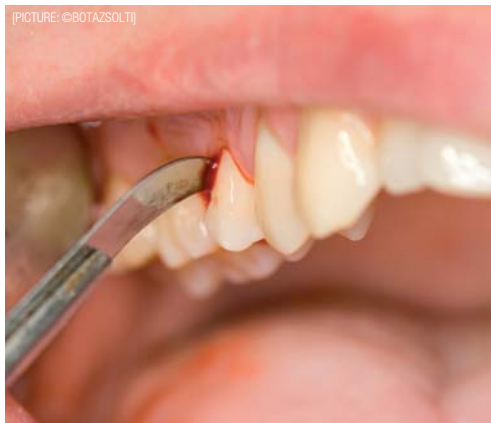## New chip accelerates

### Detection of periodontal bacteria

Of the estimated 700 bacterial species found in the oral cavity, only 11 are known to cause periodontitis. The detection of the relevant pathogens, however, has been very time-consuming to date. Now scientists from Germany hope that a newly developed diagnostic device will allow dentists and medical labs to conduct bacterial analysis in less than half an hour.

Conventionally, bacterial analyses are carried out in external contract laboratories using microbial cultures. This method bears the risk of bacteria being killed as soon as they come into contact with oxygen and the analysis can take up to four to six hours. Therefore, ParoChip, an initial lab-on-a-chip device, was designed by researchers at the Fraunhofer Institute for Cell Therapy and Immunology (IZI) to speed up the time needed for identification.

The new mobile diagnostic unit consists of a disk-shaped microfluidic card that is about 6 cm in diameter. The card has eleven reaction chambers, each containing the dried reagent for one of the eleven periodontal pathogens.

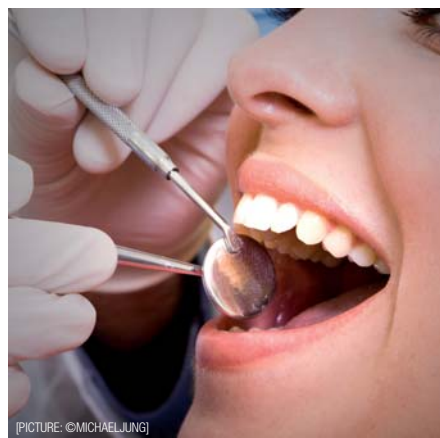

Using ParoChip, many manual steps involved in bacterial analysis can be avoided, Kuhlmeier said. In addition, the synthetic disks can be produced cheaply and are disposable, just like a single-use glove, he added.

To date, there is only a prototype of the device, which will be tested in clinical laboratories first. However, the researchers believe that it could also be used by dentists to carry out in-house analyses of patient samples in their practice in the future.

## Oral Health Care

### “Healthy Mouths, Healthy Lives”



Councilman Dan Halloran, Philips, and Dr Bernard Fialkoff DDS presented the Partnership for Healthy Mouths, Healthy Lives and the Ad Council's “Healthy Mouths, Healthy Lives” campaign at a

free oral health care event for 20 elementary aged Queens children at the Colonial Church's after-school program in Bayside, NY, this past week.

Dr Fialkoff, founder of the Fialkoff Dental Study Club, a dental educational group in Queens, learned about the Partnership for Healthy Mouths, Healthy Lives' campaign earlier this year which the Ad Council recently released to Capitol Hill and American dentists.

Dr Fialkoff encouraged all dentist members to do likewise at the group's October meeting. Mike Calia of Philips Oral Healthcare donated 20 “Sonicare for Kids” electronic toothbrushes.

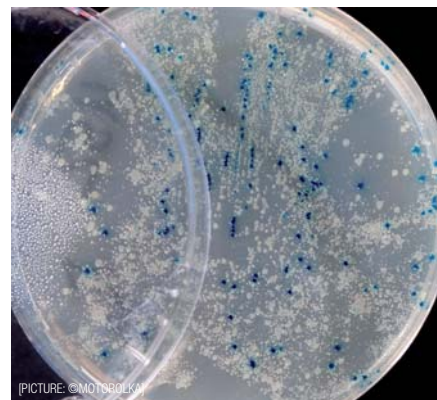
Victor Mimoni, staff representative of Councilman Dan Halloran, instructed the children on proper dental health.

## Gingivitis bacteria

### Manipulate immune system

New research from the US provides evidence that *Porphyromonas gingivalis*, the main agent of the chronic inflammatory disease periodontitis, also manipulates the human immune system. In a number of laboratory tests, scientists observed that the pathogen inhibits the body's defense processes that would normally destroy it.

In order to determine the manner in which *P. gingivalis* influences the immune system, the researchers treated cells from mice with an inhibiting antibody against Interleukin-10 (IL-10), an anti-inflammatory protein, while leaving a different portion of the same cells untreated. Afterwards, they tested whether the cells produced interferon-gamma (IFN- $\gamma$ ), a protein that has an immunostimulatory and antiviral effect.



According to the study, *P. gingivalis* stimulated the production of IL-10, which in turn inhibited the activity of T-cells and macrophages, and repressed the immune response. The researchers observed increased production of IFN- $\gamma$  in the treated cells, while no such growth was seen in the untreated cells.

The study highlighted the mechanism by which the pathogen establishes a chronic infection. “These bacteria go beyond merely evading our body's defense and actually manipulate our immune system for their own survival,” the researchers said. The findings suggested that the damage done by the bacterium occurs when the immune cells of the host are first exposed to the pathogen. With regard to successful treatment, the results demonstrated the importance of a very early intervention.



Eco-Dentistry Association to hold

## First Green Dentistry Conference

The Eco-Dentistry Association, an international association of dental professionals that promotes earth-friendly dentistry, has announced that it will be holding the first conference devoted to high-tech, environmentally sound dental practices. The event will take place on 3 and 4 May at the Redford Conference Center in Provo, Utah.

The conference will showcase the information and products needed to create and maintain state-of-the-art green practices. In this regard, it will feature a number of lectures about branding and marketing a green dental practice, as well as a presentation about how dental technologies can reduce waste and save energy. Participants may earn continuing education credits, the EDA announced. During the meeting, panel discussions will be held on various topics, from building and financing to creating a successful green hygiene program. Participants will have the opportunity to attend small-group hands-on courses for dental

technology such as laser and CAD/CAM systems.

In order to promote the overall health and well-being of the attendees, optional morning yoga and meditation courses will be held, in addition to presentations focusing on the importance of work-life balance. After the conference, participants can join a hiking tour in the 6,000 acres of pristine wilderness adjacent to the Sundance Resort on May 5.

Anyone interested can register for the event on the EDA's website, [www.ecodentistry.org/conference](http://www.ecodentistry.org/conference). However, attendance is limited to the first 100 registrants, the association said.

The EDA was founded by Dr Fred Pockrass and his wife Ina Pockrass, who created the model for eco-



[PICTURES: ©PADOVA, ©VECTOMART]

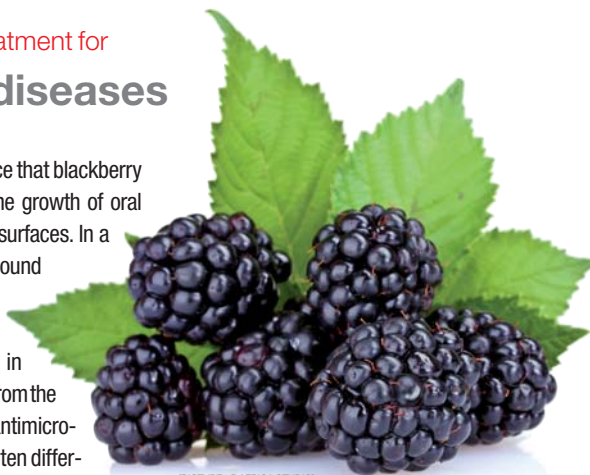friendly dentistry, which includes methods such as reducing waste and pollution, as well as saving energy, water and money. Their practice in Berkeley, CA, was the first in the country to be certified as a green business.

Blackberries: possible treatment for

## Oral bacterial diseases

New research has provided evidence that blackberry extract could be used to control the growth of oral pathogens on dental and mucosal surfaces. In a number of tests, the researchers found that it inhibited the metabolic activity of the causative agents of periodontal disease and dental caries in particular. In the study, researchers from the University of Kentucky tested the antimicrobial effects of blackberry extract on ten different oral bacteria. Among others, they observed that the extract significantly reduced the metabolic activity of *Porphyromonas gingivalis* and *Fusobacterium nucleatum*, two pathogens known to cause periodontal diseases, by about 40 per cent, and that it inhibited *Streptococcus mutans*, the primary agent of dental caries, by approximately 30 per cent. In addition, they found that at higher concentrations the extract had the ability to kill oral bacteria.

To date, mouth rinse containing chlorhexidine, a chemical antiseptic, has been one of the most effective antimicrobial agents against the colonization of oral bacteria responsible for gingivitis and periodonti-



[PICTURE: ©AFRICA STUDIO]

tis. However, its side effects, such as staining and abrasion, limit its prolonged use as antimicrobial agent by the general population. Thus, blackberry extract might be a promising adjunct for prevention and treatment of periodontal infections, the scientists concluded.

Although the mechanisms underlying the antimicrobial effects are not fully understood, the researchers suggested that berry-derived polyphenols, which can be found in red wine, citrus and black tea too, could be involved in the process. The study will be published in the February issue of the Journal of Periodontal Research.

Complete tooth loss after

## Extensive consume of soft drinks

According to recent news reports, Australian dentists have had to remove all the teeth from the mouth of a 25-year-old owing to overindulgence in soft drinks. The man had apparently drunk up to eight litres of soft drink each day for the last three years. As reported by online newspaper *adelaidenow*, William Kennewell is highly addicted to sugary drinks and ignored dentists' repeated warnings about the possible danger to his oral health. He said he drank six to eight litres a day. His addiction had not only led to severe tooth decay, leaving him with only 13 teeth, but also caused blood poisoning, which improved after his teeth were removed and replaced with dentures, the newspaper reported. Only recently, a study among 16,500 Australian children revealed that more than half of the children in the country consume at least one soft drink per day. Health experts have consequently called for tooth-decay warnings on sugar-sweetened beverages.



[PICTURE: ©BOULE]



# laser

international magazine of laser dentistry



#### Publisher

Torsten R. Oemus  
[oemus@oemus-media.de](mailto:oemus@oemus-media.de)

#### CEO

Inggolf Döbbecke  
[doebbecke@oemus-media.de](mailto:doebbecke@oemus-media.de)

#### Members of the Board

Jürgen Isbaner  
[isbaner@oemus-media.de](mailto:isbaner@oemus-media.de)

Lutz V. Hiller  
[hiller@oemus-media.de](mailto:hiller@oemus-media.de)

#### Chief Editorial Manager

Norbert Gutknecht  
[ngutknecht@ukaachen.de](mailto:ngutknecht@ukaachen.de)

#### Co-Editors-in-Chief

Samir Nammour  
Jean Paul Rocca

#### Managing Editors

Georg Bach  
Leon Vanweersch

#### Division Editors

Matthias Frentzen  
*European Division*

George Romanos  
*North America Division*

Carlos de Paula Eduardo  
*South America Division*

Toni Zeinoun  
*Middle East & Africa Division*

Loh Hong Sai  
*Asia & Pacific Division*

#### Senior Editors

Aldo Brugneira Junior  
Yoshimitsu Abiko  
Lynn Powell  
John Featherstone  
Adam Stabholz  
Jan Tuner  
Anton Sculean

#### Editorial Board

Marcia Martins Marques, Leonardo Silberman, Emna Ibrahim, Igor Cernavin, Daniel Heyselaer, Roeland de Moor, Julia Kamenova, T. Dostalova, Christliebe Pasini, Peter Steen Hansen, Aisha Sultan, Ahmed A Hassan, Marita Luomanen, Patrick Maher, Marie France Bertrand, Frederic Gaultier, Antonis Kallis, Dimitris Strakas, Kenneth Luk, Mukul Jain, Reza Fekrazad, Sharonit Sahar-Helft, Lajos Gaspar, Paolo Vescovi, Marina Vitale, Carlo Fornaini, Kenji Yoshida, Hideaki Suda, Ki-Suk Kim, Liang Ling Seow, Shaymant Singh Makhan, Enrique Trevino, Ahmed Kabir, Blanca de Grande, José Correia de Campos, Carmen Todea, Saleh Ghabban Stephen Hsu, Antoni Espana Tost, Josep Arnabat, Ahmed Abdullah, Boris Gaspirc, Peter Fahlstedt, Claes Larsson, Michel Vock, Hsin-Cheng Liu, Sajee Sattayut, Ferda Tasar, Sevil Gurgan, Cem Sener, Christopher Mercer, Valentin Preve, Ali Obeidi, Anna-Maria Yannikou, Suchetan Pradhan, Ryan Seto, Joyce Fong, Ingmar Ingenegeren, Peter Klee- mann, Iris Brader, Masoud Mojahedi, Gerd Volland, Gabriele Schindler, Ralf Borchers, Stefan Grümer, Joachim Schiffer, Detlef Klotz, Herbert Deppe, Friedrich Lampert, Jörg Meister, Rene Franzen, Andreas Braun, Sabine Sennhenn-Kirchner, Siegfried Jänicke, Olaf Oberhofer, Thorsten Kleinert

#### Executive Producer

Gernot Meyer  
[meyer@oemus-media.de](mailto:meyer@oemus-media.de)

#### Designer

Sarah Fuhrmann  
[s.fuhrmann@oemus-media.de](mailto:s.fuhrmann@oemus-media.de)

#### Customer Service

Marius Mezger  
[m.mezger@oemus-media.de](mailto:m.mezger@oemus-media.de)

#### Published by

Oemus Media AG  
Holbeinstraße 29  
04229 Leipzig, Germany  
Tel.: +49 341 48474-0  
Fax: +49 341 48474-290  
[kontakt@oemus-media.de](mailto:kontakt@oemus-media.de)  
[www.oemus.com](http://www.oemus.com)

#### Printed by

Silber Druck oHG  
Am Waldstrauch 1  
34266 Niestetal, Germany

#### laser

international magazine of laser dentistry  
is published in cooperation with the World Federa-  
tion for Laser Dentistry (WFLD).

#### WFLD President

University of Aachen Medical Faculty  
Clinic of Conservative Dentistry  
Pauwelsstr. 30  
52074 Aachen, Germany  
Tel.: +49 241 808964  
Fax: +49 241 803389644  
[ngutknecht@ukaachen.de](mailto:ngutknecht@ukaachen.de)  
[www.wfld-org.info](http://www.wfld-org.info)

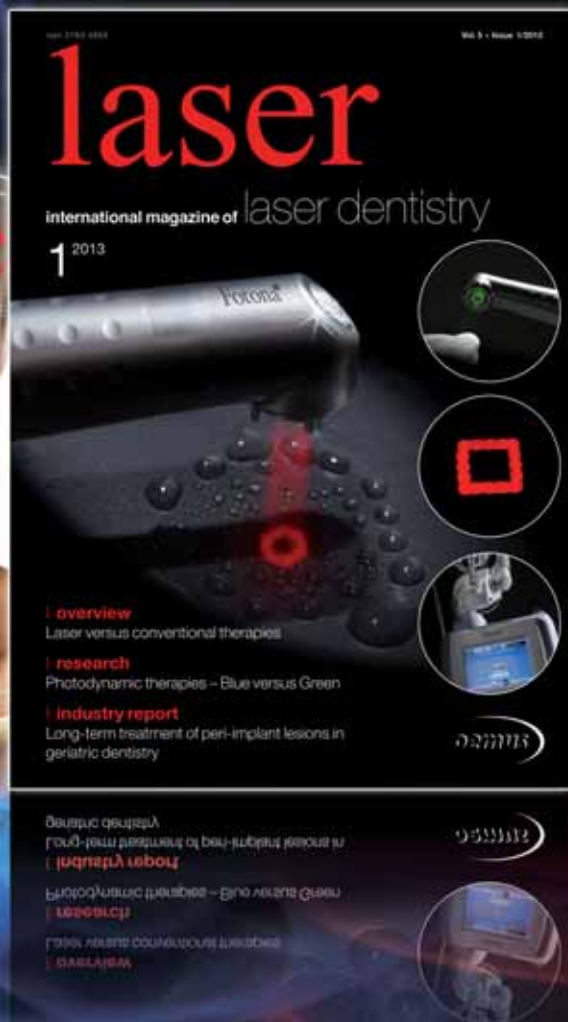#### Copyright Regulations

\_laser international magazine of laser dentistry is published by Oemus Media AG and will appear in 2013 with one issue every quarter. The magazine and all articles and illustrations therein are protected by copyright. Any utilization without the prior consent of editor and publisher is inadmissible and liable to prosecution. This applies in particular to duplicate copies, translations, microfilms, and storage and processing in electronic systems.

Reproductions, including extracts, may only be made with the permission of the publisher. Given no statement to the contrary, any submissions to the editorial department are understood to be in agreement with a full or partial publishing of said submission. The editorial department reserves the right to check all submitted articles for formal errors and factual authority, and to make amendments if necessary. No responsibility shall be taken for unsolicited books and manuscripts. Articles bearing symbols other than that of the editorial department, or which are distinguished by the name of the author, represent the opinion of the afore-mentioned, and do not have to comply with the views of Oemus Media AG. Responsibility for such articles shall be borne by the author. Responsibility for advertisements and other specially labeled items shall not be borne by the editorial department. Likewise, no responsibility shall be assumed for information published about associations, companies and commercial markets. All cases of consequential liability arising from inaccurate or faulty representation are excluded. General terms and conditions apply, legal venue is Leipzig, Germany.

# laser

international magazine of laser dentistry



**Subscribe now!**

You can also subscribe via  
[www.oemus.com/abo](http://www.oemus.com/abo)

I would like to subscribe to **laser** international magazine of laser dentistry (4 issues per year) for € 44 including shipping and VAT for German customers, € 46 including shipping and VAT for customers outside Germany, unless a written cancellation is sent within 14 days of the receipt of the trial subscription. The subscription will be renewed automatically every year until a written cancellation is sent to OEMUS MEDIA AG, Holbeinstr. 29, 04229 Leipzig, Germany, six weeks prior to the renewal date.

► Reply via Fax +49 341 48474-290 to OEMUS MEDIA AG or per E-mail to [grasse@oemus-media.de](mailto:grasse@oemus-media.de)

Last Name, First Name

Company

Street

ZIP/City/County

E-mail

Signature

Notice of revocation: I am able to revoke the subscription within 14 days after my order by sending a written cancellation to OEMUS MEDIA AG, Holbeinstr. 29, 04229 Leipzig, Germany.

Signature

# The Dual Wavelength *waterlase*\*iPlus™

## Advancing Laser Technology to Its Ultimate

### INTUITIVE & INTELLIGENT GRAPHICAL USER INTERFACE

For example, performing a Class I Cavity Prep with the iPlus™ is as easy as 1,2,3...

- Step 1** Select "Restorative" from the first screen
- Step 2** Choose "Class I" from the next screen that appears automatically
- Step 3** Specify any other concerns such as patient sensitivity or bond strength  
*That's it! Step on the foot pedal, and start working.*

### iLASE™ 940nm DIODE LASER DOCKING STATION

- + Adds dual wavelength versatility and convenience
- + First totally wireless dental laser
- + 5 Watts peak power with ComfortPulse™
- + Battery operated with finger switch activation
- + Exclusive bendable tips in many diameters & lengths



### BREAKS THE SPEED BARRIER

- + RR™ powered laser delivers 100 pulses/sec. for superior soft-tissue cutting
- + Patented laser technology delivers 10 watts of power
- + Enables multi-quadrant same-day procedures



### ENABLES BIOLOGICALLY FRIENDLY DENTISTRY

- + No micro-fractures or thermal damage
- + More precise, minimally invasive



### PROVIDES GREAT RETURN ON INVESTMENT

- + Increases treatment acceptance of day-to-day restorative cases
- + Attracts new patients
- + Increases productivity and enables new procedures

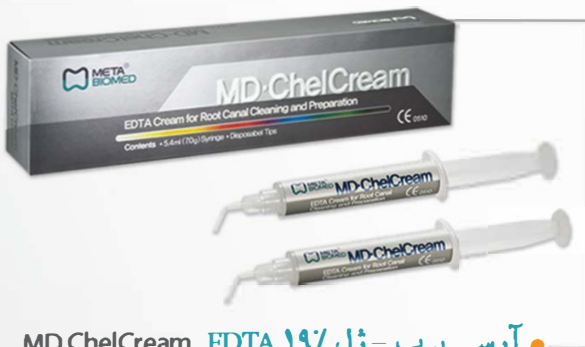

©2012



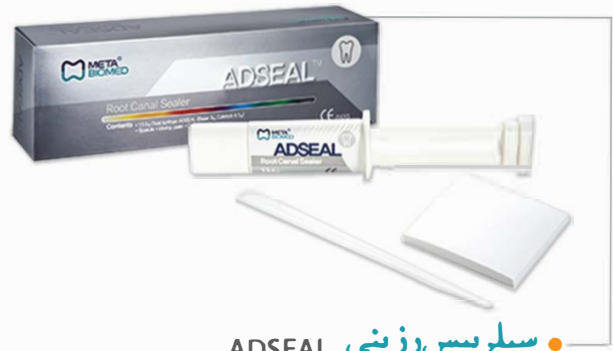

**آزاد تجارت پارس**  
Medical & Dental Products



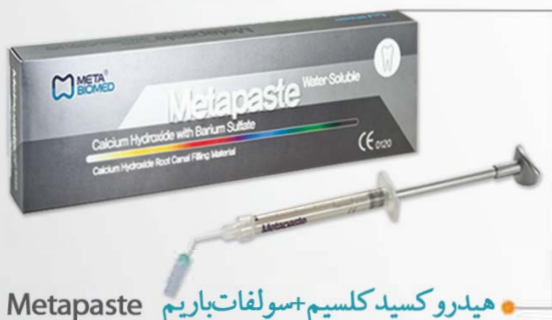• آرسی پرپ - ژل ۱۹% EDTA MD.ChelCream

- خاصیت lubricate
- ایجاد تمیزترین دیواره دنتینال پس از خارج کردن لایه جوش خورده
- خارج کردن مواد غیر عالی توسط شلاته کردن Chelation
- پاکسازی کانال ریشه و برداشتن لایه اسمیر
- استفاده راحت توسط نرم کردن دیواره کانال
- دو سرنگ ۷ گرمی



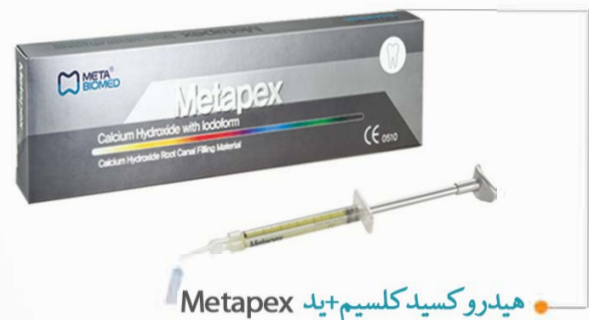• سیلریس رزینی ADSEAL

- رادیو اپسیتی خوب، زیمت سازگاری عالی
- سهولت اختلاط خود کاریس و کاتالیت
- عدم ایجاد تغییر رنگ در دندان
- نامحلول در مایعات بافتی
- سرنگ دو قلو ۱۳.۵ گرمی



• هیدروکسید کلسیم + سولفات باریم Metapaste

- پر کردن موقت ریشه
- مناسب جهت درمان کانال های لیکج دار، اپکیفیکاسیون
- سرنگ مخصوص برای انتقال به داخل کانال
- پالپ کینگ و پالپوتومی
- خمیر آماده مصرف قابل حل در آب



• هیدروکسید کلسیم + ید Metapex

- جذب مجدد داخلی و خارجی ریشه
- اثر آنتی باکتریال و رادیو اپک عالی
- پر کردن دائم کانال ریشه
- تشکیل دیواره بافت سخت در انتهای ریشه
- مناسب جهت کانال های لیکج دار و اپکیفیکاسیون
- درمانی آسان برای بستن دائمی اپکس در دندان های شیری