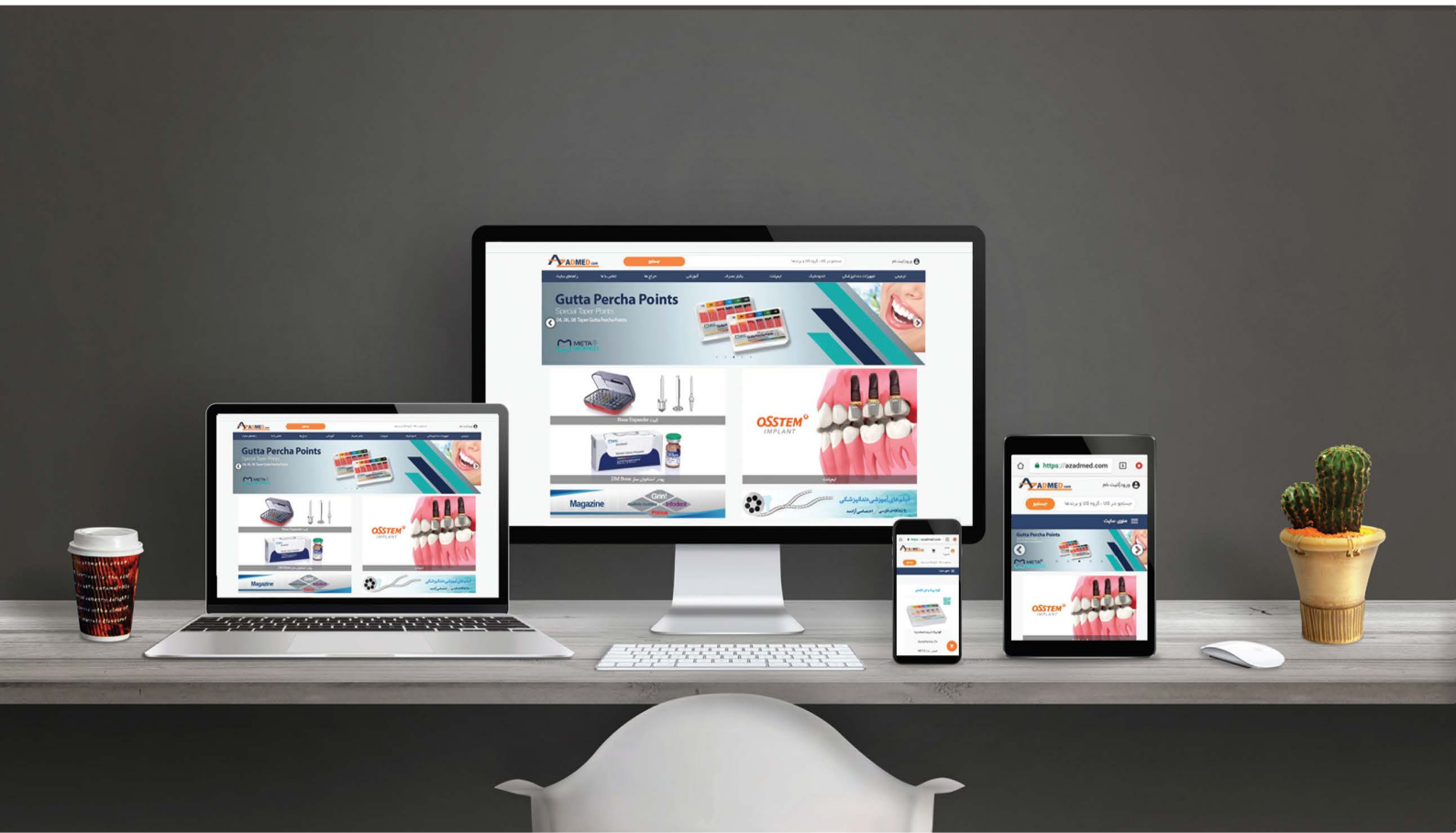




آزاد تجارت پارس
AZAD TEJARAT PARS.LTD

AZADMED.com



www.azadmed.com



 azaadtejaratpars

 @azadmed2

 88 98 80 63 - 6

laser

international magazine of laser dentistry

2²⁰¹⁴



| research

Diclofenac, dexamethasone or laser phototherapy?

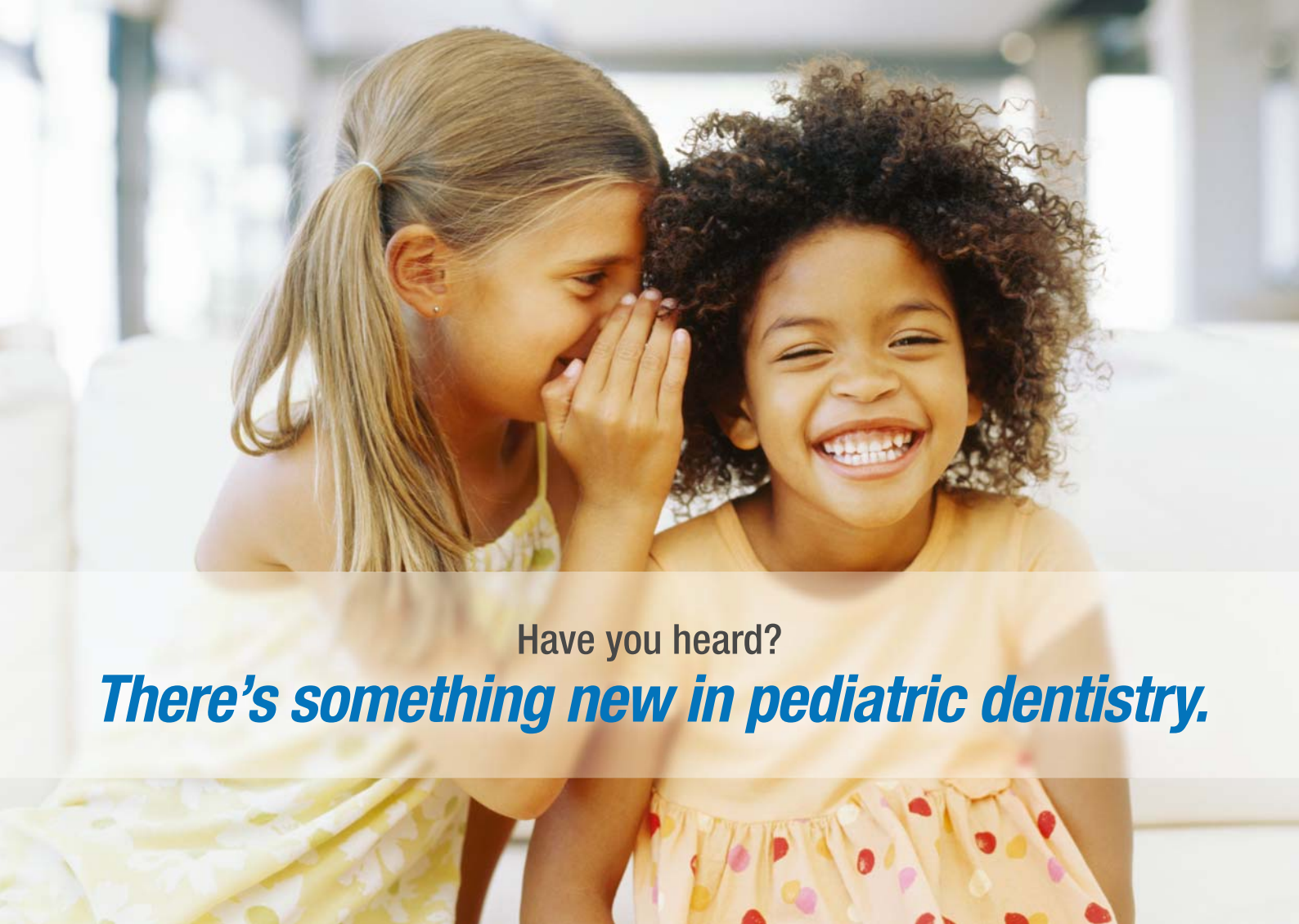| case report

Er,Cr:YSGG in laser-assisted aesthetic rehabilitation: A case report

| industry report

Innovative pathways for extensive and efficient tissue removal with Er:YAG laser





Have you heard?

There's something new in pediatric dentistry.

YOUR PEDIATRIC NEEDS ARE AS UNIQUE AS YOUR PATIENTS.

The WaterLase Pediatric Package from BIOLASE gives you both the technology and support to enhance your practice growth for kids of all ages. **Mom Approved.** Kid-friendly technology - *no shot, no drill** - that moms appreciate and talk about with other moms.



waterlase⁺iPlus
NO SHOT, NO DRILL DENTISTRY.*

Pedro Morales • BIOLASE Europe GmbH • Biolase.com
+34 679 986 593 • info@biolase-europe.com

BIOLASE

*Individual sensitivity to pain may vary. No shot in most cases. © 2014, BIOLASE, Inc. All rights reserved.

Preview on the 14th WFLD Congress in Paris



Prof. Dr Norbert Gutknecht
Editor-in-Chief

Dear colleagues,

Today, meeting all expectations participants and companies hold towards a congress has become a difficult task. Whereas in previous years, one would have attended a congress in order to expand one's knowledge with new findings, expectations towards congresses today are dominated more and more by its status as an event rather than its educational properties. Of course, both WFLD and the French organisers are open to this idea, but we also want to make sure that the congress features a programme in which the latest laser technologies and many documented case studies are presented and discussed. Of course, problems with regard to the competent integration and amortisation of laser applications in the dental practice are discussed as well.

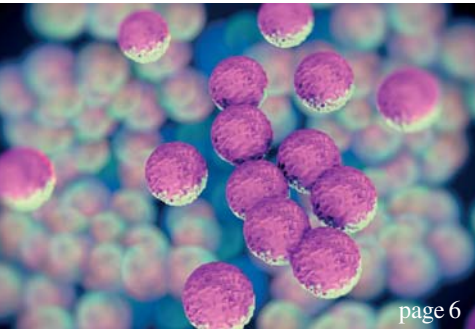
As the upcoming WFLD Congress and the Congress held by the OIWC take place at the same time and place, we came up with special topics including laser applications in implantology and periimplantitis therapy.

Last but not least: Of course, participants will meet other modern, future-oriented colleagues at the WFLD Congress in Paris. Looking forward to seeing you there!

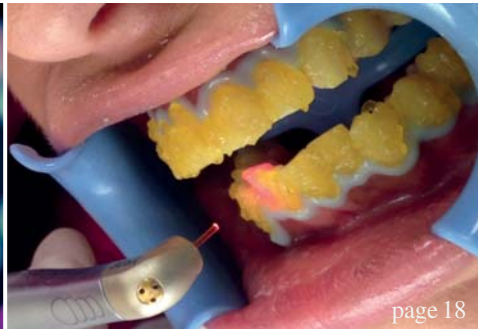
Warm regards,

A handwritten signature in black ink, appearing to read 'N. Gutknecht', written in a cursive style.

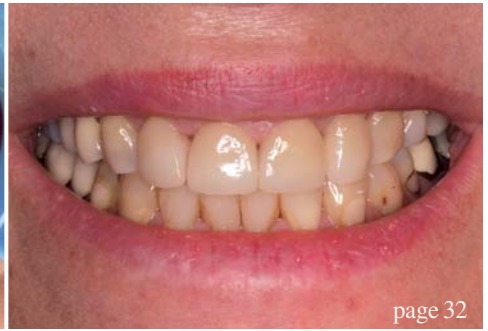Prof. Dr Norbert Gutknecht
Editor and CEO WFLD



page 6



page 18



page 32

| editorial

03 Preview on the 14th WFLD Congress in Paris
| Prof. Dr Norbert Gutknecht

| research

06 Diclofenac, dexamethasone or laser phototherapy?
| Jan Tunér

| overview

12 Laser activated irrigation—Part I
| Roeland Jozef Gentil De Moor *et al.*

| case report

18 Er,Cr:YSGG in laser-assisted aesthetic rehabilitation:
A case report.
| Dr Christina Boutsiouki *et al.*

| industry report

26 Periodontal decontamination in microsurgery
| Dr Fabrice Baudot

32 Innovative pathways for extensive and efficient tissue
removal with Er:YAG laser
| Dr Kresimir Simunovic

| education

38 Laser dentistry course for dental students in Thailand
| Associate Prof. Dr Sajee Sattayut *et al.*

| economy

40 Gain power at your laser clinics!
| Dr Anna Maria Yiannikos

| interview

42 Strong against bacteria—gentle to teeth and gingiva
44 “We still have a long way to go”
| Daniel Zimmermann

| meetings

46 Laser Dentistry in the City of Light
| Katrin Maiterth
48 Rimini show confirms that the future of dentistry
is digital

| news

49 News

| about the publisher

50 | imprint



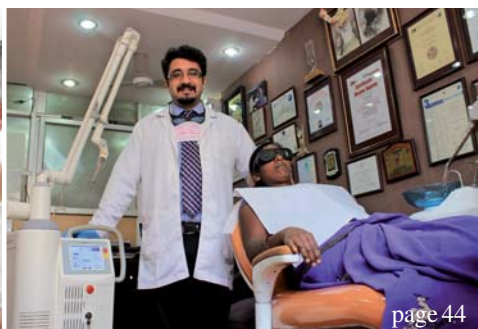
Cover image courtesy of Biolase,
www.biolase.com

background image: ©SmallAtomWorks

Artwork by Sarah Fuhrmann, OEMUS MEDIA AG.



page 40



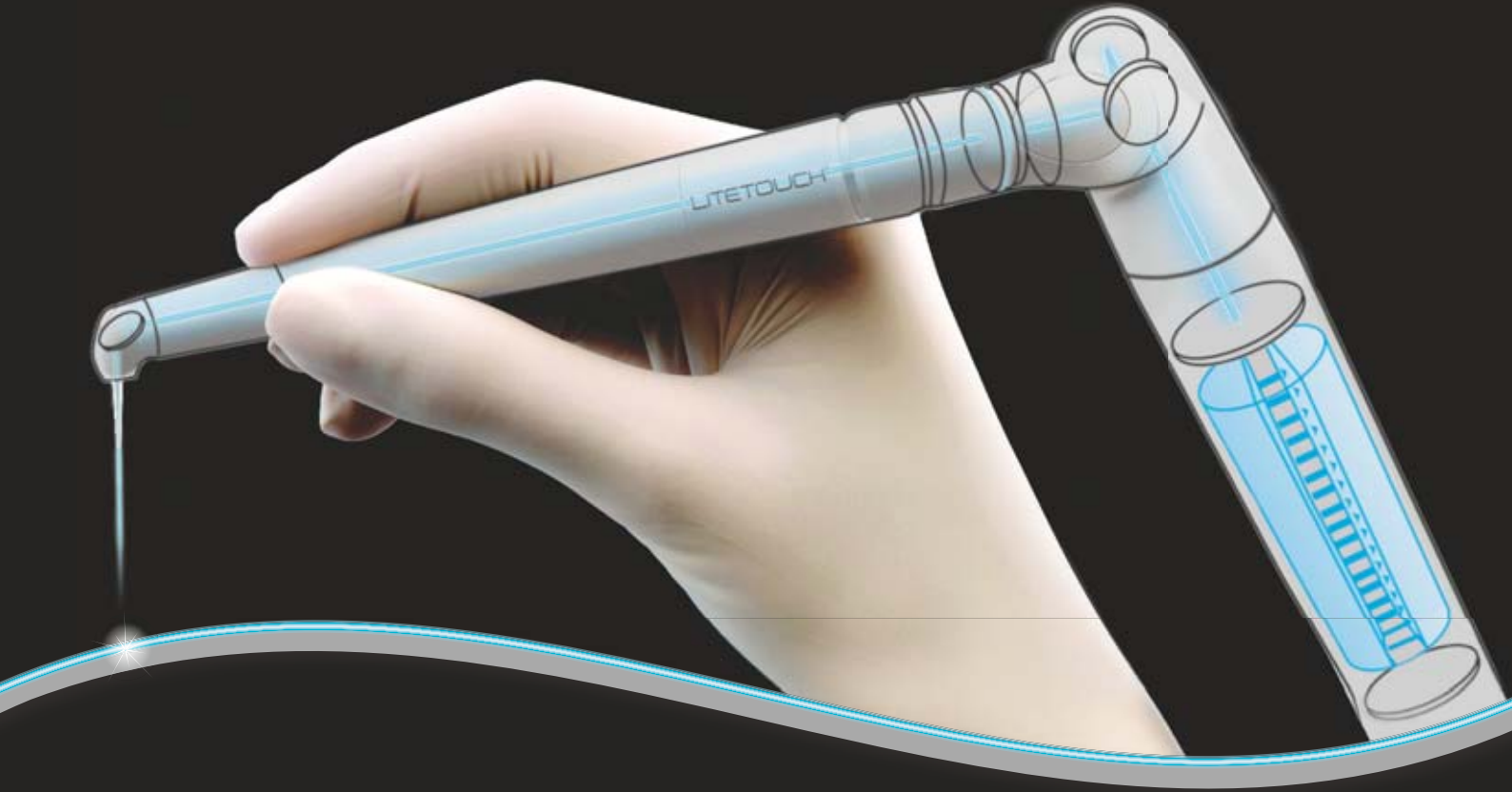
page 44



page 46

Syneron™
DENTAL LASERS

*Express
your mastery*



Education. Technology. Family.

Join the Syneron Dental Lasers Family at the WFLD 14th World Congress

Come and see the LiteTouch™ in action

The unique Er:YAG laser that has changed the face of laser dentistry

WFLD

Live presentations every hour at our booth in the WFLD 14th World Congress
July 2-4 2014 – “Maison de la Chimie” – 28, rue Saint-Dominique - Paris, France

Reserve your personal consultation at dental@syneron.com

WWW.SYNERONDENTAL.FR

WWW.SYNERONDENTAL.COM



Diclofenac, dexamethasone or laser phototherapy?

Part II

Author_Jan Tunér, Sweden

[PICTURE: ©ROBERT KNESCHKE]

Introduction

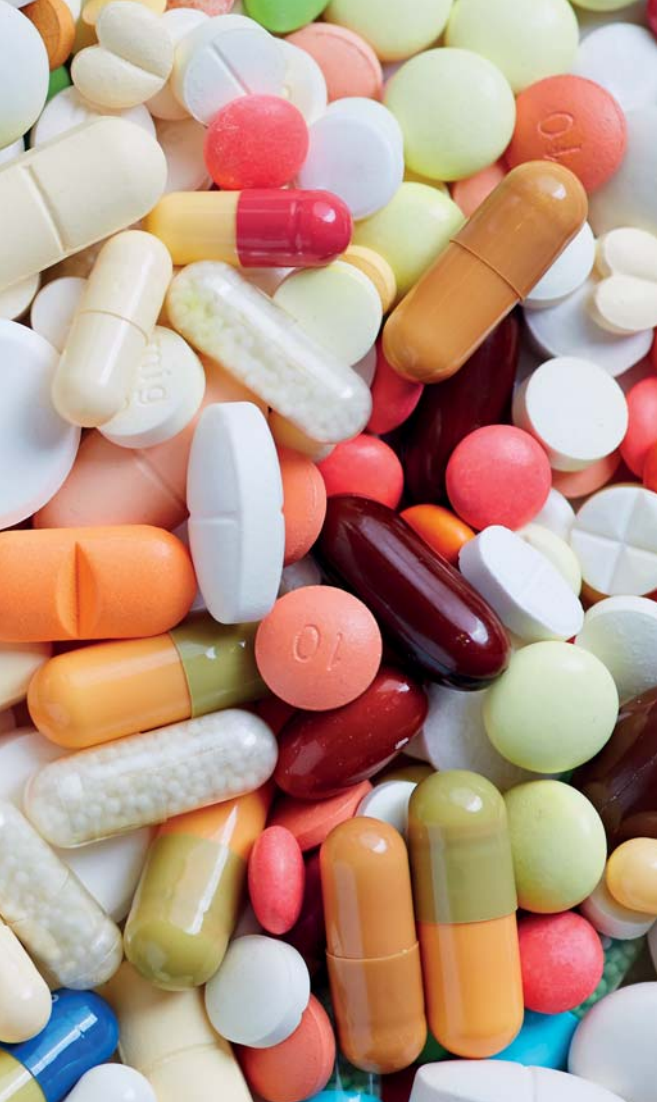In part I, the author informed about studies which investigated the effects of diclofenac and LPT. In the second part, they continue their investigation into the vast literature and studies on this topic and give their conclusion.

In the May 2013 edition of *Photomedicine and Laser Surgery*, the editorial written by Prof. Tina Karu is titled "Is it time to consider photobiomodulation as a drug equivalent?" Well, is it? Let us have a look and see what the literature has to say about two very popular drugs. Although the previously-mentioned studies indicate that LPT is as effective, or more effective as diclofenac, a potentiation of the effect of diclofenac by adding LPT is suggested in the following study:

The aim of the study by Markovic¹¹ was twofold: (1) to evaluate the postoperative analgesic efficacy, comparing long-acting and intermediate-acting local anaesthetics; and (2) to compare the use of laser irradiation and the non-steroid anti-inflammatory drug diclofenac, which are claimed to be among the most successful aids in postoperative pain control. A twofold study of 102 patients of both sexes undergoing surgical extraction of LTM

was conducted. In the first part of the study, twelve patients with bilaterally impacted lower molars were treated in a double-blind crossover fashion; local anaesthesia was achieved with 0.5% bupivacaine plain or 2% lidocaine with 1:80,000 epinephrine. In the second part of the study, 90 patients undergoing lower molar surgical extraction with local anaesthesia received postoperative laser irradiation (30 patients) and a preoperative single dose of 100 mg diclofenac (30 patients), or only regular postoperative recommendations (30 patients). The results of the first part of the study showed a strikingly better postoperative analgesic effect of bupivacaine than lidocaine/epinephrine (eleven out of twelve; four out of twelve, respectively, patients without postoperative pain). In the second part of the study, LPT irradiation significantly reduced postoperative pain intensity in patients premedicated with diclofenac, compared with the controls. Provided that basic principles of surgical practice have been achieved, the use of long-acting local anaesthetics and LPT irradiation enables the best postoperative analgesic effect and the most comfortable postoperative course after the surgical extraction of lower molars.

Dexamethasone is a corticosteroid, thus not an NSAID, but the issue of replacing pharmaceuticals



with long-term negative effects to a treatment with no side effect is urgent here as well.

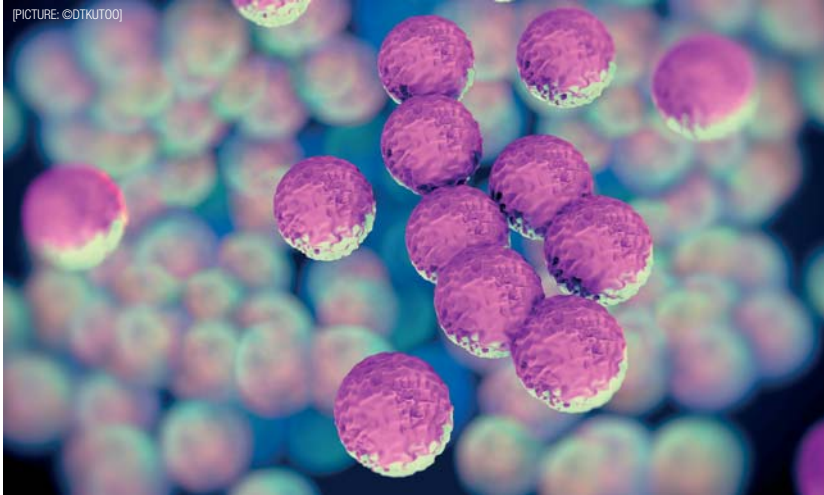
A rabbit model of endophthalmitis was established by Ma¹² to evaluate the anti-inflammatory effect of LPT as an adjunct to treatment for *Staphylococcus epidermidis endophthalmitis*. Rabbits were randomly divided into three groups to receive intravitreal injections into their left eye: group A received 0.5 mg vancomycin (100 µl), group B received 0.5 mg vancomycin + 0.2 mg dexamethasone (100 µl), and group C received 0.5 mg vancomycin (100 µl) and laser irradiation (10 mW, 632 nm) focused on the pupil. Slit lamp examination and B-mode ultrasonography were conducted to evaluate the symptoms of endophthalmitis. Polymorphonuclear cells and tumour necrosis factor alpha (TNF-α) in aqueous fluid were measured at 0 h, and one, two, three, seven and 15 days. A histology test was conducted at 15 days. B-mode ultrasonography and histology revealed that groups B and C had less inflammation than group A at 15 days. Groups B and C had fewer polymorphonuclear cells and lower levels of TNF-α in aqueous fluid than group A at two, three and seven days. There was no significant difference between groups B and C. There was no significant difference between groups A, B and C at 15 days. As an adjunct to vancomycin therapy to

treat *S. epidermidis endophthalmitis*, LPT has an anti-inflammatory effect similar to that of dexamethasone.

Castano¹³ tested LPT on rats that had zymosan injected into their knee joints to induce inflammatory arthritis. The author compared illumination regimens consisting of a high and low fluence (3 and 30 J/cm²), delivered at high and low irradiance (5 and 50 mW/cm²) using 810 nm daily for five days, with the positive control of conventional corticosteroid (dexamethasone) therapy. Illumination with a 810 nm laser was highly effective (almost as good as dexamethasone) at reducing swelling, and a longer illumination time (10 or 100 minutes compared to 1 minute) was more important in determining effectiveness than either the total fluence delivered or the irradiance. LPT induced reduction of joint swelling correlated with reduction in the inflammatory marker serum prostaglandin E2 (PGE2).

Reis¹⁴ investigated the role of extracellular matrix elements and cells during the wound healing phases following the use of LPT and anti-inflammatory drugs. Thirty-two rats were submitted to a wound inflicted by a 6-mm-diameter punch. The animals were divided into four groups: sham treated, those treated with the LPT (4 J/cm², 9 mW, 670 nm), those treated with dexamethasone (2 mg/kg), and those treated with both LPT and dexamethasone. After three and five days, the cutaneous wounds were assessed by histopathology using polarised light and ultrastructural assessments by transmission electron microscopy. Changes seen in polymorphonuclear inflammatory cells, oedema, mononuclear cells, and collagen fibre deposition were semi-quantitatively evaluated. The laser-treated group demonstrated increased collagen content and better arrangement of the extracellular matrix. Fibroblasts in these tissues increased in number and were more synthetically active. In the dexamethasone group, the collagen was shown to be non-homogenous and disorganised, with a scarcity of fibroblasts. In the group treated with both types of therapy, fibroblasts were more common and they exhibited vigorous rough endoplasmic reticulum, but they had less collagen production compared to those seen in the laser group. Thus, LPT alone accelerated post-surgical tissue repair and reduced oedema and the polymorphonuclear infiltrate, even in the presence of dexamethasone.

In a study by Jajarm¹⁵ thirty patients with erosive-atrophic OLP were randomly allocated into two groups. The experimental group consisted of patients treated with the 630 nm laser. The control group consisted of patients who used dexamethasone mouth wash. The response rate was defined



based on changes in the appearance score and pain score (VAS) of the lesions before and after each treatment. Appearance score, pain score, and lesion severity was reduced in both groups. No significant differences were found between the treatment groups regarding the response rate and relapse. The study demonstrated that LPT was as effective as topical corticosteroid therapy without any adverse effects and it may be considered as an alternative treatment for erosive-atrophic OLP in the future.

The aim of a study by Aimbire¹⁶ was to investigate if LPT can modulate the formation of haemorrhagic lesions induced by immune complex, since there is a lack of information on LPT effects in haemorrhagic injuries of high perfusion organs, and the relative efficacy of LPT compared to anti-inflammatory drugs. A controlled animal study was undertaken with 49 rats, randomly divided into seven groups. Bovine serum albumin i.v. was injected through the trachea to induce an immune complex lung injury. The study compared the effect of irradiation by a 650 nm laser with doses of 2.6 J/cm² to celecoxib, dexamethasone, and control groups for haemorrhagic index (HI) and myeloperoxidase activity (MPO) at 24 h after injury. The HI for the control group was 4.0. Celecoxib, laser, and dexamethasone all induced significantly lower HI than in the control animals at 2.5, 1.8 and 1.5, respectively. Dexamethasone, but not celecoxib, induced a slightly, but significantly lower HI than laser. MPO activity was significantly decreased at 1.6 in groups receiving celecoxib at 0.87, dexamethasone at 0.50, and laser at 0.7 when compared to the control group, but there were no significant differences between any of the active treatments. In conclusion, LPT at a dose of 2.6 J/cm² induces a reduction of HI levels and MPO activity in haemorrhagic injury, which is not significantly different from that obtained by celecoxib. Dexamethasone is slightly more effective than LPT in reducing HI, but not MPO activity.

In an effort to clarify the molecular based mechanism of the anti-inflammatory effects of laser irradiation, Abiko¹⁷ used a rheumatoid arthritis (RA) rat model with human rheumatoid synoviocytes (MH-7) challenged with IL-1, treated with laser or dexamethasone (DEX), monitored by gene expressions and analysed by the signal pathway database. RA rats were generated by the immunisation of type-II collagen, after which foot paws and knee joints became significantly swollen. The animals were laser treated and the swelling rates measured. MH-7 was challenged with IL-1 β and gene expression levels monitored, using the Affymetrix Gene Chip system, and the signal pathway database analysed using the Ingenuity Pathway Analysis (IPA) tool. LPT significantly reduced swellings in the rats' foot paws and knee joints and made it possible for them to walk on their hind legs. LPT altered many gene expressions of cytokines, chemokines, growth factors and signal transduction factors in IL- β induced MH-7. IPA revealed that LPT as well as DEX kept the MH7A at a normal state to suppress mRNA levels of IL-8, IL-1 β , CXC1, NFkB1 and FGF13, which were enhanced by IL-1 β treatment. However, certain gene expression of inflammatory factors were reduced by LPT, but were enhanced by DEX. LPT reduced inflammatory factors through altering signal pathways by gene expression levels. Interestingly, LPT altered useful targeted gene expressions, whereas DEX randomly altered many gene expressions, including the unwanted genes for anti-inflammation. Dexamethasone is a steroid known for having a long range of serious side effects. Thus, genome-based gene expression monitored by the Gene Chip system together with a signal pathway based database provide unprecedented access to elucidate the mechanism of the biostimulatory effects of LPT.

It has been suggested that LPT acts on pulmonary inflammation. Thus, Mafrade Lima¹⁸ investigated in a work if LPT (650 nm, 2.5 mW, 31.2 mW/cm², 1.3 J/cm², spot size of 0.08 cm² and irradiation time of 42 s) can attenuate oedema, neutrophil recruitment and inflammatory mediators in acute lung inflammation. Thirty-five male Wistar rats (n = 7 per group) were distributed in the following experimental groups: control, laser, LPS, LPS+laser and dexamethasone+LPS. Airway inflammation was measured 4 h post-LPS challenge. Pulmonary microvascular leakage was used for measuring pulmonary oedema. Bronchoalveolar lavage fluid (BALF) cellularity and myeloperoxidase (MPO) were used for measuring neutrophil recruitment and activation. RT-PCR was performed in lung tissue to assess mRNA expression of tumour necrosis factor-alpha (TNF-alpha), interleukin-1 β (IL-1 β), interleukin (IL-10), cytokine-induced neutrophil chemoattrac-



Master of Science (M.Sc.) in Lasers in Dentistry

Batch: EN2014 - Fulltime (new) or Module based

Next Start: **15 September 2014**

Aachen, Germany

4 semesters



Become part of the International Dental Elite

- Create new economic potential for your practice
- Two year career-accompanying postgraduate programme at the University of Excellence RWTH Aachen
- Combination of lectures, skill training sessions, live ops, tutorials, and practical workshops
- Internationally accepted and accredited by the German Government, the European Union, the Washington Accord and the Bologna Process
- Science-based and practice-orientated on highest national and international level
- Increased patient satisfaction: minimal contact reduced vibration and pain



RWTH INTERNATIONAL
ACADEMY
AACHEN UNIVERSITY

RWTH International Academy
Kackertstraße 10 | 52072 Aachen | Germany
phone +49 241 80 23543 | fax +49 241 80 92525
info@academy.rwth-aachen.de
www.academy.rwth-aachen.de

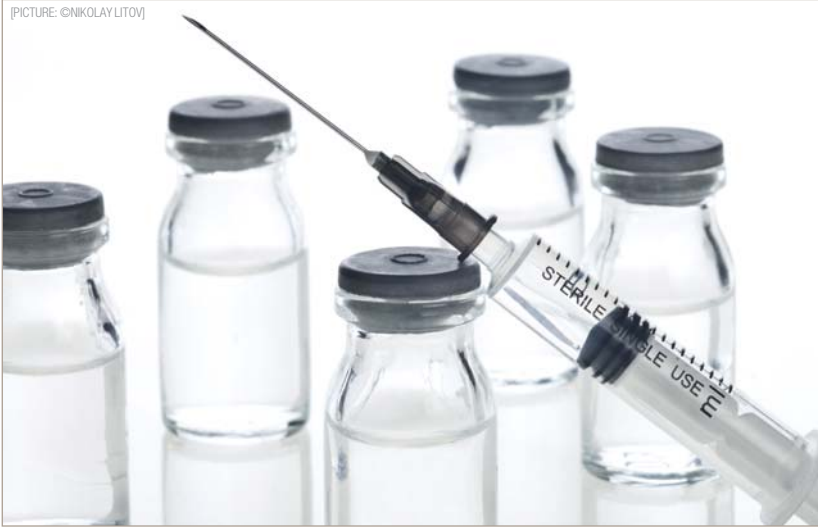PROFESSIONAL EDUCATION PROGRAMMES

AALZ

Aachen Dental Laser Center

AALZ GmbH
Pauwelsstraße 17 | 52074 Aachen | Germany
phone +49 241 47 57 13 10 | fax +49 241 47 57 13 29
info@aalz.de
www.aalz.de

[PICTURE: ©NIKOLAY LITOV]



tant-1 (CINC-1), macrophage inflammatory protein-2 (MIP-2) and intercellular adhesion molecule-1 (ICAM-1). Protein levels in both BALF and lung were determined by ELISA. LPT inhibited pulmonary oedema and endothelial cytoskeleton damage, as well as neutrophil influx and activation. Similarly, LPT reduced the TNF- α and IL-1 β , in lung and BALF. LPT prevented lung ICAM-1 up-regulation. The rise of CINC-1 and MIP-2 protein levels in both lung and BALF, and the lung mRNA expressions for IL-10, were unaffected. Data suggest that the LPT effect is due to the inhibition of ICAM-1 via the inhibition of TNF- α and IL-1 β .

Steroids are frequently used to treat inflammation. Some studies report a reduced effect of LPT in the presence of steroids, while others have found positive results of LPT even in the presence of steroids. However, steroids are known to delay wound healing through a reduction of leukocyte migration and a suppression of interleukins, while LPT is known to stimulate wound healing. In a study by Pessoa¹⁹, 48 rats were used, and after the execution of a wound on the dorsal region of each animal, they were divided into four groups ($n = 12$), receiving the following treatments: G1 (control), wounds and animals received no treatment; G2, wounds were treated with laser; G3, animals received an intraperitoneal injection of sodium phosphate of dexamethasone, dosage 2 mg/kg of body weight; G4, animals received steroids and wounds were treated with laser. The laser emission device used was a 904 nm unit, in a contact mode, with 2.75 mW gated with 2,900 Hz during 120 sec. After a period of three, seven and 14 days, the animals were sacrificed. The results showed that the wounds treated with steroid had a delay in healing, while laser accelerated the wound healing process. Additionally, wounds treated with laser in the animals, also treated with steroids, presented a differentiated healing process

with a larger collagen deposition as well as a decrease in both the inflammatory infiltrated and in the delay on the wound healing process. Laser accelerated healing, delayed by the steroids, acting as a biostimulative coadjuvant agent, balancing the undesirable effects of the steroids on the tissue's healing process. The effect of LPT is almost as potent as dexametasone but, again, without side effects.

In a study by Lara²⁰, 44 rats were treated with fluorouracil and, in order to mimic the clinical effect of chronic irritation, the palatal mucosa was irritated by superficial scratching with an 18-gauge needle. When all of the rats presented oral ulcers of mucositis, they were randomly allocated to one of three groups: group I was treated with laser (GaAlAs), group II was treated with topical dexamethasone, and group III was not treated. Excisional biopsies of the palatal mucosa were then performed, and the rats were killed. Tissue sections were stained with haematoxylin and eosin for morphological analyses, and with toluidine blue for mast-cell counts. Group I specimens showed higher prevalence of ulcers, bacterial biofilm, necrosis and vascularisation, while group II specimens showed higher prevalence of granulation tissue formation. There were no significant statistical differences in the numbers of mast cells and epithelial thickness between groups. For the present model of mucositis, rats with palatal mucositis treated with laser showed characteristics compatible with the ulcerative phase of oral mucositis, and rats treated with topical dexamethasone showed characteristics compatible with the healing phase of mucositis. Topical dexamethasone was more efficient in the treatment of rats' oral mucositis than the laser.

It has been suggested that LPT and dexamethasone (DEX) in combination do not bring about any advantages. But the following study suggests that LPT works even in an environment with DEX.

The study by Marchionni²¹ aimed to assess the effect of LPT associated with and without dexamethasone on inflammation and wound healing in cutaneous surgical wounds. Limited studies are directed at the possible interference of laser photobiomodulation on the formation of myofibroblasts, associated with an anti-inflammatory drug. Standard skin wounds were performed on 80 Wistar rats, distributed into four groups: no treatment (sham group), laser only (670 nm, 9 mW, 0.031 W/cm², 4 J/cm², single dose after surgery), dexamethasone only (2 mg/kg 1 h before surgery), and laser with dexamethasone. Tissue was examined histologically to evaluate oedema, presence of polymorphonuclear, mononuclear cells, and collagen. The analysis of myofibroblasts was assessed by immunohisto-

chemistry and transmission electron microscopy. The intensity was rated semi-quantitatively. The results showed that laser and dexamethasone acted in a similar pattern to reduce acute inflammation. Collagen synthesis and myofibroblasts were more intense in the laser group, whereas animals treated with dexamethasone showed lower results for these variables. In a combination of therapies, the synthesis of collagen and actin as well as desmin-positive cells was less than laser group. Laser was effective in reducing swelling and polymorphonuclear cells and accelerated tissue repair, even in the presence of dexamethasone.

The aim of a study by Garcia²² was to compare LPT as adjuvant treatment for induced periodontitis with scaling and root planing (SRP) in dexamethasone-treated rats. One-hundred twenty rats were divided into groups: D group (n = 60), treated with dexamethasone; ND group (n = 60) treated with saline solution. In both groups, periodontal disease was induced by ligature at the left first mandibular molar. After seven days, the ligature was removed and all animals were subjected to SRP. They were divided according to the following treatments: SRP, irrigation with saline solution (SS); SRP + LPT, SS and laser irradiation (660 nm; 24 J; 0.428 W/cm²). Ten animals in each treatment were killed after seven days, 15 days and 30 days. The radiographic and his-

tometric values were statistically analysed. In all groups, radiographic and histometric analysis showed less bone loss in animals treated with SRP + LPT in all experimental periods. SRP + LPT was an effective adjuvant conventional treatment for periodontitis in rats treated with dexamethasone.

Conclusion

From the above papers it is clear that LPT has an effect similar to that of dexamethasone. It is possibly not as strong as dexamethasone, but without the side effects. Thus, it is a promising alternative, especially for long term use. What still remains is a careful analysis about the optimal dosage windows for LPT.

Editorial note: A list of references is available from the publisher.

contact

laser

Jan Tunér

Spjutvagen 11
772 32 Grängesberg
Sweden

jan.tuner@swipnet.se

AD

[PICTURE: ©SERGEY NIVENS]



Publish – your – expertise

Hand in your article.

Please contact:





Editorial manager
Georg Isbaner
g.isbaner@oemus-media.de

Editor
Katrin Maiterth
k.maiterth@oemus-media.de

Laser activated irrigation

Part I: The power of the bubble

Authors _Roeland Jozef Gentil De Moor, Maarten Meire, Belgium

[PICTURE: ©VECTOR ILLUSTRATION]

_Introduction

Endodontic success is determined by the removal of remnants of vital and necrotic tissues, microorganisms and their microbial toxins from the root canal system.¹ Today, cleaning and shaping of the root canal is based on a sodium hypochlorite (NaOCl) supported root canal preparation followed by final rinsing with EDTA.² It is important that these irrigants come into contact with the root canal wall and biofilm (if present), especially in the apical third of the root canal system. Therefore, a number of mechanical devices have been introduced to improve the penetration and effectiveness of irrigation.³

_Laser fibre in dry root canal

In endodontics three types of investigations were performed with fibre lasers on the effect of direct irradiation of the root canal wall:

- Type I: Water absorption increases significantly at 1,450 nm. With the potential of near-IR lasers with wavelengths larger than 1,450 nm in removal of dental hard tissues, investigations were conducted on their use in the instrumentation of root canals.
- Type II: Investigations were also performed with wavelengths below 1,450 nm such as Nd:YAG

(1,032 nm), diodes (810, 830, 940, 980 nm) and KTP (532 nm) for the modification and cleaning of the root canal wall.

- Type III: Investigations examining the effect of direct irradiation with a laser fibre of the root canal wall on the eradication of bacteria.

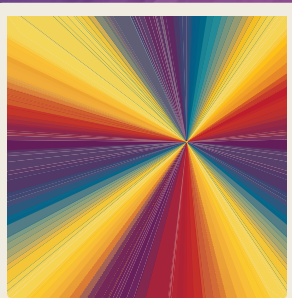
Up to 2006/2007, all these studies with high power lasers were performed with flat ending fibres. The studies had in common that a spiral motion of the laser fibre was needed in order to expose the root canal wall to the laser light. The findings were not always encouraging:

- In the type I studies,¹ canals treated with Erbium lasers resulted in significantly more debris than canals that were prepared with NiTi-rotaries,² laser instrumentation required twice as much time,³ and there was also a risk for creation of ledges and root canal wall irregularities.⁴ At the end, these type of lasers were considered to be adjuncts to mechanical instrumentation.
- The Nd:YAG laser is one of the most extensively investigated lasers in endodontics. Up to the end of the 1990s, it was also the most widely used laser in endodontics. Studies have demonstrated that the smear layer could be modified and typical aspects of glazing were described in these Type II studies.⁵ With the introduction of EDTA as a rinsing solution

**SAVE
THE DATE**

26–27 September, 2014
Düsseldorf, Germany
Hilton Hotel

**LASER
START UP
2014**



dgl. Deutsche
Gesellschaft für
laser
Zahnheilkunde e.V.

23rd

**Annual Congress
of the DGL e.V.**

Get the programme!

FAX REPLY

+49 341 48474-290

Further information about

LASER START UP 2014 23rd Annual Congress of the DGL e.V.

26–27 September, 2014, Düsseldorf, Germany.

NAME/E-MAIL

Office Stamp

laser 2/14

interacting with the smear layer, the need for the use of this wavelength for this type of laser-target interaction disappeared.⁶

- In type III studies, much of the work has been conducted with the Nd:YAG followed by the diodes. A study in 2010 by Hibst et al. demonstrated that high-power NIR laser bacterial killing is not caused by the light itself (photochemical effect).⁷ The exception are black pigmented bacteria when irradiation is performed with Nd:YAG.⁸ They found that the most important parameter was the maximum temperature, meaning that killing was the result of a photo thermal process. Hence, irradiation of the bacteria at low temperature does not result in killing.⁹ Furthermore, the spiral motion of the fibre did not allow for complete exposure of the root canal wall to the laser light.

Erbium lasers have also been investigated for this purpose (Type III studies). In general, when relying on a spiral motion of the fibre, the Nd:YAG proved to be more effective at reducing the number of CFU and at eradicating the bacteria in a biofilm when compared to Erbium lasers.¹⁰ However, when it was possible to expose the biofilm directly to the laser light, Er:YAG was significantly more effective in bacterial killing.⁹ With the introduction of radial firing tips, a better coverage of the root canal was expected.¹⁰ An increase of the disinfection effectiveness of the root canal with the Er,Cr:YSGG laser remained limited.^{10,11}

The era of the bubble

Limitations of the Erbium laser fibres

One of the problems with the Erbium lasers during disinfection of the root canal was the need to achieve a balance between sufficient power output for effective sterilization and avoidance of excessive morphological alterations or damage to root canal

wall dentine. The use of both Er:YAG and Er,Cr:YSGG may result in the creation of ledges due to their ablative nature. Effective sterilization could not be obtained at the lower power outputs.¹⁰⁻¹² Although Nd:YAG has a lower penetration depth in dentine and dentinal tubules than NaOCl,¹³ and taking into account that a direct exposure of the root canal wall to Erbium lasers for root canal disinfection is not possible yet, the 3-D sterilization of the root canal system with its anatomic aberrations remains impossible.

Free liquid environment

Of all IR lasers, the Er:YAG has the highest absorption in water.¹⁴ As the laser light can be delivered through a small-diameter fibre tip, this wavelength has already been used in a wide range of laser-assisted medical applications since the beginning of the century.^{15,16} The Erbium radiation delivered into liquid water through a submerged fibre tip is completely absorbed right beside the fibre tip due to the high absorption coefficient.¹⁷⁻²⁰

At the beginning of the laser pulse (0 to 50 μ s), the energy is absorbed in a 2 μ m layer that instantly heats over the boiling point and is turned into vapour. The time of the vapour formation depends on the pulse energy and the pulse duration.¹⁷ This vapour at high pressure starts expanding at high speed and provides an opening for the Erbium light in front of the fibre. As the laser continues to emit energy, the light passes through the bubble and evaporates the water surface at the front of the bubble. In this way, it drills a channel through the liquid until the pulse ends.¹⁸ This mechanism has been referred to as "the Moses effect in the microsecond region".²⁰

From the moment the emission of energy stops, the vapour cools and starts condensing. The internal pressure decreases and becomes lower than the pressure in the surrounding liquid. The result is the implosion of the bubble. The collapse of the bubble follows immediately. The implosion occurs near the tip of the fibre and results in the separation of the bubble from the fibre. During the collapse, a portion of energy stored in the bubble is converted into acoustic energy. This results in the emission of acoustic transients and shock waves.¹⁷ The cavitation generated pressure waves travel at supersonic speed (shock waves) in the beginning and at sonic speed (acoustic waves) later.^{21,22} Also a high-speed liquid jet is formed²³ and fluid surrounding the bubble quickly flows inside the decompressed vapour gap.

After the first large vapour bubble disappears, the shock wave abruptly and extensively changes



WFLD World Federation for Laser Dentistry

Formerly ISLD, founded in 1988



14th World Congress for **LASER DENTISTRY**



PARIS, July 2nd, 3th & 4th, 2014

**Maison de la Chimie
28, rue Saint-Dominique - 75007 Paris**

wfld@clq-group.com

THE 5TH INTERNATIONAL EVENT ORGANIZED BY

DENTAL LASER ACADEMY

www.dental-laser-academy.com

WFLD-paris2014.com




Fig. 1

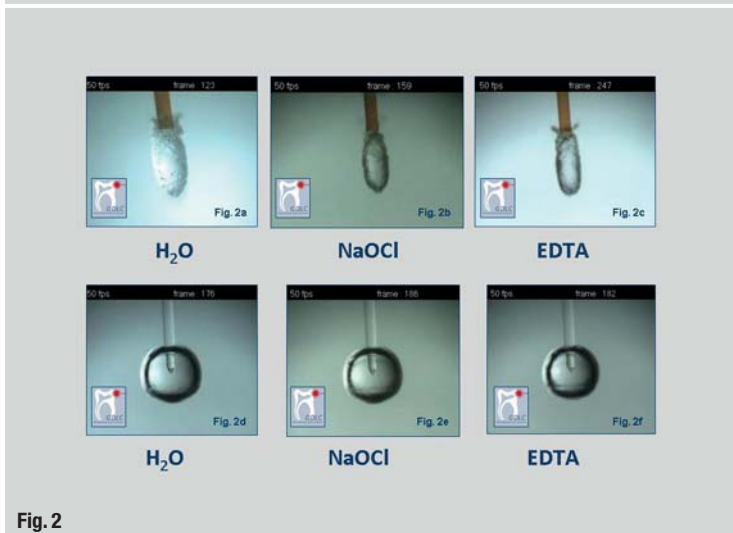

Fig. 2

Fig. 1 Frames captured at the beginning (a and b) and at the maximum size (c and d) of a vapour bubble. With the flat tip (BioLase MZ4 Ziptip) an elongated bubble is created (a and c). The radiation with the conical tip (BioLase MZ4 tip) results in a spherical bubble (b and d). Irradiation was performed with an Er,Cr:YSGG laser (Biolase) at 0.5 W – 20 Hz – 400 µm fibre.

Fig. 2 The frames are captured in three different liquids: Distilled water (H₂O), Sodium hypochlorite (NaOCl) and Ethylenediaminetetraacetic acid (EDTA). Radiation is performed with a flat tip (BioLase MZ4 Ziptip) (a, b and c) and with a conical tip (BioLase MZ4 tip) (d, e and f). Irradiation was performed with an Er,Cr:YSGG laser (Biolase) at 0.5 W – 20 Hz – 400 µm fibre.

the pressure of water around the laser tip, resulting in the nucleation of a number of new cavitation bubbles. This phenomenon is generally referred to as rebound. In this respect, Gibson described the so-called secondary cavitation which was generated around a primary cavity rebounding relatively far from a free surface, owing to the low pressure below the threshold value in the region of concern.²⁴ The low-pressure generation was reasonably explained as the result of the superimposed effect of the surrounding static pressure, decreasing as the cavity re-expanded, with the tension waves coming from the free surface. The second cavitation bubbles are much smaller compared with the first vapour bubble. When these second cavitation bubbles collapse, even smaller bubbles form and disappear repeatedly in decreasing numbers.

Important parameters that influence the bubble formation are pulse energy, pulse duration¹⁷ and pulse frequency (the latter more from the perspective that the pulse duration cannot always be changed). There is also the effect of tip design which may influence the shape of the laser-induced bub-

ble and the direction of the energy emission. The conventional laser tips are flat and end-firing generating a channel-like bubble, whereas conical fibre tips induce spherical bubbles (Fig. 1). There is also the optodynamic energy-conversion efficiency which refers to the ratio between the mechanical energy of the liquid medium and the pulse energy. When a conical tip is used, the efficiency is significantly larger and it increases with increasing pulse energy and decreasing pulse duration.¹⁷

Conventional laser-activated irrigation (C-LAI)

High-speed recordings of laser generated cavitation bubbles in glass models demonstrated that vapour bubbles were created at the end of the fibre. During these experiments, the fibre was positioned in the root canal. The form of the cavitation bubbles was identical to the ones in free liquid environment: the flat tip resulted in a cavitation bubble appearing as an elongated bubble with diffuse surface or the previously described channel like bubble. The conical tip resulted in the formation of a spherical bubble.¹⁸

In the study of de Groot et al., using an Er:YAG laser with a flat-ending fibre, the bubble grew with a velocity of the order of 1 m/s during the pulse duration. When the laser pulse ended, the bubble collapsed with a velocity of the order of 1 m/s.²⁵ When the bubble collapsed, secondary cavitation was seen with a relatively large bubble near the collapse site. The cycle of expansion and collapse of the cavitation bubble repeated for a number of times, until it was damped out within a few milliseconds. The laser bubble also grew predominantly in the coronal direction. For laser energy exceeding 120 mJ per pulse it was observed that some fluid was ejected from the root canal, leaving less irrigant in the root canal.²⁵

In the study of Blanken et al., using an Er,Cr:YSGG laser with a flat-ending fibre, bubbles up to a length of 3 to 3.5 mm were observed.¹⁸ The small canal prevented the vapour from expanding freely laterally, pushing the water both forward and backward in the canal. Since the water obstructs the expansion of vapour in the forward direction, the bubble also grows backwards along the fibre. The pressure inside the bubble remains high for a long time, since it has to fight against the resistance of the irrigant which has to be displaced in the small canal. The presence of secondary cavitation bubbles was also noted. In this study, it was emphasized that the creation of cavitation bubbles of this size in a root canal may result in the absence of irrigation solution between fibre and canal wall. Hence, there is a risk that the emitted energy can be absorbed by hydroxyapatite in the canal wall and may result in the damage of the root canal wall.

In the study of Matsumoto et al., using an Er:YAG laser with a conical tip with top angle degree of 84 degrees, large vapour bubbles were created.²¹ The maximum bubble length was 4.5 mm and the bubble expanded in vertical direction. The registrations were in line with the study of de Groot et al. and Blanken et al. The three studies also had in common that there were considerations with regards to safety to the patient and it was recommended not to position the fibre end too close to the apex (Blanken et al. recommend 5 mm from the most apical point of the preparation, Matsumoto et al. also used the fibre 5 mm short of the most apical end).

George and Walsh examined the extrusion of fluid through the apex following laser activation of irrigant with the Er:YAG and the Er,Cr:YSGGG, and with an end-firing and a radial firing tip placed 5 mm or 10 mm short from the most apical end.²⁶ Neither laser type nor tip design appeared to be significant variables. The amount of dye extrusion was higher in the laser groups than in the group with manual syringe irrigation. Also the position of the laser tip did not result in significantly different extrusion distances (the 5 mm group, however, had a generally greater amount of extrusion). One important parameter that was not taken into account was the presence of an intact periodontal ligament. Nevertheless, the risk of apical extrusion was brought to attention. The studies in the glass models also demonstrated that the form of the cavitation bubbles was identical to the ones in water. In this respect, Meire et al. demonstrated that the transmission spectra of endodontic irrigation solutions (a.o. NaOCl and EDTA) proved to follow the spectrum of pure water to a large extent.²⁷ A pilot study performed by the authors on the influence of fibre tip design and endodontic irrigant solutions on laser-activated cavitation with Er,Cr:YSGG demonstrated that there was no influence of the form of the cavitation bubble (Fig. 2).²⁸

Conventional LAI was reported to result in a significantly better debridement of artificial root canal wall grooves filled with artificially prepared dentin debris when comparing the use of PUI during 20 seconds with the use of C-LAI during 20 seconds (Er:YAG25 – Er,Cr:YSGG29). When comparing C-LAI during 20 seconds with PUI for 3 x 20 seconds, there was no statistically significant difference (however, there was a trend for better debridement scores for C-LAI with both Er:YAG and Er,Cr:YSGG).³⁰ A comparison between C-LAI (Er:YAG flat tip) during 20 seconds with LAI performed with the tip hovering over the entrance of the canal (H-LAI) (Er:YAG conical) and PUI during 20 seconds demonstrated significantly higher debridement scores for both C-LAI

and PUI than for H-LAI.³¹ There were no statistically significant differences between PUI and C-LAI.

In vitro studies investigating the bactericidal effect of C-LAI with the two types of fibre tips have not been published. At present, there is only a blind randomized controlled clinical trial with six month evaluation, where Er,Cr:YSGG was used with a radial firing tip combining C-LAI in distilled water (two times) and the spiral motion of the fibre in the dried canal (two times) in necrotic teeth with chronic apical periodontitis. This protocol was compared with the concomitant use of 3 % NaOCl and interim calcium hydroxide paste.³² There were no significant differences in terms of periapical healing between the two groups, however, they exhibited statistically significant decreases in PAI scores in favour of the laser protocol.

A comparison between the use of lasers for laser-activated irrigation with the fibre in the canal (C-LAI) versus fibre in the pulp chamber (H-LAI) will be made in Part II of this article in laser 3/2014.

Conclusion

Conventional Laser Activated Irrigation (C-LAI) with Erbium lasers, i.e. placement of the fibre tip in the proximity of the most apical end of the prepared root canal, used stationary or retracting until reaching the most coronal part of the root canal has the potential of better debridement of dentinal plugs along the root canal wall when compared to Passive Ultrasonic Irrigation. Investigations of the bactericidal effect of C-LAI have not yet been performed.

Editorial note: A list of references is available from the publisher.

_contact	laser
<p>Prof. Dr Roeland De Moor Ghent University Hospital Dental School De Pintelaan 185/P8 B-9000 Ghent, Belgium</p> <p>Tel.: +32 9332 4003</p> <p>roeland.demoor@ugent.be</p>	

Er,Cr:YSGG in laser-assisted aesthetic rehabilitation: A case report.

Authors Dr Christina Boutsiouki & Dr Dimitris Strakas, Greece

Introduction

The Er,Cr:YSGG laser is beyond doubt a very helpful tool in the hands of a trained practitioner in everyday practice. It can be used safely both for hard- and soft-tissue treatment, with minimal or no use of anaesthetic. Patients are always positive about and eager to undergo laser treatment owing to the comfort they enjoy compared to classical treatments.

The following case report details the case of a young female patient aged 28 who visited the post-graduate dental clinic at the Department of Operative Dentistry of the Aristotle University of Thessaloniki in Greece complaining about the colour of her teeth. After obtaining the medical and dental anamnesis of the patient, clinical and radiographic examination was performed to address any therapeutic (caries, periodontal or endodontic) problems.

During anamnesis, it was mentioned that the patient had undergone tooth whitening in a private

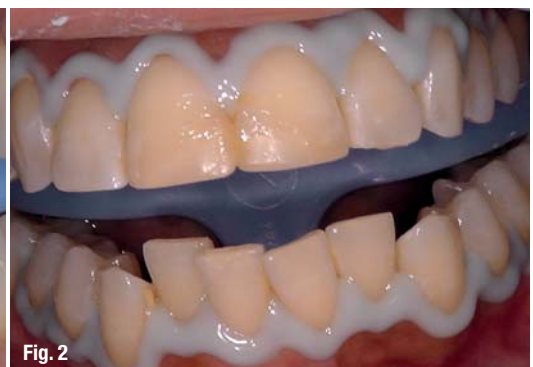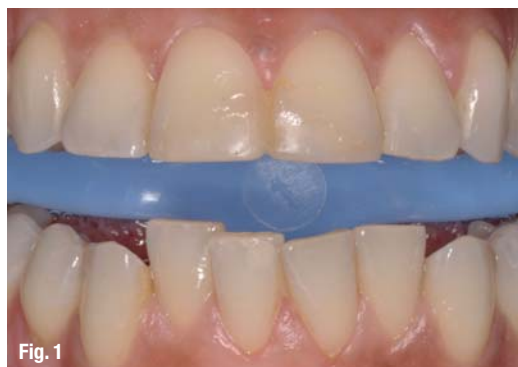dental office three to four years ago, but observed that the whitening result had not lasted. Clinical examination revealed old Class IV restorations with visible discolouration. The patient was informed that composite restorations cannot be whitened and replacement after tooth whitening would be necessary. It was also observed that the patient's smile extended up to the first premolars in both the maxillae and mandible. Moreover, soft-tissue melanchrosis was visible in several areas of patient's gingivae. Clinical and radiographic examination found no problems concerning the posterior teeth.

Er,Cr:YSGG-assisted tooth whitening

Discoloured teeth are a common concern of patients in modern society, as aesthetic demands rise constantly and people dream of a bright white smile. In order for dentists to keep up with these needs, aesthetic dentistry is constantly evolving, as new materials and techniques are introduced, giving us the opportunity to implement them in our offices. These range from conservative to invasive and include composite veneers, porcelain veneers, all-ceramic crowns and tooth whitening. Since

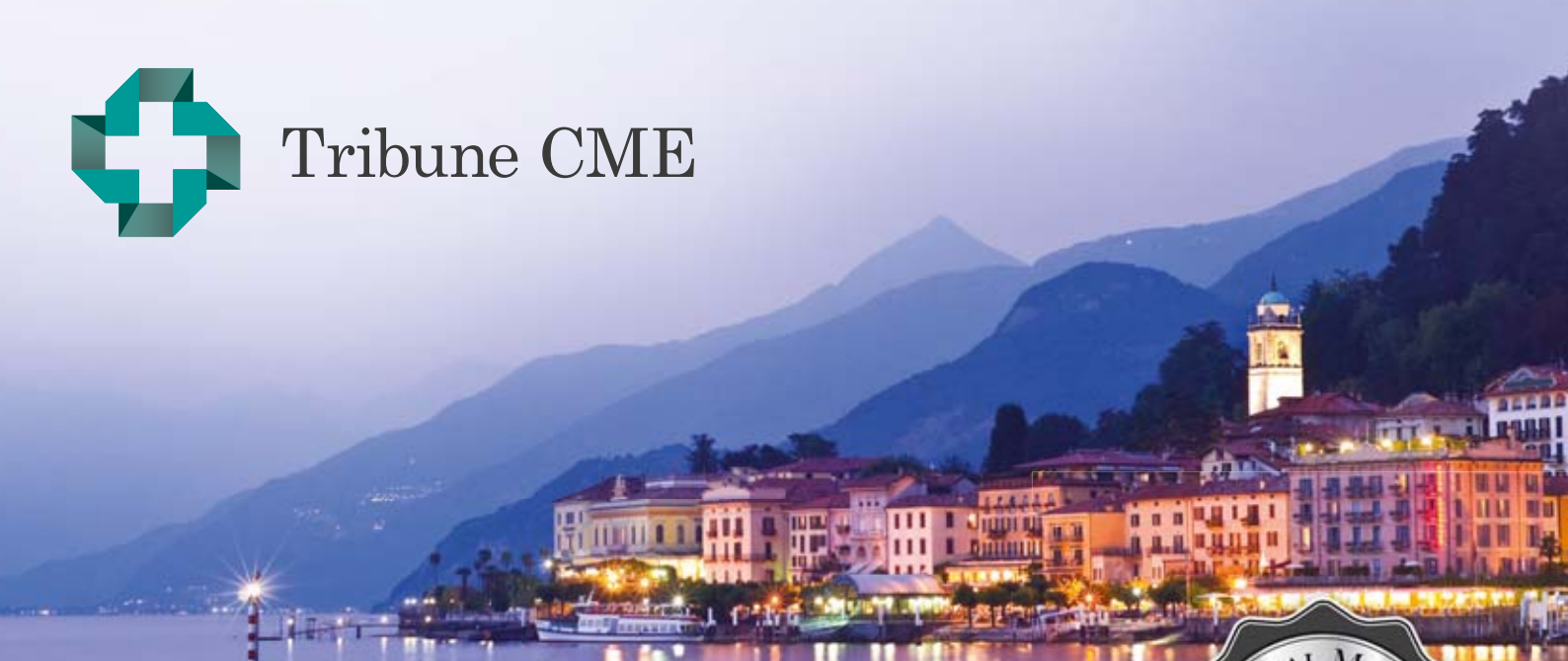Fig. 1_ The initial situation.

Fig. 2_ The gingival barrier.






Tribune CME



6 Months Clinical Masters Program in **Advanced Implant Aesthetics**

17 July 2014 to 22 November 2014, a total of 12 days of intensive live training
with the Masters in **Como (IT), Barcelona (ES), Munich (DE)**



Live surgery and **hands-on** with the masters in their own institutes plus online mentoring and on-demand learning at your own pace and location.

Learn from the Masters of Advanced Implant Aesthetics:



Registration information:

17 July 2014 to 22 November 2014
a total of 12 days in **Como (IT), Barcelona (ES), Munich (DE)**

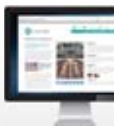Curriculum fee: € 11,900

Details on www.TribuneCME.com

contact us at tel.: +49 341 48474 302
email: request@tribunecme.com

Collaborate
on your cases

and access hours of
premium video training
and live webinars



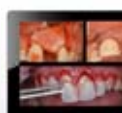University
of the Pacific

you will receive a
certificate from the
University of the Pacific



Latest iPad
with courses

all registrants receive
an iPad preloaded with
premium dental courses



100 ADA CERP
C.E. CREDITS

ADA C.E.R.P.® | Continuing Education
Recognition Program

Tribune America LLC is the ADA CERP provider. ADA CERP is a service of the American Dental Association to assist dental professionals in identifying quality providers of continuing dental education. ADA CERP does not approve or endorse individual courses or instructors, nor does it imply acceptance of credit hours by boards of dentistry.

Fig. 3_The whitening agent.

Fig. 4_Laser whitening.

Fig. 5_The silicone key.

Fig. 6_The final situation after laser treatment.

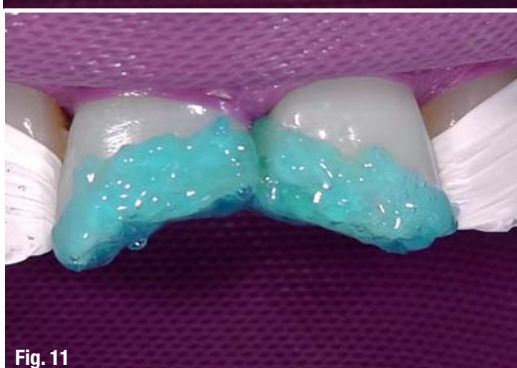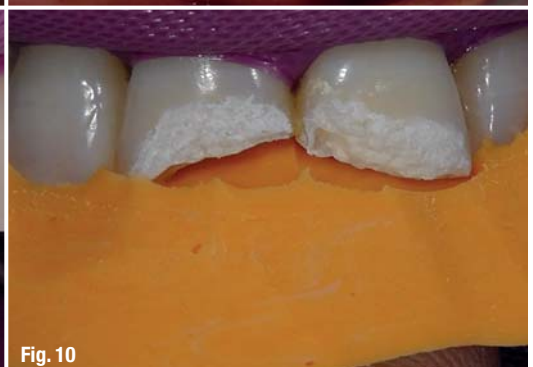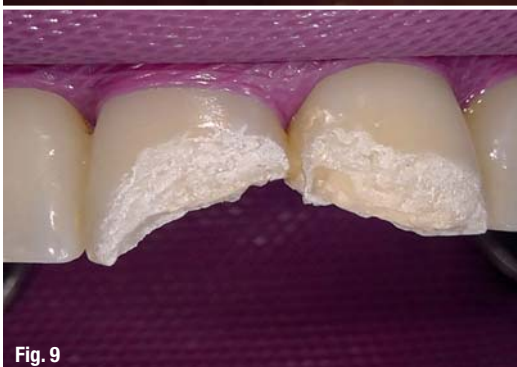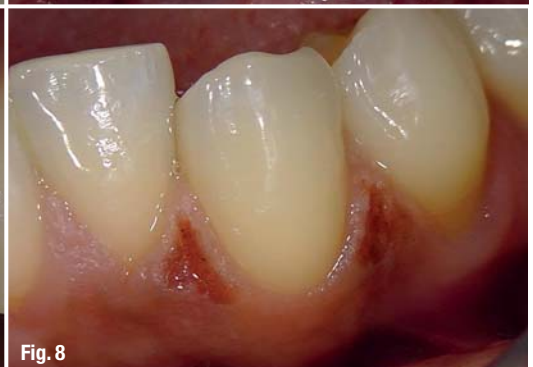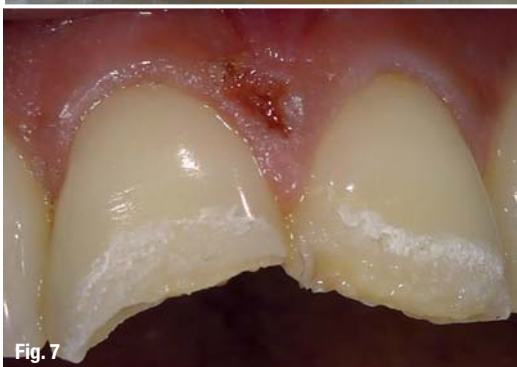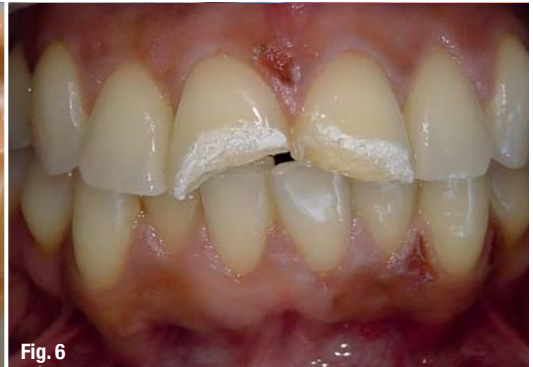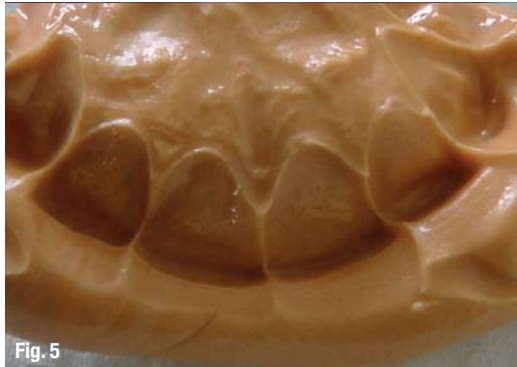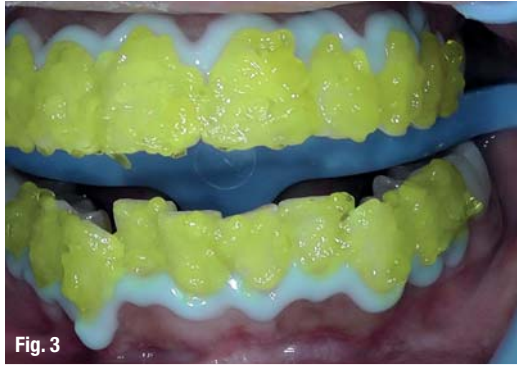Fig. 7_Laser treatment of the soft-tissue melanchrosis.

Fig. 8_Soft-tissue melanchrosis in the mandible.

Fig. 9_Rubber dam placement.

Fig. 10_Silicone key adjustment.

Fig. 11_Additional etching with 37% phosphoric acid.

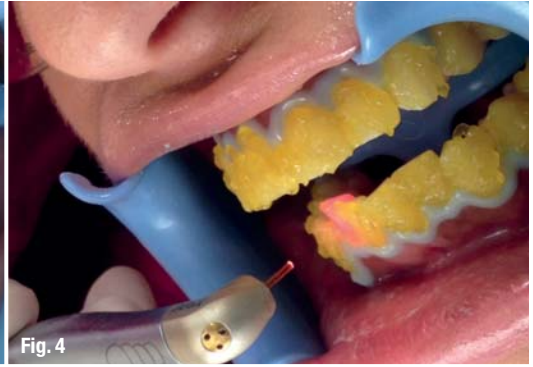

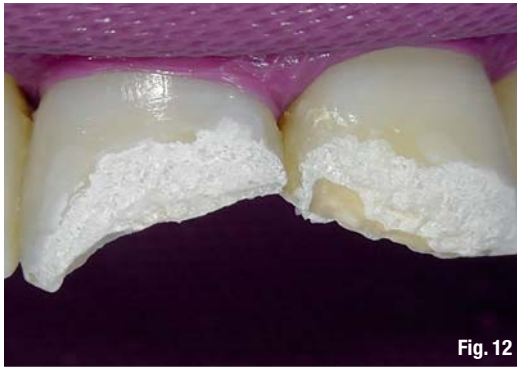


Fig. 12

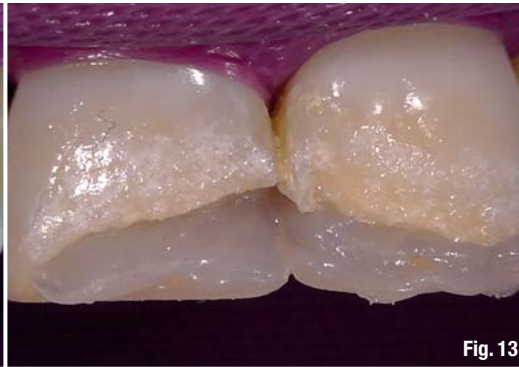

Fig. 13

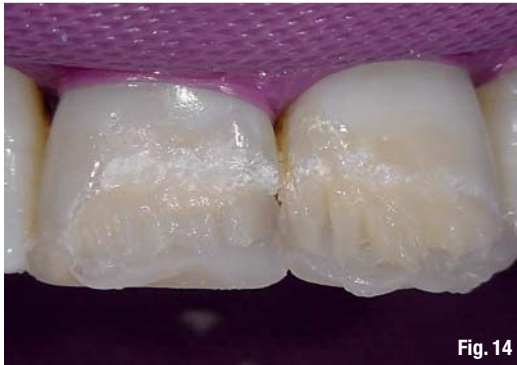

Fig. 14

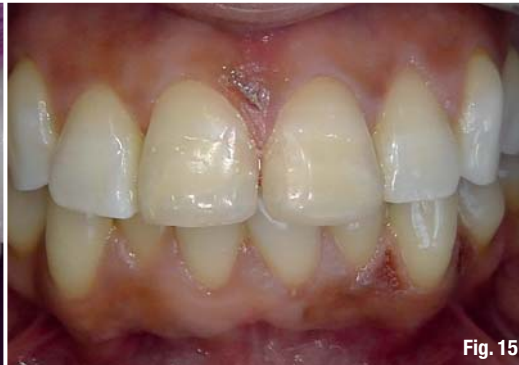

Fig. 15

Fig. 12_ The etched enamel.

Fig. 13_ The palatal enamel shade.

Fig. 14_ The dentine shade lobes.

Fig. 15_ The final restorations.

dental tissue is unable to regenerate, dentists should suggest the most conservative treatment that meets the patient's needs, allowing for procedures that are more invasive in the future.

Tooth whitening is the process through which a dentist alters the colour of the patient's teeth to appear whiter and brighter, and is considered one of the most conservative procedures in the field of aesthetic dentistry. This is made possible using various techniques and oxidising whitening agents to eliminate tooth discolouration. The main oxidising agents used are hydrogen peroxide in concentrations of 30–35% and carbamide peroxide in concentrations of 10–22%. The decomposition of these agents produces hydroperoxyl free radicals with a high whitening capability.

It is known that heating hydroxyl or carbamide peroxide accelerates its decomposition rate. By increasing the whitening agent's temperature by 10 °C, the speed of the decomposition is doubled. At this point, more hydroperoxyl free radicals are released and then the free radicals penetrate the porosities in the rodlike crystal structure of enamel and oxidise the inter-prismatic stain deposits.

Many different light sources, both coherent and incoherent, have been used to increase temperature during tooth whitening (e.g. plasma arc lamps, halogen lamps, light-emitting diodes and lasers). The advantages of the use of laser in tooth whitening include the speed of the procedure, the comfort of the

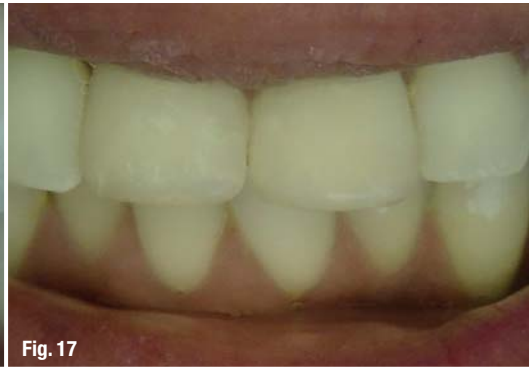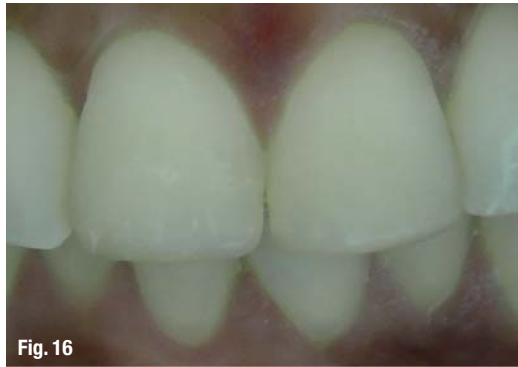patient and minimal to no post-treatment discomfort and sensitivity, which are often encountered in light-activated tooth whitening with incoherent light sources (e.g. plasma lamps). In a pulsed-mode operated laser, these advantages are more apparent owing to the fact that bursts of energy are directed to the whitening agent in a very short period, thus giving enough time for heat dissipation in the tissue and relief for the patient.

In order to achieve the best clinical results without harming teeth, it is crucial to follow the procedure carefully and to take all safety measures. Before starting the first session, the patient was informed that the result of the procedure is not permanent and is dependent on the age of the patient, the use of tobacco and extrinsic staining by the deposition of tannins found in coffee, red wine, tea and cola beverages. The average duration expectancy is three to four years for non-smokers. The patient was also informed that, if tooth sensitivity or pain was felt during tooth whitening, treatment could be paused or stopped.

Prophylaxis and tooth cleaning had been performed at a private dental office before the patient presented to our clinic. Before starting with the tooth whitening, it was checked that the teeth were free of plaque, calculus and extrinsic staining (Fig. 1). In order to prevent unwanted proteins interfering with the whitening agent, a mild polishing of the teeth to be whitened was performed with Hawe Cleanic Prophy paste (Kerr Corporation).

Fig. 16_The final restorations under a polarising filter.

Fig. 17_The final smile under a polarising filter.



A review of the literature on Er:YAG laser whitening indicates that there is a significant difference between laser-assisted and conventional whitening in terms of the speed of the procedure. We consequently expected faster activation of the whitening gel with an Er,Cr:YSGG laser device compared with other laser devices. Owing to the similarities of the two wavelengths in terms of absorption in water, we expected to achieve the same results as those observed in Gutknecht's study.¹

In the postgraduate dental clinic, we use an Er,Cr:YSGG laser (2,780 nm, Waterlase MD Turbo, BIOLASE) and a yellow whitening agent for in-office whitening with a concentration of 38% hydrogen peroxide (POWER WHITENING, WHITESmile). The tip used is a Z-type glass tip (MZ8) of 800 µm in diameter and 6 mm in length, used with the gold handpiece of the laser system. The power settings that we used for this case were an output power of 1.25 W, a pulse duration of 700 µs (S-mode) and a pulse repetition rate of 10 Hz.

The dentist, dental assistant and patient evaluated the initial tooth colour. In our case, the patient's initial colour was evaluated as Shade A3 in the VITA classical shade guide (Vident; Fig. 2). Safety goggles must be worn by the patient and by all staff in the laser working area. Lip protection cream was applied and the working area was isolated with a cheek and lip retractor. After drying the teeth and gingiva with a gentle air stream, a liquid gingival barrier was carefully applied to both the maxillary and mandibular teeth and was polymerised with a fanning motion for 40 seconds.

The whitening agent was applied in a layer of 1–2 mm in thickness to each tooth (Fig. 3), starting with the maxillary teeth. With the power settings mentioned above, we activated the whitening agent for two intervals of 10 seconds for each tooth (Fig. 4), keeping the laser handpiece at a distance of 2.5 cm from the teeth. After the end of the procedure, the activated whitening agent was left

on for 15 minutes and then removed from the teeth with high-power dry suction. The procedure was repeated twice during the same appointment. After completion of the procedure, soft-tissue irritation was noticed in the area of tooth 42, but the patient reported that she did not feel pain or tenderness.

The final colour evaluation was conducted by the dentist, dental assistant and patient. After two repetitions of the process during the same appointment, the colour of the teeth had been changed to Shade B1 according to the VITA classical shade guide. The patient was satisfied with the colour of her teeth and was advised to re-evaluate the colour after two to three days to allow for rehydration of her teeth. The patient informed us that she was satisfied with the final colour and a second appointment was arranged in order to replace the Class IV composite restorations on the mesial and labial areas of her central incisors.

Class IV restorations

Class IV restorations were scheduled to be performed after four weeks in order to allow for long-term colour evaluation by the patient. Colour differences were non-existent, as can be seen in the photograph of the restorations with a polarising filter. The restorations were performed with the silicone key technique, for which a palatal impression of the existing restorations was taken with a polyvinyl siloxane and trimmed to the incisal edges (Fig. 5).

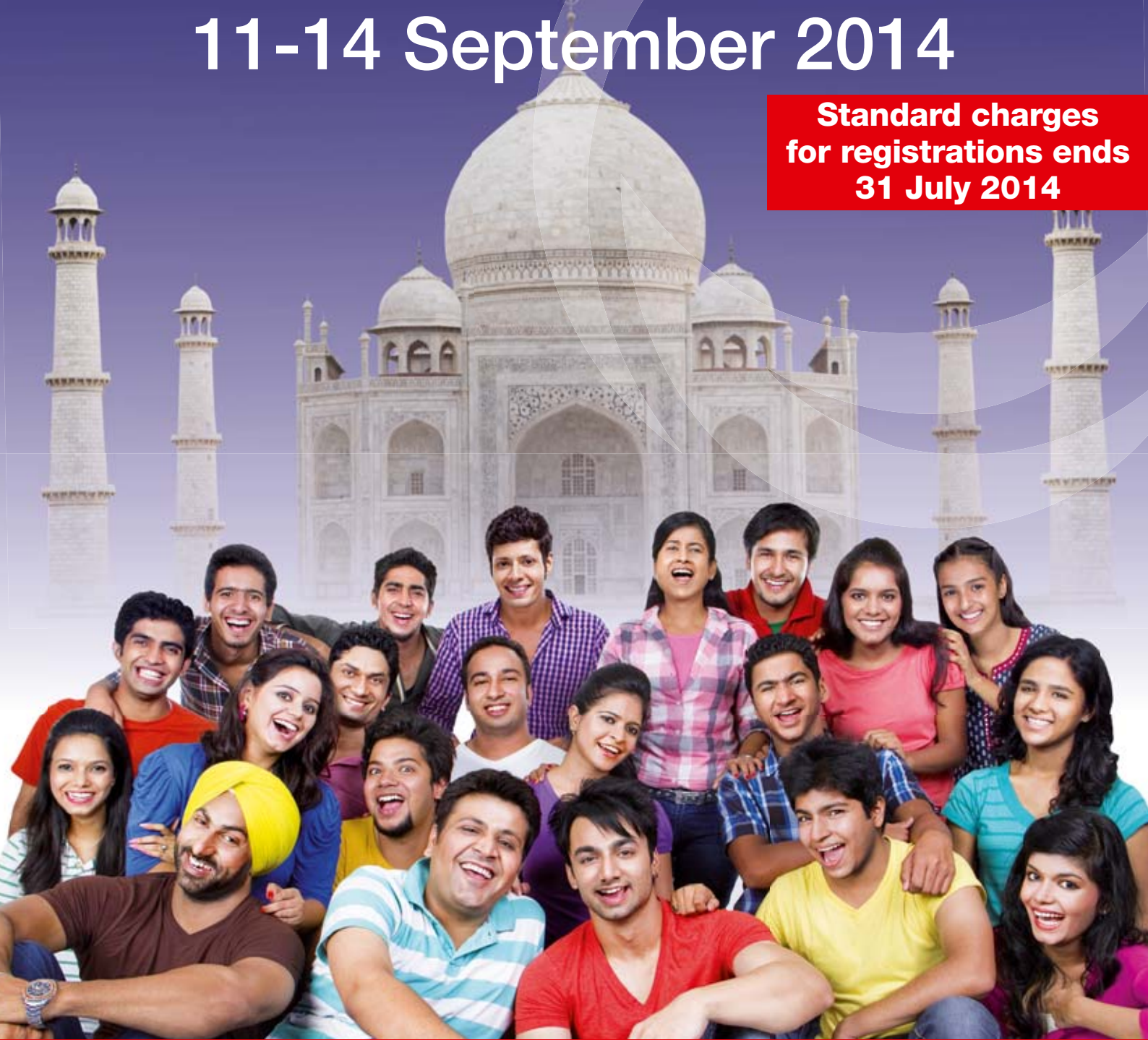Subsequently, the old composite was removed using an Er,Cr:YSGG laser (2,780 nm, Waterlase MD). The output power was set to 4.5 W, with a pulse duration of 140 µs (H-mode) and a pulse repetition rate of 20 Hz using an MZ6 tip under a water spray. Since there was no evidence of secondary caries or any other defect apart from colour and marginal integrity, it was decided to maintain the inner bulk volume of the old composite. However, all margins were placed on enamel (Fig. 6). Laser treatment of

FDI 2014 • New Delhi • India

Greater Noida (UP)

Annual World Dental Congress 11-14 September 2014

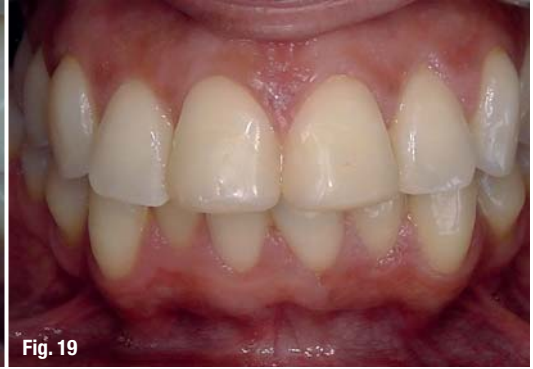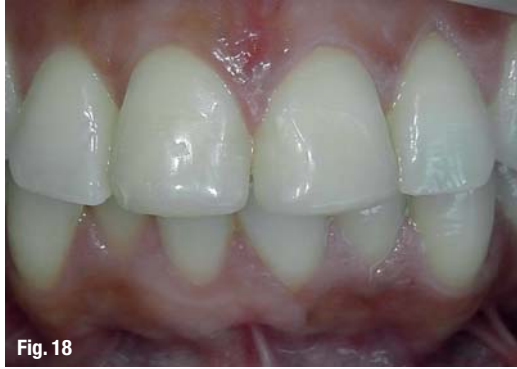**Standard charges
for registrations ends
31 July 2014**



A billion smiles welcome the world of dentistry

Fig. 18 A photograph of the situation seven days post-op.

Fig. 19 A photograph of the final situation.



the aesthetic zone was finished with the elimination of the brownish-black pigments on the gingiva between the central incisors and in the areas of teeth 32 and 33 (Figs. 7 & 8).

A restorative procedure was performed after placement of a rubber dam (Fig. 9). The silicone key was tried in (Fig. 10) and the adjacent teeth were protected with PTFE tape before etching the enamel margins with 37% phosphoric acid (Figs. 11 & 12). The resin composite bond to enamel benefits from both laser etching and acid etching. The restorations were built up incrementally, starting with the palatal enamel surface with a translucent enamel shade, Shade E (CLEARFIL MAJESTY Esthetic, Kuraray; Fig. 13). The dentine shade, Shade OA2, was then placed, forming the internal dentinal lobes (Fig. 14). A final labial enamel layer in Shade A2 was placed and was anatomically formed to recreate the macrostructure. A small quantity of Shade E was placed at the incisal edge to increase the biomimetic effect of the restorations.

The microstructure was created by polishing with fine and ultra-fine diamond burs, polishing discs of decreasing roughness, silicone points and brushes coated with diamond paste for the final gloss (Fig. 15). The colour match was checked under the polarising filter (Figs. 16 & 17). The patient was recalled seven days post-operatively in order to check the aesthetic appearance of the restorations and the healing of the soft tissue in the areas of depigmentation (Figs. 18 & 19).

Results

The aesthetic rehabilitation of the case was performed entirely with the use of an Er,Cr:YSGG laser. Laser treatment was performed with no anaesthetic. The patient reported only minor sensitivity during whitening and when the composite was removed, adding that the low temperature of the whitening agent and of the water ejected from the laser handpiece, in conjunction with the cold

air, had caused her discomfort. During depigmentation, no side-effects were reported. The Class IV restorations were built up incrementally to achieve better aesthetics. A silicone key was used to reproduce the rough shape of the old restorations and final adjustments were made during polishing to enhance the natural effect. A polarising filter was used to detect minor colour mismatches.

Discussion

The properties of the Er,Cr:YSGG wavelength (2,780 nm) are well known. Its characteristic absorption in water makes it an excellent tool not only for hard-tissue removal but also for soft-tissue and other aesthetic procedures.

One of the main components of a whitening gel is water. It can be found in percentages of up to 50% in any whitening gel. The advantage of using a laser system from the erbium family is obvious. The laser energy is fully absorbed by the water molecules in the whitening gel, thus increasing its temperature rapidly. This will result in rapid decomposition of the hydrogen peroxide and more hydroperoxyl free radicals will be produced. Consequently, the same expected result in terms of the final outcome of the whitening procedure is reached in minimal time compared with non-activated whitening gel treatment.

The laser's pulsed operation delivers bursts of high energy to the gel over a relatively small area. Its high energy density is a prominent advantage over other light sources used for laser whitening in terms of heat dissipation and safety of the pulp.

As Er,Cr:YSGG is also absorbed by hydroxylapatite, it is of great importance to select the power settings carefully in order not to ablate the enamel of the teeth to be whitened. For that reason, we kept the laser system parameters at a laser energy density (fluence) of every pulse well below the enamel ablation threshold. Our setting was

0.4 J/cm² and the ablation threshold for enamel is close to 3.5 J/cm².

Conclusion

The Er,Cr:YSGG laser can be very useful as an activation medium of the whitening agent during the tooth-whitening process. The whole procedure is faster, the results are excellent and the patient feels comfortable throughout the appointment. No harmful side-effects have been recorded. Of course, more studies are needed to corroborate these preliminary results. Future developments are encouraging and we can expect better-designed handpieces for whitening and wavelength-specific whitening agents.

Besides aesthetic dentistry, lasers have been successfully used for restorations in operative dentistry, providing pain-free treatment. The Er,Cr:YSGG laser is a powerful tool in the hands of a trained dentist for performing both hard- and soft-tissue treatment, sometimes even during the same appointment. In conclusion, it is important for the clinician to take all safety measures during the pro-

cedure, to comply with the manufacturer's guidelines, and to use the correct wavelength and the proper parameters of the laser device, depending on the therapy selected, in order to achieve the best results for the benefit of the patient.

contact

laser

Dr Dimitris Strakas

DDS, MSc, PhD cand. Department of Operative Dentistry, Aristotle University of Thessaloniki

dimitris.strakas@gmail.com

Dr Christina Boutsiouki

DDS, MSc, Department of Operative Dentistry, Aristotle University of Thessaloniki

christinaboutsiouki@gmail.com

AD

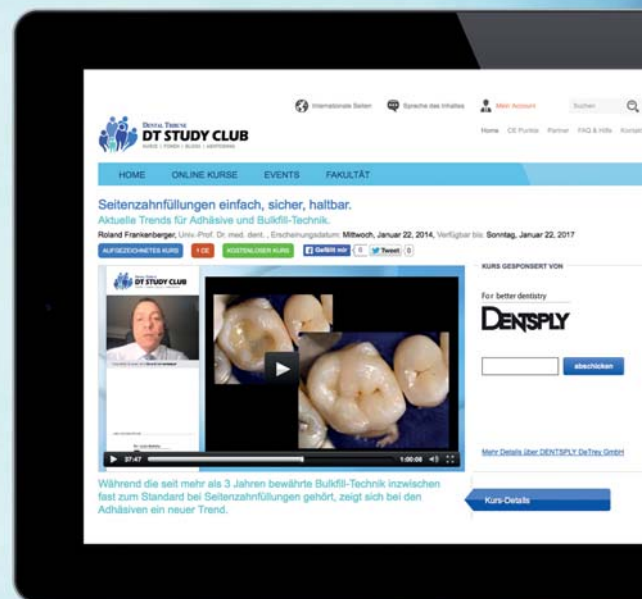
Join the largest educational network in dentistry!



Register for **FREE!**

- education everywhere and anytime
- live and interactive webinars
- more than 500 archived courses
- a focused discussion forum
- free membership
- no travel costs
- no time away from the practice
- interaction with colleagues and experts across the globe
- a growing database of scientific articles and case reports
- ADA CERP-recognized credit administration

www.DTStudyClub.com



Periodontal decontamination in microsurgery

Author_Dr Fabrice Baudot, France

_Introduction

We are witnessing today an upsurge in the use of minimally invasive techniques in the medical field. Dentistry has not escaped this rapidly expanding trend. In all the specialties of our discipline, we see the appearance of micro-dentistry operating instruments and protocols. The search for better operating comfort, greater effectiveness and better results lead us in this direction.

Periodontology also became part of this process several years ago with the development of periodontal microsurgery. This approach is based on an adapted technological platform and new operating protocols. The object of this article is to present a new surgical technique made possible by the synergy of

LiteTouch Erbium:YAG laser (Syneron Dental Lasers, Israel) and optical aids.

_Basic aspects of the microsurgery

Why microsurgery? This is a legitimate question.

Preserving vascularisation

Burkhardt & Lang in 2005 clearly showed that a microsurgical technique led to better healing than the classical technique.¹ The key to the success of microsurgery is maintaining the integrity of the tissues and in particular their vascularisation—so much so that a surgical technique can be qualified as minimally invasive when it safeguards tissue vascularisation.

Plane-by-plane surgery

In this type of surgery, attention must be paid to the thinness of the anatomic structures, namely of the different tissue planes being operated on. Just as plastic surgeons treat skin tissues plane by plane, the periodontist should handle the periodontium in the same way, taking account of the anatomic and functional specificity of each plane. The thinness of the structures to be operated on calls for a microsurgical approach.

Avoiding tissue tension

With plane-by-plane surgery it is possible to respect the various anatomic structures, as well as to manage possible tissue tensions that could be harmful to the revascularisation of the surgery site, as brilliantly demonstrated in Mammoto's article published in the well-known *Nature* review in 2009.² The development of endothelial cells, seat of the vascularisation process, is influenced by tension receivers

Fig. 1_ This strongly magnified view of the periodontium shows the abundance of the anatomic structures.

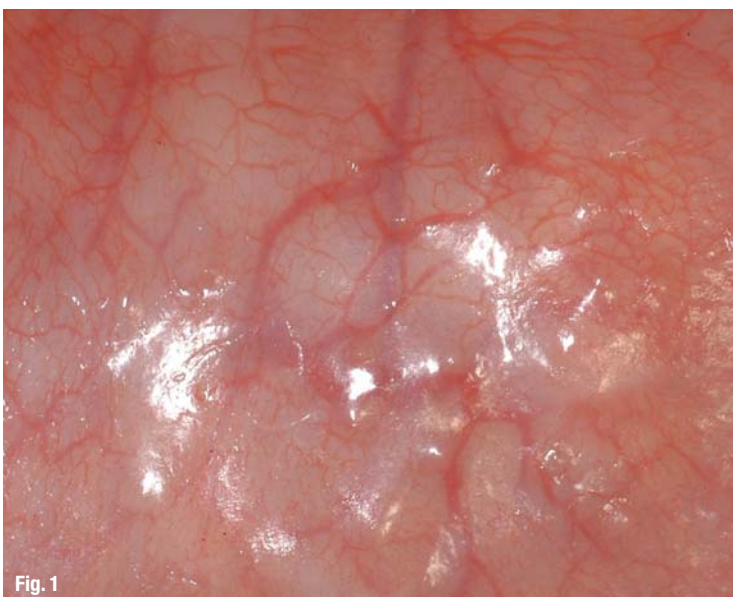

Fig. 1

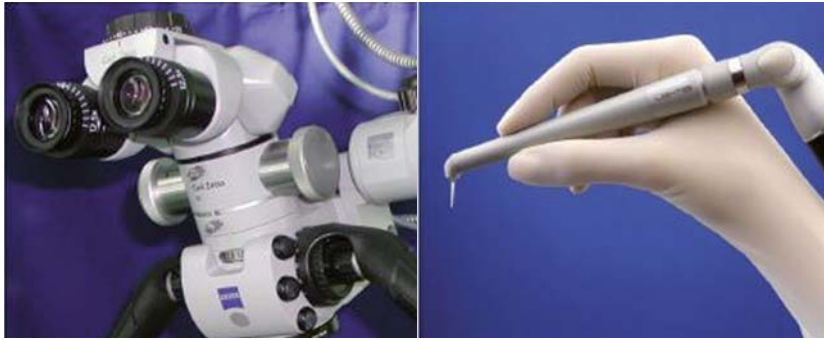


Fig. 2_The synergy of two instruments used in periodontal microsurgery.

which guide the tissue morphology in particular during tissue healing.

Fine suturing or no suturing

This is yet another surgical parameter in respect of the surgically treated tissues. Fine sutures have physical and biological properties. They avoid excessive tissue tensions, therefore ensuring better healing,³ and they limit microbial infiltration of the operated areas.⁴ With the microsurgical use of the Lite-Touch Erbium:YAG laser it is possible to operate without need of sutures, which is even less traumatic.

Avoiding periosteum detachment

The periosteum is a fundamental vascular source for the periodontium. Full thickness flaps, or even partial thickness flaps, induce a delay in healing and bone resorptions, as noted in the recent study by Fickl et al.⁵ Flapless surgery or surgery using partial thickness techniques considerably improves the healing process: this has long been studied⁶⁻⁸ and is made possible precisely by microsurgical techniques.

Advantage of the LiteTouch Erbium:YAG laser in periodontal microsurgery

As can be seen, the dental practitioner must improve his view of the tissues on which he is operating,

but he must also have tools that can meet the requirements of more precise movements.

The synergy created between optical aids and Erbium:YAG laser advantageously meets this dual requirement. Thanks to optical aids (minimum x3.5), the surgeon acquires a finer analysis of the tissues on which he is operating and the accuracy of the therapeutic effects of the LiteTouch Erbium:YAG laser allows him the optimal precision required for a minimally invasive surgical approach.

The main feature of the energy released by the laser beam at a wavelength of 2,940 nm is its massive absorption by water and hydroxylapatite. This physical property gives this laser its great versatility in dental surgery and especially in periodontology.

The energy absorbed in the targeted tissues leads to their vaporisation: visually, a tissue micro-ablation process is observed. The laser becomes a microsurgical instrument that allows precise sculpting of the tissues. The micro-ablation results depend on the water load of the targeted tissues. The greater the water load, the more intense the vaporisation. The water load of the various tissue planes is not constant. For purposes of clarity, two types of situations can be distinguished:

Increasing water load

Hard tissues against soft tissues: in such a situation, the Erbium:YAG laser is more delicate to use, with high risk of injuring the soft tissues. In these clinical cases, piezosurgery (complementary to laser) seems to be more adapted.

- Opening of the sinus flaps
- Root haemisection
- Bone grafting

Decreasing water load

Soft tissues against hard tissues: This is the optimal field of application of the Erbium:YAG laser. Radiation acts on the soft tissues (which contain more water) without affecting the hard tissues (which contain less water). The appropriate clinical situations are for example:

- Gingivectomy against the root
- Tissue degranulation against the bone and the roots
- Inflammatory tissues inlaid on the healthy gum

These concepts define the field of application and mode of operation of the Erbium:YAG laser in periodontology. Laser treatment of periodontal tissues differs from surgery with conventional instruments. No more cutting or drilling of the tissues, but very ac-

Fig. 3_Laser absorption curves.

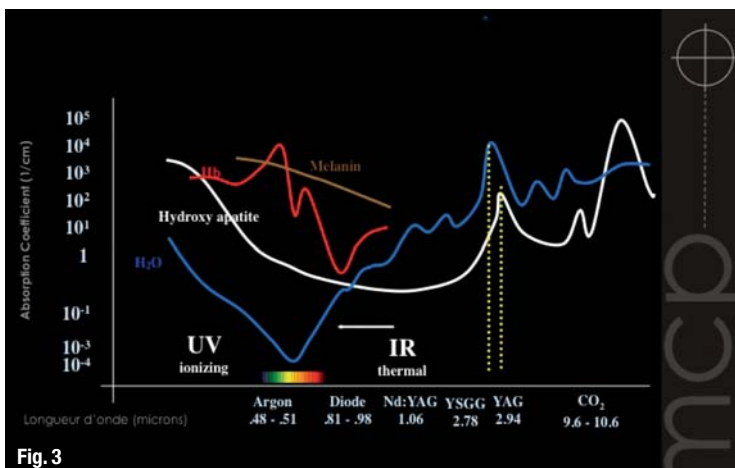


Fig. 3

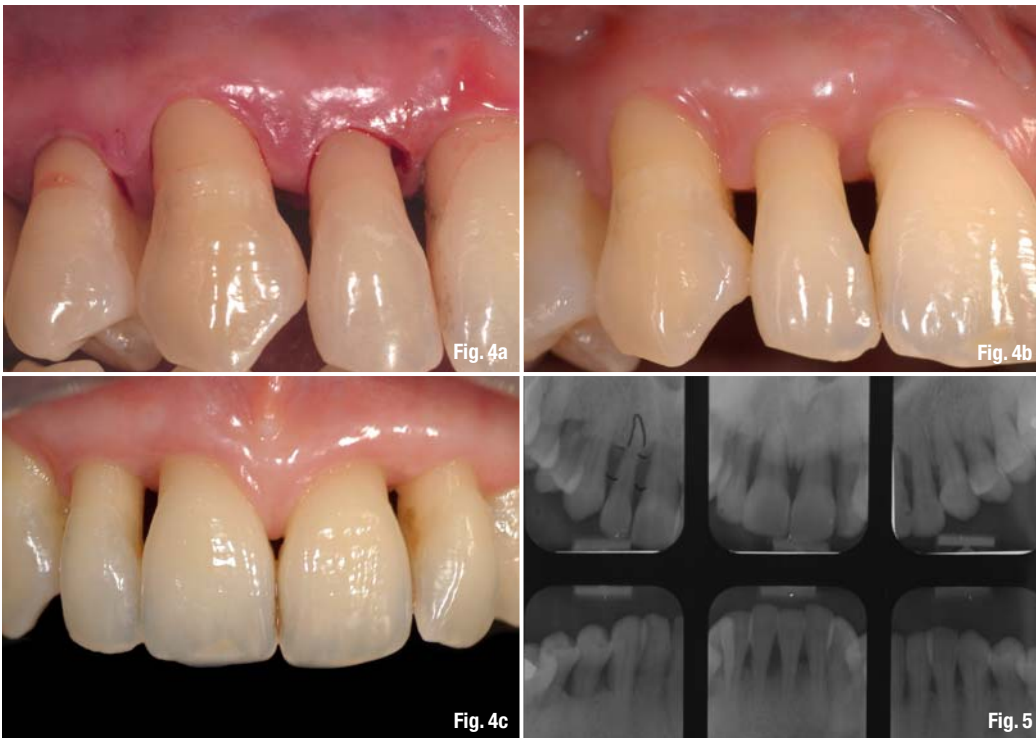

Fig. 4 a) intra-operative view with microsurgical access to the deep periodontitis: aggressive periodontitis. Note the tissue stability at two months; b) post-operative view after two months; c) Post-operative view (two months) of an aggressive periodontitis treated by microsurgical protocol and flapless PRF. Note the access to oral hygiene and the tissue stability.

Fig. 5 Pre-operative X-ray of an aggressive periodontitis, in smoker patient, 45-years-old with Vitamin D deficiency.

curate sculpting. The beam is used as a sort of optical curette with selective action on the inflammatory tissues, leaving the surrounding tissues undamaged, and particularly preserving vascularisation.

Erbium:YAG laser setting parameters

Here is not the place for explanations of laser physics; it should be noted only that the Erbium:YAG laser operates in pulse mode. Energy is released by pulses with water irrigation.

NB: the irrigation can be suspended, but thermal effects appear rapidly. This allows coagulation with the Erbium:YAG laser which, in principle, is not intended for this. The practitioner has five parameters at his disposal to adjust the therapeutic laser effect.

Two parameters set on the device

To simplify the clinical use, the manufacturers have limited the device setting to two parameters to be defined by the practitioner in order to determine the characteristics of the beam emitted: pulse frequency (in Hertz) and pulse intensity (in millijoules). The result of these two parameters is a pulse power measured in watts.

Three variable parameters in the practitioner's hands

To adjust the energy delivered to the targeted tissues, the practitioner will utilise the following parameters:

- Pulse duration
- Distance between the energy emitting source and the tissues
- Beam angulation

By regulation of these parameters, the practitioner takes full advantage of the "magic" effect of the instrument. With visual control, he will be able to sculpt the tissues with an accuracy of some tens of microns.

Microsurgical decontamination protocol

The use of such microsurgical instruments, the improvement of optical aids and the development of our knowledge of the importance of micro-vascularisation in the healing process provide us today with a third way between the surgical approach advocated by the Americans, especially by Widman,⁹

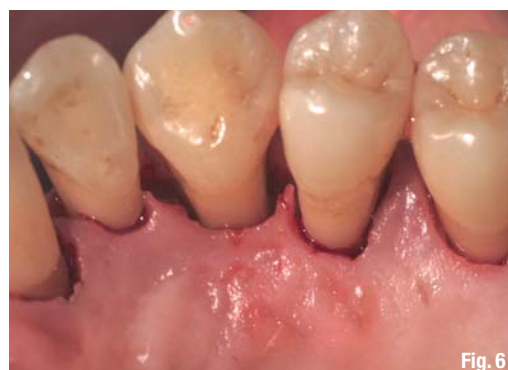

Fig. 6 After cleaning of the deep periodontium, a very light polish of the root surfaces may be performed under visual control.

Fig. 7_Defocussing effect of the tip.

and the completely non-surgical techniques proposed by the Swedes from the 1990s.¹⁰ Both approaches are efficient, but their limits have been shown in the treatment of periodontitis:

- The surgical approach is invasive, the surgical protocols are complicated and the long treatment periods expose to risks of reinfection. While the aim is to reduce the periodontal pockets, the periodontal decontamination surgery does not obviate the need for a strict maintenance programme.

- The non-surgical approach follows a microbiological rationale. Acting on the aetiology of the pathology and respecting the periodontal tissues, it has achieved good results. However, the surgical technique results in a large number of residual periodontal pockets and the non-surgical treatment of periodontitis entails an ultra-strict maintenance programme that few patients and members of the medical staff are able to maintain in the long term (especially in France where there are no dental hygienists). The way opened by the microsurgical approach is expected to combine the advantages of both techniques while smoothing out their disadvantages. This way derives from the technique pioneered by Yukna (1978) who published "E.N.A.P: Excisional for New Attachment Procedure".¹¹

Finally, the most important element in periodontitis treatment is periodontal maintenance. The patient must have access to all the dental surfaces in order to maintain a level of hygiene adapted to his physiological profile. The critical point lies in the number of periodontal pockets. The initial phase aims at reaching the deep periodontium in order to clean these pockets (non-surgical approach) and to some extent to reduce them (surgical approach).

The microsurgical approach proposed will meet both criteria in a simple, quick surgical protocol.

The practitioner works with optical aids and therefore with visual control, with an ultra-fine surgical instrument which allows him to operate in a non-invasive, flapless way, while preserving tissue vascularisation and integrity.

Three-step surgical protocol

- Internal bevel sulcular incision (more or less shifted) to access the deep periodontium. This incision may be done with a fine diamond drill (flame

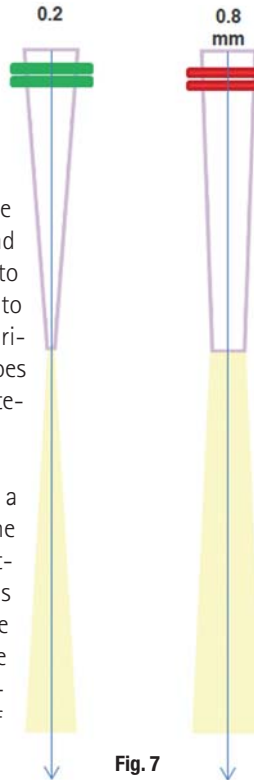


Fig. 7

shape) or with a laser in the most delicate areas. The object is to provide access to the deep periodontium (a sort of access cavity). Through this 1 mm space, it is possible to see up to 10–12 mm with high performance optical aids. Therefore, it is possible to operate with visual control without needing to detach a flap.

- Cleaning the deep periodontium is conventionally done using fine ultrasound to remove tartar. Inflammatory tissues are laser treated by selective vaporisation. The fine laser insert gives access through a widened sulcus, which will allow accurate tissue degranulation like a very high performance curette.

- At this stage, the operation is over. The surgical protocol is short, minimally invasive and the post-operative management light.

Treatment of the whole mouth is proposed in two sessions, 48 hours to one week apart at most in order to limit the risks of cross contamination. Each half-mouth (top and bottom) surgical session takes between 45 minutes and 1h30 according to the extent of the lesions. Oral hygiene teaching sessions are given on a decontaminated periodontium.

Two months after surgery, the patient pays a follow-up visit for reassessment. At this stage, the adapted periodontal maintenance programme will be established and begin. It will be reassessed yearly according to the evolution of the clinical parameters.

The periodontitis treatment in such a protocol is simple. The periodontal maintenance is rapidly initiated on a periodontium that has been treated deeply and efficiently. The microsurgical protocol is halfway between the surgical and non-surgical approaches.

Selective tissue vaporisation with Erbium:YAG laser and therapeutic properties

As already shown, one of the special features of this surgical protocol is the use of the Erbium:YAG laser which provides therapeutic efficiency in a restricted space. The characteristic of tissue micro-ablation according to the water load of the tissues allows fine and selective degranulation of the tissues, plane by plane, thus respecting the principles

of microsurgery. Inside the periodontal pocket, the laser pulses vaporise the inflammatory tissues. The first vaporised tissue planes are moisturised and infiltrated most. Under the effect of laser irrigation, the surgical site clearly emerges and the practitioner, with optical aids, can see the surfaces he or she is treating. There is no coagulation and therefore no micro-vascular lesion, but the removal of inflammatory tissues reduces bleeding and makes the surgical site clearer.

Once the inflammatory tissues are removed, the practitioner has a precise view of the pocket inside and can treat the second plane, the healthy tissues. At this stage, soft tissue plasty of the pocket may be considered to reduce depth in the sectors where this is possible. Then, the practitioner may carry out micro bone remodelling directly from inside the pocket, by tissue micro-ablation: flapless bone modelling. Laser beam angulation using the defocusing cone allows low-energy treatment of the side walls of the pocket: ligament and bone. These walls will be decontaminated and bio-stimulated according to the LLT laser principles: low level therapy. The Erbium:YAG laser absorption by the hydroxylapatite gives this radiation excellent properties for the cleaning of the bone surfaces, removing the smear layer caused by alveolysis.

The periodontal debridement by laser is performed with water irrigation. We benefit from the agitation of the irrigation solutions, as is the case in endodontic applications of the laser. The laser-triggered microcavitation of the irrigation cleans the walls of the space thus treated.

_The Erbium:YAG laser in the clinical practice

The Erbium:YAG laser beam emission inside the periodontal pocket is accompanied by physical and biological phenomena with therapeutic effects visible under high magnification. The laser is a surgical instrument with much higher performance than conventional instruments which have only a mechanical and relatively basic action in comparison with this radiation. In practice, it is all very simple. The laser tip is inserted into the pocket just like an optical curette, and the practitioner scans the surfaces to be treated while the beam is emitted in order to limit the thermal effects and to carry out a uniform and homogeneous treatment (similarly to a paint spray). The ergonomics of the insert allow visual control of the therapeutic effects. The tissue plasty requires applications in the scanning movement. To increase the surfaces to be treated, the practitioner defocuses radiation. The three parameters of time of exposure, focal distance and

beam angulation are the variables at the practitioner's disposal to express his treatment expertise.

_Conclusion

More than ten years ago, the scientific literature proved the physical and biological properties of the Erbium:YAG laser: it is a high performance, safe surgical instrument. The main advantage of this radiation lies in its high absorption by water. This is what makes it safe since it limits the collateral thermal effects. Its clinical performance can be attributed to its tissue micro-ablation properties. It is a versatile instrument allowing sculpting of enamel at the highest energy levels, and surface decontamination through its bactericidal effects on microbial biofilms, at lower energy levels.

We have described here the application of the Erbium:YAG laser in periodontal decontamination, but its field of application is not limited to periodontics. The Erbium:YAG laser is also used in plastic surgery. It allows performing of surgery, no longer by cutting or drilling tissues, but by sculpting them. Micro-plastic procedures can thus be carried out on soft tissues in mucogingival surgery, flapless crown lengthening and other minimally invasive, guided bone regeneration surgeries.

The LiteTouch Erbium:YAG laser is not a treatment, but a microsurgical instrument which, combined with optical aids, offers an additional advantage to dental surgeons who wish to offer minimally invasive treatment.

Editorial note: A list of references is available from the publisher.

_contact

laser

Dr Fabrice Baudot

dental@syneron.com
www.synerondental.fr

Innovative pathways for extensive and efficient tissue removal with Er:YAG laser

Author_Dr Kresimir Simunovic, Switzerland

_Introduction

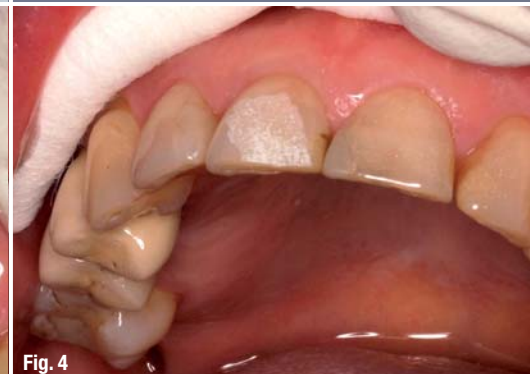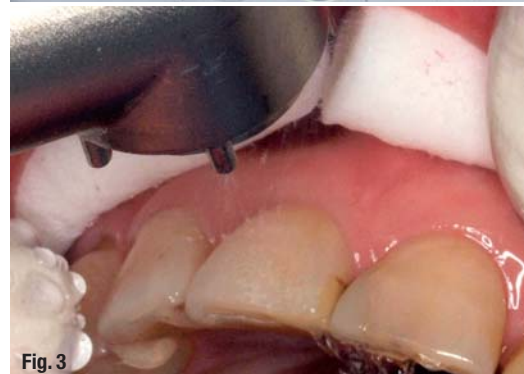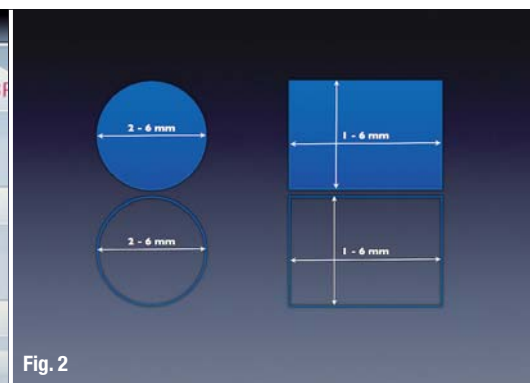
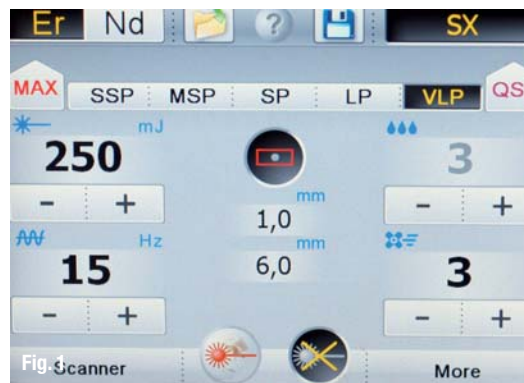The newest and most innovative handpiece for oral hard- and soft-tissue removal from Fotona is the X-Runner, an ideal accessory for the company's Light-Walker AT laser (Er:YAG & Nd:YAG). In our daily in-office applications, we notice many remarkable advantages in the preparation of veneers and partial or full crowns, in oral surgery, especially for soft-tissue management, and in implantology for implant release and certain specific steps during implant setting procedures.

The X-Runner allows for precise and extensive tissue removal, defined by the choice between three different geometrical shapes: circle, rectangle and hexagon. These can be highlighted as full ablational areas or only active along the borders as a means to carve out just the margins, maintaining the full integrity of the inner area. The extent of ablation is gradually adjustable between 1 to 6 mm, depending on the geometry, with a variety of 1 single to 99 successive passes.

The corresponding basic and advanced settings for soft- and hard-tissue management with the Light-

Figs. 1 & 2_ Settings on the LightWalker AT screen in advanced mode: highlighted SX as the X-Runner handpiece and the standard settings for soft-tissue ablation by very long pulses, which enable an efficient coagulation due to the adjustable pulse duration of 700 μ s and more (only possible with Fotona Er:YAG lasers). In this case, the full area of a rectangle with a 6 x 1 mm surface is active. Two of the three geometrical pre-settings (circle, rectangle, hexagon) are schematically shown as active on the full surface or only at their margins.

Figs. 3 & 4_ Extensive surface preparation with the X-Runner using the geometrical setting of a rectangle with 6 x 3 mm of active area.



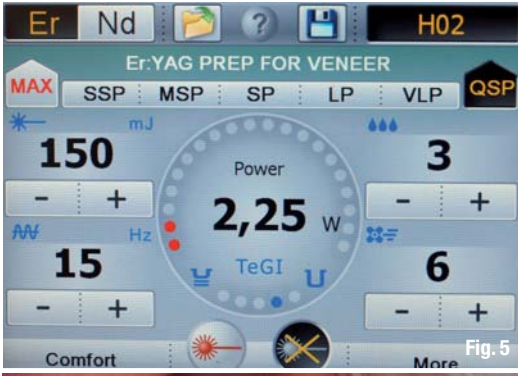


Fig. 5

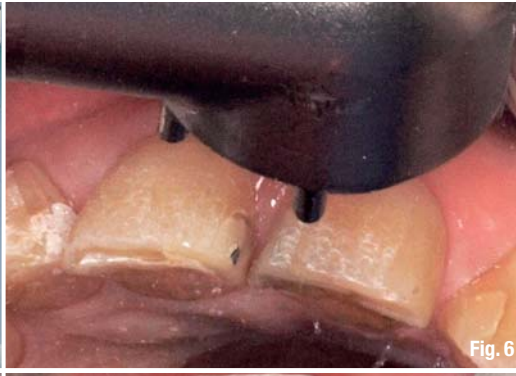

Fig. 6

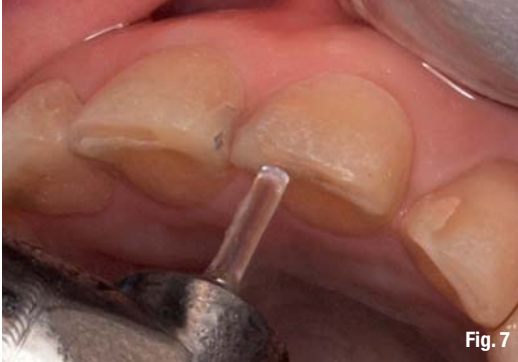

Fig. 7

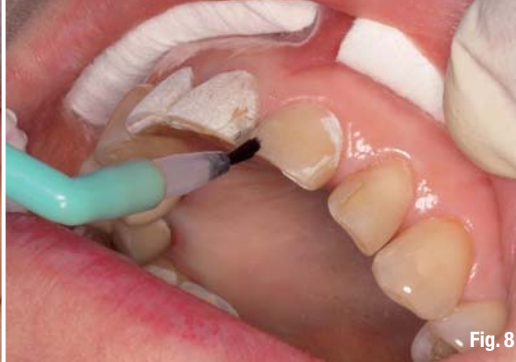

Fig. 8

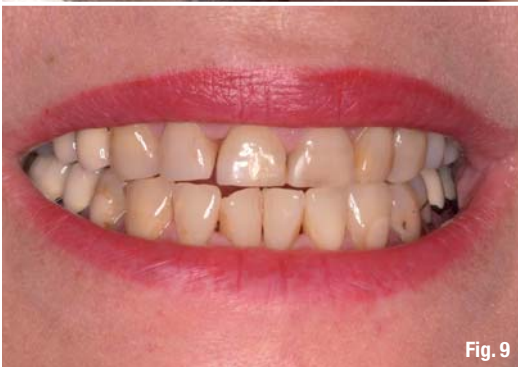

Fig. 9

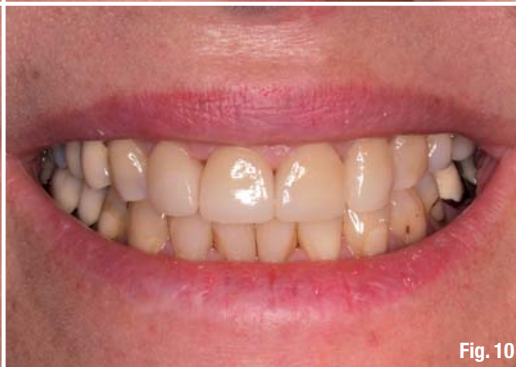

Fig. 10



Fig. 11



Fig. 12

Figs. 5 & 6_ Standard setting for veneer preparation on the LightWalker AT in QSP (Quantum Square Pulse) Mode, which allows for an efficient and fast ablation with a highly precise margin.

Figs. 7 & 8_ Final surface modification, followed by the adhesive in-office protocol (Syntac Classic/lvoclar).

Figs. 9 & 10_ Before and after pics of the veneer case on the upper incisors.

Figs. 11 & 12_ LightWalker AT either with the X-Runner handpiece in non-contact mode or with the H14 handpiece using different sapphire and quartz tips.

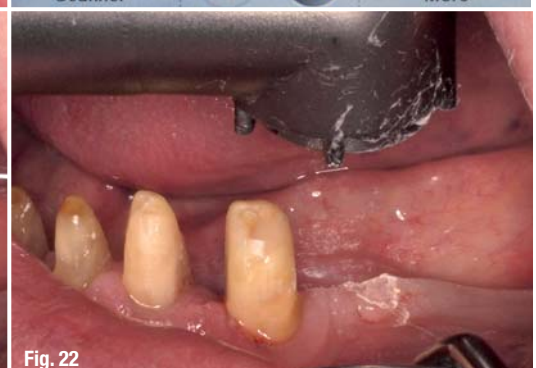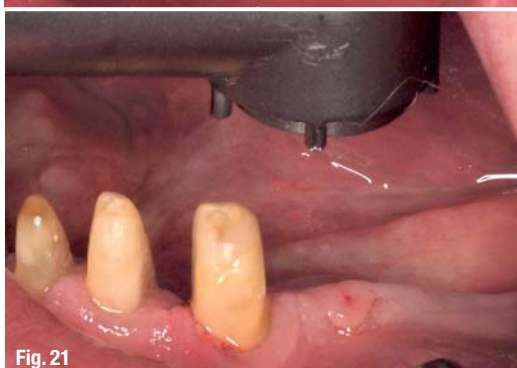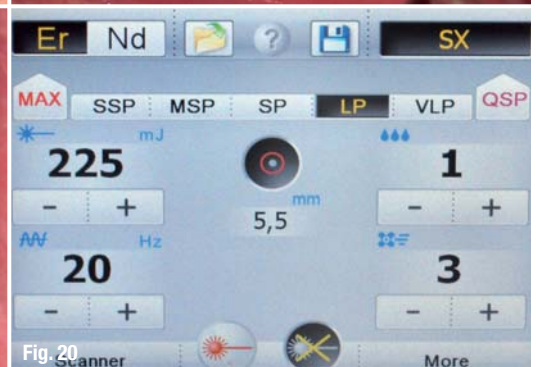
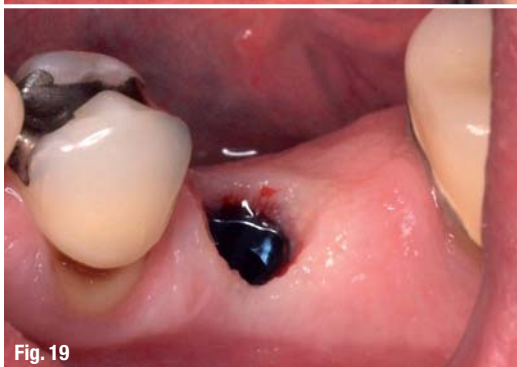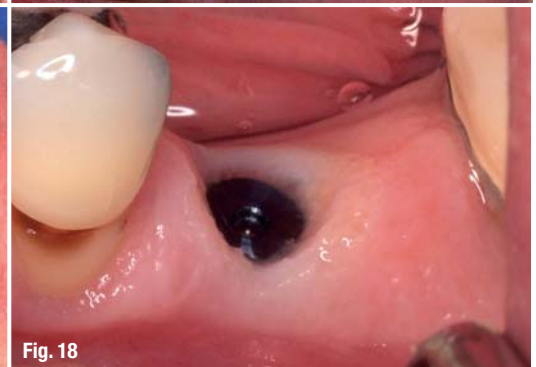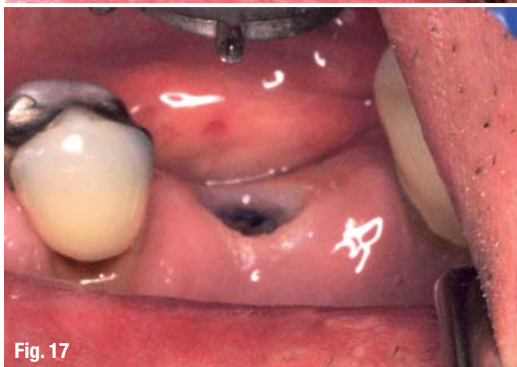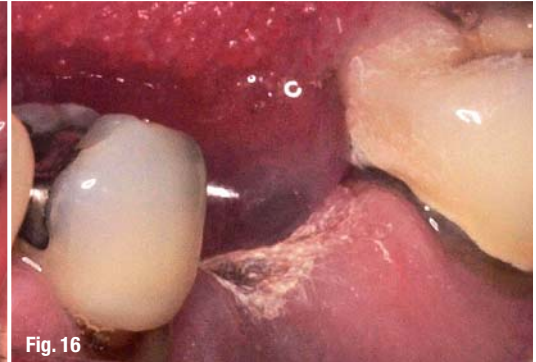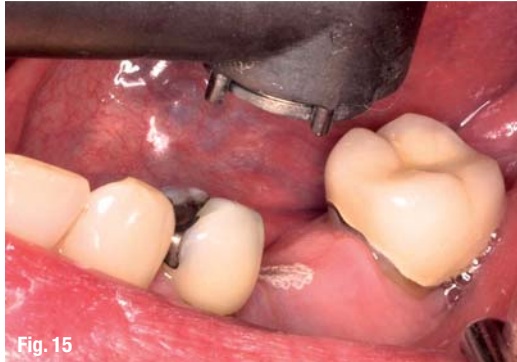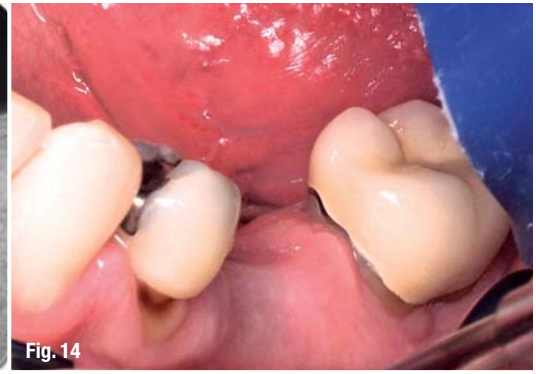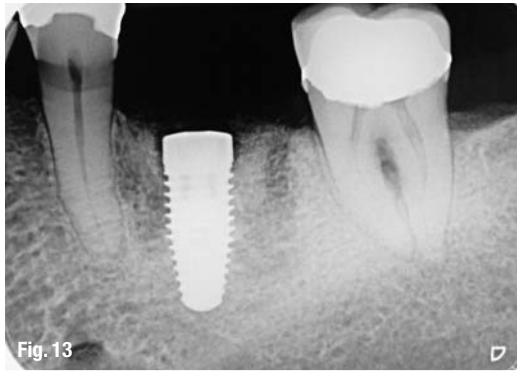
Figs. 13 & 14_Osseo-integrated implant on X-ray and the corresponding intraoral situation after the mandatory healing period of the implant in the area of the first lower left molar (Nobel Biocare).

Figs. 15 & 16_X-Runner handpiece in a fixed position with an active circle diameter of 5.5 mm, and the beginning of layer-by-layer soft-tissue ablation through multiple passes.

Figs. 17 & 18_Advanced ablation with the X-Runner and simultaneous release of the implant margins.

Figs. 19 & 20_Released implant before the impression, and Er:YAG settings in Advanced mode: SX for X-Runner, long pulse duration and circular active area of a diameter of 5.5 mm.

Figs. 21 & 22_Geometrical layer-by-layer ablation (circle) of a fibroma through multiple passes with the X-Runner in a fixed position ...



Walker AT can be directly adapted to procedures with the X-Runner, allowing for highly predefined and noticeably facilitated removal of tissue over larger areas. The Er:YAG wavelength is primarily absorbed by the water content of every tissue in the human body, and this basic nature of the Er:YAG wavelength allows for a very safe and fully manageable surgery, offering constant control of the progression of the laser-assisted ablation with no need for intervention.

To illustrate the idea, we would like to present two different clinical cases with routine indications in laser-assisted dentistry: first, a veneer preparation of the upper-central and lateral incisors and second, an implant release in the lower-left first molar area.

Veneer preparation in the upper front

An extended and fast mode of preparation was performed with the X-Runner using the predefined veneer prep setting on the LightWalker AT panel, followed by a final surface modification. There was no need for local anaesthesia.

At that time our tissue removal experience with the X-Runner in marginal areas was somewhat lim-

ited, so consequently we performed the finish with the cylindrical tips and the H14 handpiece. As an alternative, the X-Runner can be modified by a simple and time-saving change of the output settings to perform as a regular non-contact H02 handpiece.

The finished surfaces were bonded instantly, the impression taken, and a couple of days later the lab veneers were integrated into the patient's smile design dimension.

Implant release in the first lower left molar area

After the predefined healing period, the soft-tissue above an osseointegrated implant (Nobel Biocare) was removed by multiple passes, following the preset shape and extension of the ablation area. A healing abutment was fixed on the fully uncovered implant after the impression was taken for the lab. The surgery was performed without need for local anaesthesia.

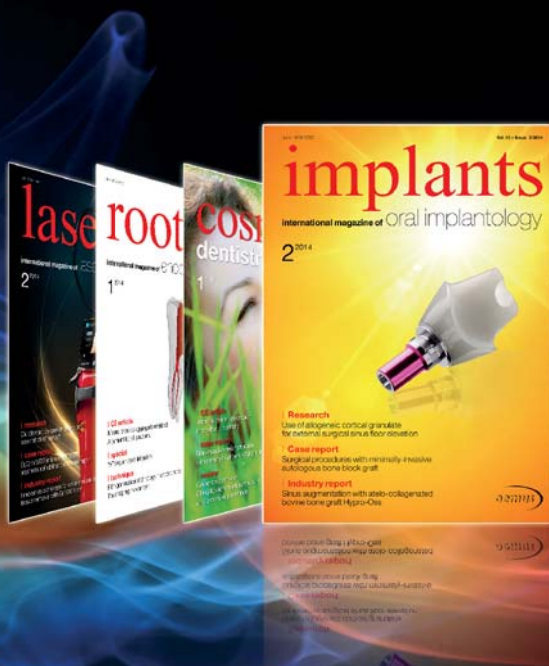Extended range of indications

Aside from the standardized indications in aesthetic and conservative dentistry and soft- and hard-

AD

implants

international magazine of oral implantology



You can also subscribe via www.oemus.com/abo



Subscribe now!

I would like to subscribe to **implants** for € 44 including shipping and VAT for German customers, € 46 including shipping and VAT for customers outside of Germany, unless a written cancellation is sent within 14 days of the receipt of the trial subscription. The subscription will be renewed automatically every year until a written cancellation is sent to OEMUS MEDIA AG, Holbeinstr. 29, 04229 Leipzig, Germany, six weeks prior to the renewal date.

▶ Reply via Fax +49 341 48474-290 to OEMUS MEDIA AG or per E-mail to grasse@oemus-media.de

Last Name, First Name

Company

Street

ZIP/City/Country

E-mail

Signature

Notice of revocation: I am able to revoke the subscription within 14 days after my order by sending a written cancellation to OEMUS MEDIA AG, Holbeinstr. 29, 04229 Leipzig, Germany.

Signature

laser 2/14



Figs. 23 & 24 ...followed by flap surgery with the Er:YAG Quartz tip (Varian/Fotona) and laser-assisted osteotomy during an implant bed procedure in the lower-left jaw area.

Figs. 25 & 26 Intermediate depth measurement with a perio probe to a value of around 8 mm, followed by a final classical drill by the manufacturers protocol (Nobel Biocare) and the implant in place before suturing.

Figs. 27 & 28 Postoperative photobiomodulation (PBM) of the surgical area on the right lower jaw with 810 nm diode (ARC, Nürnberg, Germany), and the three implants in place after laser-assisted surgery with X-Runner (LightWalker AT, Fotona).

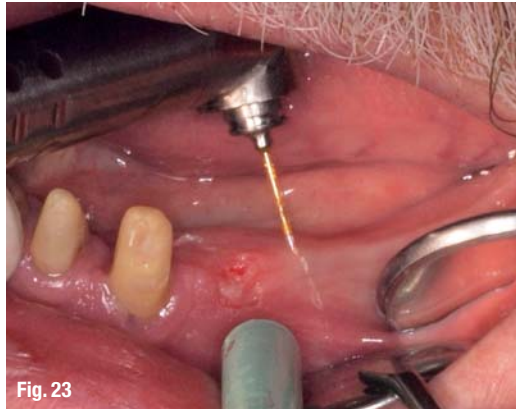


Fig. 23

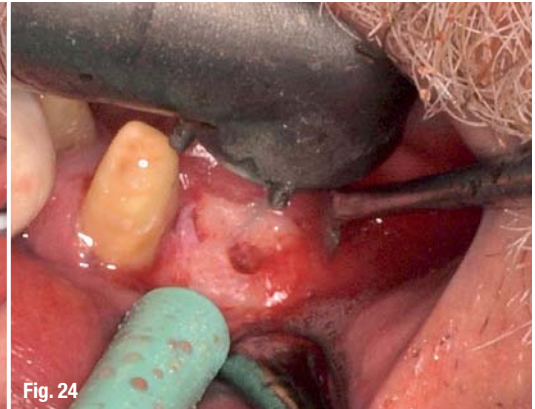


Fig. 24

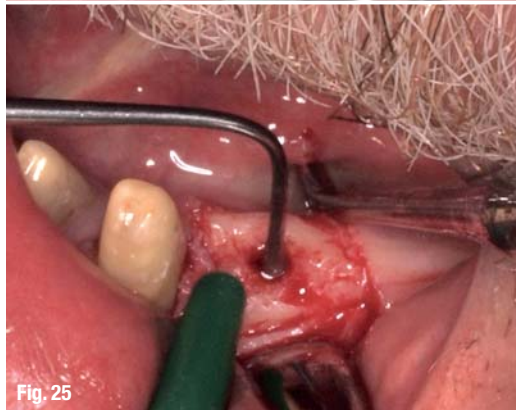


Fig. 25

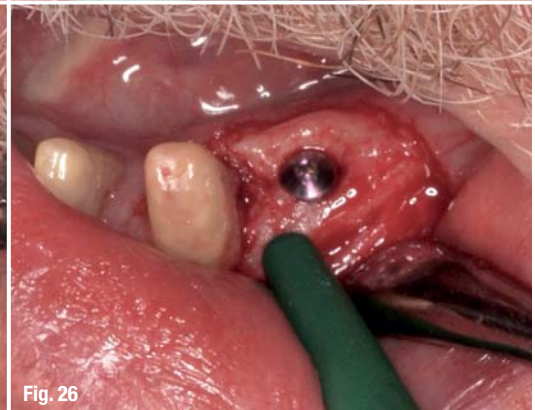


Fig. 26

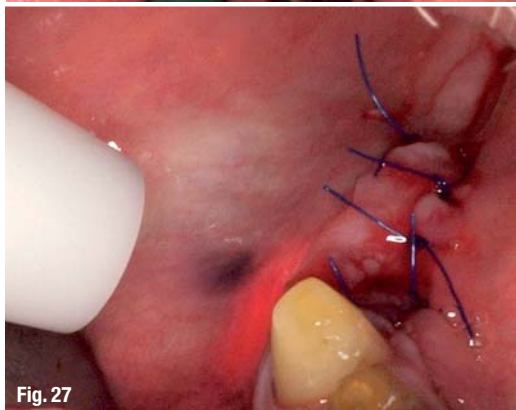


Fig. 27

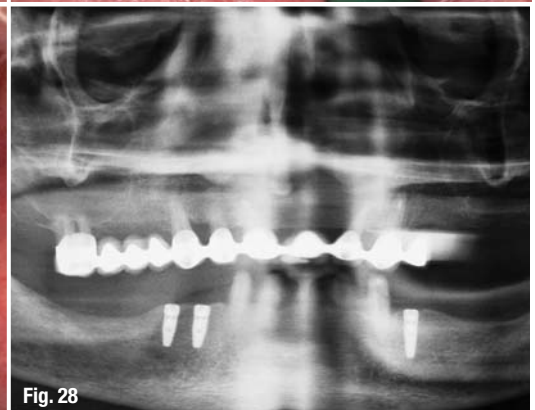

Fig. 28

tissue surgery, we also noticed some specific advantages as a support to specific steps of the implant setting procedures, with respect to other approaches developed by specialised clinical centres.

We performed an initial implant bed preparation using the X-Runner only, by choosing the geometry and corresponding area and finalising the procedure by the last step of the classical implant bed protocol. The patient presented a very solid and healthy bone of the lower jaw, so we were able to drill with the predefined shape to a depth of 8–9 mm, without the need for any classical burr-based procedures.

Our first experiences with the X-Runner handpiece used in combination with our in-office standard LightWalker AT laser (Er:YAG & Nd:YAG; Fotona) provided us with fascinating insights into new, powerful

and innovative aspects of soft- and hard-tissue management that are now possible in the daily clinical practice in Er:YAG laser-assisted dentistry.

_contact

laser

Dr Kresimir Simunovic

Office for Laser-Assisted Dentistry
Seefeldstrasse 128
8008 Zurich, Switzerland
Tel : +41 44 383 4070


ksimunovic@smile.ch
www.simident.ch

The logo for ADA 2014 features a stylized 'A' composed of three curved segments in red, green, and blue, followed by the text 'ADA.2014' in a bold, sans-serif font.

AMERICA'S DENTAL MEETING

October 9-14, 2014 | San Antonio, Texas, USA

Education: October 9-12 | **Exhibition:** October 9-11



Education

Participate in challenging CE courses that fit into your schedule and budget



Exhibition

Research and purchase dental products and services at a discount



Connections

Mingle with colleagues from across the world

Laser dentistry course for dental students in Thailand

A classroom action research

Authors Associate Prof. Dr Sajee Suttayut, Assist Prof. Dr Piyachat Pacharanuchat & Associate Prof. Suwit Undompanich, Thailand

[PICTURE: ©29OCTOBER]

Introduction

Owing to the fact that dental students at the Khon Kaen University (KKU) were interested in laser therapy, an intensive course for laser therapy in dentistry was introduced to the final year students. The instructional design was based on transferring technology and translation research to practice. A classroom action research was conducted to evaluate this course. The results showed favourable knowledge and attitude of the learners. This article reveals a pattern of instructing laser dentistry to dental students.

Laser dentistry was commenced in the faculty of dentistry, Khon Kaen University (KKU) in 1993. Consequently, the lasers in dentistry research group, Khon Kaen University, (LDRG KKU) was established in 2011. The development of this discipline has continuously been accomplished in basic research, clinical trial and technical transferring. Besides this, the dental students, KKU were also interested in conducting research in laser dentistry and using laser for their general dental practices. Therefore, we introduced an in-

tensive laser dentistry curriculum called "Laser Therapy in Dentistry" for the final-year dental students. A classroom action research was undertaken to evaluate an instructional design for dental students learning laser dentistry.

Methods

The principle of instructional design was modified from the methods of technology transferring for professionals.¹⁻³ This was based on transferring laser technology by learning both context and skills in laser dentistry in order to utilise laser dentistry for quality of life (Fig. 1). The instructional design (Fig. 2) comprised a twelve-hour interactive lecture on the basic and application of laser dentistry, a ten-hour related laboratory with co-operative learning after lecturing together with clinical demonstration from the dental students who had experiences in using lasers and a four-hour authentic evaluation and discussion using experiential-based learning. The laser techniques transferred to the students were as follows: soft tissue surgery⁴, tooth preparation, laser welding for



Fig. 1

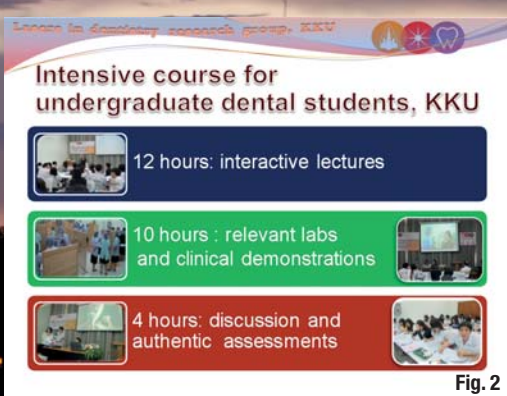

Fig. 2



Fig. 3

chronic oral ulceration^{5,6}, photocoagulation^{4,7} and low intensity laser therapy.^{6,8,9} The laser regimes in this course were founded on calibration and research conducted by the LDRG KKU team. These were also used routinely for treating patients at the faculty of dentistry already.

This one-week intensive course called "Laser Therapy in Dentistry: Research transferring to practice" (Fig. 3) was carried out with 45 final-year dental students, Khon Kaen University, 2013. For evaluation of this programme, a combined quantitative analysis and a qualitative reflection of the data from summative academic evaluation, the satisfaction of the students using questionnaires with a 10 cm visual analogue scale (VAS) and an open question were used.

_Results

The knowledge test ranges from 57 to 100 per cent (mean = 81.9, 95% CI = 79.2 to 84.6). The means of

self-assessments of the students' knowledge and confidence in practice were 8.4 (95 % CI = 8.0 to 8.8) and 9.0 (95 % CI 8.5 to 9.5), respectively, with correlation at 0.496 (P value = 0.001). The students were satisfied with this learning method at the mean VAS of 8.0 (95 % CI = 7.6 to 8.5). They thought that their skills were improved by the instructors' advices and the analytic thinking at the mean VAS of 9.2 (95 % CI 9.0 to 9.5) and 9.2 (95 % CI 8.9 to 9.5), respectively. From qualitative analysis, the students reflected their impressive experiences on the instructors and the team offering an intensely inspired learning, opportunities to expose a new technology as laser therapy and the learning style. This included student-centred learning, comprehensive knowledge, relaxed share of funny activities and practical laser hand-on offering the possibility to apply the gained knowledge to real-life clinical practice.

_Discussion

The intensive laser course for undergraduate dental students that we introduced was able to provide favourable knowledge, practical skills and attitude on laser dentistry in the learners. The important factors leading to this success were due to both instructional design for transferring technology and translation research to practice.^{1,2} Additionally, all of the laser therapy techniques taught in this course were created by LDRG KKU. The regimes of laser therapy were set up in the ranges of power and energy density. These allowed the students to practise the adjusting of lasers in detail and thereby to find out which were suitable for a variety of situations in real practice.

_Conclusion

This integrated instructional design for technology transferring and translation research "Laser Therapy in Dentistry" provided the abilities and good attitudes on laser dentistry for dental students.

Editorial note: A list of references is available from the publisher.

_contact	laser
<p>Assoc. Prof. Dr Sajee Sattayut Khon Kaen University Khon Kaen City, 40002, Thailand</p> <p>Tel: +66 9 45141644 Fax: +66 43348153</p> <p>sajee@kku.ac.th</p>	

Gain **power** at your **laser** clinics!

Author _Dr Anna Maria Yiannikos, Germany & Cyprus

_In this article, I discuss the next very important component of the marketing mix: promotion. There are two different kinds of promotion strategies: internal marketing, aimed at existing patients and their families (an example of this kind is referrals); and external marketing, aimed at those outside of the clinic. Research has proved that the most effective method to attract new patients is by word of mouth through internal marketing and that this approach attracts 80 per cent of new patients. External marketing, such as advertising or public relations, however will create awareness of the clinic among prospective patients, but very few new patients will actually visit the clinic. The following are six areas of promotion relevant to dental practices.

_Logo

The clinic's logo is its fingerprint; it is its identification. It should appear not only on the clinic's business card and stationery, but also on its outdoor signs, promotional items, uniforms and billing statements. The logo should be so identifiable with the clinic that people should be able to identify the clinic just by looking at the logo and without reading the name of the clinic.

_Business card

A business card provides a first impression of the clinic; it hints at the clinic's traits and what it stands for. A clinic's business card must make a powerful, positive personal impression by offering something out of the ordinary. For example, you could consider achieving this by means of

- a high-quality paper;
- a beautiful logo; or
- the unique use of colour.

_Newsletters

Dentists should think of newsletters as an important means of informing others about the clinic by communicating general information concerning the clinic or the services offered, as well as providing photographic material in order to communicate with patients visually and confirm the written content. Newsletters can be sent to patients by e-mail monthly, quarterly or yearly. Newsletter content could include the following for example:

- You could educate your patients about how you can prepare a tooth using laser.
- You could inform them about an educational seminar or congress that you have attended.
- You could introduce a new treatment or service that you have added to the clinic.

_Testimonial book

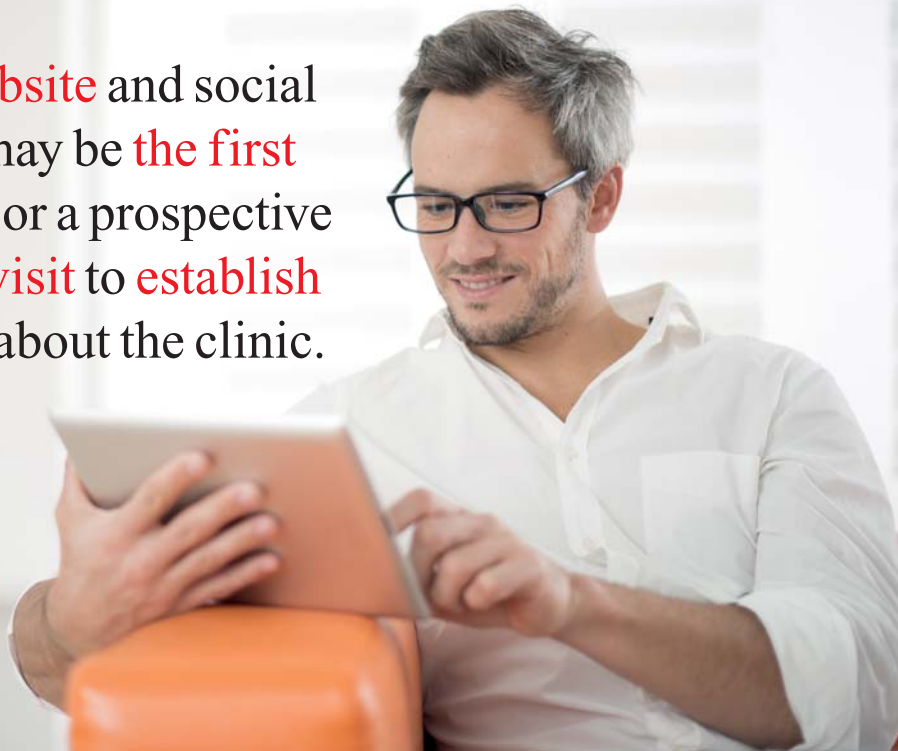Clinics can have a testimonial book either on the reception desk or in the waiting lounge. It is very comforting for new or existing patients of the clinic to read about the experiences and feelings of other patients at the clinic, especially in cases in which patients feel afraid or anxious about dental treatment, or mistrustful of the dentist.

A testimonial book is a very helpful marketing tool for two reasons: it reinforces a positive image of the clinic to the person writing the testimonial, and it encourages patients to accept the treatment recommended by the dentist and feel safer and more at ease.

_Web presence

A clinic's website and social media sites may be the first places a new or a prospective patient may visit to establish information about the clinic. The clinic's

A clinic's **website** and social media sites may be **the first places** a new or a prospective patient may visit to **establish information** about the clinic.



[PICTURE: ©JACK FROG]

competitive advantage should be clearly communicated on these sites in order to demonstrate instantly the benefits of visiting the clinic.

Presence in the dental field and networking

In addition, it is very important to establish a general presence in the dental field by presenting dentistry-related seminars or by writing articles for a journal or local newspaper, for example. In this manner, you can achieve recognition of your name and establish yourself as an expert. Such a presence acts as reinforcement for existing and prospective patients.

Furthermore, you could

- network with other professionals;
- offer scholarships or sponsorships bearing the dental clinic's logo;
- advertise or be invited to speak on television programmes or communicate via other media;
- be an active member of professional groups;
- volunteer for community activities;
- accept invitations to social functions;
- be present at political activities;
- present your hobbies and activities; or
- participate in a group form of a solo activity you enjoy, for example, if you like jogging, you could join an amateur running club that participates in charity races. You could also join a networking group, such as a social club, and attend at least two of its events a month.

Conclusion

Of course, you cannot adopt all of the above promotion strategies. Therefore, it is very important to make an accurate evaluation and invest more time and effort in those strategies that yield a greater return on your investment.

I would like to conclude with a powerful and inspirational quote from Kevin Roberts, CEO of global advertising company Saatchi & Saatchi: "Our goal, nowadays, is to create lovemarks not just brands." There is a difference between the two terms: brands are owned by companies; lovemarks are owned by us, dentists and professionals who love our jobs. Brands deliver performance, respect and trust. Lovemarks infuse intimacy (empathy, commitment and passion) and sensuality (triggers emotions). Our patients operate in terms of all five senses.

contact

laser



Dr Anna Maria Yiannikos

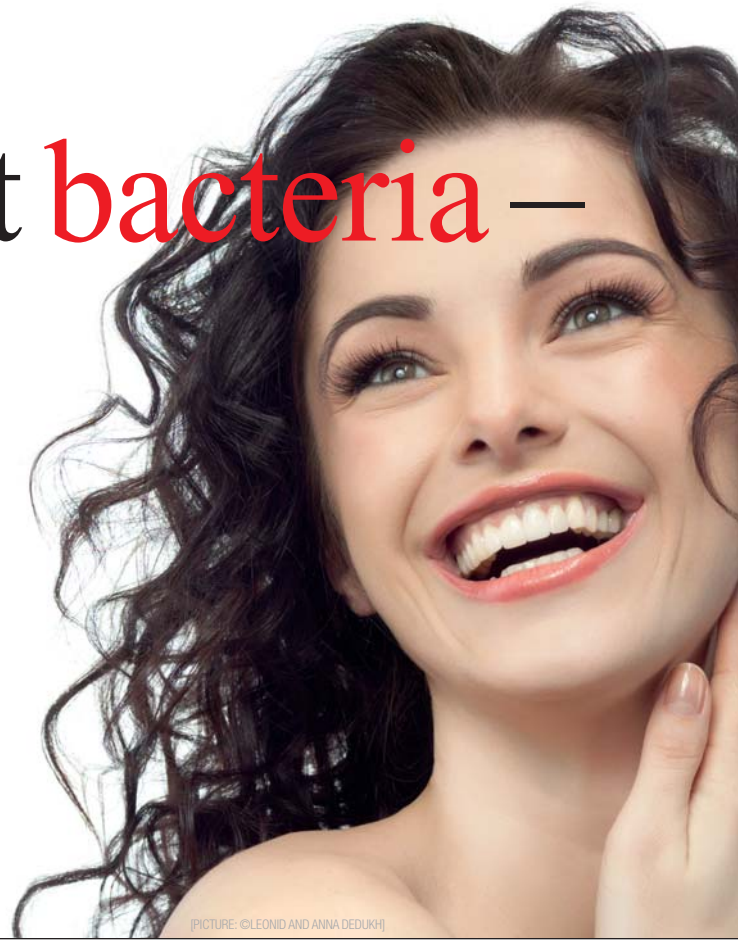Adjunct Faculty Member of AALZ at RWTH Aachen University Campus, Germany
DDS, LSO, MSc, MBA

dba@aalz.de
www.dba-aalz.com

Strong against bacteria – gentle to teeth and gingiva

Periodontitis and periimplantitis therapy with perio green®

Source_elexxion



PICTURE: ©LEONID AND ANNA DEDUKHI

With its new photodynamic agent perio green®, elexxion AG (based in Radolfzell, Germany) brings some colour to the realm of laser-supported periodontitis and periimplantitis therapy. In this interview, Dr Gordon John, scientific staff member of the Poliklinik für Zahnärztliche Chirurgie, University Hospital Düsseldorf, Germany, informs about this innovative agent.

Dr John, new technologies and materials usually aren't overnight inventions. How much time passed between the first idea until perio green's introduction to the market, and what is this new product based on?

In principle, the path from the initial idea to the final market approval of a product is long and tiring. Of course, new products must be tested with regard to their effects and, more importantly, unwanted counter effects as well as interactions with other medical products or medications. This is an essential part of patient protection. In the case of perio green®, ten years have passed from our initial idea until its application in periodontitis therapy, five years of which can be attributed to the certification process.

How does the photodynamic germ reduction with indocyanine green work? Is there any possible discomfort for the patient? Is the treatment performed under local or general anaesthesia?

The operating principle of photodynamic germ reduction or photodynamic therapy is based on placing a colouring agent in the periodontal pockets, which is activated by a light source and thus enfold its bactericidal effects. After its placement, indocyanine green (perio green®) penetrates the base of the pockets as well as small retention niches because of its very low viscosity, selectively colouring the bacterial cell walls. Endogenous cell components are not coloured. Perio green® is activated at a wavelength of 810 nm and a power of only 300 mW. Its main effect is based on a very high energy absorption of the light of the respective wavelength, which is expressed on local, short heat peaks. These result in the destruction of the bacterial cell walls, thus developing its bactericidal effect. Heat peaks are quite short and locally restricted. Therefore, neither are they noticed by the patients nor do they influence the surrounding healthy tissues. The term "photothermal therapy" would however be more accurate with regard to perio green®, as its effect relies on the impact of the photosensitizer in the form of released oxygen radicals.

A general anaesthesia is not required for germ reduction with perio green®. In most cases, even local anaesthesia is not necessary. In some cases, patients regard the insertion of the application or laser tip an unpleasant sensation. Here, local anaesthesia can be applied.

Perio green® allows a highly effective and pain-free adjuvant periodontitis and periimplantitis therapy. Are

there any risks for hard and soft tissues or any side effects?

Side effects for the dental hard tissues or surrounding soft tissues as well as any risks for restorations or implants are unlikely because of the low laser power.

For example, indocyanine green is applied intravasally in ophthalmology, visceral surgery or cardiology. Intravasal application results in a very low half-life period of indocyanine green of three to four minutes, a low toxicity and a safe intraoral and topical application. As *perio green*® is not resorbed by the intestinal mucosa, there are no serious risks for the patient even if it is swallowed during the procedure.

Systemic side effects have not been reported to date, and only a low number of allergic reactions have been described. However, indocyanine green does contain iodine and should thus be regarded cautiously in cases of iodine allergies.

Perio green® is distributed in the form of pills. How is it applied and could any colour residues of the photosensitizer remain on the root and implant surfaces?

It is correct that *perio green*® is distributed in the form of pills. This is necessary, since *perio green*®, in its operational, dissolved form, maintains its activity for only two hours. The photosensitizer is prepared chair-side, individually for each patient. This process couldn't be simpler: all necessary materials are delivered in aseptic packages. After one pill is placed in a mixing vessel, 2 ml of sterile water are added. After one minute, the solution is homogenous. The solution is then drawn into an aspiration cannula (red label), which is then exchanged with a thinner application syringe (green label). This is used to apply *perio green*® in the periodontal or periimplant pockets. After two minutes, the remaining colouring agent is rinsed off. In none of the previously treated cases, colouring residues were reported at the dental hard and soft tissues or implant structures. Afterwards, *perio green*® is activated via laser (810 nm wavelength, 300 mW) for one minute. The final treatment step is the rinsing of the pockets.

Does the photodynamic agent also remove mineralised plaque or does this require further measures?

Perio green® does not remove mineralised plaque. However, it is also not intended to do so. The mineralised biofilm should be removed mechanically, for example by special curettes. There can be up to 60 per cent of residual biofilm after the decontamination of rough implant surfaces, for example after treatment with plastic curettes. In this diluted, reduced biofilm, photodynamic/photothermal therapy can reach its full potential more easily, killing the remaining pathogenic germs.

*Which amount of time does therapy with *perio green*® take and how often does it have to be repeated*

*during recall? And another question: Is it mandatory that *perio green*® is applied by a dentist or can it also be applied by a trained assistant?*

A full-mouth application should take about one hour. If there are a high number of implants to be decontaminated, you should consider more time due to the rising difficulties in probing when compared to periodontal pockets. There are no general rules that can be applied to the repetition of the therapy. Patients should be recalled about two to three weeks after therapy for another clinical examination. Based on the results, any further steps should be decided upon individually. Highly putrid or refractory periimplantitis among our patients were treated with *perio green*®. After two or three applications, they entered a stable, stagnating situation. With regard to treatment delegation, there is still a grey area which has yet to be defined. That means: a non-invasive application can be transferred to dental assistants. However, the dentist is responsible for his personnel to be adequately educated and trained in the correct use of the equipment. The dentist must state the treatment indication and give instructions to start the therapy. The patient has to be informed about the delegation, and the dentist must supervise the procedure. Furthermore, the dentist is liable for any treatment consequences.

*New elexxion laser systems come with the software necessary for the application of *perio green*®. Can older devices also be modified?*

Older elexxion laser systems can be modified without any problems. All it takes is the new software to be loaded on the devices. This can be done during the standard safety check-up. In addition, elexxion offers another interesting service: if *perio green*® is ordered on a regular basis, we provide you with our laser system pico lite for free.

*What are your experiences with *perio green*® and can you recommend this treatment without any reservations?*

The application of *perio green*® is fairly easy, secure and effective. Of course you have to be aware of its restrictions. For example, you cannot expect a regenerative effect from the therapy. However, especially an effective decontamination of tooth or implant surfaces before surgical-regenerative therapies can help to prepare the defect situation. Furthermore, the application of *perio green*® can result in even difficult situations becoming static, thus prolonging implant preservation, for example if the patient does not approve of any surgical procedure. Photothermal therapy with *perio green*® can reduce the widespread application of antibiotics in dentistry, along with its side-effects, significantly.

Thank you for this interesting conversation.

“We still have a long way to go”

Author_Daniel Zimmermann, Germany

(PICTURE: ©OLLYY)

First introduced in the early 1990s, dental lasers are now used in almost every area of dentistry. *DT Asia Pacific* had the opportunity to speak with Dr Kirpa Johar, a dentist from Bangalore in India who received his dental laser education from the University of Vienna, about new trends in the field and the difficulties in Asia of it becoming a mainstream product despite its clinical benefits.

“Last year, the first carbon dioxide (CO₂) laser, which is also suitable for hard-tissue indications, received approval by the Food and Drug Administration in the US. Could this be the next big thing in laser dentistry, in your opinion?”

A CO₂ laser receiving FDA approval for hard-tissue indications looks promising and could definitely be a game changer, as it could alter the way we understand laser dentistry right now. We will have to wait and see how things develop in this regard.

“The laser community is split about whether CO₂ or erbium-based lasers are the superior technology. Which type do you think is better suited to dental applications?”

CO₂ lasers are usually considered to cut faster and with more precision. They also offer several advantages, such as galvanometer manipulation of the beam, a foot pedal to control speed and the ability to change the spot size with a tap on the touch screen. However, in Asia, being a price-sensitive market, the cost of dental equipment is always a decisive factor. I think a performance evaluation comparing erbium

and CO₂ lasers supported by more clinical studies would provide us with a better understanding of which technology is more suited to which application.

“Since dental lasers were introduced in the early 1990s, the range of treatments has expanded from soft-tissue treatment to cosmetic dentistry and endodontics, for example. In which areas of dentistry is this technology most commonly used at the moment?”

In this part of the world, dental lasers are commonly used for soft-tissue applications, including surgical, cosmetic and endodontic sterilisation. A contributing factor to this trend is that diode lasers have become more affordable and are available on the market in much larger variety. As lasers allow surgical procedures on soft tissue to be performed with no sutures and less anaesthesia, they are increasingly used in surgical and mucogingival procedures.

“Is this one of the fields in dentistry to have benefited most from dental lasers?”

Besides mucogingival procedures, I personally think that periodontal treatment has gained most from the use of laser technology. More patients are definitely motivated to undergo various periodontal procedures done with lasers compared with conventional surgery. Flap surgeries where bone loss is not very advanced, release of tongue-tie in infants, gingivectomies and operculectomies are some of the procedures that are simplified with laser.

“Wound healing appears to benefit particularly from laser therapy. Could you explain why?”

In my practice, I have seen good results in wound healing in cases in which I have used laser therapy for

soft-tissue injuries and lacerations in the orofacial region after trauma, as well as in post-extraction cases. Post-operative discomfort was reduced too.

The biostimulatory effects of laser have been thoroughly investigated. In vitro experimental evidence has demonstrated the acceleration of collagen synthesis in fibroblast cultures. Increased formation of granulation tissue and increased rates of epithelialisation in laser-irradiated wounds were some of the effects found in in vivo tests on animals. Low-level laser therapy has proven to be a great boon in wound healing.

With a penetration into dental practices of 20 to 50 per cent, dental lasers cannot exactly be called a mainstream product. Would you agree with that statement?

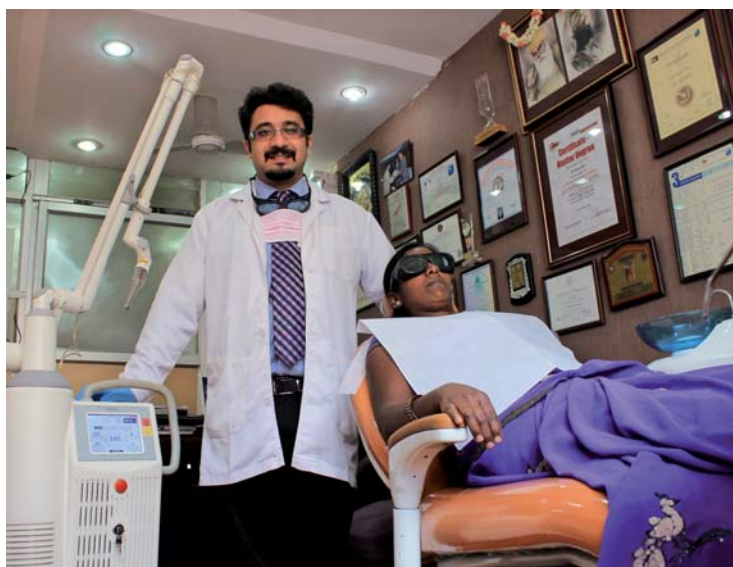It is true that dental lasers are not very common, even in technologically advanced countries. In Asia, the use of laser dentistry is still marginal. I remember when I started working with dental lasers in my practice eight years ago, this field of treatment was completely unknown and the benefits of lasers were not yet fully understood then. Awareness among the dental community however has improved and the market is growing, but we still have a long way to go in lasers being recognised as a mainstream product.

You offer international laser dentistry courses in India. What is the most common misconception concerning laser technology that you have encountered there?

I think the most common misconception still is that laser dentistry is for the elite and that it will not work in the practice owing to the cost-benefit ratio. However, more dentists have recently begun to realise that lasers can improve their patient experience and help them add more procedures to the practice, which in turn makes it more profitable and rewarding.

What is clearly lacking in this field is unbiased quality education. Dentists need to understand that with the use of dental lasers they would be providing better dentistry to their patients and would make their own work more comfortable, which would in turn lead to happier patients, more referrals, and the subsequent overall growth of their practice. My academy, Laser Dentistry Research and Review, is working in this direction and we hope to become a centre in Asia known for helping dentists receive the best in laser dental education and add value to their practice.

Once the use of dental lasers increases, more competitors will come into the market, which would help to keep prices competitive—which is good as long as the competition stays healthy. However, cost still plays an important role in the acquisition of the technology, particularly when it comes to hard-tissue lasers.



Can dental lasers be economically viable?

Dr Johar Kippar.

They definitely are. The simplification of many procedures with laser dentistry makes it possible to perform them in-house without having to refer the patient to a specialist. As the dentist would be considered someone providing the best in his or her field, referrals and income would most likely increase. I foresee that within the next decade every dental clinic will possess at least a soft-tissue laser. It is just a matter of time.

What would manufacturers have to do to make this technology more attractive to the masses?

Hard-tissue lasers need to evolve to a stage where they can be expanded to crown preparation and implant dentistry. If erbium lasers were capable of providing a wider range of applications along with routine soft-tissue procedures, this would make them more attractive. Dental Er:YAG lasers are now being developed for non-surgical facial aesthetic treatment and non-surgical treatment of sleep apnoea. Adding these procedures to the practice by incorporating laser technology will also help dentists make the investment in lasers a more viable option.

Laser experts and companies claim that laser technology is the future of dentistry. In your opinion, what role will the technology really play in clinical practice?

Laser dentistry definitely changes the way we practise dentistry. It is minimally invasive, simplifies things and reduces patient discomfort, as well as post-operative complications. It gives the dentist scope to expand his or her services to other fields, such as facial aesthetics or sleep apnoea treatment. These are some of the factors that make me believe that laser dentistry is the future of dentistry.

Thank you very much for the interview.

Laser Dentistry in the City of Light

Welcome to Paris

Author_Katrin Maiterth

For the 14th World Congress for Laser Dentistry, the WFLD chose—in the words of Prof. Josep Arnabat, chairman of the European Division of WFLD—“one of the most beautiful and breathtaking cities in the whole world” as their location. „Paris is a city of culture, artists, designers and researcher”, Arnabat states. In fact, this statement describes the emotional perspective most people might associate with Paris as well as the main themes of this place.

Starting its life as the Celto-Roman settlement Lutetia on the island in the Seine, the city got its present name from the then dominant tribe Parisii. In medieval times, the small settlement expanded onto the right bank into the so-called le Marais. Nowadays, this area is one of the most stunning and oldest quarters in Paris, where still a number of historical buildings can be seen. At first populated by the working-class and immigrants, le Marais evolved to a wealthy and prestigious quarter. Surely, this is not the liking of all. But without a doubt, it has made this area a well worth seeing place to eat, drink, lounge and walk around.

In the middle ages, also one of the most important centres for learning in old Europe was founded: the Parisian University Sorbonne. Divided into the faculties Arts, Medicine, Theology and Law, the university brought forth lots of famous clever and creative heads. For several hundred years, students from all over Europe, if not the whole world, came here to expand their knowledge and still do.

Thanks to the aims of governing elites to set themselves a monument, numerous impressing buildings such as Notre Dame, Arc de Triomphe, Louvre, Palais Royal or Eiffel Tower were built up in the course of time. More and more, the city became the cultural and intellectual hub of the Western world with its philosophers, scientists, artists and



[PICTURE: ©PLUSONE]



[FRAME: ©LIGRAPHIE, PICTURE: ©ADAM WASILEWSKI]



[FRAME: ©LIGRAPHIE, PICTURE: ©NERFY]

literati. They got together in scientific houses, parks or in one of the hundreds of Parisian cafés—places for bruits publics and rumour. The first café was established by François Procope in 1686 and became the midpoint of Enlightenment with famous people like Rousseau, Voltaire and Diderot stopping by.

Nowadays, with about 23 per cent of the total population born outside of France, Paris is one of Europe's biggest melting pots of nations. Germans, Italians, Russians, Armenians, Poles, Spaniards, Portuguese, African and Asians—since the beginning of the 19th century, people from many different countries immigrated to Paris and made the city's culture even richer and colourful in the course of time. Besides a visit of the classic Paris, it is always a good idea to just stroll through small alleys and hang out in cosy cafés, eating pastry and drinking café au lait. Around Place de la Bastille one can check out young fashion designers and newest street wear, find romantic places as well as neo-punk lolitas, tattooing and mangas. The bustling Parisian street markets invite their visitors to buy food and wine, maybe for a romantic picnic in a park or along the Seine.

When the evening comes, haute cuisine restaurants are waiting for their guests to serve fine and delicious food— don't forget to start the evening in the civilised French way with an aperitif hour. Finally one maybe ends up in Paris nightlife in trendy bars or clubs for dancing. In the summer, there are several outdoor music events, bringing people onto the street or Paris Plages.

There has been said a lot about Paris and it has been given many names over time: "International capital of style", "City of culinary finesse", "Best place to pick ideas", "City of love", "Heaven for all women's obsessions" and the "City of light"—just to mention a few. But of course, it's always better to get ones own expression.



Rimini show confirms that the future of dentistry is digital



Fig. 1 GALAXY BioMill System, which allows digital fabrication of restorations chairside.

The use of digital technology seems to be changing dentistry forever and nowhere has this been more obvious than in Italy last week, where numerous manufacturers from Italy and abroad showcased their latest devices and materials to thousands of dental professionals at this year's Amici di Brugg dental show.

Besides Henry Schein's ConnectDental pavilion, a booth dedicated entirely to the company's combined portfolio for an all-out digital workflow and other services such as Sirona's Digital Dental Academy, a new application designed for Google Glass drew special attention from visitors. Specifically designed to work on the head-mounted device, Dental Glass is intended to improve workflow in dental practices by projecting information directly in the clinician's field of view, similar to a pilot's head-up display. This way, clinicians can remotely access patient records, among other data, display radiographic images, or manage appointments through voice recognition software or a touchpad located at the earpiece, according to the Italian developer Gerhò, a subsidiary of the Breitschmid group. The manufacturer said that the app will also allow the capture of photos and video in high-definition format through its built-in camera.

Google Glass is currently only available in the US. When the device will be released to European markets is still unclear owing to some technical limitations and the lack of distributors, according to reports. The technology, however, is currently being experimented on for its future use in general and dental medicine. Last year, for example, *Dental Tribune* reported on the first maxillofacial surgery broadcast with the device, which took place at Hospital de Molina in Murcia in Spain.

Completely digital solutions however are already available in dental offices. Biolase, for example, offers such solutions and has expended great effort on its Total Technology Solution in recent years. In addition to its complete range of dental lasers, the US dental technology company now offers sophisticated imaging equipment and CAD/CAM solutions, such as the GALAXY Bio-Mill System, which allows digital fabrication of restorations chairside.

"The adoption cycle of new technologies is growing increasingly shorter and more advanced technologies like the Waterlase will rapidly find their way into dental practices. Dentists that do not upgrade their equipment will likely begin to lose patients, become uncompetitive and lag behind," CEO Federico Pignatelli explained to *Dental Tribune International* (DTI) at the show.

DTI CEO and publisher Torsten R. Oemus invited dentists who are unsure about how digital technologies could benefit their practice to attend the Digital Dentistry Show, the first edition of which will be held in autumn 2014 at the International Expodental show in Milan in Italy. Focusing entirely on digital products and applications for dentistry, the unique expo format will not only showcase the latest products and solutions by leading providers in the field, but also offer education in the form of lectures and webinars from 16 to 18 October. Information about what to expect from the event and how to register is available on the events website www.digitaldentistryshow.com/Milan.

IDEM Singapore 2014 was

A record-breaking success



This year's IDEM Singapore demonstrated why it is Asia's leading dental trade fair and scientific conference with record breaking numbers of exhibitors, conference tracks and attendees. The event saw more than 500 exhibitors from 38 countries showcasing the latest innovations in clinical dentistry, dental technology and patient care across every segment of the dental market, covering restorative and preventive treatments, surgical procedures and equipment, orthodontics, endodontics, periodontics and laboratory tools. The IDEM Singapore trade fair was the first ever to fill

both floors of exhibition space covering 16,000 sqm. The trade fair and conference welcomed 7,842 participants from 61 countries over three and a half days. IDEM Singapore is increasingly seen as the gateway to Asia for dental manufacturers and distributors wishing to break into Asian markets and this was reflected in the high number of first time exhibitors; 170 or 30 per cent were new to IDEM Singapore this year.

The conference theme this year was "Dentistry—The Future Is Now" with the programme focusing on the future of dentistry, addressing the challenges and the procedural and technical advances in the various fields of dentistry. The increased representation from countries in the Asia-Pacific region such as Australia, Cambodia, Taiwan, Hong Kong, Korea, Japan, New Zealand, Myanmar and Sri Lanka, highlighted another trend: IDEM Singapore, long considered the event where East meets West, is now also increasingly seen as the gathering point for different parts of the East to meet each other. The next edition will be staged from April 8 – 10, 2016.

The latest news about

IDS 2015 at a glance



From 10 to 14 March 2015, Cologne will once again become the capital of the dental world when the International Dental Show (IDS) opens its doors to visitors from around the globe for the 36th time. *Dental Tribune* will be keeping its readers up to date with a topic page solely dedicated to the latest information about the most important dental industry show.

worldwide well informed about the latest innovations in dentistry.

In anticipation of the event, the topic page will offer an overview of the developments prior to the show, as well as a number of review stories on past IDS editions.

Alongside its official today trade show newspaper and regular e-newsletters, *Dental Tribune* will be providing comprehensive coverage of major events of the five-day show on a daily basis through the IDS 2015 topic page.

An on-site editorial team will be conducting exclusive interviews and reporting on product launches and new technologies to keep dental professionals

Periodontal therapy may reduce

Medical expenses and hospitalisations

A study has provided new evidence for the importance of treating periodontal disease in patients with chronic systemic diseases. From 2005 to 2009, 338,891 individuals were recruited for the study. All participants had periodontal disease and one or more of the following conditions: Type 2 diabetes, coronary artery disease, cerebrovascular disease, rheumatoid arthritis, and pregnancy.



Comparing the insurance data of patients who had received periodontal treatment and those who had not been treated, the researchers found that medical costs and hospitalizations were significantly reduced in the first group. With regard to hospitalizations, the researchers found that admissions decreased by 39.4 per cent, 21.2 per cent, and 28.6 per cent in patients with Type 2 diabetes, cerebrovascular disease, and coronary heart disease, respectively.

According to the latest figures provided by the Centers for Disease Control and Prevention, over 47 per cent of US adults aged 30 and older have some form of periodontal disease. The condition is more common in men (56.4 per cent) than in women (38.4 per cent). It is also more common in people living below the federal poverty level (65.4 per cent), those with less than a high school education (66.9 per cent), and current smokers (64.2 per cent).

The study, titled "Periodontal Therapy Improves Outcomes in Systemic Conditions: Insurance Claims Evidence," was presented at the Annual Meeting and Exhibition of the American Association for Dental Research on March 21. It was conducted by researchers at the University of Pennsylvania in collaboration with dental insurance provider United Concordia.

laser
international magazine of laser dentistry



Publisher

Torsten R. Oemus
oemus@oemus-media.de

CEO

Ingolf Döbbecke
doebbecke@oemus-media.de

Members of the Board

Jürgen Isbaner
isbaner@oemus-media.de

Lutz V. Hiller
hiller@oemus-media.de

Editor in Chief

Norbert Gutknecht
ngutknecht@ukaachen.de

Coeditors in Chief

Samir Nammour
Jean Paul Rocca

Managing Editors

Georg Bach
Leon Vanweersch

Division Editors

Matthias Frentzen
European Division

George Romanos
North America Division

Carlos de Paula Eduardo
South America Division

Toni Zeinoun
Middle East & Africa Division

Loh Hong Sai
Asia & Pacific Division

Senior Editors

Aldo Brugneira Junior
Yoshimitsu Abiko
Lynn Powell
John Featherstone
Adam Stabholz
Jan Tuner
Anton Sculean

Editorial Board

Marcia Martins Marques, Leonardo Silberman, Emira Ibrahim, Igor Cernavin, Daniel Heyselaer, Roeland de Moor, Julia Kamenova, T. Dostalova, Christliebe Pasini, Peter Steen Hansen, Aisha Sultan, Ahmed A Hassan, Marita Luomanen, Patrick Maher, Marie France Bertrand, Frederic Gaultier, Antonis Kallis, Dimitris Strakas, Kenneth Luk, Mukul Jain, Reza Fekrazad, Sharonit Sahar-Helft, Lajos Gaspar, Paolo Vescovi, Marina Vitale, Carlo Fornaini, Kenji Yoshida, Hideaki Suda, Ki-Suk Kim, Liang Ling Seow, Shaymant Singh Makhan, Enrique Trevino, Ahmed Kabir, Blanca de Grande, José Correia de Campos, Carmen Todea, Saleh Ghabban Stephen Hsu, Antoni Espana Tost, Josep Arnabat, Ahmed Abdullah, Boris Gaspirc, Peter Fahlstedt, Claes Larsson, Michel Vock, Hsin-Cheng Liu, Sajee Sattayut, Ferda Tasar, Sevil Gurgan, Cem Sener, Christopher Mercer, Valentin Preve, Ali Obeidi, Anna-Maria Yannikou, Suchetan Pradhan, Ryan Seto, Joyce Fong, Ingmar Ingenegeren, Peter Kleemann, Iris Brader, Masoud Mojahedi, Gerd Volland, Gabriele Schindler, Ralf Borchers, Stefan Grümer, Joachim Schiffer, Detlef Klotz, Herbert Deppe, Friedrich Lampert, Jörg Meister, Rene Franzen, Andreas Braun, Sabine Sennhenn-Kirchner, Siegfried Jänicke, Olaf Oberhofer, Thorsten Kleinert

Editorial Office

Georg Isbaner
g.isbaner@oemus-media.de

Claudia Jahn
c.jahn@oemus-media.de

Executive Producer

Gernot Meyer
meyer@oemus-media.de

Designer

Sarah Fuhrmann
s.fuhrmann@oemus-media.de

Customer Service

Marius Mezger
m.mezger@oemus-media.de

Published by

OEMUS MEDIA AG
Holbeinstraße 29
04229 Leipzig, Germany
Tel.: +49 341 48474-0
Fax: +49 341 48474-290
kontakt@oemus-media.de
www.oemus.com

Printed by

Silber Druck oHG
Am Waldstrauch 1
34266 Niestetal, Germany

laser international magazine of laser dentistry is published in cooperation with the World Federation for Laser Dentistry (WFLD).

WFLD Headquarters

University of Aachen Medical Faculty
Clinic of Conservative Dentistry
Pauwelsstr. 30, 52074 Aachen, Germany
Tel.: +49 241 808964
Fax: +49 241 803389644
ngutknecht@ukaachen.de
www.wfld-org.info

www.laser-magazine.com

Copyright Regulations

laser international magazine of laser dentistry is published by OEMUS MEDIA AG and will appear in 2014 with one issue every quarter. The magazine and all articles and illustrations therein are protected by copyright. Any utilization without the prior consent of editor and publisher is inadmissible and liable to prosecution. This applies in particular to duplicate copies, translations, microfilms, and storage and processing in electronic systems.

Reproductions, including extracts, may only be made with the permission of the publisher. Given no statement to the contrary, any submissions to the editorial department are understood to be in agreement with a full or partial publishing of said submission. The editorial department reserves the right to check all submitted articles for formal errors and factual authority, and to make amendments if necessary. No responsibility shall be taken for unsolicited books and manuscripts. Articles bearing symbols other than that of the editorial department, or which are distinguished by the name of the author, represent the opinion of the afore-mentioned, and do not have to comply with the views of OEMUS MEDIA AG. Responsibility for such articles shall be borne by the author. Responsibility for advertisements and other specially labeled items shall not be borne by the editorial department. Likewise, no responsibility shall be assumed for information published about associations, companies and commercial markets. All cases of consequential liability arising from inaccurate or faulty representation are excluded. General terms and conditions apply, legal venue is Leipzig, Germany.

**A.R.C.
LASER**

enlighten your surgery.

FOX

SUCCESSFUL with Photothermal Therapy (PTT)

APPLICATIONS

- ▶ Endodontics
- ▶ Periodontology
- ▶ Surgery
- ▶ Periimplantitis
- ▶ Implantology
- ▶ Biostimulation
- ▶ Bleaching
- ▶ PTT - EmunDo®
PA without antibiotics

ADVANTAGES

- ▶ Stores Treatment
Protocols as Presets
- ▶ Easy to use
- ▶ Internal
PowerMeter
- ▶ Affordable Fiber
Optics
- ▶ Battery driven
- ▶ Video Function



EmunDo®
antibacterial

www.arclaser.com

Fotona[®]
choose perfection



ADMED.com

50 years
of Fotona laser innovations

The first digitally controlled
dental laser handpiece

X-Runner[™]

- instantly adjustable spot size and shape
- precise coverage of large areas
- lightweight, ergonomic design
- for Fotona LightWalker AT laser systems



The universe at your fingertips.

• LightWalker[®]



Eendo a Class
سیستم هوشمند اندوروتاری
۱۵ حافظه، ۰ انیون ترک (user friendly)

KI20
موتور جراحی ایمپلنت
قدرتمندترین موتور جراحی ایمپلنت دنیا
با ترک ۹۰ نیوتن

ENDO SMART
سیستم هوشمند
اندوروتاری

IROOTS
اپکس لوکیتور
نسل پنجم با دقت ۹۸/۸
با نرم افراز ویژه

Rootor
اپکس لوکیتور

Cybrid
لایت کیور
با قدرت فوق العاده ۲۷۰۰ وات



Endo pex
آبچوراتور (گان + هیت کریر)

سیستم تزریق گرم گوتا پرکا و فیلینگ ورتیکال با تراکم عمودی
ساده و آسان با نتیجه متفاوت



E&QMASTER
آبچوراتور (گان + هیت کریر)



GENESYS
آبچوراتور (گان + هیت کریر)