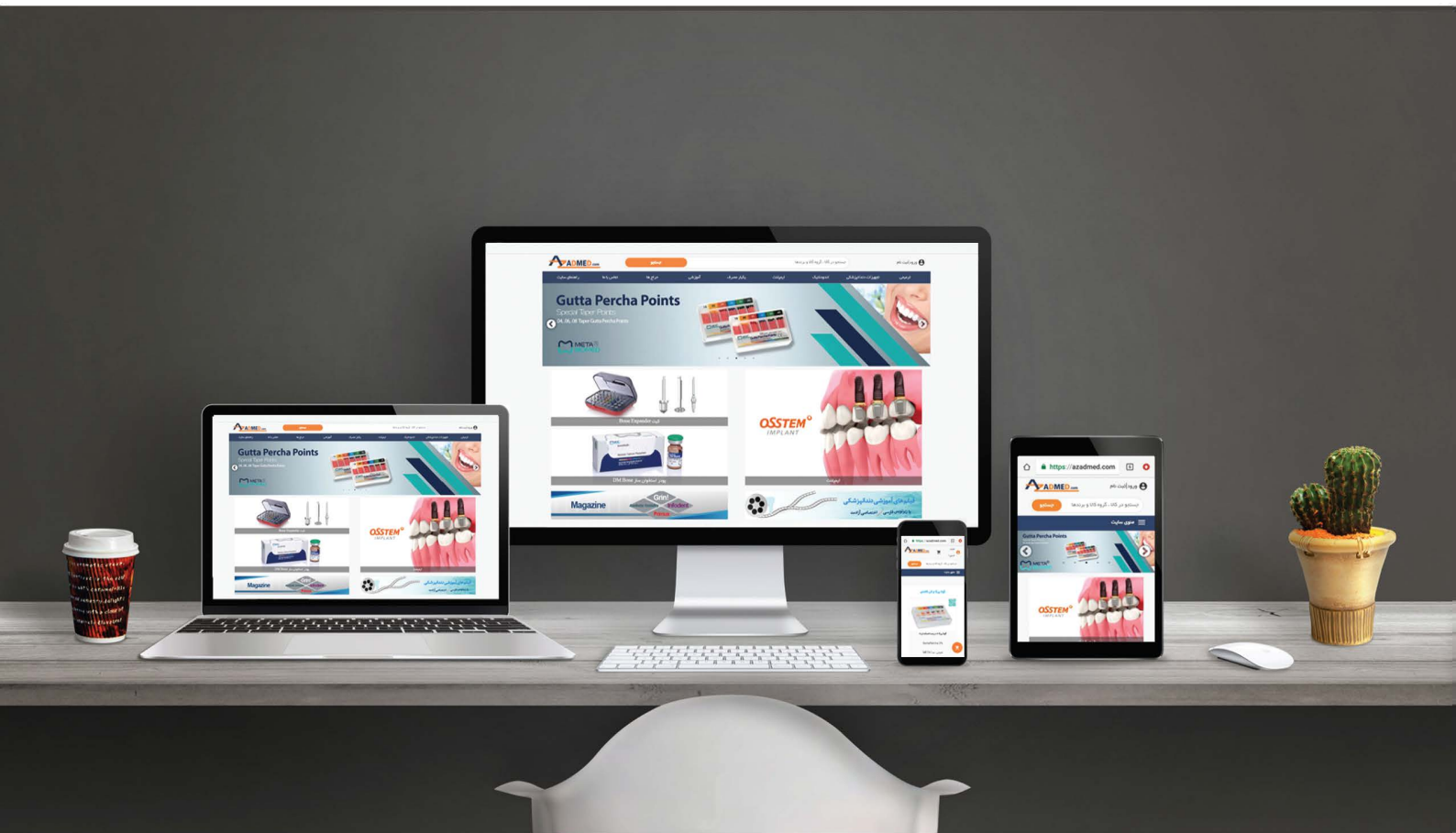




آزاد تجارات پارس
AZAD TEJARAT PARS.LTD

AZADMED.com



www.azadmed.com



 azaadtejaratpars

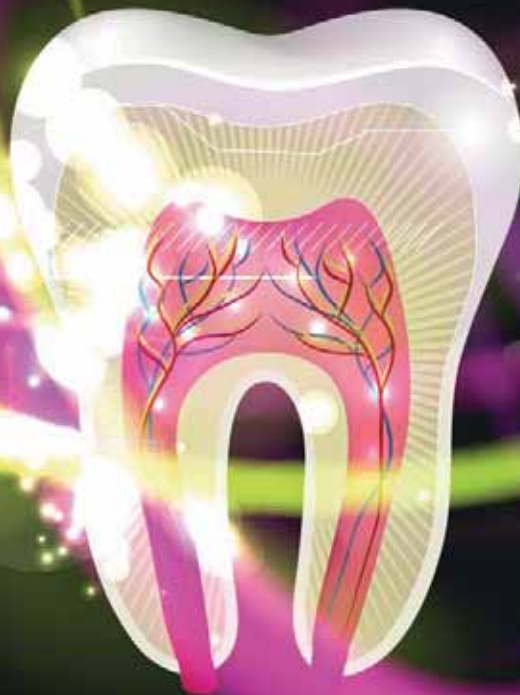 @azadmed2

 88 98 80 63 - 6

laser

international magazine of laser dentistry

3²⁰¹⁴



| **research**

Er:YAG-Laser — The key factor in the therapy of periimplant inflammations

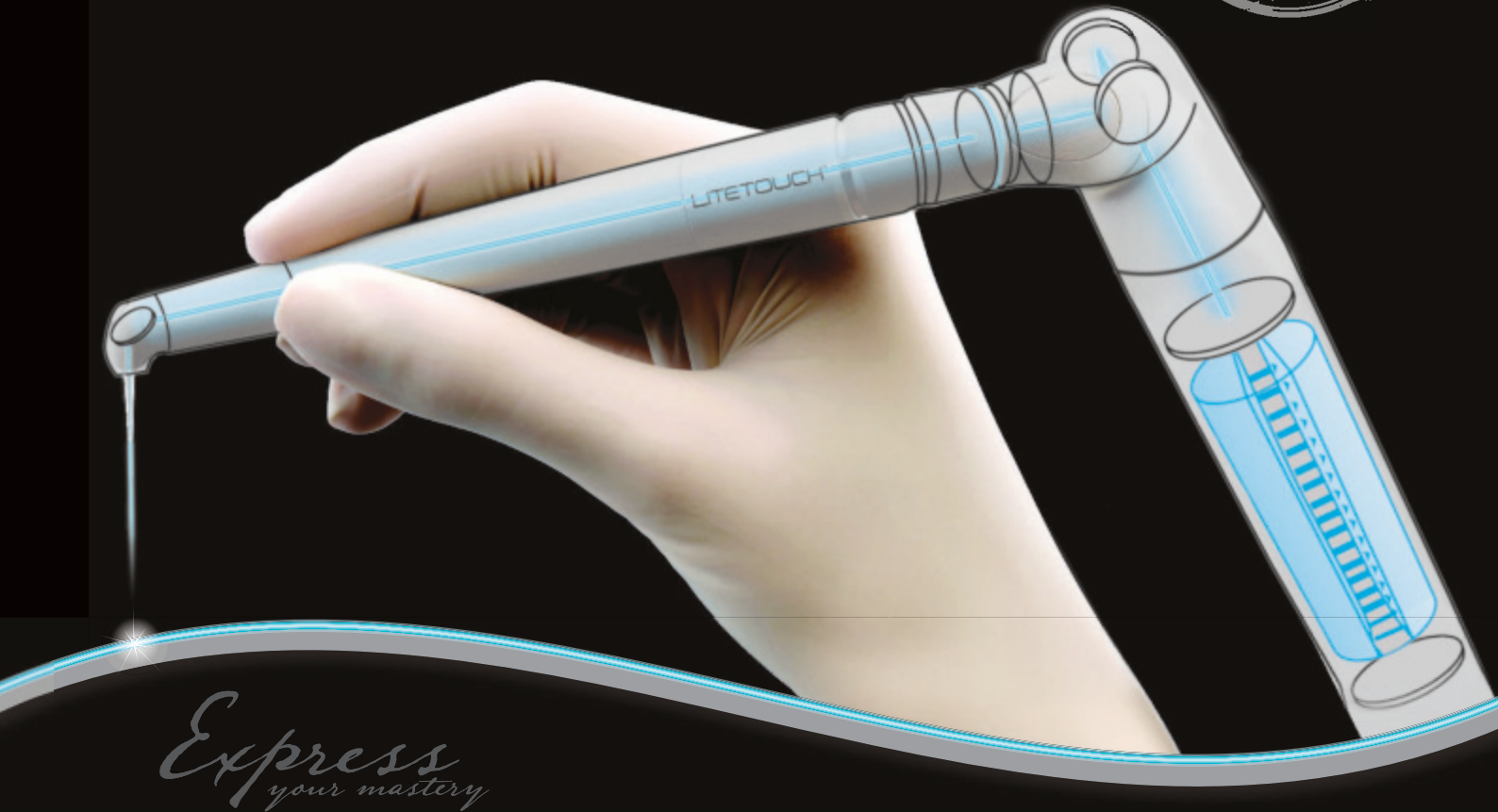| **case report**

Peripheral Giant Cell Granuloma surgery with diode laser

| **industry report**

Subjective acceptance and pain perception of Er:YAG laser therapy in children





*Express
your mastery*

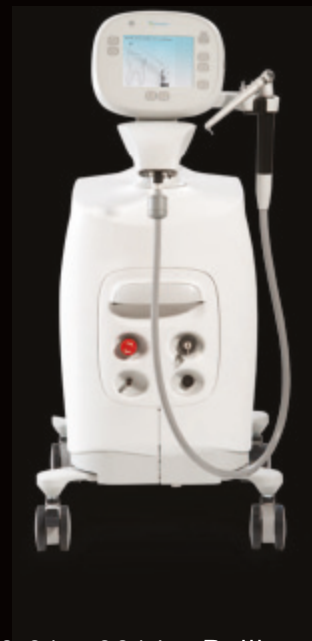Education. Technology. Family.

Join the Light Instruments Family

presenting

LITETOUCH™

The unique fiber-free Er:YAG laser
that has changed the face of laser dentistry



LHF877693EN



Live presentations every hour at our booth during Sept 20-21 ,2014, Beijing, China
at the 8th Congress of the International Society for Oral Laser Applications: <http://tfr852712.douhao.net.cn>

Reserve your personal consultation at dental@syneron.com
WWW.SYNERONDENTAL.CN WWW.SYNERONDENTAL.COM



A new level in laser dentistry



Prof. Dr. Norbert Gutknecht
Editor-in-Chief

Dear colleagues,

Laser dentistry would lose its appeal if there was no development in this innovative technology visible. At this year's WFLD congress, a portion of this innovative potential, which is still inherent to laser technology, was presented. This includes technical modifications on laser systems combined with new treatment results and indication areas with proved as well as standardised laser systems.

On the occasion of the WFLD congress, the proceeding integration of laser technology to dental treatment processes could be followed in the individual lectures. Afterwards, the speakers' abstracts could be reread in the WFLD congress edition.

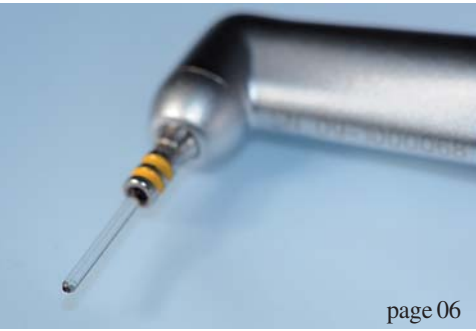The increasingly more refined and differentiated adjustment options of modern laser systems do more and more represent a great challenge for operators. Since control software of individual laser systems also pursue different technical goals, a direct comparison of settings is no longer possible today due to different performances which are emitted on the tissue. In previous times, for handling only few adjustment options a good training of the respective laser systems had been necessary in order to perform a successful treatment. With this in mind, how much more does a dentist need to be engaged to receive a solid training today in view of more than 30 adjustment and combination possibilities?

For this reason, the responsible dentist should look for an educational institute where the technical basics of laser systems, the bio-physical interactions between laser light and tissue as well as the relevant clinical indications are taught and demonstrated. A register of this institutions can be obtained by the WFLD headquarter (info@wfld.info).

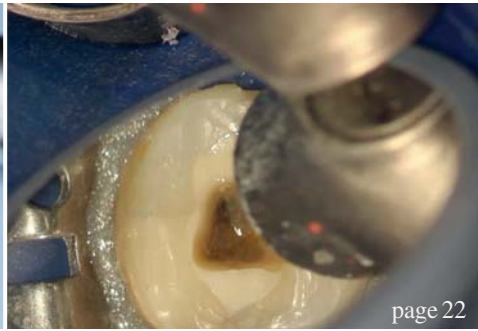
Kind regards,

A handwritten signature in black ink, appearing to read 'Norbert Gutknecht', written in a cursive style.

Prof. Dr. Norbert Gutknecht
Editor and CEO WFLD



page 06



page 22



page 32

| editorial

03 A **new level** in laser dentistry
| Prof. Dr Norbert Gutknecht

| research

06 **Er:YAG-Laser**—The **key factor** in the **therapy**
of **periimplant** inflammations
| Jiaoshou (Prof.) Dr Frank Liebaug *et al.*

16 **Alveolar** corticotomies by **laser**cision
| Dr Brice Savard

| overview

22 **Laser** activated **irrigation**—Part II
| Prof. Dr Roeland Jozef Gentil De Moor *et al.*

| case report

28 Peripheral **Giant Cell** Granuloma **surgery**
with **diode laser**
| Maziar Mir *et al.*

| industry report

32 **Subjective acceptance** and pain perception of
Er:YAG laser therapy in children
| Ani Belcheva *et al.*

36 The Delta Cube laser:
a **multi-wavelength diode laser**—Part I
| Prof. Dr Jean-Paul Rocca *et al.*

| economy

40 How **crisis** made me **doubt** my degrees!
| Dr Anna Maria Yiannikos

| interview

42 **Laser** application in **dental surgery**:
CO₂ laser for **soft tissues**
| Interview with Prof. Dr Michael Bornstein

| meetings

44 **Düsseldorf**—Beauty on the **Rhine**
| Katrin Maiterth

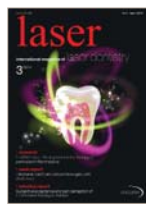46 **14th WFLD World Congress**:
The ever **increasing** use of **laser** in **dentistry**
| Aldo Brugnera Jr.

| news

48 **News**

| about the publisher

50 | imprint



Original Backgrounds: ©flaxy; GRei
Artwork by Sarah Fuhrmann, OEMUS MEDIA AG.



page 42



page 44



page 46

Fotona[®]
choose perfection



The first digitally controlled
dental laser handpiece

X-Runner[™]

- instantly adjustable spot size and shape
- precise coverage of large areas
- lightweight, ergonomic design
- for Fotona LightWalker AT laser systems

50 years
of Fotona laser innovations



The universe at your fingertips.

• LightWalker[®]

Er:YAG-Laser—The key factor in the therapy of periimplant inflammations

Authors_Jiaoshou (Prof.) Dr Frank Liebaug & Dr Ning Wu, Germany

Introduction

Today, dental implants are widely accepted by patients and are seen as a desired therapy for the restoration of partly or wholly edentulous jaws. As a result, this therapy option is applied more and more often in the daily practice. It follows that the number of periimplantitis cases, an infection of the periimplant tissue, increases. Thus, periimplant inflammations will become more and more important for dentists in the future.

The prerequisite for the development of products for the prevention and therapy of periimplant disease is of course a sound knowledge of its aetiology, pathogenesis and epidemiology. The majority of early clinical studies used to judge the quality of treatment results by survival rates, with the implants remaining physically in the oral cavity. In the beginning, authors saw mechanical incidences as the reason for implant loss rather than biological causes. Today, the health status of periimplant tissues has become a focal point for implant survival. Although implant treatment is perceived to be generally successful, periimplant infections occur fre-

quently. These are called periimplant mucositis or periimplantitis. Much like periodontal diseases, periimplant diseases are of an infectious origin and can ultimately lead to the loss of the bone supporting the implant.

In periimplant mucositis, the inflammation is by definition restricted to the periimplant mucosa, while periimplantitis also includes the periimplant bone. For positive long-term results of implants as well as for the prevention and treatment of oral infections, these diseases must be monitored.

The available epidemiological data suggest that one in five patients will develop periimplantitis sooner or later, and that, in general, periimplant mucositis often occurs in implant patients. Currently, only limited data about the treatment of periimplant diseases are available. Most of the procedures are oriented towards periodontitis therapy. The most important therapy aim is infection control. This can include the adjustment of dentures, if their form impairs an adequate oral hygiene or the professional cleansing of the implant surface from biofilm and calcifications.

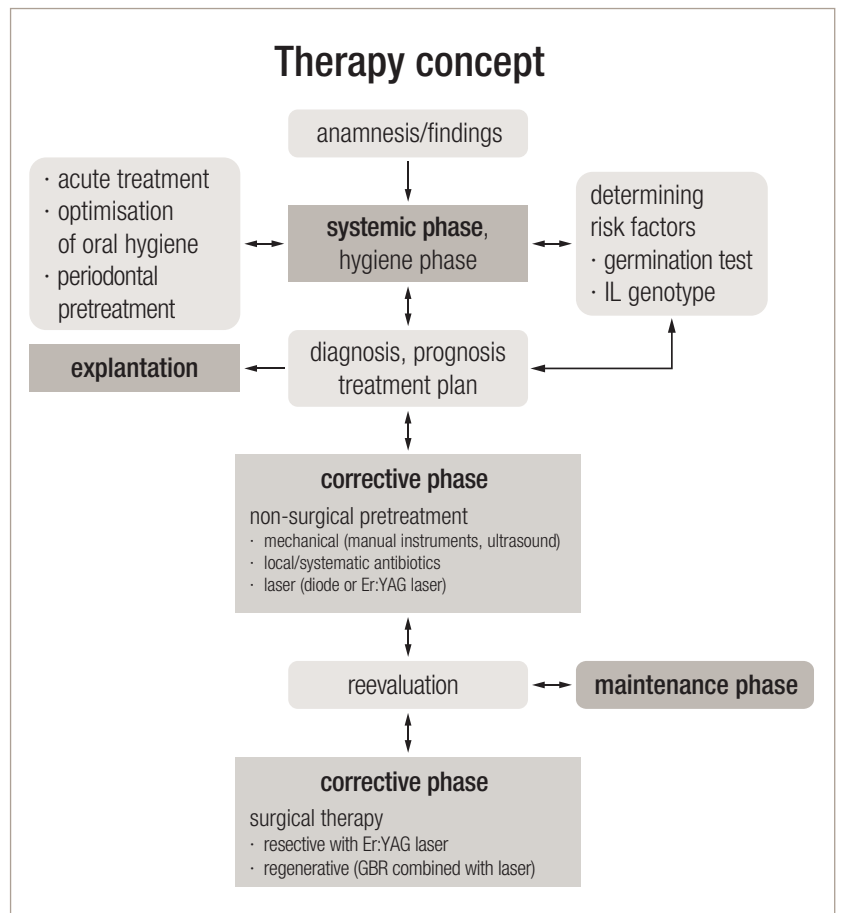
[PICTURE: ©2JENN]

In advanced periimplantitis, a surgical procedure can be indicated in order to remove the biofilm. A regenerative treatment can be done in the course of those surgical procedures in order to replace lost bone. Therapy interventions in periimplantitis are still predominantly based on the clinical experience, as reliable clinical data have not yet been available. However, research activities in this field have been numerous and new data generated constantly, which is why more distinct guidelines for the treatment of those diseases can be expected.¹ Early diagnosis by periodontal probing and the evaluation of the health status of periimplant tissues are essential for the prevention of periimplant mucositis and periimplantitis. Early diagnostic identification permits early intervention, which can be clinically effective. If early symptoms are misjudged, a complex therapy is necessary, but may produce results which are less predictable.

Aetiology and pathogenesis

The literature has proven that the presence of microorganisms is an essential prerequisite for the development of periimplant infections. We know today that glycoproteins from the saliva accumulate at the titanium surfaces of the implant or abutment which are exposed towards the oral cavity immediately after implantation. This glycoprotein layer is then colonised by microorganisms. A subgingival microflora forms within a short amount of time after implantation, which is dominated by *Peptostreptococcus micros*, *Fusobacterium nucleatum* and *Prevotella intermedia*. The majority of periimplant diseases are characterised by gram-negative, anaerobic microflora, which is found in a similar fashion in periodontitis. High concentrations of periodontal pathogens, such as *Aggregatibacter actinomycetemcomitans*, *Porphyromonas gingivalis*, *Prevotella intermedia*, *Tannerella forsythia* and *Treponema denticola*, have been detected in periimplantitis cases. Moreover, studies suggest that the microflora often contains *Fusobacterium nucleatum*, *Actinomyces* as well as *Staphylococcus aureus* and *enterococci*. *Staphylococcus aureus* also colonise other foreign elements, which, for example, may lead to complications in hip transplants. Titanium seems to promote the adhesion of *S. aureus*, which is often found in dental implants.¹

The implant's soft tissue collar consists of an epithelial and a connective-tissue attachment. The epithelial periimplant mucosa, which consists of oral gingiva epithelium, oral sulcus epithelium and non-keratinised junctional epithelium corresponds largely with the epithelial tooth-mucosa contact. The connective-tissue attachment to the



implant is achieved via fibre bundles which are inserted in the marginal bone. They arrange themselves closely to the implant, parallelly and circularly to its surface. Other than the connective tissue surrounding the tooth, the supraalveolar connective tissue is deficient in cells as well as vessels. This leads to a reduction of the defense mechanisms against bacterial influences on the implant. Periimplant inflammations can thus spread faster than comparable inflammations of the periodontium. Missing desmodontal structures limit the defense capacities of the host organism to the vessel proliferation within the marginal soft-tissue collar, which leads to an increase in the manifestation of the clinical inflammation symptoms of the marginal soft tissue.

Fig. 1 Sequence of a systematic therapy of periimplant infections.

There probably is a connection between the microflora present in the oral cavity during implanta-

Table 1 Symptoms of periimplant infections.

mucositis	periimplantitis
bleeding on probing	bleeding and/or pus on probing
reddening and swelling	reddening and swelling
surface inflammation	probing > 4 mm
no loss of bone	loss of bone
slight pocket formation	increased pocket formation

Fig. 2_Fibre tips.

Fig. 3_Cylindrical fibre tip.

Fig. 4_Window hand piece.

Figs. 5 & 6_The patient presented with a loss of the implant-supported metal-ceramic bridge 35–37.

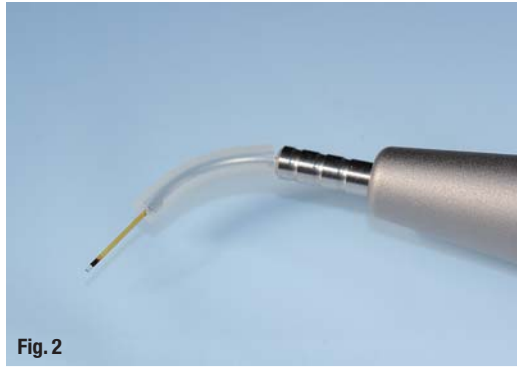

Fig. 2

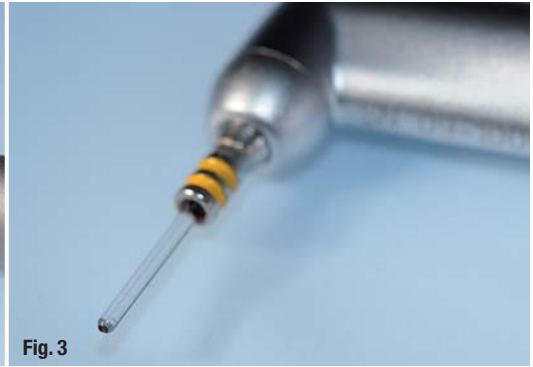

Fig. 3



Fig. 4

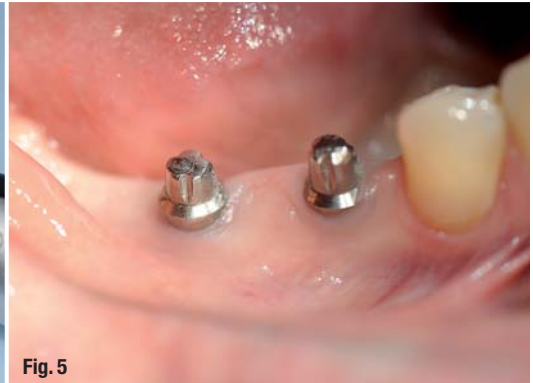

Fig. 5

tion and the biofilm which develops on the implant. Periodontal pockets can therefore function as a reservoir for microorganisms for natural teeth in the partially edentulous. The microorganisms then settle at the newly-placed implant.

Periimplantitis: an inflammatory disease caused by infection (Tab. 1)

- Microorganism colonise implants very shortly after insertion or uncovering of the implant in two-stage procedures.
- Implants are colonised by a microflora similar to that of natural teeth.
- Periodontally diseased teeth can function as a reservoir for pathogenic microorganisms.

- It is imperative that periodontally diseased teeth are treated before implantation.
- Due to the possibility of the pathogenic microflora being transferred from the periodontal lesions to the newly-placed implant, an implantation is contraindicated in cases of an active periodontal disease.

The periimplant mucosa around titanium implants has many things in common with the gingival tissues of natural teeth. Like the gingiva, periimplant mucosa forms a collar-like barrier, which adheres to the surface of the titanium abutment. Periimplant mucosa is a keratinised oral epithelium, whose collagen fibres start at the crestal bone and run parallelly to the implant surface. Similarly to natural teeth, the accumulation of bacterial plaque causes an infection in the periimplant mucosa and increases the probing depth. After longer contact with dental plaque, the periimplant lesion extends apically without being encapsulated by the collagen fibres as in periodontitis cases. The inflammatory infiltrate can extend to the alveolar bone or even the marrow spaces in periimplantitis, while it is separated from the bone by ca. 1 mm of non-inflamed connective tissue in periodontitis. This might explain the varying degree and configuration of the bone defects in periimplant inflammations.

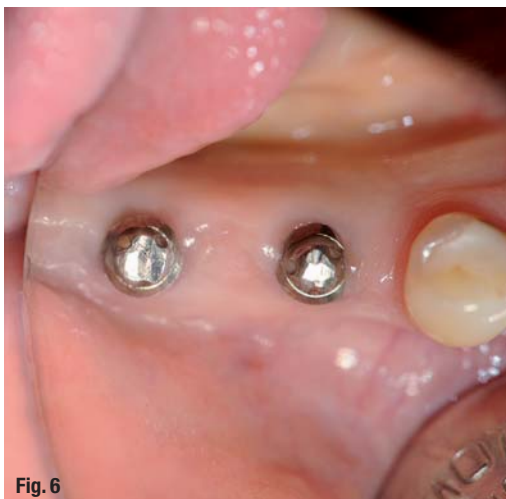

Fig. 6

Diagnosis with dental probe and X-ray

Bleeding on probing as the clinical symptom which confirms mucositis occurs in up to 90% of functioning implants. Unfortunately, the definition



Master of Science (M.Sc.) in Lasers in Dentistry

Batch: EN2014 - Fulltime (new) or Module based

Next Start: **21st September 2015**

Aachen, Germany

4 semesters

Become part of the International Dental Elite

- Create new economic potential for your practice
- Two year career-accompanying postgraduate programme at the University of Excellence RWTH Aachen
- Combination of lectures, skill training sessions, live ops, tutorials, and practical workshops
- Internationally accepted and accredited by the German Government, the European Union, the Washington Accord and the Bologna Process
- Science-based and practice-orientated on highest national and international level
- Increased patient satisfaction: minimal contact reduced vibration and pain



RWTH INTERNATIONAL ACADEMY
AACHEN UNIVERSITY

RWTH International Academy
Kackertstraße 10 | 52072 Aachen | Germany
phone +49 241 80 23543 | fax +49 241 80 92525
info@academy.rwth-aachen.de
www.academy.rwth-aachen.de

PROFESSIONAL EDUCATION PROGRAMMES

AALZ

Aachen Dental Laser Center

AALZ GmbH
Pauwelsstraße 17 | 52074 Aachen | Germany
phone +49 241 47 57 13 10 | fax +49 241 47 57 13 29
info@aalz.de
www.aalz.de

Fig. 7 Periimplant brightening in form of a significantly enlarged split in the course of the covering the complete implant surface between implant and surrounding alveolar bone.

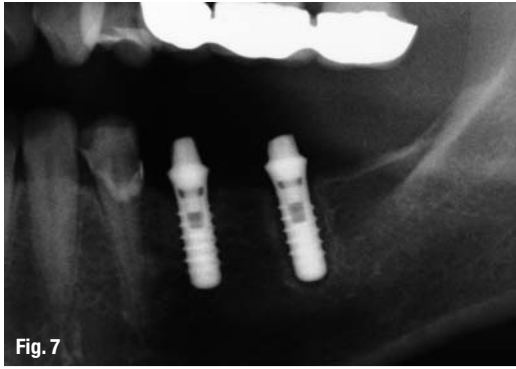

Fig. 8 Careful uncovering of the alveolar process in region 36–38 under local anaesthesia, after forming the mucoperiosteal flap and exposing the bone defect in implant region 37.

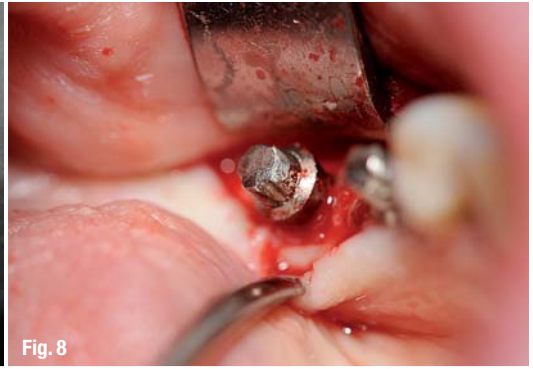
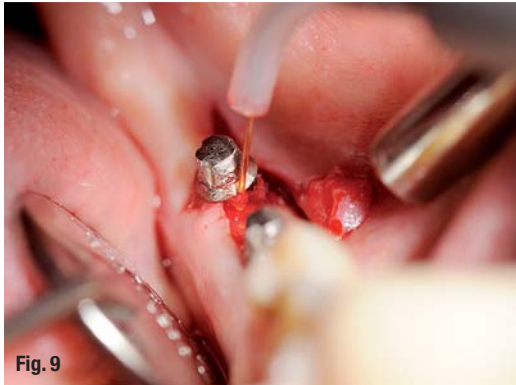
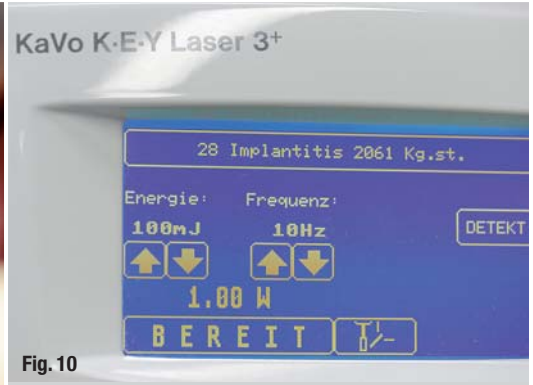Fig. 9 Granulation tissue is depicted in the cervical implant area.



Figs. 10 & 11 Settings for “implantitis” therapy (Fig. 10), which can be altered according to the experience and knowledge of the user (Fig. 11).



of periimplantitis varies and the term is used inconsistently in the literature. It was decided on a recent consensus conference that the definition of periimplantitis as an inflammatory lesion leading to bone loss was acceptable, but that the diagnostic criteria are anything but explicit. For example, it should be taken into account that bone remodelling occurs during implant healing, during which the most coronal periimplant bone can be lost. This physiological rearrangement can take up to one year and should not be seen as a pathological process. From the clinical point of view, the bone level at the moment of prosthetic restoration should be the defined as the reference value for future radiological changes of the bone height. Only in this moment should the reference X-ray be produced, which is then used for the assessment of the periimplant bone loss. It should be noted that measurement errors can occur even under ideal conditions: in cases of double measurement, a deviation of about 0.5 mm was documented. The diagnosis of periimplantitis is justified if there is a radiological bone loss of 2 mm compared to the initial values and combined with bleeding and/or pus on probing. In immediate loading, an X-ray after one year is recommended as a reference for future X-rays.¹

Periimplant mucositis and periimplantitis: frequent complications in implant patients

Periimplant mucositis is described as a reversible inflammatory reaction of the periimplant mucosa

without any symptoms of periimplant bone loss, comparable to gingivitis. Periimplantitis is described as the further progression of plaque accumulation and consequently the spreading of the bacterial infection to the periimplant bone, characterised by bone destruction due to the inflammation. It is seen as the pendant to periodontitis.

- Roughly four in five implant patients exhibit periimplant mucositis.
- After ten years, one in five patients develops periimplantitis.
- Periimplantitis is especially frequent in smokers, patients with insufficient oral hygiene and patients who have already had periodontitis.
- Implants with a rough surface accumulate more plaque when exposed towards the oral cavity than smooth implants.
- The prevalence of periimplantitis can be expected to rise in the future due the increasing replacement of teeth by implants and the use of moderately rough surfaces.

Our therapy concept

In principle, a procedure analogous to the systematic periodontal therapy, consisting of systemic phase, hygiene phase, corrective phase and supervision phase should be maintained in the therapy of periimplant infections. Figure 1 is the schematic representation of the systematic therapy of periimplant infections as performed in our clinic. Primarily, die pathogenic microflora must be reduced by a



Fig. 11

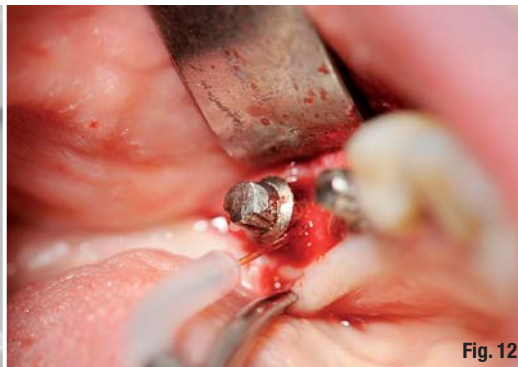

Fig. 12

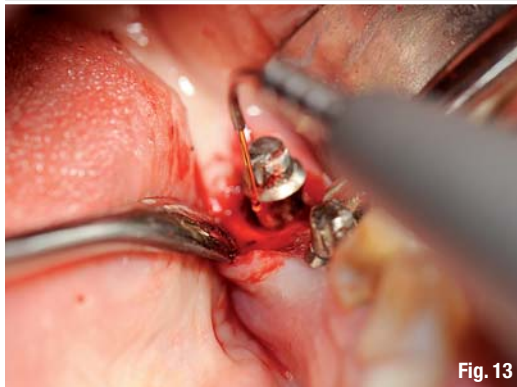


Fig. 13

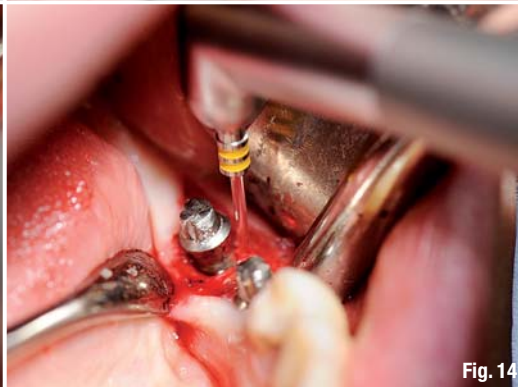

Fig. 14

Figs. 12 & 13 Removal of the soft-granulation tissue from the split-shaped bone defect and the implant surface.

Fig. 14 Application of the fibre tip parallel to the implant surface into the depth of the periimplant bone defect.

causal therapy in order to counteract a progression of the disease.² The removal of subgingival concretions and the bacterial biofilm of titanium implants is, however, hindered by various modifications of the implant surfaces.³ Prosthetic options and superstructures often make the access to infected surfaces difficult. In this regard, decontamination or conditioning of the exposed implant surface is demanded in addition to the mechanical removal of the biofilm in order to optimise the removal of bacteria and their lipopolysaccharides from the microstructured implant surface. For this, a non-surgical therapy approach can be differentiated from a surgical one. The latter is obligatory in resective or regenerative procedures (guided bone regeneration, GBR). Contrarily, the removal of the biofilm as a preliminary to resective or regenerative procedure can be done surgically as well as after mobilisation of a mucoperiosteal flap under visual control.⁴ It should, however, then be noted that critical probing depths have not yet been defined for the therapy of periimplant infections. These would help in deciding between non-surgical or surgical therapy approaches.⁵ An adequate plaque control by the patient and a sufficient recall system are basic prerequisites for all therapy concepts.

Laser application in the therapy of periimplant inflammations

Laser applications have proven to be clinically effective in periodontology in our clinic. The high

bactericidal potential of laser light in the gingival sulcus and the surrounding soft tissues is an advantage that has been described by authors such as Ben Hatit et al. 1996, Coffelt et al. 1997 and Moritz et al. 1997.⁶⁻⁸

It is imperative to note that the effects of different laser light wavelengths on implant surfaces vary. Thus, Nd:YAG laser must not be applied on titanium implant surfaces, with a macroscopically visible welding effect. In contrast, Er:YAG lasers are suitable for the application in close proximity to titanium implants, especially for cleaning and decontaminating implant surfaces. Er:YAG lasers were introduced in 1974 by Zharikov et al. as solid state lasers with a wavelength of 2,940 nm in the near-to mid-infrared range.⁹ The special quality of this wavelength is that it concurs with the maximum absorption in water and is even 15 times higher than that of the CO₂ laser. Depending on the physical laser parameters chosen by the user (laser power, focus-tissue distance, application time, pulse rate and energy density), different biological processes occur in live tissues. In thermo-mechanical ablation, the removal of biological tissue is based on the fact that the proportion of water in the tissues undergoes a rapid transition from the liquid to the gaseous state when absorbing ultra-short laser light impulses. Accompanied by a fast expansion of the water, the pressure becomes high enough to blast off and thus remove hard and soft tissue material.¹⁰

Fig. 15_Uncovering the implant circularly, split-shaped bone loss.

Fig. 16_Filling the four-wall bone defect with xenogeneic bone substitute.

Fig. 17_Good success prospects after primary coverage of the defect.

Fig. 18_Postoperative check-up after laser decontamination and augmentation with Bio-Oss® granulate of a particle size of 0.25–1 mm und coverage via Bio-Gide® membrane.

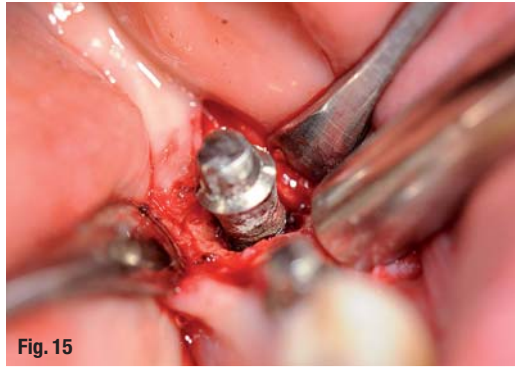


Fig. 15

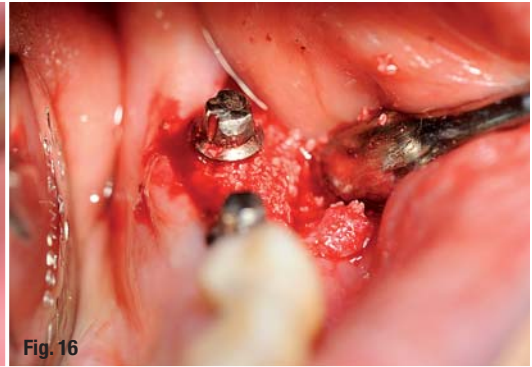

Fig. 16

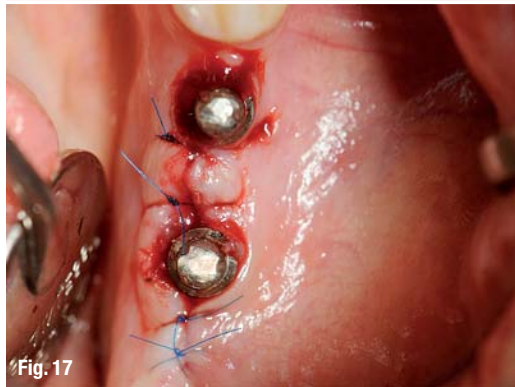

Fig. 17

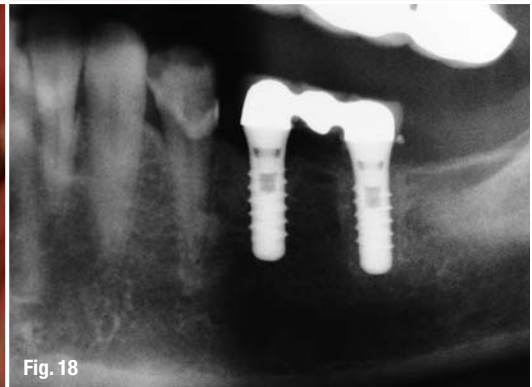


Fig. 18

Of course, the laser tip/laser fibre used must ensure that all decontaminated areas of the implant surface or the inflamed implant site in the alveolar bone can be reached precisely. In my practice, I use fibre tips (Fig. 2) as well as a cylindrical working end, which reflect the laser light via a bevel (phase) in an angle of 45° (Fig. 3), so that parts of the macroscopically present implant screw threads are treated three-dimensionally. In easily accessible or exposed implant surfaces or defect areas of the alveolar bone, I like to use the so-called window hand piece, which allows an extensive laser-light application with a high energy density without fibre or sapphire light wedge (Fig. 4).

Case presentation

In the following patient case, the resective and regenerative treatment sections of the complex therapy concept are discussed only exemplarily for didactic reasons.

Anamnesis and findings

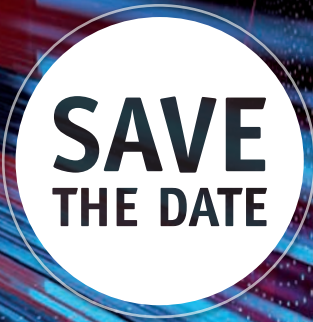Female patient, 56 years old, smoker, no general diseases, condition 14 years after implant insertion, regular dental check-ups until 20 months ago, afterwards neither prophylaxis or check-ups, treatment stop.

The patient presented with a loss of the implant-supported metal-ceramic bridge 35–37 (Figs. 5 & 6, lateral and occlusal view). Clinical examination showed: mild loosening of implant regio 37 (grade

1), minimal bleeding on probing, minor pus release region 37. Contrarily, there was no bleeding on probing or pus release in implant 35. However, all in all no redness of the gingiva, no inflammatory infiltration, swelling or loosening of implant 35, whose percussion sound was bright and clear, were detected.

Radiologically, a periimplant brightening in form of a significantly enlarged gap in the complete implant surface between implant and surrounding alveolar bone (Fig. 7) was noted.

After a modified application of our therapy concept (Fig. 1), we attempted a prompt surgical treatment of the periimplant infection in implant regio 37 due to the loss of the bridge. The patient was informed about the limited prospects of success with regard to implant preservation already at the beginning of the therapy. The alveolar process was exposed carefully under local anaesthesia after forming the mucoperiosteal flap in regio 36–38 and the bone defect was prepared in implant region 37 (Fig. 8). Granulation tissue is depicted in the cervical implant area in an overview of the exposed operational field (Fig. 9). The configuration of the bone defect made the application of various laser fibre tips necessary. We used an Er:YAG laser (KaVo KEY 3+ by KaVo GmbH, Germany). The programme selection already provides preconfigured settings for the therapy of "implantitis" (Fig. 10), which can be altered according to the experience and knowledge of the user (Fig. 11). Thus, the first therapy step of laser



30–31 October, 2015
Berlin, Germany
Hotel Palace

24th Annual Congress of the DGL e.V.

LASER START UP 2015



Figs. 19 & 20_ Probing depth of 2 to 2.5 mm.

Figs. 21 & 22_ Good agglomeration of the surrounding bone in implant regio 37.

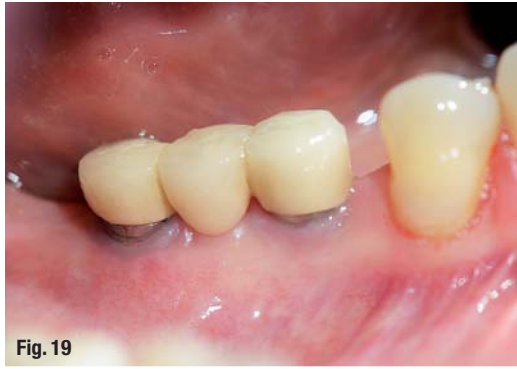

Fig. 19

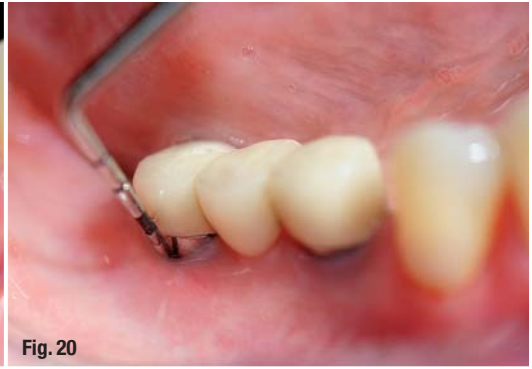

Fig. 20

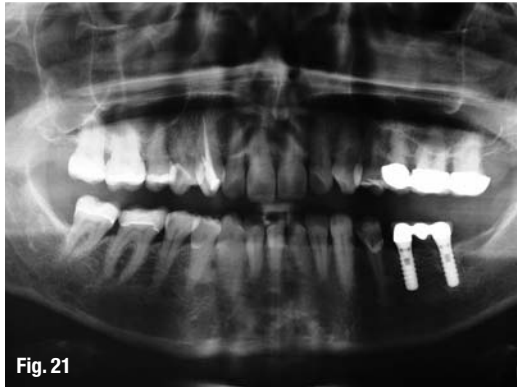

Fig. 21

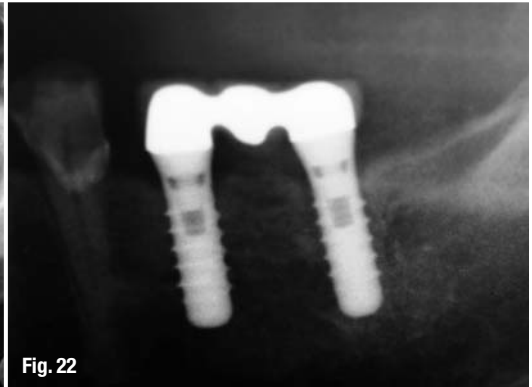


Fig. 22

applications consisted of using a thin fibre (Fig. 2), which can also be applied in other surgical situations in order to remove the soft granulation tissue from the slit-shaped bone defect and the implant surface (Figs. 12 & 13).

Afterwards, a special cylindrical sapphire tip was used (Fig. 3), which features a 45° bevel (phase), which helps the laser light reaching hardly accessible areas, for example the screw threads of the implants, by circular and lateral radiation in a 45° angle. For this, energy was increased to 350 mJ at a pulse rate of 15 Hz and 5.25 W. The figures show how the fibre tip is held parallelly in accordance with the implant surface into the depth of the peri-implant bone defect (Fig. 14). Fig. 15 already depicts a visible circular exposition of the implant with a split-shaped bone loss, which corresponds to class 4 according to Spiekermann 1993.¹¹

After laser decontamination and cleansing of the implant surface via Er:YAG laser and physiological NaCl solution, all the macroscopically present granulation tissue and the infected surface of the alveolar bone facing the implant were removed. This was followed by filling the four-wall bone defect with xenogeneic bone substitute, which was accumulated up to the implant region for minimal vertical augmentation (Fig. 16). An implant plastic with removal of the rough surface as was previously described by other authors^{1,4} was not applied in order to avoid introducing titanium particles to the surrounding bone, which can be seen later in

the X-ray. The procedure was discussed extensively with the patient beforehand and according to our experience provides good prospects of success (Fig. 17). After covering the xenogeneic augmentation material by a collagen membrane and primary wound closure, the implants were stabilised first by a long-term temporary restoration in configuration with the former bridge. This long-term temporary solution, which was visibly reduced in its occlusal height, was used for temporary splintage for six weeks in order to stabilise the minimally loosened implant 37. Immediate postoperative control after laser decontamination and augmentation with Bio-Oss® granulate of a particle size of 0.25 to 1 mm and coverage via Bio-Gide® membrane was checked radiologically (Fig. 18).

After a clinically uneventful healing period of six weeks, the long-term temporary solution was exchanged with the original definite bridge restoration. Treatment success was checked after four and, later, six months. Professional prophylaxis was performed in addition.

Clinical check-up four years after laser therapy and augmentation in region 37 presented us with a patient who was, subjectively, without any pain and a clinically stable implant abutment in region 37. Neither bleeding on probing or pus were recorded. Probing depth was and is 2–2.5 mm (Figs. 19 & 20). Radiological check-up (Figs. 21 & 22) showed a good agglomeration of the surrounding bone in implant regio 37.

The prospects of success in saving an implant by laser decontamination and combined GBR procedure, according to my experience, are high. If the implant surface as well as the bony implant site can be decontaminated, one can rely on the high regenerative quality of the alveolar bone. Additional application of xenogeneic augmentation materials suggests a significant improvement of the therapy success, as both guidance for the yet-to-be formed bone and primary mechanical stability of the implant are achieved immediately after insertion of the material.

Users of GBR techniques already know that this biological process demands space as well as stability and the longest possible regenerative period. Therefore, exposition to masticatory forces should be avoided during the four- to six-weeks healing period. For this reason, removing the complete supra structure of several implants and letting the wound heal after coverage is the safer method in general.

Summary

Today, the success rate of implant therapy is generally regarded to be high. However, infectious complications such as mucositis or periimplantitis are frequently documented and seen as usual complications in implants which have been in situ for five to ten years. Periimplant mucositis and periimplantitis have infectious origins. When not treated, they will lead to implant loss sooner or later. As soon as the inflammation has reached the periimplant bone, the implant surfaced should be cleansed and decontaminated by applying an Er:YAG laser in addition to an ablative treatment of the infected bone. The combined treatment of GBR procedures improves the clinical situation and favours biological regeneration.

contact

laser

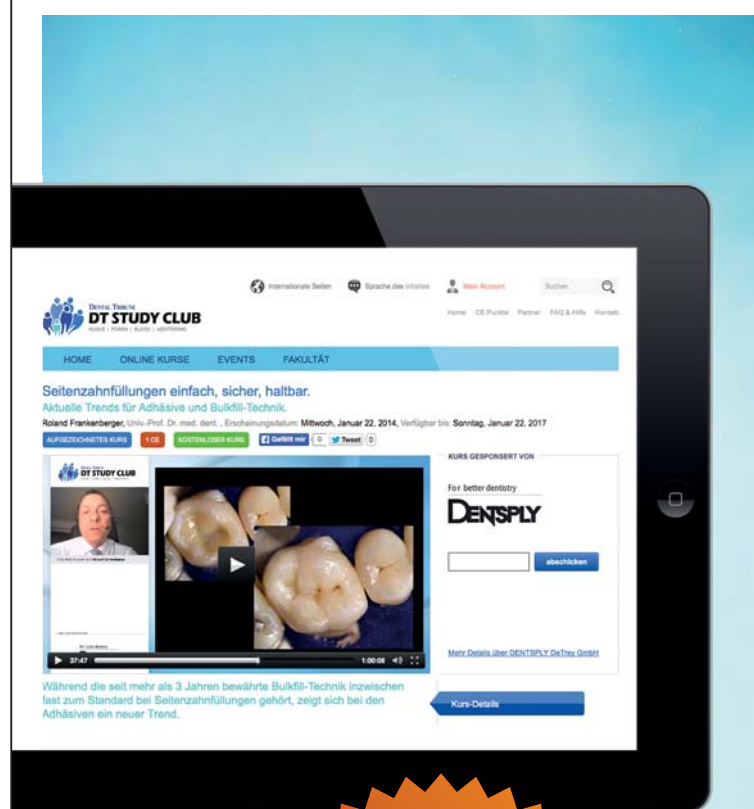
Jiaoshou (Prof.) Dr Frank Liebaug

Scientific Director of Ellen-Institute,
German Institute for Dental Research
and Education
Professor University Shandong, China
Arzbergstr. 30, 98587 Steinbach-Hallenberg
Germany

Tel.: +49 36847 31788
www.zahnarzt-liebaug.de
www.ellen-institute.com

Join the largest educational network in dentistry!

www.DTStudyClub.com



Register for
FREE!

Alveolar corticotomies by lasercision

A new procedure to accelerate orthodontic treatments

Author_Dr Brice Savard, France

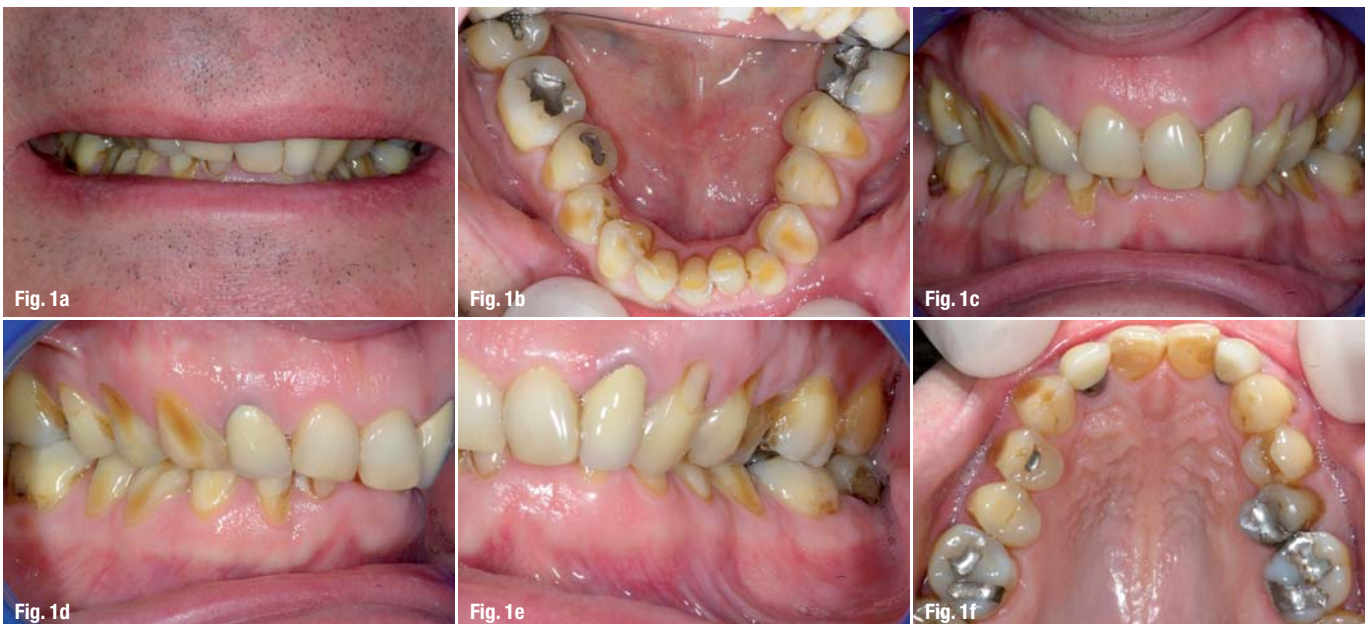An increasing number of adult patients visit us because they want to regain a more harmonious, aesthetic, young smile. To have "nicely aligned teeth" is a wish that we hear constantly. Dento-maxillary disharmony is a condition that can occur in all of the adult population. This is because over time the teeth start to overlap and/or this overlap increases for various reasons (resorption of the bone base, decreasing periodontium support, parafunction etc.). However, many patients shy away from the idea of having orthodontic treatment.

Today, we have many aesthetic methods of orthodontics at our disposal which are practically invisible (lingual orthodontics and aligners make orthodontic treatment popular with many adults). Still orthodontic treatment, even if it is done aes-

thetically, needs convincing (duration of treatment, impact on the daily life, frequent appointments, articulation difficulties, wounds, pain etc.). This is why we are frequently confronted with patients who prefer rehabilitation of their smile by means of prosthodontics.

Luckily there is a technique that reduces the time needed for orthodontic treatment and facilitates its course: Alveolar corticotomies. This is a surgical technique where we make vertical incisions into the vestibular osseous cortical, maxillary and mandibular proxy, so that the orthodontic tooth movement is accelerated. Due to the growing demand of adult patients to improve their smile and the survival of their teeth, aesthetic orthodontic treatment and alveolar corticotomy are

Figs. 1a-f_Initial situation.



carried out more and more often, especially since there are now protocols, which are much less invasive.

History

The first corticotomies were described at the end of the 19th century. In 1959, Köle suggested a protocol linking vestibular and lingual segmentary corticotomies and subapical horizontal osteotomy after elevation of a complete periosteal flap.¹ Köle developed the bony blocks theory in order to explain the faster tooth movement. At that time orthodontists thought that it was necessary to obtain an almost complete dissociation of the bony block to accelerate the tooth movement.

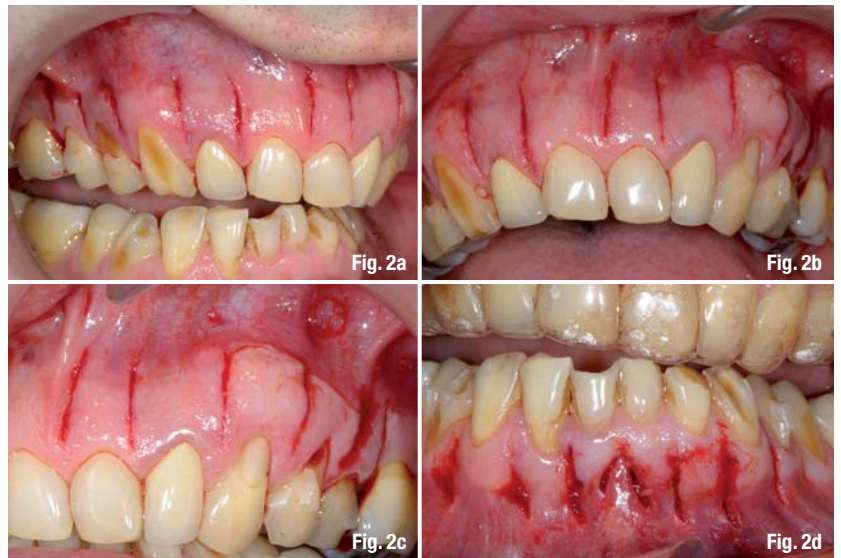This extremely invasive technique was not very popular with orthodontists. During the following years, simplified protocols without subapical osteotomy were invented^{2,3,4,20,21}, which, however, still heavily relied on the bony blocks theory. Frost, an orthopedist from the US, showed that after a surgical intervention in long bones there was an accelerated bone turnover (bone remodelling) and a transient osteopenia directly at the site of intervention.^{5,6} He introduced the so-called regional activation phenomenon (RAP) concept to explain this physiological scarring process. The concept and the correlation between post-surgical RAP and tooth mobility would later be validated by various studies. Yaffe A. et al. suggested that the RAP is responsible for the increased tooth mobility after periodontium surgery.⁷ Verna showed that there is a correlation between bone remodelling and tooth movement.⁸

Biological concept of corticotomies

Based on the various studies and the RAP concept, the Wilcko brothers (an orthodontist and a periodontist from the US) introduced the biological concept in 2001 in order to explain the increased speed of dental displacement after corticotomies.⁹ However, their protocol is still conventional and invasive: a complete vestibular and lingual mucosa periosteal flap followed by bone drill corticotomies (sometimes including a soft tissue and/or bone graft).

Later, other studies showed that the RAP effect is also present at some distance from the corticotomy zones¹⁴⁻¹⁷ and this led to less invasive protocols without flaps.^{10, 11} In 2007, Vercellotti introduced using a piezosurgical microsaw.¹² However, his method still required elevating a vestibular flap.

In the course of the evolution of knowledge and understanding of the underlying biological phenomenon (RAP concept), the methods became more



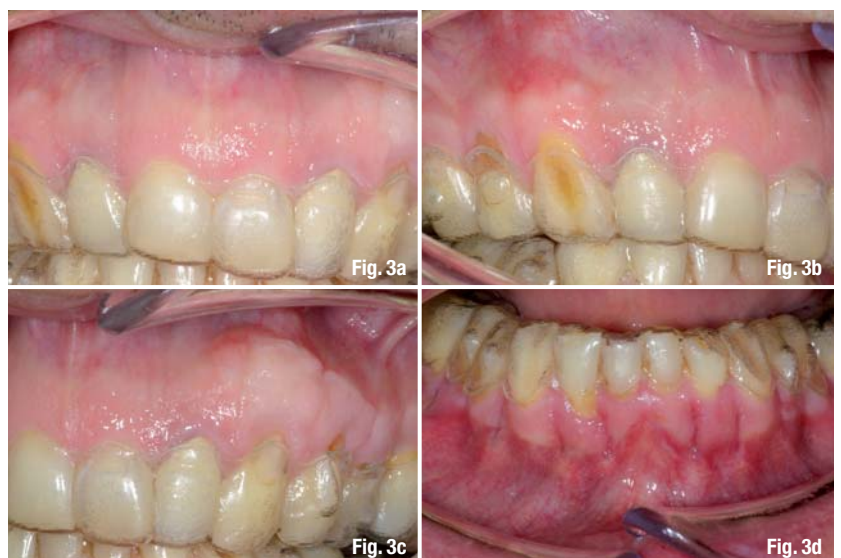Figs. 2a-d Situation immediately after the maxillary and mandible surgery.

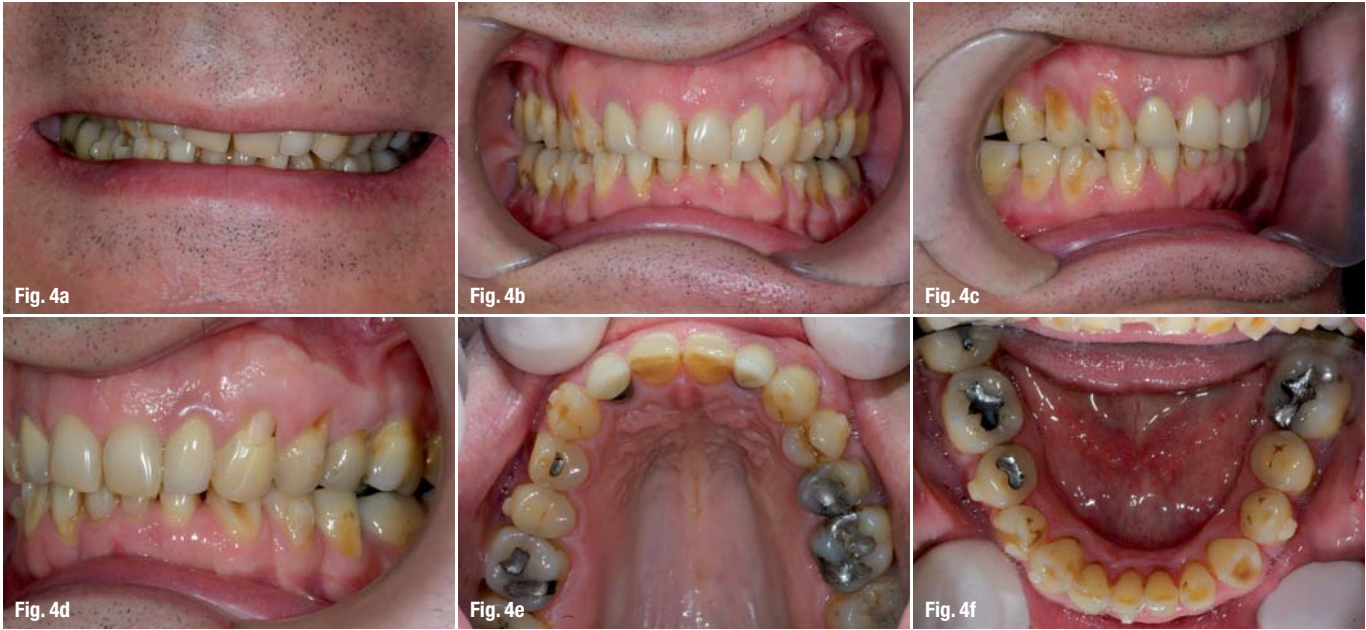
and more simple without any compromise to the results. In 2009, Dibart, Sebaoun and Surmenian used piezosurgery in forming minimally invasive segmentary corticotomies.¹³ This new method works without palatine corticotomies and mucosa periosteal flap. The corticotomies are carried out with a piezotome directly through the attached gingiva after a vertical scalpel incision. This can be combined with soft and/or hard tissue grafts.

Indications and counter-indications of corticotomies

Corticotomies help reduce the duration of orthodontic treatment significantly and facilitate its course. They can be used for most malocclusions, particularly those of class I malocclusion with DMD. Corticotomies are mostly used for aligning teeth (temporary RAP of about four to six months), but they are also useful for facilitating complex displacements in adults (distalisation of molars, mass

Figs. 3a-d Healing status 15 days after the surgery.





Figs. 4a-f_End of orthodontic treatment; the duration was nine months. Now the preconditions for a prosthesis are looking better.

distalisations, ingressions etc.) so they can simplify the treatment plan and reduce necessary orthodontic extractions. Corticotomies are also indicated with dental decompensation during orthosurgical treatment. Furthermore, corticotomies can be used with all orthodontic methods (vestibular, lingual, aligners).

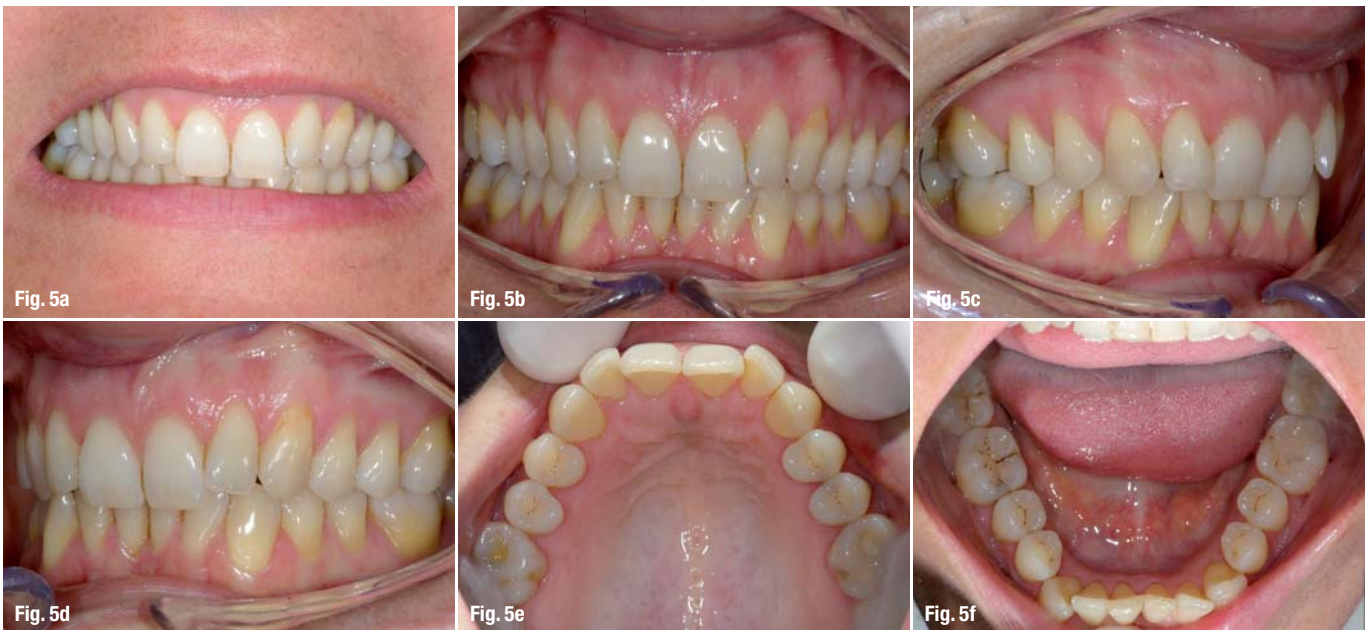The patients that can be treated with this intervention must not present active periodontal disease, periapical lesions, local or general bone pathologies or be currently undergoing an immunosuppressive, bisphosphonate or cortisone treatment (modification of the cell turnover). There must be no risk of infectious endocarditis or previous radiation therapy in the cervico-facial area. Smokers have a higher risk of post-surgical infec-

tion. Prior to surgery there must be a periodontal and dental examination carried out. Any carious lesions, periapical abscesses or active periodontal disease must be treated before an orthodontic therapy can be initiated. Shortly before the surgery, a dental cleaning and, if necessary, root planning, must be carried out. Also, a three-dimensional examination (cone beam) of the jaw and/or mandible is necessary to determine the root axis, the cortical thickness and chin foramen in the mandible.

Laser-assisted corticotomy: "lascision" corticotomy procedure

The erbium laser has successfully been used for many years in high-precision bone and muco-gingi-

Figs. 5a-f_Initial situation.



val surgery (sinus lift, crown lengthening, endodontic surgery, periodontal surgery etc.). There are two erbium laser types: Er:YAG (lasing medium erbium-doped yttrium aluminium garnet, wavelength $\lambda = 2,940$ nm) and Er,Cr:YSGG (erbium, chromium: yttrium-scandium-gallium garnet, $\lambda = 2,780$ nm). It is important to highlight that erbium lasers are the only kind of lasers used in odontology that enable a surgical treatment of hard tissue.

In 2012, Seifi et al. showed that corticotomies without flaps which were carried out with an erbium laser (Er,Cr:YSGG, Waterlase, Biolase, United States) on rabbits accelerated dental displacement.¹⁸ The ablative effect of the erbium laser on the osseous cortical leads to a RAP reaction without any post-surgical consequences or side-effects. We suggest a minimally invasive alveolar corticotomy method without muco-gingival flap using an erbium laser: the Laser-cision corticotomy procedure.

Functional principle of the erbium laser

The wavelengths of erbium lasers (2,940 and 2,780 nm) are strongly absorbed by water and hydroxylapatite. The pulse energy leads to immediate localised vaporisation of the water molecules (5 μ m depth). A brutal elevation of the intratissue pressure will trigger a micro-explosion (also called explosive vaporisation) and the dissociation of cells

from the target tissue. This is the photo-ablative effect. There is also a direct action on the hydroxylapatite (photo mechanical effect), but this is less severe. Because of the strong absorption of water, there is no carbonisation of the target tissue. Furthermore there is no distal thermal effect and therefore no tissue necrosis risk. The ablation concerns only a small area (5 μ m depth), resulting in an extremely fine incision.

Clinical procedure using an erbium laser

The intervention is carried out some days after orthodontic brackets have been installed or on the same day if transparent aligners are used. We use the LightWalker® Er:YAG laser ($\lambda = 2,940$ nm) from Fotona (Ljubljana, Slovenia). We used 2 W on the attached gingiva (energy = 200 mJ, pulse frequency = 10 Hz, MSP mode and water and air sprays) and then 3 W (energy = 200 mJ, pulse frequency = 15 Hz, QSP mode and water and air sprays). This is sufficient for attaining a rapid gingival and bone ablation without the risk of thermal injuries.

Beforehand, we use local anaesthesia. With chiselled, sapphire tip, we make an extremely fine incision into the gingiva and the bone. The intervention occurs vestibularly only. We penetrate the attached gingiva directly with the tip up to the cortical bone. The tip must always be at an angle of 45 to 60 degree to the

AD

[PICTURE: ©SERGEY NIVENS]



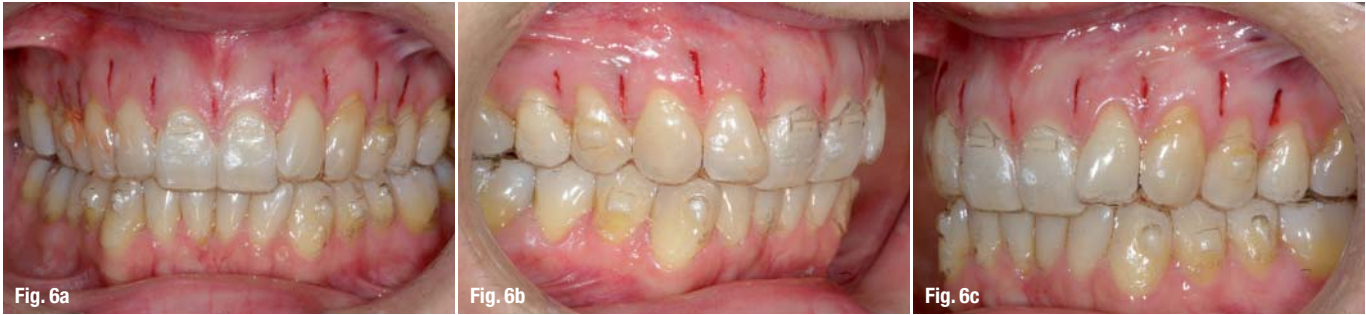Publish – your – expertise

Hand in your article.

Please contact:

Editorial manager
Georg Isbaner
g.isbaner@oemus-media.de

Editor
Katrín Maiterth
k.maiterth@oemus-media.de



Figs. 6a-c Situation immediately after the maxillary surgery. We carried out the mandible intervention 15 days afterwards as requested by the patient.

surface. The tip works in pre contact mode. The gingiva and osseous cortical should not be touched. We recommend starting the incision at the level of the muco-gingival junction and continuing up to the papilla without harming it. Several passages are necessary. We recommend "sweeping" the surface by starting at the initial spot each time so that the tip does not tear the gingiva. We then perform an ablation of the alveolar bone between every tooth that needs displacement, just as with the attached gingiva (sweeping from apical to coronal so that the cortical is not touched by the tip).

The depth of intracortical penetration is about 2 to 3 mm depending on the depth of the cortical, measured with the cone beam. The osseous cortical must never be pierced. The depth of penetration is measured with a graduated periodontal probe. It is important to stay within the attached gingiva and to reduce the incision cut into the strongly vascularised mucosa. However, it is possible to penetrate the mucosa with the tip in order to reach the osseous under the cortical so that a more extensive apical corticotomy can be realised. We do this systematically. It is possible to also carry out a gingival and/or osseous graft in the areas where the cortical is of low

depth by lifting the gingiva between the individual incisions, as described by Sebaoun et al.¹⁹

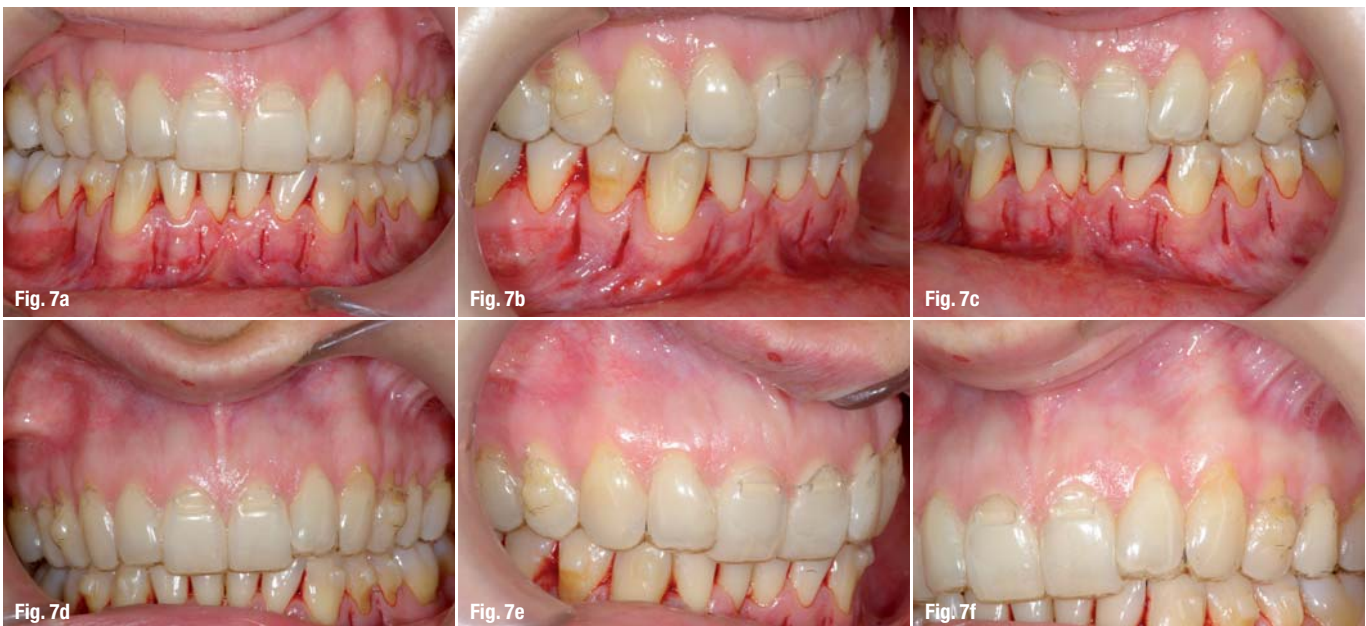At the end of the intervention, haemostasis is carried out using sterile pads. There is no suture because gingiva heals very quickly. Antibiotics are also not necessary (the laser has a bactericide effect). Most of the time, the patient feels no pain after surgery, only a prickling sensation (analgetic effect of lasers). There is no oedema (anti-inflammatory effect of lasers). The patient can return to their workplace on the same day. The follow-up appointment is one week after the intervention. The orthodontic archwires must be changed every 15 days (instead of 4 to 6 weeks). Aligners must be changed every week (instead of 2 to 3 weeks).

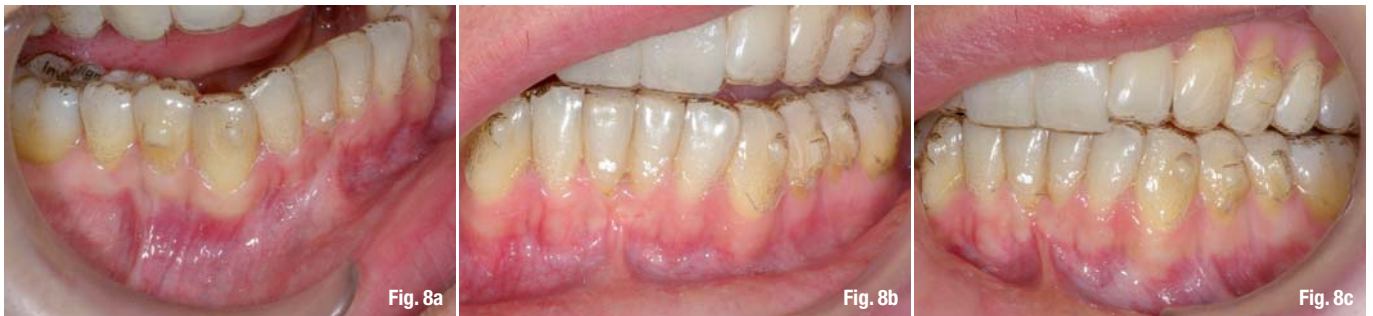Advantages of the erbium laser in corticotomies

Using a laser has many advantages as compared to conventional treatments:

- As the laser is used in pre contact mode, the patient feels no unpleasant sensation during the intervention (no vibration etc.);
- No post-surgery pain or oedema (analgetic and anti-inflammatory effect of the laser due to biomodulation);

Figs. 7a-f Situation immediately after the mandible surgery and healing status 15 days after the maxillary surgery.





Figs. 8a-c_Healing status 15 days after the mandible surgery.

- No heat (air and water spray), so no risk of tissue necrosis;
- Gingiva heals very quickly and without scars (biomodulation effect on the healing and scarring process of the gingiva);
- Thanks to using a fine tip, a more extensive corticotomy can be carried out under the mucosa without harming it;
- Quick treatment with a power of about 3 W;
- Possible link to the biostimulation effect of all lasers (LLLT) – several studies show an effect on the acceleration of dental displacement.

_Clinical cases

Case 1

Mr G was transferred to us by a colleague and we were asked to perform orthodontic treatment before a global maxillary and mandible rehabilitation with ceramic veneers and crowns was to be carried out. The patient is not happy with his smile and wants an optimal, long-lasting solution. He has a class II, two with a slight DMD, a strong supraocclusion and a maxillary constriction resulting in a pronounced linguoversion of his teeth and significant wear. The initial situation renders a successful prosthetic rehabilitation unlikely. The patient wishes a quick and aesthetic orthodontic treatment. We choose transparent aligners and laser-assisted corticotomies (Figs. 1a-f, 2a-d, 3a-d, 4a-f).

Case 2

Ms P presents with a class II, two malocclusion and a 5 mm DMD. The patient feels that misalignment has increased over time. She feels self-conscious because of her smile and does not want the situation to worsen. She wants a quick and aesthetic solution. We choose transparent aligners combined with laser-assisted corticotomies (Figs. 5a-f, 6a-c, 7a-f, 8a-c).

_Conclusion

Laser-assisted alveolar corticotomies or the Lasercision Corticotomy Procedure is a minimally invasive technology which is reliable, very well tolerated by the patients and has all the inherent ad-

vantages of laser treatments. This method has plenty of potential for the years to come as more and more dental clinics decide to buy laser equipment. Furthermore, the procedure still has simplification potential.

Due to the development of aesthetic methods and minimally invasive corticotomies, today adult orthodontics forms an inherent part of the treatment plan of general physicians. Orthodontics can make prosthetic rehabilitation easier (obtaining a better occlusal stability, molar ingressions with antagonist teeth lacking, new space in case of versions, axe straightening for minimally invasive prosthodontics restorations etc.) and improves long-term results of periodontium treatments (better hygiene, occlusal stability etc.). Last but not least, obtaining a harmonious and stable occlusion will positively impact TMJ and general locomotor system pathologies.

Even though the overall duration of treatment will be prolonged, the functional and aesthetic results will more than justify this for our patients.

Editorial note: A list of references is available from the publisher.

_contact	laser
<p>Dr Brice Savard Doctor of dental surgery Postgraduate in aesthetic dentistry Graduated from the International Orthodontic Science and Clinics Centre, Paris European Master Degree of Oral Laser Applications</p> <p>Clinique dentaire Boissière 24 Rue Boissière 75116 Paris, France Tel.: +33 1 47 27 36 55</p> <p>dr.savard@cliniquedentaireboissiere.fr www.cliniquedentaireboissiere.fr www.dental-laser-academy.com</p>	

Laser activated irrigation

Part II: Does the position of the fibre matter?

Authors Prof. Dr Roeland Jozef Gentil De Moor & Dr Maarten Meire, Belgium

[PICTURE: ©VECTOR ILLUSTRATION]

Introduction

The endodontic cleaning and shaping procedures are based on the use of instruments to shape the central body of the root canal system hereby creating a reservoir for the rinsing solutions.¹ Irrigants are needed to clean those areas that cannot be touched and reached by endodontic instruments. At present, a combination of irrigants i.e. Sodium hypochlorite (NaOCl) and Ethylenediaminetetraacetic acid (EDTA) is favoured as initial and final rinse. Both are complementary.^{2,3} The root canal system is geometrically very complex, including curvatures in multiple directions, isthmuses, fins, cul de sacs, lateral branches, the apical delta and also the dentinal tubules. These areas remain untouched during instrumentation and even get blocked with debris and smear layer as a result of root canal preparation. These locations are also excellent hiding places for bacteria.⁴ Therefore, chemical modifications of the compounds of irrigants and agitation systems for root canal irrigation have been developed to improve the penetration and effectiveness of irrigation solutions.^{5,6}

Ultrasound and the increase of efficiency of irrigants

It was already known that heating NaOCl solutions from 20 to 45 °C improved their antimicrobial and tissue-dissolution capacity.⁷ The effect of agitation of irrigants on tissue dissolution, however, was more efficient than that of temperature.⁸ Continuous agitation of sodium hypochlorite resulted in the fastest dissolution.⁸

Previous investigations had already demonstrated the very important impact of mechanical agitation of the hypochlorite solutions on tissue dissolution referring to the great impact of violent fluid flow and shear forces caused by ultrasound on the ability of hypochlorite to dissolve tissue.⁹

At that time (2005), it was concluded that acoustic micro-streaming and cavitation were to play an important role during ultrasonic activation of irrigants.¹⁰ The occurrence of cavitation, however, has been a matter of debate during the last two decades. Cavitation had been demonstrated to occur around ultrasonically driven instruments oscillating

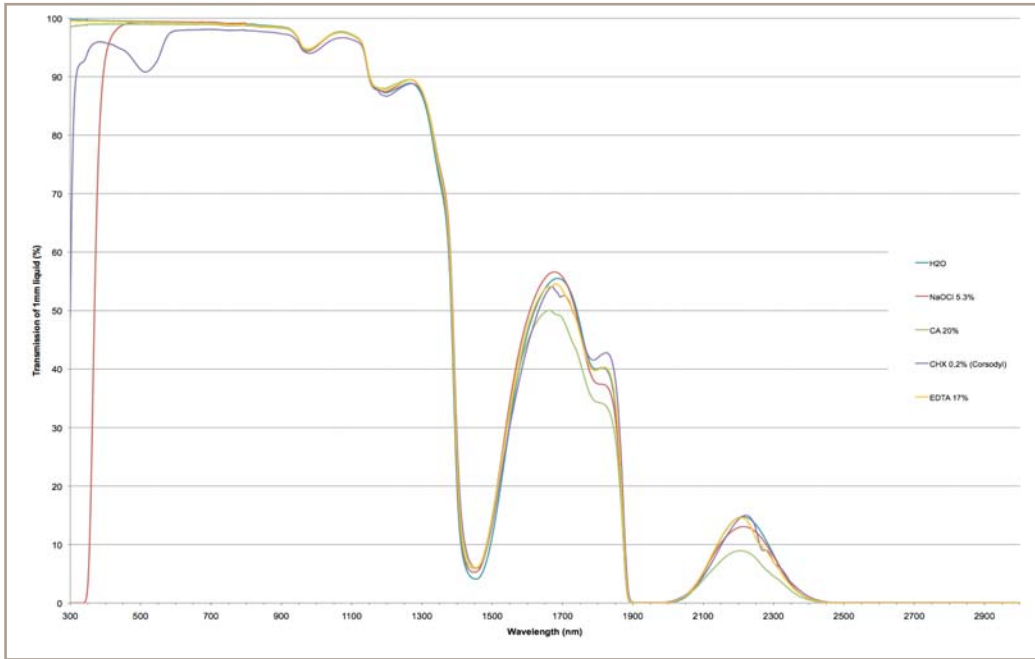


Fig. 1 Transmission spectra of distilled water, NaOCl 5.3 %, citric acid 20 %, Chlorhexidine 0.2 % (Corsodyl), EDTA 17 % (path length = 1 mm, according to Meire et al. 2013).

lating freely in a liquid medium.¹¹⁻¹³ It was argued that cavitation was unlikely to occur inside the root canal due to space restrictions and hence limiting the oscillation amplitude of the file.¹²

It was only until recently that the occurrence of cavitation with ultrasonically driven instruments has been demonstrated.^{13, 14} The oscillation of endodontic files may result in the generation of cavitation even at low power settings. Transient cavitation (i.e. the process where a void or bubble in a liquid rapidly collapses, producing a shock wave) is generated by most of the files, in the form of a large bubble cloud at the tip of a file and smaller bubbles at subsequent antinodes. The bubble cloud collapses predominantly on the file itself and not on the root canal wall, but its collapse can pull material off a neighbouring wall. At the air-liquid interface at the coronal part of the root canal, air entrainment leads to the entrapment of stable cavitation (i.e. the process in which a bubble in a fluid is forced to oscillate in size and shape due to some form of energy input) bubbles in the root canal.²¹

The amount of cavitation differs between the files. Influencing parameters are file length, diameter, cross-sectional shape, twisting of the file and the oscillation characteristics. Larger file diameters increase the cavitation activity. There is an increased cavitation activity (increase in number and size of the bubbles) within the confines of a root canal as compared to a free liquid environment.²¹

Laser activated irrigation

Activation of irrigants can also be performed with lasers. A number of researchers have investigated the ability of some laser wavelengths to activate the present-day favoured endodontic irrigants within the confines of the root canal.¹⁶⁻¹⁹

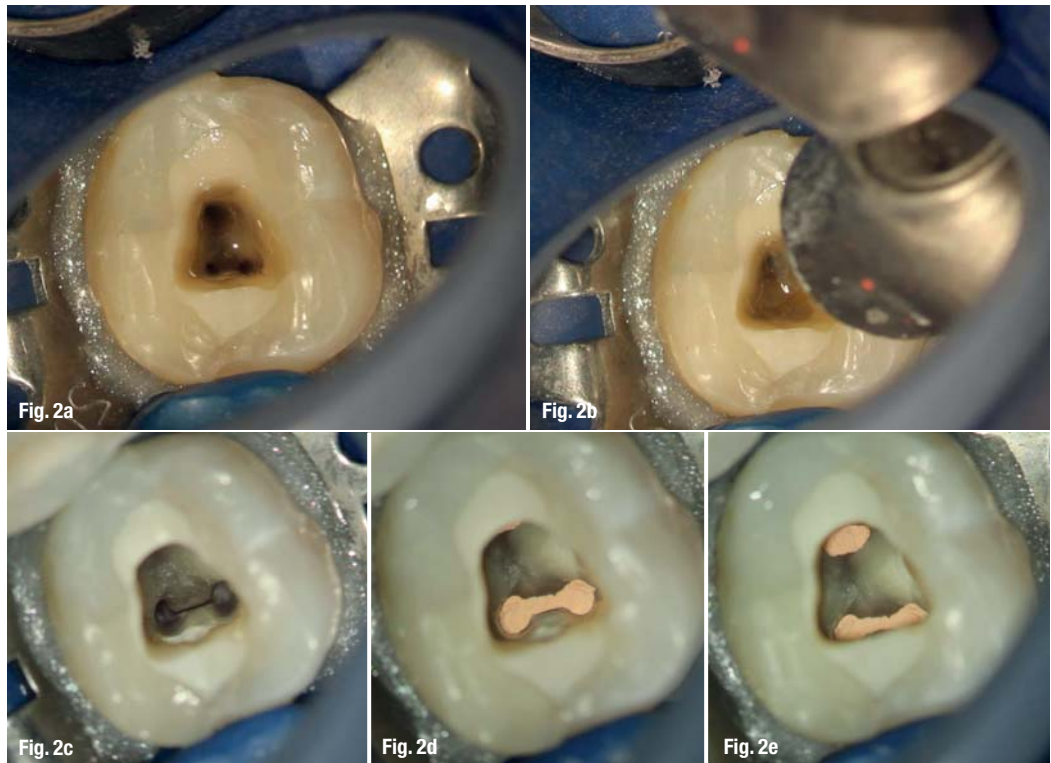
Expansion and implosion of the vapour bubble

The technique for activation of an irrigant is called "Laser Activated Irrigation—LAI". The cleaning effect of this method is based on cavitation. Laser operation results in the formation of vapour bubbles at the tip of the fibre, which expand during the pulse and then implode or collapse quickly

Laser	Wavelength	Water	NaOCl 5.3 %	EDTA 17 %
Diode	810	0.0438	0.0511	0.0512
	830	0.0486	0.0559	0.0560
	940	0.118	0.123	0.116
	980	0.243	0.250	0.234
Nd:YAG	1,064	0.101	0.108	0.105
Er,Cr:YSGG	2,790	>40	>40	36.3
Er:YAG	2,940	>40	>40	33.5

Tab. 1 Alpha values of pure water, sodium hypochlorite 5.3 % and EDTA 17 % at wavelengths corresponding to lasers used in root canal treatment (according to Meire et al. 2013).

Figs. 2a–e Root canal treatment on a mandibular first molar and the use of H-LAI with the X-Pulse tip demonstrating its cleaning efficiency (a. Access cavity, b. Root canal cleaning using X-Pulse H-LAI, c. The cleaned pulp chamber and root canals, d and e. Root canals filled with gutta-percha and Top Seal).



after termination of the laser pulse. The effect within the confines of a root canal is threefold:

- 1) The volumetric changes of the bubbles are accompanied by considerable fluid movement inside the canal.²⁰
- 2) The cavitation bubble implosion, which is a vigorous process, generates localised, large-amplitude shock waves and micro jets in the irrigant at the point of the implosion.²¹ Localized and transient surface stresses can also be generated when the bubble collapses close to solid faces.
- 3) Besides to primary cavitation, smaller secondary cavitation bubbles occur that are also activated by subsequent laser pulses resulting in acoustic streaming.²²

Absorption characteristics of the endodontic irrigants

The effect of the laser beam is dependent on the target chromophore. Knowledge of the absorption characteristics of a given irrigant permits a better estimation of the energy required to induce cavitation with a certain laser. The spectral properties of water and irrigating solutions were determined by Meire et al.²³ (Table 1). They demonstrated that NaOCl 5.3% and EDTA 17% displayed roughly the same transmission spectrum as that of pure water.

Spatial and temporal energy concentration

As previously mentioned, the mechanism behind the cleaning action of LAI is cavitation, i.e. the

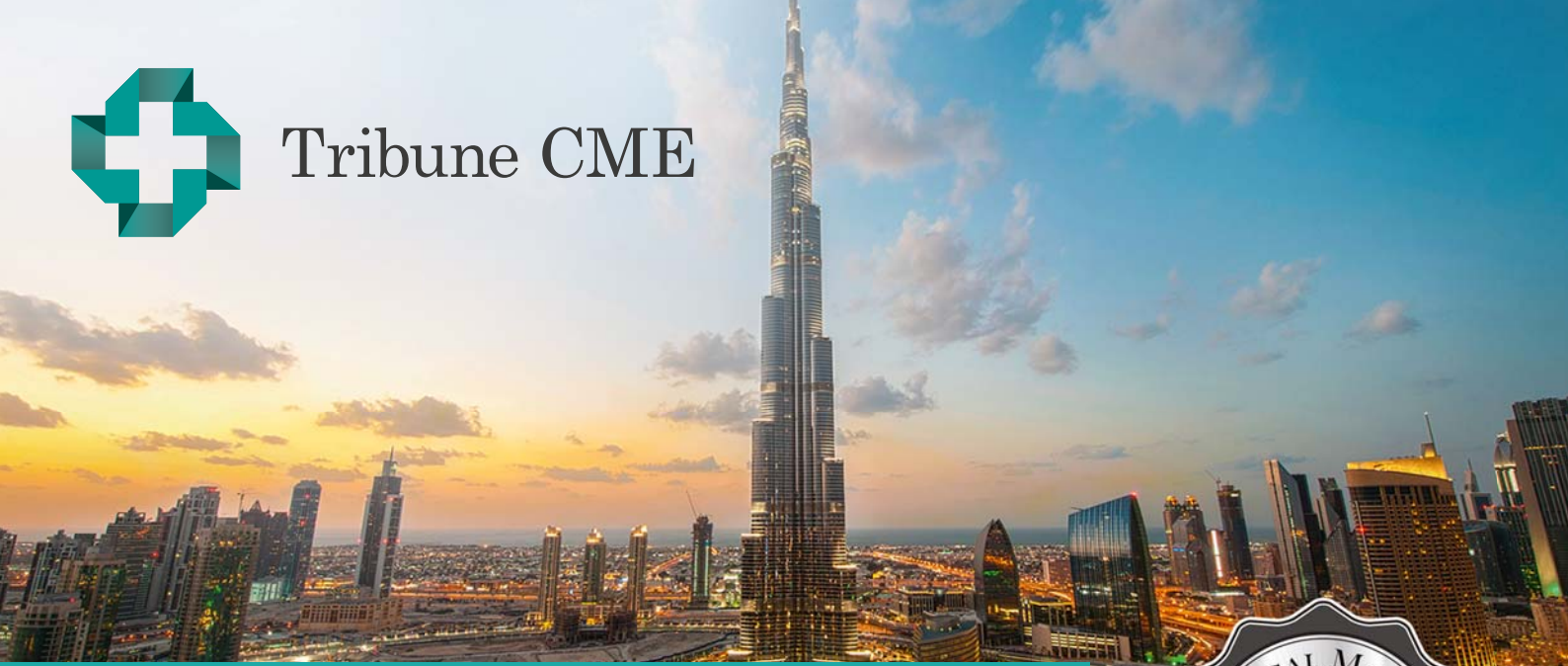formation and subsequent collapse of vapour bubbles in the irrigation solution. For this purpose, a high concentration of energy is needed to heat and to vaporise a small volume of the irrigant. The energy concentration can be obtained temporal (distributing the energy within a very small time frame) or spatial (by directing the energy onto a very small surface).

An example of temporal energy concentration is given by Lauterborn and Ohl²⁴, and Lauterborn et al.²⁵ In their studies of single bubble dynamics, they have used (1) a ruby laser with a pulse duration between 30 and 50 ns, a wavelength of 694.3 nm (hence low absorption in water), and an energy per pulse of several 10 mJ, and (2) a Nd:YAG laser with a pulse duration of 8 ns, a wavelength of 1,064 nm and similar energies per pulse. It was possible to register the collapse times of the generated bubbles: they range from 9 ns for bubbles starting to collapse from a radius of about 1.5 mm down to 4 ns for bubbles of a maximum radius of about 0.75 mm. Shock wave pressure measurement series were also obtained with different bubble sizes: About 10 kbar is reached for a bubble collapsing from a radius of 500 µm and about 25 kbar when collapsing from a radius of 3 mm.

An example of spatial energy concentration is given by Jansen et al.²⁶ Cavitation was demonstrated in water at the tip of a Ho:YAG laser ($\lambda = 2,120 \text{ nm}$, α in water is 11.3 cm^{-1} , transmission through 1 mm water is 7.4%) using 200 mJ pulses




Tribune CME



6 Months Clinical Masters™ Program in **Aesthetic and Restorative Dentistry**

Dubai Session, 12-15 November 2014



On location session, **hands on** + online learning and mentoring

Learn from the **Masters** of Aesthetic and Restorative Dentistry: _____



Prof. Angelo Putignano



Prof. Francesco Mangani

Topics

- Anterior Composite Restorations Demystifying Anteriors
- Posterior Direct Restorations
- Conservative Indirect Esthetic Restorations

Registration information: _____

12-15 November 2014

a total of 4 days of intensive live training in **Dubai** (UAE)

Curriculum fee: € 3,450

(you can decide at any time to complete the entire Clinical Masters Program and take the remaining session)

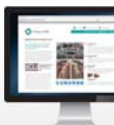Details on www.TribuneCME.com

contact us at tel.: +49 341 48474 302

email: request@tribunecme.com

Collaborate
on your cases

and access hours of
premium video training
and live webinars



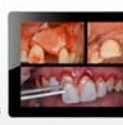
University
of the Pacific

you will receive a
certificate from the
University of the Pacific



Latest iPad
with courses

all registrants receive
an iPad preloaded with
premium dental courses



50

 ADA CERP
C.E. CREDITS

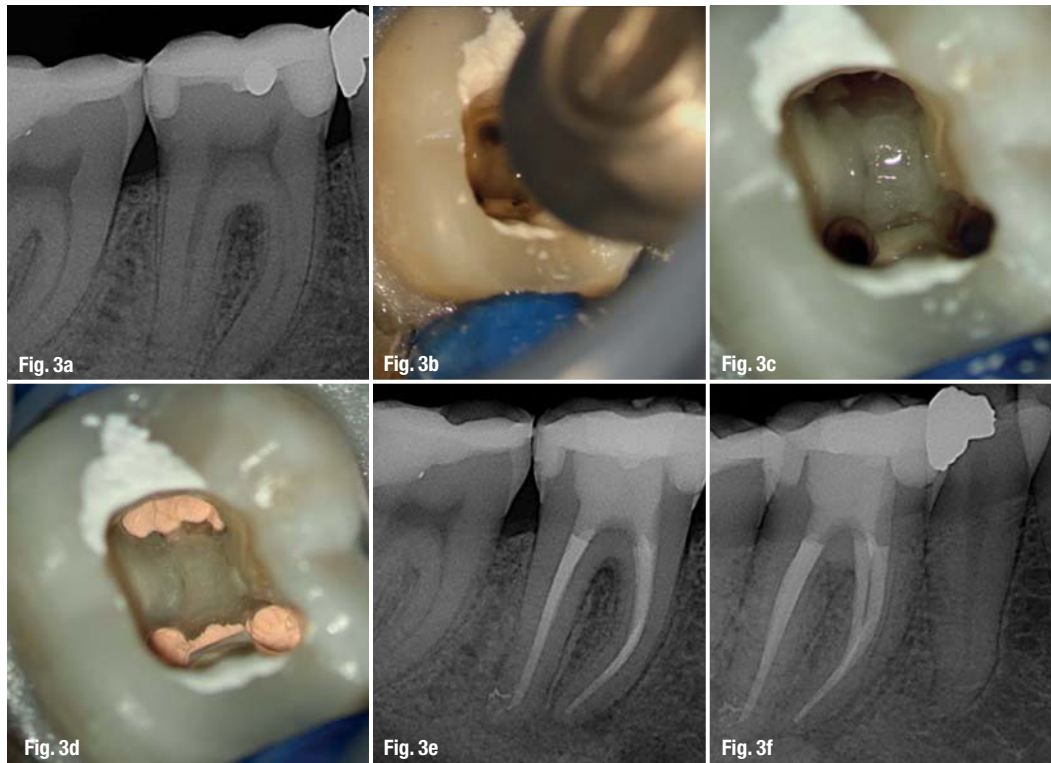
*iPad only available for the participants
in the entire Clinical Master Program

ADA CERP® | Continuing Educator
Recognition Program

Tribune America LLC is the ADA CERP provider. ADA CERP is a service of the American Dental Association to assist dental professionals in identifying quality providers of continuing dental education. ADA CERP does not approve or endorse individual courses or instructors, nor does it imply acceptance of credit hours by boards of dentistry.

Supported by:
ivoclar vivadent
passion vision innovation

Figs. 3a–f Root canal treatment on a mandibular first molar with apical periodontitis and the use of H-LAI with the PIPS tip demonstrating its cleaning efficiency, and the six month follow-up (a. Diagnostic radiograph, b. Cleaning of the root canal using PIPS H-LAI, c. The cleaned pulp chamber and root canals, d. Root canals filled with gutta-percha and Top Seal, e, f. Control radiograph of the root fillings.



and a fibre tip diameter of 400 μm . The occurrence of cavitation bubbles was demonstrated for pulse lengths in the microsecond range. The latter is the case for most of the dental laser systems.

The parameters that influence cavitation

Both examples demonstrate that cavitation does not necessarily depend on the absorption coefficient of the liquid per se. Power density and energy density (determined by pulse length, pulse energy, fibre diameter and design) are also important parameters. These parameters have to be taken into account for the amount of energy that is delivered to the tooth and in the root canal. In the situation of the root canal this means that non-absorbed radiation by the irrigant can result in unwanted side effects and consequences. For wavelengths that are well absorbed into the dentine, this will imply damage to the root canal and the root canal wall. For wavelengths that penetrate deeper into the dentine thermal damage to the dentine and even the periodontal ligament can be expected. Consequently, high α -values for the irrigation solutions are recommended. For as far as LAI is considered, a critical borderline for α -values is fixed at 10 cm^{-1} .

Hence, candidates for the induction of cavitation are both Erbium wavelengths. The absorption coefficients for water at 2,790 nm (Er,Cr:YSGG) and 2,940 nm (Er:YAG) are around 6,000 and 12,000, which is very high (Table 1). In this respect, considering a number of fixed parameters such as

the minimal and maximal diameter sizes of commercially available endodontic laser fibres, pulse duration, pulse energy and fibre design, and for same lasers also the fixed pulse frequency, become the influencing parameters for the induction of cavitation.

Fibre tip design

Fibre tips with plain ends result in the formation of cavitation bubbles appearing as channel like, elongated or elliptical bubbles with a diffuse surface. The conical tip results in the formation of a spherical bubble.^{20, 21, 26}

The ability of laser-generated shock waves to debride root canals depends upon the efficiency of the energy absorption within the fluid, the energy, shape and duration of the laser pulse and the power density achieved at the fibre tip.²⁷ The direction of the shockwaves is influenced by the shape of the fibre tip. It is expected that plain fibre tips deliver laser energy primarily in forward direction, resulting in a forward direction of the laser shock waves and largely parallel to the walls of the root canal surface.

Laser activated irrigation with the fibre in the root canal or in the region of the orifice

We make a distinction between the use of the fibre in the canal (conventional laser activated irrigation—C-LAI) and the fibre hovering over the orifice (hovering laser activated irrigation—H-LAI).

At present, our studies together with the one of de Groot et al. have demonstrated that C-LAI with the plain fibre tip ends resulted in the efficient removal of artificial dentinal debris out of an artificial root canal wall groove.^{17,18, 28}

These studies appear to be the only ones that are using a fibre in the root canal for the evaluation of debridement efficiency. The study of De Moor et al. in 2010 was the only one to compare the debridement efficiency of both Er:YAG and Er,Cr:YSGG laser.¹⁸ In a study of Macedo et al. it was demonstrated that Er:YAG C-LAI increased the reactivity of NaOCl.²⁹

PIPS-tips (Photon-Induced Photoacoustic Streaming) were presented by its developers at the World Congress of Minimally Invasive Dentistry meeting in San Francisco in August 2009. The parameter settings differ from the ones used for C-LAI, the pulse energy has been decreased to 20 to 50 mJ, and pulses of only 50 microseconds of duration are used. The pulse frequency remains in line with the previously used C-LAI frequencies of 10 to 20 Hz. With an average power of only 0.2–0.5 W, each pulse interacts with the water molecules with a nominal peak power of 400–1,000 Watts, creating a shock wave-like phenomenon leading to the formation of a powerful streaming of fluids inside the canal.³⁰ The temperature rise after 20 and 40 seconds did not exceed 1.5 °C.³¹

At present, there are contradicting findings for H-LAI with PIPS. Deleu et al. found a better debridement of dentine plugs in artificial root canal wall grooves with C-LAI than with H-LAI PIPS.¹⁹ Removal of intracanal tissue and debris, based on high-resolution micro-computed tomography, was 2.5 times higher than with conventional needle irrigation in mesial roots of mandibular molars.³² Data from the authors yet submitted for publication demonstrate that H-LAI with PIPS tips 400/14 (Fotona, Ljubljana, Slovenia) and H-LAI with XPulse tips 400/14 (Fotona, Ljubljana, Slovenia) both with the recommended PIPS power settings and exposure time result in the same amount of debris removed from artificial root canal wall grooves (Figs. 2 and 3 are examples for the use of PIPS and X-Pulse tips). It was also found that continuous irrigation was necessary, especially when the tips are placed in root canal chambers with small dimensions. This in order to avoid depletion of irrigant through splattering.

The antibacterial effect was higher with H-LAI PIPS used in conjunction with NaOCl than syringe irrigation with NaOCl in the study of Al Shahrani

et al.³³ and also higher than syringe irrigation with NaOCl and ultrasonic irrigation in NaOCl in the study of Peters et al.³⁴, comparable with syringe irrigation with NaOCl and EDTA in a study of Zhu et al.³⁵ and with syringe irrigation with NaOCl in the study of Pedulla et al.³⁶

In Part I the risk of apical extrusion with C-LAI was addressed on the basis of published data. Investigations are needed for H-LAI in order to evaluate the safety of this technique. Patients feel the action of H-LAI and describe it as gentle knocking at the top of the root. Hence, it is not unrealistic that with high peak power also high pressure can be generated.

Conclusion

Laser and fiber technology for root canal debridement and disinfection has evolved enormously during the last two decades. Fibre tip design has become important with a focus on radial firing tips, as well as the use of Erbium fibres in root canal irrigants for laser activated irrigation. At present, there is laser-activated irrigation with the fibres in the root canal (C-LAI) and fibres hovering over the root canal orifice (H-LAI). Comparison in efficiency between both has been minimally investigated. The few data available demonstrate (1) that hovering over the canal orifice with radial firing tips with pulses of reduced length and high peak powers helps in removing debris and minimises thermal effects on the dentinal walls; and (2) that the use of fibres in the root canal still is superior regarding the removal of compacted dentine debris. More research is needed for the determination and evaluation of the antibacterial effectiveness of both, preferably in the same study.

Editorial note: A list of references is available from the publisher.

_contact

laser

Prof. Dr Roeland De Moor

Ghent University Hospital
Dental School
De Pintelaan 185/P8
B-9000 Ghent, Belgium

Tel.: +32 9332 4003

roeland.demoor@ugent.be

Peripheral Giant Cell Granuloma surgery with diode laser

Authors _Maziar Mir, Masoud Mojahedi, Jan Tunér, Amir Mansour Shirani & Masoud Shabani, Iran, Germany & Sweden

_Laser surgery has many benefits such as maintenance of sterile condition, reduction of bleeding, good possible estimation of cutting depth, precision of cutting, often no need for suturing or bandages, pain reduction, minimally invasive procedure to reduction of patient stress, promotion of wound healing and less scars. Thereby, the patient can often do the routine activities after laser surgery. Many cases have been reported in literature regarding treatment of oral exophytic lesion by laser. In the following case report, we present a treatment Periodontal Peripheral Giant Cell Granuloma (PGCG) without suturing.

_Introduction

PGCG is originated from the periodontal ligament or the periosteum.¹ The lesion is more common in the lower jaw than in the upper jaw and is also more common in females than males.²⁻⁴ Any region of the jaws can be involved by this lesion.^{4,5} Mobility and displacement of the neighboring teeth can occur.⁶ The lesion size varies from about 0,1 cm to 3 cm in most cases.^{5,7}

The etiology is unknown but local irritating factors such as ill-fitting prosthesis, poor restorations, microbial dental plaque, calculus, chronic infection and lack of nutrients may have a role in the etiology. The lesion may be seen in cases of hyperparathyroidism, after periodontal surgery.⁸⁻¹¹ The presence of S-100 positive cells, which are evidence of Langerhans cells or their precursors, and the presence of fibroblasts, endothelial cells, and myofibroblasts point towards a reactive nature of the PGCG.¹²⁻¹⁴ Excision (with scalpel, electrocautery and lasers) and also eliminating any local irritating factors must be considered in the treatment of the lesion. Recurrence rate of the lesions ranges from five to eleven per cent.^{15,5}

_Case report

A 45-year-old female patient with complaints of gingival mass for a period of six months referred for treatment. The lesion was not painful but had bleeding while eating or sometimes even spontaneously.

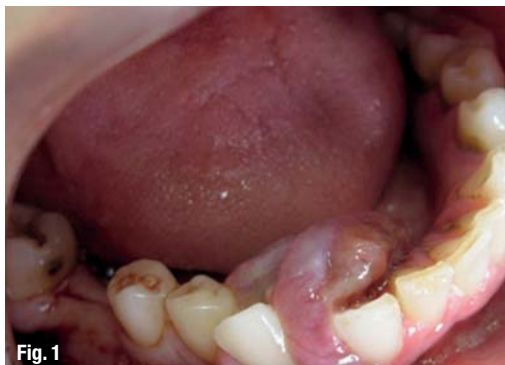Medical history

The patient's medical history has shown no systemic medical problems, no allergic reaction, no medication or drugs and no history of past surgical procedures, so that the patient does need to be referred for medical consultation.

Dental history

Oral and maxillofacial examination of the patient revealed no T.M.J. or myofacial disturbances, no functional or parafunctional habits, class I malocclusion, with poor oral hygiene and multiple caries in the permanent teeth.

Fig. 1_PGCG.



Clinical findings

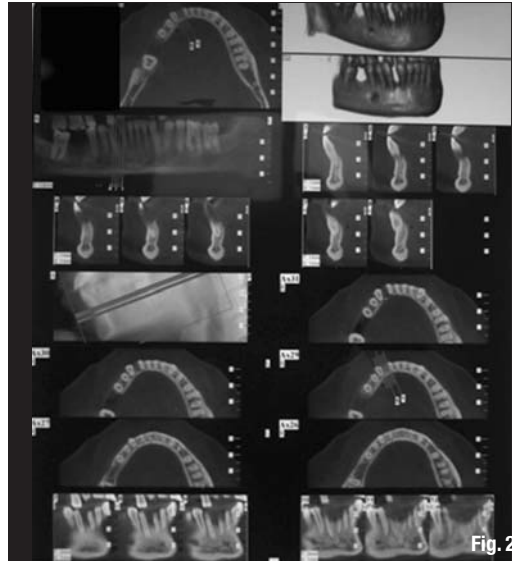
The clinical findings revealed an exophytic lesion in the labial and lingual surfaces of the lower jaw. The lesion was partially firm, red to pink, bleeding while eating or spontaneously, no pain, slightly movable with duration of more than six months, more accumulation of the dental plaque and calculus, gingivitis and pseudopockets in the other sites of both jaws.

X-ray examination

X-ray examination showed no destructive effect such as alveolar bone resorption but slight displacement of the involved teeth. The case was provisionally diagnosed as PGCG and we decided to treat it with a diode laser.

Treatment delivery sequence

After the patient filled in the consent form, the surgery area was anesthetised through infiltration method by two percent lidocaine with Epi 1:100000, 1.8 ml and then a retraction suture was placed in the lesion. In the next step, we defined the controlled area and properly placed the laser warning signs to secure the operating room. Then, we checked the safety for the patient's eye glasses, the patient's guardian eye protection and the assistant's eye protection. After this, we reviewed the patient's information (examination sheet and X-ray, consent form, etc.) and cared for a proper calibration of the laser system (fiber cleaving, beam aiming, and initiation of fiber with articulation paper and test-fire of the laser). The lesion excisional biopsy was started with initiated fiber and the incision was performed with tissue under tension and contact of the hot tip with tissue so that the lesion was separated in the proper way. In the starting of the surgery we used a



diode laser with 980 nm, fiber 400 μ, output power 2 W, CW, contact mode, irradiation time 189 sec., but after gross removal of the lesion we changed the laser setting so that we applied 1W, fiber 400 μ, CW, contact mode, irradiation time 15 sec. per pocket for sulcular debridement of the neighbouring teeth for deep ablation. During the treatment, high volume suction was used to evacuate vapour plume and objectionable odours at the site of operation. During treatment the laser tissue interaction was respected in order to prevent of any unsuitable reaction and the surrounding tissue damage through the progression of the tissue vaporization at the base of the lesion and the patient's reflexes. The moisture gauze was used for prevention of unwanted thermal damage in the adjacent tissue and also the black periosteal elevator was applied for prevention of

Fig. 2_Patients X-ray.
Fig. 3_Laser setting for the first surgery.

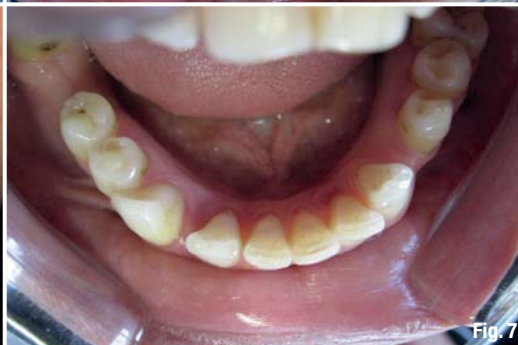
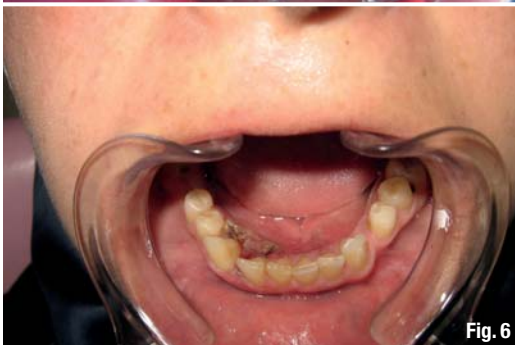
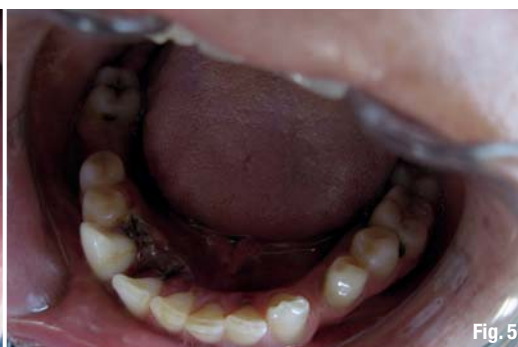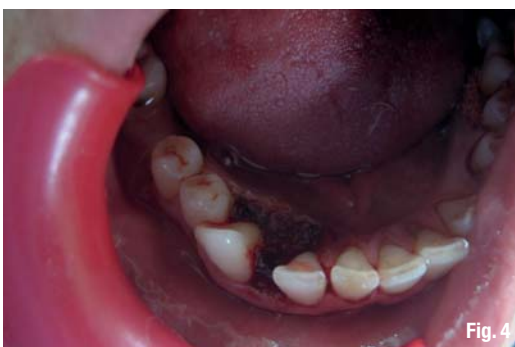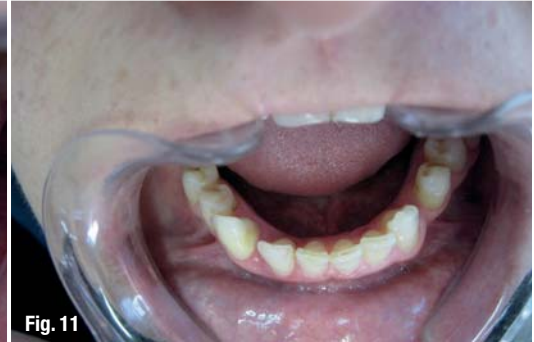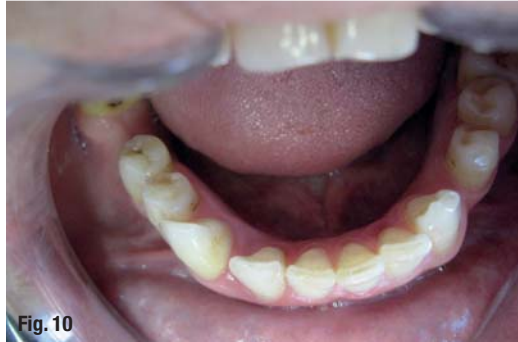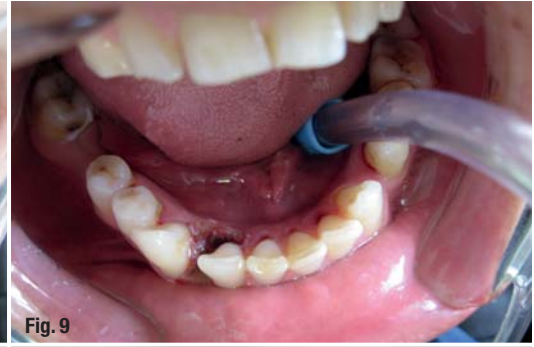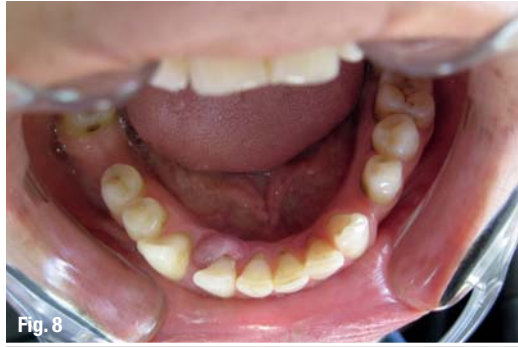Fig. 4_Immediately after lasing.
Fig. 5_One day after surgery.
Fig. 6_One week after surgery.
Fig. 7_One month after surgery.

Fig. 8_Three months after.

Fig. 9_Immediately after lasing of recurrent PGCG.

Fig. 10_Three months after lasing of recurrent PGCG.

Fig. 11_One year after lasing of recurrent PGCG and perfect treatment.



any thermal conduction in the neighbouring teeth. Removal of carbonization tissue was done by micro-applicator brush soaked in a three per cent hydrogen peroxide solution. The biopsy was sent for laboratory examination. In the post procedural education, the patient was advised to keep the area clean and plaque free with gentle brushing, avoid food and liquids that may cause pain or irritation to the sensitive tissue and taking over-the-counter analgesics as needed. The laser setting was registered in the patient's document for both stages of gross lesion removal and laser sulcular debridement.

Final result

Excellent laser excisional biopsy was observed with no bleeding, no carbonization and no char. The patient did not experience any discomfort and was satisfied.

Follow up

The first visit after laser excisional biopsy was a day after the procedure. The healing process was as expected so that the healing was progressing well and without any swelling or pain. After one week, the patient revisited with no problems in the healing process. Finally, after one month follow up, a successful treatment was observed. After three months follow up the recurrent lesion was observed and renewed lasing of the lesion was performed as the same laser setting and the same treatment delivery sequence. After three months and also after one year the patient was checked again. No recurrence was observed and the neighbouring teeth were vital and intact.

Discussion

In comparison with conventional excisional biopsy procedures (scalpel and suturing), the laser-assisted

excisional biopsy can be performed very fast, with no bleeding, less or no pain, less or no edema and little or no need for analgesics. Because of the size of the lesion, this procedure is traditionally classified as an advanced laser procedure. Full removal of the lesion is very difficult and a recurrent lesion may occur due to insufficient extension of the surgery area. In laser surgery, a larger extension in the surrounding tissue leads to an efficient removal of the lesion so that after one year follow up there was no recurrence.

_Conclusion

As we could see in this case, the diode laser proved to be a powerfull tool for the removal of a periodontal PGCG.

Editorial note: A list of references is available from the publisher.

_contact	laser
<p>Masoud Shabani Oral Health Department Official complex of Ardebil University of Medical Sciences Daneshgah Street 5618985991, Ardebil, Iran</p> <p>Tel.: +98 451 5521417 Fax: +98 451 5522196 Mobile: +98 9141511477 m.shabani@arums.ac.ir</p>	

INTRODUCING



**DIGITAL
DENTISTRY
SHOW**

AT
INTERNATIONAL EXPODENTAL MILAN

16 | 17 | 18 OCTOBER 2014

EXHIBITION

LIVE PRODUCT PRESENTATIONS

HANDS-ON WORKSHOPS

PRINTED REFERENCE GUIDE

COFFEE WITH THE EXPERTS

www.DigitalDentistryShow.com

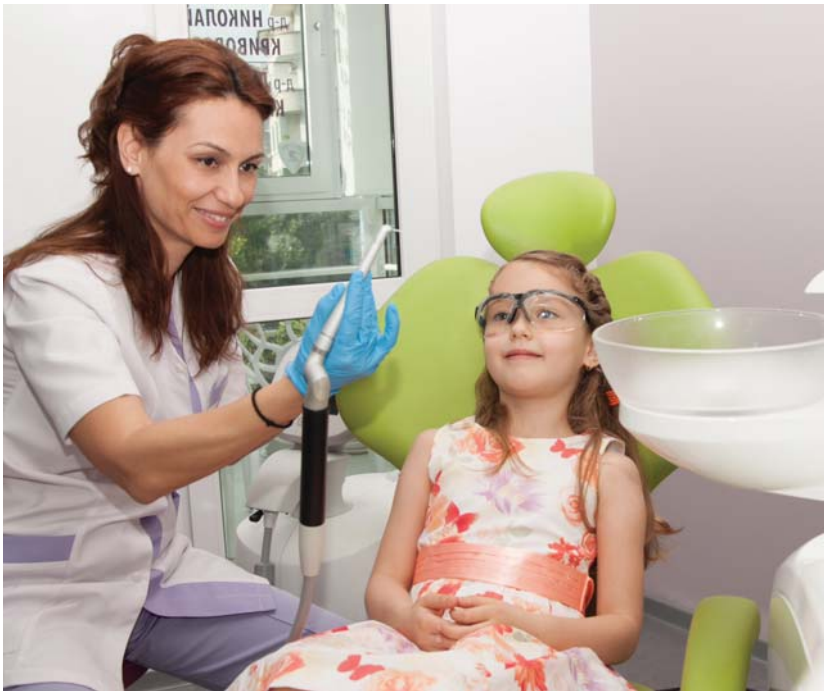Organized by Dental Tribune International in cooperation with Promunidi.
Dental Tribune International | Holbeinstraße 29 | 04229 Leipzig | Germany
T +49 341 48474 134 | F +49 341 48474 173
E info@digitaldentistryshow.com | W www.DigitalDentistryShow.com

dti Dental
Tribune
International

PROMUNIDI

Subjective acceptance and pain perception of Er:YAG laser therapy in children

Authors Ani Belcheva & Maria Shindova, Bulgaria



_Introduction

Many people report fear of pain as their chief reason for not seeking dental care, furthermore dental anxiety may lead to avoidance of dental care, increasing the risk of caries development and oral diseases.¹ It is a multidimensional complex phenomenon, and no one single variable can exclusively account for its development.²

Several studies have shown that fear of drill is a principal cause of dental anxiety among children.^{3,4} They identify a number of specific stimuli in a dental setting among which the restorative dentistry procedures deliver most potent triggers

for their dental anxiety such as the sight of the anesthetic needle and the sight, sound, smell and vibration of dental handpiece and rotary dental drill, pain associated with dental treatment.⁵⁻⁹ It has been suggested that reducing these stress-triggers is an effective procedure for managing anxious patients.^{2, 10}

For this reason, anxious patients who must undergo restorative procedures are often managed using the "4S" rule or the so called "4S" principle. It is based on removing four of the major primary sensory triggers for dental anxiety when in the dental setting—sight (air turbine drill, needles), sounds (drilling), sensations (high frequency vibrations—the annoyance factor), smells, and it is used in conjunction with other measures and alternative methods to mitigate anxious behaviors and their consequences.²

A range of approaches can be used and they can be mixed and matched to meet the particular needs of a situation. Laser therapy in pediatric dentistry is a therapy of choice for its known advantages, especially for the safety of its use and for its gentle approach with patients.¹¹ It has been in use for carious removal in anxious patients for more than 20 years.¹⁰ Dental laser treatment reduces the need for injected local anesthesia and obtains very low to null likelihood of odontoblastic pain and the annoyance factor during carious removal. There is no smell or there is dentine ablation vapor in case of inadequate suction during cavity preparation, while the dominant physical sensation is popping (shock waves) and ablation sound. This new technology offers to the pediatric dentists, new possibilities to change completely the restorative treatments.

Considering the difficulty of reducing dental anxiety in children, this study seeks to evaluate the subjective laser therapy acceptance and tolerance as an alternative method for dental tissue therapy in children, using an Erbium:YAG 2,940 nm (LiteTouch™ by Syneron Dental Lasers) and checking the impact of laser on their perception of pain.

Material and methods

The study was conducted on 45 six- to twelve-year-old children (mean age = 7.42 ± 1.35 years). A convenience sample of children was randomly selected from patients treated at the Department of Pediatric Dentistry in Faculty of Dental Medicine, Medical University – Plovdiv, Bulgaria during the period May to December 2013.

The inclusion criteria were:

- children aged six to twelve years;
- signed informed consent form from the parent;
- native language of the child—Bulgarian;
- presence of one or more dentine carious lesions without pulp involvement or pain; the cavities were matched according to the tooth type (primary or permanent; premolar or molar), cavity type (Black's classification) and cavity depth (D3 threshold, WHO system).

A total of 45 teeth were prepared without anesthesia, using an Er:YAG laser 2,940 nm (LiteTouch™ by Syneron Dental Lasers). Parameters and operative mode used for these hard tissue therapies are reported in Table 1. After cavity preparation and before restoration of the treated tooth, each patient completed a questionnaire to evaluate the subjective acceptance of laser therapy concerning the major primary stress triggers. Children were asked to rate the anxiety provoked by the sight and sound of the laser handpiece, the smell, taste, vibration sensation and discomfort of suction during the laser preparation and to integrate the degree of their pain.

Because children under eight years old are unlikely to be reliable in recalling their pain perception during treatment¹², the universal pain assessment tool was used (Fig. 1). It is a self-report instrument that comprises Wong-Baker Faces Rating Scale—a row of six representative images (icons) ranging from "No hurt" to "Hurts as much as you can imagine"¹³ in combination with a visual analogue scale of 0 to 10. There are six levels of pain quality and intensity marked by word descriptors. Each child was asked to point to the icon or choose the number which most closely depicted its pain during dental treatment (Fig. 2).

	Enamel	Dentin
Watt	4.0	2.0
Hz	20	20
mJ	200	100

Tab. 1_Hard tissue dental setting

The data obtained were tabulated and subjected to statistical analysis. SPSS 19.0 was used for data analyses. The level for statistical significance was set at $p < 0.05$.

Results

All the cases of restorative dentistry were performed without anesthesia and patients completed questionnaires. Graphic 1 shows the distribution of the results concerning the investigated triggers for dental anxiety during laser cavity preparation. The most anxiety provoking items were smell (67.7%) which is statistically different from all items ($p < 0.01$). The second factor reported as anxiety provoking one was taste (42.2%). Only one patient reported vibration sensation during cavity preparation using the LiteTouch Er:YAG laser (2.2%) which is statistically different from the triggers "taste", "suction" and "smell" ($p < 0.01$).

The analysis of pain indicated that 33.3% of children felt no pain at all with laser preparation, 37.8% reported "Hurts little bit" (level 2) and 26.7% reported moderate pain level. Only one patient reported severe pain perception on the used pain assessment tool (Graph. 2).

The laser treatment was carried out with good collaboration of the patients in 91.1% of cases within the first session. The treatment of the other 8.9% patients was stopped due to lack of accept-

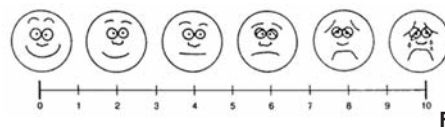


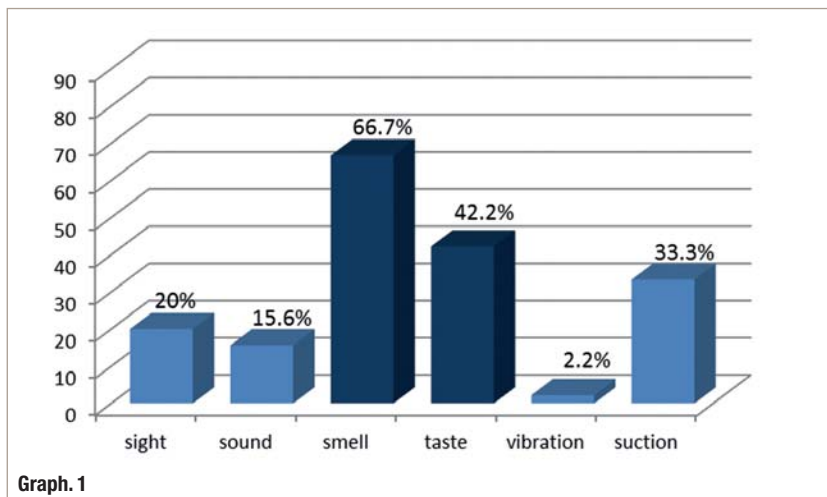
Fig. 1

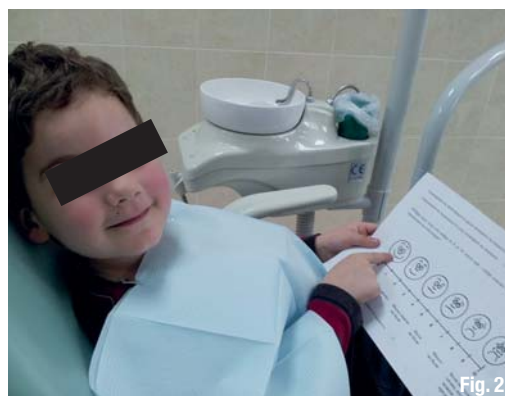

Fig. 2

Fig. 1_ Universal pain assessment tool.

Fig. 2_ A child, indicating its pain on the self-report assessment tool.



Graph. 1 Prevalence of the investigated items in the cohort of participants.

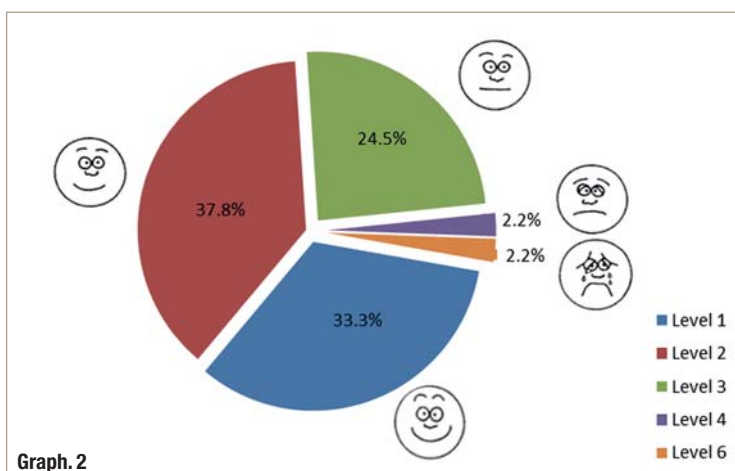
ance of the unfamiliar new technology and uncooperative behavior after placing a sterile cotton pellet and temporary material in the cavity and obturated at the second appointment.

Discussion

The present study indicates a decrease in three of four stress triggers in "4S" principle. Our results show that the sensation of high frequency vibrations—the annoyance factor for patients is eliminated. It confirms the results of Evans et al.¹⁴, who found that in children over ten years old there is a preference of laser treatment which is perceived as having less vibrations in comparison with the conventional method.

As several studies have shown that fear of drill is a principal cause of dental anxiety among children especially the sight and sound of dental hand-piece^{3-5,9}, laser therapy as an alternative method for managing anxious patients reduces the effect of these two stress triggers. It is confirmed by the obtained results of our study—less than one-fifth of the children have shown anxiety provoked by

Graph. 2 Distribution of scores on the pain scale used.



Graph. 2

the sight and sound of the laser. The results of the present study concerning the anxiety provoked by the noise are in line with the results of a previous study¹⁴, that only few children consider popping sound as a stress trigger.

However, one stress trigger in "4S" rule is not reduced. Patients in our study consider smell as the most anxiety provoking factor, followed by the unpleasant taste that are produced during the laser preparation in oral cavity. The adequate suction needed during laser cavity preparation was found to be stressful factor by one third of the studied patients.

The analysis of pain indicates that the scores obtained from 71.1 % of the cases after laser preparation were low (level 1 and 2). They are in line with the results of several researchers.^{11,15,16} They show that laser treatment reduces the need of injected local anesthesia and the sight of needle that is considered a specific anxiety provoking stimulus in dental setting. Thus laser therapy is an effective method for managing dental anxiety by influencing one of the stress triggers in "4S" principle.

Conclusions

Cavity preparation with the LiteTouch Erbium:YAG laser would seem to be an option for anxious patients. It produces less pain and has good level of subjective acceptance registered among patients. The analysis of the obtained results shows that laser therapy in pediatric dentistry is a therapy of choice for managing anxious patients who must undergo restorative treatment.

Editorial note: A list of references is available from the publisher.



_contact	laser
<p>Ani Belcheva, DDS, MSc, PhD Associate Professor Department of Pediatric Dentistry Faculty of Dental Medicine Medical University, Plovdiv 3 Hristo Botev Blvd. 4000 Plovdiv, Bulgaria</p> <p>abeltcheva@yahoo.com</p>	



CROIXTURE

PROFESSIONAL MEDICAL COUTURE



THE NEW 2014-2015 COLLECTION

EXPERIENCE OUR ENTIRE COLLECTION ON WWW.CROIXTURE.COM

The Delta Cube laser: a multi-wavelength diode laser

Part I: “Ex vivo” study

Authors_Prof. Dr Jean-Paul Rocca, Dr Sylvaine Lesnik-Cannavo & Prof. Dr Carlo Fornaini, France & Italy




Fig. 1

Fig. 1 _Complete view of the device.

_Introduction

Diode lasers are currently in relatively widespread use in dentistry for a number of reasons including their compact design, ease of use and range of applications in the field. It should nonetheless be noted from the outset that the indications are limited to soft tissue (exeresis) and only to the superficial treatment of hard tissue (disinfection) without exeresis.

Diode lasers are semi-conductor lasers and have variable wavelengths ranging from visible to infrared. It is now possible for the same device to emit several different wavelengths, one, two or three at the same time. The Delta cube laser is interesting in

this regard, as it provides four different wavelengths (405 nm blue aiming beam, 650 nm diode and 915 and 1,064 nm diodes).

_Brief description of the device

The power ranges from 0.1 W to 15 W, which allows the Delta Cube laser to be used where low-powered lasers are indicated (less than 0.5 W, Nogier frequency) and also for cutting and disinfection with higher power settings. The frequency is also variable (20 Hz-50 Hz-100 Hz and 20 kHz). The device has a display (Fig. 1) of the selected parameters, which can be changed with pushbuttons. There is a display for surgical procedures at the bottom of the device which shows the pre-programmed settings corresponding to various surgical procedures.

At the top left (seen from the front) is a purple tip which is primarily used for hemostasis and combines two wavelengths (1,064 and 915 nm) and the aiming beam (405 nm). Below is a green tip for straight cutting and below that a red tip for cutting at an angle of 90° (combination of the three wavelengths). This is the first time that a “dental” diode laser has been available in non-contact mode, and this feature is why an aiming beam (blue) is required. At the top right, a metallic tip provides low power output and is used inter alia to manage post-operative and joint pain (red laser, 650 nm and 915 nm); the diameter of the spot is 6 mm. Below, there is a yellow tip for positioning fibres of varying diameters (usually 400 µm), used in endodontics and periodontics in the disinfection process. Magnetic force means that all the tips are easily manoeuvred with the handpiece which

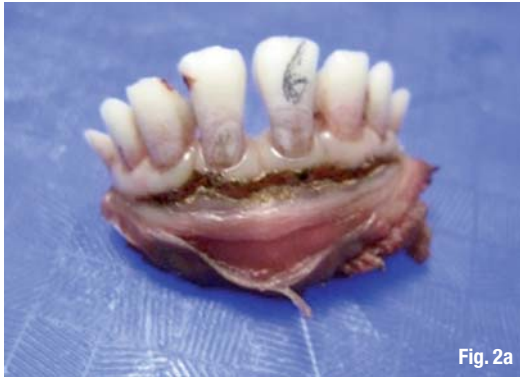

Fig. 2a

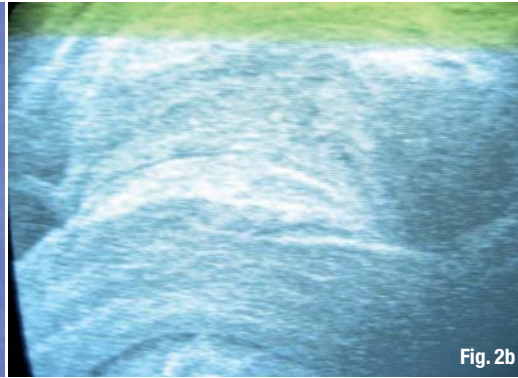


Fig. 2b

Figs. 2a & b_Incision 7 W. Precise edges. The tissue retraction is a result of the desiccation and subsequent bonding (observation with SEM).

holds the fibre. This magnetic force facilitates handling. There is an emergency stop button on the bottom of the instrument which cuts off the electricity supply.

Ex vivo tests

The choice of parameters and their effects is an issue to be addressed with any new device. Initially, *ex vivo* tests are needed to reproduce or to attempt to reproduce clinical conditions.

Relationship between cutting and temperature increase

Three power outputs were tested (3 W, 5 W and 8 W) with the green tip (straight cut) and the red tip (90° cut) on animal jaws. These power outputs have been correlated with an increase in temperature of the underlying tissue (Lesnik-Cannavo and Bertrand MF). A control group was taken with a cold blade (no. 15) and the irradiated areas were irradiated in successive passages of the laser. Irrespective of the method used, the cut was checked with a metal probe to test the depth of the cut (down to the periosteum) (Fig. 2).

The best results were obtained with a power setting of 7 W (duration of each pulse: 300 msec, frequency: 100 Hz). Few traces of carbonisation were observed. Cutting can be initiated even more rapidly if a black dot is applied to the biological tissue using a felt-tip pen, as there is high absorption of the combination 1,064 nm and 915 nm by this colour (chromophore). In these *ex vivo* tests, the thickness of the

tissue (1.2 mm to 1.5 mm) was much greater than that found *in vivo* in people. The same applies to the texture, which is much more compact in the experimental model. In the light of these two aspects, cutting requires more clinical time *ex vivo*. In this model, the total number of pulses at 7 W was 27,926 for a 10.5 mm-long incision line, which is equal to 2,660 pulses per centimetre of incision. This represents 26.6 seconds per centimetre of incision at a frequency of 100 Hz. The temperature increase measurements were conducted on the same tissue using the following parameters: incisions 1 and 2 = 3 W (power density = 9,554.14 W/cm²); incisions 3 and 4 = 5 W (power density = 15,923.56 W/cm²); incision 5 = 8 W (power density = 25,477.70 W/cm²). A thermocouple was placed under the mucous tissue and moved in line with the location of the incision lines to be under the line of irradiation. The temperature increase at 3 W was 2.27 °C in 10 seconds for a power density of 9,554 W/cm². It was 2.51 °C in 10.06 seconds at 5 W (power density: 15,923 W/cm²) and 3.68 °C at 8 W (power density = 25,477 W/cm²).

These *ex vivo* tests indicate that, no matter what the power used, the temperature increase measured in these experimental conditions is never excessive and meets the limit of 7 °C, above which protein coagulation can be observed.

Temperature increase and periodontics

Disinfection of the pockets is a stated objective, and while there are several methods available,

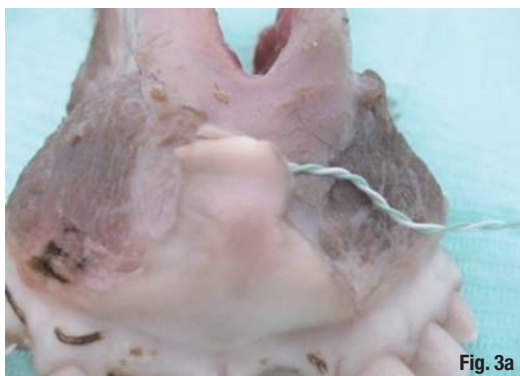

Fig. 3a

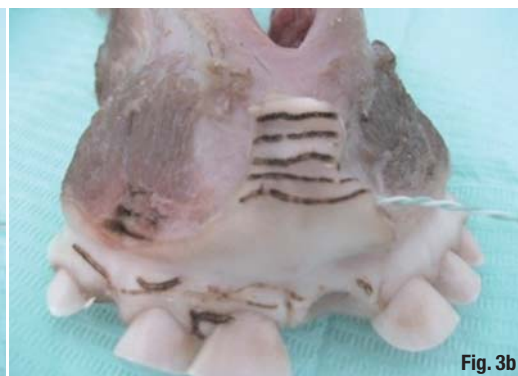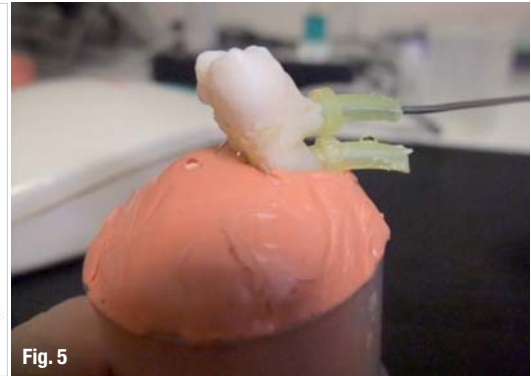
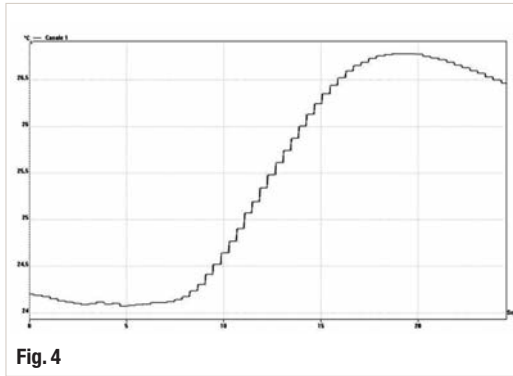


Fig. 3b

Figs. 3a & b_Positioning of the thermocouple and its movement in line with the incision line.

Fig. 4_Temperature increase at 3 W.

Fig. 5_Positioning the thermocouples.



laser technology is one of the possible therapeutic options. It must therefore be ensured that when a fibre is at the bottom of the pocket and therefore in contact with the cementum, there is no temperature risk to the pulp.

Freshly extracted monoradicular teeth were preserved for a brief period of time in saline solution at 4 °C and the root canals were prepared using the ProTaper® system, with irrigation with a 2.5 % sodium hypochlorite solution. The samples were fixed in silicone and two metallic tubes were attached to the cervical third and the apical third of each of the roots. Two thermocouples were inserted into the hollow tubes, filled with conductive gel, in contact with the radicular dentin opposite the areas irradiated. The thermocouples were connected to the data acquisition system (Picolog®).

Two periodontal pockets were simulated by creating pockets in contact with the cementum. These pockets were irrigated with oxygenated water with a small quantity of Betadine®, acting as a chromophore for wavelengths of 1,064 and 915 nm. Radiation was from the bottom of the simulated pocket towards the coronal part. The irrigation solution was changed after each cycle. Each cycle lasted 5 sec. and the intervals were 5 sec. A total of 5 cycles were observed per canal. The fibre (yellow tip) was used with power densities of 2 W, 4 W and 7 W, and two frequencies (100 Hz and 20 kHz). The measurements recorded did not indicate a temperature rise of more than 4.13 °C at any frequency, power density or position.

Temperature increase and endodontics

Once the canal had been prepared by irrigation with hypochlorite, two thermocouples were placed in contact with the cementum and the laser fibre (yellow tip) was positioned 1 mm from the operating depth. The canal was irrigated with hypochlorite and a small quantity of Betadine; irradiation was from the apical section to the coronal section. Each cycle lasted 5 sec. and the intervals were 5 sec. Five cycles were conducted, equivalent to a clinical time of around one

minute. The power outputs used were 2 W, 4 W and 7 W as in the preceding tests and the maximum temperature rise was 4.16 °C, which is almost identical to that observed when the optical fibre was placed in contact with the cementum. In endodontics, this type of laser does not remove the smear layer; this has to be done using traditional methods (17 % EDTA or 11 % citric acid). Once the smear layer has been removed, the root canal can be irrigated with hypochlorite (2.5% to 5.25 %). Near-colourless (yellow) hypochlorite does not stop these wavelengths and as the fibre is at ca. 6 mm above the operating depth, it must be activated in a spiral movement back towards the crown. A biologically neutral food colouring can be added to the irrigation solution for maximum absorption of these wavelengths. In vitro tests on a resistant bacterium (*Enterococcus faecalis*) show a significant reduction in the bacterial load. Furthermore, the light can reach 1,100 µm and therefore penetrate the accessory canals and dentinal tubules.

Discussion

Diode lasers are thermal lasers absorbed deep in the target tissue like other non-semiconductor lasers such as Nd:YAG, Nd:YAP, and to a lesser degree KTP lasers; CO₂ lasers act differently in this regard (superficial absorption, non-fibre). Avoiding all temperature damage is an objective that can be achieved provided certain simple principles are followed:

- Comply with the intervals. This can be done by using low frequencies at the risk of extending the operating time, or simply by ensuring that the intervals are equivalent to the operating times (endodontics, periodontics);
- Move rapidly (incision, excision) and do not hesitate to go back over the line, as this prevents thermal shocks;
- Initialise cutting with a black dot applied with a felt-tip pen, and start to irradiate this dot. Wavelengths 1,064 and 915 nm are absorbed by the colour black, so this enables the rapid start of cutting;
- In disinfection procedures, the fibre (yellow tip) should move relatively rapidly and from the bottom of the pocket or from the operating depth (en-

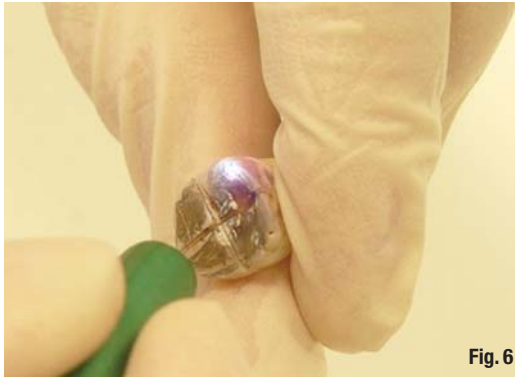

Fig. 6




Fig. 7

Fig. 6 Graphite application and irradiation.

Fig. 7 Partial closure of the dentinal tubules (output power 1 W).

dodontics) towards the crown in a spiral motion. The use of a colouring facilitates absorption.

Treating dentinal hypersensitivity

Hydrodynamic theory links the movement of intratubular fluids to the occurrence of dentin hypersensitivity characterised by acute but brief pangs of pain. A number of different methods have been proposed for managing this syndrome, with varying degrees of success. The objective is however the same in all cases: to close the opening of the dentinal tubules to prevent the movement of these fluids. An experiment was conducted in which discs of dentin were prepared and the smear layer removed, and the opening of the dentinal tubules was then monitored with a scanning microscope in a partial vacuum. The surfaces were then separated into four distinct sections (Fig. 6) and coloured using a black graphite pencil. The surfaces were irradiated with four different power outputs: 0.5 W, 0.75 W, 1 W and 1.5 W for a period of 2 mn per section.

The partial or total closure of the dentinal tubules can be achieved in these irradiation conditions, and in particular with a power output of 1 W. This output is sufficient to achieve the desired results without a temperature increase in the pulp (below 5 to 7 °C at all times). It is nevertheless always important to check the presence of graphite on the irradiated surface, to move tangentially to this surface as far as possible, and never to apply the laser without movement.

Discussion

There have as yet been no publications on this new laser diode concept combining different wavelengths, but in the light of these initial ex vivo observations, the following remarks can be made. In terms of ease of operation/handling, apart from the compact design which is standard for diode lasers in general, the originality of this device is the magnetic connection for the tips. The tip of the handpiece can be removed for changing extremely rapidly. A roller device at the side facilitates storage of the fibre. This is

also the first diode laser able to be used in non-contact mode, including an optical system for cutting with a handpiece at 90°. In difficult areas where the fibre cannot be used, this handpiece makes access to these difficult zones possible (for example the distal face of the maxillary molars). Combining 1,064 nm – 915 nm makes it possible to achieve a clean cut for surgical procedures in soft tissue in a bloodless environment. The use of higher frequencies (20 kHz) makes it possible to obtain peaks in power loosely referred to as "pulses". In a clinical setting, this should enable narrow incisions without heat damage, as demonstrated ex vivo.

Lastly, the more or less systematic use of low-energy lasers in surgical procedures (metallic tip, 650 nm) facilitates healing and merits systematic use. Future studies should examine clinical observations with different indications, such as standard surgical procedures (soft tissue) in adults and in children, pathology applications such as the management of herpetic and aphthous lesions, disinfection in endodontics and periodontics, the treatment of peri-implantitis, tooth whitening and the management of joint pain and healing processes.

_contact

laser

Prof. Dr Jean-Paul Rocca

CHU de Nice
Hôpital St Roch
5 rue Pierre Dévoluy
06000 Nice, France
jprocca@unice.fr


Dr Sylvaine Lesnik-Cannavo

250 route de Mende
34090 Montpellier, France

Prof. Dr Carlo Fornaini

Università di Parma
Via Gramsci 14
43126 Parma, Italy

How **crisis** made me doubt my degrees!



Author Dr Anna Maria Yiannikos, Germany & Cyprus

[PICTURE: ©ILLUSTRATOR]

_When I left Cyprus in March 2013 for a business trip (after two gruelling months due to the total renovation of my dental centre), I could not imagine coming back after three days. I knew that I would have to totally change my professional life after 23 years in dentistry.

Being used to see an average of 20 to 25 patients per day, I was hit by the first tragic month where rates were in single figures and I mostly unable to pay the basic dental treatments! (Our banking system had collapsed, a large amount of depositors had received a haircut in their funds and above all we could not withdraw money from the bank only a certain amount per day, with the worst to come: we had no idea when this situation would end...) It was clear: this was not just any economic crisis—we were in the eye of a black hole! I had to act immediately—aside emotions and outside the scope of my comfort zone. To change my professional situation and find a way out of the crisis, I considered six steps.

_Step 1: I fired (who had been for the past ten years) my dental assistant.

All management books advise us to not take this action since the people of our companies are considered as a worthy asset for our business. Yes, but after such a long cooperation she was in a permanent comfort zone. I would have to accept unnecessary behaviours and actions if I would have decided to keep her in the flow and progress of the clinic.

First Evaluation/Assessment of Step 1:

Compulsory but welcome! Meanwhile, the recep-

tionist offered me to increase her duties in order for her to assist me at dental care procedure. Despite the crisis, not only did I not reduce her salary but after two months I gave her an increase for thanking her willingness and promptness in action!

Second Evaluation of Step 1:

People who do not follow the flow should leave. Remaining with us should talents only!

_Step 2: Change suppliers!

Our management books suggest negotiating with our suppliers in order to obtain materials for better prices or increase the credit period. In our case, this was not only impossible (since the number of suppliers shrank immediately and the small-sized disappeared from the market), but the prices were skyrocketing. In order to get the products, I had to pay cash on delivery. If, for some reason, I did not pay immediately (either due to my absence in this time or due to being with a patient), they took their products back with them. It took a two-day-trip to one of the most popular dental exhibitions and some empty suitcases that were filled with the same consumables purchased at that time and the prices there don't even let me get started...I needed to further stick on this issue. Soon afterwards we made a big order at the manufacturing companies of our dental products (I am not talking about all dental products of course, but at least 75 per cent of them).

Evaluation of Step 2:

Our decision of changing suppliers gave us the opportunity to minimize our costs and release some ten-

sion and pressure which was not needed at this moment.

Step 3: Negotiating instalments of loans!

One of my personal principles has always been to pay my loan instalments on time. This had to change immediately. After a tough negotiation with my banker, we agreed to freeze the loan instalments for the first six months and for the then following six months to pay half of the previously agreed amount.

Evaluation of Step 3:

Taking the above measure was necessary. We had to win time and twelve months were more than sufficient!

Step 4: Strategist Porters beliefs reversed!

After my studies in management (MBA), I followed the strategic plan of Porter concerning the management of my dental centre. The famous strategist Porter had a clear point on business by saying that one must be in the position of a dental practice which is known for either its diversity or its cheapest dental services in the market—never both strategies at the same time and “never stick in the middle”.

The strategy I followed since the beginning of my dental practice was the strategy of differentiation and diversity. I cannot hide the fact that I was tempted to reduce, like many of my colleagues did, the prices of treatments. I know it would worsen things more. Imagine the impact a price reduction would have in conjunction with the shrinking number of patients.

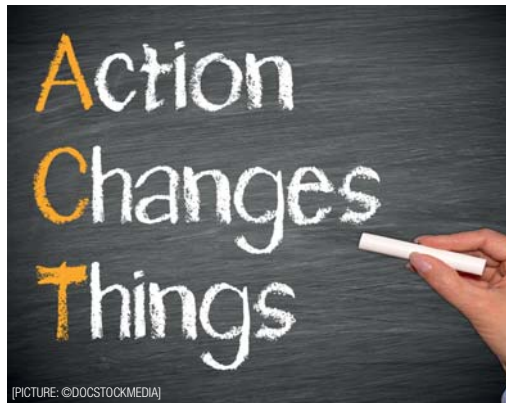What we did was to go against the teachings of Porter. We continued to offer high quality treatments without lowering prices and simply choose one treatment which our practice due to circumstances had no demand for (bleaching, in particular) and offered this for the lowest price in the market.

Evaluation of Step 4:

Because of the high demand of this particular service amongst others, we managed to increase the number of new patients by 200 per cent compared to the years before crisis. By getting to know us through this low cost treatment, people gave us the opportunity to introduce them to other treatments which they may be interested in.

Step 5: Changing our philosophy!

For years, the philosophy of my dentistry was to take care of dental patients by providing high quality



(PICTURE: ©DOCKSTOCKMEDIA)

services. I had to change! By matching my own philosophy with the trend of modern people, we now inform our patients about the interrelationship of oral and general health.

Evaluation of Step 5:

Create conscious patients with a recognition and respect for their dentist as doctor that truly cares for their health across its wide spectrum.

Step 6: Saying goodbye to my comfort zone!

For five years now, I was thinking how much I would love to create an educational programme for dentists and dental field professionals only that is concerned with the entire spectrum of management of a dental clinic—a mini MBA—in cooperation with a world-class educational and research centre. After years of debating without any tangible result, I decided that “it’s either now or never”. I travelled to Aachen three times to organise everything and in May 2014 my dream course was launched!

One year after I have started to change my professional situation, the economic situation of my country is not as tragic as in the first six months. We certainly have still a long way to go but at least I feel that my professional life, disobeying strategists and theories, is in my hands again!_

_contact

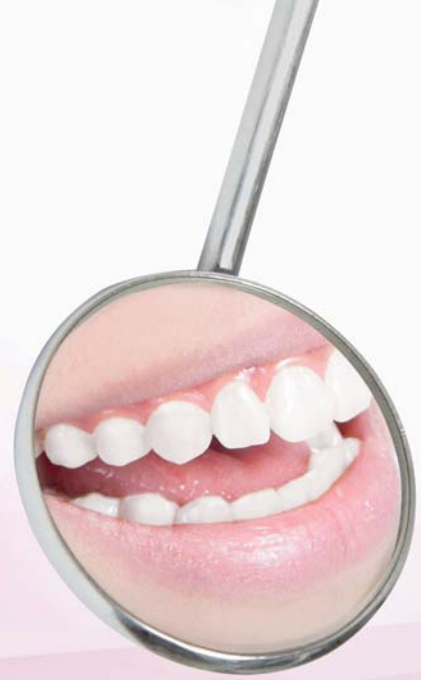laser



Dr Anna Maria Yiannikos

Adjunct Faculty Member of AALZ at RWTH Aachen University Campus, Germany
DDS, LSO, MSc, MBA

dba@yiannikosdental.com
www.dba-aalz.com
www.yiannikosdental.com



Laser application in dental surgery: CO₂ laser for soft tissues

For some years now, laser devices have been facilitating dental treatment procedures—ensuring a quick, precise and almost bleeding-free intervention. Nevertheless, there are still some questions every practitioner is faced with. Which laser is suitable for which treatment? Is a laser a valuable investment in the dental practice? Where is a laser therapy superior to conventional treatment methods? In the present interview, laser addressed some questions to Prof. Dr Michael Bornstein from the University of Bern, who is working in the Department of Oral Surgery and Stomatology and thus is an expert in the field of laser surgery.



Prof. Dr Michael Bornstein

Prof. Dr Bornstein, which type of laser would you recommend for surgical treatment and for which reasons?

First, we need to define the type of surgery. Surgical interventions in hard tissues such as bone are quite different from procedures in the oral mucosa. In our oral medicine service, the CO₂ laser is the laser we use most often. Only rarely, we use diode or Er:YAG lasers, usually for research purposes. The CO₂ laser is ideal for incisional and excisional biopsies of the oral mucosa since it offers good hemostasis and thus an optimal visibility of the surgical field, which is critical for many interventions. Nevertheless, the thermal damage to the excised tissues is limited, and can even be reduced further by choosing the optimal mode of the laser. This is also a crucial issue, as the physical side effects should be kept to a minimum when excising suspicious or precancerous soft tissue lesions for optimal histopathological evaluation.

Where do you see the advantages of the CO₂ laser application?

In dental medicine, the CO₂ laser is by far the laser that has been tested and studied the most. By choosing this laser for soft tissue applications, it is certainly a safe choice and based on solid evidence. Nevertheless, when I am speaking about advantages over the scalpel, these have not been tested in randomised controlled trials (RCTs) to date. Therefore, advantages such as better wound healing properties, less pain during or after interventions and faster duration of surgical procedures remain hypothetical. This



[PICTURES: ©ASLYSUN, FOX_INDUSTRY]

Why is the use of laser in the field of soft tissue treatment superior to conventional forms of therapy?

As I have already mentioned above, although the CO₂ laser is a very safe and well documented device, we still need further data for the direct comparison between conventional surgical techniques (e.g. scalpel) and the CO₂ laser. From RCTs only, we can learn about evidence-based advantages and clear benefits which arise from the use of laser in oral soft tissue applications. Until then, many reported advantages of the CO₂ laser still remain expert opinions or hypotheses.

Can you describe a recent case example of your practice in which the CO₂ laser has been used?

The CO₂ laser is used almost on a daily basis. The last two interventions were an excisional biopsy of a suspicious mass in the left buccal plane, which turned out to be a mucocele, and a vestibuloplasty with excision of various fibrous hyperplasias in an edentulous patient with an ill-fitting upper denture.

Why is the CO₂ laser not yet used more often in dental surgery?

Again, we are in urgent need for good clinical research that will convince dental practitioners to use the laser more often for evidence-based indications. It is time to move on from expert opinions about the potential benefits and applications to well-designed investigations that analyse the potentials and limitations of lasers in all aspects of dental medicine. In this regard, laser dentistry is still in the stages that oral implantology was about three decades ago. Only with the introduction of evidence-based concepts, oral implantology has become so successful, and is now an integral part of everyday dental care. We should make sure that oral laser dental medicine will also follow these pathways.

Thank you very much for the interview.

is exactly why we currently run a large clinical trial comparing different laser types, including the CO₂ laser, for excisional biopsies to the scalpel.

Where does the CO₂ laser reach its limits?

The CO₂ laser has limitations for lesions that are located in deeper areas of the tissues. There, we sometimes combine scalpel and laser use for an optimal surgical approach. Also, the hemostatic effect of the laser has its limits. Therefore, we often combine the laser with a bipolar for more extended interventions and in case of an arterial bleeding. Last but not least, also pain experience is very subjective. Some patients complain about substantial discomfort due to the extended wound surfaces after excisional biopsies of for example oral leukoplakia.

Fig. 1 Patient with suspected oral leukoplakia before excisional biopsies.

Fig. 2 Situation after excisional biopsies with CO₂ laser.

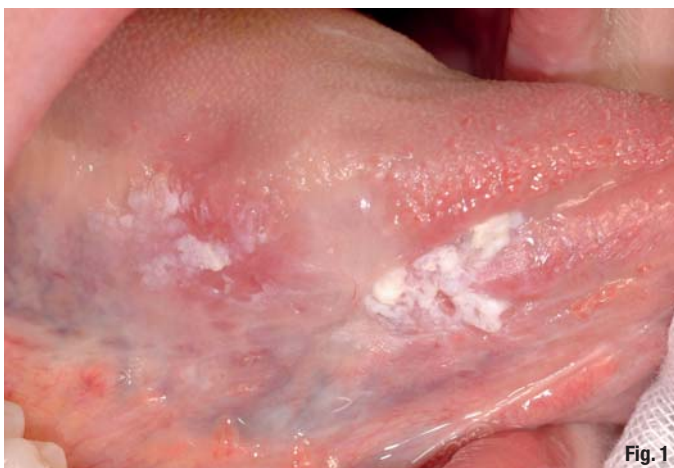

Fig. 1

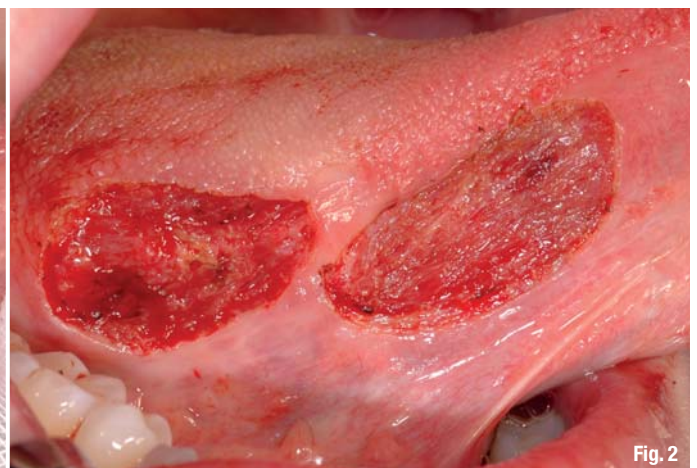
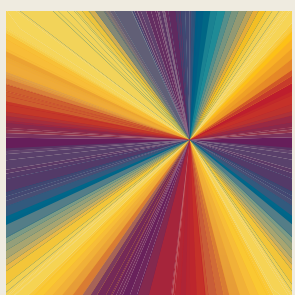


Fig. 2

Düsseldorf— Beauty on the Rhine

Author: Katrin Maiterth



dgl. Deutsche
Gesellschaft für
laser
Zahnheilkunde e.V.

_"Düsseldorf mäkt sech fein" (Düsseldorf adorns itself)—this phrase does not only apply for the fifth season—carnival season—which is intensively celebrated in the Rhine metropolis. No matter if it is spring, summer, autumn or winter: With its fine range of arts and culture, noble restaurants and traditional pubs, first-class architecture as well as wide streets and places, the city is always worth a visit. On the 26 to 27 September, the metropolis at the Rhine is hosting the 23rd Annual Congress of the DGL and LASER START UP 2014.

The medieval Dusseldorp was first mentioned in the 12th century. What is for sure is that Dusseldorp received municipal rights in 1288. With the establishment of fixed market days, trading started in the Rhine city and thus the cultural as well as economic wealth. After the building of Carlstadt in the beginning of the 18th century, the Carlsplatz became the location for the one-week market which was carried out four times a year. Today, the marketplace is still in use six days a week throughout the year and offers fruits, vegetables, eggs, meat, poultry, fish and baked goods as well as the traditional potato fritter with applesauce.

Next to Carlstadt is the Old Town—with over 260 pubs also known as "the longest bar in the world". Here, everyone finds a suitable locality: house brewery, lounge, cocktail bar, electro club or fine restaurant. However, there is no getting around the traditional Düsseldorf dark beer. Everyone who wants to learn more about the high art of brewing is welcomed to set out on the brewery path. Even elector Jan Wellem (1658–1716), whose bronze equestrian statue stands on the marketplace in front of the town hall, tipped with the Düsseldorf citizens in the house "En de Canon". Today, the restaurant invites to its delicious good plain German cooking, like Königsberg meatballs, Düsseldorf mustard roast or "Canon fooder" as medallions of pork is referred to. During a gregariously guided tour through the Old Town one will not only learn about the famous dark beer, which is brewed due to old purity law, but also about the most important sights in this historic part of the city.

Along the Old Town's front line, the Rhine promenade reaches over 1.5 km, from the Oberkasseler bridge to the state parliament. The promenade was



26. to 27. September 2014
Düsseldorf
Hilton Hotel

**LASER
START UP
2014**



**23rd
Annual Congress
of the DGL e.V.**



[PICTURE: ©SCIROCCO340]



[PICTURE: ©DANIEL LEPPENS]

built between 1990 and 1997. What had been a busy street with much traffic for decades is a vivid boulevard today. The lowering of the Rheinuferstraße and the building of the promenade on top of the tunnel has brought the citizens closer to the water again, because what are Düsseldorf and its citizens without the Rhine! Especially in the summer, the Mediterranean-like lifestyle of the people finds its expression here. From one of the countless cafés and bars bordering the promenade one can watch the passing by Rhine ships without ruffle. These do not only transport commercial goods, but also offer space for sightseeing, events and recreation.


After an extensive walk along the Rhine, it is always worthwhile to visit the Media Harbour which is a centre of modern architecture and unique working conditions. Within a few years, the former harbour warehouses have evolved to individual company locations and innovative office areas. The "avenue of architecture" presents itself as modern and flexible: during the day, employees of the nearby companies are served golden bratwurst at the "Curry", in the evening party people are offered cocktails.

Another good place to stroll around is the "Kö" as Düsseldorf's citizens name their Königsallee lovingly. The world-famous luxury street is a catwalk and resting place at the same time—true to the motto "seeing and being seen". Boutiques, jewellers, shopping malls and stores invite to watch, try and buy; there is also the possibility to hire a personal consultant for the perfect shopping trip. Rest can be found in one of the luxury street's cafés. A specific characteristic is the Kö's water moat, which separates one side of the alley from the other. Artfully designed bridges with richly ornamented fountains and sculptures built a connection between the two sides and simultaneously give the luxury mile a romantic flair.

At any time of the year, the Düsseldorf citizens know how to adorn themselves and their city—whether in the Kö, the Old City or along the Rhine. Convince yourself!_

14th WFLD World Congress: The ever increasing use of laser in dentistry

Author_Aldo Brugnera Jr



PICTURE: ©MIKOV KALININ



The 14th WFLD World Congress took place in Paris on 2 to 4 July at the Maison de La Chimie in partnership with the Oral Implantology World Congress. The 2nd WFLD World Congress had already taken place in Paris in 1990, organised by Prof. Jaques Melcer. 24 years later, it was evident how much laser in dentistry has improved and developed in the Paris WFLD Congress 2014.

A satisfaction survey was taken among participants and the quality of invited speakers, oral presentations, poster presentations, environment and organisation in general were very positively as-

essed. The innovative subjects and topics were highlighted, since they showed the new approaches of phototherapy in dentistry as well as the prize received by five researchers and their teams in the poster session.

The ever increasing use of laser was evidenced by the presence of dozens of researchers from over 20 universities from the five continents where WFLD Divisions are present. Thereby, Brazil had the largest delegation with 37 participants, who had a remarkable participation presenting several researches of the clinical use of laser. Among them, two re-

[PICTURE: ©M_PHOTO]



[PICTURE: ©LUCIANO MORTULA]



searches stood out: The first was Prof. Marcia Marques' studies using laser therapy for stem cell biomodulation and the second Prof. Bagnato's using fluorescence in the diagnosis of bucal lesions.

As WFLD President, I was honoured by the compliments on the scientific programme and the presence of renowned professors and members of the Board as S. Namour (Belgium), N. Gutknecht (Germany), K. Yoshida (Japan), A. Stabholz (Israel), A. Chan (Australia), J. Arnabat (Spain), M. Marchesan (USA), T. Zeinoun (Lebanon), C. Eduardo (Brazil), J. Rocca (France) and many other respected researchers.

The basic course of Laser in Dentistry had over 60 participants who are interested in introducing laser therapy in their dental practice. WFLD's mission, which is to disseminate laser science, was definitely accomplished. I hereby thank of all of you as well as the WFLD General Assembly for indicating my name for re-election. I am waiting for all of those interested to be at the WFLD Division Congress in Brazil from 22 to 25 January, 2015, and at the WFLD World Congress in Japan, 2016. For more information, please visit our site:

www.wfldlaser.com

AMD LASERS founder

Buys back company from DENTSPLY



AMD Group LLC and its founder and president, Alan Miller, recently announced the purchase of AMD LASERS from DENTSPLY International. The sale was effective on 1st August. Miller launched AMD (Alan Miller Designs) with the Picasso laser in 2009. The company rapidly grew and was purchased by DENTSPLY in 2011, expanding its product distribution network around the world.

“Over the past five years Picasso laser technology has been loved, celebrated and endorsed by clinicians, hygienists, universities, hospitals, dental clinics and patients around the world,” the company said in a press release announcing the sale.

“Picasso laser technology has won numerous industry awards, while Alan Miller and AMD LASERS

have also been recognized by non-dental associations for innovation, design, technology and company growth.”

Miller expressed the company’s thoughts on this organisational change. “This is a great outcome for our customers and our company,” he said. “In taking AMD LASERS private again, we can go back to our roots, focusing on the entrepreneurial spirit that made AMD LASERS one of the fastest growing and most successful companies in the dental laser industry.”

“DENTSPLY is a fantastic company with some of the most talented people I have ever met,” Miller said. “They did a great job converting AMD into a very sophisticated operating company, and I couldn’t thank them enough for furthering the interest in dental lasers.”

“Quality, value, and support set AMD LASERS and its product offering apart from the competition,” the press release continued. “This is a testament to the company’s commitment to providing not only the best dental lasers but also the education, service and support that the dental profession rightfully demands and expects.”

India targets fluorosis problem with

New identification system

The Indian Council of Medical Research (ICMR) in New Delhi has said that it has tested a new and simpler system that could help to identify dental fluorosis in the population. The tool is based on photographic information from patients with the conditions gathered from several districts in India, and can be used by health workers without prior knowledge in dentistry.

First tests conducted with the new system by an ICMR Task Force among schoolchildren in the South Delhi and Hissar districts turned out successful, with little difference found in regard to detection rates of dental specialists and field workers unfamiliar with fluorosis, the Council said. With this tool, the organisation hopes not only to help health workers nationwide to detect the condition in its early stages but also to gather reliable national data on the prevalence of fluorosis, which is considered to be a major public health problem owing to the excessive intake of fluoride through drinking water in most parts of India.



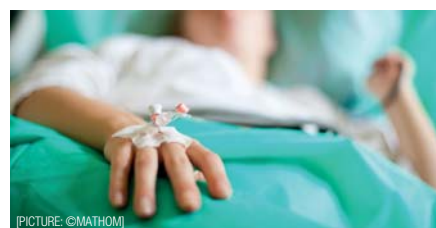(PICTURE: ©V.S.ANANDHAKRISHNA)

Although representative data in the country is lacking, results from different studies suggest a high prevalence in areas with high water fluoridation. If the condition is not detected, it can lead to skeletal fluorosis, a disease that causes bone to lose its flexibility through the accumulation of osseous tissue. It has also been associated with renal failure, atherosclerosis and other health problems.

Anaesthetised patient

Falls and dies in dental practice

In a dental office in Düsseldorf, a patient died after a tragic fall. The 45-year-old woman, who had been treated under anaesthesia owing to a mental disability, woke up dizzy in the recovery room and accidentally slammed her head against an aquarium. Still under the influence of the aesthetic, the patient apparently stumbled and hit her head against the aquarium with such a tremendous force that it burst. A shard of glass severed the woman’s carotid artery and she subsequently bled to death within a short period. The police, who began their investigation straight away, have declared the case “a tragic accident”. Practice staff was given counselling by emergency chaplains.

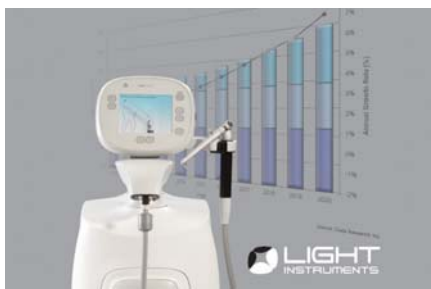

(PICTURE: ©MATHOMJ)

Analysts predict Light Instruments' dental laser

Outstanding market domination in the European market

Light Instruments Ltd., commercially known as "Syneron Dental Lasers" (www.synerondental.com), provider of innovative hard and soft tissue dental laser technology, has been predicted by iData to become the leading brand for All-Tissue dental lasers category in the European market by 2020. iData Research (www.idataresearch.com) is the leading global authority in medical device market reports for the health-care market. The Research Group provides Competitive Analysis in the medical device industry and is positioned among the leading analysts delivering strategic intelligence for the dental market. In its November market analysis, iData distinguished the hard and soft dental laser market into three categories each representing a different generation of laser energy delivery system: optic fibres, articulated arm and the Direct Delivery technology, accentuating the importance of the technology physiognomies in the field competition. According to the Research Group, in terms of ease-of-use, cutting power and portability, the Direct Delivery



Technology incorporated in the LiteTouch™ dental laser (introduced back in 2007 by Light Instruments Ltd.) is a new generation technology and expected to gain market leadership in the All Tissue Lasers category over the forecast period. The direct delivery laser provides ergonomic elasticity with a powerful, yet delicate energies spectrum, capable of easily cutting both enamel and bone tissues. This advantage is expected to prove critical in making this technology the preferred lasers of the future.

Little progress in

Highly skilled labour migration

A number of mutual recognition arrangements concerning various industries have been signed between ASEAN member states in recent years with the goal of stimulating and regulating the migration of highly skilled professionals like dentists. A new report released by both the International Labour Organization and the Asian Development Bank in Jakarta indicates that, despite the improved framework, labour mobility in these industries has not progressed much. The main obstacles to the implementation of the arrangements remain different systems of education and professional recognition, the report states. It also suggests that some countries still favour filling certain positions with native labour rather than professionals from abroad. Language, culture and social acceptance appear to be further barriers to foreigners seeking to occupy high-skill posts in another country.

Multinational mutual recognition arrangements between ASEAN members exist for a number of occupations, including engineers, architects, accountants and nurses. An agreement regulating the migration and foreign employment of dentists was signed by



ten ASEAN member states in 2009. According to the report, highly skilled workers are estimated to constitute only one per cent of the workforce in the entire ASEAN region. Combined with the lack of mobility, it predicts that they will not be able to satisfy demand, which is expected to grow by 41 per cent, or 14 million additional jobs, owing to the introduction of the ASEAN Economic Community (AEC).

Intended to establish a single regional market and to foster economic development, the AEC is anticipated to be fully established by the end of 2015.

Jeffrey M. Nugent becomes

New president and CEO of BIOLASE

US dental laser specialist BIOLASE has announced that the company's board of directors has appointed Jeffrey M. Nugent as its new president and CEO. He assumed the position as interim CEO in June this year, after Federico Pignatelli had resigned from his roles as chairman and CEO. According to the company, Nugent will be focusing on expanding BIOLASE's global leadership in dental lasers.

Paul N. Clark, chairman of the board, stated that Nugent has already had a positive impact on BIOLASE during his short term as interim CEO. In order to drive the company's growth and turnaround strat-



egy, he established the Global Commercialization Team in August and hired two seasoned executives to lead the sales and marketing division.

Nugent has broad experience in the medical device, medical laser technology and dental industries. Throughout his professional career, he has worked in chief executive positions of well-known companies, including cosmetic companies, such as Revlon and Neutrogena Corporation; and pharmaceutical and consumer goods manufacturer Johnson & Johnson, where he also led the company's dental business.

laser

international magazine of laser dentistry



Publisher

Torsten R. Oemus
oemus@oemus-media.de

CEO

Ingolf Döbbecke
doebbecke@oemus-media.de

Members of the Board

Jürgen Isbaner
isbaner@oemus-media.de

Lutz V. Hiller
hiller@oemus-media.de

Editor in Chief

Norbert Gutknecht
ngutknecht@ukaachen.de

Coaditors in Chief

Samir Nammour
Jean Paul Rocca

Managing Editors

Georg Bach
Leon Vanweersch

Division Editors

Matthias Frentzen
European Division

George Romanos
North America Division

Carlos de Paula Eduardo
South America Division

Toni Zeinoun
Middle East & Africa Division

Loh Hong Sai
Asia & Pacific Division

Senior Editors

Aldo Brugneira Junior
Yoshimitsu Abiko
Lynn Powell
John Featherstone
Adam Stabholz
Jan Tuner
Anton Sculean

Editorial Board

Marcia Martins Marques, Leonardo Silberman, Emina Ibrahim, Igor Cernavin, Daniel Heyselaer, Roeland de Moor, Julia Kamenova, T. Dostalova, Christliebe Pasini, Peter Steen Hansen, Aisha Sultan, Ahmed A Hassan, Marita Luomanen, Patrick Maher, Marie France Bertrand, Frederic Gaultier, Antonis Kallis, Dimitris Strakas, Kenneth Luk, Mukul Jain, Reza Fekrazad, Sharonit Sahar-Helft, Lajos Gaspar, Paolo Vescovi, Marina Vitale, Carlo Fornaini, Kenji Yoshida, Hideaki Suda, Ki-Suk Kim, Liang Ling Seow, Shaymant Singh Makhan, Enrique Trevino, Ahmed Kabir, Blanca de Grande, José Correia de Campos, Carmen Todea, Saleh Ghabban Stephen Hsu, Antoni Espana Tost, Josep Arnabat, Ahmed Abdullah, Boris Gaspirc, Peter Fahlstedt, Claes Larsson, Michel Vock, Hsin-Cheng Liu, Sajee Sattayut, Ferda Tasar, Sevil Gurgan, Cem Sener, Christopher Mercer, Valentin Preve, Ali Obeidi, Anna-Maria Yannikou, Suchetan Pradhan, Ryan Seto, Joyce Fong, Ingmar Ingenegeren, Peter Kleemann, Iris Brader, Masoud Mojahedi, Gerd Volland, Gabriele Schindler, Ralf Borchers, Stefan Grümer, Joachim Schiffer, Detlef Klotz, Herbert Deppe, Friedrich Lampert, Jörg Meister, Rene Franzen, Andreas Braun, Sabine Sennhenn-Kirchner, Siegfried Jänicke, Olaf Oberhofer, Thorsten Kleinert

Editorial Office

Georg Isbaner
g.isbaner@oemus-media.de

Claudia Jahn
c.jahn@oemus-media.de

Katrin Maiterth
k.maiterth@oemus-media.de

Executive Producer

Gernot Meyer
meyer@oemus-media.de

Designer

Sarah Fuhrmann
s.fuhrmann@oemus-media.de

Customer Service

Marius Mezger
m.mezger@oemus-media.de

Published by

OEMUS MEDIA AG
Holbeinstraße 29
04229 Leipzig, Germany
Tel.: +49 341 48474-0
Fax: +49 341 48474-290
kontakt@oemus-media.de
www.oemus.com

Printed by

Silber Druck oHG
Am Waldstrauch 1
34266 Niestetal, Germany

laser international magazine of laser dentistry is published in cooperation with the World Federation for Laser Dentistry (WFLD).

WFLD Headquarters

University of Aachen Medical Faculty
Clinic of Conservative Dentistry
Pauwelsstr. 30, 52074 Aachen, Germany
Tel.: +49 241 808964
Fax: +49 241 803389644
ngutknecht@ukaachen.de
www.wfld-org.info

www.laser-magazine.com

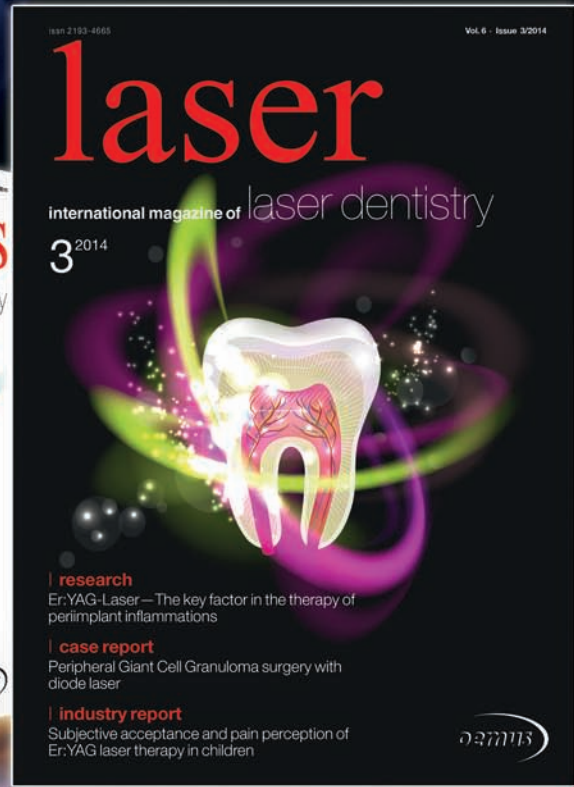

Copyright Regulations

laser international magazine of laser dentistry is published by OEMUS MEDIA AG and will appear in 2014 with one issue every quarter. The magazine and all articles and illustrations therein are protected by copyright. Any utilization without the prior consent of editor and publisher is inadmissible and liable to prosecution. This applies in particular to duplicate copies, translations, microfilms, and storage and processing in electronic systems.

Reproductions, including extracts, may only be made with the permission of the publisher. Given no statement to the contrary, any submissions to the editorial department are understood to be in agreement with a full or partial publishing of said submission. The editorial department reserves the right to check all submitted articles for formal errors and factual authority, and to make amendments if necessary. No responsibility shall be taken for unsolicited books and manuscripts. Articles bearing symbols other than that of the editorial department, or which are distinguished by the name of the author, represent the opinion of the afore-mentioned, and do not have to comply with the views of OEMUS MEDIA AG. Responsibility for such articles shall be borne by the author. Responsibility for advertisements and other specially labeled items shall not be borne by the editorial department. Likewise, no responsibility shall be assumed for information published about associations, companies and commercial markets. All cases of consequential liability arising from inaccurate or faulty representation are excluded. General terms and conditions apply, legal venue is Leipzig, Germany.

laser

international magazine of laser dentistry



Subscribe now!

You can also subscribe via www.oemus.com/abo

I would like to subscribe to **laser** international magazine of laser dentistry (4 issues per year) for € 44 including shipping and VAT for German customers, € 46 including shipping and VAT for customers outside Germany, unless a written cancellation is sent within 14 days of the receipt of the trial subscription. The subscription will be renewed automatically every year until a written cancellation is sent to OEMUS MEDIA AG, Holbeinstr. 29, 04229 Leipzig, Germany, six weeks prior to the renewal date.

Reply via Fax +49 341 48474-290 to OEMUS MEDIA AG or per E-mail to grasse@oemus-media.de

Last Name, First Name	
Company	
Street	
ZIP/City/County	
E-mail	Signature

Notice of revocation: I am able to revoke the subscription within 14 days after my order by sending a written cancellation to OEMUS MEDIA AG, Holbeinstr. 29, 04229 Leipzig, Germany.

Signature



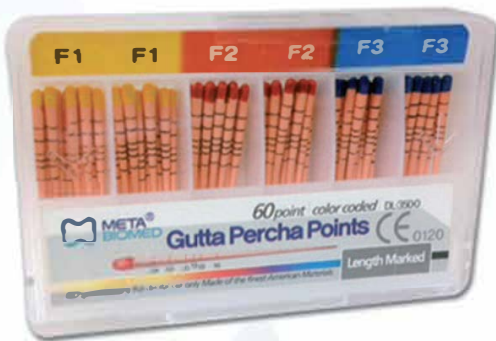Gutta Percha Points
Absorbent Paper Points

گوتا فقط META



کن کاغذی

- استریل
- جذب عالی بدون لینت
- موجود در انواع سایز ها
- در بسته بندی ۲۰۰ عددی کشویی ضد ریزش



- دارای انواع سایز های مدرج و با شیب ۰.۲ - ۰.۴ - ۰.۶ - ۰.۸
- رادیو اپسیتی عالی
- مناسب برای پر کردن کانال به روش تراکم جانبی و عمودی
- ۱۲۰ عددی با بهترین بسته بندی برای کاربری آسان
- انعطاف پذیری بسیار مناسب در حین کار
- زمان ماندگاری طولانی مدت



Available Sizes

- ISO sizes : 10, 15, 20, 25, 30, 35, 40, 45, 50, 55, 60, 70, 80, 90, 100, 110, 120, 130, 140
- Non-Standardized (Accessory sizes): XF, FF, MF, F, FM, M, ML, L, XL
- Special Taper Points : .04, .06, .08

Tel: +98 21 88 98 80 63 - 6

Fax: +98 21 88 98 75 72

www.azadmed.com

info@azadmed.com

Add: Ava Building (No 34) Kaj St, Fatemi Ave, Tehran, Iran