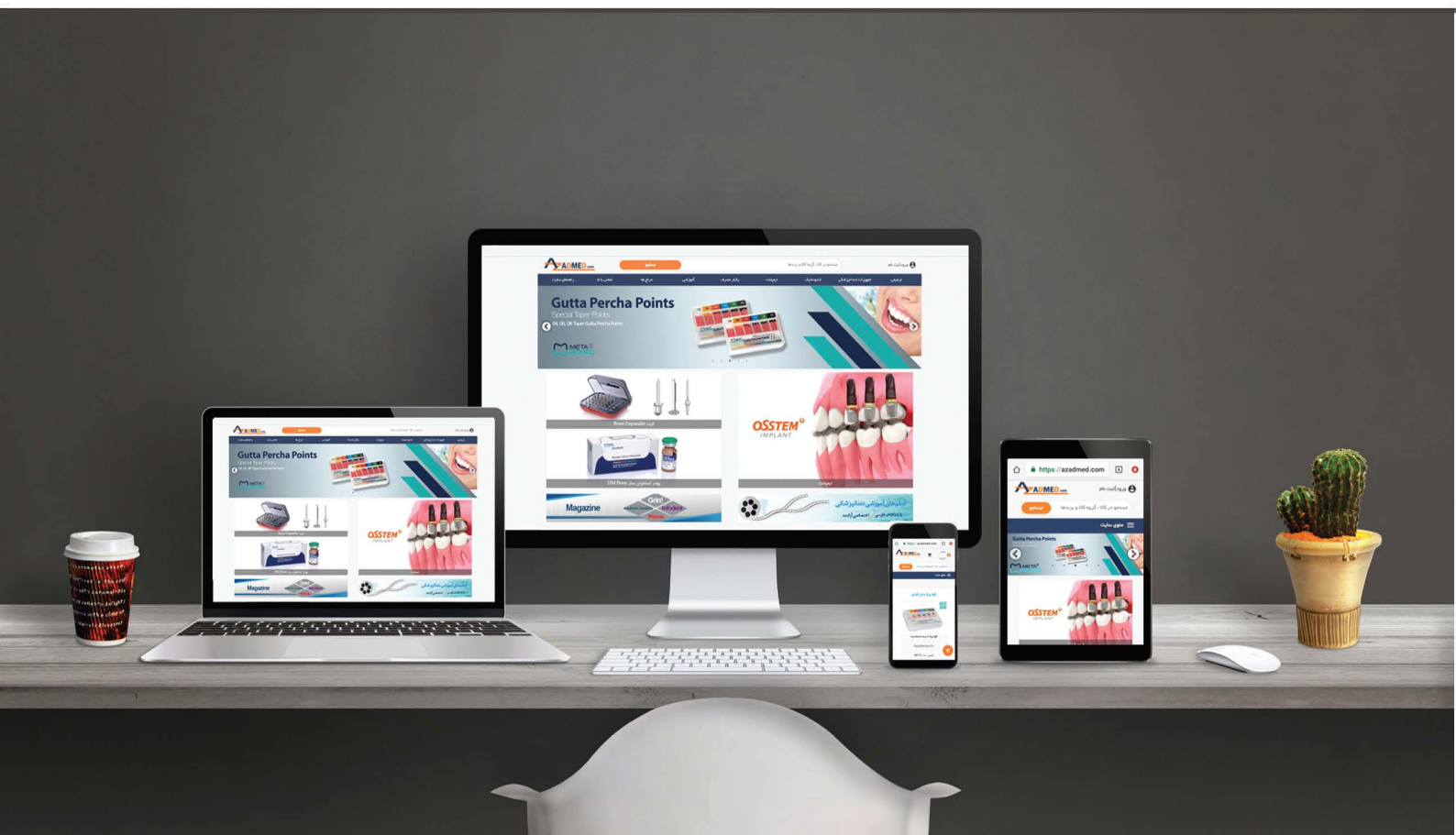

[www.azadmed.com](http://www.azadmed.com)



 azaadtejaratpars

 @azadmed2

 88 98 80 63 - 6

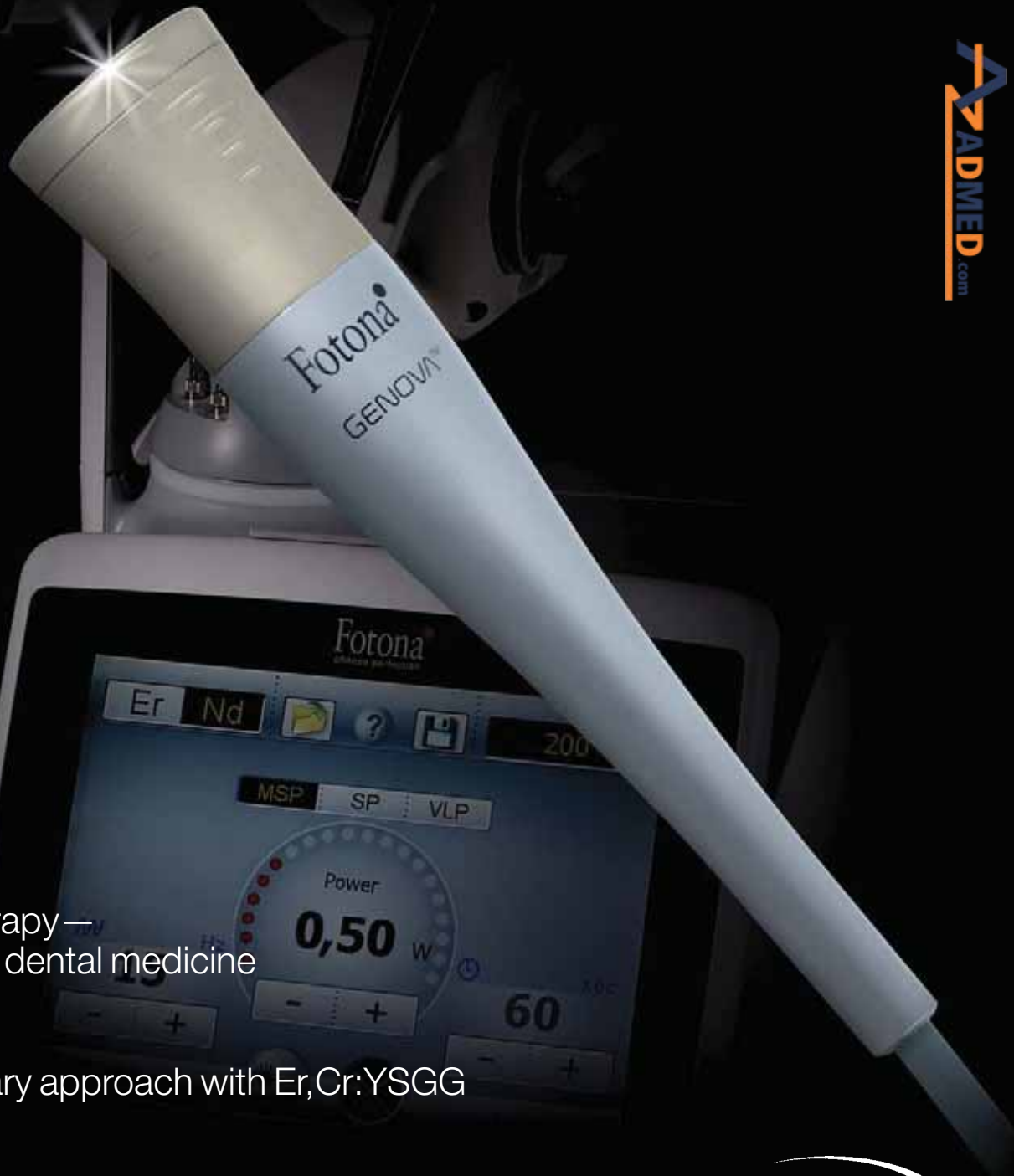# laser



international magazine of laser dentistry

4<sup>2015</sup>

ADMED.com



| **research**

Laser phototherapy —  
an expansion of dental medicine

| **case report**

A multidisciplinary approach with Er,Cr:YSGG

| **industry**

SIROLaser Blue — Three wavelenghts with one  
single device



# WFLD 2016



## The 15th Congress of the World Federation for Laser Dentistry

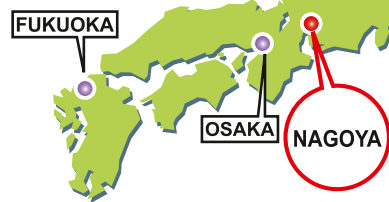
*Light to brighten the future*

in collaboration with:

The 28th Annual Meeting of  
Japanese Society for  
Laser Dentistry



**July 17(Sun)-19(Tue), 2016**  
**Nagoya, Japan**



### Venue

**Aichi Industry & Labor Center  
(WINC AICHI)**

### Chairperson

**Kenji Yoshida, D.D.S., PH.D.**  
Department of Oral & Maxillofacial Surgery,  
School of Dentistry Aichi-Gakuin University

### Secretariat

WFLD 2016 Secretariat  
c/o Convention Linkage, Inc.  
Asahiseimei Bldg., 3-32-20 Sakae, Naka-ku,  
Nagoya 460-0008, Japan  
Phone: +81-52-262-5070 Fax: +81-52-262-5084  
E-mail: wfld2016@c-linkage.co.jp

<http://www.c-linkage.co.jp/wfld2016/>

# Laser on the **rise**



Prof. Dr. Norbert Gutknecht  
Editor-in-Chief

Dear colleagues and fellow DGL members,

After years of stagnation, all signs point to a significant revival of the laser market. This became obvious during this year's DGL Congress, as visitor numbers have doubled compared to last year's event and scientific contributions covered a broad spectre of topics and various wavelengths. For instance, wavelengths of 450 nm were rediscovered, which 20 years ago featured argon lasers exclusively and today is represented by modern diode-laser technology. The field of CO<sub>2</sub> lasers (1,060 nm), which has been dominating the laser market in the previous years, was not only revived but it has "mutated": A new CO<sub>2</sub> wavelength of 9,300 nm was introduced, which is now applied in dentistry for the first time.

This development also had an effect on the diversity of companies present at the congress' dental exhibition, leading to an increased presence of visitors at the exhibition between lectures. A simultaneous interpretation of Friday's speeches made it possible for attendees of more than ten different nations to partake actively in the congress programme as speakers and passively in the auditorium.

My wish for next year is that this trend will continue, especially at the WFLD World Congress in Nagoya/Japan and on the 25<sup>th</sup> Anniversary Congress of the DGL.

The versatility of new wavelengths and wavelength combinations also forms the basis of my manifold good wishes for you, including luck and success, for 2016.

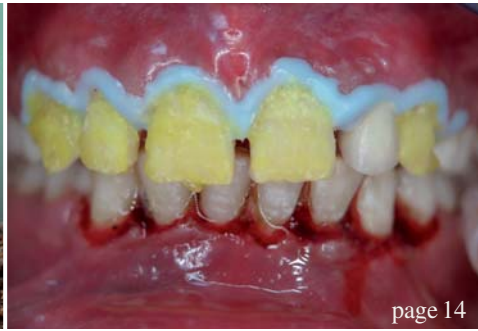Looking forward to seeing you again in the new year,

With warm regards,

Prof. Dr. Norbert Gutknecht  
Editor-in-Chief



page 6



page 14



page 22

| editorial

03 **Laser on the rise**  
| Prof. Dr Norbert Gutknecht

| research

06 **Laser phototherapy—an expansion of dental medicine**  
| Jan Tunér

| case report

10 **Denture Stomatitis: Treatment with Diode Laser**  
| Dr Maziar Mir *et al.*

14 **A multidisciplinary approach with Er,Cr:YSGG—Aesthetic management of hard and soft tissues**  
| Dr Christina Boutsiouki *et al.*

| industry

22 **SIROLaser Blue—Three wavelengths with one single device**  
| Marlene Hartinger

| practice management

26 **Infection control in an era of emerging infectious diseases**  
| Eve Cuny

28 **Laser treatment of sleep apnoea and snoring**  
| Dr Andreas Klug

32 **Eleven tips for success in your dental clinic—Part II: CAPS & CLIMB**  
| Dr Anna Maria Yannikos

| events

35 **24<sup>th</sup> International Annual Congress of the DGL—All on the same wavelength**  
| Lisa Meißner *et al.*

| special

40 **The future today—Ultrashort pulsed laser**  
| Dr Anton Kasenbacher

41 **Die Zukunft in der Gegenwart – Ultrakurzpulslaser**  
| Dr. Anton Kasenbacher

| news

20 **Manufacturer News international**  
38 **News international**

| DGL

43 **Laser im Aufwind**  
| Prof. Dr. Norbert Gutknecht  
48 **News germany**

| about the publisher

50 | imprint



Cover image courtesy of Fotona, [www.fotona.com](http://www.fotona.com)



page 32



page 35



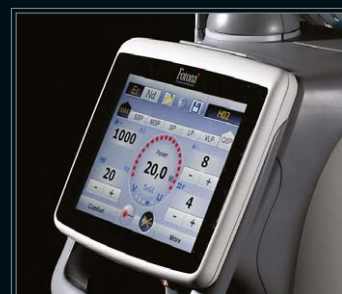page 40

The universe at your fingertips.

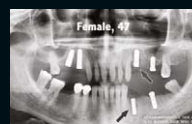
## TwinLight<sup>®</sup> Peri-implantitis Treatment

A simple and effective procedure that offers the power to treat peri-implantitis – an increasing threat to oral health.

- Minimally-invasive technique
- Fast regeneration/healing
- Reduced inflammatory response
- Highly effective treatment
- No antibiotics needed



Peri-implantitis treatment video

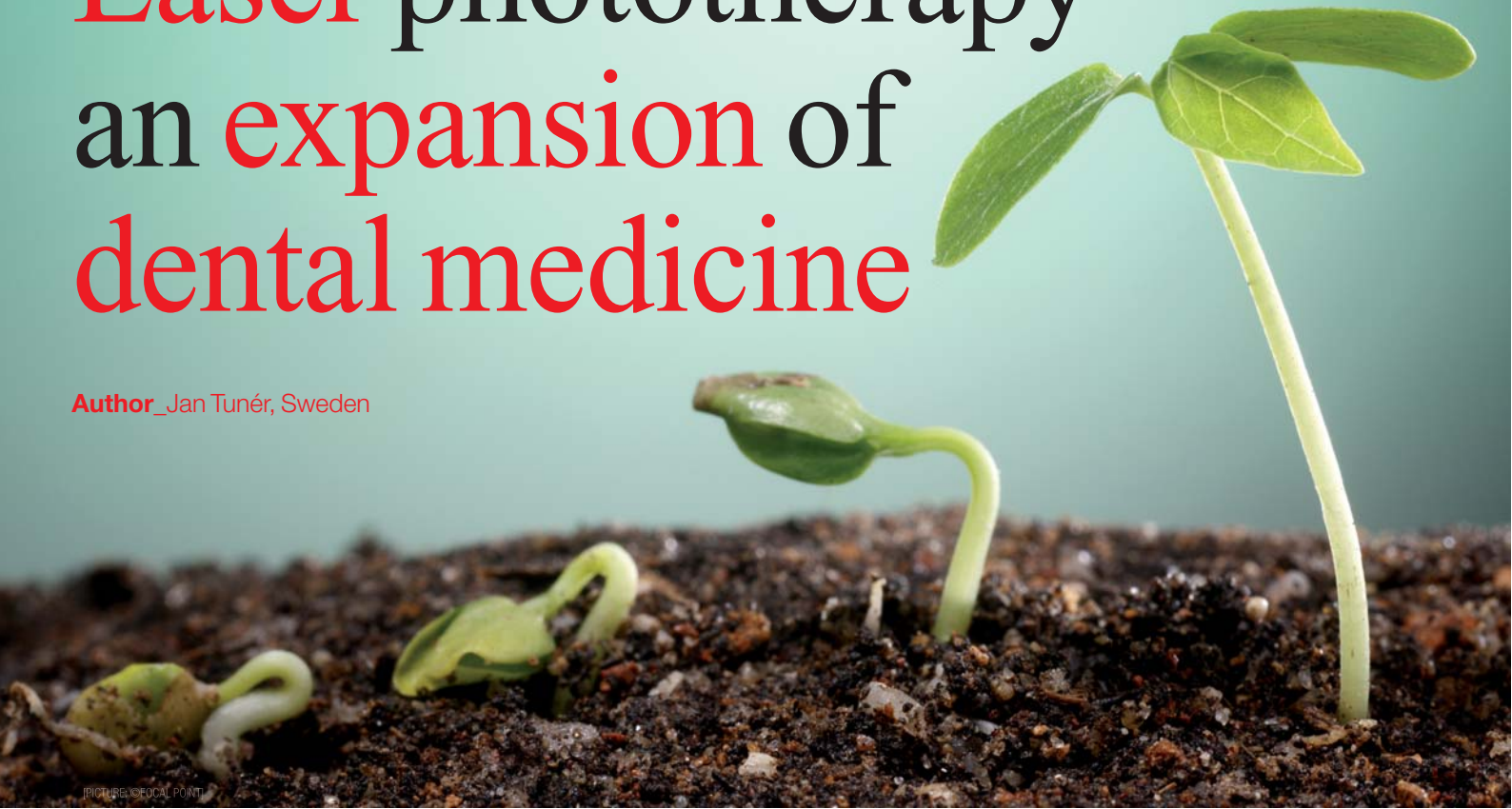


LightWalker<sup>®</sup>

[www.lightwalkerlaser.com](http://www.lightwalkerlaser.com)

# Laser phototherapy— an expansion of dental medicine

Author\_Jan Tunér, Sweden



Laser phototherapy has been used in dentistry for several decades. From an initial attitude of incredulity, there is an increasing awareness of the usefulness of this treatment option. Many indications are now recognised, such as reduction of inflammation, pain and oedema. Having the known basic mechanisms in the cellular energy transport system in mind, the wide variation of suggested applications no longer seems illogical. This article will not linger on what is already known and accepted, but rather make an effort to look ahead onto the most recent discoveries. Laser phototherapy (LPT) has been seen as a

suitable intervention when some sort of pathology is present in tissue. A modern approach is to recognise the ability to pre-condition tissue even before a trauma such as surgery. This is a bit contrary to what we have learned in the past. It is well known that the best cellular response comes from cells in a reduced environment, i.e. with a low pH. More or less healthy cells will not react much to LPT. This is shown in the illustration below (Fig. 1).

Indeed, research has confirmed that LPT is not very useful in studies where healthy animals or human volunteers have been enrolled. For instance, a model using genetically diabetic animals has demonstrated a very positive effect on wound healing, whereas the same parameters in healthy animals has been modest.<sup>1</sup> However, the minimal effect of LPT on fairly healthy tissues seems to be enough to prepare the target tissues for a surgical intervention, as a way of “pre-conditioning” the area. In fact, this was one of the earliest discoveries in the field. McGuff et al. reported already in 1966 that animals exposed to radiation developed less side effects if pre-irradiated with LPT.<sup>2</sup> This effect has later been confirmed in animal and human studies.<sup>3,4</sup> A clinical study by Nesioonpour used preoperative LPT in patients having surgical fix-

Fig. 1 From: Karu T. Ten lectures on basic science of laser phototherapy. 2007, Prima Books.

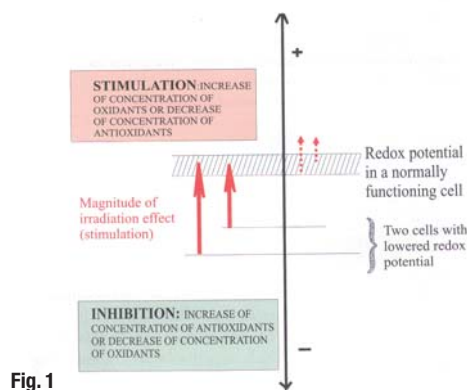


Fig. 1

ation of distal radius fractures.<sup>5</sup> Intravenous regional anaesthesia was used. The need for painkillers was less in patients having LPT immediately before surgery. The study by Santos aimed to evaluate the effects of LPT immediately before tetanic contractions in skeletal muscle fatigue development and possible tissue damage.<sup>6</sup> Optimal doses of LPT significantly delayed the development of skeletal muscle performance and protected skeletal muscle tissue against damage. Thus, it is suggested that LPT could be used prior to surgical intervention to reduce postoperative discomfort.

The fact that LPT can be useful even in healthy tissue was suggested already in 1999 by Schindl.<sup>7</sup> The study showed that patients with recurrent HSV-1 attacks could be successfully treated with LPT even in the "silent" period in-between outbreaks. Dentists could therefore, at advantage, treat known HSV-1 prone patients with LPT even if there is no clinical evidence of an outbreak. The importance of this possibility is underlined by two recent studies where patients with recurrent HSV-1 turned out to have a greater risk of developing Alzheimer's disease later on in life.<sup>8,9</sup> The connection is unknown, but if patients with recurrent HSV-1 are treated with LPT at conventional dental sessions, the risks may be reduced.

Alzheimer's disease is far from dentistry, but certainly there is a connection between the oral cavity and general medicine. A further example is Burning Mouth Syndrome [BMS]. This is in the oral cavity but considered to be a medical problem. LPT has been tried without success in early studies. However, the origin of BMS is unknown. Two more recent studies used high energies and the outcome was successful.<sup>10,11</sup> Thus, the effect behind the pain relieving result appears to be inhibition of axonal flow, as demonstrated by Chow.<sup>12</sup> LPT then could not cure these patients, as with any other therapy, but at least serve as a pain relieving therapy, open for dentists.

Diabetes is another non-dental pathology with a deep impact in dentistry. The laser dentist cannot do anything about the pathology itself, but the advantages of treating the side effects of diabetes are obvious. This is among other things demonstrated in the healing process after surgery and periodontal therapy. An animal study by al-Watban showed that wounds in the genetically diabetic animals healed just as fine as for the non-diabetic animals.<sup>13</sup> The positive effect in periodontal therapy is confirmed by Obradovic.<sup>14</sup> We can therefore expect improved heal-

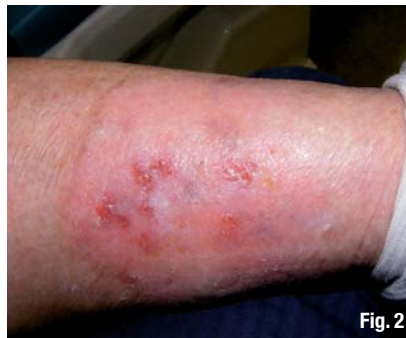

Fig. 2

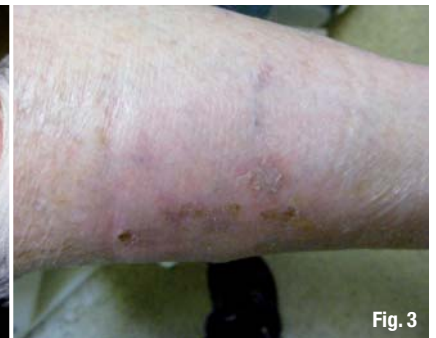

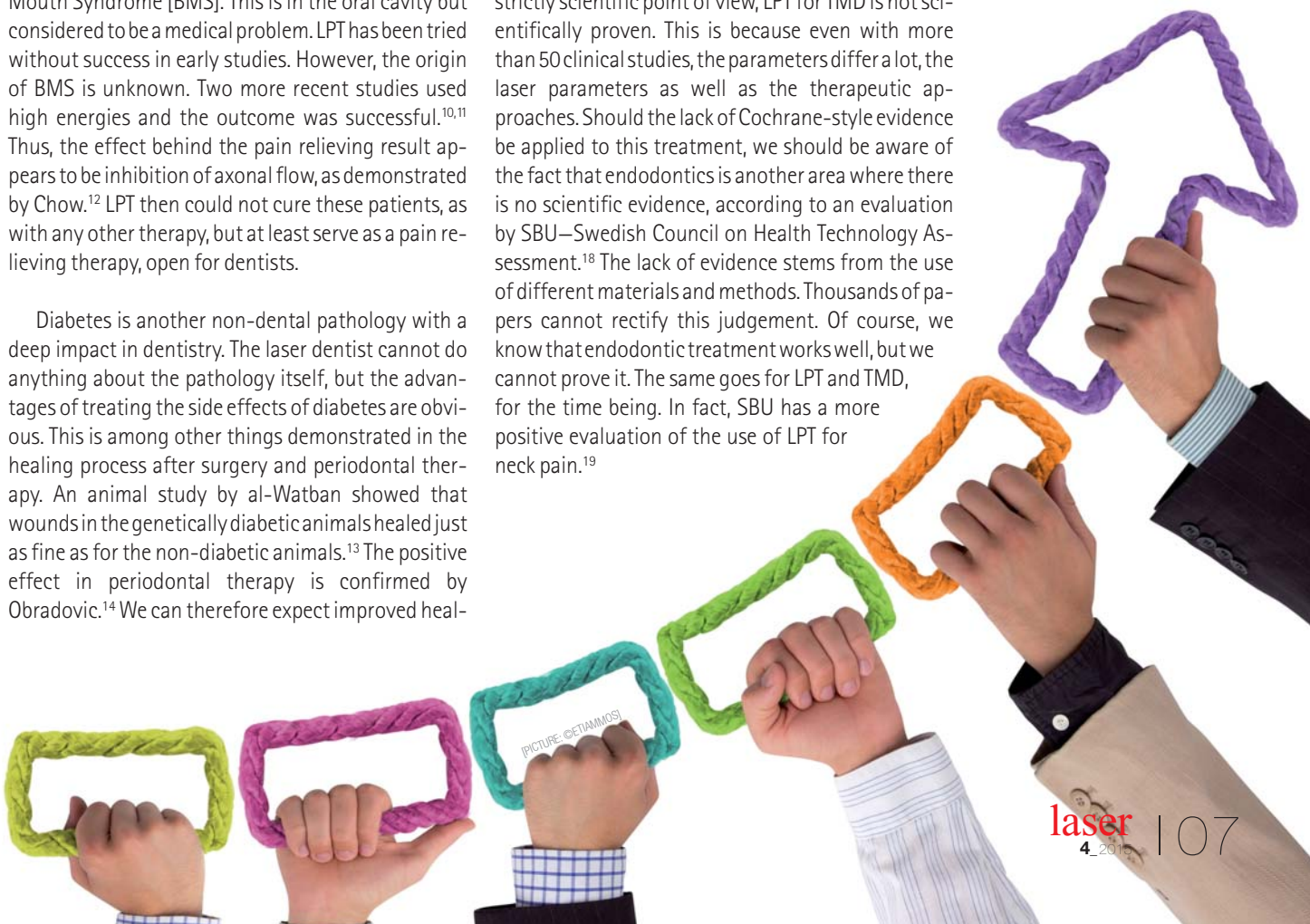Fig. 3

ing after scaling, extraction and minor surgery if LPT as applied in diabetic patients.

Lichen planus is treated by specialists in the dental field and the general dentist often refers these cases to a specialist or to a medical doctor. A recent study by Dillenburg showed a better result from LPT than for the traditional clobetasol.<sup>15</sup> Pemphigus vulgaris is yet another autoimmune condition where steroids can be replaced by LPT.<sup>16,17</sup>

TMD is indeed a dental indication, but being multifactorial, it borders to psychology and medicine. Each profession can do its own part. A more holistic attitude is required to cure some of these patients and the muscular problems are often not only related to the masticatory system but to neck and shoulders as well. A laser dentist can make these areas a dental interest and expand the therapeutic possibilities. From a strictly scientific point of view, LPT for TMD is not scientifically proven. This is because even with more than 50 clinical studies, the parameters differ a lot, the laser parameters as well as the therapeutic approaches. Should the lack of Cochrane-style evidence be applied to this treatment, we should be aware of the fact that endodontics is another area where there is no scientific evidence, according to an evaluation by SBU—Swedish Council on Health Technology Assessment.<sup>18</sup> The lack of evidence stems from the use of different materials and methods. Thousands of papers cannot rectify this judgement. Of course, we know that endodontic treatment works well, but we cannot prove it. The same goes for LPT and TMD, for the time being. In fact, SBU has a more positive evaluation of the use of LPT for neck pain.<sup>19</sup>

**Figs. 2 & 3** Non-healing wound, having been unsuccessfully treated for four months. Initial situation before LPT on January 5 on the right; situation on January 16 on the left. A home care laser device was used.





Dentists on average do not prescribe much NSAIDs and steroids, yet our patients regularly use these pharmaceuticals. They work fine for short-term use but less so for long-term use according to Bjordal.<sup>20</sup> The laser dentist can reduce the use by replacing the pharmaceuticals with LPT to a high degree.<sup>21</sup> The only limitation is that the pharmaceuticals can be taken for a long period at home, whereas the laser treatment is performed in the clinic. To a certain extent this limitation can be reduced by the use of home-care laser units. A consequence of an ageing European population, taking a lot of medications, is xerostomia. Dentists can recommend various gels and sprays to alleviate these problems but with a laser at hand, a rather long-term improvement of the xerostomia can be achieved. This requires an initial treatment in the clinic, followed by a period of the use of a home-care laser.<sup>22,23</sup>

Acupuncture is not common in dentistry but is an option for the laser dentist. Laser acupuncture has shown similar results as needle acupuncture<sup>24</sup> and a recent meta-analysis provides proof of the efficacy of laser acupuncture.<sup>25</sup> Even the inexperienced dentists can for instance use the point P6 on the wrist to reduce the gagging reflex. The pain-free and non-invasive quality of laser acupuncture paves the way for a new kind of dental profession.

Bisphosphonate-associated osteonecrosis of the jaw (BRONJ) is an emerging dental problem with an increasing number of patients using bisphosphonates. The healing capacity of these patients is low. Surgical as well as therapeutic lasers are reported to be a valuable tool in treating these cases.<sup>26,27</sup>

The above is a brief survey of indications which traditionally are not treated by dentists, but where the use of a therapeutic laser can expand the scope of dentistry. Most of the conditions described here are new for laser applications and have fairly scant scientific evidence. However, the lack of side effects of LPT still makes them a reasonable field for dentistry.

Apart from being able to do more for the patients, the laser dentist also has a possibility of treating himself, staff and family for common problems such as tennis elbow, carpal tunnel, burns etc. This poses no legal or ethical problems like treating patients for these ailments would. The legal situation will differ from country to country, but still, the side free effect of LPT opens quite new possibilities for good patient care. The case below is certainly not dentistry, but indeed a dental patient with a health problem (Figs. 2 and 3).

*References can be obtained by contacting the author at [jan.tuner@swipnet.se](mailto:jan.tuner@swipnet.se)*

## contact

**Jan Tunér**  
Spjutvägen 11  
772 32 Grängesberg, Sweden  
[jan.tuner@swipnet.se](mailto:jan.tuner@swipnet.se)  
[www.tuner.nu](http://www.tuner.nu)

### Kurz & bündig

Obwohl die laserunterstützte Phototherapie (LPT) bereits seit mehreren Jahrzehnten angewendet wird, ist die anfängliche Skepsis der Anwender erst in den letzten Jahren einer wachsenden Anerkennung ihrer Stärken gewichen. Mittlerweile ist sie bei vielen Indikationen wie Entzündungen, Schmerz oder Ödemen eine anerkannte Behandlungsoption. Betrachtet man die ihr zugrunde liegenden Mechanismen auf Zellebene, erschließt sich das breite Anwendungsspektrum der Phototherapie. Im vorliegenden Artikel wendet sich der Autor den neuesten Erkenntnissen dieser lasergestützten Behandlung zu.

Eine moderne Herangehensweise macht sich die Eigenschaft der Phototherapie zunutze, Gewebe bereits vor einem möglichen Trauma, wie beispielsweise einem chirurgischen Eingriff, zu präkonditionieren. Gesunde Zellen reagieren schwächer auf LPT als pathogene Zellen, während die beste Zellreaktion in einer reduzierten Umgebung, also einer Umgebung mit einem niedrigen PH-Wert, stattfindet.

Eine Vielzahl der im Artikel beschriebenen Indikationen sind zwar klassischerweise nicht der Zahnmedizin zuzuordnen, können jedoch unter Verwendung eines therapeutischen Lasers zu einem zahnärztlichen Anliegen gemacht werden. Die meisten hier beschriebenen Zustände sind neu für die Laseranwendung und haben eine eher spärliche wissenschaftliche Evidenz. Da die Laser-Phototherapie jedoch keine Nebeneffekte aufweist, kann eine Integration dieser Behandlungsmöglichkeiten in die Zahnmedizin zu einer sinnvollen Erweiterung des zahnärztlichen Anwendungsspektrums beitragen. Der nebenwirkungsfreie Effekt einer LPT eröffnet völlig neue Möglichkeiten für eine erfolgreiche Patientenpflege.



# Master of Science (M.Sc.) in Lasers in Dentistry

Next Start: **26<sup>th</sup> September 2016**  
Aachen, Germany  
4 semesters



## Become part of the International Dental Elite

- Create new economic potential for your practice
- Two year career-accompanying postgraduate programme at the University of Excellence RWTH Aachen
- Combination of lectures, skill training sessions, live ops, tutorials, and practical workshops
- Internationally accepted and accredited by the German Government, the European Union, the Washington Accord and the Bologna Process
- Science-based and practice-orientated on highest national and international level
- Increased patient satisfaction: minimal contact reduced vibration and pain



**RWTH INTERNATIONAL  
ACADEMY  
AACHEN UNIVERSITY**

RWTH International Academy  
Kackertstraße 10 | 52072 Aachen | Germany  
phone +49 241 80 23543 | fax +49 241 80 92525  
info@academy.rwth-aachen.de  
www.academy.rwth-aachen.de

**PROFESSIONAL EDUCATION PROGRAMMES**

**AALZ**

Aachen Dental Laser Center

AALZ GmbH  
Pauwelsstraße 17 | 52074 Aachen | Germany  
phone +49 241 47 57 13 10 | fax +49 241 47 57 13 29  
info@aalz.de  
www.aalz.de

# Denture Stomatitis: Treatment with Diode Laser

**Author** Dr Maziar Mir, Prof. Norbert Gutknecht, Dr Masoud Mojahedi, Dr Jan Tunér, Prof. Ramin Mosharraf & Dr Masoud Shabani, Germany, Sweden, Iran

## Introduction

Denture stomatitis (DS) is one of the most common oral lesions in patients who wear a complete or partial removable denture. Very few cases regarding the treatment of denture stomatitis lesions by laser are reported in the literature. We present a case of treatment of DS without the use of any pharmaceutical aids.

The prevalence of DS is 15% to 70% among patients using dentures.<sup>1,2</sup> DS is a chronic candida infection. Thus, *Candida albicans* is the main causative organism. Besides *Candida albicans*, additional predisposing factors can play a role in the occurrence and progression of DS, including poor oral and denture hygiene, continual and overnight wearing of removable dentures, hyposalivation, bacterial and yeast contamination of denture surfaces as well as poor-fitting dentures. All of the mentioned factors are able to increase the ability of *Candida albicans* to colonise both the denture and the oral mucosal surfaces. Additionally, long-term antibiotic therapy, use of corticosteroids, diabetes, impaired immunity, malignancy, alcohol consumption, trauma, and diet may increase the development of DS.<sup>3,7</sup>

DS is classified in three types (Nyoton classification): pin-point hyperemic lesions or simple inflammation (type I); diffuse erythema or generalised inflammation (type II) and inflammatory papillary hyperplasia (type III).<sup>8,9</sup>

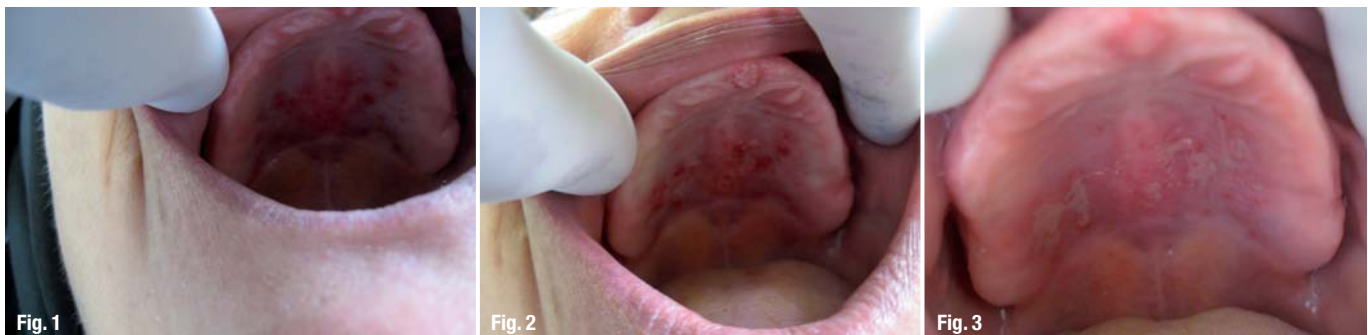Treatment of DS is traditionally started with the introduction of good oral and denture hygiene, correction of ill-fitting denture, discontinuation of nocturnal denture wearing, usage of topical agents such as nystatin and miconazole and finally relining or replacing of the denture. Systemic antifungal agents such as amphotericin B and fluconazole are also effective in cases of recurrence and for patients contraindicated to surgery. Surgical treatment of the lesion in cases of type II and type III can be applied in the form of scalpel surgery, electrosurgery and cryosurgery. Recently, laser-assisted photodynamic therapy has been reported.<sup>10</sup>

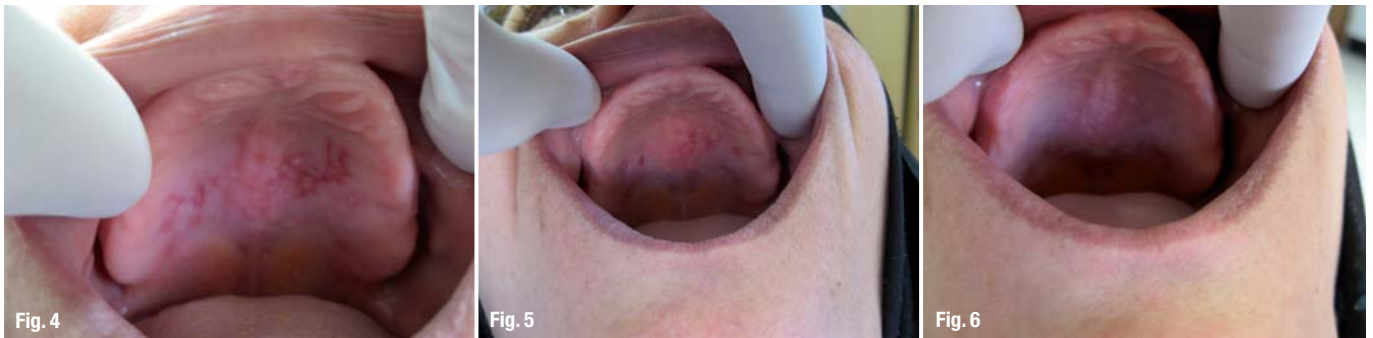Vaporisation is ideal for large surface lesions confined to the epithelium,<sup>11</sup> whereas cryosurgery is an option for the removal of superficial, wide lesions in the oral cavity. Both laser vaporisation and cryosurgery preclude a histological diagnosis. Therefore, both

**Fig. 1** Clinical view of type II DS according to the Newton classification.

**Fig. 2** Immediately after superficial contaminated layer vaporisation with diode laser.

**Fig. 3** One day after treatment.





techniques only are performed in areas that previously had biopsy specimens taken or when a clinical diagnosis has been made properly. Cryosurgery disadvantages include unpredictable degree of swelling, lack of precision for depth and freezing area, and high dependence on the operator's skill and experience. However, advantages of cryosurgery include absence of pain, low risk of infection and no need of suture removal.<sup>12,15</sup>

## Case report

A 65-year-old female patient with sore mouth sensation, who had worn her dentures for six years continuously without removing it during sleep, was referred for treatment.

### Medical history

The anamnesis of the patient revealed no systemic medical problems, no allergic reactions, no medication or drugs and no history of past surgical procedures so that the patient had no need for a referral to a medical consultant.

### Dental history

Oral and maxillofacial examination of the patient revealed no T.M.J. or myofascial disturbances.

### Clinical findings

Old and ill-fitting dentures, resorbed alveolar ridge and a diffuse erythematous lesion of the palate were observed (Fig. 1).

### X-ray examination

X-ray examination showed no abnormal destructive effects.

### Clinical diagnosis

The case was clinically diagnosed as denture stomatitis type II according to the Nyoton classification, and we decided to treat it by diode laser.

### Laser parameters

The laser had a wavelength of 980 nm, 400 µm fibre, 1.2 W output power, continues mode and initiated fibre.

### Treatment delivery sequence

After filling out the consent form, the surgery area was anaesthetised by infiltration method with 2% lidocaine with Epi 1:100,000, 1.8 ml. Afterwards, the following treatment steps were executed:

- Defining of the controlled area and the proper placing of the laser warning signs to secure the operating room.
- Checking of the safety for patient's eye glasses, patient's guardian eye protection and the assistant eye protection.
- Set up of the laser and test of proper laser operation (fibre cleaving, control of the laser output, aiming beam control, spot size estimation, initiation of the fibre with a dark articulation paper and test-fire of the laser), using minimum power and setting.
- Checking the patient's information (examination sheet and X-ray, consent form, etc.).

### The lesion vaporization

Removal of the superficial contaminated epithelial surfaces was performed with contact and scanning mode in combination and the lesion was vaporized. During the treatment, high volume suction was used to evacuate the vapor plume and objectionable odors at the site of operation. During the entire procedure, the laser-tissue interaction was respected in order to prevent any unsuitable reactions in the surrounding tissue. Removal of carbonized tissue was done by a micro-applicator brush sucked in 3% hydrogen peroxide solution.

### Post procedural education

The patient was advised to keep the area clean and to avoid food and liquids that may cause pain or irritation to the sensitive tissue, but can use over-the-counter analgesics as needed.

### Final result

Excellent laser vaporization of the contaminated layer was observed with no bleeding, no carbonization and no char (Fig. 2). The patient did not experience any discomfort and was satisfied.

### Follow-up

The first visit after laser treatment was one day after the procedure (Fig. 3). The patient revisited after five

**Fig. 4** Five day after treatment.

**Fig. 5** One week after treatment.

**Fig. 6** Two weeks after treatment.

days and one week. As Figs. 3 and 4 show, the healing process was as expected so that the healing was progressing well and devoid of any pain or discomfort. Finally after two weeks, the final goal was achieved (Fig. 5). A new denture was provided after complete treatment (Fig. 6).

## Discussion

Diode lasers with wavelengths ranging from 810 to 980 nm are used for soft tissue surgery in the oral cavity. In comparison to conventional DS treatment (scalpel technique, cryosurgery, topical or systemic antifungal agents), the laser assisted DS therapy can be performed fast, with no bleeding, with little or no pain, no oedema and little or no need to use over-the-counter analgesics. Although antifungal agents, such as nystatin (100,000 unit per ml) and amphotericin B (lotion 3%) are effective in alleviating the clinical signs and symptoms of candida infection, unpleasant taste, gastrointestinal side effects such as nausea, vomiting and diarrhoea can be seen in this model of treatment. Additionally, topical agents can be diluted through saliva and displaced by oral movable tissue so that treatment regimens may be prolonged and lead to unsuccessful treatment of the infection and also development of resistant species.<sup>16-18</sup> Systemic antifungal agents cannot fully eradicate the microorganisms that colonize the denture.<sup>19</sup> Further side effects such as gastrointestinal disturbances, hypersensitivity, renal and liver toxicity and interaction with other medicines can be seen during usage of systemic antifungal drugs.<sup>20</sup> High recurrence rates of denture stomatitis and recoloniza-

tion of candida have been reported after cessation of the antifungal treatment.<sup>19, 21</sup>

Use of disinfection agents can also have minor side effects such as staining and alterations of taste.<sup>22</sup> Photodynamic therapy has been suggested as a conservative treatment of DS but there is yet little literature to support this kind of treatment.<sup>19, 23</sup>

Cryosurgery can be used in the field of oral lesion treatment, but a relatively long period of wound healing is one of its disadvantages and the prevention of loss of gas attributable to leakage and evaporation, and a risk of accidents during storage has to be taken into account.<sup>24, 25</sup>

## Conclusion

The 980 nm diode laser is a useful tool for the treatment of denture stomatitis.

*Editorial note: A list of references is available from the publisher.*

## contact

### Dr Masoud Shabani

Deputy for Research, Ardebil University of Medical Sciences, Ardebil, Iran  
Conservative Dentistry, RWTH International Academy, Aachen, Germany  
m.shabani@arums.ac.ir

## Kurz & bündig

Prothesenstomatitis ist eine der häufigsten oralen Läsionen bei Patienten, die eine Voll- oder herausnehmbare Teilprothese tragen. In der Literatur werden nur wenige Fälle zur Laserbehandlung solcher Läsionen erörtert. Im vorliegenden Artikel der Fall präsentiert, bei dem Prothesenstomatitis ohne jegliche pharmazeutischen Mittel erfolgreich mithilfe eines Diodenlasers behandelt wurde.

Eine 65-jährige Patientin stellte sich mit schmerzdem Mund vor. Sie hatte zu diesem Zeitpunkt ihre Prothesen seit sechs Jahren getragen, ohne diese während des Schlafs herauszunehmen.

Nach klinischer und röntgenologischer Untersuchung wurde der Fall als Prothesenstomatitis Typ II gemäß der Newton-Klassifikation eingestuft und mithilfe des Diodenlasers behandelt. Nach der Behandlung zeigte sich eine sehr gute Laservaporisation der kontaminierten Gewebe, jedoch keine Blutung oder Karbonisierung. Die Patientin blieb während und nach der Behandlung schmerzfrei. Nach zwei Wochen war das Behandlungsziel vollständig erreicht, sodass eine neue Prothese verwendet werden konnte.

Zusammengefasst stellt die laserunterstützte Behandlung der Prothesenstomatitis eine gute Alternative zu konventionellen Behandlungsmethoden dar (Skalpell, Kryochirurgie, topisch applizierte oder systemisch wirkende Antimykotika), denn sie verläuft schnell und blutungsfrei. Weiterhin ist sie für den Patienten mit keinen oder geringen Schmerzen verbunden, Ödeme können ausgeschlossen und selbst frei erhältliche Schmerzmittel müssen nicht verwendet werden.



# CROIXTURE

PROFESSIONAL MEDICAL COUTURE



## NEW COLLECTION

EXPERIENCE OUR ENTIRE COLLECTION AT [WWW.CROIXTURE.COM](http://WWW.CROIXTURE.COM)

# A multidisciplinary approach with Er,Cr:YSGG

## Aesthetic management of hard and soft tissues

**Authors**\_Dr Christina Boutsiouki & Dr. Dimitris Strakas, Germany, Greece

### Introduction

The use of an Er,Cr:YSGG laser system in every day practice is beyond doubt a very helpful tool in the hands of a trained practitioner. It can be used safely both for hard and soft tissue treatments, with minimal or no use of anaesthesia, and complex cases with many different treatments can be treated in less time. Therefore patients enjoy the benefit of time-saving and pain-free treatments.

The following case report is from a female patient aged 38, who was referred to the Post-graduate Dental Clinic of the Operative Dentistry department, in Aristotle University of Thessaloniki by the Department of Orthodontics. Reason of the reference was the fact that the patient showed no compliance with the orthodontic treatment (Fig. 1). Therefore a faster and conservative aesthetic solution for the front teeth area was decided. Anterior teeth have a signif-

icant psychological and emotional impact on patients owing to their prominent position within the dentition and their main role in a smile. The patient's chief complaint was the color of her teeth and the gaps between the upper front teeth (Figs. 2-6). After obtaining the medical and dental anamnesis, clinical and radiographic examination was performed in order to address any existing therapeutical problems (caries, periodontal, endodontic).

The patient mentioned during dental anamnesis recording that she had performed periodontal therapy one month ago and that she was under observation by the Department of Periodontology. Moreover, it was mentioned that she had worn the brackets for more than five years and that she was reluctant to continue the orthodontic treatment. From the side of the orthodontists it was recorded that she was not consistent with the change of the elastic bands, she omitted a few appointments even when

**Fig. 1**\_Initial clinical image after reference from the orthodontic department.

**Fig. 2**\_Initial frontal view upper and lower arch.

**Fig. 3**\_Initial frontal view of the upper teeth.

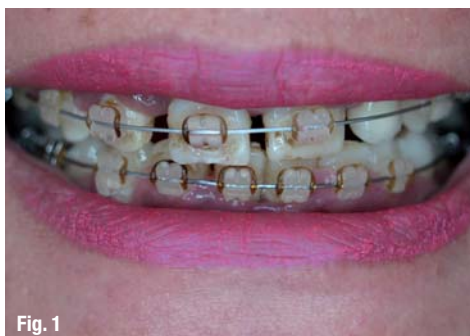

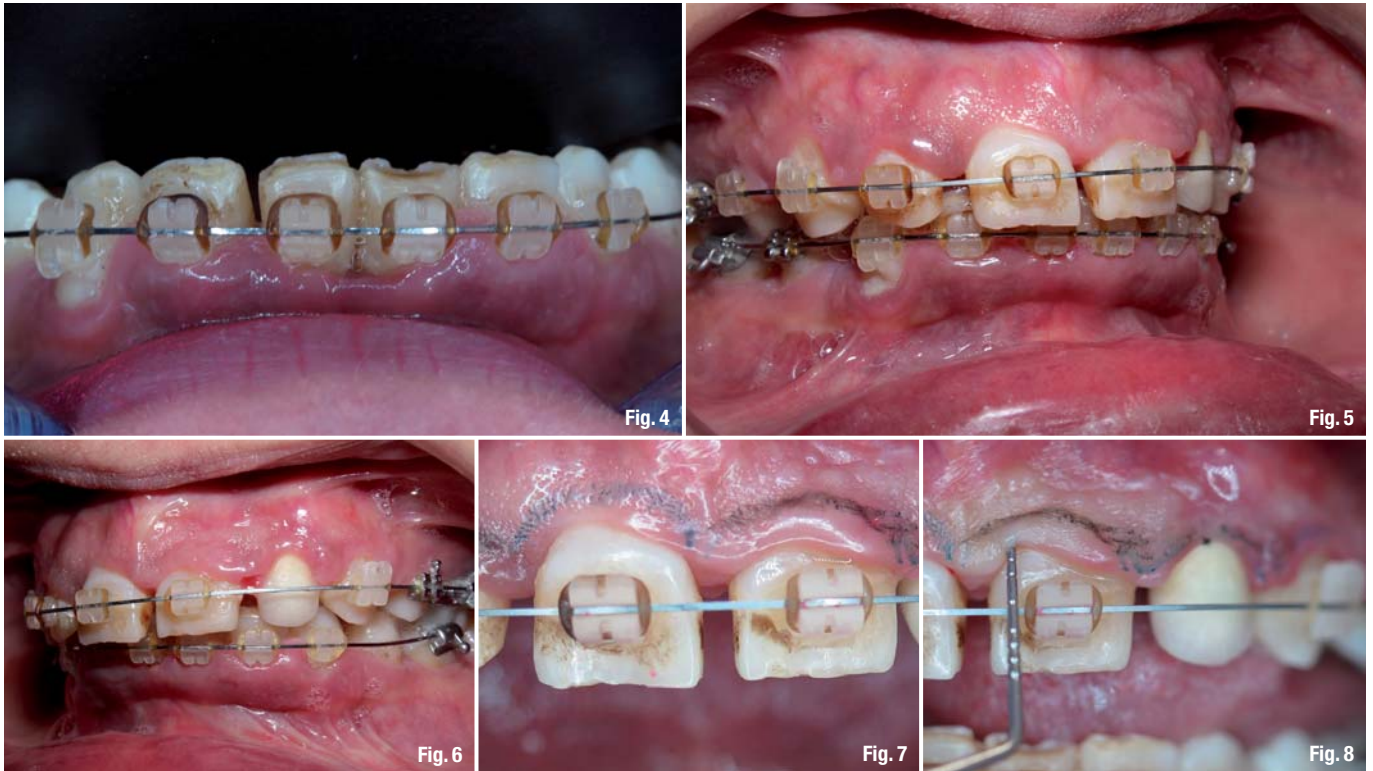
Fig. 1

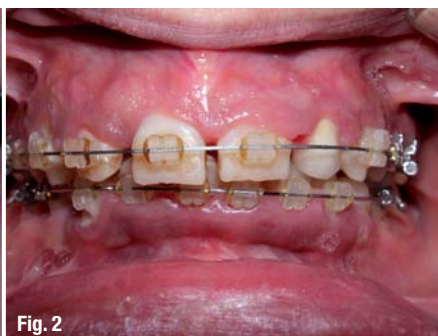

Fig. 2

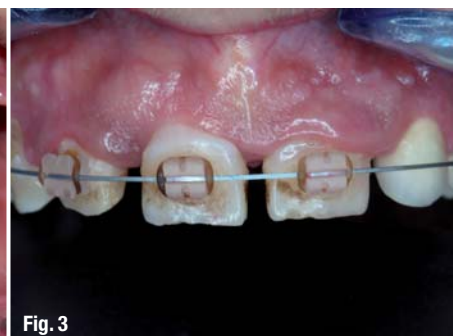

Fig. 3



brackets were debonded and that she maintained no proper hygiene. Additionally, it was made clear that it is contra-indicated to further continue with the orthodontic treatment, as the risk of root absorption was high due to the long-time activation of the brackets.

Clinical examination revealed poor oral hygiene, gums hyperplasia, visible discoloration around the brackets due to smoking, caries on the right upper canine and a PFM crown on the left lateral incisor (Figs. 2–6). Mild demineralisation around the brackets was also noted after they were removed. It was also observed that the teeth’s central mid-line did not correspond with the facial mid-line (Fig. 1). Clinical and radiographic examination showed no problem at the posterior teeth.

According to our findings, respecting the patient’s wishes and taking in consideration her financial limitations, the aesthetic rehabilitation should include a multidisciplinary approach. It was decided to perform the following treatment plan:

- Gingivectomy on upper and lower gum line
- Bleaching on upper and lower arch
- Diastema closure between teeth #11–21, #11–12 and #21–22

In order to allow proper soft tissue healing and following the guidelines for adhesive restorations performed after bleaching, a two-week interval was scheduled between each appointment. The demineralisation around the brackets was decided to be handled with fluoride gel application.

### Gingivectomy

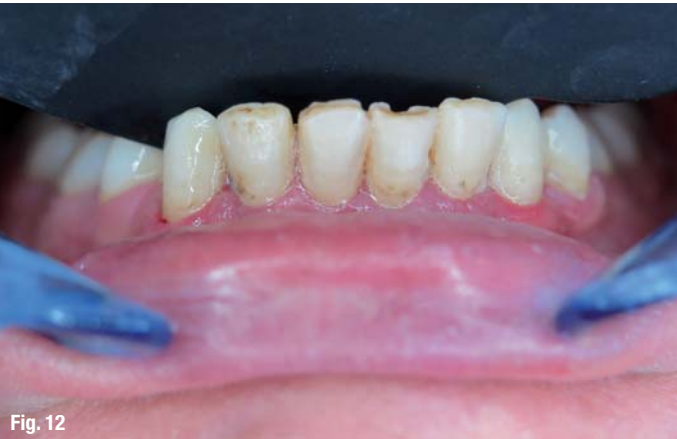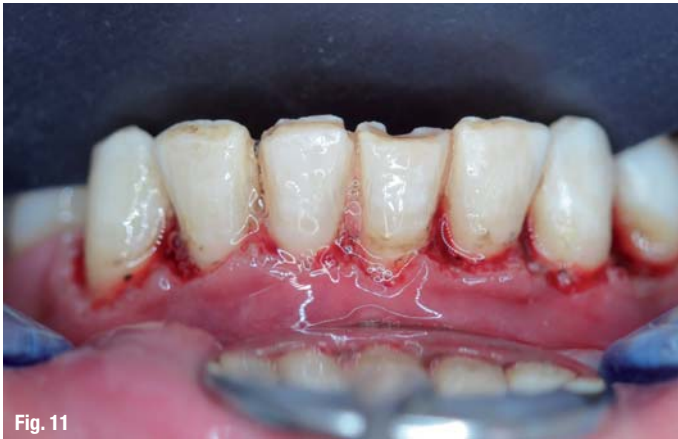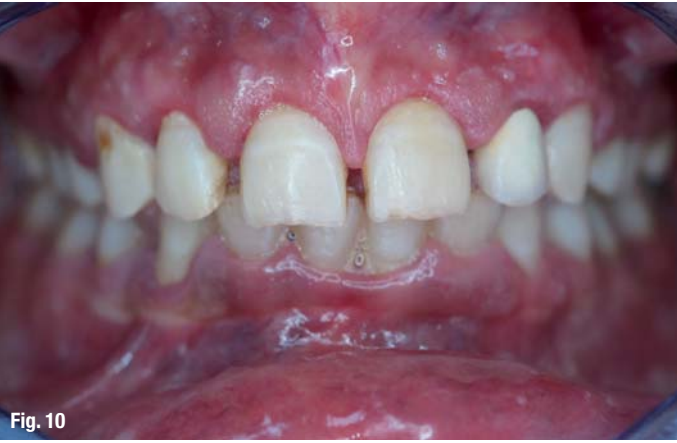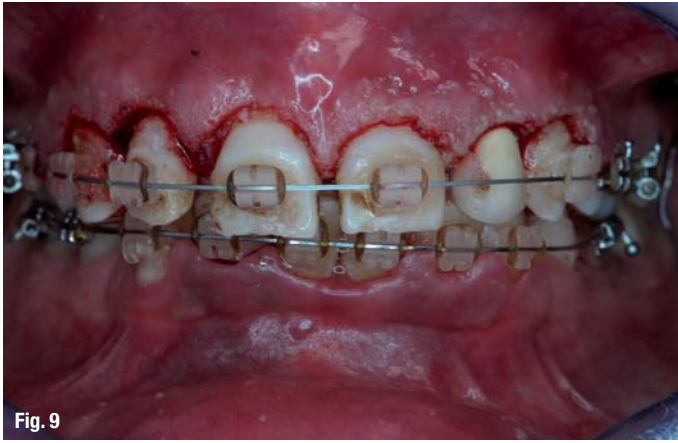Periodontal plastic surgery introduced by Miller in 1993, includes surgical procedures performed to correct or eliminate anatomic, developmental or traumatic deformities of the gingiva or alveolar mucosa.<sup>1</sup> It is often combined with aesthetic rehabilitation of the smile with conservative composite restorations or with veneers. The goal is to eliminate the periodontal pockets by excision of the excessive soft tissue.

**Fig. 4** \_Initial frontal view of the lower teeth.  
**Fig. 5** \_Right side initial view.  
**Fig. 6** \_Left side initial view.  
**Fig. 7** \_The pattern of gingivectomy was designed on the gingival tissue.  
**Fig. 8** \_Periodontal sulcus depth was checked prior to surgery.

Tooth Number	12	11	21	22
Width	7	9	9	7
Height	7,5	9	8	8
Width: Height Ratio	0,93	1	1,125	0,87

**Table 1** \_Central and lateral incisors dimensions.





**Fig. 9** Immediate image after gingivectomy in the upper arch.

**Fig. 10** Two-weeks post-operative image and healing of gingival tissue in the upper arch.

**Fig. 11** Immediate image after gingivectomy in the lower arch, following the same procedure.

**Fig. 12** Two-weeks post-operative image and healing of gingival tissue in the lower arch.

The gingival architecture in the upper arch was not even and gum hyperplasia was noted at areas #21–22 and #22–23, owing to chronic insufficient plaque removal and possibly to the PFM crown placement on tooth #22. Moreover, study of the casts showed that in order to attain an optimal length-width ratio of 62–80%, crown lengthening should take place prior to diastema closure. Normally, the gingival margin is 1 mm coronally to the cemento-enamel junction. The above-mentioned problems can be solved by removing the excessive gingiva via precisely planned incisions. When crown lengthening is planned to increase the tooth length, the biological width needs to be considered and not encroached upon, as this may lead to periodontal breakdown.

Therefore, periodontal measurements of the sulcus depth were recorded and in accordance with the preferred tooth dimensions, tooth width, height and their ratio was recorded prior to surgery (Table 1). Ideal ratio would be 0,8–0,9. Once the appropriate proportion was determined, the outlines were marked on the gingiva with a waterproof marker (Fig. 7). Since the clinical crown was measured to be shorter than the anatomical crown, approximately 2 mm of gingiva were calculated to be removed (Fig. 8). The gingival tissue was of a thick biotype and had adequate attached gingiva. Gingival recontouring was performed with the following parameters.

Average output power was set to 2,5 W, with a pulse duration of 700  $\mu$ sec (S-Mode) and a pulse repetition rate of 50 Hz using an MZ5 tip under minimal water spray (Air: 10%–Water: 10%). Gum hyperplasia areas were treated first and a scalloped excision pattern was followed (Fig. 9). As a final step, a pleasing gingival symmetry was created and the gingiva was allowed to heal for two weeks before the next treatment phase (Fig. 10). The patient reported slight bleeding at the next day following the gingival treatment, but no pain or soreness. Gingivectomy in the lower jaw (Fig. 11) was performed at the next appointment, together with bleaching of the upper teeth, and was allowed to heal for two weeks (Fig. 12).

### Er,Cr:YSGG assisted teeth bleaching

In order to achieve the best clinical results without harming dental tissues, it is crucial to follow the procedure carefully and take all safety measures. Before starting the first session, the patient was also informed that the result of the procedure is not permanent and is dependent on the age of the patient and the use of tobacco and extrinsic staining by deposition of tannins found in coffee, red wine, tea and cola beverages. The average duration expectancy is three to four years for non-smokers. The patient was instructed that if teeth sensitivity or pain was felt dur-

ing teeth bleaching, we should be notified so the treatment could be paused or stopped.

Periodontal therapy has been performed in the Department of Periodontology. Before starting with the teeth bleaching, it was checked that the teeth were free of plaque, calculus and extrinsic staining (Fig. 10). In order to prevent unwanted proteins and enzymes of saliva's biofilm to interfere with the bleaching agent, mild cleaning of the teeth to be bleached was performed, with the application of a prophylaxis paste. In the Post-graduate Dental Clinic of the Department of Operative Dentistry at the Aristotle University of Thessaloniki, we operate an Er,Cr:YSGG laser (2,780 nm, Waterlase MD, Biolase, USA) and a yellow-colored bleaching agent used for in-office bleaching with a concentration of 38% H<sub>2</sub>O<sub>2</sub> (Power whitening, WHITEsmile GmbH, Germany). The tip used is a 6 mm long Z-type glass tip (MZ8) of an 800 μm diameter, used with the gold handpiece of the laser system. The power settings that we have used were: output power 1.25 W, pulse duration 700 μsec (S-mode), while the pulse repetition rate was set to 10 Hz.

The dentist, the dental assistant and also the patient evaluated initial tooth color. In our case, the patient's initial color was evaluated as A3 in the VITA Classical Shade Guide. Both the patient and the personnel in the laser working area must wear safety goggles in advance. Lip protection cream was applied and the working area was isolated with a cheek and lip retractor. After drying teeth and gums with gentle air stream, a liquid gingival barrier was carefully ap-

plied both on upper and lower teeth and was polymerised with a fanning motion for 40 seconds.

The bleaching agent was applied in a 1-2 mm thick layer on each tooth, except from #22, due to the PFM crown. With the power settings mentioned above we activated the bleaching agent for two intervals of ten seconds on each tooth (Fig. 13), keeping the laser handpiece on a 2.5 cm distance from the teeth. After the procedure, the activated bleaching agent was left for 15 minutes and then carefully removed with high-power dry suction from the teeth. This procedure was repeated twice at the same appointment. Upper and lower arch were bleached in separate appointments. Upper teeth's bleaching was performed at the same appointment with the gingivectomy of the lower arch, thereby pointing out the advantage of the use of laser, in terms of absence of pain and bleeding. No soft tissue irritation was noticed, nor did the patient report feeling pain or soreness. Final color evaluation took place from the dentist, the dental assistant and the patient. Two repetitions of the process at the same appointment were adequate to move the color of the teeth to B1 according to VITA Classical Shade Guide (Fig. 14). The patient was satisfied with the color of her teeth and the next appointment was arranged in order to close the diastemas.

### Diastema Closure

Diastema closure was scheduled after two weeks in order to achieve high-quality bond strength between the enamel and the composite resin (Ittipuriphat and Leevailoj 2013).<sup>2</sup> Casts were studied prior to

**Fig. 13** Laser-assisted bleaching of the upper teeth. Note that tooth #22 has a PFM crown.

**Fig. 14** Immediate colour evaluation after bleaching.

**Fig. 15** Evaluation of gold proportions in casts prior to diastemas closure.

**Fig. 16** Preparation of Class V cavity on tooth #13.

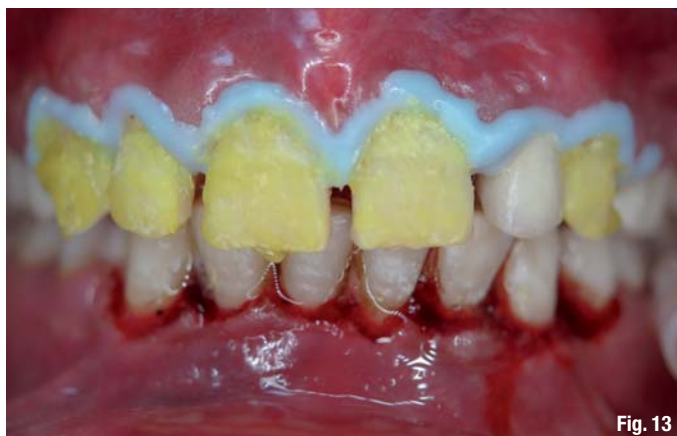

Fig. 13

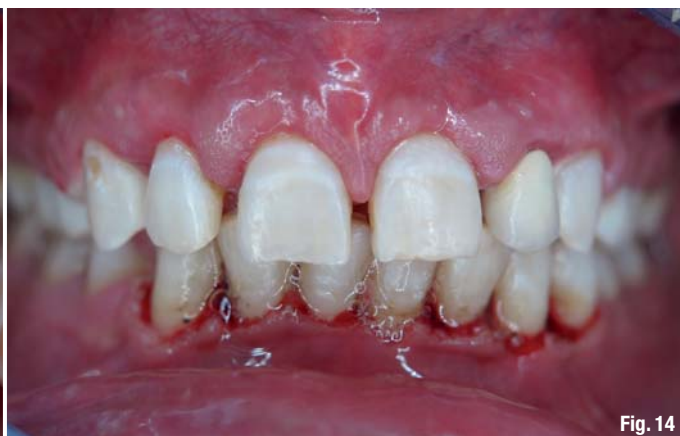

Fig. 14

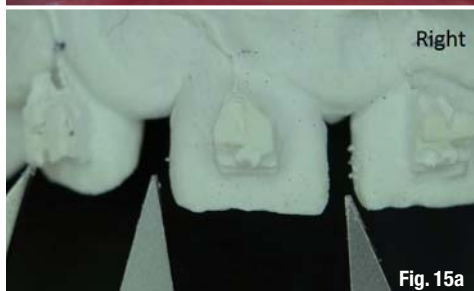

Fig. 15a

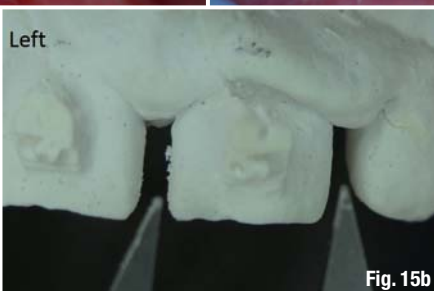

Fig. 15b

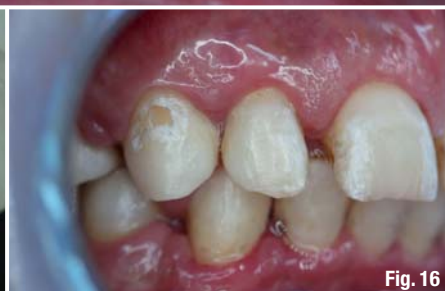
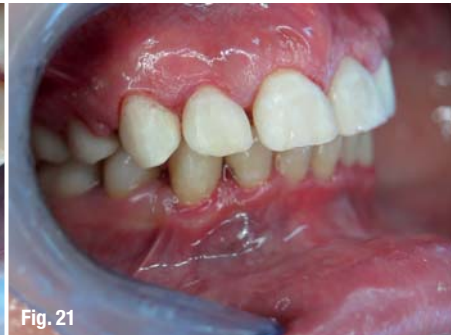
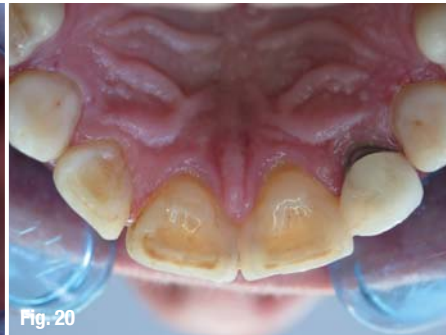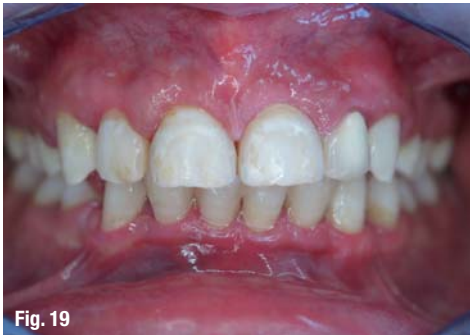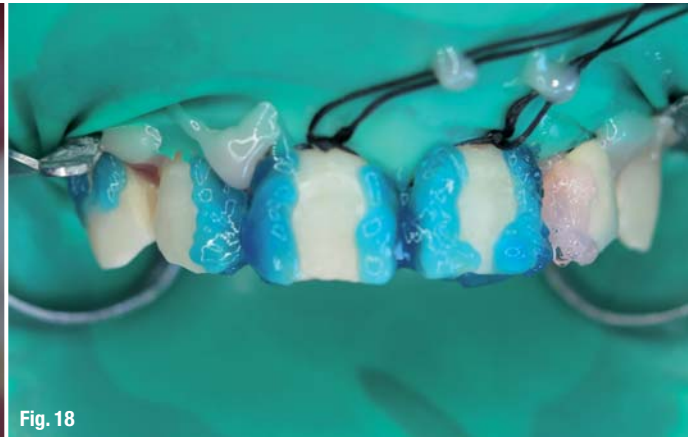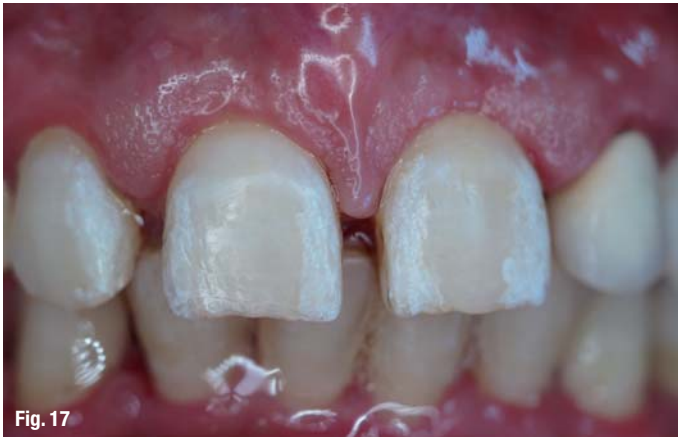Fig. 16



**Fig. 17** Etching of enamel with laser at the lateral surfaces of the teeth to be restored with composite resin and around a Class V cavity on tooth #13.

**Fig. 18** Additional acid etching was performed on enamel.

**Fig. 19** Final frontal view of restored teeth.

**Fig. 20** Final palatal view of restored diastemas.

**Fig. 21** Final right side view.

restorations; appropriate tooth proportions were calculated and checked with the golden proportions tool, which can simultaneously define the width of central incisors in comparison to the lateral incisors, or the width of the laterals in comparison to the canines (Fig. 15). This gives an idea of the ideal placement of the composite resin regarding its placement at the proximal area of two neighboring teeth and how many millimeters of composite resin are required for mesial and distal closure of a specific diastema. During this planning, the difference in facial and dental mid-line was also considered (Fig. 1) in order to achieve an even result. Prior to aesthetic rehabilitation, caries on #13 was removed using an Er,Cr:YSGG laser (2.780 nm, Waterlase MD, Biolase, USA, Fig. 16). Average output power was set to 6W, with a pulse duration of 140µsec (H-Mode) and a pulse repetition rate of 15Hz using an MZ6 tip under water spray (Air: 50%-Water: 80%). All margins and enamel were etched with the same laser device (Fig. 17). Power settings for bond preparation were (MZ6 tip, average output power 4,5W, pulse repetition rate 50Hz, H-mode).

Restorative procedure took place free-handedly after placement of a rubber dam. Enamel was additionally etched with 37% phosphoric acid while the mesial surface of the PFM crown was etched with 9% hydrofluoric acid (Fig. 18). Thus, resin composite bond to enamel will benefit both from laser etching and from acid etching. Starting from the central incisors, diastemas were closed using a single composite resin shade (A3 Shade, Beautifil, SHOFU Inc), first palatally

and then buccally. It was decided to use a single composite shade, as teeth presented high color saturation and no prominent translucency or special characteristics. Special attention was given to the proximal transition lines in order to create the illusion of narrower teeth. Microstructure was created after polishing with fine and ultra-fine diamond burs, with decreasing roughness of polishing discs, silicon points and brushes coated with diamond paste for the final gloss. The incisal plane could not be evened, despite the patient's wish, due to occlusional restraints. Final adjustments were made during polishing at the proximal curvature and at the incisal plane, to enhance the natural-looking effect. The final outcome is shown at Fig. 19 buccally and Fig. 20 palatally. Side photographs were also taken (Figs. 21 and 22). Note that, in order to gain in aesthetics, the diastema between #11-12 was decided not to be fully restored (Fig. 21). Otherwise, we would end up with very wide central or lateral incisors, which would compromise the final aesthetic result. At the same appointment, lower jaw bleaching was performed, with the same procedure described above. Fluoride gel was then applied at the end of the treatment at the demineralised areas around the brackets, in the buccal surfaces of 11, 12 and 21. Patient recall was at seven days post-op (Fig. 23).

## Results

The aesthetic rehabilitation of this complex case was completely performed with the use of an Er,Cr:YSGG laser. Laser treatment was performed

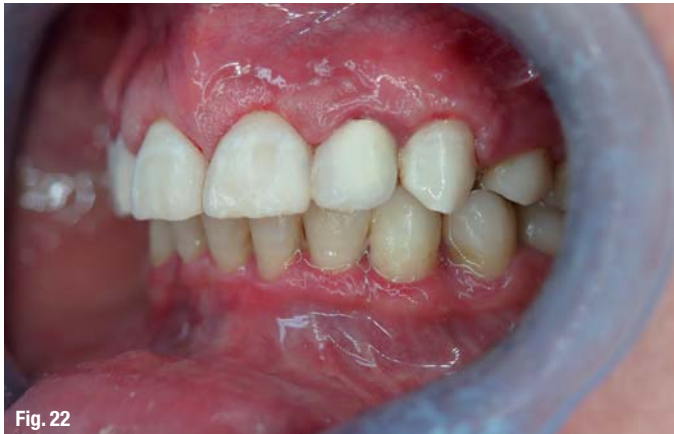

Fig. 22

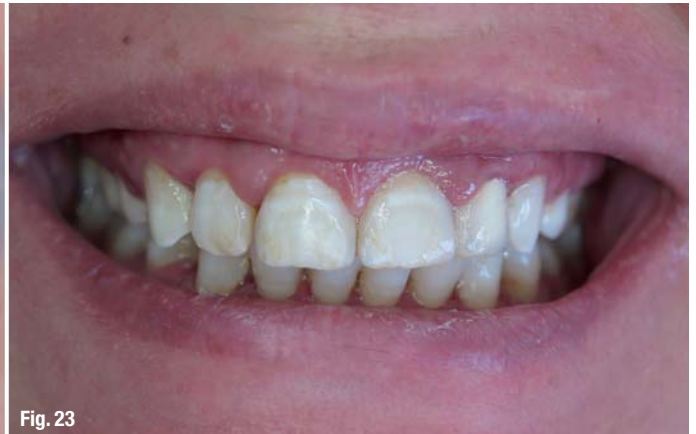

Fig. 23

with no local anaesthesia. Patient reported no sensitivity at any stage of the procedure. During gingivectomy, no side-effect or comment was reported and fast healing was exhibited. Regarding diastema closure, it was decided to use a single composite shade as the teeth presented high colour saturation and no prominent translucency or special characteristics. No silicon-key was used and composite was placed free handed, after an initial evaluation of the interdental gaps made at the casts, with the golden proportion tool. Final adjustments were made during polishing to enhance the natural effect. It is more than evident that the use of an Er,Cr:YSGG laser system as a multi-tasking tool allows the scientifically trained clinician to address the vast majority of dental treatments. By combining soft and hard tissue aesthetics, a desirable

gingival architecture and tooth proportion could be offered to the patient.

*Editorial note: A list of references is available from the publisher.*

## contact

### Dr Dimitris Strakas, MSc

PhD cand. Department of Operative Dentistry Aristotle University of Thessaloniki  
Spiridi 28, 38221  
Volos, Greece  
+30 24210 32525  
dimitris.strakas@gmail.com

**Fig. 22**\_Final left side view.

**Fig. 23**\_The patient smiles in the seven-days post-operative control.

## Kurz & bündig

Der vorliegende Artikel beschreibt einen multidisziplinären Ansatz der Lasertherapie mithilfe eines Er,Cr:YSGG-Lasers anhand des Fallbeispiels einer 38-jährigen Patientin. Diese wurde an den Autor überwiesen, nachdem eine kieferorthopädische Behandlung aufgrund schlechter Mundhygiene und mangelnder Compliance gescheitert war.

Die Hauptanliegen der Patientin waren die Zahnfarbe und eine Zahnücke zwischen den oberen Frontzähnen. Die klinische Untersuchung zeigte neben einer schlechten Mundhygiene eine Gingivahyperplasie, eine sichtbare Verfärbung im Bereich der Brackets durch Rauchen, Karies auf dem rechten oberen Eckzahn und eine Metallkeramikkrone auf dem linken lateralen Schneidezahn. Nach Entfernung der Brackets wurde zudem eine leichte Demineralisierung der Zähne sichtbar. Weiterhin entsprach die zentrale Mittellinie der Zähne nicht der des Gesichts. Die klinische und röntgenologische Untersuchung zeigten jedoch keine Probleme im Seitenzahnbereich.

Unter Berücksichtigung des Befundes und der Wünschen der Patientin wurde ein multidisziplinärer Behandlungsplan aufgestellt: Gingivektomie des oberen und unteren Zahnfleischrandes, Zahnaufhellung des oberen und unteren Zahnbogens sowie ein Diastemaschluss an den Zähnen #11–21, #11–12 und #21–22.

Diese komplexe ästhetische Rehabilitation wurde mithilfe eines Er,Cr:YSGG-Lasers durchgeführt. Obwohl auf lokale Betäubung verzichtet wurde, berichtete die Patientin, dass sie während der gesamten Behandlung keine Schmerzen verspürt habe. Während der Gingivektomie gab es keinerlei Nebenwirkungen. Eine schnelle Wundheilung konnte beobachtet werden. Zusammenfassend kann eine Vielzahl dentaler Behandlungen mithilfe des Er,Cr:YSGG-Lasers durchgeführt werden, was multidisziplinäre Behandlungssätze wie im vorliegenden Fall begünstigt. Durch die Kombination zwischen Hart- und Weichgewebsästhetik wurde der Patientin eine ansprechende Ästhetik sowohl hinsichtlich der Gingivafläche als auch der Zahnproportionen geboten.

# Manufacturer News

15<sup>th</sup> WFLD Congress 2016

## Light to brighten the future

The World Federation for Laser Dentistry (WFLD) is an organisation of academic societies with the agenda of promoting oral health by innovative developments in laser dentistry and dental care. It is comprised of 54 member countries worldwide. In addition to academic activities, the WFLD is also committed to educational activities in countries around the world. These include training and lectures, providing safe and appropriate directions for the use of dental lasers, as well as its international congress.

Every two years, the WFLD holds an international congress at a major city. In 2016, the 15<sup>th</sup> Congress of the WFLD will take place in Nagoya, Japan, hosted by honorary presidents Hajime Yamamoto and Isao Ishikawa as well as Kenji Yoshida, Chair of Organising Committee. The congress theme is "Light to brighten the future", in an effort to move ahead from existing laser dentistry and dental care, and to look at new developments by incorporating "light" into all diagnosis and treatment. The congress programme includes: specialist lectures, symposiums, workshops, oral and poster sessions, seminars and an extensive dental exhibition. The 15<sup>th</sup> WFLD Congress will be held from 17 to 19 July 2016, bringing together laser specialists in engineering and medical fields, including dentistry, from countries around the world. It is hoped that the congress will also serve as an opportunity for further advancement of academic research activities and clinical improvement. In addition, it aims at heralding



the beginning of new development of medical devices and new expansion of the industry in Japan, providing an extensive platform for information on all aspects of the dental laser industry in its dental exhibition.

### WFLD2016 Secretariat

c/o Convention Linkage, Inc.  
Asahiseimei Bldg., 3-32-20 Sakae,  
Naka-ku, Nagoya, 460-0008 JAPAN  
wfld2016@c-linkage.co.jp  
www.c-linkage.co.jp/wfld2016

FOTONA

## LightWalker with biomodulation

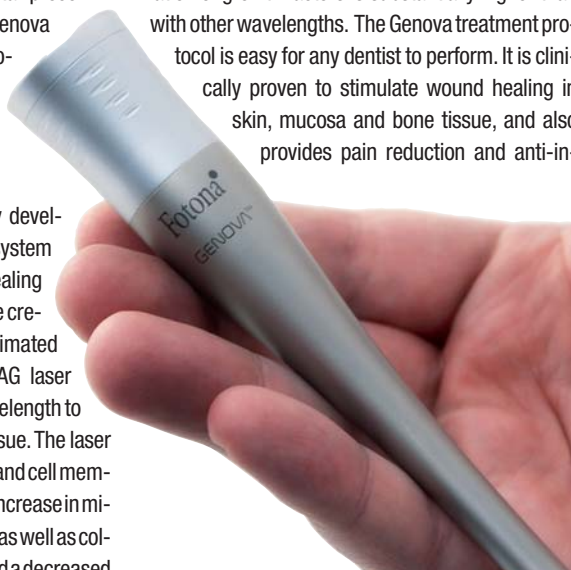
Fotona's award-winning LightWalker dental laser is widely recognised as a powerful system that enables an exceptionally broad range of dental procedures. And now with Fotona's new Genova handpiece, LightWalker also offers biomodulation capabilities, which can be an ideal complement to many surgical procedures.

The Genova handpiece was specially developed for Fotona's LightWalker laser system for inducing highly effective wound healing and pain reduction. The new handpiece creates a large spotsize with a unique collimated homogeneous beam profile of Nd:YAG laser light, which is the optimal infrared wavelength to penetrate homogeneously into soft tissue. The laser light is absorbed into the mitochondria and cell membranes of the target cells, leading to an increase in mitotic activity and number of fibroblasts, as well as collagen synthesis, neovascularisation and a decreased

level of pain. The effect of the Nd:YAG wavelength on the healing of injuries and lesions through the stimulation of growth factors is substantially higher than with other wavelengths. The Genova treatment protocol is easy for any dentist to perform. It is clinically proven to stimulate wound healing in skin, mucosa and bone tissue, and also provides pain reduction and anti-inflammatory effects.

And the new Genova handpiece, with its unique beam profile, treats affected areas with exceptional precision and control.

About Fotona: Founded in 1964, only four years after the invention of the very first laser, Fotona is one of the most experienced developers of high-technology laser systems, recognized for the design, manufacture, and support of advanced solid-state laser systems for: medicine (aesthetics, surgery, gynecology), dentistry, industry & defense. Fotona is fully committed to stringent testing of all components and in-house production of its medical and dental laser systems. This long-term dedication to perfection ensures that the company's laser systems are of the highest quality, reliability and durability.



### Fotona

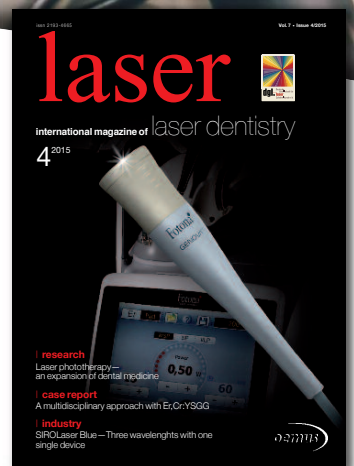
Stegne 7  
1000 Ljubljana, Slovenia  
www.fotona.com

Dear authors, thank you for your contributions in 2015.

Looking forward to working with you in 2016!

To publish, please contact:

Georg Isbaner  
Editorial manager  
g.isbaner@oemus-media.de



# SIROLaser Blue— Three wavelengths with one single device

Author\_Marlene Hartinger, Germany



Fig. 1

Fig. 1 All participants of the 2<sup>nd</sup> Sirona Laser Days.

## \_Dental diode lasers

The use of laser in dentistry has steadily grown over the past decades as lasers have repeatedly proven to be powerful surgical tools for both hard and soft tissue applications. There is no discipline in dentistry that does not benefit from the advantages of laser therapy. Among dental lasers currently available, diode lasers have become particularly popular due to their compact size, versatility and relatively affordable pricing. Diode lasers use a semiconductor stimulated by electricity to produce laser light and enable practitioners to perform less invasive procedures with greater patient comfort. Swelling, scarring and post-operative pain is considerably minimised and wounds and tissue heal faster. In addition, dental diode lasers effectively reduce the level of oral germs and bacteria. Compared to traditional procedures, diode lasers lessen stress and anxiety in patients uncomfortable with conventional instruments such as dental drills and therefore lead to a higher patient satisfaction. Ultimately, as the right instruments are crucial for the success of a treatment and hence of a practice, both dentists as well as patients profit greatly from the predictable outcome of dental laser applications.

## \_Three wavelengths—one device

At this year's IDS in Cologne, Sirona introduced SIROLaser Blue, the first dental diode laser with a blue, infrared and red diode. By providing three wavelengths (445 nm, 970 nm, 660 nm) with one single device, SIROLaser Blue enables a spectrum of 21 indications including frenectomy, fibroma, gingivoplasty, tissue management and haemostasis. The blue laser light at a wavelength of 445 nm is used in soft-tissue surgery because it is absorbed more effectively by tissue compared to infrared laser light. Due to its shorter wavelength, it does not penetrate deeply in surgery and has consequently less effect on surrounding tissue. The blue laser makes it possible to work in a non-contact mode, achieving substantially better cutting results at a lower power than infrared laser light at a higher power rating. Additionally, the blue laser light interacts better with haemoglobin, a complex protein found in the red blood cells of the body, and is therefore ideal for e.g. the treatment of vascularised tissue. The infrared light in wavelengths of 970 nm can be utilised for conventional, germ-reducing indications in endodontics and periodontics, e.g. for the treatment of connective



Fig. 2



Fig. 3

**Fig. 2** During a tour of his practise, Prof. Giuseppe Iaria explained various laser applications he and his son, Dr. Matteo Iaria, offer at their laser clinic in Brescia.

**Fig. 3** Two key members of the international laser community: Prof. Giovanni Olivi (Rom) and Prof. Andreas Braun (Marburg)

and very dense fibrous tissue. The additional third diode with wavelengths of 660 nm is used for "soft-laser" applications such as low level laser therapy (LLLT), also known as therapeutic laser treatment, and biostimulation/tissue regeneration. Laser biostimulation affects the cellular metabolic processes by providing the body with a better inflammatory response and helps to speed up the healing of post-operative wounds.

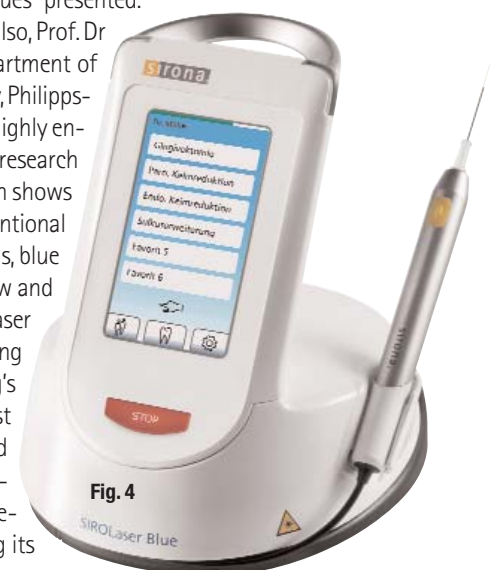### 2<sup>nd</sup> Sirona Laser Days in Brescia

To actively promote the advantages of SIROLaser Blue as one of a kind and to provide the laser community with the opportunity to meet peer-to-peer and to exchange and share their knowledge and experiences regarding the new laser device, Sirona invited 28 experienced laser users and leading laser scientists from 13 countries to Villa Fenaroli in Rezzato, Brescia/Italy, at the beginning of October. The exclusive 2-day programme of the Second Sirona Laser Days included presentations of various clinical cases using diode laser in everyday working routine, workshops and, as the highlight of the user meeting, a live laser treatment. The treatment comprised a frenectomy and fibrotic lesion on the tongue performed by Prof. Giuseppe Iaria, a pioneer and expert in the field of digital/laser dentistry, and was broadcast via livestream from his practice in Brescia. Prior to the live treatment, the participants of the event had the unique opportunity to tour Prof. Iaria's impressive, high-tech laser clinic in the heart of Brescia and to pose questions regarding his many and varied laser applications. In 1996, Dr Iaria was the first user in Europe and one of the first users worldwide of a hydrokinetic laser for dental care. In 2001, he introduced the first diode laser in his practice and now offers 15 medical and surgical lasers, microscopy-based and CEREC CAD/CAM treatments. When asked about the "magic" of lasers, Prof. Iaria highlighted three aspects that, in his opinion, must be carefully considered when utilising lasers as they play a vital role in achieving the best possible treatment results: the correct

wavelength for the intended treatment, the components of the target tissue and the knowledge and capability of the practitioner.

### The all-rounder: SIROLaser Blue

Prof. Giovanni Olivi from Rome, one of the two patrons of this year's user meeting and a long-standing expert in the field of laser dentistry, considers the blue laser's outstanding cutting performance in soft-tissue surgery as one of its unrivalled advantages. Due to its coagulation effects, the SIROLaser Blue is an excellent instrument to cut fast, precisely and in an atraumatic way; that makes it particularly suitable for laser procedures such as gingivectomies and frenectomies as well as low-bleeding implant exposure in minimally invasive surgery. According to Prof. Olivi, the infrared laser light at 970 nm particularly supports the conventional root canal treatment by reducing germs and bacteria in areas rinsing solutions cannot reach. In addition, infrared laser light proves to be very effective in treating aphthae and recurrent herpes infections. Summing up the two "Laser days" in Brescia, Prof. Olivi was highly impressed by the promising results his colleagues presented. Among the participants in Brescia was also, Prof. Dr Andreas Braun, Chief Consultant, Department of Operative Dentistry and Endodontology, Philipps-University Marburg. He presented the highly engaged audience with his latest scientific research on diode laser applications. His research shows in particular that, compared to conventional semiconductor lasers in infrared regions, blue laser technology marks a genuinely new and highly promising advancement in laser dentistry. The scientific data originating from studies carried out at Marburg's Philipps University demonstrate the fast and reliable elimination of germs and bacteria during periodontic and endodontic treatments. Furthermore, results from additional studies regarding its



**Fig. 4** SIROLaser BLUE.

Fig. 4





Fig. 5

**Fig. 5** An impressive congress venue dating back to the XVIII century: Villa Fenaroli in Rezzato, Brescia.

potential use in orthodontic treatments strongly imply future indications of SIROLaser Blue, e.g. the removal of ceramic brackets. Possible side effects of diode laser in infrared ranges, such as carbonisation at wound edges, can largely be avoided. Instead, as various cases have shown, wounds heal with no any scar formation. Due to the blue laser's low penetration depth, unintentional injuries of deeper tissue layers are effectively minimised while the laser beam can be accurately focused to create a precise coagulation. Ultimately, the use of blue laser helps not only to reduce local anaesthesia, but may dispense it altogether.

### Summary

All participants of the user meeting in Brescia agreed on the many benefits of SIROLaser Blue: its cut-

ting performance providing patients with a fast and atraumatic treatment experience, its effective reduction of bacteria and germs which makes it an excellent instrument for endodontic and periodontic applications as well as its coagulating effect which enables the user to cut with as little loss of blood as possible.

### **contact**

#### **Sirona – The Dental Company**

Fabrikstraße 31  
64625 Bensheim, Germany  
Tel.: +49 625 116-0  
Fax: +49 625 116-2591  
contact@sirona.com  
www.sirona.com

### **Kurz & bündig**

Auf der diesjährigen IDS in Köln stellte das Unternehmen Sirona eine richtungsweisende Produktneuheit vor: Der kompakte SIROLaser Blue ist der erste dentale Diodenlaser mit einer blauen, infraroten und roten Diode. Dadurch ermöglicht er eine Bandbreite von 21 Indikationen und eine Vielzahl von Einsatzmöglichkeiten im Praxisalltag. Im Vergleich zu konventionellen Behandlungsmethoden überzeugen Diodenlaser in der Zahnheilkunde durch eine meist narbenfreie Wundheilung und eine deutlich verbesserte Keimreduktion, vor allem in schwer erreichbaren Bereichen. Darüber hinaus reduziert die Laseranwendung postoperative Schmerzen und verringert so die Notwendigkeit von schmerzmindernden Medikamenten.

Vom 8. bis 10. Oktober dieses Jahres lud Sirona 28 ausgewählte Laseranwender und führende Wissenschaftler der Laserzahnheilkunde zu den zweiten Sirona Laser Days ins oberitalienische Brescia ein. Das Zwei-Tage-Programm ermöglichte es der internationalen Laser-Community, sich (weiter) kennenzulernen und sich über ihre bisherigen Erfahrungen mit dem SIROLaser Blue rege auszutauschen. Ein besonderes Highlight der Veranstaltung war die Live-Behandlung von oralen Fibromen sowie einer Durchtrennung des Lippenbändchens, welche aus der Klinik von Prof. Giuseppe Iaria, einer der Schirmherren des diesjährigen Anwendertreffens, übertragen und als Livestream über das Internet weltweit ausgestrahlt wurde. Die Live-Behandlung bestätigte die in Brescia wiederholt erörterten Vorteile des SIROLaser Blue: seine koagulierende Wirkung, seine vorzügliche, präzise Schneidleistung, die ungewollte Auswirkungen auf umliegendes Gewebe deutlich begrenzen, und seinen keimreduzierenden Effekt. Das Fazit der Veranstaltung ist damit ausgesprochen positiv: mit dem Einsatz des SIROLaser Blue entscheiden sich Zahnärzte für eine nachweislich sichere wie innovative, den Patientenkomfort deutlich steigernde Behandlungsmethode, die ihr Indikationsspektrum noch lange nicht ausgeschöpft hat.

**SAVE  
THE DATE**

**25<sup>th</sup> International Annual  
Congress of the DGL  
LASER START UP 2016**



**30 September – 1 October 2016  
Munich | The Westin Grand Hotel**



**Fax Reply**

**+49 341 48474-290**

I would like to receive further information on the

25<sup>th</sup> Annual Congress of the DGL e.V.     **LASER START UP 2016**

30 September – 1 October 2016 in Munich, Germany.

Name & email address

Practice Stamp

laser 4/15



# Infection control in an era of emerging infectious diseases

Author\_Eve Cuny, USA

[PICTURE: ©MELODIA PLUS PHOTOS]

**More than three decades** have passed since the emergence of human immunodeficiency virus (HIV) as a global pandemic. More than any other infection, it is possible to single out HIV as the primary stimulus for changing infection control practices in dentistry. Prior to the mid-1980s, it was uncommon for dentists and allied professionals to wear gloves during routine dental procedures. Many dental clinics did not use heat sterilisation, and disinfection of surfaces was limited to a cursory wipe with an alcohol-soaked gauze sponge. This was despite our knowledge that hepatitis B virus (HBV) had been spread in clusters in the offices and clinics of infected dentists and that dentists were clearly at occupational risk for acquiring HBV.

Today, many take safe dental care for granted, but there is still reason to remain vigilant in ensuring an infection-free environment for providers and patients. HIV has fortunately proven to be easily controlled in a clinical environment using the same precautions as those effective for preventing the transmission of HBV and hepatitis C virus.<sup>1</sup> These standard precautions include the use of personal protective attire, such as gloves, surgical masks, gowns and protective eyewear, in combination with surface cleaning and disinfection, instrument sterilisation, hand hygiene, immunisations and other basic infection control precautions. Sporadic reports of transmission of blood-borne diseases associated with dental care continue, but are most often linked to breaches in the practice of standard precautions.<sup>2</sup>

Emerging and re-emerging infectious diseases present a real challenge to all health care providers. Three of the more than 50 emerging and re-emerging infectious diseases identified by the Centers for Disease Control and Prevention and the World Health Or-

ganization (WHO) include Ebola virus disease (EVD), pandemic influenza and severe acute respiratory syndrome.<sup>3,4</sup> These previously rare or unidentified infectious diseases burst into the headlines in the past several years when they exhibited novel or uncharacteristic transmission patterns.

Concern about emerging infectious diseases arises for several reasons. When faced with a particularly deadly infectious disease such as EVD, which can be spread through contact with an ill patient's body fluids, health care workers are naturally concerned about how to protect themselves if an ill patient presents to the dental clinic. With diseases such as pandemic influenza and severe acute respiratory syndrome, which may be spread via inhalation of aerosolised respiratory fluids when a patient coughs or sneezes, the concern is whether standard precautions will be adequate.

In addition to standard precautions, treating patients with these diseases requires the use of transmission-based precautions. These encompass what are referred to as contact, droplet and airborne precautions for diseases with those specific routes of transmission. Transmission-based precautions may include patient isolation, placing a surgical mask on the patient when he or she is around other people, additional protective attire for care providers, and in some cases the use of respirators and negative air pressure in a treatment room. In most cases, patients who are contagious for infections requiring droplet or airborne precautions should not be treated in a traditional dental clinic setting.

Updating a patient's medical history at each visit will assist dental health professionals in identifying

patients who are symptomatic for infectious diseases. Patients with respiratory symptoms, including productive cough and fever, should have their dental treatment delayed until they are no longer symptomatic. Additionally, health care professionals who are symptomatic should refrain from coming to work until they have been free of fever without taking fever-reducing medication for 24 hours.

In most cases, a patient with symptoms as severe as those experienced with EVD will not present for dental care and therefore extraordinary screening and protection protocols are not recommended. If a patient is



[PHOTO: GETTY IMAGES]

suspected of having a highly contagious disease, he or she should be referred to a physician, hospital or public health clinic.

Dental professionals should take action to remain healthy by being vaccinated according to accepted public health guidelines, understanding that the recommendations may differ according to country of residence. Performing hand hygiene procedures at the beginning of the day, before placing and after removing gloves, changing gloves for each patient, wearing a clean mask and gown or laboratory coat, and wearing protective eyewear are all positive actions that help prevent occupational infections. In addition, cleaning and heat sterilisation of all instruments and disinfection of clinical surfaces ensure a safe environment for patients. There is solid evidence that dental care is safe for patients and providers when standard precautions are followed, but patients and dental health care workers are placed at risk when precautions are compromised and breaches occur.

*Editorial note: A list of references is available from the publisher.*

## contact

**Eve Cuny**  
2155 Webster Street  
San Francisco, CA  
USA  
ecuny@pacific.edu

### Kurz & bündig

Seit dem Auftreten des HI-Virus vor dreißig Jahren haben sich Maßnahmen zur Infektionskontrolle in Zahnarztpraxen stark verändert. War es davor i. d. R. unüblich, bei zahnärztlichen Routineprozeduren Handschuhe zu tragen oder eine Hitzesterilisation durchzuführen, so werden heutzutage solch einfache Hygienevorkehrungen vorausgesetzt. Mittlerweile lässt sich HIV mit den Standardvorsichtsmaßnahmen in der Klinik und Praxis gut kontrollieren. Eine Herausforderung stellen dagegen neu auftauchende und wieder auftauchende Infektionskrankheiten dar, wie das Ebola-Virus (EVD), Grippepandemien und das Schwere Akute Respiratorische Syndrom (SARS). Standardmaßnahmen sind dabei oftmals nicht ausreichend.

Zusätzliche Vorkehrungen hier betreffen Maßnahmen, die eine Übertragung der Erreger durch Kontakt, Tröpfchen oder über die Luft verhindern. Dies sind Patientenisolation, Aufsetzen einer chirurgischen Maske beim Patient bei Kontakt mit anderen Menschen, zusätzliche schützende Kleidung beim Behandlungspersonal und in manchen Fällen die Verwendung von Atemschutzmasken sowie Luftunterdruck im Behandlungsraum. Patienten mit einer hochgradig ansteckenden Erkrankung wie EVD werden jedoch selten in Zahnarztpraxen vorstellig und sollten im Fall der Fälle an einen Arzt oder in ein Krankenhaus überwiesen werden.

Generell sollten Zahnärzte darauf achten, gemäß der regional akzeptierten Gesundheitsrichtlinien einen ausreichenden Impfschutz zu haben, auf eine regelmäßige Handhygiene zu achten, vor jedem neuen Patienten Handschuhe zu wechseln, eine saubere Maske und Kittel sowie einen Augenschutz zu tragen. Zusätzlich gehört die Reinigung und Hitzesterilisation aller Instrumente und das Desinfizieren der Behandlungsoberflächen zur Vorsorge. Auf diese Weise kann eine sichere Behandlungsumgebung für das Behandlungsteam sowie den Patienten sichergestellt werden.



# Laser treatment of sleep apnoea and snoring

Author\_Dr Andreas Klug, Germany

**It has become common knowledge** that lasers of different wavelengths can trigger varying reactions in tissues which are only reactive at a distinct wavelength. In addition, the intensity of those reactions at each special wavelength can be modified by changing the physical parameters of those monochromatic laser waves.

## **Tackling snoring noise on a cellular level**

The typical snoring noise familiar to most of us is a result of the soft palate vibrating with each breath after becoming relaxed when one falls asleep. This phenomenon of the general tissue relaxation during sleep only becomes a health risk when the tongue slips back to such an extent that the throat is sealed completely, thus blocking the respiratory tract.

As a consequence of respiratory arrest due to sleep apnoea, the body runs its own emergency pro-

gramme—we wake up with a jolt and gasp for breath. If episodes of this kind happen frequently, the oxygen level of the blood drops below a critical value. This usually leads to the obligatory respiratory mask during sleep, which many patients resent.

In these cases, a special Er:YAG-laser programme can help, which tightens relaxed tissues by simply illuminating them. This can be illustrated to the patient by alluding to the image of the cement ceiling of a building in which the iron reinforcement is missing.

## **Explaining laser therapy to the patient**

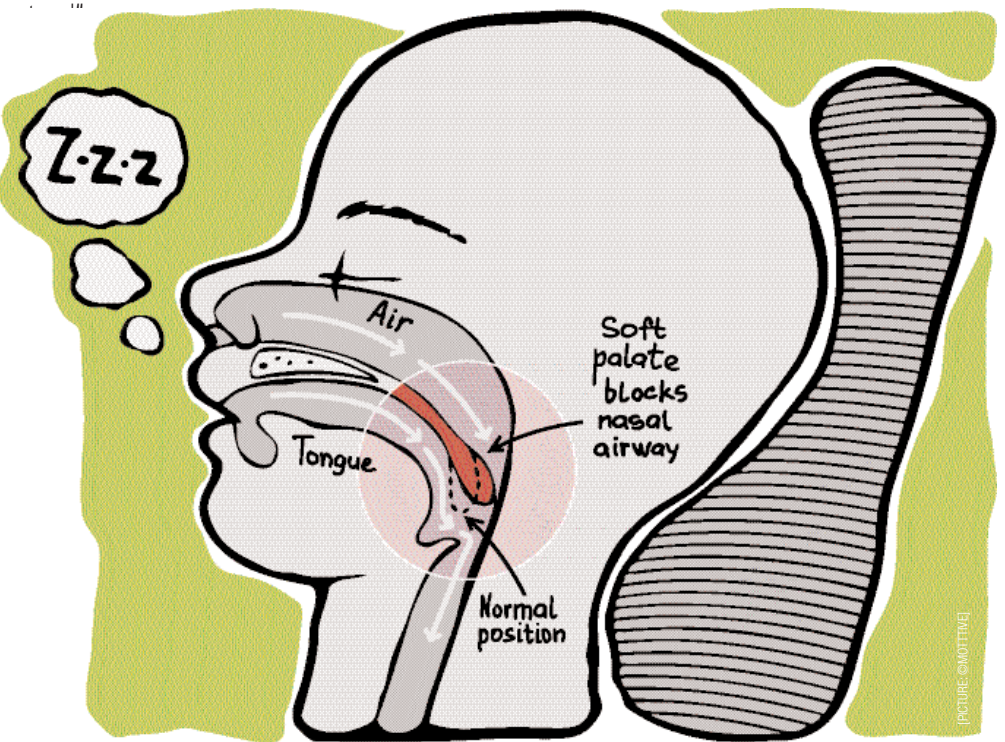
The laser forms a standing wave in the tissue, along which tissue cells are clustering—just as iron powder would cluster along the magnetic field of a magnet in a school experiment. Of course, I tell my patients, cells cannot move like iron filings. For this

reason, the laser needs more than one treatment session to become fully effective. In the course of 45 minutes, the cells are furnished with the correct amount of energy to rebuild the desired fixed "iron bar" structure. When talking to patients, I like to refer to an image of a chain of people with linked arms.

This image shows that nothing „ur or painful like burning, etching or scar happen during laser treatment. Or the contrary, the cells determine what will happen: laser treatment of the palate is a natural reaction of a group of tissue cells to a wavelength, just as the inner ear's cilia respond to sound waves.

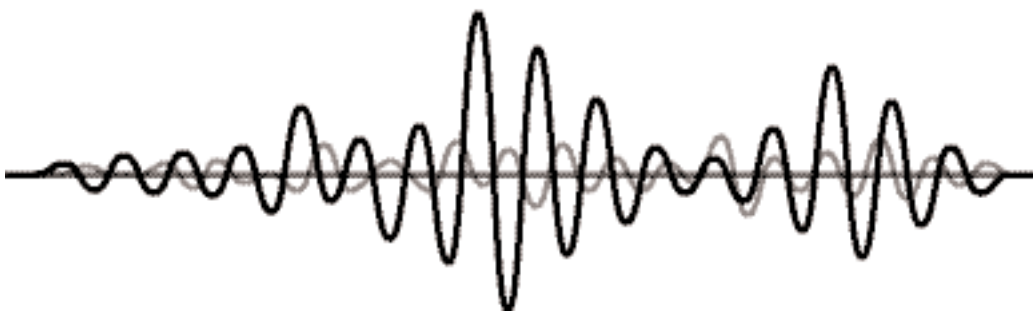The cellular reaction of the tissue soft-palate and the parapharyngea leads to the desired tightening of the tissue. When patients ask me how many sessions will be necessary, I ask them how they think they would have to be at a centre to train their muscles. This is how I tell them that there is no simple answer to this question, as many aspects, such as the condition of the tissue (trained or puffy) or the patient's age will influence the treatment. However, they happily accept my statement and reply that three to four sessions are sufficient for 85 to 92 % of all cases. In addition, I always point out that this means that while one case can be treated in only three sessions, another might take five or six appointments to achieve the desired cellular reaction. Many patients agree to give their age and weight in order to extend my statistical database. Another psychological advantage of this treatment method is that the patient is in charge of ending the treatment. He or she (women are less frequently affected by sleep apnoea) is therefore al-

“ The **typical snoring noise** familiar to most of us is a **result** of the **soft palate vibrating** with each breath after **becoming relaxed** when one **falls asleep**. ”



ways in full control. This includes the financial aspect. Sometimes intense question and answer sessions of the above kind, in combination with the assessment of findings with regard to the anatomical pharynx classification (I-IV), form the content of the first appointment. At the end of this session, also the payment modalities are discussed. Billing specifics for German dentists can be found below in the section "Kurz & bündig".

“ **Laser treatment** of the palate is a **natural reaction** of a group of tissue cells to a wavelength, just as the **inner ear's cilia** respond to **sound waves**. ”



## Legal aspects

From a legal point of view, I conclude that this kind of treatment does not constitute a bodily injury, as the body surface is neither cut nor injured. Since the legal act of bodily injury is not given, the execution of the treatment is not restricted to specially-trained personnel, but can be delegated.

So far, the treatment results have confirmed the effectiveness of this special kind of laser application, especially when it comes to the final survey of my patients—"highly recommended" usually is their verdict. This anti-snoring therapy is one of the few medical treatment methods without any known side effects. Even if the therapy should not have any success, it will not cause any harm either—and that is one positive aspect I do not want to miss. I therefore think that this new kind of therapy should be advertised widely, especially since announcing new types of therapy is explicitly granted to medical professionals in Germany by the Federal Supreme

Court. From a legal point of view, this is not classified as advertisement, a fact that protects us from any unwanted adverse reactions, such as formal warnings. Please see paragraph "Kurz & bündig" below for further information with regard to the German law.

All in all, laser treatment of sleep apnoea and snoring is a promising new therapy, and most certainly a last resort for some troubled sleeping arrangements.

## **contact**

**Dr Andreas Klug**  
 Weißhoferstraße 65–67  
 75015 Bretten  
 Germany  
 Tel.: +49 7252 958282  
 kdrklug@t-online.de  
 www.drklug-zahn.de

### **Kurz & bündig**

Ausgehend von den Wirkprinzipien unterschiedlicher Laserwellenlängen in verschiedenen Gewebearten beschreibt der Autor die theoretischen Grundlagen hinter der lasergestützten Therapie von Schnarchen und Schlafapnoe. Dabei geht er besonders darauf ein, wie diese dem Patienten erklärt werden können, ohne in die oft schwer verständlichen Fachtermini zu verfallen. Als Vorteile der lasergestützten Therapie aus Patientensicht wird hervorgehoben, dass der Patient die gesamte Zeit die Kontrolle über die Vorgänge behält – er bestimmt, wie viele Sitzungen notwendig sind, bis das gewünschte Behandlungsergebnis erreicht ist, und damit hat er volle Kontrolle über die Kosten dieser innovativen Behandlung.

Für deutsche Anwender hat der Autor zudem auch die juristischen Aspekte dieser Laseranwendung erörtert. Er beschreibt, warum diese aus seiner Sicht den juristischen Akt einer Körperverletzung nicht erfüllt und deshalb auch an geschultes Fachpersonal delegiert werden kann. Auch die Werbung für diese Behandlungsmethode werde nicht durch Mahnungen geahndet, da der Bundesgerichtshof es Medizinern explizit gestattet, auf neue Behandlungsverfahren hinzuweisen. Weiterhin schreibt der Autor:

„Während es für die Zuständigkeit u.a. der ZMK auch für den weichen Gaumen keinerlei Probleme geben sollte, könnte sich juristisch fragwürdig in diesem Zusammenhang ggf. nur die mit dem zurzeit auf dem Markt befindlichen Gerät auch mögliche Anti-Falten-Therapie der Naso-Labial-Falte oder von Falten an der Oberlippe darstellen. Hier befindet sich zwar der mögliche Ausgangspunkt der Bestrahlung innerhalb des Mundes – und damit auch innerhalb der Zuständigkeit eines Zahnmediziners –, das Zielgebiet liegt jedoch eindeutig außerhalb des gerichtlich für uns Zahnmediziner als Behandlungsgrenze definierten Lippenrots. So etwas müsste ggf. gerichtlich geklärt werden.“

Schließlich gibt der Autor deutschen Anwendern die folgenden Abrechnungshinweise, die aufgrund der Anwendbarkeit im englischen Text nicht berücksichtigt wurden:

„Am Ende der Sitzung muss der Kassenpatient ein vorbereitetes Formular nach §4(5) BMV-Z bzw. §7(7) EKV-Z (= Vereinbarung einer Privatbehandlung) bzw. als Privatversicherter eine Vereinbarung einer Analogleistung nach §6(1) unterzeichnen. Ihm wird beschieden, er solle zuerst eine Nacht darüber schlafen und dann Termine ausmachen. Damit ist auch den Erfordernissen des Patientenrechtenschutzgesetzes Genüge getan. Berechnet wird diese erste Sitzung nach Ä5 und Ä34.“

Die eigentliche Laserbehandlung ist analog zu berechnen, muss also vom Behandler selbst herausgesucht werden, je nach betriebswirtschaftlichem Aufwand. Ich selbst berechne nach Ä2074a mit Einfachsatz zuzüglich der Zuschläge Ä441 und Ä444. Insofern habe ich immer Luft nach oben, sollten sich irgendwelche Erschwernisse während der Behandlung ergeben.“

**Return address**

Deutsche Gesellschaft für Laserzahnheilkunde e.V.  
c/o Universitätsklinikum Aachen  
Klinik für Zahnerhaltung  
Pauwelsstraße 30  
52074 Aachen, Germany

Tel.: +49 241 8088164  
Fax: +49 241 803388164  
Credit institute: Sparkasse Aachen  
IBAN: DE56 3905 0000 0042 0339 44  
BIC.: AACSD33

## Membership application form (English)



Name/title: \_\_\_\_\_

Surname: \_\_\_\_\_

Date of birth: \_\_\_\_\_

Approbation: \_\_\_\_\_

Status:  self-employed  employed  civil servant  student  dental assistant

Address: Practice/office/institute (delete as applicable)

ZIP/city: \_\_\_\_\_ Street: \_\_\_\_\_

Phone/fax: \_\_\_\_\_ Email: \_\_\_\_\_

Private/place: \_\_\_\_\_ Street: \_\_\_\_\_

Due to an association agreement of DGL and DGZMK, an additional reduced annual fee for DGZMK is charged (85 EUR p.a. if you are not yet a member of DGZMK). The contribution collection is made by the DGMZK office, Liesegangstr. 17a, 40211 Düsseldorf, Germany. You will be addressed hereby.

With the application for membership I ensure that

I am owing an own practice since \_\_\_\_\_ and are working with the laser type \_\_\_\_\_ (exact name)

I am employed at the practice \_\_\_\_\_

I am employed at the University \_\_\_\_\_

I apply for membership in the German Association of Laser Dentistry (Deutsche Gesellschaft für Laserzahnheilkunde e.V.)

Place, date \_\_\_\_\_ Signature \_\_\_\_\_

Annual fee: for voting members with direct debit € 150

In case of no direct debit authorisation, an administration charge of €31 p/a. becomes due.

DIRECT DEBIT AUTHORISATION

I agree that the members fee is debited from my bank account

Name: \_\_\_\_\_ IBAN: \_\_\_\_\_

BIC: \_\_\_\_\_ Credit institute: \_\_\_\_\_

Signature of account holder

This declaration is valid until written notice of its revocation



# Eleven tips for success in your dental clinic

## Part II: CAPS & CLIMB

Author\_Dr Anna Maria Yiannikos, Germany & Cyprus



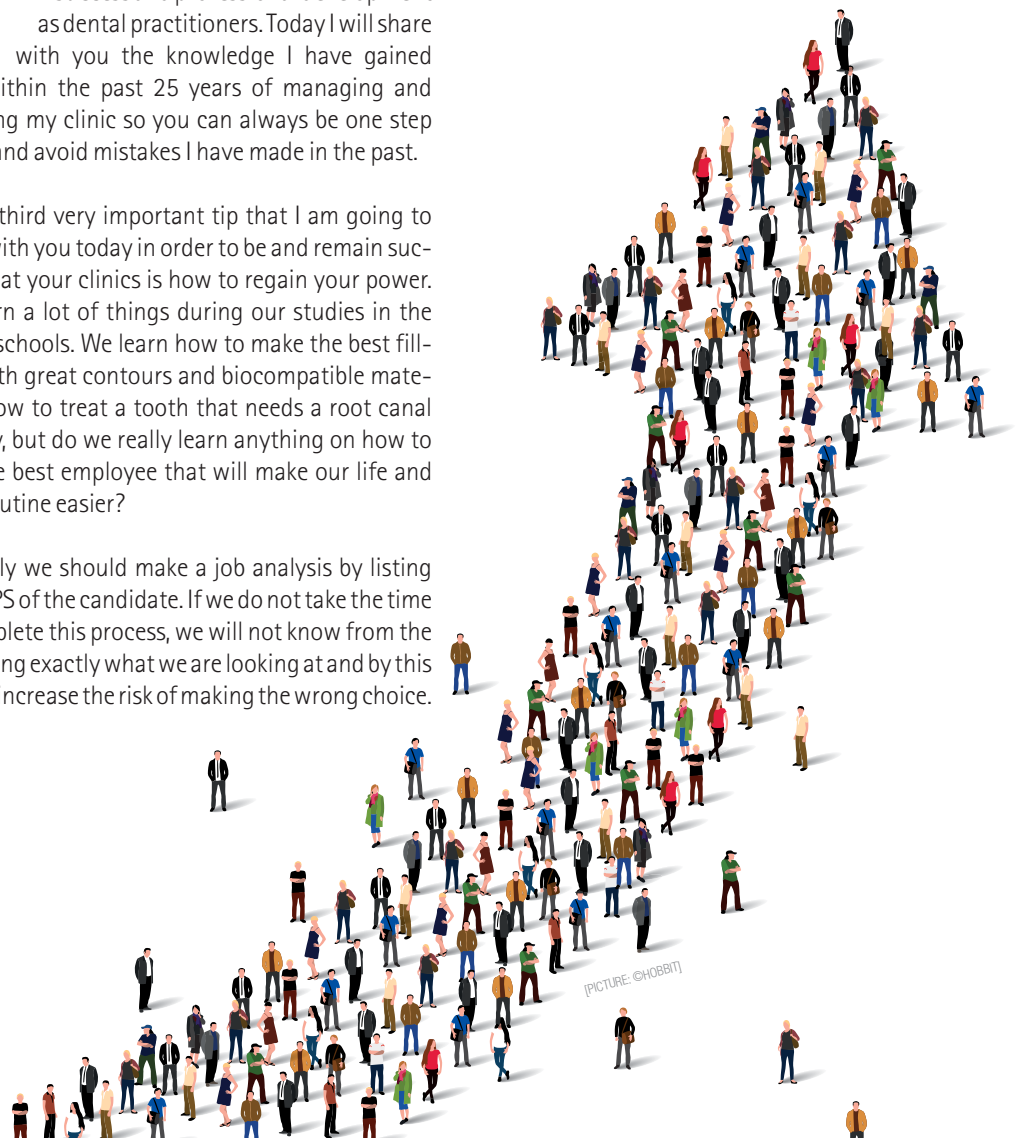After the last issue of *laser international magazine of laser dentistry*, we have begun a new journey with our brand new series "Eleven tips to gain desirable success in our dental clinics". In this publication, we are going to continue exploring different parameters that can reinforce our success and professional development as dental practitioners. Today I will share with you the knowledge I have gained within the past 25 years of managing and evolving my clinic so you can always be one step ahead and avoid mistakes I have made in the past.

The third very important tip that I am going to share with you today in order to be and remain successful at your clinics is how to regain your power. We learn a lot of things during our studies in the dental schools. We learn how to make the best fillings with great contours and biocompatible materials; how to treat a tooth that needs a root canal therapy, but do we really learn anything on how to find the best employee that will make our life and daily routine easier?

Firstly we should make a job analysis by listing the CAPS of the candidate. If we do not take the time to complete this process, we will not know from the beginning exactly what we are looking at and by this we will increase the risk of making the wrong choice.

If, for example, we go to the supermarket without our shopping list, what will we end up doing? We will most probably buy unnecessary things or even forget the things that we went in the beginning there for.

My point here is that when we decide that we need to hire an employee we should know upfront



what we are looking for, otherwise we might make mistakes that will cost us money and time!

Let's have a look now what does CAPS stand for:

- Capacities: The mental and physical abilities required to do the job. How smart and how strong (physically capable) must the successful applicant be?
- Attitudes: such as customer service, orientation, team player, reliability, honesty, willingness to follow rules, problem-solving, loyalty, safety-consciousness, ability to follow through—Imagine having a receptionist who, although she is doing the job without a mistake, complains about everything all the time. Is that a person that you would love to have as part of your team?
- Personality: traits such as competitiveness, assertiveness, attention to detail and sociability—Also search whether the person will manage his or her personality to get the job done, since as social scientists declare about 60 per cent of our personality traits are inherited and most of them are set by age nine. In other words: personality can't be taught and it doesn't change much over time.

- Skills: Expertise required to do the job—Skills are the easiest job requirements to identify. We could do that by asking the candidate to perform certain tests. For example, if we are trying to find a receptionist we could ask her to translate an article, or through role playing to check how she responds in certain scenarios.

Have always in mind the quote 'we hire them for the skills but we fire them for their attitudes'!

So finally we found our A-star employees and now what do we have to do in order to keep them? The fourth very essential tip of today's article that I would love to share with you is the different ways that we can use to retain our A-star employees. Apply CLIMB to retain your team!

Now let's explain a little what does exactly the acronym CLIMB stands for:

- Challenge: Studies have shown that the main reason that our employees resign is that they are dissatisfied with their tasks. That's why we should

[PICTURE: ©SUNNY STUDIO]



give them challenging duties to accomplish. And what will the result be? They will feel useful and they will find it difficult to leave from a job that offers them different and unique experiences.

- Loyalty: Be human with your employees and do not be afraid that you will lose your power. Show interest in their problems and lay back in times that they cannot handle any more pressure.
- Investment: Invest time and money to them so they will feel appreciated. During my lectures I get regularly the question that we reward them by giving them bonus and still they are not motivated enough, what shall we do? My answer here is that you must renew your reward system regularly. Sometimes you can give them cash (as bonuses) or maybe you can offer them other kind of incentives, like buying them a free trip for vacation on Christmas, for example. Research has proven that the more powerful and effective incentives are the ones that that are specific, tangible and noncash. Also please remember to 'Reward not the best in sales but the best' A major mistake that we usually do is to only reward the ones that bring money to our clinics. Instead we should reward the best in our practices, the ones that are completing their tasks in excellence unconditionally to what this task is.
- Measurement: Conduct a fair performance appraisal every six months.

- Building: Demonstrate your commitment to them by showing them opportunities of career development.

During the next issue we will analyse two new tips that will reveal new opportunities and potential of our dental clinics. Till then, remember that not only are you the dentist in your clinic, but you are also the manager and the leader.

You can always send me your questions and request for more information and guidance at: [dba@yiannikosdental.com](mailto:dba@yiannikosdental.com) or via our Facebook account. Looking forward to our next trip of business growth and educational development!\_

## contact



### Dr Anna Maria Yiannikos

Adjunct Faculty Member of AALZ at RWTH Aachen University Campus, Germany  
DDS, LSO, MSc, MBA

[dba@yiannikosdental.com](mailto:dba@yiannikosdental.com)  
[www.dbamastership.com](http://www.dbamastership.com)

## Kurz & bündig

*Im ersten Teil der Serie "11 Tipps zum wünschenswerten Erfolg in Zahnkliniken" wurden die ersten beiden Ratschläge dieser Reihe vorgestellt, um Anfängerfehler zu verhindern und langfristigen Erfolg zu erzielen.*

Der erste Tipp befasste sich mit der intensiven Auseinandersetzung mit dem Praxisinhaber selbst, seinen Fähigkeiten, Schwächen und Stärken. Der zweite Tipp hatte die Frage zum Ziel, wie man es schafft, nicht nur zufriedene, sondern vor allem loyale Patienten zu haben.

In der nun vorliegenden Fortsetzung der Artikelserie konzentriert sich die Autorin darauf, wie man den idealen Praxismitarbeiter findet und auch hält. So legt Tipp Nr. 3 ausführlich dar, wie man mithilfe von vier Schlüsselqualifikationen den geeigneten Mitarbeiter auswählt. Hierbei sollte man neben den geistigen und körperlichen Anforderungen (capacities), der Arbeitseinstellung (attitude) und der Persönlichkeit (personality) des Bewerbers dessen individuelle Fähigkeiten berücksichtigen. Hat man so einen geeigneten Mitarbeiter ermittelt, kann man sich mithilfe des vierten Tipps der Aufgabe zuwenden, diesen Mitarbeiter zu halten und zu motivieren.

Dafür gibt die Autorin ihren Lesern fünf einfache Maßnahmen mit auf den Weg: eine berufliche Herausforderung (challenge) und Interesse am Mitarbeiter als Mensch und nicht als reine Arbeitskraft (loyalty) können neben finanziellen Anreizen (investment) motivieren. Zudem geben eine regelmäßige Evaluierung (measurement) der individuellen Leistungen und Erfolge des Mitarbeiters auf der einen Seite und die Aussicht auf eine stetige berufliche Weiterentwicklung (building) andererseits diesem das Gefühl, im Unternehmen geschätzt zu werden und dort auch in Zukunft eine Perspektive zu haben.

*Nachdem nun aus Mitarbeiter- und Patientensicht alle Weichen für den Praxiserfolg gestellt sind, wird sich die Autorin in der nächsten Ausgabe von **laser international magazine of laser dentistry** damit beschäftigen, der Praxis selbst ihr größtmögliches Erfolgspotenzial zu entlocken.*

# 24<sup>th</sup> International Annual Congress of the DGL

## All on the same wavelength

**Authors** Lisa Meißner & Claudia Jahn, Germany



Fig. 1



Fig. 2

On 27 and 28 November, experts and members of the DGL (German Society for Laser Dentistry e.V.) met at the 24<sup>th</sup> International Annual Congress in Berlin, the vibrant capital of Germany. In cooperation with the scientific leaders of the DGL, LASER STARTUP was held as a parallel event of the congress. Here, beginners and professionals alike were given opportunities to inform themselves about modern lasers and

ways to integrate them to the various treatment methods of their dental practice. In addition, an overview on all relevant products and companies was given.

### \_Main topic wavelengths

For more than 35 years, lasers have been used for diagnosis and therapy in dentistry. The benefits of laser therapy, such as the non-contact mode and antiseptic operation, are undisputed. Yet, minimally invasive laser technology still maintains to some extent the role of an outsider. Recently, however, things have changed in this regard, as modern dental lasers are flexible, powerful and ultimately efficient. Therefore, this year's congress aim was to illustrate the many reasons why lasers should form a part of any modern dental office. The 24<sup>th</sup> Annual Congress under the headline "Wavelengths" was led by DGL President Prof. Dr Norbert Gutknecht, Aachen, Germany. Inter-

**Fig. 1** The newly elected DGL executive board: Dr Thorsten Kleinert, Dr Detlef Klotz, DGL President Prof. Dr Norbert Gutknecht, Dr Gabriele Schindler-Hultsch, Dr Stefan Grümer, Prof. Dr Siegfried Jänicke (from left to right). Board member Prof. Dr Anton Sculean was not present at the congress. **Fig. 2** In addition to academic lectures, attendees were given the opportunity to take part in a number of practical workshops.



Fig. 3

OEMUS MEDIA AG



Fig. 4

**Figs. 3 & 5** Traditionally, an industrial exhibition is run parallel to the congress, giving participants insight to the current trends of the laser market.

**Fig. 4** A display of the latest OEMUS MEDIA AG publications, among them the current issue of **laser** international magazine of laser dentistry.

nationally renowned, the event attracted many colleagues and speakers from various nations. A major role in this positive international response to the congress formed the fact that the first congress day was planned to feature all international speeches. All lectures were interpreted simultaneously into English or German. A total of 250 visitors took part in the congress.

Prof. Dr Norbert Gutknecht opened the two-day event Friday morning and gave a warm welcome as well as his introductory speech. He was followed by top-level speakers such as Prof. Dr Jens Malte Baron, Aachen, Prof. Dr. Andreas Braun, Marburg, Dr James Carroll, Chesham (GB), Dr Marina Polosky, Ottawa (CA), Dr Alin Odor, Constanta (RO), Dr Joshua Weintraub, Stevenson, MD (US), Dr Jaana Sippus, Vaasa (FI) and Dr Habib Zarifeh/Beirut (LB). All these scientific experts gave in insight to their current work, focusing on laser and its various applications.

### Election of a new executive board

In early afternoon of the first congress day, members of the DGL assembled for the society's general meeting. Prof. Dr Norbert Gutknecht, Dr Detlef Klotz, Dr Stefan Grümer, Dr Thorsten Kleinert, Prof. Dr Anton Sculean, Prof. Dr Siegfried Jänicke and Dr Gabriele Schindler-Hultsch were elected as the new executive board of the DGL. A series of further interesting speeches by Dr Gottfried Gisler, Männedorf (CH), Dr Dimitris Strakas (GR), Priv.-Doz. Dr Jörg Meister, Bonn, Prof. Dr Gerd Volland, Sevilla (ES), Dr Steffen Stein, Marburg, und Priv.-Doz. Dr Moritz Kepschull, Bonn, formed the second half of Friday's congress programme. Dr Michael Schäfer, Düsseldorf, concluded the first congress day with his lecture on opportunities and limitations of (diode-) laser-supported optimisation. of the so-called "red aesthetics".

### LASER START UP 2015

Attendees of LASER START UP 2015, which ran parallel to the 24<sup>th</sup> International Annual Congress, were given comprehensive information on the basics of laser dentistry. They were welcomed by Dr Jörg Meister, Bonn, who gave a speech on the physical principles of laser technology. He was followed by lectures on laser applications in periodontology, oral surgery and conservative dentistry.

### Yearbook Laser Dentistry 2016

Another main feature of the congress was an extensive industrial exhibition. Participants of the congress visited the exhibition either between lectures or during their seminar breaks. Thus, they made use of this opportunity to contact laser manufacturers directly and to gain background information on specific products.



Fig. 5



Fig. 6



Fig. 7

OEMUS MEDIA AG's publication *Yearbook Laser Dentistry 2016* was distributed to all congress participants free of charge, providing them additionally with concise information on all aspects of laser dentistry. The compendium features an up-to-date overview on the German dental-laser market, clinical case reports and introduces dental lasers, photodynamic systems as well as the latest innovations in laser dentistry on a total of 240 pages.

### Save the Date 2016

Of course, the twin congresses International Annual Congress of the DGL and LASER START UP will continue their success story of the previous eight years. In 2016, the 25<sup>th</sup> International Annual Congress

of the DGL and its counterpart will be held in Munich from 30 September to 1 October. In addition, the 15<sup>th</sup> Congress of the World Federation for Laser Dentistry will be held from 16 to 19 July in Nagoya, Japan.

### **contact**

#### **OEMUS MEDIA AG**

Holbeinstraße 29  
04229 Leipzig  
Tel.: +49 341 48474-308  
Fax: +49 341 48474-290  
event@oemus-media.de  
www.dgl-jahrestagung.de  
www.startup-laser.de

**Fig. 6** At the exhibition booth of this year's Main Sponsor Sirona. From left to right: André Förster, Product Manager Laser Systems, Ingo Höver, Community Manager, Sebastian Kiehne, Team Leader Sales Germany, Instruments and Special Appliances.

**Fig. 7** An international audience gathered for a series of speeches on the first congress day.

### **Kurz & bündig**

Am 27. und 28. November trafen sich die Experten und Mitglieder der Deutschen Gesellschaft für Laserzahnheilkunde e.V. (DGL) zur 24. Internationalen Jahrestagung in der pulsierenden Hauptstadt Berlin. Parallel zur Tagung fand in Kooperation und unter wissenschaftlicher Leitung der DGL auch das LASER START UP 2015 statt. Hier konnten sich sowohl Lasereinsteiger als auch versierte Anwender über die technischen Möglichkeiten der heutigen Laser und deren sinnvolle Integration in die unterschiedlichsten Behandlungsabläufe einer Zahnarztpraxis informieren. Außerdem wurde ein Überblick über die relevanten Produkte und Anbieter gegeben.

Zur 24. Jahrestagung, welche das Hauptthema „Wellenlängen“ hatte und unter der wissenschaftlichen Leitung von DGL-Präsident Prof. Dr. Norbert Gutknecht, Aachen, stand, erschienen aufgrund großer internationaler Anfragen zahlreiche ausländische Kollegen und Referenten. Organisatorisch ermöglicht wurde dies durch die Planung des Freitags als internationalen Vortragstag, an welchem alle Beiträge simultan ins Englische oder Deutsche übersetzt wurden. Insgesamt nahmen ca. 250 Interessenten an den Kongresstagen teil.

Am frühen Nachmittag des ersten Kongresstages traf sich die DGL zur Mitgliederversammlung und wählten mit Prof. Dr. Norbert Gutknecht, Dr. Detlef Klotz, Dr. Stefan Grümer, Dr. Thorsten Kleinert, Prof. Dr. Anton Sculean, Prof. Dr. Siegfried Jänicke und Dr. Gabriele Schindler-Hultsch einen neuen Vorstand.

Auch im kommenden Jahr wird das seit inzwischen 2009 bestehende Doppel wieder gemeinsam ausgetragen. Am 30. September und 1. Oktober 2016 findet die 25. Jahrestagung der DGL und LASER START UP 2016 in München statt.

## Victims of Pompeii had Excellent teeth

Two thousand years after Pompeii was buried under the ashes of Mt. Vesuvius, the archaeological site has still kept most of its secrets. The plaster that was used in the early 19<sup>th</sup> century to fill the voids that the bodies had left in the hardened rock is so dense that today's standard imaging technology cannot distinguish between the thick outer cast and the skeletal pieces inside.

(PICTURE: ©VIACHESLAV LOPATIN)



By using a special multi-layer CT scanner that is able to do just that, the specialists have been able to shed new light on the life and death of the ancient civilisation. Among other things, the scientific tests, which also included laser imaging and DNA sampling, revealed that the city's inhabitants had nearly perfect teeth.

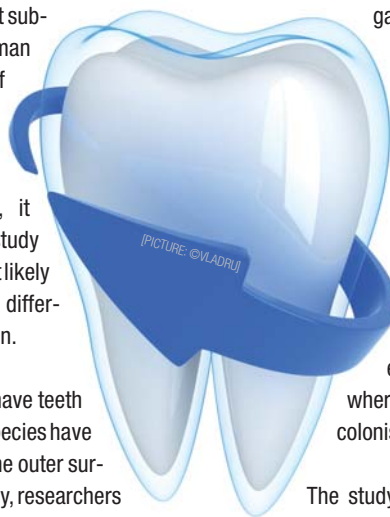
"We discovered the absence of cavities in the teeth. This is very interesting and not that surprising, because we all know about the healthy Mediterranean diet and this has really shown up in the early analyses," said Massimo Osanna, superintendent at the archaeological site.

According to the experts, the lack of sugar in the Pompeian diet and the high levels of fluorine in the air and water near the volcano are all accountable for the perfect state of their teeth. In addition to an excellent oral health, the researchers found that most of the victims still had all their teeth. However, the scans further showed that the teeth wore away, because they were used for cutting, orthodontist Dr Elisa Vanacore said.

## Tooth enamel first Evolved in the skin

Tooth enamel is the hardest substance produced by the human body. Since enamel is one of the four major tissues that make up the teeth and gives them their distinctive shiny white appearance, it comes as a surprise that a study has found that enamel most likely originated from an entirely different part of the body: the skin.

Unlike humans, who only have teeth in the mouth, certain fish species have little tooth-like scales on the outer surface of the body. In the study, researchers from Uppsala University in Sweden and the Institute of Vertebrate Paleontology and Paleoanthropology in Beijing in China analysed *Lepisosteus*, an ancient gar fish from North America whose scales are covered with an enamel-like tissue called



ganoine. Their findings suggest that enamel in fact first evolved in the skin. Dr Per Ahlberg, Professor of Evolutionary Organismal Biology at Uppsala University, explained: "Psarolepis and Andreolepis are among the earliest bony fishes, so we believe that their lack of tooth enamel is primitive and not a specialisation. It seems that enamel originated in the skin, where we call it ganoine, and only colonised the teeth at a later point."

The study is the first to combine novel palaeontological and genomic data in a single analysis to explore tissue evolution. The results have been published online on 23 September in the *Nature journal* in an article titled "New genomic and fossil data illuminate the origin of enamel".

## New pulse laser systems for A variety of indications

The Lumenis Pulse 100 H, the next generation of the VersaPulse<sup>®</sup> PowerSuite<sup>™</sup> 100 Watt system, is a versatile and enhanced laser solution for the treatment of a wide array of clinical urologic indications including benign prostatic hyperplasia (BPH), stones, tumors or strictures, along with a range of other specialties such as general surgery, ENT, gynecology and pulmonary surgery. As a greatly effective laser system for stones and BPH, the Pulse 100H enables users to perform holmium laser enucleation of the prostate (HoLEP), the gold standard treatment for BPH, and stone dusting<sup>™</sup>.

The new system features an improved design to enhance patient safety and overall user experience. It offers a robust combination of laser parameters addressing more than 70 types of procedures, an innovative pulse reshape function for improved safety, dual pedals for improved ease of use, a hands-free ready and standby mode for minimizing cost per procedure, and a high energy per pulse of up to 3.5 J with a high repetition rate of up to 50 Hz. In addition to the Pulse 100 H, Lumenis will also be unveiling another key addition to the Lumenis Pulse laser family, the Pulse 50 H laser system. Designed to efficiently address any type or size of stone in lithotripsy, the Pulse 50 H system is a superior comprehensive solution that provides 0.2 J of energy per pulse to minimize migration of even the smallest stone. Furthermore, the Pulse 50 H can be later upgraded to the new Pulse 100 H, allowing physicians to further leverage their investment as they grow their practice.

"The new Pulse 50 H system provides all features to perform modern intra corporeal Holmium laser lithotripsy including a wide range of energy levels and frequencies," said Professor Rassweiler, MD, PhD, Klinikum SLK, Heilbronn, Germany.



## Pregnancy: Majority avoids Dental check-ups



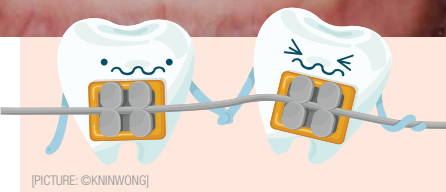
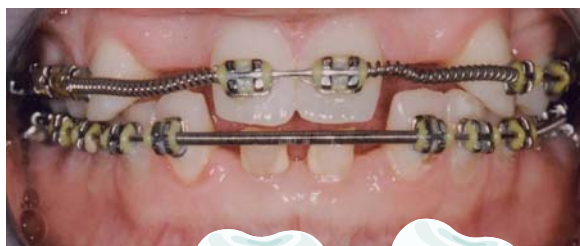In order to gain insights into women's dental visiting patterns and knowledge about the impact of oral health on their own and their babies' well-being, Cigna Corp., a global health service company, conducted an online survey in August among 801 pregnant women and new mothers aged 21–45. Only 55 per cent of the survey participants rated their oral health as very good or excellent, and

76 per cent reported oral health problems during pregnancy, including bleeding gingivae, increased tooth sensitivity and tooth pain. However, only 43 per cent of pregnant women stated that they had gone for dental check-ups during pregnancy, and 36 per cent said that they had not seen a dentist for more than a year. Overall, 33 per cent of women surveyed said that they had skipped dental checkups during pregnancy because they were concerned it would be too expensive.

In addition, the survey indicated that targeted interventions by medical professionals could significantly improve the oral health habits of pregnant women and new mothers. With regard to the daily oral hygiene habits of new mothers, the investigators found that 36 per cent have brushed and flossed less frequently since delivery, 67 per cent of whom stated that they do not have time to keep up on their hygiene. The full report can be accessed and downloaded at [www.cigna.com](http://www.cigna.com).

## UMC Utrecht discovers genetic Cause of disturbed dental development

Researchers at University Medical Center (UMC) Utrecht have identified a gene that may cause oligodontia, the agenesia of six or more teeth. The discovery of the so-called LRP6 gene makes it possible to diagnose patients more effectively, provide them with better information and develop customized treatment. The results were published today in *The American Journal of Human Genetics*. Oligodontia greatly impacts quality of life and may lead to eating and speaking problems, among other things. Dr Marijn Créton, dentist and maxillofacial prosthodontist at the Department of Oral and Maxillofacial Surgery and Special Dental Care at UMC Utrecht, ensures—in consultation with patients—that ultimately they have a good set of teeth both at a young and adult age. This requires a treatment of many years, during which patients are treated by a dentist, oral surgeon and orthodontist. “Moreover, adolescents with oligodontia often have psychosocial issues,” says Créton. “Missing many teeth is conspic-



uous. Children, teenagers and young adults are sometimes bullied and regularly experience feelings of low self-esteem and shame.”

*Reference: Massink MPG, Créton MA, Spanevello F, et al. Loss-of-Function Mutations in the WNT co-receptor LRP6 Cause Autosomal-Dominant Oligodontia, The American Journal of Human Genetics, in press 2015.*

## Water pipe smoking can lead to Serious oral conditions

According to the Centers for Disease Control and Prevention, 2.3 million Americans smoke tobacco from pipes, many of whom smoke water pipes, believing it is less harmful than cigarettes. A recent study, however, has shown that water pipe smoking is also associated with various head and neck conditions, including periodontal disease and oral cancer.



In the study, researchers at Rutgers, The State University of New Jersey, reviewed 20 published articles to identify potential health effects of water pipe smoking on the head and neck region. According to the World Health Organization, water pipe smoking sessions may expose the smoker to more smoke over a longer period than occurs when smoking a cigarette. Water pipe smokers may therefore inhale the equivalent of 100 or more cigarettes during one session, depending on the duration and number of puffs in a smoking session.

The study, titled “Association between tobacco waterpipe smoking and head and neck conditions,” was published in the October issue of the *Journal of the American Dental Association*.



# The future today

## Ultrashort pulsed laser

**Author** \_Dr Anton Kasenbacher, Germany

As this year's DGL Annual Congress has just been concluded and with the New Year lying ahead of us, author Dr Anton Kasenbacher gives another insight in future-oriented laser dentistry, focusing on the high versatility of ultrashort pulsed lasers.

Until now, the gold standard in dentistry has been the subjective mechanical probe and X-ray for diagnosis and the dental drill for therapy. In this vein, it was agreed that dental lasers could not achieve better results than conventional methods. However, this view has changed with the arrival of ultrashort pulsed lasers and the growing realisation that they open a whole new field of both diagnosis and therapy.

The patient and all dental tissues, especially the dental pulp structures, need an objective universal method, which guarantees stress, thermal and radiation confinement. In addition, it has to be ultrafast, precise, hygienic and non-carcinogenic. Only if all these requirements are fulfilled, both diagnosis and therapy are free of side effects like heat-affected zones, micro cracks, (pre/post) pain and/or induction of cancer by ionisation of water molecules.

Today dental lasers (e.g. Er:YAG, CO<sub>2</sub>), not to mention the dental drill, still have a long way to go before they can reach all these goals, as they have still too long pulse widths. These cause a too long laser-tissue interaction time and the energy used is too high. These are the reasons why even long microsecond and short nanosecond pulsed lasers have failed to replace the dental drill, not the price.

Ultrashort pulsed picosecond lasers avoid these severe disadvantages. Conversely, they generate a number of benefits for the patient and the doctor. They allow therapy and diagnosis (theragnostics) with a sin-



gle system. The controlled biosafe, non-linear absorption of photons will lead to a paradigm shift in dentistry. This is also due to the fact that futuristic technologies like nano-dental medicine and advanced 3-D robotic procedures have become reality.

The minimally-invasive therapy with picosecond lasers achieves high ablation rates with a superb quality using high scan speeds and autofocus feedback systems. Hence, possibly this special laser therapy can save costs by reducing the number of helpers, performing actually only the necessary protection and intraoral suction.

# Die Zukunft in der Gegenwart

## Ultrakurzpulslaser

**Autor**\_Dr. Anton Kasenbacher, Deutschland

Zwischen dem gerade erfolgreich abgeschlossenen Jahreskongress der DGL und dem Beginn des neuen Jahres gibt Autor Dr. med. dent. Anton Kasenbacher in der letzten Ausgabe der *laser* dieses Jahres einen kleinen Ausblick in die Laserzahnmedizin der Zukunft, die bereits heute mit den versatilen Ultrakurzpulslasern Realität geworden ist.



**„Bis heute ist der Goldstandard** in der Zahnmedizin die subjektive mechanische Sonde und das Röntgenverfahren für die Diagnostik und der Dentalbohrer im Therapiebereich. In diesem Sinne stimmte man überein, dass Dentallaser nichts können, was nicht auch mit konventionellen Methoden erreichbar wäre. Diese Sichtweise hat sich jedoch durch die Einführung der Ultrakurzpulslaser verändert, welche eine völlig neue Bandbreite von Indikationen erschließen.

Der Patient und seine dentalen Gewebe, speziell die Strukturen der Zahnpulpa, verlangen eine objektive und universelle Methode, die stress-, temperatur- und strahlungsarm ist. Zusätzlich sollte dieses Verfahren ultraschnell, präzise, hygienisch und nicht karzinogen sein. Nur wenn all diese Anforderungen erfüllt sind, können sowohl die Diagnostik als auch die Therapie ohne Nebenwirkungen wie Wärmeeinflusszonen, Mikrorisse, (pre- oder postoperativer) Schmerz und/oder eine krebserregende Wirkung durch Ionisation der Wassermoleküle stattfinden.

Heute sind Dentallaser (zum Beispiel Er:YAG, CO<sub>2</sub>) und nicht zu vergessen der Dentalbohrer immer noch

weit davon entfernt, all diese Ziele zu erreichen, denn sie besitzen immer noch viel zu große Pulsbreiten. Diese bewirken eine zu lang andauernde Interaktion zwischen Laser und Gewebe und zudem ist die Menge der benötigten Energie zu groß. Aus diesen Gründen, und nicht aufgrund des Preises, konnten langgepulste Laser im Mikrosekundenbereich und kurzgepulste im Nanosekundenbereich den Dentalbohrer bisher nicht ersetzen.

Ultrakurz gepulste Laser im Picosekundenbereich können diese schwerwiegenden Nachteile vermeiden. Im Gegenteil, sie bedeuten eine Vielzahl von Vorteilen für Patienten und Anwender. Sie ermöglichen Therapie und Diagnose (Theragnostik) mit einem einzigen System. Die kontrollierte, biosichere und nicht lineare Absorption von Photonen wird einen Paradigmenwechsel in der Zahnmedizin einläuten. Dies ist auch der Tatsache zu verdanken, dass Technologien der Zukunft wie die Nano-Zahnmedizin und fortgeschrittene, robotergesteuerte 3-D-Verfahren in die Realität Einzug gehalten haben.

Die minimalinvasive Therapie mit Picosekundenlasern erzielt hohe Ablationsraten mit einer hervorragenden Qualität auf Grundlage von hohen Scangeschwindigkeiten und Autofokus-Feedbacksystemen. Daher könnte diese spezielle Art der Lasertherapie auch kostenreduzierend wirken, indem die Anzahl von Helfern verringert wird, welche nur noch für den Arbeitsschutz und das Absaugen verantwortlich zeichnen müssen.

**SAVE  
THE DATE**

# 25. JAHRESTAGUNG DER DGL

## LASER START UP 2016

30. September bis 1. Oktober 2016  
München | The Westin Grand Hotel



**25.**  
**Jubiläums-  
kongress**

**Faxantwort**  
0341 48474-290

Bitte senden Sie mir das Programm zur/zum

25. JAHRESTAGUNG DER DGL  LASER START UP 2016

am 30. September und 1. Oktober 2016 in München zu.

Name/E-Mail-Adresse

Praxisstempel

laser 4/15

# Laser im **Aufwind**



Prof. Dr. Norbert Gutknecht  
DGL-Präsident

Sehr geehrte Frau Kollegin, sehr geehrter Herr Kollege,  
liebe DGL Mitglieder!

Nach Jahren der Stagnation stehen die Anzeichen auf eine deutliche Wiederbelebung des Lasermarktes besonders gut. Der gerade abgelaufene DGL-Kongress konnte diese Entwicklung sehr deutlich widerspiegeln. Die Zahl der Besucher hat sich mehr als verdoppelt und die wissenschaftlichen Beiträge erstrecken sich über ein sehr breites, schon seit Langem nicht mehr dagewesenes Spektrum an Vorträgen zu den unterschiedlichsten Wellenlängen. So wurde zum Beispiel nach ca. 20 Jahren erstmals wieder der Wellenlängenbereich um 450 nm entdeckt, der früher durch die Argonlaser abgedeckt wurde und heute durch eine moderne Diodenlasertechnologie dargestellt wird. Auch im Bereich der früher sehr dominant vertretenen CO<sub>2</sub>-Laser (10.600 nm) wurde nicht nur eine Neubelebung, sondern auch eine „Mutation“ der CO<sub>2</sub>-Wellenlänge vorgestellt, des erstmals in der Zahnheilkunde eingesetzten 9.300-nm-CO<sub>2</sub>-Lasers.

Diese Entwicklung spiegelte sich auch in der Vielfalt der Aussteller wieder, was dazu führte, dass unsere Gäste sich verstärkt während der Pausen in den Ausstellungsbereichen aufhielten. Eine simultane Übersetzung der Vorträge am Freitag ermöglichte es auch Teilnehmern aus mehr als zehn verschiedenen Ländern, aktiv, als Referent, und passiv, als aktive Zuhörer, am Kongressprogramm teilzunehmen.

Es wäre mein Wunsch, dass sich diese Tendenz im nächsten Jahr speziell auf dem Weltkongress der WFLD in Nagoya, Japan, und auf dem Jubiläumskongress zum 25-jährigen Bestehen der DGL fortsetzen würde.

Die Vielfältigkeit neuer Wellenlängen und Wellenlängenkombinationen bilden auch die Grundlage für meine vielfältigen guten Wünsche, kombiniert mit Glück und Erfolg für das neue Jahr 2016.

Ich freue mich auf ein Wiedersehen mit Ihnen!

Ihr

Prof. Dr. Norbert Gutknecht  
DGL-Präsident





### Nightlase Anti Schnarch Therapie – Systematik und verbesserte Einteilungen

Dr. Michael Alte, Siegburg, Dr. Thorsten Kuypers, M.Sc., Köln

Seit nunmehr einem Jahr wenden wir das Nightlase Verfahren in unseren Praxen an, um Schnarchen zu therapieren. Es wurden in dieser Zeit sowohl habituelles Schnarchen als auch obstruktives Schnarchen und auch Schlafapnoe behandelt.

Es zeigten sich durch unsere Erfahrungen Lücken in der Aufklärung der Patienten und der Patientenselektion. Aufbauend auf diesen Erfahrungen entwickelten wir eine erste Systematik, die diese Lücken schließen soll. Wir stellen diese erste Systematik vor, die zur besseren Selektion

der Patienten beiträgt. Des Weiteren wollen wir eine verbesserte Aufklärung präsentieren, die einer entsprechenden Systematik folgt. Diese soll dazu beitragen, eine Einteilung und Risikoabschätzung des zu erwartenden Behandlungserfolges zu ermöglichen. Eine anschließende Diskussion soll den Vortrag abrunden.

info@dralte.de

info@laserzahnarzt-koeln.de

### Photopolymerisation mit einem 445-nm-Diodenlaser im Vergleich zur LED- und Halogentechnologie

ZA Thomas Drost, Bonn, Dr. Susanne Reimann, Priv.-Doz. Dr. Jörg Meister, Prof. Dr. Matthias Frentzen

In dieser Studie sollte untersucht werden, ob ein Diodenlaser ( $\lambda = 445 \text{ nm}$ ) die gleichen Merkmale wie ein LED- und Halogenpolymerisationsgerät bei der Photopolymerisation von Kompositen aufweist.

Durch Bestrahlung verschiedener, mit Komposit befüllter, Kavitäten (ISO 4049) wurden die Oberflächen- und Tiefentemperatur ( $\Delta T$ ), die Polymerisationstiefe (PT) sowie die Lichtdurchlässigkeit untersucht.

Die Oberflächentemperaturmessungen zeigten keine signifikanten Unterschiede zwischen den drei Strahlungsquellen ( $\Delta T$ -Laser 1 W =  $4,5 \text{ }^\circ\text{C}$ ,  $\text{SD} = \pm 0,5 \text{ }^\circ\text{C}$ ;  $\Delta T$ -LED =  $4,1 \text{ }^\circ\text{C}$ ,  $\text{SD} = \pm 0,2 \text{ }^\circ\text{C}$ ;  $\Delta T$ -HL =  $4,3 \text{ }^\circ\text{C}$ ,  $\text{SD} = \pm 0,2 \text{ }^\circ\text{C}$ ).

Bei den Temperaturmessungen am Boden einer 6 mm tiefen Kavität ergaben sich ebenfalls keine signifikanten Unterschiede zwischen dem Laser 1 W ( $\Delta T = 2,9 \text{ }^\circ\text{C}$ ,  $\text{SD} = \pm 0,4 \text{ }^\circ\text{C}$ ) und den beiden Lichtpolymerisationsgeräten ( $\Delta T$ -LED =  $2,7 \text{ }^\circ\text{C}$ ,  $\text{SD} = \pm 0,4 \text{ }^\circ\text{C}$ ;  $\Delta T$ -HL =  $2,6 \text{ }^\circ\text{C}$ ,  $\text{SD} = \pm 0,2 \text{ }^\circ\text{C}$ ).

Die Polymerisationstiefenmessungen zeigten keine signifikanten Unterschiede zwischen dem Laser 1 W (PT =  $3,3 \text{ mm}$ ,  $\text{SD} = \pm 0,1 \text{ mm}$ ), dem Laser 0,5 W (PT =  $3,0 \text{ mm}$ ,  $\text{SD} = \pm 0,1 \text{ mm}$ ) und den beiden Lichtpolymerisationsgeräten (PT-LED =  $3,3 \text{ mm}$ ,  $\text{SD} = \pm 0,1 \text{ mm}$ ; PT-HL =  $3,1 \text{ mm}$ ,  $\text{SD} = \pm 0,1 \text{ mm}$ ).

Bei keiner der drei Strahlungsquellen konnte ein Strahlungsausstritt am Boden einer 6 mm tiefen Kavität während und nach der Polymerisation nachgewiesen werden. Die vorliegenden Ergebnisse zeigen, dass der Diodenlaser (445 nm) für die Polymerisation von Komposit geeignet und mit den im klinischen Bereich eingesetzten Lichtpolymerisationsgeräten vergleichbar ist. Die Möglichkeit, durch den dünnen und flexiblen Lichtleiter des Lasers eine sichere Bestrahlung von schwer zugänglichen Kavitäten zu erreichen, erscheint vielversprechend.

ThomasDrost@gmx.de

### Diodenlaser – Entwicklungen und klinischer Einsatz

Dr. Michael Hopp, Berlin, Dr. Jörg Meister, Prof. Dr. Rainer Biffar

Die Herstellung von Laserdioden hat sich in den letzten Jahren stark entwickelt und umfasst heute einen Wellenlängenbereich aus dem ultravioletten bis in den infraroten Bereich. Viele typische Wellenlängenbereiche klassischer Laser auf Festkörper-, Gas-, oder Farbstoffbasis können mit sehr viel einfacheren Mitteln kostengünstig und volumenminimiert ersetzt werden.

Durch diese Entwicklung können Wellenlängen optimaler für ihr jeweiliges Einsatzgebiet angewendet und das Gewebe geschont werden.

Fraglich bleibt, ob die erzeugte Laserstrahlung die der konventionellen Geräte entspricht und eine geeignete Substitution darstellt.

Die Präsentation stellt eine Übersicht aus Literaturdaten und klinischen Anwendungen vor und soll eine Orientierungshilfe im Vergleich zu konventionellen Techniken geben.

mdr.hopp@t-online.de

## Effektivität der Gewebeinzision mit einem 445-nm-Halbleiterlaser

Michael Berthold, Marburg, Moritz Kettner, Professor Dr. Andreas Braun

Bei Gewebeinzisionen mit einem 445-nm-Halbleiterlaser wird eine effektive Schnittführung mit räumlich begrenzter Hitzewirkung beschrieben. Daher war das Ziel der vorliegenden Studie die histologische Beurteilung von Gewebeproben nach Inzision mit einem 445-nm-Diodenlaser. Vierzig Mukosalappen aus dem Vestibulum von zwanzig Schweinekiefen wurden präpariert, die anschließend auf den Träger einer mechanischen Lineareinheit gespannt wurden. Das Handstück eines HF-Chirurgie-Geräts, 970-nm- und 445-nm-Halbleiterlasers wurde auf dem Verfahrensschlitten der Lineareinheit befestigt, sodass alle Gewebeinzisionen mit gleicher Geschwindigkeit und im gleichen Abstand von der Gewebeoberfläche durchgeführt werden konnten. Auf den jeweils zwei Mukosalappen eines Kiefers wurden acht Inzisionen durchgeführt (I–III): 445-nm-Laser ohne konditionierte Spitze, 90°, mit Gewebekontakt bei 1, 2 und 4 W, (IV–V): 445-nm-Laser ohne konditionierte Spitze, 90°, ohne Kontakt (1 mm) zum Gewebe bei 2 und 4 W cw, (VI): 445-nm-Laser ohne konditionierte Spitze, 45°, mit Kontakt zum Gewebe bei 2 W cw, (VII): 970-nm-Laser mit konditionierter Spitze, 90°, mit Gewebekontakt bei

3 W cw, (VIII): HF-Chirurgie-Gerät mit gerader Spitze, 90°, mit Gewebekontakt bei 50 W. Die histologische Auswertung erfolgte nach H.E.-Färbung der eingebetteten Präparate bei 35-facher Vergrößerung.

Der Vergleich der Inzisionstiefen zeigte einen signifikanten Unterschied in Abhängigkeit von der Laserwellenlänge und den gewählten Laserparametern. Dabei konnte die größte Inzisionstiefe mit dem 445-nm-Laser im direkten Gewebekontakt mit einer Leistungseinstellung von 2 W erreicht werden ( $p < 0,05$ ). Die geringste Inzisionstiefe wurde nach Verwendung des HF-Chirurgie-Geräts gemessen.

Bei Verwendung eines 445-nm-Halbleiterlasers kann im Vergleich zu einem 970-nm-Diodenlaser und einem Elektrotom mit einer höheren Schneideffizienz gerechnet werden. Auch eine Anwendung im Nicht-Kontakt-Modus zeigt klinisch akzeptable Inzisionstiefen ohne Anzeichen ausgedehnter Nekrosezonen.

michaelberthold14@alice.de

## Zell- und molekularbiologische Untersuchungen zur Anwendung von Laserstrahlung im blauen Spektralbereich

ZÄ Dr. Joana Reichelt, Bonn, PD Dr. Jochen Winter, PD Dr. Jörg Meister, Prof. Dr. Matthias Frentzen, Dr. Dominik Kraus

Ziel der Studie war es, ein neues Blaulicht-Lasersystem mit einem Emissionsbereich von 445 nm im Vergleich zu einem etablierten infraroten Diodenlasersystem (970 nm) auf zellulärer Ebene zu untersuchen. Epitheliale HaCaT- und mesenchymale MG63-Zellen wurden als Monolayerkulturen auf Glasdeckgläsern ausgesät und mit beiden Diodenlasern im Dauerstrichbetrieb im Kontakt und Non-Kontaktmodus bei Leistungen von 2 W (445 nm) und 3 W (970 nm) bestrahlt.

Als Simulation einer chirurgischen Schnittführung, erfolgte eine linienförmige Bestrahlung mit einer Faser von 300 µm Durchmesser bei einer Schnittgeschwindigkeit von 3 mm/s. Als Referenz diente diese mechanische Wundsetzung mit dem Laserapplikationstip.

Während der Laseranwendung wurde mittels einer Thermografiecamera die Temperaturentwicklung gemessen. Nach Laserinzision wurde der Wundheilungsverlauf lichtmikroskopisch beurteilt und morphometrisch vermessen. Mittels Acridinorange/Propidiumiodid-Färbung erfolgte eine Lebend-Tot-Diskriminierung. Potenzielle Zytoskelettveränderungen wurden durch Fluoreszenzfärbung der Aktinfilamente mit Phalloidin AF 800, mögliche DNA-Doppelstrangbrüche durch Immunfluoreszenznachweis von p-H2Ax dargestellt.

Eine charakteristische Zonenbildung konnte nach Bestrahlung mit beiden Wellenlängen im Kontakt- und Non-Kontaktmodus nachvollzogen werden.

Trotz eines größeren Wundbereiches nach Bestrahlung mit 445 nm, bedingt durch eine höhere Temperaturentwicklung (493,2 °C im Kontaktmodus), zeigte das neue Lasersystem eine beschleunigte Wundheilung der zentralen zellfreien Zone im Vergleich zum NIR-System. Im Non-Kontaktmodus konnte durch Vernachlässigung des thermischen Einflusses weder eine erhöhte Anzahl an devitalen Zellen noch vermehrte DNA-Doppelstrangbrüche oder Zytoskelettveränderungen detektiert werden.

Unsere Untersuchungen zeigen eine hervorragende thermische Ankopplung des Blaulicht-Lasersystems an die Zellen und unter Einsatz einer geringeren Leistung eine gute Schneidleistung, verbunden mit einer günstigen Wundheilung ohne mutagene Nebeneffekte. Daher stellt das neue Lasersystem eine innovative Alternative zu den etablierten Systemen dar.

joana.reichelt@ukb.uni-bonn.de



### Die Anwendung von Dentallasern im zahnärztlichen Praxisalltag und in der zahnärztlichen Chirurgie; Fallpräsentationen

Ioannis Papadimitriou, ZÄ Venetia Sotiri, ZA Dr Petros Almagout

Die moderne Technologie hat bereits Laser-Anwendung in der Zahnarztpraxis eingeführt. Es gibt verschiedene Arten von Laser, die in der zahnärztlichen Praxis verwendet werden können. Einige der am häufigsten verwendeten Laser sind: Erbium Nd:YAG-, CO<sub>2</sub>- (Kohlendioxid-) und Diodenlaser.

Heutzutage können Laser zur Kavitätenpräparation, Desensibilisierung von freiliegenden Zahnhälsen, Reduktion der bakteriellen Besiedlung von kontaminiertem Dentin, bei chirurgischen Techniken in der Parodontologie und der präprothetischen Chirurgie verwendet werden. Weiterhin kann Laser in Bereichen sowohl der Endodontie, Implantologie sowie Mund- und Kieferchirurgie als auch des Bleaching angewendet werden. Die Lasertherapie hat zunehmende Bedeutung in das Gesamtbehandlungskonzept in der Zahnmedizin gewonnen. Dies ist nicht überraschend, dank dem weiten Indikationsspektrum, das heutzutage mit Laser effizient behandelt werden kann, in Kombination mit den traditionellen Behandlungskonzepten.

Das Ziel der Studie ist die Darstellung von Operationen an Weichteilen (Epulis-Exzision, Exzision von traumatischen Fibromen, Frenu-

lektomie, Implantatfreilegung) und die postoperative Wundheilung der Patienten.

Die Studien wurden in der zahnärztlichen Abteilung des Allgemeinen Krankenhauses Westattika in Athen und in der Abteilung für Mund-, Kiefer- und Gesichtschirurgie, der St. Lukas Klinik in Solingen durchgeführt. Die Operationen wurden mit einem 810-nm-Diodenlaser und einem 10.600-nm-CO<sub>2</sub>-Laser durchgeführt.

CO<sub>2</sub> und Diodenlaser sind 2 Laserarten, die bevorzugt in der Chirurgie eingesetzt werden. Ihr sehr positiver Effekt beim Schneiden und Abtragen von Gewebe sowie die Möglichkeit der Koagulation von kleinen Blutgefäßen wird heutzutage routinemäßig in der Weichgewebschirurgie angewendet.

Der Einsatz von Laser in der modernen Zahnheilkunde bietet viele Vorteile. Einige von denen werden weiter unten erwähnt: ein blutungs-freies und klares Operationsfeld, keine postoperativen Blutungen, keine Naht, manchmal ist keine Anästhesie notwendig, kürzere Termine, beschleunigte Wundheilung.

giannis.papadimitriou\_4@hotmail.com

### Diodenlaser-Einsatz als Therapieoption in der Weichgewebschirurgie – Fibromexzision: Fallpräsentationen

Ioannis Papadimitriou

Durch die dauernde Entwicklung und Perfektionierung von Lasern ist ihre Anwendung in allen Bereichen der Zahnheilkunde geeignet. Früher war Laser als eine komplexe Technologie mit nur limitierendem Einsatz in der Zahnmedizin angesehen.

Heutzutage ist Laser als zusätzliches einzusetzendes System neben konventionellen Geräten in einer modernen Praxis integriert. Diodenlaser wurde in den 90er-Jahren in die Zahnmedizin eingeführt und zeichnet sich vor allem dadurch aus, dass sein Anwendungsbereich sehr breit gefächert ist. Die Laserstrahlung weist im biologischen Gewebe sehr positive Eigenschaften auf, sie wird reflektiert, transmittiert und absorbiert. Dank der meist ausgezeichneten Absorption der Wellenlängen von Diodenlasern im durchblutetem Gewebe und der geringen Absorption in Zahnhartgewebe können chirurgische Eingriffe des Weichgewebes in der näheren Distanz zu Hartgewebe (Knochen; Schmelz; Dentin, Zement) durchgeführt werden, ohne diese Strukturen zu schädigen, was eine mögliche Alternative zum Skalpell darstellt.

Ziel der Studie ist die Darstellung von klinischen Fällen von Fibromexzisionen mittels Diodenlaser, die Operationsabläufe und die postoperative Wundheilung der Patienten.

Die Studie wurde in der zahnärztlichen Abteilung des Allgemeinen Krankenhauses Westattika in Athen durchgeführt bei Patienten mit Reiz- und traumatischen Fibromen im Zungen- und Mundschleimhautbereich. Die Operationen wurden mit einem 810-nm-Diodenlaser durchgeführt.

Der Diodenlaser hat eine Wellenlänge von 810 nm. Durch seine hervorragende Absorption in Hämoglobin und Melanin werden Diodenlaser bevorzugt in der zahnärztlichen Chirurgie eingesetzt. Durch ihre bemerkenswerte koagulierende Wirkung lässt sich mit dieser Laserart Weichgewebe im Mundraum hervorragend schneiden und abtragen.

Der Einsatz von Diodenlaser hat sich in vielen Bereichen der Zahnmedizin bewährt. Ihre Vielfalt der Anwendungsmöglichkeiten sowohl der konservierenden Zahnheilkunde als auch der zahnärztlichen Chirurgie, ihr geringes Geräteausmaß sowie moderater Anschaffungspreis, machen den Diodenlaser für eine moderne Praxis sehr attraktiv.

giannis.papadimitriou\_4@hotmail.com

## Innovative Wege in der Zahnheilkunde – Der Dioden- und Er: YAG- Laser, Anwendungsbeispiele

Dr. Dr. (UMF Bukarest) Simona Baur, Zirndorf

Die Lasertechnik hat in der Zahnmedizin inzwischen einen hohen Stellenwert erreicht. Die Bedeutung des Dentallasers als sinnvoll genutzte Behandlungsalternative in der minimalinvasiven Zahnheilkunde wird in diesem Beitrag herausgearbeitet. In ausgewählten Falldokumentationen wird zum einen gezeigt, wie der Er: YAG-Laser (2,940 nm) in der Kavitätenpräparation (Kariesentfernung im Schmelz und Dentin) und Oralchirurgie effektiv genutzt werden kann. Zum anderen kommt der Diodenlaser (810 nm) in Beispielen der Parodontalbehandlung, Oralchirurgie und Bleaching zum Einsatz.

Die Fallberichte umfassen verschiedene Therapiemöglichkeiten bei Patienten, Kinder und Erwachsene, mit diversen Erkrankungen von Hart- und Weichgewebe im Mundbereich. Pre- und postoperative klinische Symptome, postoperative Entwicklung und das Wohlbefinden

der Patienten im Zusammenhang mit den angewandten Arbeitsmethoden werden im Detail herausgearbeitet. Besonders in der Kinderzahnheilkunde hat die lasergestützte Therapie (Kariesentfernung, Phrenektomie etc.) signifikante Vorteile gegenüber den konventionellen Therapiemethoden.

Die klinischen Ergebnisse zeigen bei der Verwendung von Er: YAG- und Dioden-Laser eine optimale Effizienz der Behandlung sowohl im Hart- als auch im Weichgewebe. Gerade in Kombination mit dem richtigen klinischen Prozedere ist die Akzeptanz bei Kindern und Erwachsenen hoch.

drbaur@zahnarzt-wintersdorf.de

AD

# Jahrbuch 2016



- | Klinische Fallberichte und aktuelle Forschungslage
- | Gesamtübersicht Dentallasermarkt
- | Vorstellung Dentallaser/Photodynamische Systeme
- | Marktübersicht CO<sub>2</sub>-Laser und Nd:YAG-Laser
- | Marktübersichten Diodenlaser kompakt und Diodenlaser Soft
- | Marktübersicht CO<sub>2</sub>- und Er:YAG-Laser/ Kombilaser Er:YAG

49 €\*



Jetzt bequem  
online bestellen  
[www.oemus-shop.de](http://www.oemus-shop.de)

## Jetzt bestellen!

Faxantwort an 0341 48474-290

Bitte senden Sie mir das aktuelle Jahrbuch Laserzahnmedizin 2016 zum Preis von 49 €\* zu.

Name/Vorname

Straße

PLZ/Ort

Telefon/Fax

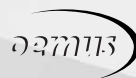
E-Mail

Datum/Unterschrift

Praxisstempel

\*Preis versteht sich zzgl. MwSt. und Versandkosten.  
Entsiegelte Ware ist vom Umtausch ausgeschlossen.

OEMUS MEDIA AG  
Holbeinstraße 29 | 04229 Leipzig  
Tel.: 0341 48474-0 | Fax: 0341 48474-290





Internationales Forschungsprojekt

## Lasergestützter Wundverschluss für die Oralchirurgie



Mit Partnern aus Deutschland, Israel, Lettland und der Toskana wird im Projekt „Biophotonic Technologies for Tissue Repair BI-TRE“ der Einsatz biophotonischer Technologien im industriellen, klinischen und medizinischen Bereich konsequent vorangetrieben. Im Rahmen der transnationalen BiophotonicsPlus-Initiative startete am 1. September 2015 das deutsche Konsortium mit seinen Aktivitäten. Ziel ist die Bereitstellung eines lasergestützten Verfahrens für die Mund-, Kiefer-, Gesichts- und Oralchirurgie zum zuverlässigen Wundverschluss nach einem operativen Eingriff.


Bisher mussten orale Wunden und Defekte ab einer bestimmten Größe nach chirurgischen Eingriffen mit Kompressen abgedeckt oder mit einem eigenen Haut- oder Schleimhauttransplantat mit oft aufwendiger Nahttechnik versorgt werden.

Eine dichte Wundabdeckung, ein zuverlässiger Schutz vor eindringenden Keimen als auch ein haftender Verband ist im Mund-Rachen-Raum somit auch heutzutage immer noch ein ungelöstes Problem. Durch den im BI-TRE Projekt erforschten Ansatz zur Wundabdeckung mit Kollagenmembranen, welche lasergestützt an der Schleimhaut befestigt werden, wird dagegen eine neue Lösung erarbeitet. Ziel ist es, einen verbesserten Schutz gegen Keime und eine beschleunigte Wundheilung zu erreichen. Zudem können die Behandlungskosten mit dem neuen Verfahren stark gesenkt werden. Die Behandlungszeit lässt sich erheblich reduzieren, dem Patienten kann eine Transplantation und somit eine weitere Wunde auf diese Weise erspart werden.

Fotobiomodulation – Neuer Trend für

## Schnellere Zahnkorrekturen

Zahnspangen sind heutzutage auch bei Erwachsenen sehr beliebt. Moderne Verfahren, um kleinere Korrekturen vorzunehmen, verschaffen innerhalb weniger Monate die gewünschte Zahnstellung. Mittels einer Lasermethode kann eine Zahnkorrektur noch be-



schleunigt werden. Damit ergibt sich ein weiteres Einsatzgebiet von Lasertechnologie in der Zahnmedizin. Die neue Methode nennt sich Fotobiomodulation und nutzt Licht im Bereich zwischen 600 und 1.000 Nanometern Wellenlänge, um den Knochen während der Behandlung mit Alignern zu stimulieren. Werden die Zähne Schritt für Schritt im Kiefer bewegt, muss der Knochen die entstandene Lücke füllen, um den Zahn an neuer Position fest im Kiefer zu halten. Durch die Stimulation mittels Laser sollen die Mitochondrien in den Knochenzellen aktiviert werden. Der Knochenumbau kann so schneller voranschreiten. Aligner können dadurch bereits nach wenigen Tagen anstatt von zwei Wochen gewechselt werden. Fünf Minuten Strahlung pro Kieferbogen am Tag sollen dafür ausreichen. Laut Dr. Marc Schätzle vom Zahnmedizinischen Institut der Universität Zürich berichten Patienten von weniger Schmerzen beim Adjustieren der Aligner. Insgesamt soll die Methode nebenwirkungsfrei sein. Zur Anwendung ist bereits das Gerät OrthoPulse™ auf dem Markt. Dieses wurde bei der AAO-Tagung in San Francisco vorgeführt und ist kompatibel mit den gängigen Alignersystemen.

Quelle: ZWP online

Laserworkshop präsentiert

## Präzision in Blau

Im Rahmen des Deutschen Zahnärztetages 2015 bot Sirona den anwesenden Fachjournalisten die Möglichkeit, den neuen SIROLaser Blue nicht nur live in Augenschein zu nehmen, sondern auch eigenhändig anzuwenden. Als erstes Gerät im Dentalbereich nutzt das System blaues Laserlicht, um chirurgische Eingriffe schmerzärmer, gewebeschonender und blutungsärmer zu gestalten.

Welche physikalischen Prinzipien den zahnmedizinischen Vorteilen zugrunde liegen, die das kurzwellige blaue Laserlicht mit sich bringt, erläuterte André



Förster, Produktmanager Lasersysteme bei Sirona. Demnach hängt die Schneid- und Desinfektionsleistung eines Lasers von der aufgenommenen Energie im Gewebe ab. Der SIROLaser Blue emittiert ein blaues Licht mit einer Wellenlänge von 445 Nanometern, wodurch die Lichtenergie von Hämoglobin und Melanin besonders gut aufgenommen wird. Dadurch erreicht der blaue Laserstrahl insgesamt eine rund 100 Mal bessere Absorption als infrarotes Licht. Somit werden präzise, atraumatische Schnitte in überzeugender Geschwindigkeit ermöglicht.

Zudem verkürzen die sterilen Einmalfaserspitzen die Vorbereitungszeit bis zur Einsatzbereitschaft des Lasers signifikant, da keine vorherige Sterilisation erfolgen muss. Die hochwertigen Edelstahlhandstücke sind abnehmbar und können autoklaviert werden.

Nach der theoretischen Einführung konnten sich die Medienvertreter bei der eigenhändigen Anwendung des Lasers an einem Tierpräparat selbst von dessen Leistungsfähigkeit überzeugen.

**Antwort:**

Deutsche Gesellschaft für Laserzahnheilkunde e.V.  
c/o Universitätsklinikum Aachen  
Klinik für Zahnerhaltung  
Pauwelsstraße 30  
52074 Aachen

Tel.: 0241 8088164  
Fax: 0241 803388164  
E-Mail: sekretariat@dgl-online.de  
Bank: Sparkasse Aachen  
IBAN: DE56 3905 0000 0042 0339 44  
BIC: AACSD33

## Aufnahmeantrag (Deutsch)



Name/Titel: \_\_\_\_\_

Vorname: \_\_\_\_\_

Geb.-Datum: \_\_\_\_\_

Approbation: \_\_\_\_\_

Status:  selbstständig  angestellt  Beamter  Student  ZMF/ZAH

### Adresse: Praxis/Dienststelle/Institut (Unzutreffendes bitte streichen)

PLZ/Ort: \_\_\_\_\_ Straße: \_\_\_\_\_

Telefon/Fax: \_\_\_\_\_ E-Mail: \_\_\_\_\_

Privat/Ort: \_\_\_\_\_ Straße: \_\_\_\_\_

Aufgrund des bestehenden Assoziationsvertrages zwischen der DGL und der DGZMK fällt zusätzlich ein reduzierter Jahresbeitrag für die DGZMK an (85 € p.a., falls Sie noch nicht Mitglied der DGZMK sind). Der Beitragseinzug erfolgt durch die DGZMK-Geschäftsstelle, Liesegangstr. 17a, 40211 Düsseldorf. Sie werden hierfür angeschrieben.

Mit der Stellung dieses Aufnahmeantrages versichere ich, dass ich

seit dem \_\_\_\_\_ in der eigenen Praxis  
mit einem Laser des Typs \_\_\_\_\_ arbeite. (genaue Bezeichnung)

in der Praxis \_\_\_\_\_ beschäftigt bin.

in der Abt. der Universität \_\_\_\_\_ beschäftigt bin.

Ich beantrage die Aufnahme in die Deutsche Gesellschaft für Laserzahnheilkunde e.V.

Ort, Datum

vollständige Unterschrift

**Jahresbeitrag:** Für stimmberechtigte Mitglieder bei Bankeinzug 150,00 €.

Sofern keine Einzugsermächtigung gewünscht wird, wird ein Verwaltungsbeitrag von 31,00 € p.a. fällig.

### EINZUGSERMÄCHTIGUNG

Ich bin einverstanden, dass der DGL-Mitgliedsbeitrag von meinem Konto abgebucht wird.

Name: \_\_\_\_\_ IBAN: \_\_\_\_\_

BIC: \_\_\_\_\_ Geldinstitut: \_\_\_\_\_

Unterschrift des Kto.-Inhabers

Diese Erklärung gilt bis auf schriftlichen Widerruf

**laser**  
international magazine of laser dentistry

**WFLD** World Federation for Laser Dentistry  
Formerly ISLD, founded 1988

0277113



**Publisher**

Torsten R. Oemus  
[oemus@oemus-media.de](mailto:oemus@oemus-media.de)

**CEO**

Ingolf Döbbecke  
[doebbecke@oemus-media.de](mailto:doebbecke@oemus-media.de)

**Members of the Board**

Jürgen Isbaner  
[isbaner@oemus-media.de](mailto:isbaner@oemus-media.de)

Lutz V. Hiller  
[hiller@oemus-media.de](mailto:hiller@oemus-media.de)

**Editor in Chief**

Norbert Gutknecht  
[ngutknecht@ukaachen.de](mailto:ngutknecht@ukaachen.de)

**Coeditors in Chief**

Samir Nammour  
Matthias Frentzen

**Managing Editors**

Georg Bach  
Leon Vanweersch

**Division Editors**

Umberto Romeo  
*European Division*

Melissa Marchesan  
*North American Division*

Carlos de Paula Eduardo  
*South American Division*

Toni Zeinoun  
*Middle East & Africa Division*

Ambrose Chan  
*Asia & Pacific Division*

**Senior Editors**

Aldo Brugneira Junior  
Kenji Yoshida  
Lynn Powell  
Dimitris Strakas  
Adam Stabholz  
Marcia Martins Marques

**Editorial Board**

Peter Steen Hansen, Aisha Sultan,  
Ahmed A Hassan, Antonis Kallis, Dimitris Strakas,  
Kenneth Luk, Mukul Jain, Reza Fekrazad,  
Sharonit Sahar-Helft, Lajos Gaspar, Paolo Vescovi,  
Ilay Maden, Jaana Sippus, Hideaki Suda,  
Ki-Suk Kim, Miguel Martins, Aslihan Üsümez,  
Liang Ling Seow, Shaymant Singh Makhan,  
Enrique Trevino, Blanca de Grande,  
José Correia de Campos, Carmen Todea,  
Saleh Ghabban Stephen Hsu, Antoni Espana Tost,  
Josep Arnabat, Alaa Sultan, Leif Berven,  
Evgeniy Mironov Ahmed Abdullah, Boris Gaspirc,  
Peter Fahlstedt, Ali Saad Alghamdi, Alireza Fallah,  
Michel Vock, Hsin-Cheng Liu, SajeeSattayut,  
Anna-Maria Yannikou, Ryan Seto, Joyce Fong,  
Iris Brader, Masoud Mojahedi, Gerd Volland,  
Gabriele Schindler, Ralf Borchers, Stefan Grümer,  
Joachim Schiffer, Detlef Klotz, Jörg Meister,  
ReneFranzen, Andreas Braun,  
Sabine Sennhenn-Kirchner, Siegfried Jänicke,  
Olaf Oberhofer,  
Thorsten Kleinert

**Editorial Office**

Georg Isbaner  
[g.isbaner@oemus-media.de](mailto:g.isbaner@oemus-media.de)

Claudia Jahn  
[c.jahn@oemus-media.de](mailto:c.jahn@oemus-media.de)

**Product Manager**

Timo Krause  
[t.krause@oemus-media.de](mailto:t.krause@oemus-media.de)

**Executive Producer**

Gernot Meyer  
[meyer@oemus-media.de](mailto:meyer@oemus-media.de)

**Designer**

Sarah Fuhrmann  
[s.fuhrmann@oemus-media.de](mailto:s.fuhrmann@oemus-media.de)

**Customer Service**

Marius Mezger  
[m.mezger@oemus-media.de](mailto:m.mezger@oemus-media.de)

**Published by**

OEMUS MEDIA AG  
Holbeinstraße 29, 04229 Leipzig, Germany  
Tel.: +49 341 48474-0  
Fax: +49 341 48474-290  
[kontakt@oemus-media.de](mailto:kontakt@oemus-media.de)  
[www.oemus.com](http://www.oemus.com)

**Printed by**

Silber Druck oHG  
Am Waldstrauch 1, 34266 Niestetal, Germany

**laser international magazine of laser dentistry**

is published in cooperation with the World Federation for Laser Dentistry (WFLD).

**WFLD Headquarters**

University of Aachen Medical Faculty  
Clinic of Conservative Dentistry  
Pauwelsstr. 30, 52074 Aachen, Germany  
Tel.: +49 241 808964  
Fax: +49 241 803389644  
[ngutknecht@ukaachen.de](mailto:ngutknecht@ukaachen.de)  
[www.wfld-org.info](http://www.wfld-org.info)

[www.laser-magazine.com](http://www.laser-magazine.com)

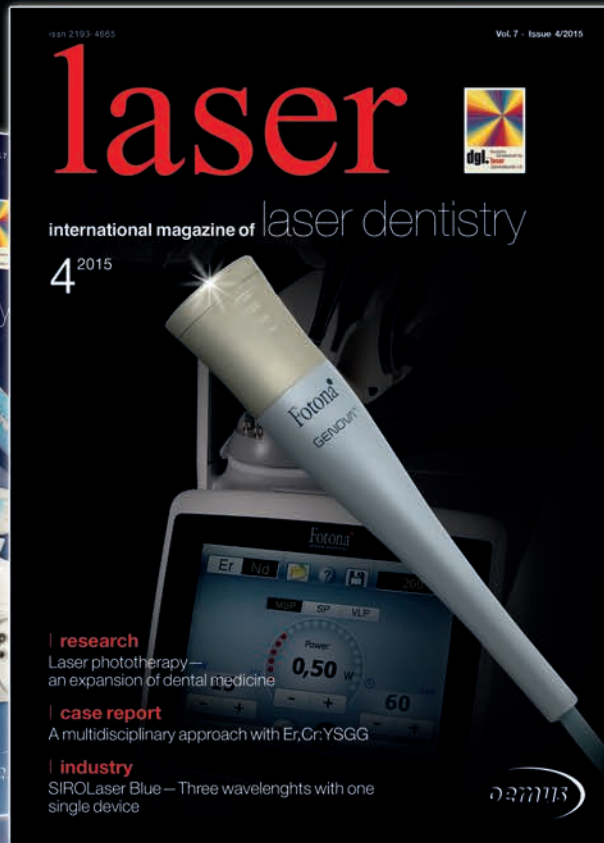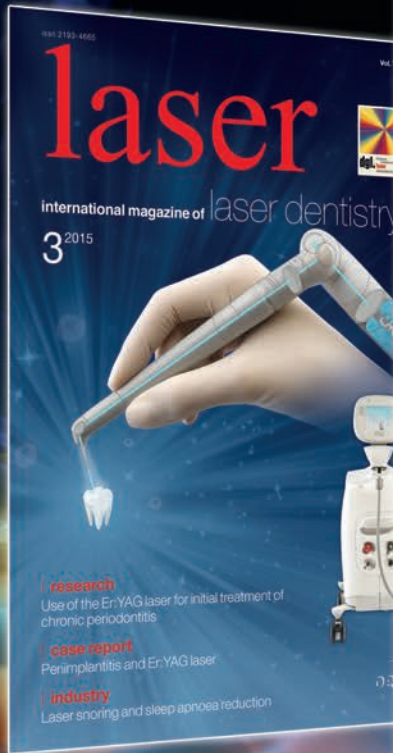**Copyright Regulations**

**laser international magazine of laser dentistry** is published by OEMUS MEDIA AG and will appear in 2015 with one issue every quarter. The magazine and all articles and illustrations therein are protected by copyright. Any utilization without the prior consent of editor and publisher is inadmissible and liable to prosecution. This applies in particular to duplicate copies, translations, microfilms, and storage and processing in electronic systems.

Reproductions, including extracts, may only be made with the permission of the publisher. Given no statement to the contrary, any submissions to the editorial department are understood to be in agreement with a full or partial publishing of said submission. The editorial department reserves the right to check all submitted articles for formal errors and factual authority, and to make amendments if necessary. No responsibility shall be taken for unsolicited books and manuscripts. Articles bearing symbols other than that of the editorial department, or which are distinguished by the name of the author, represent the opinion of the afore-mentioned, and do not have to comply with the views of OEMUS MEDIA AG. Responsibility for such articles shall be borne by the author. Responsibility for advertisements and other specially labeled items shall not be borne by the editorial department. Likewise, no responsibility shall be assumed for information published about associations, companies and commercial markets. All cases of consequential liability arising from inaccurate or faulty representation are excluded. General terms and conditions apply, legal venue is Leipzig, Germany.

# laser

international magazine of laser dentistry



Subscribe now!

I would like to subscribe to **laser international magazine of laser dentistry** (4 issues per year) for €44 including shipping and VAT for German customers, €46 including shipping and VAT for customers outside Germany, unless a written cancellation is sent within 14 days of the receipt of the trial subscription. The subscription will be renewed automatically every year until a written cancellation is sent to OEMUS MEDIA AG, Holbeinstr. 29, 04229 Leipzig, Germany, six weeks prior to the renewal date.

▶ Reply via Fax +49 341 48474-290 to OEMUS MEDIA AG or per E-mail to [grasse@oemus-media.de](mailto:grasse@oemus-media.de)

You can also subscribe via  
[www.oemus.com/abo](http://www.oemus.com/abo)

Last Name, First Name

Company

Street

ZIP/City/County

E-mail

Signature

Notice of revocation: I am able to revoke the subscription within 14 days after my order by sending a written cancellation to OEMUS MEDIA AG, Holbeinstr. 29, 04229 Leipzig, Germany.

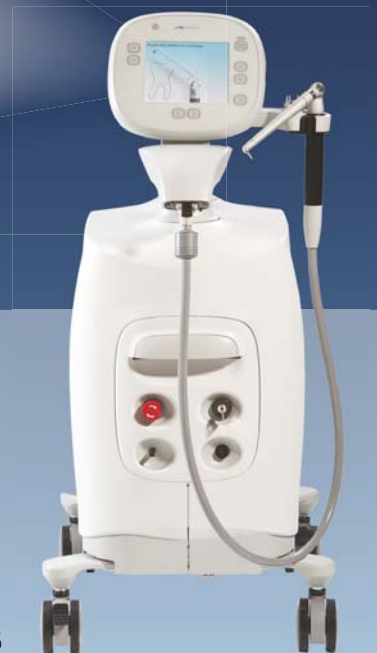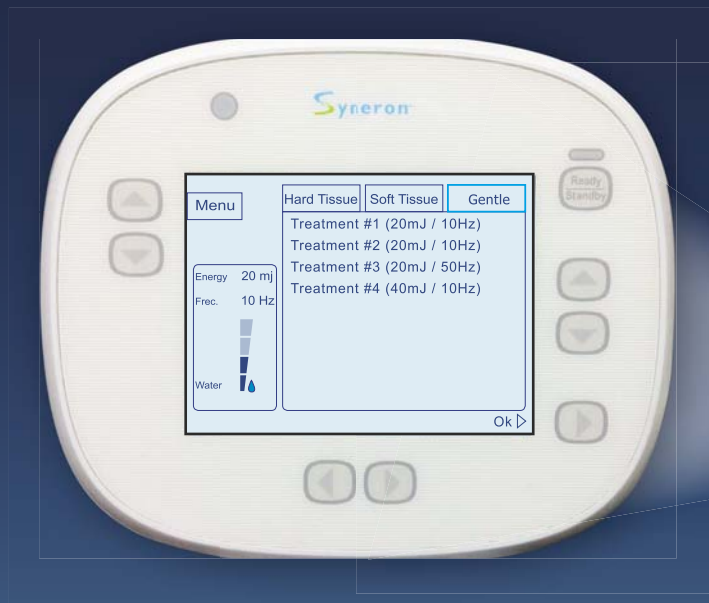Signature

**LiteTouch Er:YAG Laser-in-Handpiece**  
**Available now also with Low Energy Options**

**GENTLE TREATMENT**

Energy settings: 20mJ or 40mJ, Frequencies of 10-50 Hz

- Access a larger spectrum of dental procedures
- Minimal ablation – resulting in enhanced tissue preservation
- Preventive treatments
- Extra selective treatments
- Fine coagulation of soft tissue and nerve ends (bleeding control)
- Reduced patient discomfort



**LITETOUCH™**

**Er:YAG Laser-in-Handpiece**

Dentists' Choice for Hard & Soft Tissue Procedures

AD MED

LH-PB87412EN

To learn more about our innovative technology solutions, contact: [dental@syneron.com](mailto:dental@syneron.com), [www.synerondental.com](http://www.synerondental.com)



**Gutta Percha Points**  
Absorbent Paper Points

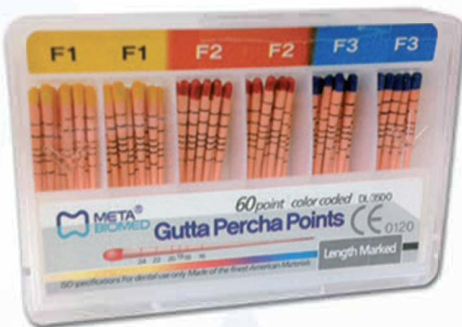**گوتا فقط META**



Adseal Meta Biomed

**کن کاغذی**

- استریل
- جذب عالی بدون لینت
- موجود در انواع سایز ها
- در بسته بندی ۲۰۰ عددی کشویی ضد ریزش



- دارای انواع سایز های مدرج و با شیب ۰.۲ - ۰.۴ - ۰.۶ - ۰.۸
- رادیو اپستی عالی
- مناسب برای پر کردن کانال به روش تراکم جانبی و عمودی
- ۱۲۰ عددی با بهترین بسته بندی برای کاربری آسان
- انعطاف پذیری بسیار مناسب در حین کار
- زمان ماندگاری طولانی مدت



**Available Sizes**

- ISO sizes : 10, 15, 20, 25, 30, 35, 40, 45, 50, 55, 60, 70, 80, 90, 100, 110, 120, 130, 140
- Non-Standardized (Accessory sizes): XF, FF, MF, F, FM, M, ML, L, XL
- Special Taper Points: .04, .06, .08

Tel: +98 21 88 98 80 63 - 6

www.azadmed.com

Add: Ava Building (No 34) Kaj St, Fatemi Ave, Tehran, Iran

Fax: +98 21 88 98 75 72

info@azadmed.com