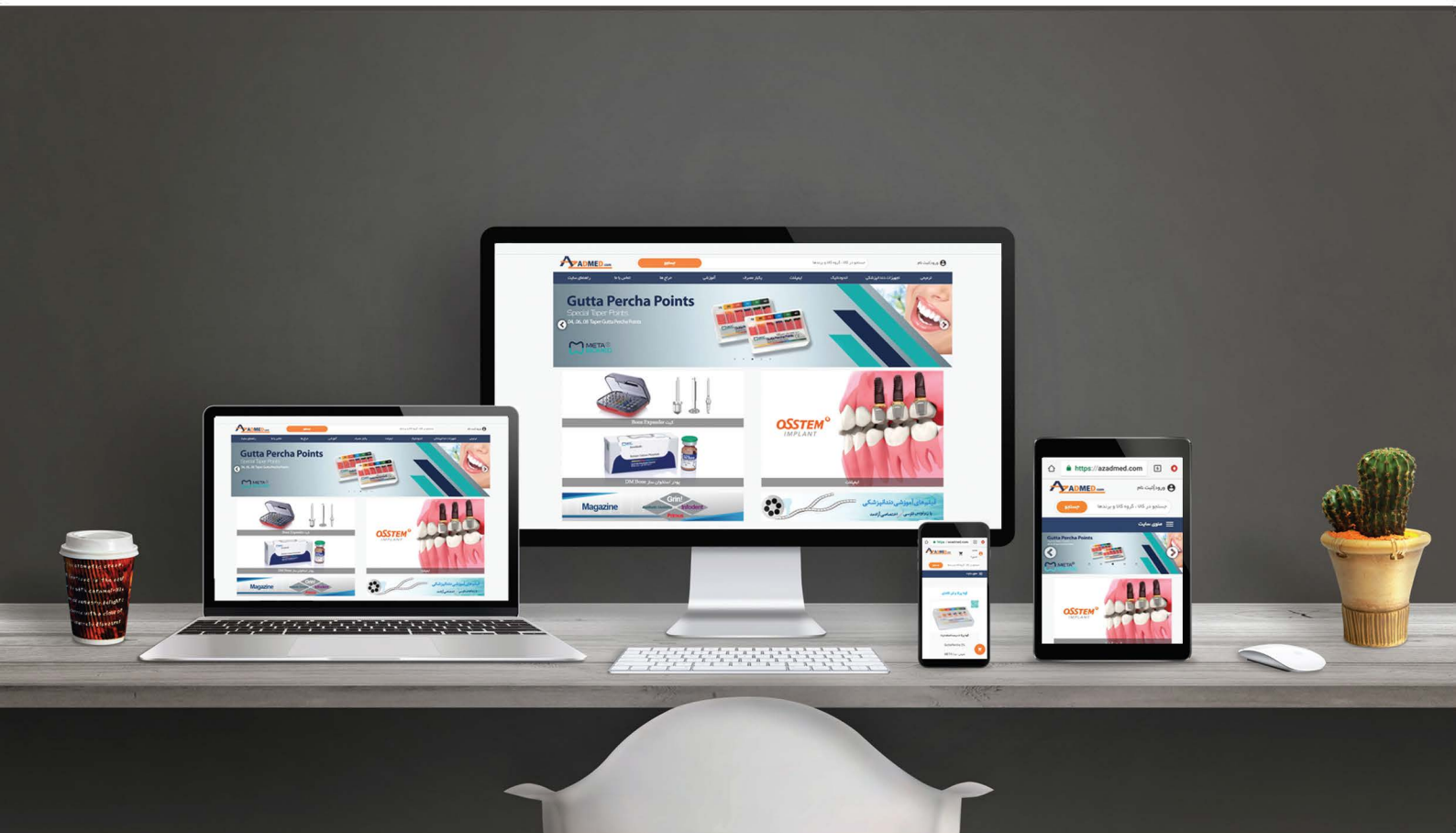




AZADMED.com



www.azadmed.com



 azaadtejaratpars

 @azadmed2

 88 98 80 63 - 6

laser



international magazine of laser dentistry

2 2017



case report

Diode-laser assisted vital pulp therapy

case report

Treatment of black hairy tongue

industry

Laser in soft tissue treatment



The universe at your fingertips.

● LightWalker

The highest technology dental laser system

Supreme clinical results:

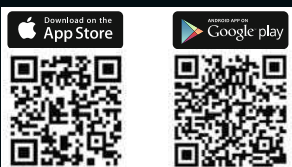
- TwinLight® Perio Treatments
- TwinLight® Endo Treatments
- No-sutures soft-tissue surgery
- Patient-friendly conservative dentistry
- Pre-sets for over 40 applications


Unmatched simplicity of use:

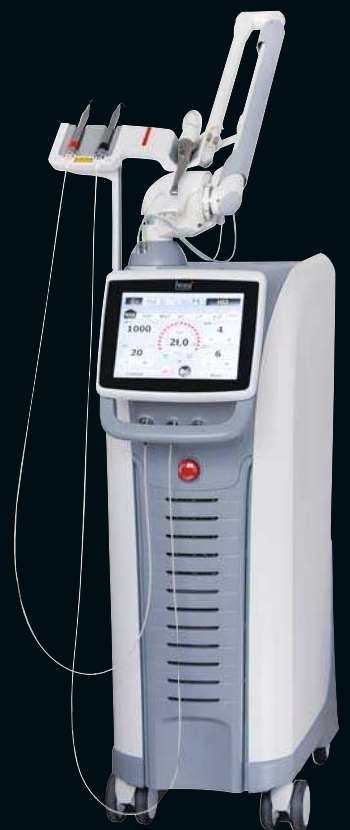- Balanced and weightless OPTOflex® arm
- Nd:YAG handpiece detection system
- Quantum Square Pulse technology for fast minimally invasive treatments
- X-Runner™ - the first digitally controlled Er:YAG dental laser handpiece

Journey into a new dental experience with speed, precision and great results.

Visit www.fotona.com today!



 Fotona App





Prof. Dr Norbert Gutknecht

Sense & sensibility

Dear colleagues,

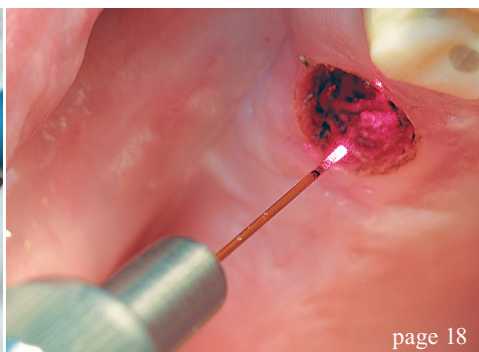
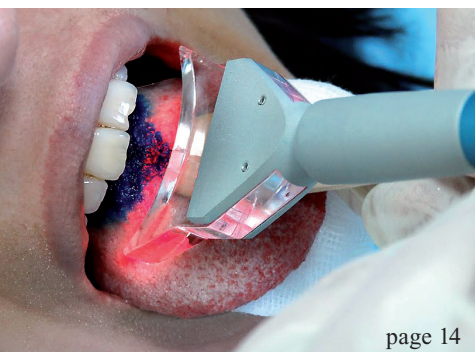When I walked the exhibition grounds of the IDS two and a half months ago, two aspects of the world's largest dental exhibition were especially touching to me. Firstly, the number of participants and exhibitors has increased significantly over the years. And secondly, innovations and digital technologies have gained more presence in dentistry. While originally a merely mechanical type of work, the profession of the dentist has turned into handling a command centre surrounded by various technologies, including the latest laser devices. If you thought that you would find hardly more than four or five laser manufacturers at the IDS only a few years ago, a look into this year's list of exhibitors will have shown otherwise. Not only were there more than 40 laser exhibitors and manufacturers present at the IDS 2017, but the technical development of the laser devices was impressive.

The devices' performance and efficiency, the increasing variability of the laser applicators and the above-mentioned further development of the software presented by many manufacturers demands a higher level of insight in these technologies from the users when treating patients. The laser industry's response to a yet palpable knowledge deficit in this regard covers elaborate treatment animations and extensive default settings for special therapies. A sensible balance of high-tech laser and extensive insights into its appropriate handling will make laser-assisted therapies in dentistry even more effective in the future.

Yours,

A handwritten signature in black ink, appearing to read 'N. Gutknecht'. The signature is fluid and cursive, with a large initial 'N'.

Prof. Dr Norbert Gutknecht



editorial

- 03 Sense & sensibility
Prof. Dr Norbert Gutknecht

case report

- 06 Dual-wavelength laser application
Dr Imneet Madan
- 10 Diode-laser assisted vital pulp therapy
Dr Masoud Shabani *et al.*
- 14 Treatment of black hairy tongue
Prof. Georgi T. Tomov *et al.*

industry

- 18 Laser in soft tissue treatment
Hans-Joachim Koort
- 22 Laser-assisted herpes labialis therapy
Dr Darius Moghtader
- 26 Sealer placement in lateral/accessory canals
Dr He-Kyong Kang & Dr John Palanci

practice management

- 30 Successful communication in your daily practice
Dr Anna Maria Yiannikos
- 32 Marketing dentistry in a global economy
Chris Barrow

events

- 35 This year's IDS sets new record in attendees
- 36 4th International SGOLA Congress
Timo Krause
- 38 Bringing laser to sunlight

news


- 41 manufacturer news
- 42 news international

DGL

- 45 Effizienz & Innovation
Prof. Dr. Norbert Gutknecht
- 46 Laserzahnheilkunde – Was geht und was nicht
- 48 news germany

about the publisher

- 50 imprint



Cover image courtesy of Biolase Technology Inc.
www.biolase.com
Original Background: © Samarets/Shutterstock.com



22 & 23 SEPTEMBER

WFLD-ED 2017
THESSALONIKI
GREECE BRINGING LASER
TO SUNLIGHT



© YK/Shutterstock



6TH EUROPEAN DIVISION CONGRESS OF THE WORLD FEDERATION FOR LASER DENTISTRY

Aachen Dental Laser Center – AALZ
Pauwelsstraße 17 · 52074 Aachen · Germany
Tel.: +49 241 4757130 · info@aalz.de



Dual-wavelength laser application

Dental-fistula in a **primary** anterior tooth

Author: Dr Imneet Madan, UAE

Primary teeth play a vital role in setting the healthy pathway towards permanent dentition. The treatment modalities for primary teeth should therefore be in best favour of preserving these teeth until they exfoliate naturally. Chronic dental caries in primary teeth are the most common cause of premature extractions. The best mode of management is to prevent the onset, nevertheless, when the decay does occur and reach the stage where there is chronic infection leading to periapical areas, laser therapy can be used effectively to save the tooth.

The current case report emphasises on the successful effect of laser in the treatment of fistula in primary upper anterior tooth in a four-year-old female. Laser-assisted endodontic treatment resulted in success and this helped to retain the anterior primary tooth until the permanent tooth will eventually replace it at the age of six to seven years. The child is under periodic follow-up and has had no clinical or radiographic signs of reinfection since the last two years.

Introduction

Primary teeth functions extend far beyond enhancing the smile of the child. They act as the natural space maintainers that can be the best guide in the eruption of permanent teeth in accurate alignment. Primary teeth contribute to the development of jaws, maintain the speech of the child and avoid the development of any parafunctional habits such as tongue thrusting.¹

Considering these vital functions of the primary teeth, it is important that under any given conditions, it should be prioritised to save them and avoid premature extraction. One of the most common reasons for the primary teeth to undergo extraction

is chronic untreated dental caries. Chronic dental carious lesions lead to necrosed pulpal changes and treatment for this is very complex in primary teeth.² Both anatomical and physiological nature of primary teeth does not allow complete elimination of root canal infection. There has been no reported endodontic concept for the treatment of primary teeth so far.³

The microbiology of endodontic infections is complicated. *Enterococcus faecalis* has been reported in high prevalence in primary root canal infections.⁴ However, lasers, by virtue of their deeper permeability help in sterilising the affected and infected canals leading to better success rates with compromised teeth.

Case report

A four-year-old female child reported to the dental clinic after referral from their general practitioner. The child came in with her mom in January, 2015 after a traumatic fall on the upper front teeth a few weeks back. No antibiotics were taken. The upper front tooth had been mobile ever since the fall. The mom took the child to her dentist and they were then referred to consult for an opinion other than extraction.

On intraoral examination

Tooth number 61 presented with grade II mobility and a periapical fistula. An intraoral periapical X-ray showed widening of the periodontal ligament in the periapical area. There were no signs of tenderness to percussion, although the child was in discomfort due to infection and swelling in the gum (Fig. 1).

Discussion prior to the treatment

Based on radiographic and clinical examination, two options of the treatment were given as follows:

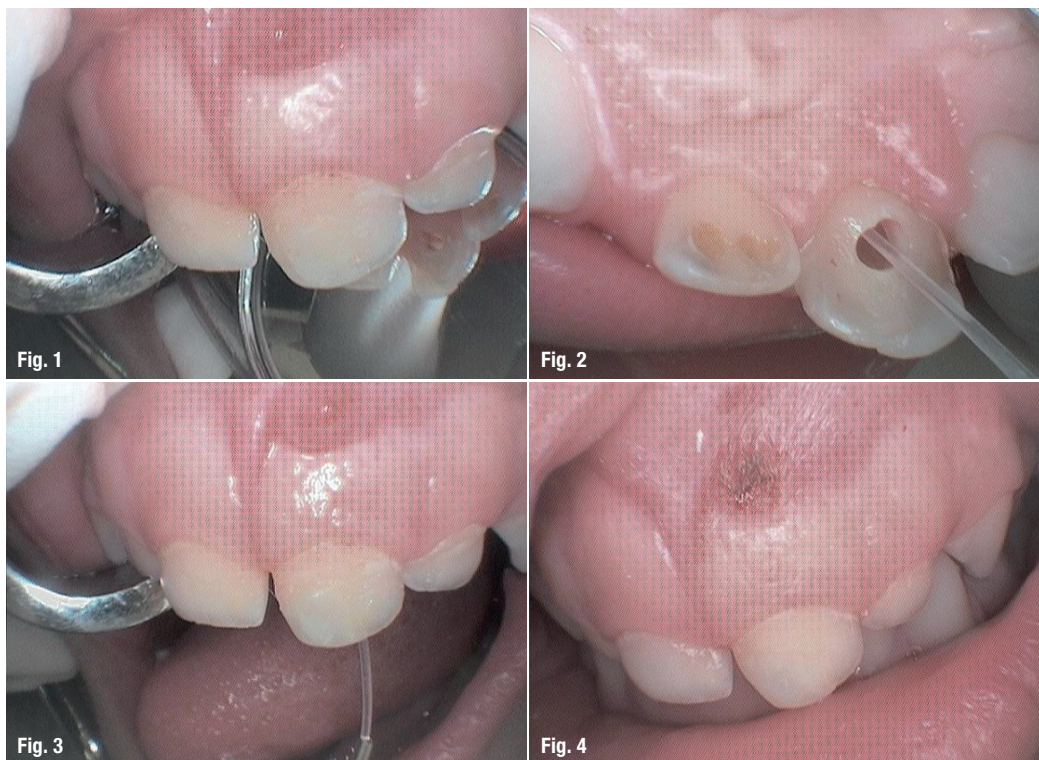


Fig. 1: Primary upper anterior tooth 61 with fistula.

Fig. 2 & 3: Zinc oxide eugenol obturation was done followed by GC Fuji IX base fill and composite fill on top.

Fig. 4: Primary upper anterior teeth after treatment.

Option 1: Extraction followed by fixed space maintainer.

Option 2: Root canal treatment with uncertain prognosis.

Cotton role: Tooth pillow

Irrigation of canals: Wash the sugar bugs

Obturation: Putting cream in the tooth

Filling: Close the hole

The child's mom was informed that after the endodontic treatment of tooth #61, the tooth will be observed for three months and an X-ray will be repeated in order to check the healing of the periapical region. In case that the tooth does not take the treatment successfully and there is a recurrence of the infection, an extraction followed by space maintainer should be planned. The mom understood both of the options and decided to go with option two.

Certain behaviour modelling tools of neuro-linguistic programming were used in order to get the child's attention and cooperation. Since the child was able to listen and agree in the best manner; the steps for next visit were informed. She was very fond of Barbie princess stories, so we agreed on telling the princess stories and watching the same in the next visit. The child then left the surgery with a small reward as a positive reinforcement of good behaviour and good listening.

Dental behaviour

The child was young, thereby, apprehensive and fearful towards the dental treatment. The Dental Behaviour Management was as following: It was suggested to use the conscious sedation with nitrous oxide. On the first visit, no treatment was performed. The child was acquainted with the dental chair, basic dental tools, water, air syringe, nasal mask and laser.

Before leaving, the "Next Time Behaviour" message was given and reinforced with small stickers. This was done to serve as a reminder for the child to be brave next time as well.

Nitrous oxide sedation

Nitrous oxide is a friendly gas that helps to relax the receptors in the way that the child acts more receptive to the instructions during the dental procedure. It does have an analgesic or anxiolytic effect that causes temporary depression of the central nervous system with very little effect on the respiratory system. It gets absorbed rapidly but stays relatively insoluble into any tissues in the body. At the end of the procedure, 100 per cent oxygen is used to flush out nitrous oxide. There is minimal impairment of any reflexes, thus cough reflex is protected.⁵

Euphemisms involved in the treatment were explained as follows:

Nasal Mask: Happy air

Laser: Popping light

Dental caries: Sugar bugs

Dental cavity: Hole

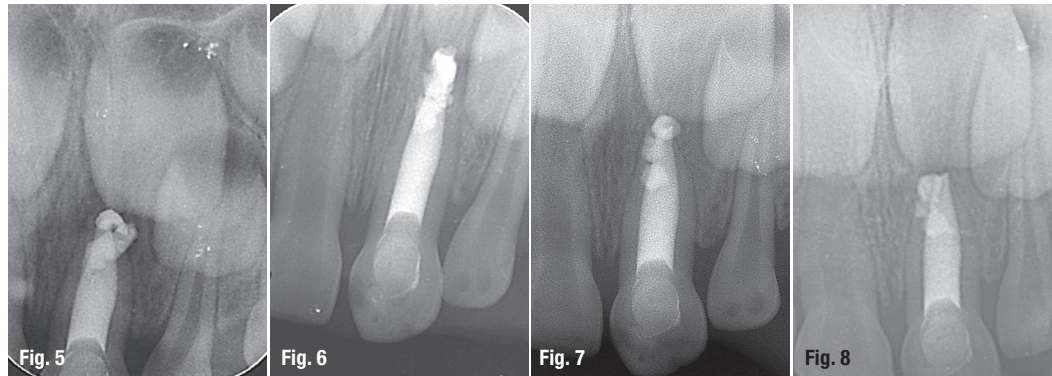
Water: Washing the sugar bugs

Fig. 5: X-ray of the primary upper anterior teeth after treatment.

Fig. 6: X-ray, follow-up after four months.

Fig. 7: X-ray, follow-up after nine months.

Fig. 8: X-ray, follow-up after eighteen months.



Informed consent

Due to the nature of pathology, uncertain prognosis for the treatment was suggested. The child's mom understood that in case of failure of treatment, retreatment is not recommended. The tooth would be extracted in such a scenario. Cost estimates for both options were given. The mom chose the treatment plan with laser under conscious sedation. Written consents for the agreed treatment, nitrous oxide sedation and costs were taken.

Procedure

As the child was seated in the chair, basic neuro-linguistic programming techniques were used to get her attention to follow the instructions of deep breathing. One of the introductory techniques is to ask the child to "imagine". As she began to imagine her own creations such as clouds, butterflies, flower garden, she was guided into deep breathing. Further continuation of stories and metaphors helped to place the mask.

Nitrous oxide was slowly increased to 50 per cent and then finally settled at 55 per cent. During this euphoric state, the child chose to watch a movie on the overhead screen. She was allowed to relax in this state for five minutes before the procedure was started. After that, an erbium laser access from the palatal surface was done with following settings: Er,Cr:YSGG 2,780 nm, MX7 tip, 3.75 W, 25 Hz, 80 water, Air 60. Rotary instruments, TCM prep, were used to enlarge the canals until ISO #35. Intermittent irrigation with saline and chlorhexidine was done. The erbium laser was used for initial sterilisation of the canals with following settings: Er,Cr:YSGG 2,780 nm, RFT2, 1.25 W, 50 Hz, Air 34, Water 24. Paper points were then used to dry the canals. A diode laser 940 nm, 1.5W, continuous wave, 2 mm/sec, 4–5 turns in circular motion was used. An interim temporary filling was placed in order to allow the fistula to heal before the final obturation.

After three days, the tooth was reintervened. The temporary fill was removed and the canals were re-irrigated with saline and chlorhexidine. Both erbium and diode laser were used to sterilise the radicular and

periapical area. Since the canals had no bleeding and were completely dry, zinc oxide eugenol obturation was done followed by GC Fuji IX base fill and the composite fill on the top (Figs. 2-5).

After four months, the child presented with no clinical signs or symptoms. An intraoral periapical X-ray showed no abnormal changes (Fig. 6). The child was able to eat, chew and there had been no recurrence of infection since the completion of treatment.

The follow-up after nine and eighteen months shows no clinical or radiographic changes (Figs. 7 & 8). The child has been completely asymptomatic and the tooth showed normal signs of physiological resorption (Fig. 9).

Discussion

Primary teeth act as the natural blue print for the eruption of permanent teeth. They facilitate vital functions:

- Act as a natural space maintainers for the teeth.
- Support proper chewing and digestion of the food.
- Help in normal development of speech.
- Add to self-esteem and confidence of the child.

Early loss of primary teeth can interrupt a proper development of the speech. It can also lead to tongue interposition and development of parafunctional oral habits. Keeping the above functions in mind, it is ideal not to decide to savage the primary tooth until it is time for the new permanent teeth to erupt.

The microbiology of fistula

The microbiology of fistula has been reported to be quite complex. Even though, the details of the same are scarce. The deep areas of periapical region and around do not provide oxygen to feed the bacteria; hence, it is mainly the anaerobic population that dwells here quite well. These bacteria can result in pain, swelling, tenderness and exudation of pus.

A high prevalence of *Enterococcus* species and *P. gingivalis* has been observed in the necrotic pulp of

2 to 5 years old. Since *E. faecalis* is very resistant to antimicrobials, this makes the endodontic treatment of primary teeth a bit more challenging.⁴ *P. gingivalis* has been found to affect about 27 per cent of primary teeth.^{6,7} *P. nigrescens*, *P. intermedia* and *P. endodontalis* also contribute to the infectious process of the pulp.³ Other bacteria that are found to contribute as well are *Fusobacterium nucleatum*.⁸ Bacterial associations such as Porphyromonas/Prevotella species and *P. gingivalis*/Enterococcus species had been found in primary teeth as per few studies done on the microbiology of the deciduous teeth with periapical abscess and fistula.⁹ Spirochaetes such as *Treponema denticola* are also profound.⁷ *Enterococcus faecalis*, *P. gingivalis* and *F. nucleatum* were found in extensive numbers especially in the fistula related to primary teeth.³ It is the complex nature of the primary root canal microbiology that renders the conventional treatment supported only with antimicrobial not 100 per cent successful.

Complex microbiology that demands laser

There are predominantly two factors that complicate the success of primary teeth root canals:

1. Anatomical root configuration
2. Complex resident bacterial flora¹⁰

The presence of lateral canals and a predominant number of canal openings in the apical delta is a specific anatomical variation of baby teeth. Blind ending canals called Diverticles pass through the root dentin.¹⁰ Additionally, dentinal tubules run through the entire dentine in complex manner and store the bacteria at the depth of up to 1,000 μm .^{11,12} At this depth, the microbes are able to sustain against the body's own defences and conventional pulpectomy procedures.^{11,12}

The conventional irrigants used in pulpectomy can penetrate to the depth of about 100 μm .¹³ Lasers of different wavelengths have been used in the root canals and have shown the depth of penetration between 500 μm to less than 1,000 μm .¹⁰ Laser light

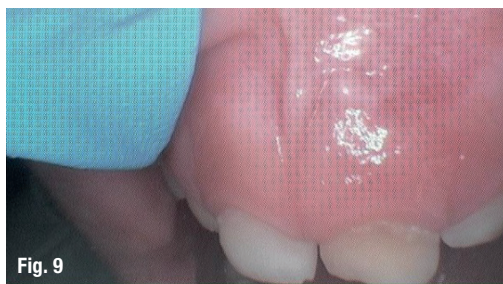

Fig. 9: The child has been completely asymptomatic and tooth showed normal signs of physiological resorption.

causes permanent destruction of the microbial cell membrane and thereby stops their further growth.¹⁰

Conclusion

Primary tooth endodontics has gained utmost importance in the past few decades, where parents come seeking root canal treatments for the chronically affected primary teeth. Those who are not aware of the same are educated about the importance of baby teeth at the first appointment. Parents feel more assured when a successful alternative to extraction is given.

Even if teeth are in grossly decayed shapes, laser-assisted endodontics proves successful in the lasting success of the treatment until the tooth exfoliates on its own.

contact

Dr Imneet Madan

Specialist Pediatric Dentist
MSc Lasers Dentistry (Germany)
MDS Pediatric Dentistry
MBA (Hospital Management)
Children's Dental Center, Dubai
Villa 1020 Al Wasl Road, Umm Suqeim 1
Dubai, United Arab Emirates
Tel.: +971 506823462
imneet.madan@yahoo.com
www.drmmichaels.com

Author details



Kurz & bündig

Das Milchzahngebiss setzt die Grundlage für die bleibenden Zähne. Daher sollte bei einer Behandlung die Bewahrung der Milchzähne im Vordergrund stehen, solange, bis diese von alleine ausfallen. Die beste Behandlungsstrategie ist Prävention. Sollte es doch einmal zu einem vorzeitigen Verfall und einer chronischen Infektion kommen, die bis in den periapikalen Bereich vordringt, kann eine Lasertherapie effektiv sein und zur Rettung des Zahns beitragen. Im Fallbericht schildert die Autorin den erfolgreichen Einsatz des Lasers bei der Behandlung einer Fistel im oberen Frontzahn einer vier Jahre alten Patientin. Die laserunterstützte, endodontische Behandlung führte zum Erfolg und trug dazu dabei, den Oberkieferfrontzahn im Milchzahngebiss bis zum Zahnwechsel im Alter von sechs bis sieben Jahren zu bewahren. Das Kind kommt zu regelmäßigen Kontrollterminen in die Praxis und zeigt seit zwei Jahren keine klinischen oder radiologischen Anzeichen einer erneuten Infektion.

Literature



Diode-laser assisted vital pulp therapy

Authors: Dr Maziar Mir, Prof. Dr Norbert Gutknecht, Dr Masoud Mojahedi, Dr Jan Tunér & Dr Masoud Shabani, Germany, Iran, Sweden

Introduction

The preservation of pulp vitality is one of the most challenging approaches in endodontics. In Vital Pulp Therapy (VPT), after pulp exposure due to extensive dental caries, tooth injuries and iatrogenic events, the intact portion and uninflamed dental pulp is preserved with a suitable dressing at the exposure area. The dressing materials are biocompatible or bioactive.¹⁻³ At the moment, different methods for VPT are used, including: (1) direct pulp capping, (2) indirect pulp capping, (3) partial pulpotomy and (4) full pulpotomy. Pulp dressing in these methods is performed using mineral trioxide aggregate (MTA), calcium-enriched material (CEM), calcium hydroxide and biodentin.⁴⁻⁶ Bleeding control and pain reduction are the most common complications in partial or full pulpotomy.⁷ Lasers have several benefits in endodontic treatment, for example: (1) pulp diagnosis, (2) dental hypersensitivity reduction, (3) pulp capping, (4) pulpotomy, (5) disinfection of root canals, (6) root canal shaping, (7) root canal obturation, (8) apicectomy and (9) root canal photodynamic therapy.⁸ Dental lasers are either Class 3B (< 500 mW) or Class 4 (< 500 to 5,000 mW). The former lasers are used for biostimulation (Low Level Laser Therapy—LLLT), whereas the latter are used for evaporation, coagulation, cutting, etc. Most lasers in both groups are based on diodes, but the 500+ mW lasers are often called "diode

lasers". Although particularly used for such procedures, they can also be set at their lowest output and be used as biostimulators in a defocused mode. In the current case, a Class 4 laser in defocused mode was used for biostimulatory purposes in a case of VPT.⁸⁻⁹

Case report

An 18-year-old female patient with complaints due to a right permanent molar tooth with deep caries was referred for treatment.

Medical history

The patient's medical history showed neither systemic medical problems nor any allergic reaction, pharmaceuticals or history of past surgical procedures. Thus, the patient did not need to be referred for medical consultation.

Dental history

Oral and maxillofacial examination of the patient revealed no TMJ or myofascial disturbances, no functional or parafunctional habits, Class I occlusion, but a relatively poor oral hygiene.

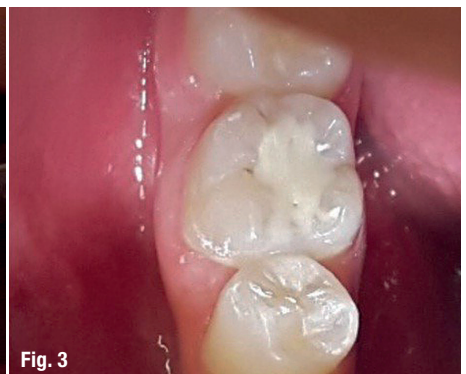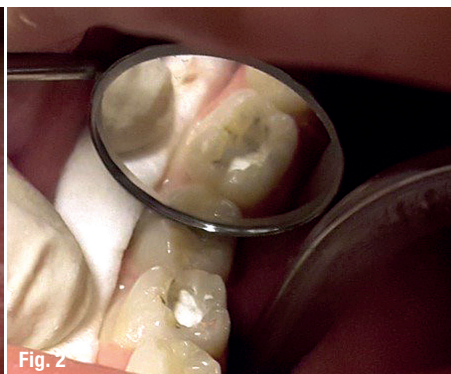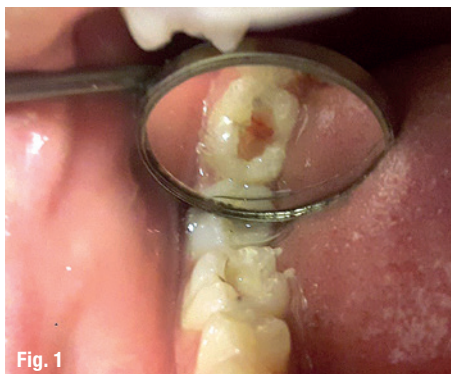Clinical findings

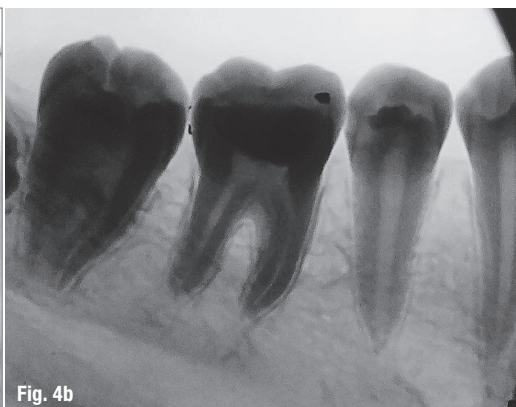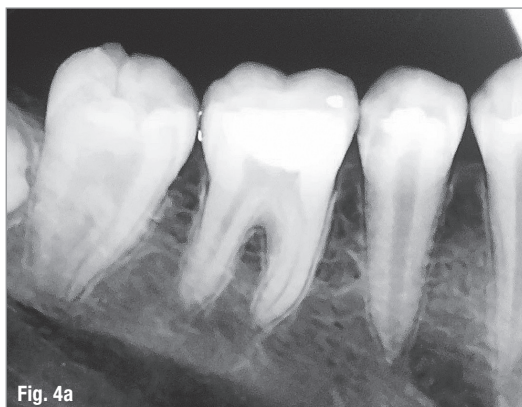Intermittent pain during the last 24 hours, binding of explorer at the occlusal surface was obvious, thermal and cold vitality pulp tests were positive.

Fig. 1: Immediately after pulpotomy with high-speed handpiece and good coagulation with diode laser and then LLLT treatment.

Fig. 2: After CEM cement placement.

Fig. 3: Immediately after interim restorative treatment (IRT) with Glass ionomer cement (GC Fuji IX).





Figs. 4a & b: X-ray examination immediately after VPT.

X-ray examination

X-ray examination showed a radiolucent lesion near the dental pulp.

Diagnosis

A reversible pulpitis was diagnosed.

Laser-assisted VPT procedure

Treatment delivery sequence

After fulfillment of the consent form, the operation area was anaesthetised by infiltration method and 2% lidocaine with Epi 1:80,000, 1.8 ml (Darou Paksh, Tehran, Iran). The controlled area and proper placing of the laser warning signs were defined to secure the operating room. The protective goggles for patient, operator and assistant were checked. Furthermore, the patient's information (examination sheet and X-ray, consent form, etc.) was reviewed.

Mouth rinsing was done by 0.2% chlorhexidine oral rinse (Shahre Daru, Tehran, Iran) for one minute and then the surface of the tooth was cleaned by a swab wetted by the same chlorhexidine solution.

Cavity preparation was performed by fissure diamond burs and then round stainless-steel burs. After caries removal, the pulpal bleeding was obvious and a partial pulpotomy was indicated.

Partial pulpotomy was started with sterile round diamond bur on a high-speed handpiece to remove the inflamed pulp tissue gently via normal saline irrigation. Haemostasis was obtained by cotton pellet soaked in normal saline for five minutes and then followed by diode laser irradiation.

CEM cement dressing was applied with a base of 2 mm CEM cement paste according to the manufacturer's instruction (Biunique Dent, Tehran, Iran) using a sterile plastic instrument and then the dry sterile cotton pellet was used for more adaptation of CEM cement to the cavity wall (Fig. 2).

Interim restorative treatment (IRT) was applied with Glass Ionomer GC Fuji IX according to the manufacturer's instruction without finger pressure (Fig. 3). Permanent filing was postponed for one month.

Laser parameters

The laser parameters were as follows:

- For bleeding control: 980 nm (diode laser, Wuhan Gigaa, Wuhan, China), power 0.8 W, 8 Joule, fibre 400 µm, non-initiated fibre, CW, non-contact mode, 10 seconds in scanning mode (Fig. 1)
- For pain reduction: 980 nm, output power 0.3 W, irradiation time 10 s, 3 Joule, spot size 3 mm, power density 4, 246 W/cm² at the end of low-level handpiece. The cavity diameter was 4 mm, irradiation area 0.1256 cm², power density at the target surface 2.388 W/cm², dose 23, 88 J/cm², non-contact (5 mm away from the exposure area), scanning mode, single dose

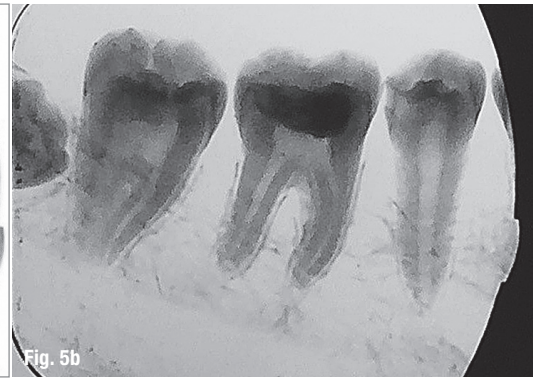
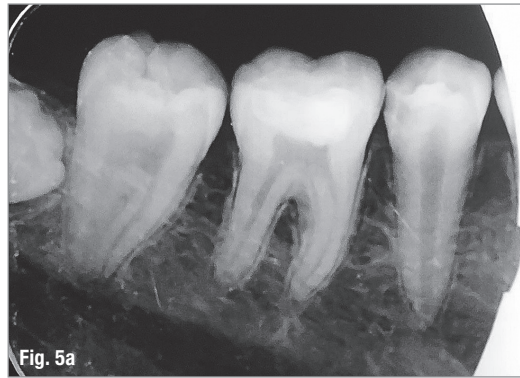Final result

Excellent VPT was observed with no bleeding, no carbonisation and no char. The patient did not experience any discomfort and was satisfied. Radiographic examination was taken in order to follow the result of laser-assisted pulpotomy based on radiographic changes (Figs. 4a & b).

Follow-up

The first visit after VPT was one day after the procedure. There was no pain, therefore, a second LLLT was not deemed necessary. The next visit was determined two days after the procedure via telephone conversation in order to check on the pain degree based on VAS scaling (Visual Analogue Scale). Since there were no symptoms, the final visit was determined to be one month after the procedure. Finally, after one month follow-up, a successful treatment was observed clinically (positive thermal pulp vitality test) and with radiographic examination (Figs. 5a & b).

Figs. 5a & b: X-ray examination five weeks after VPT. A successful treatment was observed clinically (positive thermal pulp vitality test) and with radiographic examination.



Discussion

Diode laser is extensively used in many dental practices.⁹ Laser-tissue interaction with high power diode lasers is based on photothermal effects contrary to LLLT, where there is no photothermal effect, but based on photochemical mechanisms.^{10,11} Since LLLT is dose-dependent,¹² the laser parameters have to be respected carefully.^{13,14} The precise molecular mechanisms for LLLT are not too clear, but the clinical effects on pain control, inflammation reduction and wound healing are well investigated.¹⁵⁻¹⁷ Gupta et al. reported that laser pulpotomy showed clinical and radiographical results superior to those of electro-surgery and ferric sulfate pulpotomy in human primary molars, using high power diode laser in order to achieve good coagulation.¹⁸ Uloopi et al. applied LLLT in pulpotomy and noted that this treatment modality can be considered for primary teeth pulpotomy and its success was comparable to MTA pulpotomy technique.¹⁹ It is obvious that the use of diode laser application in

pulpotomy can be twofold. In this case, higher power was first used for good coagulation and LLLT was then used in for pain reduction and anti-inflammatory purposes.

Conclusion

Diode laser based on the protocol applied in this study can successfully be used in Vital Pulp Therapy.

contact

Dr Masoud Shabani

Deputy for Research, Ardabil University of Medical Sciences, Ardabil, Iran
Conservative Dentistry, RWTH International Academy, Aachen, Germany
m.shabani@arums.ac.ir

Author details



Kurz & bündig

Im Rahmen der VPT (Vital Pulp Therapy) wird der Erhalt der intakten, nicht entzündlichen Pulpa nach Kariesinfektion, Zahntrauma oder iatrogenen Vorfällen durch einen entsprechenden Verband im Expositionsbereich erzielt. Die hierfür verwendeten Materialien sind biokompatibel oder bioaktiv.¹⁻³ Die aktuellen VPT-Verfahren schließen ein: (1) direkte Überkappung der Pulpa, (2) indirekte Überkappung der Pulpa, (3) teilweise Pulpotomie und (4) vollständige Pulpotomie.

Die Blutungskontrolle sowie die Schmerzlinderung zählen zu den häufigsten Komplikationen der teilweisen oder vollständigen Pulpotomie.⁷ In diesem Zusammenhang können sich die Vorteile der Laseranwendung positiv auf das Komplikationsmanagement der Pulpotomie sowie des Erhalts der Pulpa auswirken und kommen bei folgenden Behandlungsabschnitten zum Einsatz: (1) Pulpadiagnose, (2) Reduktion dentaler Hypersensitivität, (3) Überkappung der Pulpa, (4) Pulpotomie, (5) Desinfektion des Wurzelkanals, (6) Wurzelkanalerweiterung, (7) Obturation, (8) Wurzelspitzenresektion und (9) photodynamische Therapie.⁸ Diodenlaser können dabei auch als Biostimulatoren fungieren, wenn sie mit geringster Leistung und im nicht fokussierten Modus eingesetzt werden. So wurde im vorliegenden Fall ein Klasse IV-Laser im nicht fokussierten Modus zur Biostimulation im Rahmen der VPT eingesetzt.^{8,9}

Die Behandlungsergebnisse zeigten weder Blutung, noch Karbonisation, Vernarbung, Nebenwirkungen, jedoch eine hohe Patientenzufriedenheit. Das Follow-up nach einem Monat bestätigte klinisch (positiver thermaler Pulpa-Vitalitätstest) sowie radiologisch den Behandlungserfolg. Die Autoren fassen daher zusammen, dass der Diodenlaser gemäß dem im Artikel vorgestellten Behandlungsprotokoll erfolgreich im Rahmen der VPT eingesetzt werden kann.

Literature





Master of Science (M.Sc.) in Laser in Dentistry

Next Start: **09th October 2017** | Aachen, Germany | 4 semesters



Become part of the International Dental Elite

- Create new economic potential for your practice
- Two year career-accompanying postgraduate programme at the University of Excellence RWTH Aachen
- Combination of lectures, skill training sessions, live ops, tutorials, and practical workshops
- Internationally accepted and accredited by the German Government, the European Union, the Washington Accord and the Bologna Process
- Science-based and practice-orientated on highest national and international level
- Increased patient satisfaction: minimal contact reduced vibration and pain

**RWTH INTERNATIONAL
ACADEMY
AACHEN UNIVERSITY**

RWTH International Academy
Kackertstraße 10 | 52072 Aachen | Germany
phone +49 241 80 23543 | fax +49 241 80 92525
info@academy.rwth-aachen.de
www.academy.rwth-aachen.de

AALZ

Aachen Dental Laser Center

AALZ GmbH
Pauwelsstraße 17 | 52074 Aachen | Germany
phone +49241 47 57 13 10 | fax +49 241 47 57 13 29
info@aalz.de
www.aalz.de



PROFESSIONAL EDUCATION PROGRAMMES

Your contact for more information: Leon Vanweersch • vanweersch@aalz.de - www.aalz.de

Treatment of black hairy tongue

Authors: Prof. Georgi T. Tomov, Michail Batilas & Pavlos Spyrrantis, Bulgaria

Black hairy tongue (BHT) is a benign medical condition characterised by elongated filiform papillae with typical appearance of the dorsum of the tongue.¹ Its prevalence varies ranging from 0.6 to 11.3 per cent.²⁻⁴ Known predisposing factors include smoking, excessive coffee/black tea consumption, poor oral hygiene, xerostomia, and antibiotics use.^{5,6} Complications of BHT (burning mouth syndrome, halitosis, dysgeusia) respond poorly to conventional therapy.^{1,7} The treatment of BHT involves the identification and discontinuation of the offending agent, modifications of chronic predisposing factors, patient's reassurance to the benign nature of the con-

dition, and maintenance of adequate oral hygiene with gentle debridement to promote desquamation.

The use of antimicrobial therapies, topical triamcinolone acetonide, gentian violet, salicylic acid, vitamin B complex, thymol, and topical or oral retinoids, as well as keratinolytics (podophyllin), topical 30 per cent urea solution, and trichloroacetic acid have been reported in the literature, although potential side effects from local irritation and possible systemic absorption are important factors to consider.^{1,7} In the available literature, lasers are not reported as therapeutic modality for the treatment of BHT.

The aim of this article is to report about a new approach applied in the treatment of BHT, using a combination of laser ablation with Er:YAG laser and toluidine blue-mediated photodynamic therapy (PDT) with diode laser.

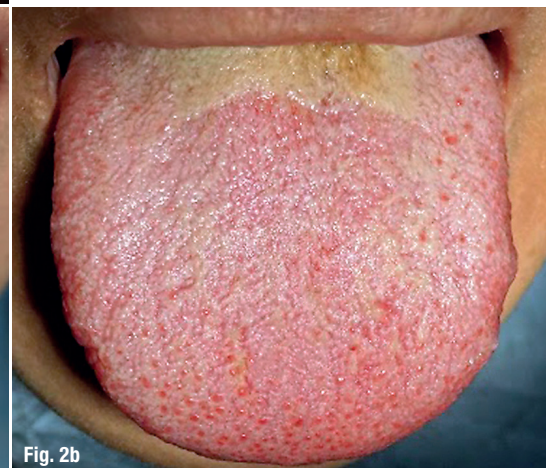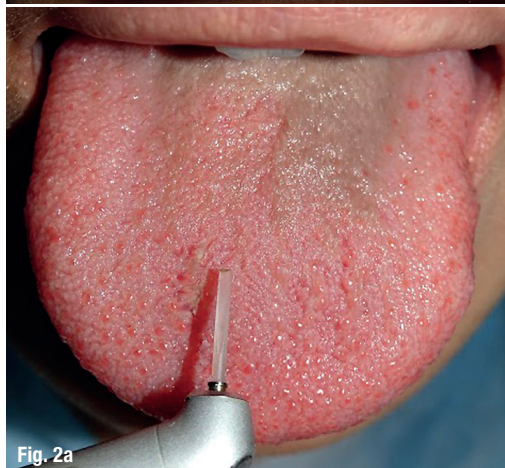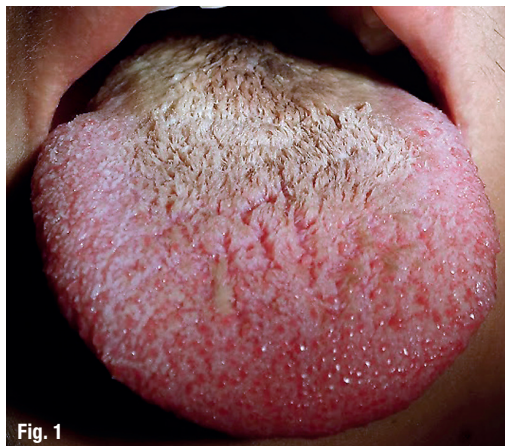Case report

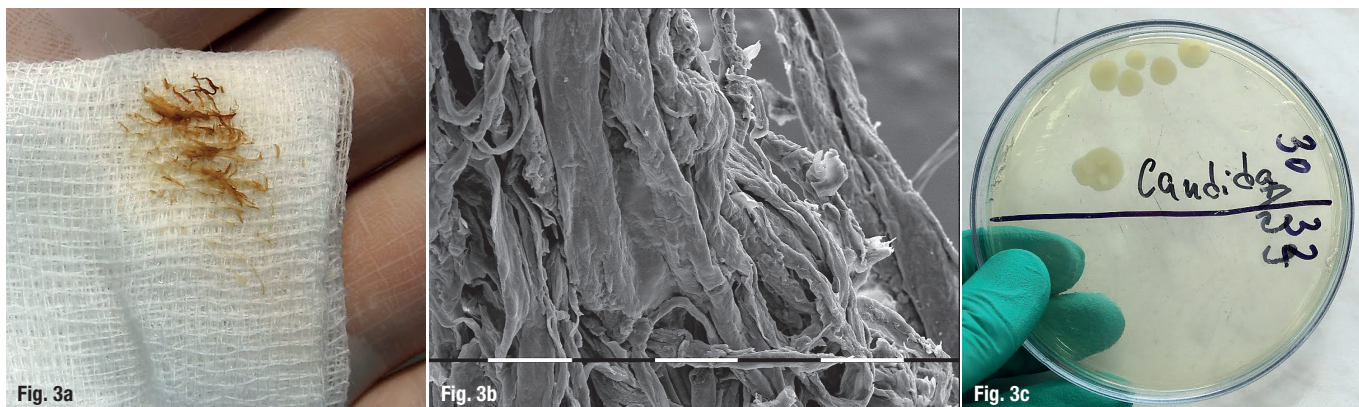
A 37-year-old female patient complained about an abnormal appearance of her tongue of seven months duration. The patient noted a bad taste in her mouth. Shortly before the oral complaint onset she was prescribed antibiotics for sinusitis. Additionally, the pa-

Fig. 1: Appearance of patient's tongue on initial presentation.

Fig. 2a: The "chisel" tip is positioned parallel to the dorsal plane in order to cut the papillae without damaging the tongue.

Fig. 2b: Visible borderline between ablated and no ablated area.





tient smoked more than one pack of cigarettes per day. Physical examination demonstrated a light brown, "furry" dorsal surface on the tongue (Fig. 1). The patient was diagnosed with black hairy tongue. After obtaining a written consent by the patient, a new approach was applied to treat the condition using a combination of laser ablation with Er:YAG laser and methylene blue-mediated photodynamic therapy (PDT) with diode laser.

Ablation therapy

During the first treatment session, the elongated papillae were ablated with Er:YAG laser (LiteTouch, Light Instruments, Israel) using "chisel" tip at the following parameters: 200 mJ/18 Hz (3.6 W) with water cooling. Only topical anaesthesia with 10 per cent lidocaine spray was performed prior to the procedure (Figs. 2a & b). The removed papillae were microbiologically tested and evaluated under SEM (Fig. 3).

Toluidine blue-mediated photodynamic therapy

The laser ablation of the elongated papillae of the tongue enhanced the consequent PDT (one day after) due to the better penetration of laser light and spread-

ing of the photosensitiser over the affected area. Five sessions of PDT were performed with the toluidine blue photosensitiser at a concentration of 0.5 per cent applied on the dorsum of the tongue. After five minutes of pre-irradiation time for photosensitiser penetration, the excess was removed and laser activation was done with infrared (890 nm and wavelength of aiming beam 635 ± 10 nm) diode laser (LITEMEDICS dental laser, LAMBDA SpA, Italy) using a bleaching handpiece at 0.5 W (cw) for 60 seconds (Fig. 4).

Results

Follow-up examinations one month as well as three, six and twelve months later revealed significant improvement of the condition with no signs of relapse (Fig. 5).

Discussion


The pathophysiology of BHT has not been fully elucidated.^{1,7} Defective desquamation of the dorsal surface of the tongue is described in a SEM study.⁸ Our findings confirmed these conclusions. This morphology prevents normal debridement, leading to an

Fig. 3: The removed "hairs" (a) observed under SEM (b) are highly elongated cornified spines that result from delayed desquamation of the cells in the central column of filiform papillae and marked retention of secondary papillary cells. The microbiological tests revealed *Candida albicans* infection (c).

ANZEIGE

Publish your expertise!

Become an author for **laser**—international magazine of laser dentistry



Please contact: Georg Isbaner · Editorial manager
g.isbaner@oemus-media.de

© Peshkova/Shutterstock.com

OEMUS

Fig. 4: Toluidine blue-mediated photodynamic therapy (PDT) with diode laser.

Fig. 5: Appearance of patient's tongue after six months of therapy.

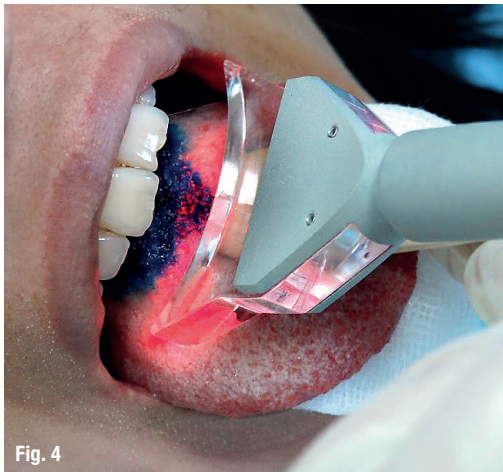


Fig. 4

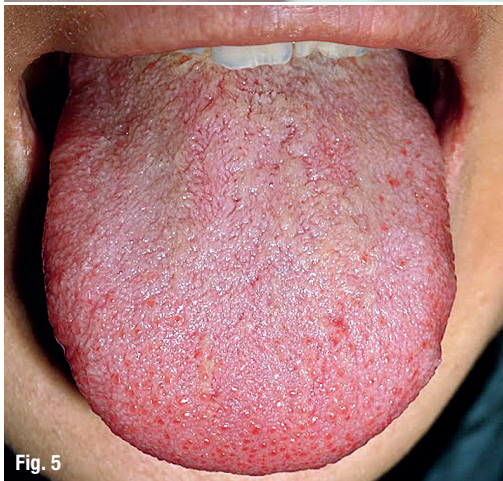

Fig. 5

accumulation of keratinised layers so the elongated papillae secondarily collect fungi and bacteria. Our patient was also positive for *Candida albicans* that is easily harboured in this retentive niche. For these reasons, the therapy effectiveness depends on the ability to remove the hyperkeratinised layer for a better antifungal therapy.

In the available literature, many treatment modalities exist, which generally means that the existing methods are ineffective.^{1,7} The efficacy of tongue scraping is also questionable. The benefits of the pro-

posed combined laser therapy include mechanical removal of the papillae by ablation with Er:YAG laser and consequent local photodynamic therapy. Photodynamic therapy (PDT) has been investigated as a potential antimicrobial therapy and an alternative tool against some infectious diseases in the oral cavity.⁹ The toluidine blue photosensitiser used in this study is absorbed well by the aiming beam of 635 nm. Similarly to methylene blue, toluidine blue has a low antiseptic effect.

Conclusion

There are many possible causes of BHT. It is important for the clinician to take an accurate and detailed history in order to determine the most likely causal agents. The treatment should be individualised, based on the clinician's assessment of the aetiological agents. This case demonstrated a successful resolution of the condition using combined laser therapy. This new modality offers possibilities for both removal of the papillae by ablation and consequent local photodynamic therapy with pronounced antifungal effect.

contact

Prof. Georgi T. Tomov
 DDS, MS, PhD
 Associate Professor and Chair of
 the Department of Oral Pathology,
 Faculty of Dental Medicine
 Medical University of Plovdiv, Bulgaria
 dr.g.tomov@gmail.com

Author details



Kurz & bündig

Die schwarze Haarzunge (engl. black hairy tongue; BHT) ist eine harmlose Erkrankung, die gekennzeichnet ist durch eine Verlängerung der Papillae filiformes, mit einem haarigen und dunklen Belag auf dem Zungenrücken.¹ Die Prävalenz zur Entwicklung von BHT liegt zwischen 0,6 und 11,3 Prozent.²⁻⁴ Begünstigt wird die Erkrankung durch Faktoren wie Rauchen, übermäßiger Kaffeekonsum, schlechte Mundhygiene sowie die Einnahme von Antibiotika.^{5,6} Bei der Therapie geht es vor allem darum, die krank machenden Erreger zu beseitigen. Ein neuer Ansatz in der Behandlung von BHT ist dabei die Kombination aus Laserablation mit dem Er:YAG-Laser und Toluidinblau-vermittelter photodynamischer Therapie (PDT) mit dem Diodenlaser. Im Falle einer 37-jährigen, weiblichen Patientin konnte die schwarze Haarzunge durch einerseits Beseitigung der Papillen mittels Laserablation und andererseits consequent lokaler photodynamischer Therapie mit stark antimykotischer Wirkung erfolgreich behandelt werden.

Literature





CROIXTURE

PROFESSIONAL MEDICAL COUTURE



NEW COLLECTION

EXPERIENCE OUR ENTIRE COLLECTION AT WWW.CROIXTURE.COM

Laser in soft tissue treatment

Author: Hans-Joachim Koort, Germany

The combination of a 975 nm diode laser and a 2.2MHz radio frequency generator in one device (LaserHF; MedLas Medical) has proven to be a unique and valuable solution for the dental soft tissue management. In search for optimal instruments for dental soft tissue treatment both laser and radio frequency devices have shown a satisfying performance. In both technologies, the rapid and locally precise heating of soft tissue is used for cutting as well as for coagulating.

Laser vs. radio frequency

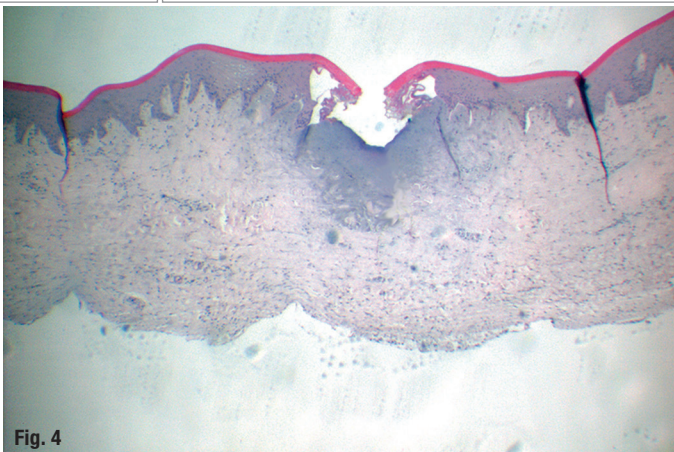
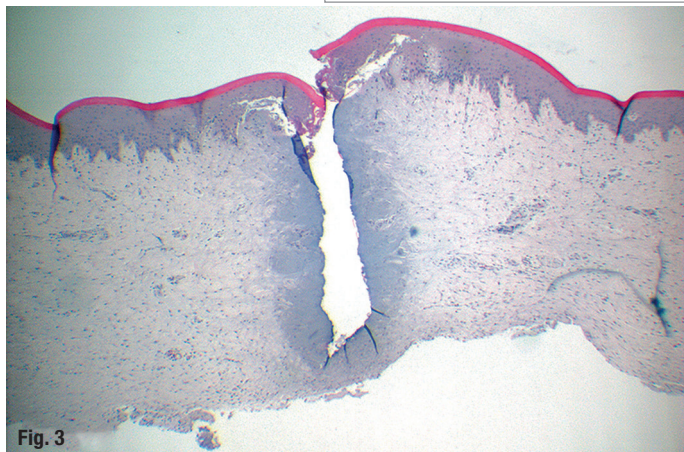
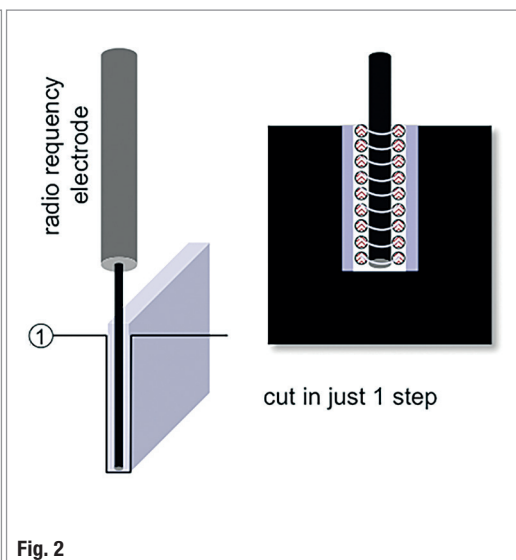
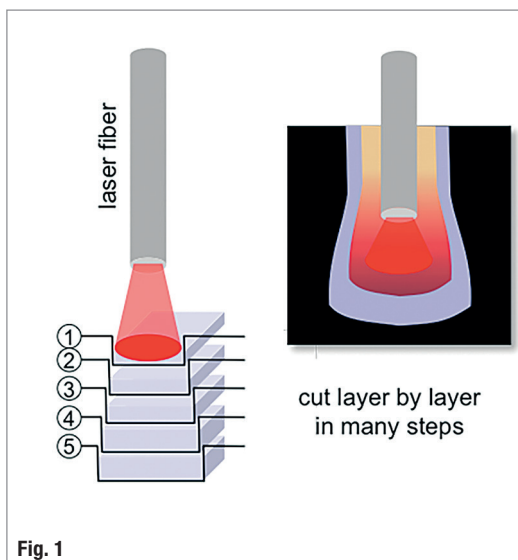
The well-known advantages of laser light become obvious in superficial applications, as for example in the elimination of bacteria in periodontic and endodontic treatments, to expose overgrown implants or trim gingival tissue. However, there are differences in the use of laser. Especially in surgical procedures when a higher power is requested such as in the removal of fibroma and

Fig. 1: Cutting of tissue with laser: The tissue is removed layer-by-layer; the deeper the cut, the greater the heat damage at the lesion base. Since the emitted laser radiation also heats the fibre end, the tissue is exposed to additional stress.

Fig. 2: Cutting of tissue with radio frequency: The tissue is removed by only one precise, uniform section in the entire length of the inserted electrode. The metal electrode remains cold at 2.2MHz.

Fig. 3: Histological section of standardised gingiva sample (HE-staining) with radio frequency at 2.2MHz, 20W permanent.

Fig. 4: Histological section of standardised gingiva sample (HE-staining) with laser at 975 nm, 3W cw.



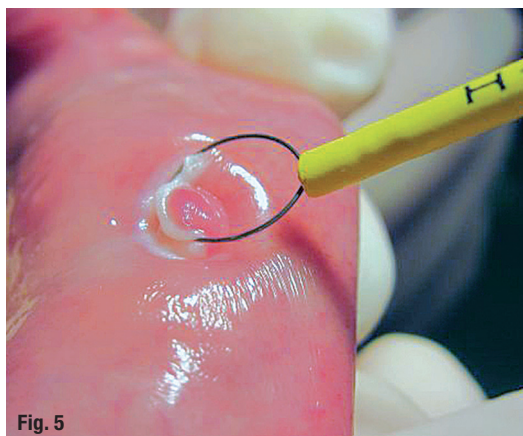


Fig. 5

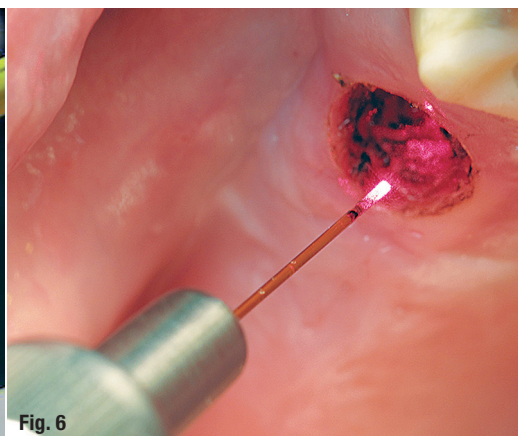


Fig. 6

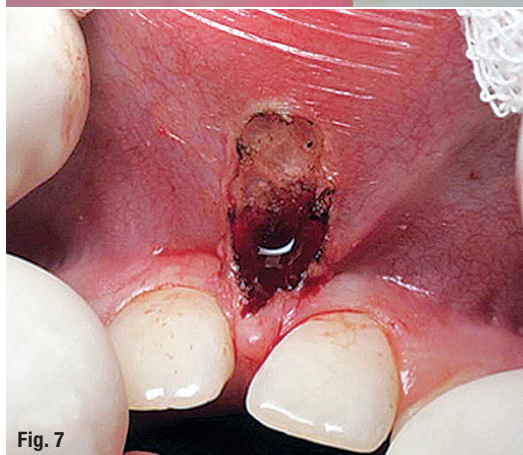


Fig. 7

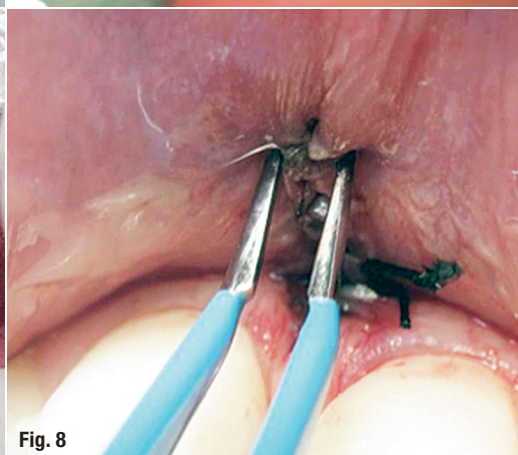


Fig. 8

Fig. 5: Removal of fibroma with radio frequency 20W and loop electrode.

Fig. 6: Implant recovery with laser 975 nm at 3W cw.

Fig. 7: Frenectomy with 975 nm laser at 4W cw.

Fig. 8: Wound edges after frenectomy are closed using the bipolar radio frequency forceps.

haemangioma or while performing a frenectomy or in need of a larger and invasive surgical application, laser is time consuming since the cutting speed of the laser beam is always limited by the fact that tissue can be removed only in superficial layers (Fig. 1). Neither increasing laser power nor changing laser wavelengths or using laser pulses can eliminate this physical fact.

The oral tissue is very thin, delicate and has a complex structure. In addition, it is in close proximity to the jaw bone and tooth structure. Laser radiation is strongly absorbed in the tissue and converted into heat, but it is also partially transmitted through the tissue without interaction. It may thus cause unpredictable and undesired side effects in adjacent healthy areas. By contrast, with radio frequency technology the tissue is heated and cut simultaneously, homogeneously and rapidly in the entire length of the inserted metal electrode (Fig. 2). Serious damages at a working frequency of 2.2 MHz to adjacent healthy areas are unlikely to occur and if they do occur, they are predictable and can be planned.

Using very thin and flexible electrodes made of special metal alloys, the electromagnetic waves are passed into the tissue. This approach allows fast, deep, precise, pressure-free and nearly athermal

cutting. In addition, bleeding is controlled effectively by the adjustable coagulation. Compared to laser, the cutting efficiency of radio frequency is much higher; because of the rigid metal electrodes the cut can be made in its full length and be done in one strike. From the view of histometry, the thermal modification in the area of the incision flanks shows a comparable thermal interaction of 125 to 150 μm in both methods. The depth of the cut with radio frequency (Fig. 3) is 0.8 to 1.0 mm, while the cut with laser (Fig. 4) is limited to 0.17 to 0.20 mm.¹

Examples of application

Due to their certain characteristics and application possibilities, laser and radio frequency can be used in different treatment settings. For the treatment of a fibroma, for example, a radio frequency device can be used to quickly remove the swelling in one strike in just five seconds with a power of 20W and loop electrode (Fig. 5). In this setting, speed and quality of a radio frequency application has been proven.² On the contrary, implant recovery is at best performed with a 975 nm laser at 3W cw (Fig. 6). In this application, laser shows its perfect superficial power in the gentle and precise opening of the implant.³ A very special application is shown in Figures 7 and 8. After having performed a frenectomy with laser, the edges of the

	Laser	RF radio frequency	Laser plus RF
oral surgery	Yellow	Green	Green
periodontics	Green	Yellow	Green
implantology	Green	Yellow	Green
endodontics	Green	Red	Green
bleaching	Green	Red	Green
PDT	Green	Red	Green
LLLT	Green	Red	Green



Fig. 9

Fig. 10

Fig. 9: The combination of a diode laser and radio frequency technology offers a wide range of applications in soft tissue management.

Fig. 10: LaserHF (MedLas Medical), combination device with two lasers (975 and 660 nm) plus monopolar and bipolar radio frequency (2.2MHz).

cut are “welded” together with forceps with radio frequency in the bipolar mode.⁴

The unique combination of a diode laser and radio frequency technology offers a wide range of application possibilities in the soft tissue management (Fig. 9). The fast and precise cutting ability of the radio frequency unit and the smooth surface coagulation and ablation of the laser complete each other very well. The use of photodynamic therapy, e.g. in Low Level Laser Therapy (LLLT) and tooth bleaching, is an additional feature and can be performed with laser only.

frequency generator with a power of 50 W. A low power laser at 660nm laser (100mW) is an additional therapy laser for PDT (photodynamic therapy) and LLLT (Low Level Laser Therapy).

A list of references is available from the author.

Conclusion

With regard to its application possibility, the combination of a diode laser with a radio frequency device meets the desire for a perfect system to perform a complete soft tissue management. Figure 10 shows this combination device. It consists of a 975 nm laser with a power of 8 W (cw and pulsed), combined with a 2.2 MHz radio

contact

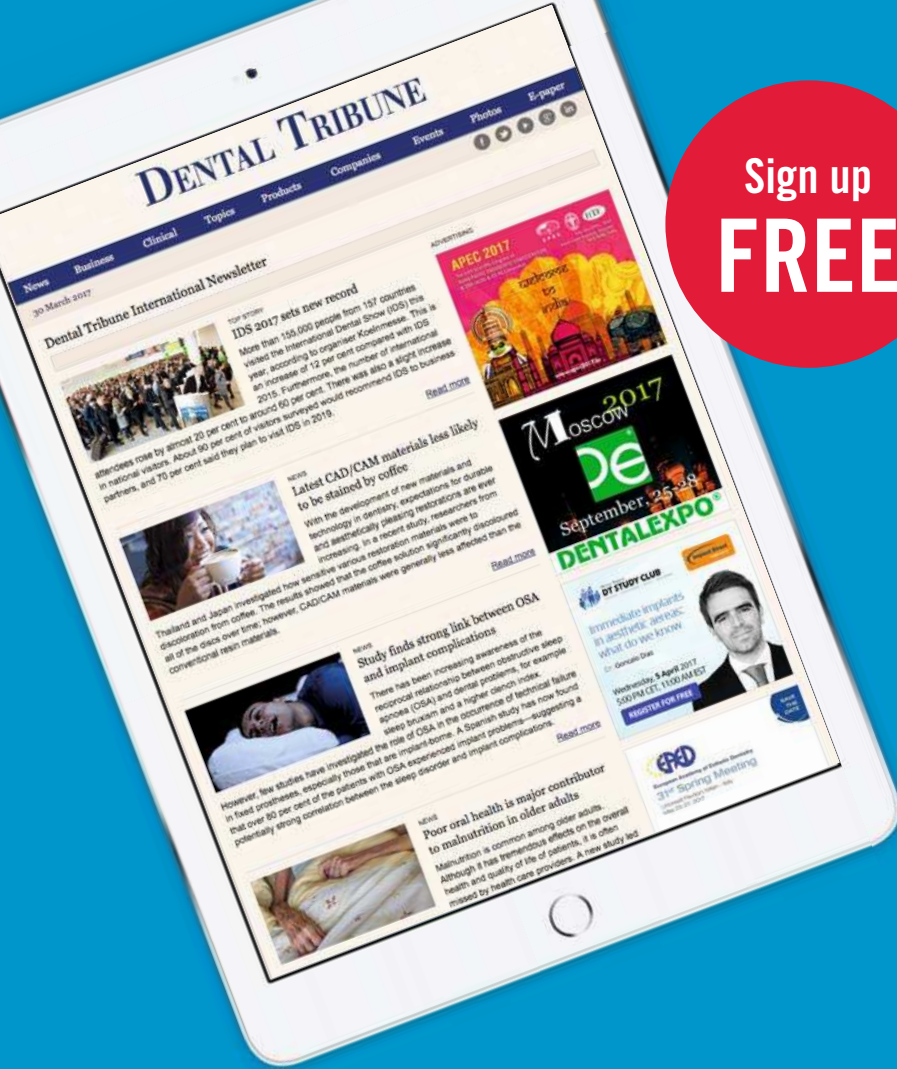Hans-Joachim Koort
 MedLas Medical GmbH
 An St. Josef 25
 53225 Bonn, Germany
 Tel.: +49 228 42290352
 ceo@medlas.com
 www.medlas.com

Author details



Kurz & bündig

Auf der Suche nach geeigneten Instrumenten für ein optimales Weichgewebsmanagement hat sich eine Kombination aus Laserlicht und Hochfrequenztechnologie in einem einzigen Gerät bewährt. Dank schneller und präziser Erhitzung des Weichgewebes eignen sich beide Technologien für ein optimales Schneiden mit Koagulation zur Blutstillung. Das Gerät LaserHF (MedLas Medical) kombiniert einen 975nm Diodenlaser und HF-Generator mit 2,2MHz. Zur Behandlung oberflächlicher Läsionen, wie der Beseitigung paropathogener Bakterien oder zur Beschneidung von Zahnfleischgewebe, eignet sich der Laser hervorragend. Andere Anwendungen, wie die Beseitigung von Fibromen oder die Durchführung einer Frenektomie, können besser mittels Hochfrequenztherapie ausgeführt werden. Die Kombination beider Technologien ermöglicht eine schnelle und einfache Handhabung für ein optimales Weichgewebsmanagement.



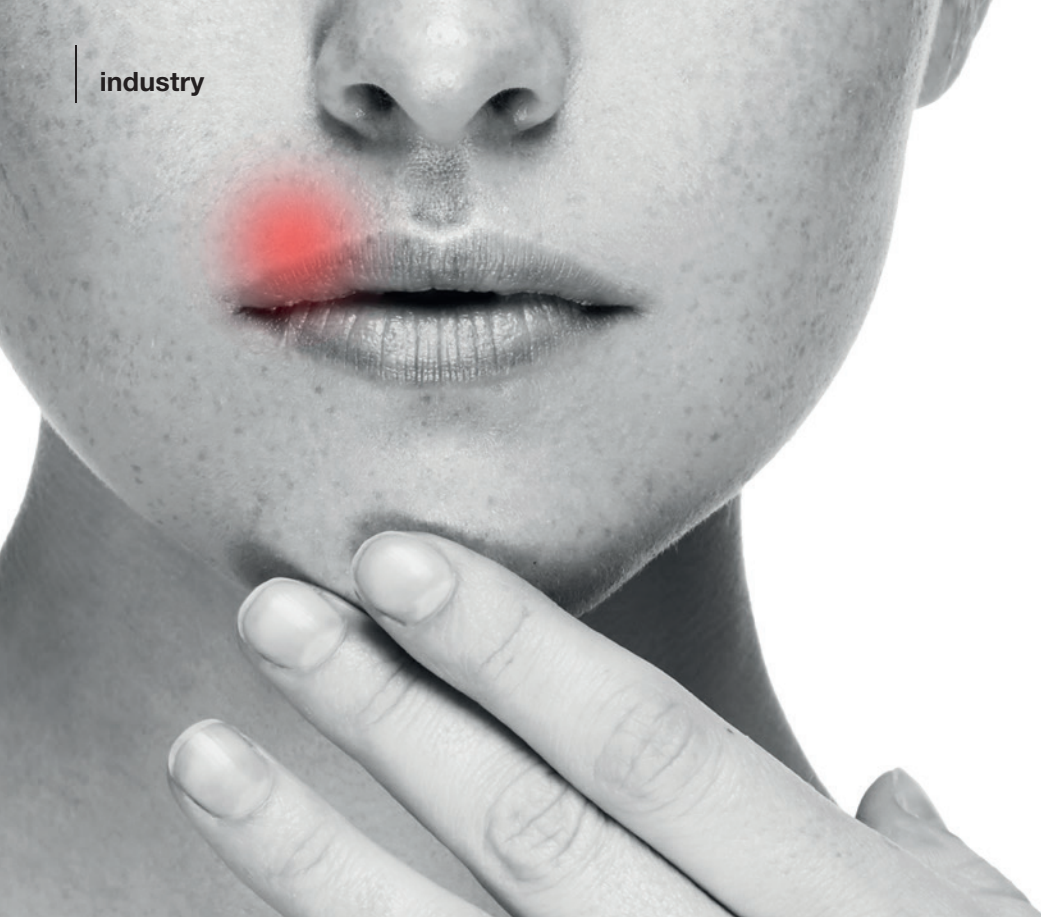
Sign up
FREE

- weekly e-news delivered to your inbox
- latest industry developments
- event specials
- exclusive interviews with key opinion leaders
- product information
- clinical cases
- job adverts

Sign up to the finest e-read in dentistry

www.dental-tribune.com

dti Dental
Tribune
International



© Irina Bg/Shutterstock.com

Laser-assisted herpes labialis therapy

Simple, fast and long-lasting

Author: Dr Darius Moghtader, Germany

"Quae medicamenta non sanant, ferrum sanat, quae ferrum non sanat, ignis sanat" (What medicines cannot cure, iron cures; what iron cannot cure, fire cures)—When Hippocrates uttered these words around 400 BC, he must have thought of skin diseases, amongst others. What else can be cured by fire when iron and medicine fail? Readers will learn from the following description that the therapy described by Hippocrates can prove successful in the treatment of herpes simplex. And of course we will also reveal the meaning behind his statement, from which both doctor and patient can benefit even more than 2,400 years later.

The term "herpes" is originated in Old Greek and actually described skin ulcers—an idea to which any

person who has suffered from this viral disease, whose symptoms are often located in the lip area, can relate. When untreated, herpes labialis can be acute for up to ten days and undergoes seven phases in its course of disease. Those phase differ widely in their duration and severity.

The first phase is the prodrome. Symptoms are pain, a tingling or burning sensation and sometimes an unpleasant feeling of tension in the yet intact areas of the skin. Not all herpes labialis patients undergo this phase. The second phase, which is called erythema phase, the skin starts to redden. This is followed by painful papules (papula phase). In the vesicle phase, the papula transform into liquid-filled blisters. This liquid contains viruses and bears a great

potential for infection on contact. The blisters burst and form painful ulcers and oozing wounds in the ulceration phase. In the encrustation phase, crusts or scab form and are often accompanied by severe itching. In the last phase, the reddish areas and swellings heal, usually without leaving any scar tissue.

Severe symptoms can be prevented if herpes labialis is treated by an antiviral cream up the beginning of the papula phase. Unfortunately, this disease often seems to break out abruptly without any previous symptoms, in which case the topical treatment with antiviral creams only helps alleviate the symptoms and reduce the risk of infection.

A large portion of the population supposedly carries herpes simplex virus type 1. Often, acute episodes of herpes occur when the immune system is weekend or in phases of severe stress, but also under strong sun exposure. Once manifested, herpes labialis may co-occur with bacterial superinfections which can affect both clinical symptoms and pain.

The HSV-1 virus is easily transferred via saliva or smear infection. Multiple relapses occur mostly in young adults, often at the vermillion border (Fig. 1).

These are the patients who usually present at the dermatologist or dentist. The herpes virus often develops a resistance against antiviral creams and does not respond to the treatment. Allergies, burning or itching sensations or headaches (in oral therapy) are common side effects of these medicines. As they are potential mutagens, their application is not recommended during pregnancy.

Fortunately, these patients can be helped in finding alleviation and fast recovery by laser therapy. However, the soft laser—which is usually recommended for these purposes—alone may lead to frustrating results, as it accelerates the healing process, but this is often neither noticed nor honoured by the patient, who will leave the dental practice with the same results as when he entered it. For this rea-

son, the author has developed a modified treatment protocol in his practice, which leads to an instant pain relief of at least 90% and a Wow-moment for the patient.

For this purpose, we use the programme „Soothing of the pockets“ of our ellexion claros laser and the soft-laser handpiece T4 with a diameter of 4 mm. A pulse power of 1.5 W and a frequency of 1,500 Hz as well as a pulse duration of 444 μ S result in an average performance of 1 W (Fig. 2).

As a first step, we inform the patient that treatment may result in a light warming of the tissues, asking him to give notice when the sensation should become too hot. Then, we decrease the distance to the source of infection under continuous suction, starting from 1 cm and up to 0.2 to 0.5 cm, and palpating it following a grit pattern under constant movement for 30 seconds. Afterwards, we check with the patient and inspect the treated tissue areas. After treatment, the skin may not exhibit any damages caused by laser and the patient should report an unsuspecting temperature sensation. If these standards are not met—in our experience, this happens in approx. 5% of the patients, please reduce the pulse performance to a level the patient can accept and prolong the treatment time accordingly. Afterwards, you can ask the patient to describe the intensity of his complaints compared to his original complaints on a scale from 1 to 10. This way, we continue therapy until we achieve a pain reduction of 90% or often 100% which corresponds to a 0 or 1 on the pain scale. This may lead to a treatment time of up to three minutes. In about 15% of the cases, increasing the pulse performance to 1.95 W may be recommended. This should be done when the patient does not report any improvements of the symptoms after one minute of treatment time. Afterwards, we use the soft laser with the programme “Wound Healing” of our laser or at 100 mW for at least one minute. When doing this, an energy level of 5 to 7 Joules should be applied to the tissue. On the next day, the patient will present at our practice for his check-up (Fig. 3) and another soft-laser therapy

Fig. 1: The HSV-1 virus is easily transferred via saliva or smear infection. Multiple relapses occur mostly in young adults, often at the vermillion border.

Fig. 2: A pulse power of 1.5 W and a frequency of 1,500 Hz as well as a pulse duration of 444 μ S result in an average performance of 1 W.

Fig. 3: Check-up after 24 hours. The patient is free from pain.

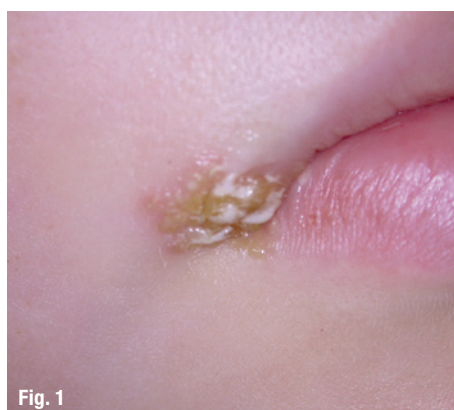

Fig. 1

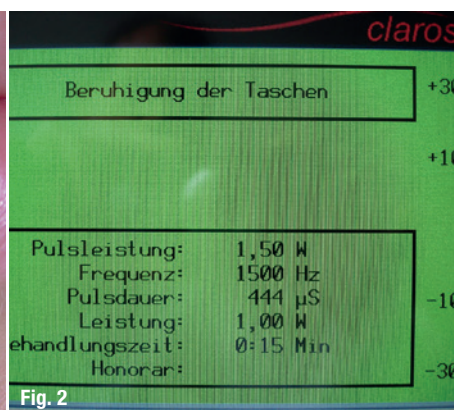


Fig. 2

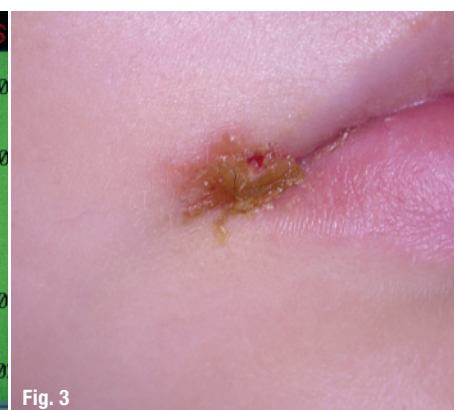

Fig. 3

session. If the patient is not yet completely free of pain, another repetition of the protocol is indicated.

Following Hippokrates, we may interpret this therapy protocol the following way: If medicine will not cure, the iron (the scalpel) will, if the scalpel will not cure, fire (the laser) will.

Laser can provide a therapy of herpes labialis which is free from pain or side effects, effective and efficient. Its instant pain relief of at least 90% (tension and itching sensation) and the no longer necessary topical therapy with creams leads to a high acceptance in the patients and an increase demand. Our clinical experience supports the findings of a study by the University of Vienna which reports that laser therapy leads to a significant decrease of relapses in cases of aphthae or herpes when compared to conventional treatment with medication.¹

The best-possible time to start this treatment protocol are prodrome or erythema phase. Most patients, however, present at our practice during the vesicle phase. We inform these patients that if their herpes should reoccur, they most react fast and visit our practice during prodrome or erythema phase. Accordingly, practice organisation must be adapted. Our receptionists are informed and give same-day appointments to these patients. Only if these prerequisites are met we can profit from the above-

described long-lasting effects and reduction of relapses.

In conclusion, it can be stated that laser treatment provides instant relief in cases of herpes labialis. If the laser is applied in time, instant pain relief can be achieved. Often, a proliferation of the herpes blisters can be prevented and the duration of the symptoms may be reduced. This form of therapy is pain free and also recommended for children and during pregnancy. Its effects are long lasting.

contact

Dr Darius Moghtader

In den Weingärten 47
55276 Oppenheim, Germany
Deutschland
Tel.: +49 6133 2371
dr-moghtader@hotmail.de
www.laser-zahn-arzt.de

Author details



Kurz & bündig

Vielen ist unbekannt, dass davon ausgegangen wird, dass ein Großteil der Bevölkerung das Herpes simplex-Virus Typ 1 bereits in sich trägt. Oft tritt ein Herpesschub in einer Phase der geschwächten Immunabwehr, bei Stress oder bei starker Sonneneinstrahlung auf. Diese Patienten werden dann meist entweder beim Dermatologen oder beim Zahnarzt vorstellig. Gegen die oft verschriebenen virustatischen Cremes entwickeln sich schnell Resistenzen des Herpesvirus, der dann nicht mehr auf diese Therapie anspricht. Zudem sind bekannte Nebenwirkungen dieser Arzneimittel Allergien, Brennen oder Reizungen der Haut, bei der oralen Therapie auch Kopfschmerzen. Da diese Medikamente potenziell mutagen sind, wird darüber hinaus von einer Anwendung in der Schwangerschaft abgeraten.

Mithilfe der Lasertherapie kann diesen Patienten jedoch auf einem anderen Weg zu Linderung und schneller Heilung verholfen werden. Der immer wieder für diesen Zweck angepriesene Softlaser allein führt allerdings mitunter zu frustrierenden Ergebnissen. Zwar schreitet der Heilungsprozess schneller voran, dies wird jedoch vom Patienten kaum bemerkt oder honoriert, da er die Praxis mit den gleichen Beschwerden verlässt, wegen derer er sie aufgesucht hat. Deshalb haben wir in unserer Praxis ein modifiziertes Verfahren entwickelt, das sofort zu einer erheblichen Schmerzlinderung und zu einem Aha-Erlebnis beim Patienten führt.

In einer Studie der Universität Wien wurde festgestellt, dass Aphthen und Herpes nach einer Laserbehandlung signifikant weniger häufig wieder auftreten, als bei einer Therapie mit Medikamenten.¹ Diesen Effekt können wir aus unseren klinischen Erfahrungen eindeutig bestätigen. Zusammenfassend lässt sich darüber hinaus festhalten, dass die Lasertherapie in den meisten Fällen sofort bei Herpes hilft. Wird der Laser frühzeitig eingesetzt, erreicht man unmittelbare Schmerzfremheit. Zudem kann oft das Ausbrechen der Herpesbläschen verhindert oder die Krankheitsdauer deutlich reduziert werden. Diese Therapie ist absolut schmerzfrei, natürlich auch für Kinder oder Schwangere geeignet und zeigt nachhaltige Wirkung.

Literature



SUBSCRIBE NOW!

ceramic implants—international magazine of ceramic implant technology

Interdisciplinary, transparent & market orientated

ONLINE
SUBSCRIPTION HERE



www.oemus.com/abo

laser 2/17

ceramic implants

international magazine of ceramic implant technology



research

How to successfully place ceramic implants

event

6th IAOCI World Congress in Miami

interview

“Metal-free restorations are medically relevant”

**COMING
SOON
SEPTEMBER
2017**

stay updated:

research

How to successfully place ceramic implants

event

6th IAOCI World Congress in Miami

interview

“Metal-free restorations are medically relevant”

Fax: **+49 341 48474-290**

I would like to subscribe for the following journals:

- ceramic implants—international magazine of ceramic implant technology 2 issues p.a. € 30*
- implants—international magazine of oral implantology 4 issues p.a. € 44*

Terms & Conditions: The subscription may be cancelled in written form without due justification within 14 days of order by contacting OEMUS MEDIA AG, Holbeinstr. 29, 04229 Leipzig, Germany. Dispatching notification in good time will suffice. The subscription is automatically extended by another twelve months if it is not cancelled in written form 6 weeks prior to the end of the reference period.

* All prices include VAT, shipping and handling (within Germany).

Last Name, First Name

Company

Street

ZIP/City/Country

E-Mail

Signature

Credit Card Number

Expiration Date

Security Code

Sealer placement in lateral/accessory canals

Utilising the Nd:YAP laser

Authors: Dr He-Kyong Kang & Dr John Palanci, USA

In 1967, Schilder¹ had postulated that the final objective of endodontic procedures should be the total three-dimensional filling of the root canals and all accessory canals, in addition to the elimination of all organic debris, bacteria, and bacterial toxin. Therefore, the ability of filling lateral canals has been regarded as a measure of the endodontic treatment quality.

Nevertheless, the substantive need for filling lateral and accessory canals is still a controversial issue among clinicians. Kasahara et al.² reported the incidence of accessory canals in the maxillary central incisors to be over 60%, and Dammaschke et al. showed 79% of molars had lateral/accessory canals.³ Large numbers of lateral/accessory canals exist in the roots, but the frequency of periapical lesions related with these ramifications is not as high as anticipated.^{4,5} The answers for these clinical observations are still not clarified. The differences in size between main apical

foramen and lateral/accessory foramen might explain why the apical lesions were observed more frequently than lateral lesions.³ The amount of bacteria existing in the small ramifications might not be sufficient to raise inflammation which can be detectable on radiographs. Occasionally, the lateral lesion is healed without lateral canal filling because simple canal treatment could stop the diffusion of bacterial products from the main canal which might reach periodontal ligaments through lateral/accessory canals maintaining vitality.⁶ However, if periapical lesions originate from bacteria surviving in some spaces derived from lateral canals and irregularities of root canals, such as isthmuses, ramifications, deltas,⁶⁻⁸ then the treatment seems to be particularly challenging for clinicians.

Since it is unlikely to kill all pathogens in entire root canals, Buchanan⁹ suggested that the embedding of remaining bacteria with filling materials can achieve the same results as from complete disinfection in the canal systems. Thermo-plasticised gutta-percha filling techniques have been considered preferable means to achieve this goal due to remarkable frequency of lateral canal filling based on case reports and *in vitro* studies.⁹⁻¹¹ Two major concerns for using thermoplastic techniques would be the periodontium damage by temperature increase and overextension of root canal filling materials, especially gutta-percha. The application of lasers in endodontic treatment is an attempt to minimise these potential risks.

The investigation of laser applications in endodontics was first reported in the early 1970s.¹² Among a variety of conceivable uses, most researches emphasised the efficiency of debridement and the possibility of shaping the root canal by laser.¹²⁻¹⁴ It seems that the disinfection and cleaning of the root canals would be the most practical use of laser devices in endodontic treatment.^{12,15-22} The maximum disinfecting effects in

Fig. 1: 320 µm (red) and 220 µm (black) laser optic fibres.

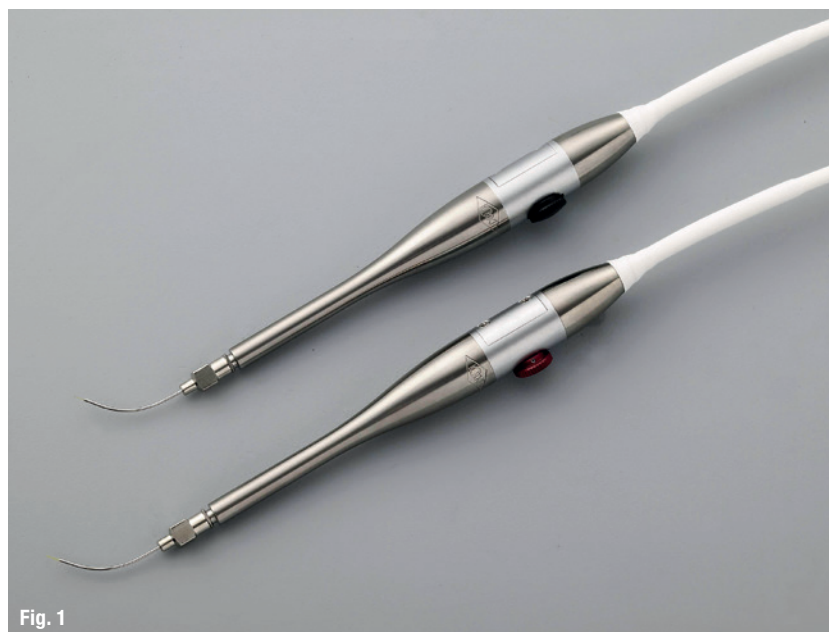

Fig. 1

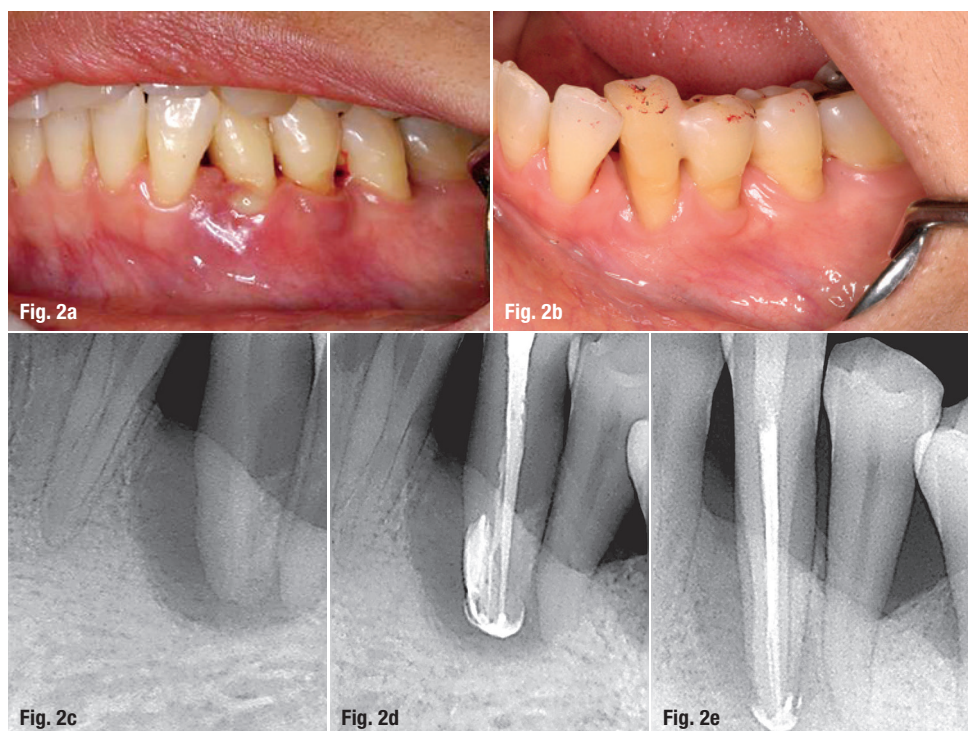
root canals can be achieved by laser-activated irrigation with NaOCl solution due to the pulsation of laser output and the easy access to root canals by an optical fibre.²² The acoustic streaming, caused by the collapse of laser-induced bubbles, was identified as an effective mechanism for dentin debridement in the apical portion of root canals.²¹ The pressure produced by the pulsation of laser beam in a narrow space like a root canal is a unique feature of laser devices.

No study addresses the application of laser pulsation on canal filling so far. This report documents three cases of traditional endodontic treatment that were supplemented with the use of the Nd:YAP laser which resulted in the radiographic identification of sealer in apical ramifications.

Material and methods

Three patients of this case report received root canal treatment necessitated by carious exposure of the pulp or apical periodontitis. Endodontic treatment consisted of the following procedures: access opening, canal preparation by hand and rotary instruments, canal irrigation, and canal filling. The canals were enlarged conservatively providing adequate proximation of the optic fibre to the apical third of the root canal. Three-percentage NaOCl solution and EDTA paste (RC-Prep, Premier, USA) were used during instrumentation; saline was used between application of NaOCl and EDTA. Gutta-percha cones (Gutta Percha Points, Meta Biomed, Korea) and zinc-oxide eugenol-based sealer (ZOB Seal, Meta Biomed, Korea) were used for canal obturation.

The exposure to the Nd:YAP laser (Lokki YAP, Lokki, France), using 220 μ m optical fibre (Fig. 1) with 160 mJ/pulse and 30 Hz, was conducted during canal irrigation. The optical fibre was put into a root canal 2–3 mm short of working length as a starting point for pulsed radiation. Radiation of the laser was followed with upward movement of the optical fibre against the canal wall and stopped when the optic fibre was close to the orifice. Laser irradiation was repeated throughout all canals as mimicking circumferential filing until no debris was noted in the pulp chamber followed by drying of the canals with paper points. The 220 μ m optical fibre with the mode of 180mJ/pulse and 5 Hz was chosen for canal filling. After root canals were filled with sealer by using a lentulo spiral, a single pulse of laser beam was radiated at a position 2–3 mm short of working length at first, and then an-



other two single pulses of laser beam were emitted in the middle of the root and at a location 2–3 mm below the orifice consecutively. Cold lateral condensation was accomplished with the placement of a master gutta-percha cone followed by accessory cones for complete obturation. Periapical X-ray films were taken to evaluate the quality of the root canal obturation. No medications were prescribed during treatment or postoperatively for patients.

Case presentation

Case 1 (Figs. 2a–e)

A 45-year-old woman sought treatment for severe pain associated with a mandibular left canine. Clinically there was severe vertical mobility and cuspal interference existed when the patient moved her mandible in lateral excursion. Radiographic examination revealed a radiolucent lesion extending along the mesial aspect of the root. Before beginning access opening, the canine was splinted to the mandibular left, lateral incisor and first premolar, and the occlusion was adjusted to eliminate lateral interference. Purulent exudate was drained not only from the periodontal pocket, but also from the canal orifice after the chamber was opened. An accessory canal mimicking a bifurcated apical canal was sealed. At the ten-month recall, bone density was increased around the root and no inflammatory signs were observed in the periodontal pocket.

Case 2 (Figs. 3a & b)

A 46-year-old woman with missing restorations on the mandibular right first and second premolars

Fig. 2: Comparison of intraoral photos and periapical radiographs before treatment (**a** and **c**) and post treatment (**b**, **d** and **e**).

a) Purulent exudate was drained from the mesiolabial periodontal sulcus. **b)** Intraoral photo: 10-month post treatment. Periodontal abscess subsided with gingival recession. **c)** Periapical radiograph before treatment. A significant radiolucency was observed around the root of mandibular left first premolar. **d)** Periapical radiograph immediately after treatment. **e)** Periapical radiograph: 10-month post treatment. The increase in bone density was noted around the root of mandibular left first premolar even though excess of sealer was remained out of the root apex.

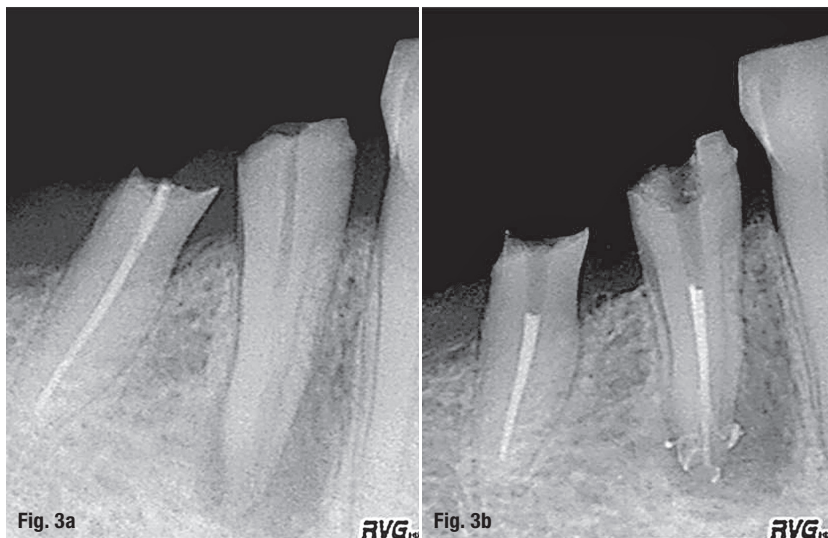


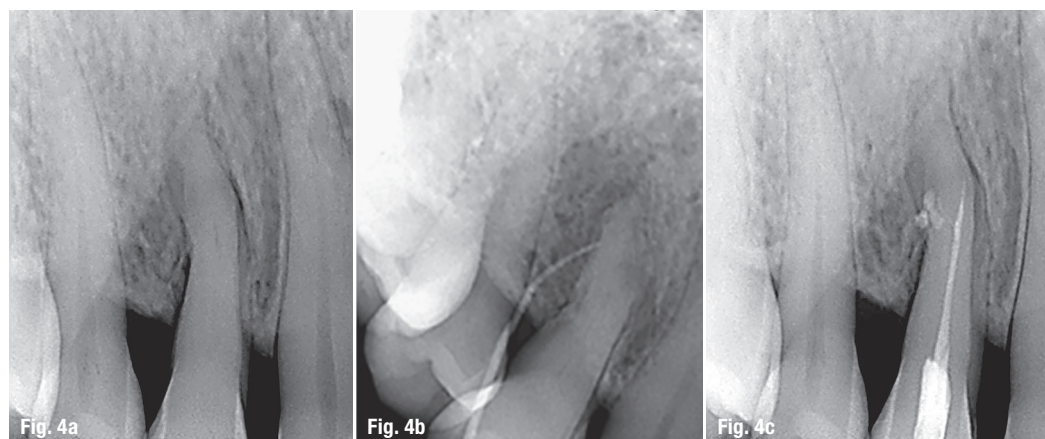
Fig. 3: Comparison of periapical radiographs before (a) and post treatment (b). a) Dental restorations of mandibular right first and second premolars were lost due to secondary caries. Periapical radiolucency around the root of mandibular right first was seen. b) One-month post treatment. Accessory canals were identified by sealer.

complained of toothache. The fracture of the crowns was a result of secondary caries at the cervical portion of premolars. A large apical lesion was observed around the root of the first premolar. A prosthodontic treatment of splinted crowns on the mandibular right first and second premolars with crown lengthening and cast posts was planned due to the patient's desire to retain teeth. All symptoms subsided after endodontic treatment was completed. There was radiographic evidence of sealer in the apical ramifications.

Case 3 (Figs. 4a–c)

A 40-year-old woman sought treatment for a labial sinus tract related to the maxillary right first premolar. Extensive pulpal calcification was noticed on the periapical radiograph. The gutta-percha cone indicated that the labial sinus tract which appears to originate from a lateral canal. A dilaceration of the apical third and calcification of the canal made access difficult, resulting in a perforation on the mesial aspect of the root. The working length was adjusted and the canal was obturated to this point. A lateral canal was filled with sealer on the distal aspect of the root. The patient returned for follow-up in two weeks. The sinus tract healed and she was asymptomatic.

Fig. 4: Comparison of periapical radiographs before treatment (a, b) and two-week post treatment (c). a) Severe canal calcification with apical root dilaceration of maxillary right first premolar was observed. b) Insertion of a gutta-percha cone into the labial sinus tract for diagnosis. The tip of the gutta-percha cone pointed to the lateral surface of the root instead of the root apex. c) A lateral canal was identified by sealer.



Discussion

Microbial infection is considered a major cause of endodontic failure. Several studies reported that periapical lesions did not develop without bacteria, although pulp tissue had been devitalised^{6,23}; therefore, thorough disinfection is strongly recommended before obturation is performed. The complexity and variability of the root canal system make it difficult to achieve ideal goals of endodontic treatment. A laser system which transmits energy through a flexible and small-diameter optical fibre can provide convenient access to root canals. Consequently, direct and indirect disinfection by laser possibly takes place while irradiating the inside of root canals. De Andrade AK et al.²⁴ reported laser disinfection is an effective way to decrease bacterial colonies when the mean power of laser exposure was over 3 Watts. The energy of the Nd:YAP laser is powerful enough to eliminate microbes because the average output of the Nd:YAP laser is 10 Watts and the peak power may reach 2.6 kW. Only 0.00015 seconds of laser energy is emitted for every pulsed irradiation,²⁵ so the fleeting moment of emission minimises the risk of overheating surrounding tissues and has bactericidal effects by direct contact. Two possibilities may explain the indirect disinfection of laser. When the mode of 30 Hz is used in narrow space such as a root canal filled with irrigation solution, shock waves may occur repeatedly and be transmitted into dentinal tubules to kill bacteria. Pulsed irradiation causes vibrations in narrow spaces similar to ultrasonic devices.²⁵ This laser energy caused by high frequency emission of the Nd:YAP laser help maintain the integrity of the root because it is not necessary to eliminate excessive contaminated dentin of canal wall. Minimal enlargement is sufficient, if the space can allow 220 µm optical fibre to move passively through the canal. The laser energy also causes temperature of the NaOCl solution to rise resulting in increased efficiency of dissolving organic debris and disinfection in canals.²⁶ This enhanced cleanliness gains space in apical ramifications for sealer placement.

In the clinical practice, the warm vertical condensation technique is widely used to obturate the canal, but keeping a gutta-percha cone warm enough to obtain favorable sealing in the ramifications may cause lasting discomfort because of thermal damage to periodontal tissues.^{27,28} On the other hand, the mechanism of sealer placement by the Nd:YAP laser is different from thermoplastic techniques. Sealer is placed in the canal with a lentulo spiral followed by application of the Nd:YAP laser to disperse the sealer into ramifications by the fleeting pressure of laser beam. Although the pressure causes slight discomfort, the post-filled sensation is not overt and dissipates clinically within a few hours. In most cases, there was radiographic evidence of sealer being forced into lateral/accessory canals. Puffs of sealer from the periapical foramen are considered an evidence of tight seal.¹ Zinc-oxide and eugenol-based sealer was chosen in this case report because working and setting time are conducive to completion of the entire obturation process before the sealer sets. The heat from laser irradiation induces fast setting and burning of epoxy resin-based sealer; these types of sealers are not recommended with this technique. Taking periapical films during obturation is recommended to confirm whether the sealer is placed into canal adequately.

Another advantage of using the Nd:YAP laser is that the need for analgesics/antibiotics after treatment can be decreased. The Nd:YAP laser has a strong antibacterial effect and an excellent potential for promoting tissue healing induced without a more invasive procedure^{29,30}; therefore, using the Nd:YAP laser may be more efficient in disinfection and obturation of the root canal system resulting in a higher success rate of non-surgical root canal treatment. Based upon personal experience and observation for four years in laser application, Nd:YAP laser-assistant endodontic treatment is less technique sensitive and easy for

general practitioners to acquire the skill and follow this method.

Further histological analysis is needed to verify the significance of laser disinfection and sealer placement with the use of the Nd:YAP laser. These additional investigations will hopefully add to the store of knowledge relative to canal disinfection and the benefits of adequate obturation of auxiliary canals.

Conclusion

Obturation of lateral canals and apical ramifications were observed on postoperative radiographs. This indicates enhanced canal cleanliness and sealing of these small ramifications. The Nd:YAP laser can be utilised as adjuncts to disinfection, canal irrigation and canal filling to improve the quality of obturation in the canal system. The efficiency of Nd:YAP laser-assistant endodontic treatment could simplify the procedure of root canal treatment without purchasing additional equipment to provide an advanced level of treatment.

Acknowledgement: The authors are grateful to Eric Jacobs, a media specialist, from University of Detroit Mercy School of Dentistry for image edition.

contact

Dr John Palanci

Clinical assistant professor
Department of Oral Health and
Integrated Care,
University of Detroit Mercy
2700 Martin Luther King Jr. Blvd.
Detroit, MI 48208, USA
Tel.: +1 313 4946863
palancjg@udmercy.edu

Author details




Kurz & bündig

Ausgehend von der Aussage Schilders (1967), dass die finale Zielvorgabe einer jeden endodontischen Behandlung die komplette, dreidimensionale Füllung der Wurzel- und Nebenkanäle sei, einschließlich der Entfernung aller organischer Ablagerungen, Bakterien und Bakteriengifte, erheben die Autoren dieses Artikels diese Maßgabe zum ultimativen Qualitätskriterium der endodontischen Behandlung. Im Bewusstsein, dass diese These auch heute noch von Behandelern kritisch diskutiert wird, stellen die Autoren eine lasergestützte endodontische Behandlungsalternative anhand dreier Fallbeispiele vor. Dabei kam der Nd:YAP-Laser bei der Einbringung des Sealers zum Einsatz. Auf den anschließend angefertigten Röntgenaufnahmen konnte die Aufbereitung der Nebenkanäle und apikalen Verzweigungen sichtbar gemacht werden, sodass aus Sicht der Autoren auch diese bestmöglich gereinigt und versiegelt werden konnten.

Abschließend kommen sie daher zu dem Schluss, dass der Nd:YAP-Laser eine geeignete Behandlungsalternative für die Desinfektion, Spülung und Füllung der Wurzelkanäle darstelle und die Qualität der Wurzelkanalaufbereitung signifikant erhöhe.

Literature



Successful communication in your daily practice

Part II: Curious patients

Author: Dr Anna Maria Yiannikos, Germany & Cyprus



Welcome to the 2nd part of the new communication series; the series that includes the most popular and challenging scenarios that might occur in your dental practice with helpful tips of how you can deal with them so your patients always leave your practice feeling: "My dentist is THE BEST!" Each individual article of this series will teach you a new specialized protocol that you can use easily, customise and adapt from the same day on to your own dental clinic's requirements and needs. I am here to teach you all

the solutions for daily communication problems you are facing with your patients that bring you into a difficult situation, make you lose your sleep or even trust to your own self!

Let's face it! We are not only dentists—we have a business to run! Are you ready to find solutions to all these problems? Let's start with today's amazing brain-melting topic which is: How to shush patients that have too many questions? Five steps to solve the problem with courtesy and caring!

How to shush curious patients

How many times have you been delayed by a patient that is constantly asking questions? Maybe it is because he wants to feel that he is in control or maybe he is afraid of the treatment or even he does not trust you enough.

Whatever the reason is, you cannot spend the whole day answering his questions! And this is a real fact! On the other hand, you do not want to be perceived as rude. So, my gift for you today is a protocol to deal with this annoying patient habit nicely and at the same time effectively!

5 steps for a successful communication

Here is how it goes:

Step 1: Be in charge of the conversation

Before you start the treatment, spend five to ten minutes sitting with your patient at your office area and explain the proposed or upcoming treatment.

Important tip: Explain already beforehand the available time and reason for this meeting. For example, you could say: "George, I would love to sit with you today and spend five minutes of our time to explain the treatment that will follow in detail."

Step 2: Ensure him

Tell him the format of contact. In case he has questions, he can ask them either during the meeting at your office, or after the treatment, or he can call your well-trained and qualified assistant or even e-mail you at own convenience for further details.

Step 3: Keep in mind the following

If during treatment, he wants to interrupt you and ask you more questions, just use the following phrase: "I am all ears, but believe me it is better if we now concentrate on the selected treatment. Me and my staff will give you more time after the completion to ask for more information about the treatment, so let's proceed..."

The above said words will relax him a bit, so you will be able to do your job, which is: treat him!

Step 4: After the treatment

You can shortly explain your findings and how you are going to proceed, ask him if he wants anything else from you and simultaneously bring your assistant in. You must continue the show...! Go into the treatment room and serve the next patient!

Step 5: Necessary documents and info

Your assistant will provide the patient with the follow-up instructions, your clinic's e-mail, etc. It is better, for your peace of mind, to not give him your private cell phone number, for obvious reasons: You do not want him calling you for unnecessary reasons (whether it is the appropriate time to take his lunch, or when he should change the gauge, etc. Correct?).

Just do it!

It is not so hard to apply the above presented 5 steps for successful communication in your daily practice. I encourage you to start doing it from today on, as part of your clinic's script! I am sure, it will give you greater peace of mind as well as more time and energy for your next patient!

In the next issue of laser magazine, I will present to you the third part of this unique new series of communication concepts that will teach you with 7 simple steps how to attract, communicate and retain millennial patients—who are our present and future patients. Until then, remember that you are not only the dentist of your clinic, but also the manager and the leader. You can always send me your questions and request for more information and guidance at dba@yiannikosdental.com or via our website www.dbamastership.com. Looking forward to our next trip of business growth and educational development! _

contact



Dr Anna Maria Yiannikos

Adjunct Faculty Member of AALZ
at RWTH Aachen
University Campus, Germany
DDS, LSO, MSc, MBA
dba@yiannikosdental.com
www.dbamastership.com

Author details



Kurz & bündig

Im zweiten Teil der Serie „Erfolgreiche Kommunikation im Praxisalltag“ gibt unsere Autorin fünf Tipps, wie Zahnärzte mit allzu wissbegierigen Patienten umgehen können. Denn ein Patient, der ständig Fragen stellt, hält den Praxisbetrieb auf und strapaziert die Nerven seines Behandlers. Schritt 1 ist daher, dem Patienten bereits im Vorhinein in fünf bis zehn Minuten im Empfangsbereich die nachfolgende Behandlung zu erklären. Im zweiten Schritt vereinbaren Sie mit ihm, dass er aufkommende Fragen entweder vor oder nach der Behandlung klären kann. Wenn er während der Behandlung weitere Fragen stellt, versichern Sie ihm im dritten Schritt, dass diese im Nachhinein eingehend beantwortet werden und Sie sich erstmal ganz auf die Therapie konzentrieren möchten. Nach der Sitzung erklären Sie Ihrem Patienten in Schritt 4 kurz die Befunde und das weitere Vorgehen. Bringen Sie gleichzeitig Ihre Assistentin in den Raum und gehen Sie dann in den nächsten Termin. Ihre Assistentin wird Ihrem Patienten im letzten Schritt alle notwendigen Dokumente und Informationen geben. Auf diese Weise vermeiden Sie unnötige Fragen und geben Ihrem Patienten trotzdem das Gefühl, in guten Händen zu sein. Im nächsten Heft gibt die Autorin sieben Tipps, wie Sie Millennials als Patienten gewinnen können.

Marketing dentistry in a global economy

Author: Chris Barrow, UK

"In an information-rich world, the wealth of information means a dearth of something else: a scarcity of whatever it is that information consumes. What information consumes is rather obvious: it consumes the attention of its recipients. Hence a wealth of information creates a poverty of attention." These prophetic lines were shared by Nobel laureate and social scientist Dr Herbert Simon in 1971. It seems incredible to think that his words predate the Internet by 20 years.

From bill-board to blog post

Simon lived in a world in which advertisers tried to gain our attention with bill-boards, newspaper advertisements and television commercials. At the same time, the local ma-and-pa business prospered through convenience and human interest. The connected economy and growth in population have created statistics that are beyond our comprehension. There were 60 trillion websites at the last count



© Jesus San/Shutterstock.com

and every year the Internet grows by eight million new songs, two million new books, 16,000 new films, 30 billion blog posts and 182 billion Tweets. Google handles 35 billion e-mails every day alone, and 1.8 billion photographs are uploaded to the Cloud from everywhere around the globe. I speculate as to how many of those photographs are of happy, smiling faces.

IBM tells us that we are "a world awash in data", 80% of which is currently invisible to our computers; however, with the IBM Watson project, the company intends to use cognitive computing to bring that data into a useable domain. With global health-care data expected to grow by 99% in the next twelve months, the search is on to find a new unified theory that will bring all of this information to the fingertips of government, business and individuals.

How to upgrade the human data system

The question is, can we cope with this? In his book "Homo Deus: A Brief History of Tomorrow", Israeli author Prof. Yuval Noah Harari visualises a completely connected world in which "Data-ism" dominates. There he writes: "Sapiens evolved in the savannah thousands of years ago and their algorithms are not built to handle 21st century data flows. We might try to upgrade the human data-processing system, but this may not be enough. The Internet of all Things may create such huge and rapid data flows that even upgraded human algorithms won't handle it. When cars replaced the horse-drawn carriage, we didn't upgrade horses—we retired them. Perhaps it is time to do the same with Homo sapiens."

A rather grim and ominous suggestion perhaps, but by jolting our sensibilities, Harari makes us pause for thought. Let us narrow our field of vision from these impossible numbers and facts. Pundits suggest that you and I are interrupted by advertising and brand exposures 5,000 times in an average day and mentally register around 350 of these. We note 150, think briefly about 80 and pause at 12 to think about whether they are relevant to us at this time. Thus, the challenge facing the dental marketer is how to become one of 12 out of 5,000 at the right time, on the right day, for the right person.

Big data—big money

Big business has a simple solution to this problem; it is called big money. Whether it is a Super Bowl television commercial, a giant bill-board on a motorway or, nowadays, massive expenditure on Internet visibility via paid media, those with the deepest pockets offering the best products and services are the win-

ners in the race to attract that poverty of attention first mentioned in 1971. So where does this place the independently owned dental practice? You are a mouse, wandering between the legs of a herd of bull elephants, all trumpeting their mating call. No matter how loudly you squeak, at best your sound will be drowned out and at worst you may be trampled in the rush.

The to-dos of digital dental marketing

I have watched the world of digital marketing in dentistry very carefully over the last five years and have reached some conclusions that are likely to land me in trouble with traditional digital marketers. However, I did not get where I am today without stepping on the fenced-off grass every now and then, running along the side of the swimming pool and tearing up the rule book. So, here is my recommended list of actions to be taken by the independent dental practice in order to gain attention:

1. Use good search engine optimisation (SEO) to optimise your position in Google's organic search. SEO is a technical skill that has to be delivered by experts. Google changes its own goalposts regularly and the savvy SEO guru will know that and take appropriate action quickly.
2. Massively encourage the collection of Google reviews, user reviews via Facebook and critic reviews via proprietorial sites. In September 2016, Google changed the rules twice, first by including external reviews alongside its own in searches and second by altering its own search criteria to favour businesses with in excess of 100 Google reviews. It is necessary that your marketing activity be adjusted to reflect such changes.
3. Connect to your patients through a well-maintained social media channel like Facebook or Twitter (and deliver daily human interest content). Remember that those 1.8 billion photograph uploads per day include the inevitable selfies. Many of my clients now take a patient selfie at the end of a course of aesthetic dental treatment. To quote again from Harari's new book: "If you experience something—record it. If you record something—upload it. If you upload something—share it."
4. Build a website that engages the visitor through video and visual testimonials. Your most powerful marketing collateral is the stories that your patients can tell about the difference that you have made to their lives.
5. Collect visitors' e-mail addresses and consent (to e-mail) via white paper marketing. A coffee shop, hotel or airport exchanges free Wi-Fi access for an e-mail address and permission to keep one informed. You can do the same by exchanging useful information (free guides).



Conclusion: to advertise or not to advertise

I have given you nine marketing actions designed especially for the smaller business. Actions that should be avoided by the independent dental practice are seeking to gain attention by paying through the nose for Google or Facebook advertising, broadcasting non-human interest material or selling services on price, discount or special offer. This is because every week I hear from dentists and their marketing teams that advertising to strangers, using jargon and cutting prices at best attract nobody and at worst attract bargain-hunters, price-shoppers and messers.

"A wealth of information creates a poverty of attention." We end where we began. The challenge is for the mouse to gain attention without competing with the bull elephants. You can only do that by stepping away from the herd of elephants and delivering your story in a different way and a different place. For me, that means human interest, personal service and recommendation, and so when I am working with clients on their marketing plans, we focus on and mobilise their most valuable asset: the goodwill of their existing patients.

6. Nurture long-term relationships with patients and prospects by publishing a monthly human interest e-mail newsletter.
7. Deal with initial enquiries directed through the Internet, by telephone or in person in a polished manner.
8. Create a memorable new patient experience from initial consultation all the way through to treatment delivery.
9. Employ a strict end-of-treatment protocol to capture reviews, testimonials and social connections (as well as plan membership).

contact

Chris Barrow

7connections
27 Clements Lane
London, EC4N 7AE, United Kingdom
Tel.: +44 20 33191709
hello@7connections.com
www.7connections.com


Author details



Kurz & bündig

Ausgehend von den Theorien der „Attention economy“ des US-amerikanischen Sozialwissenschaftlers Herbert Simon beschreibt Business-Coach Chris Barrow in seinem Artikel die Entwicklungen des (dentalen) Marketings von der händisch beschriebenen Anzeigentafel des 19. Jahrhunderts bis zu den Möglichkeiten digital und global angelegter Marketingstrategien des 21. Jahrhunderts. Damals wie heute ginge es darum, in einem Meer von Informationen die eigene Botschaft, das eigene Produkt oder die eigene Marke für das Zielpublikum präsent und relevant zu gestalten. Für das dentale Marketing erstellt Chris Barrow abschließend eine praxisnahe To-do-Liste, in der er in Kürze das digitale Praxismarketing von der Suchmaschinenoptimierung über die Gestaltung von Web- und E-Mail-Adressen bis hin zur individuellen Gestaltung von Patientenbindung und Behandlungserfahrung beschreibt.

Sein Fazit: Die Einzelpraxis kann sich in einer Welt digitaler Giganten nur behaupten, wenn Sie stets an ihrer eigenen Geschichte und ihren Alleinstellungsmerkmalen festhält und dafür individuelle Marketingstrategien entwickelt. In der Zusammenarbeit mit seinen Klienten habe sich dabei vor allem eins bewährt: der Fokus auf den „Goodwill“ der Bestandspatienten.



This year's **IDS** sets **new record** in attendees

More than 155,000 people from 157 countries visited the International Dental Show (IDS) this year, according to final figures released by organiser Koelnmesse. This is an increase of 12 per cent compared with IDS 2015. Furthermore, the number of international attendees rose by almost 20 per cent to around 60 per cent. There was also a slight increase in national visitors.

There was a significant increase in visitor numbers from almost all regions: the Americas (+52.9 per cent), eastern Europe (+43.0 per cent), the Middle East (+31.9 per cent), Africa (+31.7 per cent) and Asia (+28.0 per cent). The number of attendees from North America (+15.7 per cent) and the rest of Europe (+12.6 per cent) also rose significantly.

In a visitor survey, about three-quarters of respondents were very satisfied or satisfied with IDS 2017, as well as with achieving their targets for the exhibition. The majority of those surveyed (90 per cent) would recommend IDS to business partners, and 70 per cent said they plan to visit IDS in 2019.

At the fair, 2,305 companies from 59 countries (compared with 2,182 companies from 56 countries in 2015) exhibited in an overall area of 163,000 m² (158,200 m² in 2015). These included 624 exhibitors and 20 additionally represented companies from Germany (636 and 19, respectively, in 2015), as well as 1,617 exhibitors and 44 additionally represented companies from abroad (1,480 and 44, respectively, in 2015). The proportion of foreign companies was 72 per cent (70 per cent in 2015). Of the more than 155,000 visitors from 157 countries (138,500 visitors from 151 countries in 2015), around 60 per cent (compared with 51 per cent in 2015) came from abroad.

IDS 2017 focused on digital production and diagnostics, intelligent networking solutions for practices and laboratories, smart services for dentists and dental technicians, as well as the further improvement of patient care and thus oral health worldwide.

The next IDS will take place from 12 to 16 March 2019.



© canadastock/Shutterstock.com

4th International SGOLA Congress

Author: Timo Krause, Germany

On 1 April 2017, fortbildungROSENBERG and SGOLA (Swiss Society for Oral Laser Applications) held their 4th International Congress at the Marriott Hotel in Zurich/Switzerland. The congress title was “Laser in the Dental Practice: Focussing on Innovation and Evidence”.

Dr Kresimir Simunovic, MSc, President of SGOLA, had gathered renowned speakers from Switzerland, Germany, Italy and Slovenia and 150 international

participants. The congress aim was to present new approaches in laser dentistry and thereby substantiate traditional laser-based treatment and therapy concepts. As laser applications are almost unlimited, they open further opportunities for all other dental disciplines, for example photothermal and photodynamic protocols in the treatment of periodontitis and periimplantitis or laser applications in endodontology—participants thus received an update from the practice for the practice.

Fig. 1: From left to right: SGOLA President Prof. Dr Kresimir Simunovic, Dr Jörg Meister, Prof. Dr Matthias Frentzen, Prof. Dr Giovanni Olivi, Dr David Dovšak, Dr Michel Vock.



Fig. 1



Fig. 2



Fig. 3

After the congress was opened by SGOLA President Dr Simunovic, Dr Jörg Meister (Aachen/Germany) started the scientific presentations. With his speech "Laser Technology—Dos and Don'ts", he gave insights in the range of options for laser applications in the dental practice. His speech was followed by Prof. Dr Matthias Frentzen's (Bonn/Germany) "News in Laser Research" and Prof. Dr Giovanni Olivi's (Rome/Italy) "Lasers-Assisted Dentistry & PIPS". Dr Claude Andreoni (Zurich/Switzerland) gave interesting tips for the "Laser-Assisted Treatment of Periimplantitis" with his closing speech of the first session.

The afternoon programme started with Dr Michael Hopp (Berlin/Germany) who spoke about the current status of the universality of diode lasers. Prof. Dr Olivi

followed with his second speech on "445 nm—A New Wavelength in Laser Dentistry". Dr David Dovšak (Ljubljana/Slowenia) opened an all-new perspective on dentistry with his speech "Laser-Assisted Snoring Therapy".

Dr Alex Kelsch (Karlsruhe/Germany) gave the first presentation after the coffee break, which was titled „Photothermal Periodontal Therapy with Emundo". He was followed by Dr Michel Vock's, MSc, (Seuzach/Switzerland) review on "The Past 17 Years of Laser Treatment in the Private Practice". SGOLA President Dr Simunovic himself held the final speech "The Potential of the Er:YAG Wavelength".

Traditionally, Dr Meister's laser safety course was held on the day before the congress. Participants learned the basics of laser applications and the interactions of light and tissues. They were rewarded with the certificate "Expert in Laser Safety SGOLA".

Conclusion

Participants were equally interested in the scientific approaches towards laser application in the dental practice and the associated industry exhibition of renowned manufacturers and distributors. Once more, the 4th International SGOLA Congress highlighted the potential of laser applications in the dental practice and their high esteem among users.

contact

SGOLA
 Seefeldstr. 128
 8008 Zurich, Switzerland
 Tel.: +41 443834070
 info@sgola.ch
 www.sgola.ch

Fig. 2: Participants enjoyed the relaxed atmosphere at the Zurich Marriott Hotel.

Fig. 3: From left to right: Participants Dr Marco Stocker, Dr. Chantal Riva (Switzerland) and Claude Andreoni.

Fig. 4: The congress took place on 1 April 2017 at the Marriott Hotel in Zurich/Switzerland.



Fig. 4



Bringing laser to sunlight

6th WFLD-ED Congress

Source: WFLD-ED 2017

Save the date: September 2017 will bring laser to sunlight with the joint event of the 6th WFLD-ED Congress and the 5th WALED Congress being held in sunny Thessaloniki, Greece. Organising Committee Chairman Dr Dimitris Strakas, Scientific Committee Chairman Prof. Dr Norbert Gutknecht and AALZ Business Development Manager Leon Vanweersch took the time to shine a light on the exclusive features of this special congress in the following interview.

lasers have entered the market and treatment concepts have been established to improve the success of dental treatment. I expect from the upcoming 6th WFLD-ED Congress in Thessaloniki that a large number of dentists will come in contact with the use of lasers and its benefits. This will create a growing interest in this technology.

You have already visited Thessaloniki and also supervised the preparations. Tell us a few words about the location and the organisation so far.

The location is very attractive. Not only is it a good place for the scientific programme, but also for a lot of social activities. This city is an extraordinary place. The local organisation is led by a person with a very high dedication to our Federation and to the use of lasers, thus his engagement is extremely high. Also his connection to the authorities of the University and to its professors is very helpful and beneficial for the preparation of the congress.

You will be also hosting the major event of the 16th World Federation Congress in Berlin next year, which coincides with the 30 year anniversary of ISLD (International Congress for Laser in Dentistry). Can you please update our readers on this very important meeting?

I am very happy that you have brought up this question. Indeed, it will be an extraordinary meeting in Berlin, not only because it is the World Congress, but also because we are celebrating it in the city of Albert Einstein—the father of the laser idea. I am sure that a large number of participants will come to Berlin and we are very dedicated and motivated to prepare a scientific programme of excellence. But due to the fact that we will celebrate the 30th anniversary of ISLD, we will also host a special party for our participants which will be a remarkable social event. I think it is a positive must to join this congress if you are a real laser enthusiast.

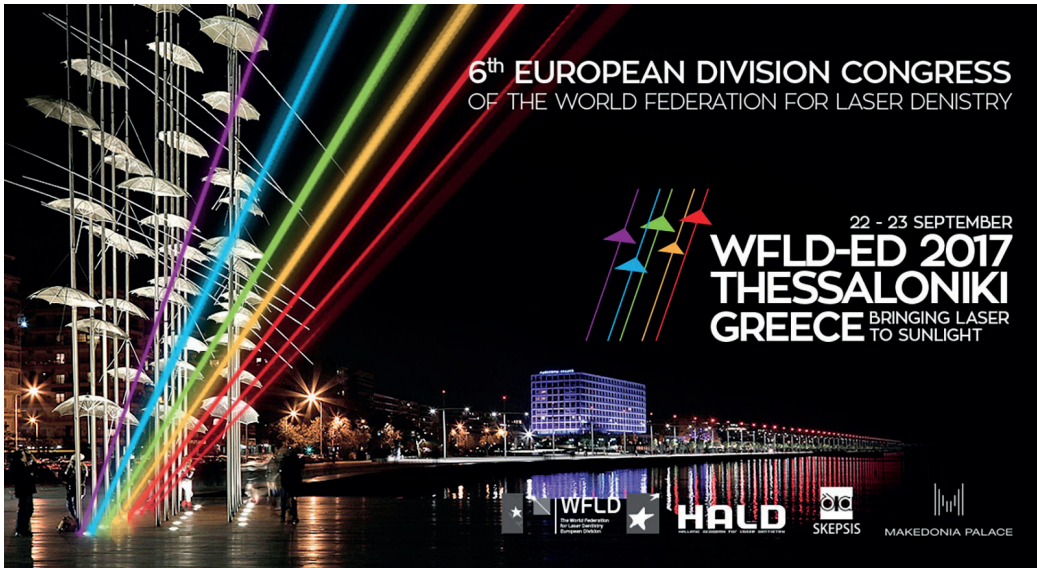Fig. 1: From left to right: Leon Vanweersch (Manager of WALED), Dr Dimitris Strakas (WFLD-ED Organising Committee Chairman), laser authors Dr Hubert Stieve and Augustus Crocker, Prof. Dr Norbert Gutknecht (CEO WFLD).

Professor Gutknecht, as CEO of WFLD, what is your opinion about laser dentistry improvements and how will this 6th European Laser Congress help to promote the use of laser even further amongst dentists?

During the last five years, we have seen a lot of improvements in the field of laser dentistry. New



Fig. 1



Dr Strakas, as the Chairman of WFLD-ED, can you please tell us your goals for the upcoming 6th European Laser Congress?

First of all, I want to thank OEMUS MEDIA AG and laser: international magazine of laser dentistry for their invaluable help. Coming to your question. I am honoured to host the 6th WFLD-ED Congress in my country and the city of Thessaloniki. My bonds with this beautiful city go very deep since I have lived here during my undergraduate studies, but also now as we have established the first laser clinic in Greece at the Aristotle University of Thessaloniki.

This year we reach the ten-year anniversary after the first WFLD-ED Congress in Nice, France. The goals of these congresses are always the same: to gather and disseminate the current knowledge in laser dentistry and provide the highest possible scientific quality presentations.

From my side, I would like to achieve after many years to have a great "laser party" both in terms of science and social events. This will strengthen the bonds between laser users worldwide and also the dynamics of our European Division, which always plays an important role in WFLD.

This is already happening: the registrations that we have received so far are from a big variety of countries, not only Greece and Europe, but globally with countries such as Egypt, Iran, Israel, Brazil, Colombia, Turkey and even Canada.

Finally, I am more than grateful to our sponsors. It is a very rare occasion that a European Laser Congress will have such a large number of laser companies in the exhibition area, whilst all of them are leaders in the field of dental laser system devices.

What was the inspiration for the congress motto "Bringing Laser to Sunlight"?

We all know that lasers have a direct association to electromagnetic radiation and light. It is also widely known that our country is renowned for its amount of sunshine and quality of light, both in Europe and worldwide. So the motto was brought up spontaneously by association. We want to bring together the photons of the coherent, monochromatic laser light with those of the Greek sunlight. In the same manner, our congress logo combined the famous artwork "Umbrellas" by the great sculptor Giorgios Zoggolopoulos in the awarded new promenade of Thessaloniki with the colours representing the different wavelengths of the visible spectrum.

What are the subjects of the congress and how can this be helpful for the laser user in his everyday practice?

Our esteemed invited speakers are internationally renowned for their work and research in the field of laser dentistry. The subjects of the scientific programme will cover the whole spectrum of the wavelengths that are currently used in dentistry. That means that the participant will not only discover the basic principles, but moreover all indications of laser applications including periodontology, endodontics, operative dentistry, oral surgery, paediatric dentistry, photodynamic therapy, prosthetics and implantology.

With an abundance of oral and poster presentations we will cover the needs of colleagues that are currently entering the fascinating world of laser dentistry as well as the needs of advanced laser users who want to follow up on new technological improvements and recent studies in this field.



© erveridis Vasilis/Shutterstock.com

Mr Vanweersch, as manager of WALED, can you please tell us some things about the World Academy and its goals?

WALED—the abbreviation of World Academy for Laser Education in Dentistry—is the alumni club of the Mastership/Fellowship and Master of Science programmes in Lasers in Dentistry of Aachen Dental Laser Center (AALZ) at RWTH Aachen University, Germany. Membership of this association is exclusively limited to students, graduates and alumni of these programmes in the field of lasers in dentistry. With WALED, we have established a worldwide academic and educational network in dental laser therapy. With respect to our vision of lifelong learning we provide our members the unique possibility to upgrade their knowledge every year with the newest developments in basic and clinical research.

Why did you select Thessaloniki for this 5th WALED Congress?

One of our closest and longest academic co-workers, Dr Dimitris Strakas, is the Organising Chairman and the Chairman of the European Division of WFLD. Due to the fact that our WALED members are spread around the globe, we try every year to give our members the highest value for their participation in our congress, and this is why we decided to organize a joint congress of WALED and WFLD-ED. Furthermore, the city of Thessaloniki definitively is a highly attractive motivation to participate in this congress, due to the unique location at the seaside, the touristic possibilities, and the very nice weather during the con-

gress days in September. On top, the congress hotel selected by us, the five-star Makedonia Palace Hotel, will be one of the best locations ever for organising such a congress, providing the best-possible background to the events we will offer our participants.

It seems to be a universal truth for the dentists participating in your events that the programme and social events related to it are of the highest quality. What can a dentist expect when registering for the upcoming joined WALED/WFLD-ED Congress in Thessaloniki?

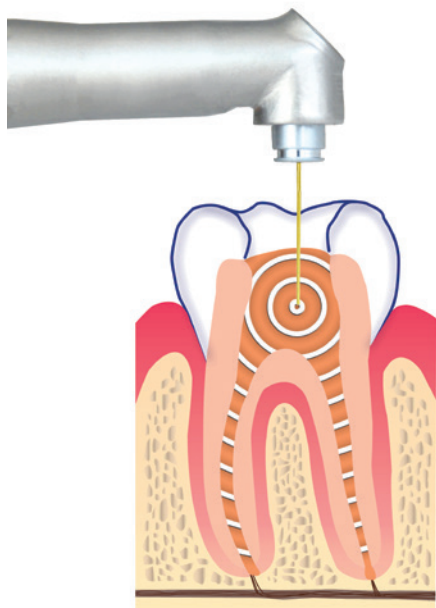
In addition to the high quality of all presentations in the WALED Congress and the two very interesting congress days of WFLD-ED, we offer our participants a unique, all-inclusive package, which also includes our WALED Get-Together Party on 21 September, the welcome cocktail reception on Friday, 22 September and the Gala Dinner on Saturday, 23 September as well as all coffee and lunch breaks during all three congress days. When WALED members book before 1 June, they can enjoy all of this for an all-inclusive registration fee of 350 Euro.

Thank you for the interview.

contact

Dr Dimitris Strakas
 Chairman of WFLD-ED
 DDS, MSc. in Lasers in Dentistry,
 RWTH Aachen University
 PhD Department of Operative Dentistry
 Aristotle University of Thessaloniki
 Spiridi 28
 38221 Volos, Greece
 Tel.: +30 24210 32525
www.wfld-thessaloniki2017.com





Fotona

Enhancing laser endodontics

Fotona's proprietary ASP (Adaptive Structured Pulse) technology represents a step forward with respect to controlling laser pulses in the temporal domain. By introducing a revolutionary new SWEEPS™ (Shock Wave Enhanced Emission Photoacoustic Streaming) mode, developed to further improve the cleaning and disinfecting efficacy of LightWalker's laser-assisted PIPS® endodontic procedures. Although the PIPS® irrigation is very effective, its cavitation dynamics is still much slower than what it could be if not slowed down by the friction on the root canal walls. With the specially adapted SWEEPS™ pulse structure, a faster photoacoustic collapse can now be pro-

duced even in narrow root canals, resulting in the emission of a large number of enhanced pressure waves throughout the canal. This is a very exciting development. With SWEEPS™-supported endodontics, you not only improve the streaming of irrigants throughout the complex root canal system, but also enhance the direct removal of the smear layer and disinfection, potentially eliminating the need for the use of aggressive irrigants.

Fotona, d.o.o.
Stegne 7
1000 Ljubljana, Slovenia
www.fotona.com

BIOLASE

Worldwide launch of new all-tissue laser system



BIOLASE, the global leader in dental lasers, announced today that its new, fifth-generation Waterlase Express™ all-tissue laser system, having received 510(k) clearance for commercial distribution from the U.S. Food and Drug Administration (FDA), is available for immediate sale to dentists in the US as well as select international markets in Europe, the Middle East and Asia.

Waterlase Express was first unveiled internationally in Cologne, Germany, at the International Dental Show (IDS), which is the world's leading trade show for the dental industry.

With extensive qualitative and quantitative research from a team of dentists around the world guiding the design of the system, Waterlase Express represents the new foundation of the Company's strategy to greatly expand all-tissue laser use in dentistry.

Biolase
4 Cromwell
Irvine, CA 92618, USA
www.biolase.com

cumdente

Contact-free incision

High performance for dental surgery, parodontology and implantology—this is possible with LASER blue® by cumdente. The blue light laser is superior to diode laser (infrared) due to its high effectiveness and incision efficiency at low energy parameters. One main advantage of the blue light laser is its property of being more tissue-conserving. Due to contact-free incision without touching any tissue and immediate entry into tissue ablation there is minimal tissue damage and no thermal tissue disruption or damage to contiguous structures such as tooth or implants. Furthermore, no delay effects with simultaneously minimised fibre optic wear and tear appear. With LASER blue®, practitioners can rely on an optimised incision effectiveness and haemostasis during the treatment with minimal biological side effects and coagulation. The device's antimicrobial effect and disinfection of contaminated tissue round off the picture. Currently, no disadvantages are known for the wavelength of this high performance laser, which makes it a perfect alternative for scalpel or HF units. Thanks to the mobile equipment with integral battery pack, one can immediately start using the blue light laser. The very simple touch screen controls allow 10 settings for each indication, which makes LASER blue® a perfect device for surgery, parodontology, implantology, endodontics, prosthetics as well as aesthetics.

Cumdente GmbH
Paul-Ehrlich-Straße 11
72076 Tuebingen, Germany
www.cumdente.com



New laser applications at the

7th LA&HA Symposium

Fotona's new SWEEPS™ endodontic treatment, first announced at this year's IDS, was one of the highlights of the 7th Annual Laser & Health

Academy Symposium. SWEEPS™ uses the power of the Er:YAG laser and Fotona's revolutionary new ASP technology to create non-ther-

mal photoacoustic shock waves for removing the smear layer in root canals. Also of special interest at the LA&HA Symposium were cases utilising the innovative TwinLight® approach for treatments in periodontics, oral surgery and even in NightLase®.

The 7th Annual Laser & Health Academy Symposium took place in May at the Slovenian Alpine resort of Kranjska Gora. This year's Symposium attracted a record number of nearly 500 participants, with more than 50 clinical experts from around the world presenting the latest innovations and applications in the field of medical and dental laser technology. The annual LA&HA Symposium is held to exchange research and education among medical professionals in the field of laser medicine, with a focus on practical instruction and presentations of the latest laser procedures and research. For further information, visit www.laserandhealthacademy.com.



Supplements are only effective in

Significant vitamin D deficiency

An international study of older adults has found that mass, untargeted provision of vitamin D supplements provides little clinical benefit to many when it comes to the common bone disease, osteoporosis. Instead, the study recommends targeting vitamin D supplements at individuals whose levels of this vitamin are markedly reduced. The results of the study—carried out by researchers at the University of Auckland, New Zealand, and Harvard Medical School, Boston—were announced today by Professor Ian R. Reid at ECTS 2017, the 44th European Calcified Tissue Society Congress being held in Salzburg, Austria.

Professor Reid concluded: "It was clear to us that future trials of vitamin D supplements in older adults should focus on those who have baseline vitamin D levels equal to or below 30nmol per litre and that the findings represent a significant step towards defining vitamin D deficiency for bone health in older adults."

New cost-effective blue laser

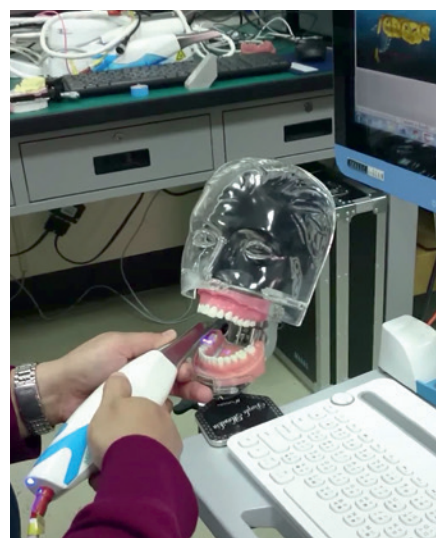Intraoral scanning technology

Taiwan's Metal Industries Research and Development Centre (MIRDC) has introduced a new blue laser line intraoral scanning technology. According to the developers, the device is built with mostly Taiwanese electronic components and will be significantly cheaper than similar scanning devices from international competitors. Through software, the device uses a triangular measuring method to focus a high-coherence laser light on to the object to be scanned. In this manner, it is able to accurately construct a dental model, taking precise measurements within an area of 22 x 18 mm, which reduces the margin of error, the developers said.

Developed by the MIRDC, the blue laser line was transferred to several Taiwanese companies, *Taiwan News* reported online.

The scanner, which is currently being tested in clinical trials, is to be introduced to the market later this year. According to the MIRDC, similar oral scanning devices made in Germany, Denmark and the US, for example, cost about NT\$1.2–1.6 million (US\$39,900–53,200). The

MIRDC's partners, however, hope that the commercialised product will sell for US\$30,000 to hospitals and dental clinics globally.

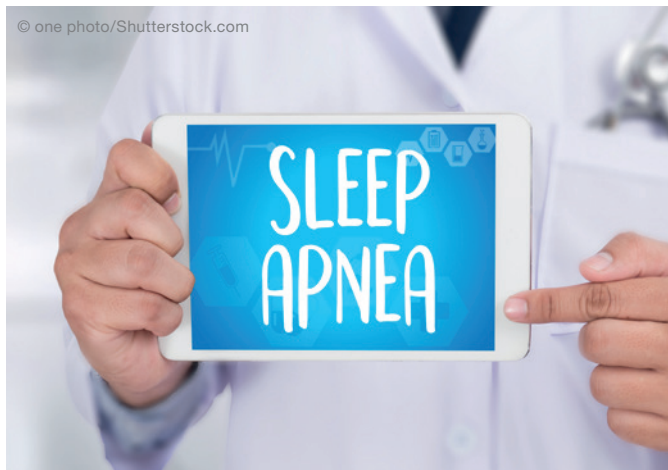

Screenshot (YouTube/solberg hu) of the newly developed blue laser line intraoral scanning device (MIRDC Taiwan).

Obstructive Sleep Apnea causes

Complications in implant-borne prostheses

Researchers from OSI Araba University Hospital in Victoria, Spain, published a study that investigated how Obstructive Sleep Apnea (OSA) affects implant-borne prostheses. The frequency with which a complication occurred



and the type of complication were studied in 67 patients. Contradictory to their initial hypothesis, the researchers found a high instance of complications related to OSA.

Of the 67 patients included in the study, the researchers found that 16 experienced complications; 13 of which had OSA. Among these 16 patients with complications, there were 22 prostheses with a total of 30 issues. The researchers found these complications consisted of porcelain fracture, fracture of the screw/implant, loosening of the screw, and decementation. The average time for a complication to occur was 73 months' post-implantation. During the study, the researchers also noted a strong relation between individuals who suffer from OSA and those who suffer from bruxism. Past studies revealed that those afflicted with bruxism had a higher instance (6/10) of complications with implant prostheses than those without bruxism (13/75). This shows that people suffering from OSA and/or bruxism have a more difficult time with successful prosthetic implantation.

This study shows that 81 per cent of patients with OSA experienced complications with their prostheses. Given that the success rate of implants is reported to be between 92 and 97 per cent, there is a strong correlation between OSA and prosthetic complications.

Survey exposes truth about

Our oral health habits

FDI World Dental Federation is myth busting what people around the world believe to be good oral health practices, encouraging them to become better informed and take action. Oral health is integral to our general health and well-being; impacting every aspect of our lives. The results from a survey carried out in 12 countries, by YouGov on behalf of FDI, exposed a significant gap between what people believe to be good oral health practices, versus what they actually do. Eight of the countries reported that 50 per cent or more of the people surveyed think it is important to brush your teeth straight after every main meal. Brazil, Mexico, Egypt and Poland were the worst offenders of this incorrect oral health practice (84%, 81%, 62% and 60% respectively). FDI recommends waiting at least 30 minutes after eating to brush your teeth to avoid weakening tooth enamel. The majority of countries surveyed incorrectly believe that rinsing the mouth out with water after brushing is important; Brazil, South Africa,

Mexico, India and Canada were found to practice this myth the most (77%, 75%, 73%, 67% and 67% respectively). It is actually recommended not to rinse with water straight after brushing to allow maximum exposure to fluoride, which will optimize the preventative effects.

Nearly half the population surveyed in India, South Africa, Brazil and Poland (52%, 49%, 48% and 42% respectively), felt that drinking fruit juice rather than fizzy drinks was important for good oral health. Fruit juice however, can also be high in sugar which can cause tooth decay. FDI recommends keeping consumption of sugary drinks to a minimum as part of a healthy, balanced diet.



FÜR JEDE KLINISCHE INDIKATION DAS OPTIMALE SYSTEM

LASER EINFACH, SICHER & SANFT



www.henryschein-dental.de

HENRY SCHEIN DENTAL – IHR PARTNER IN DER LASERZAHNHEILKUNDE

Wir bieten Ihnen ein breites und exklusives Sortiment marktführender Lasermodele verschiedener Hersteller an.

Unsere Laserspezialisten beraten Sie gern über die vielfältigen Möglichkeiten und das für Sie individuell am besten geeignete System.

Laser ist nicht gleich Laser und genau hier liegt bei uns der Unterschied:

Sie, Ihre Patienten und Ihre gemeinsamen Bedürfnisse stehen bei uns an erster Stelle.

Bei Henry Schein profitieren Sie vom Laserausbildungskonzept!

Von der Grundlagenvermittlung über hochqualifizierte Praxistrainings und Workshops zu allen Wellenlängen bis hin zu Laseranwendertreffen.

Unsere Laser-Spezialisten in Ihrer Nähe beraten Sie gerne.

FreeTel: 0800-1400044 oder FreeFax: 08000-404444

Erfolg verbindet.

 **HENRY SCHEIN®**
DENTAL

Effizienz & Innovation



Prof. Dr. Norbert Gutknecht

Liebe Kolleginnen und Kollegen,

als ich vor zweieinhalb Monaten über die Ausstellungsfläche der IDS gelaufen bin, haben mich zwei Aspekte besonders berührt. Zum einen ist die Zahl der Teilnehmer an der IDS und die Menge der Aussteller gestiegen, zum anderen nehmen die Innovationen und digitalen Technologien einen immer breiteren Raum ein. Der Beruf des Zahnarztes (vormals eine rein mechanische Arbeitsweise) wird zunehmend ein Kommando- und Kontrollplatz, umgeben von den unterschiedlichsten Technologien – so auch den neuen modernen Lasergeräten. Wenn man meinte, nur vier oder fünf Laserhersteller auf dieser Ausstellung anzutreffen, so musste man sich bei dem Blick ins Ausstellerverzeichnis eines Besseren belehren lassen. Nicht nur, dass mehr als 40 Laseraussteller und -hersteller vertreten waren, sondern die technische Weiterentwicklung der Lasergeräte war beeindruckend.

Die Leistungsfähigkeit der Geräte, die immer größer werdende Variabilität der Applikatoren und die, wie schon oben angesprochen, technische Weiterentwicklung der Software vieler Hersteller erfordert vom Benutzer ein immer größeres Maß an Verständnis dieser Technologie beim Einsatz am Patienten. Diesem Defizit an Kenntnissen versucht die Industrie mit aufwendigen Behandlungsanimationen und umfangreichen Voreinstellungen für bestimmte Therapien zu begegnen. Die Symbiose aus einem Hightech-Laser und einem guten Verständnis der adäquaten Handhabung derselben wird die Anwendung von Lasergeräten in Zukunft noch sinnvoller und effektiver machen.

Ihr

Prof. Dr. Norbert Gutknecht



Laserzahnheilkunde – Was geht und was nicht

Am 23. Juni 2017 findet der DGL-Kongress erstmalig in Form eines Workshops im Universitätsklinikum Aachen statt. Dieser Workshop-Kongress soll alle interessierten Anwender im Bereich der Laserzahnmedizin sowohl theoretisch als auch praktisch mit den täglichen Herausforderungen des Lasers konfrontieren.

Im Vordergrund der theoretischen und praktischen Einheiten werden dabei nachfolgende Fragen und Themen stehen:

1. Welche neuen Wellenlängen stehen Anwendern als Alternative zur Verfügung und wie unterscheiden sie sich?
2. Kann der Lasereinsatz in der Praxis optimiert werden?
3. Ist es ethisch vertretbar, für eine Laserbehandlung ein höheres Honorar zu verlangen?

4. Warum ist Diodenlaser nicht gleich Diodenlaser?
5. Auf Knopfdruck die richtige Therapie?
6. Kann heute noch ein 3-Watt-Nd:YAG-Laser erfolgreich in die Behandlung integriert werden?

Zusätzliche Fragen der Teilnehmer werden in einer Podiumsdiskussion besprochen und können der DGL bereits im Vorfeld zugesandt werden.

In den angebotenen Workshops sollen Schwerpunkte wie Endodontie, Parodontologie, Kinderzahnheilkunde, Implantologie und Periimplantitis, minimalinvasive Kariologie und Kavitätenpräparation sowie Ästhetische Zahnheilkunde und Bleaching diskutiert werden. Des Weiteren finden ein Marketing- und Abrechnungsworkshop statt. Die Teilnehmer erhalten ebenso einen Überblick über die neuesten Änderungen im Bereich der Lasersicherheit (neue Verordnung OStrV & TROS).

Einladung zur DGL-Mitgliederversammlung

Freitag, 23.06.2017, 11.30–12.30 Uhr
Aachen – Universitätsklinikum

Tagesordnung:

- TOP 1 Genehmigung der Tagesordnung
- TOP 2 Bericht des DGL-Vorstandes
- TOP 3 Vorstandswahlen
- TOP 4 WFLD/DGL-Weltkongress 2018 in Berlin
- TOP 5 Anträge zur Mitgliederversammlung
- TOP 6 Verschiedenes

WERDEN SIE
DGL-MITGLIED



DGL c/o Universitätsklinikum Aachen, Klinik für ZPP, Pauwelsstraße 30, 52074 Aachen

26. DGL-Jahrestagung Workshop-Kongress

Freitag, 23.06.2017, 08.00 – 18.00 Uhr | Aachen – Universitätsklinikum

09.00 Uhr	Begrüßung und Eröffnungsansprache Prof. Gutknecht, RWTH Aachen	11.00 Uhr	Klinisch relevante Indikationen für den Einsatz des 2.790nm Er,Cr:YSGG Lasers
09.30 Uhr	Klinisch relevante Indikationen für den Einsatz des 455/660/970 nm- Diodenlasers	11.30 Uhr	Klinisch relevante Indikationen für den Einsatz des 810nm-Diodenlasers
10.00 Uhr	Klinisch relevante Indikationen für den Einsatz des 2.940nm-Erbium YAG Lasers	11.30 Uhr	DGL-Mitgliederversammlung
10.30 Uhr	Klinisch relevante Indikationen für den Einsatz des 940nm-Diodenlasers	12.30 Uhr	Mittagspause

Workshop	Aussteller	Thema	Referent
1+2	Dentsply Sirona	Der Sirolaser – Eine Übersicht über seine drei Wellenlängen, 445/660/970 nm // Hands-on	Dr. Johannes-Simon Wenzler
3	Biolase	Laserunterstützte Kinderzahn- heilkunde / Von Kons bis Chirurgie	Dr. Gabi Schindler-Hultzsch
4	Biolase	Laserunterstützte Chirurgie / Dioden- oder Er,Cr:YSGG-Laser?	Dr. Gabi Schindler-Hultzsch
5	Morita	Die Anwendung des Er:YAG- Laser in der Praxis	Dr. Detlef Klotz
6	DGL	Neuerungen in der Lasersicherheit	Dr. René Franzen
7	DGL	Neuerungen in der Abrechnung	Dr. Detlef Klotz

Jeder Teilnehmer muss an mindestens drei unterschiedlichen Workshops teilgenommen haben, um sein Zertifikat mit 8 Fortbildungspunkten erhalten zu können. Folgende Workshops werden angeboten, in die Sie sich bitte vorab bei den Ausstellern eintragen.

Uhrzeit	Dentsply Sirona	Biolase	Morita	DGL
14.00 – 15.00 Uhr	1	2	4	
15.00 – 16.00 Uhr	1	3	4	
16.00 – 17.00 Uhr	1	2	4	
17.00 – 18.00 Uhr	1	3	4	
18.00 – 18.30 Uhr				5
18.30 – 19.00 Uhr				6

Änderungen vorbehalten



Laserzahnmedizin kompakt

Jahrbuch Laserzahnmedizin 2017

Das umfassend überarbeitete und aktualisierte Jahrbuch Laserzahnmedizin in seiner 18. Auflage ist die einzige rein deutschsprachige Laserzahnmedizin-Publikation am Markt. In der Fülle an Fachartikeln, Grundlagenbeiträgen sowie den aktuellsten Lasermarktübersichten ermöglicht es einen fundierten Einblick für Einsteiger und erfahrene Anwender. Neben bewährten Verfahren greift das neue Jahrbuch Laserzahnmedizin 2017 in mehreren Artikeln auch die Ultrakurzpulslasertechnologie auf, welche entscheidende Verbesserungen auf dem Gebiet der Laserzahnheilkunde ermöglichen könnte. Zusätzlich stellen sich erfahrene Industriepartner der Laserzahnmedizin vor und führen in ihre Produkte und Services auf diesem Gebiet ein. Einen besseren und aktuelleren Überblick, als es das Jahrbuch Laserzahnmedizin 2017 bietet, gibt es nicht.

Das Jahrbuch ist zum Preis von 49 Euro (zzgl. MwSt + Versand) im OEMUS Onlineshop erhältlich oder kann über grasse@oemus-media.de angefordert werden.

Quelle: OEMUS MEDIA AG



Zufriedenere Patienten dank

Online-Terminlösung

Das Angebot einer Online-Terminbuchung wirkt sich positiv auf die allgemeine Zufriedenheit von Patienten mit ihren Ärzten aus. Das zeigt eine Auswertung der Arztbewertungen auf www.jameda.de. Demnach erhalten Mediziner, die ihren Patienten eine Online-Terminbuchung anbieten, auf einer Schulnotenskala von 1 bis 6 die Durchschnittsnote 1,28, womit sie deutlich besser abschneiden als ihre Kollegen ohne Online-Terminbuchung. Letztere werden von ihren Patienten mit der Durchschnittsnote 1,80 bewertet. Patienten bewerten zahlreiche Aspekte ihres Arztbesuchs besser, wenn es sich um eine Praxis mit Online-Terminbuchung handelt. So fällt zum Beispiel die Wartezeit auf einen Termin (1,42) bei diesen Arztpraxen deutlich besser aus als bei Medizinern, die keine Online-Terminbuchung anbieten (1,88).

Quelle: jameda



Henry Schein Gründer Camp

Das Gründerforum für Zahnärzte

Am 29. und 30. September 2017 findet eine Veranstaltungspremiere statt: Das Gründer Camp von [denttalents.](http://denttalents.de), eine Plattform für Austausch, Inspiration und Networking rund um die Zukunft in der eigenen Praxis. Geboten wird ein abwechslungsreiches Programm in der Union Halle in Frankfurt am Main. Im östlichen Szeneviertel der Stadt gelegen, passt die Location perfekt zur Atmosphäre, die das Gründer Camp ausmacht: kreativ und inspirierend. Das Gründer Camp bereitet interessierte Zahnärzte auf die Existenzgründung vor. Wenn es um die Frage „Selbstständigkeit: Ja oder Nein?“ geht, bietet das Camp Inspiration und Entscheidungshilfe. Häufig lassen kleine Impulse Ideen für die Zukunft in der eigenen Praxis entstehen. Acht Praxisgründerinnen und -gründer mit unterschiedlichen Praxiskonzepten und Gründungsgeschichten werden einen Teil des Pro-

gramms abdecken und machen das Gründer Camp zu einem komplett neuen Veranstaltungsformat. Alle Gründungen liegen maximal fünf Jahre zurück. Durch diese Vielfältigkeit ist für jeden Zuhörer etwas dabei. Ergänzt wird das Programm durch weitere Gründungsspezialis-

ten aus den Bereichen Businessplan, Marketing, Führung und Kommunikation. Die Anmeldung ist unter www.denttalents.de/gruendercamp möglich.

Quelle: Henry Schein



Antwort:

Deutsche Gesellschaft für Laserzahnheilkunde e.V.
c/o Universitätsklinikum Aachen
Klinik für Zahnerhaltung
Pauwelsstraße 30
52074 Aachen

Tel.: 0241 8088164
Fax: 0241 803388164
E-Mail: sekretariat@dgl-online.de
www.dgl-online.de

26. DGL-Jahrestagung Workshop-Kongress

23. Juni 2017 im Universitätsklinikum Aachen



- Hiermit melde ich mich verbindlich zur 26. Jahrestagung der DGL im Universitätsklinikum Aachen am Freitag, dem 23. Juni 2017, von 9.00 bis 19.00 Uhr an (inkl. Kaffee, Kaltgetränke, Mittagessen).

Name: _____

Straße/Nr.: _____

Vorname: _____

PLZ/Ort: _____

Unterschrift: _____

Datum: _____

Status: DGL-Mitglied 230,- € Nichtmitglied 280,- € Student/Assistent/Helferin 90,- €

Die Bestätigung Ihrer Anmeldung erfolgt nach dem Eingang Ihrer Kongressgebühren auf das Konto der DGL: Sparkasse Aachen, IBAN: DE56 3905 0000 0042 0339 44, BIC: AACSD33

Allgemeine Bedingungen

Anmeldeschluss ist der **31. Mai 2017**. Anmeldungen nach diesem Zeitpunkt können nur noch vor Ort bearbeitet werden (bis zur max. Teilnehmerzahl). Nach Zugang der Anmeldung ist diese für den Teilnehmer verbindlich. Die Gestaltung und Durchführung des wissenschaftlichen Programms obliegt der Deutschen Gesellschaft für Laserzahnheilkunde e.V. Für die Durchführung der Workshops während der Dentalausstellung übernimmt die Deutsche Gesellschaft für Laserzahnheilkunde e.V. keine Verantwortung.

Bankverbindung: Sparkasse Aachen, IBAN: DE56 3905 0000 0042 0339 44, BIC: AACSD33



Publisher

Torsten R. Oemus
oemus@oemus-media.de

CEO

Ingolf Döbbecke
doebbecke@oemus-media.de

Members of the Board

Jürgen Isbaner
isbaner@oemus-media.de

Lutz V. Hiller
hiller@oemus-media.de

Editor in Chief

Norbert Gutknecht
ngutknecht@ukaachen.de

Coeditors in Chief

Samir Nammour
Matthias Frentzen

Managing Editors

Georg Bach
Leon Vanweersch

Division Editors

Umberto Romeo
European Division

Melissa Marchesan
North American Division

Carlos de Paula Eduardo
South American Division

Toni Zeinoun
Middle East & Africa Division

Ambrose Chan
Asia & Pacific Division

Senior Editors

Aldo Brugneira Junior
Kenji Yoshida
Lynn Powell
Dimitris Strakas
Adam Stabholz
Marcia Martins Marques

Editorial Board

Peter Steen Hansen, Aisha Sultan,
Ahmed A Hassan, Antonis Kallis,
Dimitris Strakas, Kenneth Luk, Mukul Jain,
Reza Fekrazad, Sharonit Sahar-Helft,
Lajos Gaspar, Paolo Vescovi, Ilay Maden,
Jaana Sippus, Hideaki Suda, Ki-Suk Kim,
Miguel Martins, Aslihan Üsümez,
Liang Ling Seow, Shaymant Singh Makhan,
Enrique Trevino, Blanca de Grande,
José Correia de Campos, Carmen Todea,
Saleh Ghabban, Stephen Hsu, Antoni Espana Tost,
Josep Arnabat, Alaa Sultan, Leif Berven,
Evgeniy Mironov, Ahmed Abdullah, Boris Gaspirc,
Peter Fahlstedt, Ali Saad Alghamdi, Alireza Fallah,
Michel Vock, Hsin-Cheng Liu, Sajee Sattayut,
Anna-Maria Yannikos, Ryan Seto, Joyce Fong,
Iris Brader, Masoud Mojahedi, Gerd Volland,
Gabriele Schindler, Ralf Borchers, Stefan Grümer,
Joachim Schiffer, Detlef Klotz, Jörg Meister,
Rene Franzen, Andreas Braun,
Sabine Sennhenn-Kirchner, Siegfried Jänicke,
Olaf Oberhofer, Thorsten Kleinert

Editorial Office

Georg Isbaner
g.isbaner@oemus-media.de

Claudia Jahn
c.jahn@oemus-media.de

Product Manager

Timo Krause
t.krause@oemus-media.de

Executive Producer

Gernot Meyer
meyer@oemus-media.de

Designer

Sandra Ehnert
s.ehnert@oemus-media.de

Stephan Krause

s.krause@oemus-media.de

Customer Service

Marius Mezger
m.mezger@oemus-media.de

Published by

Oemus Media AG
Holbeinstraße 29, 04229 Leipzig, Germany
Tel.: +49 341 48474-0
Fax: +49 341 48474-290
kontakt@oemus-media.de
www.oemus.com

Printed by

Silber Druck oHG
Am Waldstrauch 1, 34266 Niestetal, Germany

laser international magazine of laser dentistry
is published in cooperation with the World
Federation for Laser Dentistry (WFLD).

WFLD Headquarters

University of Aachen Medical Faculty
Clinic of Conservative Dentistry
Pauwelsstr. 30, 52074 Aachen, Germany
Tel.: +49 241 808964
Fax: +49 241 803389644
ngutknecht@ukaachen.de
www.wfld-org.info

www.laser-magazine.com

Copyright Regulations

laser international magazine of laser dentistry is published by OEMUS MEDIA AG and will appear in 2017 with one issue every quarter. The magazine and all articles and illustrations therein are protected by copyright. Any utilisation without the prior consent of editor and publisher is inadmissible and liable to prosecution. This applies in particular to duplicate copies, translations, microfilms, and storage and processing in electronic systems. Reproductions, including extracts, may only be made with the permission of the publisher. Given no statement to the contrary, any submissions to the editorial department are understood to be in agreement with a full or partial publishing of said submission. The editorial department reserves the right to check all submitted articles for formal errors and factual authority, and to make amendments if necessary. No responsibility shall be taken for unsolicited books and manuscripts. Articles bearing symbols other than that of the editorial department, or which are distinguished by the name of the author, represent the opinion of the afore-mentioned, and do not have to comply with the views of OEMUS MEDIA AG. Responsibility for such articles shall be borne by the author. Responsibility for advertisements and other specially labelled items shall not be borne by the editorial department. Likewise, no responsibility shall be assumed for information published about associations, companies and commercial markets. All cases of consequential liability arising from inaccurate or faulty representation are excluded. General terms and conditions apply, legal venue is Leipzig, Germany.

SUBSCRIBE NOW!

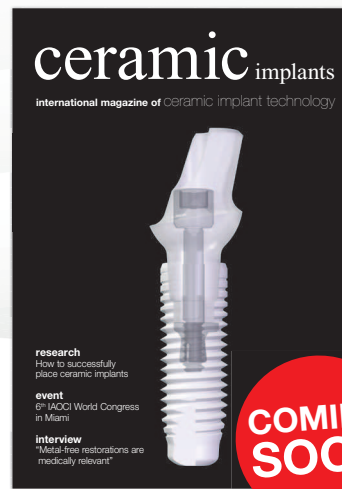
laser – international magazine of laser dentistry

Interdisciplinary, transparent & market orientated

ONLINE
SUBSCRIPTION HERE



www.oemus.com/abo



ADMED.com

Fax: +49 341 48474-290

I would like to subscribe for the following journals:

- laser – international magazine of laser dentistry 4 issues p.a. € 44*
- implants – international magazine of oral implantology 4 issues p.a. € 44*
- ceramic implants – international magazine of oral ceramic implant technology 2 issues p.a. € 30*

Terms & Conditions: The subscription may be cancelled in written form without due justification within 14 days of order by contacting OEMUS MEDIA AG, Holbeinstraße 29, 04229 Leipzig, Germany. Dispatching notification in good time will suffice. The subscription is automatically extended by another twelve months if it is not cancelled in written form 6 weeks prior to the end of the reference period.

* All prices include VAT, shipping and handling (within Germany).

Last Name, First Name

Company

Street

ZIP/City/Country

E-Mail

Signature

Credit Card Number Expiration Date Security Code

Eendo e Class
سیستم هوشمند اندوروتاری
۱۵ حافظه، ۱۰ انیوتن ترک (user friendly)

K120
موتور جراحی ایمپلنت
قدرتمندترین موتور جراحی ایمپلنت دنیا
با ترک ۹۰ نیوتن

ENDO SMART
سیستم هوشمند
اندوروتاری

IROOTS
اپکس لوکیتور
نسل پنجم با دقت ۹۸/۸
با نرم افزاز ویژه

Rootor
اپکس لوکیتور

Cybrid
لایت کیور
با قدرت فوق العاده ۲۷۰۰ وات

META[®] BIOMED



Endo pex
آبچوراتور (گان + هیت کریر)

سیستم تزریق گرم گوتاپر کا و فیلینگ ورتیکال با تراکم عمودی
ساده و آسان با نتیجه متفاوت



E&QMASTER
آبچوراتور (گان + هیت کریر)



GENESYS
آبچوراتور (گان + هیت کریر)