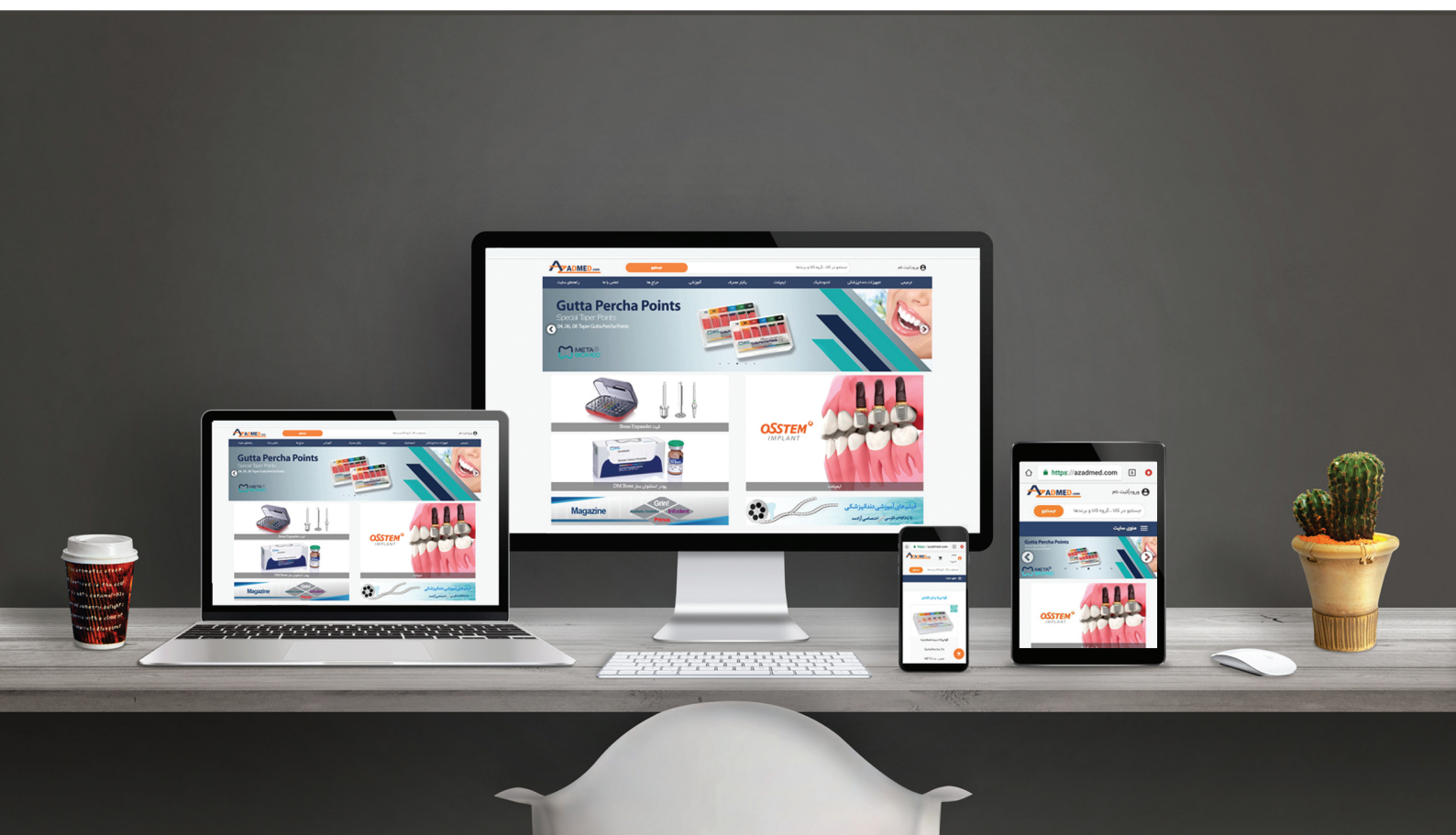

www.azadmed.com



 azaadtejaratpars

 @azadmed2

 88 98 80 63 - 6

laser

international magazine of laser dentistry



ISLD



research

Diverse applications of lasers in dentistry

case report

Diode laser-assisted vital pulp therapy

events

1st IDSCLD in Plovdiv, Bulgaria





16th WORLD CONGRESS WFLD 2018

1 – 3 OCTOBER 2018
RWTH AACHEN UNIVERSITY
AACHEN, GERMANY



The 16th Congress of the
World Federation for Laser
Dentistry (WFLD)

The 27th Annual Meeting of
the German Society for Laser
Dentistry (DGL)

The 6th Annual Congress
of the World Academy for
Laser Education
in Dentistry (WALD)

This congress will integrate science and practical experience on different levels of presentation and demonstrations, like:

- High ranked international keynote speaker lectures
- On stage live patient demonstrations
- Interactive digital poster presentations
- Oral presentations combined with clinical relevant skill training
- Short presentations of latest research findings
- Clinical case presentations
- Rotating company supporting workshops, gaining continuous education certificates.

CONTACT

Headquarters WFLD 2018 Aachen
Mr. Leon Vanweersch
Vice-Organizing Chairman
Phone: +49 151 50610781
headquarters@wfl-d-aachen2018.com
www.wfl-d-aachen2018.com

Prof. Dr Norbert Gutknecht

DGL President & Organising Chairman
of the 16th WFLD World Congress



Anniversary congress in Aachen from 1 to 3 October 2018

Dear friends of laser dentistry,

It is my great pleasure to be able to welcome you in Aachen, Germany, for this extraordinary congress event: 30 years of WFLD/ISLD, 27 years of DGL and 12 years of WALED. With this anniversary congress, we are making it possible for many colleagues from all over the world to jointly participate in the scientific presentations and clinical treatment sessions.

If we are considering the application of lasers in dentistry, we have to realise that while it is a well-established treatment method today, it was only initiated 30 years ago. Diverse universities have conducted research which in the end has led to a scientifically ensured application of these methods. At the same time, scientists and doctors have come together in working groups which have eventually become the foundation for the establishment of laser societies. Today, nobody would question an indication-based application of lasers in dentistry anymore.

The ISLD (International Society for Laser Dentistry), as well as the DGL were founded with the objective to promote the application of lasers in dentistry in both science and practice. In 1998, the DGL and ISLD thus became associated and have been closely collaborating ever since.

As part of this collaboration, the DGL successfully organised the ISLD World Congress in Berlin in 2006. As one of the founding members of DGL and Organising Chairman, I am especially happy and honoured that

the DGL will again be the hosting society of the anniversary congress of WFLD/ISLD in Aachen, Germany, and that Prof. Dr Lynn Powell as a founding member of ISLD has taken over the position as Chairman of the Scientific Committee.

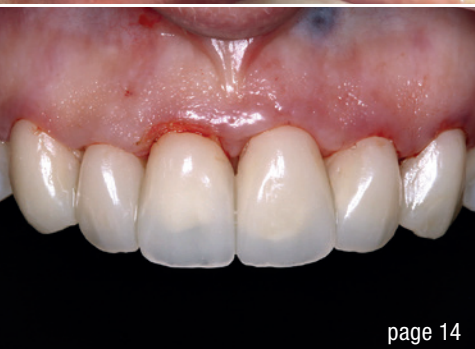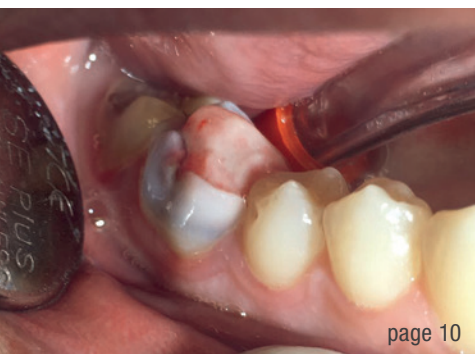We will offer scientists and practitioners the scientific and clinical platform to present and discuss their research results and clinical cases, and to stay up-to-date with the developments and possibilities, as well as with the limits of applying lasers in oral medicine. The workshops offered as part of the congress are dedicated to continuous clinical education and are thus acknowledged with further education credits.

As you know, it is not only the aim of a congress to further educate oneself scientifically and clinically but also to socialise with friends and colleagues. I am thus looking forward to enjoying good food and live music with you at Rahe Castle on Tuesday evening.


With all this in mind, I would like to wish us all a harmonious congress.

Yours

Prof. Dr Norbert Gutknecht



Cover image courtesy of
Light Instruments Ltd.,
in cooperation with Swarovski
www.light-inst.com



editorial

- Anniversary congress** in Aachen from 1 to 3 October 2018 03
Prof. Dr Norbert Gutknecht

research

- Diverse **applications** of **lasers** in dentistry 06
Dr Igor Cernavin

case report

- Diode laser-assisted **vital pulp therapy** in pulp polyp treatment 10
Drs Maziar Mir, Masoud Mojahedi, Jan Tunér & Masoud Shabani

industry

- Dual-wavelength** laser in **aesthetic** and **prosthetic** dentistry 14
Dr Bogdan Crisan *et al.*

practice management

- Six Sigma** in the management of **laser-assisted** dental practices 20
Dr Imneet Madan, UAE
- Successful **communication** in your **daily practice** 24
Dr Anna Maria Yiannikos

interview

- Launching a **novel cutting-edge** dental laser line 26

events

- 1st International Dental Students Congress for Laser Dentistry** 30
Dr Georgi Tomov

news

- manufacturer **news** 28
- news** international 32

DGL

- Jubiläumskongress** vom 1. bis 3. Oktober 2018 in Aachen 37
Prof. Dr. Norbert Gutknecht
- news** germany 38

about the publisher

- imprint 42

The universe at your fingertips.

● LightWalker

The highest technology dental laser system

Supreme clinical results:

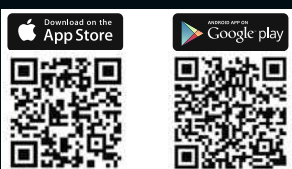
- TwinLight® Perio Treatments
- TwinLight® Endo Treatments
- No-sutures soft-tissue surgery
- Patient-friendly conservative dentistry
- Pre-sets for over 40 applications


Unmatched simplicity of use:

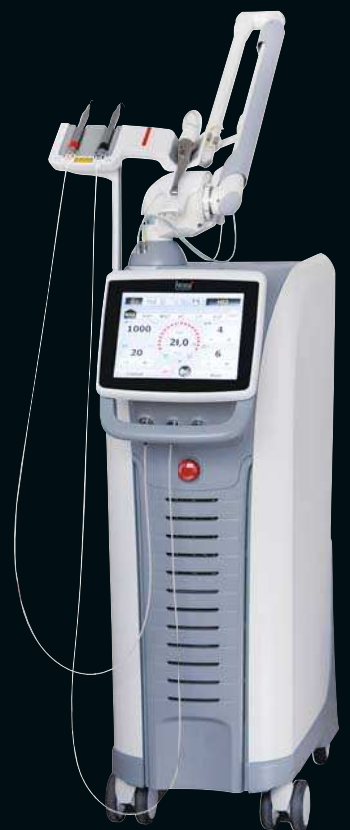- Balanced and weightless OPTOflex® arm
- Nd:YAG handpiece detection system
- Quantum Square Pulse technology for fast minimally invasive treatments
- X-Runner™ - the first digitally controlled Er:YAG dental laser handpiece

Journey into a new dental experience with speed, precision and great results.

Visit www.fotona.com today!



 Fotona App





© tandaV/Shutterstock.com

Diverse applications of lasers in dentistry

Recent literature

Dr Igor Cernavin, Australia

When considering whether to work with lasers and in which field they could be applied, recent studies provide many application options and issues for practitioners to consider. The following presents some of the newest research on possible areas of application and further investigation.

Petrov et al. used a femtosecond laser with a high repetition rate, which is probably the future of lasers for hard-tissue removal to achieve fast and more precise ablation in dentine and enamel.¹ They concluded that the ultra-fast femtosecond laser used in their work holds the promise of a significant drilling ability without collateral thermomechanical effects. It achieved high processing efficiency, overcame disadvantages of other laser sys-

tems reported, and can be used to develop an instrument for cavity preparation based on fast and precise ablation. Their further aim is to exceed the speed of conventional drilling instruments and thus to reduce the treatment time, which in turn will bring comfort to the patient.

Levine published an article on how to choose the right laser for one's practice, which readers may find of interest.²

Hashimoto et al. investigated fluoridated hydroxyapatite for application as an implant coating for titanium bone substitute materials for dental implants.³ They concluded that fluoridated hydroxyapatite coatings are suitable for real-world implantation applications.

Giannelli et al. carried out a double-blind, randomised, single-centre, split-mouth clinical trial investigating the efficacy of and patient-reported outcomes after one year of treatment of severe periodontitis with a laser and light-emitting diode (LED) procedure adjunctive to scaling and root planing.⁴ Their study confirmed the efficacy of combined phototherapy and scaling and root planing, which had emerged from previous clinical trials, extending its field of application to severe periodontitis.⁴

Belcheva et al. carried out a study whose aim was to evaluate the positive effects of the carbon dioxide laser (10,600nm) with acidulated phosphate fluoride gel on enamel acid resistance.⁵ Their conclusion was that this combination was more effective in protecting the enamel surface and resisting demineralisation than was carbon dioxide laser irradiation or fluoride alone.⁵

Campos et al. published a double-blind study on immediate laser-induced haemostasis in anticoagulated rats subjected to oral soft-tissue surgery.⁶ There has been much controversy about the management of patients on oral anticoagulants requiring oral surgical procedures. The haemostatic properties of high-power lasers were perceived to be potentially helpful during oral soft-tissue surgeries in anticoagulated patients. The authors concluded that laser-induced haemostasis is an alternative for intra- and postoperative bleeding control in patients on anticoagulation therapy.⁶

As oncological treatment can result in changes in the oral cavity, Carvalho et al. drafted a guide, based on a systematic review, directed at the team of health professionals involved in the oral care of oncological patients.⁷ The review concentrated on randomised clinical trials involving paediatric and adult oncological patients, focusing on the prevention and treatment of oral complications.⁷ The studies included in the review emphasise the provision of Low Level Laser Therapy, among other interventions, to minimise the severity of oral problems in such patients.⁷

Tani et al. carried out an *in vitro* study that compared photo-biomodulation potentiality using red (635 ± 5 nm) or near-infrared (808 ± 10 nm) diode lasers and violet-blue (405 ± 5 nm) LED operating in a continuous wave with a 0.4 J/cm energy density, on human osteoblast and mesenchymal stromal cell viability, proliferation, adhesion and osteogenic differentiation.⁸ They concluded that the 635 nm laser had a potential effective option for promoting/improving bone regeneration.⁸

Ghouth et al. carried out a systematic review of the evidence on the use of laser Doppler flowmetry in the assessment of the pulpal status of permanent teeth compared with other sensibility and/or vitality tests. They con-

cluded that, despite the higher reported sensitivity and specificity of laser Doppler flowmetry in assessing pulp blood flow, this data is based on studies with a high level of bias and serious shortfalls in study design.⁹ More research is needed to study the effect of different laser Doppler flowmetry's parameters on its diagnostic accuracy and the true cut-off ratios by which a tooth could be diagnosed as having a normal pulp.⁹

Kaur et al. compared soft-tissue wound healing using diode lasers (810 nm) versus the conventional scalpel approach as an uncovering technique during second-stage surgery for implants.¹⁰ They found that it can minimise surgical trauma, reduce the amount of anaesthetic required, improve visibility during surgery owing to the absence of bleeding and eliminate postoperative discomfort.¹⁰

Efficiency in debonding porcelain laminate veneers was studied by Al-Balkhi et al. using several laser parameters and two different application modes of the Er:YAG laser (contact and non-contact mode).¹¹ Their finding was that the Er:YAG laser is an effective tool in debonding porcelain laminate veneers. The non-contact application mode was more efficient in reducing debonding time than the contact application mode, but resulted in a higher change in pulp temperature.¹¹

Kellesarian et al. carried out a comprehensive review to assess the effectiveness of erbium lasers in the removal of all-ceramic fixed dental prostheses and found that the benefits of lasers over mechanical instrumentation for crown removal encompassed efficient restoration retrievability without restoration or tooth surface damage and a relatively easier and more time-effective procedure with no prerequisite for anaesthetic agents.¹² It is, however, imperative for clinicians to be well trained and exhibit adequate knowledge regarding recommended power settings and laser-safety parameters with reference to interactions between light and different tissues and ceramics.¹²

The effect of Er:YAG (Smart 2940D Plus, DEKA) and Er,Cr:YSGG (Waterlase iPlus, BIOLASE) lasers on the shear bond strength between orthodontic brackets and dental porcelain in comparison

with conventional acid etching with 9 % hydrofluoric acid (Ultradent Products) was investigated by Mirhashemi et al.¹³ They concluded that with the laser groups the failures were mostly adhesive, while they were mostly cohesive with the controls.¹³ They found that the Er:YAG laser with the specifications they used was not a suitable alternative to hydrofluoric acid etching.¹³ In the case of the Er,Cr:YSGG laser, although the conditioning outcome met the bond strength requirement for orthodontic brackets (6–8 MPa) they concluded that the bond strength must be further improved by fine-tuning the irradiation parameters.

Yassaei et al. assessed the efficacy of an Er:YAG laser and pastes containing casein phosphopeptide-amorphous calcium phosphate (CPP-ACP) with and without fluoride and their combination for prevention of white spot lesions in the enamel.¹⁴ They found that the Er:YAG laser was able to decrease demineralisation.¹⁴ It further proved to be a potential alternative to preventative dentistry and was more effective when combined with CPP-ACP products.¹⁴ This would be useful especially for orthodontics.

Sarmadi et al. evaluated patients' experiences of two excavation methods, the Er:YAG laser and rotary bur, and the time required with these methods, as well as objective assessments of quality and durability of restorations over a two-year period.¹⁵ Their conclusions were that the Er:YAG laser technique was more time-consuming than the rotary bur, but despite this, the laser technique caused less discomfort and was preferred as an excavation method by patients.¹⁵

Li et al. carried out a meta-analysis to systematically evaluate the applications of Er:YAG lasers for the removal of caries and cavity preparation in children.¹⁶ They concluded that the time required for Er:YAG laser treatment was longer than that for the conventional mechanical method, but there was less pain associated with the Er:YAG laser treatment.¹⁶ There were no significant differ-

ences in the complete retention rate, marginal discoloration and marginal adaptation when compared with the conventional method.¹⁶

Pinheiro et al. assessed the utility of dental acid etchants containing 37 % phosphoric acid and methylene blue dye as a sensitising agent for photodynamic therapy to reduce *Streptococcus mutans* in dental caries.¹⁷ They concluded that this treatment can be used as a photosensitising agent for photodynamic therapy to reduce the *S. mutans* burden in dental caries.

Laser dentistry offers many application options and numerous research approaches that might be interesting to investigate or to stay up-to-date with for practitioners. This consideration of recent literature has shown that there is still much potential for the increased use and application of lasers in the different fields of dentistry.



contact

Dr Igor Cernavin

Prosthodontist
Honorary Senior Fellow at the
University of Melbourne School of Medicine,
Dentistry and Health Sciences
Director and co-founder of the
Asia Pacific Institute of Dental Education
and Research (AIDER)
Australian representative of WFLD

Private practice
274 Main Rd East
St Albans VIC 3021, Australia



Kurz & bündig

Zahnmedizinern, welche Laser zukünftig in ihrer Praxis einsetzen möchten oder wissenschaftliche Erkenntnisse zu den passenden Einsatzgebieten suchen, bieten aktuelle Studien viele Einblicke in nutzbringende Anwendungsbereiche. Der Autor stellt diverse aktuelle Studien der Laserforschung und -nutzung wie zum Beispiel zur Verwendung von Lasern zur Implantatfreilegung oder zur Auswahl des geeigneten Lasers für das persönliche Tätigkeitsfeld vor. Kurze Auszüge und Zusammenfassungen geben Anwendern einen ersten Eindruck und bieten ihnen eine Übersicht zu den gegenwärtigen Einsatzmöglichkeiten und Forschungsansätzen, u. a. zum Einsatz der Lasertherapie zur Minimierung oraler Beschwerden von Krebspatienten. Der Autor offeriert dem Leser verschiedene Optionen für die interessante Lektüre oder weiterführende Recherche.

Die Lasierzahnmedizin bietet viele Anwendungsoptionen, sowie zahlreiche interessante Forschungsgebiete, bei welchen es sich für Anwender lohnt, auf dem neusten Stand zu bleiben. Die hier aufgezeigte Literatur verdeutlicht, dass noch sehr viel Potenzial zum vermehrten Einsatz von Lasertechnik in den diversen Feldern der Zahnmedizin besteht.



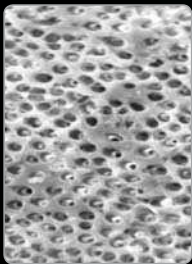
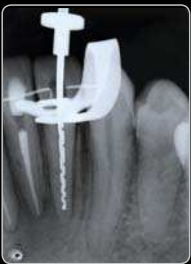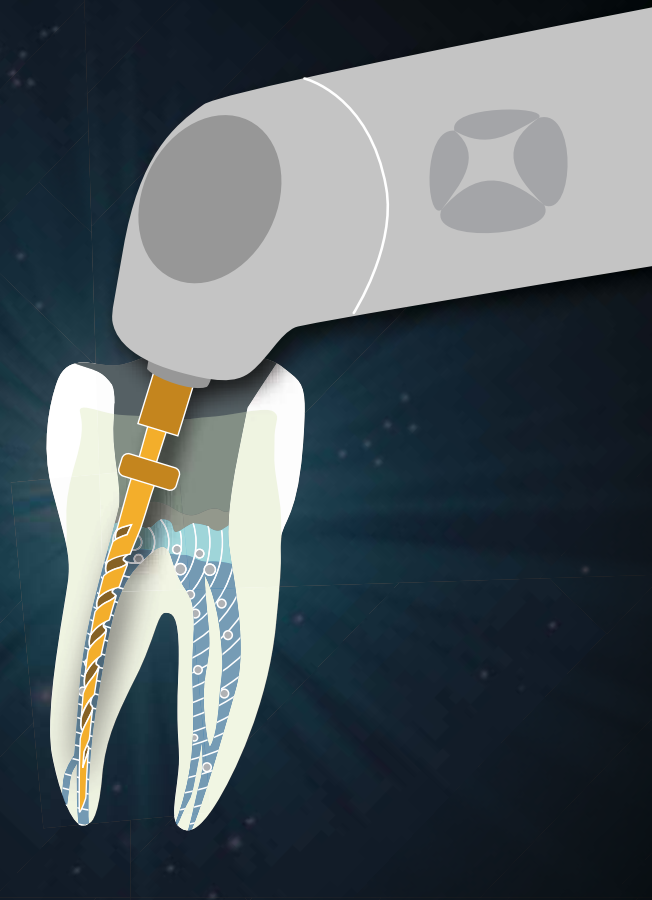LIGHT INSTRUMENTS
RISE ABOVE TECHNOLOGY

NEW!

New Endo Tip for LiteTouch™

Get the best results with the most efficient technology for cleaning and disinfecting the root canal system.

- Introducing the brand new **Endo Tip** for LiteTouch™, especially suitable for cleaning and disinfecting the root canal system during endodontic treatment and retreatment.
- The new **Endo Tip** is a flexible, hollow, side-firing conical tip, with circumferential spiral slits located throughout the length of the tip. The tip is designed to fit the shape and volume of root canals prepared by NiTi rotary instrumentation. It emits the Er:YAG laser radiation laterally, throughout all the root canal walls.
- The tip is sealed at its end, preventing the transmission of radiation through the apical foramen of the tooth.
- The new **Endo Tip's** special design allows omnidirectional (360°) laser beam delivery throughout the tip's length, rather than direct emission through a single opening at the tip end. This unique design enables more efficient cleaning, disinfection and removal of smear layer.



SEM studies of extracted teeth after using the new **Endo Tip** showed clean surfaces of the root canal walls, free of smear layer and debris.

The **Endo Tip** was developed by Prof. Adam Stabholz and Light Instruments. The SEM studies were conducted at the Hebrew University - Hadassah School of Dental Medicine in Jerusalem, by Prof. Adam Stabholz & Dr. Sharonit Sahar-Helft.

LiteTouch™, the world's most versatile non-fiber Er:YAG laser device for soft and hard tissue dental treatments.

To learn more about our innovative technologies please visit:

www.light-inst.com



Diode laser-assisted **vital pulp therapy** in pulp polyp treatment

Dr Maziar Mir, Germany; Dr Masoud Mojahedi, Germany; Dr Jan Tunér, Sweden & Dr Masoud Shabani, Iran

A pulp polyp or hyperplastic pulpitis is inflammation of the exposed dental pulp owing to an open cavitated carious lesion, tooth fracture after trauma or long-standing fractured restoration.¹ Type I hypersensitivity reactions may also have a role in pathogenesis of pulp polyps because of the higher concentration of histamine, immunoglobulin E and interleukin in primary or permanent teeth.² Removal of the polyp, pulpectomy and root canal therapy are considered for treatment of this disease.^{1,3}

Internal root resorption and a periapical lesion (apical periodontitis) can often be seen in a tooth affected by a pulp polyp. The former indicates chronic inflammation with odontoclastic activity, and the latter expresses severely inflamed pulps, for example irreversible pulpitis or an infected root canal system.^{4,5} A pulp polyp is referred to as asymptomatic irreversible pulpitis.

Recently, vital pulp therapy (VPT) has proven to be a successful treatment for molars with irreversible pulpitis associated with apical periodontitis. Based on many effective diode laser properties, diode laser-assisted VPT has shown to be a powerful method for VPT.⁶⁻⁹

This article aims to present successful results obtained by diode laser-assisted VPT in a case of pulp polyp disease, applied in permanent mandibular molars using calcium-enriched mixture (CEM) cement. One tooth also showed internal root resorption and periapical periodontitis and the other was not.

Case presentation

A 17-year-old male patient with complaints of deep caries and an exophytic mass at a right mandibular permanent molar was referred to us for treatment (Figs. 1a & b).

Medical history

The patient's medical history showed no systemic medical problems, no allergic reaction, no use of medications or recreational drugs and no history of past surgical procedures. Thus, the patient did not need to be referred for medical consultation.



Dental history

Oral and maxillofacial examination of the patient revealed no temporomandibular joint disorder or myofascial disturbances, no functional or parafunctional habits, a Class I occlusion and poor oral hygiene.

Clinical findings

In the oral examination process, the exophytic mass was found to interfere with eating and occlusion, causing intermittent pain and simultaneous bleeding.

Diagnosis

The radiographic examination showed internal root resorption at the middle third and a periapical lesion at the end of the mesial root of the first molar, as well as large dental carious lesions in the first and second right molars of the mandible (Fig. 2). The patient was thus diagnosed with a pulp polyp.

Laser-assisted VPT in the treatment of a pulp polyp

After the patient had completed the consent form, the operation area was anaesthetised through blocking of the inferior mandibular alveolar nerve with 2% lidocaine (1:80,000 adrenaline; 1.8 ml; Darou Pakhsh Pharmaceutical).

In the next step, the controlled area was defined and laser warning signs were properly placed in order to secure the operating room. The eye protection of the patient, the patient's guardian and the assistant were checked.

After reviewing the patient's information (examination sheet and radiograph, consent form, etc.), mouth rinsing was done with a 0.2% chlorhexidine oral rinse (Shahre Daru Laboratories) for about one minute.

The pulp polyp was removed with a high-power diode laser (Gigaa Laser) and the canal orifices were cleaned with a cotton pellet soaked in normal saline for five minutes, followed by low-level diode laser irradiation.

The laser parameters applied for the pulp polyp removal were as follows: wavelength of 980 nm, power of 1.2 W, fibre of 400 µ, initiated fibre, continuous wave and con-

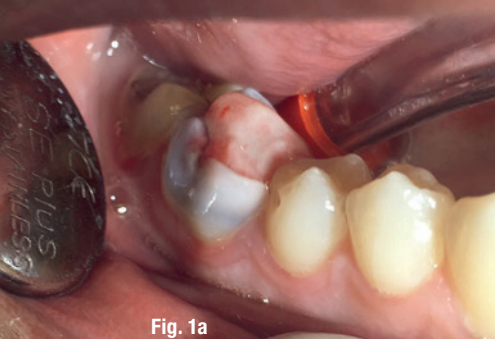

Fig. 1a

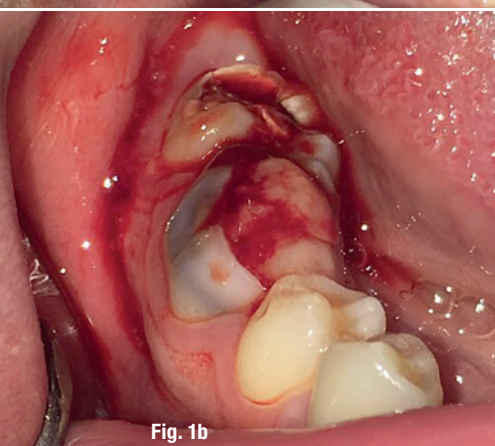


Fig. 1b

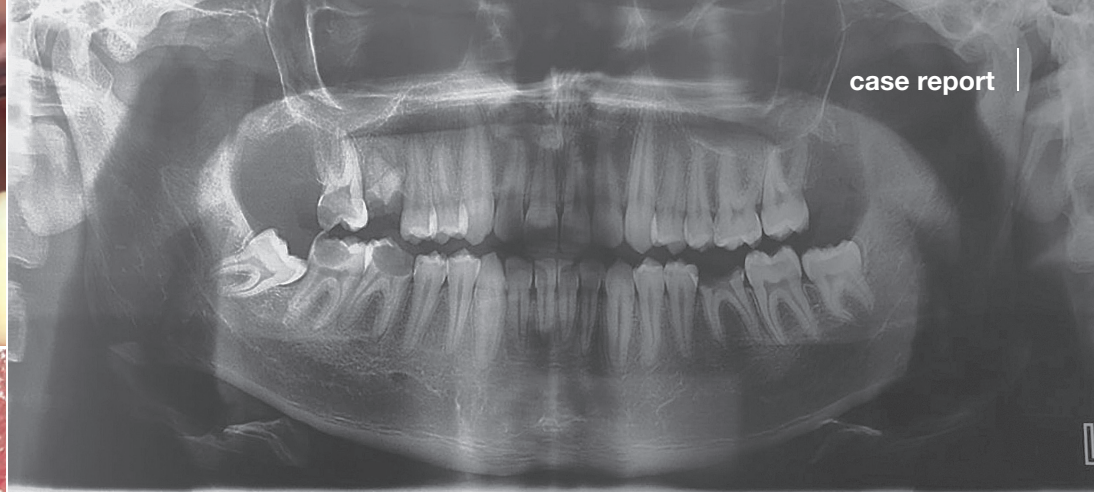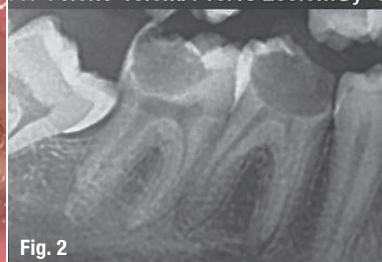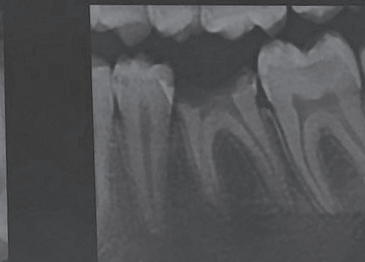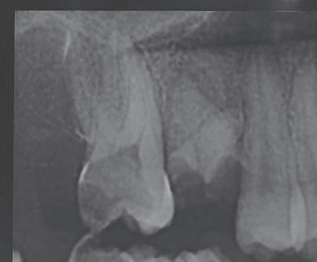/17 76.0kV 15.0mA 16.1s 265.3mGy×cm²

Fig. 2



Figs. 1a & b: Clinical appearance of the pulp polyp disease in the first and second right molars of the mandible. **Fig. 2:** Radiographic examination showing large cavities in the first and second right molars, a radiolucent lesion in the periapical area and internal root resorption of the first molar mesial root.

tact mode. After completing this procedure, Low Level Laser Therapy (LLLT) was performed (Figs. 3a & b). The laser parameters for bio-modulation intentions were the following: wavelength of 980nm, output power of 300mW, irradiation time of 10s and energy of 3J. The size of the laser aperture was 7 mm² and irradiation was performed in a rotational mode at a distance of 5 mm. The area of the canal orifice was 13 mm².

After this procedure, the CEM cement dressing was placed (Fig. 4a). The CEM cement dressing was done on a base of 2 mm of CEM cement paste (Biunique Dent) prepared according to the manufacturer's instructions using a sterile plastic instrument. A dry sterile cotton pellet was used to achieve better adaptation of the CEM cement to the cavity wall at the exposure site.

Interim restorative treatment with a glass ionomer cement (Fuji IX, GC Europe) was applied according to the manufacturer's instructions without finger pressure after CEM cement placement (Fig. 4b). We decided to place the permanent filling after one month.

Post-procedural education

The patient was advised to respect oral hygiene according to the Caries Management by Risk Assessment requirements, and the next visit was scheduled for two days after the VPT procedure.

Final result

Excellent pulp polyp removal was achieved and the VPT was carried out with no bleeding, carbonisation or char. The patient did not experience any discomfort and was satisfied with the result. Radiographic examination was performed in order to monitor the result

of the laser-assisted pulpotomy based on radiographic changes (Fig. 5).

Follow-up

The first visit after treatment was scheduled for two days after the procedure. No pain was experienced and the second LLLT was performed with the same setting, but in contact mode at the coronal part, the mid-root part and the apical part of each root of the two affected molars in order to promote the healing process. The next visit was again scheduled for two days later in order to perform the third LLLT.

Finally, at the follow-up appointment at seven months, a successful treatment outcome was observed clinically and the patient experienced no pain. The good results were also evident in the radiographic examination (Fig. 6). A successful treatment outcome could be observed, the periapical radiolucency had disappeared and the internal root resorption of the mesial root of the first molar had stopped.

Discussion

Diode lasers are used extensively in many dental practices.¹⁰ Laser-tissue interaction with a high-power diode laser is based on photothermal effects and in LLLT is not photothermal, but works based on a photochemical mechanism.^{11,12} Since LLLT is dose-dependent,¹³ the laser parameters have to be respected carefully.^{14,15} The precise molecular mechanisms for LLLT are not entirely clear, but its clinical effects on pain control, inflammation reduction and wound healing are well investigated.¹⁶⁻¹⁸ Gupta et al. reported that laser pulpotomy with high-power diode lasers showed better clinical and radiographic

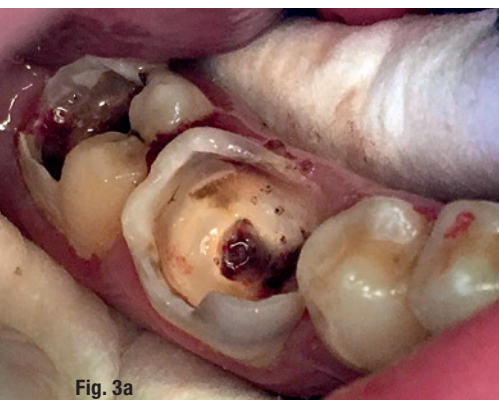

Fig. 3a

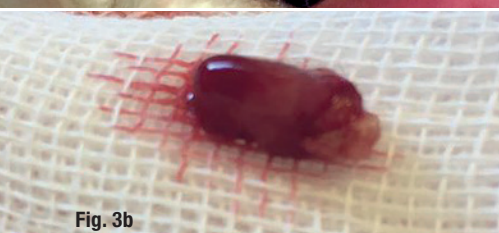


Fig. 3b

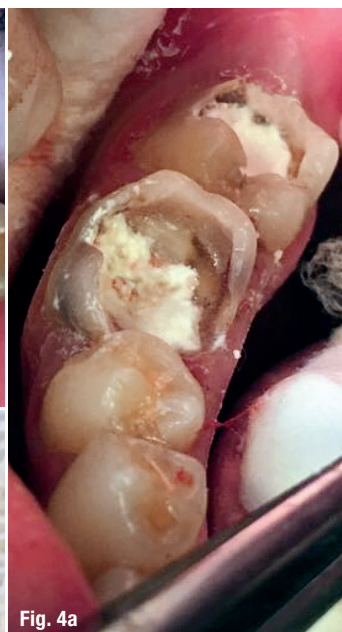

Fig. 4a

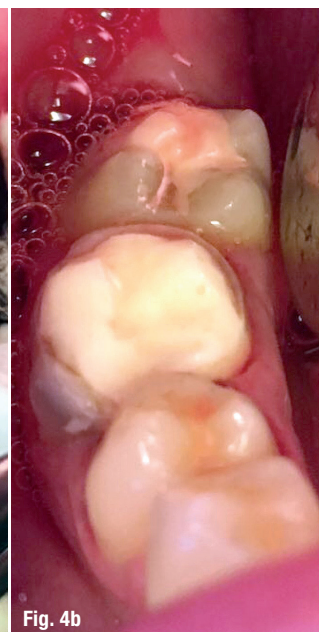


Fig. 4b

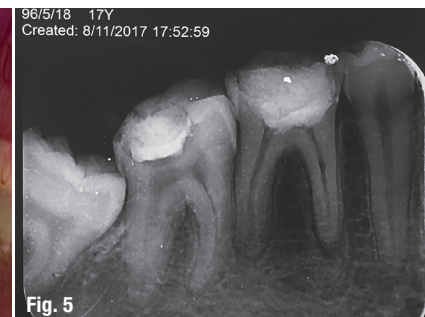


Fig. 5

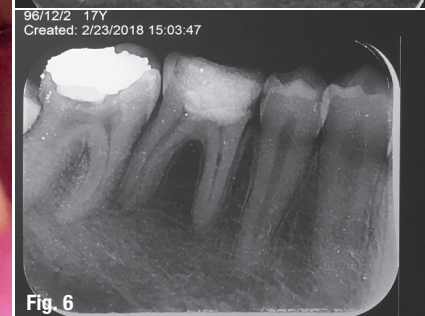

Fig. 6

Figs. 3a & b: Situation immediately after pulp polyp removal and achievement of good coagulation with the diode laser and subsequent LLLT. **Figs. 4a & b:** Situation immediately after CEM cement placement and interim restorative treatment with a glass ionomer cement. **Fig. 5:** Radiographic examination immediately after VPT of the teeth affected by the pulp polyp disease. **Fig. 6:** Radiographic examination at approximately seven months after VPT: successful situation after treatment.

results in human primary molars than did electrosurgery and ferric sulphate pulpotomy in order to achieve good coagulation.¹⁹ Uloopi et al. have applied low-level diode lasers in pulpotomy and they noted that Low Level Laser Therapy can be considered for pulpotomy in primary teeth, its success being comparable to mineral trioxide aggregate pulpotomy technique.²⁰

Conclusion

It is clear that the aim of diode laser application in pulpotomy can be very different. In this case, a high-power diode laser was applied for pulp polyp removal and good coagu-

lation, and LLLT was used to promote the healing process. Based on the laser protocol applied in this study, diode lasers can be successfully used for VPT of pulp polyps.

contact

Dr Masoud Shabani

Department of Community Dentistry
School of Dentistry
Ardabil University of Medical Sciences
Ardabil, Iran
m.shabani@arums.ac.ir

Author details



Kurz & bündig

Ein Pulpapolyp wird auch als asymptomatische irreversible Entzündung der Zahnpulpa bezeichnet. Eine derzeit als erfolgreich angesehene Behandlung von Molaren, welche von einer derartigen Pulpitis in Verbindung mit apikaler Parodontitis betroffen sind, ist die Vitale Pulpatherapie (VPT). Aufgrund der vielen fördernden Eigenschaften von Diodenlasern, hat sich der Einsatz eines entsprechenden Lasers, als besonders effektive Methode zur Vitalen Pulpatherapie erwiesen.

Die Autoren spezifizieren in ihren Ausführungen die Behandlungserfolge einer in diesem Sinne vorgenommenen laserbasierten VPT eines Pulpapolypen. Im dargestellten Fall eines 17-jährigen Patienten wurde diese Methode zur Behandlung bleibender Unterkiefermolaren mit massiven Kavitäten angewandt. Ein Zahn zeigte zudem eine interne Wurzelresorption und periapikale Parodontitis auf.

Zur Entfernung des Pulpapolypen wurde ein 980 nm-Diodenlaser genutzt und CEM-Zement platziert. Im Anschluss folgte eine mehrphasige Low-Level-Laser-Therapie (LLLT), um den Heilungsprozess zu beschleunigen. Die verwendeten Laserparameter werden detailliert wiedergegeben. Basierend auf dem im Zuge dieser Fallstudie angewandten Laserprotokoll kann der Einsatz eines Diodenlasers als erfolgreich in der VPT von Pulpapolypen bestätigt werden.



M.Sc. Lasers in Dentistry

Specialist in dental laser therapies

Next Start: **23rd September 2019** | Aachen, Germany | 4 semesters

Aachen Dental Laser Center - AALZ
Pauwelsstraße 17 | 52074 Aachen | Germany
phone +49 241 47 57 13 10 | fax +49 241 47 57 13 29
info@aalz.de
www.aalz.de

RWTH International Academy
Kackertstraße 10 | 52072 Aachen | Germany
phone +49 241 80 23543 | fax +49 241 80 92525
info@academy.rwth-aachen.de
www.academy.rwth-aachen.de



Aachen Dental Laser Center

**INTERNATIONAL
ACADEMY**

**RWTH AACHEN
UNIVERSITY**

PROFESSIONAL EDUCATION PROGRAMMES

Your contact for more information: Leon Vanweersch • vanweersch@aalz.de - www.aalz.de

Dual-wavelength laser in aesthetic and prosthetic dentistry

A minimally invasive approach

Dr Bogdan Crisan, Dr Liana Crisan, Dr Mihaela Baciut, Prof. Grigore Baciut, Dr Simion Bran, Dr Horatiu Rotar, Dr Adrian Petrutu, Dr Darius Tomina, Dr Cristina Dinu & Dr Cristian Dinu, Romania

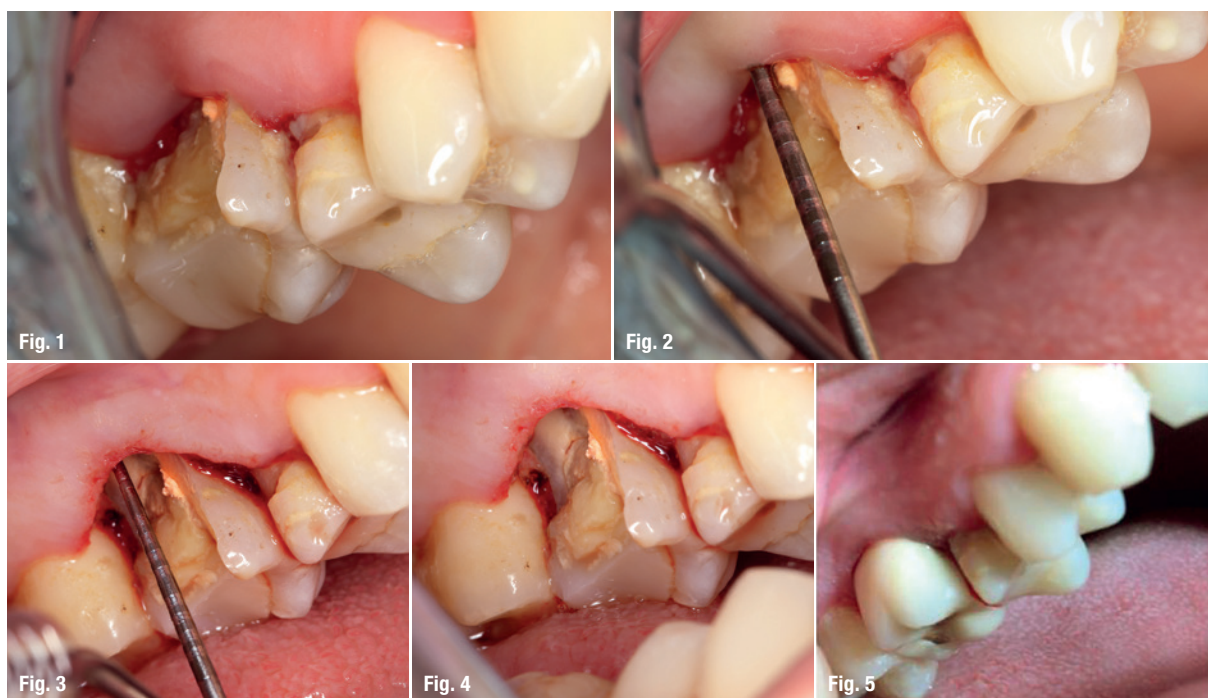
Introduction

In recent decades, lasers have been developed to be a very useful tool in everyday dental practice. Laser systems have found increasing application in more and more areas of dentistry. Aesthetic and prosthetic dentistry, in particular, are two fields of dentistry in which laser light has been found useful. Crown lengthening, removal of gingival pigmentation, tooth whitening, debonding of ceramic crowns or veneers, sulcular conditioning and minimal preparation of the tooth structure are just some of the dental procedures in which a laser can be used with success.¹⁻⁷

Minimally invasive dentistry (MID) was defined as a philosophy of professional care that is concerned with

first occurrence, the earliest possible resolution of disease at a micro level, followed by a minimally invasive treatment approach to repair irreversible damage caused by such disease.⁸ MID is a concept that was initially applied in conservative dentistry. This concept has been further developed in other areas of dentistry in recent years. MID reaches the treatment objective using the least invasive surgical approach with the removal of a minimal amount of healthy tissue.⁹ A minimally invasive approach is used today by many dental practitioners in all dental procedures.

The laser is a minimally invasive tool for the requirements of a MID approach. Today multiple laser wavelengths with different absorption in tissue can be used for maximum results with minimal side effects. Lasers



Case 1 – Fig. 1: Initial situation: hypertrophic and bleeding gingiva. **Fig. 2:** Clinical examination found a probing depth of 6 mm. **Fig. 3:** Situation after removal of the hypertrophic tissue with Er:YAG laser. **Fig. 4:** Area after Nd:YAG laser treatment. **Fig. 5:** Two months later with ceramic reconstruction *in situ*.

have been widely used in many fields of dentistry, and several wavelengths have been investigated as substitutes for a high- or low-speed handpiece, scalpel or various invasive instruments.¹⁰ The lasers of the erbium family with wavelengths in the mid-infrared region of the electromagnetic spectrum were introduced in dentistry especially for hard-tissue removal owing to their high absorption by water and hydroxyapatite molecules. The Er:YAG laser with a wavelength of 2,940nm, which corresponds to the absorption peak of water, is indicated for hard dental tissue and bone ablation. The ablative action is also due to a combination of photothermal and photoacoustic effects caused by micro-explosions of water against the target tissue.¹¹ In contrast with erbium lasers, the Nd:YAG laser with a wavelength of 1,064nm is poorly absorbed by water and selectively absorbed by haemoglobin and hyperpigmented tissue.¹² In this context, the Nd:YAG laser has been found to be valuable for treatment of benign, vascular and pre-malignant lesions of the oral mucosa.¹³

The purpose of this article is to demonstrate the usefulness of a dual-wavelength Er:YAG and Nd:YAG laser (Light-Walker, Fotona, Slovenia) in aesthetic and prosthetic dentistry, following the concept of MID in three clinical cases.

Case presentation

Case 1

A 35-year-old male patient was referred to our private clinic for surgical intervention in order to remove the hypertrophic gingiva around tooth #16 (Fig. 1). The patient's major complaint was a fracture of the buccal wall of the first molar with pain and bleeding on probing.

During clinical examination we found a 6mm depth on probing in the buccal area (Fig. 2). Therefore, we decided to perform a minimally invasive gingivectomy. The LightWalker Er:YAG (2,940nm) and Nd:YAG (1,064nm) laser system was used for this approach. For the removal of the hypertrophic gingiva, a contact handpiece for the Er:YAG laser

(H14-N) with a cylindrical tip (8.0mm in length; 1.3mm in diameter) was used. The laser parameters utilised for this case were as follows: average output power of 1.2W, pulse duration of 500µs (Long Pulse [LP] mode), pulse repetition rate of 10Hz (120mJ per pulse) and under water spray (water: 1; air: 2). The hypertrophic tissue was removed layer by layer until the fractured margins of the crown were visible (Fig. 3).

Haemostasis was established and final removal of the bleeding tissue was performed with a laser fibre (300µm in diameter) attached to the R21-C3 handpiece of the Nd:YAG laser. The laser parameters used for this procedure were as follows: average output power of 4W, pulse duration of 250µs (Short Pulse [SP] mode) and pulse repetition rate of 50Hz.

After this minimally invasive procedure, we obtained a clean and visible area, required for achieving an optimal crown reconstruction (Fig. 4). The laser procedure was performed under local anaesthesia (articaine and 1:100,000 adrenaline). The patient reported no pain at any stage of the procedure and no discomfort after laser treatment. Two months later, the patient received a prosthetic restoration with a ceramic onlay produced by CAD/CAM (Fig. 5).

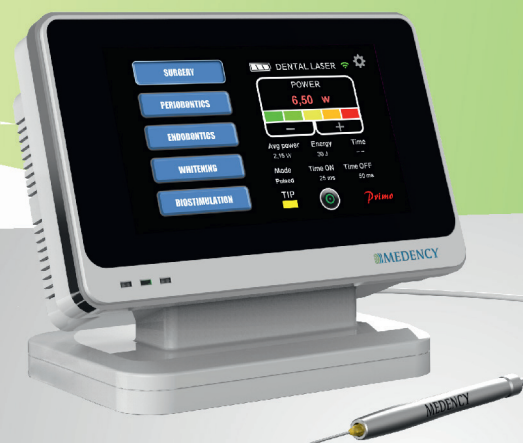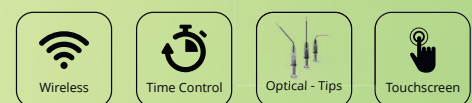Case 2

A 68-year-old female patient presented to our department because of a lesion that had developed on the left upper lip. It had grown in size lately and bothered her in terms of appearance. The patient required a minimally invasive solution to remove the lesion and to improve her appearance.

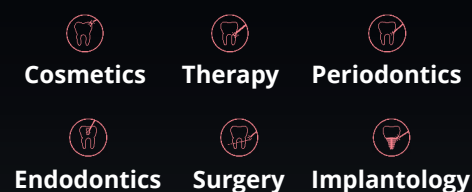A thorough medical and dental history were taken prior to the clinical examination. After the clinical and dental examination, we suspected the presence of a vascular disease, because the lesion disappeared upon digital pressure and the colour was red-blue (Fig. 6). We recommended a colour Doppler ultrasonographic examination to confirm the diagnosis. The examination revealed a vascular lesion localised under the oral

EXCEED YOUR EXPECTATIONS

The most innovative Dental Laser technology for your practice



PRIMO



One-touch TECHNOLOGY +35 pre-set TREATMENT 5-Top FAVORITES

Stress-free software, fully automatic parameter selection offers the ideal way to boost productivity. Versatile, fast and accurate selection of protocols from a large variety of programs. Every functional aspect of Primo has been developed with end users in mind. Most useful programs at your finger touch.

Active Time ASSIST Multi-function HANDPIECES Master-mode FOR EXPERTS

Designed to help users to improve patient's care by stopping the laser output to potentially avoid tissue overheating. The ergonomic lightweight handpiece gives the user a total control of movements. Wide selection of optical tips, whitening arch biostimulation and cosmetic tools. Advanced software-enabled mode allows experienced users to achieve outstanding performance and to generate new protocols.



medency.com



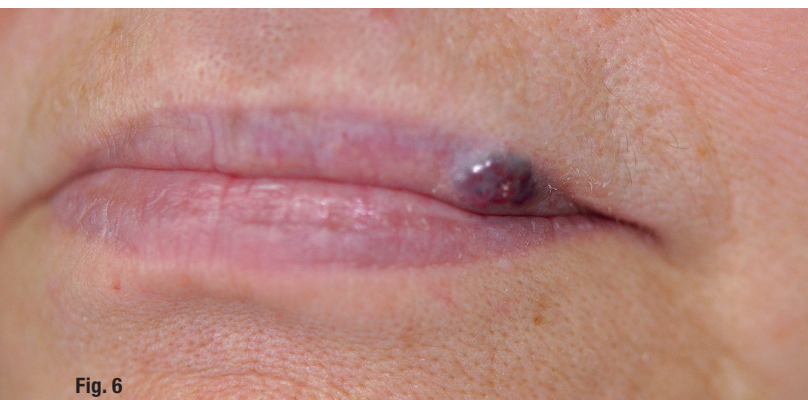

Fig. 6

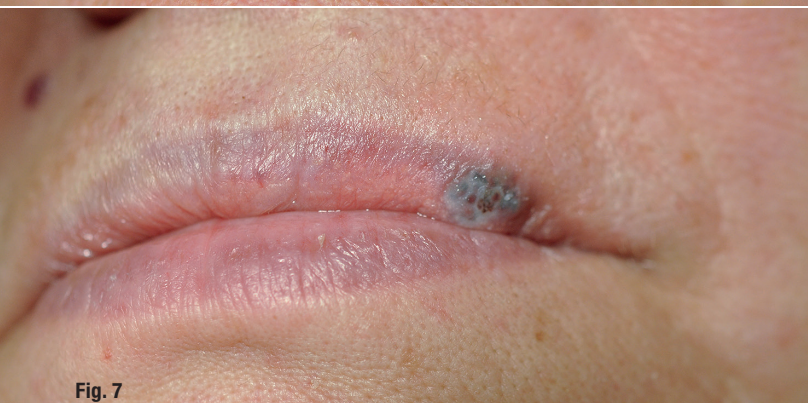

Fig. 7

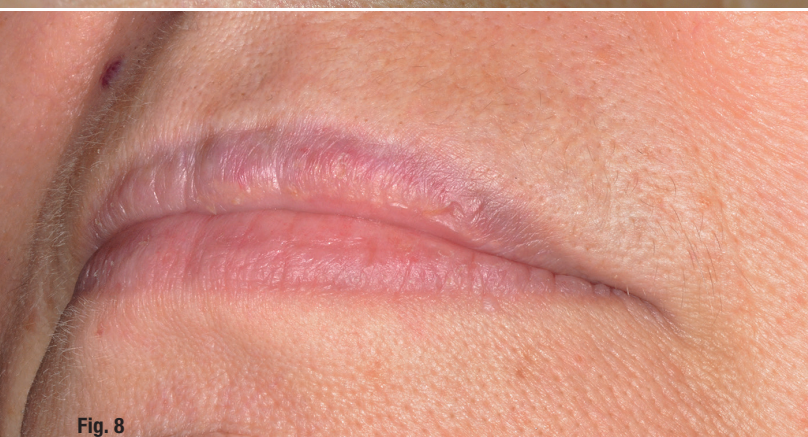

Fig. 8

Case 2 – Fig. 6: Clinical view of the venous malformation. **Fig. 7:** After Nd:YAG laser treatment. **Fig. 8:** Situation at the six-week follow-up.

mucosa with a venous vascular signal (a venous malformation).

Photocoagulation with a laser wavelength that has good absorption in haemoglobin was performed under local anaesthesia (articaine and 1:100,000 adrenaline), using the Nd:YAG laser (1,064 nm, LightWalker) in a non-contact mode, through a glass plate and under continuous cooling with ice cubes. For the procedure, the R21-C3 handpiece and a laser fibre (300µm in diameter) were used. The laser parameters in this case were as follows: average output power of 5W, pulse duration of 250µs (SP mode) and pulse repetition rate of 100Hz.

Immediately after laser therapy, we obtained bleaching by sclerosis and a decrease of the vascular lesion (Fig. 7). Postoperatively, we recommended anti-inflammatory treatment with ibuprofen (400 mg b.d.) and the local application of Cicaderm cream (Ivatherm). The patient reported no pain after the laser procedure, only a reduced oedema for two to three days.

At the follow-up appointment six weeks later, very good healing of the treated area without any recurrence or revascularisation and a good aesthetic result were evident (Fig. 8).

Case 3

A 36-year-old female patient presented to the private practice with an aesthetic complaint. The patient was unhappy with the shape and colour of the porcelain veneers on her maxillary anterior teeth and with the level and appearance of the gingiva (Fig. 9). The patient required a minimally invasive solution to improve her smile.

The laser-assisted removal of veneers is a fast and minimally invasive method. For debonding the porcelain veneers, an Er:YAG laser (2,940nm, LightWalker) with a non-contact handpiece (H02-N) was used. The laser parameters for this procedure were as follows: average output power of 6W, pulse duration of 100µs (Micro Short Pulse [MSP] mode), pulse repetition rate of 30Hz (200mJ per pulse) and under water spray (water: 3; air: 3). The veneers (IPS e.max lithium disilicate, Ivoclar Vivadent) were removed one by one without any fracturing, because only the bonding adhesive absorbed the laser irradiation (Fig. 11). The laser treatment was performed without local anaesthetic. The patient reported no sensitivity at any stage of the procedure.

Immediately after the procedure for removal of the porcelain veneers, the patient received temporary composite veneers. Two weeks later, we realised a recontouring of the gingiva around these provisional veneers (Fig. 12). For aesthetic gingival recontouring, a dual-wavelength laser (Er:YAG/Nd:YAG, LightWalker) was used. The Er:YAG laser parameters for reshaping the gingiva were as follows: average output power of 1.2W, pulse duration of 500µs (LP mode), pulse repetition rate of 10Hz (120mJ per pulse) and under water spray (water: 1; air: 2). A contact handpiece (H14-N) for the Er:YAG laser with a conical tip (16.0mm in length; 0.6mm end diameter) was used.

The finishing of the shape was performed and haemostasis was established with a laser fibre (300µm in diameter) attached to the R21-C3 handpiece of the Nd:YAG laser. The laser parameters used for this procedure were as follows: average output power of 3.5W, pulse duration of 250µs (SP mode) and pulse repetition

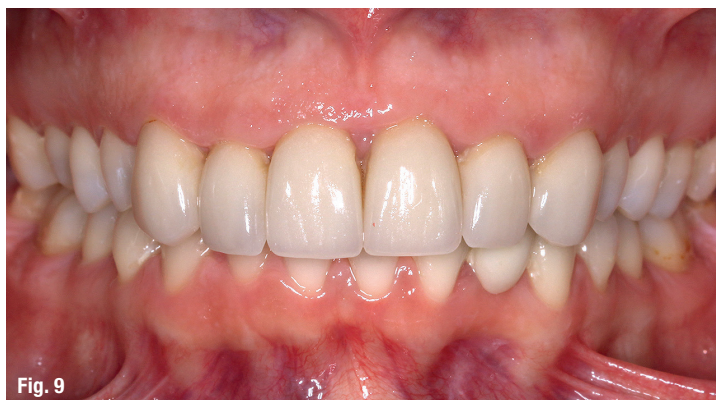

Fig. 9

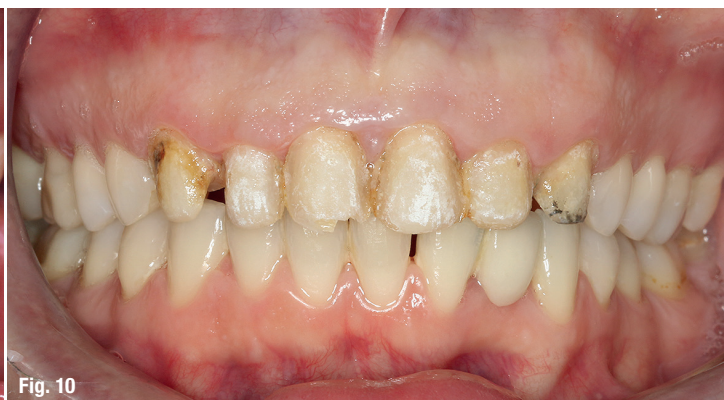

Fig. 10

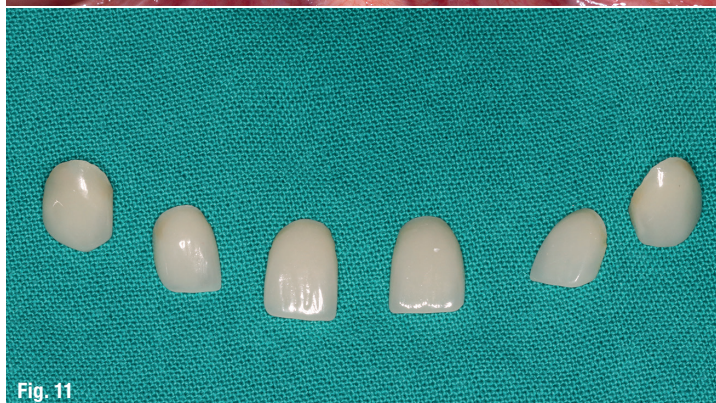

Fig. 11

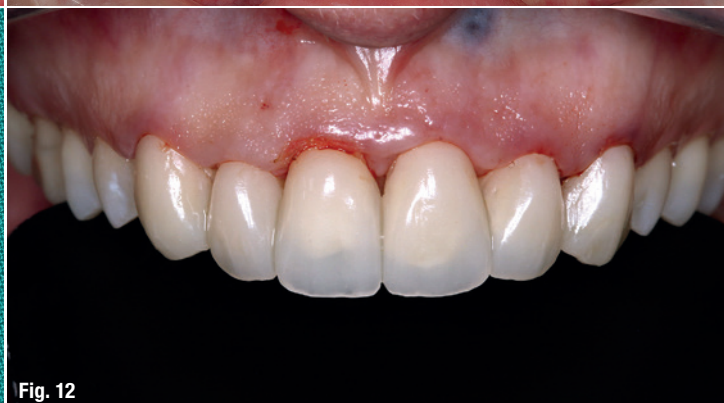

Fig. 12

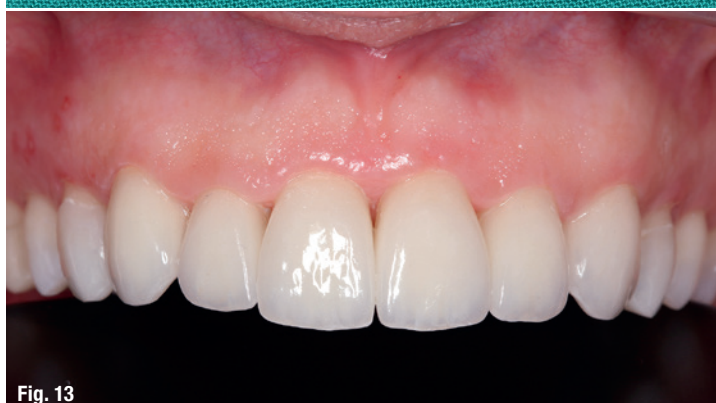

Fig. 13

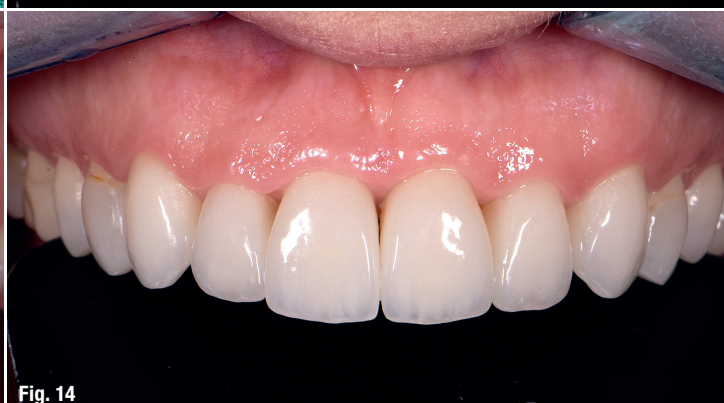

Fig. 14

Case 3 – Fig. 9: Initial situation: shape and colour of the veneers and level of the gingiva. **Fig. 10:** Clinical view immediately after removal of the veneers. **Fig. 11:** Ceramic veneers removed. **Fig. 12:** Immediately after gingival recontouring. **Fig. 13:** Final restoration with ceramic veneers. **Fig. 14:** Situation at the two-year follow-up.

rate of 40Hz. Four weeks after gingival healing, the final restoration was achieved with IPS e.max lithium disilicate veneers (Fig. 13).

At the follow-up appointment two years later, the patient was still satisfied with the aesthetic appearance achieved (Fig. 14).

Discussion

In the development of MID, it is important to use innovative materials, new and improved clinical techniques, and the latest equipment and systems in order to preserve the natural tissue. Using a creative and minimally

invasive approach to dentistry helps us provide our patients with new levels of excellence in care.¹⁴

Low- and high-power lasers have been adopted as useful tools in minimally invasive dentistry owing to their clinical benefits. Successful aesthetic treatments involve not only restorative procedures, but also the presence of healthy surrounding tissue.¹⁵ Lasers are now widely used for minimally invasive treatment in routine clinical procedures. The dual-wavelength laser can be used in various aesthetic and prosthetic procedures, as has been described in the clinical cases presented in this article. Er:YAG and Nd:YAG lasers have become more popular owing to their dual hard- and soft-tissue applications.

In the first case, the removal of the hypertrophic gingiva would conventionally have been performed with a scalpel or a round diamond bur, resulting in a bleeding surface and additional patient discomfort. In contrast, the use of a dual laser for this procedure resulted in a bloodless environment that healed quickly and uneventfully, while facilitating subsequent restorative procedures. Additionally, lasers offer superior control of the gingival sculpting process and should be part of aesthetic crown lengthening.¹


According to the literature, laser therapy for treatment of vascular anomalies has improved significantly over the last three decades to treat haemangiomas, capillary malformations and venous malformations of the head and neck.¹⁶ In the second case, the Nd:YAG laser was effective in treating the mucosal venous malformation. Laser therapy, sclerotherapy, surgical excision, or a combination of these treatment modalities may be necessary for disease control. In our case, laser photocoagulation was the optimal minimally invasive treatment, achieving a good result in a short period.

The results of Oztoprak et al. showed that the Er:YAG laser is effective in reducing the shear bond strengths of porcelain laminate veneers from very high values to a level that allows their easy removal from the teeth.¹⁷ Er:YAG lasers are clinically indicated for the removal of composite fillings. Laser absorption occurs in the organic components of the resin. The ablative mechanism involved is an explosive vaporisation followed by a hydrodynamic ejection. The Er:YAG laser can thus successfully be used to efficiently debond all-ceramic full-contour crowns from natural teeth.⁴ In our last clinical case, the dual-wavelength laser successfully demonstrated this efficacy in debonding all-ceramic veneers with a minimal effect on the healthy tissue.

Conclusion

As a conclusion to our clinical case presentations, it can be said that the dual-wavelength laser (Er:YAG laser and Nd:YAG laser) represents a very useful tool in aesthetic and prosthetic treatment in accordance with the concepts of minimally invasive dentistry.

Literature




contact

Dr Bogdan Crisan

Iuliu Hatieganu University of Medicine and Pharmacy Cluj-Napoca
Department of Implantology and Maxillofacial Surgery
Cardinal Iuliu Hossu St. No. 37
400029 Cluj-Napoca, Romania

Med Artis Dent Private Clinic
Strada Voltaire 16
400130 Cluj-Napoca, Romania
bbcrisan@yahoo.com
www.medartisdent.ro

Author details



Kurz & bündig

Laser haben sich besonders in der ästhetischen und prothetischen Zahnheilkunde als effektives Instrument erwiesen und werden in diesen Bereichen speziell im Sinne der minimalinvasiven Zahnmedizin (MID: minimally invasive dentistry) bevorzugt eingesetzt. Ziel des minimalinvasiven Ansatzes ist es dabei, maximale Resultate bei minimalen Nebeneffekten zu erreichen.

Anhand von drei Fallbeispielen stellen die Autoren den Einsatz der Dual-Wellenlängen-Methode mit dem LightWalker von Fotona als Alternative zu invasiven Instrumenten vor. So konnte zum Beispiel im ersten Fall die hypertrophe Gingiva mit dem dualen Laser blutungs-frei entfernt und somit eine schnelle Heilung erreicht werden. In der Folge wurden dadurch auch die restaurativen Prozesse erleichtert. Im dritten Fall konnten die Autoren zudem die Effizienz des Einsatzes des Dual-Wellenlängen-Lasers im schonenden Entfernen von Keramikveneers mit minimalen Auswirkungen auf das umliegende gesunde Gewebe nachweisen. Die einzelnen Behandlungsstufen und genutzten Laserparameter werden für jeden der drei Fälle spezifiziert.

Die kombinierte Anwendung der Er:YAG- und Nd:YAG-Laser in Form des LightWalker erwies sich in den drei dargestellten Fallbeispielen als erfolgreich und wird von den Autoren daher als effektive Methode für den Einsatz in der minimalinvasiven Zahnmedizin speziell in der Behandlung von ästhetischen und prothetischen Fällen empfohlen.

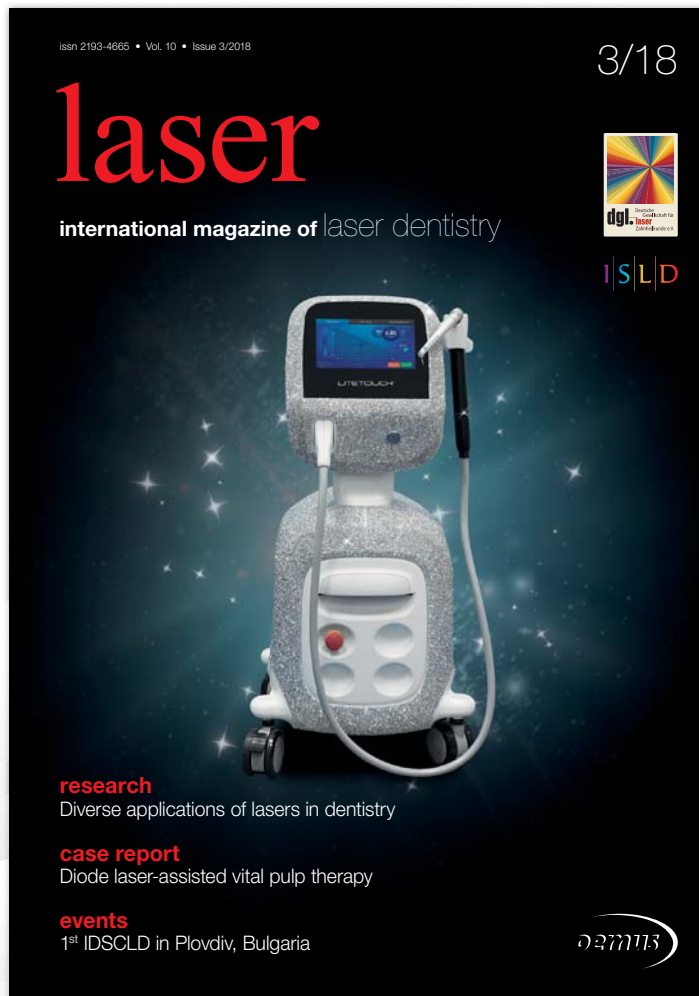
BECOME AN AUTHOR

for laser—international magazine of laser dentistry

Interdisciplinary and close to the market



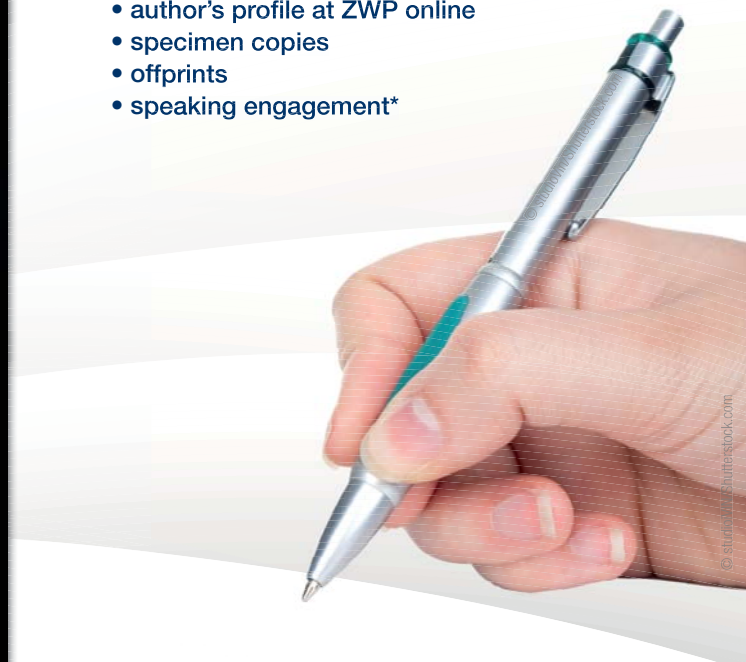www.oemus.com



Become part of a successful network and benefit from a wide reach and high level of awareness

Your benefits:

- author's profile at ZWP online
- specimen copies
- offprints
- speaking engagement*



*according to the required profile

Fax to **+49 341 48474-290**

☐ Yes, I want to become an **author** for laser—international magazine of laser dentistry. I would like to submit an article on the following topic:

Please send back your fax form
or contact Mr. **Georg Isbaner**:
g.isbaner@oemus-media.de · Phone: +49 341 48474-123

Last Name, First Name

Street/ZIP/City

Phone/E-Mail

Stamp

laser 3/18



© Billion Photos/Shutterstock.com

Six Sigma in the management of laser-assisted dental practices

Part II: Business restructuring

Dr Imneet Madan, UAE

Laser-assisted dentistry is an expensive practice not only for the provider but also for the patient. It thus makes sense to take the necessary steps to modify this practice for the mutual benefit of all.

Six Sigma is a quality assurance strategy that helps reconstitute the existing business in a way that the final turnover improves not only in terms of finances but also in terms of the business model. Its main principles were presented in detail in the first part of the article published in *laser* 2/18, where it was discussed that commitment to true process improvement is one of the most important steps for advancing the practice according to Six Sigma.

Reconstituting the business involves several internal changes and works around the existing model and the team. The idea is to reinvent the current performers and their performances.

Six Sigma initiatives

In order to achieve such reinventions, the Six Sigma initiatives detailed in this section can be implemented.

Restructuring the front desk

The front desk is the doorway to the practice; its strength determines the strength and outcomes of the practice to a great extent. Six Sigma greatly acknowl-

edges this fact. It is thus important for the practice to have well-trained front desk staff. Complete information on laser practice should be made available to the front desk team members. They should be able to offer the alternative laser treatment whenever a patient enquires. Staff must use clinical terms in the simplest manner so that the patient will be able to understand. This training is best provided by the laser dentist himself or herself.

The hours when the dentist is not occupied with the patient can be utilised for staff training and shadowing so that the staff can actually see the laser in action and will thus be able to relate this to what they have learnt when speaking with patients on the phone.

Training can include the answers to some of the more common questions that might be posed by clients:

- How are laser fillings done?
- What is a laser?
- How is it better than conventional treatment?
- Is it worth paying the extra cost?
- Will my child be at ease?
- Is there any time difference between a laser and a normal appointment for fillings?
- Will the laser damage any surrounding teeth?
- Is laser treatment safe for young children?
- Will the insurance cover the procedure?
- How can the practice help to get the procedure covered?

If the front desk is able to respond to such questions adequately when proposing the option of laser treatment, this improves the likelihood that the patient will agree to the treatment. In order to add to the patient's further understanding, it is also an option to arrange a free pre-procedural appointment to discuss the queries at length. Especially in the case of paediatric patients such informative appointments with only the parents are recommended.

Utilising auxiliary staff during free hours

In order to use the existing assets of the practice more effectively, the assistant and sterilisation staff can be assigned duties apart from their routine tasks. These duties could include the following:

1. Checking missed appointments, listing them, informing the front desk, who can then make routine timely calls to these patients and try to rebook them, and making sure that these patients are called at least three times before sending the final SMS reminder;
2. recalls or periodic check-up appointment reminders can be automatically

generated or given through manually via phone calls or by SMS;

3. updating the practice in terms of improving the information that is given to the patient, preparing the literature to be given out, and preparing optimal standard of teaching models and videos for patients.

Continuing education for the dentist and the auxiliary staff

Train the trainer programmes are the idea of the moment. Further the laser dentist should conduct occasional training for other dental professionals and for the assisting staff.

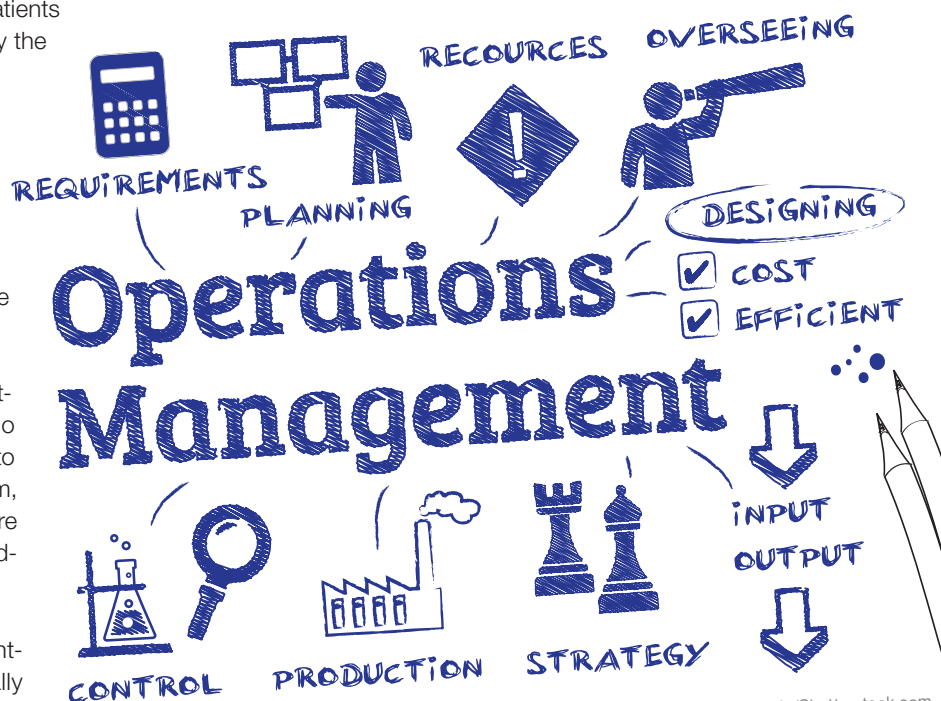Training the assisting staff regarding the machine, its functioning and its maintenance can spare the practice long-term expenses that may otherwise be incurred if problems were not diagnosed in time. These courses are generally offered by the laser companies periodically and can be pre-checked and registered for.

Utilising technical assistance in the practice

The information technology department can be utilised along with the media department to create videos of lasers during treatment and these can then be used for social media promotion. People's understanding of lasers is better when they have seen them in action.

Involving the financial department

Whatever is monitored or measured is what is improved. Feedback from the financial department on the cost of the investment in laser and the return on the same allows the practice to better plan for the future. It is important to establish on a regular basis



© Trueffelpix/Shutterstock.com

SUCCESS



© Pikul Noorod/Shutterstock.com

the cost of the upkeep of the laser, the actual cost of investment, the break-even period and/or the percentage of profits expected.

Feedback from the financial department can be the underlying foundation that helps the practice foresee the possible returns on the laser investment.

Conclusion

In precise terms, reinventing/restructuring the existing assets in the practice can itself produce a manifold outcome. The target of successful practice management is to see the maximum outcomes, but this does not always have to be based on more input.

The Six Sigma implementation steps follow the DMAIC model: define, measure, analyse, improve and control (as described in *laser 2/18*). Restructuring the existing system by giving standardised protocols of functioning to each level is the core structure build-up of Six Sigma-based dental practice. Once the systems have been established in relation to performance, there needs to be continual monitoring; otherwise, the whole system can crash and revert to the beginning.

These relapses can be avoided if there is an assigned member of the team at each level to monitor and report

to the person concerned. Creating hierarchy was once obsolete, but according to Six Sigma, the flow of activities can best be monitored when there are checks by the right people at all levels.

The final step towards optimised practice management is maintaining the established model of performance at all levels, documenting the success achieved and striving for further progress during the next control stage.

contact

Dr Imneet Madan

Laser Pediatric Dentist
NLP Coach
Six Sigma Green Belt
MDS (Pediatric Dentistry)
MSc (Laser Dentistry, AALZ, RWTH Aachen University)
Children's Dental Center, Dubai
Villa 1020 Al Wasl Road
Umm Suqeim 1, Dubai
United Arab Emirates
Tel.: +971 506823462
imneet.madan@yahoo.com
www.drmmichaels.com

Author details



Kurz & bündig

Im ersten Teil des Artikels erläuterte die Autorin bereits detailliert, die Bedeutung des Six Sigma als Managementsystem zur kontinuierlichen Prozessverbesserung und Qualitätssteigerung. Die wichtigsten Prinzipien zur Implementierung in der zahnärztlichen Praxis, insbesondere mit Fokus auf Laserbehandlungen wurden bereits in der *laser 2/18* vorgestellt. Im zweiten Teil präsentiert Dr. Imneet Madan die fünf wichtigsten Schritte, um die angestrebte Prozessverbesserung bestmöglich umzusetzen und unterstreicht welche Teamkomponenten dabei von besonderer Bedeutung sind. Aufgrund der relativ hohen Kosten, welche mit Laserbehandlungen sowohl für den Zahnarzt als auch für den Patienten verbunden sind, sollte eine Prozessoptimierung auf allen Ebenen angestrebt werden.


Beim Six Sigma steht das Team stets im Vordergrund. Die Idee ist es, die vorhandenen Bedingungen zu optimieren, d. h. die gegenwärtigen Mitarbeiter und deren Leistungen effektiver zu nutzen und Potenziale gezielter auszuschöpfen. Bedeutend ist es zudem, eine Six Sigma-Hierarchie zu implementieren, um eine regelmäßige Prüfung, Dokumentierung der erzielten Erfolge und eine beständige Optimierung aller Prozesse auf allen Ebenen zu garantieren.

SUBSCRIBE NOW!

ceramic implants—international magazine of ceramic implant technology

Interdisciplinary, transparent & market orientated

ONLINE
SUBSCRIPTION HERE



www.oemus-shop.de



stay updated:

research
**Guided regeneration
of lamellar bone tissue**

case report
**Immediate placement
in the aesthetic zone**

interview
**Clear trend towards
metal-free reconstructions**

Fax: **+49 341 48474-290**

I would like to subscribe for the following journals:

- ☐ ceramic implants—international magazine of
ceramic implant technology 2 issues p.a. € 30*
- ☐ implants—international magazine of oral implantology 4 issues p.a. € 44*

Terms & Conditions: The subscription may be cancelled in written form without due justification within 14 days of order by contacting OEMUS MEDIA AG, Holbeinstraße 29, 04229 Leipzig, Germany. Dispatching notification in good time will suffice. The subscription is automatically extended by another twelve months if it is not cancelled in written form 6 weeks prior to the end of the reference period.

* All prices include VAT, shipping and handling.

Last Name/First Name

Company

Street

ZIP/City/Country

E-Mail

Signature

Credit Card Number

Expiration Date

Security Code

OEMUS MEDIA AG

Holbeinstraße 29 · 04229 Leipzig · Germany · Phone: +49 341 48474-200 · d.duetsch@oemus-media.de

Successful communication in your daily practice

Part VII: Special services for VIP patients

Dr Anna Maria Yiannikos, Germany & Cyprus



© Ollyy/Shutterstock.com

Hi! I am Dr Anna Maria Yiannikos and I am very happy to share the 7th part of this loved series filled with communication protocols with you. This series includes the most popular and challenging scenarios that might occur in your dental practice and presents successful ways of how to deal with them—so your patients will always leave your practice feeling satisfied and thinking: “My dentist is THE BEST!”

Each article of this series will teach you a new, easy to use specialised protocol, which can easily be customised and adapted to your own dental clinic’s requirements and needs right from day one.

Let’s start with today’s challenging topic which is... how to offer VIP services to your distinguished patients. Imagine, that the atmosphere in your clinic is unique, ideal for VIP patients. You probably already know this, but these patients are less affected by the recession.

Might this fact somehow relate to you? Of course, it does. These are the patients who will have a full-mouth reconstruction done without second thoughts. These patients are also the ones who will pay you without a hassle. Thus, your desire should be to attract this group of patients. Is there anything you can do in order to encourage them to choose you? Yes, there is!

5 revolutionary tips

I am going to share five revolutionary tips with you that guarantee this wonderful outcome. Are you ready to attract your VIP patients?

1. Have a special website section

Create a special VIP section on your website providing all information exclusively for their superior needs. Here you can describe in detail why your clinic is the one they should come to and why it absolutely has to be their first

choice. Offer them extra incentives like a limousine service and remember, they already expect such amenities.

2. Create a VIP environment

Adapt your clinic's environment according to their wishes and expectations. You can, for example, have a private entrance only for them, since they hate others gossiping about them.

3. Offer first class amenities

Treat your VIP patients as if they were on a first-class flight. Offer them warm towels before and after the treatment, or a special dental kit (with toothbrush and toothpaste), that has your logo and their name on it. Thus, equipping them with the perfect accessory to use after a quick brunch. Keep in mind that this group of people sometimes does not even have the time to eat.

4. Pay full attention

Assign one of your staff members to be at the individual service of your VIP patients during their entire visit to your practice. Accompany them from the time they arrive at your clinic until the time they leave. They expect your and your staff's full attention, without disturbance—at all times.

5. Avoid delays

For your VIP patients, time is money. Therefore, they hate waiting. So, offer them a quick and excellent experience.

Are you ready?

It really is this easy. Plus, you will gain the reputation of being a VIP dentist. Are you wondering, why that should be so vital? The reason is that people love to be associated with distinguished professionals. If you think about it, this is exactly the same situation as with upscale brands, like

Gucci or Prada. People love buying such brands since their high status is easily recognised! And that is why your clinic will in the end be full of patients who love to be associated with your name! That would be just perfect, wouldn't it?

This is very useful insight, don't you think? I am sure that you are looking forward to the next issue of laser magazine, where I will present the eighth part of this unique series of communication concepts to you. Are you wondering what will be the next beautiful and interesting topic? We will take a look at how to transform a fearful patient into a loyal one. You will certainly agree with me, that this is a regular situation that we all face in our clinics and I will thus teach you 5 essential ways to tackle it.

Until then, remember that you are not only the dentist of your clinic, but also its manager and leader. For further questions and requests for more information and guidance, keep in touch by sending me an e-mail to dba@yiannikosdental.com or via our website www.dbamastership.com. I am looking forward to our next trip of business growth and educational development!



Author details



Dr Anna Maria Yiannikos

Adjunct Faculty Member of AALZ
at RWTH Aachen
University Campus, Germany
DDS, LSO, MSc, MBA
dba@yiannikosdental.com
www.dbamastership.com

contact

Kurz & bündig

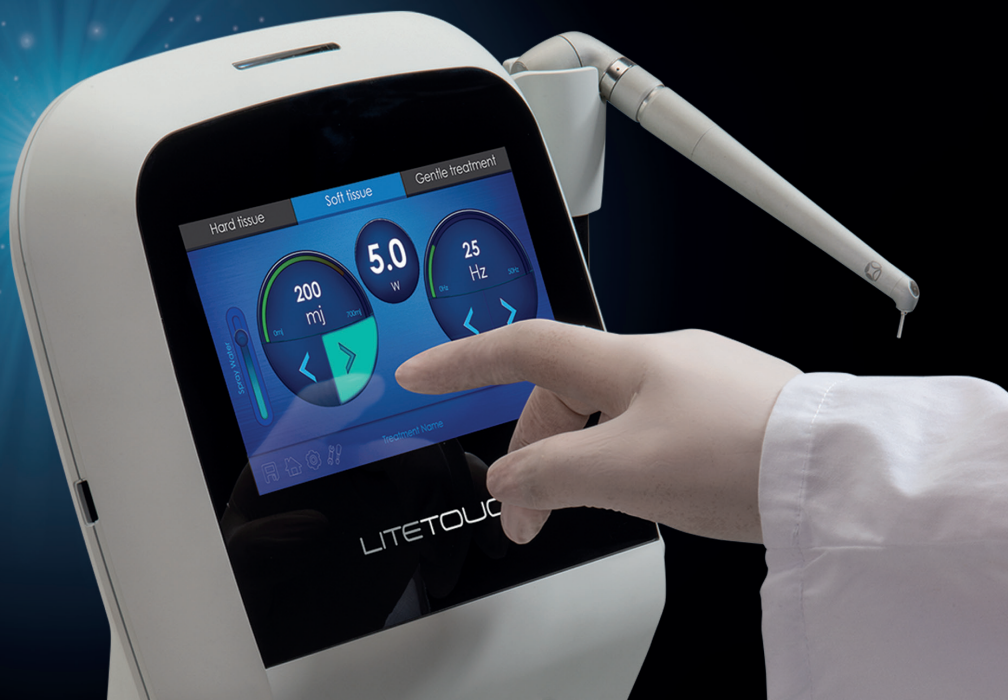Im siebten Teil ihrer Serie „Erfolgreiche Kommunikation im Praxisalltag“ stellt Dr. Anna Maria Yiannikos fünf Tipps vor, um VIP-Patienten für die eigene Praxis zu gewinnen. Ziel ist es, diese mit einzigartigen Services zu binden, auf deren besondere Ansprüche einzugehen und somit auch die eigene Reputation zu steigern.

Als ersten Tipp empfiehlt die Autorin, das Einrichten eines Extrabereichs der Praxiswebsite speziell für VIP-Patienten und deren Bedürfnisse sowie besondere Dienstleistungsangebote wie zum Beispiel Limousinen-Service. Des Weiteren lohnt es sich, eine VIP-Praxisatmosphäre zu schaffen und herausragende Annehmlichkeiten, wie warme Handtücher zu offerieren, sodass sich die VIP-Patienten wie auf einem Flug erster Klasse fühlen. Im vierten Tipp unterstreicht Dr. Yiannikos, wie wichtig es ist, diesem Patiententyp für die gesamte Zeit des Praxisbesuchs einen speziellen Begleiter zur Seite zu stellen und ihm somit von Ankunft bis Abschied vollste Aufmerksamkeit zu schenken. Last, but not least sollte es besonders bei derart wichtigen Patienten niemals zu Verspätungen kommen.

Letztendlich profitiert besonders der eigene Ruf von dem geschaffenen Image, ein VIP-Zahnarzt zu sein. Die Patientenzahlen können somit deutlich gesteigert und Einkünfte auch in rezessiven Zeiten gesichert werden.



LIGHT INSTRUMENTS
RISE ABOVE TECHNOLOGY



Launching a novel cutting-edge dental laser line

During the upcoming International Dental Show (IDS) in Cologne, Germany, taking place from 12 to 16 March 2019, Light Instruments, inventor of LiteTouch™ and the Laser-in-Handpiece technology, will present a new line of dental lasers.

In a recent interview with laser, Eric Ben-Mayor, the CEO of Light Instruments and Prof. Roly Kornblit, Light Instruments' Scientific Advisor, talked about the company, technological innovations, scientific developments and the new dental laser line just added to the company portfolio.

Mr Ben-Mayor, what developments have you experienced at Light Instruments in the past two years?

Since 2016, many changes have occurred, both within our organisation and in the world of the dental laser market. We first experienced this change at the IDS in 2017, where we could feel the curiosity and the acknowledgement of the dental community towards dental lasers. At the IDS we also officially launched our new and impressive LiteTouch™ 3 model which, without a doubt, has changed the face of all-tissue dental lasers as we know it. We have been working tirelessly, and with our newly opened Latin American market following the ANVISA approval of the Brazilian Health Regulatory Agency for the LiteTouch™ and the entry into this huge

and growing LATAM market, we have driven the brand further than before.

Today, as the front-runners of the dental laser market, I am excited to announce that we are expanding our variety of high-end dental lasers. In addition to the D-Touch which is our newly developed diode laser, we have added the Dentaray brand to our portfolio and it is an unmatched CO₂ laser, the first and only 9.6µm wavelength.

Why did Light Instruments decide to partner with Dentaray? And what are the main advantages of the new 9.6µm CO₂ laser?

Dentaray is an Israeli brand avant-garde start-up. Its addition to our portfolio was another step within a sequence of collaborations with high technology manufacturers and innovative companies that the group intends to partner with, while affirming our position as a global leader.

Dentaray is the first and only 9.6µm CO₂ dental laser. This widely researched wavelength is applicable in hard and soft tissue, and allows unique clinical applications, thus positioning the Dentaray as to become a premium laser device.

The Dentaray has been designed as an eye-catcher within the clinic. Its sophisticated design combined with its unique capabilities will certainly make it a must-have

for every dental clinic that wants to become a major player in the dental laser world—with a bit of chic.

What are the highlights of the new D-Touch diode laser?

Our new D-Touch diode laser is a 980nm. This wavelength is well absorbed by pigments and provides additional range of possibilities for soft-tissue procedures. Diodes today are a common tool in almost all advanced dental clinics. Our D-Touch laser will provide all dentists with an easy access to the advanced world of laser dentistry. We have decided to provide our customers with the same ease and comfort of a diode laser, as we did with our Erbium:YAG laser. I am sure that anyone who will use our D-Touch will quickly understand the difference.

Prof. Kornblit, what can you tell us about the latest scientific developments of the company?

Over the recent years, Light Instruments has invested much effort and resources in the development of new applications perfecting the existing protocols and most importantly, training dentists around the world—spreading the gained knowledge about the LiteTouch™ Er:YAG laser's large diversity of dental and maxillofacial surgery applications.

“We have added the Dentaray brand to our portfolio and it is an unmatched CO₂ laser, the first and only 9.6 μm wavelength.”

Many of Light Instruments' researches are conducted in collaboration with universities, based on multicentre academic consultations and users' clinical evaluation processes. To name just a few: In paediatric dentistry for example, the pre-eruptive intra-coronal resorption (PEIR), a defect located in the dentine of an unerupted tooth can today be resolved following a simple clinical protocol using LiteTouch™ that we developed together with the Paediatric Department of Hadassah Jerusalem University. In restorative dentistry, we developed a special protocol for the debonding of veneers without damaging the tooth structure or the porcelain veneer, allowing the reuse of the veneer.

Further, peri-implant diseases have drawn much attention in recent years owing to the continuously growing num-

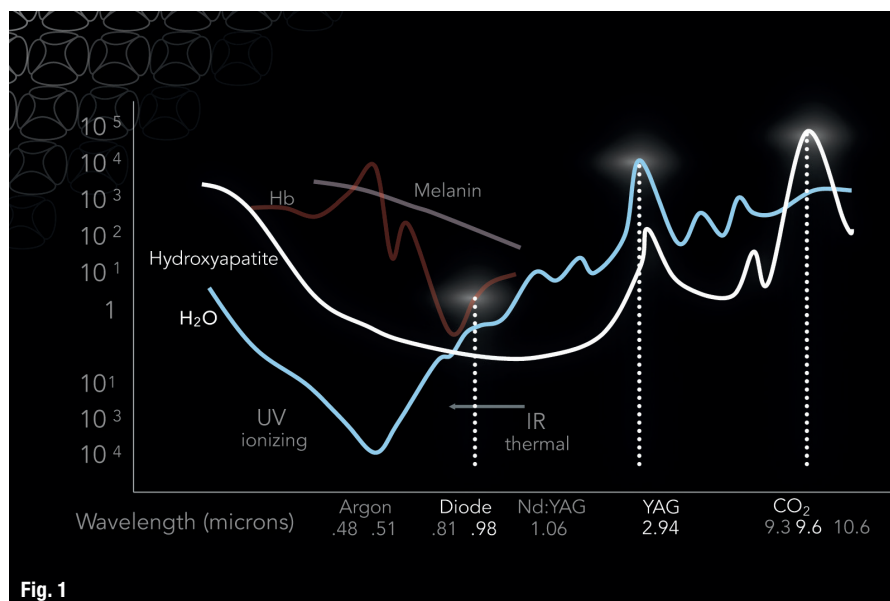


Fig. 1: Wavelengths offered by Light Instrument's family of dental lasers.

ber of cases. To this day, there is no validated treatment. Light Instruments is currently developing a new unique tip for LiteTouch™ that can perform a perfect 360-degree disinfection of the implant surface without causing any damage to the implant surface or any rise in temperature neither in the implant nor the surrounding tissue.

More and more universities around the world have included the LiteTouch™ Er:YAG laser in their graduate and post-graduate education programmes, as well as in their hospitals. Light Instruments pays particular attention to continuous education, offering a growing number of laser dentistry postgraduate programmes at academic institutions and private training centres in different countries.

Mr Ben-Mayor concluded: We are excited to launch our new dental laser line at the IDS 2019, implementing our vision of developing the latest cutting-edge technologies and products. We believe that our new dental laser line is a breakthrough line providing dentists with the best available solutions, contributing to improved modern dentistry anywhere in the world. We will continue to provide superior products with the highest technology in the future.

To arrange a meeting during the IDS in Cologne, Germany, please send an e-mail to office@light-inst.com.

contact

Light Instruments Ltd.
Industrial Zone, Tavor Building
P.O.B. 223
20692 Yokneam, Israel
www.light-inst.com

Henry Schein Dental Deutschland

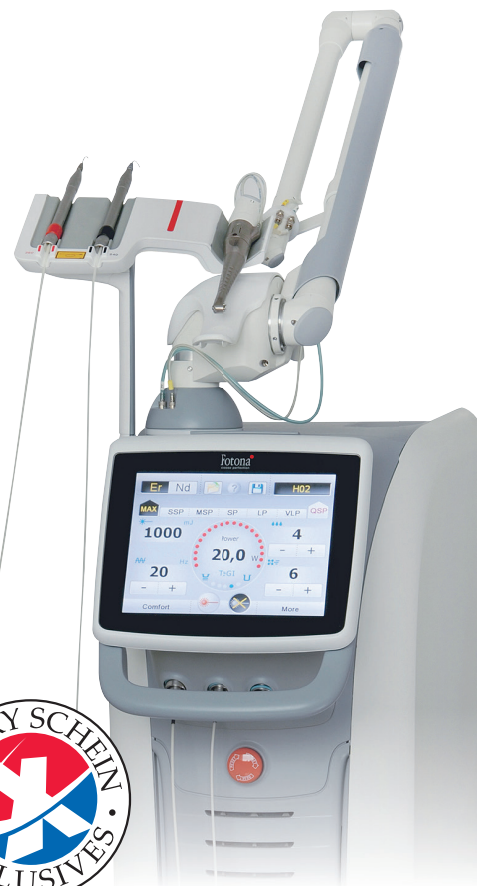High-standard laser system

LightWalker offers a high standard of dental treatment, and at the same time simplicity of use. The innovative system combines the power of the industry's highest performance Er:YAG and Nd:YAG dental lasers for extensive dual-wavelength treatment options, including the Fotona TwinLight® Endodontic and Periodontal Treatment methods.

The top-of-the-line LightWalker ATS model guarantees convenience and ergonomic comfort, and is the only dental laser system on the market that contains built-in scanner-ready technology.

The lasers are designed for ultimate versatility, with one of the most comprehensive lists of clinical applications available in any dental laser. These options include the removal of soft-granulation tissue, the ablation of infected bone and the removal of bacterial biofilm on implant surfaces with the Er:YAG, while bacterial reduction and biostimulation of bone tissue can be achieved with the Nd:YAG laser.

Henry Schein Dental Deutschland GmbH
Monzastraße 2a
63225 Langen, Germany
www.henryschein-dental.de



Light Instruments

Exclusively elegant limited edition

Light Instruments has officially announced the launch of an exclusive limited edition of LiteTouch™, embellished with Swarovski® crystals. According to the company's constant pursuit of creating the perfect dental laser experience for both dentists and patients alike, LiteTouch's intuitive and appealing industrial design contrib-

utes to a welcoming clinic atmosphere. Owing to the partnership with Swarovski an elegant, limited edition was designed as the ultimate expression of care and expertise. The limited edition includes 100 per cent original Swarovski crystals. Each laser unit comes with the "Crystals from Swarovski®" seal which serves as a certificate

of authenticity for products with genuine Swarovski crystals. Each seal has a unique 16-digit code used as a security tracking mechanism based on alphanumeric codes that allow customers to check the authenticity of their embellished unit.

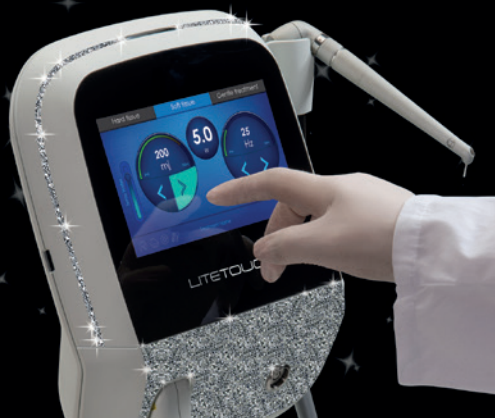The Erbium:YAG dental laser for both soft- and hard-tissue dental treatments is equipped with the Laser-in-Handpiece™ technology, which houses the entire laser mechanism within an impressively small chamber of only 12 cm in length and 2.5 cm in diameter. This innovative solution mimics the feel of a turbine drill, yet incorporates the laser's unique benefits: micro surgery, faster healing, minimally invasive treatments and higher patient acceptance.

Light Instruments Ltd.
Industrial Zone, Tavor Building
P.O.B. 223
20692 Yokneam, Israel
www.light-inst.com

LITETOUCH™
Er:YAG Laser-in-Handpiece
A Diamond for Every Clinic

Limited Edition

Embellished with Swarovski® crystals





Fotona

IFW Meeting attracted over 700 laser experts from 56 countries

The 15th annual International Fotona Weekend (IFW), organised in cooperation with the 8th Annual Laser & Health Academy Symposium, took place in Portorož, Slovenia, at the end of May. With a record of more than 100 presentations and over 700 participants from 56 different countries, this year's IFW exceeded everyone's expectations owing to an exceptional panel of medical laser professionals covering the latest developments and research findings from the three medical laser categories Aesthetics & Dermatology, Dentistry and Gynaecology.

The field of endodontics focused on the latest modifications in the SWEEPS® protocol, an advanced and highly effective root canal irrigation technique available for LightWalker laser systems. In addition to optimised endodontic solutions and the latest

clinical developments in several different dental fields, experts presented a new TwinLight® periodontal indication called "Periodontal regeneration" that had recently been cleared by the FDA and CE marked. This innovative laser treatment allows true regeneration of the attachment apparatus on a previously diseased root surface.

The 16th IFW will take place from 22 to 25 May 2019 at Lake Bled in Slovenia.

Fotona d.o.o.

Stegne 7

1000 Ljubljana, Slovenia

www.fotona.com

MEDENCY

State-of-the-art diode laser technology

The Italian company MEDENCY has been built upon profound global expertise in the dental market and dental lasers in particular. "Our flagship product PRIMO combines state-of-the-art diode laser technology with innovation and the experience of MEDENCY in the dental industry. PRIMO provides a variety of applications and is thus a viable alternative to conventional surgical methods like electrocautery and the scalpel. Owing to its intuitive interface, the device is easy to use," stated the company's general manager, Alessandro Boschi.

All products are designed, engineered and manufactured in Italy—with passion and commitment. "Our overall mission is to deliver a combination of cutting-edge products, services and interaction with customers drawing on a wide network of academic partners," said Boschi.

The company supports its partners with tailor-made educational courses in different countries in order to gain prac-

tical experience in the use of the system in daily practice. Using dental laser technology has never been so easy.

MEDENCY Srl

Piazza della Libertà 49

36077 Altavilla – Vicenza, Italy

www.medency.com



laser
3 2018

129

1st International Dental Students Congress for Laser Dentistry

Dr Georgi Tomov, Bulgaria



Sensing the increasing importance of education in laser dentistry, Plovdiv Medical University hosted the 1st International Dental Students Congress for Laser Dentistry (IDSCLD), from 22 to 23 March 2018 in Plovdiv, Bulgaria, dedicated to the motto “Next-Generation Laser Dentistry”. The congress was successful in gathering eminent speakers from various reputed universities and organisations and their paramount lectures enlightened the audience (Fig. 1).

The event organised in collaboration with the Bulgarian Dental Laser Society received generous response from the Bulgarian Dental Students Association, as well as expertise from academia, talented researchers and student communities from the faculties in Plovdiv, Varna and Sofia, Bulgaria.

The congress started with an opening ceremony and the special presence of the academic body of Plovdiv

Medical University (Fig. 2). In his welcome message the Dean of Plovdiv Dental Faculty, Prof. Georgi Todorov (Fig. 3), said that “The dental students’ educational needs sometimes go beyond the dental curriculum and clinical practice obtained at the faculty. Students feel the need to get a taste of extracurricular activities. New technologies like lasers are a bright example for next-generation dentistry and the students’ interest is intelligible. Only through these activities they can become leaders of their dental student communities”.

The opening ceremony was followed by keynote lectures, a poster session and a series of presentations of both honourable guests and students. IDSCLD was marked by the presence of renowned speakers from Switzerland, Turkey, Israel, Greece, Poland and Bulgaria—with thought-provoking keynote and plenary presentations the young researchers, students and



Fig. 1




Fig. 2



Fig. 3



Fig. 4

Fig. 1: More than 250 attendants participated in the congress and the diverse scientific lectures following the motto: "Next-Generation Laser Dentistry". **Fig. 2:** Congress President Dr. Georgi Tomov at the opening ceremony of the 1st International Dental Students Congress for Laser Dentistry. **Fig. 3:** Prof. Georgi Todorov, Dean of Plovdiv Dental Faculty, during his speech at the opening ceremony. **Fig. 4:** Highlight of the event: Award ceremony for the best students' poster presentation.

business delegates made the two-day event a success.

The highlight of the congress was the award ceremony for the best students' poster presentation. After careful consideration the renowned scientific jury awarded Elitza Veneva, Martin Arabadjiev and Anna Koleva for their poster entitled "Evaluation of Er:YAG laser induced analgesia in children" (Fig. 4). With more than 250 attendants, the congress was one of the most successful and productive student events in 2018.

Keeping the IDSCLD motto in mind and having witnessed the triumph of the 1st International Dental Students Congress for Laser Dentistry in Plovdiv, the Bulgarian Dental Laser Society is delighted to invite all of

its members and students to attend the most significant upcoming event of the laser world—the 16th WFLD World Congress 2018 taking place in Aachen, Germany, from 1 to 3 October 2018.

contact

Bulgarian Dental Laser Society

4 Veliko Tarnovo Str
Plovdiv 4000, Bulgaria
office@dentallasersociety.com



Children in Germany among

The best globally in oral health

According to new research, nearly 80 per cent of 12-year-old children in Germany have caries-free permanent dentition, making Germany top internationally, alongside Denmark, in terms of dental health in this age group. For the study, regularly conducted by the Deutsche Arbeitsgemeinschaft für Jugendzahnpflege (DAJ), a German organisation dedicated to maintaining and promoting oral health of children and adolescents, more than 300,000 children in ten federal states of Germany underwent dental examinations in the 2015/2016 school year. The oral health status was determined for three age groups: 12-year-old pupils, first-graders and, for the first time, 3-year-old kindergarten children. The unit of measure used to assess oral health was the dmf/DMF index. The study found a DMF score of 0.44 for the 12-year-olds studied and 78.8 per cent of the children in this age

group had a healthy dentition. Both values were the best ever achieved in Germany.

In the 6- to 7-year-old schoolchildren, however, still mainly having primary teeth, only 53.8 per cent had a healthy dentition. For the 3-year-olds it was found that 13.7 per cent already had dental caries, while 86.3 per cent had healthy teeth. These data underline suggestions of previous regional studies and clinical experience stating caries of the primary dentition to occur very early in some cases.

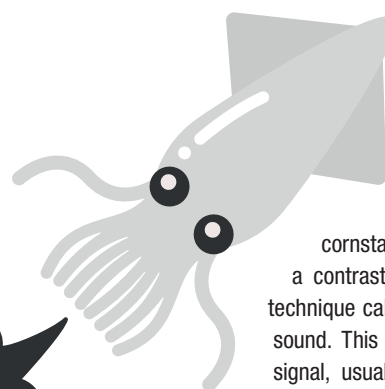
The findings show that the implementation of the DAJ recommendations published in 2016 for the prevention of early childhood caries for day care centres and parents was a step in the right direction and must be further extended.

Source: DTI

New laser-assisted method uses squid ink for

Periodontal disease check-ups

An engineer-lead team from the University of California San Diego, USA, has developed a new dental imaging method to examine the health of patients' gingivae and believe the new method could be less invasive, more comprehensive and more accurate than anything else available today. "The last time I was at the dentist, I realised that the tools that are currently being used to image teeth and gums could use significant updating," said Dr Jesse Jokerst, assistant professor at the Department of NanoEngineering at UC San Diego and senior author of the study, titled "Photoacoustic imaging for non-invasive periodontal probing depth measurements". The usual way of checking pocket depth for any signs of periodontal disease can be invasive and uncomfortable for patients, and measurements can vary greatly between dentists. For this new method, the mouth is first rinsed with a paste made of commercially available food-grade



squid ink, water and cornstarch. The rinse serves as a contrast agent for an imaging technique called photoacoustic ultrasound. This involves shining a light signal, usually a short laser pulse, on to a sample, which heats up and expands, generating an acoustic signal

that researchers can then analyse.

Squid ink naturally contains melanin nanoparticles, which absorb light. During the oral rinse, these are trapped in the pockets between the teeth and gingivae. When lit with a laser, the paste heats and swells, creating pressure in the pockets that is detected with ultrasound. Thus a full map of the pocket depth around each tooth can be created.

Source: DTI

New classification of

Periodontal diseases and conditions

A new global classification system for periodontal health, diseases and conditions, as well as peri-implant diseases and conditions, has been announced at the EuroPerio9 congress in June 2018. The comprehensive classification was based upon the most contemporary evidence and includes a staging and grading system for periodontitis, indicating severity and extent of disease, accounting for lifetime disease experience and taking into account the patient's overall health status.

The new classification is the outcome of a joint workshop held by the European Federation of Periodontology (EFP) and the American Academy of Periodontology (AAP) in Chicago, USA, in 2017. The workshop included over 100 experts from Europe, America, Australia and Asia who reviewed existing literature to

create a global consensus that enables care to be standardised for patients around the world. In the new classification, clinical health is defined for the first time and periodontitis is described in four stages, ranging from "least severe" (Stage 1) to "most severe" (Stage 4). The risk and rate of disease progression has been categorised into three grades. The grading considers risk factors like smoking and the presence of concomitant diseases, such as diabetes.

"The new classification should provide a globally consistent approach to diagnosis and management and ultimately improve outcomes for our patients," said Prof Iain Chapple, EFP Secretary General.

Source: EFP



© CarmenKarin/Shutterstock.com

Join DGL!

Register now at www.qr.oemus.com/6152 or scan the QR on the right and become a member of the German Association of Laser Dentistry (DGL).

Application form



Virtual reality achieves

Pain reduction and higher patient satisfaction

Though the use of virtual reality (VR) in dentistry is steadily growing, variation in its efficacy due to differing VR environments has rarely been measured. A new study, titled "The soothing sea: A virtual coastal walk can reduce experienced and recollected pain", conducted by a team from the universities of Plymouth, Exeter and Birmingham—in conjunction with Torrington Dental Practice in Devon—has found that dental patients enjoy an overall better experience when engaged in a VR walk in a coastal area than in a city. Patients who agreed to the study were randomly assigned to three separate situations: conventionally performed procedures without VR, a walk around a virtual city or a walk along the coastline of Devon's Wembury Beach. Patients chosen for the last two groups were provided with a headset and handheld controls. The study found that the group who virtually walked along the coastline experienced the least amount of pain and recollected their treatment as such. These findings were not evident in the group who engaged with the cityscape VR. "The use of virtual reality in healthcare settings is on the rise but we need more rigorous evidence of whether it actually improves patient experiences," said Dr Karin Tanja-Dijkstra, lead author of the study.

The researchers emphasised that the VR environment patients engage with is crucial to reducing their pain and anxiety when visiting the dentist. It should thus not only be distracting but also a welcoming and relaxing setting.

Source: DTI



© Standret/Shutterstock.com

Examination of primary dentition might help in

Early autism diagnosis

With prevalence of the autism spectrum disorder reportedly increasing annually, the need for early detection is critical. In a new study, titled "Dynamical features in fetal and postnatal zinc-copper metabolic cycles predict the emergence of autism spectrum disorder", researchers have found that a close examination of primary dentition may help with early diagnosis and give an insight into the origin of the disorder using novel tooth-matrix biomarkers.

Senior author of the study Dr Manish Arora, Professor of Dentistry and of Environmental Medicine and Public Health at the Icahn School of Medicine at Mount Sinai, NY, USA, said: "We had undertaken a study in 2016 on twins living in Sweden and found that metal uptake was different in the sibling affected by autism spectrum disorder. The strongest signal was for zinc, which was lower in the affected twin [...]." For the current study, the team set out to develop an

© Hatsaniuk/Shutterstock.com



algorithm through the replication of their findings from 2016 to help with early detection. Focusing on two populations in the USA and one in the UK, and cross-referencing them to the Swedish study, they found that it was not the concentration of metals that was the difference, but rather the rhythms of the cyclic processes underlying the metabolism of the metals. By employing two distinct classification models that used metal rhythmicity data, the researchers were able to achieve 90 per cent accuracy in classifying cases and controls, with sensitivity to autism spectrum disorder diagnosis ranging from 85 to 100 per cent and specificity from 90 to 100 per cent. Despite the positive results, Arora emphasised that further research is required before any concrete markers can be set.

Source: DTI

Researchers develop material that could

Emulate dental enamel

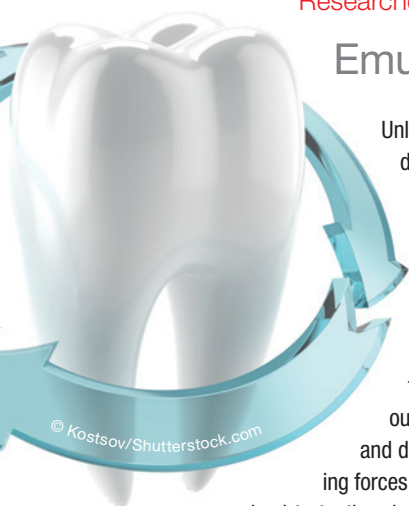
Unlike many other tissues in the human body, dental enamel does not regenerate itself once it is damaged. In what could potentially be a breakthrough for dentistry, researchers at Queen Mary University of London, UK, have developed a new method for growing mineralised materials that could regenerate dental enamel, bone and other hard tissue. As the hardest tissue in the body, enamel allows our teeth to withstand exposure to acidic foods and drinks, extreme temperatures, and frequent biting forces. Unfortunately, enamel's inability to renew can

lead to tooth pain and tooth loss, conditions that affect a large proportion of the world's population.

By focusing on a specific protein material that can trigger and guide the growth of apatite nanocrystals, the researchers found that the microscopic prisms created by the material possessed similar physical properties to dental enamel. These structures can be grown over large uneven surfaces and native tissue, opening opportunities for hard-tissue repair. "For example, we could develop acid-resistant bandages that can infiltrate, mineralise, and shield exposed dentinal tubules of human teeth for the treatment of dentine hypersensitivity," stated Dr Sherif Elsharkawy, a dentist at Queen Mary's School of Engineering and Materials Science.

The study's lead researcher Prof. Alvaro Mata, from the same school, emphasised: "A major goal in materials science is to learn from nature to develop useful materials based on the precise control of molecular building-blocks. The key discovery has been the possibility to exploit disordered proteins [...] with the capacity to tune their properties."

Source: DTI



© Kostsov/Shutterstock.com

E-cigarettes may modify

Genetic material in oral cells

Electronic cigarettes are viewed as a safer alternative to smoking, their effects are, however, relatively unknown. Researchers from the University of Minnesota Masonic Cancer Center in Minneapolis, USA, have outlined how e-cigarettes may modify the DNA of oral cells and increase cancer risks. "It's clear that more carcinogens arise from the combustion of tobacco in regular cigarettes than from the vapor of e-cigarettes," said the project's lead investigator, Dr Silvia Balbo. "However, we don't really know the impact of inhaling the combination of compounds produced by this device. [...]"

To characterise chemical exposures during vaping (the inhaling and exhaling of e-cigarette vapor), the researchers recruited five e-cigarette users. They collected salivary samples before and after a 15-minute vaping session and analysed them for chemicals known to damage DNA. To evaluate the possible long-term effects,



© gmstockstudio/Shutterstock.com

the team assessed DNA damage in the cells of the volunteers' mouths. Three DNA-damaging compounds were identified, formaldehyde, acrolein and methylglyoxal, whose levels all increased in the saliva after vaping. The danger is when the toxic chemicals react with DNA and cause damage. If the cell does not repair the damage so that normal DNA replication can take place, cancer could result. The scientists plan to follow up this preliminary study with more extensive research involving more e-cigarette users and controls.

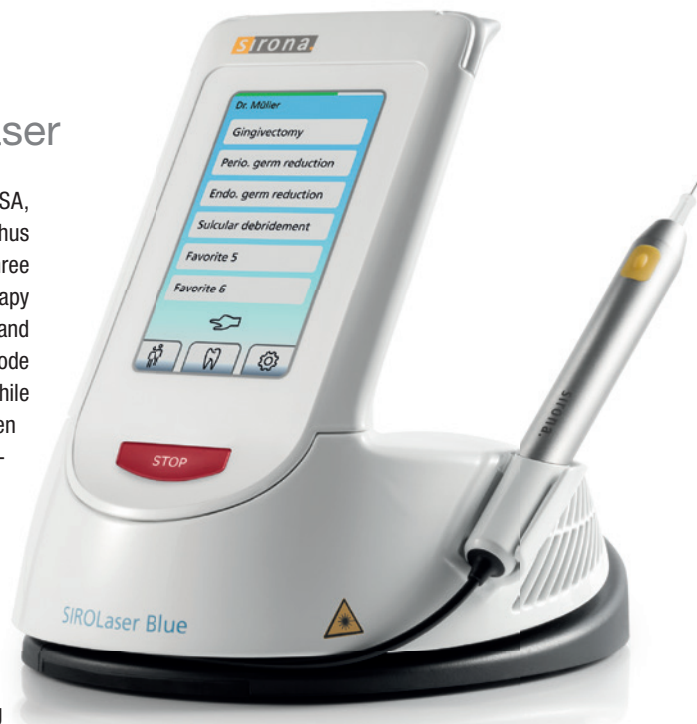Source: DTI

Dentsply Sirona

FDA approval of new diode laser

As announced at the Dentsply Sirona World 2018 in Orlando, USA, the SiroLaser Blue has just recently been FDA approved and is thus now also available for practitioners in the US. With diodes at three different wavelengths, this dental laser is a versatile laser therapy device. It is the first dental diode laser to feature blue, infrared and red wavelengths. The short wavelength of the blue 445nm diode improves the results of surgery thanks to its high absorption while it requires less power. Moreover, after surgery there is often no need for sutures, usually allowing the wound to heal without scarring. In endodontics and periodontology, the infrared 970nm diode helps to reduce germs already in the dentinal tubules, as well as in the periodontal pockets during adjuvant therapy. Another advantage is that it may be possible to dispense with antibiotics. Further the red 660nm diode is especially beneficial for photo-biomodulation treatments. This light therapy combats inflammation that occurs in connection with oral mucosa diseases, supports wound healing after surgery and helps reduce postoperative pain.

The market leader in innovative dental products and technologies, Dentsply Sirona, will be present at this year's WFLD congress in Aachen, Germany, and will bring the SiroLaser Blue. Dentists from all over the world will thus be able to find out more about the quality of the treatment results for a range of indications at numerous specialist lectures, a workshop and a live treatment. As a Gold Sponsor at the 16th WFLD Congress from 1 to 3 October 2018 in Aachen, Germany, Dentsply Sirona will be supporting many different specialist lectures. The SiroLaser Blue can be used to treat more than 20 indications. Attendees will be able to learn about the advantages of laser applications in clinical settings.

**Try out the SiroLaser Blue for yourself**

Any dentists wanting to try out the SiroLaser Blue for themselves are warmly welcome to join the practical workshop—whether they would like to experience the clean, usually bloodless incision achieved in microsurgery, the procedure for treating mucous membrane alterations or adjuvant therapy following root canal preparation. After the presentation attendees can test out the many different applications of the dental laser under guidance on a porcine jaw, and see the excellent results first hand.

Source: Dentsply Sirona



From left: Product Manager Laser Systems André Förster, Marketing Manager Ingo Höver and Director Product Management Julius Müller-Albinus of Dentsply Sirona Instruments at the Dentsply Sirona World 2018 in Orlando, USA.

FÜR JEDE KLINISCHE INDIKATION DAS OPTIMALE SYSTEM

LASER EINFACH, SICHER & SANFT

**A.R.C.
LASER**

Fotona
choose perfection

www.henryschein-dental.de

HENRY SCHEIN DENTAL – IHR PARTNER IN DER LASERZAHNHEILKUNDE

Wir bieten Ihnen ein breites und exklusives Sortiment marktführender Lasersysteme verschiedener Hersteller an.

Unsere Laserspezialisten beraten Sie gern über die vielfältigen Möglichkeiten und das für Sie individuell am besten geeignete System.

Laser ist nicht gleich Laser und genau hier liegt bei uns der Unterschied:

Sie, Ihre Patienten und Ihre gemeinsamen Bedürfnisse stehen bei uns an erster Stelle.

Bei Henry Schein profitieren Sie vom Laserausbildungskonzept!

Von der Grundlagenvermittlung über hochqualifizierte Praxistrainings und Workshops zu allen Wellenlängen bis hin zu Laseranwendertreffen.

Unsere Laser-Spezialisten in Ihrer Nähe beraten Sie gerne.

FreeTel: 0800-1400044 oder FreeFax: 08000-404444

Erfolg verbindet.

 **HENRY SCHEIN®**
DENTAL

Prof. Dr. Norbert Gutknecht

Präsident der Deutschen Gesellschaft
für Laserzahnheilkunde e.V. (DGL)



Jubiläumskongress vom 1. bis 3. Oktober 2018 in Aachen

Liebe Freunde der Laserzahnheilkunde,

es ist mir eine besondere Freude, Sie anlässlich dieses außergewöhnlichen Kongressereignisses – 30 Jahre WFLD/ISLD, 27 Jahre DGL und 12 Jahre WALED – hier in Aachen begrüßen zu dürfen. Mit diesem Jubiläumskongress ermöglichen wir es vielen Kolleginnen und Kollegen aus allen Erdteilen, gemeinsam den wissenschaftlichen Vorträgen und klinischen Behandlungsabläufen beizuwohnen.

Wenn wir in der Zahnheilkunde an die Anwendung von Lasern denken, so müssen wir feststellen, dass diese heute fest etablierte Behandlungsmethode erst vor ca. 30 Jahren ins Leben gerufen wurde. Verschiedene Universitäten haben Untersuchungen durchgeführt, die dann letztlich zu wissenschaftlich abgesicherten Anwendungen dieser Methoden führten. Parallel dazu haben sich Wissenschaftler und Zahnärzte zuerst in Arbeitskreisen zusammengeschlossen, die im weiteren Verlauf zur Gründung von Laser-Gesellschaften führten. Heute würde niemand mehr eine indikationsgerechte Anwendung von Lasern in der Zahnheilkunde infrage stellen.

Sowohl die ISLD als auch die DGL wurden mit dem Ziel gegründet, die Anwendung von Lasern in der Zahnheilkunde in Wissenschaft und Praxis zu fördern. Deshalb erfolgte im Jahre 1998 die Assoziation der DGL mit der ISLD (International Society for Laser Dentistry), die seit dieser Zeit eng zusammenarbeiten.

Innerhalb dieser Zusammenarbeit hat die DGL im Jahre 2006 den ISLD-Weltkongress in Berlin mit großem Erfolg ausgerichtet. Deshalb bin ich als eines der DGL-Gründungsmitglieder und als Kongresspräsident besonders

glücklich und stolz, dass die DGL erneut gastgebende Gesellschaft für den Jubiläumskongress der WFLD/ISLD hier in Aachen sein darf und dass Prof. Dr. Lynn Powell als Gründungsmitglied der ISLD die Leitung des wissenschaftlichen Programms übernommen hat.

Wir bieten die wissenschaftliche/klinische Plattform, die es Wissenschaftlern und Praktikern ermöglicht, ihre Forschungsergebnisse und klinischen Fälle vorzustellen, zu diskutieren und sich über neue Entwicklungen und Möglichkeiten sowie Grenzen des Einsatzes von Lasersystemen in der oralen Medizin zu informieren. Die innerhalb des Kongresses angebotenen Workshops dienen der kontinuierlichen klinischen Ausbildung und werden deshalb auch mit entsprechenden Fortbildungspunkten bewertet.

Wie Sie wissen, ist ein solcher Kongress nicht nur dazu da, um sich wissenschaftlich und klinisch weiterzubilden, sondern es ist mir ein besonderes Anliegen, dass auch die persönlichen und kollegialen Kontakte gepflegt werden können. Deshalb freue ich mich, mit Ihnen am Dienstagabend im Schloss Rahe bei gutem Essen und Livemusik feiern zu können.

In diesem Sinne wünsche ich uns allen einen harmonischen Kongressverlauf.

Ihr

Prof. Dr. Norbert Gutknecht



Chemotherapie

Laser hemmt Entwicklung oraler Mukositis

Orale Mukositis ist eine der häufigsten unerwünschten Nebeneffekte bei der Therapie von Krebserkrankungen. Die Entzündungen in der Mundhöhle stellen für Patienten nicht nur eine starke Einschränkung der Lebensqualität dar, sondern zwingen Mediziner zum Teil auch zu Unterbrechungen der Behandlung. Um Patienten zu entlasten und somit Verzögerungen bei der Chemotherapie bzw. Bestrahlung zu vermeiden, forschen Wissenschaftler seit einiger Zeit in diverse Richtungen. Neben dem Einsatz von Honig oder dem Keratinozytenwachstumsfaktor scheint nun ein weiterer möglicher Ansatz gefunden: Die Low-Level-Laser-Therapie (LLLT).

Forscher des UPMC Shadyside Hospitals, USA, setzten bei 19 Probanden mit hämatologischen Krebserkrankun-

gen während einer Chemotherapie LLLT ein. Bei den Personen handelte es sich um Krebspatienten, die im Vorfeld einer Stammzellentransplantation eine chemotherapeutische Konditionierung erhielten. Auch wenn es sich um eine relativ kleine Teilnehmerzahl handelte, sind die Ergebnisse recht vielversprechend. Bei keinem der Patienten entwickelte sich eine orale Mukositis 4. Grades. Rund zwei Drittel wiesen Grad 3 auf, der Rest wies nur leichte Formen der Erkrankung auf. Nur etwa ein Drittel benötigte schmerzlindernde Mittel.

Ob LLLT auch bei anderen Krebserkrankungen ähnliche Effekte erzielt, muss in weiteren Untersuchungen geprüft werden. Die Forschungsergebnisse wurden auf dem Oncology Nursing Society's (ONS) Annual Congress 2018 in Washington DC, USA, vorgestellt.

Quelle: ZWP online

27. DGL-Jahreskongress

Scannen Sie den nebenstehenden QR-Code für Details zum vorläufigen Programm des DGL-Jahreskongress am 2. & 3. Oktober 2018 im Universitätsklinikum Aachen.



Wissenschaft

Hauptschalter für die Regeneration von Knochengewebe identifiziert

Wissenschaftler der Universitäten Freiburg im Breisgau und Basel haben einen Hauptschalter für die Regeneration von Knochengewebe identifiziert. Prof. Dr. Prasad Shastri, Professor für Biofunktionale Makromolekulare Chemie und Professor für Cell Signalling Environments an der Universität Freiburg, hat die Studie geleitet.

Shastri hat mit seiner Arbeitsgruppe im Labor eine mineralische Phase entwickelt, die das Hydroxylapatit im Knochen nachahmt. Mithilfe dieses biomimetischen Materials hat Dr. Melika Sarem aus Shastris Arbeitsgruppe zusammen mit der Forschungsgruppe von Prof. Dr. Ivan Martin, Departement Biomedizin von Universität und Universitätsspital Basel, herausgefunden: Bei der Entscheidung, auf welchem Weg der Knochen neu gebildet wird, nimmt die mineralische Phase eine Schlüsselrolle ein. Sie kann den calciumsensitiven Rezeptor (CaSR) stimulieren, ein

Protein, das von Stammzellen aus dem Knochenmark (MSC) gebildet wird und für die Zelle den Calciumspiegel in deren Umgebung bestimmt. Eine übermäßige Stimulation führt dazu, dass die MSC sich direkt in Knochenzellen differenzieren – ohne Zwischenschritt über Knorpelzellen. Außerdem haben die Wissenschaftler in Zellkulturen gezeigt, dass sich die Knochenbildung mit einem Eingriff in die Signalkette über den CaSR vollständig unterbinden lässt. Allerdings ist es auch möglich, die MSC aus der Abhängigkeit von CaSR zu lösen: indem der Rezeptor PTH1R (parathyroid hormone 1 receptor), der den Calcium-Ionen-Haushalt im Gleichgewicht hält, stimuliert wird und daraufhin die Knochenbildung über den Zwischenschritt der Knorpelzellbildung in Gang setzt.

Quelle: Albert-Ludwigs-Universität Freiburg



16th WORLD CONGRESS WFLD 2018

1. – 3. Oktober 2018,
RWTH Aachen,
Aachen

**RWTHAACHEN
UNIVERSITY**



The 16th Congress of the
World Federation for Laser
Dentistry (WFLD)



The 27th Annual Meeting of
the German Society for Laser
Dentistry (DGL)



The 6th Annual Congress
of the World Academy for
Laser Education
in Dentistry (WALED)

Dieser Kongress verbindet Wissenschaft und Praxis auf
diversen Präsentations- und Demonstrationsebenen durch:

- Hochwertige Vorträge internationaler Keynote-Referenten
- Live-Demonstrationen am Patienten
- Interaktive digitale Posterpräsentationen
- Vorträge in Kombination mit klinisch relevanten Fähigkeiten
- Kurzpräsentationen aktueller wissenschaftlicher Ergebnisse
- Klinische Fallpräsentationen
- Rotierende, firmenunterstützte Workshops zum Erwerb von Weiterbildungszertifikaten

Kontakt

WFLD 2018 Hauptsitz Aachen
Herr Leon Vanweersch
Stellvertretender Vorsitzender
des Organisationskomitees
Telefon: +49 151 50610781
headquarters@wfl-d-aachen2018.com
www.wfl-d-aachen2018.com



Innovative Dentallaser

Prävention statt Restauration

Dank modernster Technik nehmen Laserbehandlungen in der Zahnmedizin immer mehr Raum ein. Schon heute sind Dentallaser bei chirurgischen Eingriffen, in der Implantologie und Parodontologie sowie bei Wurzelbehandlungen nützlich. Die Behandlung ist nicht nur weniger invasiv, schonender und blutfreier, sondern auch weniger schmerzintensiv für den Patienten. Zu den genannten Vorteilen kommt nun ein entscheidender hinzu: Laser könnten zukünftig eine große Rolle bei der Prävention spielen. Ein Team aus Laserphysikern

der UC San Francisco (UCSF), USA, hat nach jahrelanger Zusammenarbeit einen Laser entwickelt, der positiven Einfluss auf die Zusammensetzung des Zahnschmelzes nehmen kann. Durch die hohe Temperatur des Lasers wird die oberste Schicht des Zahnschmelzes säureresistenter und damit weniger angreifbar gemacht.

Eine Studie mit 20 Probanden konnte die Effekte auf den Zahnschmelz bei der Behandlung mit dem kurzpulsigen Kohlendioxidlaser bestätigen. Zukunftsweisend erscheint die Erkenntnis, dass in Verbindung mit Fluorid sogar eine Remineralisierung der Zähne stattfindet, sodass bei bereits vorhandenen Beschädigungen die Selbstheilung induziert werden kann. Um dieses Ziel zu erreichen, müssen präventive Laser im Vergleich zu derzeit gängigen Dentallasern eine höhere Präzision aufweisen. In der UCSF-Studie kamen kurzpulsige CO₂-Laser mit einer Wellenlänge von 9,6 µm zum Einsatz.

Präventive Laserbehandlungen könnten die Dentalmedizin umfassend verändern. Anstelle wiederkehrender Fluoridanwendungen würden einmalige Kombinationsbehandlungen mit Fluoridlacken und CO₂-Lasern treten. Insbesondere in der Kieferorthopädie bei Patienten mit Zahnsparren und folglich erschwerten Zahnpflege-Bedingungen erscheint diese Form der Kariesprävention sinnvoll.

Quelle: ZWP online

Periimplantitisprophylaxe

Kavitation als Schlüssel zum Erfolg

Gehen Zähne aufgrund von Erkrankungen, mangelnder Mundhygiene oder Unfällen verloren, können sie komfortabel durch Implantate ersetzt werden.

Doch auch bei den „künstlichen“ Zähnen ist eine gründliche Mundhygiene und Prophylaxe wichtig.

Das implantatumgebende Gewebe ist weiterhin nicht gegen Bakterien immun. Eine Periimplantitis, in deren Folge die Implantate verloren gehen können, ist eine gefürchtete Komplikation, die es unbedingt zu vermeiden gilt. Bisher kommen bei der Prophylaxe in der Regel Ultraschall-, Schall- sowie Luft-Pulver-Wasserstrahl-Geräte zum Einsatz, damit auch der Biofilm im Gewinde des Implantats gründlich entfernt werden kann. Die raue Oberfläche und kleinen Rillen von Implantaten, die eine bessere Osseointegration ermöglichen sollen, erschweren jedoch die Arbeit.

Japanische Forscher haben kürzlich eine neue Methode entwickelt, die zukünftig bei der Periimplantitisprophylaxe eingesetzt werden könnte. Dabei machten sie sich die sogenannte Kavitation zunutze:



Mithilfe von Wasser erzeugten sie kleine Dampfblasen, die beim Auftreffen auf die Implantatoberfläche zerplatzen. Dabei entsteht eine Art Druckwelle, die den vorhandenen Biofilm am Implantat entfernt.

Im direkten Vergleich mit einem Wasserstrahl hatte der Kavitationsstrahl die Nase vorn: Er konnte in drei Minuten bis zu einem Drittel mehr Plaque entfernen. Dabei wurden nicht nur die unteren Gewinderillen sehr gut gereinigt, sondern auch jene im Kambereich. Die Studie wurde erst kürzlich im Journal *Implant Dentistry* veröffentlicht.

Quelle: ZWP online

Werden Sie DGL-Mitglied!

Registrieren Sie sich jetzt unter www.qr.oemus.com/6153 oder scannen Sie den nebenstehenden QR-Code und werden Sie Teil der Deutschen Gesellschaft für Laserzahnheilkunde e.V.

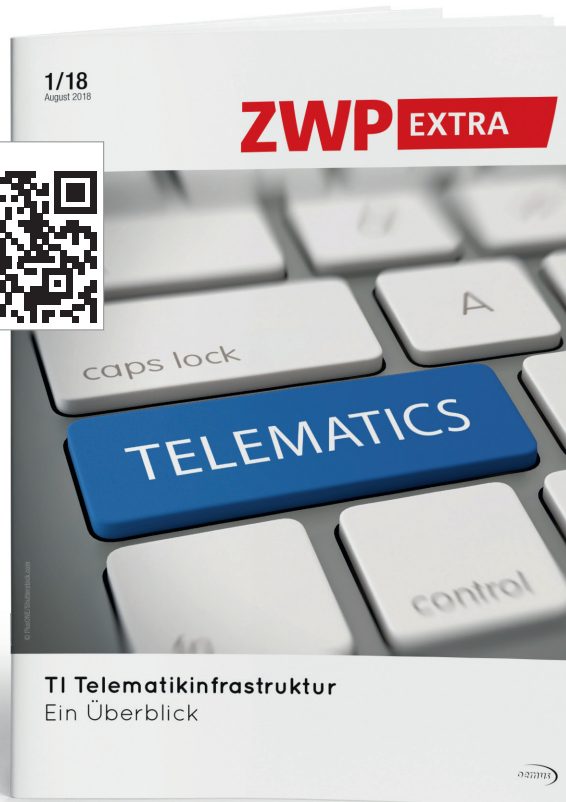Aufnahmeantrag



E-Paper

ZWP extra zur Telematikinfrastruktur

Auf Grundlage des E-Health-Gesetzes vom 1. Januar 2016 (Gesetz für sichere digitale Kommunikation und Anwendungen im Gesundheitswesen) hat die Bundesregierung die erweiterte Nutzung der elektronischen Gesundheitskarte sowie deren Anbindung an die Telematikinfrastruktur (TI) beschlossen. Mit der Telematikinfrastruktur sollen die Akteure des Gesundheitswesens im Bereich der gesetzlichen Krankenversicherung miteinander vernetzt werden. Ziel ist es, medizinische Informationen für die Patientenbehandlung sektoren- und systemübergreifend sowie schnell, einfach und vor allem sicher zur Verfügung zu stellen. Allerdings verlangt die Telematikinfrastruktur von Praxisinhabern und -mitarbeitern eine große Bereitschaft, sich dieser digitalen Herausforderung zu stellen. Fast wöchentlich ändern sich offizielle Aussagen und einzelne Vorgaben, das grundsätzliche TI-Projekt scheint jedoch unabwendbar und muss somit von jeder Praxis individuell geschultert werden. Genau hier setzt das neue Supplement der *ZWP Zahnarzt Wirtschaft Praxis*, das *ZWP extra* zur Telematikinfrastruktur, an. Es bietet einen Einstieg in die komplexe Thematik, Hilfestellungen im Dschungel verschlüsselter Begrifflichkeiten und konkrete Orientierung anhand von FAQs und einer umfassenden Checkliste für die Praxis. Zudem werden der rechtliche, technische und finanzielle Rahmen der



Telematikinfrastruktur beleuchtet und erste Erfahrungen aus der Praxis abgebildet. Das Supplement ist als E-Paper bequem unter www.zwp-online.info/publikationen abrufbar.

Quelle: ZWP Zahnarzt Wirtschaft Praxis

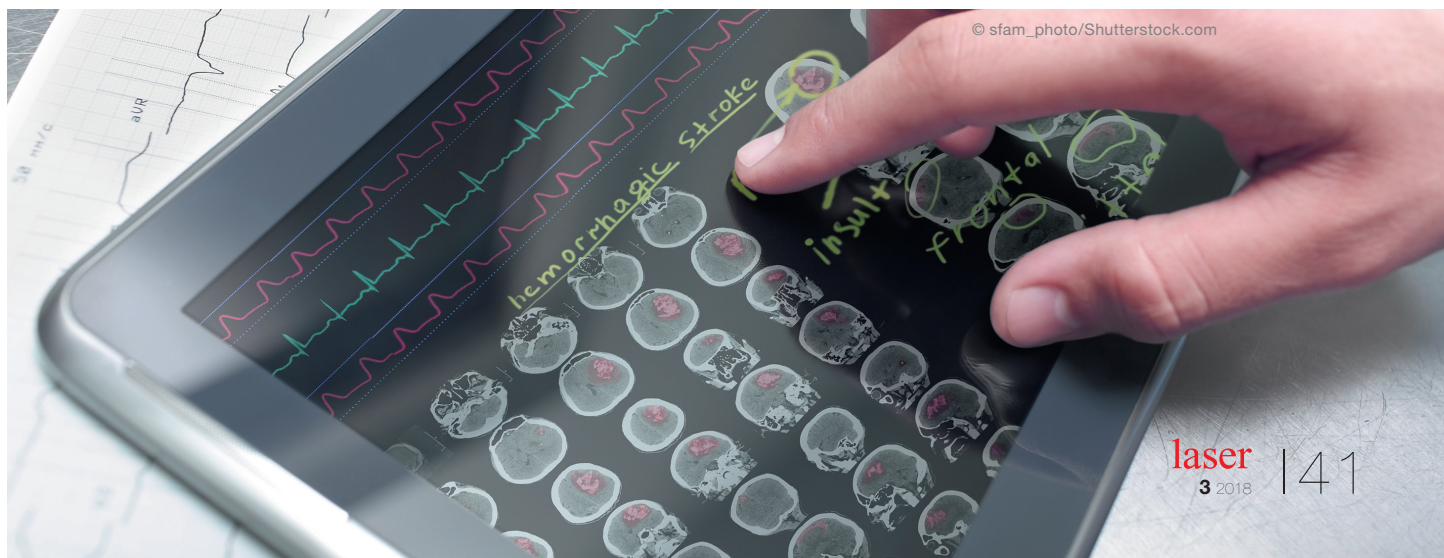
Datenerfassung

Unis betonen Wichtigkeit für Forschung und Medizin

Die österreichischen Medizinischen Universitäten MedUni Wien, Med Uni Graz und Medizinische Universität Innsbruck sowie die Medizinische Fakultät an der Johannes Kepler Universität Linz unterstrichen kürzlich die Wichtigkeit der im geplanten neuen Forschungsorganisationsgesetz vorgesehenen Möglichkeit, auf forschungsrelevante, patientenbezogene Daten zugreifen zu dürfen. Mit der ermöglichten Datenverfügbarkeit entsprechend des neuen Gesetzes und seiner Richtlinien werde gewährleistet, dass Patientendaten dem Datenschutz entsprechend behandelt würden, gleichzeitig aber auch für die Forschung zur Verfügung ste-

hen. Der Schutz und das Wohl der Patienten stehe selbstverständlich immer im Vordergrund, allerdings würden die Patienten selbst stets dazu beitragen wollen, dass auch folgende Generationen von den gewonnenen Erkenntnissen profitieren können. Der technologische Fortschritt gibt der Medizin und Forschung Werkzeuge in die Hand, um Daten immer besser nutzen zu können, insbesondere bei der personalisierten Medizin. Daher müsse die Datennutzung in Medizin und Forschung auch zukünftig gewährleistet bleiben.

Quelle: MedUni Wien



laser

international magazine of laser dentistry

ISLD International Society for Laser Dentistry



Imprint

Publisher

Torsten R. Oemus
oemus@oemus-media.de

CEO

Ingolf Döbbecke
doebbecke@oemus-media.de

Members of the Board

Jürgen Isbaner
isbaner@oemus-media.de

Lutz V. Hiller
hiller@oemus-media.de

Editor in Chief

Norbert Gutknecht
ngutknecht@ukaachen.de

Coeditors in Chief

Adam Stabholz
Matthias Frentzen

Editorial Managers

Dimitris Strakas
Leon Vanweersch

Regional Editors

Georgi Tomov
Europe

Marina Polonsky
North America

Marcia Martins Marques
South America

Youssef Sedky
Middle East & Africa

Ambrose Chan
Asia & Pacific

Senior Editors

Aslihan Üsümez
Josep Arnabat
Kosmas Tolidis
Andreas Braun
Rene Franzen
Lynn Powell

Editorial Board

Peter Steen Hansen, Aisha Sultan, Ahmed A Hassan, Antonis Kallis, Dimitris Strakas, Kenneth Luk, Reza Fekrazad, Sharonit Sahar-Helft, Lajos Gaspar, Paolo Vescovi, Ilay Maden, Jaana Sippus, Hideaki Suda, Ki-Suk Kim, Miguel Martins, Aslihan Üsümez, Enrique Trevino, José Correia de Campos, Saleh Ghabban, Stephen Hsu, Antoni Espana Tost, Josep Arnabat, Alaa Sultan, Evgeniy Mironov, Ahmed Abdullah, Boris Gaspirc, Peter Fahlstedt, Alireza Fallah, Michel Vock, Anna Maria Yiannikos, Ryan Seto, Joyce Fong, Iris Brader, Masoud Mojahedi, Gerd Volland, Gabriele Schindler, Ralf Borchers, Stefan Grümer, Detlef Klotz, Jörg Meister, Rene Franzen, Andreas Braun, Siegfried Jänicke, Olaf Oberhofer, Thorsten Kleinert

Editorial Office

Georg Isbaner
g.isbaner@oemus-media.de

Katharina Rühling

k.ruehling@oemus-media.de

Product Manager

Timo Krause
t.krause@oemus-media.de

Executive Producer

Gernot Meyer
meyer@oemus-media.de

Art Director

Alexander Jahn
a.jahn@oemus-media.de

Designer

Sandra Ehnert
s.ehnert@oemus-media.de

Theresa Weise

t.weise@oemus-media.de

Customer Service

Marius Mezger
m.mezger@oemus-media.de

Published by

OEMUS MEDIA AG
Holbeinstraße 29
04229 Leipzig, Germany
Tel.: +49 341 48474-0
Fax: +49 341 48474-290
kontakt@oemus-media.de

Printed by

Silber Druck oHG
Am Waldstrauch 1
34266 Niestetal, Germany

laser international magazine of laser dentistry
is published in cooperation with the International Society for Laser Dentistry (ISLD).

ISLD Headquarters

University of Aachen Medical Faculty
Clinic of Conservative Dentistry
Pauwelsstraße 30
52074 Aachen, Germany
Tel.: +49 241 808964
Fax: +49 241 803389644
ngutknecht@ukaachen.de
www.isldlaser.com

www.laser-magazine.com • www.oemus.com



Copyright Regulations

laser international magazine of laser dentistry is published by OEMUS MEDIA AG and will appear with one issue every quarter in 2018. The magazine and all articles and illustrations therein are protected by copyright. Any utilisation without the prior consent of editor and publisher is inadmissible and liable to prosecution. This applies in particular to duplicate copies, translations, microfilms, and storage and processing in electronic systems. Reproductions, including extracts, may only be made with the permission of the publisher. Given no statement to the contrary, any submissions to the editorial department are understood to be in agreement with a full or partial publishing of said submission. The editorial department reserves the right to check all submitted articles for formal errors and factual authority, and to make amendments if necessary. No responsibility shall be taken for unsolicited books and manuscripts. Articles bearing symbols other than that of the editorial department, or which are distinguished by the name of the author, represent the opinion of the aforementioned, and do not have to comply with the views of OEMUS MEDIA AG. Responsibility for such articles shall be borne by the author. Responsibility for advertisements and other specially labeled items shall not be borne by the editorial department. Likewise, no responsibility shall be assumed for information published about associations, companies and commercial markets. All cases of consequential liability arising from inaccurate or faulty representation are excluded. General terms and conditions apply, legal venue is Leipzig, Germany.

SUBSCRIBE NOW!


laser—international magazine of laser dentistry

Interdisciplinary, transparent & market orientated

ONLINE
SUBSCRIPTION HERE



www.oemus-shop.de



stay updated:

research

Diverse applications of lasers in dentistry

case report

Diode laser-assisted vital pulp therapy

events

1st IDSCLD in Plovdiv, Bulgaria



Fax: **+49 341 48474-290**

I would like to subscribe for the following journals:

- ☐ laser—international magazine of laser dentistry 4 issues p.a. € 44*
- ☐ implants—international magazine of oral implantology 4 issues p.a. € 44*
- ☐ ceramic implants—international magazine of ceramic implant technology 2 issues p.a. € 30*

Terms & Conditions: The subscription may be cancelled in written form without due justification within 14 days of order by contacting OEMUS MEDIA AG, Holbeinstraße 29, 04229 Leipzig, Germany. Dispatching notification in good time will suffice. The subscription is automatically extended by another twelve months if it is not cancelled in written form 6 weeks prior to the end of the reference period.

* All prices include VAT, shipping and handling.

Last Name/First Name

Company

Street

ZIP/City/Country

E-Mail

Signature

Credit Card Number

Expiration Date

Security Code

OEMUS MEDIA AG

Holbeinstraße 29 · 04229 Leipzig · Germany · Phone: +49 341 48474-200 · d.duetsch@oemus-media.de

**A.R.C.
LASER**

enlighten your surgery.

FOX + EmunDo

LASER & PTT IN PERFECT HARMONY FOR HEALTHY GUMS

445
nm

1064
nm

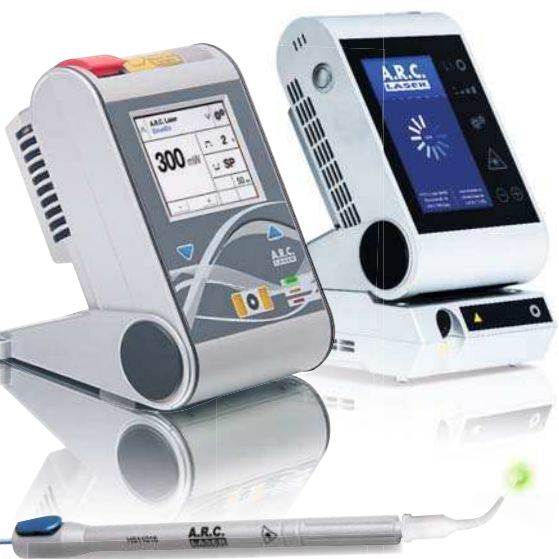980
nm

810
nm

Start right away with **EmunDo®**
and improve your patients health!

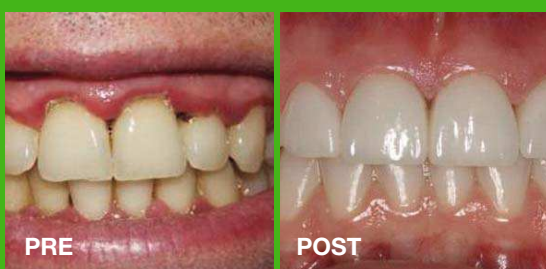To activate **EmunDo®** go for
one of the FOX Dental Lasers

FOX III or FOX IV



The
EmunDo®
healthy gums
effect:

EmunDo® - Treatment



EmunDo®

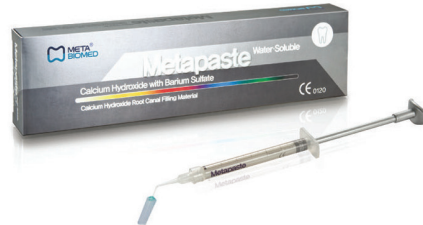- Free of iodine
- Kills all Germ:
Gram-positive as well
as Gram negative
- No exposure time
required



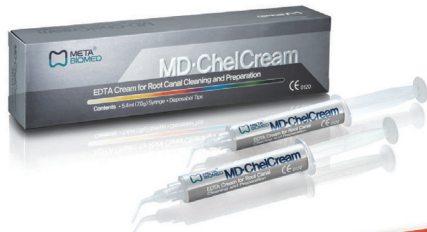• سیلر بیس رزینی
ADSEAL



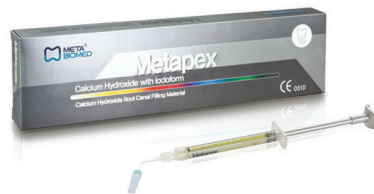• هیدروکسید کلسیم + سولفات باریم
Metapaste



• ژل آرسی پرپ ۱۹٪
MD.ChelCream

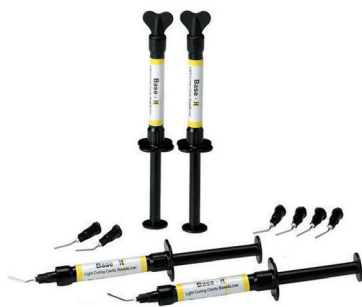

• هیدروکسید کلسیم + ید
Metapex

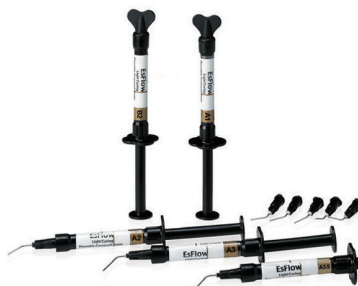

• گوتا پرکا
Gutta Percha Point

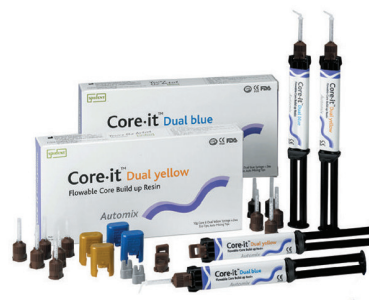* ISO sizes : 10, 15, 20, 25, 30, 35, 40, 45, 50, 55, 60, 70, 80, 90, 100, 110, 120, 130, 140
* Non-Standardized (Accessory sizes): XF, FF, MF, F, FM, M, ML, L, XL
* Special Taper Points : .04, .06, .08 • protaper : F1, F2, F3



Base.It
(بیس و لاینر) دایکال نوری



EsFlow
کامپوزیت نانو فلو لایت کیور



Core.it
کریبلد آپ دوال کیور