

[www.azadmed.com](http://www.azadmed.com)



 azaadtejaratpars

 @azadmed2

 88 98 80 63 - 6



# laser

international magazine of laser dentistry

I | S | L | D



## research

Use of carbon dioxide  
lasers in dentistry

## case report

Treatment of oral leukoplakia  
with a 980 nm diode laser

## case report

Facial swelling caused  
by infected teeth





The universe at your fingertips.

# ● LightWalker

## The highest technology dental laser system

### Supreme clinical results:

- TwinLight® Perio Treatments
- TwinLight® Endo Treatments
- No-sutures soft-tissue surgery
- Patient-friendly conservative dentistry
- Pre-sets for over 40 applications


### Unmatched simplicity of use:

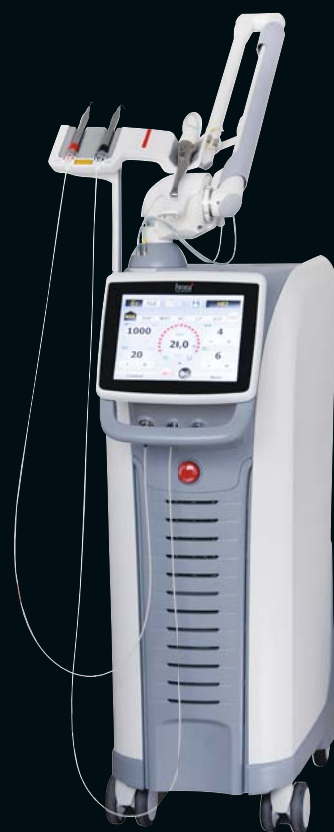- Balanced and weightless OPTOflex® arm
- Nd:YAG handpiece detection system
- Quantum Square Pulse technology for fast minimally invasive treatments
- X-Runner™ - the first digitally controlled Er:YAG dental laser handpiece

Journey into a new dental experience with speed, precision and great results.

Visit [www.fotona.com](http://www.fotona.com) today!



 Fotona App





**Prof. Dr Norbert Gutknecht**

ISLD President and Scientific Chairman



# Together towards a **bright** future

Dear friends and colleagues,

I believe that all of us dental laser users worldwide would love to see a bright future for laser dentistry. Your participation in our International Society for Laser Dentistry (ISLD), German association for laser dentistry (Deutsche Gesellschaft für Laserzahnheilkunde—DGL) and World Academy for Laser Education and Research in Dentistry (WALED) congresses, held from 6 to 8 June in Plovdiv in Bulgaria, was essential for strengthening not only the ISLD but also the participating national societies, which are constantly striving to enrich the knowledge of their members and to promote professional excellence in the use of dental lasers through research and education.

Plovdiv, the oldest city in Europe, has been designated the 2019 European Capital of Culture. It was, thus, only natural that the city, founded 4,000 years ago, had unanimously been selected as the venue for the 17<sup>th</sup> International Congress of the ISLD, the 28<sup>th</sup> annual meeting of the DGL and the 7<sup>th</sup> WALED Congress. Our Organising Chairman, Dr Georgi Tomov, his team and the entire Bulgarian Society for Laser Dentistry did a fantastic job

in hosting more than 250 laser enthusiasts from around the globe in their beautiful city.

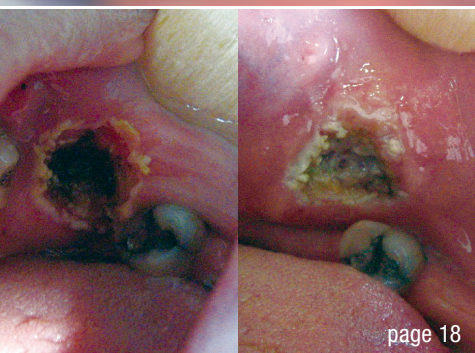
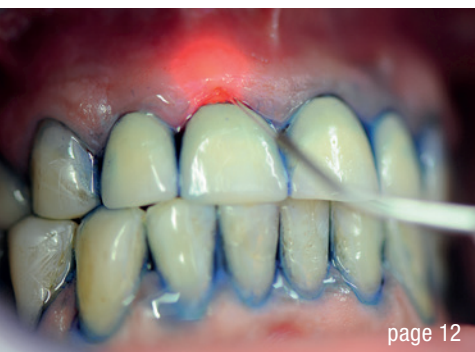I would like to express my deepest gratitude to everyone who attended our congress in Plovdiv and joined us for an outstanding event that brought technology and culture together to create an unforgettable experience.

I am already looking forward to our next World Congress, to be held from 1 to 3 October 2020 in Cairo in Egypt. Save the date and join us for yet another great celebration of laser art and science, helmed by the ISLD—the leading society worldwide for laser dentistry.


Yours

Prof. Dr Norbert Gutknecht





Cover image:  
© Pixel Embargo/Shutterstock.com



## editorial

- Together towards a **bright** future 03  
Prof. Dr Norbert Gutknecht

## research

- Use of **carbon dioxide** lasers in dentistry 06  
Dr Kenneth Luk, Irene Shuping Zhao, Prof. Norbert Gutknecht & Prof. Chun Hung Chu
- Initial therapy** of periodontitis using dental **lasers** 12  
Dr Frank Liebaug

## case report

- Treatment** of oral **leukoplakia** with a **980 nm** diode laser 18  
Dr Maziar Mir, Prof. Norbert Gutknecht, Dr Masoud Mojahedi, Dr Jan Tunér & Dr Masoud Shabani
- Facial swelling** caused by infected teeth 20  
Dr Imneet Madan
- Peri-implant** bone regeneration through **laser** decontamination 24  
Prof. Wilfried Engelke, Dr Christian Engelke, Dr Victor Beltrán & Dr Marcio Lazzarini

## practice management

- Successful **communication** in your **daily practice** 30  
Dr Anna Maria Yiannikos

## events

- A look back at the **17<sup>th</sup> International Congress of ISLD** in Plovdiv 34  
Dr Dimitris Strakas & Dr Georgi T. Tomov

## news

- manufacturer **news** 32
- news** 36

## about the publisher

- imprint 42





# M.Sc. Lasers in Dentistry

Specialist in dental laser therapies

Next Start: **23<sup>rd</sup> September 2019** | Aachen, Germany | 4 semesters

Aachen Dental Laser Center - AALZ  
Pauwelsstraße 17 | 52074 Aachen | Germany  
phone +49 241 47 57 13 10 | fax +49 241 47 57 13 29  
info@aalz.de  
www.aalz.de

RWTH International Academy  
Kackertstraße 10 | 52072 Aachen | Germany  
phone +49 241 80 23543 | fax +49 241 80 92525  
info@academy.rwth-aachen.de  
www.academy.rwth-aachen.de



Aachen Dental Laser Center

**INTERNATIONAL  
ACADEMY**

**RWTH AACHEN  
UNIVERSITY**

**PROFESSIONAL EDUCATION PROGRAMMES**

Your contact for more information: Leon Vanweersch • vanweersch@aalz.de - www.aalz.de



# Use of carbon dioxide lasers in dentistry

Dr Kenneth Luk, Irene Shuping Zhao, China; Prof. Norbert Gutknecht, Germany & Prof. Chun Hung Chu, China

“**Laser**” is an acronym that stands for “light amplification by stimulated emission of radiation”.<sup>1</sup> The photons that make up a laser beam are coherent, amplified in phase (standing wave) and of a specific wavelength (monochromatic). Laser has been used in dentistry for over two decades.<sup>2</sup> Dental lasers are categorised according to their active medium and wavelengths. The currently available dental lasers are diode lasers (445, 635 and 810–980 nm), potassium titanyl phosphate lasers (532 nm, green), neodymium-doped yttrium aluminium garnet (Nd:YAG) la-

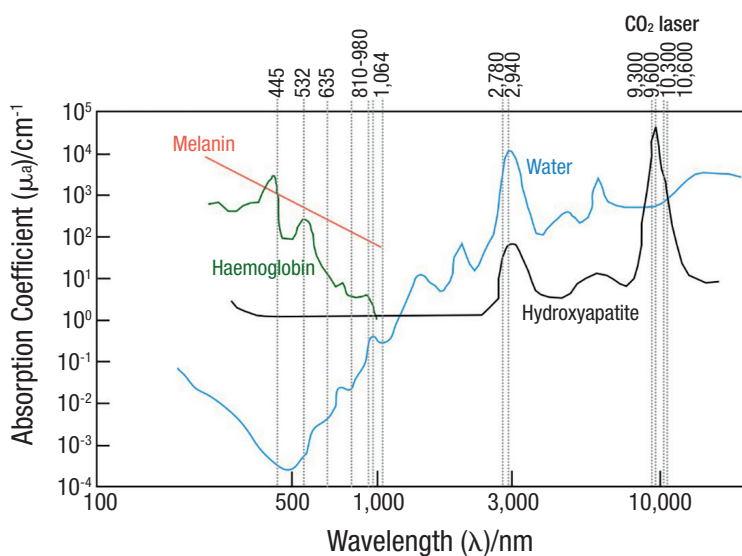
asers (1,064 nm), erbium lasers (2,780 and 2,940 nm) and carbon dioxide (CO<sub>2</sub>) lasers (9,300 and 10,600 nm). Each laser wavelength has a specific thermal output and a particular tissue interaction.

Dental lasers of different wavelengths are used to perform different procedures. Blue lasers, diode lasers, Nd:YAG lasers and CO<sub>2</sub> lasers are primarily used in soft-tissue surgery to provide good coagulation.<sup>3–6</sup> Because CO<sub>2</sub> laser energy is well absorbed by water, it is absorbed on the surface of the soft tissue. The visible lasers (445–660 nm) are absorbed within the first centimetre of the soft tissue because they are best absorbed by pigmented chromophores such as melanin and haemoglobin. Lasers with 810 to 1,064 nm wavelengths in the near-infrared spectrum can penetrate into the soft tissue by a few centimetres because they are comparatively less well absorbed by melanin and haemoglobin. Erbium lasers, operating in free-running pulse mode, are highest in water absorption, enabling their use for soft-tissue ablation, as well as for dental hard tissue and osseous preparation. The two erbium wavelengths commonly used in dentistry are erbium, chromium-doped yttrium, scandium, gallium and garnet (Er,Cr:YSGG) lasers (2,780 nm) and erbium-doped yttrium aluminium garnet (Er:YAG; 2,940 nm) lasers. Although erbium lasers can be used for soft-tissue procedures, bleeding control is less effective than with diode and CO<sub>2</sub> lasers, which offer better visualisation of the surgical site.<sup>6</sup> A CO<sub>2</sub> laser is a useful and efficient gas laser for use in clinical dentistry. It is available in 10,600 nm on the market (Table 1).

CO<sub>2</sub> lasers are often used in soft-tissue surgery because their wavelengths are well absorbed by water, which makes up 70 % of biological tissue. They penetrate less than a millimetre and can produce excellent coagulation, along with a very precise cut.<sup>7,8</sup> The optical property of the wavelength in tissue is important to determine the use of lasers to perform dental hard-tissue preparation. Enamel and dentine are mainly composed of hydroxyapatite, which has a high absorption coefficient to the wavelengths of CO<sub>2</sub> lasers. Nevertheless, it takes time for a CO<sub>2</sub> laser to ablate dental hard tissue, which contains mainly hydroxyapatite, with a melting point over 1,600 °C.

Model	Manufacturer	Location
Miran	Mediclase	Tel Aviv, Israel
CYMA Dental	BISON MEDICAL	Seoul, South Korea
Surgical CO <sub>2</sub> laser	DOCTOR MED	Seoul, South Korea
2015 Korea fractional CO <sub>2</sub> laser	Daeshin Enterprise	Seoul, South Korea
DETA 2	GPT Dental	Fairfield, Neb., USA
LightScalpel	LightScalpel	Bothell, Wash, USA
OPELASER PRO	YOSHIDA DENTAL	Tokyo, Japan
Smart US20D	DEKA	Calenzano, Italy

**Table 1:** Several 10,600 nm carbon dioxide lasers on the market.



**Fig. 1:** Absorption spectra (log scale) of several biological materials and laser wavelengths (adapted from Zuerlein et al.<sup>15</sup>).

The time required results in carbonisation, melting and cracking of enamel.<sup>9-11</sup> The transversely excited atmospheric pressure (TEA) CO<sub>2</sub> laser was developed by energising a gas laser with a high-voltage electrical discharge in a gas mixture, generally above atmospheric pressure.<sup>12</sup> A pulsed low-energy CO<sub>2</sub> laser is available with very short pulse durations of a few microseconds with a high repetition rate (frequency) of over 1,000 Hz per second. These developments make CO<sub>2</sub> lasers suitable for dental hard-tissue preparation.<sup>13</sup> In this paper, the production of CO<sub>2</sub> lasers and their technological advancement, optical properties, and parameters in relation to clinical applications in dentistry will be discussed.

### Production of CO<sub>2</sub> lasers

The CO<sub>2</sub> laser was one of the earliest gas lasers to be developed, in 1964.<sup>14</sup> It is one of the most useful and continuous-wave lasers currently available. The lasing medium is a gas discharge, and the three main filling gases within the discharge tube are CO<sub>2</sub>, nitrogen (N<sub>2</sub>) and helium (He). With electrical discharge, microwave or radio frequency, electron impact excites the vibrational motion of N<sub>2</sub> molecules. This marks the beginning of the population inversion, where molecules in the system are in their excited states. N<sub>2</sub> cannot lose this energy by photon emission because it is a homonuclear diatomic molecule. Excited vibrational levels are relatively long-lived and in a metastable state. The energy transfer that occurs owing to the collision between N<sub>2</sub> molecules and CO<sub>2</sub> molecules causes vibrational (resonant) excitation of CO<sub>2</sub> molecules, with sufficient efficiency to lead to the required population inversion of CO<sub>2</sub> for laser operation (collision of the second kind). The N<sub>2</sub> molecules are then returned to ground state.

The CO<sub>2</sub> molecules are still at a higher energy level after emission of photons. They return to ground state by colliding with cold He atoms. The resulting hot He atoms can be cooled by striking the bore (wall of the tube). The pressure in the tube must be low for adequate flow of photons. This limits the amount of CO<sub>2</sub> molecules in the tube, producing a low-power laser. The photons emitted owing to transition between energy levels have low energy and a longer wavelength than visible and near-infrared light because the energy levels of molecular vibration and rotation are similar.

### Technological advancements of CO<sub>2</sub> lasers

More than one laser wavelength can be produced by a CO<sub>2</sub> gas laser. The wavelength depends on the isotope and resonator amplifying the wavelength desired. In dentistry, the 10,600 nm (<sup>12</sup>C<sup>16</sup>O<sub>2</sub> molecule) wavelength is the earliest and most commonly produced wavelength. A CO<sub>2</sub> laser is more efficient than other lasers because of its comparatively higher ratio of output power to pump power. Higher peak powers of CO<sub>2</sub> lasers can be achieved by slow flowing of the gas instead of using a sealed tube. Another method to achieve higher peak power is to increase the density of excited CO<sub>2</sub> molecules (i.e. the gas pressure). However, the voltage needed to achieve gas breakdown and couple energy into the upper laser levels also increases. The method to prevent production of a high voltage is to pulse the voltage transversely to the laser axis. Because electrical discharge can move transversely perpendicular to the laser axis, the electrons can travel at a substantially shorter distance and collide with more molecules.<sup>12</sup> The TEA CO<sub>2</sub> laser has such a design. The TEA CO<sub>2</sub> laser can achieve

### Wavelength of CO<sub>2</sub> lasers (nm)

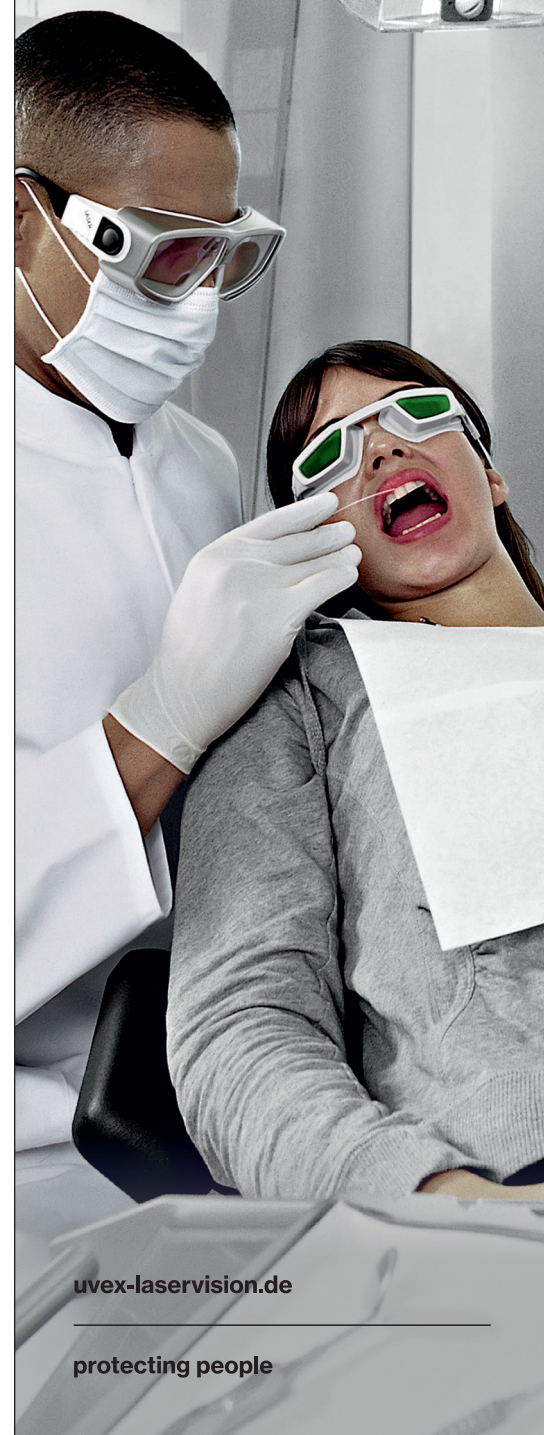
	9,300	9,600	10,300	10,600
Absorption coefficient of enamel (cm <sup>-1</sup> ) <sup>17</sup>	5,500	8,000	1,125	825
Absorption depth of enamel (μm) <sup>17</sup>	2.0	1.0	9.0	12.0
Absorption coefficient of dentine (cm <sup>-1</sup> ) <sup>16</sup>	5,000	6,500	1,200	813
Absorption depth of dentine (μm) <sup>16</sup>	2.0	1.5	8.3	12.0

**Table 2:** Absorption coefficient and depth of carbon dioxide lasers in enamel/dentine.

# laservision

## shop online!

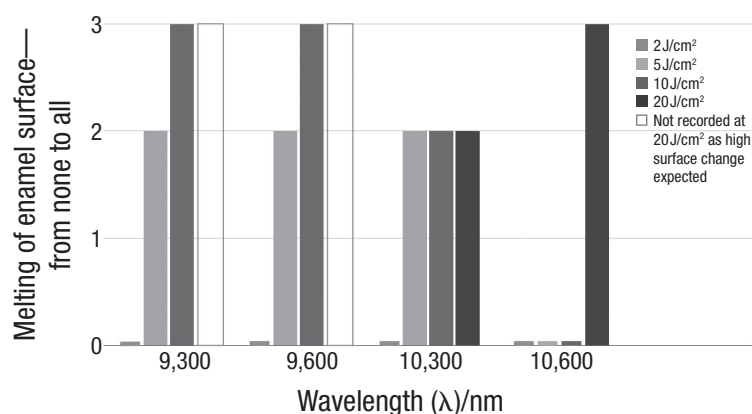
## Dental Laser Protection



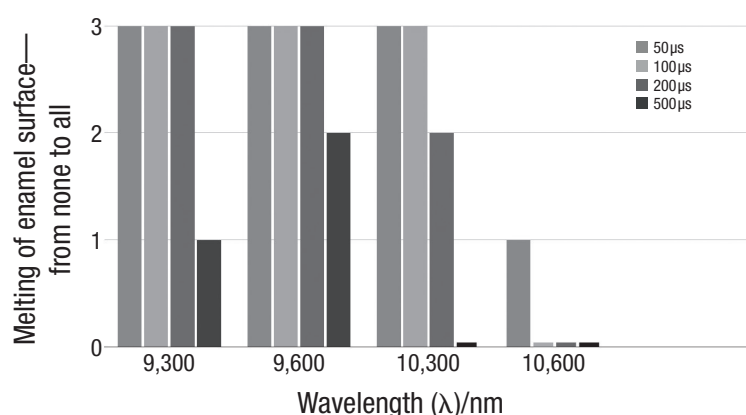
uvex-laservision.de

protecting people





**Fig. 2:** Effect on enamel by carbon dioxide lasers according to wavelength and fluence. Irradiation parameters: 25 carbon dioxide laser pulses at 100  $\mu$ s (data adapted from McCormack et al.<sup>18</sup>). Melting of enamel surface: 0 = no surface melting; 1 = some surface melting, no crystal fusion; 2 = some surface melting with crystal fusion; 3 = general surface melting with crystal fusion.



**Fig. 3:** Effect on enamel by carbon dioxide lasers according to wavelength and pulse duration. Irradiation parameters: 25 carbon dioxide laser pulses at 5 J/cm<sup>2</sup> (data adapted from McCormack et al.<sup>18</sup>). Melting of enamel surface: 0 = no surface melting; 1 = some surface melting, no crystal fusion; 2 = some surface melting with crystal fusion; 3 = general surface melting with crystal fusion.

high peak power in short pulses ( $\sim 2 \mu$ s) and at a high repetition rate. The 9,300 nm CO<sub>2</sub> laser was approved by the U.S. Food and Drug Administration (FDA) and introduced in 2010 for both hard- and soft-tissue surgery (Solea, Convergent Dental). The 9,300 nm wavelength is produced by using an isotope <sup>12</sup>C<sup>18</sup>O<sub>2</sub> gas molecule instead of the normal <sup>12</sup>C<sup>16</sup>O<sub>2</sub> molecule. Both <sup>18</sup>O and <sup>16</sup>O are naturally stable CO<sub>2</sub> molecules. Because <sup>18</sup>O is heavier, with extra two neutrons, the frequency and energy level of molecular vibration are different from those of <sup>16</sup>O.<sup>13</sup>

### Optical properties and laser parameters

Clinical applications with CO<sub>2</sub> lasers rely on understanding of optical properties (how tissue acts on laser energy) and laser parameters (how laser energy acts on tissue). Different isotopes contained in the CO<sub>2</sub> molecule generate different output wavelengths of CO<sub>2</sub> lasers. A CO<sub>2</sub> laser generates a beam of infrared light with the wavelength bands primarily at 9,300; 9,600; 10,300 and 10,600 nm. The CO<sub>2</sub> wavelengths lie in the far-infrared electromagnetic spectrum. The main chromophores

are water and hydroxyapatite. Figure 1 shows the absorption spectra in log scale of common biological materials of common dental lasers. The absorption coefficients of all CO<sub>2</sub> wavelengths to water are very similar. The 10,600 nm CO<sub>2</sub> wavelength has an absorption coefficient to water of approximately  $6.6 \times 102.0 \text{ cm}^{-1}$ . This gives an absorption or penetration depth (reciprocal of absorption coefficient) of 15  $\mu$ m in water. Because soft tissue contains over 70% water, this makes CO<sub>2</sub> laser wavelengths suitable for soft-tissue surgery. The CO<sub>2</sub> wavelengths have a higher absorption coefficient to hydroxyapatite than to water. Among the four CO<sub>2</sub> laser wavelengths, 9,600 nm has the best absorption coefficient to hydroxyapatite, which is the main component of enamel and dentine. Table 2 provides a summary of the absorption coefficients and depth of 9,300; 9,600; 10,300 and 10,600 nm CO<sub>2</sub> laser wavelengths in enamel and dentine.<sup>16</sup> The absorption depths in enamel and dentine of 9,300 and 9,600 nm wavelengths are shallower than for 10,300 and 10,600 nm wavelengths. Variations in laser parameters acting on enamel and dentine produce different thermal effects.

Early studies investigated the interaction of CO<sub>2</sub> wavelengths and laser parameters on surface temperature increase, surface melting, morphological surface changes and chemical changes on the enamel surface.<sup>18–21</sup> These early studies showed how a combination of the fluence and pulse duration of CO<sub>2</sub> lasers acts on different enamel surface changes (Figs. 2–4). At 4–6 J/cm<sup>2</sup> and a 100  $\mu$ s pulse, a temperature increase of 590–770 °C (Fig. 4) with 10,300 and 10,600 nm wavelengths is expected to reduce the carbonate, acid phosphate and protein content of enamel (Table 3). After shortening the pulse duration to 50  $\mu$ s, the melting effect was observed with a 10,600 nm wavelength at 5 J/cm<sup>2</sup>, suggesting a temperature increase of over 1,000 °C (Fig. 3). However, enamel ablation without carbonisation was reported with a pulse duration of between 10 and 20  $\mu$ s at 30 J/cm<sup>2</sup>.<sup>22</sup> For 9,300 and 9,600 nm wavelengths with 4–6 J/cm<sup>2</sup> and a 100  $\mu$ s pulse, the temperature increase (720–1,150 °C) is higher than for 10,300 and 10,600 nm wavelengths owing to the higher absorption coefficient. This rise in temperature correlated with the observed surface melting on enamel (Fig. 2).

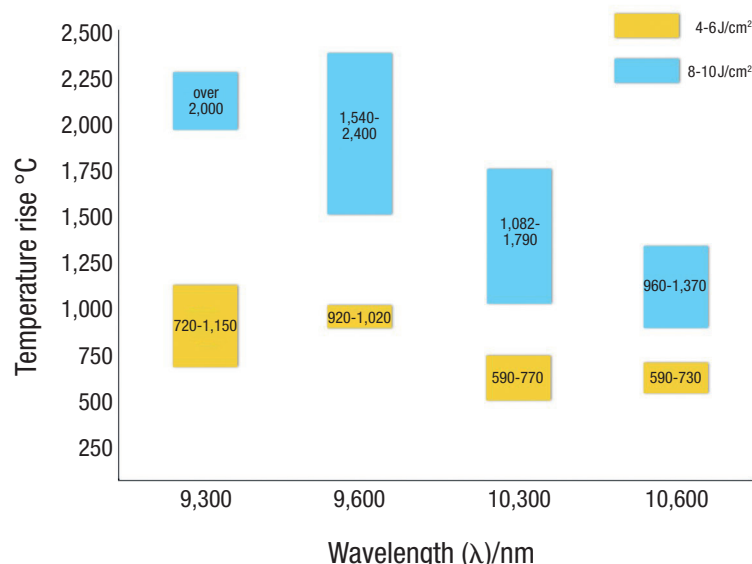
Currently, the parameters for a 9,300 nm CO<sub>2</sub> laser (Solea) operate uniquely in dental hard-tissue ablation and differently from 10,600 nm CO<sub>2</sub> lasers in soft-tissue ablation. According to the manufacturer's specifications, the laser operates between 1 and 130  $\mu$ s, with a maximum pulse energy of 42.5 mJ and 1,019 Hz at 130  $\mu$ s. These parameters are not displayed on the control panel. The parameters were measured using a PowerMax-Pro 150F HD, 50 mW, 150 W fan-cooled sensor and LabMax-Pro SSIM Laser Power Meter (both Coherent). For adult hard-tissue mode, Figure 5 shows the pulses measured (from the authors' unpublished data). Fifty-three

pulses (30–106W) are delivered in 43µs, followed by a pulse pause of 13µs. The frequency is calculated as 950 pulses per second. The laser operates differently in soft-tissue mode. For example, at 0.75 mm spot size, the frequency is constant at 187Hz, while the peak power is 150W at 10% power. The peak power is 260W at 20–100% power (Fig. 6). Pulse duration increases from 16.5µs at 10% power to 133µs at 100% power (from the authors' unpublished data; Fig. 7).

## Laser interactions with dental hard tissue and their clinical applications

Although many laboratory and clinical studies have been conducted with CO<sub>2</sub> lasers on dental hard tissue, only recently could these findings be clinically implemented because there is currently only one 9,300nm CO<sub>2</sub> dental laser approved for hard-tissue application by the FDA. Laser interactions with dental hard tissue fall into three major categories, namely: (1) interaction with the mineral; (2) interaction with the protein and lipid; and (3) interaction with the water.<sup>23</sup> CO<sub>2</sub> lasers can be used in tooth ablation and caries prevention. For ablation, the fluence must be above the ablation threshold, the point above which sufficient energy has been added to the surface in a short enough period to cause expansion and/or vaporisation of the tissue. In the case of CO<sub>2</sub> lasers, absorption in both the mineral and water will occur with some melting and vaporisation of the mineral at around 1,000 °C and above, as well as heating and expansion of subsurface water. It has been reported that the use of a 9,300nm CO<sub>2</sub> laser with a fluence of 9–42 J/cm<sup>2</sup> at a higher repetition rate (300Hz) can ablate enamel and dentine effectively.<sup>24</sup>

The role of CO<sub>2</sub> lasers in dental caries prevention has been explored since the 1960s. For caries prevention purposes, it is likely that the most effective wavelengths are those that are most strongly absorbed by the mineral of dental hard tissue. The CO<sub>2</sub> laser wavelengths of 9,300; 9,600; 10,300 and 10,600nm overlap with the



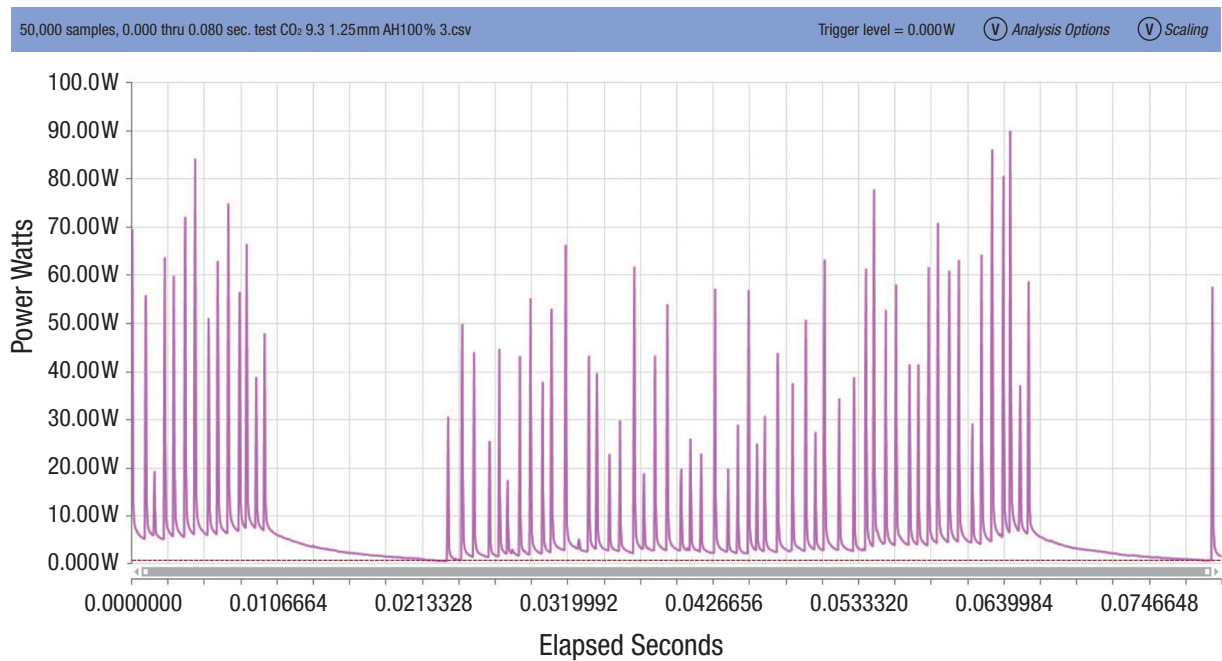
**Fig. 4:** Temperature rise of enamel after irradiation with carbon dioxide lasers. Irradiation parameters: single pulse of carbon dioxide wavelengths of 4–6 J/cm<sup>2</sup> and 8–10 J/cm<sup>2</sup> at 100 µs (data adapted from Fried et al. and Fowler & Kuroda<sup>20,21</sup>).

strong phosphate absorption bands of the mineral. To prevent dental caries, the laser light must alter the composition or solubility of the dental substrate and the energy must be strongly absorbed and efficiently converted to heat without damage to the underlying or surrounding tissue.<sup>25</sup> Studies on the effects of CO<sub>2</sub> lasers have focused on increasing the resistance to caries by reducing the rate of subsurface enamel and dentine demineralisation.<sup>26,27</sup> A greater depth of carbonate loss in enamel with a 10,600nm CO<sub>2</sub> laser was observed compared with that with a 9,600nm CO<sub>2</sub> laser.<sup>17</sup> Featherstone and Frieda reported that using a pulsed 9,600nm CO<sub>2</sub> laser produced an 84% inhibition of demineralisation in an intraoral cross-over study.<sup>23</sup> Furthermore, some studies have combined the effects of lasers with those of fluoride.<sup>28,29</sup> In an *in vivo* study, Rechmann et al. showed that occlusal fissures irradiated with a 9,600nm CO<sub>2</sub> laser followed by fluoride varnish application twice a year were more resistant to caries than fissures that did not undergo irradiation.<sup>30</sup> Another study using a 9,300nm CO<sub>2</sub>

Temperature	Chemical and morphological changes in enamel during heating in furnace
Above 1,100 °C	1,225 °C β-Ca <sub>3</sub> (PO <sub>4</sub> ) <sub>2</sub> converted to α'-Ca <sub>3</sub> (PO <sub>4</sub> ) <sub>2</sub> , 1,250 °C Ca <sub>4</sub> (PO <sub>4</sub> ) <sub>2</sub> O melting 1,450 °C disproportionate to α'-Ca <sub>3</sub> (PO <sub>4</sub> ) <sub>2</sub> 1,600 °C α'-Ca <sub>3</sub> (PO <sub>4</sub> ) <sub>2</sub> and Ca <sub>4</sub> (PO <sub>4</sub> ) <sub>2</sub> O melts. Conversion of OH <sup>-</sup> to O <sup>2-</sup>
650–1,100 °C	Recrystallisation, crystal growth of β-Ca <sub>3</sub> (PO <sub>4</sub> ) <sub>2</sub> formed in tooth enamel Decrease in OH <sup>-</sup> and conversion of OH <sup>-</sup> to O <sup>2-</sup> Loss of H <sub>2</sub> O and CO <sub>3</sub> <sup>2-</sup> and loss of trapped CO <sub>2</sub> +NCO <sup>-</sup>
110–650 °C	Decomposition and denaturation of proteins Formation of pyrophosphate P <sub>2</sub> O <sub>7</sub> from acid phosphate HPO <sub>4</sub> <sup>2-</sup> CO <sub>3</sub> <sup>2-</sup> loss (–66%)

**Table 3:** Chemical and morphological changes of enamel at different temperatures (adapted from Fowler and Kuroda 1986)<sup>21</sup>.



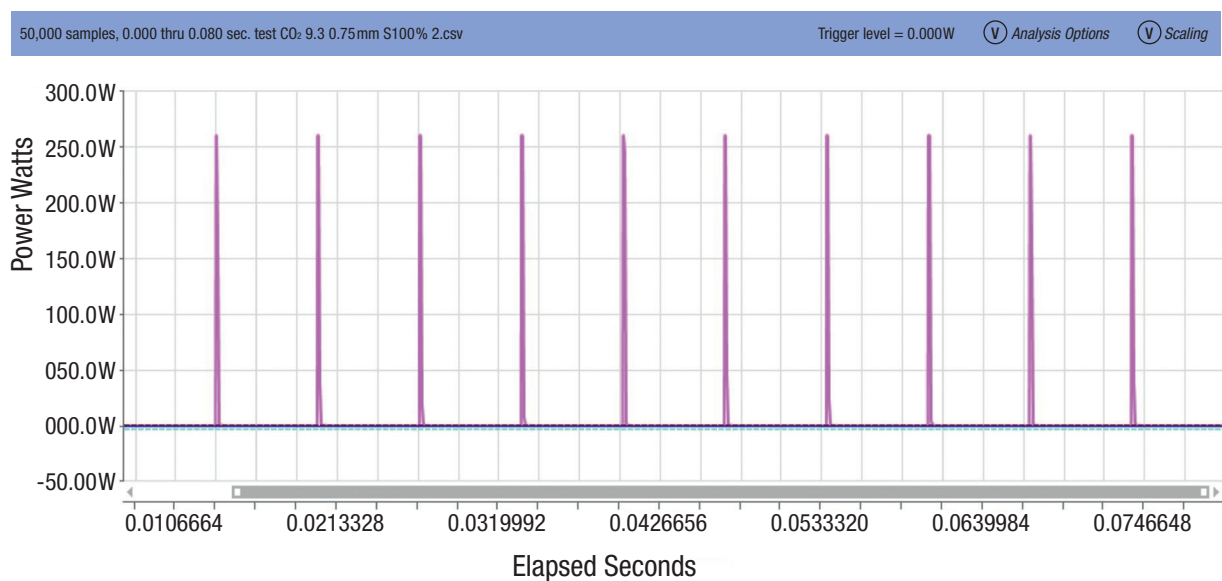


**Fig. 5:** Adult hard-tissue mode at 100 % power of the 9,300 nm Solea laser.

laser showed that mineral loss was reduced by 55 % compared with fluoride application.<sup>31</sup> However, it was reported that there was no increase in acid resistance in dentine when using 9,300 nm CO<sub>2</sub> lasers.<sup>32</sup> Further studies are needed to determine the clinical application of CO<sub>2</sub> lasers in caries prevention because there are vast variations in the parameters used.

Currently, the Solea 9,300nm CO<sub>2</sub> laser is the only CO<sub>2</sub> laser on the market that is approved by the FDA for dental hard-tissue ablation. Dental hard-tissue ablation is possible with minimal collateral tooth and pulpal damage.<sup>33–37</sup>

Power, pulse duration and frequency as adjustable parameters were discarded from the panel. They were replaced by spot size, power percentage and water percentage. This makes the unit user-friendly for operators without much understanding of laser parameters. The novel idea was implemented of using a digital rheostat foot pedal to change the power percentage, thereby controlling the speed of ablation. Dentists are familiar with using a foot pedal to control turbine speed. The presence of a continuous water spray is essential to prevent a rise in temperature and the possibility of irreversible damage to the pulp.<sup>38</sup> The clinical application of CO<sub>2</sub> lasers in pre-



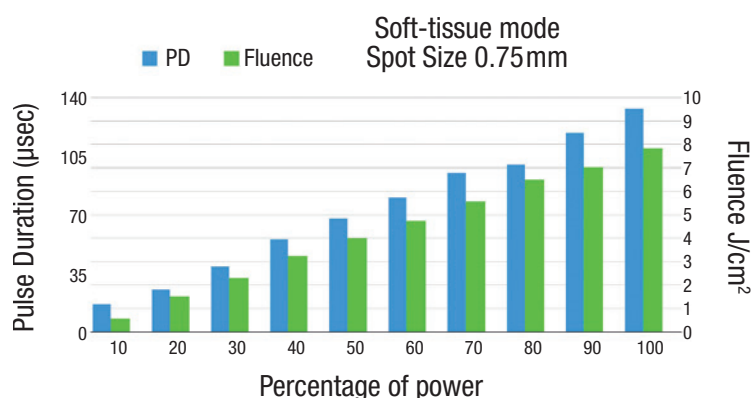
**Fig. 6:** A 9,300 nm carbon dioxide laser in soft-tissue mode with spot size of 0.75 mm and 100 % power (measured peak power: 260 W; repetition rate: 187 Hz).

ventative and restorative dentistry may be closer to being a reality.<sup>13</sup>

## Laser interactions with oral soft tissue and their clinical applications

Oral soft tissue is largely composed of water, which absorbs laser wavelengths in the mid-infrared (erbium lasers) and far-infrared spectra (CO<sub>2</sub> lasers) well. Penetration depth in water by CO<sub>2</sub> laser energy is in the region of 10 µm. This results in tissue interaction predominantly on the surface of soft tissue at 50 µm. Volumetric expansion from liquid to steam is in the ratio of 1:1,600. This rapid expansion results in vaporisation (ablation) of the soft tissue. Rapid thermal conduction of tissue around the vaporised zone results in protein denaturation, desiccation and shrinkage, and carbonisation of tissue. There are many advantages to performing soft-tissue surgery with a 10,600 nm CO<sub>2</sub> laser. Capillaries are effectively sealed and coagulated during ablation in surgical sites, resulting in minimal bleeding with a clearly visible operating field, which may reduce operation time. The laser surgical wound heals by secondary intention. The surgical site is decontaminated by laser energy with a low chance of bacteraemia and less suturing need. In all laser wounds beyond the ablation and coagulation zones, there is a zone of photo-biomodulation, which improves wound healing compared with scalpel surgery and electrosurgery. Hyaluronic acid is a chemical which plays a key role in wound repair. A higher level of hyaluronic acid is found in a CO<sub>2</sub> laser wound than a scalpel wound. Reduction in post-operative swelling, pain and scarring is achieved with the appropriate laser parameters and clinical technique. Patient acceptance is high, with less post-operative discomfort. Hence, the CO<sub>2</sub> laser was first used in oral surgery and in implant surgery, such as for excision, incision of soft tissue, pre-malignant lesion removal and pre-prosthetic surgical procedures.<sup>39,40</sup>

In orthodontics, a CO<sub>2</sub> laser can be used to perform frenectomies in children and teenagers<sup>41</sup> and removal of hyperplastic tissue around orthodontic brackets.<sup>33</sup> Gingivectomies, gingivoplasties,<sup>42</sup> de-epithelialisation for periodontal tissue regeneration,<sup>43</sup> soft-tissue crown lengthening and cosmetic gingival recontouring<sup>44</sup> are periodontal procedures for which a CO<sub>2</sub> laser can be used. Furthermore, CO<sub>2</sub> lasers can be used for mucocoele removal in soft tissue.<sup>45</sup> Pre-malignant lesions such as leukoplakia and oral lichen planus may be treated by excision for biopsy or ablation.<sup>46</sup> CO<sub>2</sub> lasers have also been used for removal of hyperplastic soft tissue and soft-tissue management around the implant in cases of peri-implantitis and implant uncovering of submerged healed implants.<sup>47</sup> In addition, CO<sub>2</sub> lasers can be used for tissue removal layer by layer (i.e. peeling) in melanin depigmentation of gingiva and vaporisation of vascular lesions. The advanced laser parameters of the 9,300 nm Solea CO<sub>2</sub> laser will give the operator even greater control in soft-tissue surgery.<sup>13</sup>




**Fig. 7:** Pulse duration and fluence in relation to the power percentage of a 9,300 nm carbon dioxide laser in soft-tissue mode with a repetition rate of 187 Hz.

## Conclusion

The 10,600 nm CO<sub>2</sub> laser is widely accepted for soft-tissue surgery applications. Although CO<sub>2</sub> lasers have been studied extensively in caries prevention, they have not been applied in clinical practice. The optical properties of 9,300 nm and 9,600 nm CO<sub>2</sub> wavelengths are suitable for dental hard-tissue treatment. Technological advancements in software and laser parameters will aid in new clinical application and technique development. CO<sub>2</sub> lasers as hard-tissue lasers will become more popular and more widely accessible to researchers and clinicians.

*Editorial note: This article was originally published by Springer International in Lasers in Dental Science (Luk K, Zhao IS, Gutknecht N, Chu CH. Use of carbon dioxide lasers in dentistry. Laser Dent Sci. 2019 Mar;3(1):1–9. doi: 10.1007/s41547-018-0047-y). It is reprinted here (with editing changes) with permission.*



## about the author



Hong Kong-based dentist **Dr Kenneth Luk** completed his BDS at the University of Liverpool. In addition, he obtained his diploma in General Dental Practice from the Royal College of Surgeon in England and an MSc in Lasers in Dentistry from the Aachen Dental Laser Center at RWTH University in Germany.

## contact

**Dr Kenneth Luk**  
Room 502, Winway Building  
No. 50 Wellington Street  
Hong Kong, China  
Phone: +852 2530 2837  
laserdentic@me.com





# Initial therapy of periodontitis using dental lasers

Dr Frank Liebaug, Germany

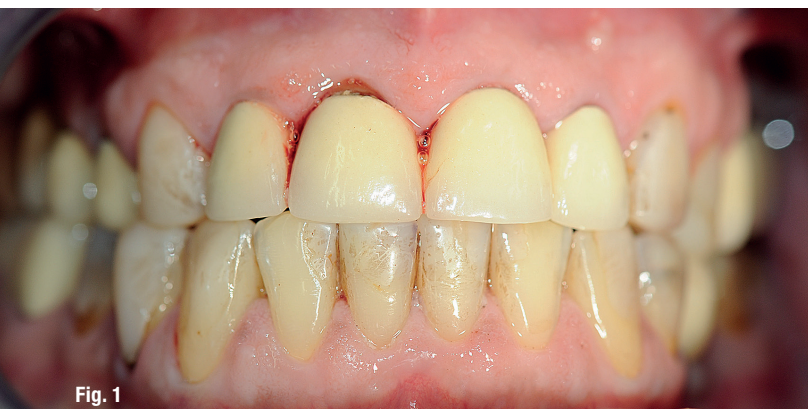

Fig. 1

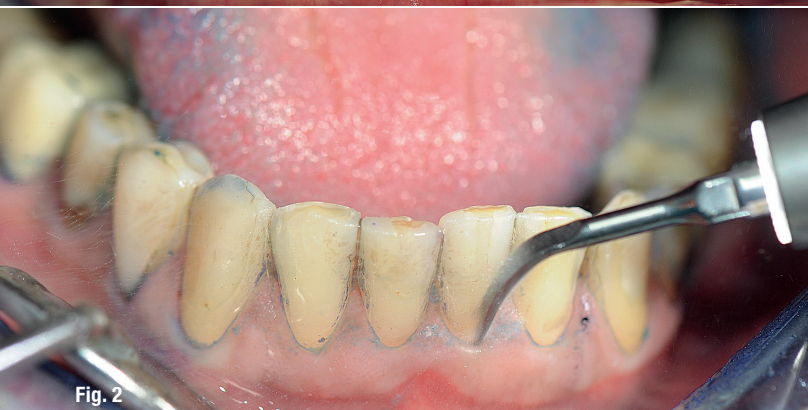

Fig. 2

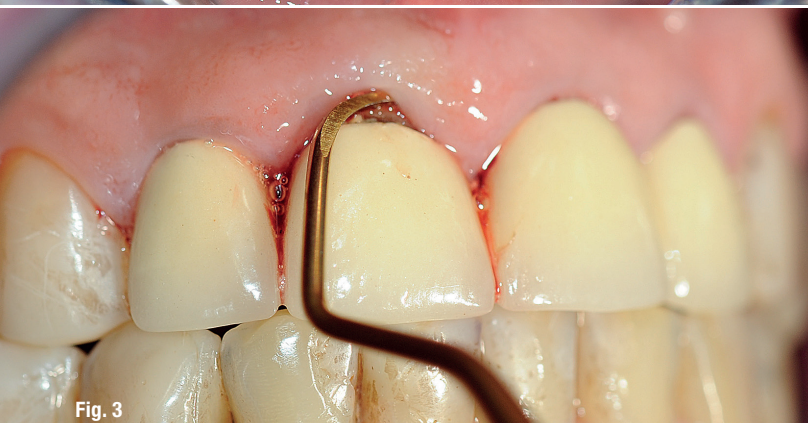

Fig. 3

**Fig. 1:** In the oral hygiene phase, mechanical cleaning is first carried out using ultrasonic scalers and polishing agents, protruding filling and crown margins are removed, and the actual prosthetic restoration is carried out after systemic periodontal therapy has been completed. **Fig. 2:** Ultrasonic scaler for mechanical debridement after staining with a plaque disclosing agent. **Fig. 3:** Breaking up the biofilm surface using scaling and root planing.

**Gingivitis and marginal periodontitis** are predominantly bacterial diseases. Periodontitis is a chronic, multifactorial inflammatory disease caused by the accumulation of bacterial biofilm on the tooth surface. It is promoted by an impaired local and/or systemic immune response.<sup>1</sup> Clinically, therapy must primarily have an anti-infective character. The reduction or elimination of this infectious disease is usually carried out by mechanical treatment of the affected tooth and root surfaces of the gingival pockets and adjacent soft tissue. Possible individual risk factors of the patient must be identified and eliminated as far as possible. In special cases, local or systemic antibiotic support is indicated.<sup>2</sup>

In our long-standing practice, adjuvant use of dental lasers of different wavelengths is an indispensable therapeutic option. Additional interdisciplinary cooperation with other specialist areas is always advisable. For some time now, knowledge about the possibilities of bacterial reduction by medical lasers has led to this treatment option being used to support local periodontal therapy.<sup>3</sup>

The new S3 guidelines on systematic periodontal therapy, presented at the German Dentists' Conference in November 2018, recommend adjuvant systemic antibiotic administration with subgingival instrumentation after careful evaluation of the severity of the condition and individual co-factors. The efficacy of supportive systemic antibiotic administration in combination with mechanical periodontal therapy has been largely proved.<sup>4</sup> Nevertheless, antibiotics still have numerous unexplored influences on human microbiota and pose the risk of resistance development. The scientific findings of recent years on the one hand and new approaches for holistic treatment on the other hand drive the search for treatment strategies for successfully treating patients with marginal periodontitis without additional antibiotic therapy. In recent years, the number of people refusing antibiotics, but also patients with intolerance or resistance, has increased steadily. With the development of antimicrobial photodynamic therapy (aPDT) and new laser technologies, it has become possible to inactivate or destroy microorganisms that are difficult or impossible to reach mechanically without damaging the surrounding tissue.<sup>5</sup>

## Treatment planning and sequence

In principle, the sequence of periodontal therapy is similar for all forms of the disease. It is divided into stages or phases depending on the spread, severity and duration of the disease. In detail, however, the therapy shows remarkable differences, which depend on the disease type, the patient's attitude, age and general illnesses, and the preferences of the clinician. Naturally, all roads lead to Rome.

### Pre-phase of periodontitis treatment:

#### Systemic examination and oral hygiene

Prior to the actual therapy, anamnesis of the patient's systemic health, a careful diagnostic assessment and radiographic examination are carried out in order to make a preliminary diagnosis. There are cases, such as gingival pocket abscesses, in which local emergency therapy needs to be carried out without any delay. In these cases, we perform laser treatment in our practice immediately. Creating optimal oral hygiene and establishing cooperation with the patient regarding future appointments are vital for long-lasting treatment success. Professional supragingival plaque and calculus removal, the removal of iatrogenic risks and bacterial hiding places, and instruction in simple, yet effective plaque control quickly improve the overall oral situation.

### First and second phases of the initial treatment:

#### Causal, antimicrobial, anti-infective

After the initial findings and a preliminary diagnosis, the findings, diagnosis and prognosis are verified in the context of the initial treatment phase. Radiographic examination is also a prerequisite for determining an exact diagnosis. At the beginning of the initial treatment, the team of clinicians focus on oral hygiene. This is often described by some authors as being part of the pre-phase. After plaque and inflammation reduction in the pre-phase through oral hygiene by the patient and the dentist and, as a result, regression of greatly swollen gingival areas, clinical assessments should be made (probing depth, attachment loss), which serve as the foundation for the definitive diagnosis, the prognosis and developing the final treatment plan.<sup>2</sup> While the measures of the pre-phase are carried out with all patients, the treatment modalities can deviate in the second phase of the initial treatment.

In the second phase, closed root cleaning can be performed on the one hand—with or without the use of medication or laser of suitable wavelengths—and on the other hand, direct surgical treatment can be started, depending on the individual case. Periodontal surgical intervention without preceding non-surgical therapy is only indicated in rare cases. In 98% of the cases treated in our practice, we initially prefer closed non-surgical pocket therapy and, whenever the patient gives his or her consent, the use of dental lasers. In mild cases, especially with chronic periodontitis, closed and laser-assisted ther-

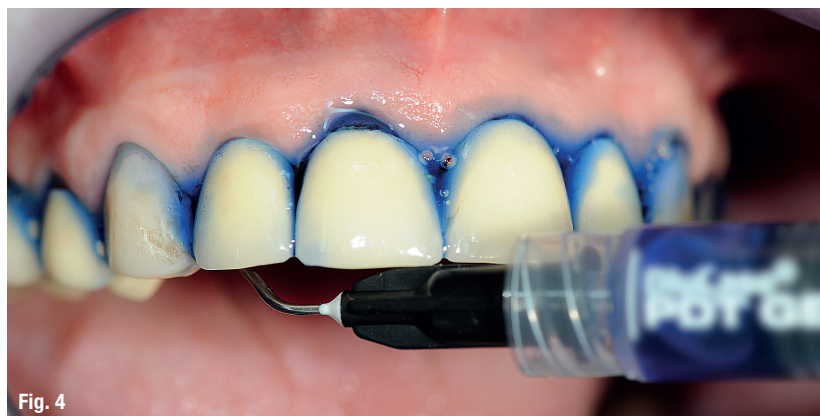

Fig. 4

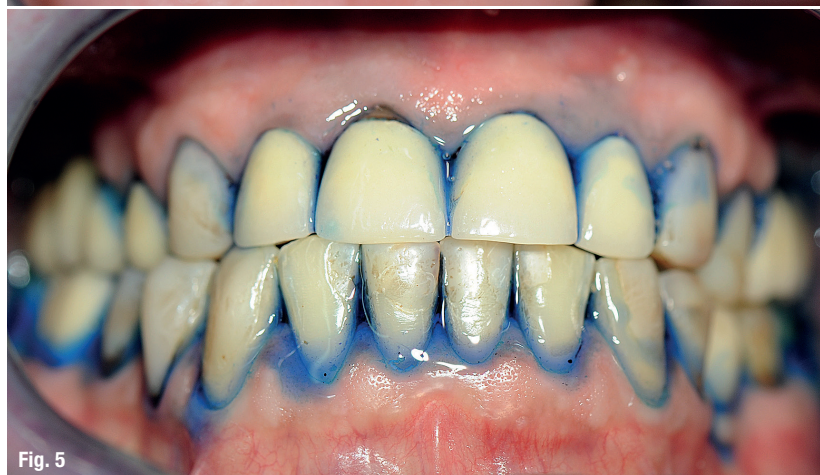

Fig. 5

**Fig. 4:** Insertion of photosensitizer into all gingival pockets for full-mouth disinfection. **Fig. 5:** Excess photosensitizer rinsed off before using laser light.

apy are often sufficient—provided the patient cooperates. In severe cases, it is possible to move directly from an intensive pre-phase to surgical corrective therapy. In this regard, the updated classification of periodontal diseases can help clinicians decide. However, the content of this classification is not to be discussed further in this article. In the clinical daily routine, closed and open therapies are applied one after the other. As a consequence, less periodontal tissue has to be treated openly and tissue loss appears to be lower post-operatively.

### Treatment goals of non-surgical anti-infective therapy

The objective of traditional non-surgical therapy is to eliminate microorganisms causing inflammation from the pocket and the adjacent tissue, to achieve teeth with a clean, smooth, bio-acceptable root surface and, in rare cases, to remove diseased, possibly infected tissue.<sup>6-9</sup> However, complete elimination of all pathogenic microorganisms is not possible—no matter which method is used. Even the removal of diseased, infected tissue through curettage is, according to the latest findings, no longer indicated, with rare exceptions. In 2019, Jockel-Schneider et al. reported on the adjuvant systemic





Fig. 7

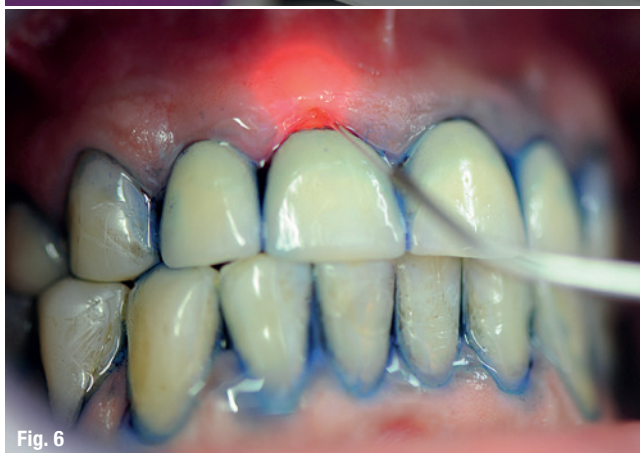

Fig. 6

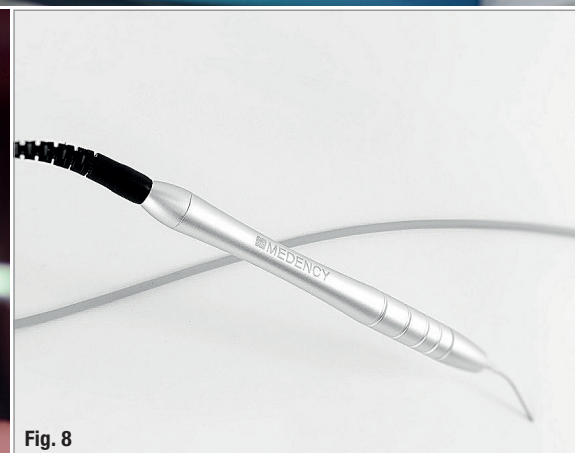

Fig. 8

**Fig. 6:** With flexible fibre, the photosensitiser is activated by laser light of a suitable wavelength and the bacterial membrane is destroyed as a result of the formation of oxygen radicals. **Fig. 7:** Example of a user-friendly touch screen for selecting the various therapy options already stored in the programme by the manufacturer (Schneider Dental). **Fig. 8:** Flexible laser fibres also allow access to the bifurcation area or where the tooth position is unfavourable.

administration of antibiotics with subgingival instrumentation, which, however, must always be accompanied by mechanical destruction or rupture of the bacterial biofilm in order to improve its effectiveness.<sup>4</sup>

## Laser in periodontics

This is where dental lasers come into play. In the context of periodontal treatment, three different laser types are commonly used: Nd:YAG laser, the different types of diode lasers and the Er:YAG laser. More than 20 years ago, the Nd:YAG laser was used to decontaminate periodontal pockets, and in recent years, various diode lasers have become established. The Er:YAG laser has clearly receded into the background in its use for periodontal therapy, although it was even used for removing dark concretions on the root surface, using a so-called feedback system. In principle, the Er:YAG laser is very well suited for de-epithelialisation or for ablating both hard- and soft-tissue. Lastly, it was possibly the high acquisition costs of an Er:YAG laser that brought the diode laser into the foreground of various therapy

concepts. With diode lasers, different wavelengths need to be distinguished: wavelengths of 660nm, which are only used in connection with a photosensitiser; and 810, 940 and 980nm, which are most commonly used. With the 810nm, both blue photosensitisers and indocyanine green can be used for aPDT. A diode laser with a 980nm wavelength does not require any additional dye and it can be used without additional agents both for decontaminating periodontal pockets and for cutting soft tissue. In our practice, however, the use of a combination of a photosensitiser and laser therapy has been proved, particularly in the bifurcation area, which is usually difficult to reach, and generally in the posterior region. When lasers with wavelengths of 940, 980 or 1,064nm are solely employed for treating periodontal pockets, higher energy values are used and, as a result, a thermal effect in the tissue is achieved. This treatment, therefore, requires local anaesthesia, which is not usually required for aPDT (the combination of a photosensitiser and laser energy). Manufacturers of dental laser systems often provide various scientific studies upon request if clinicians are interested in specific products.

# DER NEUE SKYPULSE®:

DIE IDS NEUHEIT: NOCH KOMPAKTER,  
NOCH BENUTZERFREUNDLICHER!

Für PIPS®  
geeignet!

Fotona®  
choose perfection

Exklusiv bei Henry Schein Dental

## HENRY SCHEIN DENTAL – IHR PARTNER IN DER LASERZAHNHEILKUNDE

Wir bieten Ihnen ein breites und exklusives Sortiment marktführender  
Lasermodele verschiedener Hersteller an.

Unsere Laserspezialisten beraten Sie gern über die vielfältigen Möglichkeiten  
und das für Sie individuell am besten geeignete System.

### Bei Henry Schein profitieren Sie vom Laserausbildungskonzept!

Von der Grundlagenvermittlung über hochqualifizierte Praxistrainings  
und Workshops zu allen Wellenlängen bis hin zu Laseranwendertreffen.

Unsere Laser-Spezialisten in Ihrer Nähe beraten Sie gerne.

Marcus Dahlinger  
Mobil +49 172 8419167 oder  
laser@henryschein.de

Informationen direkt von der IDS:



[www.henryschein-mag.de/  
ids-neuheiten/skypulse](http://www.henryschein-mag.de/ids-neuheiten/skypulse)

Erfolg verbindet.

 **HENRY SCHEIN®**  
DENTAL





Fig. 9

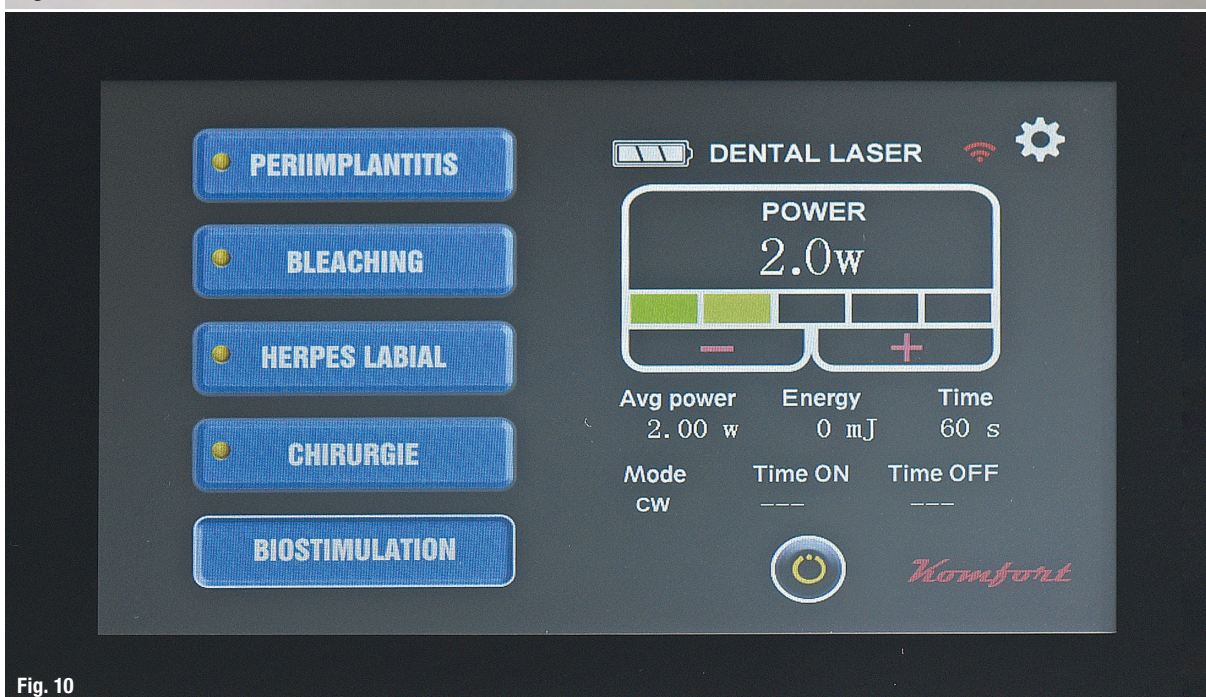


Fig. 10

**Fig. 9:** Example of a therapy handpiece for transmucosal dye activation and/or biostimulation ... **Fig. 10:** ... and the according settings on the screen.

Owing to the good clinical experience we have had using aPDT, I would like to explain the basic procedure of this therapy on the basis of the following case study. After the universally valid hygiene measures at the beginning of the initial therapy (Figs. 1 & 2), the laser is additionally used for removing subgingival calculus and plaque (Fig. 3). It is advantageous if the pocket bleeding can already be reduced to a minimum in this phase so that the dye can successfully attach itself to the bacterial surface and is not diluted by bleeding or washed out of the pocket. In addition, blood leads to the absorption of laser light energy, which sometimes poses an additional problem in the case of acute inflammation. First, the dye (photosensitiser) is applied to the periodontal pockets using a blunt cannula (Fig. 4). After an exposure time of 1 to 2 minutes, the excess dye is rinsed off the tooth surfaces (Fig. 5). Irradiation is then carried out in the area of the pocket by introducing suitable flexible laser fibres (Figs. 6–8). Transgingival beam application with a handpiece with a

diameter larger than that of the exit window (8–12 mm) is also used in our practice. Yet, experience has shown that laser light energy and its biological effect are significantly weakened (Figs. 9 & 10). In addition to photodynamic processes as part of a Low Level Laser Therapy, effects at the cellular level are discussed later in this article.

In our daily clinic routine, we observed a significant increase in wound healing immediately in the post-operative period compared with a control group of patients who were treated without lasers. In our practice, this became apparent through a quicker reduction of the probable pocket depths.<sup>10</sup> The laser fibres used for pocket decontamination are recommended for single use and are sterile-packed, depending on the manufacturer. Some manufacturers offer disposable tips that are attachable to the large-diameter light stick. Despite sterilisation procedures, multiple use is not recommended for hygienic reasons. In periodontal therapy, laser light not only treats



inflamed tissue but also ensures that the bacteria it contains are immediately and efficiently combated, which also virtually eliminates the risk of bacteraemia.<sup>11</sup> However, the optimal result of systematic periodontal therapy is not only the elimination of inflammatory processes but also the regeneration of the periodontal structures. The less tissue is injured during treatment, the faster regeneration can begin.

## Antimicrobial photodynamic therapy


In recent years, aPDT for inactivating pathogenic biofilm has established itself as a minimally invasive technique as an alternative to the classical disinfection procedures used in dentistry. It can be used in an adjuvant fashion for treating acute and chronic infections in the various phases of implant treatment. With aPDT, complication-free and immediate bacterial reduction in the infected tissue is achieved by a photodynamic reaction mechanism. A sterile light-active dye solution is applied to the periodontal pockets as a photosensitiser. During the exposure time of at least 60 to 180 seconds, photosensitiser molecules diffuse into the biofilm and attach themselves to negatively charged centres of the bacterial wall. Clinically, the breaking open of the biofilm surface by means of previous scaling has been proved. Afterwards, as an essential step before laser light application, photosensitiser residues are carefully rinsed off. The adsorbed photosensitiser molecules are then activated unhindered by means of non-thermal laser light.

A quantum mechanical transfer process produces singlet oxygen molecules at the photosensitiser molecules through energy absorption and spin change. This potent oxidation agent causes lethal, irreversible damage to the bacteria on the bacterial wall through the oxidation of membrane lipids. Fungi too are usually destroyed according to the same principle. This achieves photodynamic decontamination of the infected pocket tissue and the treated root surface. Eukaryotic cells are not stained, owing to their membrane potential, so no singlet oxygen is formed on them, which makes this particular kind of treatment rather gentle.<sup>12</sup> So far, various studies on photodynamic therapy have been published. The most common therapy concept is a combination of closed curettage with dye and dental lasers.<sup>13–16</sup> One must also mention the treatment potential of indocyanine green in combination with an 810nm wavelength laser. A decisive advantage of this dye is its effectiveness against Gram-positive and Gram-negative bacteria, as well as against numerous viruses and fungi. The iodine-free and, thus, non-allergic component has also been highlighted by other authors.<sup>17</sup> In contrast to the established sensitiser methylene blue (absorption maximum at 660nm), this dye has no intrinsic effect and is only activated and degraded when laser light enters. It is not absorbed by the intestinal mucosa.

## Conclusion

Today, there is hardly any field in modern dentistry that could not benefit from the use of a laser, either as a replacement of conventional therapy forms or as a supportive measure. Not only can laser treatment improve existing therapy concepts in the various areas of dentistry, but, according to our experience, it can also increase the comfort of the patient during surgery owing to its minimally invasive and tissue-conserving nature.

Wavelengths of 660, 810, 980 and 1,064nm are clinically suitable for supporting the initial therapy of marginal periodontopathies. aPDT in combination with diode lasers with wavelengths of 660 and 810nm represents an alternative method to the known pharmacological and chemical decontamination procedures for the prevention and treatment of peri-implant infections. An adjuvant systemic antibiotic administration with subgingival instrumentation must be decided by the dentist according to the patient's individual risk profile. Since no resistance to individual bacterial species is known to date in laser applications, in particular aPDT, repeated laser decontamination of inflamed pockets can also be carried out within the framework of periodontal therapy in order to offer the organism better conditions for healing and regeneration. The various laser devices available on the market demand sufficient instruction and training efforts from the dentist's side. Thus, after completing a course to become a laser safety officer, which is prescribed by law for operating a dental laser, we strongly recommend attending user courses that entail practical exercises or live surgeries.



## about the author



Germany-based dentist **Dr Frank Liebaug** is specialised in laser dentistry, implantology and regenerative periodontal therapy, among others. He graduated from the University of Leipzig and the Medical Academy in Erfurt in Germany in 1990 and received his PhD in 1992. Since 2010, he has been giving guest lectures at the University of Shandong in China. Today, he works as a private practitioner in a joint practice in Steinbach-Hallenberg in Germany.

## contact

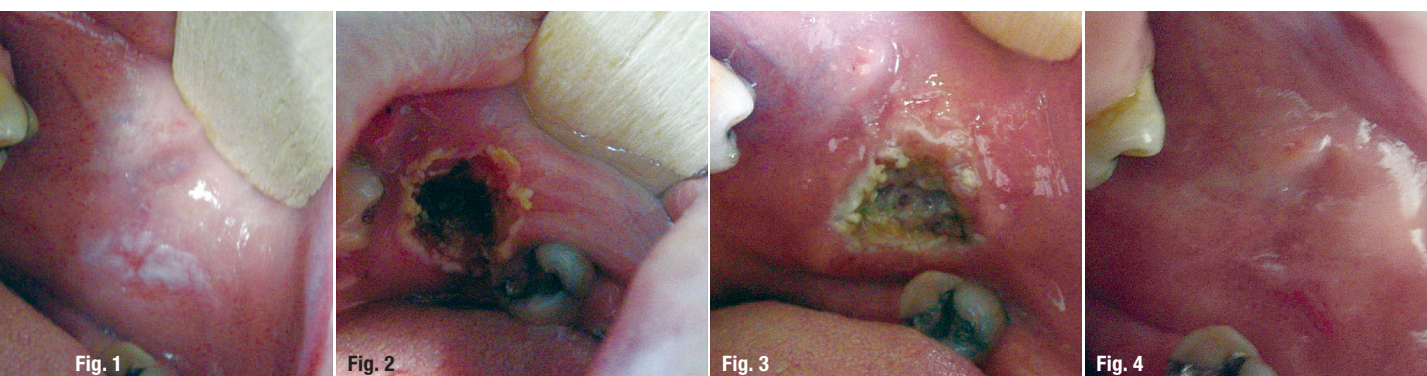
### Dr Frank Liebaug

Private practice  
Arzbergstraße 30  
98587 Steinbach-Hallenberg, Germany  
info@ellen-institute.org



# Treatment of oral leukoplakia with a 980 nm diode laser

Dr Maziar Mir, Prof. Norbert Gutknecht, Dr Masoud Mojahedi, Germany;  
Dr Jan Tunér, Sweden & Dr Masoud Shabani, Iran



**Fig. 1:** Oral leukoplakia was diagnosed pre-op. **Fig. 2:** Clinical situation immediately after surgery. **Fig. 3:** Clinical situation one day after surgery. **Fig. 4:** Clinical situation at follow-up one month after surgery.

**Leukoplakia is a common precancerous lesion** of the oral cavity. It is defined as “a predominantly white lesion of the oral mucosa that cannot be characterised as any other definable lesion”.<sup>1–3</sup> Clinically, leukoplakias are divided into homogenous (a thin, flat and uniform white plaque with at least one area that is well demarcated, with or without fissuring) and non-homogeneous lesions that are characterised by the presence of speckled or erythroplakic and nodular or verrucous areas.<sup>4</sup> Various non-surgical treatments (including the use of carotenoids [beta-carotene, lycopene]; vitamins A, C and K; fenretinide; bleomycin; photodynamic therapy) and surgical treatments (including cryosurgery, electrocautery, laser ablation) have been reported.<sup>5</sup> This article presents successful results of oral leukoplakia treatment with a 980 nm diode laser.

## Case report

A 55-year-old female patient with a white discoloration of her buccal mucosa that had been diagnosed as oral leukoplakia was referred for treatment with laser. The patient's medical history showed no systemic medical problems, no allergies, no prescribed medications or drugs that the patient was taking and no history of past surgical procedures, which was why the patient did not need to be referred for medical consultation. The oral and maxillofacial examination of the patient revealed no

temporomandibular joint dysfunction, myofascial disturbances or parafunctional habits. The patient maintained good overall dental hygiene. In terms of the clinical findings, there was white pigmentation on the buccal mucosa that was flat, well demarcated and painless for the patient. Based on these observations, oral homogenous leukoplakia was diagnosed (Fig. 1). Laser-assisted surgery with a 980 nm diode laser was recommended to the patient as a treatment approach.

## Procedure

After completion of the consent form, the operation area was anaesthetised through infiltration with 2% lidocaine with 1:80,000 adrenaline (1.8 ml; Darou Pakhsh Pharmaceutical). The patient's information, such as the examination sheet and the completed consent form, was reviewed. The controlled area was defined and laser signs were properly displayed to secure the operating room. The eye protection (safety glasses) of the patient, her guardian and the assistant was checked. The patient's mouth was then rinsed with a 0.2% chlorhexidine oral rinse (Shahre Daru Pharmaceutical) for a duration of one minute. Then the oral leukoplakia was removed by means of a high-power diode laser (GIGAALASER). The laser was set to contact mode and the following parameters: wavelength of 980 nm, power of 1.5 W, 400 µ fibre, initiated fibre and continuous wave.

## After the procedure

The patient was advised to keep the area around the surgical site as clean as possible. She was also told to avoid foods and liquids that may have irritated the sensitive tissue and made it painful to eat. If necessary, over-the-counter analgesics were to be taken. The laser settings were documented in the patient's medical file.

Immediately after surgery, excellent oral leukoplakia removal was observed, with no bleeding, no carbonisation and no char (Fig. 2). The patient did not experience any discomfort and was satisfied. The first post-operative follow-up was scheduled one day after the procedure. As expected, healing was progressing well and there were no signs of swelling or pain (Fig. 3). At the follow-up after one month, a successful outcome was clinically observed (Fig. 4).


## Discussion

Diode lasers are used extensively in many dental practices.<sup>6</sup> Laser-tissue interaction with a high-power diode laser is based on photothermal effects.<sup>7</sup> According to Nammour et al., the removal of a minimum of 1 mm in lesion depth and 3mm of surrounding healthy tissue can lead to the highest treatment success rate.<sup>8</sup> Natekar et al. argue that diode laser or carbon dioxide laser surgery seems to be more effective than cryotherapy.<sup>9</sup> Monteiro et al. report favourable experiences regarding oral leukoplakia surgery with an Er:YAG laser.<sup>10</sup> The 980nm wavelength has low tissue penetration, which can be advantageous for removing superficial structures and protecting surrounding healthy tissue. Laser surgery of oral leukoplakia may be helpful in reducing malignant transformation of lesions. However, each patient should be aware of the recurrent nature of the lesion, which is why periodic monitoring is mandatory.<sup>11,12</sup> Removing oral leukoplakia

through laser surgery is usually a quick procedure that typically does not result in bleeding, pain (in most cases) or oedema. Moreover, there is usually no need for analgesics, since lasers have analgesic effects on tissue. Since oral leukoplakia lesions tend to transform into malignant lesions, this procedure is traditionally classified as an advanced laser procedure.

## Conclusion

The use of a 980nm diode laser following the treatment protocol which is described in this article has proven to be a successful alternative for treating patients with homogenous leukoplakia. Given the recurrent nature of the lesion, however, long-term follow-up appointments should be considered mandatory for the patient and should be taken seriously by the treating clinician.



## about the author

**Dr Masoud Shabani** is a lecturer at the Department of Community Dentistry at the School of Dentistry of the Ardabil University of Medical Sciences in Ardabil in Iran.

## contact

### Dr Masoud Shabani

Department of Community Dentistry  
School of Dentistry  
Ardabil University of Medical Sciences  
Ardabil, Iran  
m.shabani@arums.ac.ir



AD

# BECOME AN AUTHOR

for laser — international magazine of laser dentistry

Interdisciplinary and close to the market



www.oemus.com



Become part of a successful network and benefit from a wide reach and high level of awareness

Your benefits:

- author's profile at ZWP online
- specimen copies
- offprints
- speaking engagement\*

Please contact Mr. Georg Isbaner:  
g.isbaner@oemus-media.de  
Phone: +49 341 48474-123

\*according to the required profile





# Facial swelling caused by infected teeth

## Dual wavelengths for immediate healing

Dr Imneet Madan, UAE

**Primary teeth retain their position** in children's mouths until they reach the age of 10 to 12, when molars exfoliate. Until then, it is vital for primary teeth to stay cavity-free and in a healthy condition. A mindset that we encounter quite commonly is that primary teeth do not necessarily need to be treated, as they are to fall out anyway. Yet, the contrary is true: it can be argued that primary teeth play a vital role in paving the way towards healthy permanent dentition.

They have an important purpose and are of great significance for children. They contribute to a harmonic cosmetic smile, building children's self-confidence as a consequence—and, of course, they are vital for creating beautiful childhood photographs. Furthermore, primary teeth serve as natural placeholders for permanent teeth to erupt in the right position. Besides that, they are vital for digestion, since properly chewed food is digested better. Primary teeth are also important for the jaws to develop properly. Additionally, they help children to express themselves verbally, and they keep children from developing parafunctional habits, such as tongue thrusting or mouth breathing. Given these vital functions of primary teeth, it is by all means necessary to retain them and to refrain from premature extractions.

When dental health is compromised and the resulting conditions remain untreated, there is a strong possibility that permanent teeth will erupt into an unhealthy den-

tal environment, thus, compromising overall health. Good oral hygiene and well-maintained primary teeth, however, allow permanent teeth to erupt in a healthy fashion. Chronic untreated caries is the primary cause of long-standing infections. It goes without saying that the best mode of management is to prevent the onset of the condition in the first place. However, if dental decay and the associated condition are already present in a patient and have reached the stage of chronic infection in the periapical area, which in turn results in facial swelling, it is mandatory to consider treatment options.

Chronic irreversible pulpitis is one of the primary causes of facial swelling, gingival infections, and abscesses. Untreated primary molars with gross decay allow for bacteria to enter and accumulate inside the pulp, leading to the death of the pulp as a consequence. This is referred to as necrosed or non-vital pulp. Bacteria feed on pulp contents and produce exudate that seeps into the facial spaces, often leading to face swelling.

### Case reports

This article will depict two cases in which facial swelling was caused by grossly decayed molars in children. In both cases, laser-assisted root canal therapy was suggested as an alternative to extraction in order to retain the teeth. Both children were under periodic follow-up at the time of writing.

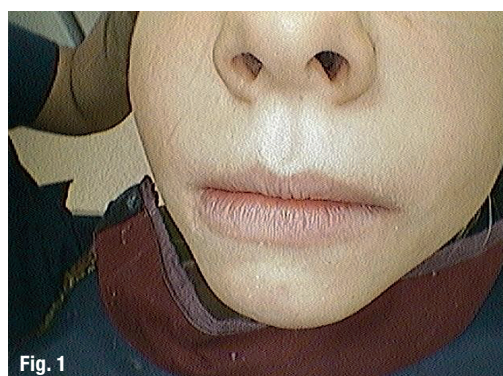


Fig. 1

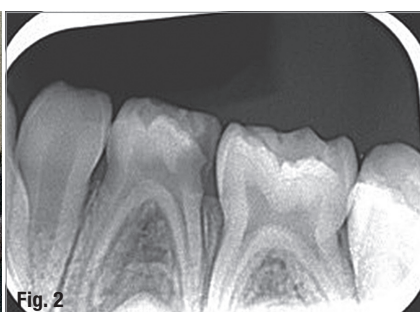

Fig. 2

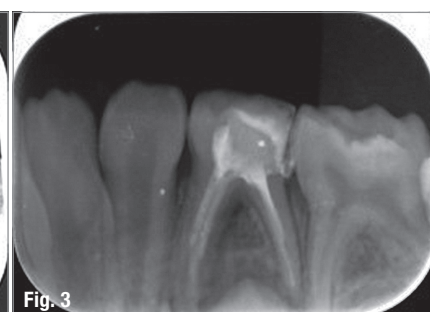

Fig. 3

**Case 1—Fig. 1:** Clinical situation at first appointment with swelling visible. **Figs. 2 & 3:** Intraoral radiographs taken prior to treatment.

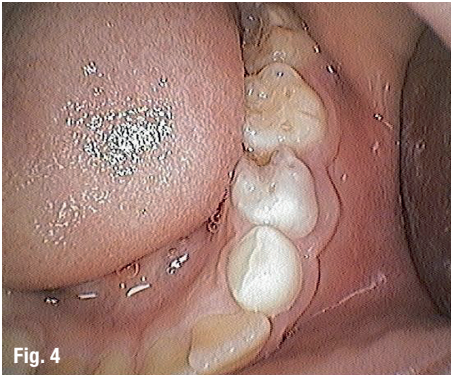


Fig. 4

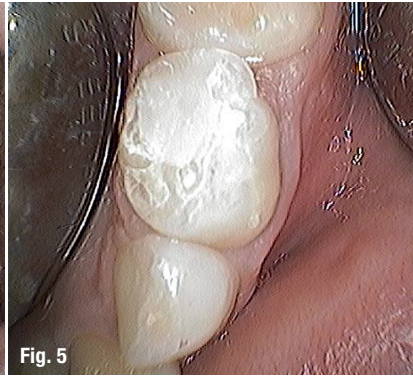


Fig. 5

**Case 1—Figs. 4 & 5:** Intraoral examination revealed Grade II mobility of tooth #74 and a periapical infection caused by carious decay.

### Case 1

An 8-year-old girl presented with the left half of her face swollen (Fig. 1). She complained about pain when chewing and continuous discomfort. The child showed mild symptoms of fever. Upon intraoral examination, it was found that tooth #74 had Grade II mobility and periapical swelling was present (Figs. 2 & 3). Intraoral periapical radiographs showed a widening of the periodontal ligament in the periapical area (Figs. 4 & 5). The tooth was tender to percussion and the child was in discomfort owing to infection and swelling extending up to the lower jaw. In this case, the submandibular swelling was primarily caused by long-standing carious decay that extended into the pulp, resulting in a periapical infection.

### Case 2

A 4-year-old boy came to our surgery with his face swollen in the area around a maxillary right posterior tooth (Fig. 6). The swelling extended from the upper right cheek to his ears and lower eyelids. The boy had a fever and he had not slept well the night before the appointment. Upon intraoral examination, it was noted that tooth #54 had Grade I mobility and that it had an old filling. Intraoral periapical radiographs (Figs. 7 & 8) and the medical history of the patient revealed that a deep filling with indirect pulp capping had been done approximately five months before, in August 2018. At the time the filling was done, dental decay had been in close proximity to the nerve, but the procedure was carried out nonetheless.

## Before the treatment

### Treatment options

Two options were proposed for treating the compromised primary tooth. The first approach would involve tooth extraction followed by the insertion of a space maintainer. The second option was laser-assisted root canal therapy. Yet, a successful treatment outcome could not be guaranteed with this option. In the case of a reinfection, the first option would have to be seriously considered. Scientific research has shown that bacteria remains in the root canals to a depth of up to 1,000µm. Conventional root canal therapy is able to clean canals up to this depth. With laser-assisted treatment, however, canals can be cleaned to a depth of 600–800µm. The two treatment options, as well as the associated costs, were explained to the parents. In both cases, the parents opted for the laser-assisted root canal therapy.

### Informed consent

Owing to the nature of the pathology, only an uncertain prognosis could be made. The parents understood that, in the case of failure, the teeth would need to be extracted. The treatment costs for both approaches were thoroughly explained to them. Consent forms for the approach that was agreed on were completed and signed.

## Treatment sequence

### Dental behaviour management

In Case 1, the girl was able to cope very well with only basic behaviour manage-

# BECOME AN AUTHOR

for ceramic implants  
—international magazine of ceramic implant technology

Interdisciplinary and close to the market



www.oemus.com

Fax:  
**+49 341 48474-290**

☐ Yes, I want to become an **author** for ceramic implants—international magazine of ceramic implant technology. I would like to submit an article on the following topic:

Please send back your fax form or contact

Mr **Georg Isbaner**: g.isbaner@oemus-media.de

Phone: +49 341 48474-123

Last Name, First Name

Street, ZIP, City

Phone, E-Mail

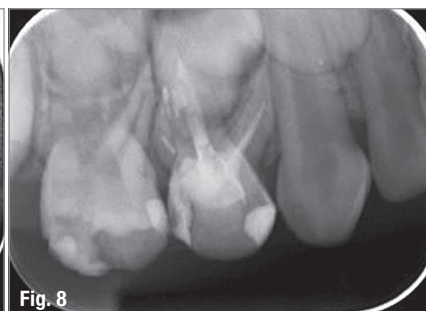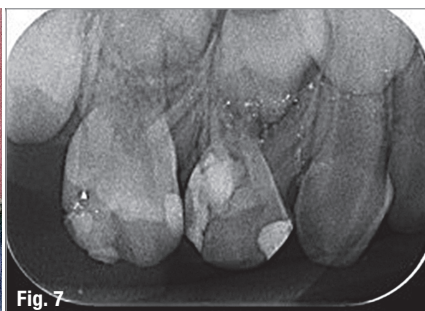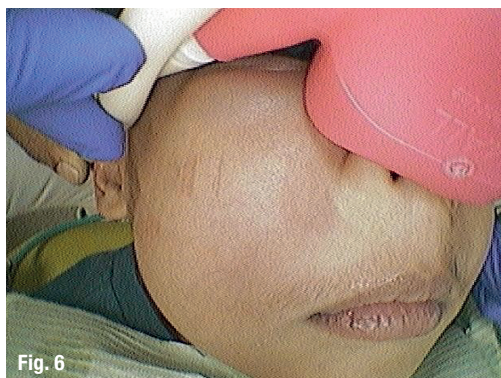Stamp

laser 2/19

**OEMUS MEDIA AG**

Holbeinstraße 29 · 04229 Leipzig · Germany  
Phone: +49 341 48474-0 · info@oemus-media.de





**Case 2—Fig. 6:** Swelling extended from the upper right cheek to the patient's ears and lower eyelids. **Figs. 7 & 8:** Intraoral radiographs taken prior to treatment.

ment techniques, whereas in Case 2, conscious sedation with nitrous oxide was needed (Fig. 9). Paediatric dentistry revolves majorly around how we communicate and present the individual treatment steps to children that are about to be treated. Surgical terms should be euphemised and communicated in a child-friendly manner. For instance, a nasal mask can be referred to as “happy air”, a laser as “popping light”, caries as “sugar bugs”, a dental cavity as “hole”, a cotton roll as “tooth pillow”, irrigating the canals as “washing the sugar bugs”, obturation as “putting cream in the tooth” and applying tooth filling material as “closing the hole”.

#### Neurolinguistic programming

In the cases described here, neurolinguistic programming was used as a way to obtain the children's attention and cooperation and to have them follow deep-breathing instructions. In combination with conscious sedation through nitrous oxide, neurolinguistic programming works well for calming down children ahead of treatment. In both cases, treatment started already at the first appointment owing to severe swelling. The procedure began five minutes after administering sedation in Case 2. The amount of administered nitrous oxide was slowly increased to 55%. During treatment, a movie was shown overhead for the purpose of distracting the children. Since both children were able to listen attentively after the treatment, the steps for the next visit were commu-

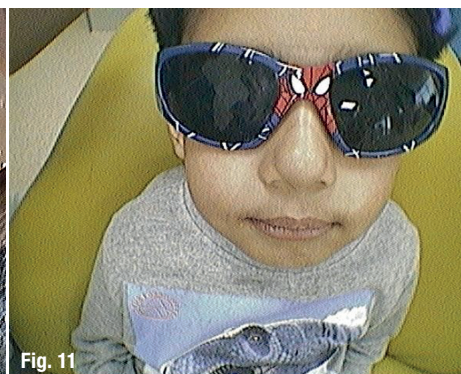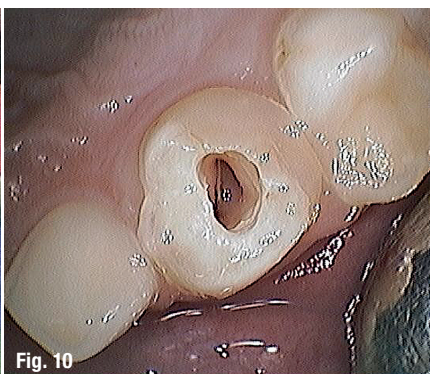
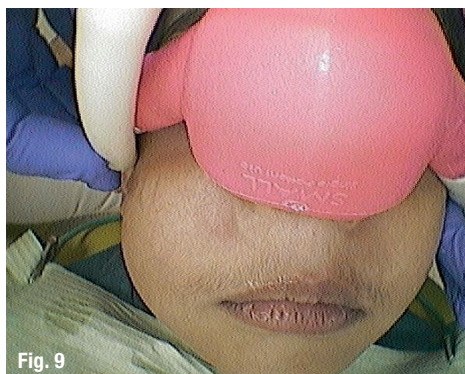nicated to them. Before leaving the practice, they were given a small reward for behaving well and listening attentively during the appointment, which hopefully had a positively reinforcing effect.

#### Nitrous oxide

Nitrous oxide, commonly known as “laughing gas”, was administered in order to relax the receptors. It has an analgesic or anxiolytic effect, which causes temporary depression of the central nervous system. It is absorbed rapidly and remains relatively insoluble in any tissues in the body. At the end of the procedure, 100% oxygen is used to flush out the nitrous oxide. There is minimal impairment of bodily reflexes.

#### Surgical procedure

The Er,Cr:YSGG laser, with the MX7 tip, was directed to the occlusal surface and set to the following parameters: 2,780nm, 3.75W, 25Hz, water 80 and air 60. Rotary instruments were used to enlarge the canals up to ISO #35. Intermittent irrigation with saline and chlorhexidine was done. For sterilising the canals initially, the Er,Cr:YSGG laser, with the RFT2, was set to 2,780nm, 1.25W, 50Hz, water 24 and air 34. Paper points were then used to dry the canals. A diode laser in continuous wave mode was then used, set at 940nm, 1.5W, 2mm/second, four to five turns in circular motion. At that point, an open dressing was put on to the site.



**Case 2—Fig. 9:** Nitrous oxide was used to calm the patient down. **Fig. 10:** The filling in tooth #54 was removed. **Fig. 11:** The procedure was completed after three appointments.



At the second appointment, two days later, the open dressing was removed. The canals were re-irrigated with saline and chlorhexidine. Both erbium and diode lasers were used to sterilise the radicular and periapical areas. In Case 1, the canals showed no bleeding and were completely dry. Zinc oxide eugenol obturation was carried out, followed by a base filling with dental cement (GC Fuji IX GP, GC) and composite filling on top. In Case 2, since the swelling had not regressed completely, it was decided to place a temporary filling first (Fig. 10).

In Case 1, the procedure was completed after two appointments, whereas in Case 2, it was complete after three (Fig. 11). There was no need to prescribe antibiotics post-operatively. Periodic follow-up appointments were scheduled for both patients, with the first starting three months after the treatment. Stainless-steel crowns were prospectively planned in the case of no further reinfections.

## Discussion

### Microbiology of periapical infections

The microbiology of fistulas is complex. The deep areas around the periapical region are low in oxygen, allowing only anaerobic bacteria to dwell there. They cause pain, swelling, tenderness and exudation of pus. A high prevalence of *Enterococcus* species and *Porphyromonas gingivalis* is found in the necrotic pulp of 2- to 5-year-old children. *P. gingivalis* has been found to affect about 27 % of primary teeth. *Prevotella nigrescens*, *Prevotella intermedia* and *Porphyromonas endodontalis* also contribute to the infectious processes inside the pulp. *Fusobacterium nucleatum* too is a bacterium that contributes to an increase of the earlier-mentioned symptoms. *Enterococcus faecalis*, *P. gingivalis* and *F. nucleatum* are found in extensive numbers, especially in fistulas related to primary teeth. It is because of the complex nature of the primary root canal microbiology that conventional treatment supported only with antimicrobials often is not completely successful.

### Reasons for complicated infections in primary teeth

Primary teeth diagnosed with chronic gross decay have a high chance of recurring infections. There are certain factors that compromise the health of primary tooth root canals. For a start, there is the anatomical root configuration. Variations in the root canal anatomy of primary teeth can complicate dental treatment. Primary teeth have flat ribbon-shaped canals with multiple lateral canals that often cannot be properly sealed after treatment. Also, these lateral canals accommodate bacteria in their deep ends. Roots in primary teeth are in a constant state of resorption due to eruptive forces from the underlying permanent teeth. This leads to a steady ingress of bacteria. Moreover, canal openings in the apical delta contribute to bacteria spreading even further. Another factor compromising the health of root canals of primary teeth is the complex resident bacterial flora. As stated earlier, scien-

tific research suggests that bacteria are found at a depth of up to 1,000 µm in the root canals.

### Benefits of laser-assisted treatment


Conventional irrigants used in pulpectomy penetrate canals to a depth of about 100 µm. Penetrating a depth between 500 µm and 1,000 µm, lasers of different wavelengths can be considered a valuable treatment alternative. They permanently destroy the microbial cell membrane, thus, stopping any further growth. As laser allows for such a deep reach, there is a higher possibility of bacterial lysis. After laser-assisted treatment, clinical symptoms should have ceased to exist and radiographs should show no signs of treatment failure.

## Conclusion

Laser-assisted endodontic treatment in compromised primary teeth has come a long way. When this treatment is suggested as an alternative approach to dental extraction, most parents tend to opt for this treatment, since they understand that early loss of primary tooth can lead to numerous complications later in life. In addition, dental extraction is most certainly more psychologically challenging for a child.

*Editorial note: References can be provided by the author upon request.*

## about the author



**Dr Imneet Madan** is a UAE-based dentist specialising in paediatric dentistry and laser dentistry. She obtained an MSc in Lasers in Dentistry from the Aachen Dental Laser Center at RWTH Aachen University in Germany. In addition, she is a coach in neurolinguistic programming, a psycho-communicative approach, and has Six Sigma Green Belt certification.

## contact

### Dr Imneet Madan

Laser Pediatric Dentist  
NLP Coach  
Six Sigma Green Belt  
MDS (Pediatric Dentistry)  
MSc (Laser Dentistry, AALZ, RWTH Aachen University)  
Children's Dental Center, Dubai  
Villa 1020 Al Wasl Road  
Umm Suqeim 1, Dubai  
United Arab Emirates  
Phone: +971 506823462  
imneet.madan@yahoo.com  
www.drmichaels.com



# Peri-implant bone regeneration through laser decontamination

## Endoscopic paracrestal tunnel technique

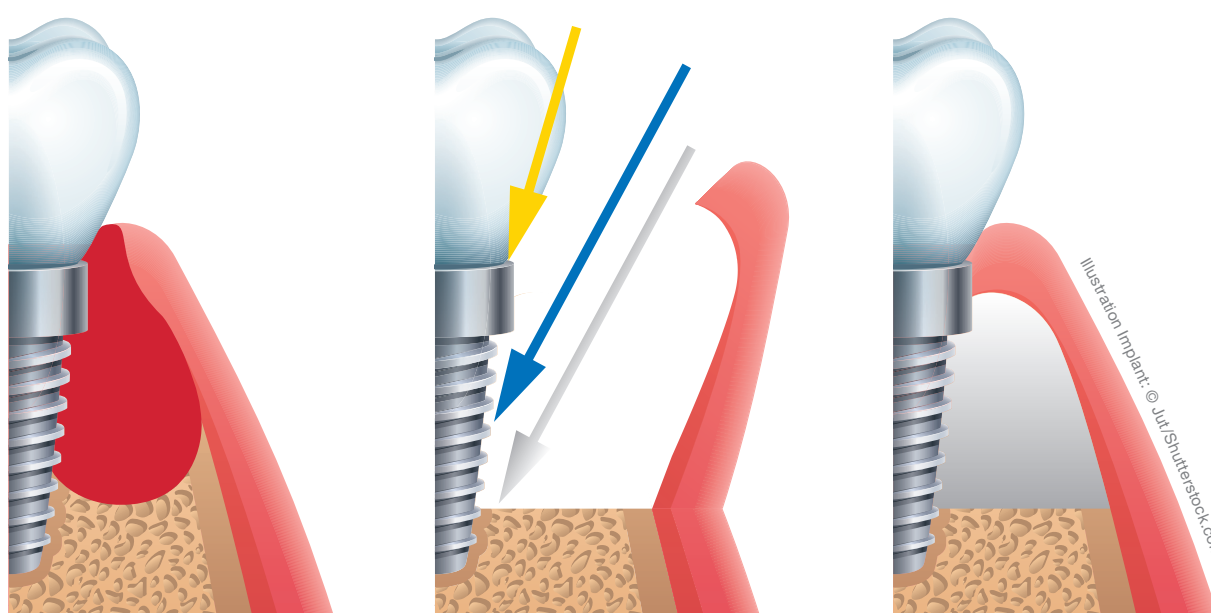
Prof. Wilfried Engelke, Dr Christian Engelke, Germany;  
Dr Victor Beltrán, Chile & Dr Marcio Lazzarini, Germany

### Introduction

The recently published S3 guidelines of the German Association of Oral Implantology (DGI) and the German Society of Dentistry and Oral Medicine (DGZMK) state that peri-implant infections can be categorised into peri-implant mucositis and peri-implantitis.<sup>1</sup> In peri-implant mucositis, only the supracrestal soft-tissue interface is involved; in peri-implantitis, the bony implant site is also involved.<sup>2</sup> Smoking is the main risk factor for peri-implant mucositis, but it is likely that there are further contributing factors, such as cement residue, diabetes mellitus and sex.<sup>2</sup> The development of peri-implantitis is particularly favoured by a history of periodontal disease, smoking and interleukin-1 polymorphism.<sup>4,5</sup> The main diagnostic criterion for distinguishing peri-implantitis from peri-implant mucositis is the lack of reversibility of the condition. Peri-implantitis can be characterised by putrid secretion,

increasing probing depth, pain and radiographic bone resorption. Implant loosening requires a high degree of bone resorption in the case of peri-implantitis. Microbiological tests are rather unspecific regarding peri-implant mucositis and peri-implantitis.

The goal of non-surgical peri-implantitis therapy is to eliminate the clinical signs of the infection. In addition to a partial or complete reduction in bleeding on probing (BOP), an effective therapy should lead to a reduction in the depth of periodontal pockets.<sup>6</sup> To date, deep peri-implant pockets have not been clearly defined, but in most cases, a probing depth of less than 6mm is considered a treatment success.<sup>7</sup> There are various treatment protocols used for non-surgical therapy: procedures for biofilm removal, antiseptic therapy and adjuvant antibiotic therapy. Surgical peri-implantitis treatment includes surface decontamination, adjuvant resectional therapy and, if necessary,



**Fig. 1a:** Open surgical peri-implantitis therapy with basal stemmed flap: application and operating direction of the laser for sulcular decontamination (yellow), implant surface decontamination (blue) and bone decontamination (white).



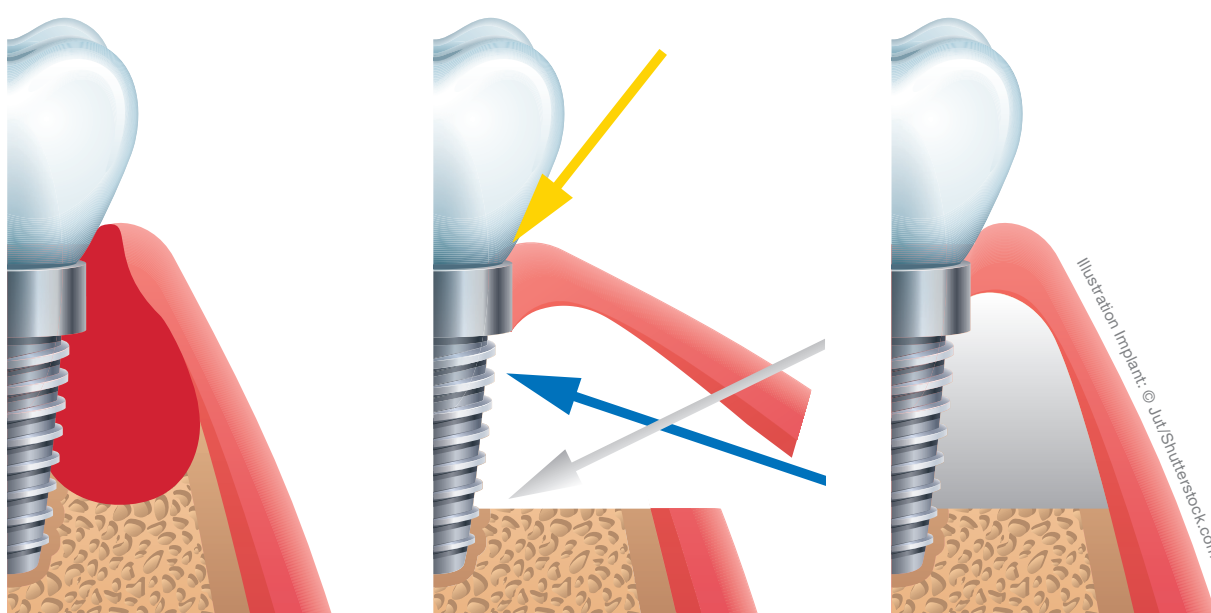
adjuvant augmentative therapy. Surface decontamination by means of a modified ultrasonic system (hydroxyapatite suspension) led to a comparable reduction in mucosal bleeding and probing depth after six months to mechanical debridement using carbon fibre or titanium curettes.<sup>8</sup> After an observation period of 12 months, BOP values increased again, especially in initially deep pockets.<sup>9</sup> In conventional flap surgery for surface decontamination, the use of special decontamination methods (e.g. 980nm diode laser, carbon dioxide laser, chlorhexidine digluconate and cetylpyridinium chloride) did not lead to significantly better clinical or radiographic results than in the respective control groups, in which air polishing, chlorhexidine solutions and placebo solutions were used.<sup>10,11</sup>

The clinical effectiveness of an adjuvant augmentative measure for flap surgery alone (titanium curettes and surface conditioning with 24 % ethylenediaminetetraacetic acid and covered wound healing for six months) was investigated in a prospective clinical study using a porous titanium granulate for treating intraosseous defect components.<sup>12</sup> After the primarily covered wound healing, a very high exposure rate was observed in both groups (control group: 12/16; test group: 13/16). After 12 months, both procedures showed a comparable reduction in probing depth and only minor improvements in peri-implant bleeding values. However, in the test group, a significantly higher decrease in radiographic translucency in the intraosseous defect area, as well as an increase in implant stability, was observed.<sup>12</sup> For advanced, complex defect configurations, surgical augmentative and resectional procedures were combined as part of an implantoplasty procedure. An implantoplasty was aimed at smoothing the macro- and microstructure of the implant body in

areas outside the physiological barrier of current augmentation procedures. Augmentation (xenogeneic bone substitute material of bovine origin and a barrier membrane) was carried out only in the area of intraosseous defects, whereby the adjacent implant surfaces were preserved in their original structure, and these surfaces were decontaminated before augmentation. Over an observation period of four years, combination therapy after open wound healing led to a clinically relevant reduction in BOP and ST values. A difference between the two investigated decontamination methods was not observed.<sup>13</sup>

In summary, it is not possible at this point to clearly determine which protocol should be preferred, based on current literature. In the case of surgical therapy, granulation tissue should first be entirely removed. The decontamination of exposed implant surfaces should be of central importance. Mechanical procedures (for reducing biofilm) and chemical procedures (for reducing and inactivating biofilm) are often combined. At this point in time, the additional benefit of peri- and/or post-operative antibiotic therapy cannot be assessed. Analogous to the guideline for perioperative antibiotic prophylaxis, a supportive once-off administration can be done as part of surgical peri-implantitis therapy. After decontamination, augmentative measures can lead to a radiographically detectable filling of intraosseous defect components. It should be noted that all surgical therapy approaches involve a high risk of post-operative mucosal recession. Soft-tissue augmentation can be performed to stabilise the peri-implant mucosa.<sup>14</sup>

In addition to these general explanations based on the guidelines, a number of techniques have been described



**Fig. 1b:** Surgical peri-implantitis therapy with closed endoscopic paracrestal tunnel technique: application and operating direction of the laser for sulcular decontamination (yellow), implant surface decontamination (blue) and bone decontamination (white).

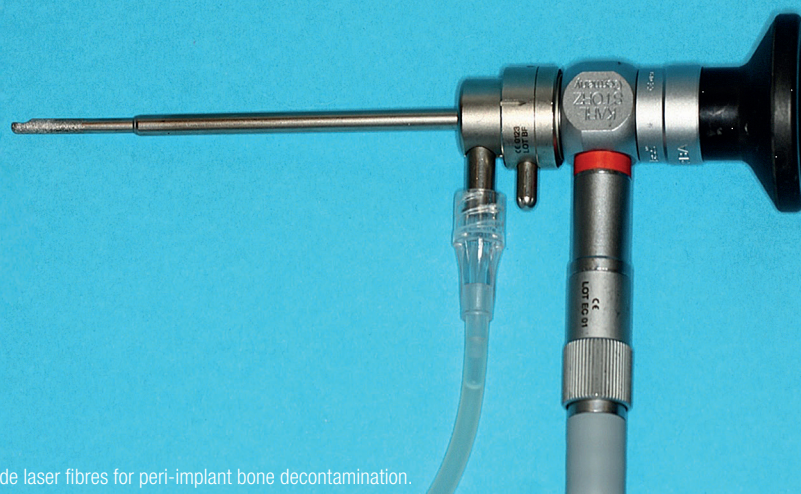


Fig. 2: Endoscopic equipment to guide laser fibres for peri-implant bone decontamination.

that could support modern peri-implantitis treatment based on a minimally invasive therapy concept, given that their concepts can be combined in order to safely decontaminate the implant surface. Kim et al. made a small labial incision with subperiosteal tunnelling for horizontal ridge augmentation.<sup>15</sup> They used bone grafts, which were placed in the soft-tissue pocket created by tunnelling and subsequently fixed by conventional means so that they could successfully integrate implants into the alveolar ridge in the context of a two-stage procedure.<sup>15</sup> Montevicchi et al. reported cases of peri-implantitis in which fibres of dental floss attached themselves to the implant superstructure and, as a result, gave rise to peri-implantitis.<sup>16</sup> They were able to remove these fibres using a periodontal endoscopic technique and, in doing so, promote healing. The healing was confirmed over a six-year period. An endoscopically supported therapy in implant dentistry was described by our working group for implant cavities and for sinus floor augmentation in a closed procedure.<sup>17,18</sup> In this context, a tunnel technique was carried out laterally for the augmentation of the sinus floor, in which the entire basal maxillary sinus mucosa was detached and tunnelled through without having to cut a bony window, which made the procedure less invasive.

In 2003, Sennhenn-Kirchner and Engelke reported on a procedure in which peri-implantitis can be successfully treated by endoscopic tunnelling and the use of a diode laser.<sup>19</sup> The laser is used for decontaminating the exposed implant surfaces, followed by augmentation of the peri-implant bone defects.<sup>19</sup> The authors found that radiographic defect filling and a reduction in probing depths can be achieved, with no post-operative infections and no augmentation losses observed in five patients with eight implants.<sup>19</sup> Prior to the operation which their research is based on, the probing depths were deeper than 6 mm and, afterwards, between 3 and 4 mm.<sup>19</sup> Sennhenn-

Kirchner and Engelke emphasised the satisfaction of the patients owing to the minimally invasive nature of the procedure.<sup>19</sup> However, there has not been a good solution, thus, far to the problem of accessing contaminated and infected implants, since most endoscopes do not feature working shafts particularly designed for this kind of application. This paper presents a concept that allows for targeted and visually controlled implant decontamination, removal of granulation tissue and simultaneous augmentation without the need for open-flap reflection.

## Case report

A 48-year-old female patient presented with an in alio loco placed exposed titanium screw-retained implant. Upon examination, a triangular bony defect situation was noted, extending into the middle third of the implant. In addition, there was secretion of pus. Upon pressure, the patient experienced a feeling of tension and local pain. Explanation of the implant and bone regeneration measures for the purpose of a new restoration were discussed. Various possible treatment protocols were explained to the patient, and minimally invasive microsurgical treatment using the tunnel technique was proposed. The patient was thoroughly informed about possible risks and the overall problematic prognosis. In the tunnel technique, the implant surface is reached through an entrance fashioned away from the implant, without interrupting the continuity of the peri-implant tissue cuff. In order to gain an optimal view in the tunnelled area throughout the procedure, support immersion endoscopy is used (Fig. 1b).

The operation was performed via a mesial tunnel entrance outside the surgical field and under local anaesthesia. After access away from the implant through a vertical mucosal periosteal incision, subperiosteal tunnelling was performed up to the affected implant. The surface of the implant was visualised by advancing the endoscope



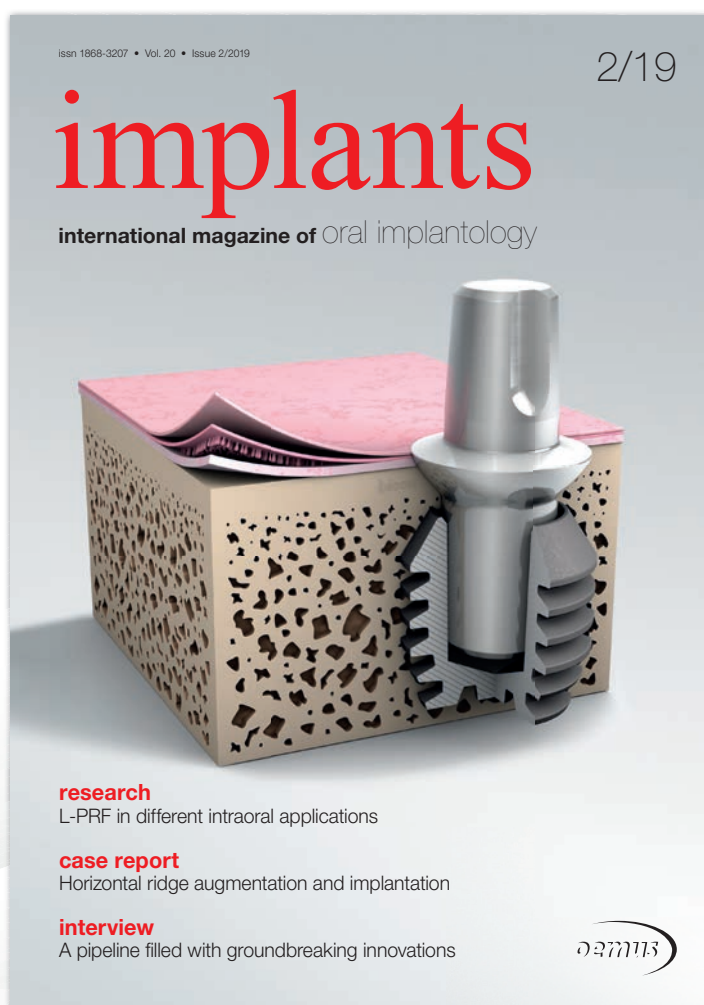# BECOME AN AUTHOR

for implants—international magazine of oral implantology

Interdisciplinary, transparent & market orientated



www.oemus.com



Become part of a successful network and benefit from a wide reach and high level of awareness

Your benefits:

- author's profile at ZWP online
- specimen copies
- offprints
- speaking engagement\*



\*according to the required profile

Fax to **+49 341 48474-290**

☐ Yes, I want to become an **author** for implants—international magazine of oral implantology. I would like to submit an article on the following topic:

---

---

Please send back your fax form  
or contact Mr **Georg Isbaner**:  
g.isbaner@oemus-media.de · Phone: +49 341 48474-123

\_\_\_\_\_  
Last Name / First Name

\_\_\_\_\_  
Street/ZIP/City

\_\_\_\_\_  
Phone/E-Mail

Stamp

laser 2/19

while perfusing the tunnel with a sterile sodium chloride solution. The gingival cuff could be mobilised towards the occlusal plane via a high vestibular periosteal slit. Granulation tissue was removed and the implant surface decontaminated under direct endoscopic vision without irrigation. Decontamination was done with a GaAlAs laser set at 1W and at a wavelength of 809nm (Fig. 3). The exposure time was 20 seconds. Four repetitions in contact mode were enough to produce sterile conditions.<sup>20</sup> After filling the defect with tricalcium phosphate ceramic and locally obtained autogenous bone particles, the minimally invasive access was closed with two button sutures. The post-operative medication consisted of an analgesic (paracetamol, 500mg, if necessary) and a single dose of antibiotic (clindamycin, 600mg). The post-operative course was inconspicuous, and the augmentation height showed that the defect had been completely regenerated. In the re-entry to expose the implant after four months, a complete bony covering of the implant could be observed vestibularly (Fig. 4). The prosthetic restoration was performed by the family dentist.

## Discussion

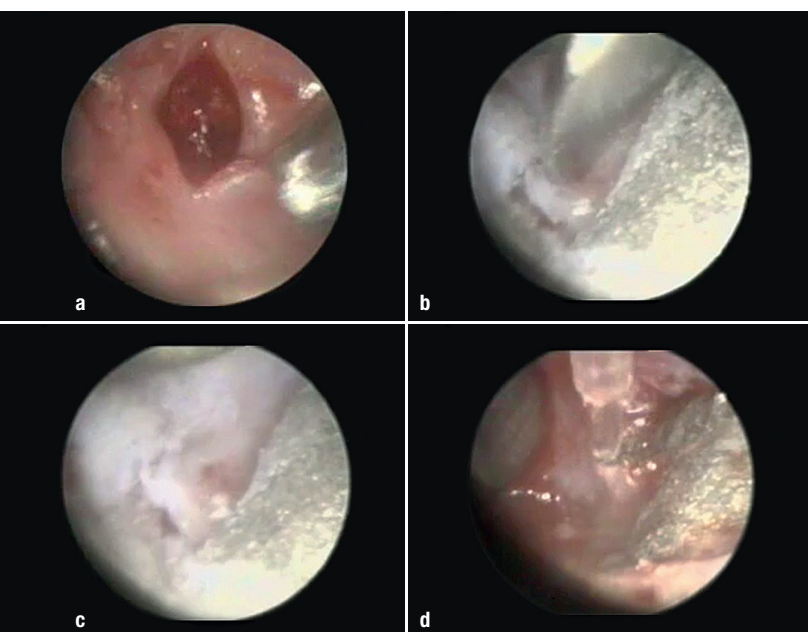
The concept of microsurgical peri-implant bone regeneration using the tunnel technique complies with the DGI/DGZMK guidelines and has two significant advantages: firstly, the cervical gingival cuff around the implant is preserved, and secondly, augmentation material can be securely positioned in a zone of optimal perfusion through the local periosteum. This significantly reduces the risk of post-operative recession and promotes bone regener-

ation. Support immersion endoscopy allows a minimally invasive approach away from the implant. The different types of support and irrigation shafts allow preparation under immersion. Blood and secretion are immediately removed by the irrigation flow and do not interfere with the preparation of the operation site. After exposure of the infected part of the implant surface inside the tunnel, laser decontamination should be done in an aerobic environment, reducing heat generation and, thus, allowing for targeted decontamination. Using intermittent irrigation, the operating field can be freed from detritus and secretion at any time. Finally, surface decontamination is done in the open operation area. The size of the tunnel entrance and its localisation can be reduced to such an extent that large-area detachment of the flap and basal flap extension by periosteal slitting can be avoided without compromising visualisation of the contaminated implant surface.

Bleeding in the tunnel can be stopped by means of vasoconstrictors or direct laser coagulation so that an optically perfect assessment of the critical parts of the bone pockets is possible using support immersion endoscopy. Removal of granulation tissue with a laser has the advantage that a low-bleeding preparation technique facilitates the precision of the subsequent steps significantly. This advantage of the endoscopic technique can also be used for tunnel procedures in primary bone augmentation, allowing reliable intraoperative quality control of the microsurgical measures even without flap reflection. If dealing with fixed implants, it is not advantageous to remove the superstructure before the operation, since the operating direction is apical. Removal should only be carried out in pathological situations, for example inaccuracies in fit. In the case of extensive interdental or oral defects, multiple tunnelling sessions might be necessary. Their indication should be clarified beforehand by means of 3D imaging. In the case that is described in this article, 3D diagnosis was not desired by the patient. Based on the extensive experience of the authors with the described procedure, it can be stated that the tunnelling of apicoapproximal peri-implantitis is advantageous for the majority of referred peri-implantitis cases and that the frequency of dehiscence may be significantly reduced by modifying the approach.

The recommended treatment sequence for the peri-implantitis therapy described in this article is as follows:

- Granulation tissue is first removed completely.
- The implant surfaces exposed in the tunnel are safely decontaminated.
- After decontamination, suitable augmentative procedures are performed for radiographically detectable filling of intraosseous defects. The choice of suitable procedures depends on the clinician's experience. The use of bone block grafts can also be considered if the tunnel entrance is wide enough.



**Fig. 3:** Intra-op situation: (a) mucosal incision away from implant, (b) vestibular mucosa, (c) laser fibre in the fundus of the bone pocket (immersion), (d) decontamination of the bone pocket (without immersion).

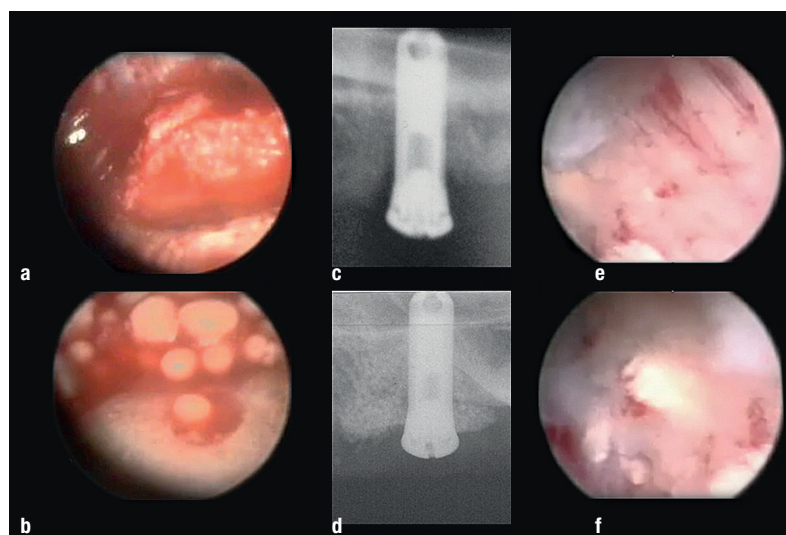


In all surgical therapy approaches without preservation of the cervical peri-implant gingival cuff, there is a high risk of post-operative mucosal recession. Only through systematic comparative investigations of the influence of soft-tissue surgery with and without preservation of the cervical gingival cuff can solid data be obtained in order to adequately evaluate the influencing parameters. The microbial analysis of implant surfaces shows a significant relation between peri-implant infections and the number of microorganisms on the surface. Therefore, laser treatment units should be considered for treating such cases owing to their inherent and well-documented disinfection potential. The visually controlled implant surface decontamination with a laser has a clear advantage over the closed application of a laser in the periodontal pocket, since clinically problematic areas can be treated with better visualisation. In addition, carbonised tissue and necroses can be easily and safely ablated during surgery. Up to this point, surface smoothing of the implant was usually not necessary owing to the augmentation in the closed tunnel procedure, as regeneration was aimed for. The re-entry image shows that regenerate had formed on the initially exposed and visibly contaminated rough implant surface, effectively preventing recession.

Guiding the laser fibre via an apical tunnel entrance allows for the cervical gingival cuff on the implant to be altered as little as possible. The procedure described in this article can also be used on implants prior to their definite exposure if it becomes apparent that the cervical vestibular bone lamella is insufficiently dimensioned and requires secondary augmentation. In addition, apical tunnel access can be gained in all stages of a prosthetic restoration without changing the soft-tissue situation in contact with the superstructure. The tunnel boundaries should be fashioned in such a way that outflow of the augmentation material is prevented and the placement of the augmentation material is gradually controlled endoscopically. In this context, form stability of the augmentation material, as recommended by manufacturers of biomaterials such as GUIDOR easy-graft (Sunstar Suisse), is very important. If followed, a certain overcontouring in the crestal area can be achieved. The relocation of tissue required for this is determined by the particular type of defect. With concave alveolar ridges, the restoration up to overcontouring of the original ridge volume can mostly be easily achieved. In some cases, however, the coronal relocation of the soft-tissue cover should be supported by a basal periosteal slit.


## Conclusion

Practitioners who consider using the described technique can safely assume that the minimal invasiveness of the procedure is highly appreciated by patients. Furthermore, the number of post-operative complaints is considerably lower compared with those with open procedures.



**Fig. 4:** Intra-op situation: augmentation with autologous bone material (a) and tricalcium phosphate augmentation material (b). Radiographic findings: pre-op (c) and post-op site (d) on the tooth film, clear filling of the defect. Re-entry after four months: implant surface covered by bone (e) with residue of bone replacement material (f).

In order to finally assess the clinical value of this procedure with regard to compliance and the post-operative healing period, however, extensive, preferably prospective, randomised studies are required.



## about the author



**Prof. Wilfried Engelke** works as a private practitioner in a joint practice in Göttingen in Germany. He is specialised in oral surgery and implantology. In addition, he is head of the DZOI "Curriculum Implantologie". In 1996, he was appointed Professor and since then, he has been giving lectures not only at the Medical Faculty of the University of

Göttingen, but at Universities all around the globe.

## contact

### Prof. Wilfried Engelke

Praxis für Zahnärztliche Chirurgie  
Dr. Möller, Prof. Engelke, Dr. Kanzow  
Herzberger Landstraße 25a  
38073 Göttingen, Germany  
Phone: +49 551 58889  
wengelke@med.uni-goettingen.de





# Successful communication in your daily practice

## Part X: How to improve your own punctuality

Dr Anna Maria Yiannikos, Germany & Cyprus

**This series covers** the most common and challenging scenarios that might arise in your dental practice and presents successful ways to deal with them in order for you to enjoy greater peace of mind. Each article of this series teaches you a new, easy-to-use specialised protocol which can easily be adapted to your own dental clinic's requirements and needs right from the start. Today's challenging topic: how to improve on delays that might occur in your dental practice owing to poor time management and find ways to be more punctual instead.

In the following, I will provide five essential steps to manage it. Being on time is significant—not only for you as a dentist, but for your practice staff and patients as well. They only feel respected if you are on time and don't keep

them waiting. Always keep in mind that they have more important things to do than being kept waiting in the reception area of your dental practice. Your schedule might easily go off the rails if a patient still needs to be taken care of, but the next one is already waiting.

Consider the following scenario: you are preparing for a normal and—usually—easy tooth extraction. However, the procedure turns out to be more complicated than you thought and now you have to perform a complicated and time-consuming surgery instead. This situation becomes even worse when the next patient arrives on time for his or her scheduled appointment and you still have to treat the patient sitting in front of you. The patient left waiting will probably be angry and frustrated and you might lose him or her as a loyal patient.

## 5 essential steps

In order to cope with situations like the one that I have just described more effortlessly and effectively, follow these five steps:

### 1. Say that you're sorry

Immediately express your apologies to the patient who has been kept waiting and state how deeply sorry you are. If necessary and possible, interrupt the still ongoing previous appointment in order to do that. Here's what you can say: "I promise that, next time, you will get the first appointment of the day, so that there cannot be any delays whatsoever."

The best dentist is the one  
that respects his or her  
patients by being punctual.

### 2. Avoid excuses

Don't try to wriggle out of the situation by giving drawn-out explanations for why there are delays. It's unprofessional and the patient probably won't care anyway; he or she just wants to be treated. Patients come to you to have their problems fixed and not the other way around.

### 3. Give in order to receive

Replace bad news with good news. For instance, tell the patient who has been kept waiting that he or she will receive a free laser-assisted treatment session to make up for the inconvenience caused. However, be prepared for possible negative reactions towards your offer. If that happens, show understanding and compassion.

### 4. Make use of your assistant

Instruct your assistant to always remind you of an upcoming appointment five minutes ahead. Your assistant can become your personal alarm. If there are any delays, also instruct him or her to let your next patient know for how long he or she will probably have to wait. By doing so, possible annoyance and irritation from the patient's side can be avoided.

### 5. Make a change

Start your daily programme earlier than usual each day. In addition, schedule some extra time for every appointment, even if you don't end up needing it. For instance, if you schedule 20 minutes per appointment, now plan for 30 minutes instead. I'm aware that, in the beginning, you probably won't like it, but by doing so, you are already allowing for possible delays.

## Isn't that easy?

Implement the above-mentioned steps as a protocol in your daily practice and you will soon notice that you are in control again of time-related issues in the day-to-day work of your practice. Now knowing the exact steps to avoid and resolve unwanted situations created by poor time management, you will gain greater peace of mind in the long run. Moreover, I'm certain that you won't end up losing patients (and possibly their families too) when following these steps. Just try them out and let me know what you think!

I am sure that you are already looking forward to the next issue of the laser magazine, in which I will present the 11<sup>th</sup> part of this unique series of communication concepts and touch on further useful and interesting topics. Are you curious about what's next? We will discuss how to attract patients from abroad and extend your patient base on an international scale. Wouldn't you agree that the topic of medical tourism is extremely interesting? In addition to discussing the subject, I will provide seven crucial methods to achieve your goals.

Until then, remember that you are not only the dentist at your clinic, but also its manager and leader. For questions and further information and guidance, don't hesitate to reach out by sending me an e-mail at [dba@yiannikosdental.com](mailto:dba@yiannikosdental.com) or via our website, [www.dbamastership.com](http://www.dbamastership.com). I am looking forward to our next step towards business growth and educational development!

## about the author



**Dr Anna Maria Yiannikos** (DDS, LSO, MSc, MBA) is one of the first two women worldwide to have obtained a master's degree in laser dentistry. She has owned a dental clinic for 23 years now and is the leader of the innovative Dental Business Administration Mastership Course at RWTH Aachen University in Germany.

## contact

**Dr Anna Maria Yiannikos**  
Adjunct Faculty Member of AALZ  
at RWTH Aachen  
University Campus, Germany  
DDS, LSO, MSc, MBA  
[dba@yiannikosdental.com](mailto:dba@yiannikosdental.com)  
[www.dbamastership.com](http://www.dbamastership.com)





## LASERVISION

### Lightweight magnifying goggle for laser treatment

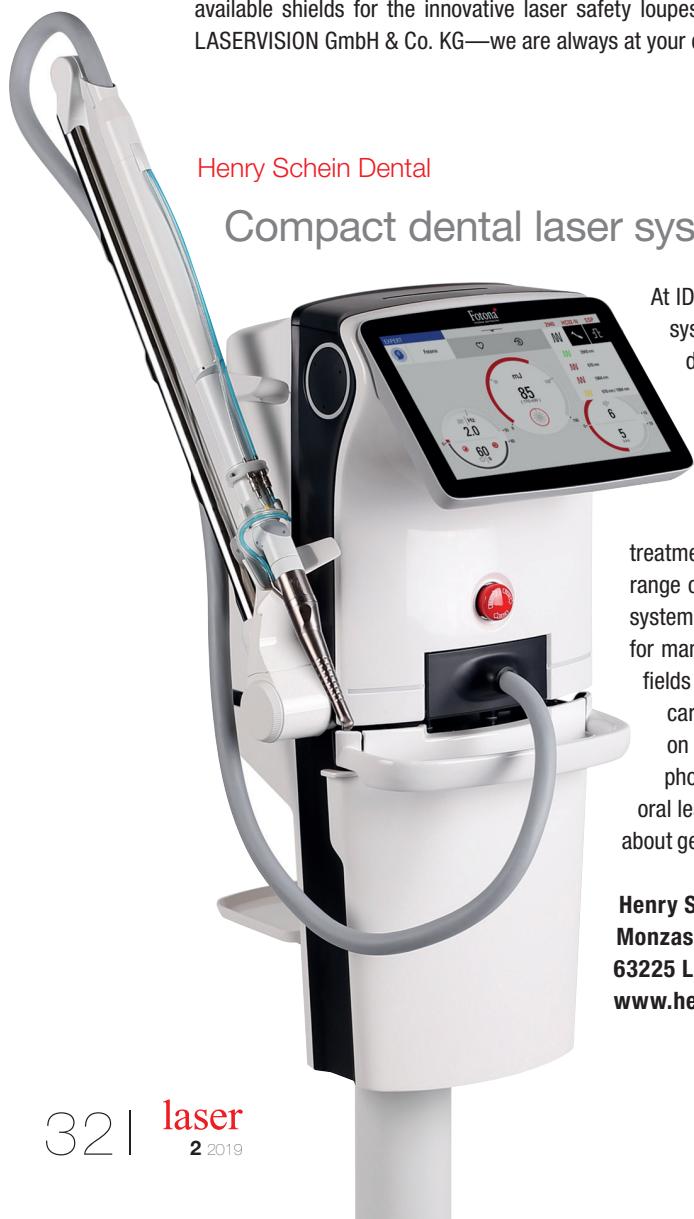Laser-safe loupes are especially required in dentistry. Owing to the optical characteristics of a loupe the protection of the eyes is notably considered. When used in laser-assisted applications, loupes allow for an increase in the power- and energy density of the laser. Within dentistry, precise laser treatments and, as a consequence, successful treatment outcomes can be achieved using loupes. The new F27 magnifying eyewear combines the already proven F22 eyewear frame and a newly developed adapter with the magnifying glass of one of the leading German manufacturers. Owing to the large number of available laser protection filters for this spectacle frame, a suitable magnifying glass can be configured for almost every laser-assisted application. Especially in combination with the HR2.5x/340 mm binocular loupe, the new F27 loupes cover almost the entire range of laser-assisted applications. Moreover, laservision offers magnifiers with working distances of 340, 420 and 520 mm. For further information on the available shields for the innovative laser safety loupes, contact LASERVISION GmbH & Co. KG—we are always at your disposal.



**LASERVISION GmbH & Co. KG**  
**Siemensstraße 6**  
**90766 Fürth, Germany**  
**[www.uvex-laservision.de](http://www.uvex-laservision.de)**

## Henry Schein Dental

### Compact dental laser system for endodontists



At IDS 2019, the specialist for dental laser systems Fotona presented the SkyPulse system for the first time. The highly mobile, compact laser system is ideal for dental practices that want to perform the laser-assisted irrigation protocol Photon Induced Photoacoustic Streaming (PIPS™) in endodontics for the effective cleaning and debridement of root canals. Until now, the protocol could only be performed with the much larger Fotona LightWalker. In addition, SkyPulse is also ideal for clinicians new to the field of laser dentistry. Excellent ease of use and a new graphical touchscreen display for selecting pre-set options and treatment parameters make it easy for aspiring laser enthusiasts to get started. A wide range of handpieces and additional dental equipment for the high-performance diode system provide versatility, a wide range of wavelengths and various treatment options for managing soft tissue. The SkyPulse Er:YAG system is well suited for the following fields of application: PIPS™, periodontics, periimplantitis therapy, removal of dental caries, desensitisation and ablating ceramics. The SkyPulse diode laser system, on the other hand, is perfectly suited for soft tissue management, bio-modulation, photodynamic therapy, intraoral photocoagulation, haemostasis, as well as treating oral lesions, herpes and oral aphthae. For further information about the SkyPulse and about getting started in laser dentistry please refer to the Henry Schein laser specialists.

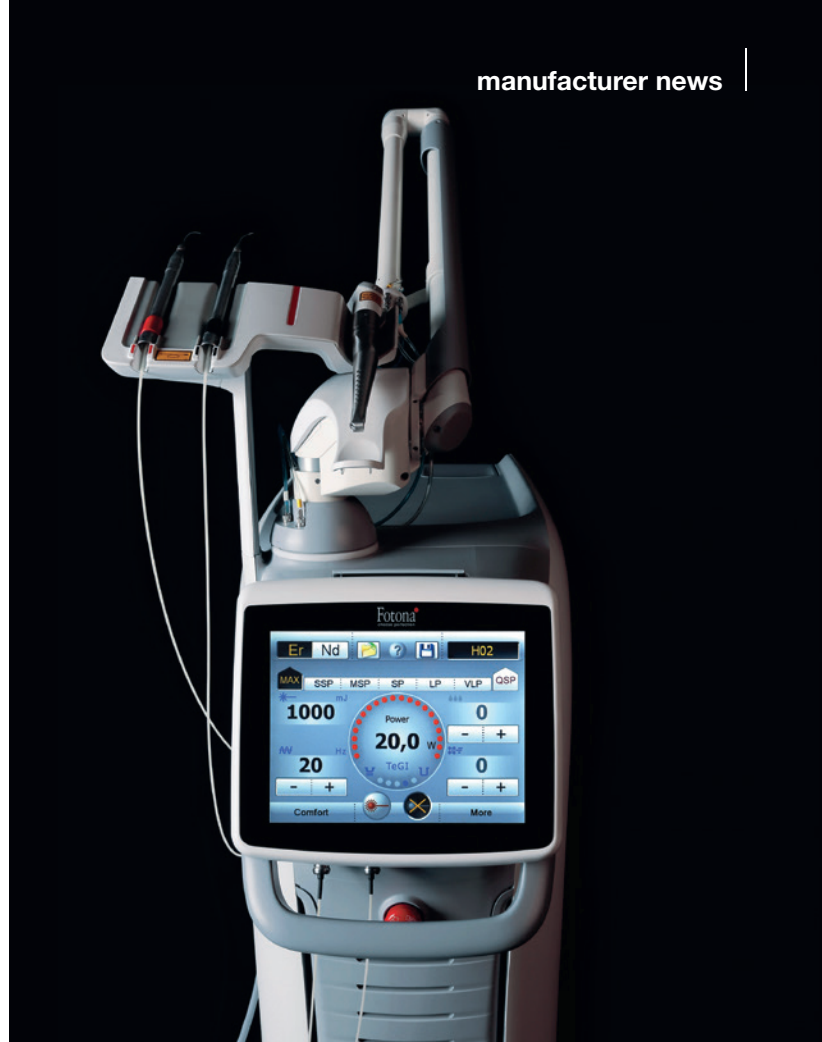**Henry Schein Dental Deutschland GmbH**  
**Monzastraße 2a**  
**63225 Langen, Germany**  
**[www.henryschein-dental.de](http://www.henryschein-dental.de)**

Fotona

## Dual wavelength laser system

Following its launch at IDS in March 2011, Fotona's dual wavelength (Er:YAG and Nd:YAG) LightWalker laser system quickly earned widespread industry appreciation and highly respected technology and innovation awards. Today, it is a preferred laser system of dental perfectionists and forward-thinking professionals who wish to upgrade their dental experience with new treatment possibilities that only the latest technology can offer. Owing to Fotona's advanced R&D capabilities which regularly introduce new features, software updates and usability improvements that further enhance the system's comprehensive feature set, it remains one of the most leading edge and reliable laser systems on the market. With the most state-of-the-art design, engineering and patented technologies, offering a wide range of highly effective TwinLight® hard- and soft-tissue treatments, aiming at providing the most extensive list of applications of any dental laser made today, LightWalker will continue to set standards for cutting-edge laser technology in years to come.

**Fotona d.o.o.**  
**Stegne 7**  
**1000 Ljubljana, Slovenia**  
**www.fotona.com**



AD

## SUBSCRIBE NOW!

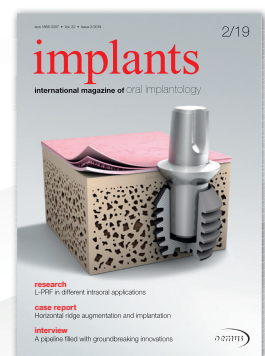implants—international magazine  
of oral implantology

Interdisciplinary, transparent &  
market orientated

ONLINE  
SUBSCRIPTION HERE



www.oemus-shop.de



laser 2/19

Fax: +49 341 48474-290

I would like to subscribe for the following journals:

☐ implants—international magazine of oral implantology 4 issues p.a. € 44\*

☐ laser—international magazine of laser dentistry 4 issues p.a. € 44\*

Terms & Conditions: The subscription may be cancelled in written form without due justification within 14 days of order by contacting OEMUS MEDIA AG, Holbeinstraße 29, 04229 Leipzig, Germany. Dispatching notification in good time will suffice. The subscription is automatically extended by another twelve months if it is not cancelled in written form 6 weeks prior to the end of the reference period.

\* All prices include VAT, shipping and handling.

\_\_\_\_\_  
Last Name, First Name

\_\_\_\_\_  
Company

\_\_\_\_\_  
Street

\_\_\_\_\_  
ZIP, City, Country

\_\_\_\_\_  
E-mail

\_\_\_\_\_  
Signature

\_\_\_\_\_  
Credit Card Number

\_\_\_\_\_  
Expiration Date

\_\_\_\_\_  
Security Code





Fig. 1



Fig. 2

**Fig. 1:** Congress participants enjoyed numerous presentations on cutting edge topics. **Fig. 2:** The organising team succeeded in putting together three highly scientific congress days.

# A look back at the 17<sup>th</sup> International Congress of ISLD in Plovdiv

Dr Dimitris Strakas, Greece & Dr Georgi T. Tomov, Bulgaria

The annual congresses of the International Society for Laser Dentistry (ISLD), which was formed 31 years ago, have always been considered important scientific gatherings for dental laser enthusiasts from all around the globe. Following the successful congresses in Thessaloniki in 2017 and Aachen in 2018, which brought about a new congress era, the historic and beautiful Bulgarian city of Plovdiv was chosen as this year's venue for the 17<sup>th</sup> International Congress of ISLD, held from 6 to 8 June 2019. Set in the Medical University of the city, which also has been designated the 2019 European capital of Culture, the three-day congress was supported by the Bulgarian Dental Laser Society, the Bulgarian Association of Oral Medicine, the German association for laser dentistry (Deutsche Gesellschaft für Laserzahnheilkunde–DGL) and the World Academy for Laser Education and Research in Dentistry (WALED).

On 6 June, the congress opened with the 7<sup>th</sup> Annual Meeting of the World Academy for Laser Dentistry, which

is the alumni society of the M.Sc. and Master's graduates of the Aachen Dental Laser Center (AALZ) at the RWTH Aachen University Campus. In addition, numerous workshops and clinical courses were held on the first congress day, which ended with the already famous WALED get-together party. On the following day, 7 June, the ISLD



International  
Society for  
Laser Dentistry

Congress was officially opened by Congress Chairman Dr Georgi Tomov and Scientific Chairman Prof. Norbert Gutknecht. The opening ceremony included a fantastic laser show and a heart-warming local music experience. The overriding theme of the congress "Laser Technologies and Translation to Clinical Practice" was chosen





**Fig. 3:** Prof. Norbert Gutknecht (left) and Dr Georgi Tomov (right) welcomed participants to the congress. **Fig. 4:** More than 250 laser enthusiasts from around the globe gathered for the event in Plovdiv.

to reflect two major challenges in the field of laser dentistry: rapidly evolving new technologies and both the possibilities and the limitations of applying these technological advancements in the daily clinical practice in an evidence-based fashion. The congress programme comprised round table debates, numerous workshops and short oral presentations addressing cutting edge topics.

Several promising new technologies are on the horizon in laser dentistry and this congress served as an ideal forum for exchanging professional knowledge in order to advance and elevate the medical field. Educational sessions and practical courses were offered on topics with a strong emphasis on research and clinical application, making them of immediate relevance for clinicians. More than 250 participants enjoyed not only the scientific programme, but also the exquisite social events including the welcome cocktail party and the gala dinner party.

The ISLD is the leading society worldwide for laser dentistry. You can become a member of the now 31-year-old expert society online on [www.isldlaser.com](http://www.isldlaser.com). Members enjoy numerous privileges including the unique Laser Dentistry World Academic Map, where you can pin yourself and interact with your colleagues and fellow researchers on dental laser technologies on a global scale. The next congress of the International Society for Laser Dentistry will be held in Cairo in Egypt from 1 to 3 October 2020. Further information on this magnificent upcoming event will be published soon.



**Fig. 3**



**Fig. 4**



## contact

### International Society for Laser Dentistry (ISLD)

University of Aachen Medical Faculty  
Pauwelsstraße 30  
52074 Aachen, Germany  
[www.isldlaser.com](http://www.isldlaser.com)





## DGL-Einführungskurs 2019

### „Laser in der Zahnheilkunde“ neu aufgelegt

Nach wie vor ist der Einsatz von Lasergeräten in der zahnmedizinischen Therapie, trotz inzwischen fast dreißigjähriger Nutzung in Deutschland, kein Bestandteil des zahnärztlichen Curriculums an bundesdeutschen Universitäten. Die Deutsche Gesellschaft für Laserzahnheilkunde e.V. (DGL) hat es sich zur Aufgabe gemacht, Laser in das zahnärztliche Therapiespektrum zu integrieren und den Einsatz dieser modernen Behandlungsmethode zu verbreiten. In diesem Zusammenhang wird ein Einführungskurs an mehreren Terminen im kommenden Jahr gehalten. Ziel des Kurses ist es, die Teilnehmer produktneutral über die Einsatzmöglichkeiten und Indikationen verschiedener Dentallaser zu informieren. Neben der Vermittlung physikalischer Grundlagen und der biophysikalischen Interaktion der aktuellen Wellenlängen mit unterschiedlichen Geweben werden vor allem die klinische Anwendung und der Mehrwert für Patient und Behandler in dieser Fortbildung herausgestellt. Eine Vielzahl an Fallbeispielen und ein Hands-on-Training an Präparaten sollen den direkten Bezug zur Praxis sicherstellen. Neben der Vermittlung von Basiswissen wird mit allgegenwärtigen Vorurteilen aufgeräumt und durch erfahrene Spezialisten die Chancen und Behandlungsoptionen des Lasereinsatzes dargestellt. Zielgruppe sind Studierende der Zahnmedizin, Assistenzärzte und interessierte zahnärztliche Kollegen.



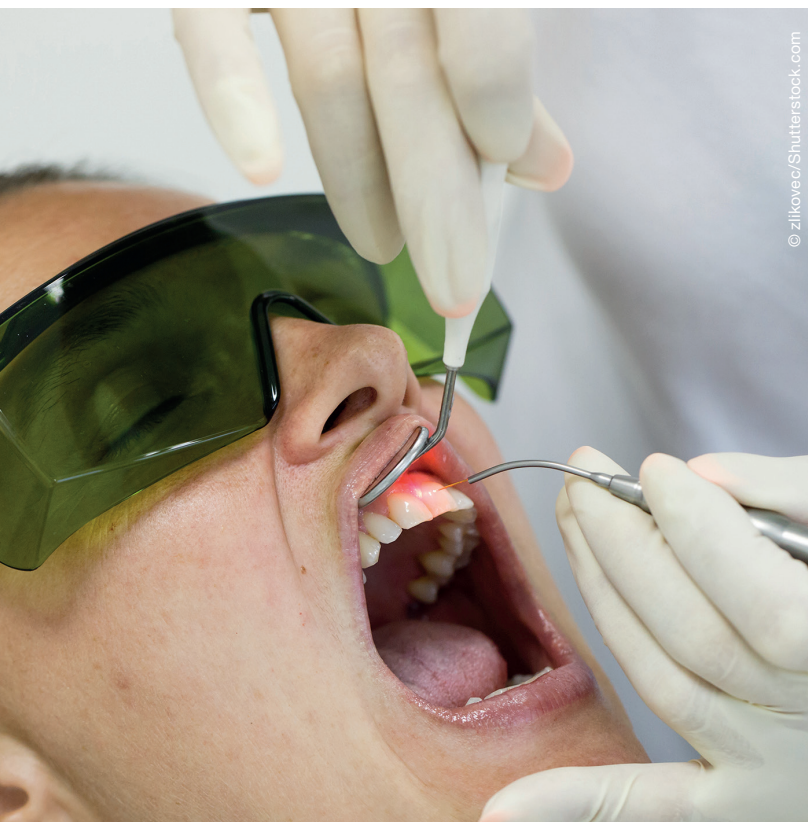Zur Auswahl stehen folgende Kurstermine:

- **06. September 2019** (Köln)
- **20. September 2019** (Berlin)
- **12. Oktober 2019** (Erwitte)
- **15. November 2019** (Grimmen)

Die Kursdauer wird pro Termin etwa 4 Stunden betragen. Bestandteil sind eine kurze Lernkontrolle und ein Hands-

on-Training. Gemäß den DGZMK-/BZÄK-Richtlinien wird dieser Kurs mit 6 Fortbildungspunkten bewertet. Der Kostenbeitrag liegt bei 30 Euro, allerdings ist die Teilnahme für Studierende mit einem gültigen Studentenausweis frei. Die Kursanmeldung erfolgt über die Geschäftsstelle der DGL, das Anmeldeformular ist entweder auf [dgl-online.de](http://dgl-online.de) oder über den anbei stehenden QR-Code zu finden. Falls Sie teilnehmen möchten, senden Sie uns bitte das ausgefüllte Anmeldeformular entweder per E-Mail an [sekretariat@dgl-online.de](mailto:sekretariat@dgl-online.de) oder [especk@ukaachen.de](mailto:especk@ukaachen.de), per Fax an 0241 803388164 oder per Post an folgende Adresse: Uniklinik Aachen, Abt. für ZPP/DGL, Frau Eva Speck, Pauwelsstraße 30, 52074 Aachen.

**Quelle: Deutsche Gesellschaft für Laserzahnheilkunde e.V.**



## Laser therapy effective in

### Treating periodontitis and peri-implantitis

The American Academy of Periodontology (AAP) has investigated current scientific research to find out whether laser therapy alone or in combination with classical periodontal therapy is superior in treating periodontal diseases. The aim was to determine the advantages and limitations of laser therapy in order to formulate guidelines for the clinical practice. The scientists went through literature and databases in order to find relevant studies that can be used. Overall, it was found that current data is somewhat contradictory, yet, there was evidence that in moderate to severe cases of periodontitis, conventional therapy supported by laser therapy provided slightly better results in terms of probing depth and clinical attachment levels. This was particularly evident in the use of antimicrobial photodynamic therapy (aPDT). The AAP proclaims, among other things, the simplification of protocols and continuous maintenance of the database in order to further advance the evaluation of clinical studies. The findings were first published in the *Journal of Periodontology* in April 2018 (J Periodontol. 2018;89:737–742).

**Source: ZWP online**

Stress levels are

## Reflected in teeth

Emerging evidence suggests that exfoliated teeth may be a promising biomarker for modern medicine. They are one of the few tissues in the body that permanently record the history of environmental insults. At a meeting of the American Association for the Advancement of Science (AAAS) in Washington, researchers showed what teeth can reveal about stress levels of patients. The most important finding was that it can be observed in children's teeth whether they were exposed to high stress factors at an early age. According to Dr W. Thomas Boyce from the University of California, San Francisco, the individual layers that build up the tooth enamel are thinner and less dense if exposed to stress, which "increases the vulnerability to dental cavities." These changes can be measured by examining a primary tooth in a 3D model based on a radiograph. The presentation, titled "Social disparities in child oral health: Interactions between stress and pathogens", was



presented on 15 February 2019, in a scientific session at the Annual Meeting of the AAAS.

Source: DTI

## Join DGL!

Register now at [www.qr.oemus.com/6152](http://www.qr.oemus.com/6152) or scan the QR on the right and become a member of the German Association of Laser Dentistry (DGL).

Application form



Norwegian healthcare professionals could play

## Greater role in snus prevention

Snus is a type of smokeless tobacco peculiar to Nordic countries. In 2017, 32% of men and 22% of women aged 16–24 used snus on a daily or occasional basis. Although various studies have suggested that snus has lower risks of causing oral or lung cancer than smoking, its use still involves a range of adverse health effects. Researchers recently conducted a survey of 557 dentists and dental

hygienists working in the public dental service (PDS) in seven counties in Norway. Dentists' and dental hygienists' activities regarding intervention to prevent snus use were analysed and measured on a five-point scale based on four questions. The results showed that approximately 87% of the dentists and 58% of the dental hygienists were not familiar with the minimum intervention methods commonly used in tobacco prevention and cessation. However, dental hygienists were found to be the most active in informing and supporting their patients in prevention and cessation of snus use. The findings suggest that the untapped potential of the PDS for promoting tobacco prevention and cessation among adolescents is particularly high among dentists. The study, titled "Prevention of snus use: Attitudes and activities in the Public Dental Service in the south-eastern part of Norway", was published online in *Clinical and Experimental Dental Research*.

Source: DTI





## Brexit reason for imminent

## Shortage of dentists in the UK

According to a recently published report from the General Dental Council (GDC), it is possible that there will be a shortage of dentists in the UK in the near future. The report states that almost a third of dentists from Europe are considering leaving the UK in the next few years. More than eight in ten of those intending to leave blame uncertainty over Brexit arrangements as a significant factor. "Exploring the intentions of people who are currently able to work in UK healthcare because their qualifications are recognised under EU legislation is essential," head of regulatory intelligence at the GDC, David Teeman, said. "This research was undertaken before important issues have been resolved, such as recognition of qualifications, residency rights and access to the UK for existing and prospective dental professionals. Once these issues are settled, we are planning a further round of research." The survey also found that 84 per cent of respondents believe Brexit is leading to a shortage of healthcare workers and 75 per cent of people believe it is leading to a shortage of dental professionals.

Source: [dentistry.co.uk](http://dentistry.co.uk)



## Tooth enamel of panda bears

## Inspiration for dental prostheses



Pandas spend more than 12 hours a day eating, approximately eating 30 kilograms of bamboo. The bears have developed an intelligent protective mechanism to counter the threat of tooth wear. Researchers at the Institute of Metal Research of the Chinese Academy of Science, Lanzhou University of Technology and the University of California, Berkeley found that the panda's tooth enamel recovers its structure and geometry at nano- to micro-scale dimensions autonomously after deformation to counteract the early stage of damage. "[This] property results from the unique architecture of tooth enamel, specifically the vertical alignment of nano-scale mineral fibres and micro-scale prisms within a water-responsive organic-rich matrix," explains first author Zengqian Liu. Owing to the viscoelasticity of this matrix, water absorption is promoted, which contributes significantly to regeneration. The team is hoping to develop tooth enamel-inspired self-recoverable durable materials by introducing shape-memory polymers at the interfaces of ceramics.

Source: [materialstoday](http://materialstoday)

## M.Sc. programme "Lasers in Dentistry" at

## RWTH Aachen University

Since October 2018, the Aachen Dental Laser Centre (AALZ) offers a new batch of the M.Sc. programme "Lasers in Dentistry" at RWTH Aachen University in Germany. The postgraduate programme is aimed at dentists who want keep pace with their patients' wishes for innovative and gentle treatment methods. In standard academic studies in dentistry, dentists have never learned about dental laser technology and treatment concepts. Building on a university degree in dentistry, the necessary professional knowledge for laser applications in dental practice is taught at the highest academic level in theoretical lec-



tures and practical teaching during this two-year Master course. Participants obtain sound theoretical knowledge in lectures and seminars led by renowned and experienced international scientists and practitioners. Skill training sessions, exercises, practical applications, live operations and workshops with intensive assistance from scientific associates with doctorates guide participants towards using lasers professionally in their own surgeries.

Source: [AALZ](http://AALZ)



## Einführungskurse 2019

# „Laser in der Zahnheilkunde“



© Alexander Lysenko/Shutterstock.com

Bitte ausgefüllt per E-Mail an: sekretariat@dgl-online.de | especk@ukaachen.de  
oder per Fax: 0241 803388164 oder per Post: Uniklinik Aachen, **Abt. für ZPP/DGL**,  
Frau Eva Speck | Pauwelsstraße 30 | 52074 Aachen

**Hiermit melde ich mich verbindlich zum Einführungskurs der DGL  
zum Preis von 30,00€ pro Teilnehmer (Studenten der Zahnmedizin  
mit gültigem Ausweis frei) an.**

### Termine:

- |  |                                       |                  |
|--|---------------------------------------|------------------|
| <input type="checkbox"/> Fr. <b>06.09.2019</b> | Referent: Dr. Thorsten Kuypers, M.Sc. | Kursort: Köln    |
| <input type="checkbox"/> Fr. <b>20.09.2019</b> | Referent: Dr. Thorsten Kleinert       | Kursort: Berlin  |
| <input type="checkbox"/> Sa. <b>12.10.2019</b> | Referent: ZA Olaf Oberhofer, M.Sc.    | Kursort: Erwitte |
| <input type="checkbox"/> Fr. <b>15.11.2019</b> | Referentin: Dr. Birgit Fitsch, M.Sc.  | Kursort: Grimmen |

**Kursdauer:** ca. 4 Std.; Zeiten werden noch individuell mitgeteilt

<b>Kursorte:</b>	50737 Köln, Neusser Straße 600	Tel.: 0221 71500679
	10119 Berlin, Schönhauser Allee 10–11	Tel.: 030 4426843
	59597 Erwitte, Hellweg 23	Tel.: 02943 97470
	18507 Grimmen, Fritz-Reuter-Straße 9	Tel.: 038326 3147

Name		Vorname	
Straße, Nr.		PLZ, Ort	
Telefon		E-Mail	
Unterschrift		Datum	

**Die Bestätigung Ihrer Anmeldung erfolgt nach dem Eingang Ihrer Kursgebühren auf das Konto der DGL:  
Sparkasse Aachen | IBAN: DE56 3905 0000 0042 0339 44 | BIC: AACSD33**

### Allgemeine Bedingungen

Nach Zugang der Anmeldung ist diese für den Teilnehmer verbindlich. Bei Stornierung der Teilnahme erfolgt keine Rückerstattung der Gebühren. **Studenten bitte Studentenausweiskopie einsenden.**

Die Gestaltung und Durchführung des Kurses obliegt der Deutschen Gesellschaft für Laserzahnheilkunde e.V.

Für diese Veranstaltung inkl. Lernerfolgskontrolle werden gemäß BZÄK/DGZMK-Richtlinie 6 Fortbildungspunkte vergeben.



© Foxys Forest Manufacture/Shutterstock.com

Vegan diet contributes to

## Periodontal health

A new study has shown that eating habits contribute to periodontal health. Scientists from the Department of Conservative Dentistry and Periodontology at the University Hospital of Freiburg in Germany have investigated the extent to which a specific diet can have a positive effect on gingivitis. The study involved 30 patients suffering from gingivitis, which were randomly assigned to two groups. The control group kept their “western” eating habits, including a daily intake of up to 45 per cent carbohydrates. The experimental group was instructed to maintain an anti-inflammatory diet for four weeks. Processed carbohydrates such as sugar, white flour, fruit juices and polished rice should be avoided. Trans-fatty acids, omega-6 fatty acids, as well as milk and meat products weren’t allowed either. However, the group was advised to increase their daily intake of omega-3 fatty acids, vitamins C and D, antioxidants, fibre and nitrate containing plants. Throughout the study, the degree of gingivitis was regularly determined via the gingival index (GI) and the plaque values. It was found that the prescribed diet significantly improved GI levels and reduced bleeding of the gums. In addition, the control group showed an increase in gingival pocket depth, while the other group remained unchanged. The study, titled “The influence of an anti-inflammatory diet on gingivitis. A randomized controlled trial”, was published in the *Journal of Clinical Periodontology* in April 2019.


Source: ZWP online

Fear of being sued to cause

## Stress and anxiety among dentists

A recent Dental Protection survey found that the fear of being sued causes stress and anxiety in eight out of ten dental professionals, dentistry.co.uk reported. According to Dental Protection, healthcare professionals often don’t seek help when they find themselves in such circumstances. Raj Rattan, dental director at Dental Protection, says: “Stress can impact on a dentist’s health and practice in a number of ways. It can affect confidence, clinical judgement, morale and even lead to performance issues. Research confirms that high stress levels affect performance and increase the potential for adverse outcomes of error.” The publication of the findings coincides with Stress Awareness Month, which is held every year in April to increase awareness about the causes and cures for stress. The Mental Health Foundation claims 74 per cent of adults felt stressed at some point over the last year to such an extent that they felt unable to cope. Dental Protection offers a counselling service for members experiencing stress due to receiving complaints from patients.

Source: dentistry.co.uk



© one line man/Shutterstock.com




# SUBSCRIBE NOW!

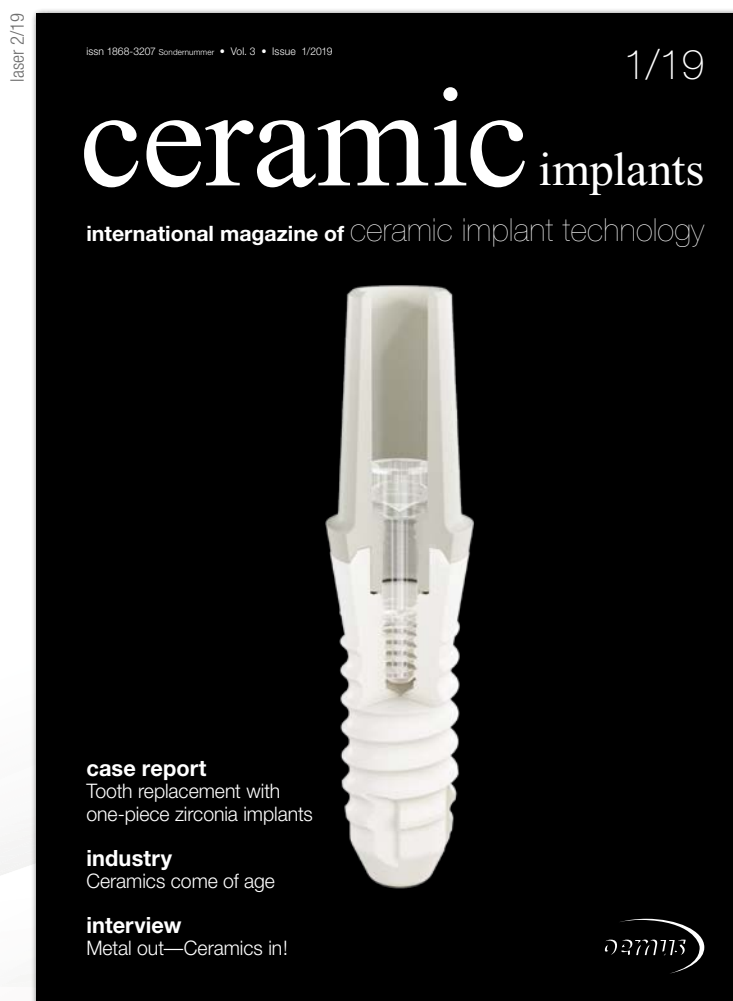
ceramic implants—international magazine of ceramic implant technology

Interdisciplinary, transparent & market orientated

ONLINE  
SUBSCRIPTION HERE



www.oemus-shop.de



## stay updated:

case report  
**Tooth replacement with one-piece zirconia implants**

industry  
**Ceramics come of age**

interview  
**Metal out—Ceramics in!**

Fax: **+49 341 48474-290**

I would like to subscribe for the following journals:

- ☐ ceramic implants—international magazine of ceramic implant technology 2 issues p.a. € 30\*
- ☐ implants—international magazine of oral implantology 4 issues p.a. € 44\*

Terms & Conditions: The subscription may be cancelled in written form without due justification within 14 days of order by contacting OEMUS MEDIA AG, Holbeinstraße 29, 04229 Leipzig, Germany. Dispatching notification in good time will suffice. The subscription is automatically extended by another twelve months if it is not cancelled in written form 6 weeks prior to the end of the reference period.

\* All prices include VAT, shipping and handling.

\_\_\_\_\_  
Last Name, First Name

\_\_\_\_\_  
Company

\_\_\_\_\_  
Street

\_\_\_\_\_  
ZIP, City, Country

\_\_\_\_\_  
E-mail

\_\_\_\_\_  
Signature

\_\_\_\_\_  
Credit Card Number

\_\_\_\_\_  
Expiration Date

\_\_\_\_\_  
Security Code

**OEMUS MEDIA AG**

Holbeinstraße 29 · 04229 Leipzig · Germany · Phone: +49 341 48474-315 · [grasse@oemus-media.de](mailto:grasse@oemus-media.de)

# laser

international magazine of laser dentistry

ISLD International Society for Laser Dentistry



## Imprint

### Publisher

Torsten R. Oemus  
[oemus@oemus-media.de](mailto:oemus@oemus-media.de)

### CEO

Ingolf Döbbecke  
[doebbecke@oemus-media.de](mailto:doebbecke@oemus-media.de)

### Members of the Board

Jürgen Isbaner  
[isbaner@oemus-media.de](mailto:isbaner@oemus-media.de)

Lutz V. Hiller  
[hiller@oemus-media.de](mailto:hiller@oemus-media.de)

### Editor in Chief

Norbert Gutknecht  
[ngutknecht@ukaachen.de](mailto:ngutknecht@ukaachen.de)

### Coeditors in Chief

Adam Stabholz  
Matthias Frentzen

### Editorial Managers

Dimitris Strakas  
Leon Vanweersch

### Regional Editors

Georgi Tomov  
*Europe*

Marina Polonsky  
*North America*

Marcia Martins Marques  
*South America*

Youssef Sedky  
*Middle East & Africa*

Ambrose Chan  
*Asia & Pacific*

### Senior Editors

Aslihan Üsümez  
Josep Arnabat  
Kosmas Tolidis  
Andreas Braun  
Rene Franzen  
Lynn Powell

### Editorial Board

Peter Steen Hansen, Aisha Sultan, Ahmed A Hassan, Antonis Kallis, Dimitris Strakas, Kenneth Luk, Reza Fekrazad, Sharonit Sahar-Helft, Lajos Gaspar, Paolo Vescovi, Ilay Maden, Jaana Sippus, Hideaki Suda, Ki-Suk Kim, Miguel Martins, Aslihan Üsümez, Enrique Trevino, José Correia de Campos, Saleh Ghabban, Stephen Hsu, Antoni Espana Tost, Josep Arnabat, Alaa Sultan, Evgeniy Mironov, Ahmed Abdullah, Boris Gaspirc, Peter Fahlstedt, Alireza Fallah, Michel Vock, Anna Maria Yiannikos, Ryan Seto, Joyce Fong, Iris Brader, Masoud Mojahedi, Gerd Volland, Gabriele Schindler, Ralf Borchers, Stefan Grümer, Detlef Klotz, Jörg Meister, Rene Franzen, Andreas Braun, Siegfried Jänicke, Olaf Oberhofer, Thorsten Kleinert

### Editorial Office

Georg Isbaner  
[g.isbaner@oemus-media.de](mailto:g.isbaner@oemus-media.de)

Johannes Liebsch  
[j.liebsch@oemus-media.de](mailto:j.liebsch@oemus-media.de)

### Product Manager

Timo Krause  
[t.krause@oemus-media.de](mailto:t.krause@oemus-media.de)

### Executive Producer

Gernot Meyer  
[meyer@oemus-media.de](mailto:meyer@oemus-media.de)

### Art Director

Alexander Jahn  
[a.jahn@oemus-media.de](mailto:a.jahn@oemus-media.de)

### Designer

Sandra Ehnert  
[s.ehnert@oemus-media.de](mailto:s.ehnert@oemus-media.de)

Theresa Weise

[t.weise@oemus-media.de](mailto:t.weise@oemus-media.de)

### Customer Service

Marius Mezger  
[m.mezger@oemus-media.de](mailto:m.mezger@oemus-media.de)

### Published by

OEMUS MEDIA AG  
Holbeinstraße 29  
04229 Leipzig, Germany  
Tel.: +49 341 48474-0  
Fax: +49 341 48474-290  
[kontakt@oemus-media.de](mailto:kontakt@oemus-media.de)

### Printed by

Silber Druck oHG  
Otto-Hahn-Straße 25  
34253 Lohfelden, Germany

*laser* international magazine of laser dentistry  
is published in cooperation with the International Society for Laser Dentistry (ISLD).

### ISLD Headquarters

University of Aachen Medical Faculty  
Clinic of Conservative Dentistry  
Pauwelsstraße 30  
52074 Aachen, Germany  
Tel.: +49 241 808964  
Fax: +49 241 803389644  
[info@isldlaser.com](mailto:info@isldlaser.com)  
[www.isldlaser.com](http://www.isldlaser.com)

[www.laser-magazine.com](http://www.laser-magazine.com) • [www.oemus.com](http://www.oemus.com)



## Copyright Regulations


*laser* international magazine of laser dentistry is published by OEMUS MEDIA AG and will appear with one issue every quarter in 2019. The magazine and all articles and illustrations therein are protected by copyright. Any utilisation without the prior consent of editor and publisher is inadmissible and liable to prosecution. This applies in particular to duplicate copies, translations, microfilms, and storage and processing in electronic systems. Reproductions, including extracts, may only be made with the permission of the publisher. Given no statement to the contrary, any submissions to the editorial department are understood to be in agreement with a full or partial publishing of said submission. The editorial department reserves the right to check all submitted articles for formal errors and factual authority, and to make amendments if necessary. No responsibility shall be taken for unsolicited books and manuscripts. Articles bearing symbols other than that of the editorial department, or which are distinguished by the name of the author, represent the opinion of the aforementioned, and do not have to comply with the views of OEMUS MEDIA AG. Responsibility for such articles shall be borne by the author. Responsibility for advertisements and other specially labeled items shall not be borne by the editorial department. Likewise, no responsibility shall be assumed for information published about associations, companies and commercial markets. All cases of consequential liability arising from inaccurate or faulty representation are excluded. General terms and conditions apply, legal venue is Leipzig, Germany.

# SUBSCRIBE NOW!


laser—international magazine of laser dentistry

Interdisciplinary, transparent & market orientated

ONLINE  
SUBSCRIPTION HERE



www.oemus-shop.de



## stay updated:

research

**Use of carbon dioxide  
lasers in dentistry**

case report

**Treatment of oral leukoplakia  
with a 980 nm diode laser**

case report

**Facial swelling caused  
by infected teeth**



Fax: **+49 341 48474-290**

I would like to subscribe for the following journals:

☐ laser—international magazine of laser dentistry 4 issues p.a. € 44\*

☐ implants—international magazine of oral implantology 4 issues p.a. € 44\*

Terms & Conditions: The subscription may be cancelled in written form without due justification within 14 days of order by contacting OEMUS MEDIA AG, Holbeinstraße 29, 04229 Leipzig, Germany. Dispatching notification in good time will suffice. The subscription is automatically extended by another twelve months if it is not cancelled in written form 6 weeks prior to the end of the reference period.

\* All prices include VAT, shipping and handling.

\_\_\_\_\_  
Last Name, First Name

\_\_\_\_\_  
Company

\_\_\_\_\_  
Street

\_\_\_\_\_  
ZIP, City, Country

\_\_\_\_\_  
E-mail

\_\_\_\_\_  
Signature

\_\_\_\_\_  
Credit Card Number

\_\_\_\_\_  
Expiration Date

\_\_\_\_\_  
Security Code

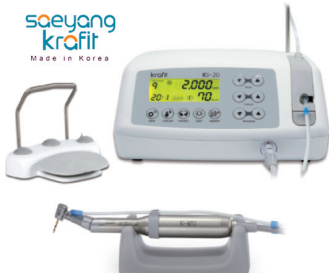**OEMUS MEDIA AG**

Holbeinstraße 29 · 04229 Leipzig · Germany · Phone: +49 341 48474-315 · [grasse@oemus-media.de](mailto:grasse@oemus-media.de)

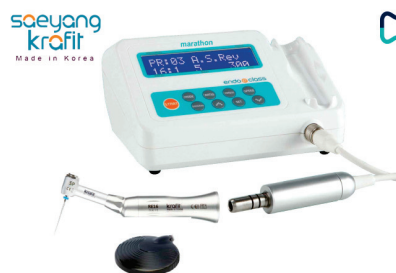



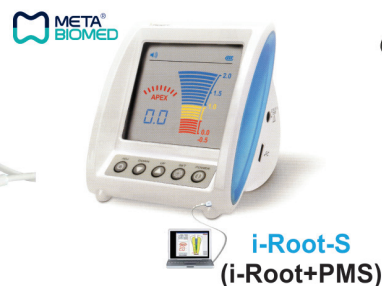### KI-20 (Optic)



### Endo E Class



### i-ROOTS



### EQ-V

