AZADMED.com

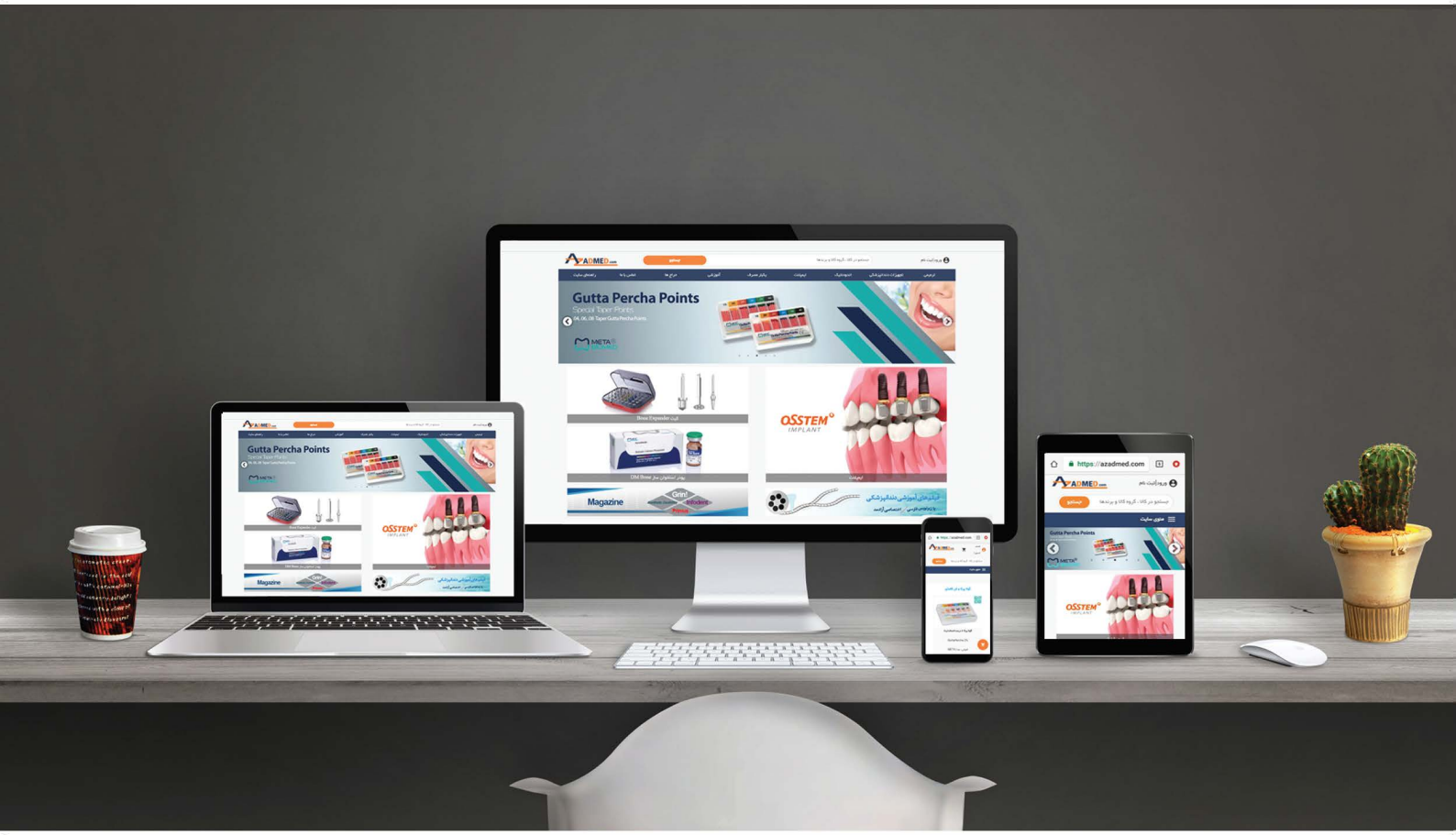

www.azadmed.com

azaadtejaratpars

@azadmed2

88 98 80 63 - 6

Journal of

Oral Science & Rehabilitation

Journal for periodontology, implant dentistry, dental prosthodontics and maxillofacial surgery

ISSN 2365-6123

Volume 2 — Issue 2/2016

dti] Dental Tribune International

in a place that has no borders, creativity goes unbound...

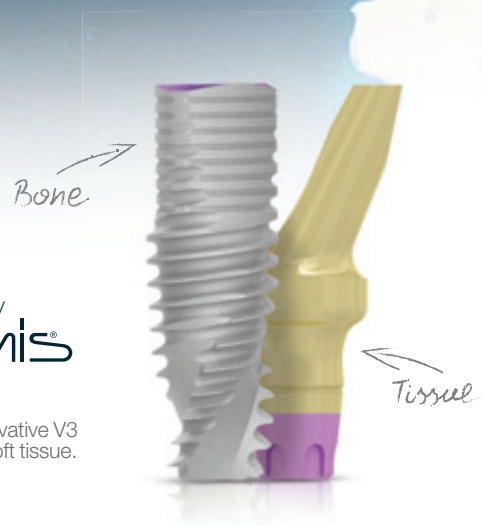

VCONCEPT™ By MIS®

SET THE VOLUME

VCONCEPT is a universal approach that takes into consideration an entire structure: The innovative V3 implant, the advanced prosthetic appliance and their affect on a greater volume of bone and soft tissue. To learn more about VCONCEPT visit: www.vconcept.com

Journal of

Oral Science & Rehabilitation

For dentists, daily clinical work is as easy as driving a car. Their own experience provides them with the necessary confidence and skill. However, the situation changes with the introduction of a new method or product. In order to gain the requisite skill for performing a new technique, it may be enough to participate in practical courses. Using a new biomaterial for regeneration or sinus floor elevation may instead require small changes in technique. However, this may represent a substantial change in biology because biomaterials do not have the same response during healing and do not achieve the same results.

When we have doubts about the quality of a new technique or a new material, we often ask for the opinion of experts and we trust their advice. It would, however, be better to be already well prepared so that we may gain greater value from consultations with experts about the issue of interest.

Only through continued updating is it possible to gain the knowledge to help us make independent choices regarding materials and methods to be used in our daily practice and, indeed, the *Journal of Oral Science & Rehabilitation* was born out of a desire to update clinicians regarding new techniques and materials.

As said above, it is easy to drive a car. However, it may be useful to know how the car functions and how to fix it when it does not work properly.

Dr. Daniele Botticelli
Co-editor

Contents

Tissue care philosophy

- Implant-Prosthesis **adjustment**
- **Integrative surface**
- **Delicacy** in the **drilling** sequence
- **We care** for the **treatment,** we trace every **implant**

MOZOGRAU® ticare

TISSUE CARE PHILOSOPHY

www.ticareimplants.com www.mozo-grau.com

About the *Journal of Oral Science & Rehabilitation*

The aim of the *Journal of Oral Science & Rehabilitation* is to promote rapid communication of scientific information between academia, industry and dental practitioners, thereby influencing the decision-making in clinical practice on an international level.

The *Journal of Oral Science & Rehabilitation* publishes original and high-quality research and clinical papers in the fields of periodontology, implant dentistry, prosthodontics and maxillofacial surgery. Priority is given to papers focusing on clinical techniques and with a direct impact on clinical decision-making and outcomes in the above-mentioned fields. Furthermore, book reviews, summaries and abstracts of scientific meetings are published in the journal.

Papers submitted to the *Journal of Oral Science & Rehabilitation* are subject to rigorous double-blind peer review. Papers are initially screened for relevance to the scope of the journal, as well as for scientific content and quality. Once accepted, the manuscript is sent to the relevant associate editors and reviewers of the journal for peer review. It is then returned to the author for revision and thereafter submitted for copy editing. The decision of the editor-in-chief is made after the review process and is considered final.

About Dental Tribune Science

Dental Tribune Science (DT Science) is an online open-access publishing platform (www.dtscience.com) on which the *Journal of Oral Science & Rehabilitation* is hosted and published.

DT Science is a project of the Dental Tribune International Publishing Group (DTI). DTI is composed of the leading dental trade publishers around the world. For more, visit

www.dental-tribune.com

Benefits of publishing in the journal for authors

There are numerous advantages of publishing in the *Journal of Oral Science & Rehabilitation*:

– Accepted papers are published in print and as e-papers on www.dtscience.com.

– Authors' work is granted exposure to a wide readership, ensuring increased impact of their research through open-access publishing on www.dtscience.com.

– Authors have the opportunity to present and promote their research by way of interviews and articles published on both www.dtscience.com and www.dental-tribune.com.

– Authors can also post videos relating to their research, present a webinar and blog on www.dtscience.com.

Subscription price

€50.00 per issue, including VAT and shipping costs.

Information for subscribers

The journal is published quarterly. Each issue is published as both a print version and an e-paper on www.dtscience.com.

Terms of delivery

The subscription price includes delivery of print journals to the recipient's address. The terms of delivery are delivered at place (DAP); the recipient is responsible for any import duty or taxes.

The role of melatonin in periodontal and periimplant bone homeostasis and regeneration

Pablo Galindo Moreno,[a] Gustavo Avila Ortiz,[b] Hom-Lay Wang,[c] Miguel Padial Molina,[a] Inmaculada Ortega Ollera[a] & Francisco O'Valle[d]

[a] Department of Oral Surgery and Implant Dentistry, School of Dentistry, University of Granada, Granada, Spain
[b] Department of Periodontics, College of Dentistry, University of Iowa, Iowa City, Iowa, U.S.
[c] Department of Periodontics and Oral Medicine, School of Dentistry, University of Michigan, Ann Arbor, Mich., U.S.
[d] Pathology Department, School of Medicine, and Institute of Biopathology and Regenerative Medicine, University of Granada, Granada, Spain

Corresponding author:

Dr. Pablo Galindo Moreno

C/ Recogidas, 39 5º Izq
18005 Granada
Spain

T +34 958 52 0658
F +34 958 52 0658
pgalindo@ugr.es

How to cite this article:

How to cite this article: Galindo Moreno P, Avila Ortiz G, Wang HL, Padial Molina M, Ortega Oller I, O'Valle F. The role of melatonin in periodontal and periimplant bone homeostasis and regeneration.

J Oral Science Rehabilitation. 2016 Jun;2(2):8–15.

Abstract

Background

Melatonin, a hormone produced primarily in the pineal gland, possesses a series of biological properties that appear to have an influence on bone homeostasis. Currently, little is known about how melatonin influences bone metabolism in periodontology and implantology.

Objectives

The objectives of this study are (1) to review the properties of melatonin in regulating bone homeostasis; (2) to discuss its direct and indirect effects on bone; and (3) to propose mechanisms for the use of melatonin as an agent to promote alveolar bone regeneration.

Conclusion

Melatonin positive regulation of bone formation and homeostasis, in combination with the inhibitory effects on bone resorption, highlights the potential use of melatonin as a marker of periodontal and periimplant bone-related diseases. *In vitro* and animal studies show promising results on the use of melatonin as a regenerative agent, although no clinical studies have yet been performed.

Keywords

Melatonin, osteoblasts, osteoclasts, periodontal disease, dental implant, free radicals.

Introduction

Numerous systemic hormonal changes are known to be associated with aging.[1] Some conditions linked to circadian rhythms and age may alter bone metabolism, resulting in changes in immune activity or bone-associated pathologies,[2] such as periodontal disease. These disorders may be associated with alterations in normal levels of melatonin.[3, 4]

Melatonin (*N*-acetyl-5-methoxytryptamine), a hormone that is endogenously synthesized, primarily in the pineal gland, is a molecule with intense antioxidant activity[5] and a wide range of biological actions, notably in the control of metabolism and bone development.[6] Melatonin is currently used in therapies as a coadjuvant in cancer therapy,[7] for anti-aging,[8] as an immunostimulatory agent[9] or as a sleep regulator,[10] as well as to increase bone density in menopausal patients[11] **(Fig. 1)**. It is reported that salivary melatonin is released by the acinar cells of the major salivary glands and the gingival crevicular fluid. It follows a circadian rhythm, with the highest values at night. Moreover, in the oral cavity, melatonin can act both by receptor-mediated and by receptor-independent pathways.[12] Therefore, through complex molecular pathways that have gained special interest for the research community in periodontology, it may play a role in alveolar periodontal and periimplant bone maintenance and regeneration.

Melatonin is an amphiphilic molecule that is able to cross most biological barriers. It can exert its effect by binding to G-protein-coupled membrane receptors (MT_1 and MT_2) or by penetrating the cell through a specific family of transmembrane channels,[13] subsequently initiating a nuclear or cytoplasmic molecular cascade. When it reaches the nuclei, melatonin binds to a subfamily of nuclear receptors key in regulating bone metabolism, the RZR (retinoid Z receptor)/ROR (retinoid orphan receptor) receptor.[14] It then regulates a number of cellular events, such as promotion of mitosis, induction of DNA repair,[15] or cell differentiation and proliferation.[16]

Interestingly, it is known that melatonin can be synthesized in the bone marrow, where its concentration is around 100-fold higher than in serum.[17] Furthermore, melatonin in the bone marrow protects its cells against cytotoxic agents *in vivo*.[18] However, the specific biochemical mechanisms that regulate this modulation, specifically in alveolar bone in humans, are currently not fully understood.[11] Hence, it is the purpose of this review to describe the properties of melatonin in regulating bone homeostasis, directly and indirectly, as well as to analyze different therapeutic strategies for the use of melatonin as an agent to promote periodontal and periimplant bone maintenance and regeneration **(Fig. 2)**.

Direct effects on bone

I. Melatonin and bone formation

The major organic component of bone extracellular matrix is Type I collagen, which supports the expression of bone cell phenotypes and enhances mineralization. Melatonin has been shown to regulate the synthesis of Type I collagen as a preliminary step to the expression of other bone-related proteins, such as bone sialoprotein, alkaline phosphatase and osteocalcin, during osteoblastic maturation.[16]

Bone sialoprotein (BSP) is referred to as a marker of the late stage of osteoblastic differentiation. BSP is expressed during osteoblastic cell differentiation in the extracellular matrix, where it is essential for osteoblast attachment and bone mineralization. Within this context, it has been reported that MC3T3 pre-osteoblast cells matured in 12 days in the presence of melatonin compared with 21 days without melatonin. Gene expression of BSP and related proteins of osteoblastic differentiation (e.g., osteocalcin, alkaline phosphatase) is also accelerated and increased in melatonin-treated compared with nontreated cells.[19] Furthermore, by inhibiting the interaction of BSP with osteoblastic cell lines, the activity of alkaline phosphatase, osteocalcin synthesis and cellular response to parathyroid hormone (PTH) are also inhibited[20] and, subsequently, osteoblast differentiation is impaired.[21] Thus, these findings suggest that melatonin may have an effect in regulating osteoblast proliferation and differentiation. These effects could lead to beneficial effects in the treatment of pathological processes associated with bone resorption or destruction by mediating not only in the expression of BSP but of other bone glycoproteins as well, resulting in enhanced bone apposition.

II. Melatonin and bone resorption

Melatonin also exerts an important direct biological action on the osteoclast, another key cell in

Fig. 1

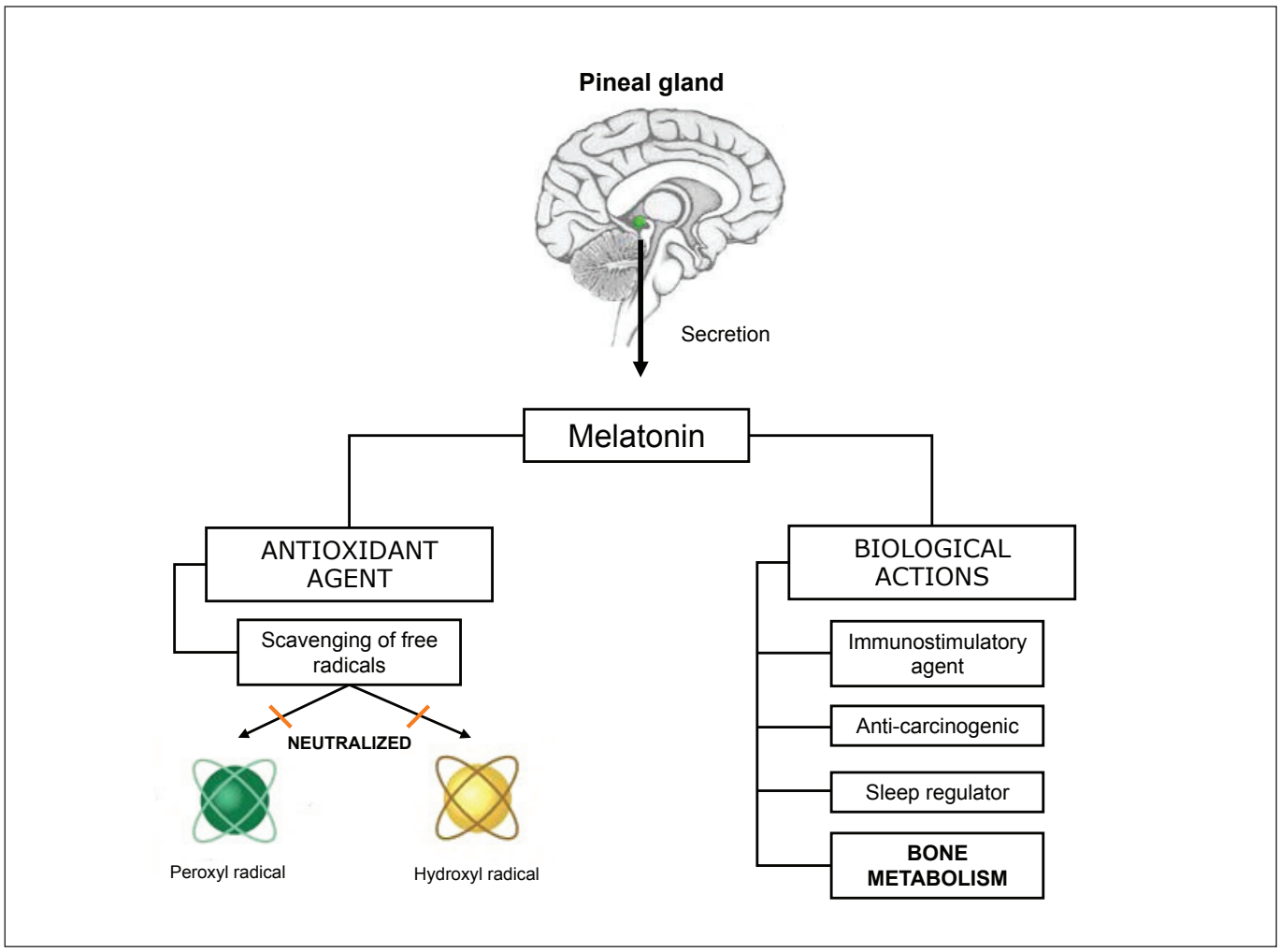

Fig. 1

Melatonin properties.

bone turnover. The biological activity of osteoclasts is bone resorption, initiated by attachment to the surface of the bone tissue and secreting protons and free radicals into the cell compartment formed below their ruffled border. The activity of osteoclasts is essentially regulated by the molecular triad osteoprotegerin/receptor activator of nuclear factor-kappa B/receptor activator of nuclear factor-kappa-B ligand (OPG/RANK/RANKL). The balance and expression of this triad in bone tissue decisively influence differentiation and activation of osteoclasts and play an important role in coordinating osteogenesis, odontogenesis and tooth eruption. The proteins of this triad can be synthesized by a large number of cells, including bone marrow cells, dendritic cells, lymphoid cells and endothelial cells. Osteoblasts are the key cell type in the secretion of OPG and RANKL and, therefore, orchestrate the bone turnover. Changes in the expression balance of this triad can be responsible for hereditary bone disorders, such as familiar expansile osteolysis, expansile skeletal hyperphosphatasia and juvenile Paget's disease; different forms of osteoporosis; and other metabolic bone diseases.

The OPG/RANK/RANKL triad can be modulated by numerous molecules, including melatonin.[22] Melatonin suppresses osteoclastic and osteoblastic activity by interacting with this triad.[23] It reduces the expression of RANK in osteoblasts[24] and RANK receptor in osteoclasts[19] while increasing OPG,[24] eventually preventing the appearance and activation of osteoclasts.[19] This suggests that melatonin in pharmacological doses can inhibit bone resorption and increase bone mass by down-regulating RANK-mediated osteoclast proliferation and activation.[24]

Another important aspect of the relationship between osteoclasts and melatonin concerns the production of free radicals by osteoclasts during osteolysis. Osteoclasts generate high levels of superoxide anions during bone resorption that contribute to the degenerative process of the organic bone matrix. One of the most important

Fig. 2

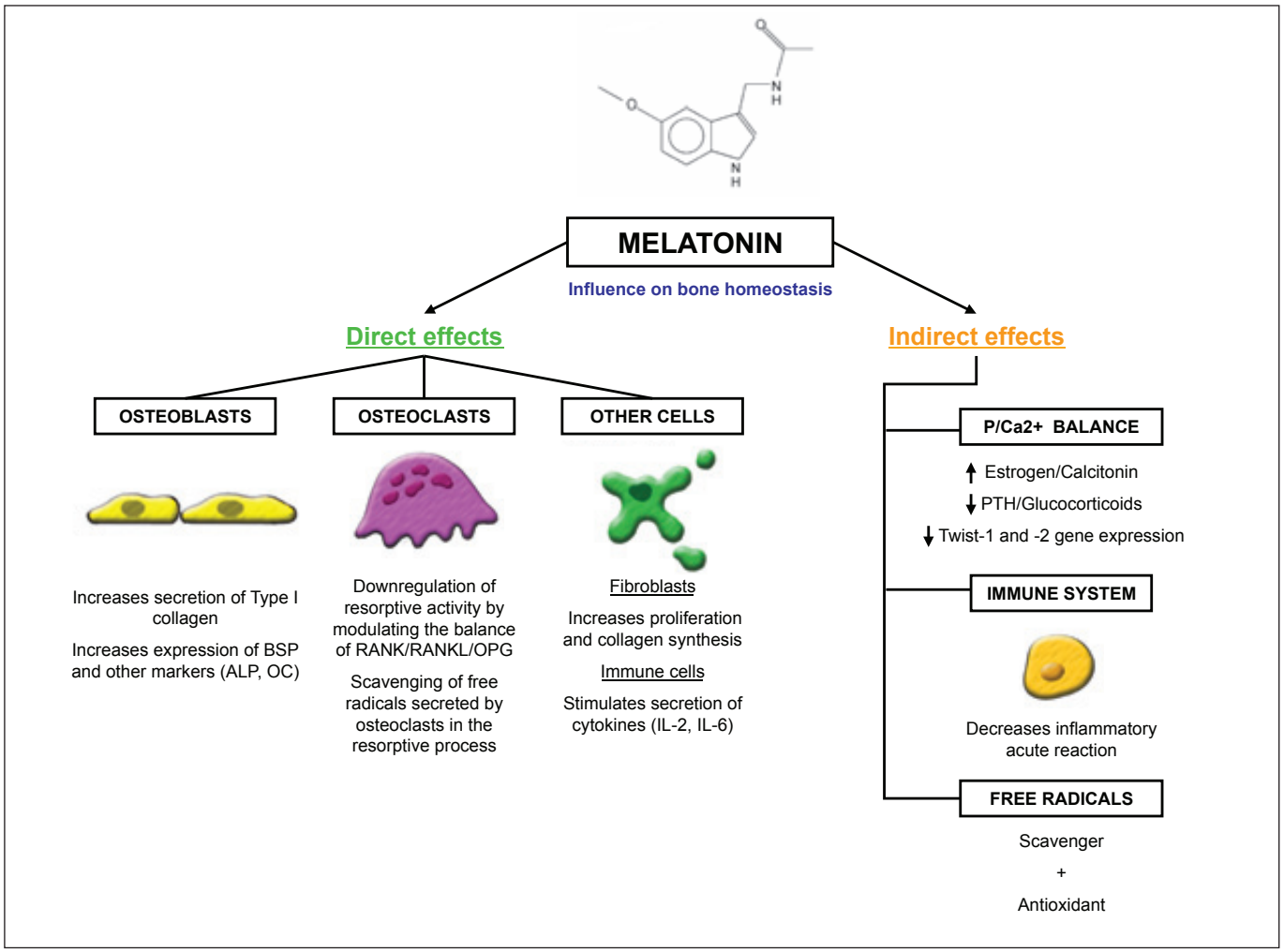

Fig. 2

Effects of melatonin on bone. ALP: alkaline phosphatase; OC: osteocalcin.

mechanisms underlying this resorption involves the protective superoxide-scavenging enzyme superoxide dismutase. Melatonin is a significant free-radical scavenger and antioxidant at both physiological and pharmacological concentrations.[6] Beside its ability to directly neutralize a number of free radicals and reactive oxygen and nitrogen species, melatonin stimulates several antioxidative enzymes,[19,25] limiting the resorptive osteoclast activity.

Indirect effects on bone

I. Relationship with hormones and genes involved in bone turnover

Melatonin is an important modulator of calcium and phosphorus metabolism.[26] In addition to its direct actions on cells that modulate bone homeostasis, melatonin may exert its effects indirectly on the bone system by influencing the activity of important regulators of the phosphorus–calcium balance and bone metabolism. Many studies have indicated that melatonin may influence the release of several factors that affect bone, such as calcitonin,[27] corticosterone,[28] growth factors[29] and immunological factors.[30]

- Calcitonin, together with bisphosphonates and estrogens, is an important regulator of the apoptosis of osteoclasts. It is a powerful inhibitor of osteoclastic resorptive activity by promoting the reduction of contact between osteoclasts and the bone surface, altering the morphology of osteoclasts and decreasing their mobility. Melatonin increases secretion of calcitonin in rats, and this may inhibit bone resorption.[31]
- PTH increases the expression of RANKL and decreases the expression of OPG. Melatonin decreases the levels of PTH, and this may, indirectly, generate an increase in bone mineralization.[32]

– Cortisol (also known as hydrocortisone) and other glucocorticoids are increased when melatonin is reduced. They are responsible for inhibiting bone formation through direct actions on osteoblasts by blocking their recruitment and differentiation, and subsequently inhibiting the production of Type I collagen. An increase in cortisol is also responsible for an increase in bone resorption via antagonism of the 1,25-dihydroxyvitamin D. Therefore, as melatonin increases, glucocorticoids are reduced and their pro-resorptive effects are limited.
– Melatonin also stimulates estrogen secretion and, therefore, limits the associated deleterious effects of deficiency.[33]

II. Action in immune system

The role played by melatonin in the immune system is well documented.[34] The effects of melatonin have been most widely studied in the context of depressed immune systems with the aim of improving immunodeficiency situations. Melatonin regulates the apoptosis of B and T cells and has been reported to accelerate the production of leukocytes.[35]
In addition to the direct effect on cells of the immune system, melatonin reduces the synthesis of prostaglandins, especially PGE-2; prevents the translocation of nuclear factor-kappa B to the nucleus and its binding to DNA, thereby reducing the up-regulation of a variety of pro-inflammatory cytokines;[36] inhibits the production of adhesion molecules that promotes the adhesion of leukocytes to endothelial cells;[37] and attenuates transendothelial cell migration and edema, which contribute to tissue damage.[30] It also stimulates the release of interleukin-2 in Jurkat cells[38] and interleukin-6 in peripheral blood mononuclear cells,[39] while it inhibits the inflammatory enzyme cyclooxygenase-2 (COX-2) and binds to the active sites of COX-1 and COX-2.[40] Therefore, melatonin can inhibit acute inflammatory reaction and contribute to generating an immune reaction, minimizing the associated bone loss.[30]

III. Action on free radicals

One of the principal biological actions of melatonin is its wide antioxidant spectrum and powerful endogenous effect as a free-radical scavenger.[41] Thus, it has an indirect reparative effect and prevents intracellular damage, protecting cells from free radicals and chemical substances. Melatonin acts on oxygen- and nitrogen-derived free radicals, including the highly toxic hydroxyl radical,[42] peroxynitrite anion[43] and hypochlorous acid.[44] In addition to directly neutralizing free radicals and reactive species of nitrogen and oxygen, melatonin stimulates other antioxidant enzymes, such as glutathione.[45]

At the bone level, these effects are of vital importance because osteoclasts secrete a wide variety of molecular agents for bone degradation. Free radicals are the highly secreted ones. Osteoclasts generate superoxide anions during resorption that contribute to the degradative processes of the organic bone matrix. Other cell types, such as monocytes, macrophages and neutrophils, accumulate on the adjacent surfaces of the bone in chronic inflammatory processes. These cells have the capacity to produce free radicals and, as previously mentioned, are able to stimulate osteoclastic response by liberating mediators (cytokines, tumor necrosis factors, etc.). Therefore, the use of anti-free-radical agents might be an adequate alternative therapy for these types of pathologies, by limiting osteoclastic activation or free-radical production.

Melatonin and periodontal disease

Periodontal disease is caused by a bacterial challenge that triggers an inflammatory reaction in a susceptible host. Alterations in the OPG/RANK/RANKL complex, among other cytokines and local factors, have been linked to an increase in the periodontal destruction, mediated by the increase in RANKL production by inflammatory cells, mainly macrophages, and the decrease of OPG. Additionally, the periodontal tissue is affected by the free radicals that burst from phagocytic cells, such as neutrophils and macrophages, which significantly damage the gingival tissue.

In view of these common factors and targets, it is reasonable to expect an association between periodontal disease and levels of melatonin.[46] Several clinical studies have demonstrated it.[3,4,47] These studies showed that levels of melatonin in serum, saliva, gingival crevicular fluid or all three are inversely associated with the severity of the disease, which indicates that melatonin may have a protective role against periodontal disease.

Moreover, the effects of melatonin on the reduction of osteoclastogenesis, the capture of reactive oxygen species and their metabolites in the inflamed area, the increase in bone minera-

lization through the increase in proliferation, differentiation and activity of osteoblasts, and collagen and BSP regulation, as already explained, together with its anti-fibrotic and anti-inflammatory effects on gingival tissue by a reduction of the matrix metalloproteinase-1/tissue inhibitor of metalloproteinases-1 ratio, suggest the possibility of using melatonin as a host-modulating agent in the treatment and control of periodontal disease, improving the bone tissue conditions and the soft-tissue stability.[48] The *in vivo* administration of local or systemic melatonin could, therefore, be indicated in these patients, although no studies have yet been performed in this sense with validated methods.

Melatonin and dental implants

Dental implants are commonly used in current treatment of tooth loss. However, to avoid potential early complications and implant failures,[49, 50] bone healing must occur in the proper way. Bone remodeling around dental implants is highly influenced by the implant surface characteristics and evolves as a balance between the activity of osteoblasts and osteoclasts.[51, 52] Therefore, the use of melatonin as a topical agent to induce biomimetic properties of the implant surface has emerged as a promising technique.[53] Melatonin directly influences the osteoblast's response to the implant surface and osseointegration. The addition of melatonin improves results for cell adhesion, proliferation and differentiation on different titanium surface modifications at early time points, although longer culturing times seem to reduce those differences.[54]

These effects have been confirmed *in vivo* in several studies.[55, 56] The effects around dental implants are similar to those that take place in bone repair. Bone repair consists, biologically, of three different stages: inflammatory, proliferative and remodeling. Melatonin may play a role in these phases owing to its regulatory effects on inflammation, antioxidant properties, regulation of bone cells, and stimulation of collagen synthesis and deposition. Moreover, melatonin has been shown to increase the number of blood vessels, which is a prerequisite for the supply of mineral elements and the migration of angiogenic and osteogenic cells. As a consequence, histological evaluation of the periimplant bone shows more trabecular bone, but less cortical bone and higher bone-to-implant contact in melatonin-treated sockets compared with controls.[55] Therefore, the use of melatonin for osseointegration might be of interest as a biomimetic agent. Moreover, it has been suggested to induce bone growth when applied in combination with bone grafts.[56] However, its potential use in regenerating post-periimplantitis defects has not been studied yet.

Conclusion

Melatonin positive regulation of bone formation and homeostasis, in combination with the inhibitory effects on bone resorption, highlights the potential use of melatonin as a marker of periodontal and periimplant bone-related diseases. Moreover, *in vitro* and animal studies are starting to show promising results on its use as a regenerative agent, although no clinical studies have yet been performed. This new strategy may create possibilities for novel therapies in the treatment of periodontal disease or enhancing the outcomes of implant dentistry.

Competing interests

The authors declare that they have no conflict of interests related to this study.

Acknowledgments

The authors would like to thank Mr. Chris Jung for the original images presented in this review. MPM received funding from the Talentia Fellowship Program (Regional Government of Andalusia, Spain). The authors have been partially supported by Research Groups No. CTS-138 and No. CTS-583 (Regional Government of Andalusia) and by the Andalucía Talent Hub Fellowship Program (European Union's Seventh Framework Programme, Marie Skłodowska-Curie actions, COFUND, grant agreement No. 291780; and Regional Government of Andalusia).

References

1.
Morley JE. Hormones and the aging process.
→ J Am Geriatr Soc.
2003 Jul;51(7 Suppl):S333–7.

2.
Eastell R, Calvo MS, Burritt MF, Offord KP, Russell RG, Riggs BL. Abnormalities in circadian patterns of bone resorption and renal calcium conservation in type I osteoporosis.
→ J Clin Endocrinol Metab.
1992 Mar;74(3):487–94.

3.
Cutando A, Galindo P, Gómez-Moreno G, Arana C, Bolaños J, Acuña-Castroviejo D, Wang HL. Relationship between salivary melatonin and severity of periodontal disease.
→ J Periodontol.
2006 Sep;77(9):1533–8.

4.
Gómez-Moreno G, Cutando-Soriano A, Arana C, Galindo P, Bolaños J, Acuña-Castroviejo D, Wang HL. Melatonin expression in periodontal disease.
→ J Periodontal Res.
2007 Dec;42(6):536–40.

5.
Reiter RJ, Tan DX, Poeggeler B, Menendez-Pelaez A, Chen LD, Saarela S. Melatonin as a free radical scavenger: implications for aging and age-related diseases.
→ Ann N Y Acad Sci.
1994 May;719:1–12.

6.
Liu J, Huang F, He HW. Melatonin effects on hard tissues: bone and tooth.
→ Int J Mol Sci.
2013 May;14(5):10063–74.

7.
Rapozzi V, Zorzet S, Comelli M, Mavelli I, Perissin L, Giraldi T. Melatonin decreases bone marrow and lymphatic toxicity of adriamycin in mice bearing TLX5 lymphoma.
→ Life Sci.
1998 Oct;63(19):1701–13.

8.
Poeggeler B. Melatonin, aging, and age-related diseases: perspectives for prevention, intervention, and therapy.
→ Endocrine.
2005 Jul;27(2):201–12.

9.
Maestroni GJ. MLT and the immune-hematopoietic system. In: Olcese J, editor. Melatonin after four decades: an assessment of its potential.
→ New York: Springer;
1999. p. 395–405. (Advances in Experimental Medicine and Biology; vol. 460).

10.
Buscemi N, Vandermeer B, Pandya R, Hooton N, Tjosvold L, Hartling L, Baker G, Vohra S, Klassen T. Melatonin for treatment of sleep disorders.
→ Evid Rep Technol Assess (Summ).
2004 Nov;(108):1–7.

11.
Ostrowska Z, Kos-Kudla B, Marek B, Swietochowska E, Górski J. Assessment of the relationship between circadian variations of salivary melatonin levels and type I collagen metabolism in postmenopausal obese women.
→ Neuro Endocrinol Lett.
2001 Apr;22(2):121–7.

12.
Reiter RJ, Rosales-Corral SA, Liu XY, Acuna-Castroviejo D, Escames G, Tan DX. Melatonin in the oral cavity: physiological and pathological implications.
→ J Periodontal Res.
2015 Feb;50(1):9–17.

13.
Reppert SM, Weaver DR, Godson C. Melatonin receptors step into the light: cloning and classification of subtypes.
→ Trends Pharmacol Sci.
1996 Mar;17(3):100–2.

14.
Meyer T, Kneissel M, Mariani J, Fournier B. *In vitro* and *in vivo* evidence for orphan nuclear receptor RORα function in bone metabolism.
→ Proc Natl Acad Sci U S A.
2000 Aug;97(16):9197–202.

15.
Tan D, Reiter RJ, Chen LD, Poeggeler B, Manchester LC, Barlow-Walden LR. Both physiological and pharmacological levels of melatonin reduce DNA adduct formation induced by the carcinogen safrole.
→ Carcinogenesis.
1994 Feb;15(2):215–8.

16.
Nakade O, Koyama H, Ariji H, Yajima A, Kaku T. Melatonin stimulates proliferation and type I collagen synthesis in human bone cells in vitro.
→ J Pineal Res.
1999 Sep;27(2):106–10.

17.
Tan DX, Manchester LC, Reiter RJ, Qi WB, Zhang M, Weintraub ST, Cabrera J, Sainz RM, Mayo JC. Identification of highly elevated levels of melatonin in bone marrow: its origin and significance.
→ Biochim Biophys Acta.
1999 Oct;1472(1-2):206–14.

18.
Anwar MM, Mahfouz HA, Sayed AS. Potential protective effects of melatonin on bone marrow of rats exposed to cytotoxic drugs.
→ Comp Biochem Physiol A Mol Integr Physiol.
1998 Feb;119(2):493–501.

19.
Cardinali DP, Ladizesky MG, Boggio V, Cutrera RA, Mautalen C. Melatonin effects on bone: experimental facts and clinical perspectives.
→ J Pineal Res.
2003 Mar;34(2):81–7.

20.
Mizuno M, Imai T, Fujisawa R, Tani H, Kuboki Y. Bone sialoprotein (BSP) is a crucial factor for the expression of osteoblastic phenotypes of bone marrow cells cultured on type I collagen matrix.
→ Calcif Tissue Int.
2000 May;66(5):388–96.

21.
Cooper LF, Yliheikkilä PK, Felton DA, Whitson SW. Spatiotemporal assessment of fetal bovine osteoblast culture differentiation indicates a role for BSP in promoting differentiation.
→ J Bone Miner Res.
1998 Apr;13(4):620–32.

22.
Theoleyre S, Wittrant Y, Tat SK, Fortun Y, Redini F, Heymann D. The molecular triad OPG/RANK/RANKL: involvement in the orchestration of pathophysiological bone remodeling.
→ Cytokine Growth Factor Rev.
2004 Dec;15(6):457–75.

23.
Suzuki N, Hattori A. Melatonin suppresses osteoclastic and osteoblastic activities in the scales of goldfish.
→ J Pineal Res.
2002 Nov;33(4):253–8.

24.
Koyama H, Nakade O, Takada Y, Kaku T, Lau KH. Melatonin at pharmacologic doses increases bone mass by suppressing resorption through down-regulation of the RANKL-mediated osteoclast formation and activation.
→ J Bone Miner Res.
2002 Jul;17(7):1219–29.

25.
Ladizesky MG, Boggio V, Albornoz LE, Castrillón PO, Mautalen C, Cardinali DP. Melatonin increases oestradiol-induced bone formation in ovariectomized rats.
→ J Pineal Res.
2003 Mar;34(2):143–51.

26.
Ladizesky MG, Cutrera RA, Boggio V, Somoza J, Centrella JM, Mautalen C, Cardinali DP. Effect of melatonin on bone metabolism in ovariectomized rats.
→ Life Sci.
2001 Dec;70(5):557–65.

27.
Turgut M, Uslu S, Uysal A, Yurtseven ME, Ustün H. Changes in vascularity of cartilage endplate of degenerated intervertebral discs in response to melatonin administration in rats.
→ Neurosurg Rev.
2003 May;26(2):133–8.

28.
Hakanson DO, Bergstrom WH. Pineal and adrenal effects on calcium homeostasis in the rat.
→ Pediatr Res.
1990 Jun;27(6):571–3.

29.
Ostrowska Z, Kos-Kudla B, Marek B, Kajdaniuk D. Influence of lighting conditions on daily rhythm of bone metabolism in rats and possible involvement of melatonin and other hormones in this process.
→ Endocr Regul.
2003 Sep;37(3):163–74.

30.
Reiter RJ, Calvo JR, Karbownik M, Qi W, Tan DX. Melatonin and its relation to the immune system and inflammation.
→ Ann N Y Acad Sci.
2000 Jan;917:376–86.

31.
Ostrowska Z, Kos-Kudla B, Marek B, Kajdaniuk D, Ciesielska-Kopacz N. The relationship between the daily profile of chosen biochemical markers of bone metabolism and melatonin and other hormone secretion in rats under physiological conditions.
→ Neuro Endocrinol Lett.
2002 Oct-Dec;23(5-6):417–25.

32.
Sandyk R, Anastasiadis PG, Anninos PA, Tsagas N. Is postmenopausal osteoporosis related to pineal gland functions?
→ Int J Neurosci.
1992 Feb;62(3-4):215–25.

33.
Okatani Y, Morioka N, Wakatsuki A. Changes in nocturnal melatonin secretion in perimenopausal women: correlation with endogenous estrogen concentrations.
→ J Pineal Res.
2000 Mar;28(2):111–8.

34.
Carrillo-Vico A, Guerrero JM, Lardone PJ, Reiter RJ. A review of the multiple actions of melatonin on the immune system.
→ Endocrine.
2005 Jul;27(2):189–200.

35.
Guerrero JM, Reiter RJ. Melatonin-immune system relationships.
→ Curr Top Med Chem.
2002 Feb;2(2):167–79.

36.
Mohan N, Sadeghi K, Reiter RJ, Meltz ML. The neurohormone melatonin inhibits cytokine, mitogen and ionizing radiation induced NF-kappa B.
→ Biochem Mol Biol Int.
1995 Dec;37(6):1063–70.

37.
Bertuglia S, Marchiafava PL, Colantuoni A. Melatonin prevents ischemia reperfusion injury in hamster cheek pouch microcirculation.
→ Cardiovasc Res.
1996 Jun;31(6):947–52.

38.
Guerrero JM, Pozo D, García-Mauriño S, Osuna C, Molinero P, Calvo JR. Involvement of nuclear receptors in the enhanced IL-2 production by melatonin in Jurkat cells.
→ Ann N Y Acad Sci.
2000 Jan;917:397–403.

39.
Garcia-Mauriño S, Gonzalez-Haba MG, Calvo JR, Goberna R, Guerrero JM. Involvement of nuclear binding sites for melatonin in the regulation of IL-2 and IL-6 production by human blood mononuclear cells.
→ J Neuroimmunol.
1998 Dec;92(1-2):76–84.

40.
De la Rocha N, Rotelli A, Aguilar CF, Pelzer L. Structural basis of the anti-inflammatory activity of melatonin.
→ Arzneimittelforschung.
2007;57(12):782–6.

41.
Reiter RJ, Tan DX, Mayo JC, Sainz RM, Leon J, Czarnocki Z. Melatonin as an antioxidant: biochemical mechanisms and pathophysiological implications in humans.
→ Acta Biochim Pol.
2003 Jan;50(4):1129–46.

42.
Stasica P, Ulanski P, Rosiak JM. Melatonin as a hydroxyl radical scavenger.
→ J Pineal Res.
1998 Aug;25(1):65–6.

43.
Gilad E, Cuzzocrea S, Zingarelli B, Salzman AL, Szabó C. Melatonin is a scavenger of peroxynitrite.
→ Life Sci.
1997 Jan;60(10):PL169–74.

44.
Marshall KA, Reiter RJ, Poeggeler B, Aruoma OI, Halliwell B. Evaluation of the antioxidant activity of melatonin in vitro.
→ Free Radic Biol Med.
1996 Dec;21(3):307–15.

45.
Chapple IL. Reactive oxygen species and antioxidants in inflammatory diseases.
→ J Clin Periodontol.
1997 May;24(5):287–96.

46.
Cengiz Mİ, Cengiz S, Wang HL. Melatonin and oral cavity.
→ Int J Dent [Internet].
2012 Jun 25 [cited 2016 May 4];2012:Article 491872 [9 p.]. Available from: downloads.hindawi.com/journals/ijd/2012/491872.pdf
doi:10.1155/2012/491872.

47.
Srinath R, Acharya AB, Thakur SL. Salivary and gingival crevicular fluid melatonin in periodontal health and disease.
→ J Periodontol.
2010 Feb;81(2):277–83.

48.
Gómez-Florit M, Ramis JM, Monjo M. Anti-fibrotic and anti-inflammatory properties of melatonin on human gingival fibroblasts *in vitro*.
→ Biochem Pharmacol.
2013 Dec;86(12):1784–90.

49.
Galindo-Moreno P, Padial-Molina M, Avila G, Rios HF, Hernández-Cortés P, Wang HL. Complications associated with implant migration into the maxillary sinus cavity.
→ Clin Oral Implants Res.
2012 Oct;23(10):1152–60.

50.
Galindo-Moreno P, Padial-Molina M, Sánchez-Fernández E, Hernández-Cortés P, Wang HL, O'Valle F. Dental implant migration in grafted maxillary sinus.
→ Implant Dent.
2011 Dec;20(6):400–5.

51.
Padial-Molina M, Galindo-Moreno P, Fernández-Barbero JE, O'Valle F, Jódar-Reyes AB, Ortega-Vinuesa JL, Ramón-Torregrosa PJ. Role of wettability and nanoroughness on interactions between osteoblast and modified silicon surfaces.
→ Acta Biomater.
2011 Feb;7(2):771–8.

52.
Padial-Molina M, Galindo-Moreno P, Avila-Ortiz G. Biomimetic ceramics in implant dentistry.
→ Minerva Biotecnol.
2009 Sep;21(3):173–86.

53.
Gómez-Moreno G, Aguilar-Salvatierra A, Boquete-Castro A, Guardia J, Piattelli A, Perrotti V, Delgado-Ruiz RA, Calvo-Guirado JL. Outcomes of topical applications of melatonin in implant dentistry: a systematic review.
→ Implant Dent.
2015 Feb;24(1):25–30.

54.
Solá-Ruiz MF, Pérez-Martínez C, Martín-del-Llano JJ, Carda-Batalla C, Labaig-Rueda C. *In vitro* preliminary study of osteoblast response to surface roughness of titanium discs and topical application of melatonin.
→ Med Oral Patol Oral Cir Bucal.
2015 Jan;20(1):e88–93.

55.
Tresguerres IF, Clemente C, Blanco L, Khraisat A, Tamimi F, Tresguerres JA. Effects of local melatonin application on implant osseointegration.
→ Clin Implant Dent Relat Res.
2012 Jun;14(3):395–9.

56.
Calvo-Guirado JL, Gómez-Moreno G, Maté-Sánchez JE, López-Marí L, Delgado-Ruiz R, Romanos GE. New bone formation in bone defects after melatonin and porcine bone grafts: experimental study in rabbits.
→ Clin Oral Implants Res.
2015 Apr;26(4):399–406.

Three-year clinical and radiographic outcomes of patients treated according to the All-on-4 concept in the daily practice: A prospective observational study on implants and prosthesis survival rates and complications

Marco Tallarico,[a] Silvio Mario Meloni,[b] Erta Xhanari[c] & Luigi Canullo[d]

[a] Private practice, Rome, Italy
& University of Sassari, Sassari, Italy
[b] University of Sassari, Sassari, Italy
[c] Independent researcher, Tirana, Albania
[d] Independent researcher, Rome, Italy

Corresponding author:

Dr. Marco Tallarico
Via di Val Tellina 116
00151 Rome
Italy

M +39 3280758769
me@studiomarcotallarico.it

How to cite this article:

Tallarico M, Meloni MS, Xhanari E, Canullo L. Three-year clinical and radiographic outcomes of patients treated according to the All-on-4 concept in the daily practice: a prospective observational study on implants and prosthesis survival rates and complications.

J Oral Science Rehabilitation.
2016 Jun;2(2):16–25.

Abstract

Objective

All-on-4 treatment concept is widely applied for complete-arch rehabilitations. Nevertheless, minor technical and biological complications can occur. The objective of this study was to evaluate the three-year clinical and radiographic data of complete-arch fixed dental prostheses supported by four implants according to the All-on-4 protocol.

Materials and methods

Thirty consecutive edentulous patients or patients with terminal dentition (18 females and 12 males; mean age of 67.4 years), with a preference for implant-supported complete-arch screw-retained fixed dental prostheses, were enrolled and treated according to the All-on-4 protocol between January 2008 and December 2011. The outcomes evaluated were implant and prosthesis survival and success rates, any technical and biological complications, periimplant marginal bone loss and patient satisfaction.

Results

One hundred and twenty regular platform implants were placed. No patients dropped out. One implant failed two months after placement, resulting in a cumulative implant survival rate of 99.2%. No definitive prostheses failed. Eight technical and three biological complications were reported in 11 patients during the entire follow-up period. At the three-year examination, the mean marginal bone loss was 1.52 ± 0.41 mm.

Conclusion

Within the limitations of the present study, the All-on-4 protocol was deemed a viable treatment concept for the complete-arch rehabilitation of both jaws in the medium term. Further long-term prospective studies are needed to confirm these results.

Introduction

Complete edentulism is associated with decreased masticatory function, as well as unfavorable esthetics due to the loss of support for the facial musculature, decreased vertical dimension and speech impairment.[1–3] The conventional method for treating edentulous patients is to rehabilitate them with a complete removable denture. However, the denture must be adjusted over time to compensate for the progressive tissue changes associated with denture wearing.[4, 5] Advances in implant dentistry have allowed a shift from a complete removable denture to an implant-supported overdenture for the oral rehabilitation of edentulous patients.[6] The McGill consensus statement in 2002[7, 8] and some independent studies[9–11] state that mandibular two-implant overdentures are the gold standard for edentulous patients. However, technical and biological complications can occur.[12–15]

In two pilot retrospective studies, Maló et al. presented a planning protocol for the rehabilitation of the edentulous mandible and maxilla using four implants (All-on-4, Nobel Biocare, Kloten, Switzerland) to overcome anatomical limitations in the mandible that make it challenging to treat without the use of more complex techniques.[16, 17] The two most anterior implants are placed axially, and the posterior implants are placed in an angled position to maximize implant length and avoid anatomical structures (i.e., the mental nerve and anterior border of the maxillary sinus). The All-on-4 treatment concept seems to be a safe, effective and efficient surgical and prosthetic procedure on both jaws after ten years in function.[18, 19] However, as confirmed in a recent systematic review, few independent uncontrolled prospective and retrospective studies have confirmed these preliminary results.[20]

The purpose of this prospective observational study was to evaluate the three-year clinical and radiographic outcomes of implant-supported complete-arch fixed dental prostheses (FDPs) delivered on four implants placed according to the All-on-4 protocol in edentulous or partially edentate patients with a preference for an implant-supported restoration. This study followed the Strengthening the Reporting of Observational Studies in Epidemiology guidelines.[21]

Materials and methods

This prospective observational study was designed to evaluate patients treated according to the All-on-4 protocol in the mandible or maxilla. The patients were selected and treated in two private centers in Rome and Sassari, between January 2008 and December 2011.

The inclusion criteria were a healthy patient aged 18 years or older at the time of implant placement, able to give her or his informed consent for participation, with a residual alveolar crest, distal to the first premolar, of ≤ 5 mm in height and ≤ 4 mm in width, assessed by computed tomography (CT) or scans, and refusal of a conventional bone augmentation procedure; partially edentate patient with hopeless dentition based on multiple risk factors, including endodontic[22] and periodontal criteria,[23] prosthetic restorability of the tooth, cost–benefit ratio and patient preference in terms of refusing any major bone augmentation procedures.

The exclusion criteria were general medical (American Society of Anesthesiologists Physical Status Class III or IV) and/or psychiatric contraindications; pregnancy or nursing; any interfering medication, such as steroid therapy or bisphosphonate therapy; alcohol or drug abuse; heavy smoking (> 10 cigarettes/day); radiation therapy to the head or neck region within five years; high or moderate parafunctional activity; untreated periodontitis; poor oral hygiene and motivation, defined as full-mouth bleeding on probing and a full-mouth plaque index of ≥ 25%; known allergic or adverse reactions to the restorative material; and unavailability for regular follow-ups.

This investigation was conducted according to the principles embodied in the Declaration of Helsinki of 1975 for biomedical research involving human subjects, as amended in 2008. All of patients were duly informed about the nature of the study and gave their written consent.

Before implant placement, all of the patients underwent CT or CBCT scan according to a double-scan protocol.[24] In the case of immediately post-extraction implants, a previously reported two-piece radiographic guide was used for the diagnostic study and for virtual implant planning.[25, 26] If the operator decided to wait for healing of the post-extraction socket, the implant sites had to heal for at least three months before radiographic examination **(Figs. 1–2)**.

DICOM data of the two sets of scans were transferred to a 3-D software planning program (NobelGuide, Nobel Biocare) and matched to each

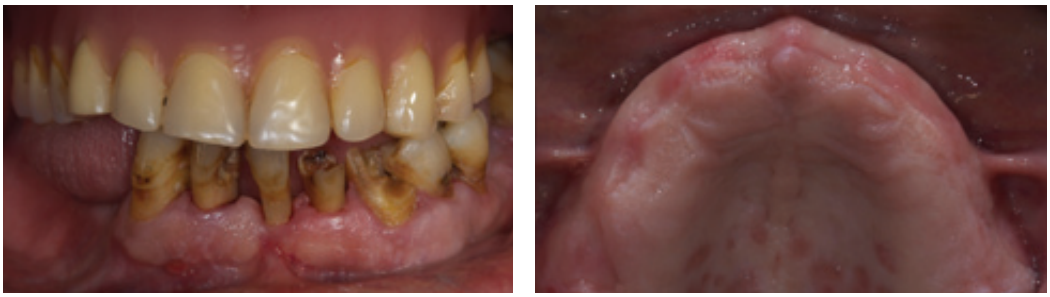

Figs. 1 & 2

Fig. 1

Pretreatment intra-oral photograph.

Fig. 2

Intra-oral photograph three months after tooth extractions.

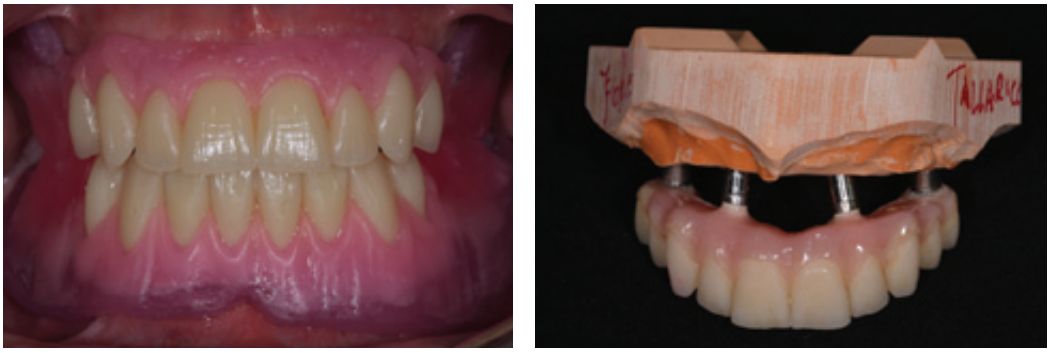

Figs. 3 & 4

Fig. 3

Try-in of the dental set-up modeled on the established vertical dimension of occlusion according to functional and esthetic parameters.

Fig. 4

Screw-retained temporary restoration.

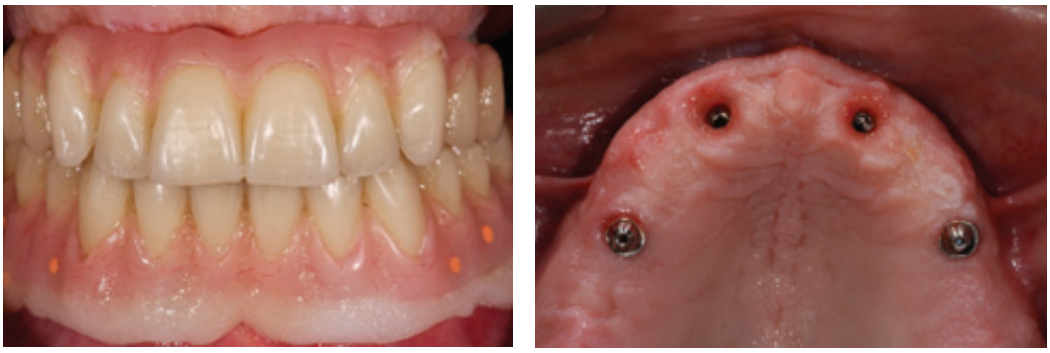

Figs. 5 & 6

Fig. 5

Intra-oral photograph of the temporary restoration screwed onto the implants.

Fig. 6

Intra-oral photograph five days after flapless implant placement.

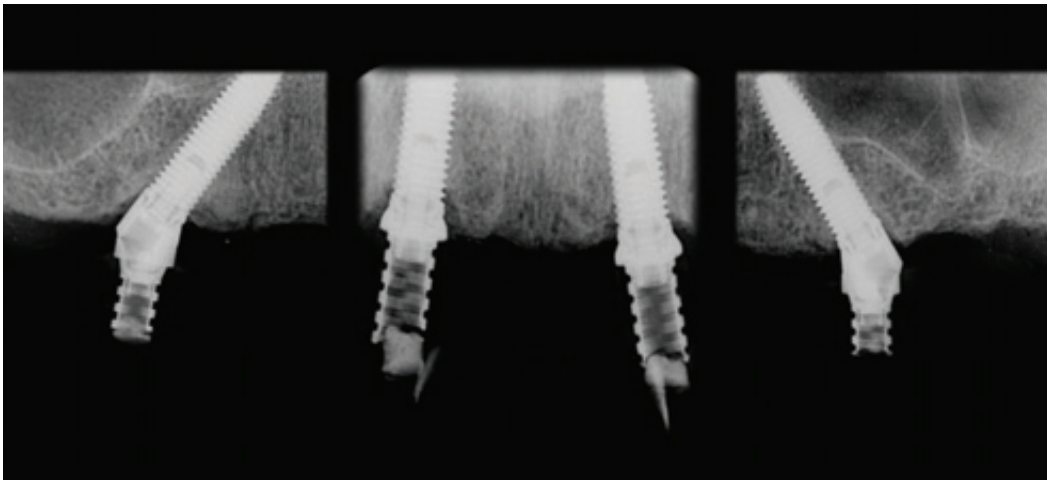

Fig. 7

Fig. 7

Periapical radiographs five days after implant placement.

other. Four implants were planned for the rehabilitation of each participant in post-extraction or healed sockets, according to the All-on-4 protocol.[16, 17] Planning data of the patients who required template-guided surgery were sent to a milling center (NobelProcera, Nobel Biocare), where stereolithographic surgical templates with hollow metallic cylinders to guide implant placement in the virtually planned position were fabricated. Patients received professional oral hygiene prior to the surgery and were instructed to rinse with a 0.2% chlorhexidine mouthwash for 1 min, starting two days prior to the intervention.

Surgical protocol

An antibiotic (2 g of amoxicillin and clavulanic acid or 600 mg clindamycin if allergic to penicillin) was administered 1 h prior to surgery and continued for six days (1 g amoxicillin and clavulanic acid or 300 mg clindamycin b.i.d.) after surgery. Local anesthesia was induced using a 4% articaine solution with 1:100,000 epinephrine (Ubistesin; 3M Italia, Milan, Italy). Implants were placed in the planned anatomical sites either conventionally or using a fully guided approach. A flapless or a flap approach was performed in order to maintain an adequate residual band of keratinized mucosa around the implants. When the alveolar crest was too thin (knife edge) to place the implant, the alveolar crest was remodeled using piezoelectric bone surgery under copious irrigation with sterile saline to obtain a flat bony crest. Each patient received four NobelSpeedy Groovy implants (Nobel Biocare), featuring a flat-to-flat matched implant-abutment interface with a 0.7 mm tall external hexagonal prosthetic connection and a rough, highly crystalline and phosphate-enriched titanium oxide surface (TiUnite, Nobel Biocare). All of the implants were placed according to the surgical and prosthetic protocols recommended by the manufacturer (IFU 73494 Manual 2/All-on-4 and IFU 71286), with no deviations from the original protocol. The drilling sequence was chosen according to the manufacturer's instructions in relation to the bone quality, achieving an insertion torque at implant placement ranging from 35 to 45 N cm in the mandible or from 35 to 55 N cm in the maxilla, measured using a surgical unit (OsseoCare Pro Drill Motor Set, Nobel Biocare). In the post-extraction sites, the gaps between the implants and the surrounding socket walls were filled with 0.25–1 mm granules of deproteinized bovine bone (Geistlich Bio-Oss or Geistlich Bio-Oss Collagen, Geistlich Pharma, Wolhusen, Switzerland), hydrated using the patient's blood mixed with antibiotic solution (Rifocin 250 mg/10 mL, Sanofi-aventis, Milan, Italy).

Seventeen- or thirty-degree angled multi-unit abutments (Nobel Biocare) were immediately connected to the distal implants for better orientation of the screw access hole. Straight multi-unit abutments (Nobel Biocare) were used in the anterior implants if needed.

A prefabricated screw-retained acrylic resin provisional restoration without any cantilever was delivered immediately after surgery **(Figs. 3–5)**. All of the patients received oral and written recommendations regarding medication, oral hygiene maintenance and diet. Post-surgical analgesic treatment was provided with ibuprofen 600 mg, administered every 8 h for two days after the surgery, and later on if needed. The patients were instructed to rinse the mouth with a 0.2% chlorhexidine mouthwash t.i.d. without brushing the implant area **(Figs. 6 & 7)**.

Prosthetic protocol

After three to four months of healing, a definitive impression was taken at the implant or abutment level according to a previously reported protocol.[27] Definitive prostheses with titanium or zirconia frameworks, fabricated using CAD/CAM technology (NobelProcera), were screwed on at either the implant or abutment level according to the manufacturer's instructions three to five months after implant placement (in the mandible and the maxilla, respectively). The definitive implant-supported complete-arch FDP was designed with (hybrid design) or without pink material in the cervical region (crown design) and veneered with ceramic, acrylic or composite according to the patients' needs **(Figs. 8a–c)**. Clinical accuracy of the framework (strain-free screwing and absence of an open margin upon clinical and radiographic examination) was evaluated before prosthesis delivery.[28–30] The occlusion was adjusted avoiding any premature contacts. Mutually protected occlusion with anterior guidance or balanced occlusion was used in cases of opposing natural dentition or an FDP and complete removable denture, respectively. Follow-up visits were scheduled at one and six months and then annually up to five years of function. The patients underwent a professional cleaning by a dental hygienist every four to six months **(Figs. 9a–c)**. Panoramic and periapical radiographs were obtained annually after definitive prosthesis delivery **(Fig. 10)**.

The primary outcome measures were as follows:
- An implant was classified as "successful" when the following criteria[31] were fulfilled: did not cause pain or suppuration, did not show any mobility, did not show any signs of radiolucency, and did not show periimplant bone loss of > 1.5 mm during the first year and then > 0.2 mm yearly.
- An implant was classified as "surviving" when the implant remained in the jaw and was stable after the prosthesis was removed, even though all of the success criteria were not fulfilled.

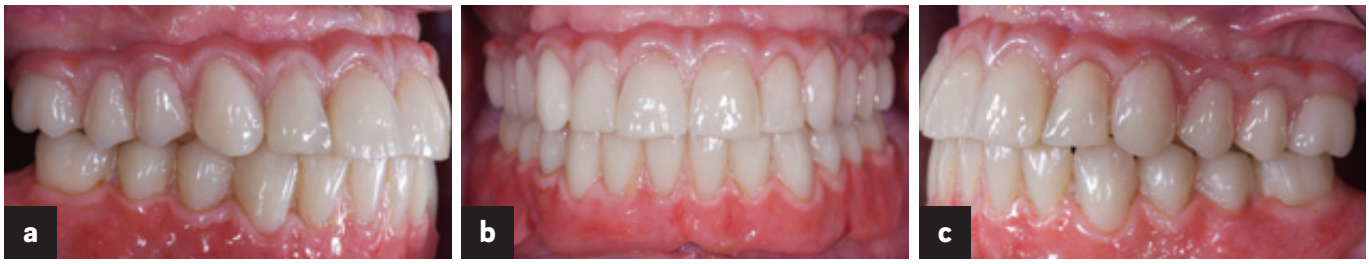

Figs. 8a–c

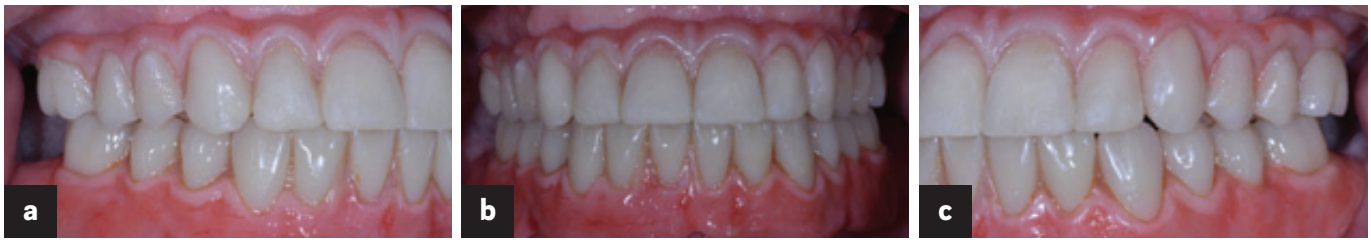

Figs. 9a–c

Figs. 8a–c

Lateral **(a & c)** and frontal **(b)** intra-oral photographs of the carbon-fiber-reinforced definitive prosthesis screwed onto the implants.

Figs. 9a–c

Lateral **(a & c)** and frontal **(b)** intra-oral photographs of the definitive prosthesis taken three years after implant placement.

Fig. 10

Panoramic radiograph three years after implant placement.

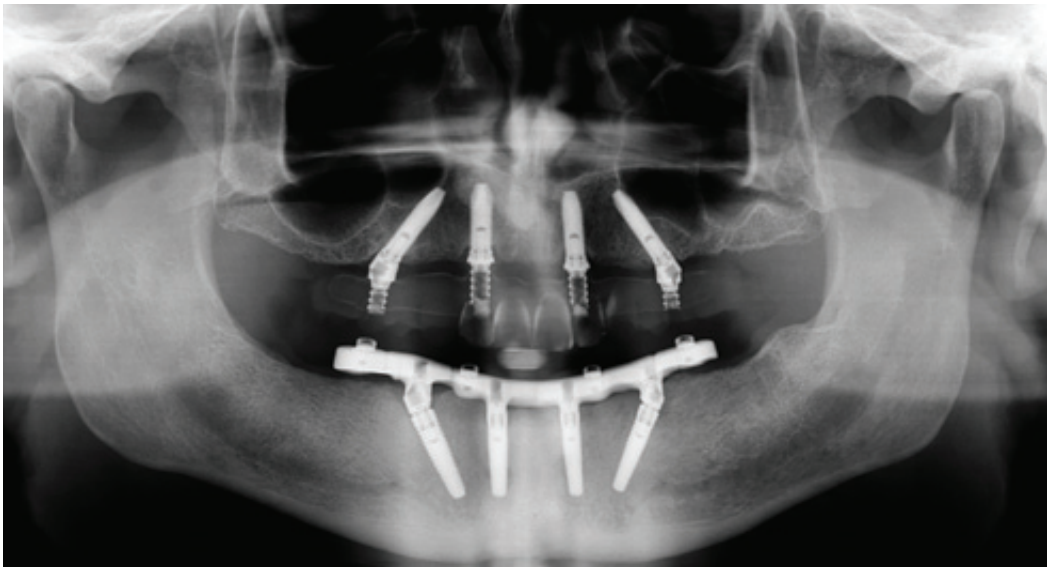

Fig. 10

– An implant-supported complete-arch FDP was defined as "successful" when the dental prosthesis remained in function and the esthetic evaluation, assessed by the dentist and the patient, was satisfactory during the study period.
– An implant-supported complete-arch FDP was considered as "surviving" when the dental prosthesis remained in function, even though all of the success criteria were not fulfilled.

The secondary outcome measures were as follows:
– Any technical (fracture of the framework and/or the veneering material, screw loosening, etc.) and/or biological (pain, swelling, suppuration, etc.) complications were considered.
– The distance from the most coronal margin of the implant collar and the most coronal point of bone-to-implant contact was taken as the marginal bone level. This level was evaluated on intra-oral digital radiographs taken with the paralleling technique using a film holder (Rinn XCP, DENTSPLY, Elgin, Ill., U.S.) at implant placement (baseline) and then yearly up to three years of function. Radiographs were accepted or rejected for evaluation based on the clarity of the implant threads. All readable radiographs were displayed in image analysis software (Digora for Windows 2.8, SOREDEX, Tuusula, Finland) that was calibrated for every single image using the known measure of the implant thread pitch. Measurements of the mesial and distal bony crest level adjacent to each implant were made to the nearest 0.1 mm and averaged at the patient level.
– Patient satisfaction was evaluated with a questionnaire one month after delivery of the final prosthesis and at the three-year follow-up examination, provided by independent and blinded outcome assessors. The assessor asked the following questions: Are you satis-

fied with the function of your implant-supported prosthesis? Are you satisfied with the esthetic outcome of your implant-supported prosthesis? Would you undergo the same therapy again?

An independent assessor evaluated the implant and prosthesis survival and success rates. Complications were assessed and treated by the same clinicians. The marginal bone loss was evaluated by an independent radiologist.

Statistical analysis

Patient data were collected in an Excel spreadsheet (Microsoft). Finally, all of the data were exported into IBM SPSS Statistics for Macintosh (Version 22.0; IBM, Armonk, N.Y., U.S.) for statistical analysis. A bio-statistician with expertise in dentistry analyzed the data using PASW Statistics for Windows (Version 18.0; SPSS, Chicago, Ill., U.S.). Descriptive analysis was performed for numeric parameters using mean ± standard deviation (median; 95% CI). Dichotomous and continuous outcomes were compared using the chi-squared test and one-way analysis of variance, respectively. Differences in the proportions of patients with implant failures, prosthesis failures and complications (dichotomous outcomes) were compared between the subgroups using the Fisher exact test. Patient was the statistical unit of the analyses. All statistical comparisons were conducted at a 0.05 level of significance.

Results

Thirty-two patients were screened for eligibility. Two patients were not enrolled in the trial, because of refusal to sign the informed consent. A total of 120 NobelSpeedy Groovy implants were placed using either computer-assisted template-guided ($n = 15$) or conventional freehand surgery ($n = 15$) in 30 consecutive patients (18 females and 12 males) with a mean age of 67.4 ± 6.9 (range of 51–87). Thirty CAD/CAM screw-retained implant-supported complete-arch FDPs (18 in the mandible and 12 in the maxilla) were delivered. No patients dropped out of the study within three years after implant placement and no deviation from the original protocol occurred. All of the patients were followed up for a minimum period of three years (mean of 53.8 months; range of 36–84 months). Data collected were included in the statistical analysis. The main patients' and interventions' characteristics are summarized in **Table 1**.

At the three-year follow-up examination, one out of 120 implants (0.8%) had failed, resulting in a cumulative implant survival rate of 99.2%. The only implant failure occurred in one patient two months after placement, before delivery of the final prosthesis. The affected implant had an infectious etiology (pain, swelling and suppuration) and it was 11.5 mm long in position 16, placed using guided surgery in a healed site. The implant was replaced three months after bone healing. The temporary prosthesis was shortened, but not replaced by a conventional complete removable denture, and the patient was adequately informed and instructed to pay attention and follow a soft diet. At the three-year follow-up examination, no definitive prostheses had failed, resulting in a cumulative prosthesis survival rate of 100%.

Eleven patients experienced one technical or biological complication each, resulting in eight technical and three biological complications reported during the entire follow-up period. Six technical and one biological complication were reported during the healing period with temporary prostheses, while two technical and two biological complications were reported after definitive prosthesis delivery. All of the complications were successfully resolved.

Three prosthetic screws loosened in the temporary prostheses (in three patients) during the healing period, and this was resolved by retightening the screws, stabilizing the occlusion and advising the patients not to overload the prostheses (not to ingest food that may require significant masticatory effort). Three fractures of the provisional acrylic prostheses occurred (in three patients) during the healing period. The temporary prosthesis was adjusted chairside, the occlusion was stabilized and a night guard was delivered for each patient. Fracture of the composite veneering material of the definitive implant-supported cross-arch FDP occurred in one patient two years after loading, most likely due to occasional parafunctional habits. These situations were resolved by adjusting the definitive prosthesis chairside, stabilizing the occlusion and a delivering a night guard.

The first biological complication was reported six weeks after implant placement in an 11.5 mm long implant placed in position 45, using guided surgery in a healed site. The patient reported pain and swelling without suppuration. The temporary abutment was replaced with a healing abutment. The temporary prosthesis was shortened to the

right canine. The implant was left to heal for four months according to a conventional loading protocol. The other two complications were periimplantitis, consisting of a mean mesiodistal peri-implant bone loss of 2.6 and 2.8 mm, reported at the one-year follow-up examination. The first case of periimplantitis developed around a 15 mm long implant in position 35, placed using conventional freehand surgery in a healed site. The second case developed around a 13 mm long implant in position 32, placed using guided surgery in a healed site and immediately loaded. No other technical or biological complications occurred during the entire follow-up period.

After an initial mean marginal bone loss of 1.16 ± 0.40 mm (1.06 mm; 95% CI: 0.92–1.20), all of the implants lost a mean of 0.21 ± 0.11 mm (0.20 mm; 95% CI: 0.16–0.24) between the one- and two-year follow-ups, and 0.16 ± 0.07 mm (0.15 mm; 95% CI: 0.13–0.17) between the two- and three-year follow-ups. At the three-year follow-up, the mean marginal bone loss was 1.52 ± 0.41 mm (1.42 mm; 95% CI: 1.27–1.57). The radiographic data are shown in **Table 2**.

All of the patients were fully satisfied with the function and esthetics of their definitive prostheses, and all of the patients declared that they would undergo the same treatment again.

Maxilla versus mandible

Twelve patients were treated in the maxilla, while 18 patients were treated in the mandible. There were no statistically significant differences between centers for the number of patients who had failed implants (1/12 vs. 0/18; risk ratio = NA; $p = 0.399$) or complications (3/12 vs. 8/18; risk ratio = 0.5625; 95% CI: 0.19–1.70; $p = 0.442$). At the three-year follow-up examination, the mean marginal bone loss was 1.49 ± 0.34 mm (1.42 mm; 95% CI: 1.23–1.61) in the maxilla versus 1.54 ± 0.46 mm (1.38 mm; 95% CI: 1.17–1.59) in the mandible ($p = 0.756$). The radiographic data are shown in **Table 3**.

Guided versus conventional freehand surgery

Fifteen patients were treated using computer-assisted template-based surgery and 15 with conventional freehand surgery. There were no statistically significant differences between centers for the number of patients who had failed implants (1/15 vs. 0/15; risk ratio = NA; $p = 0.999$) or complications (4/15 vs. 7/15; risk ratio = 0.5714; 95% CI: 0.21–1.55; $p = 0.449$). At the three-year follow-up examination, the mean marginal bone loss was 1.48 ± 0.47 mm (1.33 mm; 95% CI: 1.09–1.57) in the guided surgery group versus 1.55 ± 0.34 mm (1.46 mm; 95% CI: 1.29–1.63) in the conventional freehand surgery group ($p = 0.365$). The radiographic data are shown in **Table 3**.

Discussion

The present study reported data on 30 implant-supported restorations delivered according to the All-on-4 protocol and followed for at least three years after implant placement. Because it was designed as a single-cohort prospective study, the main limitation of the present research was the lack of a control group and the small sample size. Another limitation of the present study was the variability within the cohort of patients.

In the present study, the three-year implant (99.2%) and prosthesis success rates (100.0%), as well as the mean bone loss of 1.52 ± 0.41 mm, indicate that the All-on-4 treatment concept is a promising treatment modality. Furthermore, the results of this prospective observational study are consistent with other studies investigating the same topic.

A recent systematic review by Patzelt et al., which included 4,804 implants, demonstrated a mean cumulative implant and prosthesis survival rate at three years of 99.0 ± 1.0% and 99.9 ± 0.3%, respectively.[20] The mean bone loss at three years amounted to 1.3 ± 0.4 mm. However, 12 out of the 13 included studies were considered to be highly biased. Most of the studies included (69%) in the systematic review derived from a limited number of investigators in Italy and Portugal, which may limit the generalizability of the findings, and only 31% of the studies reported a completed follow-up period of three years.

Malo et al. retrospectively reported a cumulative patient-related success rate of 93.8% up to ten years of follow-up in the mandible and a prosthesis survival rate of 99.2%.[18] In the maxilla, a five-year survival rate of 93% was reported, and the survival rate of the prostheses was 100%.[19] The mean marginal bone loss was 1.52 ± 0.30 mm after three years. Similar results were reported by Browaeys et al., who highlighted unacceptable ongoing bone loss in 49.2% of the patients.[32]

Balshi et al. retrospectively analyzed the outcomes of 200 arches (800 implants) treated

Table 1

	Total
Males	12 (40.00%)
Females	18 (60.00%)
Mean age at implant placement	67.4 ± 6.9
Smokers (< 10 cigarettes/day)	5 (16.67%)
Patients treated in the maxilla	12 (40.00%)
Patients treated in the mandible	18 (60.00%)
Patients treated using guided surgery	15 (50.00%)
Patients treated using conventional surgery	15 (50.00%)
Post-extraction implants	19 (15.83%)
10.0 mm implant length	14 (11.67%)
11.5 mm implant length	42 (35.00%)
13.0 mm implant length	62 (51.67%)
15.0–16.0 mm implant length	2 (1.67%)
Patients with prosthesis failures	0
Patients with implant failures	1 (3.33%)
Patients with complications	11 (36.67%)

Table 1

Patients' and interventions' characteristics.

Table 2

Follow-up period			
Baseline to 1 year	**1–2 years**	**2–3 years**	**Baseline to 3 years**
1.16 ± 0.40 (0.92–1.20)	0.21 ± 0.11 (0.16–0.24)	0.16 ± 0.07 (0.13–0.17)	1.52 ± 0.41 (1.27–1.57)

Table 2

Mean marginal bone loss ± standard deviation (mm) (95% CI) between follow-up examinations.

Table 3

Location	Mandible (n = 18)	Maxilla (n = 12)	P-value†
	1.54 ± 0.46	1.49 ± 0.34	P = 0.756
Type of surgery	Guided (n = 15)	Freehand (n = 15)	P-value†
	1.48 ± 0.47	1.55 ± 0.34	P = 0.365

Table 3

Three-year marginal bone loss ± standard deviation (mm) according to the jaw location and type of surgery.

† Unpaired t-test assuming normal distribution.

according to the All-on-4 protocol.[33] Twenty percent (168 implants out of 800) of the implants analyzed had a follow-up period of three years or more. Cumulative implant and prosthesis survival rates amounted to 97.3% and 99.0%, respectively.

Grandi et al. analyzed 47 patients treated with 188 immediately loaded implants placed in the mandible according to the All-on-4 protocol in post-extraction sites.[34] At the 18-month follow-up, no implant had failed and all of the restorations were stable. However, three patients experienced fracture of the provisional restoration. No significant differences in bone loss were found between axially placed and tilted implants at the 18-month follow-up.

Babbush et al. retrospectively examined 165 patients treated according to the All-on-4 protocol.[35] The cumulative implant survival rate was 99.6% (99.3% in the maxilla and 100.0% in the mandible) for up to 29 months of loading. The definitive prosthesis survival rate was 100%. Recently, the same authors retrospectively analyzed the patient-centered outcomes, including the cost of treatment, length of the treatment period and comfort provided by the provisional restoration, in patients treated according to the All-on-4 protocol and compared these results to a historical control group, which included complete-arch FDPs supported by natural teeth or implants and implant-supported overdentures.[36] This study demonstrated that the cost, length of treatment and comfort provided by the provisional restoration significantly favored the All-on-4 treatment modality.

In the present study, the overall percentage of complications experienced was large (36.6 %). Nevertheless, this result did not differ from those normally encountered in oral rehabilitation in which implants are used as support for an FDP (33.6% at five years).[37] Moreover, most of these complications were reported on the temporary restoration, during healing. The clinicians who carried out the procedures addressed all of the complications chairside. Furthermore, the condition of the patients remained stable up to the completion of the three-year follow-up period. In order to minimize the incidence of complications, dental clinicians should exert great effort in selecting patients, respecting the original protocols, and choosing reliable components and materials for implant-supported complete-arch FDPs.

Patients with untreated periodontitis were not included in the study. Implant therapy in patients with a history of chronic periodontitis and generalized aggressive periodontitis might be considered a viable treatment with similar survival outcomes to those reported for healthy patients. Periodontally compromised patients were included after being treated to reduce the inflammation and halt the disease progression, before tooth extraction and implant placement. According to Donos et al., it is necessary to treat and control the periodontal disease, regardless of its progression pattern and subtype, before implant therapy is initiated in order to improve the overall implant success and achieve a more favorable bone resorption pattern.[38] Nevertheless, a comprehensive implant maintenance program has to be encouraged and continued in order to identify periimplant bone loss early on, particularly in patients with a history of periodontal disease.

Conclusion

Within the limitations of the present study, the All-on-4 concept is a predictable and minimally invasive treatment concept for the complete-arch rehabilitation of both jaws, regardless of jaw location and type of surgery. It may decrease the overall treatment time and re-establish adequate function in a cost-effective way. Further long-term prospective data (five years and more) and outcomes beyond cumulative survival rates are needed.

Competing interests

The authors declare that they have no competing interests. This study was completely self-financed and no funding was sought or obtained, not even in the form of free materials.

References

1.
Polzer I, Schimmel M, Müller F, Biffar R. Edentulism as part of the general health problems of elderly adults.
→ Int Dent J.
2010 Jun;60(3):143–55.

2.
Emami E, de Souza RF, Kabawat M, Feine JS. The impact of edentulism on oral and general health.
→ Int J Dent.
2013;2013:498305. doi: 10.1155/2013/498305. Epub 2013 May 8.

3.
Slade GD, Akinkugbe AA, Sanders AE. Projections of U.S. edentulism prevalence following 5 decades of decline.
→ J Dent Res.
2014 Oct;93(10):959–65.

4.
Felton D, Cooper L, Duqum I, Minsley G, Guckes A, Haug S, Meredith P, Solie C, Avery D, Chandler ND; American College of Prosthodontists; Academy of General Dentistry; American Dental Association Council on Scientific Affairs; American Dental Hygienists' Association; National Association of Dental Laboratories; GlaxoSmithKline Consumer Healthcare. Evidence-based guidelines for the care and maintenance of complete dentures: a publication of the American College of Prosthodontists.
→ J Am Dent Assoc.
2011 Feb;142 Suppl 1:1S–20S.

5.
Carlsson GE. Clinical morbidity and sequelae of treatment with complete dentures.
→ J Prosthet Dent.
1998 Jan;79(1):17–23.

6.
Batenburg RH, Meijer HJ, Raghoebar GM, Vissink A. Treatment concept for mandibular overdentures supported by endosseous implants: a literature review.
→ Int J Oral Maxillofac Implants.
1998 Jul;13(4):539–45.

7.
Feine JS, Carlsson GE, Awad MA, Chehade A, Duncan WJ, Gizani S, Head T, Heydecke G, Lund JP, MacEntee M, Mericske-Stern R, Mojon P, Morais JA, Naert I, Payne AG, Penrod J, Stoker GT, Tawse-Smith A, Taylor TD, Thomason JM, Wismeijer D. The McGill consensus statement on overdentures. Mandibular two-implant overdentures as first choice standard of care for edentulous patients.
→ Gerodontology.
2002 Jul;19(1):3–4.

8.
Thomason JM, Kelly SA, Bendkowski A, Ellis JS. Two implant retained overdentures –A review of the literature supporting the McGill and York consensus statements.
→ J Dent.
2012 Jan;40(1):22–34.

9.
Harris D, Höfer S, O'Boyle CA, Sheridan S, Marley J, Benington IC, Clifford T, Houston F, O'Connell B. A comparison of implant-retained mandibular overdentures and conventional dentures on quality of life in edentulous patients: a randomized, prospective, within-subject controlled clinical trial.
→ Clin Oral Implants Res.
2013 Jan;24(1):96–103.

10.
Emami E, Heydecke G, Rompré PH, De Grandmont P, Feine JS. Impact of implant support for mandibular dentures on satisfaction, oral and general health-related quality of life: a meta-analysis of randomized-controlled trials.
→ Clin Oral Implants Res.
2009 Jun;20(6):533–44.

11.
Krennmair G, Seemann R, Fazekas A, Ewers R, Piehslinger E. Patient preference and satisfaction with implant-supported mandibular overdentures retained with ball or locator attachments: a crossover clinical trial.
→ Int J Oral Maxillofac Implants.
2012 Nov-Dec;27(6):1560–8.

12.
Jemt T. Failures and complications in 391 consecutively inserted fixed prostheses supported by Brånemark implants in edentulous jaws: a study of treatment from the time of prosthesis placement to the first annual checkup.
→ Int J Oral Maxillofac Implants.
1991 Fall;6(3):270–6.

13.
Jemt T, Book K, Lindén B, Urde G. Failures and complications in 92 consecutively inserted overdentures supported by Brånemark implants in severely resorbed edentulous maxillae: a study from prosthetic treatment to first annual check-up.
→ Int J Oral Maxillofac Implants.
1992 Summer;7(2):162–7.

14.
French D, Tallarico M. Eight-year clinical and radiologic results of maxillary and mandibular implant-retained bar overdentures carried out on oxidized (TiUnite™) replace select implants placed in regenerated bone: a clinical case.
→ Quintessence Int.
2014 Feb;45(2):135–40.

15.
Babbush CA, Tallarico M. Twelve-year clinical and radiological results of maxillary and mandibular implant-retained bar overdentures carried out on oxidized (TiUnite) replace select implants: a clinical case.
→ J Oral Implantol.
2013 Dec;39(6):737–42.

16.
Maló P, Rangert B, Nobre M. "All-on-Four" immediate-function concept with Brånemark System implants for completely edentulous mandibles: a retrospective clinical study.
→ Clin Implant Dent Relat Res.
2003 Mar;5 Suppl 1:2–9.

17.
Maló P, Rangert B, Nobre M. All-on-4 immediate-function concept with Brånemark System® implants for completely edentulous maxillae: a 1-year retrospective clinical study.
→ Clin Implant Dent Relat Res.
2005 Jun;7 Suppl 1:S88–94.

18.
Malo P, de Araújo Nobre M, Lopes A, Moss SM, Molina GJ. A longitudinal study of the survival of All-on-4 implants in the mandible with up to 10 years of follow-up.
→ J Am Dent Assoc.
2011 Mar;142(3):310–20.

19.
Maló P, de Araújo Nobre M, Lopes A, Francischone C, Rigolizzo M. "All-on-4" immediate-function concept for completely edentulous maxillae: a clinical report on the medium (3 years) and long-term (5 years) outcomes.
→ Clin Implant Dent Relat Res.
2012 May;14 Suppl 1:e139–50.

20.
Patzelt SB, Bahat O, Reynolds MA, Strub JR. The all-on-four treatment concept: a systematic review.
→ Clin Implant Dent Relat Res.
2014 Dec;16(6):836–55.

21.
Von Elm E, Altman DG, Egger M, Pocock SJ, Gøtzsche PC, Vandenbroucke JP. The Strengthening the Reporting of Observational Studies in Epidemiology (STROBE) statement: guidelines for reporting observational studies.
→ J Clin Epidemiol.
2008 Apr;61(4):344–9.

22.
Zitzmann NU, Krastl G, Hecker H, Walter C, Weiger R. Endodontics or implants? A review of decisive criteria and guidelines for single tooth restorations and full arch reconstructions.
→ Int Endod J.
2009 Sep;42(9):757–74.

23.
Becker W, Berg L, Becker BE. The long term evaluation of periodontal treatment and maintenance in 95 patients.
→ Int J Periodontics Restorative Dent.
1984;4(2)54–71.

24.
Van Steenberghe D, Naert I, Andersson M, Brajnovic I, Van Cleynenbreugel J, Suetens P. A custom template and definitive prosthesis allowing immediate implant loading in the maxilla: a clinical report.
→ Int J Oral Maxillofac Implants.
2002 Sep-Oct;17(5):663–70.

25.
Polizzi G, Cantoni T. Five-year follow-up of immediate fixed restorations of maxillary implants inserted in both fresh extraction and healed sites using the NobelGuide™ system.
→ Clin Implant Dent Relat Res.
2015 Apr;17(2):221–33.

26.
Cantoni T, Giovanni P. Implant treatment planning in fresh extraction sockets: use of a novel radiographic guide and CAD/CAM technology.
→ Quintessence Int.
2009 Oct;40(9):773–81.

27.
Pozzi A, Tallarico M, Mangani F, Barlattani A. Different implant impression techniques for edentulous patients treated with CAD/CAM complete-arch prostheses: a randomised controlled trial reporting data at 3 year post-loading.
→ Eur J Oral Implantol.
2013 Winter;6(4):325–40.

28.
Abduo J, Bennani V, Waddell N, Lyons K, Swain M. Assessing the fit of implant fixed prostheses: a critical review.
→ Int J Oral Maxillofac Implants.
2010 May-Jun;25(3):506–15.

29.
Eisenmann E, Mokabberi A, Walter MH, Freesmeyer WB. Improving the fit of implant-supported superstructures using the spark erosion technique.
→ Int J Oral Maxillofac Implants.
2004 Nov-Dec;19(6):810–8.

30.
Katsoulis J, Mericske-Stern R, Rotkina L, Zbären C, Enkling N, Blatz MB. Precision of fit of implant-supported screw-retained 10-unit computer-aided-designed and computer-aided-manufactured frameworks made from zirconium dioxide and titanium: an *in vitro* study.
→ Clin Oral Implants Res.
2014 Feb;25(2):165–74.

31.
Papaspyridakos P, Chen CJ, Singh M, Weber HP, Gallucci GO. Success criteria in implant dentistry: a systematic review.
→ J Dent Res.
2012 Mar;91(3):242–8.

32.
Browaeys H, Dierens M, Ruyffelaert C, Matthijs C, De Bruyn H, Vandeweghe S. Ongoing crestal bone loss around implants subjected to computer-guided flapless surgery and immediate loading using the All-on-4® concept.
→ Clin Implant Dent Relat Res.
2015 Oct;17(5):831–43.

33.
Balshi TJ, Wolfinger GJ, Slauch RW, Balshi SF. A retrospective analysis of 800 Brånemark System implants following the All-on-Four™ protocol.
→ J Prosthodont.
2014 Feb;23(2):83–8.

34.
Grandi T, Guazzi P, Samarani R, Grandi G. Immediate loading of four (All-on-4) post-extractive implants supporting mandibular cross-arch fixed prostheses: 18-month follow-up from a multicentre prospective cohort study.
→ Eur J Oral Implantol.
2012 Autumn;5(3):277–85.

35.
Babbush CA, Kutsko GT, Brokloff J. The All-on-Four immediate function treatment concept with NobelActive implants: a retrospective study.
→ J Oral Implantol.
2011 Aug;37(4):431–45.

36.
Babbush CA, Kanawati A, Kotsakis GA, Hinrichs JE. Patient-related and financial outcomes analysis of conventional full-arch rehabilitation versus the All-on-4 concept: a cohort study.
→ Implant Dent.
2014 Apr;23(2):218–24.

37.
Schwarz F, Hegewald A, Becker J. Impact of implant-abutment connection and positioning of the machined collar/microgap on crestal bone level changes: a systematic review.
→ Clin Oral Implants Res.
2014 Apr;25(4):417–25.

38.
Donos N, Laurell L, Mardas N. Hierarchical decisions on teeth vs. implants in the periodontitis-susceptible patient: the modern dilemma.
→ Periodontol 2000.
2012 Jun;59(1):89–110.

Accelerated generation of human induced pluripotent stem cells from human oral mucosa using episomal plasmid vectors and maternal transcription factor *Glis1*

Takahiro Kashiwagi,[a] Yoshiya Hashimoto,[b] Masahiro Tanaka[c] & Shunsuke Baba[a]

[a] Department of Oral Implantology, Osaka Dental University, Hirakata, Japan
[b] Department of Biomaterials, Osaka Dental University, Hirakata, Japan
[c] Department of Fixed Prosthodontics and Occlusion, Osaka Dental University, Hirakata, Japan

Corresponding author:

Dr. Yoshiya Hashimoto

yoshiya@cc.osaka-dent.ac.jp

How to cite this article:

Kashiwagi T, Hashimoto Y, Tanaka M, Baba S. Accelerated generation of human induced pluripotent stem cells from human oral mucosa using episomal plasmid vectors and maternal transcription factor *Glis1*.

J Oral Science Rehabilitation.
2016 Jun;2(2):26–35.

Abstract

Objective

Induced pluripotent stem cells (iPSCs) possess high pluripotency and differentiation potential and may constitute a possible source of autologous stem cells for clinical applications. However, the lengthy reprogramming process (up to one month) remains one of the most significant challenges facing standard virus-mediated methodology. The Gli-like transcription factor *Glis1* is highly expressed in unfertilized eggs and one-cell-stage embryos. In this study, iPSCs were generated using a combination of primary human oral mucosal fibroblasts (HOFs) and episomal plasmid vectors expressing transcription factors, including *Glis1*.

Materials and methods

HOFs were established from oral mucosal tissue 3 mm in diameter from a 23-year-old Asian male using a skin trephine. Human iPSCs were generated from the established HOFs using the following episomal plasmid vectors: pCXLE-hOCT3/4-shp53-F that expresses *OCT3/4* and short-hairpin RNA (shRNA) against *p53*, pCXLE-hSK that expresses *SOX2* and *KLF4*, pCXLE-hUL that expresses *L-MYC* and *LIN28*, and pCXLE-hGlis1 that expresses *Glis1*.

Results

Fifty colonies of human embryonic stem (ES)-like cells were observed as early as 20 days after initial episomal plasmid vector transduction. The resulting cell lines shared several characteristics with human ES cells, including morphology, pluripotency-associated gene and protein markers, karyotype analysis and the ability to differentiate *in vivo* into all three germ layers.

Conclusion

Our method, combining the use of HOFs and episomal plasmid vectors expressing *OCT3/4*, shRNA against *p53*, *SOX2*, *KLF4*, *L-MYC*, *LIN28* and *Glis1*, offers a powerful tool for safely and rapidly generating bona fide human iPSCs and facilitates the application of iPSC technology to biomedical research.

Keywords

iPSC, integration-free plasmid vector, Glis1, human oral mucosal tissue.

Introduction

The successful reprogramming of human and mouse somatic cells into induced pluripotent stem cells (iPSCs) via ectopic overexpression of pluripotency-associated transcription factors is considered a major scientific breakthrough.[1–5] Similar to the characteristics of embryonic stem (ES) cells,[6–8] human iPSCs can proliferate indefinitely, while retaining pluripotency, and can differentiate into all cell types found in the body. IPSCs have been generated from dermal fibroblasts,[3] peripheral blood,[9] dental pulp cells,[10] gingival fibroblasts,[11] periodontal ligaments,[12] oral mucosa[13] and mesenchymal stromal cells.[14]

Gingival tissue is routinely resected during general dental treatments, such as tooth extraction, periodontal surgery and dental implantation, and generally treated as biomedical waste.[15] Egusa et al. successfully derived iPSCs from human gingival fibroblasts (HGFs) using retroviral transduction of transcription factors; they also reported that the reprogramming efficiency of mouse gingival fibroblasts was higher than that of dermal fibroblasts.[11] However, retroviral integration increases the risk of tumor formation, while integration-free methods decrease this potential risk.[15] The development of novel approaches to generating integration-free iPSCs has eliminated the concern of integrating virus-associated genotoxicity in clinical applications.[16] Integration-free human iPSCs have been generated using several methods.[15] Okita et al. reported a simple method that uses *p53* suppression and nontransforming *L-MYC* to generate human iPSCs with episomal plasmid vectors.[15] Our recent study demonstrated that iPSCs could be generated from a combination of primary HGFs and an episomal plasmid vector.[17] However, the lengthy reprogramming process (up to one month) remains one of the most significant challenges facing standard virus-mediated methodology.

Maekawa et al. reported that the Gli-like transcription factor *Glis1* (Glis family zinc finger 1) markedly enhances the generation of iPSCs from both mouse and human somatic fibroblasts when it is expressed together with three transcription factors collectively known as OSK (*OCT3/4*, *SOX2* and *KLF4*) using retroviral transduction.[18] However, little is known regarding whether *Glis1* can effectively promote direct reprogramming during iPSC generation using an episomal plasmid vector. In the current study, iPSCs were generated by combining primary human oral mucosal fibroblasts (HOFs) with episomal plasmid vectors expressing *OCT3/4*, short-hairpin RNA (shRNA) against *p53*, *SOX2*, *KLF4*, *L-MYC*, *LIN28* and *Glis1*.

Materials and methods

Ethical statement

Approval for the sampling of human oral mucosa tissue, establishing iPSCs and genome/gene analysis was obtained from the Ethics Committee of Osaka Dental University, Hirakata, Japan (authorization No.: 110783; approval date: 30 September 2013) and the DNA Recombination Experiment Safety Committee of Osaka Dental University (authorization No.: 54; approval date: 18 July 2014). Written informed consent was obtained from the participant. The animal experiments followed a protocol approved by the Animal Committee of Osaka Dental University (authorization No.: 14-06002; approval date: 8 July 2014).

Cell culturing

HOFs were established from oral mucosal tissue 3 mm in diameter obtained using a skin trephine (derma punch, Maruho, Osaka, Japan) from a 23-year-old Asian male. Human oral mucosal tissue was placed in 35 mm tissue culture dishes and cultured in Dulbecco's Modification of Eagle's Medium (DMEM) containing 10% fetal bovine serum at 37 °C and 5% CO_2.[11] The medium was replaced every three days. Once the HOFs had proliferated, the tissue was removed. When the cells reached subconfluence, they were dissociated using 0.25% trypsin (Invitrogen, Carlsbad, Calif., U.S.) and transferred to 60 mm tissue culture dishes (passage 1). HOFs were regularly passaged at a 1:3 ratio every three to four days.

Generation of iPSCs from HOFs with episomal vectors

One microgram of an expression episomal plasmid mixture containing pCXLE-hOCT3/4-shp53-F that expresses *OCT3/4* and shRNA against *p53*, pCXLE-hSK that expresses *SOX2* and *KLF4*, pCXLE-hUL that expresses *L-MYC* and *LIN28*, and pCXLE-hGlis1 that expresses *Glis1* (Addgene, Cambridge, Mass., U.S.) was electroporated into 6×10^5 primary HOFs (passage 5) with the Amaxa 4D-Nucleofector (Lonza, Basel,

Table 1

Primer	Gene		Sequences (5′ to 3′)
Pluripotent marker	OCT3/4	Forward	GAAACCCACACTGCAGCAGA
		Reverse	TCGCTTGCCCTTCTGGCG
	NANOG	Forward	CTCAGCTACAAACAGGTGAAGAC
		Reverse	TCCCTGGTGGTAGGAAGAGTAAA
	SOX2	Forward	GGGAAATGGGAGGGGTGCAAAAGAGG
		Reverse	TTGCGTGAGTGTGGATGGGATTGGTG
	KLF4	Forward	CGCTCCATTACCAAGAGCTCAT
		Reverse	CGATCGTCTTCCCCTCTTTG
	TERT	Forward	CGTACAGGTTTCACGCATGTG
		Reverse	ATGACGCGCAGGAAAAATGT
	C-MYC	Forward	GTTGGTCAGGCTGGTCTTGAA
		Reverse	CATGCGCCTGTAATCCTAGCA
Internal control	GAPDH	Forward	CCACTCCTCCACCTTTGACG
		Reverse	ATGAGGTCCACCACCCTGTT

Table 1

List of primers used for qRT-PCR.

Switzerland) according to the manufacturer's instructions using program DT-130 (Lonza). These cells were then transferred on to mitomycin C-treated SNL 76/7 cells (cat. No. 07032801, lot No. 08F009; European Collection of Authenticated Cell Cultures, Porton Down, U.K.) at 5×10^4 cells per 100 mm dish. The following day, the culture medium was replaced with embryonic stem cell (ESC) culture medium consisting of DMEM/F12 medium (Sigma-Aldrich, St. Louis, Mo., U.S.) supplemented with 20% Knock-Out Serum Replacement (Gibco, Grand Island, N.Y., U.S.), 2 mM L-glutamine (Nacalai Tesque, Kyoto, Japan), 1% nonessential amino acids (Gibco), 0.1 mM 2-mercaptoethanol (Gibco) and 5 ng/mL fibroblast growth factor-2 (ReproCELL, Kanagawa, Japan). Thirty days subsequent to transduction, a number of colonies were mechanically picked and transferred to a 24-well plate. After several passages, ESC-like colonies were selected for further cultivation and characterization. IPSCs were generated and maintained in ESC culture medium. For routine passaging, iPSC colonies were detached with CTK solution (2.5 µg/mL trypsin, 1 mg/mL collagenase IV, 20% KSR, 1 mM $CaCl_2$/PBS, and 70% PBS) and split at a 1:3 ratio every four to five days.

Quantitative real-time reverse transcription-polymerase chain reaction

Total RNA was isolated using the RNeasy Micro Kit (Qiagen, Limburg, Netherlands) according to the manufacturer's protocol. Single-stranded complementary DNA was synthesized from a total of 500 ng RNA (DNase-treated) using the PrimeScript RT Master Mix (Takara, Shiga, Japan). KhES-1 RNA was provided by the Foundation for Biomedical Research and Innovation (Kobe, Japan). Quantitative real-time reverse transcription-polymerase chain reaction (qRT-PCR) was conducted in triplicate using SYBR Select Master Mix (Life Technologies, Grand Island, N.Y., U.S.) with a StepOnePlus system (Life Technologies) and the following PCR program: 95 °C for 10 min, then 40 cycles of 95 °C for 15 s, 60 °C for 1 min and 72 °C for 15 s. Specific primers are listed in **Table 1**. The glyceraldehyde-3-phosphate dehydrogenase (GAPDH) gene was co-amplified as an internal standard. Gene expression was measured using the $\Delta\Delta C_T$ method.[20] Differences in gene expression between KhES-1, HOF-iPSCs and HOFs were evaluated by variance analysis with the Tukey test.

Table 2

Antibodies	Supplier	Cat. No	Dilution
OCT3/4	Santa Cruz Biotechnology, Dallas, Texas, U.S.	SC5279	1/100
NANOG	Cell Signaling Technology, Danvers, Mass., U.S.	3680S	1/100
SSEA-3	Abcam, Cambridge, Mass., U.S.	ab16286	1/100
SSEA-4	Millipore, Billerica, Mass., U.S.	MAB4360	1/100
TRA-1-60	Millipore, Billerica, Mass., U.S.	MAB4304	1/100
TRA-1-81	Millipore, Billerica, Mass., U.S.	MAB4381	1/100
DAPI	Invitrogen, Carlsbad, Calif., U.S.	D1306	5 µg/mL
Alexa Fluor 594 mouse	Invitrogen, Carlsbad, Calif., U.S.	A11062	1/500
Alexa Fluor 594 rat	Invitrogen, Carlsbad, Calif., U.S.	A21211	1/500

Table 2

Antibodies used for flow cytometry and immunochemical staining of HOF-iPSCs.

Surface antigen analysis

Cells (5×10^5) were obtained after treatment with 0.025% trypsin (Life Technologies). Cell surface antigen staining was performed in phosphate-buffered saline (PBS) with 2% human serum albumin (Mitsubishi-Tanabe Pharma, Osaka, Japan). The cell suspension was incubated with the antibodies listed in **Table 2** for 30 min at 4 °C. Murine anti-human antibodies were used at the recommended concentrations. Primary antibodies and isotype controls are listed in **Table 2**. The stained cells were analyzed with FACSAria II (Becton Dickinson, Franklin Lakes, N.J., U.S.) and the data were analyzed using the FlowJo software (Tree Star, Ashland, Ore., U.S.).

Immunocytochemistry

For fixed staining of differentiation-specific markers, cells were fixed for 30 min in 4% paraformaldehyde at 4 °C, followed by washing in PBS. The cells were then permeabilized for 15 min with 2% bovine serum albumin and 0.1% Triton X-100 (Sigma-Aldrich) and incubated overnight at 4 °C with the primary antibodies diluted in PBS containing 2% bovine serum albumin. The cells were then washed and incubated for 1 h with the appropriate fluorescence-conjugated secondary antibodies. Primary antibodies and secondary antibodies are listed in **Table 2**. The staining images were acquired with a ZOE Fluorescent Cell Imager (Bio-Rad Laboratories, Hercules, Calif., U.S.).

In vivo differentiation (teratoma formation)

NOD.Cg-*Prkdc*^{scid} *Il2rg*^{tm1Wjl}/SzJ mice (Jackson Laboratory, Bar Harbor, Maine, U.S.) were anesthetized and iPSCs (1×10^6) were transplanted under the epidermal space of the neck. Two hundred microliters of saline was injected into a second epidermal space as a negative control. Mice were euthanized 12 weeks later and teratoma samples were collected and subjected to histological analysis. Teratomas were processed according to standard paraffin embedding and hematoxylin and eosin staining procedures by the Business Support Center for Biomedical Research Activities (Kobe, Japan).

Table 3

ESC-like colonies obtained from HOFs. The number of colonies per 5×10^4 cells after cell reprogramming with episomal vectors. These data were obtained from three independent induction experiments using HOFs from a donor.

Table 3

	ES–like	Non-ES–like
HOFs	54	23
	52	24
	58	29

Fig. 1

Excision of oral mucosal tissue by punch biopsy.

Fig. 1

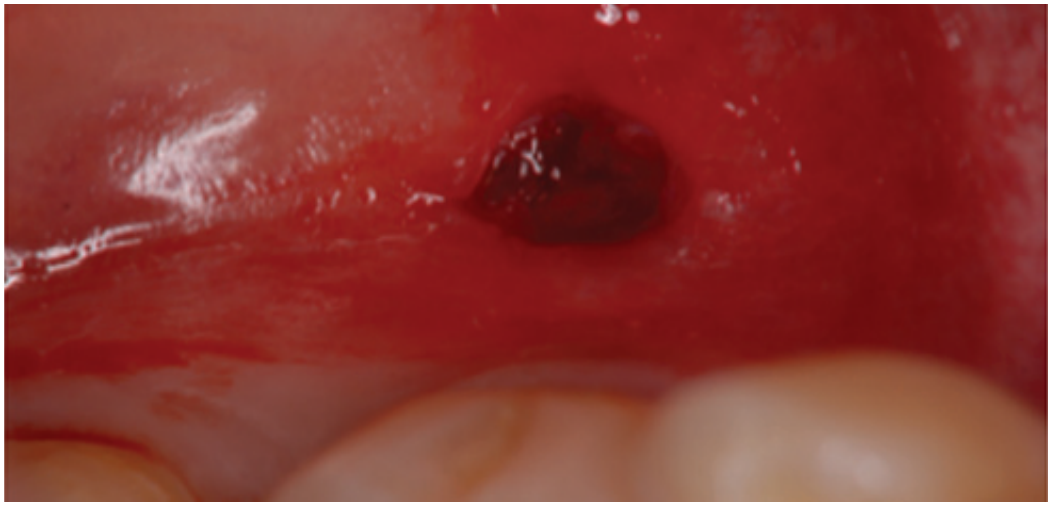

Karyotype analysis

Chromosome G-band analysis was performed at Nihon Gene Research Laboratories (Sendai, Japan). At least 15 metaphases were analyzed.

Results

Generation of iPSCs from HOFs using episomal plasmid vectors

Three lines of HOFs were established from the oral mucosa of the 23-year-old Asian male **(Fig. 1)**. Homogeneous fibroblasts emerged from the oral mucosal tissue one week after the start of culturing. HOFs were exponentially expanded up to 30 passages; cells were counted at each passage and plated at 1.5×10^4 cells/cm^2. Colonies with a flat human ESC-like morphology and non-ESC-like colonies were counted at around day 20 after HOF transfection with episomal plasmid vectors expressing human *OCT3/4*, shRNA against *p53*, *SOX2*, *KLF4*, *L-MYC*, *LIN28* and *Glis1*. The average number of ESC-like colonies from three experiments was 54.7 ± 3.05, with a reprogramming efficiency of approximately 1%; the average number of non-ESC-like colonies was 25.3 ± 3.21 **(Table 3)**. A number of colonies obtained from the HOF cells were mechanically picked at passage 1. Several days later, four ESC-like colonies were selected and expanded. All colonies were similar to ESCs in morphology and proliferative capacity and were named "HOF-iPSCs".

Expression of ESC-specific marker genes in HOF-iPSCs

HOF-iPSCs were selected for characterization from among the picked clones after 23 passages based on their higher level of proliferation and stability of the ESC-like morphology. The expression of the ESC-specific marker genes *OCT3/4*, *NANOG*, *SOX2*, *TERT*, *KLF4* and *C-MYC* in HOF-iPSCs was analyzed using qRT-PCR **(Fig. 3)**. Expression of *NANOG* and *SOX2* was significantly higher and that of *C-MYC* and *TERT* was lower in KhES-1 cells compared with that in HOF-iPSCs **(Figs. 3b–e)**. No significant difference was observed between KhES-1 and HOF-iPSCs for *OCT3/4* and *KLF4* expression **(Figs. 3a & f)**. *KLF4* was the only gene to exhibit higher expression in HOF cells compared with both the KhES-1 cells and HOF-iPSCs **(Fig. 3f)**.

Characterization of HOF-iPSCs

HOF-iPSCs were selected for characterization from among the picked clones after 20 passages

Fig. 2

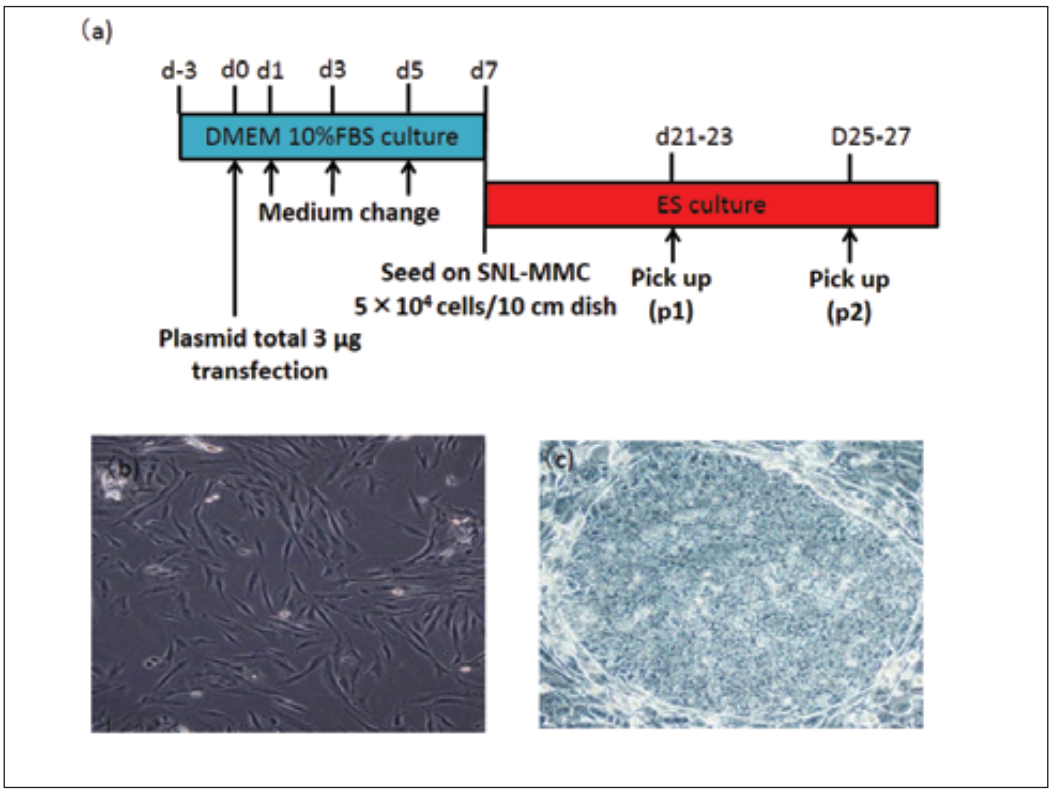

Figs. 2 a–c

Generation of HOF-iPSCs.
(a) Time course for HOF reprogramming.
(b) Microscopy image of original HOFs in culture.
(c) Generated HOF-iPSC colonies on SNL feeder cells.

Fig. 3

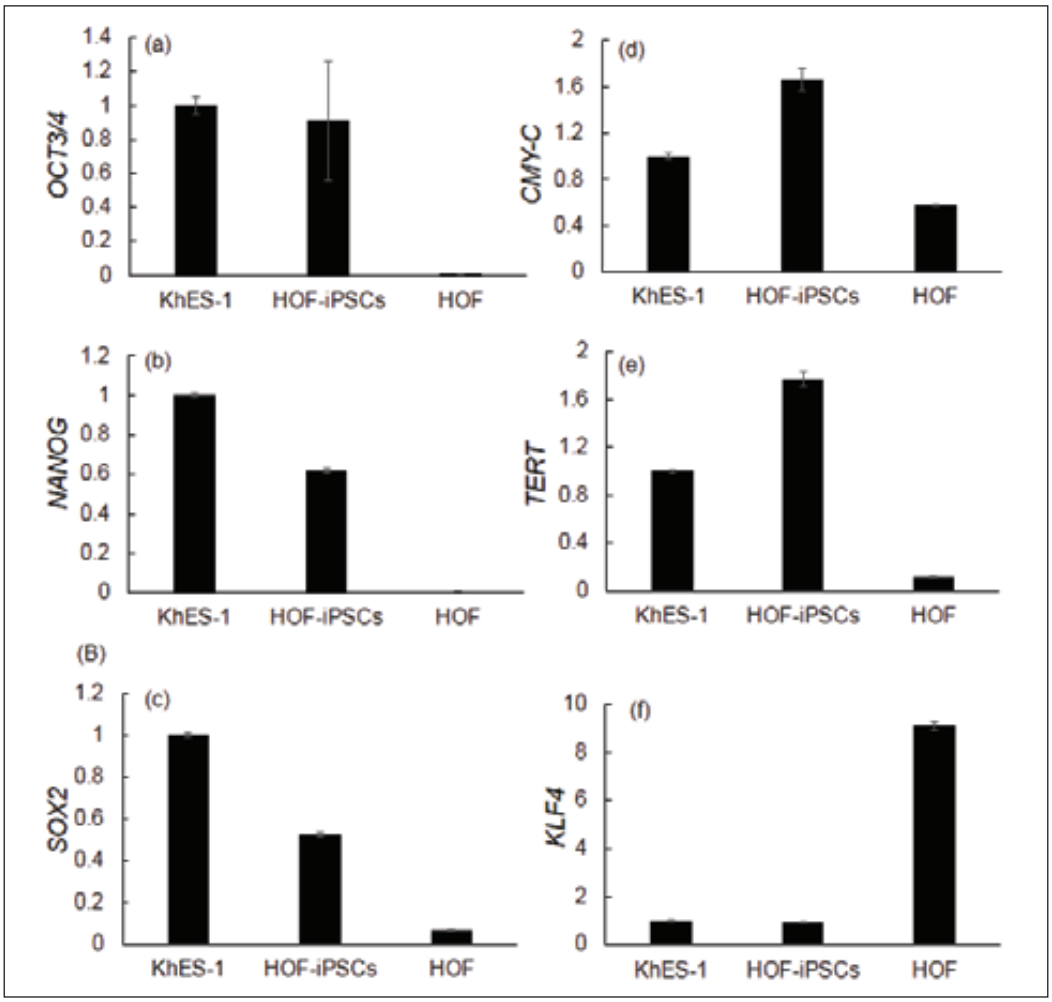

Figs. 3 a–f

QRT-PCR analysis of the expression of six pluripotency-related genes in HOF-iPSCs:
(a) *OCT3/4*,
(b) *NANOG*,
(c) *SOX2*,
(d) *C-MYC*,
(e) *TERT*
and **(f)** *KLF4*. KhES-1 cells (passage 23) were used as the positive control and HOFs (passage 6) as the negative control.

based on increased proliferation and stability of the ESC-like morphology. Expression of the ESC-specific surface markers SSEA-3, SSEA-4 and TRA-1-60 in HOF-iPSCs was analyzed using flow cytometry; all three markers were expressed **(Fig. 4)**. HOF-iPSCs could be maintained beyond 20 passages and still demonstrated ESC-like morphology. In addition, HOF-iPSCs expressed ESC-specific surface markers, such as OCT3/4, SSEA-4, TRA-1-60 and TRA-1-81 **(Fig. 5)**. Tumor formation was observed three months after the injection of HOF-iPSCs under the epidermal space in the neck of immunodeficient mice. Histological examination showed that the tumor contained various tissues, including cartilage (mesoderm), melanocytes (ectoderm), gut-like tube tissue (endoderm) and neural tissue (ectoderm; **Fig. 6**). Karyotype analysis of the tested clones showed a normal human karyotype **(Fig. 7)**.

Discussion

Many strategies have been proposed for the management of large defects in oral tissue or organs such as due to congenital abnormalities, trauma or cancer treatment. Autogenous bone grafts are the gold standard for such reconstruction because of their osteoconductive, osteoinductive and nonimmunogenic properties.[20, 21] Recently, cell therapy using stem cells combined with osteoconductive biomaterials or scaffolds has become a promising alternative to autogenous bone grafts.[22] In order for cell therapy to efficiently treat large defects in oral tissue or organs, it is important to produce a sufficient number of cells that function similarly to primary islets. IPSCs, referred to as pluripotent stem cells, have been generated via retrovirus-mediated introduction of four transcription factors[3, 4] and represent a potentially unlimited source of cells. IPSCs that can be efficiently generated from tissue easily accessible to dentists have great potential;[23] iPSCs have been generated from various oral mesenchymal cells[23] and these cells have been reported to possess higher reprogramming efficiency than skin fibroblasts do.[10]

Oral mucosal tissue is easily accessible and can be harvested by a simple and safe procedure. Oral mucosal wounds are characterized by rapid re-epithelialization and remodeling and are known to heal quickly compared with other skin injuries. This rapid re-epithelialization and remodeling is due to the increased production of active MMP-2 in oral mucosal fibroblasts compared with skin fibroblasts; MMP-2 may play an important role in rapid extracellular matrix reorganization and scarless wound healing.[13, 24, 25] Therefore, we hypothesized that HOFs generated from patient tissue might provide a superior cell source for iPSCs. In the present study, we found that the endogenous expression level of *KLF4* was higher in HOFs than in ESCs or HOF-iPSCs. Endogenous *KLF4* has been shown to be expressed in gingival and periodontal fibroblasts derived from oral tissue.[12] Miyoshi et al. also found that HOFs express not only *KLF4* and *C-MYC* but also *NANOG* and *OCT4* at low levels, suggesting that HOFs possess a number of epigenetic advantages for reprogramming.[13]

Integrating virus-associated genotoxicity and tumor formation in iPSCs is of concern for clinical application.[15] Integration-free human iPSCs have been generated using several methods.[24, 26–30] Okita et al. used two of their findings to improve reprogramming efficiency using episomal plasmids;[15] iPSC generation is markedly enhanced by *p53* suppression[31] and *L-MYC* is more potent and specific than *C-MYC* during human iPSC generation.[32] In our previous study,[17] iPSCs were generated from HGFs using the above-mentioned method. The generated iPSCs expressed ESC-specific markers, as assessed by gene analysis and immunocytochemistry. Embryoid bodies and teratomas were formed from the iPSCs, demonstrating their ability to differentiate into three germ layers. However, 50 ESC-like colonies were obtained only 30 days post-HGF transfection. This lengthy reprogramming process (up to one month) is comparable to that of the standard virus-mediated methodology.[33]

The maternal Gli-like transcription factor *Glis1* is highly expressed in unfertilized eggs and one-cell-stage embryos.[18] Maekawa et al. showed that *Glis1*, but not C-MYC, increased iPSC tumorigenicity and markedly enhanced the generation of iPSCs from both mouse and human fibroblasts when expressed together with *OCT3/4*, *SOX2* and *KLF4*.[18] In the present study, we observed 50 colonies of human ES-like cells as early as 20 days after initial episomal plasmid vector transduction. These results demonstrate that *Glis1* enhances the efficiency of iPSC generation using episomal plasmid vectors expressing *OCT3/4*, shRNA against *p53*, *SOX2*, *KLF4*, *L-MYC* and *LIN28*. However, iPSC generation from multiple donors will be required to establish the application of iPSC technology to biomedical research.

Fig. 4

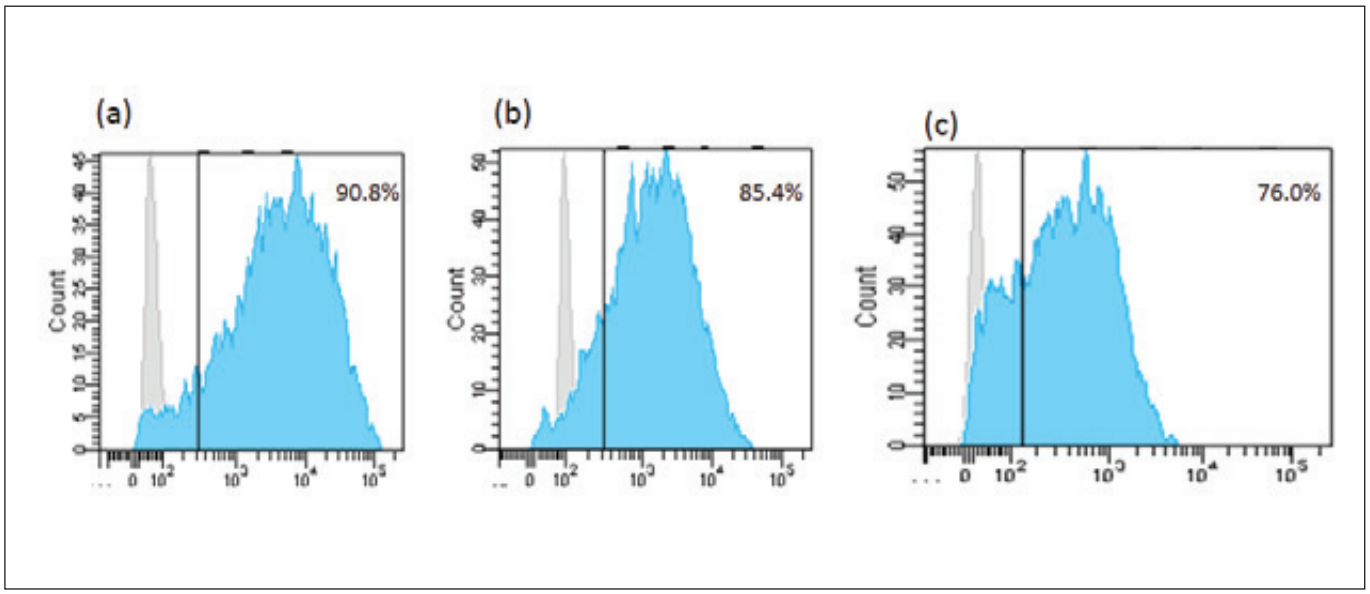

Fig. 5

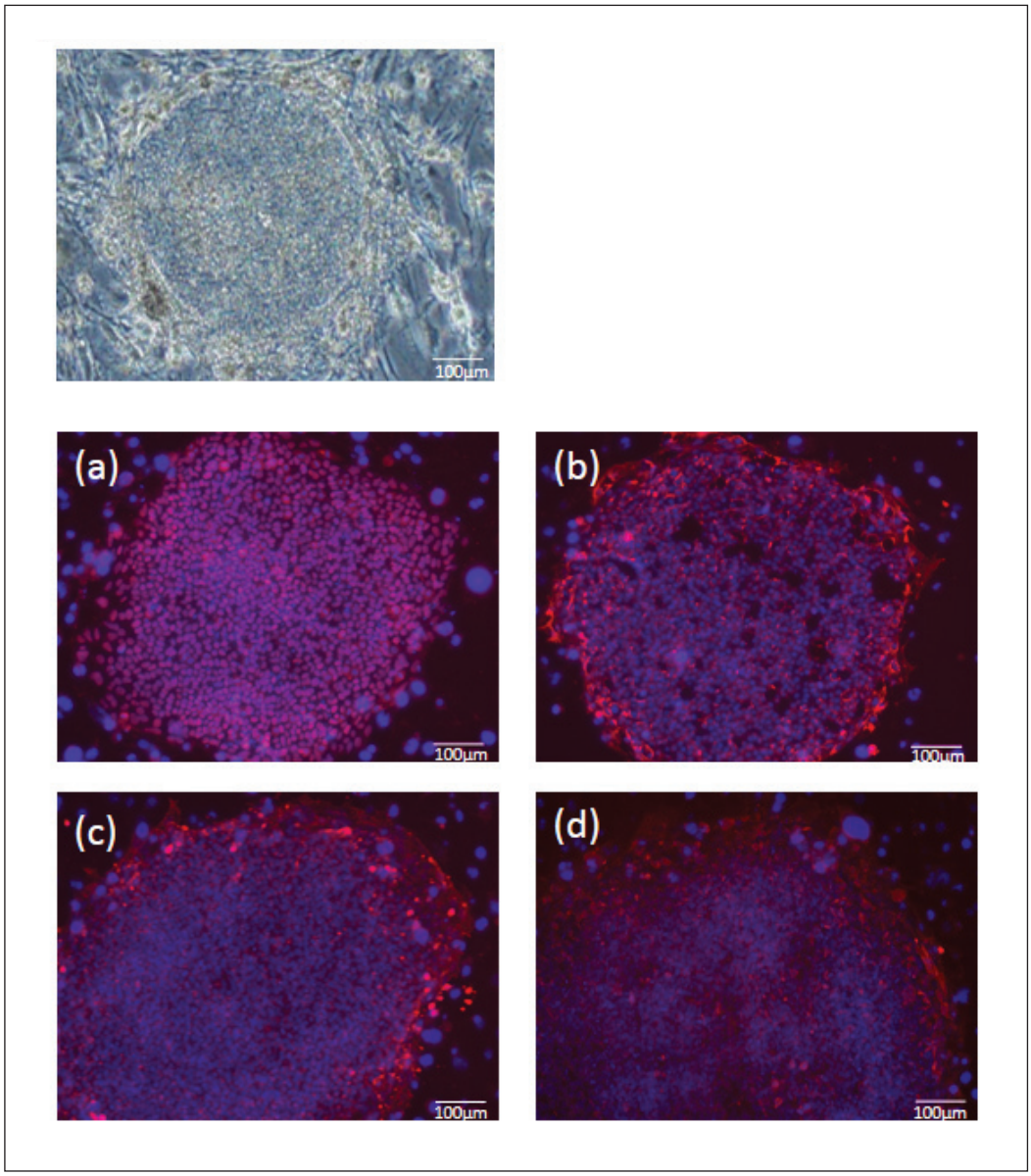

Figs. 4a–c

Flow cytometry analysis of pluripotent markers in HOF-iPSCs: **(a)** SSEA-3, **(b)** SSEA-4 and **(c)** TRA-1-60.

Figs. 5a–d

Generated HOF-iPSCs stained for **(a)** OCT3/4, **(b)** SSEA-4, **(c)** TRA-1-60 and **(d)** TRA-1-81; scale bar = 100 µm.

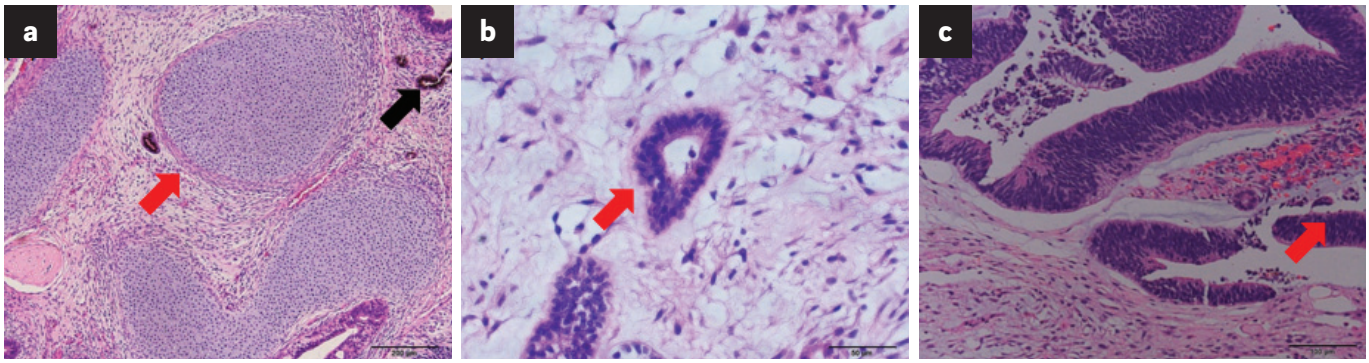

Figs. 6a–c

Figs. 6a–c

IPSCs have the potential to differentiate into three germ layers *in vivo*. Hematoxylin and eosin staining of teratomas derived from iPSCs at passage 20 revealed the presence of **(a)** cartilage (mesoderm; red arrow), melanocytes (ectoderm; black arrow), **(b)** gut-like tube tissue (endoderm; red arrow) and **(c)** neural tissue (ectoderm; red arrow).

Fig. 7

Karyotype analysis of iPSCs at passage 20 using G-band staining.

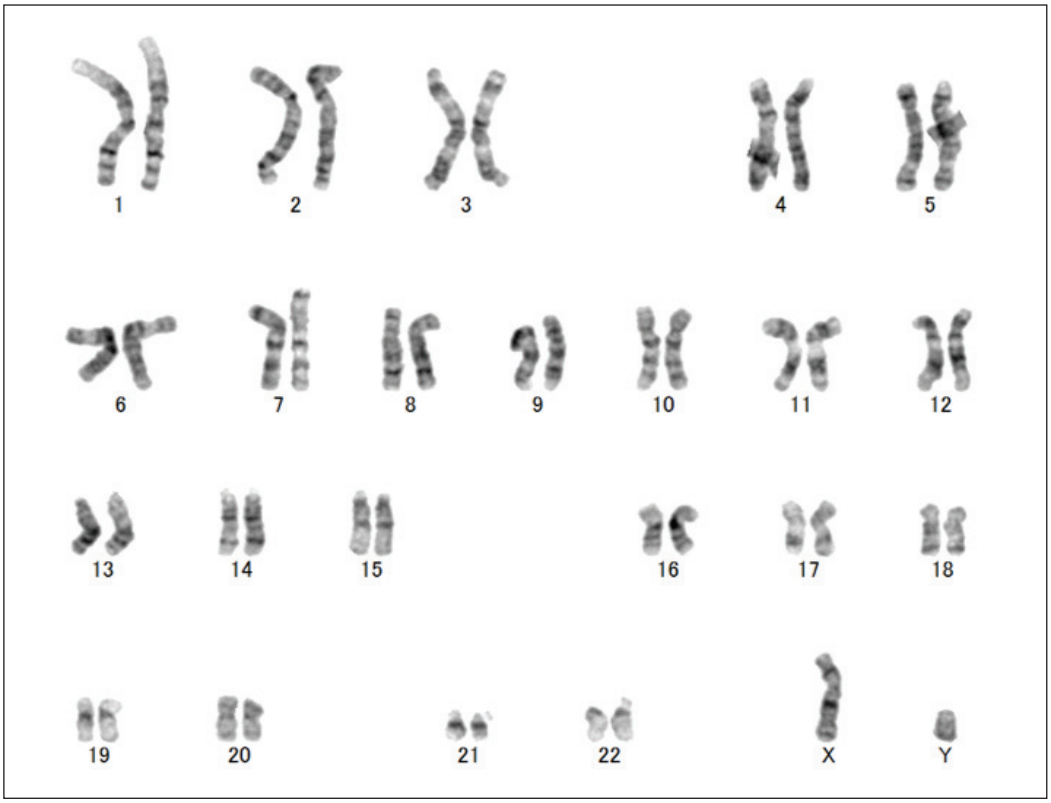

Fig. 7

Conclusion

Oral mucosal tissue can be conveniently obtained using a simple and safe procedure and possesses epigenetic advantages for reprogramming. We have successfully established a technique for rapidly and safely generating human iPSCs from oral mucosa using episomal plasmid vectors expressing *OCT3/4*, shRNA against *p53*, *SOX2*, *KLF4*, *L-MYC*, *LIN28* and *Glis1*. In order to repair large bone defects caused by trauma, tumors or congenital deficiency, it is necessary to combine sufficient cell numbers and biomaterials. The accelerated generation of integration-free human iPSCs would facilitate the application of clinical-grade iPSC technology for the treatment of large oral tissue or organ defects.

Competing interests

The authors declare that they have no competing interests.

Acknowledgments

We wish to thank Takako Yamamoto of the Foundation for Biomedical Research and Innovation for her support with flow cytometry analysis. This study was supported by a MEXT/JSPS KAKENHI grant (No. 25463041).

References

1.
Lowry WE, Richter L, Yachechko R, Pyle AD, Tchieu J, Sridharan R, Clark AT, Plath K. Generation of human induced pluripotent stem cells from dermal fibroblasts.
→ Proc Natl Acad Sci U S A.
2008 Feb;105(8):2883–8.

2.
Park IH, Zhao R, West JA, Yabuuchi A, Huo H, Ince TA, Lerou PH, Lensch MW, Daley GQ. Reprogramming of human somatic cells to pluripotency with defined factors.
→ Nature.
2008 Jan;451(7175):141–6.

3.
Takahashi K, Tanabe K, Ohnuki M, Narita M, Ichisaka T, Tomoda K, Yamanaka S. Induction of pluripotent stem cells from adult human fibroblasts by defined factors.
→ Cell.
2007 Nov;131(5):861–72.

4.
Takahashi K, Yamanaka S. Induction of pluripotent stem cells from mouse embryonic and adult fibroblast cultures by defined factors.
→ Cell.
2006 Aug;126(4):663–76.

5.
Yu J, Vodyanik MA, Smuga-Otto K, Antosiewicz-Bourget J, Frane JL, Tian S, Nie J, Jonsdottir GA, Ruotti V, Stewart R, Slukvin II, Thomson JA. Induced pluripotent stem cell lines derived from human somatic cells.
→ Science.
2007 Dec;318(5858):1917–20.

6.
Evans MJ, Kaufman MH. Establishment in culture of pluripotential cells from mouse embryos.
→ Nature.
1981 Jul;292(5819):154–6.

7.
Martin GR. Isolation of a pluripotent cell line from early mouse embryos cultured in medium conditioned by teratocarcinoma stem cells.
→ Proc Natl Acad Sci U S A.
1981 Dec;78(12):7634–8.

8.
Thomson JA, Itskovitz-Eldor J, Shapiro SS, Waknitz MA, Swiergiel JJ, Marshall VS, Jones JM. Embryonic stem cell lines derived from human blastocysts.
→ Science.
1998 Nov;282(5391):1145–7.

9.
Su RJ, Neises A, Zhang XB. Generation of iPS cells from human peripheral blood mononuclear cells using episomal vectors. In: Turksen K, Nagy A, editors. Induced pluripotent stem (iPS) cells: methods and protocols.
→ New York: Springer;
2016. p. 57–69. (Walker JM, editor. Methods in molecular biology; vol. 1357).

10.
Tamaoki N, Takahashi K, Tanaka T, Ichisaka T, Aoki H, Takeda-Kawaguchi T, Iida K, Kunisada T, Shibata T, Yamanaka S, Tezuka K. Dental pulp cells for induced pluripotent stem cell banking.
→ J Dent Res.
2010 Aug;89(8):773–8.

11.
Egusa H, Okita K, Kayashima H, Yu G, Fukuyasu S, Saeki M, Matsumoto T, Yamanaka S, Yatani H. Gingival fibroblasts as a promising source of induced pluripotent stem cells.
→ PLoS One.
2010 Sep;5(9):e12743.

12.
Wada N, Wang B, Lin NH, Laslett AL, Gronthos S, Bartold PM. Induced pluripotent stem cell lines derived from human gingival fibroblasts and periodontal ligament fibroblasts.
→ J Periodontal Res.
2011 Aug;46(4):438–47.

13.
Miyoshi K, Tsuji D, Kudoh K, Satomura K, Muto T, Itoh K, Noma T. Generation of human induced pluripotent stem cells from oral mucosa.
→ J Biosci Bioeng.
2010 Sep;110(3):345–50.

14.
Oda Y, Yoshimura Y, Ohnishi H, Tadokoro M, Katsube Y, Sasao M, Kubo Y, Hattori K, Saito S, Horimoto K, Yuba S, Ohgushi H. Induction of pluripotent stem cells from human third molar mesenchymal stromal cells.
→ J Biol Chem.
2010 Sep;285(38):29270–8.

15.
Okita K, Matsumura Y, Sato Y, Okada A, Morizane A, Okamoto S, Hong H, Nakagawa M, Tanabe K, Tezuka K, Shibata T, Kunisada T, Takahashi M, Takahashi J, Saji H, Yamanaka S. A more efficient method to generate integration-free human iPS cells.
→ Nat Methods.
2011 May;8(5):409–12.

16.
Su RJ, Baylink DJ, Neises A, Kiroyan JB, Meng X, Payne KJ, Tschudy-Seney B, Duan Y, Appleby N, Kearns-Jonker M, Gridley DS, Wang J, Lau KH, Zhang XB. Efficient generation of integration-free iPS cells from human adult peripheral blood using BCL-XL together with Yamanaka factors.
→ PLoS One.
2013 May;8(5):e64496.

17.
Umezaki Y, Hashimoto Y, Nishishita N, Kawamata S, Baba S. Human gingival integration-free iPSCs; a source for MSC-like cells.
→ Int J Mol Sci.
2015 Jun;16(6):13633–48.

18.
Maekawa M, Yamaguchi K, Nakamura T, Shibukawa R, Kodanaka I, Ichisaka T, Kawamura Y, Mochizuki H, Goshima N, Yamanaka S. Direct reprogramming of somatic cells is promoted by maternal transcription factor Glis1.
→ Nature.
2011 Jun;474(7350):225–9.

19.
Livak KJ, Schmittgen TD. Analysis of relative gene expression data using real-time quantitative PCR and the $2^{-\Delta\Delta C_T}$ method.
→ Methods.
2001 Dec;25(4):402–8.

20.
Gimbel M, Ashley RK, Sisodia M, Gabbay JS, Wasson KL, Heller J, Wilson L, Kawamoto HK, Bradley JP. Repair of alveolar cleft defects: reduced morbidity with bone marrow stem cells in a resorbable matrix.
→ J Craniofac Surg.
2007 Jul;18(4):895–901.

21.
Sakamoto F, Hashimoto Y, Kishimoto N, Honda Y, Matsumoto N. The utility of human dedifferentiated fat cells in bone tissue engineering in vitro.
→ Cytotechnology.
2015 Jan;67(1):75–84.

22.
Levi B, Glotzbach JP, Wong VW, Nelson ER, Hyun J, Wan DC, Gurtner GC, Longaker MT. Stem cells: update and impact on craniofacial surgery.
→ J Craniofac Surg.
2012 Jan;23(1):319–22.

23.
Egusa H, Sonoyama W, Nishimura M, Atsuta I, Akiyama K. Stem cells in dentistry—part I: stem cell sources.
→ J Prosthodont Res.
2012 Jul;56(3):151–65.

24.
Zhou W, Freed CR. Adenoviral gene delivery can reprogram human fibroblasts to induced pluripotent stem cells.
→ Stem Cells.
2009 Nov;27(11):2667–74.

25.
Stephens P, Davies KJ, Occleston N, Pleass RD, Kon C, Daniels J, Khaw PT, Thomas DW. Skin and oral fibroblasts exhibit phenotypic differences in extracellular matrix reorganization and matrix metalloproteinase activity.
→ Br J Dermatol.
2001 Feb;144(2):229–37.

26.
Woltjen K, Michael IP, Mohseni P, Desai R, Mileikovsky M, Hämäläinen R, Cowling R, Wang W, Liu P, Gertsenstein M, Kaji K, Sung HK, Nagy A. *piggyBac* transposition reprograms fibroblasts to induced pluripotent stem cells.
→ Nature.
2009 Apr;458(7239):766–70.

27.
Jia F, Wilson KD, Sun N, Gupta DM, Huang M, Li Z, Panetta NJ, Chen ZY, Robbins RC, Kay MA, Longaker MT, Wu JC. A nonviral minicircle vector for deriving human iPS cells.
→ Nat Methods.
2010 Mar;7(3):197–9.

28.
Warren L, Manos PD, Ahfeldt T, Loh YH, Li H, Lau F, Ebina W, Mandal PK, Smith ZD, Meissner A, Daley GQ, Brack AS, Collins JJ, Cowan C, Schlaeger TM, Rossi DJ. Highly efficient reprogramming to pluripotency and directed differentiation of human cells with synthetic modified mRNA.
→ Cell Stem Cell.
2010 Nov;7(5):618–30.

29.
Kim D, Kim CH, Moon JI, Chung YG, Chang MY, Han BS, Ko S, Yang E, Cha KY, Lanza R, Kim KS. Generation of human induced pluripotent stem cells by direct delivery of reprogramming proteins.
→ Cell Stem Cell.
2009 Jun;4(6):472–6.

30.
Fusaki N, Ban H, Nishiyama A, Saeki K, Hasegawa M. Efficient induction of transgene-free human pluripotent stem cells using a vector based on Sendai virus, an RNA virus that does not integrate into the host genome.
→ Proc Jpn Acad Ser B Phys Biol Sci.
2009;85(8):348–62.

31.
Hong H, Takahashi K, Ichisaka T, Aoi T, Kanagawa O, Nakagawa M, Okita K, Yamanaka S. Suppression of induced pluripotent stem cell generation by the p53-p21 pathway.
→ Nature.
2009 Aug;460(7259):1132–5.

32.
Nakagawa M, Takizawa N, Narita M, Ichisaka T, Yamanaka S. Promotion of direct reprogramming by transformation-deficient Myc.
→ Proc Natl Acad Sci U S A.
2010 Aug;107(32):14152–7.

33.
Shimada H, Hashimoto Y, Nakada A, Shigeno K, Nakamura T. Accelerated generation of human induced pluripotent stem cells with retroviral transduction and chemical inhibitors under physiological hypoxia.
→ Biochem Biophys Res Commun.
2012 Jan;417(2):659–64.

Bone block graft to treat an apicomarginal defect simultaneously with apical surgery of the maxillary incisors: A case report with three-year follow-up

Juan Cervera Ballester,[a] David Peñarrocha Oltra,[a] María Peñarrocha Diago,[a] Laura Maestre Ferrín[a] & Miguel Peñarrocha Diago[a]

[a] Department of Stomatology, Faculty of Medicine and Odontology, University of Valencia, Valencia, Spain

Corresponding author:

Dr. David Peñarrocha Oltra
Cirugía Bucal. Clínicas Odontológicas
C/Gascó Oliag, 1
46021 Valencia
Spain

T +34 963 86 4144
david.penarrocha@uv.es

How to cite this article:

Cervera Ballester J, Peñarrocha Oltra D, Peñarrocha Diago M, Maestre Ferrín L, Peñarrocha M. Bone block graft to treat an apicomarginal defect simultaneously with apical surgery of the maxillary incisors: a case report with three-year follow-up.

J Oral Science Rehabilitation.
2016 Jun;2(2):36–40.

Abstract

Objective

The objective of this article is to describe the successful management of an apicomarginal defect of a maxillary lateral incisor with a bone block graft performed simultaneously with apical surgery of both lateral and central incisors.

Case presentation

A 15-year-old male patient with a recurrent sinus tract involving the maxillary right incisors was referred for possible treatment with apical surgery. Root canal treatment and apical surgery had been undertaken unsuccessfully one year before. Radiographic examination revealed a radiolucent area surrounding the tooth apexes. A bone block was harvested from the apical area of the central incisor with ultrasound tips to gain access to the root end and apical surgery of both incisors was performed. The bone block graft was used to cover an apicomarginal bony defect of the maxillary lateral incisor. At the three-year follow-up, the teeth had no clinical signs or symptoms, and the periapical radiograph demonstrated complete healing around the apexes.

Conclusion

The use of a bone block graft to treat an apicomarginal defect in conjunction with apical surgery achieved complete healing of the periradicular tissue in this case.

Keywords

Apicomarginal defect, apical surgery, bone regeneration.

Introduction

An apicomarginal defect is defined as a localized bony defect that is characterized by the absence of alveolar bone over the entire root length.[1] This type of defect significantly reduces the prognosis of periapical surgery. Hirsch et al.[2] and Skoglund and Persson[3] observed healing rates of 27% and 37%, respectively, in teeth that had undergone periapical surgery and with apicomarginal defects, substantially lower than teeth in which the vestibular cortical was intact. Current surgical techniques, supported by the use of ultrasound, amplification and magnification devices, have improved the prognosis of periapical surgery,[4] also in teeth with this type of bony defect. Kim et al. observed a healing success of 77.5% in teeth with apicomarginal defects using a microsurgical technique, but still significantly lower than the 95.2% rate of teeth with lesions confined to the apical area.[5]

The reason for the poorer prognosis in teeth with apicomarginal defects has been suggested to be the formation of a long junctional epithelium over the denuded root surface, preventing bone regeneration.[6] Experimental[7, 8] and clinical studies[9] have shown significantly higher success rates with the use of tissue regeneration techniques (guided tissue regeneration, GTR) in apicomarginal defects.

The purpose of this article is to describe the successful management of an apicomarginal defect of a maxillary lateral incisor with a bone block graft performed simultaneously with apical surgery of both lateral and central incisors.

Case report

A 15-year-old male patient was referred to our clinic because of a recurrent sinus tract involving the maxillary right incisors **(Fig. 1)**. Regarding the patient's medical history, no health problem was reported, nor was a history of allergies or the use of any medication. The patient had suffered a traumatism one year before that caused fracturing of the central incisors and the right lateral incisor. The central incisors were restored with composite and root canal fillings were performed in both central and lateral right incisors; in addition, root resection of the lateral incisor had been performed without retrograde filling. The periapical radiograph showed a radiolucent area surrounding the tooth apex **(Fig. 2)**. Probing depth was normal around the central incisor and the lateral incisor had a 7 mm depth at the vestibular aspect.

The surgical treatment combined two procedures: endodontic surgery of both maxillary right incisors and a bone autograft to regenerate the buccal bone plate of the lateral incisor. The surgery was carried out under local anesthesia with 4% articaine and 1:100,000 epinephrine (Inibsa, Lliçà de Vall, Spain). After elevation of a full-thickness mucoperiosteal flap, the pathological tissue around the apex of the lateral incisor was debrided. Afterward, a bone block was harvested from the apical area of the central incisor with ultrasound tips to gain access to the root end **(Fig. 3)**; the block was kept submerged in saline solution. The root of the central incisor was then resected approximately 3 mm from the apex; the lateral incisor root had been resected in a previous periapical surgery **(Fig. 4)**. Hemostasis of the bony crypt was achieved with aluminum chloride (Expasyl, Produits Dentaires Pierre Rolland, Merignac, France).[10] The root ends were inspected using a rigid endoscope (Möller-Wedel, Munich, Germany; **Figs. 5 & 6**). The root-end cavities were prepared with sonic-driven microtips (Piezon Master 400, EMS Electro Medical Systems, Nyon, Switzerland; **Fig. 7**) and were retrofilled with mineral trioxide aggregate (MTA; DENTSPLY Tulsa Dental Specialties, Tulsa, Okla., U.S.; **Fig. 8)**. The quality of the retrograde fillings was inspected with the endoscope **(Fig. 9)**. The bone block graft was fixed with an osteosynthesis screw to regenerate the buccal wall of the lateral incisor **(Fig. 10)**. The bony defect at the donor area and the apical area of tooth #12 were covered with textured bovine collagen (Lyostypt, B. Braun Melsungen, Tuttlingen, Germany). After cleaning the wound area, primary wound closure was accomplished with multiple interrupted sutures.

The patient was prescribed amoxicillin (500 mg/8 h) preoperatively (two days before surgery) for suppurative abscess and five days after intervention owing to the bone block graft procedure, ibuprofen (400 mg/8 h for four days), a 0.12% chlorhexidine rinse (t.i.d. for seven days) and paracetamol (500 mg on demand) in the event of intense pain. The sutures were removed after one week.

At the follow-up visit after three years, the teeth were asymptomatic, no gingival recession had occurred and normal periodontal probing depths were recorded around both teeth **(Fig. 11)**. The periapical radiograph showed complete bone regeneration around the apexes **(Fig. 12)**.

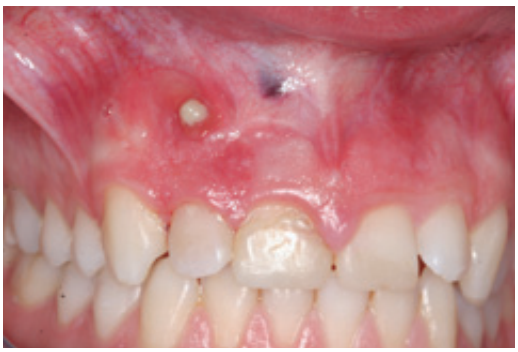

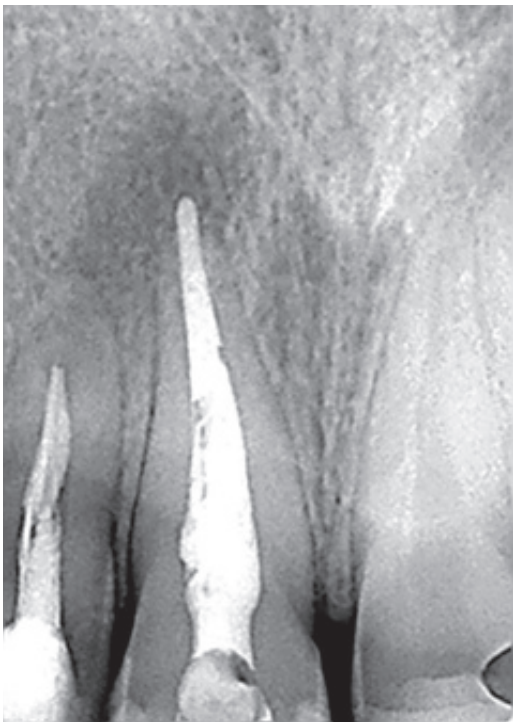

Figs. 1 & 2

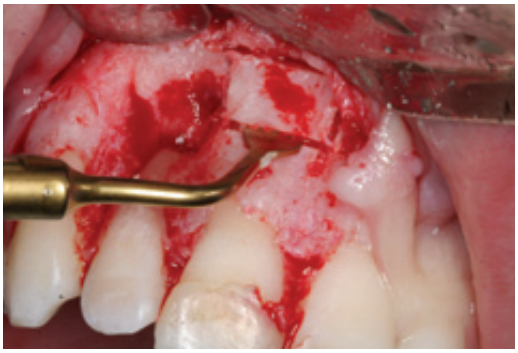

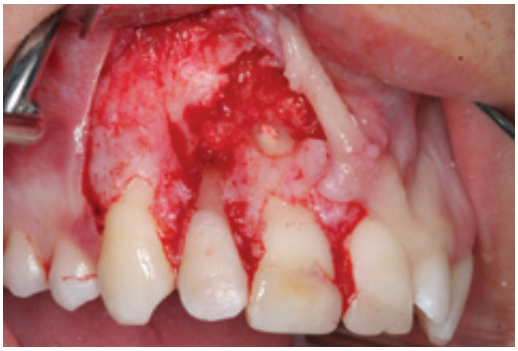

Figs. 3 & 4

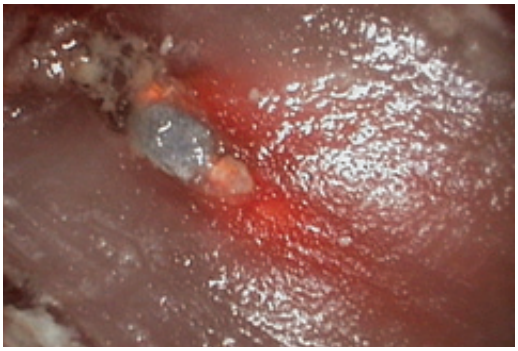

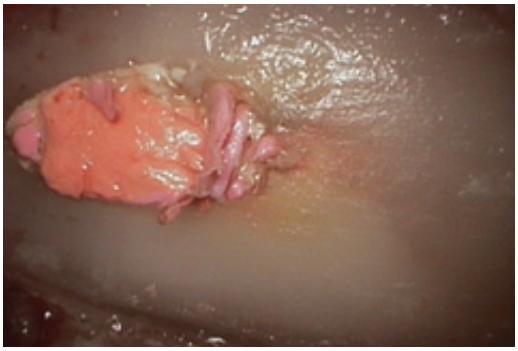

Figs. 5 & 6

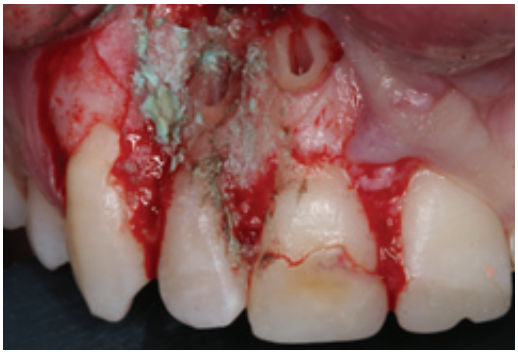

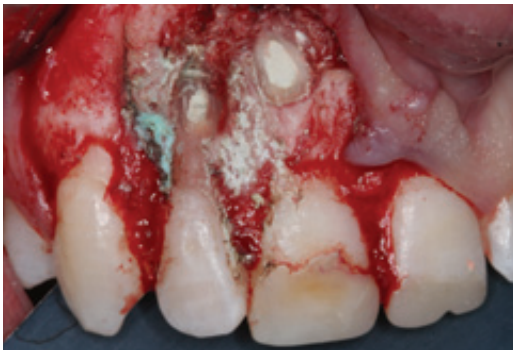

Figs. 7 & 8

Fig. 1

Sinus tract involving the maxillary right incisors.

Fig. 2

The periapical radiograph shows a radiolucency around the apexes of the central and lateral incisors.

Fig. 3

Using ultrasound, a bone block was harvested from the apical area of the central incisor.

Fig. 4

Intraoperative image after root-end resection.

Fig. 5

Endoscopic image of the lateral incisor apex, resected during a previous periapical surgery.

Fig. 6

Endoscopic image of the central incisor apex after root-end resection, showing the gutta-percha.

Fig. 7

Root-end cavities prepared in both teeth.

Fig. 8

Image after root-end cavity filling. The apicomarginal defect of the lateral incisor is evident over the entire buccal bone plate.

Fig. 9

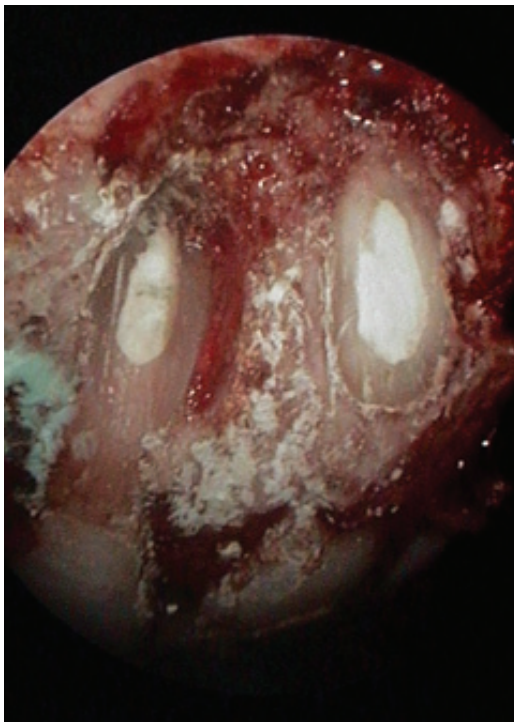

Fig. 10

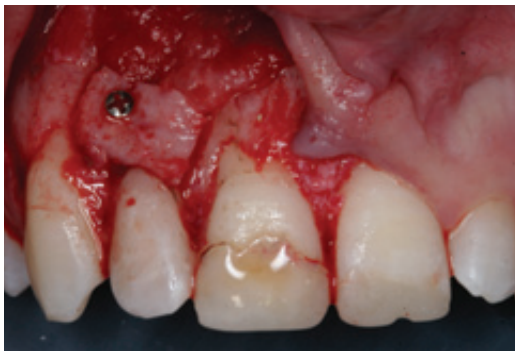

Fig. 11

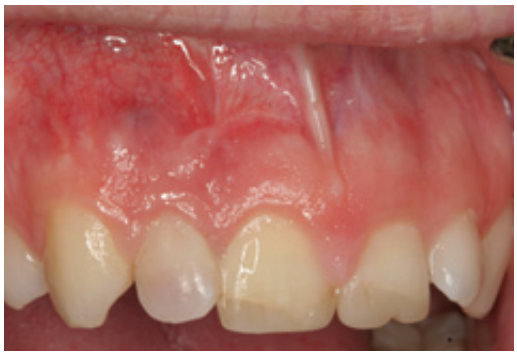

observed that GTR improved the success rate of periapical surgery, particularly in large and through-and-through lesions, although the differences were not statistically significant.[15] However, none of the studies included evaluated the prognosis of teeth with apicomarginal defects. Tissue regeneration in teeth with apicomarginal defects is not as predictable and there is no verified treatment option.[16] Only four clinical trials, none of them with control groups, were found in which the prognosis of periapical surgery in teeth with apicomarginal lesions was studied. Dietrich et al. grafted the defects with inorganic bovine bone material and a collagen membrane.[17] After one year, the clinical and radiographic assessment demonstrated a success rate of 82.6% and the median probing pocket depth decreased from 9 mm to 3 mm. Three years later, Marín-Botero et al. found similar results in two study groups.[9] In one group, a polyglactin 910 membrane was placed over the apicomarginal defect (n = 15), and in the other group, a sliding periosteal graft was used to cover the defect (n = 15). Identical success rates of 87% were observed in both groups.

Recently, the outcome of modern endodontic microsurgery was evaluated by Kim et al. in a prospective study.[5] They studied healing according to the type of lesion and observed a healing success rate of 73.7% for teeth with apicomarginal defects treated with calcium sulfate placed into the periradicular bony defect and a collagen membrane covering the denuded buccal surface. Goyal et al. evaluated the use of platelet-rich plasma (PRP) for the treatment of apicomarginal

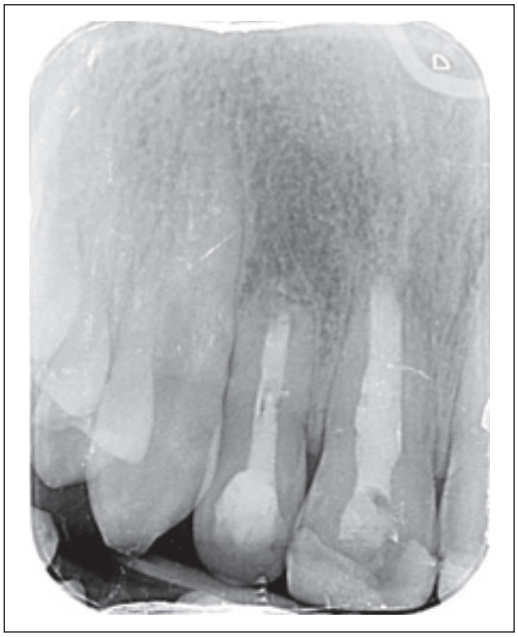

Fig. 9

Endoscopic image after cavity filling with MTA.

Fig. 10

The bone block graft was fixed with an osteosynthesis screw to regenerate the buccal wall of the lateral incisor.

Fig. 11

Clinical appearance at the three-year follow-up visit.

Fig. 12

Periapical radiograph three years after surgery. Complete bone regeneration around the apexes was observed.

Discussion

Complete healing of periapical tissue after periapical surgery includes regeneration of the alveolar bone, periodontal ligament and cementum.[11] Several studies have shown that GTR applied with periapical surgery promotes healing of apical lesions and improves the prognosis of the treatment.[12–14] In a recent meta-analysis, Tsesis et al.

defects.[18] They conducted a study with three groups: In the first group, the defect was covered with a collagen membrane ($n = 10$); in the second group, a PRP preparation was placed over the defect ($n = 10$); and in the last group, PRP was packed into the defect and a collagen sponge was used to cover it ($n = 10$). The overall rate of healed cases was 80.76%, with differences that were not statistically significant between the groups.

Currently, the use of ultrasound, amplification and magnification devices has improved the prognosis of periapical surgery.[4] In this case report, these advances allowed treatment of an apicomarginal defect with a bone block graft after periapical surgery of two maxillary incisors. There are no studies in the literature on the use of a block graft to treat this type of lesion simultaneously with apical surgery. Bone block grafts are used in implantology owing to osteogenic, osteoinductive and osteoconductive potential. Thus, although there are currently very few studies that provide scientific evidence sufficient to determine the ideal treatment of apicomarginal defects, we believe that the procedure proposed in this article can be an alternative for the treatment of these defects.

One of the main problems with this type of graft is management of the soft tissue, since in order to minimize the risk of dehiscence, it is necessary to achieve a tension-less wound closure.[19] The stabilization and intimate contact between the block graft and the recipient bed have been considered crucial to a successful outcome.[20] This can be achieved with the use of osteosynthesis screws.[21]

Conclusion

The use of a bone block graft to treat an apicomarginal defect in conjunction with apical surgery achieved complete healing of the periradicular tissue in this case.

Competing interests

The authors declare that they have no competing interests.

References

1.
Dietrich T, Zunker P, Dietrich D, Bernimoulin JP. Apicomarginal defects in periradicular surgery: classification and diagnostic aspects.
→ Oral Surg Oral Med Oral Pathol Oral Radiol Endod.
2002 Aug;94(2):233–9.

2.
Hirsch JM, Ahlström U, Henrikson PA, Heyden G, Peterson, LE. Periapical surgery.
→ Clin Implant Dent Relat Res.
1979 Jun;8(3):173–85.

3.
Skoglund A, Persson G. A follow-up study of apicoectomized teeth with total loss of the buccal bone plate.
→ Oral Surg Oral Med Oral Pathol.
1985 Jan;59(1):78–81.

4.
Kim S, Kratchman S. Modern endodontic surgery concepts and practice: a review.
→ J Endod.
2006 Jul;32(7):601–23.

5.
Kim E, Song JS, Jung IY, Lee SJ, Kim S. Prospective clinical study evaluating endodontic microsurgery outcomes for cases with lesions of endodontic origin compared with cases with lesions of combined periodontal-endodontic origin.
→ J Endod.
2008 May;34(5):546–51.

6.
Rankow HJ, Krasner PR. Endodontic applications of guided tissue regeneration in endodontic surgery.
→ J Endod.
1996 Jan;22(1):34–43.

7.
Douthitt JC, Gutmann JL, Witherspoon DE. Histologic assessment of healing after the use of a bioresorbable membrane in the management of buccal bone loss concomitant with periradicular surgery.
→ J Endod.
2001 Jun;27(6):404–10.

8.
Britain SK, von Arx T, Schenk RK, Buser D, Nummikoski P, Cochran DL. The use of guided tissue regeneration principles in endodontic surgery for induced chronic periodontic-endodontic lesions: a clinical, radiographic, and histologic evaluation.
→ J Periodontol.
2005 Mar;76(3):450–60.

9.
Marín-Botero ML, Domínguez-Mejía JS, Arismendi-Echavarría JA, Mesa-Jaramillo AL, Flórez-Moreno GA, Tobón-Arroyave SI. Healing response of apicomarginal defects to two guided tissue regeneration techniques in periradicular surgery: a double-blind, randomized-clinical trial.
→ Int Endod J.
2006 May;39(5):368–77.

10.
Von Arx T, Jensen SS, Hänni S, Schenk RK. Haemostatic agents used in periradicular surgery: an experimental study of their efficacy and tissue reactions.
→ Int Endod J.
2006 Oct;39(10):800–8.

11.
Lin L, Chen MY, Ricucci D, Rosenberg PA. Guided tissue regeneration in periapical surgery.
→ J Endod.
2010 Apr;36(4):618–25.

12.
Taschieri S, del Fabbro M, Testori T, Weinstein R. Efficacy of xenogeneic bone grafting with guided tissue regeneration in the management of bone defects after surgical endodontics.
→ J Oral Maxillofac Surg.
2007 Jun;65(6):1121–7.

13.
Taschieri S, Del Fabbro M, Testori T, Saita M, Weinstein R. Efficacy of guided tissue regeneration in the management of through-and-through lesions following surgical endodontics: a preliminary study.
→ Int J Periodontics Restorative Dent.
2008 Jun;28(3):265–71.

14.
Pecora G, De Leonardis D, Ibrahim N, Bovi M, Cornelini R. The use of calcium sulphate in the surgical treatment of a 'through and through' periradicular lesion.
→ Int Endod J.
2001 Apr;34(3):189–97.

15.
Tsesis I, Rosen E, Tamse A, Taschieri S, Del Fabbro M. Effect of guided tissue regeneration on the outcome of surgical endodontic treatment: a systematic review and meta-analysis.
→ J Endod.
2011 Aug;37(8):1039–45.

16.
Von Arx T, AlSaeed M. The use of regenerative techniques in apical surgery: a literature review.
→ Saudi Dent J.
2011 Jul;23(3):113–27.

17.
Dietrich T, Zunker P, Dietrich D, Bernimoul in JP. Periapical and periodontal healing after osseous grafting and guided tissue regeneration treatment of apicomarginal defects in periradicular surgery: results after 12 months.
→ Oral Surg Oral Med Oral Pathol Oral Radiol Endod.
2003 Apr;95(4):474–82.

18.
Goyal B, Tewari S, Duhan J, Sehgal PK. Comparative evaluation of platelet-rich plasma and guided tissue regeneration membrane in the healing of apicomarginal defects: a clinical study.
→ J Endod.
2011 Jun;37(6):773–80.

19.
Felice P, Pellegrino G, Checchi L, Pistilli R, Esposito M. Vertical augmentation with interpositional blocks of anorganic bovine bone vs. 7-mm-long implants in posterior mandibles: 1-year results of a randomized clinical trial.
→ Clin Oral Implants Res.
2010 Dec;21(12):1394–403.

20.
De Carvalho PS, Vasconcellos LW, Pi J. Influence of bed preparation on the incorporation of autogenous bone grafts: a study in dogs.
→ Int J Oral Maxillofac Implants.
2000 Jul-Aug;15(4):565–70.

21.
Buser D, Dula K, Hirt HP, Schenk RK. Lateral ridge augmentation using autografts and barrier membranes: a clinical study with 40 partially edentulous patients.
→ J Oral Maxillofac Surg.
1996 Apr;54(4):420–32.

Composition of platelet-rich plasma gel: A Western blot analysis

Pablo Galindo Moreno,[a] Gustavo Avila Ortiz,[b] Laura Torrecillas Martinez,[a] Juan Emilio Fernández Barbero,[c] Francisco O'Valle[d] & Hom-Lay Wang[e]

[a] Oral Surgery and Implant Dentistry Department, School of Dentistry, University of Granada, Granada, Spain
[b] Department of Periodontics, College of Dentistry, University of Iowa, Iowa City, Iowa, U.S.
[c] Human Anatomy and Embryology Department, School of Medicine, University of Granada, Granada, Spain
[d] Pathology Department, School of Medicine, and Institute of Biopathology and Regenerative Medicine, University of Granada, Granada, Spain
[e] Department of Periodontics and Oral Medicine, School of Dentistry, University of Michigan, Ann Arbor, Mich., U.S.

Corresponding author:

Dr. Pablo Galindo Moreno

C/ Recogidas, 39 5º Izq
18005 Granada
Spain

T +34 958 52 0658
F +34 958 52 0658
pgalindo@ugr.es

How to cite this article:

Galindo Moreno P, Avila Ortiz G, Torrecillas Martinez L, Fernández Barbero JE, O'Valle F, Wang HL. Composition of platelet-rich plasma gel: a Western blot analysis.

J Oral Science Rehabilitation.
2016 Jun;2(2):42–8.

Abstract

Objective

Platelet-rich plasma (PRP) gel is an autogenous blood-derived material that may be used as a regenerative agent of oral structures. The regenerative capacity of PRP is largely attributed to its composition, including many different growth factors. Thus far, no study has identified the molecular content of this gel. Therefore, it was the purpose of this study to assess the presence of different growth factors in PRP gel, using the Western blot technique.

Materials and methods

Blood samples were collected from 20 healthy donors and then processed to obtain PRP gel samples. The Western blot technique was used to determine the presence of the following growth factors: vascular endothelial growth factor (VEGF), platelet-derived growth factor (PDGF), transforming growth factor-beta (TGF-β1), fibroblast growth factor (FGF), insulin-like growth factor-1 (IGF-1) and epidermal growth factor (EGF).

Results

Western blot analysis showed positive electrophoretic bands corresponding to molecular weights of the examined platelet growth factors. These bands were observed in every sample of PRP, demonstrating their presence as constituents of PRP gel.

Conclusion

Data from our study showed that PRP gel contains varying amounts of VEGF, TGF-β1, bFGF, PDGF-A, IGF-1 and EGF.

Keywords

Platelet-rich plasma, growth factors, tissue engineering, wound healing, Western blotting.

Introduction

Tissue integrity and blood vessel repair are essential after destructive and reconstructive events, such as surgery, trauma and regenerative procedures. The seeking for and identification of reliable and safe techniques or therapeutic methods that would predictably enhance the regenerative capacity in damaged tissue has become a major focus of current research. A large number of cells are involved in wound healing, including platelets, which play a crucial role in controlling coagulation and releasing growth factors and cytokines related to tissue regeneration. Platelet-derived products isolated from the patient's own blood have been extensively studied and tested because platelets are considered a source of cytokines and growth factors, which amplify wound healing and tissue repair.[1]

Platelet-rich plasma (PRP) offers much potential owing to its autogenous nature and a supposed molecular content. PRP was originally defined as a product with a high concentration of platelets, obtained from autologous blood, that contains different growth factors that may potentially influence cells involved in wound healing and bone regeneration.[2] Besides its adhesive and hemostatic properties, from a biological standpoint, the rationale for the use of PRP is rooted in the idea that regenerative advantages are obtained after the application of this product, given the modulating activity that is supposed to be exerted by molecules released from the α-granules, which are stored in the cytoplasm of platelets.[3, 4] A wide variety of molecules with different biological roles are known to be contained in the different platelet granules, such as serotonin, coagulation factors, proteoglycans, membrane-associated proteins and different types of proteases.[1, 5] However, some researchers believe that the activity of specific mitogenic/growth factors, concretely stored in the α-granules, is of major importance in regenerative events.[6, 7] Growth factors, including those that have been classically associated with PRP, are included in a family of polypeptides of low molecular weight with a very short life span. Growth factors can modulate cell behavior, alter gene expression of target cells and ultimately lead to promotion of cell migration, proliferation, differentiation and eventually maturation.[8] The growth factors that have been reported to be in PRP include vascular endothelial growth factor (VEGF), platelet-derived growth factor (PDGF), transforming growth factor-beta (TGF-β1), fibroblast growth factor (FGF), insulin-like growth factor-1 (IGF-1) and epidermal growth factor (EGF).[2, 6, 9]

When PRP was introduced in dentistry, most of the knowledge that justified its attributed regenerative potential came from experimental animal models[10, 11] and several human case reports.[12–15] Nowadays, clinical trials conducted to assess the clinical validity of PRP have shown controversial results, many of them advocating for no significant effect when PRP is used alone.[16–18] However, it has been reported that the addition of PRP to bone substitutes promotes enhancement of osseointegration of dental implants, optimizing the expansion of new bone cells, and improvement of the aggregation and cohesiveness of particulate-based bone substitutes.[19, 20] In order to understand how PRP works, it is important to know its structure and molecular composition.[21] It is important to know whether the described factors are present in an amount that can be easily detectable and in what proportion of the population. However, only limited evidence is currently available. Hence, it was the aim of this study to conduct a qualitative analysis to screen the molecular composition of PRP.

Materials and methods

Preparation of PRP

Venous blood was obtained from 20 healthy volunteers (16 males and four females; mean age of 27.4), who gave their informed consent and met the following inclusion criteria after a complete medical history recording and examination: no medication taken in the last two weeks, no dental or intra-oral surgical treatment within the last month, and no vaccine received and no infection history within the last three months. Briefly, 20 cm^3 of blood was drawn per patient and 5 cm^3 placed into each of four Vacutainer tubes (Becton Dickinson, Oxford, U.K.), which contained 0.1 cm^3 of 3.8% (w/v) sodium citrate. In order to minimize platelet activation during blood collection, a 19-gauge butterfly needle with a light tourniquet was used and the first 2 mL of blood was discarded. For the preparation of the PRP, a modification of the original procedure proposed by Anitua in 1999 was followed.[4] Immediately after collection, the tubes were placed in a centrifuge machine to spin at 1,500 rpm for 7 min

Fig. 1

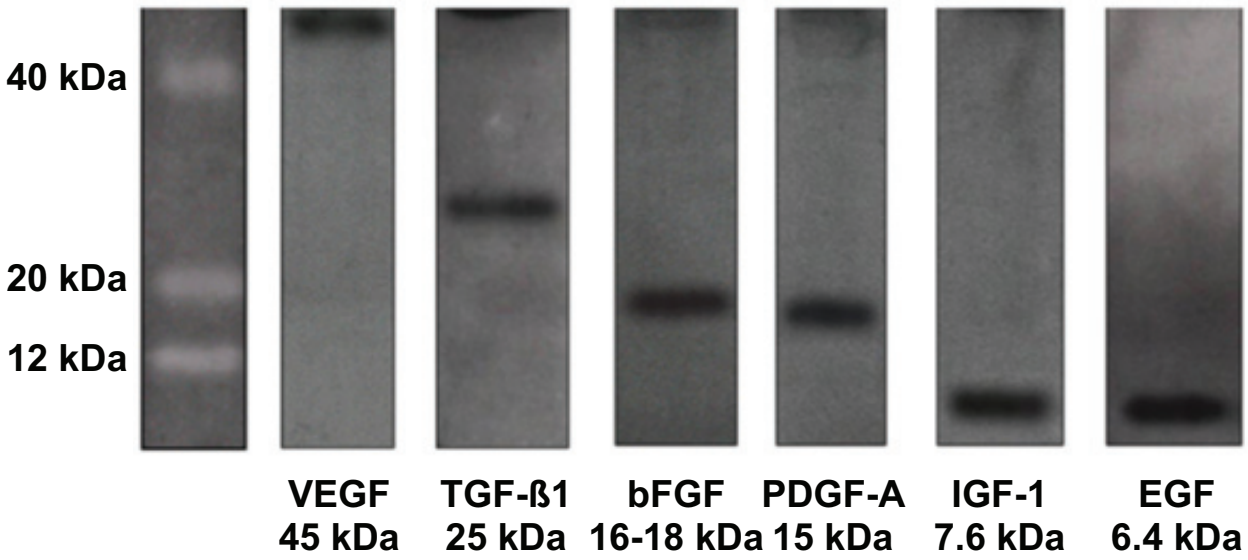

Fig. 1

Western blot analysis illustrated the expression of VEGF, TGF-β1, bFGF, PDGF-A, IGF-1 and EGF.

in order to separate the blood fractions. In order to produce PRP, 500 mL from the volume of plasma situated just over the top of the red fraction was collected from every sample. To each 500 mL of plasma, 250 mL of calcium chloride was added. Finally, the tubes were placed in a 37 °C warm water bath for 20 min to accelerate the formation of a PRP gel. The remaining contents of the tubes was discarded.

Monoclonal and polyclonal antibodies

The Western blot technique was performed using monoclonal antibodies for the selected platelet growth factors: anti-VEGF (C-1: sc-7269; Santa Cruz Biotechnology, Santa Cruz, Calif., U.S.), anti-PDGF-A (E-10; sc-9974; Santa Cruz Biotechnology), anti-human TGF-ß1 (Clone 9016.2; Sigma-Aldrich, St. Louis, Mo., U.S.), anti-human IGF-1 Goat (Sigma-Aldrich), anti-human bFGF (Clone FB-8; Sigma-Aldrich) and anti-human EGF (Clone EGF-10; Sigma-Aldrich). Fluorochrome-marked polyclonal immunoglobulin-G antibodies able to bind the previously mentioned antibodies were purchased from Santa Cruz Biotechnology to be used as secondary antibodies.

Western blot technique

Gels for electrophoresis (12% SDS-PAGE) were initially prepared for each experiment. Final samples consisting of a volume of 15 mL of PRP clot, previously diluted in a sample buffer (at a proportion of 1 mg/mL), were properly identified and placed on each well of the electrophoresis gels. The proteins were electrophoretically run at a rate of 60 V and 45 mA for 2 h, using the PowerPac HC electrophoresis kit (Bio-Rad, Laboratories, Hercules, Calif., U.S.). Transference of the proteins located in the running gel was performed using a Trans-Blot SD device (Bio-Rad), at 25 V/60 mA for 50 min. Once the transference to nitrocellulose membranes, designed for protein transference, had been completed, specimens were submerged in 20 mL of blocking suspension (5 mg of fat-free powder milk diluted in 100 mL of 1 × TBS) for 60 min, at room temperature. After that, the membranes were incubated with the mentioned specific monoclonal antibodies for different growth factors in agitation, for 24 h at 4 °C. Three 5 min washes using a washing solution (0.5 mL of 0.1% TWEEN 20 in 500 mL of 1 × TBS) were performed prior to the incubation of the membranes with the secondary antibodies,

Table 1

Donor	VEGF 45 kDa	TGF-β1 25 kDa	bFGF 16–18 kDa	PDGF-A 15 kDa	IGF-1 7.6 kDa	EGF 6.4 kDa
JF	+	+	+	+	+	+
PG	+	+	+	+	+	+
OC	+	+	+	+	+	+
SR	+	+	+	+	+	+
JL	+	+	+	+	+	+
GA	+	+	+	+	+	+
VR	+	+	+	+	+	+
GG	+	+	+	+	+	+
MF	+	+	+	+	+	+
EM	+	+	+	+	+	+
EF	+	+	+	+	+	+
FG	+	+	+	+	+	+
IM	+	+	+	+	+	+
JS	+	+	+	+	+	+
DG	+	+	+	+	+	+
AA	+	+	+	+	+	+
RG	+	+	+	+	+	+
CF	+	+	+	+	+	+
LG	+	+	+	+	+	+
LF	+	+	+	+	+	+

Table 1

Expression of VEGF, TGF-β1, bFGF, PDGF-A, IGF-1 and EGF in the different PRP gel samples obtained from donors, after Western blotting.

for 2 h at room temperature. Finally, the membranes received three 5 min washes (0.5 mL of 0.1% TWEEN 20 in 500 mL of 1 × TBS), and they were developed and scanned. Bands for each sample were assessed and assigned to three levels of intensity: band not visible (–); band visible but not solid (+/–); and solid positive band (+).

Results

In this qualitative analysis, all growth factors under study (VEGF, PDGF-A, TGF-β1, bFGF, IGF-1 and EGF) were present in all of the patients **(Table 1)**. The bands observed as positive after developing the membrane were located at the presumed molecular weight for each of the factors: VEGF at 45 kDa, TGF-β1 at 25 kDa, bFGF at 17 kDa, PDGF-A at 15 kDa, IGF-1 at 7.6 kDa and EGF at 6.4 kDa **(Fig. 1)**.

Discussion

PRP has been suggested to be a novel agent that could promote not only hard-tissue regeneration[3] but also soft-tissue healing.[22] Although controversy exists regarding its ability to promote regeneration, especially in hard tissue,[17, 23, 24] many clinicians remain loyal to its clinical usage. In order to enhance understanding of PRP, our research group has focused on analyzing the structure and composition of PRP gel using flow cytometry and the scanning electron microscope.[25] Our results have shown PRP's microstructural composition, essentially constituted by fibrin in relation to the different cellular elements in the clot, identified as largely platelets in different stages of activation.

Following the line traced by those previous findings, our group has designed a further *in vitro* study to determine the presence of different

growth factors known to be present in the α-granules of the platelets in PRP gel samples.[26] Results obtained from the present study indicate that PRP gel contains the six tested growth factors: VEGF, PDGF, TGF-β1, FGF, IGF-1 and EGF. These growth factors have been known for their influence at different stages of the healing processes.[8, 19] Basically, growth factors are low-weighted molecules produced and released by many different cell types under variable stimuli and play a determinant role in the development and maturation of different tissues in mammals. For instance, VEGF is an important regulator of angiogenic processes, increasing vessel permeability and contributing essentially to neoangiogenesis. Its presence in the clot of PRP can partially justify the positive outcomes obtained in some studies regarding the beneficial effect of PRP on capillary growth in soft-tissue wound healing.[27] Several *in vitro* and animal studies have illustrated the modulating effect that growth factors exert on different cell types. PDGF is primarily responsible for tissue healing and has been shown to induce proliferation of gingival fibroblasts and osteoblasts[28] and adherence of periodontal ligament cells to root surfaces.[29] TGF-β1 is essential for normal tissue remodeling and wound healing; it is chemotactic for human fibroblasts,[30] enhances the proliferation and differentiation of osteoblasts,[31–33] and intervenes in angiogenesis and immunomodulation.[34] BFGF induces stimulation of periodontal ligament cell proliferation, osteoblastic cell proliferation and growth and fibroblasts, and plays a role in angiogenesis.[35–37] IGF-1, also known as somatomedin, is a mediator in the activity of growth hormone[38] and a positive regulator of cell proliferation and differentiation for most cell types.[39] EGF enhances the proliferation of keratinocytes[40] and is implicated in epithelialization, wound contraction and remodeling.[41]

Thus far, the majority of studies reporting detection of one or some of the previously mentioned growth factors in PRP samples have been conducted on nonclotted samples, without any platelet activator added.[3, 42–45] In our opinion, direct analysis of the presence of growth factors in PRP gel would provide a more accurate idea regarding which are the bioactive constituents of PRP gel.

El-Sharkawy et al. performed a similar study based on a different technique, enzyme-linked immunosorbent assay (ELISA), and the same growth factor content of PRP was found.[9] They quantified platelet and growth factor levels. PDGF, TGF-β1, IGF-1, EGF, VEGF and bFGF were also identified in their PRP samples. They attributed the biological properties of these growth factors, such as proliferation of fibroblasts and periodontal ligament cells and extracellular matrix formation, to PRP. Lu et al. also used the same technique, ELISA, and they identified and quantified PRP growth factors released (PDGF, TGF-β1 and IGF-1), obtaining similar results, although no search for EGF, VEGF or bFGF was conducted.[2]

Despite the contribution of our findings to the understanding of PRP biology, they also raise more questions that need to be addressed. The identification of these growth factors in PRP gel only suggests their presence in the clot, without providing evidence supporting its biological benefit after its clinical usage, especially for regenerative approaches. Growth factors are proteins that, once released from the producer cell, exert a very localized action at specific ratios,[46] owing to their short life span. They are labile molecules highly susceptible to denaturalization mediated by proteases present in the wound site and to phagocytosis and might even become solubilized in the carrier.[47] These undesirable events usually lead to the inactivation or annulment of the biological properties of these mediators. For instance, PDGF cannot be detected in circulating blood in normal conditions, and when it is intravenously injected, its life span is around 2 min.[48] This lack of long-term activity associated with the short half-life of this platelet growth factor may require repeated applications over time to maintain their therapeutic effect.

Both the vehicle and concentration (dose) of biological mediators, such as platelet growth factors, may be critical factors to consider when seeking to achieve controlled modulation of cellular events in the desired time interval.[49] However, it has to be taken into consideration that there is no currently available information about the optimal dosages of PRP needed to achieve the highest effectiveness.[1]

It is also important to note that the technique used in this study for the detection of growth factors, Western blotting, allows detection of the presence of a determined protein in a sample by highly specific binding of antibodies to epitopes of that polypeptide. However, it is not possible to ultimately determine whether the target protein is biologically active and therefore able to exert its effect when applied to a wound. This fact, along with the arguments discussed before,

moves us to reason that the beneficial effects obtained after application of autologous PRP gel may not be mediated only by the action of growth factors.

Considering this data, it is logical to outline several questions and doubts regarding the variable amount of growth factors, presenting a true ability to interact with the environment, that may be released from the PRP gel sample that is clinically applied. Are those growth factors the exclusive or major mediators responsible for a change in the biological conditions that lead to an improvement in tissue regeneration? Does the fibrillar component of the clot have a role in modulating the biological response that permits a better clinical response? Or, is it a synergistic effect between the fibrillar scaffold and different molecular components of blood plasma, among which growth factors are present, that induces those beneficial effects?

Understanding the role of each component of PRP gel in wound-healing events and the optimal concentration of molecules with the capacity of modulating these processes remains one of the major challenges for researchers in this field of tissue engineering. In order to address those questions, further *in vitro* and *in vivo* studies seeking to determine the physical interaction of PRP elements with cell types present in the craniofacial surgical field and its impact on cell proliferation and differentiation are needed.

Competing interests

The authors do not have any financial interests, either directly or indirectly, in the products listed in the study.

Acknowledgments

This article was supported partially by Research Group #CTS-583 (Junta de Andalucía, Spain).

References

1.
De Pascale MR, Sommese L, Casamassimi A, Napoli C. Platelet derivatives in regenerative medicine: an update.
→ Transfus Med Rev.
2015 Jan;29(1):52–61.

2.
Lu HH, Vo JM, Chin HS, Lin J, Cozin M, Tsay R, Eisig S, Landesberg R. Controlled delivery of platelet-rich plasma-derived growth factors for bone formation.
→ J Biomed Mater Res A.
2008 Sep;86(4):1128–36.

3.
Marx RE, Carlson ER, Eichstaedt RM, Schimmele SR, Strauss JE, Georgeff KR. Platelet-rich plasma: growth factor enhancement for bone grafts.
→ Oral Surg Oral Med Oral Pathol Oral Radiol Endod.
1998 Jun;85(6):638–46.

4.
Anitua E. Plasma rich in growth factors: preliminary results of use in the preparation of future sites for implants.
→ Int J Oral Maxillofac Implants.
1999 Jul-Aug;14(4):529–35.

5.
Anitua E, Andia I, Ardanza B, Nurden P, Nurden AT. Autologous platelets as a source of proteins for healing and tissue regeneration.
→ Thromb Haemost.
2004 Jan;91(1):4–15.

6.
Marx RE. Platelet-rich plasma: evidence to support its use.
→ J Oral Maxillofac Surg.
2004 Apr;62(4):489–96.

7.
Dohan DM, Choukroun J, Diss A, Dohan SL, Dohan AJ, Mouhyi J, Gogly B. Platelet-rich fibrin (PRF): a second-generation platelet concentrate. Part II: platelet-related biologic features.
→ Oral Surg Oral Med Oral Pathol Oral Radiol Endod.
2006 Mar;101(3):e45–50.

8.
Xie X, Zhang C, Tuan RS. Biology of platelet-rich plasma and its clinical application in cartilage repair.
→ Arthritis Res Ther.
2014 Feb;16(1):204.

9.
El-Sharkawy H, Kantarci A, Deady J, Hasturk H, Liu H, Alshahat M, Van Dyke TE. Platelet-rich plasma: growth factors and pro- and anti-inflammatory properties.
→ J Periodontol.
2007 Apr;78(4):661–9.

10.
Kim ES, Park EJ, Choung PH. Platelet concentration and its effect on bone formation in calvarial defects: an experimental study in rabbits.
→ J Prosthet Dent.
2001 Oct;86(4):428–33.

11.
Kim SG, Kim WK, Park JC, Kim HJ. A comparative study of osseointegration of Avana implants in a demineralized freeze-dried bone alone or with platelet-rich plasma.
→ J Oral Maxillofac Surg.
2002 Sep;60(9):1018–25.

12.
Shanaman R, Filstein MR, Danesh-Meyer MJ. Localized ridge augmentation using GBR and platelet-rich plasma: case reports.
→ Int J Periodontics Restorative Dent.
2001 Aug;21(4):345–55.

13.
Petrungaro PS. Treatment of the infected implant site using platelet-rich plasma.
→ Compend Contin Educ Dent.
2002 Apr;23(4):363–6, 368, 370 passim; quiz 378.

14.
Froum SJ, Wallace SS, Tarnow DP, Cho SC. Effect of platelet-rich plasma on bone growth and osseointegration in human maxillary sinus grafts: three bilateral case reports.
→ Int J Periodontics Restorative Dent.
2002 Feb;22(1):45–53.

15.
Thor A. Reconstruction of the anterior maxilla with platelet gel, autogenous bone, and titanium mesh: a case report.
→ Clin Implant Dent Relat Res.
2002 Oct;4(3):150–5.

16.
Powell CA, Bannister SR, Mackey SA, Maller SC, McDonnell HT, Deas DE. Periodontal wound healing with and without platelet-rich plasma: histologic observations and assessment of flap tensile strength.
→ J Periodontol.
2009 Jun;80(6):985–92.

17.
Farina R, Bressan E, Taut A, Cucchi A, Trombelli L. Plasma rich in growth factors in human extraction sockets: a radiographic and histomorphometric study on early bone deposition.
→ Clin Oral Implants Res.
2013 Dec;24(12):1360–8.

18.
Bezgin T, Yilmaz AD, Celik BN, Kolsuz ME, Sonmez H. Efficacy of platelet-rich plasma as a scaffold in regenerative endodontic treatment.
→ J Endod.
2015 Jan;41(1):36–44.

19.
Plachokova AS, Nikolidakis D, Mulder J, Jansen JA, Creugers NH. Effect of platelet-rich plasma on bone regeneration in dentistry: a systematic review.
→ Clin Oral Implants Res.
2008 Jun;19(6):539–45.

20.
Forni F, Marzagalli M, Tesei P, Grassi A. Platelet gel: applications in dental regenerative surgery.
→ Blood Transfus.
2013 Jan;11(1):102–7.

21.
Pietrzak WS, Eppley BL. Platelet rich plasma: biology and new technology.
→ J Craniofac Surg.
2005 Nov;16(6):1043–54.

22.
Man D, Plosker H, Winland-Brown JE. The use of autologous platelet-rich plasma (platelet gel) and autologous platelet-poor plasma (fibrin glue) in cosmetic surgery.
→ Plast Reconstr Surg.
2001 Jan;107(1):229–37; discussion 238–9.

23.
Thor A, Wannfors K, Sennerby L, Rasmusson L. Reconstruction of the severely resorbed maxilla with autogenous bone, platelet-rich plasma, and implants: 1-year results of a controlled prospective 5-year study.
→ Clin Implant Dent Relat Res.
2005 Oct;7(4):209–20.

24.
Raghoebar GM, Schortinghuis J, Liem RS, Ruben JL, Van Der Wal JE, Vissink A. Does platelet-rich plasma promote remodeling of autologous bone grafts used for augmentation of the maxillary sinus floor?
→ Clin Oral Implants Res.
2005 Jun;16(3):349–56.

25.
Fernández-Barbero JE, Galindo-Moreno P, Avila-Ortiz G, Caba O, Sánchez-Fernández E, Wang HL. Flow cytometric and morphological characterization of platelet-rich plasma gel.
→ Clin Oral Implants Res.
2006 Dec;17(6):687–93.

26.
Rendu F, Brohard-Bohn B. The platelet release reaction: granules' constituents, secretion and functions.
→ Platelets.
2001 Aug;12(5):261–73.

27.
Lindeboom JA, Mathura KR, Aartman IH, Kroon FH, Milstein DM, Ince C. Influence of the application of platelet-enriched plasma in oral mucosal wound healing.
→ Clin Oral Implants Res.
2007 Feb;18(1):133–9.

28.
Zhang L, Leeman E, Carnes DC, Graves DT. Human osteoblasts synthesize and respond to platelet-derived growth factor.
→ Am J Physiol.
1991 Aug;261(2):C348–54.

29.
Gamal AY, Mailhot JM. The effect of local delivery of PDGF-BB on attachment of human periodontal ligament fibroblasts to periodontitis-affected root surfaces—in vitro.
→ J Clin Periodontol.
2000 May;27(5):347–53.

30.
Postlethwaite AE, Keski-Oja J, Moses HL, Kang AH. Stimulation of the chemotactic migration of human fibroblasts by transforming growth factor β.
→ J Exp Med.
1987 Jan;165(1):251–6.

31.
Centrella M, McCarthy TL, Canalis E. Transforming growth factor β is a bifunctional regulator of replication and collagen synthesis in osteoblast-enriched cell cultures from fetal rat bone.
→ J Biol Chem.
1987 Feb;262(6):2869–74.

32.
Mundy GR, Boyce B, Hughes D, Wright K, Bonewald L, Dallas S, Harris S, Ghosh-Choudhury N, Chen D, Dunstan C, Izbicka E, Yoneda T. The effects of cytokines and growth factors on osteoblastic cells.
→ Bone.
1995 Aug;17(2 Suppl):S71–75.

33.
Graham S, Leonidou A, Lester M, Heliotis M, Mantalaris A, Tsiridis E. Investigating the role of PDGF as a potential drug therapy in bone formation and fracture healing.
→ Expert Opin Investig Drugs.
2009 Nov;18(11):1633–54.

34.
Ghosh D, Lili L, McGrail DJ, Matyunina LV, McDonald JF, Dawson MR. Integral role of platelet-derived growth factor in mediating transforming growth factor-β1-dependent mesenchymal stem cell stiffening.
→ Stem Cells Dev.
2014 Feb;23(3):245–61.

35.
Sonmez AB, Castelnuovo J. Applications of basic fibroblastic growth factor (FGF-2, bFGF) in dentistry.
→ Dent Traumatol.
2014 Apr;30(2):107–11.

36.
Terranova VP, Odziemiec C, Tweden KS, Spadone DP. Repopulation of dentin surfaces by periodontal ligament cells and endothelial cells: effect of basic fibroblast growth factor.
→ J Periodontol.
1989 Jun;60(6):293–301.

37.
Cross MJ, Claesson-Welsh L. FGF and VEGF function in angiogenesis: signalling pathways, biological responses and therapeutic inhibition.
→ Trends Pharmacol Sci.
2001 Apr;22(4):201–7.

38.
Laron Z. Clinical use of somatomedin-1: yes or no?
→ Paediatr Drugs.
1999 Jul-Sep;1(3):155–9.

39.
Ren J, Anversa P. The insulin-like growth factor I system: physiological and pathophysiological implication in cardiovascular diseases associated with metabolic syndrome.
→ Biochem Pharmacol.
2015 Feb;93(4):409–17.

40.
Brown GL, Nanney LB, Griffen J, Cramer AB, Yancey JM, Curtsinger LJ 3rd, Holtzin L, Schultz GS, Jurkiewicz MJ, Lynch JB. Enhancement of wound healing by topical treatment with epidermal growth factor.
→ N Engl J Med.
1989 Jul;321(2):76–9.

41.
Brown GL, Curtsinger LJ, White M, Mitchell RO, Pietsch J, Nordquist R, von Fraunhofer A, Schultz GS. Acceleration of tensile strength of incisions treated with EGF and TGF-β.
→ Ann Surg.
1988 Dec;208(6):788–94.

42.
Zimmermann R, Jakubietz R, Jakubietz M, Strasser E, Schlegel A, Wiltfang J, Eckstein R. Different preparation methods to obtain platelet components as a source of growth factors for local application.
→ Transfusion.
2001 Oct;41(10):1217–24.

43.
Weibric G, Buch RS, Kleis WK, Hafner G, Hitzler WE, Wagner W. Quantification of thrombocyte growth factors in platelet concentrates produced by discontinuous cell separation.
→ Growth Factors.
2002 Jun;20(2):93–7.

44.
Weibrich G, Kleis WK, Buch R, Hitzler WE, Hafner G. The Harvest Smart PReP™ system versus the Friadent-Schütze platelet-rich plasma kit.
→ Clin Oral Implants Res.
2003 Apr;14(2):233–9.

45.
Eppley BL, Woodell JE, Higgins J. Platelet quantification and growth factor analysis from platelet-rich plasma: implications for wound healing.
→ Plast Reconstr Surg.
2004 Nov;114(6):1502–8.

46.
Vilček J. The cytokines: an overview. In: Thomson AW, Lotze MT, editors.
→ The cytokine handbook. Vol. 1. Avon (MA): Academic Press;
2003. p. 3–18.

47.
Giannobile WV. Periodontal tissue engineering by growth factors.
→ Bone.
1996 Jul;19(1 Suppl):S23–37.

48.
Nimni ME. Polypeptide growth factors: targeted delivery systems.
→ Biomaterials.
1997 Sep;18(18):1201–25.

49.
Hokugo A, Ozeki M, Kawakami O, Sugimoto K, Mushimoto K, Morita S, Tabata Y. Augmented bone regeneration activity of platelet-rich plasma by biodegradable gelatin hydrogel.
→ Tissue Eng.
2005 Jul-Aug;11(7-8):1224–33.

PRESENT ▲ NETWORK ▲ ADVANCE

Make plans to attend and present your research at the 94th General Session & Exhibition of the International Association for Dental Research, held in conjunction with the 3rd Meeting of the IADR Asia Pacific Region and the 35th Annual Meeting of the IADR Korean Division. This will be an exciting opportunity to network with other delegates while exploring cutting-edge scientific discoveries!

Following are the confirmed Distinguished Lecture Series Speakers:

Eunjoon Kim
Center for Synaptic Brain Dysfunctions, Institute for Basic Science and
The Department of Biological Sciences, Korea Advanced Institute of Science and Technology (KAIST)
Daejeon, Republic of Korea

Pekka Puska
Former Director General, National Institute for Health and Welfare
Helsinki, Finland

Important Dates:

Oct. 26, 2015:	Deadline to submit proposals.
Jan. 19, 2016:	Deadline to submit abstracts.
Apr. 20, 2016:	Presenter pre-registration deadline.
May 18, 2016:	Non-presenter pre-registration deadline.

Continue to visit the IADR website for more information as it becomes available.
We look forward to seeing you in Seoul!

www.iadr.org/iags

Spontaneous bone regeneration after removal of cysts: One-year follow-up of 336 consecutive cases

Marco Di Dio,[a] Dario Scarapecchia,[b] Daniela Porcelli[c] & Claudio Arcuri[d]

[a] Department of Oral Surgery, San Giovanni Calibita Fatebenefratelli Hospital, Rome, Italy
[b] Private practice, Rome, Italy
[c] Department of Odontostomatology, San Giovanni Calibita Fatebenefratelli Hospital, Rome, Italy; University of Rome Tor Vergata, Rome, Italy
[d] Department of Odontostomatology, San Giovanni Calibita Fatebenefratelli Hospital, Rome, Italy; University of Rome Tor Vergata, Rome, Italy

Corresponding author:

Dr. Daniela Porcelli
Department of Oral Surgery
San Giovanni Calibita Fatebenefratelli Hospital
Rome
Italy

T +39 348 162 2588
porcellidaniela@libero.it

How to cite this article:

Di Dio M, Scarapecchia D, Porcelli D, Arcuri C. Spontaneous bone regeneration after removal of cysts: one-year follow-up of 336 consecutive cases.

J Oral Science Rehabilitation. 2016 Jun;2(2):50–6.

Abstract

Objective

The objective of this study was to assess spontaneous bone healing after enucleation of large jaw cysts without using any grafting material.

Materials and methods

The study was conducted at the Department of Oral Surgery of the San Giovanni Calibita Fatebenefratelli Hospital, Rome, Italy. Between January 2000 and July 2012, 336 consecutive patients with large jaw cysts (average size of 1.50 ± 0.80 × 1.06 ± 0.50 cm) were treated by a Partch II surgical enucleation. Postoperative clinical and radiographic examinations were performed at ten and 30 days, respectively, and then at six and 12 months on the basis of panoramic radiographs, using the Kawai et al. classification.

Results

Healing and radiographic spontaneous bone regeneration of the residual cavities were obtained in all of the cases. Radiographic controls after cystic enucleation showed no evidence of recurrence.

Conclusion

The study demonstrated that spontaneous bone regeneration can be obtained after enucleation of large jaw cysts without using filling material, thereby decreasing the financial and biological costs and reducing the risk of postoperative complications.

Keywords

Odontogenic cysts, enucleation, oral surgery, spontaneous bone regeneration.

Introduction

The gold standard for the treatment of most jaw cysts is enucleation of the lesions. The cavity remaining after enucleation may heal spontaneously by the physiological appositional mechanism of bone growth. However, in larger bony defects, the use of bone grafting materials is still controversial.[1–13] Many studies have concluded that bone grafts should be used to reduce the risk of jaw weakness.[14–18] Some researchers have supported that the remaining cystic cavities should be filled with biointegrative materials to prepare the site for implant placement.[19] However, other authors have reported that spontaneous bone healing occurred without the use of bone grafts.[20] According to this last study, bone density can increase by 48% after 12 months and by 91% after 24 months, as seen after marsupialization of large jaw cysts. The success of spontaneous regeneration should be directly related to the size of the bony defect, anatomical features, patient's age and other parameters, such as monocortical or bicortical defect type.[19]

The objective of this retrospective clinical study was to evaluate spontaneous bone regeneration after enucleation of large jaw cysts, achieved with a conservative surgical technique, without using any filling material.

Materials and methods

This study was conducted at the Department of Oral Surgery of the San Giovanni Calibita, Fatebenefratelli Hospital, Rome, Italy, from January 2000 to July 2012. All consecutive patients requiring a Partch II surgical intervention for cyst removal were enrolled. Each patient was completely informed about the possible risks of the intervention and the surgical procedure.

Preoperative analysis

Panoramic radiographs were obtained for all of the patients subjected to surgical enucleation **(Fig. 1)**. The dimensions of the cysts were evaluated on panoramic radiographs taken just before surgical treatment. A preoperative computed tomography (CT) scan was required only in cases of very large jaw cysts with erosion of cortical plates, in order to evaluate more precisely the extent of the lesions **(Fig. 2)**.

Surgical protocol

The surgery was conducted by one surgeon (MDD) in a single session for each patient, with standardized techniques. All of the patients received antibiotics before surgery. Local antimicrobial treatment was performed with 0.12% chlorhexidine digluconate mouth rinses t.i.d. for two weeks, starting three days before surgery, interrupted only on the first postoperative day. The majority of the surgeries (93.5%) were performed under local anesthesia with 2% mepivacaine. Only 22 (6.5%) surgical procedures were conducted under general anesthesia (in cases of cysts entering into the nasal cavity), depending on the general conditions, compliance, local and anatomical characteristics (such as the lesion extent), the site accessibility and the expected duration of the surgery. When the cysts were placed into the anterior region of the mandible, bilateral local anesthesia at Spix's spine with 2% mepivacaine and infiltrative anesthesia with 2% mepivacaine and 1:100,000 epinephrine was administered. After the elevation of a full-thickness flap of adequate dimensions, with two lateral releasing incisions on the vestibular aspect (to preserve the lingual nerve in the mandible; **Figs. 3 & 4**), conservative access to the lesion was obtained using a round bur in a low-speed handpiece under irrigation with sterile saline **(Fig. 5)**. In all of the cases, there was very little bone debris, owing to the minimally invasive surgical approach. Particular care was taken to preserve the maximum amount of bone in order to allow postoperative regeneration of the defect and to provide adequate support to the soft tissue during the healing period (bone bridging). Whenever possible, the cysts were enucleated in one piece with minimal invasion. The remaining cyst cavity was curetted to remove all residual fragments and to reduce the risk of recurrence **(Fig. 6)**. The hopeless teeth were either extracted or endodontically treated, followed by apicectomy. In all of the cases, after the careful cleaning of the residual cavity, a primary closure was performed with a nonresorbable thread and interrupted sutures. No grafting material was placed into the residual bone sites. In all of the cases, a histological examination was performed, after fixation in a 4% formalin solution **(Fig. 7)**.

The patients were advised to refrain from drinking and eating for 2 h after the surgical procedure and to then eat only cold and soft food for 24 h. After ten days, upon removal of the sutures, the wound was examined and controlled.

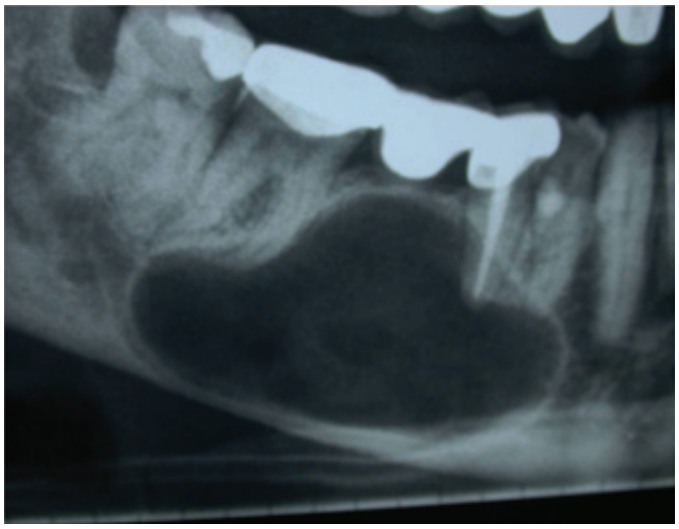



Figs. 1 & 2

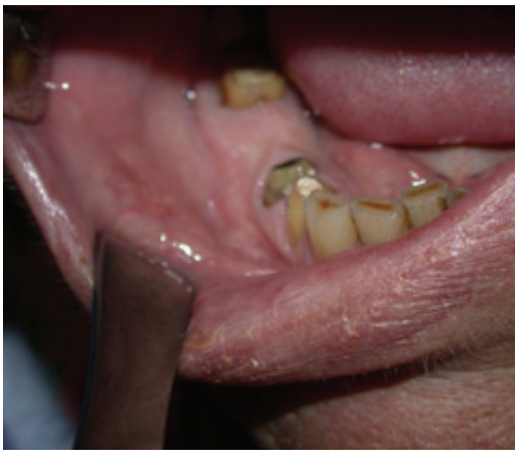

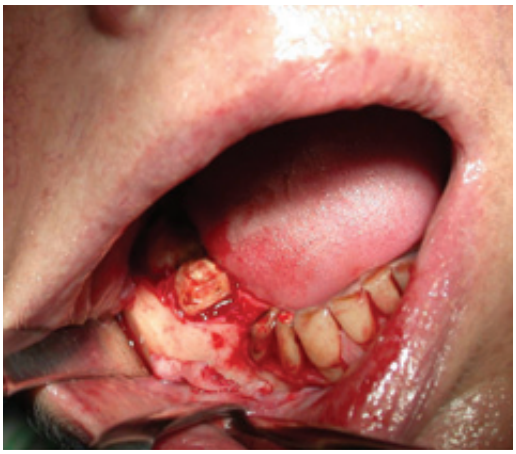

Figs. 3 & 4

Fig. 1

Preoperative radiographic view (2005).

Fig. 2

Preoperative CT scan view (2005).

Fig. 3

Preoperative clinical view.

Fig. 4

The surgery was performed under local anesthesia to obtain a larger working area.

All of the patients were followed for possible complications, including hemorrhagic complications, swelling, hematoma and ecchymosis. Follow-ups entailed both clinical and radiographic evaluations in order to assess the reduction in size of the residual cavities. Clinical controls were performed ten days after surgery and radiographic assessment after 30 days and at six and 12 months postoperatively. The radiographic examinations, performed in order to evaluate the bone regeneration rate, entailed preoperative and postoperative panoramic radiographs and, in some cases, CT scans **(Figs. 8 & 9)**. A CT dental scan was required in order to evaluate more precisely the rate of bone healing in the buccolingual dimension, using axial slices, if necessary. The findings from the panoramic radiographs were analyzed both subjectively and using the Kawai et al. radiographic classification, which evaluates the variation of the surgical site margins and the interior contents of the sites based on radiographs.[21]

Results

The sample included 336 patients, 200 males (59.5%) and 136 females (40.5%) ranging from 10 to 83 years of age (mean age and standard deviation of 43.4 ± 16.8), as demonstrated in **Table 1**. No patients were lost during follow-up. The majority (68.8%) of the patients had mandibular cysts and the remainder of the sample (31.3%) had maxillary lesions.

Surgical and radiographic data

The mean dimensions of the bony defects were 1.50 ± 0.80 × 1.06 ± 0.50 cm. Primary closure was obtained in all of the cases. Minor complications (swelling, hematoma and ecchymosis were present in 85% of the cases) were reported during the first week. At the second recall, these minor complications were no longer present. No hemorrhagic complications occurred. An inferior alveolar nerve paresthesia and a compound fracture both occurred in only one patient (0.3%).

Figs. 5 & 6

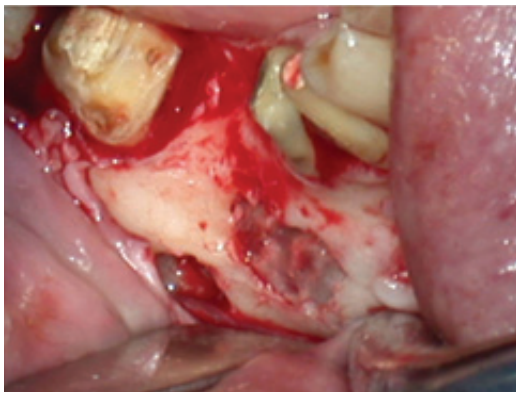

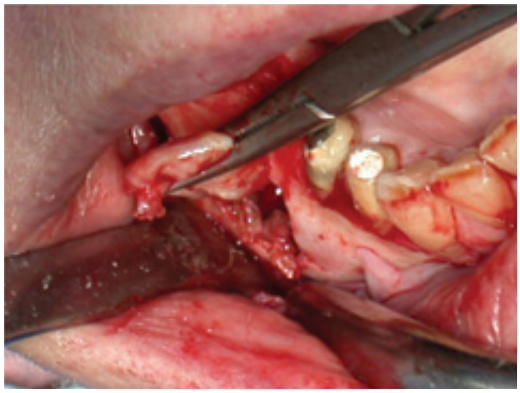

Fig. 7

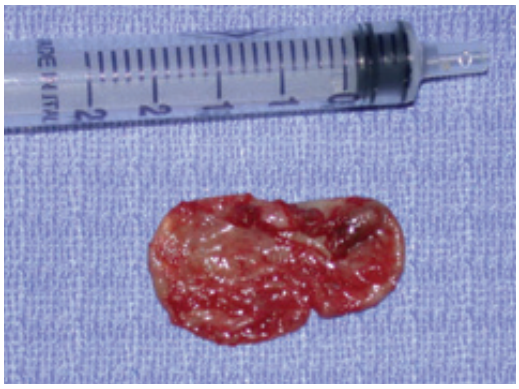

Figs. 8 & 9

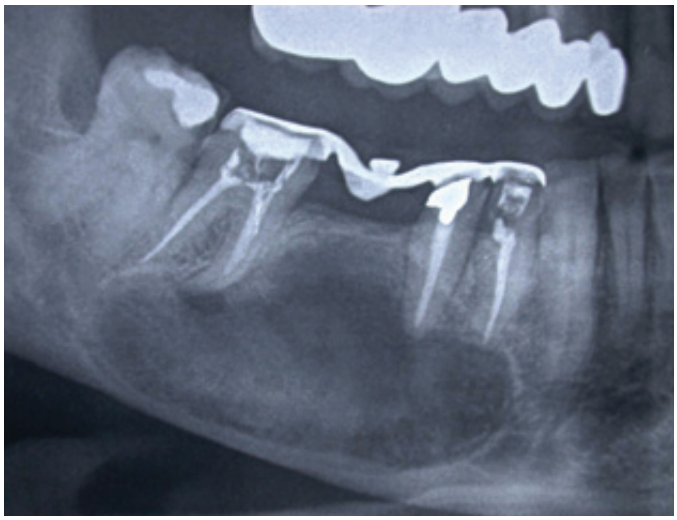

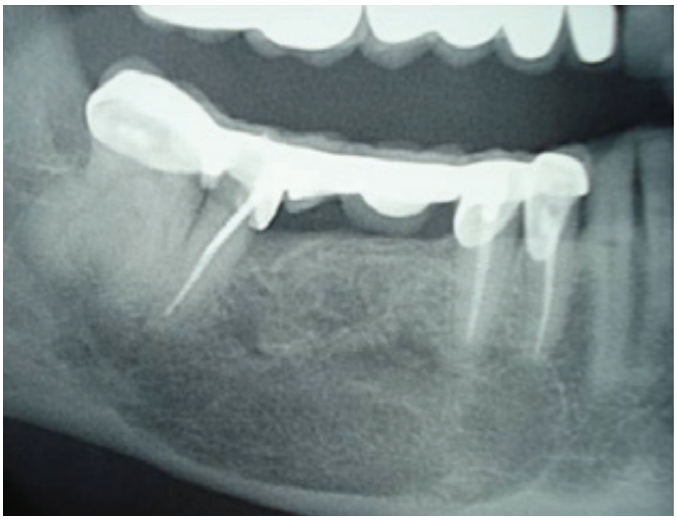

Fig. 5

An intra-oral view.

Fig. 6

An intra-oral view during the cyst enucleation.

Fig. 7

The cystic specimen.

Fig. 8

Postoperative radiographic view (six months after surgery).

Fig. 9

Postoperative radiographic view (one year after surgery).

The patient with the mandibular fracture was treated with analgesics and a soft diet under close observation. No surgical intervention to reduce and stabilize the fracture was carried out. At six months postoperatively, the affected patient experienced a spontaneous full recovery of the inferior alveolar nerve paresthesia.

Clinical and radiographic evaluation performed 12 months after the surgical procedure showed complete healing of the lesions in all of the cases, with no sign of inflammation, infection or recurrence. On the basis of Kawai et al.'s criteria[21] and of the postoperative radiographic and clinical controls, all of these areas were considered healthy and showed complete bone recovery. The postoperative CT scans performed on patients with very large mandibular cysts showed complete bone regeneration and reconstitution of almost normal anatomy of the previously affected jaw segment 12 months after surgery. There were also gradual increases in bone density in both mandibular and maxillary defects. In all of the cases, the clinical healing patterns were similar.

Histological data

According to the World Health Organization classification, most of the cysts were odontogenic cysts of inflammatory origin, followed by odontogenic cysts of unspecified nature; radicular cysts (also termed periapical cysts); cystic lesions of odontogenic developmental dentigerous (or follicular) nature, unilocular and/or multilocular; unspecified granulation tissue; odontomas; periapical granulomas; ameloblastomas; keratocysts; nonodontogenic nasopalatine duct cysts; inflammatory residual cysts; and lesions due to other diseases, such as odontogenic fibromas, nonepithelial, traumatic and hemorrhagic cysts, sinus polyposis, epulis, fibrous bone dysplasia and oral melanosis. The diagnoses are reported in **Table 2**.

Discussion

Bone reconstruction has been considered an essential requirement for complete functional rehabilitation after jaw surgery. Although many studies have supported the use of different bone grafts to reduce the risk of jaw weakness,[14–17] the present study showed that spontaneous bone regeneration occurred in all of the residual bony defects without the use of any filling material. The physiological healing process occurred with spontaneous bone regeneration even in the presence of large residual cystic cavities. The present study suggested that this type of intervention was very safe and minimally invasive, despite the increased surgical duration and technical complexity, with a complete recovery of the area occupied by jaw cysts. The bone recovery could be demonstrated with absolute accuracy only on CT scan controls, comparing on a digitalized image the preoperative and postoperative bone density. However, the main limitation of the present study was the short follow-up period. In fact, in order to confirm data from the present study, a longitudinal control (five years after surgery) would be recommended.

However, in most cases, patients with cysts in edentulous areas underwent a CT scan evaluation for the following implant-supported prosthetic rehabilitation.[22] Morphometric analysis, similarly to Chiapasco et al.,[14] was not performed because implant stability and survival clinically demonstrated that bone was of a good quality. These results corroborate those of Pradel et al., who concluded that the bone density increased after enucleation of large mandibular cysts without using filling material.[20] Similar results were obtained by Chiapasco et al.[14]

The differential diagnosis between odontogenic cysts and ameloblastomas could be attained by analyzing the postoperative recurrence in the short term. Differences such as root resorption of adjacent teeth may aid the clinician in the preoperative differential diagnosis. In a radiographic preoperative analysis, ameloblastomas proved to have a root resorptive potential far greater than did other cystic lesions. No recurrence was noted during the entire follow-up period of the study, although the incidence was about 3%. However, ongoing follow-up examination is required and essential for management.

Conclusion

Within the limitations of this study, some observations in agreement with current literature can be made. Spontaneous bone regeneration with bone bridging outside the residual cyst cavity can occur after surgical removal of large jaw cysts without the aid of any grafting materials, according to evidence-based clinical and radiographic criteria. There was also a reduction of the risks of paresthesia and fracture in the mandible, owing to the conservative approach. This will simplify the surgical procedure, decreasing financial and biological costs and reducing the risk of postoperative complications.

Competing interests

The authors declare that they have no competing interests.

Table 1

Variables	Number of patients	%
Sex		
Males	200	59.5
Females	136	40.5
Age category (years)		
Mean	336	100
43.4 ± 16.8		
min. 10		
max. 83		
Location of cyst		
Mandibular	231	68.8
Maxillary	105	31.2
Anesthesia		
Local	314	93.5
General	22	6.5
Complications		
Paresthesia	1	0.3
Fracture	1	0.3
Dimension of bony defects (cm)		
Mean	336	100
1.50 ± 0.80 × 1.06 ± 0.50 cm		

Table 1

Demographic composition of the study population and clinical features.

Table 2

Distribution of oral cysts in the population sample.

* Unspecified.
** Such as odontogenic fibromas, nonepithelial, traumatic and hemorrhagic cysts, sinus polyposis, epulis, fibrous bone dysplasia and oral melanosis.

Table 2

Year	Odontogenic cysts, inflammatory origin	Odontogenic cysts, develop-mental dentigerous nature	Radicular cysts	Residual cysts	Periapical granulomas	Granulation tissue*	Odontogenic cysts, unspecified nature	Ameloblastomas	Odontomas	Keratocysts	Nasopalatine cysts	Other**	Total
2001	9	2	13	-	-	-	4	-	-	1	-	1	30
2002	10	9	3	-	-	-	2	-	1	-	-	1	26
2003	13	2	9	-	1	2	4	-	-	1	-	-	32
2004	10	2	3	-	1	1	4	-	-	-	-	1	22
2005	19	3	8	-	1	1	-	-	-	-	-	2	34
2006	8	4	3	-	-	1	-	-	-	-	-	-	16
2007	8	5	2	-	-	3	6	-	1	-	1	-	26
2008	16	2	7	-	-	1	7	-	1	-	1	2	37
2009	8	2	5	1	-	1	9	-	1	-	-	-	27
2010	10	2	3	-	1	-	13	1	1	-	1	2	34
2011	5	2	3	-	-	2	15	2	-	-	-	1	30
2012	4	-	2	-	-	2	13	-	-	1	-	-	22
Total	120	35	61	1	4	14	77	3	5	3	3	10	336
%	35.7	10.4	18.1	0.3	1.2	4.2	22.9	0.9	1.5	0.9	0.9	3	100

References

1.
Getter L, Bhaskar SN, Cutright DE, Perez B, Brady JM, Driskell TD, O'Hara MJ. Three biodegradable calcium phosphate slurry implants in bone.
→ J Oral Surg.
1972 Apr;30(4):263–8.

2.
Salama R. Xenogeneic bone grafting in humans.
→ Clin Orthop Relat Res.
1983 Apr;(174):113–21.

3.
Horowitz I, Bodner L. Use of xenograft bone with aspirated bone marrow for treatment of cystic defect of the jaws.
→ Head Neck.
1989 Nov-Dec;11(6):516–23.

4.
Mitchell R. An evaluation of bone healing in cavities in the jaws implanted with a collagen matrix.
→ Br J Oral Maxillofac Surg.
1992 Jun;30(3):180–2.

5.
Moskow BS, Gold SI, Gottsegen R. Effects of scleral collagen upon the healing of experimental osseous wounds.
→ J Periodontol.
1976 Oct;47(10):596–606.

6.
Del Balso AM, Adrian JC. Collagen gel in osseous defects: a preliminary report.
→ Oral Surg Oral Med Oral Pathol.
1976 Nov;42(5):562–9.

7.
Bodner L. Effect of decalcified freeze-dried bone allograft on the healing of jaw defects after cyst enucleation.
→ J Oral Maxillofac Surg.
1996 Nov;54(11):1282–6.

8.
Bodner L. Osseous regeneration in the jaws using demineralized allogenic bone implants.
→ J Craniomaxillofac Surg.
1998 Apr;26(2):116–20.

9.
Schepers EJ, Ducheyne P, Barbier L, Schepers S. Bioactive glass particles of narrow size range: a new material for the repair of bone defects.
→ Implant Dent.
1993 Fall;2(3):151–6.

10.
Marx RE, Kline SN, Johnson RP, Malinin TI, Matthews JG 2nd, Gambill V. The use of freeze-dried allogeneic bone in oral and maxillofacial surgery.
→ J Oral Surg.
1981 Apr;39(4):264–74.

11.
Spengos MN. Irradiated allogeneic bone grafts in the treatment of odontogenic cysts.
→ J Oral Surg.
1974 Sep;32(9):674–8.

12.
Constantinides J, Zachariades N. Homogenous bone grafts to the mandible.
→ J Oral Surg.
1978 Aug;36(8):599–603.

13.
Marble HB Jr. Homografts of freeze-dried bone in cystic defects of the jaws: a survey of ninety-one cases.
→ Oral Surg Oral Med Oral Pathol.
1968 Jul;26(1):118–23.

14.
Chiapasco M, Rossi A, Motta JJ, Crescentini M. Spontaneous bone regeneration after enucleation of large mandibular cysts: a radiographic computed analysis of 27 consecutive cases.
→ J Oral Maxillofac Surg.
2000 Sep;58(9):942–8.

15.
Damante JH, Da S Guerra EN, Ferreira O Jr. Spontaneous resolution of simple bone cysts.
→ Dentomaxillofac Radiol.
2002 May;31(3):182–6.

16.
Caicoya SO. Bone cavity filling with alloplastic material in maxillofacial surgery.
→ Rev Esp Cir Oral y Maxillofac.
2007 Jan-Feb;29(1):21–32.

17.
Wiltfang J, Kloss FR, Kessler P, Nkenke E, Schultze-Mosgau S, Zimmermann R, Schlegel KA. Effects of platelet-rich plasma on bone healing in combination with autogenous bone and bone substitutes in critical-size defects: an animal experiment.
→ Clin Oral Implants Res.
2004 Apr;15(2):187–93.

18.
Santamaría J, García AM, de Vicente JC, Landa S, López-Arranz JS. Bone regeneration after radicular cyst removal with and without guided bone regeneration: pathology.
→ Int J Oral Maxillofac Surg.
1998 Apr;27(2):118–20.

19.
Ihan Hren N, Miljavec M. Spontaneous bone healing of the large bone defects in the mandible.
→ Int J Oral Maxillofac Surg.
2008 Dec;37(12):1111–6.

20.
Pradel W, Eckelt U, Lauer G. Bone regeneration after enucleation of mandibular cysts: comparing autogenous grafts from tissue-engineered bone and iliac bone.
→ Oral Surg Oral Med Oral Pathol Oral Radiol Endod.
2006 Mar;101(3):285–90.

21.
Kawai T, Murakami S, Hiranuma H, Sakuda M. Healing after removal of benign cysts and tumors of the jaws: a radiologic appraisal.
→ Oral Surg Oral Med Oral Pathol Oral Radiol Endod.
1995 Apr;79(4):517–25.

22.
Di Dio M, De Luca M, Cammarata L, Pierazzi G. Bone regeneration after removal of a mandibular cyst and following prosthetic rehabilitation with implants. Case report.
→ Minerva Stomatol.
2005 Jun;54(6):373–8.

Knowledge about risk factors associated with periodontal disease among patients referred to a specialist periodontal clinic

Giovanni Serino,[a, b] Masahiro Wada[a,c] & Konstantinos Bougas[a]

[a] Department of Periodontology, Södra Älvsborg Hospital, Borås, Sweden
[b] Research and Development Unit, Southern Älvsborg County, Borås, Sweden
[c] Department of Prosthodontics, Gerodontology and Oral Rehabilitation, Graduate School of Dentistry, Osaka University, Osaka, Japan

Corresponding author:

Dr. Giovanni Serino
Department of Periodontology
Södra Älvsborg Hospital
50182 Borås
Sweden

T +46 33 661 3750
F +46 33 616 1235
giovanni.serino@vgregion.se

How to cite this article:

Serino G, Wada M, Bougas K. Knowledge about risk factors associated with periodontal disease among patients referred to a specialist periodontal clinic.

J Oral Science Rehabilitation.
2016 Jun;2(2):58–63.

Abstract

Objective

The patient's awareness and knowledge of periodontal disease is a key factor for successful periodontal treatment. The objective of this study was to evaluate this knowledge among patients referred to a specialist periodontal clinic.

Methods

145 consecutive patients referred for treatment of periodontitis were asked about the causes/risk factors associated to periodontitis. Their answers were collated into the following groups: genetics/inheritance, stress, smoking, poor oral hygiene/bacteria, systemic disease (diabetes, cardiovascular disease, medicine intake).

Results

Among the 145 patients referred, 60% had some knowledge about the causes of or risk factors associated to periodontal disease. Among these 87 patients, poor oral hygiene/bacteria was the most mentioned cause (40.6%), followed by smoking (22.9%). Genetics/inheritance, stress and systemic disease were seldom reported. The majority of the patients (70.1%) with knowledge about periodontal disease had received information about the disease from the dental staff, while the rest had acquired their knowledge from other sources.

Conclusion

The knowledge about the etiology of periodontal disease among the referred patients was poor since 40% had not received any information about the disease. In order to treat and control periodontal disease effectively, programs with a focus on improving both professional and patient awareness of periodontal disease are needed.

Keywords

Periodontal disease, risk factors, plaque control, compliance.

Introduction

The role of plaque accumulation as an etiological factor to the development of periodontal disease is well established.[1–3] In the last decades, some risk factors associated with the progression of periodontal disease have also been identified (i.e., specific bacteria, smoking habit, poorly controlled diabetes, stress, obesity, gender, socio-economic status, genetics).[4] The association between periodontal status and systemic diseases, such as cardiovascular disease, respiratory disease and obesity, has also been highlighted during the last years.[5–8] It is the duty of dentists and dental hygienists to transfer this knowledge to the patients. It has been reported that once patients are informed about the nature of their disease, the dental professionals are consequently able to obtain the patients' compliance in establishing good periodontal health behavior.[9] In this matter, Horne et al. identified three important aspects: the patient's compliance ("the extent to which the patient's behavior matches the prescriber's recommendations"), the adherence (the agreement between the patient and the health care provider to follow the prescriber's recommendations) and the concordance (the agreement between a patient and a health care professional in determining whether, when and how medicines have to be taken).[10]

Blinkhorn considers that unsatisfactory adherence can often be explained by inadequate information and when the information is irrelevant to the patient.[11] The patient's awareness and knowledge of periodontal disease appears also to be a key factor for successful periodontal treatment.[12, 13] Deinzer et al., in a study involving 1,001 interviews in a German community, reported a deficit in knowledge about risk factors associated with periodontal disease and suggested that education on periodontal disease should be improved.[9] Pralhad and Thomas reported that there were some differences in the knowledge of periodontitis among different health care professionals.[14]

Knowledge about risk factors associated with periodontal disease among patients referred to specialist periodontal clinics has not yet evaluated. For this reason, the objective of the present study was to evaluate knowledge about periodontal disease among patients referred to a specialist periodontal clinic for a periodontal examination. The second objective was to evaluate the source of the patients' information.

Materials and methods

All consecutive patients ($N = 145$) referred to the specialist periodontal clinic in Borås, Sweden, for a periodontal clinical examination between June and December 2014 were included. The patients were referred from private and public dental clinics in the county of Södra Älvsborg, in Sweden.

After registration of the patients' anamneses and before undergoing clinical examination, the patients were asked whether they had been referred from a private or public clinic, whether they knew the reason why they had been referred to a specialist clinic (yes/no) and whether they knew about possible causes/risk factors associated with periodontal disease. Patients could express one or more causes and did not have to choose from a list of suggestions or a questionnaire. Their answers were then collated into the following groups: genetics/inheritance, stress, smoking, poor oral hygiene/bacteria, systemic disease (diabetes, cardiovascular disease, medicine intake). The patients were also asked whether they had obtained their knowledge on periodontal disease from dental professionals, the Internet, newspapers or other sources.

The patients were informed that their answers were being collected anonymously for research analysis. All of the patients gave their consent.

Statistical analysis

Mean value and standard deviation were used for data description. The percentage of patients with respect to the different answers was calculated and differences were analyzed by a chi-squared test, using IBM SPSS Statistics (Version 22.0; IBM, Armonk, N.Y., U.S.). A p-value of < 0.05 was considered to be significant.

Results

The number of patients included in the study was 145; 64 were males (mean age of 54.4; S.D. ± 14.6) and 81 were females (mean age of 57.8; S.D. ± 15.8). Of these patients, 37.2% had been referred from private clinics and 62.8% from public clinics **(Table 1)**. Only 9.7% had not been informed about the reason they were being referred to the specialist clinic, and in this respect, no difference was noted between private and public dental clinics **(Table 2)**. When asked whether they had any knowledge about the causes of or risk factors for periodontal disease

Table 1

Sample description.

Table 2

Awareness of the reason for referral to a specialist periodontal clinic.

Table 1

	N = 145	%	Mean age (years)	S.D. (years)
Referral from				
Private clinics	54	37.2	61.8	13.9
Public clinics	91	62.8	52.4	15.0
Sex				
Male	64	44.1	54.4	14.6
Female	81	55.9	57.8	15.8
Total	145	100	56.0	15.3

Table 2

	Male (%)	Female (%)	All (%)	Difference according to sex	
				X^2	*P*-value
Private clinics	91.6	83.3	87.0	0.9059	0.365
Public clinics	89.7	94.2	92.3	0.7949	0.427
Total	90.5	90.2	90.3	0.0469	0.963

(yes/no), only 60% answered "yes". The mean age of the patients who answered "yes" was 58 ± 17 and was 55 ± 14 for the patients who answered "no", and these values were not statistically significantly different. Concerning the 40% of patients without any knowledge about the causes of or risk factors for periodontal disease, no difference was noted between patients referred from private dental clinics or those referred from public dental clinics **(Fig. 1)**. Among the 87 patients with knowledge about the causes of or risk factors for periodontal disease, 53 (61%) expressed only one possible cause, 24 (28%) two causes and 10 (11%) three **(Fig. 2)**. Poor oral hygiene/bacteria was the most commonly mentioned cause of periodontal disease (40.6%), followed by smoking (22.9%). Among the patients who reported only one cause, poor oral hygiene/bacteria was the most cited. In patients who mentioned two causes, smoking was the most cited, followed by poor oral hygiene/bacteria and genetics/inheritance. Stress and systemic disease were seldom reported **(Fig. 2)**. The majority of the patients (70.1%) with knowledge about periodontal disease stated that they had been informed about the causes of the disease by dental professionals, while the rest of the patients had obtained their knowledge from the Internet, magazines or other sources **(Fig. 3)**.

Discussion

The objective of the present study was to investigate the knowledge about periodontal disease among patients referred to a specialist periodontal clinic. All of the patients regularly visited public or private dental clinics for dental treatment and received periodontal nonsurgical therapy at least once a year, among other dental treatments. Among those patients, 90.3% knew the reason for their referral to a specialist clinic. When the patients were asked whether they were familiar with the causes of periodontal disease, surprisingly, 40% answered "no", even though they had been sent to a specialist clinic and received regular nonsurgical periodontal treatment from their dentist or dental hygienist. Regardless of whether they were referred from public or private clinics, the percentage of patients with no knowledge about periodontal disease was similar. Males tended to have less knowledge than females. It has been suggested that men may have less interest in their oral health and knowledge about periodontal disease compared with women.[15] The high frequency of patients without any knowledge about periodontal disease among these regular recipients of dental care highlights the ineffectiveness in transferring individual tailored information from the professional dental staff to

Fig. 1

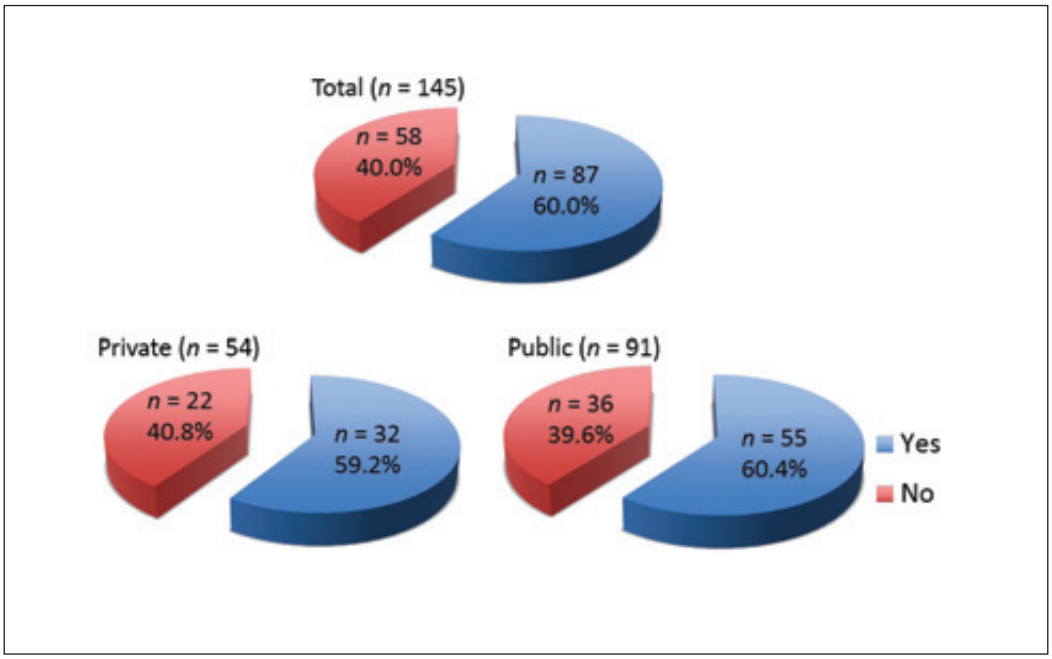

Fig. 2

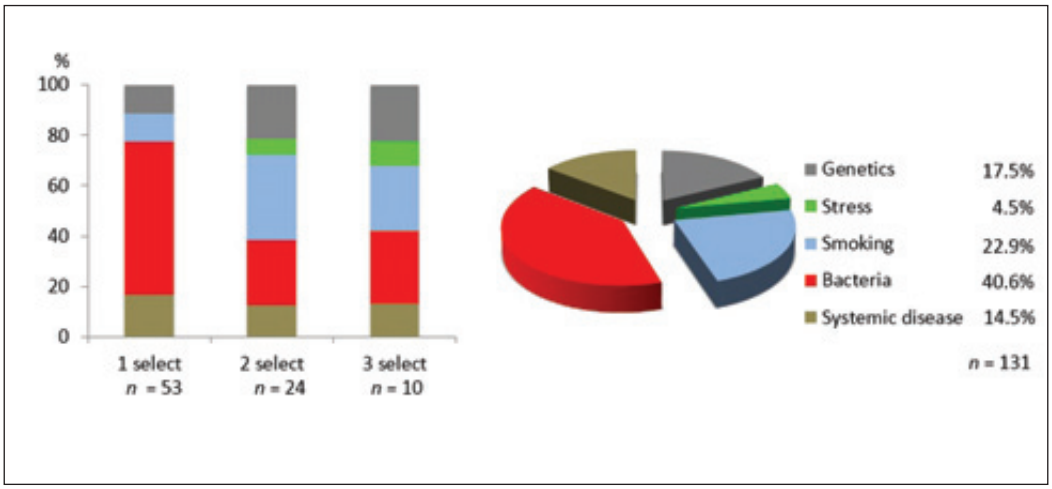

Fig. 3

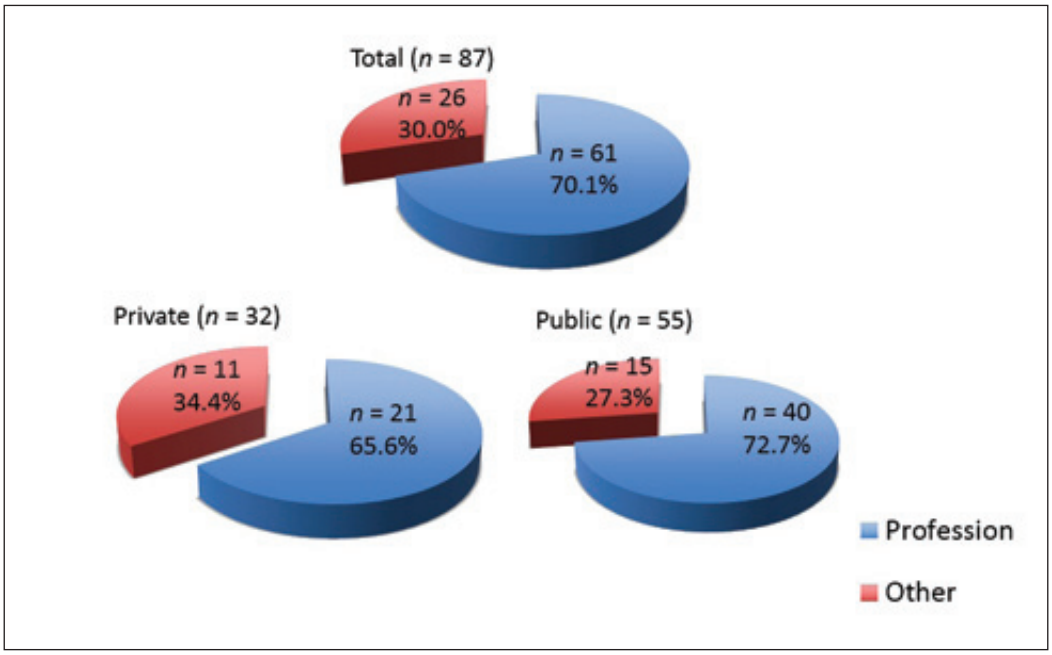

Fig. 1

Knowledge about causes of or risk factors for periodontal disease. Only about 60% of patients overall responded positively, irrespective of whether they were referred from private or public dental clinics.

Fig. 2

Answers from the 87 patients with knowledge about the causes of or risk factors for periodontal disease: The graph on the left shows that 60.9% of these patients expressed only one putative cause, while 39.1% cited two or more. The graph on the right shows that poor oral hygiene/ bacteria was the most mentioned cause of periodontal disease (40.6%), followed by smoking (22.9%). Stress, genetics/inheritance and systemic disease were seldom reported (4.5%, 17.5% and 14.5%, respectively).

Fig. 3

The source of information among the 87 patients with knowledge about periodontal disease: The majority had obtained the information from dental professionals, but 30% of them had gained their knowledge from other sources.

the patients, which might be due to low interest among general practitioners in the etiology and prevention of periodontal disease[16] or to inadequate techniques used to achieve patients' awareness of the disease and compliance.[17, 18] Compliance with periodontal therapy is directly related to its success.[13] Gao et al. reviewed the effect of motivational interviewing in improving periodontal health and concluded that dental professionals should assess the presence of adequate knowledge of periodontal disease before starting treatment.[19]

It is important to point out that the patients in our study were asked whether they had any knowledge about periodontal disease and that they answered using their own words, not via a questionnaire requiring selection from multiple options. Their answers were then collated into different groups of causes or risk factors. The majority of the patients cited only one cause and the remainder reported two or more causes. Among the patients who gave only one cause of periodontal disease, the majority cited poor oral hygiene/bacteria; poor oral hygiene/bacteria was also the most common cause reported when data from all of the patients were considered. The second most common cause was smoking. It is well established that poor oral hygiene is a major risk factor for periodontal disease, as are smoking, stress, genetic factors, diabetes, obesity and cardiovascular disease.[4] Surprisingly, among those patients who cited two causes, smoking was more commonly mentioned than was poor oral hygiene/bacteria. It is reported in the literature that smoking is a risk factor for periodontal disease and results in accelerated onset, severity and progression of the disease,[20, 21] but this is the case only in the presence of plaque[20] and is related to the number of cigarettes smoked per day.[21] However, in recent years, smoking has been evaluated as a risk factor for periodontal disease together with other subject-related risk factors and in that context does not seem to have a stronger impact than factors such as cardiovascular disease or obesity.[7]

Thus, among the patients involved in our study, smoking seemed to be overestimated almost to the level of poor oral hygiene/bacteria. However, only a few patients cited other subject-related risk factors. Genetics/inheritance had a slightly higher percentage (17.5%) compared with systemic disease (14.5%) and stress (4.5%). Linden et al. reported that occupational stress has a relationship to the progression of periodontitis.[22] Peruzzo et al. reviewed the relationship between psychological factors and periodontal disease and concluded that there is a positive relationship between stress and periodontal disease.[23] Studies have shown a correlation between poorly controlled diabetes and specific gene polymorphisms and periodontal disease.[24] Our results on the knowledge of causes of periodontal disease among patients referred to the specialist periodontal clinic are in agreement with a similar study by Razzak et al.[25] and point to the need to improve patients' knowledge about periodontal disease and its risk factors. In our study, the majority of the patients (70.1%) were informed by dental professionals.

Conclusion

Within the limitations of this study, we conclude that the rate of knowledge about periodontal disease among the patients referred to the specialist periodontal clinic was poor, since 40% of the referred patients had not received any information about the disease. Patients suffering from periodontal disease require motivation in order to comply with the treatment. Therefore, in order to treat or control periodontal disease effectively, programs that focus on improving both the dental professionals' and the patients' knowledge about periodontal risk factors and on motivation techniques among general dentists and dental hygienists should be implemented.

Competing interests

The authors declare that they have no competing interests related to this study. This project was self-financed by the Department of Periodontology at Södra Älvsborg Hospital, Borås, Sweden.

References

1.
Löe H, Theilade E, Jensen SB.
Experimental gingivitis in man.
→ J Periodontol.
1965 May-Jun;36(3):177–87.

2.
Theilade E, Wright WH, Jensen SB, Löe H.
Experimental gingivitis in man. II.
A longitudinal clinical and bacteriological investigation.
→ J Periodontal Res.
1966 Feb;1(1):1–13.

3.
Lindhe J, Hamp SE, Löe H. Plaque induced periodontal disease in beagle dogs.
A 4-year clinical, roentgenographical and histometrical study.
→ J Periodontal Res.
1975 Oct;10(5):243–55.

4.
Borrell LN, Papapanou PN. Analytical epidemiology of periodontitis.
→ J Clin Periodontol.
2005 Oct;32 Suppl 6:132–58.

5.
Renvert S, Ohlsson O, Persson S, Lang NP, Persson GR. Analysis of periodontal risk profiles in adults with or without a history of myocardial infarction.
→ J Clin Periodontol.
2004 Jan;31(1):19–24.

6.
Norderyd O, Hugoson A, Grusovin G. Risk of severe periodontal disease in a Swedish adult population: a longitudinal study.
→ J Clin Periodontol.
1999 Sep;26(9):608–15.

7.
D'Aiuto F, Nibali L, Parkar M, Patel K, Suvan J, Donos N. Oxidative stress, systemic inflammation, and severe periodontitis.
→ J Dent Res.
2010 Nov;89(11):1241–6.

8.
Nibali L, D'Aiuto F, Griffiths G, Patel K, Suvan J, Tonetti MS. Severe periodontitis is associated with systemic inflammation and a dysmetabolic status: a case–control study.
→ J Clin Periodontol.
2007 Nov;34(11):931–7.

9.
Deinzer R, Micheelis W, Granrath N, Hoffmann T. More to learn about: periodontitis-related knowledge and its relationship with periodontal health behaviour.
→ J Clin Periodontol.
2009 Sep;36(9):756–64.

10.
Horne R, Barber N, Elliott R, Morgan M. Concordance, adherence and compliance in medicine taking: Report for the National Co-ordinating Centre for NHS Service Delivery and Organisation R & D (NCCSDO) [Internet]. London: National Coordinating Centre for Service Delivery and Organisation;
2005 Dec [cited 2016 Mar 9]. 309 p.
→ Available from: http://www.netscc.ac.uk/hsdr/files/project/SDO_FR_08-1412-076_V01.pdf.

11.
Blinkhorn AS. Factors affecting the compliance of patients with preventive dental regimens.
→ Int Dent J.
1993 Jun;43(3 Suppl 1):294–8.

12.
Jönsson B, Öhrn K, Lindberg P, Oscarson N. Cost-effectiveness of an individually tailored oral health educational programme based on cognitive behavioural strategies in non-surgical periodontal treatment.
→ J Clin Periodontol.
2012 Jul;39(7):659–65.

13.
Mårtensson C, Söderfeldt B, Axtelius B, Andersson P. Knowledge of periodontitis and self-perceived oral health: a survey of periodontal specialist patients.
→ Swed Dent J.
2013;37(1):49–58.

14.
Pralhad S, Thomas B. Periodontal awareness in different healthcare professionals: a questionnaire survey.
→ J Educ Ethics Dent.
2001 Jul;1(2):64–67.

15.
Furuta M, Ekuni D, Irie K, Azuma T, Tomofuji T, Ogura T, Morita M. Sex differences in gingivitis relate to interaction of oral health behaviors in young people.
→ J Periodontol.
2011 Apr;82(4):558–65.

16.
Gift HC. Awareness and assessment of periodontal problems among dentists and the public.
→ Int Dent J.
1988 Sep;38(3):147–53.

17.
Jönsson B, Öhrn K, Lindberg P, Oscarson N. Evaluation of an individually tailored oral health educational programme on periodontal health.
→ J Clin Periodontol.
2010 Oct;37(10):912–9.

18.
Croxson LJ. Periodontal awareness: the key to periodontal health.
→ Int Dent J.
1993 Apr;43(2 Suppl 1):167–77.

19.
Gao X, Lo EC, Kot SC, Chan KC. Motivational interviewing in improving oral health: a systematic review of randomized controlled trials.
→ J Periodontol.
2014 Mar;85(3):426–37.

20.
Ismail AI, Burt BA, Eklund SA. Epidemiologic patterns of smoking and periodontal disease in the United States.
→ J Am Dent Assoc.
1983 May;106(5):617–21.

21.
Amarasena N, Ekanayaka AN, Herath L, Miyazaki H. Tobacco use and oral hygiene as risk indicators for periodontitis.
→ Community Dent Oral Epidemiol.
2002 Apr;30(2):115–23.

22.
Linden GJ, Mullally BH, Freeman R. Stress and the progression of periodontal disease.
→ J Clin Periodontol.
1996 Jul;23(7):675–80.

23.
Peruzzo DC, Benatti BB, Ambrosano GM, Nogueira-Filho GR, Sallum EA, Casati MZ, Nociti FH Jr. A systematic review of stress and psychological factors as possible risk factors for periodontal disease.
→ J Periodontol.
2007 Aug;78(8):1491–504.

24.
Lalla E, Kaplan S, Chang SM, Roth GA, Celenti R, Hinckley K, Greenberg E, Papapanou PN. Periodontal infection profiles in type 1 diabetes.
→ J Clin Periodontol.
2006 Dec;33(12):855–62.

25.
Razzak A, Aslam M, Malik S. Patient's awareness about the risk of factors and the prevention of dental disease.
→ Pak Oral Dent J.
2012 Aug;32(2):300–3.

Authors must adhere to the following guidelines

Informed consent

Patients have a right to privacy that should not be violated without informed consent. Identifying information, including patients' names, initials or hospital numbers, should not be provided in the manuscript or visual material unless the information is essential for scientific purposes and the patient (or parent or guardian) has given written informed consent for publication. Informed consent for this purpose requires that an identifiable patient be shown the manuscript to be published. Authors should disclose to these patients whether any potential identifiable material might be available via the Internet as well as in print after publication. Nonessential identifying details should be omitted. Informed consent should be obtained if there is any doubt that anonymity can be maintained. For example, masking the eye region in photographs of patients is inadequate protection of anonymity. If identifying characteristics are altered to protect anonymity, authors should provide assurance that alterations do not distort scientific meaning. **When informed consent has been obtained, it should be indicated in the manuscript.**

Human and animal rights

When reporting experiments on human subjects, authors should indicate whether the procedures followed were in accordance with the ethical standards of the responsible committee on human experimentation (institutional and national) and with the Declaration of Helsinki of 1975, as revised in 2013 (www.wma.net/en/30publications/ 10policies/b3/index.html). If doubt exists whether the research was conducted in accordance with the Declaration of Helsinki, the authors must explain the rationale for their approach, and demonstrate that the institutional review body explicitly approved the doubtful aspects of the study. When reporting experiments on animals, authors should indicate whether institutional and national standards for the care and use of laboratory animals were followed. Further guidance on animal research ethics is available from the International Association of Veterinary Editors' Consensus Author Guidelines on Animal Ethics and Welfare (www.veteditors.org/consensus-author-guidelines-onanimal-ethics-and-welfare-for-editors).

Preparing the manuscript text

General

The manuscript must be written in U.S. English. The main body of the text, excluding the title page, abstract and list of captions, but including the references, may be a maximum of 4,000 words. Exceptions may be allowed with prior approval from the publisher.

Authors will have the opportunity to add more information regarding their article, as well as post videos, present a webinar and blog on the DT Science website.

It is preferred that there be no more than six authors. If more authors have participated in the study, the contribution of each author must be disclosed at the end of the document.

Title

The title should not exceed 35 characters. Capitalize only the first word and proper nouns in the title. Please include a running title as well.

Author information

The following information must be included for each author:

– Full author name(s)
– Full affiliation (department, faculty, institution, town, country).

For the corresponding author, the following information should be included in addition:

– Full mailing address
– Email address.

Abstract and keywords

The manuscript must contain an abstract and a maximum of five keywords. The abstract should be self-contained, not cite any other work and not exceed 250 words. It should be structured into the following separate sections: objective, materials and methods, results, conclusion, and keywords.

Structure of the main text

The body of the manuscript must be structured as follows:

– Introduction (no subheadings)
– Materials and methods
– Results
– Discussion
– Conclusion.

Competing interests

Authors are required to declare any competing financial or other interests regarding the article submitted. Such competing interests are to be stated at the end of manuscript before the references. If no competing interests are declared, the following will be stated: "The authors declare that they have no competing interests."

Acknowledgments

Acknowledgments (if any) should be brief and included at the end of the manuscript before the references, and may include supporting grants.

References

Authors are responsible for ensuring that the information for each reference is complete and accurate. All references must be cited within the manuscript. References appearing in the list but not in the manuscript will be removed. In-text citation should follow the citation–sequence format (e.g., "as discussed by Haywood et al.[15]") using superscript numbers placed after the punctuation in the relevant sentence. The references must be numbered consecutively.

The reference list must be numbered and the references provided in order of appearance. For the reference list, the journal follows the citation style stipulated in *Citing medicine: the NLM style guide for authors, editors, and publishers.* The guidelines may be viewed and downloaded free of charge at

www.ncbi.nlm.nih.gov/books/NBK7256/
The reference list may not exceed 50 references.

List of captions

Please provide the captions for all visual material at the end of the manuscript.

Abbreviations

Abbreviations should be used sparingly and defined when first used. The abstract and the main manuscript text should be regarded as separate documents in this regard.

Typography

- Use Times New Roman regular with a font size of 12 pt.
- Use double line spacing with blank lines separating sections and paragraphs.
- Type the text unjustified and do not apply hyphenation at line breaks.
- Number all of the pages.
- Use endnotes if necessary, but not footnotes.
- Greek and other special characters may be included.

Preparing the visual material

Requirements for images

Each image should be supplied separately and the following formats are accepted: PSD, TIFF, GIF and JPEG. The image must have a resolution of 300 dpi and must be no smaller than 6 cm × 6 cm.

Please number the images consecutively throughout the article by using a new number for each image. If it is imperative that certain images be grouped together, then use lowercase letters to designate these in a group (e.g., "Figs. 2a–c").

Place the references to the images in your article wherever they are appropriate, whether in the middle or at the end of a sentence. Provide a caption for each image at the end of your article.

Requirements for tables

Each table should be supplied separately and in Microsoft Word format. Tables may not be embedded as images and no shading or color is to be used.

Tables should be cited consecutively in the manuscript. Place the references to the tables in your article wherever they are appropriate, whether in the middle or at the end of a sentence. Every table must have a descriptive caption, and if numerical measurements are given the units should be included in the column headings.

Supplements/supporting material

DT Science allows an unlimited amount of supporting material (such as datasets, videos or other additional information) to be uploaded. This material should be presented succinctly (in English). The author bears full responsibility for the content. Color, animated multimedia presentations, videos and so on are welcome and published at no additional cost to the author or reader. Please refer briefly to such material in the manuscript where appropriate (e.g., as an endnote).

Submit your research and clinical articles to

Dr. Daniele Botticelli at
daniele.botticelli@gmail.com

For all other requests, contact

Nathalie Schüller at
n.schueller@dental-tribune.com
T +49 341 4847 4136

Dental Tribune International Publishing Group
Holbeinstr. 29
04229 Leipzig
Germany

www.dtscience.com
www.dental-tribune.com

dti] Dental Tribune International

International office

Dental Tribune International
Holbeinstr. 29
04229 Leipzig
Germany

T +49 341 4847 4302
F +49 341 4847 4173

info@dental-tribune.com
www.dental-tribune.com

Publishing team

Publisher

Torsten R. Oemus
t.oemus@dental-tribune.com

Managing Editor

Nathalie Schüller
n.schueller@dental-tribune.com

Concept & design

Rhowerk
www.rhowerk.com

Digital Manager

Serban Veres
serbanveres@gmail.com

Copy editors

Sabrina Raaff
sabrina@greenbadger.co.za

Hans Motschmann
h.motschmann@oemus-media.de

International administration

Chief Financial Officer

Dan Wunderlich
d.wunderlich@dental-tribune.com

Executive Producer

Gernot Meyer
g.meyer@dental-tribune.com

Printer
Löhnert Druck | Handelsstr. 12 | 04420 Markranstädt | Germany

€50/issue of the Journal (4 issues/year; including VAT and shipping costs, for a total of €200/year)

Your subscription will be renewed automatically every year until a written cancellation is sent six weeks prior to the renewal date to

Dental Tribune International GmbH, Holbeinstr. 29, 04229 Leipzig, Germany.

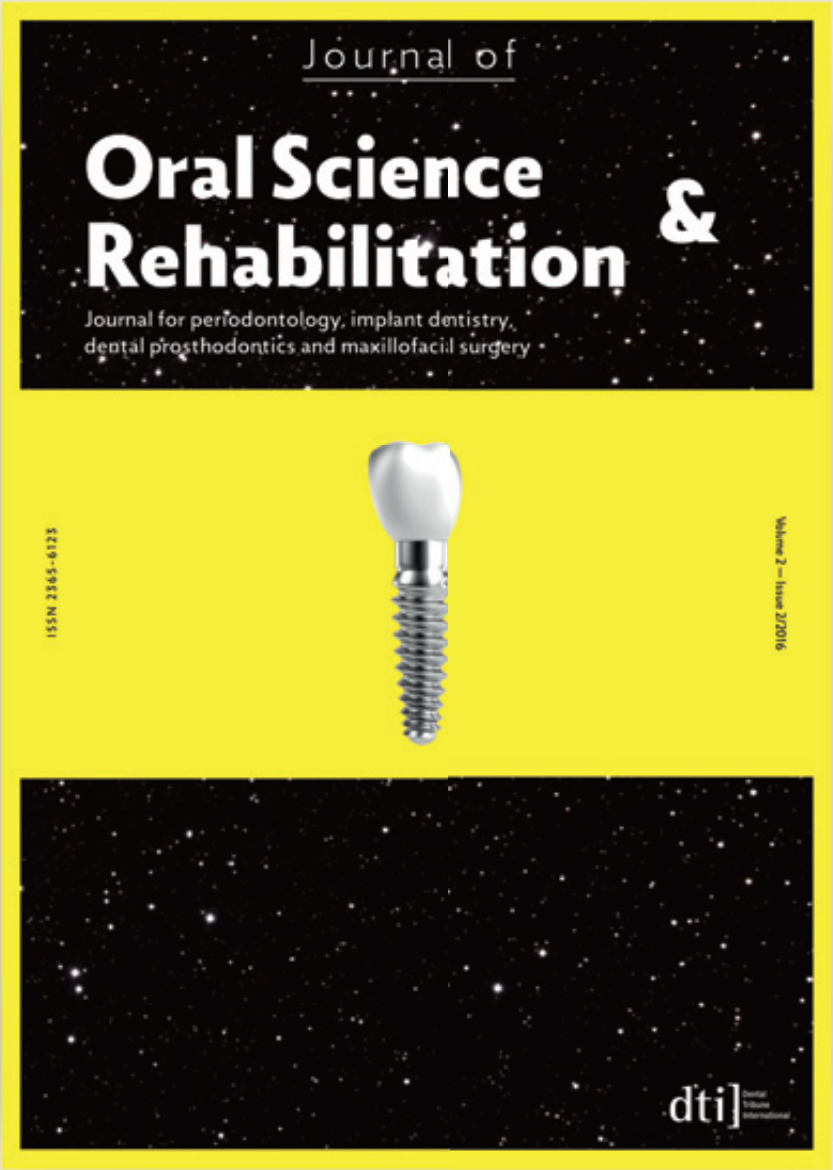

Subscribe Now!

Shipping address

City | Country

Phone | Fax

Signature | Date

☐ PayPal | subscriptions@dental-tribune.com ☐ Credit card

Credit card number | Expiration date | Security code

fax: +49 341 4847 4173 | email: subscriptions@dental-tribune.com

dti Dental Tribune International

Nobel Biocare Global Symposium

June 23–26, 2016 – New York

Where innovation comes to life

nobelbiocare.com/global-symposium-2016

An experience beyond the ordinary

The Nobel Biocare Global Symposium 2016 program will offer unparalleled clinical and scientific education, as well as in-depth hands-on training. Held at the Waldorf Astoria in New York, it's a unique opportunity to experience how innovation can come to life in your daily work.

Design your own learning experience

Choose from numerous lectures, forums, master classes and hands-on sessions – from over 150 of the best speakers and presenters in the world. This must-attend event will cover a vast variety of techniques and treatment solutions, from diagnosis to treatment completion. Don't miss this opportunity. Sign up now and we'll see you in New York!

Read more about the Symposium

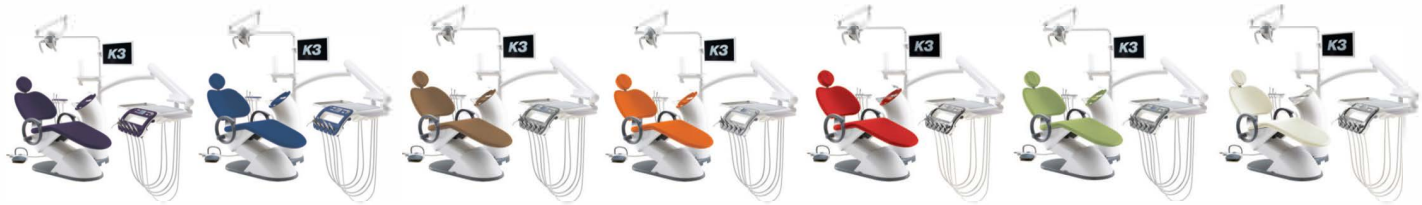

پنل عملکرد

عملکردهای متنوت با دکمه برای تنظیمات دستی، کراشوار از جنس شیشه نشکن و دکمه On/Off چراغ که بر روی پنل، درSide Table قرار داده شده است.

Rotating double-jointed table arm

تیبل آرم دو مفصله چرخشی

تیبل آرم چرخشی دو مفصله باعث استفاده بهتر از فضا برای دستیار پزشک و کاربردوستی می شود.

Water supply system with double sensor / Glass spittoon container

سیستم لیوان پر کن هوشمند/ محتوی اسپیتون شیشه ای

تغذیه آب وکراشوار از جنس شیشه نشکن طراحی شده با شکل و ارتفاع مناسب برای بیماران در تمامی سنین و افزایش آرامش و راحتی بیمار می باشد. علاوه بر آن سیستم لیوان پر کن هوشمند حجم آب مورد نیاز را کنترل می کند و شیشه ی شفاف و بزرگ، کراشوار نظافت آن را دقیق تر و بهتر خواهد کرد.

With adjustable water supply / Switch for hot water

مخزن آب، قابل تنظیم/ مجهز به سیستم آبگرمکن

دکمه کنترل ذخیره آب و زیر آب،،On/Off برای آب داغ، تعبیه شده در قسمت جلوی یونیت که باعث راحتی کار کاربران می شود.

USB Port & 220V power socket

خروجی USB و سوکت ۲۲۰ ولت

Suction filter & side rack

فیلتر ساکشن و میز ابزار

فیلتر ساکشن با قابلیت شستشوی آسان نظافت و نگهداری را آسان می کند و میز ابزار قابل جدا شدن قابلیت نگهداری ابزار گوناگون در طول درمان را دارد.

www.azadmed.com
Tel: +98 21 88 98 80 63 - 6