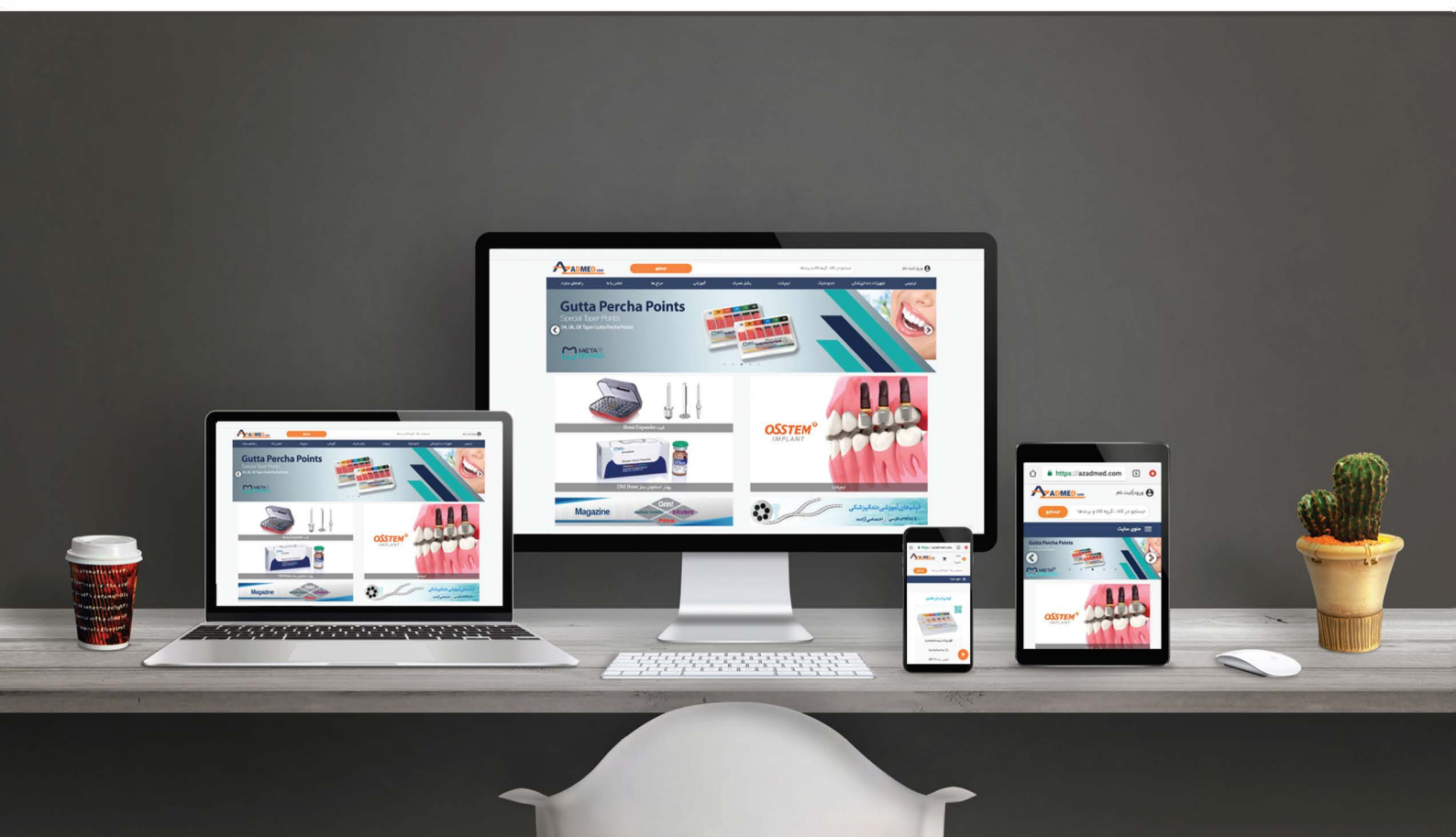




[www.azadmed.com](http://www.azadmed.com)



 azaadtejaratpars  
 @azadmed2  
 88 98 80 63 - 6

Journal of

# Oral Science & Rehabilitation

Journal for periodontology, implant dentistry,  
dental prosthodontics and maxillofacial surgery

ISSN 2365-6123 (Print)  
ISSN 2365-6891 (Online)

Volume 3 — Issue 4/2017

dti] Dental  
Tribune  
International



# EuroPerio9

JUNE 20-23 | 2018  
RAI AMSTERDAM

ADMED.com

LEARN THE  
LATEST FROM  
THE GREATEST

at the World's Leading  
Congress in Periodontology.

- › more than 100 top international speakers
- › latest findings and treatment methods from the fields of periodontology and implant dentistry
- › for the first time with live-surgery and many other innovative session formats



Have a look at the exciting programme online at  
[www.efp.org/europerio9](http://www.efp.org/europerio9)

Save a lot  
and register  
early until

**MARCH 14, 2018**



Diamond Sponsors:



Platinum Sponsors:



Gold Sponsors:



Journal of

# Oral Science & Rehabilitation

Clinical and experimental research provides us with the basic knowledge to support the procedures that we apply in our daily practice. We are all aware that we should not use techniques that are not yet supported by scientific evidence or use material that has not been sufficiently tested.

Clinical research gives us the information needed to confirm the validity of new clinical procedures and whether a given device or biomaterial is able to render the expected results. However, to obtain information on healing patterns, experimental research is crucial.

When writing an article or conducting a review for a scientific journal, we should assess materials and methods carefully and whether the conclusions are congruent with the results. In research, to evaluate the phenomenon under study, it is very important to select with accuracy the variables and the methods to measure these variables. In addition, to eliminate possible biases that may lead to incorrect measurements and wrong conclusions, particular attention has to be paid to correct use of randomization and calibration procedures. We need to apply these measures to reduce the risk of bias and improve the quality of our research so that our results and interpretations may be relied on. This improved quality will be useful for systematic reviews that are located at the top of the evidence-based medicine pyramid. However, it should be emphasized that systematic reviews would not exist without the daily work of the researchers. As researchers, it is important that we apply proper procedures to reduce the risk of bias and to improve the quality of our methodology and data collection. If we do not ensure this, systematic reviews will rely on few studies, few patients, low homogeneity regarding population, and poor standardization of methods and data, and the conclusions will thus not be clinically relevant.

Dr. Daniele Botticelli  
Co-Editor

**3**

**Editorial**

Dr. Daniele Botticelli

**6**

**About the *Journal of Oral Science & Rehabilitation***

**08**

**Roberto Luongo et al.**

Buccal plate reconstruction with an intentionally exposed nonresorbable membrane: 1 year after loading results of a prospective study

**16**

**Natalia Ribes Lainez et al.**

Periimplant soft-tissue and bone levels around dental implants with different neck designs and neck surface treatments: A retrospective cohort study with 3-year follow-up

**24**

**Saverio Cosola et al.**

Antimicrobial efficacy of mouthwashes containing zinc-substituted nanohydroxyapatite and zinc L-pyrrolidone carboxylate on suture threads after surgical procedures

**32**

**Carlo Prati et al.**

Multifactorial statistical analysis toward evaluation of MBL, PES and PI of a novel nonsubmerged implant to restore a single tooth: A 1-year prospective cohort study

**42**

**Christian Brenes et al.**

Digital approach to the fabrication of a wax prototype for full-mouth rehabilitation of a worn dentition: A clinical report

**48**

**Shahnawaz Khijmatgar et al.**

Is there a justification for cone beam computed tomography for assessment of proximity of mandibular first and second molars to the inferior alveolar canal: A systematic review

**58**

**Interview Prof. Matthias Karl**

Bringing science to the surface

**60**

**Guidelines for authors**

**62**

**Imprint — about the publisher**



## INSPIRING SPEAKERS. BREATHTAKING VIEWS MAKE IT SIMPLE

MIS is proud to introduce the Global Conference Speakers Team: • Yuval Jacoby • Ignacio Sanz Sánchez • Vincent Fehmer • Emilio Arguello • Eric Van Dooren • Galip Gürel • Mauro Fradeani • Christian Stappert • Myron Nevins • Joseph Kan • Edward P. Allen • German O. Gallucci • Lesley David • Stefan Koubi • Leila Jahangiri • Carlo Marinello • Ariel J. Raigrodski • Mirela Feraru • Tali Chackartchi • Tommie Van De Velde • Pablo Galindo-Moreno • Stavros Pelekanos • Juan Arias Romero • Víctor Clavijo • Anas Aloum • Gustavo Giordani. To learn more about the conference visit: [www.mis-implants.com/bahamas](http://www.mis-implants.com/bahamas)

**mis**<sup>®</sup>



## About the *Journal of Oral Science & Rehabilitation*

The aim of the *Journal of Oral Science & Rehabilitation* is to promote rapid communication of scientific information between academia, industry and dental practitioners, thereby influencing the decision-making in clinical practice on an international level.

The *Journal of Oral Science & Rehabilitation* publishes original and high-quality research and clinical papers in the fields of periodontology, implant dentistry, prosthodontics and maxillofacial surgery. Priority is given to papers focusing on clinical techniques and with a direct impact on clinical decision-making and outcomes in the above-mentioned fields. Furthermore, book reviews, summaries and abstracts of scientific meetings are published in the journal.

Papers submitted to the *Journal of Oral Science & Rehabilitation* are subject to rigorous double-blind peer review. Papers are initially screened for relevance to the scope of the journal, as well as for scientific content and quality. Once accepted, the manuscript is sent to the relevant associate editors and reviewers of the journal for peer review. It is then returned to the author for revision and thereafter submitted for copy editing. The decision of the editor-in-chief is made after the review process and is considered final.

## About Dental Tribune Science

Dental Tribune Science (DT Science) is an online open-access publishing platform ([www.dtscience.com](http://www.dtscience.com)) on which the *Journal of Oral Science & Rehabilitation* is hosted and published.

DT Science is a project of the Dental Tribune International Publishing Group (DTI). DTI is composed of the leading dental trade publishers around the world. For more, visit

[www.dental-tribune.com](http://www.dental-tribune.com)



## **Benefits of publishing in the journal for authors**

There are numerous advantages of publishing in the *Journal of Oral Science & Rehabilitation*:

- Accepted papers are published in print and as e-papers on [www.dtscience.com](http://www.dtscience.com).
- Authors' work is granted exposure to a wide readership, ensuring increased impact of their research through open-access publishing on [www.dtscience.com](http://www.dtscience.com).
- Authors have the opportunity to present and promote their research by way of interviews and articles published on both [www.dtscience.com](http://www.dtscience.com) and [www.dental-tribune.com](http://www.dental-tribune.com).
- Authors can also post videos relating to their research, present a webinar and blog on [www.dtscience.com](http://www.dtscience.com).

## **Subscription price**

€50.00 per issue, including VAT and shipping costs.

## **Information for subscribers**

The journal is published quarterly. Each issue is published as both a print version and an e-paper on [www.dtscience.com](http://www.dtscience.com).

## **Terms of delivery**

The subscription price includes delivery of print journals to the recipient's address. The terms of delivery are delivered at place (DAP); the recipient is responsible for any import duty or taxes.

Copyright © Dental Tribune International GmbH. Published by Dental Tribune International GmbH. All rights reserved. No part of this publication may be reproduced, stored or transmitted in any form or by any means without prior permission in writing from the copyright holder.



# Buccal plate reconstruction with an intentionally exposed nonresorbable membrane: 1 year after loading results of a prospective study

## Abstract

### Objective

The aim of this study was to investigate the barrier effect of a high-density polytetrafluoroethylene (d-PTFE) membrane left intentionally exposed in post-extraction sockets grafted with an allograft biomaterial and removed after 5 weeks.

### Materials and methods

Forty-seven hopeless teeth were extracted. Residual sockets were grafted with an allograft biomaterial and covered with a d-PTFE membrane. Six months later, 47 submerged implants were installed. Four months later, implants were uncovered and a temporary restoration was delivered. Outcomes were implant and prosthetic survival rate, complications, alveolar ridge width measurement, marginal bone loss (MBL) and gingival recession. Follow-up ranged from 1 to 3 years. The buccal plate was measured after tooth extraction (BPS), at implant placement (BPW) and at implant uncovering/loading (BBT).

### Results

No deviation from the original protocol occurred. All of the implants were osseointegrated. None of the prostheses failed and no complications occurred during the follow-up. The mean BPS at the midpoint was  $6.5 \pm 1.5$  mm (at the time of extraction;  $T^0$ ). At time of implant placement ( $T^1$ ), the mean BPW was  $6.30 \pm 1.30$  mm, with a crestal reduction of  $0.19 \pm 0.34$  mm ( $P = 0.0006$ ). At implant uncovering/loading, the mean BBT was  $1.7 \pm 0.5$  mm. One year after loading ( $T^3$ ), periapical radiographs revealed a mean MBL of  $0.62 \pm 0.16$  mm, compared with  $T^1$ . One year after initial loading there was no buccal gingival recession compared with  $T^0$ , with a mean soft-tissue creeping of  $0.8 \pm 0.2$  mm.

### Conclusion

Buccal plate reconstruction with an intentionally exposed nonresorbable membrane is an effective and easy procedure for regeneration of a resorbed buccal bone plate.

### Keywords

Dental implants, biomaterials, guided bone regeneration, dense PTFE.

Roberto Luongo,<sup>a</sup> Giuseppe Bianco,<sup>b</sup> Calogero Bugea<sup>c</sup> & Marco Tallarico<sup>d</sup>

<sup>a</sup> Ashman Department of Periodontology and Implant Dentistry College of Dentistry, New York University, New York, U.S.; private practice, Bari, Italy

<sup>b</sup> Ashman Department of Periodontology and Implant Dentistry College of Dentistry, New York University, New York, U.S.; private practice, Rome, Italy

<sup>c</sup> Private practice, Galatone, Italy

<sup>d</sup> Aldent University, Tirana, Albania; private practice, Rome, Italy

### Corresponding author:

**Dr. Marco Tallarico**

Via di Val Tellina, 116  
00151 Rome  
Italy

T +39 328 075 8769  
me@studiomarcotallarico.it

### How to cite this article:

Luongo R, Bianco G, Bugea C, Tallarico M. Buccal plate reconstruction with an intentionally exposed nonresorbable membrane: 1 year after loading results of a prospective study.  
J Oral Science Rehabilitation. 2017 Dec;3(4):8–14.

## Introduction

A significant 3-D remodeling of the bone crest, especially horizontally, always occurs after the extraction of a tooth.<sup>1</sup> This makes it difficult to insert an implant, especially in the frontal areas, where residual bone thickness is fundamental for optimal esthetic results. In order to reduce this contraction, a socket preservation technique entailing the insertion of a bone graft and of a resorbable membrane inside the socket, followed after 4–6 months by the positioning of a delayed implant, has usually been proposed.<sup>2,3</sup> However, such a technique does not always have predictable results, especially when the buccal plate of the alveolar socket is missing after tooth extraction.

Guided bone regeneration (GBR) has been proposed as a possible alternative for patients with severe horizontal bone atrophy, to overcome the drawback of bone block techniques.<sup>4,5</sup> In order to protect the clot and prevent the invasion of the clot by nonosteogenic cells, maintaining an adequate biological space for the regeneration of bone tissue, the use of either nonresorbable or resorbable membranes has been proposed.<sup>6</sup> Expanded polytetrafluoroethylene (e-PTFE) membranes and resorbable membranes classically require soft-tissue coverage or primary closure to prevent soft-tissue ingrowth, bacterial contamination, infection, membrane migration, early membrane degradation, and graft exposure. The major feature of the e-PTFE membrane is macroporosity, which is believed to enhance regeneration by improving wound stability.<sup>7</sup> Nevertheless, its main drawback is that an early bacterial infection can occur, affecting the outcome of the regeneration.

High-density polytetrafluoroethylene (d-PTFE) membranes offer an alternative to e-PTFE or resorbable membranes.<sup>8–11</sup> A d-PTFE membrane is made of 100% pure medical-grade bio-inert PTFE, which is nonporous, dense, non-expanded and nonpermeable.<sup>3,5</sup> The thickness of the various commercially available membranes ranges from 0.13 to 0.25 mm and their low porosity ranges from 0.2 to 0.3 mm; e-PTFE membranes have a similar thickness, but a higher porosity (5–30 nm).<sup>12</sup> The indications for d-PTFE membranes are similar to those for e-PTFE, but the different porosity of the first avoids any inflammation of the surrounding soft tissue in case of accidental exposure.<sup>13</sup> There is limited clinical and histological evidence for the use of d-PTFE membranes at present, with some

indications for guided tissue regeneration and GBR, especially in immediate implants and fresh extraction sockets.<sup>7</sup>

The aim of the present prospective study was to investigate the barrier effect of a d-PTFE membrane left intentionally exposed in post-extraction sockets grafted with an allograft biomaterial and removed after 5 weeks. This study is reported in accordance with the Strengthening the Reporting of Observational Studies in Epidemiology statement for improving the quality of observational studies.<sup>14</sup>

## Materials and methods

This prospective study was conducted in a private dental practice from February 2012 to March 2016. Forty-three patients of both sexes requiring 47 implant-supported single-crown restorations to rehabilitate an esthetic area with a hopeless tooth with an Elian type II socket (facial soft tissue was present, but the buccal plate was partially missing after extraction of the tooth),<sup>15</sup> aged 18 years or older and able to sign an informed consent form, were enrolled and treated consecutively. This was provided that they fulfilled the inclusion criteria and gave their written consent to take part in the study. The buccal plate was defined as partially missing when the distance from the gingival margin to the most coronal part of the buccal plate was greater than 4 mm, even in only 1 of the 3 reference points (mesial, distal and midpoint), while both the mesial, distal and the palatal bony walls were present at a distance of less than 4 mm from the palatal gingival margin.

The exclusion criteria were positive medical findings (such as stroke, recent myocardial infarction, severe bleeding disorder, uncontrolled diabetes, or cancer), psychiatric therapy, pregnancy or nursing, smoking more than 10 cigarettes per day, untreated periodontitis, acute or chronic infections of the adjacent tissue or natural dentition, previous radiotherapy of the oral and maxillofacial region within the last 5 years, absence of teeth in the opposing jaw, severe clenching or bruxism, severe maxillomandibular skeletal discrepancy, and poor oral hygiene (full-mouth bleeding and a full-mouth plaque index of higher than or equal to 25%). Patients were informed about the clinical procedures, the materials to be used, the benefits, potential risks and complications, as well as any follow-up evaluations required for the clinical

study. The medical history of the enrolled patients was collected and study models were produced. Preoperative radiographs, including periapical and panoramic radiographs, and computed tomography or cone beam computed tomography scans, were obtained for initial screening and evaluation.

All procedures were conducted in accordance with the Declaration of Helsinki of 1975, as revised in 2013, for biomedical research involving human subjects. One clinician (RL) performed all of the surgical and prosthetic procedures, and one dental laboratory manufactured all of the restorations.

#### Surgical and prosthetic protocols

The teeth were atraumatically extracted with the aid of a periosteal elevator and atraumatic elevators (PT1 and EPTSMS, Hu-Friedy Italy, Milan, Italy) to reduce trauma to the bony walls (**Fig. 1**). After accurate debridement of the socket with a curette (CL866, Hu-Friedy), the distance from the gingival margin to the residual buccal or palatal bone plate was measured with the aid of a periodontal probe (PCPUNC15, Hu-Friedy, Chicago, Ill., U.S.) in order to verify the degree of bone crest resorption. If the distance was more than 5 mm, a nonresorbable d-PTFE membrane (Cytoplast TXT-200, De Ore, Negrar, Italy), adequately cut into an ice-cream cone shape,<sup>16</sup> was introduced into the socket corresponding to the area of the missing buccal plate, in order to prevent soft-tissue proliferation. Subsequently, the d-PTFE membrane was inserted into the socket with the narrower part facing the buccal soft tissue and stabilized with a cortico-cancellous particulate allograft biomaterial (Puros, Zimmer Dental, Carlsbad, Calif., U.S.), placed inside the socket using a curved stainless-steel graft delivery syringe with a 4.5 mm funnel opening (ACE Surgical Supply, Brockton, Mass., U.S.; **Fig. 2a**). Then the wider part of the membrane was overturned above the bone graft and sutured with a 5-0 PTFE mattress suture (Cytoplast, De Ore) to the palatal and buccal mucosa, leaving it intentionally exposed (**Fig. 2b**). The patient was placed on an antibiotic regimen of 1 g of amoxicillin and clavulanic acid (Augmentin, GlaxoSmithKline, Verona, Italy) twice a day, starting the day before the surgery and continuing 7 days after, and an analgesic (ibuprofen, 600 mg) was prescribed if needed. All of the patients were instructed to rinse with 0.12% chlorhexidine 3 times a day for 1 min after

brushing their teeth. No special indications were recommended for the area of the graft.

After 5 weeks, the membrane was removed without the need for anesthetic, leaving the exposed site to heal by secondary intention (**Fig. 3**). After 6 months, a crestal incision was performed, then a full-thickness flap was elevated, and an implant of 4.0 mm in width and 11.5 mm in length was placed according to the manufacturer's instruction (Full OSSEOTITE Tapered Natural, Implant Innovations, Palm Beach Gardens, Fla., U.S.; **Fig. 4**). The implant was submerged and the flap was sutured using a resorbable suture (4-0; Vicryl, Ethicon, Ohio, U.S.), obtaining a primary closure healing. After 4 months of healing, the implant was uncovered and the provisional prosthesis was immediately delivered. Four months later, the definitive metal-free crown was delivered and the occlusion was adjusted (**Fig. 5**). The patients were enrolled in a strict hygiene program and were followed up to 3 years after initial loading.

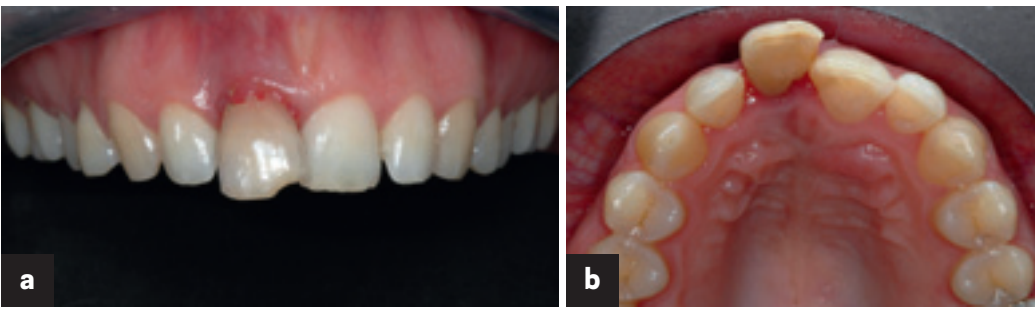The primary outcome measures were the success rates of the implants and prostheses and any surgical and prosthetic complications that occurred during the entire follow-up. An independent blinded assessor recorded all of the measurements and collected the related data according to the following criteria:

- An implant was considered a failure if it presented with any mobility, tested by tapping or rocking the implant head with a hand instrument and/or any signs of radiolucency and/or fracture on an intraoral radiograph taken with the paralleling technique strictly perpendicular to the implant–bone interface. The implant stability was assessed at initial loading and at each follow-up.
- A prosthesis was considered a failure if it needed to be replaced with a different type of prosthesis.
- Complications: Any biological (pain, swelling, suppuration, etc.) and/or mechanical (fracture of the framework and/or the veneering material, screw loosening, etc.) complication was considered.

The secondary outcome measures were dimensional changes in the alveolar ridge width, marginal bone level changes and gingival recession.

- The alveolar ridge width was measured to the nearest millimeter using a periodontal probe (PCPUNC156, Hu-Friedy) at the time of tooth extraction ( $T^0$ ), at implant placement (6 months later;  $T^1$ ), and at the time of implant

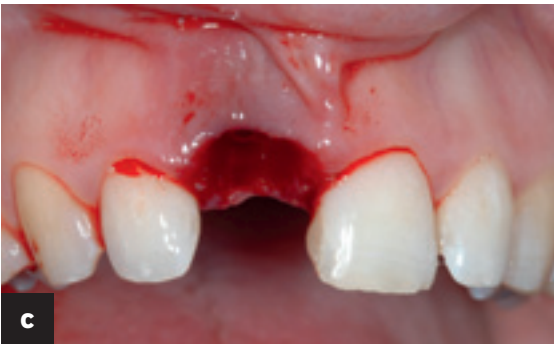Figs. 1a & b



**Figs. 1a–c**

Clinical view of the central incisor before (a,b) and after extraction (c).

Fig. 1c



**Figs. 2a & b**

Allograft inserted into the socket after d-PTFE membrane placement (a) and suturing (b) at T<sup>0</sup>.

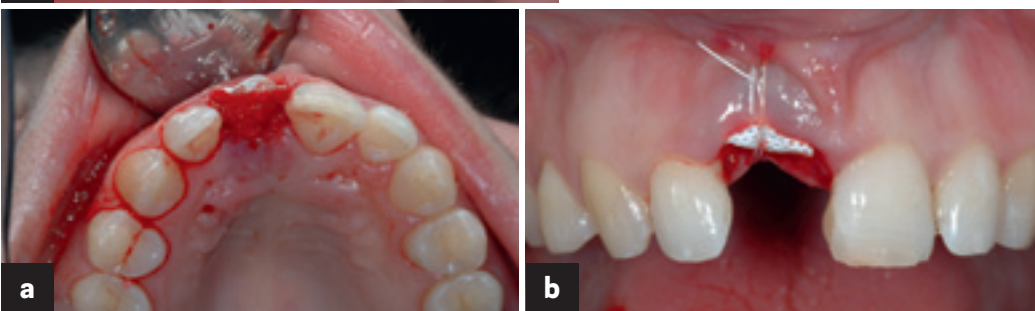
**Figs. 3a & b**

Membrane after 5 weeks (a). Well-vascularized osteoid tissue was evident after removal (b).

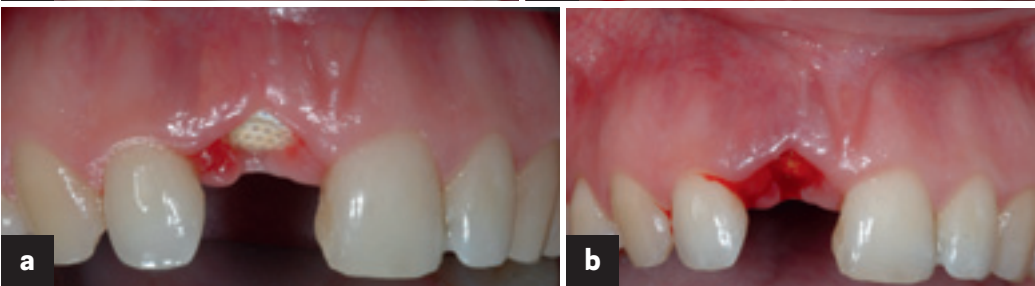
**Figs. 4a & b**

Implant placement at T<sup>1</sup>: The ridge appeared well formed (a), and the implant could be placed in an ideal position (b).

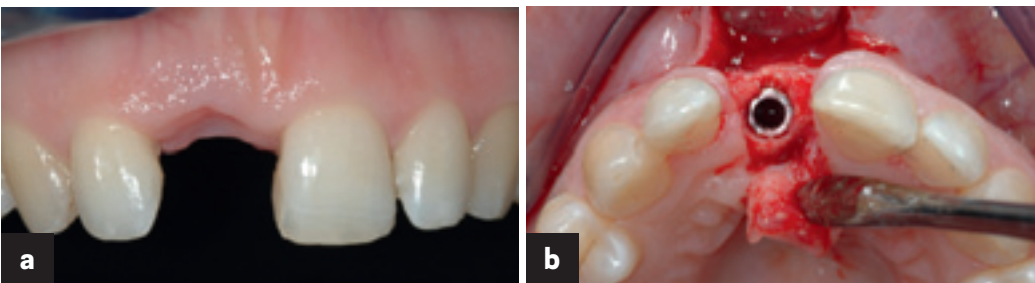Figs. 2a & b



Figs. 3a & b



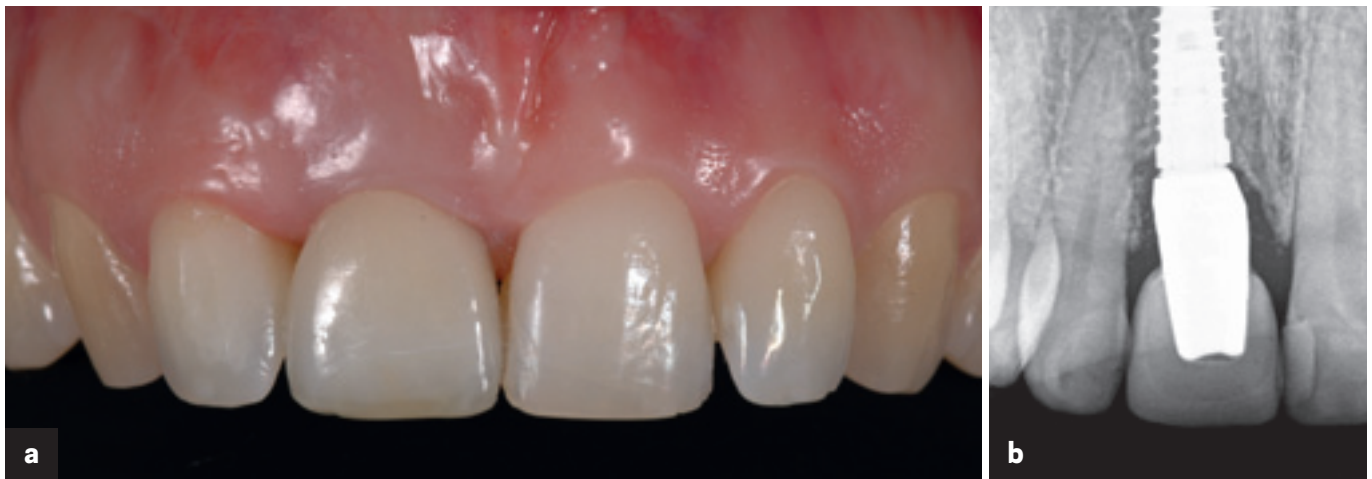Figs. 4a & b



uncovering/loading (4 months later; T<sup>2</sup>). The same clinicians who performed the tooth extractions and implant placement performed all of the measurements as follows: After tooth extraction (T<sup>0</sup>), the buccolingual dimension of the alveolar crest was measured from the inner

part of the buccal gingival margin to the inner part of the palatal soft tissue at the mesiodistal midpoint of the socket (BPS), 3 mm subgingivally, using a periodontal probe (PCPUNC 15; **Fig. 6**). Six months later, at (T<sup>1</sup>), a crestal incision was done and a full-thickness flap was





Figs. 5a &amp; b

**Figs. 5a & b**

The final restoration delivery at T<sup>2</sup> showed a good esthetic result (a) and marginal periimplant bone preserved at T<sup>3</sup> (b).

elevated in order to expose the edentulous ridge. Then the alveolar ridge thickness was measured from the buccal to the palatal side at the mesiodistal midpoint (BPW), as previously described (**Fig. 7**). Four months later, at (T<sup>2</sup>), the horizontal width of the ridge was measured buccally, starting from the outer part of the implant platform (BBT; **Fig. 8**).

- Marginal bone level changes were assessed using intraoral digital periapical radiographs taken with the paralleling technique at (T<sup>1</sup>) and 1 year after loading (T<sup>3</sup>), using a customized holder. The radiographs were accepted or rejected for evaluation based on the clarity of the implant threads. All readable radiographs were viewed in an image analysis program (Kodak Digital Imaging Software, Version 6.11.7.0, Eastman Kodak, Rochester, N.Y., U.S.) on a 24-in LCD screen (iMac, Apple, Cupertino, Calif., U.S.) and evaluated under standardized conditions (ISO 12646:2004). The software was calibrated for every image using the known implant diameter or length. The distance from the most coronal margin of the implant collar and the top of the bone crest was taken as marginal bone level. The average radiographic values of the mesial and distal measurements were taken for each implant at the time of implant placement and 6 months later. The difference between the marginal bone levels at various time points was taken as marginal bone loss (MBL). An independent radiologist performed all of the bone measurements.
- Gingival recession was evaluated using a reference line connecting the midfacial gingival level of the 2 adjacent teeth. The changes in the gingival margin of the implant restoration were evaluated before extraction (T<sup>0</sup>) and at T<sup>3</sup>.

All data analysis was carried out according to a pre-established analysis plan using software (IBM SPSS Statistics for Macintosh, Version 22.0, IBM, Armonk, N.Y., U.S.). Descriptive analysis was performed using mean and standard deviation. Comparison of the means was performed by paired tests. A biostatistician with expertise in dentistry analyzed the data.

## Results

In total, 47 teeth were extracted in 43 patients, 26 women and 17 men, with a mean age of 54 years (**Table 1**). At the last follow-up, no dropout and no deviation from the original protocol occurred. All 47 implants were osseointegrated and none of the prostheses failed. The follow-up ranged from a minimum of 1 year to a maximum of 3 years after loading.

In all of the treated cases, there was no dehiscence of the buccal or palatal portion of the implant at the moment of its exposure. There was no site infection either before or after the removal of the nonresorbable membrane, and no patient presented with edema or ecchymosis post-implant surgery.

The mean BPS at the midpoint was  $6.5 \pm 1.5$  mm at T<sup>0</sup>. At T<sup>1</sup>, the mean BPW was  $6.30 \pm 1.30$  mm, with a crestal reduction of  $0.19 \pm 0.34$  mm ( $P = 0.0006$ ), while at T<sup>2</sup>, the mean BBT was  $1.7 \pm 0.5$  mm. At T<sup>3</sup>, periapical radiographs revealed a marginal bone loss of  $0.62 \pm 0.16$  mm in the area surrounding the implant, compared with T<sup>0</sup>. At T<sup>3</sup>, a mean soft-tissue gain of  $0.8 \pm 0.2$  mm was recorded, with no buccal gingival recession compared with T<sup>0</sup>.

Fig. 6

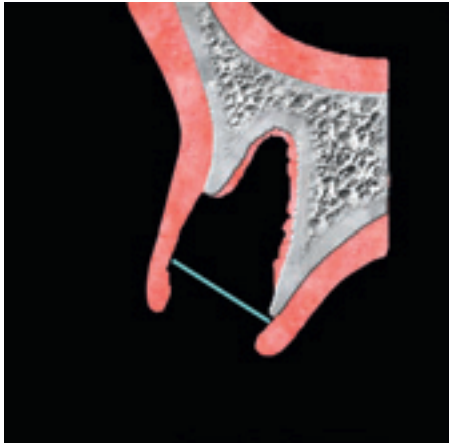


Fig. 7

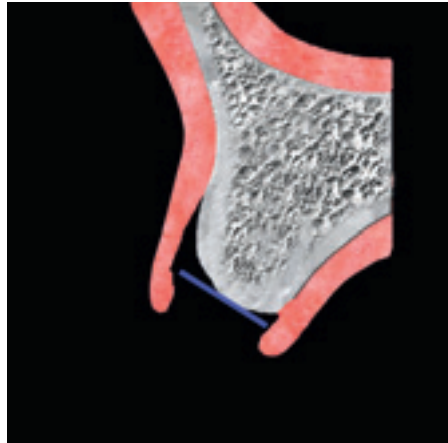


Fig. 8

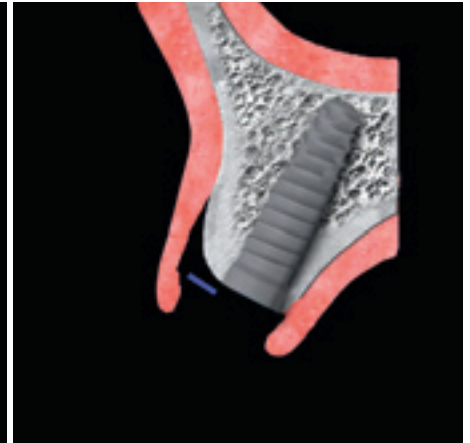


Table 1

Tooth	No.
Maxillary central incisor	12
Maxillary lateral incisor	5
Maxillary canine	7
Maxillary first premolar	4
Maxillary second premolar	3
Mandibular central incisor	3
Mandibular canine	4
Mandibular first premolar	6
Mandibular second premolar	3

## Discussion

This study has presented the results of a new technique for the spontaneous regeneration of the missing buccal plate of a dental socket that avoids the ingrowth of soft tissue inside it and regenerates the previously resorbed buccal cortical bone. This technique may avoid invasive further regenerative techniques, thus notably reducing treatment time without impairing the esthetic results, the predictability of the implant treatment or patient satisfaction.

A limiting situation for post-extraction implants, especially in areas of high esthetic concern, is the resorption of the buccal bone plate, which is fundamental for soft-tissue stability in the area surrounding the fixture and therefore for long-term esthetic results. The reconstruction of such a bone wall almost always requires an additional regenerative surgery, usually invasive for the patient, and precedes the prosthetically guided insertion of an implant. The use of a nonresorbable membrane intentionally left exposed inside the socket and removed after 4–6 weeks seems to work as a barrier in the separation of the soft tissue from

the bone graft.<sup>17</sup> The removal of the membrane after 4–6 weeks seems to give sufficient time to seclude fibroblasts from the gingival flap and to allow inside the socket the differentiation of mesenchymal cells into osteoblasts, leading then to bone. In a histological human study, a biopsy, taken at the moment of removal of a d-PTFE membrane left intentionally exposed for 28 days before, demonstrated the absence of epithelial tissue over a dense connective tissue matrix.<sup>12</sup> This finding indicates that this connective tissue seems to be a well-vascularized osteoid matrix that needs some more maturation time to become a mineralized tissue and allow placement of an implant.<sup>18</sup> This period can last from 3 to 6 months, depending on the size of the defect and the biomaterial used as a graft.

In another histological study, a combination of 70% mineralized and 30% demineralized cortical allograft material placed in a post-extraction socket together with a d-PTFE membrane intentionally left exposed was compared with a group for which only a mineralized allograft material was used. The biopsy showed increased vital bone formation (36.16%) and a reduced residual graft (18.24%) compared with the 100% mineralized bone allograft group (24.69% and 27.04%, respectively).<sup>19</sup>

In the present study, no infection of either the surrounding soft tissue or of the underlying graft was experienced owing to the low porosity of the d-PTFE membrane, which does not allow bacterial contamination. The nanoporosity of the d-PTFE membrane is about 0.2–0.3  $\mu$ , too small for the penetration of a bacterium, the size of which is about 5  $\mu$ . This was confirmed by a histological study in which a membrane, removed after 21 days, did not show any bacterial cell on the inferior border or surface.<sup>20</sup>

Fig. 6

BPS: the distance from the inner part of the buccal gingival margin to the inner part of the palatal soft tissue at the mesiodistal midpoint of the socket 3 mm subgingivally at T<sup>0</sup>.

Fig. 7

BPW: the alveolar ridge thickness from the buccal to the palatal side at the mesiodistal midpoint at T<sup>1</sup>.

Fig. 8

BBT: the horizontal width of the ridge measured from the outer part of the implant platform to the buccal bone at T<sup>2</sup>.

Table 1

Extracted teeth.

Another important result of this study is the regeneration of the most coronal part of the buccal plate with the combination of the ice-cream cone membrane technique and a nonresorbable membrane intentionally left exposed. The results of this study have shown that minimal crestal resorption occurs even if part of the buccal plate is missing. The minimal crestal resorption allows ideal implant placement with the presence of about 2 mm of residual buccal bone, fundamental to support the soft-tissue margins, avoiding in this way gingival recession. These results seem to be stable even 6 months after crown placement with creeping of the soft tissue on the buccal side compared with the initial situation. However, further histological studies are needed to validate these promising clinical results.

## Conclusion

Buccal plate reconstruction with an intentionally exposed nonresorbable membrane is an effective and easy procedure for regeneration of a resorbed buccal bone plate, especially after tooth extraction in the esthetic zone, where the stability of the periimplant tissue is fundamental.

## Competing interests

The authors declare that they have no conflict of interest regarding the materials used in the present study.

## References

- Tallarico M, Khanari E, Pisano M, De Riu G, Tullio A, Meloni SM. Single post-extractive ultra-wide 7 mm-diameter implants versus implants placed in molar healed sites after socket preservation for molar replacement: 6-month post-loading results from a randomised controlled trial. → *Eur J Oral Implantol*. 2016 Oct;9(3):263–75.
- Canullo L, Wiel Marin G, Tallarico M, Canciani E, Musto F, Dellavia C. Histological and histomorphometrical evaluation of postextractive sites grafted with mg-enriched nano-hydroxyapatite: a randomized controlled trial comparing 4 versus 12 months of healing. → *Clin Implant Dent Relat Res*. 2016 Oct;18(5):973–83.
- Tallarico M, Khanari E, Pisano M, Gatti F, Meloni SM. Molar replacement with 7 mm wide diameter implants: to place the implant immediately or to wait 4 months after socket preservation? 1 year loading results from a randomized controlled trial. → *Eur J Oral Implantol*. 2017 Sep;10(2):169–78.
- Buser D, Ingimarsson S, Dula K, Lussi A, Hirt HP, Belser UC. Long-term stability of osseointegrated implants in augmented bone: a 5-year prospective study in partially edentulous patients. → *Int J Periodontics Restorative Dent*. 2002 Apr;22(2):109–17.
- Urban IA, Jovanovic S, Lozada JL. Vertical ridge augmentation using guided bone regeneration (GBR) in three clinical scenarios prior to implant placement: a retrospective study of 35 patients 12 to 72 months after loading. → *Int J Oral Maxillofac Implants*. 2009 May-Jun;24(3):502–10.
- Urban IA, Caplanis N, Lozada JL. Simultaneous vertical guided bone regeneration and guided tissue regeneration in the posterior maxilla using recombinant human platelet-derived growth factor: a case report. → *J Oral Implantol*. 2009 Oct;35(5):251–6.
- Carbonell JM, Martín IS, Santos A, Pujol A, Sanz-Moliner JD, Nart J. High-density polytetrafluoroethylene membranes in guided bone and tissue regeneration procedures: a literature review. → *Int J Oral Maxillofac Surg*. 2014 Jan;43(1):75–84.
- Waasdorp J, Feldman S. Bone regeneration around immediate implants utilizing a dense polytetrafluoroethylene membrane without primary closure: a report of 3 cases. → *J Oral Implantol*. 2013 Jun;39(3):355–61. Epub 2011 Sep 9.
- Hoffmann O, Bartee BK, Beaumont C, Kasaj A, Deli G, Zafiropoulos GG. Alveolar bone preservation in extraction sockets using non-resorbable dPTFE membranes: a retrospective non-randomized study. → *J Periodontol*. 2008 Aug;79(8):1355–69.
- Barber HD, Lignelli J, Smith BM, Bartee BK. Using a dense PTFE membrane without primary closure to achieve bone and tissue regeneration. → *J Oral Maxillofac Surg*. 2007 Apr;65(4):748–52.
- Monteiro AS, Macedo LG, Macedo NL, Balducci I. Polyurethane and PTFE membranes for guided bone regeneration: histopathological and ultrastructural evaluation. → *Med Oral Patol Oral Cir Bucal*. 2010 Mar;15(2):e401–6.
- Laurito D, Cugnetto R, Lollobrigida M, Guerra F, Vestri A, Gianni F, Bosco S, Lamazza L, De Biase A. Socket preservation with d-PTFE membrane: histologic analysis of the newly formed matrix at membrane removal. → *Int J Periodontics Restorative Dent*. 2016 Nov/Dec;36(6):877–83.
- Bartee BK. Evaluation of a new polytetrafluoroethylene guided tissue regeneration membrane in healing extraction sites. → *Compend Contin Educ Dent*. 1998 Dec;19(12):1256–8, 1260, 1262–4.
- Elm von E, Altman DG, Egger M, Pocock SJ, Gøtzsche PC, Vandenbroucke JP; STROBE Initiative. Strengthening of Reporting of Observational Studies in Epidemiology (STROBE) statement: guidelines for reporting observational studies. → *BMJ*. 2007 Oct 20;335(7624):806–8.
- Elia N, Cho SC, Froum S, Smith RB, Tarnow DP. A simplified socket classification and repair technique. → *Pract Proced Aesthet Dent*. 2007 Mar;19(2):99–104; quiz 106.
- Tan-Chu JH, Tuminelli FJ, Kurtz KS, Tarnow DP. Analysis of buccolingual dimensional changes of the extraction socket using the "ice cream cone" flapless grafting technique. → *Int J Periodontics Restorative Dent*. 2014 May-Jun;34(3):399–403.
- Bartee BK. A simplified technique for ridge preservation after tooth extraction. → *Dent Today*. 1995 Oct;14(10):62–7.
- Beck TM, Mealey BL. Histologic analysis of healing after tooth extraction with ridge preservation using mineralized human bone allograft. → *J Periodontol*. 2010 Dec;81(12):1765–72.
- Borg TD, Mealey BL. Histologic healing following tooth extraction with ridge preservation using mineralized versus combined mineralized-demineralized freeze-dried bone allograft: a randomized controlled clinical trial. → *J Periodontol*. 2015 Mar;86(3):348–55.
- Krauser JT. High-density PTFE membranes: uses with root-form implants. → *Dent Implantol Update*. 1996 Sep;7(9):65–9.

# The Dental Tribune International Magazines

[www.dental-tribune.com](http://www.dental-tribune.com)

## I would like to subscribe to

- |  |  |
|--|--|
| <input type="checkbox"/> CAD/CAM             | <input type="checkbox"/> ortho**                 |
| <input type="checkbox"/> Clinical Masters*   | <input type="checkbox"/> prevention*             |
| <input type="checkbox"/> cosmetic dentistry* | <input type="checkbox"/> roots                   |
| <input type="checkbox"/> implants            | <input type="checkbox"/> Journal of Oral Science |
| <input type="checkbox"/> laser               | & Rehabilitation***                              |

EUR 44 per year (4 issues per year; incl. shipping and VAT for customers in Germany) and EUR 46 per year (4 issues per year; incl. shipping for customers outside Germany).

\* EUR 12 per year (1 issue per year; incl. shipping and VAT for customers in Germany) and EUR 14 per year (1 issue per year; incl. shipping for customers outside Germany).

\*\* EUR 22 per year (2 issues per year; incl. shipping and VAT for customers in Germany) and EUR 23 per year (2 issues per year; incl. shipping for customers outside Germany).

\*\*\* EUR 200 per year (4 issues per year; incl. shipping and VAT).

Your subscription will be renewed automatically every year until a written cancellation is sent to Dental Tribune International GmbH, Holbeinstr. 29, 04229 Leipzig, Germany, six weeks prior to the renewal date.

## Shipping Address

Name	
Address	
Zip Code, City	Country
E-mail	
Date, Signature	

☐ PayPal ☐ Credit Card

Credit Card Number

Expiration Date

Security Code

## SUBSCRIBE NOW!

F +49 341 48474 173  
[subscriptions@dental-tribune.com](mailto:subscriptions@dental-tribune.com)

**dti** Dental  
Tribune  
International



# Periimplant soft-tissue and bone levels around dental implants with different neck designs and neck surface treatments: A retrospective cohort study with 3-year follow-up

## Abstract

### Objective

The objective of the study was to assess the influence of the implant neck designs and neck surface treatments on periimplant tissue health and radiographic bone loss after 3 years of functional loading of implants with the same body and prosthetic connection.

### Materials and methods

A retrospective cohort study was carried out in the Oral Surgery and Implantology Unit of the University of Valencia, Valencia, Spain. Patients treated with implants presenting a neck design without microthreads and a 1.5 mm machined surface and implants with a 0.7 mm machined surface and microthreads with a rough surface with a minimum of 3 years of follow-up were included. Probing pocket depth, bleeding on probing, presence of mucositis and width of keratinized mucosa were assessed 3 years after prosthesis placement. Marginal bone loss was measured in intraoral radiographs by calculating the difference between the measurements at the prosthesis placement and 3 years after loading.

### Results

The final sample consisted of 27 partially edentulous patients with a total of 51 dental implants. No significant differences were observed on evaluating probing pocket depth ( $P = 0.195$ ), bleeding on probing ( $P = 0.524$ ), presence of mucositis ( $P = 0.916$ ), width of keratinized mucosa ( $P = 0.435$ ) and marginal bone loss ( $P = 0.217$ ) between both groups.

### Conclusion

Within the limitations of the present investigation, implant neck designs and neck surface treatments were not significantly related to periimplant tissue health and radiographic bone loss after 3 years of follow-up.

### Keywords

Periimplant hard tissue, periimplant soft tissue, radiology, CT imaging, clinical research, clinical trials.

Natalia Ribes Lainez,<sup>a</sup> Alba Monreal Bello,<sup>a</sup>  
María Ángeles Fuster Torres,<sup>a</sup> David Peñarrocha Oltra<sup>a</sup>  
& Miguel Peñarrocha Diago<sup>a</sup>

<sup>a</sup> Stomatology Department, Faculty of Medicine and  
Dentistry, University of Valencia, Valencia, Spain

### Corresponding author:

**Dr. David Peñarrocha Oltra**  
Cirugía Bucal. Clínicas Odontológicas  
C/Gascó Oliag, 1  
46021 Valencia  
Spain

T +34 963 86 4144  
david.penarrocha@uv.es

### How to cite this article:

Ribes Lainez N, Monreal Bello A, Fuster Torres MA,  
Peñarrocha Oltra D, Peñarrocha Diago M. Periimplant  
soft-tissue and bone levels around dental implants  
with different neck designs and neck surface treatments:  
A retrospective cohort study with 3-year follow-up.  
J Oral Science Rehabilitation. 2017 Dec;3(4):16–23.

## Introduction

Bone loss after implant integration and through time of function usually begins at the neck and spreads to the first thread of the body or to the first contact between the bone and the rough surface of the implant,<sup>1</sup> and can be divided into 2 different phases depending on the time of occurrence.<sup>2–5</sup> The first, early bone loss, is related to re-entry surgery after the healing time or prosthetic connection,<sup>6</sup> and the second, late bone loss, emerges during the time of implant and prosthesis function.<sup>4,7,8</sup> Criteria for evaluation of implant success are generally based on clinical and radiological aspects, such as probing depth, implant mobility and periimplant bone changes.<sup>9</sup> It has been reported that the criteria for successful implant therapy include a median marginal bone loss of <1–1.5 mm during the first year, followed by an annual rate of vertical bone loss of  $\leq 0.2$  mm.<sup>10</sup>

In the last few decades, it has been suggested that marginal bone loss is dependent on several factors, such as the implant neck surface design<sup>1,4,11–13</sup> and characteristics.<sup>14,15</sup> It has been proposed that bone retention elements such as microthreads and a rough surface at the implant neck might help stabilize the marginal bone.<sup>1,12,16,17</sup> Although the conventional smooth implant neck allows the least accumulation of plaque,<sup>18,19</sup> several studies have evaluated marginal bone loss according to the implant neck involved—machined implant necks and rough necks with microthreads—and have shown more marginal bone loss around these implants compared with implants with a rough surface topography at the implant neck.<sup>4,12,13,20</sup> The relatively smooth, machined coronal portion is designed to end slightly above the gingival margin of the periimplant soft tissue, thus making the microgap or interface between implant and restoration easily accessible for oral hygiene and resulting in a supragingival location of the crown margin.<sup>21</sup> Lang et al. in a consensus report concluded that prospective controlled studies on the effects of different implant designs and surfaces had demonstrated that marginal bone levels were generally well preserved after installation of the dental prosthesis (at least for fixed restorations) on a variety of implant types (cumulative bone loss: < 0.5 mm after 3 years).<sup>11</sup> However, these studies had a 1-year follow-up and there are no clinical studies comparing the long-term influence of different designs and

surface treatments of implant necks on periimplant tissue. The purpose of this study was to assess the effect of the implant neck designs and neck surface treatments on periimplant tissue health and radiographic bone loss after 3 years of functional loading of implants with the same body and prosthetic connection but different neck designs.


## Materials and methods

### Study design and sample

A retrospective cohort study was carried out in the Oral Surgery and Implantology Unit of the University of Valencia, Valencia, Spain, between September 2015 and December 2016. This study complied with the ethical principles for medical research involving human subjects established in the Declaration of Helsinki of 1975, as revised in 2013, of the World Medical Assembly. All of the patients received information about the study and were asked to sign a written informed consent form before taking part. The study design was approved by the ethics board of the University of Valencia (approval number: H1467620442582).

Patients who had received single or partial prosthetic rehabilitations on TSA or TSA Advance implants (Phibo, Barcelona, Spain), had a minimum of 3 years of follow-up and who agreed to participate in the study and signed an informed consent were included. Patients who had undergone bone grafting procedures (block bone grafts or guided bone regeneration), had immediate post-extraction implants, had systemic diseases, were undergoing drug treatments capable of affecting gingival health, or had a history of bisphosphonate use during control visits, as well as pregnant or nursing women and patients with missing information, were excluded. Patients were classified into 2 cohorts according to the implant design:

- group A (TSA): patients treated with implants presenting a neck design without microthreads, with a 1.5 mm machined surface and an internal connection and without platform switching (**Fig. 1a**); and
- group B (TSA Advance): patients treated with implants presenting a neck design with a 0.7 mm machined surface and microthreads with a rough surface and an internal connection and without platform switching (**Fig. 1b**).



**Figs. 1a & b**

Macrodesign of (a) TSA and (b) TSA Advance implants.

### Surgical procedure

The surgery was performed under local anesthesia with 4% articaine with 1:100,000 epinephrine (Inibsa, Lliçà de Vall, Spain). A crestal incision was made, and a full-thickness mucoperiosteal flap was raised. The drilling sequence recommended by the manufacturer was followed. Implants were placed at a torque of 35 N and positioned with the limit between rough and polished surfaces at crestal level. Suturing was carried out with 4-0 sutures (Supramid, B. Braun, Barcelona, Spain).

All of the patients received postoperative treatment: 500 mg of amoxicillin (Clamoxyl, GlaxoSmithKline, Madrid, Spain) 3 times daily for 7 days, 600 mg of ibuprofen (Bexistar, Bacino, Barcelona, Spain) to be taken as needed, a 0.12% chlorhexidine mouthwash (GUM, Sunstar, Chicago, Ill., U.S.) twice daily for 2 weeks and brushing with a chlorhexidine toothpaste. The sutures were removed 8–10 days after surgery.

### Data collection and follow-up

All of the surgeries were carried out by 1 experienced surgeon (MPD) and control visits were performed by 2 trained and calibrated clinicians at prosthesis placement ( $T^0$ ) and at 6 and 12 months and 3 years after prosthesis placement ( $T^1$ ).

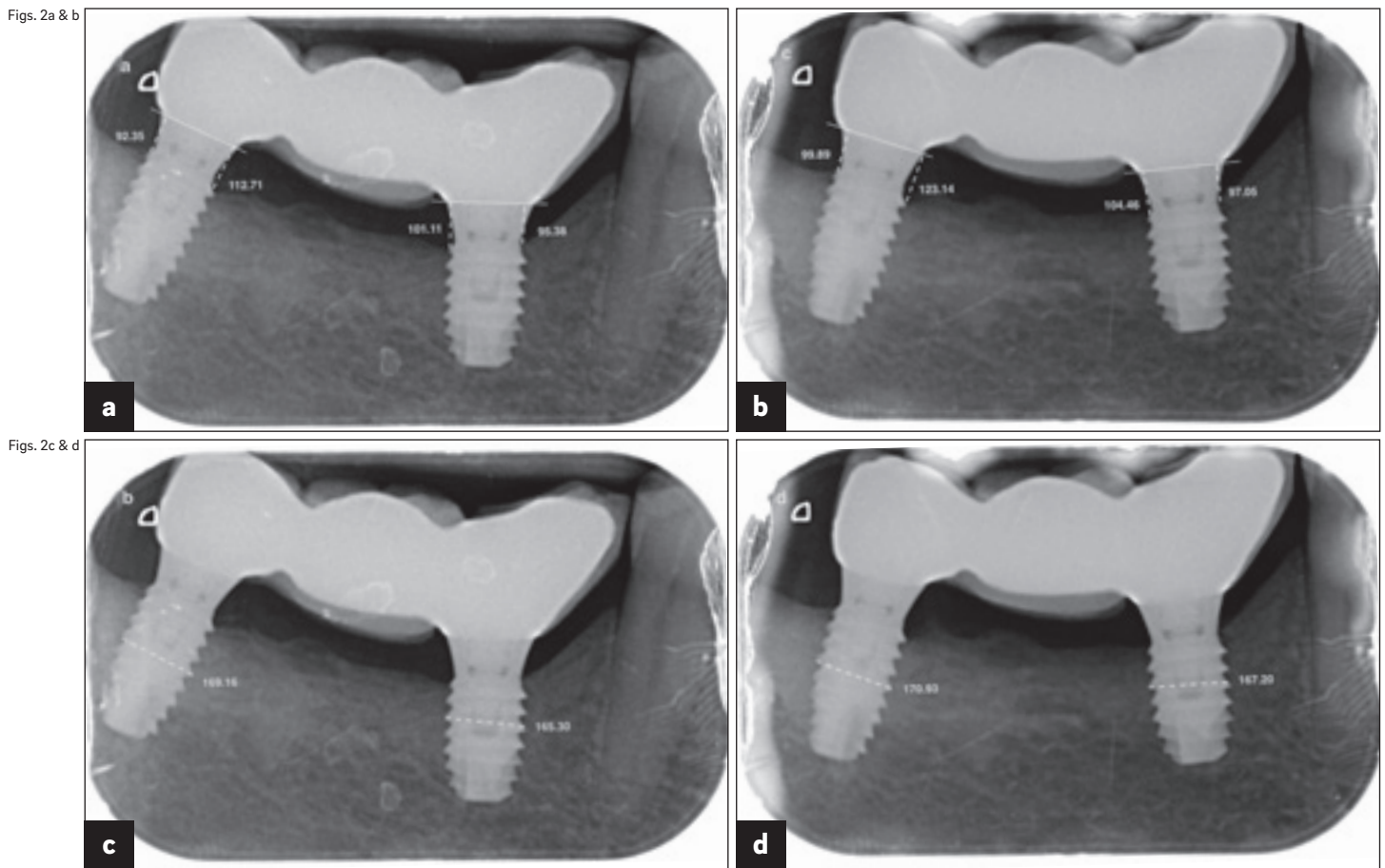
The following variables were collected retrospectively: sex, age, smoking habit (<10 cigarettes/day, 10–20 cigarettes/day, >20 cigarettes/day), implant diameter and length, implant position (anterior, premolar or molar), arch (maxilla or mandible) and antagonist teeth (natural, implant,

absent). A millimetric calibrated periodontal probe (Hawe Neos Probe 1395, Hawe, U.K.) was used to assess the following clinical variables:

- probing pocket depth (PPD), measured from the gingival margin to the deepest part of the periimplant pocket, at 6 locations per implant (mesiobuccal, buccal, distobuccal, mesiolingual/-palatal, lingual/palatal and distolingual/-palatal) choosing the largest value;
- bleeding on probing (BoP);
- presence of mucositis, understood as inflammation of the periimplant mucosa without progressing to crestal bone loss;<sup>22</sup> and
- width of keratinized mucosa in the buccal and lingual region.

Intraoral radiographs were used to measure marginal bone loss. Radiographic exploration was carried out using the intraoral XMind system (Groupe Satelec-Pierre Rolland, Bordeaux, France) and the RVG intraoral digital sensor (Kodak Dental System, Atlanta, Ga., U.S.). In order to reproduce the X-ray angles in posterior reviews, XCP positioners were used (DENTSPLY, Des Plaines, Ill., U.S.), placing the guide bar parallel to the direction of the X-ray beam and perpendicular to the digital sensor.

All of the measurements were carried out by 2 examiners (different from the surgeon), who were initially calibrated to evaluate the interexaminer error using the Dahlberg formula and coefficient of variation. Each examiner measured 30 radiographs to evaluate the interexaminer error. The error according to Dahlberg's test ranged between 0.63 and 0.93 mm for the various parameters and the coefficient of variation between 5.2% and 6.4%.



**Figs. 2a–d**

Adimensional measurements of marginal bone loss (a) at prosthesis placement and (b) after 3 years of follow-up. Adimensional measurements across the implant diameter with the objective of calibrating the bone level measurements, knowing the true width of the implant: calibration of (c) the prosthesis placement and (d) the 3-year follow-up radiographs.

Marginal bone loss was measured with the software ImageJ (National Institute of Health, Md., U.S.) to process JPG files as obtained from intra-oral radiographs. Two reference points were marked on each implant at the implant–prosthesis interface and joined with a line representing height 0. Two vertical lines were traced perpendicular to the 0 line up to the first mesial and distal bone–implant contacts (**Figs. 2a & b**). Differences between these perpendicular lines in radiographs taken at the different time points ( $T^0$  and  $T^1$ ) were used to calculate bone loss. The highest difference value was chosen between the mesial and the distal values. A line was traced across the implant diameter (**Figs. 2c & d**) with the objective of calibrating the periapical radiograph measurements, knowing the true width of the implant.

#### Statistical analysis

The principal predictor variable was the implant neck designs and neck surface treatments (group A and group B). The outcome variables

of interest were periimplant tissue health and radiographic bone loss after 3 years of functional loading.

A descriptive analysis of the parameters was performed. Sample distribution of bone loss was assessed, and due to lack of adjustment to normal distribution and dependence of observations, the corresponding nonparametric tests were applied: method for longitudinal data of Brunner and Langer, providing an analysis of variance statistic. Generalized estimating equations models were estimated to analyze the probability of the neck design affecting the various clinical variables through the Wald chi-squared statistic. For the variables BoP and presence of mucositis, a binary logistic regression model was estimated. For PPD and width of keratinized mucosa, an ordinal logistic regression model was estimated. The statistical analysis was performed using SPSS (statistical package for Microsoft Windows, Version 15.0, SPSS, Chicago, Ill., U.S.) and R software (Version 2.15.0, R Foundation for Statistical Computing, Vienna, Austria). The



significance level was set at  $P < 0.05$ . The statistical methodology, with a confidence level of 95% and the median effect size to detect  $f = 0.25$ , reached a power of 0.81 for the contrast of the interaction effect (homogeneity of bone loss in the groups).

## Results

Fifty-five patients fulfilled the inclusion criteria. Patients who had undergone guided bone regeneration ( $n = 9$ ), had immediate implants ( $n = 3$ ), had missing information ( $n = 8$ ) or failed to attend control visits ( $n = 6$ ) were excluded. The final sample consisted of 27 partially edentulous patients, 12 women and 15 men (mean age:  $63.5 \pm 11.6$ ), with a total of 51 dental implants: 13 patients with 28 implants (group A) and 14 patients with 23 implants (group B). In group A, 22% were smokers, and in group B, 44%. The implant sample was homogeneous regarding the implant diameter, length and position, arch and antagonist dentition (**Table 1**).

No significant differences were observed on evaluating clinical variables (**Table 2**). Higher PPD was measured in group B ( $5.3 \pm 0.9$  mm) compared with group A ( $4.8 \pm 1.4$  mm), with no statistically significant differences ( $P = 0.195$ ). Group A showed lower BoP (47.1%) compared with group B (60%), although the odds ratio suggested an increased BoP risk with a TSA Advance implant (+27%), but there was insufficient statistical evidence to conclude a true effect ( $P = 0.524$ ). Mucositis was present in 14.3% in group B and 12.5% in group A, and the odds ratio suggested a higher risk of mucositis with a TSA Advance implant (14%), with no statistically significant differences between the groups ( $P = 0.916$ ). The higher score on width of keratinized mucosa was found in group A ( $3.50 \pm 2.44$  mm) in comparison with group B ( $2.7 \pm 2.4$  mm); however, no statistically significant difference was found ( $P = 0.435$ ). The mean radiographic marginal bone loss with the TSA implants was  $0.57 \pm 0.55$  mm (range: 0.00–2.10 mm) and with the TSA Advance implants was  $0.46 \pm 0.49$  mm (range: 0.00–1.61 mm), and the median was 0.47 mm for the TSA implants and 0.25 mm for the TSA Advance implants (**Table 3**). Despite the greater marginal bone loss around TSA implants, no statistically significant differences were observed ( $P = 0.217$ ).

## Discussion

This study evaluated and compared 2 implants with the same body and prosthetic connection, but with different neck designs after 3 years of follow-up to assess the influence of these variables on periimplant tissue health and radiographic bone loss. The present study did not find statistical differences between the 2 implants on evaluating PPD, BoP, presence of mucositis, width of keratinized mucosa and marginal bone loss.

It has been suggested that the initial marginal bone level change occurs as an adaptation of the periimplant bone to the occlusal load.<sup>23–26</sup> In studies involving a follow-up of over year,<sup>1,23–26</sup> the greatest bone loss was observed during the first year and then bone loss gradually decreased. The addition of threads or microthreads up to the crestal module of an implant might provide a potentially positive contribution to bone–implant contact, as well as improve preservation of marginal bone.<sup>4, 20, 23, 27</sup> Shin et al. observed that the most effective design for minimizing marginal bone loss during functional loading was a rough surface with microthreads at the implant neck.<sup>12</sup> Abrahamsson and Berglundh drew a similar conclusion in an experimental study in dogs.<sup>28</sup> They found that the degree of bone–implant contact within the marginal portion of the implants was significantly higher for the microthreaded implants compared with the implants with polished necks. Lee et al., in a well-controlled split-mouth study, also found that implants with microthreads showed significantly less bone loss compared with implants without them.<sup>2</sup> However, although the studied implants were of the same brand and surface characteristics, they differed in their macrodesign: one had a tapered neck and the other had a cylindrical design. In the present study, both implant models, although distinct in thread configuration, had a tapered design. Bratu et al. compared implants of the same brand and with the same dimensions, taper, titanium alloy and surface characteristics but different neck designs: one model with a polished neck and the other with a rough surface and microthreads up to its prosthetic platform.<sup>5</sup> Unlike the present study, the implants with a rough surface and microthreads displayed statistically significantly less early marginal bone loss and greater bone level stability compared with the polished-neck implants. The results of Piao et al. demonstrated that the amount of marginal bone loss at 12 months of functional loading was significantly

Table 1

		TSA	TSA Advance	P value (chi <sup>2</sup> )
Implant diameter (mm)	3.6	2	1	0.547
	4.2	14	15	
	5.5	12	7	
Implant position	Incisor	0	1	0.519
	Canine	1	0	
	Premolar	11	7	
	Molar	16	15	
Arch	Maxilla	0	9	0.802
	Mandible	8	14	
Antagonist	Natural tooth	8	18	0.276
	Implant	10	5	

Table 1

Descriptive statistics of the implant sample.

Table 2

Statistical results regarding periimplant clinical variables.

Table 3

Radiographic marginal bone loss.

Table 2

	TSA	TSA Advance	Odds ratio	P value
Probing pocket depth	4.8 ± 1.4 mm	5.3 ± 0.9 mm		0.195
Bleeding on probing	47.1%	60%	1.27	0.524
Presence of mucositis	12.5%	14.3%	1.14	0.916
Width of keratinized mucosa	3.50 ± 2.44 mm	2.70 ± 2.40 mm		0.435

Table 3

	Total	TSA	TSA Advance
n	51	28	23
Mean	0.52	0.57	0.46
Standard deviation	0.52	0.55	0.49
Minimum	-0.22	0.00	-0.22
Maximum	2.10	2.10	1.61
Median	0.39	0.47	0.25

different among the 3 groups they analyzed: The rough-surfaced microthread implant group showed less bone loss than the rough-surfaced implant group and the machined hybrid design implant group, but these implants had some differences other than the configuration of the coronal part, so these might have impacted on the results.<sup>20</sup>

Some studies have compared polished-neck implants to rough-neck implants and found significantly greater bone loss with the polished-neck implants.<sup>4, 12, 13, 25, 29–32</sup> In contrast, others have found no statistically significant differences in bone loss.<sup>20, 24, 25, 33, 34</sup> Some studies have evaluated the presence of microthreads at the coronal portion using radiographic evaluation of the marginal bone level and found a positive effect in maintaining the marginal bone level for rough-surfaced implants with

microthreads at the coronal portion after functional loading.<sup>1, 13, 20, 35–36</sup> However, Van de Velde et al. observed that, after 1 year of loading, a microthread design of the implant collar did not seem to improve bone preservation in the mandible.<sup>38</sup> Aloy-Prósper et al. in their literature review found that marginal bone loss with polished-neck implants was greater 3 months after implant placement, while bone loss with rough-neck implants with and without microthreads was greater 6 months after insertion of the implants.<sup>39</sup> Lang et al. in a consensus report concluded that prospective controlled studies on the effects of different implant designs and surfaces demonstrated that marginal bone levels were generally well preserved after installation of the dental prosthesis (at least for fixed restorations) on a variety of implant types (cumulative bone loss: < 0.5 mm after 3 years).<sup>11</sup>

Most of the studies measured bone loss from the start of prosthetic loading to the end of follow-up, except Nickenig et al., who measured loss from the time of placement of the implants.<sup>14</sup> They compared smooth and rough implants for restoring missing mandibular molars. In their study, for smooth implants, bone loss progressed from 0.5 mm in the healing period to 1.1, 1.3 and 1.4 mm in the second, third and fifth year of follow-up, respectively. In contrast, for the rough-surfaced, microthreaded implants, bone loss progressed from 0.1 mm in the healing period to 0.5, 0.6 and 0.7 mm in the second, third and fifth year of follow-up, respectively. They found a significant difference in bone level changes, suggesting that rough-surfaced, microthreaded implants more effectively minimized overall marginal bone loss than machined-neck implants did, particularly during the healing period.

Even if some studies have shown less marginal bone loss around implants with a rough neck, these implants favor bacterial plaque retention when exposed to the oral environment, and this in turn would imply an increased risk of periimplant disease such as mucositis or periimplantitis.<sup>40,41</sup> The relatively smooth implant neck allows the least accumulation of plaque<sup>18,19</sup> and

is designed as a transmucosal component, thus making the microgap or interface between implant and restoration easily accessible for oral hygiene.<sup>21</sup>

Taking into account the results, it is necessary to highlight the limitations of the present study. Sample size and the lack of randomization could limit generalization of the results. Further studies with a larger sample are needed to clarify the influence of implant neck design on periimplant tissue health and periimplant bone remodeling after medium- to long-term functional loading.

## Conclusion

According to the results of the present study, the implant neck designs and neck surface treatments did not significantly influence periimplant tissue health and radiographic bone loss after 3 years of follow-up.

## Competing interests

The authors declare that they have no competing interests.

## References

- Albrektsson T, Zarb G, Worthington P, Eriksson AR. The long-term efficacy of currently used dental implants: a review and proposed criteria of success. → *Int J Oral Maxillofac Implants*. 1986 Summer;1(1):11–25.
- Lee DW, Choi YS, Park KH, Kim CS, Moon IS. Effect of microthread on the maintenance of marginal bone level: a 3-year prospective study. → *Clin Oral Implants Res*. 2007 Aug;18(4):465–70.
- Manz MC. Factors associated with radiographic vertical bone loss around implants placed in a clinical study. → *Ann Periodontol*. 2000 Dec;5(1):137–51.
- Spray JR, Black CG, Morris HF, Ochi S. The influence of bone thickness on facial marginal bone response: stage 1 placement through stage 2 uncovering. → *Ann Periodontol*. 2000 Dec;5(1):119–28.
- Bratu EA, Tandlich M, Shapira L. A rough surface implant neck with microthreads reduces the amount of marginal bone loss: a prospective clinical study. → *Clin Oral Implants Res*. 2009 Aug;20(8):827–32.
- Hartman GA, Cochran DL. Initial implant position determines the magnitude of crestal bone remodeling. → *J Periodontol*. 2004 Apr;75(4):572–7.
- Oh TJ, Yoon J, Misch CE, Wang HL. The causes of early implant bone loss: myth or science? → *J Periodontol*. 2002 Mar;73(3):322–33.
- Kronström M, Svenson B, Hellman M, Persson GR. Early implant failures in patients treated with Brånemark System titanium dental implants: a retrospective study. → *Int J Oral Maxillofac Implants*. 2001 Mar–Apr;16(2):201–7.
- Esposito M, Hirsch JM, Lekholm U, Thomsen P. Biological factors contributing to failures of osseointegrated oral implants. (II). Etiopathogenesis. → *Eur J Oral Sci*. 1998 Jun;106(3):721–64.
- Misch CE, Perel ML, Wang HL, Sammartino G, Galindo-Moreno P, Trisi P, Steigmann M, Rebaudi A, Palti A, Pikos MA, Schwartz-Arad D, Choukroun J, Gutierrez-Perez JL, Marenzi G, Valavanis DK. Implant success, survival, and failure: the International Congress of Oral Implantologists (ICOI) Pisa Consensus Conference. → *Implant Dent*. 2008 Mar;17(1):5–15.
- Lang NP, Jepsen S; Working Group 4. Implant surfaces and design (Working Group 4). → *Clin Oral Implants Res*. 2009 Sep;20 Suppl 4:228–31.
- Shin YK, Han CH, Heo SJ, Kim S, Chun HJ. Radiographic evaluation of marginal bone level around implants with different neck designs after 1 year. → *Int J Oral Maxillofac Implants*. 2006 Sep–Oct;21(5):789–94.
- Nickenig HJ, Wichmann M, Schlegel KA, Nkenke E, Eitner S. Radiographic evaluation of marginal bone levels adjacent to parallel-screw cylinder machined-neck implants and rough-surfaced microthreaded implants using digitized panoramic radiographs. → *Clin Oral Implants Res*. 2009 Jun;20(6):550–4.
- Nickenig HJ, Wichmann M, Happe A, Zöller JE, Eitner S. A 5-year prospective radiographic evaluation of marginal bone levels adjacent to parallel-screw cylinder machined-neck implants and rough-surfaced microthreaded implants using digitized panoramic radiographs. → *J Craniomaxillofac Surg*. 2013 Oct;41(7):564–8.

15. Peñarrocha M, Palomar M, Sanchis JM, Guarinos J, Balaguer J. Radiologic study of marginal bone loss around 108 dental implants and its relationship to smoking, implant location, and morphology. → *Int J Oral Maxillofac Implants*. 2004 Nov–Dec;19(6):861–7.
16. Hansson S. The implant neck: smooth or provided with retention elements. A biomechanical approach. → *Clin Oral Implants Res*. 1999 Oct;10(5):394–405.
17. Tan WC, Lang NP, Schmidlin K, Zwahlen M, Pjetursson BE. The effect of different implant neck configurations on soft and hard tissue healing: a randomized-controlled clinical trial. → *Clin Oral Implants Res*. 2011 Jan;22(1):14–9.
18. Teughels W, Van Assche N, Sliepen I, Quirynen M. Effect of material characteristics and/or surface topography on biofilm development. → *Clin Oral Implants Res*. 2006 Oct;17 Suppl 2:68–81.
19. Baldi D, Menini M, Pera F, Ravera G, Pera P. Plaque accumulation on exposed titanium surfaces and peri-implant tissue behavior. A preliminary 1-year clinical study. → *Int J Prosthodont*. 2009 Sep–Oct;22(5):447–55.
20. Piao CM, Lee JE, Koak JY, Kim SK, Rhyu IC, Han CH, Herr Y, Heo SJ. Marginal bone loss around three different implant systems: radiographic evaluation after 1 year. → *J Oral Rehabil*. 2009 Oct;36(10):748–54.
21. Hänggi MP, Hänggi DC, Schoolfield JD, Meyer J, Cochran DL, Hermann JS. Crestal bone changes around titanium implants. Part I: a retrospective radiographic evaluation in humans comparing two non-submerged implant designs with different machined collar lengths. → *J Periodontol*. 2005 May;76(5):791–802.
22. Albrektsson T, Buser D, Chen ST, Cochran D, DeBruyn H, Jemt T, Koka S, Nevins M, Sennerby L, Simion M, Taylor TD, Wennerberg A. Statements from the Estepona consensus meeting on peri-implantitis, February 2–4, 2012. → *Clin Implant Dent Relat Res*. 2012 Dec;14(6):781–2.
23. Puchades-Roman L, Palmer RM, Palmer PJ, Howe LC, Ide M, Wilson RF. A clinical, radiographic, and microbiologic comparison of Astra Tech and Brånemark single tooth implants. → *Clin Implant Dent Relat Res*. 2000 Apr;2(2):78–84.
24. Hallman M, Mordenfeld A, Strandkvist T. A retrospective 5-year follow-up study of two different titanium implant surfaces used after interpositional bone grafting for reconstruction of the atrophic edentulous maxilla. → *Clin Implant Dent Relat Res*. 2005 Jul;7(3):121–6.
25. Karlsson U, Gotfredsen K, Olsson C. A 2-year report on maxillary and mandibular fixed partial dentures supported by Astra Tech dental implants. A comparison of 2 implants with different surface textures. → *Clin Oral Implants Res*. 1998 Aug;9(4):235–42.
26. Van Steenberghe D, De Mars G, Quirynen M, Jacobs R, Naert I. A prospective split-mouth comparative study of two screw-shaped self-tapping pure titanium implant systems. → *Clin Oral Implants Res*. 2000 Jun;11(3):202–9.
27. Abuhussein H, Pagni G, Rebaudi A, Wang H. The effect of thread pattern upon implant osseointegration. → *Clin Oral Implants Res*. 2010 Feb;21(2):129–36.
28. Abrahamsson I, Berglundh T. Effects of different implant surfaces and designs on marginal bone-level alterations: a review. → *Clin Oral Implants Res*. 2009 Sep;20 Suppl 4:207–15.
29. Zechner W, Trinkl N, Watzek G, Busenlechner D, Tepper G, Haas R, Watzek G. Radiologic follow-up of peri-implant bone loss around machine-surfaced and rough-surfaced interforaminal implants in the mandible functionally loaded for 3 to 7 years. → *Int J Oral Maxillofac Implants*. 2004 Mar–Apr;19(2):216–21.
30. Hermann JS, Buser D, Schenk RK, Cochran DL. Crestal bone changes around titanium implants. A histometric evaluation of unloaded non-submerged and submerged implants in the canine mandible. → *J Periodontol*. 2000 Sep;71(9):1412–24.
31. Stein AE, McGlimphy EA, Johnston WM, Larsen PE. Effects of implant design and surface roughness on crestal bone and soft tissue levels in the esthetic zone. → *Int J Oral Maxillofac Implants*. 2009 Sep–Oct;24(5):910–9.
32. Schwarz F, Herten M, Bieling K, Becker J. Crestal bone changes at nonsubmerged implants (Camlog) with different machined collar lengths: a histomorphometric pilot study in dogs. → *Int J Oral Maxillofac Implants*. 2008 Mar–Apr;23(2):335–42.
33. Astrand P, Engquist B, Dahlgren S, Gröndahl K, Engquist E, Feldmann H. Astra Tech and Brånemark implants: a 5-year prospective study of marginal bone reactions. → *Clin Oral Implants Res*. 2004 Aug;15(4):413–20.
34. Den Hartog L, Meijer HJ, Stegenga B, Tymstra N, Vissink A, Raghoobar GM. Single implants with different neck designs in the aesthetic zone: a randomized clinical trial. → *Clin Oral Implants Res*. 2011 Nov;22(11):1289–97.
35. Norton MR. Marginal bone levels at single tooth implants with a conical fixture design. The influence of surface macro- and microstructure. → *Clin Oral Implants Res*. 1998 Apr;9(2):91–9.
36. Deppe H, Horch H, Kolk A. Microstructured dental implants and palatal mucosal grafts in cleft patients: a retrospective analysis. → *J Craniomaxillofac Surg*. 2004 Aug;32(4):211–5.
37. Song D, Lee DW, Kim CK, Park KH, Moon IS. Comparative analysis of peri-implant marginal bone loss based on microthread location: a 1-year prospective study after loading. → *J Periodontol*. 2009 Dec;80(12):1937–44.
38. Van de Velde T, Collaert B, Sennerby L, De Bruyn H. Effect of implant design on preservation of marginal bone in the mandible. → *Clin Implant Dent Relat Res*. 2010 Jun 1;12(2):134–41.
39. Aloy-Prósper A, Maestre-Ferrin L, Peñarrocha-Oltra D, Peñarrocha-Diago M. Marginal bone loss in relation to the implant neck surface: an update. → *Med Oral Patol Oral Cir Bucal*. 2011 May;16(3):e365–8.
40. Cosyn J, Sabzevar MM, De Wilde P, De Rouck T. Two-piece implants with turned versus microtextured collars. → *J Periodontol*. 2007 Sep;78(9):1657–63.
41. Brägger U, Häfeli U, Huber B, Hämmerle CH, Lang NP. Evaluation of postsurgical crestal bone levels adjacent to non-submerged dental implants. → *Clin Oral Implants Res*. 1998 Aug;9(4):218–24.



# Antimicrobial efficacy of mouthwashes containing zinc-substituted nanohydroxyapatite and zinc L-pyrrolidone carboxylate on suture threads after surgical procedures

## Abstract

### Objective

Saverio Cosola,<sup>a,b</sup> Simone Marconcini,<sup>a,b</sup> Enrica Giammarinaro,<sup>a,c</sup> Olivia Marchisio,<sup>a</sup> Marco Lelli,<sup>d</sup> Norberto Roveri<sup>d</sup> & Anna Maria Genovesi<sup>a,e</sup>

<sup>a</sup> Tuscan Stomatologic Institute, Foundation for Dental Clinic, Research and Continuing Education, Versilia General Hospital, Lido di Camaiore, Italy

<sup>b</sup> Department of Surgical, Medical, Molecular and Critical Area Pathology, University Hospital of Pisa, University of Pisa, Pisa, Italy

<sup>c</sup> Department of Stomatology, Faculty of Medicine and Dentistry, University of Valencia, Valencia, Spain

<sup>d</sup> "Giacomo Ciamician" Department of Chemistry, University of Bologna, Bologna, Italy

<sup>e</sup> Department of General Hygiene, Guglielmo Marconi University, Rome, Italy

Suture threads used after oral surgery may be colonized by pathogenic microorganisms which could infect the surrounding tissue and impair the wound-healing process. Therefore, the postoperative use of antimicrobial mouthwashes is highly recommended. In this study, a mouthwash containing zinc-substituted nanohydroxyapatite (Zn-nHAp) and zinc L-pyrrolidone carboxylate (Zn-PCA) was compared with a product containing chlorhexidine for its efficacy in reducing microbial adherence to suture threads.

### Materials and methods

Twenty-six patients subjected to minimal surgical interventions were randomized into a chlorhexidine group (C-group; n = 13) and a hydroxyapatite group (H-group; n = 13). All of the subjects followed a postoperative home treatment with a mouthwash containing chlorhexidine and a mouthwash containing Zn-nHAp/Zn-PCA, respectively. After their removal, suture threads were cut into segments and bacteria present on them were allowed to grow in different media and under different conditions. Colony-forming units were then enumerated.

### Results

Quantification of mesophilic bacteria, *Lactobacillus* spp and total bacterial load and the search for specific anaerobic strains resulted in no statistically significant differences between the C-group and H-group. Hydroxyapatite, zinc ions and Zn-PCA are all endowed with antimicrobial properties. All of them presumably contribute to the overall high antimicrobial efficacy shown by oral care products containing a combination of these components.

### Conclusion

The mouthwash containing Zn-nHAp and Zn-PCA was found to possess at least the same antibacterial efficacy as the mouthwash containing chlorhexidine, but without exerting the typical side effects of chlorhexidine itself.

### Keywords

Zinc-substituted nanohydroxyapatite, zinc L-pyrrolidone carboxylate, bacterial load, mouthwash, suture thread.

### Corresponding author:

#### Dr. Saverio Cosola

Tuscan Stomatologic Institute  
Via Padre Ignazio da Carrara, 39  
55045 Forte dei Marmi LU  
Italy

T +39 0584 605 9888  
F +39 0584 605 8716  
saverio.cosola@gmail.com

### How to cite this article:

Cosola S, Marconcini S, Giammarinaro E, Marchisio O, Lelli M, Roveri N, Genovesi AM. Antimicrobial efficacy of mouthwashes containing zinc-substituted nanohydroxyapatite and zinc L-pyrrolidone carboxylate on suture threads after surgical procedures. J Oral Science Rehabilitation. 2017 Dec;3(4):24–30.

## Introduction

Oral surgery interventions usually require sutures in order to facilitate wound healing and to prevent dehiscence. However, suture threads are inevitably colonized by microorganisms that could infect surrounding tissue and impair the wound-healing process.<sup>1–4</sup> Many different kinds of surgical sutures (natural and synthetic) with different properties have been proposed over the years to overcome plaque stratification over threads. It is already known that bacterial adherence to suture threads may delay and affect the wound-healing process. For this purpose, several antimicrobial agents have been tested to be incorporated in or to coat suture threads.<sup>5</sup> Mouthwashes are highly recommended for home care maintenance as an adjunctive measure to reduce bacterial colonization of sutures and postoperative inflammation.<sup>6</sup> Nowadays, chlorhexidine is the gold standard in terms of antimicrobial activity because of its wide spectrum of actions. Chlorhexidine has been commercially proposed in many different formulas.<sup>7</sup> Even though its several advantages have been profusely demonstrated, some adverse effects, such as tooth staining,<sup>8,9</sup> tongue discoloration, and desquamation and soreness of the oral mucosa, should be considered.<sup>3,10–12</sup> Because of its nature, clinicians must look at chlorhexidine as an antimicrobial agent to which bacteria could develop resistance, especially in the case of long-term use.<sup>13</sup> Given those issues, researchers have been seeking alternatives to chlorhexidine in terms of antiseptic designs. In the present study, the authors tested a mouthwash containing zinc-substituted nanohydroxyapatite (Zn-nHAp) and zinc L-pyrrolidone carboxylate (Zn-PCA) in terms of microbial adherence to suture threads compared with a mouthwash containing chlorhexidine.

## Materials and methods

### Study protocol

The present clinical case–control study was a multicenter study including the Tuscan Stomatologic Institute, Versilia General Hospital, Lido di Camaiore, Italy, and the University of Bologna, Bologna, Italy. All of the participants were screened according to the following inclusion and exclusion criteria.

Inclusion criteria:

- aged 30 years and older;
- received minimal surgical interventions (extraction, implant surgery, periodontal surgery) with sutures; and
- compliance with the study protocol and willingness to adhere to the hygiene instructions.

Exclusion criteria:

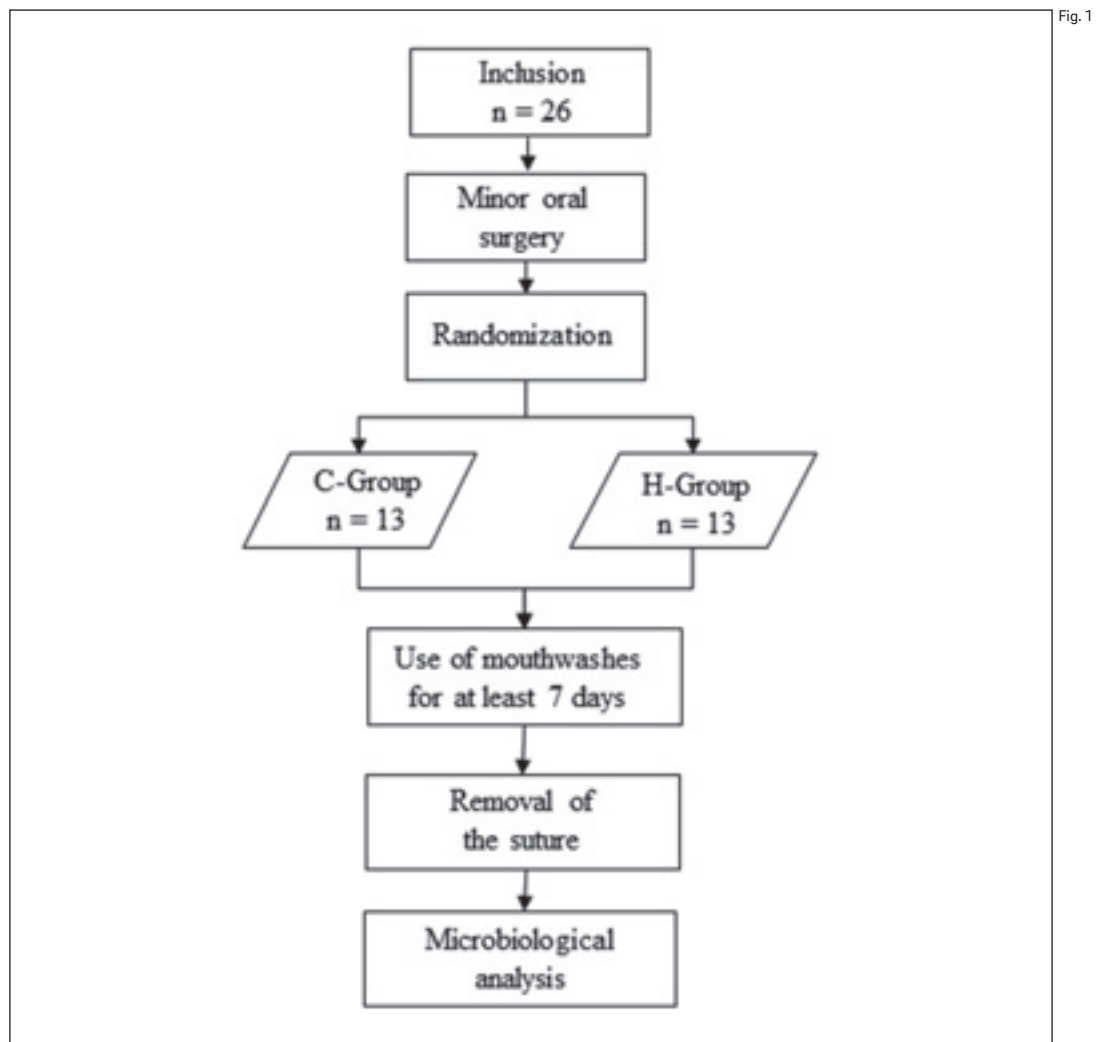
- pregnancy;
- antibiotics, nonsteroidal anti-inflammatory drugs, or steroids in the previous 3 months;
- severe systemic disease that could compromise the conduct of the study;
- untreated diabetes;
- chronic or aggressive periodontitis or other severe oral pathologies;
- smoking more than 5 cigarettes a day; and
- alcohol or other drug abuse.

At the end of the screening procedure, 26 patients were enrolled in the study and randomized into 2 maintenance groups according to the mouthwash used: (a) a control group (the chlorhexidine group, or C-group,  $n = 13$ ), in which the patients followed a postoperative home treatment for at least 7 days with a mouthwash containing 0.2% chlorhexidine (Dentosan, Johnson & Johnson, Rome, Italy); and a treatment group (the hydroxyapatite group, or H-group,  $n = 13$ ), in which the patients followed a postoperative home treatment for at least 7 days with a mouthwash containing Zn-nHAp/Zn-PCA (Biorepair, Coswell, Fano, Italy), with a 2.0% w/v concentration of Zn-nHAp and an overall concentration of Zn of 11.0% w/v. Nonabsorbable silk sutures (Sweden & Martina, Due Carrare, Italy) were removed after 10 days from the surgical sites of all of the patients. All sutures were placed and removed by the same skilled operator to eliminate inter-examiner variability. The collected samples were immediately transported to the laboratory and stored at  $-20^{\circ}\text{C}$  until microbiological analysis.

All subject randomization was performed by means of a computer program generating random numbers. Oral and written information was given to each enrolled subject. All of the patients enrolled were informed about the study protocol and were asked to sign an informed written consent for participation. This study was carried out according to the ethical principles of the Declaration of Helsinki of 1975, as revised in 2013, for medical research involving human subjects. **Figure 1** provides a flowchart summarizing the study protocol.

**Fig. 1**

Flowchart illustrating the study protocol.



#### Culture media and conditions

Bacteria were cultured in Petri dishes containing tryptone soy agar (TSA) as growth medium at an incubation temperature of  $36 \pm 1^\circ\text{C}$ . In this way, it was possible to obtain the growth of mesophilic bacteria. De Man, Rogosa and Sharpe (MRS) agar at  $36 \pm 1^\circ\text{C}$  allowed the growth of *Lactobacillus* spp. Bacteroides bile esculin (BBE) agar and brucella blood agar (BRU) with vitamin K and hemin, incubated at  $36 \pm 1^\circ\text{C}$  under anaerobic conditions allowed the qualitative analysis of specific anaerobic strains.

#### Test procedure and bacterial scoring

Microbial load was assessed after suture removal using in vitro bacterial cultures.

Suture thread samples were stored at  $-20^\circ\text{C}$  until microbiological analysis. Before testing,

samples were thawed at room temperature. Each sample was cut into 3 segments of similar length, then each thread sample was subjected to analysis as follows. The control sample was represented by segments of a sterile, unused suture thread.

#### **Assessment of the absence/presence of bacterial load:**

Two segments of the thread were scraped on 2 culture plates containing agar-based broth media (TSA and MRS) and incubated for 48 h at  $36 \pm 1^\circ\text{C}$  in order to determine whether microbial load was present on the thread surface. The plates were visually inspected and bacterial load accordingly classified as absent or present.

#### **Enumeration of bacterial colonies:**

One segment was placed in a tube containing a diluent solution (buffered peptone water; BPW) for 1 h, then, further serial decimal dilutions were carried out.

Each dilution, the first included, was seeded in plates with the same agar-based broth media and incubated for 48 h at  $36 \pm 1^\circ\text{C}$  in order to quantify the microbial load. Bacterial colonies were then counted and expressed as colony-forming units per mL (cfu/mL). Concerning the enumeration of bacterial colonies, a bacterial score (BS) was obtained by classifying the enumerated bacterial colonies according to the following scheme:

- Class 0: BS  $\leq 103$  cfu/mL
- Class 1:  $\leq 103$  cfu/mL BS  $\leq 105$  cfu/mL
- Class 2:  $\leq 105$  cfu/mL BS  $\leq 107$  cfu/mL
- Class 3: BS  $> 107$  cfu/mL

**Search for specific anaerobic bacteria:** Each sample was seeded on 2 different plates (BBE and brucella blood agar) to determine the eventual presence of anaerobic microbial strains. Seeded plates were placed in the oxygen-free vessels and incubated at  $36 \pm 1^\circ\text{C}$  for 7 days. After this period, the plates were analyzed to evaluate the presence of bacterial colonies. In positive cases, individual colonies were reseeded to achieve a pure bacterial culture suitable for biochemical recognition. For evaluation of the growth of specific anaerobic bacteria, the classes of “growth” and “no growth” were established, depending on whether bacterial growth was observed.

#### Statistical analysis

Data were expressed as mean  $\pm$  standard deviation (SD) of BS values, where available. The Mann–Whitney *U* test for independent samples was used to evaluate the difference between the C-group and H-group. In the case of categorical data, that is growth/no growth classes and absence/presence classes, data were organized in contingency tables and analyzed by the Fisher exact test. A value of  $P \leq 0.05$  was taken as statistically significant. Statistical analysis was performed using OpenStat version 26.03.2012 ([www.statprograms4u.com](http://www.statprograms4u.com)).

## Results

The results of the microbiological analysis are summarized in Tables 1–4. **Table 1** reports mean  $\pm$  SD values for BSs calculated from the cfus developed under different conditions. The mean  $\pm$  SD score of bacteria seeding calculated on TSA was  $2.000 \pm 1.080$  and  $1.462 \pm 1.198$  in the H-group and C-group, respectively. The

mean  $\pm$  SD score of bacteria-seeding calculated on MRS was  $1.462 \pm 1.050$  and  $1.077 \pm 1.320$  in the H-group and C-group, respectively. In all cases, the *P* values were not statistically significant, meaning that no statistically significant differences were observed between the H-group and the C-group. In more detail, the total bacterial load developed after seeding BPW solutions that had been in contact with suture thread segments on TSA plates and the *Lactobacillus* spp. developed after seeding BPW solutions that had been in contact with suture thread segments were comparable between groups. **Table 2** is the contingency table summarizing data resulting from inoculation on BRU plates. In this case too, no statistically significant differences between the H-group and C-group were observed ( $P = 0.411$ ). **Tables 3** and **4** are contingency tables summarizing data resulting from scraping suture thread segments on TSA plates and MRS plates, respectively. Again, no statistically significant differences between the H-group and C-group were observed. Inoculation in BBE under anaerobic conditions produced negative results (no growth) for all samples and the control. **Figure 2** illustrates Petri dishes after the optional development of bacterial colonies.

## Discussion

The present study aimed to evaluate the bacterial load on suture threads after their removal in 2 different situations. Patients were assigned either to a chlorhexidine mouthwash or to a zinc one. Among the suture thread samples taken from the 13 patients who used the mouthwash containing chlorhexidine (C-group), 7 showed a high bacterial load (BS = 2 or 3) with the presence of *Lactobacillus* spp. in 5 cases; 2 of them presented a poor bacterial load (BS = 1); and 4 of them did not present any appreciable microbial colonization (BS = 0). The search for specific anaerobic strains, when positive (3 samples), resulted in establishing the presence of *Fusobacterium varium* (1 occurrence), *Actinomyces meyeri* (1 occurrence) and *Streptococcus intermedius* (1 occurrence). Of the 13 suture thread samples taken from patients who used a mouthwash containing Zn-nHAp/Zn-PCA, 10 showed a high bacterial load (BS = 2 or 3) associated with the presence of *Lactobacillus* spp., 1 had a moderate bacterial load (BS = 1), and 2 did not show any appreciable microbial colonization. The search for specific anaerobic strains, when pos-



**Table 1**

Mean  $\pm$  SD values for BSs calculated from the cfus developed under different conditions. From left to right, the columns report data concerning the quantification of total bacterial load and *Lactobacillus* spp., respectively, after seeding the BPW solutions that had been in contact with suture thread segments. Growth media were TSA and MRS agar, respectively.

Hydroxyapatite Chlorhexidine	Seeding on TSA		Seeding on MRS	
	2.000 $\pm$ 1.080		1.462 $\pm$ 1.050	
	1.462 $\pm$ 1.198		1.077 $\pm$ 1.320	
	$P = 0.2668$		$P = 0.4084$	

Table 1

**Table 2**

Contingency table summarizing data resulting from inoculation on BRU.

		Hydroxyapatite n	Chlorhexidine n	P
Inoculation on BRU	Growth	6	3	0.411
	No growth	7	10	

Table 2

**Table 3**

Contingency table summarizing data resulting from scraping on TSA.

		Hydroxyapatite n <sup>†</sup>	Chlorhexidine n	P
Scraping on TSA	Absence	2	3	1.000
	Presence	10	10	

Table 3

<sup>†</sup> The total number of suture threads in the H-group was 12 instead of 13 because 1 thread was too short to be cut into segments for scraping on TSA plates.

**Table 4**

Contingency table summarizing data resulting from scraping on MRS.

		Hydroxyapatite n <sup>†</sup>	Chlorhexidine n	P
Scraping on MRS	Absence	3	7	0.226
	Presence	9	6	

Table 4

<sup>†</sup> The total number of suture threads in the H-group was 12 instead of 13 because 1 thread was too short to be cut into segments for scraping on MRS plates.

itive (6 samples), resulted in establishing the presence of *Actinomyces meyeri* (3 occurrences), *Bifidobacterium* spp. (1 occurrence), *Staphylococcus saccharolyticus* (1 occurrence) and *Actinomyces viscosus* (1 occurrence).

In vitro studies have already demonstrated that hydroxyapatite shows antimicrobial activity; for example, Tin-Oo et al. reported the efficacy of HAp against *Streptococcus mutans*.<sup>19</sup> The antimicrobial activity of nHAp was also investigated when intercalated by several metal ions, including zinc ions,<sup>15, 16</sup> and shown to be higher than that of nHAp alone. Furthermore, zinc ions are known to possess antimicrobial properties, and the activity of zinc in the oral cavity has been well documented.<sup>17, 18</sup> PCA possesses a certain antimicrobial activity as well, as demonstrated by Yang et al., who tested it in in vivo studies against several microorganisms.<sup>19</sup> Moreover, PCA increases the solubility rate of zinc ions in the saliva such that its antibacterial action is readily exerted.

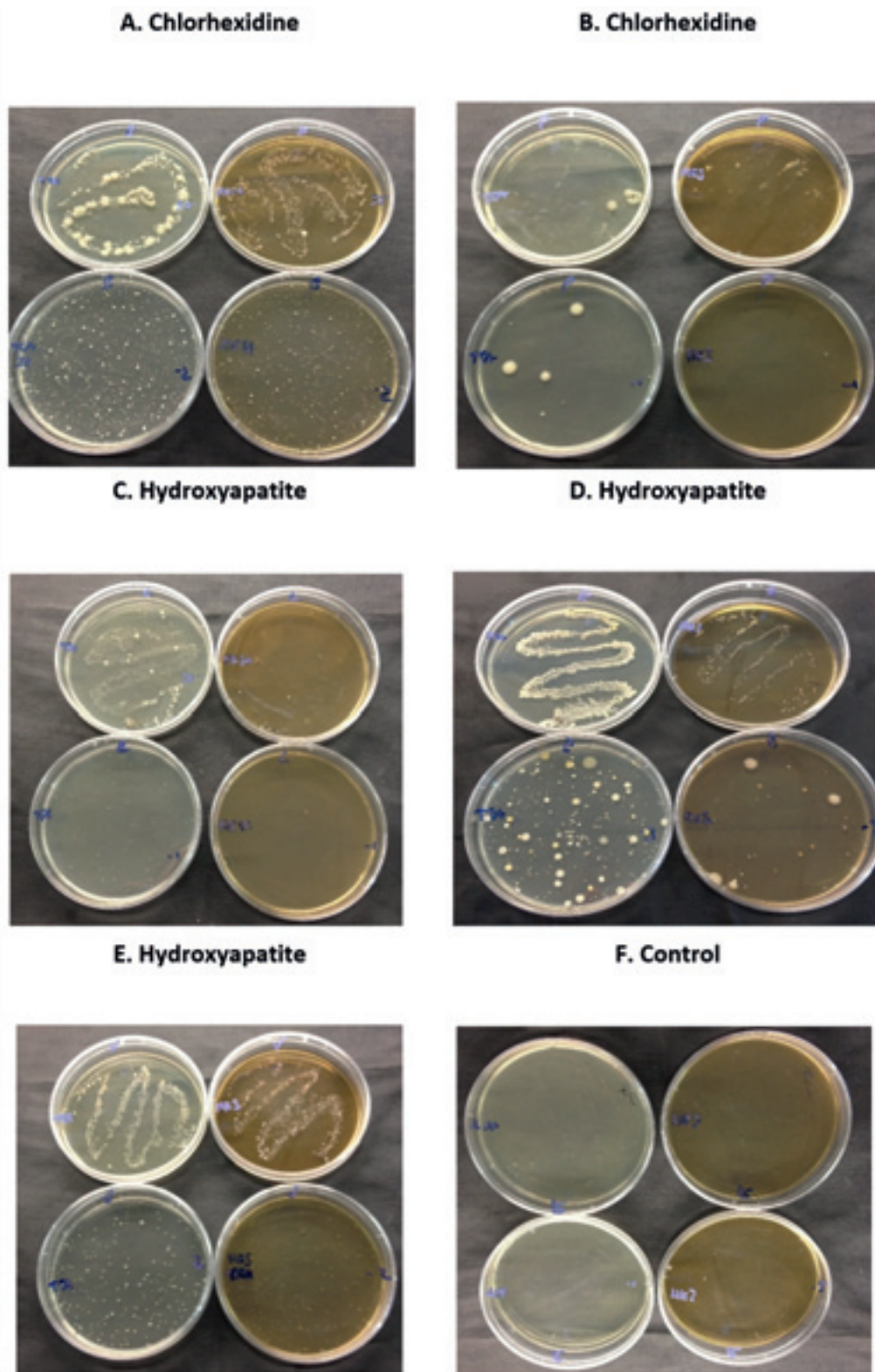
Oral care products based on the association of Zn-nHAp and Zn-PCA could create a combination of 3 active ingredients that are very well tolerated and maintain the same efficacy of chlorhexidine against bacteria. Indeed, the present study demonstrated that mouthwashes

containing Zn-nHAp and Zn-PCA represent a valid alternative to mouthwashes containing chlorhexidine. They do not exert the typical side effects of chlorhexidine, such as alteration of taste perception, tooth staining, tongue discoloration, and desquamation and soreness of the oral mucosa, while maintaining at least its same antibacterial efficacy.<sup>20</sup> Also, Marchetti et al., in a clinical comparative trial, found a similar effect of inhibiting plaque regrowth between zinc and chlorhexidine mouthwashes.<sup>21</sup> Further studies are needed to better understand whether this new antimicrobial mouthwash could substitute chlorhexidine as the gold standard in promoting wound healing after surgery owing to its antimicrobial effect and no side effects.

## Conclusion

Within the limitations of this study, the mouthwash containing Zn-nHAp and Zn-PCA was found to have similar antibacterial efficacy to the mouthwash containing chlorhexidine, but without exerting the typical side effects of chlorhexidine itself. These results should be interpreted with caution owing to the small sample of the study and the few kinds of bacteria analyzed.

Figs. 2A–F

**Figs. 2A–F**

Petri dishes after the optional development of bacterial colonies. A and B come from patients who used a mouthwash containing chlorhexidine for 7 days after surgery. C, D and E come from patients who used a mouthwash containing Zn-nHAp and Zn-PCA for 7 days after surgery. F represents control plates. Within each photograph, the upper left and right plates correspond to suture thread segments scraped on TSA for the growth of mesophilic bacteria and MRS agar for the growth of *Lactobacillus* spp., respectively. The bottom left and right plates correspond to the quantitative analysis of mesophilic bacteria on TSA and *Lactobacillus* spp. on MRS agar, respectively.

## Competing interests

The authors declare that they have no conflict of interest regarding the present research.

## Acknowledgments

The authors are grateful to the Chemical Center, Bologna, Italy, for technical support and to Drs. Alice Borghini and Daniele Pietra for statistical analysis and manuscript drafting.

For their important contribution to this investigation, the authors are also very grateful to

- Prof. Ugo Covani, Department of Surgical, Medical, Molecular and Critical Area Pathology, University of Pisa, Pisa, Italy; and Tuscan Stomatologic Institute, Foundation for Dental Clinic, Research and Continuing Education, Versilia General Hospital, Lido di Camaiore, Italy;
- Dr. Andrea Butera, Department of Surgical Sciences, Dental and Maxillofacial Department, University of Pavia, Pavia, Italy; and
- Drs. Dario Bertossi, Antonio Iurlaro and Federico Gelpi, Department of Surgical Sciences and Dental and Maxillofacial Department, University of Verona, Verona, Italy.

## References

1. Otten JE, Wiedmann-Al-Ahmad M, Jahnke H, Pelz K. Bacterial colonization on different suture materials—a potential risk for intraoral dentoalveolar surgery. → J Biomed Mater Res B Appl Biomater. 2005 Jul;74(1):627–35.
2. Katz S, Izhar M, Mirelman D. Bacterial adherence to surgical sutures. A possible factor in suture induced infection. → Ann Surg. 1981 Jul;194(1):35–41.
3. Banche G, Roana J, Mandras N, Amasio M, Gallesio C, Allizond V, Angeretti A, Tullio V, Cuffini AM. Microbial adherence on various intraoral suture materials in patients undergoing dental surgery. → J Oral Maxillofac Surg. 2007 Aug;65(8):1503–7.
4. Pons-Vicente O, López-Jiménez L, Sánchez-Garcés MA, Sala-Pérez S, Gay-Escoda C. A comparative study between two different suture materials in oral implantology. → Clin Oral Implants Res. 2011 Mar;22(3):282–8.
5. Harnet JC, Le Guen E, Ball V, Tenenbaum H, Ogier J, Haikel Y, Vodouhe C. Antibacterial protection of suture material by chlorhexidine-functionalized polyelectrolyte multilayer films. → J Mater Sci Mater Med. 2009 Jan;20(1):185–93.
6. Brown AR, Papasian CJ, Shultz P, Theisen FC, Shultz RE. Bacteremia and intraoral suture removal: can an antimicrobial rinse help? → J Am Dent Assoc. 1998 Oct;129(10):1455–61.
7. Jones CG. Chlorhexidine: is it still the gold standard? → Periodontol 2000. 1997 Oct;15:55–62.
8. Addy M, Sharif N, Moran J. A non-staining chlorhexidine mouthwash? Probably not: a study in vitro. → Int J Dent Hyg. 2005 May;3(2):59–63.
9. Bagis B, Baltacioglu E, Özcan M, Ustaomer S. Evaluation of chlorhexidine gluconate mouthrinse-induced staining using a digital colorimeter: an in vivo study. → Quintessence Int. 2011 Mar;42(3):213–23.
10. Helms JA, Della-Fera MA, Mott AE, Frank ME. Effects of chlorhexidine on human taste perception. → Arch Oral Biol. 1995 Oct;40(10):913–20.
11. Frank ME, Gent JF, Hettinger TP. Effects of chlorhexidine on human taste perception. → Physiol Behav. 2001 Sep 1–15;74(1–2):85–99.
12. Marinone MG, Savoldi E. Chlorhexidine and taste. Influence of mouthwashes concentration and of rinsing time. → Minerva Stomatol. 2000 May;49(5):221–6.
13. Russell AD. Biocide use and antibiotic resistance: the relevance of laboratory findings to clinical and environmental situations. → Lancet Infect Dis. 2003 Dec;3(12):794–803.
14. Tin-Oo MM, Gopalakrishnan V, Samsuddin AR, Al Salihi KA, Shamsuria O. Antibacterial property of locally produced hydroxyapatite. → Arch Orolfac Sci. 2007;2:41–4.
15. Swetha M, Sahithi K, Moorthi A, Saranya N, Saravanan S, Ramasamy K, Srinivasan N, Selvamurugan N. Synthesis, characterization, and antimicrobial activity of nano-hydroxyapatite-zinc for bone tissue engineering applications. → J Nanosci Nanotechnol. 2012 Jan;12(1):167–72.
16. Kim TN, Feng QL, Kim JO, Wu J, Wang H, Chen GC, Cui FZ. Antimicrobial effects of metal ions (Ag<sup>+</sup>, Cu<sup>2+</sup>, Zn<sup>2+</sup>) in hydroxyapatite. → J Mater Sci Mater Med. 1998 Mar;9(3):129–34.
17. Lynch RJ. Zinc in the mouth, its interactions with dental enamel and possible effects on caries; a review of the literature. → Int Dental J. 2011 Aug;61 Suppl 3:46–54.
18. Hannig C, Basche S, Burghardt T, Al-Ahmad A, Hannig M. Influence of a mouthwash containing hydroxyapatite microclusters on bacterial adherence in situ. → Clin Oral Investig. 2013 Apr;17(3):805–14.
19. Yang Z, Suomalainen T, Mäyrä-Mäkinen A, Huttunen E. Antimicrobial activity of 2-pyrrolidone-5-carboxylic acid produced by lactic acid bacteria. → J Food Protect. 1997 Jul;60(7):786–90.
20. Flötra L, Gjermo P, Rölla G, Waerhaug J. Side effects of chlorhexidine mouth washes. → Scand J Dent Res. 1971;79(2):119–25.
21. Marchetti E, Casalena F, Capestro A, Tecco S, Mattei A, Marzo G. Efficacy of two mouthwashes on 3-day supragingival plaque regrowth: a randomized crossover clinical trial. → Int J Dent Hyg. 2017 Feb;15(1):73–80.

€50/issue of the Journal  
(4 issues/year; including  
VAT and shipping costs,  
for a total of €200/year)

Your subscription will be  
renewed automatically  
every year until a written  
cancellation is sent  
six weeks prior to the  
renewal date to

Dental Tribune  
International GmbH,  
Holbeinstr. 29, 04229  
Leipzig, Germany.



## Subscribe Now!

Shipping address

City

Country

Phone

Fax

Signature

Date

☐ PayPal | [subscriptions@dental-tribune.com](mailto:subscriptions@dental-tribune.com)

☐ Credit card

Credit card number

Expiration date

Security code

fax: +49 341 4847 4173 | email: [subscriptions@dental-tribune.com](mailto:subscriptions@dental-tribune.com)

**dti** Dental  
Tribune  
International



# Multifactorial statistical analysis toward evaluation of MBL, PES and PI of a novel non-submerged implant to restore a single tooth: A 1-year prospective cohort study

## Abstract

### Objective

The objective of this study was to evaluate radiographic, clinical and esthetic parameters of a new type of nonsubmerged 2-piece implant placed in patients in need of single-tooth replacement.

### Materials and methods

Fifty-four consecutive patients requiring single-tooth replacement received 62 2-piece nonsubmerged flapless implants characterized by an innovative hyperbolic neck. The implant placement timing was as follows: 15 immediately post-extraction (immediate), 18 after 8–12 weeks (early) and 29 after 10–12 months (delayed). Customized abutments with an abutment–implant connection approximately 1–2 mm above the soft-tissue level were positioned after 3 months, loaded with provisional crowns and 20 days later with definitive crowns.

Gingival biotype (thin or thick) was investigated in all patients. Peri-implant marginal bone level (MBL; mm) was measured single-blinded on periapical radiographs at 1, 3, 6 and 12 months ( $T_1$ ,  $T_3$ ,  $T_6$ ,  $T_{12}$ ). Papilla index (PI), plaque score and bleeding on probing (BoP) were evaluated as clinical parameters of soft tissue. Pink Esthetic Score (PES) was calculated as the esthetic parameter.

### Results

The survival rate was 100%. The dropout rate was 1.85%. The mean MBL was  $-0.01 \pm 0.26$  at  $T_1$ ,  $-0.17 \pm 0.38$  at  $T_3$ ,  $-0.28 \pm 0.32$  at  $T_6$  and  $-0.37 \pm 0.41$  at  $T_{12}$ . The PES (0–14) was  $7.30 \pm 2.80$  at  $T_0$  (preoperatively),  $11.06 \pm 0.97$  at  $T_6$  and  $11.95 \pm 1.04$  at  $T_{12}$ .

At ( $T_{12}$ ), delayed implants showed a greater ( $P < 0.05$ ) bone loss compared with early and immediate implants. Implants placed in thin biotype tissue showed the greatest bone loss at 12 months with a significant ( $P < 0.01$ ) difference with respect to that at ( $T_6$ ). PES and PI increased from  $T_0$  to  $T_{12}$ .

### Conclusion

These implants allow preservation of a good MBL and offer a new approach to soft- and hard-tissue management, allowing a reduced healing time with minimally invasive surgery, no additional re-entry and fewer complications.

### Keywords

Nonsubmerged dental implants, flapless surgery, marginal bone level (MBL), papilla index (PI), bleeding on probing (BoP), Pink Esthetic Score (PES).

Carlo Prati,<sup>a</sup> Fausto Zamparini,<sup>a,b</sup> Chiara Pirani,<sup>a</sup> Lucio Montebugnoli<sup>a</sup> & Maria Giovanna Gandolfi<sup>b</sup>

<sup>a</sup> Endodontic Clinical Section, Department of Biomedical and Neuromotor Sciences, School of Dentistry, University of Bologna, Bologna, Italy

<sup>b</sup> Laboratory of Biomaterials and Oral Pathology, Department of Biomedical and Neuromotor Sciences, School of Dentistry, University of Bologna, Bologna, Italy

### Corresponding author:

#### Prof. Carlo Prati

Via San Vitale, 59  
40125 Bologna  
Italy

T +39 051 208 8126  
carlo.prati@unibo.it

### How to cite this article:

Prati C, Zamparini F, Pirani C, Montebugnoli L, Gandolfi MG. Multifactorial statistical analysis toward evaluation of MBL, PES and PI of a novel nonsubmerged implant to restore a single tooth: A 1-year prospective cohort study. *J Oral Science Rehabilitation*. 2017 Dec;3(4):32–41.

## Introduction

Flap raising and surgical trauma,<sup>1, 2</sup> second re-entry surgeries and application of subgingival abutments<sup>3</sup> may lead to both hard- and soft-tissue complications, i.e., crestal bone loss, wound dehiscence and gingival recession. The need for less-invasive protocols may be useful to avoid these complications. The use of nonsubmerged implants may prevent any surgical re-intervention for cover screw exposure and abutment or further prosthetic phases. The use of a flapless technique may reduce the risk of surgical complications and marginal bone loss.<sup>4, 5</sup> The type of implant and morphology of the neck may play some critical role in preserving marginal soft and bone tissue.

Recently, a new 2-piece nonsubmerged zirconium dioxide-blasted, acid-etched titanium implant (Prima, Sweden & Martina, Due Carrare, Italy) was marketed based on the biologically oriented preparation technique (BOPT). This prosthetic approach entails the creation of an ideal esthetic contour through gingival adaptation of the crown without the need for invasive surgical procedures. The crown is positioned on a previously prepared tooth with no finishing line, allowing the possibility of creating a new prosthetic cemento-enamel junction and allowing the crown's gingival margin to be shaped as desired.<sup>6</sup> This prosthetic technique was first described in the context of natural tooth-supported restorations,<sup>7</sup> but may be applied also to implant rehabilitation. The Prima implant was designed with a 3 mm hyperbolic machined neck that simulates a natural prosthetic abutment without a finishing line.

Short-term case reports and case series are beginning to be published in the literature.<sup>8, 9</sup> Preliminary investigations have found promising soft- and hard-tissue management using a flapless technique and indicated that all prosthetic procedures resulted in simpler and easier procedures than with a conventional submerged implant-abutment connection.<sup>8–10</sup>

The aim of this consecutive prospective cohort study was to evaluate the failure rate and hard- and soft-tissue modifications and parameters during the first year of placement of non-submerged Prima implants.

## Materials and methods

### Study setting and patient selection

The study design was a single-blinded human longitudinal prospective cohort study evaluating

clinical and radiographic parameters after 1 year for the treatment of patients who required replacement of a single tooth. The study was conducted in a university endodontic clinical department and 2 private dental offices. Patient recruitment was performed from September 2014 to September 2015. Patients were followed up between October 2014 and May 2017 by the same clinical team.

All of the patients included in this investigation were treated according to the principles established by the Declaration of Helsinki of 1975, as revised in 2013.<sup>11</sup> Before enrolment, written and verbal information were given by the clinical staff and each patient gave written consent according to the above-mentioned principles. An additional signed informed consent was obtained from all patients stating that they accepted the treatment plan and agreed to cover the costs and follow the maintenance hygiene program. This report was written according to the Strengthening the Reporting of Observational Studies in Epidemiology (STROBE)<sup>12</sup> and respecting the guidelines published by Dodson in 2007.<sup>13</sup> The patients were considered eligible for inclusion in the clinical protocol based on the following inclusion criteria:

- aged 18–75;
- presence of a single failing tooth or a single tooth gap with both neighboring teeth present;
- possibility of inclusion in a hygiene recall program and implant control for at least 1 year; and
- smoking less than 10 cigarettes a day.

Exclusion criteria were as follows:

- medical and/or general contraindications for the surgical procedures (American Society of Anesthesiologists Physical Status  $\geq 3$ );
- poor oral hygiene and lack of motivation;
- active clinical periodontal disease in the natural dentition determined by a probing pocket depth  $> 4$  mm and bleeding on probing;
- smoking more than 10 cigarettes a day;
- uncontrolled diabetes mellitus;
- systemic or local disease that could compromise postoperative healing and osseointegration;
- alcohol and/or drug abuse;
- pregnancy or lactation;
- malocclusion or other occlusal disorder (bruxism); and
- bisphosphonate therapy.

### Patient allocation

The timing of implant placement (immediate, early or delayed according to the third ITI

Consensus Conference)<sup>14</sup> was specifically determined by an experienced university clinician following rigorous criteria aimed at best clinical practice (judgmental allocation).<sup>15</sup>

The following groups were defined:

- Immediate post-extraction implant group (type 1 for ITI):<sup>14</sup> placement of the implant into the fresh extraction socket immediately after extraction of a tooth affected by chronic periapical disease or of a seriously damaged, hopeless tooth. Only chronic periapical lesions were present and identified by periapical radiolucency.
- Early implant group (type 2 for ITI):<sup>14</sup> placement of the implant in healed bone after 8–12 weeks after extraction of a tooth affected by an acute periapical lesion and/or abscess, pus and clinical symptoms.
- Delayed implant group (type 4 for ITI):<sup>14</sup> placement of the implant in edentulous mature bone 10–12 months after tooth extraction.

#### Preoperative protocol

The day before surgery, all of the patients were subjected to a preventive pharmacological treatment consisting of 1 g of amoxicillin/clavulanic acid (Augmentin, GlaxoSmithKline, Brentford, U.K.; 1 tablet at 24 and 12 h before the surgery) and a 0.12% chlorhexidine digluconate gel (Corsodyl Gel, GlaxoSmithKline; 3 applications per day). Antibiotic administration was continued for 5 days postoperatively.

#### Implant surgery

Implant surgeries were conducted by the same operator (C.P.) under local anesthesia with 30 mg/mL of mepivacaine hydrochloride (Carboplyina, Dentsply Italia, Rome, Italy) in sterile conditions. All of the implants were placed in 1-stage surgical procedures. No flaps were raised and no surgical guides were used.

A pilot drill of 1.2 mm in diameter was used to mark the position, angle and depth. The drill passed through the mucosa (nonsubmerged), cortical bone and cancellous bone at 225 rpm. A series of calibrated drills working at 225 rpm were used to create a site of adequate depth and diameter.

Prima implants, characterized by a 3 mm transmucosal machined neck with a hyperbolic profile (as illustrated by the environmental scanning electron microscopy image in **Fig. 1**) were inserted to keep the blasted surface at cortical bone level and the smooth machined neck

surface 1–3 mm above the gingival level, according to the transmucosal technique.<sup>16</sup> No sutures were placed. A surgical dressing (COE-PAK, GC America, Alsip, Ill., U.S.) was applied to the implant site and kept in position for 5–7 days.

#### Postoperative procedures

Patients were instructed to follow a soft diet regime for 1 week, to rinse 3 times per day with a 0.12% chlorhexidine mouthwash for 3 weeks and to perform oral hygiene on the COE-PAK using a normal-medium-hardness toothbrush for the first week and for 2 weeks after removal of the surgical dressing. Thereafter, conventional brushing and flossing were permitted.

#### Prosthetic restoration

Three months after implant insertion, impressions using polyether materials (Permadyne and Garant, 3M ESPE, St. Paul, Minn., U.S.) were taken using customized resin trays (pickup impression technique). Gypsum model casts were obtained and provisional resin crowns were carefully designed to keep the crown margins at gingival level with the finishing line on the implant hyperbolic neck.


Customized titanium abutments were screwed in after 5–7 days. All of the resin crowns were positioned with temporary cement (Temp Bond, Kerr, Scafati, Italy) for initial prosthetic restoration. In this way, the implant–abutment connection was internal to the crowns. Abutments were intended to increase the retention of the cement–crown monobloc.

Twenty days later, definitive prosthetic metal–ceramic crowns were positioned and fixed with a polycarboxylate cement (Heraeus Kulzer, Hanau, Germany). Definitive crowns were also prepared according to the BOPT so that all metal and ceramic finishing lines corresponded to the implant hyperbolic neck. Fitting of the metal was gently and carefully done to create a mechanical metal–metal friction. Two experienced prosthodontists (C.P. and L.M.) performed all of the prosthetic procedures. Great attention was given to avoiding any cement excess around the restorations.

#### Follow-up implant evaluation

Active periodontal therapy consisting of motivation, instruction in oral hygiene practice, scaling and root planing was performed until no or modest periodontal disease was present.

Fig. 1



**Fig. 1**

Optical microscopy and environmental scanning electron microscopy images showing the hyperbolic machined collar and the microtopography of the collar, body and apex portions of Prama implant.

## Hard- and soft-tissue evaluation

Marginal bone level (MBL): Intraoral periapical radiographs of all of the implants were taken using the paralleling technique with Rinn holders (Dentsply Rinn, Elgin, Ill., U.S.) and analog films (Kodak Ektaspeed Plus, Eastman Kodak, Rochester, N.Y., U.S.) after implant placement (baseline) and at 1, 3, 6 and 12 months ( $T_1$ ,  $T_3$ ,  $T_6$ ,  $T_{12}$ ) after implant insertion.

All radiographs were scanned with a slide scanner with a resolution of 968 dpi and a magnification factor of  $\times 20$ . The known lengths and diameters of the implants were used to calibrate the measurement. The crestal marginal bone and the bone–implant interface were examined to evaluate the marginal bone morphology. MBL was assessed at the mesial and distal implant surfaces by measuring the distance between the reference point of the implant platform to the most coronal bone–implant contact level using a scale of 0.1 mm increments according to previous studies<sup>17, 18</sup> and corrected according to the known length and diameter of each implant.<sup>19</sup>

Radiographic evaluation was performed single-blinded by 1 additional examiner (F.Z.). Before evaluating the radiographs, the examiner was calibrated using well-defined instructions and reference radiographs with different MBL measures.

Periimplant soft-tissue thickness/gingival biotype: The soft-tissue thickness around the implants and their corresponding mesial/distal neighboring teeth was determined. The soft tissue was pierced midfacially at 3 mm apical to the gingival margin with an endodontic file (No. 20 K-file, Dentsply Maillefer, Switzerland). Gingival biotype was defined as thick (soft-tissue thickness > 2 mm) or thin (soft-tissue thickness  $\leq$  2 mm).<sup>20–22</sup>

Pink Esthetic Score (PES): PES<sup>23</sup> was assessed preoperatively and at T<sub>6</sub> and T<sub>12</sub>. Seven

variables were evaluated against a natural reference tooth by 1 trained operator (the contralateral tooth for an incisor and contralateral tooth or neighboring tooth for a premolar) using a 0–2 scoring system (0 being the lowest and 2 being the highest value): mesial papilla, distal papilla, soft-tissue level, soft-tissue contour, alveolar process deficiency, soft-tissue color and soft-tissue texture. The maximum achievable PES was 14. According to Raes et al., a PES < 8 is considered an esthetic failure, while a PES ≥ 12 is considered an (almost) perfect outcome.<sup>1</sup>

Papilla index (PI): PI<sup>24</sup> was assessed mesially and distally by 1 trained operator using a 0–4 scale at T<sub>6</sub> and T<sub>12</sub>. A PI score was given as follows: 0 = no papilla; 1 = papilla fills less than 50% of the interproximal space; 2 = papilla fills more than 50% of the interproximal space, but not entirely; 3 = papilla fills the entire interproximal space harmoniously; 4 = hyperplastic papilla.

Plaque score: Plaque score<sup>25</sup> was assessed at 4 sites (mesial, distal, vestibular and palatal) around the implant restorations at T<sub>6</sub> and T<sub>12</sub>. A dichotomous score was given (0 = no visible plaque at the soft margin; 1 = visible plaque at the soft margin).

Bleeding on probing (BoP): BoP<sup>25</sup> was measured at 4 sites (mesial, distal, vestibular and palatal) around the implant restorations at T<sub>6</sub> and T<sub>12</sub>. A dichotomous score was given (0 = no bleeding; 1 = bleeding).

## Statistical analysis of the MBL

Linear regression models were fitted to evaluate the existence of any significant difference regarding placement (immediate, early and delayed), times (1 month, 3 months, 6 months and 12 months), and the interactions between placement and time. In order to take into account the correlation in the data due to the presence of multiple implants per subject, the



above-mentioned regression models were estimated following a generalized estimating equation approach. The implant was used as the unit of analysis. We adjusted the estimates of the coefficients' standard errors and confidence intervals using a robust variance-covariance estimator.<sup>26</sup> The same analysis was performed for gingival biotype.

A multiple linear regression model with stepwise selection was fitted to evaluate the relationship between MBL at 12 months and the following variables: sex (male/female), location (mandible/maxilla), tooth type (anterior/posterior), endodontically treated adjacent teeth (yes/no), implant placement (immediate, early, delayed), implant diameter (3.80, 4.25 or 5.00 mm), implant length (10.0/11.5 mm) and gingival biotype (thin/thick). All statistical analysis was performed using Stata (Version 13.1, StataCorp, College Station, Texas, U.S.).

## Results

Based on the inclusion and exclusion criteria, 54 patients (62 implants) with a mean age of  $56.8 \pm 12.0$  years (26 men and 28 women) were included. **Table 1** depicts implant distribution and MBL (mean  $\pm$  SD) at 12 months according to the pre-, intra- and postoperative parameters evaluated.

The survival rate was 100%. The total patient dropout rate was 1.85%. No wound infection, osteitis, bone graft sequestration or implant loosening occurred during the follow-up period.

Mean MBL values according to implant placement group and gingival biotype are reported in **Tables 2** and **3**, respectively. The delayed implant group showed the greatest bone loss from  $T_6$  to  $T_{12}$ , the difference being statistically significant ( $P < 0.05$ ) with respect to both the early and immediate groups. The early implant group showed the lowest bone loss at all times. Interestingly, all 3 groups showed a statistically different MBL at  $T_3$  with respect to  $T_1$ . Considering gingival thickness, MBL significantly ( $P < 0.01$ ) decreased with time in both groups, but patients with a thin biotype showed a greater bone loss ( $P < 0.01$ ) than patients with a thick biotype. A statistically significant difference ( $P < 0.01$ ) in MBL between groups was found at 6 and at 12 months. The results of the multiple linear regression (**Table 4a**) showed that implant diameter and gingival biotype were the only variables significantly ( $P < 0.01$ ) related to

MBL at  $T_{12}$ , the gingival biotype being the most important one (**Table 4b**).

As soft-tissue evaluation parameters, PES and PI assessment are reported in **Tables 5** and **6**. Adequate/good PES scores were reported for all implants, increasing from  $T_6$  to  $T_{12}$ . Also, PI increased from  $T_6$  to  $T_{12}$ . Plaque score and BoP are reported in **Table 7**. A clinical photograph sequence of an example of implant rehabilitation is shown in **Figure 2**. A periapical radiograph sequence of a representative case is presented in **Figure 3**.

## Discussion

The study has demonstrated that the proposed nonsubmerged technique with a hyperbolic neck design allows the achievement of a stable periimplant MBL and an adequate soft-tissue morphology. MBL was evaluated at 1 and 3 months after implant insertion (preloading period) and demonstrated very limited bone loss despite the gingival emergence of a yellow implant neck.

Previous studies have evaluated MBL from initial loading (postloading period), not considering that bone loss may occur during the preloading time.<sup>5</sup> Interestingly, in the present study, a stable MBL was observed after 1 month from insertion. The flapless technique<sup>27–29</sup> probably minimized surgical trauma that may be responsible for initial marginal bone loss.<sup>30</sup>

Our investigation is the first prospective clinical study to evaluate a high number of clinical (BoP, PI and plaque score), radiographic (MBL) and esthetic (PES) parameters and include a reasonable number of implants and patients. Currently, only a case report<sup>8</sup> and a prospective cohort study<sup>10</sup> at 18 months with just 14 patients, showing a stable MBL and a soft-tissue improvement, have been published on the Prama implant.

A study on another implant system demonstrated in both flapless and flapped groups a marginal bone loss of 0.5 mm after the stress-free healing period,<sup>31</sup> not far from our results. Similar values were reported in other investigations regarding different implant systems and the flapless technique.<sup>28, 29</sup> Long-term results from a randomized clinical trial on a 1-piece implant with a conical neck shape (similar to the hyperbolic profile) have recently been published,<sup>32</sup> reporting high success (96.4%) and survival rates (100%) and acceptable periimplant

Table 1

Preoperative parameters		n	MBL (mm)
Sex	Male	28	- 0.47 ± 0.39
	Female	34	- 0.45 ± 0.41
Location	Maxilla	48	- 0.40 ± 0.34
	Mandible	14	- 0.60 ± 0.47
Tooth type	Anterior	14	- 0.28 ± 0.42
	Posterior	48	- 0.54 ± 0.49
Endodontic treated adjacent teeth	No	27	- 0.44 ± 0.47
	Yes	35	- 0.46 ± 0.43
Intra-operative parameters			
Implant placement	Immediate	15	- 0.34 ± 0.46
	Early	18	- 0.25 ± 0.22
	Delayed	29	- 0.59 ± 0.46
Diameter (mm)	3.80	23	- 0.63 ± 0.44
	4.25	31	- 0.44 ± 0.46
	5.00	8	- 0.15 ± 0.47
Implant length (mm)	10.0	40	- 0.51 ± 0.44
	11.5	22	- 0.41 ± 0.42
Postoperative parameters			
Gingival biotype	Thin	37	- 0.60 ± 0.46
	Thick	25	- 0.26 ± 0.41
Total		62	- 0.37 ± 0.41

† One patient dropped out 1 month after implant insertion (2 delayed implants). Total dropout was 1.85%.

Table 2

	Immediate	Early	Delayed
T <sub>1</sub>	- 0.06 ± 0.13 <sup>Aa</sup>	+ 0.01 ± 0.26 <sup>Aa</sup>	- 0.05 ± 0.26 <sup>Aa</sup>
T <sub>3</sub>	- 0.19 ± 0.30 <sup>Ab</sup>	- 0.14 ± 0.44 <sup>Ab</sup>	- 0.26 ± 0.34 <sup>Ab</sup>
T <sub>6</sub>	- 0.25 ± 0.22 <sup>Ab</sup>	- 0.16 ± 0.38 <sup>Ab</sup>	- 0.44 ± 0.30 <sup>Bc</sup>
T <sub>12</sub>	- 0.34 ± 0.04 <sup>Ab</sup>	- 0.25 ± 0.45 <sup>Ab</sup>	- 0.61 ± 0.38 <sup>Bd</sup>

Equal superscript capital letters represent no statistically significant difference between groups ( $P > 0.05$ ).

Equal superscript small letters represent no statistically significant time-related difference with times in both groups ( $P > 0.05$ ).

Table 3

	Thin	Thick
T <sub>1</sub>	- 0.09 ± 0.28 <sup>Aa</sup>	+ 0.03 ± 0.32 <sup>Aa</sup>
T <sub>3</sub>	- 0.26 ± 0.32 <sup>Ab</sup>	- 0.12 ± 0.53 <sup>Bb</sup>
T <sub>6</sub>	- 0.40 ± 0.40 <sup>Ab</sup>	- 0.19 ± 0.44 <sup>Bb</sup>
T <sub>12</sub>	- 0.62 ± 0.37 <sup>Ac</sup>	- 0.26 ± 0.41 <sup>Bb</sup>

Equal superscript capital letters represent no statistically significant difference between groups ( $P > 0.05$ ).

Equal superscript small letters represent no statistically significant time-related difference with times in both groups ( $P > 0.05$ ).

Table 4a

Groups	Coefficient	Robust SE	95% CI	P value
Preoperative parameters				
Sex	- 0.080	0.625	(- 0.203; - 0.041)	0.196
Location	- 0.024	0.887	(- 0.198; 0.150)	0.787
Tooth type	0.160	0.091	(- 0.019; - 0.339)	0.080
Endodontic adjacent teeth	0.029	0.070	(- 0.108; 0.167)	0.674
Implant placement group	- 0.039	0.049	(- 0.136; 0.058)	0.432
Intra-operative parameters				
Implant diameter	- 0.146	0.071	(- 0.286; - 0.007)	0.040*
Implant length	0.031	0.068	(- 0.102; 0.165)	0.643
Postoperative parameters				
Gingival biotype	- 0.183	0.056	(- 0.295; - 0.071)	0.001*

Table 1

Distribution, number of implants placed (n) and MBL (mean ± SD) at 12 months.

Table 2

Linear regression results for implant placement using GEE with the robust covariance estimator to account for correlation in the data. The implant was used as the unit of analysis (MBL values expressed as mean ± SD).

Table 3

Linear regression results for gingival biotype using GEE with the robust covariance estimator to account for correlation in the data. The implant was used as the unit of analysis (MBL values expressed as mean ± SD).

Table 4a

Multiple linear regression relating MBL at 12 months to all variables considered.

Groups	Coefficient	Robust SE	95% CI	P value
Implant diameter	- 0.142	0.066	(- 0.278; - 0.006)	0.041*
Gingival biotype	- 0.168	0.063	(- 0.292; - 0.044)	0.008*

Table 4b

\* asterisks indicate statistically significant differences (p < 0.05)

Parameter	Pink Esthetic Score (%)			
	Score	(T <sub>0</sub> ) Preoperative	T <sub>6</sub>	T <sub>12</sub>
Mesial papilla	0	23.07	0.00	0.00
	1	62.3	44.9	45.4
	2	7.7	55.1	54.6
Distal papilla	0	38.5	0.00	0.00
	1	53.8	37.9	40.9
	2	7.7	62.1	59.1
Soft-tissue level	0	0.00	0.00	0.00
	1	84.6	62.1	36.4
	2	15.4	37.9	63.6
Soft-tissue contour	0	15.4	0.00	0.00
	1	69.2	57.7	31.8
	2	15.4	42.3	68.2
Alveolar process deficiency	0	15.4	0.00	0.00
	1	61.5	34.5	22.7
	2	23.1	65.5	77.3
Soft-tissue color	0	23.1	0.00	0.00
	1	61.5	34.5	22.7
	2	15.4	65.5	77.3
Soft-tissue texture	0	15.4	0.00	0.00
	1	76.9	17.9	4.6
	2	7.7	82.1	95.4

Table 5a

Mean ± SD	7.30 ± 2.80	11.06 ± 0.97	11.95 ± 1.04
Median (IQR)	7.5 (6; 9.5)	11 (10.75; 12)	12 (11; 12)
Range [min; max]	[2; 10]	[9; 13]	[10; 13]

Table 5b

Table 4b

Multiple linear regression after stepwise selection.

Table 5a

Pink Esthetic Score of single implant (expressed as percentage).

	T <sub>6</sub>	T <sub>12</sub>
PI-M (0 – 4)	1.48 ± 0.59	1.92 ± 0.49
PI-D (0 – 4)	1.59 ± 0.50	2.07 ± 0.52

Table 6

PI-M: papilla index of mesial papilla; PI-D: papilla index of distal papilla.

Table 5b

Pink Esthetic Score (0–14).

Table 6

Papilla index (mean ± SD).

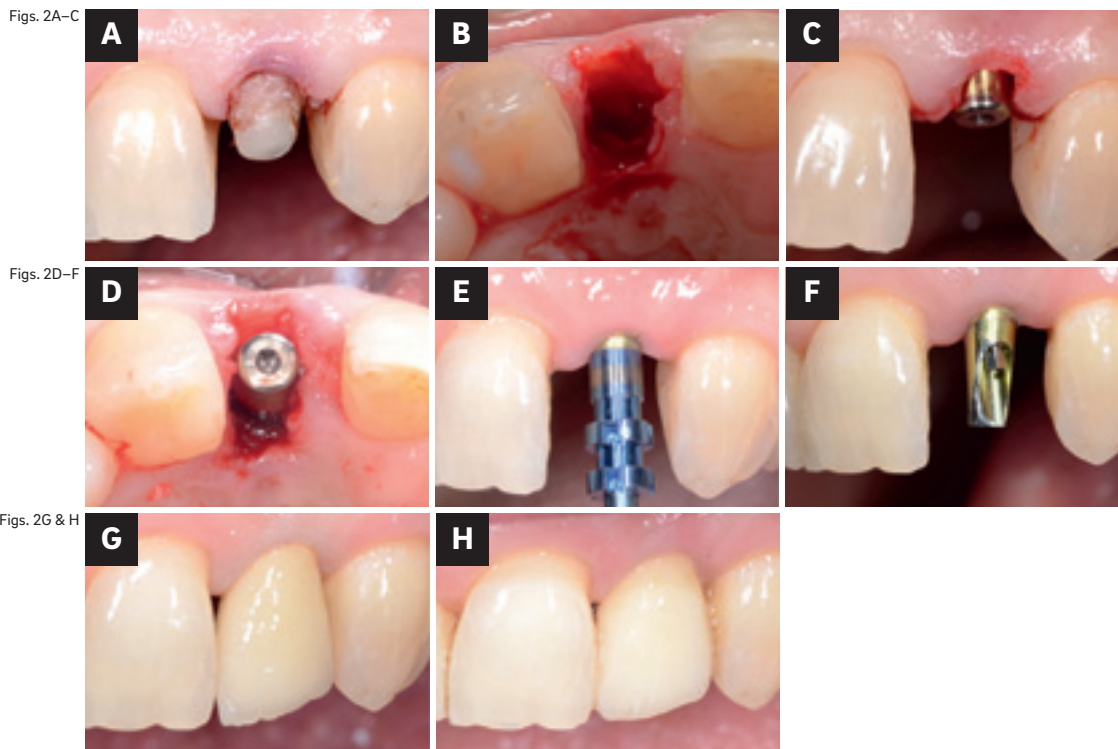
Table 7

Periodontal parameters around implant restorations after definitive loading.

	Plaque score				Bleeding on probing			
	T <sub>6</sub>		T <sub>12</sub>		T <sub>6</sub>		T <sub>12</sub>	
	0 (%)	1 (%)	0 (%)	1 (%)	0 (n%)	1 (n%)	0 (n%)	1 (n%)
Mesial	41.6	58.4	83.3	16.7	83.3	16.7	87.5	12.5
Distal	58.4	41.6	58.4	41.6	87.5	12.5	87.5	12.5
Vestibular	70.8	29.2	70.8	29.2	83.3	16.7	87.5	12.5
Palatal	62.5	37.5	70.8	29.2	100.0	0.0	100.0	0.0

Table 7

A 0 value indicates that no bleeding on probing/plaque accumulation was present.  
A 1 value indicates that bleeding on probing/plaque accumulation was present.

**Figs. 2A–H**

Maxillary left lateral incisor that had previously undergone an apicoectomy. The tooth presented high-grade mobility and extraction was scheduled. (A) Pre-extraction vestibular view. Atraumatic extraction was performed, as well as adequate alveolar socket debridement. (B) Post-extraction view. A Prama implant was placed nonsubmerged according to the manufacturer's instructions; (C) vestibular and (D) occlusal views. After 3 months, impressions were taken (D) and an abutment was fixed (E). No second surgeries were performed to expose the implant neck. A provisional crown was cemented free from tissue compression (F) and a metal–ceramic crown was later cemented (G).

bone loss (mean MBL:  $-0.30 \pm 0.78$  mm). Considering all of the implants placed and evaluated in the present study, a mean MBL of  $-0.37 \pm 0.41$  mm was observed at  $T_{12}$ , in agreement with standard success criteria and the previous recent study.<sup>32</sup>

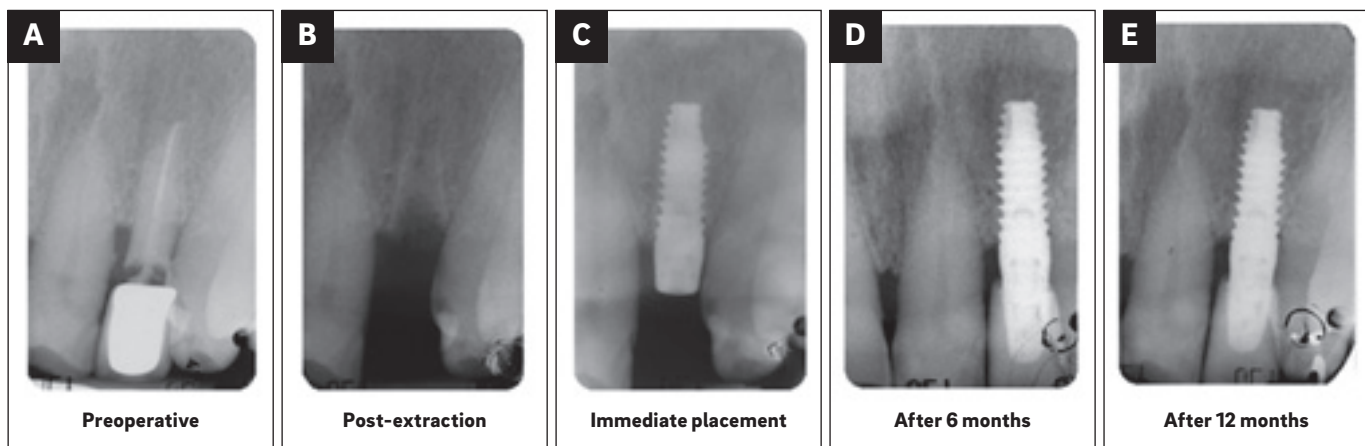
Concerning MBL in relation to placement timing groups (immediate, early and delayed), delayed implants showed greater bone loss ( $0.61 \pm 0.38$  mm) at 12 months, while early and immediate implants showed limited bone loss (MBL:  $0.25 \pm 0.45$  mm and  $0.34 \pm 0.04$  mm, respectively). These results were in accordance with another previous published study, which investigated implants with the same surface, but a different neck morphology (tulip-shaped, platform-switched implants).<sup>33</sup> Bone remodeling procedures are probably different in mature (delayed group) or immature bone (early and immediate group), as recently shown in several in vivo animal studies that tested the ZrTi implant surface micromorphology used in Prama implants.<sup>34, 35</sup>

In all of the patients, periimplant gingival biotype was evaluated after 12 months from implant insertion. Thin gingival biotype demonstrated greater bone loss values at 12 months ( $P = 0.008$ ). This is in accordance with the findings of a recent study with a different bone level implant.<sup>36</sup> Considering all of the parameters

evaluated in the statistical analysis, gingival biotype was found to greatly affect MBL.<sup>37</sup> Berglundh and Lindhe demonstrated in an animal study that a thin gingival biotype may affect crestal bone stability.<sup>38</sup> Thus, also for this type of implant, postoperative gingival biotype may be considered one of the most important clinical parameters that may affect MBL at least after 12 months from placement. Soft-tissue parameters evidenced an improvement from 6 to 12 months, showing a soft-tissue maturation over time. The mean PES was 11.09 at 6 months (2 months from definitive loading) and improved at the 12-month follow-up, showing a mean value of 11.95. This confirms that soft-tissue modifications occur during the first months of loading. Similar PES values are reported in the literature. In a 12-month clinical study, the PES of 2 different implant treatment strategies was evaluated (immediate implants versus conventional loading). Their 12-month mean values were 10.33 and 10.35, respectively.<sup>1</sup>

Interestingly, in our study, a high prevalence of the maximum soft-tissue color score was found (65.51% at 6 months and 77.28% at 12 months), despite the presence of an unfavorable preoperative score (approximately a quarter of the preoperative soft-tissue color presented a 0 score). The yellow Prama hyperbolic neck, together with the presence of a thick gingival





Figs. 3A–E

**Figs. 3A–E**

Periapical radiograph sequence of immediate implant placement restoring a fractured endodontically treated lateral incisor. (A) Preoperative radiograph. (B) Post-extraction radiograph. (C) A 3.8 × 11.5 mm implant was placed nonsubmerged immediately after extraction. A stable MBL was observed at 6 months (D) and it remained stable at the 12-month follow-up (E).

biotype (60.19%), may explain these results. Demonstrating a healthy gingiva with no inflammation, 95.44% of the implants showed an optimal soft-tissue texture. In order to further consolidate these results, BoP at the 12-month evaluation was negative in approximately 90% of the periimplant sites evaluated.

It is known that plaque accumulation around implant restorations may induce soft-tissue chronic inflammation, gingival bleeding and, in the long-term, periimplant bone loss.<sup>39</sup> Little plaque accumulation was present around implant sites at 12 months. Sites totally free from plaque ranged from 58.4% to 83.3%. The 3 mm machined surface of the implant neck, the crown design and the hygienic recall program may also have contributed to this result. It has been reported that machined surfaces may reduce plaque and bacteria accumulation around the implant emergence profile.<sup>40</sup>

Limitations of the study are represented by the small sample size and the short-term follow-up. Thus, results should be interpreted with caution. Further investigations in the long term and with a larger study cohort may confirm our results. The Prama implant, following BOPT principles, allows the clinician to model the soft tissue and have the gingival margin level with the periimplant tissue in the same way as natural tooth-supported restorations, as no finishing line is present. Moreover, the implant emergence profile with the hyperbolic configuration allows creation of the crown finishing line corresponding to the gingival margin or to the periimplant sulcus without any tissue compression. Within the limitations of this preliminary study, the results demonstrated some advantages that may be the result of simpler prosthetic management:

1. use of a noninvasive flapless technique with no second surgery for neck exposure and no need for a healing screw;
2. possibility of positioning the crown margin at different levels close to the periimplant sulcus and corresponding to the (yellow) implant neck;
3. implant–abutment connection above the gingival level;
4. minimal trauma and stress on the soft tissue during prosthetic procedures to preserve the MBL;
5. adequate control to avoid excess cement.

Two drawbacks must be reported:

1. Surgical implant positioning is critical, as no modification of the abutment axis may be later performed, so a partial lack of abutment versatility must be included.
2. The implant requires adequate distance from the opposite antagonist tooth, as the implant neck plus abutment requires at least 5 mm plus crown restoration.

## Conclusion

The use of a 2-piece nonsubmerged implant with a hyperbolic neck profile offers a new approach to the management of soft and hard tissue. In this, the prosthetic preparation makes it possible to preserve a good MBL, to reduce healing time, to perform a minimally invasive surgery, to avoid additional re-entry and to have fewer complications.

## Competing interests

The authors declare that they have no competing interests.

## References

- Raes F, Cosyn J, Crommelink E, Coessens P, De Bruyn H. Immediate and conventional single implant treatment in the anterior maxilla: 1-year results of a case series on hard and soft tissue response and aesthetics. → *J Clin Periodontol*. 2011 Apr;38(4):385–94.
- Qian J, Wennerberg A, Albrektsson T. Reasons for marginal bone loss around oral implants. → *Clin Implant Dent Relat Res*. 2012 Dec;14(6):792–807.
- Sánchez-Siles M, Muñoz-Cámara D, Salazar-Sánchez N, Camacho-Alonso F, Calvo-Guirado JL. Crestal bone loss around submerged and non-submerged implants during the osseointegration phase with different healing abutment designs: a randomized prospective clinical study. → *Clin Oral Implants Res*. 2016 Sep 5. doi:10.1111/clr.12981. [Epub ahead of print]
- Becker W, Goldstein M, Becker BE, Sennerby L. Minimally invasive flapless implant surgery: a prospective multicenter study. → *Clin Implant Dent Relat Res*. 2005;7 Suppl 1:S21–7.
- Prati C, Zamparini F, Scialabba VS, Gatto MR, Piattelli A, Montebugnoli L, Gandolfi MG. A 3-year prospective cohort study on 132 calcium phosphate-blasted implants: flap vs flapless technique. → *Int J Oral Maxillofac Implants*. 2016 Mar–Apr;31(2):413–23.
- Cocchetto R, Canullo L. The “hybrid abutment”: a new design for implant cemented restorations in the esthetic zones. → *Int J Esthet Dent*. 2015 Summer;10(2):186–208.
- Loi I, Di Felice A. Biologically oriented preparation technique (BOPT): a new approach for prosthetic restoration of periodontically healthy teeth. → *Eur J Esthet Dent*. 2013 Spring;8(1):10–23.
- Solá-Ruiz MF, Highsmith JD, Labaig-Rueda C, Agustín-Panadero R. Biologically oriented preparation technique (BOPT) for implant-supported fixed prostheses. → *J Clin Exp Dent*. 2017 Apr 1;9(4):e603–e607.
- Prati C, Zamparini F, Chersoni S, Montebugnoli L, Gandolfi MG. 12-months prospective study on two-piece transmucosal-implants in the aesthetic zone. → *J Dent Res*. 2017;96A:202.
- Canullo L, Tallarico M, Pradies G, Marinotti F, Loi I, Cocchetto R. Soft and hard tissue response to an implant with a convergent collar in the esthetic area: preliminary report at 18 months. → *Int J Esthet Dent*. 2017;12(3):306–23.
- Vandenbroucke JP, von Elm E, Altman DG, Gøtzsche PC, Mulrow CD, Pocock SJ, Poole C, Schlesselman JJ, Egger M; STROBE Initiative. Strengthening the reporting of observational studies in epidemiology (STROBE): explanation and elaboration. → *PLoS Med*. 2007 Oct 16;4(10):e297.
- Dodson TB. A guide for preparing a patient-oriented research manuscript. → *Oral Surg Oral Med Oral Pathol Radiol Endod*. 2007 Sep;104(3):307–15.
- Hämmerle CH, Chen ST, Wilson TG Jr. Consensus statements and recommended clinical procedures regarding the placement of implants in extraction sockets. → *Int J Oral Maxillofac Implants*. 2004;19 Suppl:26–8.
- Taxel P, Ortiz D, Shafer D, Pendrys D, Reisine S, Rengasamy K, Freilich M. The relationship between implant stability and bone health markers in post-menopausal women with bisphosphonate exposure. → *Clin Oral Investig*. 2014 Jan;18(1):49–57.
- Buser D, Sennerby L, De Bruyn H. Modern implant dentistry based on osseointegration: 50 years of progress, current trends and open questions. → *Periodontol* 2000. 2017 Feb;73(1):7–21.
- Sanz M, Cecchinato D, Ferrus J, Salvi GE, Ramseier C, Lang NP, Lindhe J. Implants placed in fresh extraction sockets in the maxilla: clinical and radiographic outcomes from a 3-year follow-up examination. → *Clin Oral Implants Res*. 2014 Mar;25(3):321–7.
- Thoma DS, Sanz Martin I, Benic GI, Roos M, Hämmerle CH. Prospective randomized controlled clinical study comparing two dental implant systems: demographic and radiographic results at one year of loading. → *Clin Oral Implants Res*. 2014 Feb;25(2):142–9.
- Galindo-Moreno P, León-Cano A, Ortega-Oller I, Monje A, Suárez F, ÓValle F, Spinato S, Catena A. Prosthetic abutment height is a key factor in peri-implant marginal bone loss. → *J Dent Res*. 2014 Jul;93(7 Suppl):80S–85S.
- Ferrari M, Carrabba M, Vichi A, Goracci C, Cagidiaco MC. Influence of abutment color and mucosal thickness on soft tissue color. → *Int J Oral Maxillofac Implants*. 2017 Mar–Apr;32(2):393–9.
- Cosgarea R, Gasparik C, Duda D, Culic B, Dannewitz B, Sculean A. Peri-implant soft tissue colour around titanium and zirconia abutments: a prospective randomized controlled clinical study. → *Clin Oral Implants Res*. 2015 May;26(5):537–44.
- Zembic A, Sailer I, Jung RE, Hämmerle CH. Randomized-controlled clinical trial of customized zirconia and titanium implant abutments for single-tooth implants in canine and posterior regions: 3-year results. → *Clin Oral Implants Res*. 2009 Aug;20(8):802–8.
- Fürhauser R, Florescu D, Benesch T, Haas R, Mailath G, Watzek G. Evaluation of soft tissue around single-tooth implant crowns: the pink esthetic score. → *Clin Oral Implants Res*. 2005 Dec;16(6):639–44.
- Jemt T. Regeneration of gingival papillae after single-implant treatment. → *Int J Periodontics Restorative Dent*. 1997 Aug;17(4):326–33.
- Cosyn J, Eghbali A, Hermans A, Vervaeke S, De Bruyn H, Cleymaet R. A 5-year prospective study on single immediate implants in the aesthetic zone. → *J Clin Periodontol*. 2016 Aug;43(8):702–9.
- Rogers WH. Regression standard errors in clustered samples. → *Stata Technical Bulletin*. 1993 May;13:19–23.
- Chrcanovic BR, Albrektsson T, Wennerberg A. Flapless versus conventional flapped dental implant surgery: a meta-analysis. → *PLoS ONE*. 2014 Jun 20;9(6):e100624.
- De Bruyn H, Atashkadeh M, Cosyn J, van der Velde T. Clinical outcome and bone preservation of single TiUnite implants installed with flapless or flap surgery. → *Clin Implant Dent Relat Res*. 2011 Sep;13(3):175–83.
- Rousseau P. Flapless and traditional dental implant surgery: an open, retrospective comparative study. → *J Oral Maxillofac Surg*. 2010 Sep;68(9):2299–306.
- Galindo-Moreno P, León-Cano A, Ortega-Oller I, Monje A, O'Valle F, Catena A. Marginal bone loss as success criterion in implant dentistry: beyond 2 mm. → *Clin Oral Implants Res*. 2015 Apr;26(4):e28–34.
- Nickening HJ, Wichmann M, Schlegel KA, Nkenke E, Eiter S. Radiographic evaluation of marginal bone levels during healing period, adjacent to parallel-screw cylinder implants inserted in the posterior zone of the jaws, placed with flapless surgery. → *Clin Oral Implants Res*. 2010 Dec;21(12):1386–93.
- Froum SJ, Khoully I. Survival rates and bone and soft tissue level changes around one-piece dental implants placed with a flapless or flap protocol: 8.5-year results. → *Int J Periodontics Restorative Dent*. 2017 May–Jun;37(3):327–37.
- Prati C, Zamparini F, Pirani C, Gatto MR, Piattelli A, Gandolfi MG. Immediate early and delayed implants: a 2-year prospective cohort study of 131 transmucosal flapless implants placed in sites with different pre-extractive endodontic infections. → *Implant Dent*. 2017 Oct;26(5):654–63.
- Mainetti T, Lang NP, Bengazi F, Sbricoli L, Soto Cantero L, Botticelli D. Immediate loading of implants installed in a healed alveolar bony ridge or immediately after tooth extraction: an experimental study in dogs. → *Clin Oral Implants Res*. 2015 Apr;26(4):435–41.
- Mainetti T, Lang NP, Bengazi F, Favero V, Soto Cantero L, Botticelli D. Sequential healing at implants installed immediately into extraction sockets. An experimental study in dogs. → *Clin Oral Implants Res*. 2016 Jan;27(1):130–8.
- Puysys A, Linkevicius T. The influence of mucosal tissue thickening on crestal bone stability around bone-level implants. A prospective controlled clinical trial. → *Clin Oral Implants Res*. 2015 Feb;26(2):123–9.
- Zweers J, Thomas RZ, Slot DE, Weisgold AS, Van der Weijden FG. Characteristics of periodontal biotype, its dimensions, associations and prevalence: a systematic review. → *J Clin Periodontol*. 2014 Oct;41(10):958–71.
- Berglundh T, Lindhe J. Dimension of the periimplant mucosa. Biological width revisited. → *J Clin Periodontol*. 1996 Oct;23(10):971–3.
- Renvert S, Quirynen M. Risk indicators for peri-implantitis. A narrative review. → *Clin Oral Implants Res*. 2015 Sep;26 Suppl 11:15–44.
- Calvo-Guirado JL, López-López PJ, Maté Sánchez de Val JE, Mareque-Bueno J, Delgado-Ruiz RA, Romanos GE. Influence of collar design on peri-implant tissue healing around immediate implants: a pilot study in Foxhound dogs. → *Clin Oral Implants Res*. 2015 Jul;26(7):851–7.

# Digital approach to the fabrication of a wax prototype for full-mouth rehabilitation of a worn dentition: A clinical report

## Abstract

### Background

This article describes a technique of the creation of a virtual wax-up and design of a wax prototype used as a pattern for the fabrication of posterior metal–ceramic and anterior pressed lithium disilicate restorations for a patient with a severely worn dentition.

### Materials and methods

During the rehabilitation of a patient, computer-aided design (CAD) can be used as a tool to verify marginal adaptation, occlusion and contact points before pressing or fabricating the final restorations. The prototypes work as an esthetic try-in that can be modified easily if necessary.

### Results

After proper verification, there were no marginal discrepancies and no occlusal modification was required, nor were contact points adjusted during final delivery. After a 1-year follow-up, the patient reported no complications.

### Conclusion

Computer-aided design/computer-aided manufacturing has brought many advantages to restorative dentistry, including producing predictable restorations in less time compared with traditional methods of fabrication. In this comprehensive prosthodontic rehabilitation of a severely worn dentition, the virtual diagnostic wax-up and final restoration CAD took less than 60 min for each procedure. Additionally, the wax prototype is a multipurpose restorative tool, as it serves as both an esthetic and functional try-in device and as a wax pattern for the final restoration.

### Keywords

CAD/CAM, wax prototype, smile design, digital design, lithium disilicate, virtual wax-up.

Christian Brenes,<sup>a</sup> Courtney S. Babb,<sup>a</sup> Sompop Bencharit,<sup>b</sup> Mario Romero<sup>c</sup> & Roger Arce<sup>d</sup>

<sup>a</sup> Department of General Dentistry, Dental College of Georgia, Augusta University, Augusta, Ga., U.S.

<sup>b</sup> Department of General Dentistry, Virginia Commonwealth University, Richmond, Va., U.S.

<sup>c</sup> Department of Restorative Sciences, Dental College of Georgia, Augusta University, Augusta, Ga., U.S.

<sup>d</sup> Department of Periodontics, Dental College of Georgia, Augusta University, Augusta, Ga., U.S.

### Corresponding author:

#### **Dr. Christian Brenes**

Department of General Dentistry  
Dental College of Georgia  
Augusta University  
1120 15th St  
Augusta, GA 30912  
U.S.

cbrenesvega@augusta.edu

### How to cite this article:

Brenes C, Babb CS, Bencharit S, Romero M, Arce R. Digital approach to the fabrication of a wax prototype for full-mouth rehabilitation of a worn dentition: A clinical report. J Oral Science Rehabilitation. 2017 Dec;3(4):42–47.

## Introduction

Tooth wear is a multifactorial process that can be attributed to the mechanisms of attrition, erosion and abrasion<sup>1</sup> and can adversely impact patient satisfaction with appearance, pain levels, oral comfort and chewing capacity.<sup>2</sup> Patients tend to seek help from dental professionals at a more advanced stage of wear, especially when it has esthetically compromised the incisal edges of the anterior teeth.<sup>3</sup> Alteration in clinical crown height may be necessary to improve esthetics, and this is often facilitated by increasing the vertical dimension of occlusion (VDO).<sup>4</sup> When changing the incisal position restoratively, trial restorations should be used as a guide for the patient to experience function, comfort, stability and esthetics at the new increased VDO.<sup>5</sup> Necessary changes can then be made prior to fabrication of the permanent restorations, instead of having the final restorations created without any verification process, which can potentially lead to minor or major adjustments and possible defects of the ceramic restorations. The wax prototype can easily be modified and used as a template for fabrication.

The advances in computer-aided design/computer-aided manufacturing (CAD/CAM) technology over the recent years have led to an evolution in restorative dentistry. Digital dentistry can be useful in full-mouth rehabilitation, as it has increased the ability of the dental team to efficiently create, communicate and digitally store smile designs<sup>6</sup> and wax-ups. The final restorations can be designed and milled based on the digital smile design, or the same smile design can be used to create prototypes of the final restorations for verification purposes. While scanning and milling CAD/CAM restorations have been shown to produce restorations of acceptable marginal fit below 100 µm,<sup>7</sup> recent studies have shown that the combination of a conventional polyvinylsiloxane impression method and the pressed fabrication technique produces the most accurate 3-D and 2-D marginal fit.<sup>8</sup>

The purpose of this article is to describe a technique of the creation of a virtual wax-up and design of a wax prototype used as a pattern for the fabrication of posterior metal–ceramic and anterior pressed lithium disilicate restorations for a patient with a severely worn dentition.

## Clinical report

A 66-year-old woman presented to the Department of Prosthodontics at the University of

North Carolina at Chapel Hill School of Dentistry, Chapel Hill, N.C., U.S., with the chief complaints of missing teeth and worn dentition (**Fig. 1**). Clinical examination found multiple teeth with moderate to severe attrition and erosion. The patient stated that she drank lemonade daily and had been without posterior teeth for over 5 years (**Figs. 2 & 3**). Previous dental history established replacement of missing teeth with a mandibular removable partial denture, which the patient had never tolerated owing to movement and food accumulation. The patient presented with excellent periodontal status and hygiene, and no endodontic lesions or pathologies. After evaluation of the patient records, a digital smile design was created to evaluate the possible esthetic outcome of the treatment to include the midline, occlusal plane and ideal proportions, position, symmetry and shape of the anterior teeth. Incisal edge position was determined first<sup>9</sup> by adding composite to the maxillary central incisors and evaluating the lips at rest and during smiling following the Vig and Brundo parameters of lip display.<sup>10</sup> After the length had been established, a digital smile design protocol was created and width was determined using a proportion close to 80% of the length.<sup>11</sup> The maxillary lateral incisors, canines and premolars were designed following the curvature of the lower lip and with relative tooth sizes close to the golden percentage (**Fig. 4**).<sup>12</sup>

The articulated casts were scanned using a 3-D scanner (3Shape D700, 3Shape, Copenhagen, Denmark). The 3-D image of the smile design was imported into the design software (Smile Composer, 3Shape) to follow the same design during the virtual diagnostic wax-up. The virtual diagnostic wax-up was created at an increased VDO (**Fig. 5**).

The occlusion was verified in the CAD software, and stereolithographic files were sent to the Microdental laboratory, Raleigh, N.C., U.S., to mill replicas in wax and in polymethyl methacrylate (PMMA) to be used as shell provisionals with a dry milling machine (Zenotec mini, Wieland Dental, Pforzheim, Germany).

Upon completion of the diagnostic wax-up, the dental team developed a treatment plan that included implant-supported fixed partial dentures for the missing mandibular left second premolar through first molar and mandibular right second premolar through second molar, full-coverage crowns for the mandibular left canine and right first premolar, full-coverage crowns for the maxillary anterior teeth, and a



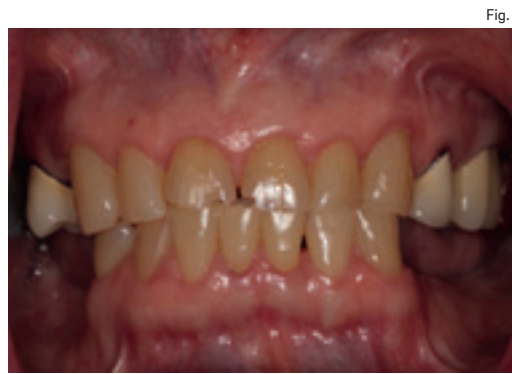

Fig. 1

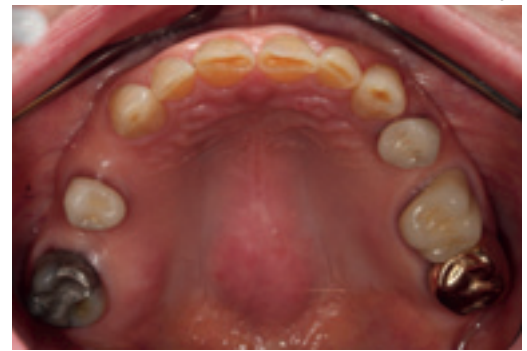

Fig. 2

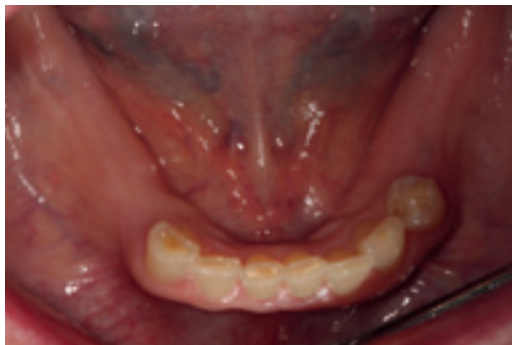

Fig. 3

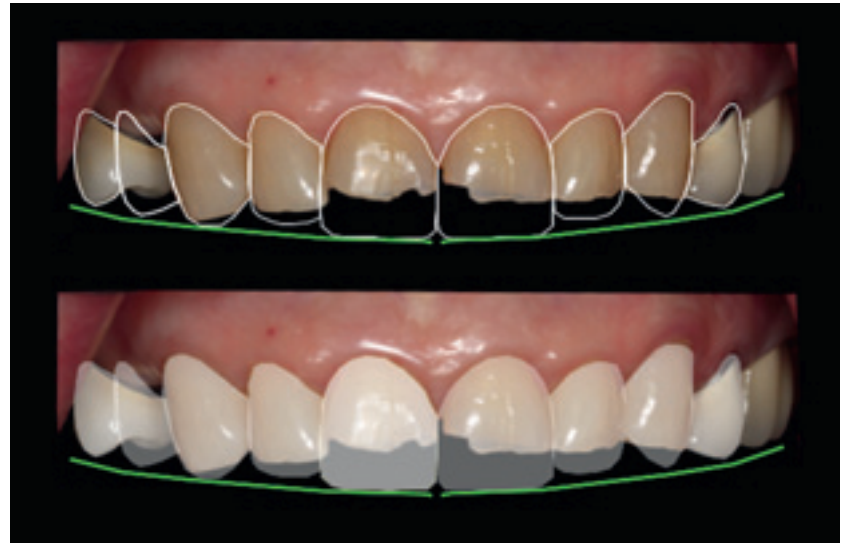

Fig. 4

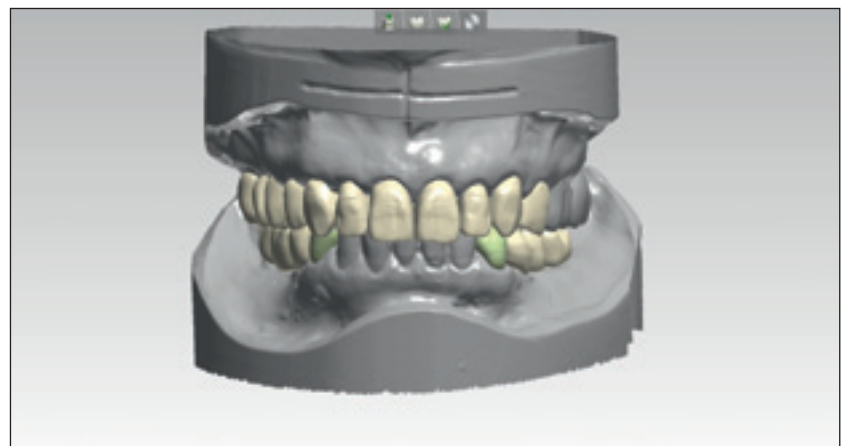


Fig. 5

**Fig. 1**  
Preoperative smile view. Note attrition on incisal edges.

**Fig. 2**  
Preoperative occlusal view of maxillary teeth. Note erosion on incisal edges and erosion on lingual surfaces of anterior teeth.

**Fig. 3**  
Preoperative occlusal view of mandibular teeth.

**Fig. 4**  
Digital smile design, establishing maxillary incisal edge position.

**Fig. 5**  
Completed virtual diagnostic wax-up at increased VDO after digital smile design.

fixed partial denture from the maxillary right second molar to second premolar.

Based on the diagnostic wax-up, a radiographic stent was fabricated and used to perform a cone beam computed tomography scan for implant placement planning. A surgical guide based on the milled wax-up was used to place 2  $4.1 \times 10.0$  mm implants (Tapered Screw-Vent Implants, Zimmer Biomet, Warsaw, Ind., U.S.)

in the position of teeth #3.4 and 4.5 and two  $4.75 \times 10.0$  mm Tapered Screw-Vent implants in the positions of teeth #3.6 and 4.7. Three months later, a second-stage surgery was performed to uncover the implants and healing abutments were placed for a period of 2 weeks.

At the preparation appointment, teeth #1.7 through 2.4 and teeth #3.3 and 4.4 were prepared for full-coverage anterior lithium disilicate

Fig. 6

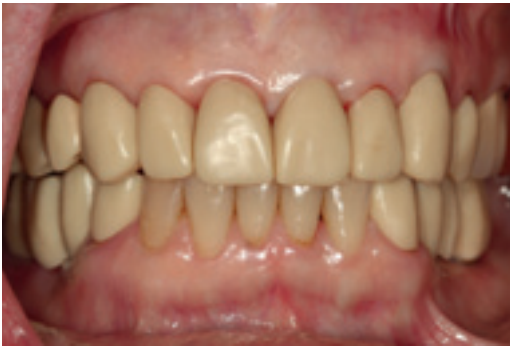
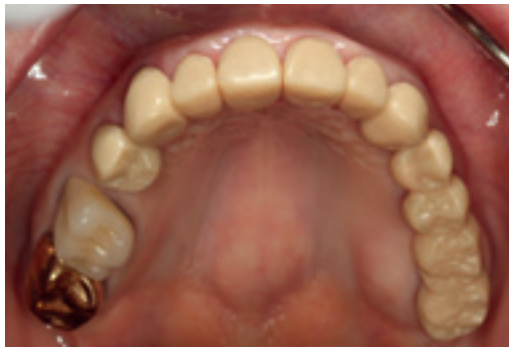
Fig. 7



**Fig. 6**

Milled wax prototype try-in, smile view.

**Fig. 7**

Milled wax prototype try-in, maxillary occlusal view.

**Fig. 8**

Milled wax prototype try-in, mandibular occlusal view.

Fig. 8

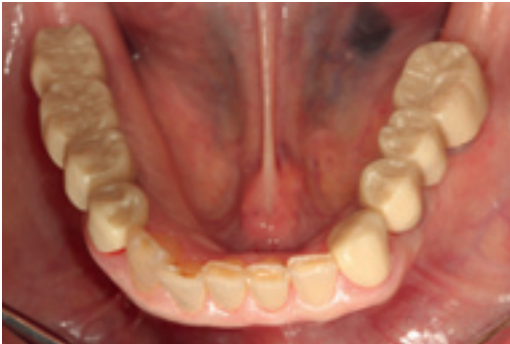
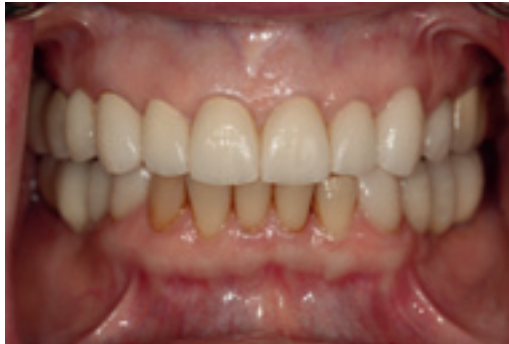
Fig. 9



**Fig. 9**

Final restorations cemented.

**Fig. 10**

Final restorations, maxillary occlusal view.

**Fig. 11**

Final restorations, mandibular occlusal view.

Fig. 10

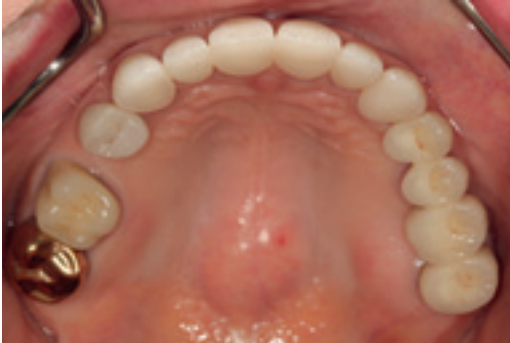
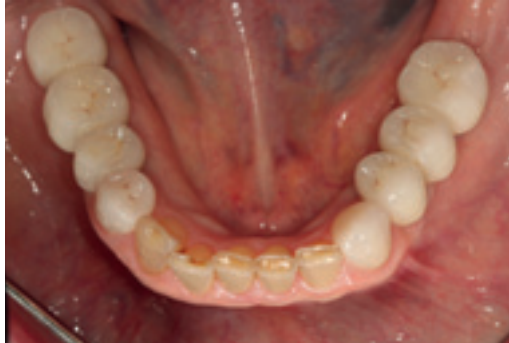
Fig. 11



crowns (IPS e.max Press, Ivoclar Vivadent, Ellwangen, Germany) and posterior metal–ceramic crowns. A double-cord impression technique for prepared teeth and a closed-tray impression technique with the impression abutments in position for the implants were performed to produce final impressions using a silicone impression material (Aquasil Ultra, Dentsply Sirona, York, Pa., U.S.). The milled PMMA provisionals, sectioned into sextants, were relined with self-curing acrylic resin (Jet Acrylic, Lang Dental, Wheeling, Ill., U.S.). Casts made from the final impressions were cross mounted with casts of the provisional restorations. All of the dies and casts were scanned with the 3Shape D700 for custom titanium abutments (Atlantis, Dentsply Sirona, York, Pa., U.S.) to be designed based on a copy of the virtual wax-up.

The custom abutments were manufactured, and the CADs of the final restorations were then copy-milled into wax prototypes by the dental laboratory with the purpose of using them as templates for the final restorations. The milled wax prototype was tried in for an occlusal and esthetic evaluation (**Figs. 7 & 8**). Both arches were evaluated and no occlusal adjustments were necessary in centric relation and during excursive movements. Minimal reduction of the incisal edges was performed to make the esthetics more age-appropriate.<sup>13</sup> The case was sent to the dental laboratory for the fabrication of the final restorations. Final characterization was done, followed by glazing and polishing (**Table 1**).

At delivery, the posterior metal–ceramic restorations and anterior IPS e.max pressed restorations were approved by the patient for

**Table 1**

Summary of the steps in the wax prototype technique.

Clinical step	Procedure
1	Preliminary impressions are taken and a traditional or digital diagnostic wax-up is made.
2	Teeth are prepared and provisionalized based on the diagnostic wax-up and following the guidelines for the type of material chosen.
3	A final traditional polyvinylsiloxane impression or digital impression is taken and used to design the final restorations.
4	A traditional digital bite record in centric relation is taken to mount the case.
5	The case is digitally designed and wax patterns are milled for verification purposes.
6	The wax patterns are modified if needed by selective grinding or wax addition.
7	Restorations are used to press or scan-copy-mill the final restorations.
8	Restorations are delivered with no expected modifications required.

Table 1

esthetics, and the restorations were verified for marginal fit, proximal contacts and occlusion. No adjustments were needed. Implant abutments were torqued to the manufacturer-recommended values, and the posterior restorations were cemented with resin cement (RelyX Unicem, 3M ESPE, Seefeld, Germany). The anterior crowns were bonded using resin cement (Variolink Esthetic, Ivoclar Vivadent; **Figs. 9–11**). The patient was very satisfied with the treatment outcome and was followed for a period of 6 months, during which time she reported no complications or complaints.

### Discussion

This clinical situation illustrated a patient with a severely worn dentition who sought dental treatment after the maxillary anterior incisal edges had become compromised, thereby affecting esthetics. Owing to the loss of clinical crown height of the maxillary incisors subsequent to erosion and attrition, the decision was made to increase the VDO in order to provide adequate space for esthetically pleasing restorations. The patient was amenable to comprehensive fixed prosthodontic rehabilitation because of missing teeth and her inability to tolerate a removable prosthesis. The diagnostic wax-up had revealed very minor issues that the patient was not interested in addressing at the time of the treatment; thus, she did not desire whitening or direct restorations on the mandibular incisors.

Traditionally, diagnostic wax-ups done by hand, by the clinician or technician, have been known to be a time-consuming step in the treatment planning process. The advantage of incorporating digital dentistry into the workflow of pressed restorations is that it provides a more consistent result in diagnostic wax-ups obtained through the use of CAD libraries, instead of relying on freehand wax-ups. Additionally, the time needed for the creation of a diagnostic wax-up is significantly reduced; in this situation, the virtual wax-up was created in less than 60 min.

The employment of CAD/CAM to create a milled wax prototype of the final restorations is a revolutionary use of the technology for both dentists and dental technicians. Not only can it be used as an esthetic and functional try-in tool by the clinician to verify marginal adaptation, occlusion and esthetics prior to delivery of the final restorations, but it also can serve as essentially a wax pattern for the fabrication of pressed or metal–ceramic restorations or a scan copy for milled restorations if any modifications are made. The wax used in CAD/CAM milling discs is very different than traditional dental wax. In order to resist the heat produced by the burs during milling, these waxes are developed as a hard hybrid plasticized wax blend, with a melting point between 101.667 and 121.111 °C.<sup>14</sup> During try-in, the shape, marginal fit, occlusion and proximal contacts of the restorations can be verified, because the rigidity of the wax allows for this. If adjustments are needed, the wax can be modified accordingly with heat or rotary

instrumentation. One limitation is that the wax prototypes do not have enough retention, a problem with restoration try-ins. Denture adhesive or fit checker (GC America, Tokyo, Japan) can be used to minimize this issue. The wax prototype can then be sent to the laboratory technician, who can then invest it as he or she would a wax pattern created through the traditional waxing process.

This wax prototype technique presents a unique melding of traditional and digital dental processes. CAD/CAM technology is used for designing and milling the wax prototype, which is then used as a traditional wax pattern to create the pressed, metal–ceramic or milled final restorations. Using this method in this clinical situation allowed for all of the restorations to be made in the same method, even though different materials (lithium disilicate for the anterior and metal–ceramic for the posterior) were used, making for a more streamlined production process. When used to create the final restoration, the wax prototype works as a template, to avoid modifying the final restoration during the delivery. In many cases, clinicians need to modify the restoration by grinding and polishing. Depending on the modification process, the final restoration can end up with internal fracture lines developed as a consequence of grinding the ceramic material that are not recognized by the clinician

and can jeopardize the treatment plan and the life span of the restoration.

## Conclusion

CAD/CAM has brought many advantages to restorative dentistry, including producing predictable restorations in less time compared with traditional methods of fabrication. In this comprehensive prosthodontic rehabilitation of a severely worn dentition, the virtual diagnostic wax-up and final restoration CAD took less than 60 min for each procedure. Additionally, the wax prototype is a multipurpose restorative tool, as it serves as both an esthetic and functional try-in device and as a wax pattern for the final restoration.

## Competing interests

The authors declare that they have no conflict of interest regarding the materials used in the present study.

## Acknowledgments

The authors thank Dr. William Bracket for his assistance in reviewing this article.

## References

- Johansson A, Johansson AK, Omar R, Carlsson GE. Rehabilitation of the worn dentition. → J Oral Rehabil. 2008 Jul;35(7):548–66.
- Al-Omri MK, Lamey PJ, Clifford T. Impact of tooth wear on daily living. → Int J Prosthodont. 2006 Nov–Dec;19(6):601–5.
- Vailati F, Carciofo S. CAD/CAM monolithic restorations and full-mouth adhesive rehabilitation to restore a patient with a past history of bulimia: the modified three-step technique. → Int J Esthet Dent. 2016 Spring;11(1):36–56.
- Wassell RW, Steele JG, Welsh G. Considerations when planning occlusal rehabilitation: a review of the literature. → Int Dent J. 1998 Dec;48(6):571–81.
- Bloom DR, Padayachy JN. Increasing occlusal vertical dimension—why, when and how. → Br Dent J. 2006 Mar 11;200(5):251–6.
- Ferencz JL. Increasing VDO and the use of CAD/CAM: prosthodontic principles and the full-mouth reconstruction. → J Cosmetic Dent. 2013 Summer;29(2):86–96.
- Reich S, Trentszsch L, Gozdowski S, Krey KF. In vitro analysis of laboratory-processed and CAD/CAM-generated occlusal onlay surfaces. → Int J Prosthodont. 2009 Nov–Dec;22(6):620–2.
- Anadioti E, Aquilino SA, Gratton DG, Holloway JA, Denry I, Thomas GW, Qian F. 3D and 2D marginal fit of pressed and CAD/CAM lithium disilicate crowns made from digital and conventional impressions. → J Prosthodont. 2014 Dec;23(8):610–7.
- Chiche GJ, Aoshima H. Functional versus aesthetic articulation of maxillary anterior restorations. → Pract Periodontics Aesthet Dent. 1997 Apr;9(3):335–42; quiz 343.
- Vig RG, Brundo GC. The kinetics of anterior tooth display. → J Prosthet Dent. 1978 May;39(5):502–4.
- Wolfart S, Thormann H, Freitag S, Kern M. Assessment of dental appearance following changes in incisor proportions. → Eur J Oral Sci. 2005 Apr;113(2):159–65.
- Murthy BV, Ramani N. Evaluation of natural smile: Golden proportion, RED or Golden percentage. → J Conserv Dent. 2008 Jan;11(1):16–21.
- Freedman GA. Contemporary Esthetic Dentistry. 1st ed. → St. Louis: Mosby/Elsevier; 2012. 461 p.
- Denry I, Holloway JA. Ceramics for dental applications: a review. → Materials (Basel). 2010 Jan;3(1):351–68.



# Is there a justification for cone beam computed tomography for assessment of proximity of mandibular first and second molars to the inferior alveolar canal: A systematic review

## Abstract

### Objective

The objective of this review was to determine the distance from the apices of mandibular first and second molars to the inferior alveolar canal (IAC) using cone beam computed tomography (CBCT).

### Data sources and study selection

Articles published between the period of 1988 to 2016 were included. This review included mandibular first and second molar studies that sought to observe proximity to the IAC using 3-D imaging modalities. The authors developed specific search strategies for PubMed, Scopus and Web of Science and evaluated the methodological quality of the included studies using criteria from the PICO protocol. Articles that aimed at determining the distance of the apices of mandibular first or second molars or both from the IAC and that used CBCT as an imaging modality were included in the study.

### Results

This review identified an average mean distance of 7.3 mm (range: 0.00–14.71 mm) from the apices of mandibular first and second molars from the IAC. The mean difference (IV, fixed, 95% CI) for first molars in women was 0.29 (95% CI: 0.11, 0.48) and for second molars was 0.50 (95% CI: -0.00, 1.01) compared with 0.31 (95% CI: 0.08, 0.54) for first molars in men and 0.23 (95% CI: -0.51, 0.98) for second molars on both sides of the mandible.

### Conclusion

We can conclude that an approximate average mean distance of 7.3 mm is present between the IAC and the apices of mandibular molars.

### Keywords

Radiology, CT imaging, imaging, surgical techniques, occlusion, stomatognathic physiology.

Shahnawaz Khijmatgar,<sup>a</sup> Chitta Chowdhury,<sup>a</sup> Kumuda Rao,<sup>b</sup> Sanal Thankappan Swarnadhai<sup>c</sup> & Nayak Krishna<sup>d</sup>

<sup>a</sup> Department of Oral Biology and Genomic Studies, A.B. Shetty Memorial Institute of Dental Sciences, Nitte University, Deralakatte, India

<sup>b</sup> Department of Oral Medicine and Radiology, A.B. Shetty Memorial Institute of Dental Sciences, Nitte University, Deralakatte, India

<sup>c</sup> Department of Statistics, K.S. Hegde Medical College and Hospital, Nitte University, Deralakatte, India

<sup>d</sup> Department of Orthodontics and Dentofacial Orthopaedics, A.B. Shetty Memorial Institute of Dental Sciences, Nitte University, Deralakatte, India

### Corresponding author:

#### Dr. Shahnawaz Khijmatgar

Department of Oral Biology and Genomic Studies  
A.B. Shetty Memorial Institute of Dental Sciences  
Nitte University  
Deralakatte-575018  
Mangalore, Karnataka  
India

khijmatgar.s@gmail.com

### How to cite this article:

Khijmatgar S, Chowdhury C, Rao K, Thankappan Swarnadhai S, Krishna N. Is there a justification for cone beam computed tomography for assessment of proximity of mandibular first and second molars to the inferior alveolar canal: A systematic review. J Oral Science Rehabilitation. 2017 Dec;3(4):48–56.



## Introduction

The inferior alveolar canal (IAC) runs in an S-shaped pattern in the mandible. Factors like age, race, sex and the anatomy of the mandible influence its location. The IAC contains a nerve that, along with the inferior alveolar artery and vein, innervates the posterior teeth through the IAC before splitting into incisive and mental components that innervate the mandibular anterior teeth, lower lip and gingiva. All of these factors have clinical significance with reference to the distance from the first and second molars to the IAC, more so than the distance from the third mandibular molar. These facts are well documented with regard to the proximity of the IAC to the apices of the mandibular first molars. The inferior alveolar nerve (IAN) is the most commonly injured nerve—about 64.4% of injuries occur from trauma due to implant placement.<sup>1</sup> While evaluating the benefits and outcomes of dental treatment, the dentist should be aware of the position of the IAN/IAC with respect to the apices of the mandibular molars.<sup>2</sup>

Injuries to the IAC are mostly iatrogenic.<sup>3</sup> Dental clinical procedures such as endodontics, tooth extraction, implant placement and other surgical procedures in the area of the first and second molars are the major causes of iatrogenic injury to the branches of the trigeminal nerve within the IAC.<sup>4</sup> In 40% of the cases, injury is due to dental implants,<sup>1</sup> followed by 1–10% due to endodontic procedures (**Fig. 1**). Other types of injury to the IAN occur through mechanical trauma caused by overinstrumentation, extrusion of chemical agents such as irrigants, intracanal medicaments, root filling materials, the presence of foreign material or thermal injury during endodontic procedures.<sup>1,5</sup> The consequence of injury to the nerve is postoperative paresthesia or anesthesia that may be transient or permanent. The mandibular second molar apices have been reported to be the closest to the IAN compared with the premolars and first molar<sup>1</sup> and hence more prone to injury.

In order to interpret these problems, clinicians rely on various methods of radiographic examination. Information regarding teeth and their associated anatomy, including root canal morphology, is commonly obtained from conventional imaging modalities such as intraoral radiographs, cephalograms, dental panoramic tomograms and cone beam computed tomography (CBCT). The conventional signs of proximity of the IAN to molars include root

narrowing, root deflection and bifid apices, as well as root canals that show diversion, narrowing or loss of lamina dura.<sup>4</sup> Hence, the newer method of 3-D imaging is considered to be the most reliable aid in assessing the relationship of roots to the IAN because of its accuracy, efficiency and effectiveness.<sup>5</sup>

The objective of this review was to determine the proximity of mandibular first and second molar apices to the IAC and to determine the justification of the use of CBCT of mandibular first and second molars to assess treatment outcome. The results of this review will enable clinicians to estimate the distance between the IAN/IAC and the apices of mandibular first and second molars on the basis of various published studies. The information obtained can be applied during various dental procedures to estimate the potential risk of any injury to the IAN/IAC due to varying dental procedures in the mandibular posterior areas.

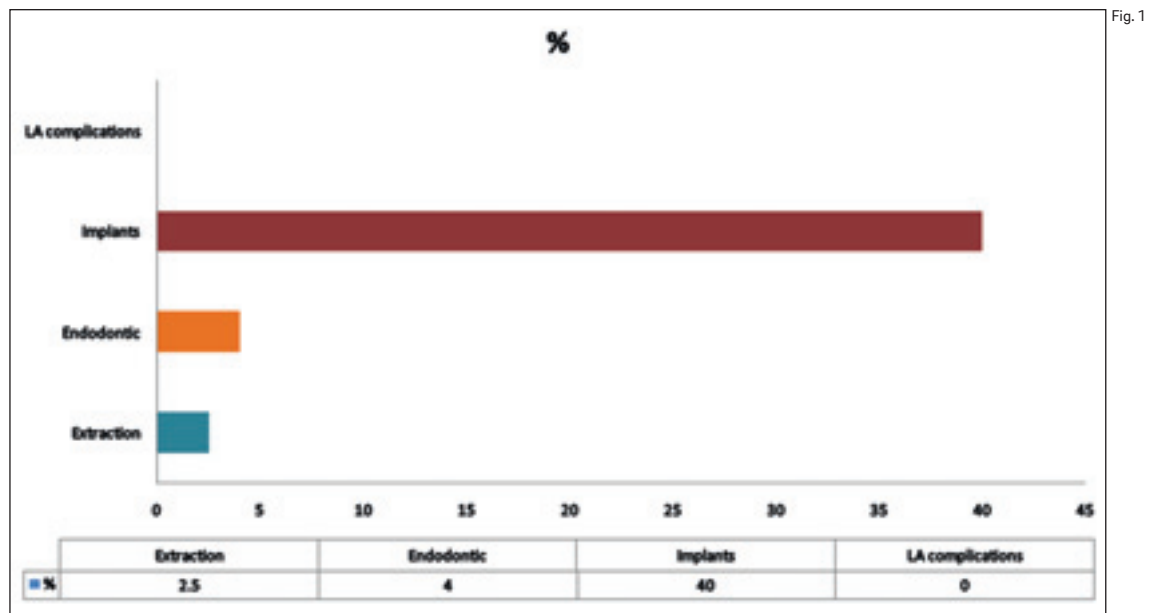
## Materials and methods

We used secondary data and included studies that considered mandibular first and second molar apices in determining proximity to the IAC using 3-D imaging. We did not include the studies for analysis from 2-D imaging, but considered them to determine the difference between 3-D and 2-D imaging in distances recorded.

### Search methods and identification and selection of studies

We carried out a search of the literature using the PubMed, Web of Science and Scopus databases. A total of three independent searches were carried out. The study used reports of CBCT scans from 1986 to 2016 that included first and second mandibular molars and their distance to the IAC in different populations and considering age, sex and various other factors. The key terms used for extracting the relevant articles were "cone beam computed tomography" or "cbct" or "CBCT dental" or "cone beam CT dental" or "cone beam dental" and "inferior alveolar canal" or "IAN canal" or "IAN" and "lower molar" or "lower first molar" or "lower second molar" or "mandibular molar". The process of article inclusion and exclusion was according to the PRISMA protocol (**Fig. 2**).

The initial search of all three databases yielded 94 articles. Later, after reviewing the



**Fig. 1**  
Prevalence of causes of inferior alveolar nerve injury.

titles and abstracts, 74 articles found to be duplicates and not to meet the criteria were eliminated. Ten articles were included for full-text reading and one study was eliminated. The 3-D studies Hiremath et al.,<sup>6</sup> Kawashima et al.,<sup>1</sup> Chong et al.,<sup>2</sup> Bürklein et al.,<sup>7</sup> Adigüzel et al.<sup>8</sup> and Simonton et al.<sup>9</sup> were included for further data analysis. The 2-D studies Tilotta-Yasukawa et al.<sup>10</sup> and Littner et al.<sup>11</sup> were included for the sake of comparison. A summary of the included articles found in the search of the databases is provided in **Table 1**.

#### Data collection and analysis

The data were the year of publication, author, country of study, type of imaging modality, model of CBCT machine, technical specifications and the distances in millimeters measured from the apices of mandibular first and second molars to the IAC. Meta-analyses were planned only when sufficient similarities were found among the included studies with regard to the side of mandible, that is, right or left; mesial or distal root; first or second molar; male or female. Sub-group analyses were conducted for different quadrants of the mandible, sex and tooth. Mean differences and standard deviations were used to summarize the data in the studies with continuous outcomes. Heterogeneity was assessed using the  $I^2$  statistic. A forest plot was constructed using Review Manager (Version 5.3, Nordic Cochrane Centre, Cochrane Collaboration, Copenhagen, Denmark).

#### Assessment of risk of bias in included studies

Based on the design and content of the selected studies, their quality was evaluated independently by two reviewers (SK and STS). The risk of bias assessment was not possible owing to nonavailability of clinical trials and the nature of the study. It was only possible to extract data from secondary data.

## Results

Among 94 articles, the authors selected 9 articles, including 7 studies that used a 3-D imaging modality, for further analysis. Since the review made use of secondary data, it was not possible to comment on risk of bias. The sample size ranged from 216 to 999 adults. This review identified an average mean distance of 7.3 mm (range: 0.00–14.71 mm) from the apices of mandibular first and second molars to the IAC. The mean difference (IV, fixed, 95% CI) on both sides of the mandible for first molars in women was 0.29 (95% CI: 0.11, 0.48) and for second molars was 0.50 (95% CI: -0.00, 1.01) compared with 0.31 (95% CI: 0.08, 0.54) for first molars in men and 0.23 (95% CI: -0.51, 0.98) for second molars. The proportion of women to men whose first or second molars were closely located to the IAC was 3 to 1. According to some studies, the distance was smaller in young individuals. The meta-analysis of the articles that had

Fig. 2

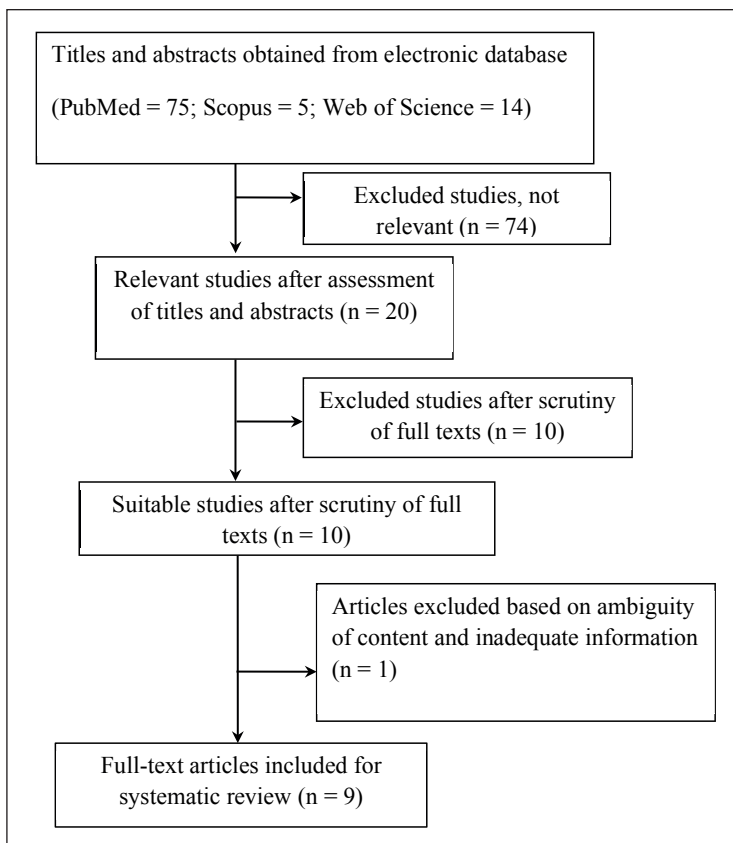


Fig. 2

Schematic representation of the article selection process.

similar characteristics and data is illustrated in **Figures 3 to 11**.

## Discussion

According to the studies in **Table 1**, the distance of the IAN from the apices of first and second molars ranged from 0.00 to 14.71 mm. The average mean distance was found to be 7.3 mm. These findings were from both 2-D and 3-D imaging techniques (**Fig. 12**). The distance varied according to factors such as sex, age and race (**Table 2**).

### Sex

Recent studies Hiremath et al. and Adigüzel et al. considered sex as one of the factors in their studies that may influence proximity of the IAN to the apices of first and second molars.<sup>6,8</sup> These studies found that the distance from the IAN to the apices of first and second molars was smaller in women than in men.<sup>6,7</sup> Studying an Indian population, Hiremath et al. found that the distance of the mesial apices of first molars from the IAN was 1.46–13.2 mm in men and 0.93–8.03 mm in women, and for second molar,

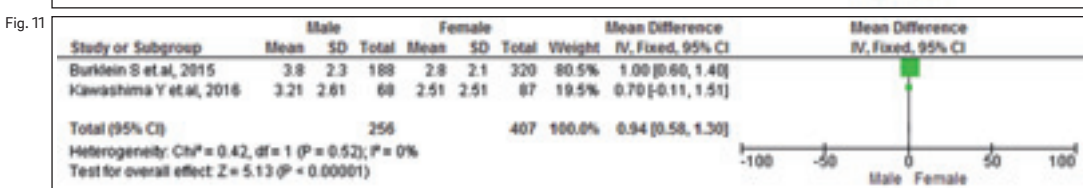
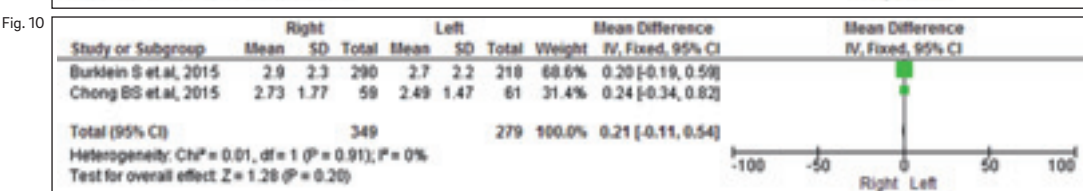
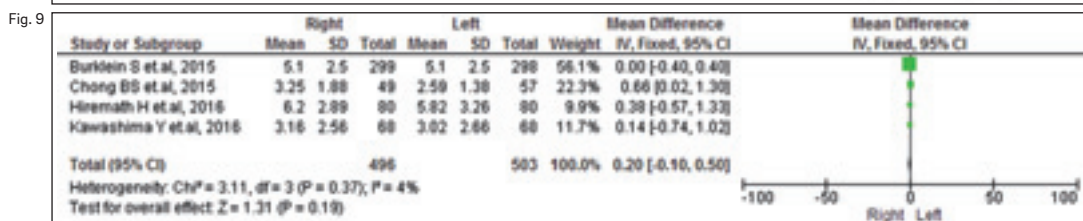
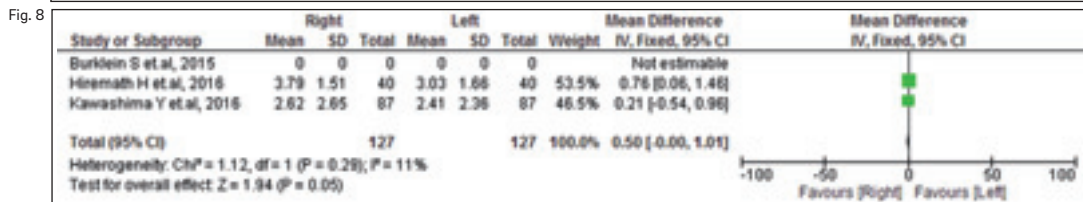
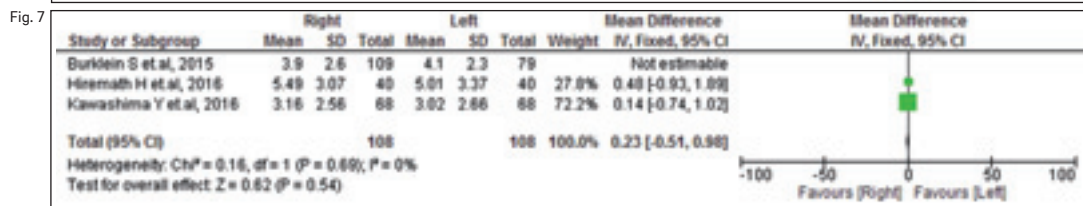
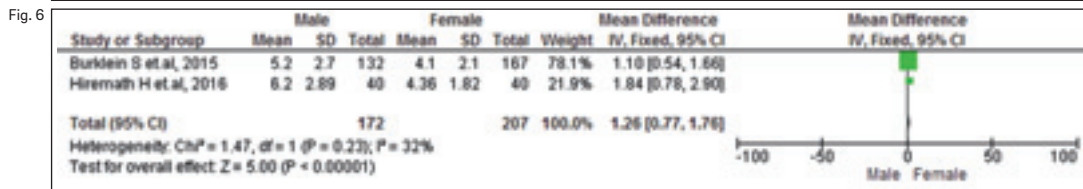
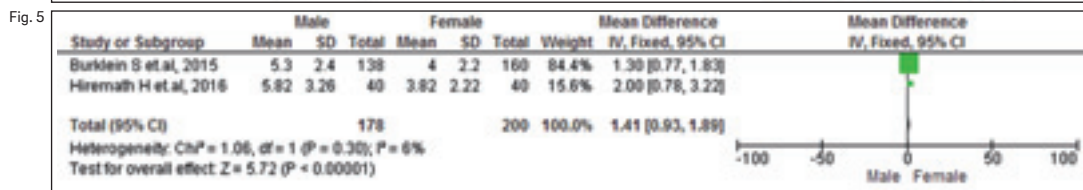
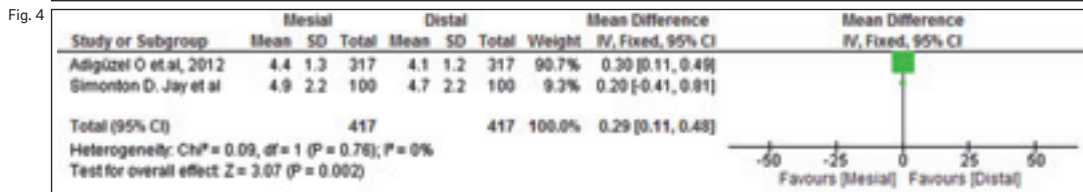
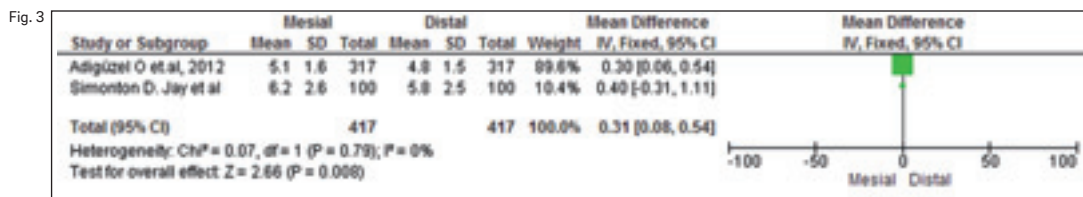
the average distance was 1.31–14.71 mm in men and 0.00–6.90 mm in women.<sup>6</sup> A study by Adigüzel et al. on a Turkish population found that the distance from the IAN to first molars in men was 5.1 mm mesially and 4.8 mm distally and for women was 4.4 mm mesially and approximately 4.1 mm distally.<sup>8</sup> The difference in distance between men and women may be due to men generally having a larger bone structure and consequently a greater distance between apices and first and second molars.<sup>7</sup> Hence, clinically, there will be a greater possibility of iatrogenic nerve damage in women compared with men.<sup>1</sup>

### Age

Bürklein et al. and Adigüzel et al. considered age also as a factor in their studies to determine proximity of the IAN to the apices of first, second and third molars.<sup>7,8</sup> In a study conducted on a German population, Bürklein et al. sought to determine the proximity of the IAN to the apices of mandibular first and second molars.<sup>7</sup> They found that the distance from the IAN to the mandibular first, second and third molars was smaller in patients younger than 35 years when compared with older age groups. Adigüzel et al.

Table 1

No.	Author	Country	Imaging modality	Method	Result (distance in mm)
1	Hiremath et al. <sup>6</sup>	India	3-D (CS 9300, Kodak CBCT)	CBCT scans of 40 men and 40 women	Distance from IAN to mesial apex of 1 <sup>st</sup> molar: 1.46–3.23 mm (men); 0.93–8.03 mm (women) Average distance for 2 <sup>nd</sup> molar: 1.31–14.7 mm (men); 0.00–6.91 mm (women)
2	Kawashima et al. <sup>1</sup>	U.S.	3-D (i-CAT, Imaging Sciences International) at 120 kVp and 4–7 mA with 14-bit gray scale resolution and voxel size of 0.125–0.300 mm	68 men, 87 women aged 20 years and older	See Table 1 in study
3	Chong et al. <sup>2</sup>	U.K.	3-D (PaX-Reve3D, VATECH, Ewoo Technology) operating at 3.5 mA and 85 kV; field of view for mandibular molar region was 5 × 9 × 5 cm and voxel size was 0.08 mm.	272 mandibular 2 <sup>nd</sup> molar roots evaluated from 134 CBCT scans	Distance between anatomical apex and IAN was < 3 mm
4	Bürklein et al. <sup>7</sup>	Germany	3-D (Planmeca ProMax 3D, Planmeca)	627 CBCT scans of a German population (58.2% women, 41.8% men); mean age of 51 years	Distance from IAN/IAC to 1 <sup>st</sup> molar was 4.9 mm, to 2 <sup>nd</sup> molar was 3.1 mm and to 3 <sup>rd</sup> molar was 2.6 mm
5	Tilotta-Yasukawa et al. <sup>10</sup>	France	2-D	2-D radiographic study of 35 out of 40 cases	Distance of 2 <sup>nd</sup> and 3 <sup>rd</sup> molars from mandibular canal was < 1 mm
6	Al-Jandan et al. <sup>14</sup>	Saudi Arabia	3-D	CBCT scans of hemimandibles	Horizontal distance at level of apex and IAC area at 2 <sup>nd</sup> molar: 4 mm; greater than that of 1 <sup>st</sup> molar
7	Adigüzel et al. <sup>8</sup>	Turkey	3-D (i-CAT Next Generation, Imaging Sciences International)	CBCT scans of 100 male and female patients aged 15–65 years	Distance from IAN to 1 <sup>st</sup> molar: men: 5.1 mm (mesial), 4.8 mm (distal); women: 4.4 mm (mesial), approx. 4.1 mm (distal)
8	Simonton et al. <sup>9</sup>	U.S.	3-D (Accuitomo 3DX Morita CBCT, J. Morita)	200 patients (1) Known age: 30–69 years; (2) Known sex: 25 men and 25 women were collected for each 10-year age bin (3) CBCT scans covered mandibular 1 <sup>st</sup> molar and IAN	See Table 1 in study
9	Littner et al. <sup>11</sup>	Israel	2-D	2-D radiographic study of 46 dry mandibles	Mandibular canal was located 3.5–5.4 mm below apices of both 1 <sup>st</sup> and 2 <sup>nd</sup> molars
10	Chrcanovic et al. <sup>13</sup>	Sweden	3-D	CBCT scans of 118 subjects	1 <sup>st</sup> and 2 <sup>nd</sup> molar distance was < 6 mm

**Table 1**

Summary of the articles that were included in the review.

**Fig. 3**

Forest plot for the comparison of the distance of the inferior alveolar canal from the apices of first molars in men.

**Fig. 4**

Forest plot for the comparison of the distance of the inferior alveolar canal from the apices of first molars in women.

**Fig. 5**

Forest plot for the comparison of the distance of the inferior alveolar canal from the apices of left first molars in men and women.

**Fig. 6**

Forest plot for the comparison of the distance of the inferior alveolar canal from the apices of right first molars in men and women.

**Fig. 7**

Forest plot for the comparison of the distance of the inferior alveolar canal from the apices of second molars in men.

**Fig. 8**

Forest plot for the comparison of the distance of the inferior alveolar canal from the apices of second molars in women.

**Fig. 9**

Forest plot for right and left side.

**Fig. 10**

Forest plot for second molar distal root.

**Fig. 11**

Forest plot for comparison of differences in the distance of the inferior alveolar canal from second molars in relation to sex.

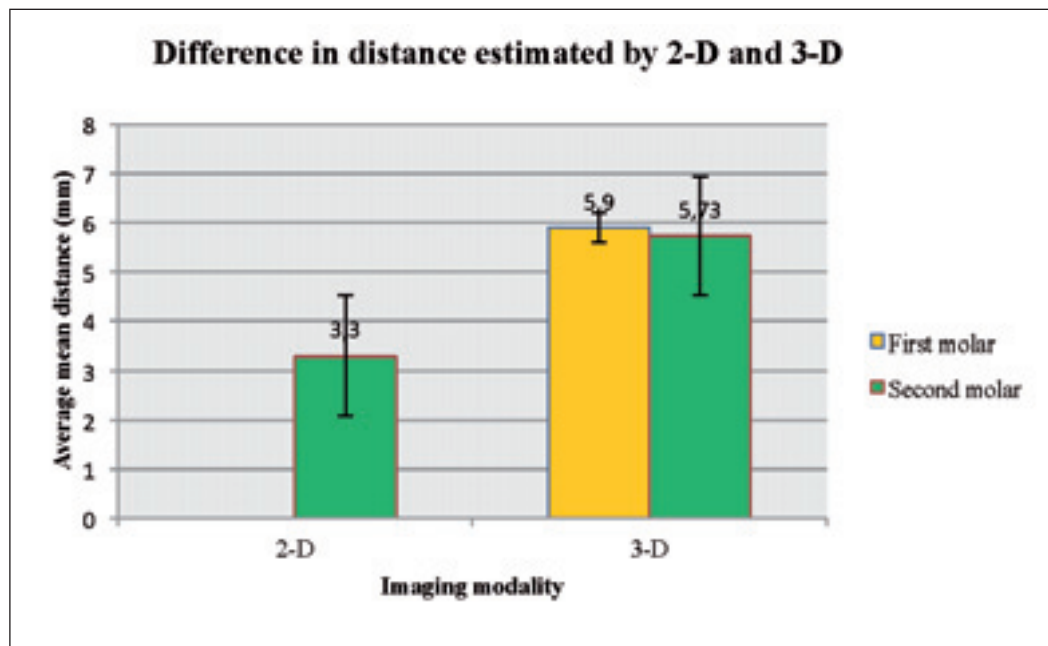


**Fig. 12**

Schematic representation of differences in distance estimated with the respective 2-D and 3-D imaging modality.

**Table 2**

Overview of the distance between the apices of mandibular first and second molars (data considered for meta-analysis).

**Fig. 12**

concluded that the distance was smaller in the groups aged 16–25 years and 56–65 years compared with other age groups.<sup>8</sup> Previous studies have confirmed that the distance between the apices and the mandibular canal increased with eruption of mandibular teeth.<sup>11</sup> Kawashima et al. showed that there was increased bone growth after eruption of teeth and/or inferior migration of the IAC with age in both sexes.<sup>1</sup>

#### Race

Levine studied an American population and found that white patients on average had a lower distance between the buccal aspect of the canal and the outer buccal and superior cortical plates of the mandible.<sup>12</sup> They concluded that, in order to minimize the risk of IAN injury, these variables should be considered when planning mandibular osteotomies or using monocortical plates.

Hiremath et al. found that the distance from the IAN to the apices of first and second molars ranged from 0.00 to 14.71 mm in general,<sup>6</sup> and Adigüzel et al. found it to be 4.1–5.1 mm.<sup>8</sup> Chrcanovic found the distance from the IAN to first and second molars to be less than 6 mm.<sup>13</sup> Bürklein et al. showed that the distance from the IAN to first molars to be 4.9 mm, to second molars to be 3.1 mm and to third molars to be 2.6 mm.<sup>7</sup> Chong et al. demonstrated that the distance between the anatomical apex and the IAN was less than 3 mm.<sup>2</sup> Al-Jandan et al.

showed that the horizontal distance at the level of the apex and the IAC area at the second molar was 4 mm greater than at the first molar.<sup>14</sup> Alves et al. found that the distance of second and third molars from the mandibular canal was less than 1 mm.<sup>15</sup> Littner et al. suggested that the mandibular canal was located 3.5–5.4 mm.<sup>11</sup> Denio et al.'s study of dry mandibles concluded that the distance from second molars to the IAN was 3.7 mm and from first molars was 6.9 mm on 2-D radiographs.<sup>8, 16–18</sup>

Basically, there are three important processes that influence the development of the craniofacial bones: size increase, remodeling and displacement. The first two processes occur simultaneously by a combination of bone resorption and displacement. The last one results in the displacement of all the bones away from each other to undergo a size increase. The remodeling and displacement processes change and vary according to age, sex and race. These changes will have impact on the location of the IAC/IAN with respect to the apices of mandibular first and second molars.

#### Quality of evidence

The data in the first instance were derived from secondary data and the studies used varying methodologies to estimate the distance from the apices of the mandibular first and second molars to the IAC. Hence, the results obtained should be interpreted with caution.

Table 2

Type of tooth	Study	Variables		Sample size (n)	Mean $\pm$ SD
First molar	Bürklein et al. <sup>7</sup>	Left side	Mesial	298	5.1 $\pm$ 2.5
			Male	138	5.8 $\pm$ 2.4
			Female	160	4.5 $\pm$ 2.4
		Right side	Mesial	299	5.1 $\pm$ 2.5
			Male	132	5.7 $\pm$ 2.7
			Female	167	4.6 $\pm$ 2.2
		Left side	Distal	298	4.6 $\pm$ 2.4
			Male	138	5.3 $\pm$ 2.4
			Female	160	4.0 $\pm$ 2.2
		Right side	Distal	299	4.6 $\pm$ 2.4
			Male	132	5.2 $\pm$ 2.7
			Female	167	4.1 $\pm$ 2.1
		Male	–	270	5.6 $\pm$ 2.4
		Female	–	327	4.3 $\pm$ 2.3
		Left side	Male	138	5.3 $\pm$ 2.4
			Female	160	4.0 $\pm$ 2.2
		Right side	Male	132	5.2 $\pm$ 2.7
			Female	167	4.1 $\pm$ 2.1
		–	–	597	4.85 $\pm$ 2.5
	Hiremath et al. <sup>6</sup>	Left side	Male	40	5.82 $\pm$ 3.26
			Female	40	3.82 $\pm$ 2.22
		Right side	Male	40	6.20 $\pm$ 2.89
			Female	40	4.36 $\pm$ 1.82
	Adigüzel et al. <sup>8</sup>	Mesial	Male	317	5.1 $\pm$ 1.6
			Female	317	4.4 $\pm$ 1.3
		Distal	Male	317	4. $\pm$ 1.5
			Female	317	4.1 $\pm$ 1.2
	Simonton et al. <sup>9</sup>	Male	Mesial	100	6.2 $\pm$ 2.6
			Distal	100	5.8 $\pm$ 2.5
		Female	Mesial	100	4.9 $\pm$ 2.2
			Distal	100	4.7 $\pm$ 2.2
Second molar	Bürklein et al. <sup>7</sup>	Left side	Mesial	218	3.5 $\pm$ 2.3
		Mesial	Male	79	4.1 $\pm$ 2.3
			Female	139	3.1 $\pm$ 2.3
		Right side	Mesial	290	3.4 $\pm$ 2.3
		Mesial	Male	109	3.9 $\pm$ 2.6
			Female	181	2.9 $\pm$ 2.0
		Left side	Distal	218	2.7 $\pm$ 2.2
		Distal	Male	79	3.7 $\pm$ 2.2
			Female	139	2.7 $\pm$ 2.2
		Right side	Distal	290	2.9 $\pm$ 2.3
			Male	109	3.5 $\pm$ 2.6
			Female	181	2.5 $\pm$ 1.9
		Mesial	–	508	3.4 $\pm$ 2.3
			Male	188	4.0 $\pm$ 2.4
			Female	320	3.0 $\pm$ 2.2
		Distal	–	508	2.8 $\pm$ 2.3
			Male	188	3.6 $\pm$ 2.4
			Female	320	2.6 $\pm$ 2.1
		Total	–	508	3.13 $\pm$ 2.3
		Male	–	188	3.8 $\pm$ 2.3
		Female	–	320	2.8 $\pm$ 2.1
	Kawashima et al. <sup>1</sup>	Male	–	68	3.21 $\pm$ 2.61
		Female	–	87	2.51 $\pm$ 2.51
		Male	Right side	68	3.16 $\pm$ 2.56
			Left side	68	3.02 $\pm$ 2.66
		Female	Right side	87	2.62 $\pm$ 2.65
			Left side	87	2.41 $\pm$ 2.36
	Chong et al. <sup>2</sup>	Mesial	Right side	49	3.25 $\pm$ 1.88
			Left side	57	2.59 $\pm$ 1.38
		Distal	Right side	59	2.73 $\pm$ 1.77
			Left side	61	2.49 $\pm$ 1.47
	Hiremath et al. <sup>6</sup>	Male	Left side	40	5.01 $\pm$ 3.37
			Right side	40	5.49 $\pm$ 3.07
		Female	Left side	40	3.03 $\pm$ 1.66
			Right side	40	3.7 $\pm$ 1.51

### Agreements and disagreements between studies included in the review

Adigüzel et al. and Simonton et al. used a similar methodology in determining the distance between the apices of mandibular first and second molars and the IAC.<sup>8,9</sup> These two studies used sagittal scans and intervariability tests and considered various factors that influence IAC location with respect to first and second molars. Bürklein et al. stated the inclusion and exclusion criteria.<sup>7</sup> The above-mentioned studies lack a scientific approach in determining the distance and hence, this might be a source of potential bias. Chong et al. tried to follow the principle of the Pythagoras theorem to determine the distance, which is the scientific method of determining the distance between two points.<sup>2</sup> The investigators should have considered an inter-observer reliability between two dental radiologists. The study should also have considered sex and age as factors in determining the distance.

### Conclusion

We can conclude that the average mean distance between the IAC and the apices of mandibular molars is approximately 7.3 mm. In addition to this, certain factors, such as age, sex, race, position of tooth and bone thickness, play a key role in determining the distance between the IAC and the apex. The values found are mean values and the clinical decision should be made on a case-by-case basis and the type of imaging modality used. There is significant application of CBCT in clinical outcome while treatment planning in the first and second mandibular molar region.

### Acknowledgment

We would like to thank Drs. Namitha Thomas, Natasha Shetty and Neethu for their initial participation in the review.

### Competing interests

The authors declare that they have no conflict of interest regarding the materials used in the present study. No funding was given to conduct this review.

## References

- Kawashima Y, Sakai O, Shosho D, Kaneda T, Gohel A. Proximity of the mandibular canal to teeth and cortical bone. → J Endod. 2016 Feb 29;42(2):221–4.
- Chong BS, Quinn A, Pawar RR, Makdissi J, Sidhu SK. The anatomical relationship between the roots of mandibular second molars and the inferior alveolar nerve. → Int Endod J. 2015 Jun;48(6):549–55.
- Burstein J, Mastin C, Le B. Avoiding injury to the inferior alveolar nerve by routine use of intraoperative radiographs during implant placement. → J Oral Implantol. 2008 Feb;34(1):34–8.
- Renton T. Prevention of iatrogenic inferior alveolar nerve injuries in relation to dental procedures. → Dental Update. 2010 Jul–Aug;37(6):350–2, 354–6, 358–60 passim.
- Escoda-Francoli J, Canalda-Sahli C, Soler A, Figueiredo R, Gay-Escoda C. Inferior alveolar nerve damage because of overextended endodontic material: a problem of sealer cement biocompatibility? → J Endod. 2007 Dec;33(12):1484–9.
- Hiremath H, Agarwal R, Hiremath V, Phulambrikar T. Evaluation of proximity of mandibular molars and second premolar to inferior alveolar nerve canal among central Indians: a cone-beam computed tomographic retrospective study. → Indian J Dent Res. 2016 May–Jun;27(3):312–6.
- Bürklein S, Grund C, Schäfer E. Relationship between root apices and the mandibular canal: a cone-beam computed tomographic analysis in a German population. → J Endod. 2015 Oct;41(10):1696–700.
- Adigüzel Ö, Yiğit-Özer S, Kaya S, Akkuş Z. Patient-specific factors in the proximity of the inferior alveolar nerve to the tooth apex. → Med Oral Patol Oral Cir Bucal. 2012 Nov 1;17(6):e1103–8.
- Simonton JD, Azevedo B, Schindler WG, Hargreaves KM. Age- and gender-related differences in the position of the inferior alveolar nerve by using cone beam computed tomography. → J Endod. 2009 Jul;35(7):944–9.
- Tilotta-Yasukawa F, Millot S, El Haddioui A, Bravetti P, Gaudy JF. Labiomandibular paresthesia caused by endodontic treatment: an anatomic and clinical study. → Oral Surg Oral Med Oral Pathol Oral Radiol Endod. 2006 Oct;102(4):e47–59.
- Littner MM, Kaffe I, Tamse A, Dicapua P. Relationship between the apices of the lower molars and mandibular canal—a radiographic study. → Oral Surg Oral Med Oral Pathol. 1986 Nov;62(5):595–602.
- Levine MH, Goddard AL, Dodson TB. Inferior alveolar nerve canal position: a clinical and radiographic study. → J Oral Maxillofac Surg. 2007 Mar;65(3):470–4.
- Chrcanovic BR, de Carvalho Machado V, Gjølvd B. Immediate implant placement in the posterior mandible: a cone beam computed tomography study. → Quintessence Int. 2016 May;47(6):505–14.
- Al-Jandan BA, Al-Sulaiman AA, Marei HF, Syed FA, Almana M. Thickness of buccal bone in the mandible and its clinical significance in mono-cortical screws placement. A CBCT analysis. → Int J Oral Maxillofac Surg. 2013 Jan;42(1):77–81.
- Alves FR, Coutinho MS, Gonçalves LS. Endodontic-related facial paresthesia: systematic review. → J Can Dent Assoc. 2014;80:e13.
- Sharma U, Narain S. Unusual facial pain secondary to inferior alveolar nerve compression caused by impacted mandibular second molar. → J Indian Soc Pedod Prev Dent. 2014 Apr–Jun;32(2):164–7.
- Umar G, Bryant C, Obisesan O, Rood JP. Correlation of the radiological predictive factors of inferior alveolar nerve injury with cone beam computed tomography findings. → Oral Surgery. 2010 Aug;3(3):72–82.



# 13-15 APRIL 2018 SUNTEC SINGAPORE

## THE LEADING DENTAL EXHIBITION AND CONFERENCE IN ASIA PACIFIC

### MEET THE 2018 CONFERENCE SPEAKERS



**Galip  
Gurel**



**Magda  
Feres**



**Christopher  
Ho**



**Simone  
Grandini**



**Lawrence  
Lau**



**Magda  
Mensi**



**Angelo  
Mariotti**



**Marcus  
Dagnelid**



**Andreas  
Kurbad**



### TRADE EXHIBITION


Meet over **550** exhibitors at IDEM and discover the latest products and services the dental industry has to offer. IDEM attracts all the major players in the dental industry to the Asia Pacific for three power packed days of exhibition, making it the ideal platform to cement your existing professional relationships and connect with future business partners.

## EARLY BIRD REGISTRATION CLOSES ON 31 JANUARY 2018!

#### Registration

Koelnmesse Pte Ltd  
Ms. Cindy Tantarica  
T: +65 6500 6700  
E: idem-reg@koelnmesse.com.sg

#### Connect with us



#### Endorsed by



#### Supported by



#### Held in



#### Organised by



# Bringing science to the surface

An interview with Prof. Matthias Karl



**Prof. Matthias Karl**  
of Saarland University  
in Germany

answers questions on the significance of a newly published meta-analysis evaluating Nobel Biocare's TiUnite implant surface<sup>1</sup> for researchers, clinicians and patients.

**Prof. Karl, what was your rationale for conducting a meta-analysis to investigate the clinical performance of implants with the TiUnite surface?**

The TiUnite surface was launched over 15 years ago and in that time certainly has set the standard in implant dentistry. It's one of the major implant surfaces on the market. We felt that it was time to evaluate TiUnite implants in a comprehensive meta-analysis of prospective clinical studies—not with preclinical data, not with retrospective data, not with case reports, but the highest possible quality of evidence.

**How did you decide which studies to include in the analysis?**

We had strict inclusion criteria. We looked only at prospective clinical studies with at least 20 patients who had received TiUnite implants at the beginning of the study. A minimum of a 1-year postloading follow-up was also required. In terms of reporting, we had to be able to either derive the cumulative survival rate from the paper or calculate the survival rate based on the data given in the paper.

**Despite the strict inclusion criteria, the study is thought to be the largest analysis of this kind on a single brand of implants. What was the scale of the data examined?**

It's certainly the largest such study I've seen. We reviewed 106 well-documented prospective clinical studies. To have such a high number of primary studies in a single review is something really unique. In total, over 12,000 TiUnite implants were part of the evaluation. This represents a huge database and should be regarded as a real strength for Nobel Biocare, as well as the clinicians using Nobel Biocare implants and their patients. I think it's really the highest level of evidence we have right now documenting the clinical success of a single implant surface.

**What did you set out to discover in all this data?**

We did not have any predetermined expectations—that is another strong point of this review in my opinion. Our aim was not to cherry-pick data, but to conduct an unbiased review of the literature.

Another unique feature of the study is that we used implant placement as a baseline. Bone remodeling takes place predominantly between implant placement and abutment connection. In many studies, it's only at the prosthetic restoration that the clock starts to run, but by then a certain amount of remodeling has already taken place. It's more honest to go back and report the implant surgery as the baseline and assess the bone levels from then on.

We were able to really look at marginal bone level changes from the beginning, from the surgery, for many, many studies, and also looked into biological complications if they had been reported. Of course, we also looked at periimplantitis and periimplant pathology.

**The definition of "periimplantitis" is presently a much-debated topic in dental implantology. How did you define it for the purposes of this paper?**

The definition of "periimplantitis" is indeed a hot topic right now. What we did in the paper is not to over- or underestimate periimplantitis. If the primary author referred to "periimplantitis" or if there was periimplant inflammation or periimplant pathology, we counted this as periimplantitis no matter what. We are well aware that these authors were acting on different scales, but if they used the term "periimplantitis" or similar, we did not question it.

**What were the key findings of your analysis?**

For me, the key finding was that TiUnite is a highly reliable implant surface even in very



challenging situations. Nobel Biocare has a full range of implant designs with the TiUnite surface, and we could not differentiate implant performance between different implant geometries. In the end, the study results demonstrated that it's a really great surface. It keeps the implant in place, and the longevity is proven. The prevalence of periimplantitis was extremely low. There were no major biological complications and the marginal bone level changes were well within the accepted thresholds for a successful implant.

**How can the findings of your analysis now be used to optimize clinical practice?**

Clinicians can use the values presented in the paper as a reference. This is the real benefit of such an extensive review. In our own practices, we can only see a limited number of patients. What we have here is an analysis of over 12,000 implants spanning a 15-year period. I would advise clinicians to look at these values and compare them with what they have seen in their practices. Then they can ask themselves where they are in relation to the data and why that might be. If they are not seeing the same success, why is that? The findings are a helpful benchmark for modern practice.

## Reference

1. Karl M, Albrektsson T. Clinical performance of dental implants with a moderately rough (TiUnite) surface: a meta-analysis of prospective clinical studies. → Int J Oral Maxillofac Implants. 2017 Jul-Aug;32(4):717–34.

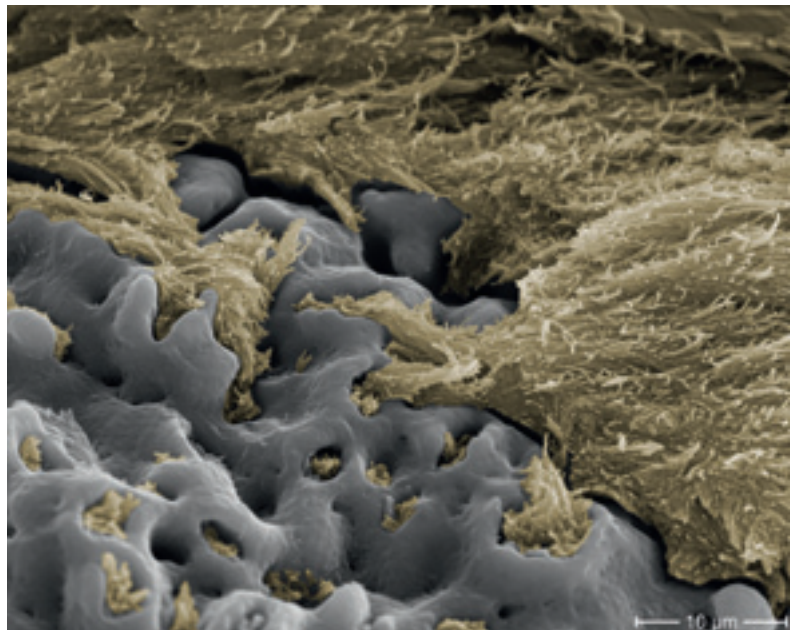
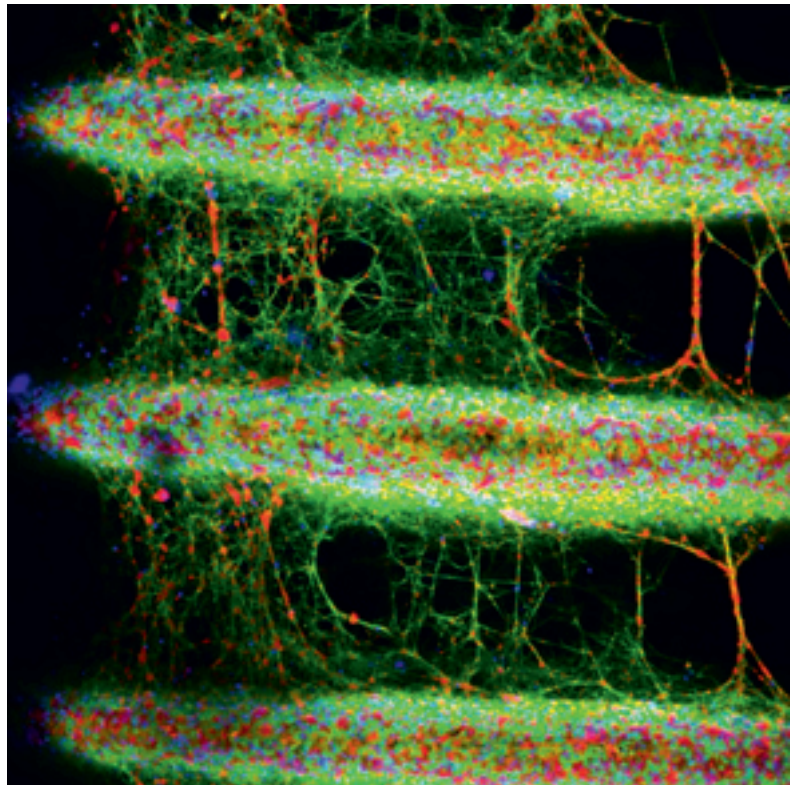


Image: © Schüpbach Ltd.

For more information about the TiUnite surface and its supporting clinical evidence, visit [nobelbiocare.com/tiunite](https://nobelbiocare.com/tiunite).

# Authors must adhere to the following guidelines

## Informed consent

Patients have a right to privacy that should not be violated without informed consent. Identifying information, including patients' names, initials or hospital numbers, should not be provided in the manuscript or visual material unless the information is essential for scientific purposes and the patient (or parent or guardian) has given written informed consent for publication. Informed consent for this purpose requires that an identifiable patient be shown the manuscript to be published. Authors should disclose to these patients whether any potential identifiable material might be available via the Internet as well as in print after publication. Nonessential identifying details should be omitted. Informed consent should be obtained if there is any doubt that anonymity can be maintained. For example, masking the eye region in photographs of patients is inadequate protection of anonymity. If identifying characteristics are altered to protect anonymity, authors should provide assurance that alterations do not distort scientific meaning. **When informed consent has been obtained, it should be indicated in the manuscript.**

## Human and animal rights

When reporting experiments on human subjects, authors should indicate whether the procedures followed were in accordance with the ethical standards of the responsible committee on human experimentation (institutional and national) and with the Declaration of Helsinki of 1975, as revised in 2013 ([www.wma.net/en/30publications/10policies/b3/index.html](http://www.wma.net/en/30publications/10policies/b3/index.html)). If doubt exists whether the research was conducted in accordance with the Declaration of Helsinki, the authors must explain the rationale for their approach, and demonstrate that the institutional review body explicitly approved the doubtful aspects of the study. When reporting experiments on animals, authors should indicate whether institutional and national standards for the care and use of laboratory animals were followed. Further guidance on animal research ethics is available from the International Association of Veterinary Editors' Consensus Author Guidelines on Animal Ethics and Welfare ([www.veteditors.org/consensus-author-guidelines-on-animal-ethics-and-welfare-for-editors](http://www.veteditors.org/consensus-author-guidelines-on-animal-ethics-and-welfare-for-editors)).

## Preparing the manuscript text

### General

The manuscript must be written in U.S. English. The main body of the text, excluding the title page, abstract and list of captions, but including the references, may be a maximum of 4,000 words. Exceptions may be allowed with prior approval from the publisher.

Authors will have the opportunity to add more information regarding their article, as well as post videos, present a webinar and blog on the DT Science website.

It is preferred that there be no more than six authors. If more authors have participated in the study, the contribution of each author must be disclosed at the end of the document.

### Title

The title should not exceed 35 characters. Capitalize only the first word and proper nouns in the title. Please include a running title as well.

### Author information

The following information must be included for each author:

- Full author name(s)
- Full affiliation (department, faculty, institution, town, country).

For the corresponding author, the following information should be included in addition:

- Full mailing address
- Email address.

### Abstract and keywords

The manuscript must contain an abstract and a minimum of 3, maximum of 6 keywords. The abstract should be self-contained, not cite any other work and not exceed 250 words. It should be structured into the following separate sections: objective, materials and methods, results, conclusion and keywords. For case reports, the sections should be background, case presentation, conclusion and keywords.

### Structure of the main text

The body of the manuscript must be structured as follows:

- Introduction (no subheadings)
- Materials and methods
- Results
- Discussion
- Conclusion

### Competing interests

Authors are required to declare any competing financial or other interests regarding the article submitted. Such competing interests are to be stated at the end of manuscript before the references. If no competing interests are declared, the following will be stated: "The authors declare that they have no competing interests."

### Acknowledgments

Acknowledgments (if any) should be brief and included at the end of the manuscript before the references, and may include supporting grants.

### References

Authors are responsible for ensuring that the information for each reference is complete and accurate. All references must be cited within the manuscript. References appearing in the list but not in the manuscript will be removed. In-text citation should follow the citation–sequence format (e.g., “as discussed by Haywood et al.<sup>15</sup>”) using superscript numbers placed after the punctuation in the relevant sentence. The references must be numbered consecutively.

The reference list must be numbered and the references provided in order of appearance. For the reference list, the journal follows the citation style stipulated in *Citing medicine: the NLM style guide for authors, editors, and publishers*. The guidelines may be viewed and downloaded free of charge at

[www.ncbi.nlm.nih.gov/books/NBK7256/](http://www.ncbi.nlm.nih.gov/books/NBK7256/)

**The reference list may not exceed 50 references.**

### List of captions

Please provide the captions for all visual material at the end of the manuscript.

### Abbreviations

Abbreviations should be used sparingly and defined when first used. The abstract and the main manuscript text should be regarded as separate documents in this regard.

### Typography

- Use Times New Roman regular with a font size of 12 pt.
- Use double line spacing with blank lines separating sections and paragraphs.
- Type the text unjustified and do not apply hyphenation at line breaks.
- Number all of the pages.
- Use endnotes if necessary, but not footnotes.
- Greek and other special characters may be included.

## **Preparing the visual material**

### Requirements for images

Each image should be supplied separately and the following formats are accepted: PSD, TIFF, GIF and JPEG. The image must have a resolution of 300 dpi and must be no smaller than 6 cm × 6 cm.

Please number the images consecutively throughout the article by using a new number for each image. If it is imperative that certain images be grouped to-

gether, then use lowercase letters to designate these in a group (e.g., “Figs. 2a–c”).

Place the references to the images in your article wherever they are appropriate, whether in the middle or at the end of a sentence. Provide a caption for each image at the end of your article.

### Requirements for tables

Each table should be supplied separately and in Microsoft Word format. Tables may not be embedded as images and no shading or color is to be used.

Tables should be cited consecutively in the manuscript. Place the references to the tables in your article wherever they are appropriate, whether in the middle or at the end of a sentence. Every table must have a descriptive caption, and if numerical measurements are given the units should be included in the column headings.

### Supplements/supporting material

DT Science allows an unlimited amount of supporting material (such as datasets, videos or other additional information) to be uploaded. This material should be presented succinctly (in English). The author bears full responsibility for the content. Color, animated multimedia presentations, videos and so on are welcome and published at no additional cost to the author or reader. Please refer briefly to such material in the manuscript where appropriate (e.g., as an endnote).

### **Submit your research and clinical articles to**

Dr. Daniele Botticelli at  
[daniele.botticelli@gmail.com](mailto:daniele.botticelli@gmail.com)

### **For all other requests, contact**

Nathalie Schüller at  
[n.schueller@dental-tribune.com](mailto:n.schueller@dental-tribune.com)  
T +49 341 4847 4136

Dental Tribune International Publishing Group  
Holbeinstr. 29  
04229 Leipzig  
Germany

[www.dtscience.com](http://www.dtscience.com)  
[www.dental-tribune.com](http://www.dental-tribune.com)



## International office

Dental Tribune International  
Holbeinstr. 29  
04229 Leipzig  
Germany

T +49 341 4847 4302  
F +49 341 4847 4173

info@dental-tribune.com  
www.dental-tribune.com



## Publishing team

### Publisher/President/CEO

Torsten R. Oemus  
t.oemus@dental-tribune.com

### Managing Editor

Nathalie Schüller  
n.schueller@dental-tribune.com

### Concept & design

Rhowerk  
www.rhowerk.de

### Chief Technology Officer

Serban Veres  
serbanveres@gmail.com

### Copy editor

Sabrina Raaff  
Ann-Katrin Paulick

## International administration

### Chief Financial Officer

Dan Wunderlich  
d.wunderlich@dental-tribune.com

### Business Development Manager

Claudia Salwiczek-Majonek  
c.salwiczek@dental-tribune.com

### Marketing Services

Nadine Dehmel  
n.dehmel@dental-tribune.com

### Sales Services

Nicole Andrae  
n.andrae@dental-tribune.com

### Accounting Services

Karen Hamatschek  
k.hamatschek@dental-tribune.com

Manuela Hunger  
m.hunger@dental-tribune.com

Anja Maywald  
a.maywald@dental-tribune.com

### Executive Producer

Gernot Meyer  
g.meyer@dental-tribune.com

## Editorial board

### Editor-in-Chief

Ugo Covani, Pisa and Camaiore, Italy

### Co-editors

Daniele Botticelli, Rimini, Italy  
José Luis Calvo Guirado, Murcia, Spain  
Miguel Peñarrocha Diago, Valencia, Spain

### Associate editors

Antonio Barone, Geneva, Switzerland  
Luigi Canullo, Rome, Italy  
Rafael Arcesio Delgado Ruiz, Stony Brook, N.Y., U.S.  
David Peñarrocha Oltra, Valencia, Spain

### Scientific advisers

Pablo Galindo Moreno, Granada, Spain  
Georgios Romanos, Stony Brook, N.Y., U.S.  
Giovanni Serino, Borås, Sweden

### Statistical advisers

Marco Tallarico, Sassari, Italy  
Francesco Tassarolo, Mattarello, Italy

### Executive board

Daniele Botticelli, Rimini, Italy  
Luigi Canullo, Rome, Italy  
Torsten R. Oemus, Leipzig, Germany

### Board of reviewers

Marcus Abboud, Stony Brook, N.Y., U.S.  
Marco Álvarez, Mexico City, Mexico  
Conrado Aparicio, Minneapolis, Minn., U.S.  
Shunsuke Baba, Osaka, Japan  
Franco Bengazi, Brescia, Italy  
Andrea Edoardo Bianchi, Milan, Italy  
Manuel Bravo Pérez, Granada, Spain  
Eriberto Bressan, Padua, Italy  
Marco Caneva, Trieste, Italy  
Juan Carlos De Vicente Rodríguez, Oviedo, Spain  
Stefan Fickl, Würzburg, Germany  
Joseph Fiorellini, Philadelphia, Pa., U.S.  
Carlo Fornaini, Fiorenzuola d'Arda, Italy  
Abel García García, Santiago de Compostela, Spain  
Gerardo Gómez Moreno, Granada, Spain  
Federico Hernández Alfaro, Barcelona, Spain  
Carlos Larrucea Verdugo, Talca, Chile  
Baek-Soo Lee, Seoul, South Korea  
Dehua Li, Xi'an, China  
Francesco Guido Mangano, Milan, Italy  
Aleksa Markovic, Belgrade, Serbia  
José Eduardo Maté Sánchez de Val, Murcia, Spain  
Silvio Meloni, Sassari, Italy  
Eitan Mijiritsky, Tel Aviv, Israel  
Alberto Monje, Ann Arbor, Mich., U.S.  
Yasushi Nakajima, Osaka, Japan  
Ulf Nannmark, Gothenburg, Sweden  
Wilson Roberto Poi, Araçatuba, Brazil  
Rosario Prisco, Foggia, Italy  
Alessandro Quaranta, Dunedin, New Zealand  
Maria Piedad Ramírez Fernández, Murcia, Spain  
Idelmo Rangel García, Araçatuba, Brazil  
Fabio Rossi, Bologna, Italy  
Hector Sarmiento, Philadelphia, Pa., U.S.  
Nikola Saulacic, Bern, Switzerland  
Alessandro Scala, Pesaro, Italy  
Carlos Alberto Serrano Méndez, Bogotá, Colombia  
Andrew Tawse-Smith, Dunedin, New Zealand  
Cemal Ucer, Manchester, U.K.  
Joaquín Urbizo Velez, La Habana, Cuba

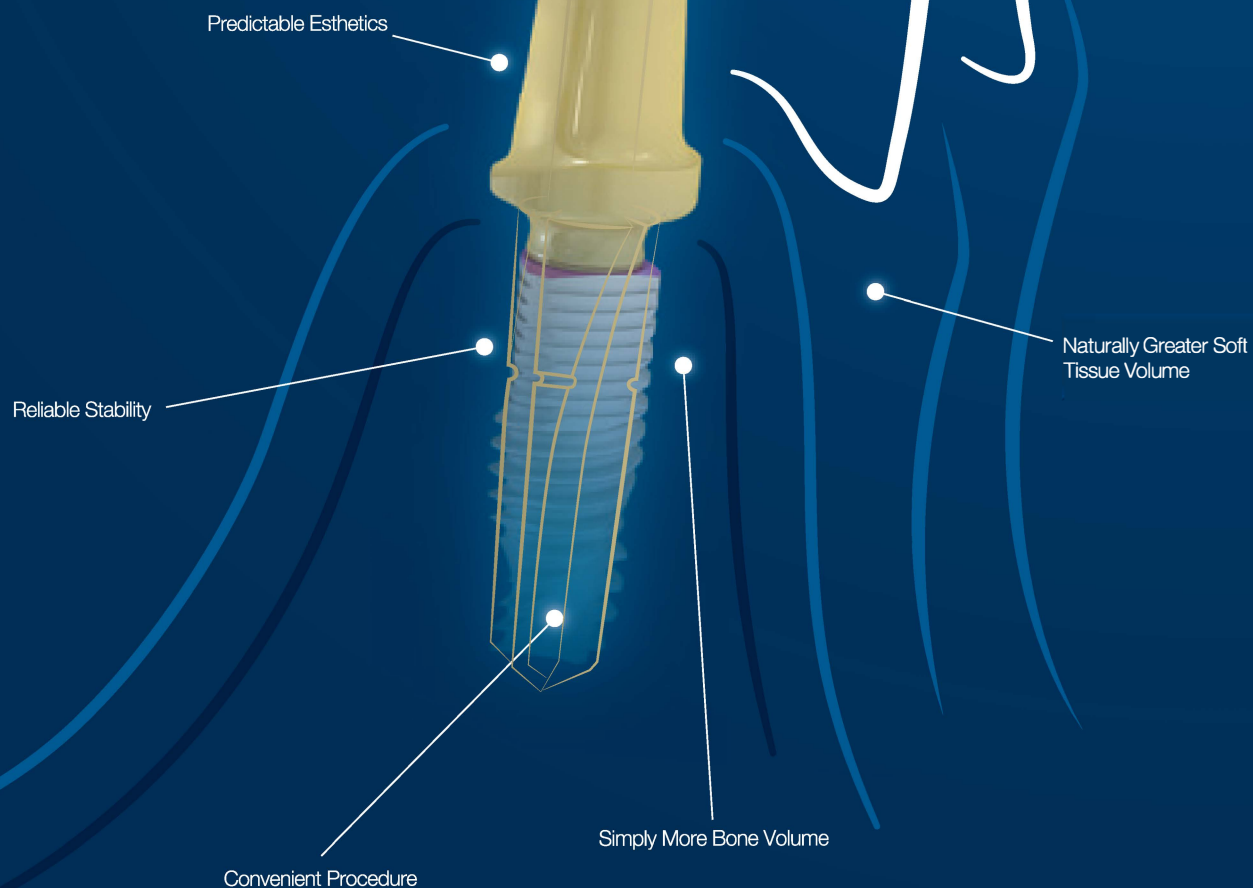
## Copyright regulations

The *Journal of Oral Science & Rehabilitation* is published quarterly by Dental Tribune International (DTI). The journal and all articles and illustrations contained therein are protected by copyright. Any utilization without the prior consent of the authors, editor and publisher is prohibited and liable to prosecution. This applies in particular to the duplication of copies, translations, microfilms, and storage and processing in electronic systems. Reproductions, including extracts, may only be made with the permission of the publisher. Given no statement to the contrary, any submissions to the editorial department are understood to be in agreement with full or partial publishing of said submission. The editorial department reserves the right to check all submitted articles for formal errors and factual authority, and to make amendments if necessary. Articles bearing symbols other than that of the editorial department, or that are distinguished by the name of the author, represent the opinion of the afore-mentioned, and do not have to comply with the views of DTI. Responsibility for such articles shall be borne by the author. Responsibility for advertisements and other specially labeled items shall not be borne by the editorial department. Likewise, no responsibility shall be assumed for information published about associations, companies and commercial markets. All cases of consequential liability arising from inaccurate or faulty representation are excluded. The legal domicile is Leipzig, Germany.

## Printer

Löhnert Druck | Handelsstr. 12 | 04420 Markranstädt | Germany

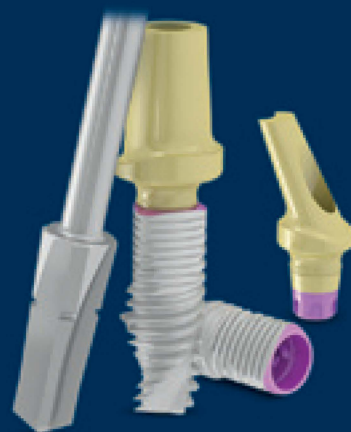



## MAKE IT SIMPLE. WE KNOW HOW!

The revolutionary design of the V3 implant makes implant placement simple, by leaving more room for bone and soft tissue, ensuring immediate biological benefits and improved performance. Learn more about the V3 implant and MIS at: [www.mis-implants.com](http://www.mis-implants.com)

V3<sup>By</sup> MIS







# Setting the scientific standard. Again.

The evidence points to TiUnite®

The largest meta-analysis of a single implant brand unequivocally shows that the TiUnite implant surface supports peri-implant health, bone maintenance and overall treatment success, long term.<sup>1</sup>

TiUnite is proven to perform – is your implant surface?

## Largest meta-analysis of a single implant brand



**106**

prospective  
studies



**4,694**

patients



**12,803**

TiUnite  
implants



## Highest-level evidence confirms clinical success

**95.1%**

10-year survival rate  
at implant level<sup>1</sup>

**1.36%**

Prevalence of  
peri-implantitis<sup>1,2</sup>

**-0.9 mm**

5-year bone level change  
at implant level<sup>1</sup>

<sup>1</sup> Karl, M. and Albrektsson, T. Clinical performance of dental implants with a moderately rough (TiUnite) surface: a meta-analysis of prospective clinical studies. Int J Oral Maxillofac Implants. 2017;32(4):717-734.

<sup>2</sup> Of 106 studies, 47 reported biological complications. Of these 47 papers, 19 reported cases of peri-implantitis in 5.2% of patients (64/1229). The authors postulated that, if peri-implantitis did not occur in studies where it was not explicitly reported, its prevalence would be 1.36%.

Details of regression analysis can be found in the full publication.

Visit [nobelbiocare.com/tiunite](http://nobelbiocare.com/tiunite)

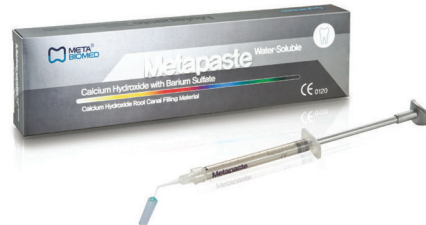



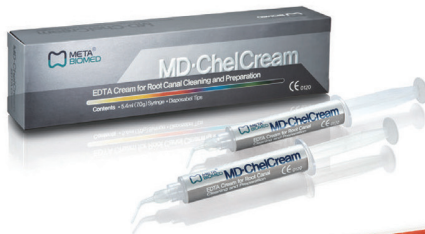• سیلر بیس رزینی  
ADSEAL



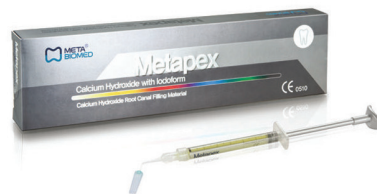• هیدروکسید کلسیم + سولفات باریوم  
Metapaste



• ژل آرسی پرپ ۱۹٪  
MD.ChelCream

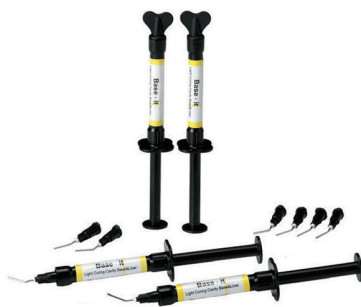

• هیدروکسید کلسیم + ید  
Metapex

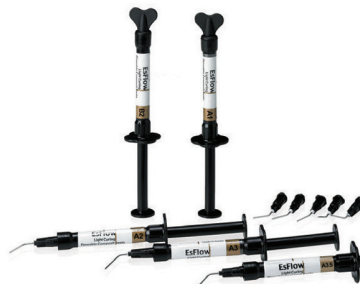

• گوتا پرکا  
Gutta Percha Point

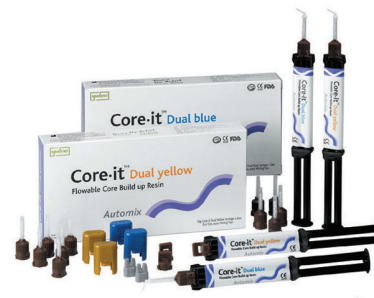- ISO sizes : 10, 15, 20, 25, 30, 35, 40, 45, 50, 55, 60, 70, 80, 90, 100, 110, 120, 130, 140
- Non-Standardized (Accessory sizes): XF, FF, MF, F, FM, M, ML, L, XL
- Special Taper Points : .04, .06, .08
- protaper : F1, F2, F3



Base.It  
(بیس و لاینر) دایکال نوری



EsFlow  
کامپوزیت نانو فلو لایت کیور



Core.it  
کریبلد آپ دوال کیور