



Article

Bone Replacement Materials and Techniques Used for Achieving Vertical Alveolar Bone Augmentation

Zeeshan Sheikh ^{1,*}, Corneliu Sima ² and Michael Glogauer ¹

¹ Matrix Dynamics Group, Faculty of Dentistry, University of Toronto, Room 221, Fitzgerald Building, 150 College Street, Toronto, ON M5S 3E2, Canada; E-Mail: michael.glogauer@utoronto.ca

² Department of Applied Oral Sciences, The Forsyth Institute, 245 First Street, Cambridge, MA 02142, USA; E-Mail: csima@forsyth.org

* Author to whom correspondence should be addressed; E-Mail: zeeshan.sheikh@utoronto.ca; Tel.: +1-514-224-7490.

Academic Editor: Franz E. Weber

Received: 31 March 2015 / Accepted: 19 May 2015 / Published: 27 May 2015

Abstract: Alveolar bone augmentation in vertical dimension remains the holy grail of periodontal tissue engineering. Successful dental implant placement for restoration of edentulous sites depends on the quality and quantity of alveolar bone available in all spatial dimensions. There are several surgical techniques used alone or in combination with natural or synthetic graft materials to achieve vertical alveolar bone augmentation. While continuously improving surgical techniques combined with the use of auto- or allografts provide the most predictable clinical outcomes, their success often depends on the status of recipient tissues. The morbidity associated with donor sites for auto-grafts makes these techniques less appealing to both patients and clinicians. New developments in material sciences offer a range of synthetic replacements for natural grafts to address the shortcoming of a second surgical site and relatively high resorption rates. This narrative review focuses on existing techniques, natural tissues and synthetic biomaterials commonly used to achieve vertical bone height gain in order to successfully restore edentulous ridges with implant-supported prostheses.

Keywords: vertical bone augmentation; alveolar ridge augmentation; biomaterials; bone graft materials; bone replacement; osteoconduction; osteoinduction; creeping substitution



1. Introduction

Advances in biomaterials research and development of new and improved surgical techniques and armamentarium have resulted in an ever increasing use of dental implants for tooth replacement. The long-term success of dental implants is highly dependent upon the degree of osseointegration in sufficient and healthy bone [1–6]. Bone volume is often reduced due to extended time after tooth loss before implant placement, or due to periodontitis or trauma [1,7,8]. After tooth extraction an average alveolar bone loss of 1.5–2 mm (vertical) and 40%–50% (horizontal) occurs within 6 months [9,10]. Most of alveolar dimensional changes occur during the first 3 months [11]. If no treatment to restore the dentition is provided, then continued bone loss occurs and up to 40%–60% of ridge volume is lost in first 3 years [12–14]. The loss of vertical bone height leads to great challenges to dental implant placement due to surgical difficulties and anatomical limitations [1] (Figure 1). This lack of sufficient bone volume and height if unresolved eventually proves to be detrimental to the final treatment outcome with respect to implant success and survival [1,15].

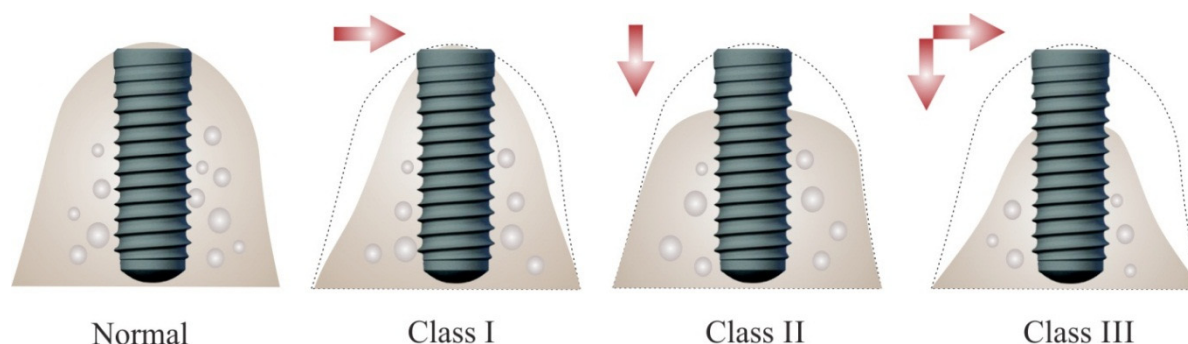


Figure 1. Bone volume insufficiency for implant placement. In Siebert class I ridge defects there is horizontal bone loss with adequate height, which leads to insufficient bone volume for successful placement of regular diameter implants. In class II there is vertical bone loss with adequate width, which leads to insufficient bone volume for proper positioning of regular length implants in correct prosthetic corono-apical position. In class III there is vertical and horizontal bone loss that prevents placement of successful implants in all spatial dimensions.

Various surgical techniques and biomaterials have been developed to make possible the successful placement of dental implants in resorbed alveolar bone [16–20]. Multiple bone grafting techniques, natural and synthetic graft materials have been tested for this purpose [21–25]. Although animal experiments have reported promising results, vertical bone augmentation procedures experience a high rate of failure in clinical practice [21–23,25]. The main reasons for failure are poor bone augmentation as a result of soft tissue encroachment and graft shrinkage due to poor blood supply. Granulation tissue formation and lack of adequate bone callus formation are generally caused by graft instability, exposure of graft material to the oral environment and infection [23,24]. Insufficient or delayed vascularization of the graft often leads to a mismatch between blood flow and bone resorption/formation coupling, which can result in unpredictable bone augmentation. In this review article we discuss the various techniques and materials currently available to achieve vertical alveolar bone augmentation.



2. Principles of Bone Regeneration

2.1. Basic Multicellular Units

The central anatomic structures involved in bone regeneration are the basic multicellular units formed by temporary assembly of osteoblasts (bone forming cells) and osteoclasts (bone resorbing cells). While the two cell types function as a unit in rebuilding the bone structure, they develop from two separate embryonic lineages: osteoblasts derive from mesenchymal stem cells (bone marrow stromal stem cells) while osteoclasts derive from hematopoietic progenitors (monocyte lineage). Two transcriptional factors expressed by osteoblasts, Runt-related transcription factor-2 (Runx2) and Osterix/SP7, are necessary for commitment of mesenchymal progenitor cells to osteoblast lineage [26,27]. The novel zinc finger-containing transcription factor osterix is required for osteoblast differentiation and bone formation [27]. Key factors involved in osteoblast differentiation include vitamin D3, estrogen, parathyroid hormone, fibroblast growth factors (FGFs) and transforming growth factor beta family (TGF- β) [28–30]. Osteoclast differentiation depends on activation of colony-stimulating factor-1 receptor/macrophage–colony-stimulating factor/CD115 (MCSF, a colony-stimulating factor receptor) and receptor activator of nuclear factor kappa-B (RANK) receptors [31]. Osteoblasts produce RANK ligand (RANKL) and its high-affinity decoy receptor, osteoprotegerin, to regulate osteoclast differentiation and activation. Therefore, osteoblasts are required for osteoclast differentiation primarily through regulating the balance between RANKL and osteoprotegerin [32].

2.2. Space Maintenance

In the oral cavity two specific local aspects impose difficulties in creation and maintenance of space where bone regeneration is intended. One is the pattern of bone loss that often generates non self-containing bone defects covered by soft tissues, muscles and/or prostheses that would collapse onto a grafting site if not supported. The second is the relatively high turnover rate of soft tissues during oral mucosal healing, which would take over the space for bone regeneration if barriers were not used [33]. Therefore, in large defects barrier membranes are used in combination with graft materials to allow for migration of osteoblasts and ingrowth of blood vessels from adjacent osteogenic tissues. To increase mechanical support and stability of membranes, tenting screws, titanium-reinforced membranes or titanium meshes are used in conjunction with graft materials. The relatively slow rate of graft resorption also contributes to space maintenance.

2.3. Osteogenesis

A requirement for bone regeneration is the presence or recruitment of osteoblast precursors and growth factors at sites of augmentation. Osteoblast precursors can be provided by the graft material (cancellous autogenous grafts) or by the recipient bed. Growth factors come from the graft, recipient bed and vasculature. It is believed that intramarrow penetration of recipient beds favors both cellular and growth factor migration into the sites where bone is regenerated, which is associated with up to 30% greater bone regeneration and higher bone density at grafted sites [34,35]. Osteoprogenitor cells from the host infiltrate the host within 7 days. Surface osteocytes from cancellous autografts survive and are



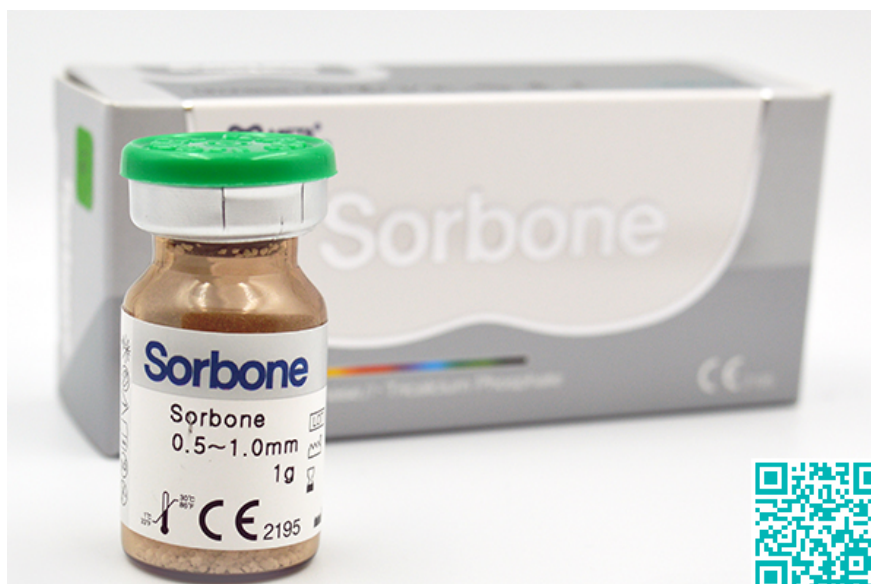nourished by diffusion [36]. Similarly, oral and iliac cancellous autogenous grafts were shown to be osteogenic in vertical periodontal defects [37,38].

2.4. Osteoconduction

The early phase of bone regeneration at grafted sites is dominated by active bone resorption and formation throughout the graft. The latter phase of incorporation is characterized by osteoconduction and a process known as creeping substitution [39]. Osteoconduction is a function of a bone graft that provides a tridimensional scaffold for ingrowth of host capillaries and osteoprogenitor cells [40]. Many of the bone graft materials used today are able to contribute to new bone formation through this biological process [41]. Material structure and design are critical for osteoconduction. Materials that best mimic bone chemistry are optimal for cellular osteogenic differentiation. Further, macroporosity and patterns of pore interconnection have a significant impact on potential for osteoinduction. High porosity levels are required for blood vessel ingrowth and bone matrix deposition. Pore shape and interconnection size may be limiting factors for vascular flow [42]. Therefore, material composition and design need to allow for finely tuned graft resorption and conduction for new bone formation.

2.5. Osteoinduction

The osteoblast precursors differentiate into mature osteoblasts under the influence of osteoinductors and synthesize new bone during the first weeks. Growth factors involved in bone formation act on fibroblast and osteoblast proliferation, extracellular matrix deposition, mesenchymal cell differentiation and vascular proliferation (Figure 2). The complexity of bone induction regulation is reflected by the growth factor specificity of action during early phases of bone regeneration [43]. Platelet derived growth factor (PDGF) and fibroblast growth factor (FGF) act on early stages of induction by stimulating fibroblast and osteoblast proliferation. Similarly, insulin-like growth factor (IGF) acts on cell proliferation but also on extracellular matrix deposition. By contrast, bone morphogenetic proteins (BMPs) act primarily on later stages of osteoinduction such as mesenchymal cell differentiation and vascular proliferation. Transforming growth factor beta (TGF- β) acts on cellular proliferation, matrix deposition and vascularization but not on mesenchymal cell differentiation.



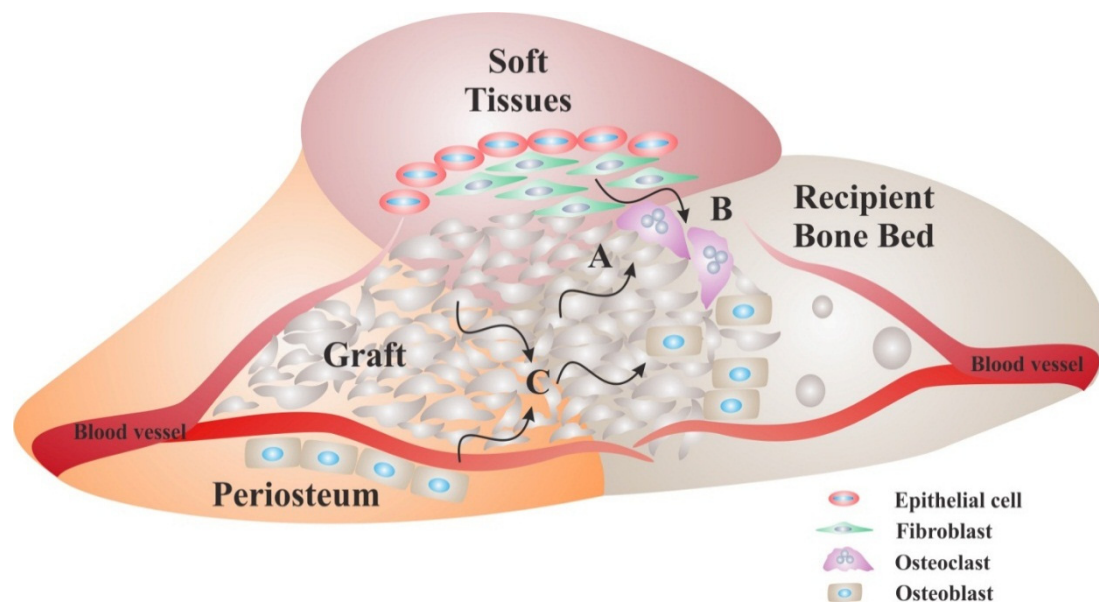


Figure 2. Biological requirements for bone regeneration. Surgical procedures for ridge augmentation are designed based on biological principles of bone regeneration. First, space-maintenance where new bone formation is needed is achieved by use of grafts and/or membranes. In order for bone formation to occur, grafts need to be osteoconductive acting as a scaffold onto which bone resorption and deposition occurs. Most graft materials allow for their resorption by osteoclasts prior to bone deposition by osteoblasts (A). Since the turnover rate of soft tissues is higher than that of bone, grafts are used alone when their surfaces have low resorption rates, or in combination with membranes that separate the graft from soft tissues, when their surfaces have high resorption rates; This approach ensures that soft tissues are prevented from occupying the space where bone formation is intended (B); Bone deposition by osteoblasts is facilitated by adequate blood flow through the graft and osteoinductive properties of the graft that provide the growth factors necessary for osteoblast differentiation and function (C). Some grafts (autologous) act as osteogenic materials when they contain sufficient amount of osteoblasts precursors and growth factors.

3. Techniques for Vertical Bone Augmentation

Ewers *et al.* proposed a new classification of bone augmentation techniques based on vascularization or induction of vascularization in the graft: class I, microanastomosed free bone flaps; class II, distraction osteogenesis; class III, pedicled segmental osteotomies; class IV, bone morphogenetic induction grafts; class V, nonvascularized bone grafts. The latter was subdivided into class Va–onlay bone grafts and class Vb–guided bone regeneration [44]. There are 4 major recognized techniques for achieving vertical bone augmentation (Figure 3).

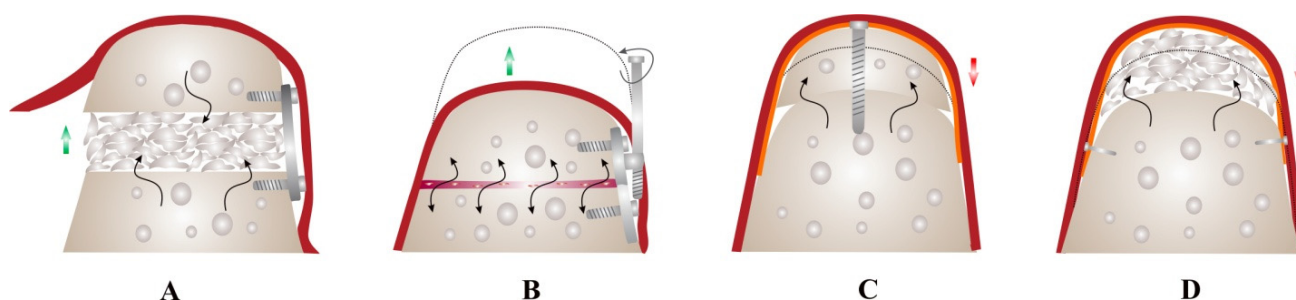


Figure 3. Vertical bone augmentation techniques. Ridge augmentation for implant site development can be achieved through several techniques based on basic principles of bone regeneration, availability of tissue at recipient site and desired clinical outcomes. Osteoperiosteal flaps (OPF) (microanastomosed free bone grafts or interpositional bone grafts) (A) and distraction osteogenesis (DO) (B) can achieve high bone volume gain (green arrows) but require adequate local tissues at recipient site and are highly technique-sensitive. DO offers the advantage of increasing both soft and hard tissues simultaneously, without the need for grafting; Block grafting (C) and guided bone regeneration (D) can be used to correct ridge defects of varying degrees but are associated with high resorption rate (red arrows) compared to OPF and DO. This is due to the limited vascularization of the graft and reduced osteogenic surface in the recipient bed (black arrows) compared to OPF. Red, soft tissues; Orange, resorbable or non-resorbable membrane.

3.1. Osteoperiosteal Flap Techniques

The osteoperiosteal flap (OPF) is achieved through a vascularized segmental osteotomy performed on alveolar bone. The biologic principles of osteoperiosteal flap techniques are based on vascularization studies and experience with Le Fort I techniques in craniomaxillofacial surgery. Alveolar bone receives blood supply from both bone marrow and periosteum, the latter becoming more significant with age when atrophy of the ridge is associated with decreased bone marrow blood flow. This technique depends on maintenance of vascularization in bone fragments from periosteum. Osteoperiosteal flaps through segmental osteotomies are used in combination with interpositional grafts in the gap generated by transposition of the flap in the desired position to achieve vertical ridge gain.

The micro-anastomosed free bone flaps such as fibular grafts are used in craniomaxillofacial surgery to correct severe bone deficiencies. These grafts offer bone gain of the highest quality (native bone) combined with greatest bone volumetric stability due to continuous blood flow achieved through venular and arterial microsurgical anastomosis [45,46]. However, free bone grafts are extremely technique-sensitive and are associated with significant morbidity at the donor site compared to other techniques used for implant site development. Therefore free bone flaps are reserved for reconstruction of severe mandibular deficiencies due to trauma, cancer or dysplasia. Numerous studies reported successful and stable results with fibular free grafts used for implant site development [47,48].

OPF combined with interpositional (inlay) grafts are increasingly being used more for implant site development in ridges with height deficiencies. The main advantage of osteotomy-based techniques is the preservation of the attached gingiva and even the papillae in some cases [49,50]. Sandwich techniques are similar to distraction osteogenesis in terms of surgical approach and having



similar healing patterns and end results [51,52]. As a replacement to callus distraction, a gap is formed by the placement of the bone fragment in final position and stabilized and fixed with either osteosynthesis screws or the dental implant itself [49,53].

3.2. Distraction Osteogenesis

Distraction osteogenesis (DO) is a technique used in craniomaxillofacial surgery to achieve high bone volume gain in all spatial dimensions. DO is based on the biological principle of bone callus mechanical elongation through slow and progressive separation under tension of two bone fragments surrounding the callus to achieve new bone formation [54–65]. The DO technique includes three phases: (i) the latency phase of 7 days, when soft tissues heal around the surgical site where the distractor is placed; (ii) the distraction phase, when the two bone fragments are separated incrementally at a rate of 0.5–1 mm/day; and (iii) the consolidation phase, when the newly formed bone mineralizes and matures [65–69].

The potential of DO to achieve significant vertical bone augmentation has been extensively reported in the literature [70–72]. Devices utilized for DO can be of intraosseous or extraosseous configuration [73–76]. Intraosseous distractors have been tested in dogs and demonstrated gains in vertical height of bone up to 9 mm [56,72]. An intraosseous approach with a small-diameter device has been tried and achieved vertical bone augmentation of 9 mm [74,77]. One intraosseous type of DO device used for alveolar bone distraction is the distraction implant. This device allows for simultaneous placement of the future dental implant (the apical distraction cylinder), thus reducing the numbers of surgical procedures needed for tooth replacement. A partially biodegradable distraction implant is currently being tested in dogs [78]. However, adequate bone width and proper distraction vector control are required for success with use of such devices.

Extraosseous distraction systems anchored to the cortical plate are more commonly used than intraosseous devices [62,79,80]. 4 to 6 mm of vertical height gain has been reported with prosthetic restorable distractors [81]. DO can achieve significantly greater and stable bone height gain compared to other vertical augmentation techniques and implant therapy in distracted bone shows favorable long term results [54]. However, there is evidence of higher rate of complication associated with DO [82–86]. One of the major problems encountered with DO is vector control, particularly against muscle pull. This often leads to lingual inclination of the transport segment in the mandible. Vector control is one of the most critical aspects of DO. Other potential complications include inability to mobilize the transport fragment, interference of the distractor with occlusion, distraction prevented by premature consolidation, loss of the distractor, infection, perforation of the mucosa by the transport segment, dehiscence of incision, fracture of the mandible and resorption of the transport fragment [87]. DO may allow for greater vertical regeneration from native bone, but it is of little use in routine clinical practice due to sensitivity of the technique and strict anatomical requirements for predictable results [19].

3.3. Block Graft Techniques

To increase the vertical height of mandibular and maxillary edentulous ridges, onlay grating using bone blocks was first introduced in early 1990s [88]. The classic block augmentation technique involves



the use of an autologous bone block fixed to the recipient ridge with osteosynthesis screws or dental implants [21,89–93]. After performing recipient site corticotomy to encourage blood clot formation and bone marrow osteoblast precursor migration into the graft, the latter is laid over the defective recipient bed devoid of soft tissues, and immobilized. The most common donor sites for block grafts are the mandibular ramus or mental region (intraoral) and the iliac crest (extraoral) [94–98]. Several autologous bone grafting techniques have been used for the treatment of severely resorbed edentulous mandible and maxilla [99–101]. In particular, the use of barrier membranes for block grafts seems to significantly improve the clinical outcome [102–107].

Extraoral autogenous bone harvested from the iliac crest was used to gain ridge height with varying degrees of success, the main disadvantage being the high resorption rate before implant placement and after loading [94]. This may be due to low cortical to trabecular ratio in the graft, memory of endochondral vs. intramembranous ossification and different osteoblast mechano-sensing memory between donor and recipient sites. Less common extraoral donor sites for block grafts used in ridge augmentation include the tibia and cranial vault [108,109]. The use of such autologous grafts is not common in practice mainly due the aforementioned disadvantages and the high morbidity associated with the donor site.

Intraoral block grafts are commonly harvested from the mandibular ramus or the symphysis, the latter offering the greatest bone volume [23,110]. However, ramus grafts are associated with significantly lower morbidity compared to symphysis grafts that may be associated with significant post-operative pain, altered sensation of mandibular anterior teeth, neurosensory disturbances in the chin region, temporary mental nerve paresthesia and mandibular fracture [111,112]. Therefore, the symphysis is often reserved for cases that require thicker block grafts that cannot be obtained from other intraoral donor sites.

Although onlay bone grafting procedures have reasonably acceptable results with an improvement from the initially reported 50% failure [101], complications are often observed at the donor site [113–118]. Further, implant survival rates continue to remain a concern for full-arch onlay grafting procedures [113,114]. The close contact and stabilization of autologous block grafts to the recipient bed is considered crucial towards achieving successful clinical results [119,120]. This can be assured by simultaneous implant placement [88,101,121,122], or the use of fixation screws [104,123]. A study on 115 autologous block grafts reported only one failure when all these conditions were met [109]. Revascularization and rate of remodeling can also be enhanced through decortication of the recipient bed, and inlay shaping [34,109,120,121,124,125]. Ridge augmentation with allograft block material has also demonstrated success [126–128]. However, histologically the performance of these allogenic grafts remains inconclusive.

3.4. Guided Bone Regeneration

Guided bone regeneration (GBR) is a technique that works on the principle of separating particulate graft material from surrounding soft tissue to allow for bone regeneration, which occurs at a slower rate compared to soft tissues [129,130]. Resorbable (usually collagen based) or non-resorbable (usually expanded-polytetrafluoroethylene based) membranes are frequently used to stabilize the graft material, limit graft resorption and act as an occlusive barrier toward the surrounding soft tissue



regeneration and infiltration [130] (Figure 4). The desired clinical outcome and knowledge of the local anatomy, graft type used and biology of healing drive the choice of a specific membrane. The main problems associated with particulate graft techniques are the higher than anticipated graft resorption rate and the anatomical limitations for graft containment [131,132].

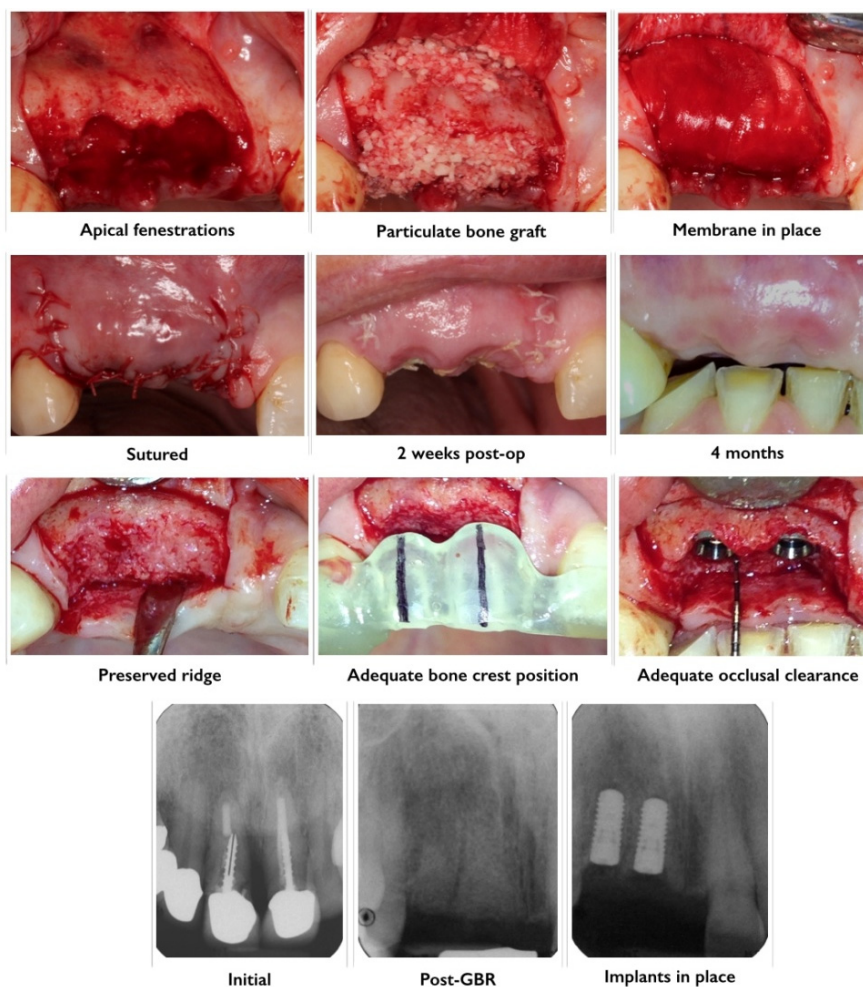


Figure 4. Alveolar bone preservation using a particulate allograft material. Exodontia of teeth 1.1 and 1.2 (failed endodontic treatments, post fracture, loss of clinical attachment) was performed and full thickness buccal and palatal flaps were raised. Post-extraction sockets were generously irrigated with saline and inspected for integrity of bony walls. Apical fenestrations of the buccal wall were detected at 1.1 and 1.2 sites. Irrigated particulate freeze dried bone allograft (FDBA) was gently packed into sockets and covered with a double-layered porcine collagen membrane. Post-guided bone regeneration (GBR) healing was uneventful. Four months post-GBR adequate height and width of bone was observed clinically and radiographically at 1.1 and 1.2 sites. There was adequate distance between alveolar crest and cement-enamel junction of adjacent teeth as well as occlusal clearance for the future crowns.

The principles of GBR were initially applied for implant site development in atrophic jaws [133]. The expansion of GBR to a large variety of bone defect types led to the widespread use of this technique in clinical practice [9,134,135]. In some cases, the use of barrier membranes is not warranted and the



graft material can be used alone to fill the defect [136]. This is commonly referred to as bone replacement graft. Acceptable predictability of bone gain with use of such grafts is limited to small self-containing defects. Bone resorption has been reported with the use of autografts without membranes [123,137]. Therefore, membranes are utilized in non-space making bone defects that require space maintenance and prevention of soft tissue ingrowth where bone regeneration is required [18,136,138]. In most cases, the use of membranes alone for GBR is associated with membrane compression into the defect space by overlying soft tissues [139–142]. In a study it was shown that significantly less resorption of block grafts was observed when they were used in combination with expanded-polytetrafluoroethylene (ePTFE) membranes [102]. Barrier membranes combined with particulate and/or block grafts materials have resulted in more predictable clinical outcomes [133,138,141].

Treatment of complex vertical defects requires a stable and stiff membrane, usually made of titanium or metal-reinforced polytetrafluoroethylene (PTFE) [18,131]. GBR therapy by means of titanium reinforced non-resorbable barrier membranes in conjunction with dental implants has been carried out with varying levels of clinical success [1,58,133,143–147]. Vertical GBR is a sensitive technique that limits clinical success, and failure often occurs due to wound dehiscence [1,58,144,147–149]. Another limitation of vertical GBR is the ability to regenerate bone along the long axis of the applied force [1,54–58,60–62,80,92,93,150,151]. Specific problems associated with titanium membranes used for GBR are fibrous ingrowth through wide holes present in their structure and exposure of the membrane [107,152].

3.5. Minimally Invasive Approaches to GBR

The concept of minimally invasive surgery was devised to achieve vertical bone regeneration and to prevent post-operative complications and graft exposure [153–164]. A subperiosteal tunneling technique was developed in late 1970s by Kent *et al.* [154]. This technique involved a small surgical incision made in the alveolar ridge to elevate the periosteum and inject a low viscosity paste of hydroxyapatite (HA) particles [154]. Although appealing, it was found that HA particles were unstable and diffused into adjacent tissues causing the formation of a fibrous capsule that prevented bone formation [160,161]. Newer graft materials with optimized viscosity and an improved surgical technique continued to offer potential for this method but results are controversial [153–155,157–161,165].

There is still insufficient comparable quantitative data to assess the clinical usefulness of this technique. However, some studies demonstrated that tunneling combined with screw or membrane mediated stabilization of the grafts can be a predictable vertical augmentation technique [153–156,158–163,165–167]. Calcium phosphate based biomaterials such as brushite cement pastes have been evaluated in various *in vivo* studies as injectable pastes with controlled viscosity and additives to achieve minimally invasive vertical bone augmentation [168–177].

4. Natural Transplants and Synthetic Bone Replacement Graft Tissues and Biomaterials

Materials used for bone augmentation are divided into natural transplants (autografts, allografts and xenografts) and synthetic materials (alloplasts) [7,8,178] (Table 1). These graft materials are used for clinical applications based on the hypothesis that they are osteogenic, osteoinductive, osteoconductive or possess a combination of these properties [17].



Table 1. Bone replacement graft tissues and materials.

Human bone sources		Non-human natural sources	Synthetic sources (Alloplasts)	
Autografts	Allografts	Xenografts	Bioactive glasses	Bioceramics
-Extra oral sites	-Fresh frozen bone	-Bovine Hydroxyapatite	–	-Hydroxyapatite
	-Freeze dried bone allograft (FDBA)	-Coralline calcium carbonate	–	-Other calcium phosphates (Tricalcium phosphate, brushite, monetite)
–	-Demineralized freeze dried bone allograft (FDBA)	–	–	

4.1. Autografts

Autografts are harvested and transferred from intraoral or extraoral site to bone deficient-sites within the same individual. Autografts are the most predictable osteogenic organic graft for osseous tissue regenerate [179–181]. Grafts harvested from the iliac crest provide optimal osteoconductive, osteoinductive and osteogenic properties [182]. However, due to the donor site morbidity, increased cost and graft volume limitations, the use of other graft materials became more common in clinical practice [182–186] (Table 2). It has also been noted that autografts may fail at recipient sites as the majority of cellular (osteogenic) elements do not survive the transplantation procedure [187].

Table 2. Advantages and disadvantages of using autografts for bone augmentation.

Advantages	Disadvantages
Biocompatible	Need for additional surgery to procure the tissue
Osteoinductive	Increase in operative time and cost
Osteoconductive	Donor site morbidity and postoperative pain
High osteogenic potential	Increased risk of fracture to donor site
Adequate mechanical strength	Limited amount of tissue can be procured
Available in both cortical and cancellous types	High variability in quality of harvested bone tissue

The most common sites for autograft harvesting are the mandible (chin, mandibular ramus, and mandibular corpus) [98,188], the maxilla (tuber, spina nasalis, and crista zygomatico-alveolaris), the calvaria, the iliac crest (pelvic rim) and the tibia [98]. There is less morbidity associated with intraoral donor sites when compared to extraoral sites [95]. The mandibular bone is the most common transplant in dental surgery [95] and the graft may be harvested as bone blocks or milled to generate particles [95,132]. A scraper can also be utilized to obtain bone chips [132]. The most common extraoral donor site to harvest large amounts of autologous cortical-cancellous bone is the pelvic rim [189].

Autografts can be of cancellous or cortical nature or a combination of both. Cancellous grafts have the ability to revascularize sooner than cortical grafts due to their spongy architecture. Revascularization of these grafts begins around the fifth day after transplantation [190]. The cortical grafts have a high initial strength that decreases over time. After several weeks to 6 months post implantation, cortical



autografts have been shown to be 40%–50% weaker than normal bone when strength is compared [190]. Conversely, cancellous autografts are softer initially because of their porous (open) architecture. Over a period of time they continue to gain strength and biomechanical stimulation is critical for achieving adequate dimensional stability and strength [17]. Vertical and horizontal bone augmentation with block or particulate autografts in combination with GBR shows that both techniques are clinically successful for implant placement [107,131,191,192]. The histological outcomes, including revascularization and bone remodeling, of the two techniques differ with block grafts outperforming particulate grafts in terms of bone-to-implant contact and bone fill values [191].

4.2. Allografts

Allografts are harvested from genetically non-identical members of same species. There has been a great interest in allograft use for implant site development since availability in large quantities and use off-the-shelf eliminate the drawbacks associated with a second surgical site. Although allografts undergo multiple treatments prior to use, risk of disease transmission is still a possibility. It has been estimated that the risk of human immunodeficiency virus (HIV) transmission is 1 in 1.6 million with use of allografts [193]. There have been some reports of cross-infection and incidences of disease transmission of bovine spongiform encephalopathy [194–196]. However, these very low risks are far outweighed by the advantages associated with allografts, which resulted in an increased use of allografts in routine practice [166,197–200]. Allograft particles of different sizes and origins (cortical, cancellous or both) are being used for various bone augmentation procedures such as ridge augmentation [147,166,200,201], sinus augmentation [122,124,202–204] and in ridge preservation after tooth extraction [201,205–210]. Allografts are mostly prepared as fresh, frozen, freeze-dried, mineralized and demineralized, and each of these are available as cortical chips, cortical granules, cortical wedges or cancellous powdered grafts [17,211].

4.2.1. Fresh or Frozen Iliac Cancellous Bone and Marrow Allografts

Fresh or frozen iliac cancellous bone and marrow tissues possess the highest osteoconductive and osteoinductive potential among all allografts available [212,213]. Clinical studies in patients having atrophic maxillary ridge were subjected to bone grafting with human block grafts of tibia fresh-frozen chips and histological analysis revealed a living bone that showed features characteristic of mature and compact osseous tissue surrounded by marrow spaces [214,215]. The risk of disease transmission, antigenicity and extensive cross-matching and treatment required has rendered the use of frozen iliac allografts obsolete in modern practice [17].

4.2.2. Mineralized Freeze-Dried Bone Allografts

Freeze-dried bone allografts (FDBA) have been extensively used for treatment of periodontal defects [216–225]. Compelling evidence suggests that the health risks associated with fresh frozen bone is minimal [226], and clinical success of grafting procedures is high [227]. It is assumed that the process of freeze-drying affects the immune recognition in the host by distorting the three dimensional presentation of the human leukocyte antigens on the surface of allograft particles [226,228].



FDDBA possess inferior osteoinductive and mechanical properties when compared to fresh or frozen allografts [17,227]. Cortical FDDBA did not elicit an immune response in non-human primates [219]. Advantages of cortical vs. cancellous FDDBA include higher volume of bone matrix that increases graft resorption time, higher inductive potential through growth factors stored in the matrix and less overall antigenicity. FDDBA are considered osteoconductive [40,229], space maintaining and can be used in combination with autografts to enhance the graft's osteogenic potential [230]. Ridge augmentation procedures using FDDBA blocks have demonstrated formation of vital and mineralized bone with lamellar organization at the grafted sites [231,232]. Ridge augmentation results suggest that FDDBA in conjunction with resorbable membranes may be an acceptable alternative to the autogenous block graft in the treatment of compromised alveolar ridge deficiencies [126].

4.2.3. Demineralized Freeze-Dried Bone Allografts

Demineralized freeze-dried bone allografts (DFDBA) are frequently used for maxillofacial and periodontal grafting procedures alone or in combination with FDDBA or autografts. Compared to other bone regeneration materials DFDBA has the advantage of rapid resorption and exposure of osteoinductive proteins following demineralization [198,233–235]. The osteoinductive potential of DFDBA is mainly attributed to morphogenetic proteins (BMPs) stored in the matrix [236,237]. Growth and differentiation factors have been shown to be present in DFDBA preparations [238–241]. The bioactivity of DFDBA seems to depend on donor age, with grafts harvested from the younger individuals having higher osteogenic potential in comparison with grafts from older individuals [242–244]. In maxillary sinus augmentation procedures, DFDBA showed 29% new bone formation while autogenous grafts showed 40% in comparison [245]. It has also been observed that DFDBA particles situated near pre-existing bone were enclosed by new bone, whereas particles located near the center of the graft show no signs of remineralization or new bone formation [245,246]. However, there are reports that show poor bone formation with commercially available DFDBA [240,247].

4.3. Xenografts

Xenografts are derived from species other than human. They are considered to be biocompatible with human recipients and have osteoconductive properties. Bone grafting using xenografts in aseptic bone cavities was first reported in 1889 [248]. Xenograft materials have shown potential for resorption and replacement by new bone at recipient sites over time [249–251]. Commercially available bovine bone is processed to yield natural bone mineral without the organic component. Anorganic bone of bovine origin comprises of a HA skeleton that retains the microporous and macroporous structure of cancellous and cortical bone [252] remaining after low-heat and chemical extraction of the organic component. In the past, bovine xenografts had failed due to graft rejection [253], which was probably due to chemical detergent extraction techniques that left residual proteins and hence produced adverse reactions [254]. Xenografts of bovine origin carry a theoretical risk of disease transmission. Although existing data indicates a negligible risk of bovine spongiform encephalopathy, concerns still exist [255,256]. An advantage of these graft materials is the higher osteoconductive potential compared with synthetically derived materials. Bovine-derived bone grafts (particulate and blocks) have successfully been used for the treatment of human intrabony defects and ridge augmentation [122,124,250,255,257–259]. The bone



blocks of xenogenic origin used in vertical bone augmentation studies are very brittle and lack toughness. They often break during the screw fixation process which results in a more sensitive surgical procedure and less than favorable healing process [115,117,248].

Coralline calcium carbonate is obtained from natural coral, genus *Porites*, and is composed primarily of aragonite (>98% calcium carbonate). It has a pore size of 100 to 200 μm which is similar to that present in cancellous bone [260]. The relative high porosity of ~45% provides a large surface area for graft resorption and replacement by new bone [261]. Calcium carbonate is resorbable *in vivo*, unlike HA that can also be derived from the same coral by heat conversion. Calcium carbonate does not require surface transformation to carbonate like other graft materials in order to induce bone formation; hence it can potentially initiate new bone deposition rapidly [260]. Coralline calcium carbonate was also shown to have high osteoconductivity and it does not undergo fibrous encapsulation [262]. Coralline calcium carbonate was associated with a significant gain in periodontal ligament (PDL) clinical attachment, reduction of probing depths and greater defect fill in periodontal regeneration applications [263–265].

4.4. Alloplasts

Alloplastic bone graft materials are synthetic materials developed to overcome the inherent problems associated with autograft use [266]. The major advantages of alloplastic materials include their high abundance relative to natural materials, no risk of disease transmission and the very low antigenicity [216]. Alloplasts can be manufactured in various forms and with varying physicochemical properties. They can be made available in both resorbable and nonresorbable forms and can be customized with varying levels of porosity and pore sizes [17,267,268]. Alloplastic materials are mainly osteoconductive without intrinsic potential for osteogenesis or osteoinduction and have been used successfully in periodontal reconstructive surgery [216]. The most common alloplastic materials are tricalcium phosphates (TCP) [269], bioactive glasses [270], HA and dicalcium phosphates [271]. One feature that appears to be critical for success with use of alloplasts is the relative rough structure and large particle size, which proved to allow for adequate bone ingrowth [272].

4.4.1. Tricalcium Phosphate

TCP is a porous form of calcium phosphate. TCP has two crystallographic forms, α -TCP and β -TCP [273]. The most common type is β -TCP and it is used as partially resorbable filler that allows for bone formation and replacement [216,274]. Over the years β -TCP has gained high acceptance as a bone filler material despite results not always being predictable. When a direct comparison is made, the allogenic grafts appear to outperform β -TCP in terms of resorption and bone formation [275]. There is evidence that TCP granules undergo fibrous tissue encapsulation and do not stimulate bone growth adequately [104,105]. On the other hand, some studies reported bone deposition with β -TCP [275–277]. Vertical and horizontal ridge augmentation using α and/or β TCP has been evaluated in animal and clinical studies with variable results [278–280].



4.4.2. Synthetic Hydroxyapatite

Synthetic HA have been marketed for use in variety of forms: porous non-resorbable, solid nonresorbable, and resorbable (non-ceramic, porous) [17,19]. HA is non-osteogenic, not conclusively osteoinductive, but rather functions as an osteophillic and osteoconductive graft material. The resorptive potential of HA is dependent upon the temperature at which it is processed. When prepared at higher temperatures the HA produced is dense, non-resorbable and has a larger crystal size [281]. The dense HA grafts are osteoconductive, osteophillic and act primarily as inert biocompatible fillers. It has been shown that HA can produce a clinical defect fill greater than flap debridement alone in the treatment of intrabony periodontal defects [282,283]. A resorbable HA, which is particulate and porous, processed at low temperatures is also available for clinical use. This type of HA is a non-sintered (not ceramic) precipitate with particles measuring 300 to 400 μm in size. It is believed that this non-sintered HA acts as a mineral reservoir inducing bone formation via osteoconductive mechanisms [284]. The resorption rate is slow allowing grafts to act as a scaffold for bone replacement [285]. Few studies also reported osteoinductive potential with porous HA grafts [286,287], and early implant loading studies in ridges vertically augmented with nano-structured hydroxyapatite has shown promise [143]. Sinus elevation and alveolar ridge augmentation with HA granules alone [288] or in combination with autogenous bone grafts had high success rates [289–293]. Vertical ridge augmentation of atrophic mandible (posterior region) with customized, computer-aided design/computer-aided manufacturing (CAD/CAM) porous hydroxyapatite scaffolds has been tried [294]. However, HA has limited *in vivo* resorption and remodeling capacity, and are therefore unsuitable as onlay bone graft substitutes for vertical bone augmentation [19,295].

4.4.3. Bioactive Glasses

Bioactive glass is composed of silicon dioxide (45%), calcium oxide (24.5%), sodium oxide (24.5%), and phosphorus pentoxide (6%) [270]. When implanted *in vivo* the pH of the local environment increases >10 , and a silicon-rich gel is formed on the bioactive ceramic surface with the outer layer serving as a bonding surface for osteogenic cells and collagen fibers [296]. Particle sizes range from 90–710 μm to 300–355 μm [270,297]. Formation of hollow calcium phosphate growth chambers occurs as a result of phagocytosing cells penetrating the outer silica gel layer and resorbing the gel. This leads to formation of pouches where osteoprogenitor cells can adhere, differentiate and proliferate [298]. Several studies reported bioactive glasses to have superior manageability, hemostatic and osteoconductive properties and may act to retard epithelial down-growth [206,296,298–303]. Clinical reports of alveolar ridge augmentation with bioglass showed bone formation in intimate contact to the particles [304]. However, since bioglass undergoes no resorption, bone forms around the particles and grows via osteoconduction [305]. This limits the ability of bioglass to work as a bioresorptive scaffold for vertical alveolar bone augmentation.

4.4.4. Dicalcium Phosphates

Recent studies have shown that dicalcium phosphate compounds with high solubility at physiological pH can be successfully utilized for vertical bone augmentation [97,306,307]. Brushite (dicalcium



phosphate dihydrate, DCPD), has the ability to support partial osteogenesis that results in generation of varying amounts of woven bone and fibrovascular tissue [169,308]. Brushite cements have been tested for both vertical bone augmentation and bone defect repair as injectable cements or as preset cement granules [306,309]. Injectable brushite cement has been evaluated in animal studies for minimally invasive craniofacial vertical bone augmentation [306]. Brushite cement was injected under the periosteum on the bone surface, allowing it to set and provide enough healing time to promote vertical bone growth in the local area of cement injection [306]. Several clinical studies have also shown that injectable brushite cements are capable of regenerating bone in buccal dehiscence defects, atrophic ridges and maxillary sinus floor elevation procedures [310]. Similarly, preset granules of brushite cement also promoted vertical bone augmentation in animal models [311]. The amount of vertical bone growth obtained with brushite cement granules was higher than that obtained with commercial bovine HA materials *in vivo* [312]. However, brushite cements exhibit limited *in vivo* resorption due to phase conversion to insoluble HA upon implantation [273,313]. This results in incomplete vertical bone growth in the treated site. Development of brushite cements that do not convert to HA after implantation is necessary to allow for clinical application [306].

Monetite (dicalcium phosphate anhydrous, DCPA) based biomaterials resorb at faster rates compared to brushite [314–316] and do not convert to HA [312,317]. Monetite bioceramic materials have been tested as onlay blocks (3D printed) for vertical bone augmentation and in the form of granules as bone defect fillers [2,273,307,317]. It has been shown that monetite blocks can be used as synthetic onlay bone grafts and can achieve adequate vertical augmentation for dental implant placement [97]. Monetite granules were able to promote bone healing in post-extraction dental alveolar sockets in human patients [307] and of craniofacial defect in animals [317]. The clinical performance of monetite granules has been compared with commercially available bovine HA, and demonstrated greater resorption *in vivo* and bone formation in the alveolar ridge sockets [307].

5. Developments and the Future of Bone Augmentation

The development of biomaterials and techniques for alveolar bone augmentation applications is a challenge from an engineering, surgical and biological perspective. In the field of biomaterials research, degradable materials for bone augmentation are actively sought. Biodegradable natural and synthetic polymers and bioceramics are already in clinical use as for bone tissue engineering applications [318–322]. The degradation rate is one of the most important characteristics for materials to be used for achieving gain in vertical height of bone. Bioceramics show the ability to degrade predictably and show *in vivo* resorption by cell-mediated and solution-driven processes and demonstrate progressive replacement by lamellar true bone [323,324]. The newer generation of biomaterials will have to be fine-tuned in terms of their physico-chemical properties to have more predictable and improved graft resorption after implantation to be used as effective scaffolds for bone augmentation.

Research in the field of bone augmentation and regeneration is currently focused on cellular, molecular and gene therapeutics [325–329]. Bone morphogenetic proteins (BMPs) have generated a lot of interest recently, as they are differentiation factors [330] and have the ability to differentiate osteoprogenitor cells into mineral forming osteoblasts and stimulate vascular proliferation [331]. BMPs have shown promising results for intraoral applications such as sinus augmentation and ridge



preservation [259,332–335]. The most studied BMPs for bone regeneration applications are BMP-2 and BMP-7 [336,337]. Many preclinical studies have shown the usefulness of recombinant human BMPs for the regeneration of bone tissue [338–341]. Bone defect healing using genetic approach where an implant comprising of a bioresorbable polymer mixed with mesenchymal stem cells transfected with adenovirus BMP-2 has been demonstrated [342]. Systemic administration of rhBMP-2 has been shown to result in increased activity of mesenchymal stem cells [343]. It has been seen that rhBMP-2 when delivered when using a calcium phosphate carrier, a liposome carrier and collagen sponges result in accelerated bone healing in rat and rabbit models [342,344]. Other femoral defect studies in sheep have shown evidence of new bone formation four weeks post rhBMP-2 grafting and histological evaluation after fifty two weeks revealed woven and lamellar bone being formed [345]. Studies in dogs have evaluated use of BMP in bone defects revealed complete healing of mandibular defects within three months and significant improvement was observed in degree of mineralization, bone thickness and biomechanical strength [346]. A great deal of resources has been invested in the area of micro and nanoparticles in search of simple, efficient and affordable drug delivery systems [347–350]. Researchers have also tested microspheres and nanoparticles for delivery of BMPs, cytokines and mesenchymal cells [351–354]. Following promising results of poly-lactic-glycolic acid (PLGA) based delivery systems; microspheres of PLGA have been studied in various animal models including calvarial bone defects in rats [355], rat femur [356] and rabbit calvarial defects [357].

Platelet derived growth factor (PDGF) has also shown great potential for use in bone regeneration [358]. Recombinant human PDGFF-BB (rhPDGF-BB) and inorganic bone blocks have been tested for vertical bone augmentation and demonstrated increased vertical gain compared to controls [359]. PDGF used in combination with ePTFE membranes around implants in dogs was shown to induce rapid and increased bone formation around implants compared to no-PDGF control [358]. Vertical bone augmentation using collagen membranes and chitosan sponges with PDGF showed promising results [360,361]. However, the optimal dosage and carriers for PDGF are still to be determined and further animal and human studies are necessary before clinical application. A new approach to bone augmentation is separation of platelet-rich plasma (PRP) from patient blood to be added to the graft material [362–365]. Initial results showed more and denser bone compared to autografts used alone for bone augmentation procedures [362]. Research has shown that PRP *in vitro*, stimulated PDL and fibroblast cell line growths and keratinocyte growth rate was inhibited [366]. A split mouth clinical trial with matched defects of 13 patients found significantly improved results with PRP [367]. The combination of PRP with other graft materials has been inconclusive [368,369]. Gene therapy is based on the principle of modified genetic material being delivered to cells in order to enhance their regenerative potential by increased production and local concentration of differentiation and growth factors [370,371]. A cellular tissue engineering approach is being explored in which the regenerative potential of bone tissue is used by performing *in vitro* amplification of osteoblasts or osteoprogenitor cells grown with and on 3D constructs [372–374]. The seeding of constructs with mesenchymal stem cells also holds great promise and can potentially be investigated in future for vertical alveolar bone augmentation therapy [375,376].

Various approaches discussed here separately or in combination have the potential for providing improved tissue regenerative results [370]. It is expected that the next generation of biomaterials will demonstrate vast improvements in graft and biological tissue interfacing based on the knowledge gained



from recent research and allow clinicians to achieve more predictable clinical results with regards to vertical alveolar bone augmentation.

6. Conclusions

There are a plethora of techniques with various combinations of natural and synthetic graft materials that can be utilized for achieving vertical alveolar bone augmentation. There is no single ideal technique or graft material to choose in clinical practice but rather an increasing number of materials and methods to be used in individualized approaches to ridge reconstruction. Treatment protocols that involve less invasive, more reproducible and less technique sensitive vertical bone augmentation procedures and biomaterials need constant revisions in light of new developments in bone regeneration therapeutics.

Author Contributions

Zeeshan Sheikh performed the literature search, wrote the manuscript and compiled the information to create the Tables 1 and 2. As the corresponding author, was responsible for all corrections and revisions needed in the manuscript. Corneliu Sima performed the literature search, wrote the manuscript, created the illustrations and contributed the clinical case figure. Michael Glogauer performed literature search, compiled the information, provide the guidelines in order to prepare the manuscript and finalized the manuscript.

Conflicts of Interest

The authors declare no conflict of interest.

References

1. Rocchietta, I.; Fontana, F.; Simion, M. Clinical outcomes of vertical bone augmentation to enable dental implant placement: A systematic review. *J. Clin. Periodontol.* **2008**, *35*, 203–215.
2. Tamimi, F.; Torres, J.; Al-Abedalla, K.; Lopez-Cabarcos, E.; Alkhraisat, M.H.; Bassett, D.C.; Gbureck, U.; Barralet, J.E. Osseointegration of dental implants in 3D-printed synthetic onlay grafts customized according to bone metabolic activity in recipient site. *Biomaterials* **2014**, *35*, 5436–5445.
3. Lipkowitz, R. An overview of the osseointegration of dental implants. *J. Mass. Dent. Soc.* **1989**, *38*, 173–175.
4. Lipkowitz, R.D.; Berger, J.R.; Gold, B. The osseointegration of dental implants. An overview. *NY State Dent. J.* **1989**, *55*, 32–34.
5. Goto, T. Osseointegration and dental implants. *Clin. Calcium* **2014**, *24*, 265–271.
6. Javed, F.; Ahmed, H.B.; Crespi, R.; Romanos, G.E. Role of primary stability for successful osseointegration of dental implants: Factors of influence and evaluation. *Int. Med. Appl. Sci.* **2013**, *5*, 162–167.
7. Khoury, F.; Buchmann, R. Surgical therapy of peri-implant disease: A 3-year follow-up study of cases treated with 3 different techniques of bone regeneration. *J. Periodontol.* **2001**, *72*, 1498–1508.



8. Esposito, M.; Grusovin, M.G.; Kwan, S.; Worthington, H.V.; Coulthard, P. Interventions for replacing missing teeth: Bone augmentation techniques for dental implant treatment. *Cochrane Database Syst. Rev.* **2008**, doi: 10.1002/14651858.CD003607.pub3.
9. Liu, J.; Kerns, D.G. Mechanisms of guided bone regeneration: A review. *Open Dent. J.* **2014**, *8*, 56–65.
10. Van der Weijden, F.; Dell'Acqua, F.; Slot, D.E. Alveolar bone dimensional changes of post-extraction sockets in humans: A systematic review. *J. Clin. Periodontol.* **2009**, *36*, 1048–1058.
11. Schropp, L.; Wenzel, A.; Kostopoulos, L.; Karring, T. Bone healing and soft tissue contour changes following single-tooth extraction: A clinical and radiographic 12-month prospective study. *Int. J. Periodontics Restor. Dent.* **2003**, *23*, 313–323.
12. Tallgren, A. The continuing reduction of the residual alveolar ridges in complete denture wearers: A mixed-longitudinal study covering 25 years. 1972. *J. Prosthet. Dent.* **2003**, *89*, 427–435.
13. Carlsson, G.E.; Thilander, H.; Hedegard, B. Histologic changes in the upper alveolar process after extractions with or without insertion of an immediate full denture. *Acta Odontol. Scand.* **1967**, *25*, 21–43.
14. Bernstein, S.; Cooke, J.; Fotek, P.; Wang, H.L. Vertical bone augmentation: Where are we now? *Implant Dent.* **2006**, *15*, 219–228.
15. Tolman, D.E. Advanced residual ridge resorption: Surgical management. *Int. J. Prosthodont.* **1993**, *6*, 118–125.
16. Tonetti, M.S.; Hammerle, C.H. Advances in bone augmentation to enable dental implant placement: Consensus report of the sixth european workshop on periodontology. *J. Clin. Periodontol.* **2008**, *35*, 168–172.
17. Sheikh, Z.A.; Javaid, M.A.; Abdallah, M.N. Bone replacement graft materials in dentistry. In *Dental Biomaterials (Principle and Its Application)*, 2nd ed.; Khurshid, Z., Zafar, S.Z., Eds.; Paramount Publishing Enterprise: Karachi, Pakistan, 2013.
18. Sheikh, Z.; Abdallah, M.N.; Hamdan, N.; Javaid, M.A.; Khurshid, Z. Barrier membranes for tissue regeneration and bone augmentation techniques in dentistry. In *Handbook of Oral Biomaterials*; Matilina, K.P., Ed.; Pan Stanford Publishing: Singapore, Singapore, 2014.
19. Tevlin, R.; McArdle, A.; Atashroo, D.; Walmsley, G.G.; Senarath-Yapa, K.; Zielins, E.R.; Paik, K.J.; Longaker, M.T.; Wan, D.C. Biomaterials for craniofacial bone engineering. *J. Dent. Res.* **2014**, *93*, 1187–1195.
20. McAllister, B.S.; Haghghat, K. Bone augmentation techniques. *J. Periodontol.* **2007**, *78*, 377–396.
21. Chiapasco, M.; Zaniboni, M.; Rimondini, L. Autogenous onlay bone grafts vs. Alveolar distraction osteogenesis for the correction of vertically deficient edentulous ridges: A 2–4-year prospective study on humans. *Clin. Oral Implant. Res.* **2007**, *18*, 432–440.
22. Sacco, A.G.; Chepeha, D.B. Current status of transport-disc-distraction osteogenesis for mandibular reconstruction. *Lancet Oncol.* **2007**, *8*, 323–330.
23. Von Arx, T.; Buser, D. Horizontal ridge augmentation using autogenous block grafts and the guided bone regeneration technique with collagen membranes: A clinical study with 42 patients. *Clin. Oral Implant. Res.* **2006**, *17*, 359–366.



24. Von Arx, T.; Hardt, N.; Wallkamm, B. The time technique: A new method for localized alveolar ridge augmentation prior to placement of dental implants. *Int. J. Oral Maxillofac. Implant.* **1996**, *11*, 387–394.
25. Rocuzzo, M.; Ramieri, G.; Bunino, M.; Berrone, S. Autogenous bone graft alone or associated with titanium mesh for vertical alveolar ridge augmentation: A controlled clinical trial. *Clin. Oral Implant. Res.* **2007**, *18*, 286–294.
26. Karsenty, G. Transcriptional control of skeletogenesis. *Ann. Rev. Genomics Hum. Genet.* **2008**, *9*, 183–196.
27. Nakashima, K.; Zhou, X.; Kunkel, G.; Zhang, Z.; Deng, J.M.; Behringer, R.R.; de Crombrughe, B. The novel zinc finger-containing transcription factor osterix is required for osteoblast differentiation and bone formation. *Cell* **2002**, *108*, 17–29.
28. Ornitz, D.M.; Marie, P.J. FGF signaling pathways in endochondral and intramembranous bone development and human genetic disease. *Genes Dev.* **2002**, *16*, 1446–1465.
29. Wu, X.; Shi, W.; Cao, X. Multiplicity of BMP signaling in skeletal development. *Ann. NY Acad. Sci.* **2007**, *1116*, 29–49.
30. Krishnan, V.; Moore, T.L.; Ma, Y.L.; Helvering, L.M.; Frolik, C.A.; Valasek, K.M.; Ducy, P.; Geiser, A.G. Parathyroid hormone bone anabolic action requires Cbfa1/Runx2-dependent signaling. *Mol. Endocrinol.* **2003**, *17*, 423–435.
31. Teitelbaum, S.L.; Ross, F.P. Genetic regulation of osteoclast development and function. *Nat. Rev. Genet.* **2003**, *4*, 638–649.
32. Lacey, D.L.; Timms, E.; Tan, H.L.; Kelley, M.J.; Dunstan, C.R.; Burgess, T.; Elliott, R.; Colombero, A.; Elliott, G.; Scully, S.; *et al.* Osteoprotegerin ligand is a cytokine that regulates osteoclast differentiation and activation. *Cell* **1998**, *93*, 165–176.
33. Melcher, A.H. On the repair potential of periodontal tissues. *J. Periodontol.* **1976**, *47*, 256–260.
34. Majzoub, Z.; Berengo, M.; Giardino, R.; Aldini, N.N.; Cordioli, G. Role of intramarrow penetration in osseous repair: A pilot study in the rabbit calvaria. *J. Periodontol.* **1999**, *70*, 1501–1510.
35. Crea, A.; Deli, G.; Littarru, C.; Lajolo, C.; Orgeas, G.V.; Tatakis, D.N. Intrabony defects, open-flap debridement, and decortication: A randomized clinical trial. *J. Periodontol.* **2014**, *85*, 34–42.
36. Goldberg, V.M. Selection of bone grafts for revision total hip arthroplasty. *Clin. Orthop. Relat. Res.* **2000**, *381*, 68–76.
37. Hiatt, W.H.; Schallhorn, R.G.; Aaronian, A.J. The induction of new bone and cementum formation. Iv. Microscopic examination of the periodontium following human bone and marrow allograft, autograft and nongraft periodontal regenerative procedures. *J. Periodontol.* **1978**, *49*, 495–512.
38. Hiatt, W.H.; Schallho, R. Intraoral transplants of cancellous bone and marrow in periodontal lesions. *J. Periodontol.* **1973**, *44*, 194–208.
39. Urist, M.R. Bone transplants and implants. In *Fundamental and Clinical Bone Physiology*; Urist, M.R. Ed.; JB Lippincott: Philadelphia, PA, USA, 1980; pp. 331–368.
40. Goldberg, V.M.; Stevenson, S. Natural history of autografts and allografts. *Clin. Orthop. Relat. Res.* **1987**, *23*, 7–16.
41. Cornell, C.N. Osteoconductive materials and their role as substitutes for autogenous bone grafts. *Orthop. Clin. North Am.* **1999**, *30*, 591–598.



42. Mastrogiacomo, M.; Scaglione, S.; Martinetti, R.; Dolcini, L.; Beltrame, F.; Cancedda, R.; Quarto, R. Role of scaffold internal structure on *in vivo* bone formation in macroporous calcium phosphate bioceramics. *Biomaterials* **2006**, *27*, 3230–3237.
43. Boyne, P.J. Bone induction and the use of HTR polymer as a vehicle for osseous inductor materials. *Compendium* **1988**, *10*, S337–S341.
44. Ewers, R.T.B.; Ghali, G.; Jensen, O. A new biologic classification of bone augmentation. In *The Osteoperiosteal Flap: A Simplified Approach to Alveolar Bone Reconstruction*; Quintessence Publishing: Chicago, IL, USA, 2010.
45. Ito, T.; Kohno, T.; Kojima, T. Free vascularized fibular graft. *J. Trauma* **1984**, *24*, 756–760.
46. Malizos, K.N.; Zalavras, C.G.; Soucacos, P.N.; Beris, A.E.; Urbaniak, J.R. Free vascularized fibular grafts for reconstruction of skeletal defects. *J. Am. Acad. Orthop. Surg.* **2004**, *12*, 360–369.
47. Kramer, F.J.; Dempf, R.; Bremer, B. Efficacy of dental implants placed into fibula-free flaps for orofacial reconstruction. *Clin. Oral Implant. Res.* **2005**, *16*, 80–88.
48. Raoul, G.; Ruhin, B.; Briki, S.; Lauwers, L.; Haurou Patou, G.; Capet, J.P.; Maes, J.M.; Ferri, J. Microsurgical reconstruction of the jaw with fibular grafts and implants. *J. Craniofac. Surg.* **2009**, *20*, 2105–2117.
49. Jensen, O.T.; Kuhlke, K.L. Maxillary full-arch alveolar split osteotomy with island osteoperiosteal flaps and sinus grafting using bone morphogenetic protein-2 and retrofitting for immediate loading with a provisional: Surgical and prosthetic procedures and case report. *Int. J. Oral Maxillofac. Implant.* **2013**, *28*, e260–e271.
50. Kilic, E.; Alkan, A.; Ulu, M.; Zortuk, M.; Gumus, H.O. Vertical ridge augmentation using sandwich osteotomy: 2 case reports. *Gen. Dent.* **2013**, *61*, e22–e25.
51. Scipioni, A.; Bruschi, G.B.; Calesini, G. The edentulous ridge expansion technique: A five-year study. *Int. J. Periodontics Restor. Dent.* **1994**, *14*, 451–459.
52. Duncan, J.M.; Westwood, R.M. Ridge widening for the thin maxilla: A clinical report. *Int. J. Oral Maxillofac. Implant.* **1997**, *12*, 224–227.
53. Yoshioka, I.; Tanaka, T.; Khanal, A.; Habu, M.; Kito, S.; Kodama, M.; Oda, M.; Wakasugi-Sato, N.; Matsumoto-Takeda, S.; Seta, Y.; *et al.* Correlation of mandibular bone quality with neurosensory disturbance after sagittal split ramus osteotomy. *Br. J. Oral Maxillofac. Surg.* **2011**, *49*, 552–556.
54. Jensen, O.T.; Cockrell, R.; Kuhike, L.; Reed, C. Anterior maxillary alveolar distraction osteogenesis: A prospective 5-year clinical study. *Int. J. Oral Maxillofac. Implant.* **2002**, *17*, 52–68.
55. Rachmiel, A.; Srouji, S.; Peled, M. Alveolar ridge augmentation by distraction osteogenesis. *Int. J. Oral Maxillofac. Surg.* **2001**, *30*, 510–517.
56. McAllister, B.S. Histologic and radiographic evidence of vertical ridge augmentation utilizing distraction osteogenesis: 10 consecutively placed distractors. *J. Periodontol.* **2001**, *72*, 1767–1779.
57. Klug, C.N.; Millesi-Schobel, G.A.; Millesi, W.; Watzinger, F.; Ewers, R. Preprosthetic vertical distraction osteogenesis of the mandible using an l-shaped osteotomy and titanium membranes for guided bone regeneration. *J. Oral Maxillofac. Surg.* **2001**, *59*, 1302–1308; discussion 1309–1310.
58. Simion, M.; Fontana, F.; Rasperini, G.; Maiorana, C. Vertical ridge augmentation by expanded-polytetrafluoroethylene membrane and a combination of intraoral autogenous bone graft and deproteinized anorganic bovine bone (bio oss). *Clin. Oral Implant. Res.* **2007**, *18*, 620–629.



59. Enislidis, G.; Fock, N.; Ewers, R. Distraction osteogenesis with subperiosteal devices in edentulous mandibles. *Br. J. Oral Maxillofac. Surg.* **2005**, *43*, 399–403.
60. Kunkel, M.; Wahlmann, U.; Reichert, T.E.; Wegener, J.; Wagner, W. Reconstruction of mandibular defects following tumor ablation by vertical distraction osteogenesis using intraosseous distraction devices. *Clin. Oral Implant. Res.* **2005**, *16*, 89–97.
61. Chiapasco, M.; Romeo, E.; Casentini, P.; Rimondini, L. Alveolar distraction osteogenesis vs. Vertical guided bone regeneration for the correction of vertically deficient edentulous ridges: A 1–3-year prospective study on humans. *Clin. Oral Implant. Res.* **2004**, *15*, 82–95.
62. Chiapasco, M.; Consolo, U.; Bianchi, A.; Ronchi, P. Alveolar distraction osteogenesis for the correction of vertically deficient edentulous ridges: A multicenter prospective study on humans. *Int. J. Oral Maxillofac. Implant.* **2004**, *19*, 399–407.
63. Oda, T.; Sawaki, Y.; Ueda, M. Experimental alveolar ridge augmentation by distraction osteogenesis using a simple device that permits secondary implant placement. *Int. J. Oral Maxillofac. Implant.* **2000**, *15*, 95–102.
64. Block, M.S.; Akin, R.; Chang, A.; Gottsegen, G.B.; Gardiner, D. Skeletal and dental movements after anterior maxillary advancement using implant-supported distraction osteogenesis in dogs. *J. Oral Maxillofac. Surg.* **1997**, *55*, 1433–1439; discussion 1439–1440.
65. Block, M.S.; Almerico, B.; Crawford, C.; Gardiner, D.; Chang, A. Bone response to functioning implants in dog mandibular alveolar ridges augmented with distraction osteogenesis. *Int. J. Oral Maxillofac. Implant.* **1998**, *13*, 342–351.
66. Ilizarov, G.A. Basic principles of transosseous compression and distraction osteosynthesis. *Ortop. Travmatol. Protez.* **1971**, *32*, 7–15.
67. Ilizarov, G.A. The tension-stress effect on the genesis and growth of tissues: Part II. The influence of the rate and frequency of distraction. *Clin. Orthop. Relat. Res.* **1989**, *239*, 263–285.
68. Davies, J.; Turner, S.; Sandy, J.R. Distraction osteogenesis—A review. *Br. Dent. J.* **1998**, *185*, 462–467.
69. Maffuli, N.; Fixsen, J.A. Distraction osteogenesis in congenital limb length discrepancy: A review. *J. R. Coll. Surg. Edinb.* **1996**, *41*, 258–264.
70. Hidding, J.; Lazar, F.; Zoller, J.E. Initial outcome of vertical distraction osteogenesis of the atrophic alveolar ridge. *Mund Kiefer Gesichtschirurgie MKG* **1999**, *3*, S79–S83.
71. Chiapasco, M.; Romeo, E.; Vogel, G. Vertical distraction osteogenesis of edentulous ridges for improvement of oral implant positioning: A clinical report of preliminary results. *Int. J. Oral Maxillofac. Implant.* **2001**, *16*, 43–51.
72. Urbani, G.; Lombardo, G.; Santi, E.; Consolo, U. Distraction osteogenesis to achieve mandibular vertical bone regeneration: A case report. *Int. J. Periodontics Restor. Dent.* **1999**, *19*, 321–331.
73. McAllister, B.S.; Gaffaney, T.E. Distraction osteogenesis for vertical bone augmentation prior to oral implant reconstruction. *Periodontology 2000* **2003**, *33*, 54–66.
74. Chin, M.; Toth, B.A. Distraction osteogenesis in maxillofacial surgery using internal devices: Review of five cases. *J. Oral Maxillofac. Surg.* **1996**, *54*, 45–53; discussion 54.
75. Maull, D.J. Review of devices for distraction osteogenesis of the craniofacial complex. *Semin. Orthod.* **1999**, *5*, 64–73.



76. Uckan, S.; Oguz, Y.; Bayram, B. Comparison of intraosseous and extraosseous alveolar distraction osteogenesis. *J. Oral Maxillofac. Surg.* **2007**, *65*, 671–674.
77. Chin, M. The role of distraction osteogenesis in oral and maxillofacial surgery. *J. Oral Maxillofac. Surg.* **1998**, *56*, 805–806.
78. Li, T.; Zhang, Y.; Shao, B.; Gao, Y.; Zhang, C.; Cao, Q.; Kong, L. Partially biodegradable distraction implant to replace conventional implants in alveolar bone of insufficient height: A preliminary study in dogs. *Clin. Implant Dent. Relat. Res.* **2014**, doi:10.1111/cid.12229.
79. Polo, W.C.; Cury, P.R.; Sendyk, W.R.; Gromatzky, A. Posterior mandibular alveolar distraction osteogenesis utilizing an extraosseous distractor: A prospective study. *J. Periodontol.* **2005**, *76*, 1463–1468.
80. Iizuka, T.; Hallermann, W.; Seto, I.; Smolka, W.; Smolka, K.; Bosshardt, D.D. Bi-directional distraction osteogenesis of the alveolar bone using an extraosseous device. *Clin. Oral Implant. Res.* **2005**, *16*, 700–707.
81. Gaggl, A.; Schultes, G.; Karcher, H. Vertical alveolar ridge distraction with prosthetic treatable distractors: A clinical investigation. *Int. J. Oral Maxillofac. Implant.* **2000**, *15*, 701–710.
82. McCarthy, J.G.; Schreiber, J.; Karp, N.; Thorne, C.H.; Grayson, B.H. Lengthening the human mandible by gradual distraction. *Plast. Reconstr. Surg.* **1992**, *89*, 1–8; discussion 9–10.
83. Lammens, J.; Liu, Z.; Aerssens, J.; Dequeker, J.; Fabry, G. Distraction bone healing vs. osteotomy healing: A comparative biochemical analysis. *J. Bone Miner. Res.* **1998**, *13*, 279–286.
84. Verlinden, C.R.; van de Vijfeijken, S.E.; Jansma, E.P.; Becking, A.G.; Swennen, G.R. Complications of mandibular distraction osteogenesis for congenital deformities: A systematic review of the literature and proposal of a new classification for complications. *Int. J. Oral Maxillofac. Surg.* **2015**, *44*, 37–43.
85. Kempton, S.J.; McCarthy, J.E.; Afifi, A.M. A systematic review of distraction osteogenesis in hand surgery: What are the benefits, complication rates, and duration of treatment? *Plast. Reconstr. Surg.* **2014**, *133*, 1120–1130.
86. Verlinden, C.R.; van de Vijfeijken, S.E.; Tuinzing, D.B.; Jansma, E.P.; Becking, A.G.; Swennen, G.R. Complications of mandibular distraction osteogenesis for developmental deformities: A systematic review of the literature. *Int. J. Oral Maxillofac. Surg.* **2015**, *44*, 44–49.
87. Batal, H.S.; Cottrell, D.A. Alveolar distraction osteogenesis for implant site development. *Oral Maxillofac. Surg. Clin. North Am.* **2004**, *16*, 91–109.
88. Isaksson, S.; Alberius, P. Maxillary alveolar ridge augmentation with onlay bone-grafts and immediate endosseous implants. *J. Cranio Maxillo Fac. Surg.* **1992**, *20*, 2–7.
89. Barone, A.; Covani, U. Maxillary alveolar ridge reconstruction with nonvascularized autogenous block bone: Clinical results. *J. Oral Maxillofac. Surg.* **2007**, *65*, 2039–2046.
90. Cordaro, L.; Amade, D.S.; Cordaro, M. Clinical results of alveolar ridge augmentation with mandibular block bone grafts in partially edentulous patients prior to implant placement. *Clin. Oral Implant. Res.* **2002**, *13*, 103–111.
91. Bahat, O.; Fontanessi, R.V. Implant placement in three-dimensional grafts in the anterior jaw. *Int. J. Periodontics Restor. Dent.* **2001**, *21*, 357–365.



92. Schleier, P.; Wolf, C.; Siebert, H.; Shafer, D.; Freilich, M.; Berndt, A.; Schumann, D. Treatment options in distraction osteogenesis therapy using a new bidirectional distractor system. *Int. J. Oral Maxillofac. Implant.* **2007**, *22*, 408–416.
93. Turker, N.; Basa, S.; Vural, G. Evaluation of osseous regeneration in alveolar distraction osteogenesis with histological and radiological aspects. *J. Oral Maxillofac. Surg.* **2007**, *65*, 608–614.
94. Tolman, D.E. Reconstructive procedures with endosseous implants in grafted bone: A review of the literature. *Int. J. Oral Maxillofac. Implants* **1995**, *10*, 275–294.
95. Misch, C.M. Comparison of intraoral donor sites for onlay grafting prior to implant placement. *Int. J. Oral Maxillofac. Implant.* **1997**, *12*, 767–776.
96. Proussaefs, P.; Lozada, J.; Kleinman, A.; Rohrer, M.D. The use of ramus autogenous block grafts for vertical alveolar ridge augmentation and implant placement: A pilot study. *Int. J. Oral Maxillofac. Implant.* **2002**, *17*, 238–248.
97. Tamimi, F.; Torres, J.; Gbureck, U.; Lopez-Cabarcos, E.; Bassett, D.C.; Alkhraisat, M.H.; Barralet, J.E. Craniofacial vertical bone augmentation: A comparison between 3D printed monolithic monetite blocks and autologous onlay grafts in the rabbit. *Biomaterials* **2009**, *30*, 6318–6326.
98. Draenert, F.G.; Huetzen, D.; Neff, A.; Mueller, W.E. Vertical bone augmentation procedures: Basics and techniques in dental implantology. *J. Biomed. Mater. Res. Part A* **2014**, *102*, 1605–1613.
99. Sailer, H.F. A new method of inserting endosseous implants in totally atrophic maxillae. *J. Cranio Maxillo Fac. Surg.* **1989**, *17*, 299–305.
100. Keller, E.E.; Tolman, D.E.; Eckert, S. Surgical-prosthetic reconstruction of advanced maxillary bone compromise with autogenous onlay block bone grafts and osseointegrated endosseous implants: A 12-year study of 32 consecutive patients. *Int. J. Oral Maxillofac. Implant.* **1999**, *14*, 197–209.
101. Breine, U.; Branemark, P.I. Reconstruction of alveolar jaw bone. An experimental and clinical study of immediate and preformed autologous bone grafts in combination with osseointegrated implants. *Scand. J. Plast. Reconstr. Surg.* **1980**, *14*, 23–48.
102. Jensen, O.T.; Greer, R.O., Jr.; Johnson, L.; Kassebaum, D. Vertical guided bone-graft augmentation in a new canine mandibular model. *Int. J. Oral Maxillofac. Implant.* **1995**, *10*, 335–344.
103. Jardini, M.A.; De Marco, A.C.; Lima, L.A. Early healing pattern of autogenous bone grafts with and without e-PTFE membranes: A histomorphometric study in rats. *Oral Surg. Oral Med. Oral Pathol. Oral Radiol. Endod.* **2005**, *100*, 666–673.
104. Buser, D.; Dula, K.; Hirt, H.P.; Schenk, R.K. Lateral ridge augmentation using autografts and barrier membranes: A clinical study with 40 partially edentulous patients. *J. Oral Maxillofac. Surg.* **1996**, *54*, 420–432; discussion 432–433.
105. Ronda, M.; Rebaudi, A.; Torelli, L.; Stacchi, C. Expanded vs. Dense polytetrafluoroethylene membranes in vertical ridge augmentation around dental implants: A prospective randomized controlled clinical trial. *Clin. Oral Implant. Res.* **2014**, *25*, 859–866.
106. Handelsman, M.; Celletti, R. Alveolar ridge augmentation using membranes. *Oral Maxillofac. Surg. Clin. North Am.* **2004**, *16*, 33–39.



107. Urban, I.A.; Lozada, J.L.; Jovanovic, S.A.; Nagursky, H.; Nagy, K. Vertical ridge augmentation with titanium-reinforced, dense-PTFE membranes and a combination of particulated autogenous bone and anorganic bovine bone-derived mineral: A prospective case series in 19 patients. *Int. J. Oral Maxillofac. Implant.* **2014**, *29*, 185–193.
108. Pikos, M.A. Block autografts for localized ridge augmentation: Part I. The posterior maxilla. *Implant Dent.* **1999**, *8*, 279–285.
109. Pikos, M.A. Block autografts for localized ridge augmentation: Part II. The posterior mandible. *Implant Dent.* **2000**, *9*, 67–75.
110. Levin, L.; Nitzan, D.; Schwartz-Arad, D. Success of dental implants placed in intraoral block bone grafts. *J. Periodontol.* **2007**, *78*, 18–21.
111. Stubinger, S.; Nuss, K.; Landes, C.; von Rechenberg, B.; Sader, R. Harvesting of intraoral autogenous block grafts from the chin and ramus region: Preliminary results with a variable square pulse Er:YAG laser. *Lasers Surg. Med.* **2008**, *40*, 312–318.
112. Pourabbas, R.; Nezafati, S. Clinical results of localized alveolar ridge augmentation with bone grafts harvested from symphysis in comparison with ramus. *J. Dent. Res. Dent. Clin. Dent. Prospect.* **2007**, *1*, 7–12.
113. Verhoeven, J.W.; Cune, M.S.; Terlou, M.; Zoon, M.A.; de Putter, C. The combined use of endosteal implants and iliac crest onlay grafts in the severely atrophic mandible: A longitudinal study. *Int. J. Oral Maxillofac. Surg.* **1997**, *26*, 351–357.
114. Proussaefs, P.; Lozada, J. The use of intraorally harvested autogenous block grafts for vertical alveolar ridge augmentation: A human study. *Int. J. Periodontics Restor. Dent.* **2005**, *25*, 351–363.
115. Felice, P.; Checchi, V.; Pistilli, R.; Scarano, A.; Pellegrino, G.; Esposito, M. Bone augmentation vs. 5-mm dental implants in posterior atrophic jaws. Four-month post-loading results from a randomised controlled clinical trial. *Eur. J. Oral Implantol.* **2009**, *2*, 267–281.
116. Felice, P.; Cannizzaro, G.; Checchi, V.; Marchetti, C.; Pellegrino, G.; Censi, P.; Esposito, M. Vertical bone augmentation vs. 7-mm-long implants in posterior atrophic mandibles. Results of a randomised controlled clinical trial of up to 4 months after loading. *Eur. J. Oral Implantol.* **2009**, *2*, 7–20.
117. Felice, P.; Marchetti, C.; Iezzi, G.; Piattelli, A.; Worthington, H.; Pellegrino, G.; Esposito, M. Vertical ridge augmentation of the atrophic posterior mandible with interpositional bloc grafts: Bone from the iliac crest vs. Bovine anorganic bone. Clinical and histological results up to one year after loading from a randomized-controlled clinical trial. *Clin. Oral Implant. Res.* **2009**, *20*, 1386–1393.
118. Felice, P.; Pistilli, R.; Lizio, G.; Pellegrino, G.; Nisii, A.; Marchetti, C. Inlay vs. onlay iliac bone grafting in atrophic posterior mandible: A prospective controlled clinical trial for the comparison of two techniques. *Clin. Implant Dent. Relat. Res.* **2009**, *11*, e69–e82.
119. Lin, K.Y.; Bartlett, S.P.; Yaremchuk, M.J.; Fallon, M.; Grossman, R.F.; Whitaker, L.A. The effect of rigid fixation on the survival of onlay bone grafts: An experimental study. *Plast. Reconstr. Surg.* **1990**, *86*, 449–456.
120. De Carvalho, P.S.; Vasconcellos, L.W.; Pi, J. Influence of bed preparation on the incorporation of autogenous bone grafts: A study in dogs. *Int. J. Oral Maxillofac. Implant.* **2000**, *15*, 565–570.



121. Jensen, J.; Reiche-Fischel, O.; Sindet-Pedersen, S. Autogenous mandibular bone grafts for malar augmentation. *J. Oral Maxillofac. Surg.* **1995**, *53*, 88–90.
122. Valentini, P.; Abensur, D. Maxillary sinus floor elevation for implant placement with demineralized freeze-dried bone and bovine bone (bio-oss): A clinical study of 20 patients. *Int. J. Periodontics Restor. Dent.* **1997**, *17*, 232–241.
123. Urbani, G.; Lombardo, G.; Santi, E.; Tarnow, D. Localized ridge augmentation with chin grafts and resorbable pins: Case reports. *Int. J. Periodontics Restor. Dent.* **1998**, *18*, 363–375.
124. Whittaker, J.M.; James, R.A.; Lozada, J.; Cordova, C.; GaRey, D.J. Histological response and clinical evaluation of heterograft and allograft materials in the elevation of the maxillary sinus for the preparation of endosteal dental implant sites. Simultaneous sinus elevation and root form implantation: An eight-month autopsy report. *J. Oral Implantol.* **1989**, *15*, 141–144.
125. Albrektsson, T. Repair of bone grafts. A vital microscopic and histological investigation in the rabbit. *Scand. J. Plast. Reconstr. Surg.* **1980**, *14*, 1–12.
126. Lyford, R.H.; Mills, M.P.; Knapp, C.I.; Scheyer, E.T.; Mellonig, J.T. Clinical evaluation of freeze-dried block allografts for alveolar ridge augmentation: A case series. *Int. J. Periodontics Restor. Dent.* **2003**, *23*, 417–425.
127. Leonetti, J.A.; Koup, R. Localized maxillary ridge augmentation with a block allograft for dental implant placement: Case reports. *Implant Dent.* **2003**, *12*, 217–226.
128. Keith, J.D., Jr. Localized ridge augmentation with a block allograft followed by secondary implant placement: A case report. *Int. J. Periodontics Restor. Dent.* **2004**, *24*, 11–17.
129. Dahlin, C.; Linde, A.; Gottlow, J.; Nyman, S. Healing of bone defects by guided tissue regeneration. *Plast. Reconstr. Surg.* **1988**, *81*, 672–676.
130. Buser, D.; Dula, K.; Hess, D.; Hirt, H.P.; Belser, U.C. Localized ridge augmentation with autografts and barrier membranes. *Periodontology 2000* **1999**, *19*, 151–163.
131. Deshpande, S.; Deshmukh, J.; Deshpande, S.; Khatri, R.; Deshpande, S. Vertical and horizontal ridge augmentation in anterior maxilla using autograft, xenograft and titanium mesh with simultaneous placement of endosseous implants. *J. Indian Soc. Periodontol.* **2014**, *18*, 661–665.
132. Simion, M.; Jovanovic, S.A.; Tinti, C.; Benfenati, S.P. Long-term evaluation of osseointegrated implants inserted at the time or after vertical ridge augmentation. A retrospective study on 123 implants with 1–5 year follow-up. *Clin. Oral Implant. Res.* **2001**, *12*, 35–45.
133. Simion, M.; Jovanovic, S.A.; Trisi, P.; Scarano, A.; Piattelli, A. Vertical ridge augmentation around dental implants using a membrane technique and autogenous bone or allografts in humans. *Int. J. Periodontics Restor. Dent.* **1998**, *18*, 8–23.
134. Bholá, M.; Kinaia, B.M.; Chahine, K. Guided bone regeneration using an allograft material: Review and case presentations. *Pract. Proced. Aesthet. Dent. PPAD* **2008**, *20*, 551–557.
135. Chiapasco, M.; Zaniboni, M. Clinical outcomes of GBR procedures to correct peri-implant dehiscences and fenestrations: A systematic review. *Clin. Oral Implant. Res.* **2009**, *20*, 113–123.
136. Clarizio, L.F. Successful implant restoration without the use of membrane barriers. *J. Oral Maxillofac. Surg.* **1999**, *57*, 1117–1121.
137. Ten Bruggenkate, C.M.; Kraaijenhagen, H.A.; van der Kwast, W.A.; Krekeler, G.; Oosterbeek, H.S. Autogenous maxillary bone grafts in conjunction with placement of I.T.I. Endosseous implants. A preliminary report. *Int. J. Oral Maxillofac. Surg.* **1992**, *21*, 81–84.



138. Malmquist, J.P. Successful implant restoration with the use of barrier membranes. *J. Oral Maxillofac. Surg.* **1999**, *57*, 1114–1116.
139. Jovanovic, S.A.; Spiekermann, H.; Richter, E.J. Bone regeneration around titanium dental implants in dehiscence defect sites: A clinical study. *Int. J. Oral Maxillofac. Implant.* **1992**, *7*, 233–245.
140. Schenk, R.K.; Buser, D.; Hardwick, W.R.; Dahlin, C. Healing pattern of bone regeneration in membrane-protected defects: A histologic study in the canine mandible. *Int. J. Oral Maxillofac. Implant.* **1994**, *9*, 13–29.
141. Mellonig, J.T.; Nevins, M. Guided bone regeneration of bone defects associated with implants: An evidence-based outcome assessment. *Int. J. Periodontics Restor. Dent.* **1995**, *15*, 168–185.
142. Hurzeler, M.B.; Kohal, R.J.; Naghshbandi, J.; Mota, L.F.; Conradt, J.; Huttmacher, D.; Caffesse, R.G. Evaluation of a new bioresorbable barrier to facilitate guided bone regeneration around exposed implant threads. An experimental study in the monkey. *Int. J. Oral Maxillofac. Surg.* **1998**, *27*, 315–320.
143. Canullo, L.; Trisi, P.; Simion, M. Vertical ridge augmentation around implants using e-PTFE titanium-reinforced membrane and deproteinized bovine bone mineral (bio-oss): A case report. *Int. J. Periodontics Restor. Dent.* **2006**, *26*, 355–361.
144. Parma-Benfenati, S.; Tinti, C.; Albrektsson, T.; Johansson, C. Histologic evaluation of guided vertical ridge augmentation around implants in humans. *Int. J. Periodontics Restor. Dent.* **1999**, *19*, 424–437.
145. Tinti, C.; Parma-Benfenati, S. Vertical ridge augmentation: Surgical protocol and retrospective evaluation of 48 consecutively inserted implants. *Int. J. Periodontics Restor. Dent.* **1998**, *18*, 434–443.
146. Tinti, C.; Parma-Benfenati, S.; Manfrini, F. Spacemaking metal structures for nonresorbable membranes in guided bone regeneration around implants. Two case reports. *Int. J. Periodontics Restor. Dent.* **1997**, *17*, 53–61.
147. Simion, M.; Trisi, P.; Piattelli, A. Vertical ridge augmentation using a membrane technique associated with osseointegrated implants. *Int. J. Periodontics Restor. Dent.* **1994**, *14*, 496–511.
148. Torres, J.; Tamimi, F.; Alkhraisat, M.H.; Manchon, A.; Linares, R.; Prados-Frutos, J.C.; Hernandez, G.; Lopez Cabarcos, E. Platelet-rich plasma may prevent titanium-mesh exposure in alveolar ridge augmentation with anorganic bovine bone. *J. Clin. Periodontol.* **2010**, *37*, 943–951.
149. Tinti, C.; Parma-Benfenati, S.; Polizzi, G. Vertical ridge augmentation: What is the limit? *Int. J. Periodontics Restor. Dent.* **1996**, *16*, 220–229.
150. Enislidis, G.; Fock, N.; Millesi-Schobel, G.; Klug, C.; Wittwer, G.; Yerit, K.; Ewers, R. Analysis of complications following alveolar distraction osteogenesis and implant placement in the partially edentulous mandible. *Oral Surg. Oral Med. Oral Pathol. Oral Radiol. Endod.* **2005**, *100*, 25–30.
151. Raghoebar, G.M.; Liem, R.S.; Vissink, A. Vertical distraction of the severely resorbed edentulous mandible: A clinical, histological and electron microscopic study of 10 treated cases. *Clin. Oral Implant. Res.* **2002**, *13*, 558–565.
152. Rakhmatia, Y.D.; Ayukawa, Y.; Furuhashi, A.; Koyano, K. Current barrier membranes: Titanium mesh and other membranes for guided bone regeneration in dental applications. *J. Prosthodont. Res.* **2013**, *57*, 3–14.



153. Kent, J.N. Reconstruction of the alveolar ridge with hydroxyapatite. *Dent. Clin. North Am.* **1986**, *30*, 231–257.
154. Kent, J.N.; Quinn, J.H.; Zide, M.F.; Finger, I.M.; Jarcho, M.; Rothstein, S.S. Correction of alveolar ridge deficiencies with nonresorbable hydroxylapatite. *J. Am. Dent. Assoc.* **1982**, *105*, 993–1001.
155. Kent, J.N.; Quinn, J.H.; Zide, M.F.; Guerra, L.R.; Boyne, P.J. Alveolar ridge augmentation using nonresorbable hydroxylapatite with or without autogenous cancellous bone. *J. Oral Maxillofac. Surg.* **1983**, *41*, 629–642.
156. Smiler, D.; Soltan, M.; Lee, J.W. A histomorphogenic analysis of bone grafts augmented with adult stem cells. *Implant Dent.* **2007**, *16*, 42–53.
157. Rothstein, S.S.; Paris, D.A.; Zacek, M.P. Use of hydroxylapatite for the augmentation of deficient alveolar ridges. *J. Oral Maxillofac. Surg.* **1984**, *42*, 224–230.
158. Hasson, O. Augmentation of deficient lateral alveolar ridge using the subperiosteal tunneling dissection approach. *Oral Surg. Oral Med. Oral Pathol. Oral Radiol. Endod.* **2007**, *103*, e14–e19.
159. Mehlich, D.R.; Taylor, T.D.; Leibold, D.G.; Hiatt, R.; Waite, D.E.; Waite, P.D.; Laskin, D.M.; Smith, S.T. Collagen/hydroxylapatite implant for augmenting deficient alveolar ridges: Twelve-month clinical data. *J. Oral Maxillofac. Surg.* **1988**, *46*, 839–843.
160. Williams, C.W.; Meyers, J.F.; Robinson, R.R. Hydroxyapatite augmentation of the anterior portion of the maxilla with a modified transpositional flap technique. *Oral Surg. Oral Med. Oral Pathol.* **1991**, *72*, 395–399.
161. Marshall, S.G. The combined use of endosseous dental implants and collagen/hydroxylapatite augmentation procedures for reconstruction/augmentation of the edentulous and atrophic mandible: A preliminary report. *Oral Surg. Oral Med. Oral Pathol.* **1989**, *68*, 517–525; discussion 525–526.
162. Kfir, E.; Kfir, V.; Eliav, E.; Kaluski, E. Minimally invasive guided bone regeneration. *J. Oral Implantol.* **2007**, *33*, 205–210.
163. Mazzocco, C.; Buda, S.; De Paoli, S. The tunnel technique: A different approach to block grafting procedures. *Int. J. Periodontics Restor. Dent.* **2008**, *28*, 45–53.
164. Li, J.; Xuan, F.; Choi, B.H.; Jeong, S.M. Minimally invasive ridge augmentation using xenogenous bone blocks in an atrophied posterior mandible: A clinical and histological study. *Implant Dent.* **2013**, *22*, 112–116.
165. Vanassche, B.J.; Stoelinga, P.J.; de Koomen, H.A.; Blijdorp, P.A.; Schoenaers, J.H. Reconstruction of the severely resorbed mandible with interposed bone grafts and hydroxylapatite. A 2–3 year follow-up. *Int. J. Oral Maxillofac. Surg.* **1988**, *17*, 157–160.
166. Block, M.S. Horizontal ridge augmentation using particulate bone. *Atlas Oral Maxillofac. Surg. Clin. North Am.* **2006**, *14*, 27–38.
167. Block, M.S.; Degen, M. Horizontal ridge augmentation using human mineralized particulate bone: Preliminary results. *J. Oral Maxillofac. Surg.* **2004**, *62*, 67–72.
168. Kuemmerle, J.M.; Oberle, A.; Oechslin, C.; Bohner, M.; Frei, C.; Boecken, I.; von Rechenberg, B. Assessment of the suitability of a new brushite calcium phosphate cement for cranioplasty—An experimental study in sheep. *J. Cranio Maxillofac. Surg.* **2005**, *33*, 37–44.
169. Frayssinet, P.; Gineste, L.; Conte, P.; Fages, J.; Rouquet, N. Short-term implantation effects of a DCPD-based calcium phosphate cement. *Biomaterials* **1998**, *19*, 971–977.



170. Apelt, D.; Theiss, F.; El-Warrak, A.O.; Zlinszky, K.; Bettschart-Wolfisberger, R.; Bohner, M.; Matter, S.; Auer, J.A.; von Rechenberg, B. *In vivo* behavior of three different injectable hydraulic calcium phosphate cements. *Biomaterials* **2004**, *25*, 1439–1451.
171. Flautre, B.; Lemaitre, J.; Maynou, C.; Van Landuyt, P.; Hardouin, P. Influence of polymeric additives on the biological properties of brushite cements: An experimental study in rabbit. *J. Biomed. Mater. Res. Part A* **2003**, *66A*, 214–223.
172. Flautre, B.; Maynou, C.; Lemaitre, J.; van Landuyt, P.; Hardouin, P. Bone colonization of beta-TCP granules incorporated in brushite cements. *J. Biomed. Mater. Res.* **2002**, *63*, 413–417.
173. Flautre, B.; Delecourt, C.; Blary, M.C.; van Landuyt, P.; Lemaitre, J.; Hardouin, P. Volume effect on biological properties of a calcium phosphate hydraulic cement: Experimental study in sheep. *Bone* **1999**, *25*, 35S–39S.
174. Lu, J.X.; About, I.; Stephan, G.; Van Landuyt, P.; Dejou, J.; Fiocchi, M.; Lemaitre, J.; Proust, J.P. Histological and biomechanical studies of two bone colonizable cements in rabbits. *Bone* **1999**, *25*, 41S–45S.
175. Penel, G.; Leroy, N.; Van Landuyt, P.; Flautre, B.; Hardouin, P.; Lemaitre, J.; Leroy, G. Raman microspectrometry studies of brushite cement: *In vivo* evolution in a sheep model. *Bone* **1999**, *25*, 81S–84S.
176. Ohura, K.; Bohner, M.; Hardouin, P.; Lemaitre, J.; Pasquier, G.; Flautre, B. Resorption of, and bone formation from, new beta-tricalcium phosphate-monocalcium phosphate cements: An *in vivo* study. *J. Biomed. Mater. Res.* **1996**, *30*, 193–200.
177. Munting, E.; Mirtchi, A.A.; Lemaitre, J. Bone repair of defects filled with phosphoclastic hydraulic cement—An *in vitro* study. *J. Mater. Sci. Mater. Med.* **1993**, *4*, 337–344.
178. Hallman, M.; Thor, A. Bone substitutes and growth factors as an alternative/complement to autogenous bone for grafting in implant dentistry. *Periodontology 2000* **2008**, *47*, 172–192.
179. Botticelli, D.; Berglundh, T.; Buser, D.; Lindhe, J. The jumping distance revisited: An experimental study in the dog. *Clin. Oral Implant. Res.* **2003**, *14*, 35–42.
180. Wilson, T.G., Jr.; Schenk, R.; Buser, D.; Cochran, D. Implants placed in immediate extraction sites: A report of histologic and histometric analyses of human biopsies. *Int. J. Oral Maxillofac. Implant.* **1998**, *13*, 333–341.
181. Yukna, R.A. Clinical comparison of hydroxyapatite-coated titanium dental implants placed in fresh extraction sockets and healed sites. *J. Periodontol.* **1991**, *62*, 468–472.
182. Cypher, T.J.; Grossman, J.P. Biological principles of bone graft healing. *J. Foot Ankle Surg.* **1996**, *35*, 413–417.
183. Younger, E.M.; Chapman, M.W. Morbidity at bone graft donor sites. *J. Orthop. Trauma* **1989**, *3*, 192–195.
184. Dodd, C.A.; Fergusson, C.M.; Freedman, L.; Houghton, G.R.; Thomas, D. Allograft vs. autograft bone in scoliosis surgery. *J. Bone Joint Surg. Br.* **1988**, *70*, 431–434.
185. Summers, B.N.; Eisenstein, S.M. Donor site pain from the ilium. A complication of lumbar spine fusion. *J. Bone Joint Surg. Br.* **1989**, *71*, 677–680.
186. Arrington, E.D.; Smith, W.J.; Chambers, H.G.; Bucknell, A.L.; Davino, N.A. Complications of iliac crest bone graft harvesting. *Clin. Orthop. Relat. Res.* **1996**, 300–309.



187. Sandhu, H.S.; Grewal, H.S.; Parvataneni, H. Bone grafting for spinal fusion. *Orthop. Clin. N. Am.* **1999**, *30*, 685–698.
188. Khoury, F. Augmentation of the sinus floor with mandibular bone block and simultaneous implantation: A 6-year clinical investigation. *Int. J. Oral Maxillofac. Implant.* **1999**, *14*, 557–564.
189. Nkenke, E.; Weisbach, V.; Winckler, E.; Kessler, P.; Schultze-Mosgau, S.; Wiltfang, J.; Neukam, F.W. Morbidity of harvesting of bone grafts from the iliac crest for preprosthetic augmentation procedures: A prospective study. *Int. J. Oral Maxillofac. Surg.* **2004**, *33*, 157–163.
190. Wilk, R.M. Bony reconstruction of the jaws. In *Peterson's Principles of Oral and Maxillofacial Surgery*, 2nd ed.; Miloro, M., Ed. B C Decker Inc.: Hamilton, ON, Canada, 2004; pp. 785–787.
191. Rocchietta, I.; Simion, M.; Hoffmann, M.; Trisciuglio, D.; Benigni, M.; Dahlin, C. Vertical bone augmentation with an autogenous block or particles in combination with guided bone regeneration: A clinical and histological preliminary study in humans. *Clin. Implan. Dent. Relat. Res.* **2015**, in press.
192. Merli, M.; Migani, M.; Esposito, M. Vertical ridge augmentation with autogenous bone grafts: Resorbable barriers supported by osteosynthesis plates vs. titanium-reinforced barriers. A preliminary report of a blinded, randomized controlled clinical trial. *Int. J. Oral Maxillofac. Implant.* **2007**, *22*, 373–382.
193. Boyce, T.; Edwards, J.; Scarborough, N. Allograft bone. The influence of processing on safety and performance. *Orthop. Clin. North Am.* **1999**, *30*, 571–581.
194. Tomford, W.W. Transmission of disease through transplantation of musculoskeletal allografts. *J. Bone Joint Surg. Am.* **1995**, *77*, 1742–1754.
195. Centers for Disease Control and Prevention (CDC). Update: Allograft-associated bacterial infections—United States, 2002. *MMWR Morb. Mortal. Wkly. Rep.* **2002**, *51*, 207–210.
196. Centers for Disease Control and Prevention (CDC). Septic arthritis following anterior cruciate ligament reconstruction using tendon allografts—Florida and Louisiana, 2000. *MMWR Morb. Mortal. Wkly. Rep.* **2001**, *50*, 1081–1083.
197. Oxlund, H.; Andersen, N.B.; Ortoft, G.; Orskov, H.; Andreassen, T.T. Growth hormone and mild exercise in combination markedly enhance cortical bone formation and strength in old rats. *Endocrinology* **1998**, *139*, 1899–1904.
198. Bolander, M.E.; Balian, G. The use of demineralized bone matrix in the repair of segmental defects. Augmentation with extracted matrix proteins and a comparison with autologous grafts. *J. Bone Joint Surg. Am.* **1986**, *68*, 1264–1274.
199. Araujo, P.P.; Oliveira, K.P.; Montenegro, S.C.; Carreiro, A.F.; Silva, J.S.; Germano, A.R. Block allograft for reconstruction of alveolar bone ridge in implantology: A systematic review. *Implant Dent.* **2013**, *22*, 304–308.
200. Sterio, T.W.; Katancik, J.A.; Blanchard, S.B.; Xenoudi, P.; Mealey, B.L. A prospective, multicenter study of bovine pericardium membrane with cancellous particulate allograft for localized alveolar ridge augmentation. *Int. J. Periodontics Restor. Dent.* **2013**, *33*, 499–507.
201. Cochran, D.L.; Douglas, H.B. Augmentation of osseous tissue around nonsubmerged endosseous dental implants. *Int. J. Periodontics Restor. Dent.* **1993**, *13*, 506–519.
202. Guerrero, J.S.; Al-Jandan, B.A. Allograft for maxillary sinus floor augmentation: A retrospective study of 90 cases. *Implant Dent.* **2012**, *21*, 136–140.



203. Avila, G.; Neiva, R.; Misch, C.E.; Galindo-Moreno, P.; Benavides, E.; Rudek, I.; Wang, H.L. Clinical and histologic outcomes after the use of a novel allograft for maxillary sinus augmentation: A case series. *Implant Dent.* **2010**, *19*, 330–341.
204. Sohn, D.S.; Lee, J.K.; An, K.M.; Shin, H.I. Histomorphometric evaluation of mineralized cancellous allograft in the maxillary sinus augmentation: A 4 case report. *Implant Dent.* **2009**, *18*, 172–181.
205. Smukler, H.; Landi, L.; Setayesh, R. Histomorphometric evaluation of extraction sockets and deficient alveolar ridges treated with allograft and barrier membrane: A pilot study. *Int. J. Oral Maxillofac. Implant.* **1999**, *14*, 407–416.
206. Froum, S.; Cho, S.C.; Rosenberg, E.; Rohrer, M.; Tarnow, D. Histological comparison of healing extraction sockets implanted with bioactive glass or demineralized freeze-dried bone allograft: A pilot study. *J. Periodontol.* **2002**, *73*, 94–102.
207. Wood, R.A.; Mealey, B.L. Histologic comparison of healing after tooth extraction with ridge preservation using mineralized vs. demineralized freeze-dried bone allograft. *J. Periodontol.* **2012**, *83*, 329–336.
208. Beck, T.M.; Mealey, B.L. Histologic analysis of healing after tooth extraction with ridge preservation using mineralized human bone allograft. *J. Periodontol.* **2010**, *81*, 1765–1772.
209. Eskow, A.J.; Mealey, B.L. Evaluation of healing following tooth extraction with ridge preservation using cortical vs. cancellous freeze-dried bone allograft. *J. Periodontol.* **2014**, *85*, 514–524.
210. Borg, T.D.; Mealey, B.L. Histologic healing following tooth extraction with ridge preservation using mineralized freeze dried bone allograft alone vs. a combined mineralized-demineralized freeze dried bone allograft. A randomized controlled clinical trial. *J. Periodontol.* **2014**, *86*, 1–13.
211. Al Ruhaimi, K.A. Bone graft substitutes: A comparative qualitative histologic review of current osteoconductive grafting materials. *Int. J. Oral Maxillofac. Implant.* **2001**, *16*, 105–114.
212. Dias, R.R.; Sehn, F.P.; de Santana Santos, T.; Silva, E.R.; Chaushu, G.; Xavier, S.P. Corticocancellous fresh-frozen allograft bone blocks for augmenting atrophied posterior mandibles in humans. *Clin. Oral Implant. Res.* **2014**, doi: 10.1111/clr.12509.
213. Macedo, L.G.; Mazzucchelli-Cosmo, L.A.; Macedo, N.L.; Monteiro, A.S.; Sendyk, W.R. Fresh-frozen human bone allograft in vertical ridge augmentation: Clinical and tomographic evaluation of bone formation and resorption. *Cell Tissue Bank.* **2012**, *13*, 577–586.
214. Contar, C.M.; Sarot, J.R.; da Costa, M.B.; Bordini, J.; de Lima, A.A.; Alanis, L.R.; Trevilatto, P.C.; Machado, M.A. Fresh-frozen bone allografts in maxillary ridge augmentation: Histologic analysis. *J. Oral Implantol.* **2011**, *37*, 223–231.
215. Contar, C.M.; Sarot, J.R.; Bordini, J., Jr.; Galvao, G.H.; Nicolau, G.V.; Machado, M.A. Maxillary ridge augmentation with fresh-frozen bone allografts. *J. Oral Maxillofac. Surg.* **2009**, *67*, 1280–1285.
216. Shetty, V.; Han, T.J. Alloplastic materials in reconstructive periodontal surgery. *Dent. Clin. North Am.* **1991**, *35*, 521–530.
217. Shah, M.; Lobo Gajiwala, A.; Shah, S.; Dave, D. Comparative study of indigenously prepared and imported, demineralized, freeze-dried, irradiated bone allograft in the treatment of periodontal infrabony defects. *Cell Tissue Bank.* **2014**, doi:10.1007/s10561-014-9481-6.
218. Gurinsky, B.S.; Mills, M.P.; Mellonig, J.T. Clinical evaluation of demineralized freeze-dried bone allograft and enamel matrix derivative vs. enamel matrix derivative alone for the treatment of periodontal osseous defects in humans. *J. Periodontol.* **2004**, *75*, 1309–1318.



219. Turner, D.W.; Mellonig, J.T. Antigenicity of freeze-dried bone allograft in periodontal osseous defects. *J. Period. Res.* **1981**, *16*, 89–99.
220. Pearson, G.E.; Freeman, E. The composite graft: Autogenous cancellous bone and marrow combined with freeze-dried bone allograft in the treatment of periodontal osseous defects. *Ont. Dent.* **1980**, *57*, 10–13.
221. Markou, N.; Pepelassi, E.; Vavouraki, H.; Stamatakis, H.C.; Nikolopoulos, G.; Vrotsos, I.; Tsiklakis, K. Treatment of periodontal endosseous defects with platelet-rich plasma alone or in combination with demineralized freeze-dried bone allograft: A comparative clinical trial. *J. Periodontol.* **2009**, *80*, 1911–1919.
222. Agarwal, A.; Bhattacharya, H.S.; Srikanth, G.; Singh, A. Comparative evaluation of decalcified freeze dried bone allograft with and without local doxycycline in non-contained human periodontal infrabony defects. *J. Indian Soc. Periodontol.* **2013**, *17*, 490–494.
223. Blaggana, V.; Gill, A.S.; Blaggana, A. A clinical and radiological evaluation of the relative efficacy of demineralized freeze-dried bone allograft vs. anorganic bovine bone xenograft in the treatment of human infrabony periodontal defects: A 6 months follow-up study. *J. Indian Soc. Periodontol.* **2014**, *18*, 601–607.
224. Mazor, Z.; Mamidwar, S.; Ricci, J.L.; Tovar, N.M. Bone repair in periodontal defect using a composite of allograft and calcium sulfate (dentogen) and a calcium sulfate barrier. *J. Oral Implantol.* **2011**, *37*, 287–292.
225. Kukreja, B.J.; Dodwad, V.; Kukreja, P.; Ahuja, S.; Mehra, P. A comparative evaluation of platelet-rich plasma in combination with demineralized freeze-dried bone allograft and DFDBA alone in the treatment of periodontal intrabony defects: A clinicoradiographic study. *J. Indian Soc. Periodontol.* **2014**, *18*, 618–623.
226. Friedlaender, G.E.; Strong, D.M.; Sell, K.W. Studies on the antigenicity of bone. I. Freeze-dried and deep-frozen bone allografts in rabbits. *J. Bone Joint Surg. Am.* **1976**, *58*, 854–858.
227. Mellonig, J.T. Freeze-dried bone allografts in periodontal reconstructive surgery. *Dent. Clin. North Am.* **1991**, *35*, 505–520.
228. Quattlebaum, J.B.; Mellonig, J.T.; Hensel, N.F. Antigenicity of freeze-dried cortical bone allograft in human periodontal osseous defects. *J. Periodontol.* **1988**, *59*, 394–397.
229. Committee on Research, Science. Tissue banking of bone allografts used in periodontal regeneration. *J. Periodontol.* **2001**, *72*, 834–838.
230. Mellonig, J.T. Human histologic evaluation of a bovine-derived bone xenograft in the treatment of periodontal osseous defects. *Int. J. Periodontics Restor. Dent.* **2000**, *20*, 19–29.
231. Wallace, S.; Gellin, R. Clinical evaluation of freeze-dried cancellous block allografts for ridge augmentation and implant placement in the maxilla. *Implant Dent.* **2010**, *19*, 272–279.
232. Jacotti, M.; Wang, H.L.; Fu, J.H.; Zamboni, G.; Bernardello, F. Ridge augmentation with mineralized block allografts: Clinical and histological evaluation of 8 cases treated with the 3-dimensional block technique. *Implant Dent.* **2012**, *21*, 444–448.
233. Russell, J.; Scarborough, N.; Chesmell, K. Re: Ability of commercial demineralized freeze-dried bone allograft to induce new bone formation (1996, 67, 918–26). *J. Periodontol.* **1997**, *68*, 804–806.



234. Hopp, S.G.; Dahners, L.E.; Gilbert, J.A. A study of the mechanical strength of long bone defects treated with various bone autograft substitutes: An experimental investigation in the rabbit. *J. Orthop. Res.* **1989**, *7*, 579–584.
235. Urist, M.R.; Chang, J.J.; Lietze, A.; Huo, Y.K.; Brownell, A.G.; DeLange, R.J. Preparation and bioassay of bone morphogenetic protein and polypeptide fragments. *Methods Enzymol.* **1987**, *146*, 294–312.
236. Urist, M.R.; Iwata, H.; Strates, B.S. Bone morphogenetic protein and proteinase in the guinea pig. *Clin. Orthop. Relat. Res.* **1972**, *85*, 275–290.
237. Mellonig, J.T.; Bowers, G.M.; Cotton, W.R. Comparison of bone graft materials. Part II. New bone formation with autografts and allografts: A histological evaluation. *J. Periodontol.* **1981**, *52*, 297–302.
238. Urist, M.R.; Huo, Y.K.; Brownell, A.G.; Hohl, W.M.; Buyske, J.; Lietze, A.; Tempst, P.; Hunkapiller, M.; DeLange, R.J. Purification of bovine bone morphogenetic protein by hydroxyapatite chromatography. *Proc. Natl. Acad. Sci. USA* **1984**, *81*, 371–375.
239. Sampath, T.K.; Muthukumar, N.; Reddi, A.H. Isolation of osteogenin, an extracellular matrix-associated, bone-inductive protein, by heparin affinity chromatography. *Proc. Natl. Acad. Sci. USA* **1987**, *84*, 7109–7113.
240. Shigeyama, Y.; D’Errico, J.A.; Stone, R.; Somerman, M.J. Commercially-prepared allograft material has biological activity *in vitro*. *J. Periodontol.* **1995**, *66*, 478–487.
241. Hauschka, P.V.; Chen, T.L.; Mavrakos, A.E. Polypeptide growth factors in bone matrix. *Ciba Found. Symp.* **1988**, *136*, 207–225.
242. Jergesen, H.E.; Chua, J.; Kao, R.T.; Kaban, L.B. Age effects on bone induction by demineralized bone powder. *Clin. Orthop. Relat. Res.* **1991**, 253–259.
243. Syftestad, G.T.; Urist, M.R. Bone aging. *Clin. Orthop. Relat. Res.* **1982**, *162*, 288–297.
244. Dodson, S.A.; Bernard, G.W.; Kenney, E.B.; Carranza, F.A. *In vitro* comparison of aged and young osteogenic and hemopoietic bone marrow stem cells and their derivative colonies. *J. Periodontol.* **1996**, *67*, 184–196.
245. Scarano, A.; Degidi, M.; Iezzi, G.; Pecora, G.; Piattelli, M.; Orsini, G.; Caputi, S.; Perrotti, V.; Mangano, C.; Piattelli, A. Maxillary sinus augmentation with different biomaterials: A comparative histologic and histomorphometric study in man. *Implant Dent.* **2006**, *15*, 197–207.
246. Scarano, A.; Piattelli, A.; Perrotti, V.; Manzon, L.; Iezzi, G. Maxillary sinus augmentation in humans using cortical porcine bone: A histological and histomorphometrical evaluation after 4 and 6 months. *Clin. Implant Dent. Relat. Res.* **2011**, *13*, 13–18.
247. Becker, W.; Urist, M.R.; Tucker, L.M.; Becker, B.E.; Ochsenschein, C. Human demineralized freeze-dried bone: Inadequate induced bone formation in athymic mice. A preliminary report. *J. Periodontol.* **1995**, *66*, 822–828.
248. Senn, N. Senn on the healing of aseptic bone cavities by implantation of antiseptic decalcified bone. *Ann. Surg.* **1889**, *10*, 352–368.
249. Thaller, S.R.; Hoyt, J.; Borjeson, K.; Dart, A.; Tesluk, H. Reconstruction of calvarial defects with anorganic bovine bone mineral (bio-oss) in a rabbit model. *J. Craniofac. Surg.* **1993**, *4*, 79–84.
250. Wallace, S.S.; Froum, S.J.; Tarnow, D.P. Histologic evaluation of a sinus elevation procedure: A clinical report. *Int. J. Periodontics Restor. Dent.* **1996**, *16*, 46–51.



251. McAllister, B.S.; Margolin, M.D.; Cogan, A.G.; Buck, D.; Hollinger, J.O.; Lynch, S.E. Eighteen-month radiographic and histologic evaluation of sinus grafting with anorganic bovine bone in the chimpanzee. *Int. J. Oral Maxillofac. Implant.* **1999**, *14*, 361–368.
252. Jarcho, M. Calcium phosphate ceramics as hard tissue prosthetics. *Clin. Orthop. Relat. Res.* **1981**, *157*, 259–278.
253. Melcher, A.H.; Dent, H.D. The use of heterogenous anorganic bone as an implant material in oral procedures. *Oral Surg. Oral Med. Oral Pathol.* **1962**, *15*, 996–1000.
254. Emmings, F.G. Chemically modified osseous material for the restoration of bone defects. *J. Periodontol.* **1974**, *45*, 385–390.
255. Sogal, A.; Tofe, A.J. Risk assessment of bovine spongiform encephalopathy transmission through bone graft material derived from bovine bone used for dental applications. *J. Periodontol.* **1999**, *70*, 1053–1063.
256. Wenz, B.; Oesch, B.; Horst, M. Analysis of the risk of transmitting bovine spongiform encephalopathy through bone grafts derived from bovine bone. *Biomaterials* **2001**, *22*, 1599–1606.
257. Zitzmann, N.U.; Naef, R.; Scharer, P. Resorbable vs. nonresorbable membranes in combination with bio-oss for guided bone regeneration. *Int. J. Oral Maxillofac. Implants* **1997**, *12*, 844–852.
258. Yildirim, M.; Spiekermann, H.; Biesterfeld, S.; Edelhoff, D. Maxillary sinus augmentation using xenogenic bone substitute material bio-oss in combination with venous blood. A histologic and histomorphometric study in humans. *Clin. Oral Implant. Res.* **2000**, *11*, 217–229.
259. Thoma, D.S.; Jones, A.; Yamashita, M.; Edmunds, R.; Nevins, M.; Cochran, D.L. Ridge augmentation using recombinant bone morphogenetic protein-2 techniques: An experimental study in the canine. *J. Periodontol.* **2010**, *81*, 1829–1838.
260. Guillemin, G.; Patat, J.L.; Fournie, J.; Chetail, M. The use of coral as a bone graft substitute. *J. Biomed. Mater. Res.* **1987**, *21*, 557–567.
261. Yukna, R.A. Clinical evaluation of coralline calcium carbonate as a bone replacement graft material in human periodontal osseous defects. *J. Periodontol.* **1994**, *65*, 177–185.
262. Piattelli, A.; Podda, G.; Scarano, A. Clinical and histological results in alveolar ridge enlargement using coralline calcium carbonate. *Biomaterials* **1997**, *18*, 623–627.
263. Gao, T.J.; Tuominen, T.K.; Lindholm, T.S.; Kommonen, B.; Lindholm, T.C. Morphological and biomechanical difference in healing in segmental tibial defects implanted with biocoral or tricalcium phosphate cylinders. *Biomaterials* **1997**, *18*, 219–223.
264. Kim, C.K.; Choi, E.J.; Cho, K.S.; Chai, J.K.; Wikesjo, U.M. Periodontal repair in intrabony defects treated with a calcium carbonate implant and guided tissue regeneration. *J. Periodontol.* **1996**, *67*, 1301–1306.
265. Mora, F.; Ouhayoun, J.P. Clinical evaluation of natural coral and porous hydroxyapatite implants in periodontal bone lesions: Results of a 1-year follow-up. *J. Clin. Periodontol.* **1995**, *22*, 877–884.
266. Hench, L.L. Bioactive materials: The potential for tissue regeneration. *J. Biomed. Mater. Res.* **1998**, *41*, 511–518.
267. AlGhamdi, A.S.; Shibly, O.; Ciancio, S.G. Osseous grafting part II: Xenografts and alloplasts for periodontal regeneration—A literature review. *J. Int. Acad. Periodontol.* **2010**, *12*, 39–44.



268. Teng, F.; Zhang, Q.; Wu, M.; Rachana, S.; Ou, G. Clinical use of ridge-splitting combined with ridge expansion osteotomy, sandwich bone augmentation, and simultaneous implantation. *Br. J. Oral Maxillofac. Surg.* **2014**, *52*, 703–708.
269. Saffar, J.L.; Colombier, M.L.; Detienville, R. Bone formation in tricalcium phosphate-filled periodontal intrabony lesions. Histological observations in humans. *J. Periodontol.* **1990**, *61*, 209–216.
270. Schepers, E.; de Clercq, M.; Ducheyne, P.; Kempeneers, R. Bioactive glass particulate material as a filler for bone lesions. *J. Oral Rehabil.* **1991**, *18*, 439–452.
271. Hislop, W.S.; Finlay, P.M.; Moos, K.F. A preliminary study into the uses of anorganic bone in oral and maxillofacial surgery. *Br. J. Oral Maxillofac. Surg.* **1993**, *31*, 149–153.
272. Pallesen, L.; Schou, S.; Aaboe, M.; Hjorting-Hansen, E.; Nattestad, A.; Melsen, F. Influence of particle size of autogenous bone grafts on the early stages of bone regeneration: A histologic and stereologic study in rabbit calvarium. *Int. J. Oral Maxillofac. Implant.* **2002**, *17*, 498–506.
273. Tamimi, F.; Sheikh, Z.; Barralet, J. Dicalcium phosphate cements: Brushite and monetite. *Acta Biomater.* **2012**, *8*, 474–487.
274. Hashimoto-Uoshima, M.; Ishikawa, I.; Kinoshita, A.; Weng, H.T.; Oda, S. Clinical and histologic observation of replacement of biphasic calcium phosphate by bone tissue in monkeys. *Int. J. Periodontics Restor. Dent.* **1995**, *15*, 205–213.
275. Strub, J.R.; Gaberthuel, T.W.; Firestone, A.R. Comparison of tricalcium phosphate and frozen allogenic bone implants in man. *J. Periodontol.* **1979**, *50*, 624–629.
276. Amler, M.H. Osteogenic potential of nonvital tissues and synthetic implant materials. *J. Periodontol.* **1987**, *58*, 758–761.
277. Baldock, W.T.; Hutchens, L.H., Jr.; McFall, W.T., Jr.; Simpson, D.M. An evaluation of tricalcium phosphate implants in human periodontal osseous defects of two patients. *J. Periodontol.* **1985**, *56*, 1–7.
278. Shalash, M.A.; Rahman, H.A.; Azim, A.A.; Neemat, A.H.; Hawary, H.E.; Nasry, S.A. Evaluation of horizontal ridge augmentation using beta tricalcium phosphate and demineralized bone matrix: A comparative study. *J. Clin. Exp. Dent.* **2013**, *5*, e253–e259.
279. Wang, S.; Zhang, Z.; Zhao, J.; Zhang, X.; Sun, X.; Xia, L.; Chang, Q.; Ye, D.; Jiang, X. Vertical alveolar ridge augmentation with beta-tricalcium phosphate and autologous osteoblasts in canine mandible. *Biomaterials* **2009**, *30*, 2489–2498.
280. Nyan, M.; Miyahara, T.; Noritake, K.; Hao, J.; Rodriguez, R.; Kasugai, S. Feasibility of alpha tricalcium phosphate for vertical bone augmentation. *J. Investig. Clin. Dent.* **2014**, *5*, 109–116.
281. Klein, C.P.; Driessen, A.A.; de Groot, K.; van den Hooff, A. Biodegradation behavior of various calcium phosphate materials in bone tissue. *J. Biomed. Mater. Res.* **1983**, *17*, 769–784.
282. Rabalais, M.L., Jr.; Yukna, R.A.; Mayer, E.T. Evaluation of durapatite ceramic as an alloplastic implant in periodontal osseous defects. I. Initial six-month results. *J. Periodontol.* **1981**, *52*, 680–689.
283. Meffert, R.M.; Thomas, J.R.; Hamilton, K.M.; Brownstein, C.N. Hydroxylapatite as an alloplastic graft in the treatment of human periodontal osseous defects. *J. Periodontol.* **1985**, *56*, 63–73.
284. Wagner, J.R. Clinical and histological case study using resorbable hydroxylapatite for the repair of osseous defects prior to endosseous implant surgery. *J. Oral Implantol.* **1989**, *15*, 186–192.



285. Ricci, J.L.; Blumenthal, N.C.; Spivak, J.M.; Alexander, H. Evaluation of a low-temperature calcium phosphate particulate implant material: Physical-chemical properties and *in vivo* bone response. *J. Oral Maxillofac. Surg.* **1992**, *50*, 969–978.
286. Heughebaert, M.; LeGeros, R.Z.; Gineste, M.; Guilhem, A.; Bonel, G. Physicochemical characterization of deposits associated with ha ceramics implanted in nonosseous sites. *J. Biomed. Mater. Res.* **1988**, *22*, 257–268.
287. Yamasaki, H. Heterotopic bone formation around porous hydroxyapatite ceramic in the subcutis of dogs. *Jpn. J. Oral Biol.* **1990**, *32*, 190–192.
288. Sugar, A.W.; Thielens, P.; Stafford, G.D.; Willins, M.J. Augmentation of the atrophic maxillary alveolar ridge with hydroxyapatite granules in a vicryl (polyglactin 910) knitted tube and simultaneous open vestibuloplasty. *Br. J. Oral Maxillofac. Surg.* **1995**, *33*, 93–97.
289. Frame, J.W. A convenient animal model for testing bone substitute materials. *J. Oral Surg.* **1980**, *38*, 176–180.
290. Small, S.A.; Zinner, I.D.; Panno, F.V.; Shapiro, H.J.; Stein, J.I. Augmenting the maxillary sinus for implants: Report of 27 patients. *Int. J. Oral Maxillofac. Implant.* **1993**, *8*, 523–528.
291. Hurzeler, M.B.; Kirsch, A.; Ackermann, K.L.; Quinones, C.R. Reconstruction of the severely resorbed maxilla with dental implants in the augmented maxillary sinus: A 5-year clinical investigation. *Int. J. Oral Maxillofac. Implant.* **1996**, *11*, 466–475.
292. Frame, J.W. Hydroxyapatite as a biomaterial for alveolar ridge augmentation. *Int. J. Oral Maxillofac. Surg.* **1987**, *16*, 642–655.
293. Jensen, O.T.; Shulman, L.B.; Block, M.S.; Iacono, V.J. Report of the sinus consensus conference of 1996. *Int. J. Oral Maxillofac. Implant.* **1998**, *13*, 11–45.
294. Figliuzzi, M.; Mangano, F.G.; Fortunato, L.; De Fazio, R.; Macchi, A.; Iezzi, G.; Piattelli, A.; Mangano, C. Vertical ridge augmentation of the atrophic posterior mandible with custom-made, computer-aided design/computer-aided manufacturing porous hydroxyapatite scaffolds. *J. Craniofac. Surg.* **2013**, *24*, 856–859.
295. Petrovic, V.; Zivkovic, P.; Petrovic, D.; Stefanovic, V. Craniofacial bone tissue engineering. *Oral Surg. Oral Med. Oral Pathol. Oral Radiol.* **2012**, *114*, e1–e9.
296. Hall, E.E.; Meffert, R.M.; Hermann, J.S.; Mellonig, J.T.; Cochran, D.L. Comparison of bioactive glass to demineralized freeze-dried bone allograft in the treatment of intrabony defects around implants in the canine mandible. *J. Periodontol.* **1999**, *70*, 526–535.
297. Schepers, E.J.; Ducheyne, P.; Barbier, L.; Schepers, S. Bioactive glass particles of narrow size range: A new material for the repair of bone defects. *Implant Dent.* **1993**, *2*, 151–156.
298. MacNeill, S.R.; Cobb, C.M.; Rapley, J.W.; Glaros, A.G.; Spencer, P. In vivo comparison of synthetic osseous graft materials. A preliminary study. *J. Clin. Periodontol.* **1999**, *26*, 239–245.
299. Wilson, J.; Clark, A.E.; Hall, M.; Hench, L.L. Tissue response to bioglass endosseous ridge maintenance implants. *J. Oral Implantol.* **1993**, *19*, 295–302.
300. Stanley, H.R.; Hall, M.B.; Clark, A.E.; King, C.J., 3rd; Hench, L.L.; Berte, J.J. Using 45s5 bioglass cones as endosseous ridge maintenance implants to prevent alveolar ridge resorption: A 5-year evaluation. *Int. J. Oral Maxillofac. Implant.* **1997**, *12*, 95–105.



301. Ong, M.M.; Eber, R.M.; Korsnes, M.I.; MacNeil, R.L.; Glickman, G.N.; Shyr, Y.; Wang, H.L. Evaluation of a bioactive glass alloplast in treating periodontal intrabony defects. *J. Periodontol.* **1998**, *69*, 1346–1354.
302. Wang, S.A.; Chen, A.Y.; Yu, Z.E.; Huang, Z.J.; Wao, Y.M. Alveolar ridge augmentation with bioactive glass ceramics: A histological study. *J. Oral Rehabil.* **1989**, *16*, 229–239.
303. Stavropoulos, A.; Sima, C.; Sima, A.; Nyengaard, J.; Karring, T.; Sculean, A. Histological evaluation of healing after transalveolar maxillary sinus augmentation with bioglass and autogenous bone. *Clin. Oral Implant. Res.* **2012**, *23*, 125–131.
304. Maria, S.M.; Prukner, C.; Sheikh, Z.; Mueller, F.; Barralet, J.E.; Komarova, S.V. Reproducible quantification of osteoclastic activity: Characterization of a biomimetic calcium phosphate assay. *J. Biomed. Mater. Res. B Appl. Biomater.* **2013**, *102*, 903–912.
305. Gunn, J.M.; Rekola, J.; Hirvonen, J.; Aho, A.J. Comparison of the osteoconductive properties of three particulate bone fillers in a rabbit model: Allograft, calcium carbonate (biocoral(r)) and S53P4 bioactive glass. *Acta Odontol. Scand.* **2013**, *71*, 1238–1242.
306. Tamimi, F.; Torres, J.; Lopez-Cabarcos, E.; Bassett, D.C.; Habibovic, P.; Luceron, E.; Barralet, J.E. Minimally invasive maxillofacial vertical bone augmentation using brushite based cements. *Biomaterials* **2009**, *30*, 208–216.
307. Tamimi, F.; Torres, J.; Bassett, D.; Barralet, J.; Cabarcos, E.L. Resorption of monetite granules in alveolar bone defects in human patients. *Biomaterials* **2010**, *31*, 2762–2769.
308. Bauer, T.W.; Muschler, G.F. Bone graft materials. An overview of the basic science. *Clin. Orthop. Relat. Res.* **2000**, *371*, 10–27.
309. Marino, F.T.; Torres, J.; Tresguerres, I.; Jerez, L.B.; Cabarcos, E.L. Vertical bone augmentation with granulated brushite cement set in glycolic acid. *J. Biomed. Mater. Res. Part A* **2007**, *81*, 93–102.
310. Gehrke, S.A.; Fama, F.G. Buccal dehiscence and sinus lift cases-predictable bone augmentation with synthetic bone material. *Implants* **2010**, *11*, 28–31.
311. Torres, J.; Tamimi, I.; Cabrejos-Azama, J.; Tresguerres, I.; Alkhraisat, M.; López-Cabarcos, E.; Hernández, G.; Tamimi, F. Monetite granules versus particulate autologous bone in bone regeneration. *Ann. Anat. Anat. Anz.* **2015**, *200*, 126–133.
312. Tamimi, F.M.; Torres, J.; Tresguerres, I.; Clemente, C.; Lopez-Cabarcos, E.; Blanco, L.J. Bone augmentation in rabbit calvariae: Comparative study between bio-oss(r) and a novel beta-TCP/DCPD granulate. *J. Clin. Periodontol.* **2006**, *33*, 922–928.
313. Bohner, M.; Gbureck, U. Thermal reactions of brushite cements. *J. Biomed. Mater. Res. Part B Appl. Biomater.* **2008**, *84B*, 375–385.
314. Gbureck, U.; Hozel, T.; Klammert, U.; Wurzler, K.; Muller, F.A.; Barralet, J.E. Resorbable dicalcium phosphate bone substitutes prepared by 3d powder printing. *Adv. Funct. Mater.* **2007**, *17*, 3940–3945.
315. Tamimi, F.; Le Nihouannen, D.; Eimar, H.; Sheikh, Z.; Komarova, S.; Barralet, J. The effect of autoclaving on the physical and biological properties of dicalcium phosphate dihydrate bioceramics: Brushite vs. Monetite. *Acta Biomater.* **2012**, *8*, 3161–3169.
316. Idowu, B.; Cama, G.; Deb, S.; di Silvio, L. *In vitro* osteoinductive potential of porous monetite for bone tissue engineering. *J. Tissue Eng.* **2014**, *5*, doi:10.1177/2041731414536572.



317. Tamimi, F.; Torres, J.; Kathan, C.; Baca, R.; Clemente, C.; Blanco, L.; Cabarcos, E.L. Bone regeneration in rabbit calvaria with novel monetite granules. *J. Biomed. Mater. Res. Part A* **2008**, *87A*, 980–985.
318. Rezwani, K.; Chen, Q.; Blaker, J.; Boccaccini, A.R. Biodegradable and bioactive porous polymer/inorganic composite scaffolds for bone tissue engineering. *Biomaterials* **2006**, *27*, 3413–3431.
319. Sabir, M.I.; Xu, X.; Li, L. A review on biodegradable polymeric materials for bone tissue engineering applications. *J. Mater. Sci.* **2009**, *44*, 5713–5724.
320. Liu, X.; Ma, P.X. Polymeric scaffolds for bone tissue engineering. *Ann. Biomed. Eng.* **2004**, *32*, 477–486.
321. Yunos, D.M.; Bretcanu, O.; Boccaccini, A.R. Polymer-bioceramic composites for tissue engineering scaffolds. *J. Mater. Sci.* **2008**, *43*, 4433–4442.
322. Sheikh, Z.; Geffers, M.; Christel, T.; Barralet, J.E.; Gbureck, U. Chelate setting of alkali ion substituted calcium phosphates. *Ceram. Int.* **2015**, in press.
323. Paul, W.; Sharma, C.P. Bioceramic scaffold—Bone tissue engineering. In *Handbook of Intelligent Scaffold for Tissue Engineering and Regenerative Medicine*; Pan Stanford Publishing: Danvers, MA, USA, 2012.
324. Barinov, S.; Komlev, V. *Calcium Phosphate Based Bioceramics for Bone Tissue Engineering*; Trans Tech Publications: Zurich, Switzerland, 2008.
325. Taba, M., Jr.; Jin, Q.; Sugai, J.V.; Giannobile, W.V. Current concepts in periodontal bioengineering. *Orthod. Craniofac. Res.* **2005**, *8*, 292–302.
326. Howell, T.H.; Fiorellini, J.; Jones, A.; Alder, M.; Nummikoski, P.; Lazaro, M.; Lilly, L.; Cochran, D. A feasibility study evaluating rhBMP-2/absorbable collagen sponge device for local alveolar ridge preservation or augmentation. *Int. J. Periodontics Restor. Dent.* **1997**, *17*, 124–139.
327. Margolin, M.D.; Cogan, A.G.; Taylor, M.; Buck, D.; McAllister, T.N.; Toth, C.; McAllister, B.S. Maxillary sinus augmentation in the non-human primate: A comparative radiographic and histologic study between recombinant human osteogenic protein-1 and natural bone mineral. *J. Periodontol.* **1998**, *69*, 911–919.
328. Becker, W.; Becker, B.E.; Caffesse, R. A comparison of demineralized freeze-dried bone and autologous bone to induce bone formation in human extraction sockets. *J. Periodontol.* **1994**, *65*, 1128–1133.
329. Boyne, P.J.; Nath, R.; Nakamura, A. Human recombinant BMP-2 in osseous reconstruction of simulated cleft palate defects. *Br. J. Oral Maxillofac. Surg.* **1998**, *36*, 84–90.
330. Schmitt, J.M.; Hwang, K.; Winn, S.R.; Hollinger, J.O. Bone morphogenetic proteins: An update on basic biology and clinical relevance. *J. Orthop. Res.* **1999**, *17*, 269–278.
331. Urist, M.R. Bone: Formation by autoinduction. *Science* **1965**, *150*, 893–899.
332. Edmunds, R.K.; Mealey, B.L.; Mills, M.P.; Thoma, D.S.; Schoolfield, J.; Cochran, D.L.; Mellonig, J. Maxillary anterior ridge augmentation with recombinant human bone morphogenetic protein 2. *Int. J. Periodontics Restor. Dent.* **2014**, *34*, 551–557.
333. Katanec, D.; Granic, M.; Majstorovic, M.; Trampus, Z.; Panduric, D.G. Use of recombinant human bone morphogenetic protein (rhBMP2) in bilateral alveolar ridge augmentation: Case report. *Coll. Antropol.* **2014**, *38*, 325–330.



334. Kim, Y.J.; Lee, J.Y.; Kim, J.E.; Park, J.C.; Shin, S.W.; Cho, K.S. Ridge preservation using demineralized bone matrix gel with recombinant human bone morphogenetic protein-2 after tooth extraction: A randomized controlled clinical trial. *J. Oral Maxillofac. Surg.* **2014**, *72*, 1281–1290.
335. Sheikh, Z.; Javaid, M.A.; Hamdan, N.; Hashmi, R. Bone regeneration using bone morphogenetic proteins and various biomaterial carriers. *Materials* **2015**, *8*, 1778–1816.
336. Shweikeh, F.; Hanna, G.; Bloom, L.; Sayegh, E.T.; Liu, J.; Acosta, F.L.; Drazin, D. Assessment of outcome following the use of recombinant human bone morphogenetic protein-2 for spinal fusion in the elderly population. *J. Neurosurg. Sci.* **2014**, in press.
337. Zhang, H.; Wang, F.; Ding, L.; Zhang, Z.; Sun, D.; Feng, X.; An, J.; Zhu, Y. A meta analysis of lumbar spinal fusion surgery using bone morphogenetic proteins and autologous iliac crest bone graft. *PLoS ONE* **2014**, *9*, doi:10.1371/journal.pone.0097049.
338. Myllyla, R.M.; Haapasaari, K.M.; Lehenkari, P.; Tuukkanen, J. Bone morphogenetic proteins 4 and 2/7 induce osteogenic differentiation of mouse skin derived fibroblast and dermal papilla cells. *Cell Tissue Res.* **2014**, *355*, 463–470.
339. Hu, W.; Ye, Y.; Wang, J.; Zhang, W.; Chen, A.; Guo, F. Bone morphogenetic proteins induce rabbit bone marrow-derived mesenchyme stem cells to differentiate into osteoblasts via BMP signals pathway. *Artif. Cells Nanomed. Biotechnol.* **2013**, *41*, 249–254.
340. Saito, E.; Saito, A.; Kawanami, M. Favorable healing following space creation in rhBMP-2-induced periodontal regeneration of horizontal circumferential defects in dogs with experimental periodontitis. *J. Periodontol.* **2003**, *74*, 1808–1815.
341. Wikesjo, U.M.; Xiropaidis, A.V.; Thomson, R.C.; Cook, A.D.; Selvig, K.A.; Hardwick, W.R. Periodontal repair in dogs: rhBMP-2 significantly enhances bone formation under provisions for guided tissue regeneration. *J. Clin. Periodontol.* **2003**, *30*, 705–714.
342. Chen, D.; Zhao, M.; Mundy, G.R. Bone morphogenetic proteins. *Growth Fact.* **2004**, *22*, 233–241.
343. Turgeman, G.; Zilberman, Y.; Zhou, S.; Kelly, P.; Moutsatsos, I.K.; Kharode, Y.P.; Borella, L.E.; Bex, F.J.; Komm, B.S.; Bodine, P.V. Systemically administered rhBMP-2 promotes MSC activity and reverses bone and cartilage loss in osteopenic mice. *J. Cell. Biochem.* **2002**, *86*, 461–474.
344. Marden, L.J.; Hollinger, J.O.; Chaudhari, A.; Turek, T.; Schaub, R.G.; Ron, E. Recombinant human bone morphogenetic protein-2 is superior to demineralized bone matrix in repairing craniotomy defects in rats. *J. Biomed. Mater. Res.* **1994**, *28*, 1127–1138.
345. Kirker-Head, C.A.; Gerhart, T.N.; Schelling, S.H.; Hennig, G.E.; Wang, E.; Holtrop, M.E. Long-term healing of bone using recombinant human bone morphogenetic protein 2. *Clin. Orthop. Relat. R.* **1995**, *318*, 222–230.
346. Toriumi, D.M.; Kotler, H.S.; Luxenberg, D.P.; Holtrop, M.E.; Wang, E.A. Mandibular reconstruction with a recombinant bone-inducing factor: Functional, histologic, and biomechanical evaluation. *Arch. Otolaryngol. Head Neck Surg.* **1991**, *117*, 1101–1112.
347. Agnihotri, S.A.; Mallikarjuna, N.N.; Aminabhavi, T.M. Recent advances on chitosan-based micro-and nanoparticles in drug delivery. *J. Control. Release* **2004**, *100*, 5–28.
348. Panyam, J.; Labhasetwar, V. Biodegradable nanoparticles for drug and gene delivery to cells and tissue. *Adv. Drug Deliv. Rev.* **2003**, *55*, 329–347.



349. Farokhzad, O.C.; Langer, R. Impact of nanotechnology on drug delivery. *ACS Nano* **2009**, *3*, 16–20.
350. Pridgen, E.M.; Alexis, F.; Farokhzad, O.C. Polymeric nanoparticle drug delivery technologies for oral delivery applications. *Expert Opin. Drug Deliv.* **2015**, 1–15.
351. Martino, M.M.; Briquez, P.S.; Maruyama, K.; Hubbell, J.A. Extracellular matrix-inspired growth factor delivery systems for bone regeneration. *Adv. Drug Deliv. Rev.* **2015**, in press.
352. Hu, Y.-L.; Fu, Y.-H.; Tabata, Y.; Gao, J.-Q. Mesenchymal stem cells: A promising targeted-delivery vehicle in cancer gene therapy. *J. Control. Release* **2010**, *147*, 154–162.
353. Caplan, A.I. Review: Mesenchymal stem cells: Cell-based reconstructive therapy in orthopedics. *Tissue Eng.* **2005**, *11*, 1198–1211.
354. Bessa, P.C.; Casal, M.; Reis, R. Bone morphogenetic proteins in tissue engineering: The road from laboratory to clinic, part II (bmp delivery). *J. Tissue Eng. Regen. Med.* **2008**, *2*, 81–96.
355. Kenley, R.; Marden, L.; Turek, T.; Jin, L.; Ron, E.; Hollinger, J. Osseous regeneration in the rat calvarium using novel delivery systems for recombinant human bone morphogenetic protein-2 (rhBMP-). *J. Biomed. Mater. Res.* **1994**, *28*, 1139–1147.
356. Lee, S.; Shea, M.; Battle, M.; Kozitza, K.; Ron, E.; Turek, T.; Schaub, R.; Hayes, W. Healing of large segmental defects in rat femurs is aided by rhBMP-2 in PLGA matrix. *J. Biomed. Mater. Res.* **1994**, *28*, 1149–1156.
357. Schrier, J.A.; Fink, B.F.; Rodgers, J.B.; Vasconez, H.C.; DeLuca, P.P. Effect of a freeze-dried CMC/PLGA microsphere matrix of rhBMP-2 on bone healing. *AAPS PharmSciTech* **2001**, *2*, 73–80.
358. Becker, W.; Lynch, S.E.; Lekholm, U.; Becker, B.E.; Caffesse, R.; Donath, K.; Sanchez, R. A comparison of ePTFE membranes alone or in combination with platelet-derived growth factors and insulin-like growth factor-I or demineralized freeze-dried bone in promoting bone formation around immediate extraction socket implants. *J. Periodontol.* **1992**, *63*, 929–940.
359. Simion, M.; Rocchietta, I.; Kim, D.; Nevins, M.; Fiorellini, J. Vertical ridge augmentation by means of deproteinized bovine bone block and recombinant human platelet-derived growth factor-bb: A histologic study in a dog model. *Int. J. Periodontics Restor. Dent.* **2006**, *26*, 415–423.
360. Tsuchiya, N.; Sato, S.; Kigami, R.; Kawano, E.; Takane, M.; Arai, Y.; Ito, K.; Ogiso, B. Effect of a chitosan sponge impregnated with platelet-derived growth factor on bone augmentation beyond the skeletal envelope in rat calvaria. *J. Oral Sci.* **2014**, *56*, 23–28.
361. Kammerer, P.W.; Palarie, V.; Schiegnitz, E.; Nacu, V.; Draenert, F.G.; Al-Nawas, B. Influence of a collagen membrane and recombinant platelet-derived growth factor on vertical bone augmentation in implant-fixed deproteinized bovine bone—Animal pilot study. *Clin. Oral Implants Res.* **2013**, *24*, 1222–1230.
362. Marx, R.E.; Carlson, E.R.; Eichstaedt, R.M.; Schimmele, S.R.; Strauss, J.E.; Georgeff, K.R. Platelet-rich plasma: Growth factor enhancement for bone grafts. *Oral Surg. Oral Med. Oral Pathol. Oral Radiol. Endod.* **1998**, *85*, 638–646.
363. Eskin, M.A.; Greenwell, H.; Hill, M.; Morton, D.; Vidal, R.; Shumway, B.; Girouard, M.E. Platelet-rich plasma-assisted guided bone regeneration for ridge augmentation: A randomized, controlled clinical trial. *J. Periodontol.* **2014**, *85*, 661–668.



364. Khairy, N.M.; Shendy, E.E.; Askar, N.A.; El-Rouby, D.H. Effect of platelet rich plasma on bone regeneration in maxillary sinus augmentation (randomized clinical trial). *Int. J. Oral Maxillofac. Surg.* **2013**, *42*, 249–255.
365. Cabbar, F.; Guler, N.; Kurkcu, M.; Iseri, U.; Sencift, K. The effect of bovine bone graft with or without platelet-rich plasma on maxillary sinus floor augmentation. *J. Oral Maxillofac. Surg.* **2011**, *69*, 2537–2547.
366. Annunziata, M.; Oliva, A.; Buonaiuto, C.; Di Feo, A.; Di Pasquale, R.; Passaro, I.; Guida, L. *In vitro* cell-type specific biological response of human periodontally related cells to platelet-rich plasma. *J. Period. Res.* **2005**, *40*, 489–495.
367. Hanna, R.; Trejo, P.M.; Weltman, R.L. Treatment of intrabony defects with bovine-derived xenograft alone and in combination with platelet-rich plasma: A randomized clinical trial. *J. Periodontol.* **2004**, *75*, 1668–1677.
368. Sanchez, A.R.; Sheridan, P.J.; Kupp, L.I. Is platelet-rich plasma the perfect enhancement factor? A current review. *Int. J. Oral Maxillofac. Implant.* **2003**, *18*, 93–103.
369. Wallace, S.S.; Froum, S.J. Effect of maxillary sinus augmentation on the survival of endosseous dental implants. A systematic review. *Ann. Periodontol. Am. Acad. Periodontol.* **2003**, *8*, 328–343.
370. Breitbart, A.S.; Grande, D.A.; Mason, J.M.; Barcia, M.; James, T.; Grant, R.T. Gene-enhanced tissue engineering: Applications for bone healing using cultured periosteal cells transduced retrovirally with the BMP-7 gene. *Ann. Plast. Surg.* **1999**, *42*, 488–495.
371. Lieberman, J.R.; Daluiski, A.; Stevenson, S.; Wu, L.; McAllister, P.; Lee, Y.P.; Kabo, J.M.; Finerman, G.A.; Berk, A.J.; Witte, O.N. The effect of regional gene therapy with bone morphogenetic protein-2-producing bone-marrow cells on the repair of segmental femoral defects in rats. *J. Bone Joint Surg. Am.* **1999**, *81*, 905–917.
372. Malekzadeh, R.; Hollinger, J.O.; Buck, D.; Adams, D.F.; McAllister, B.S. Isolation of human osteoblast-like cells and *in vitro* amplification for tissue engineering. *J. Periodontol.* **1998**, *69*, 1256–1262.
373. Freed, L.E.; Marquis, J.C.; Nohria, A.; Emmanuel, J.; Mikos, A.G.; Langer, R. Neocartilage formation *in vitro* and *in vivo* using cells cultured on synthetic biodegradable polymers. *J. Biomed. Mater. Res.* **1993**, *27*, 11–23.
374. Ishaug, S.L.; Yaszemski, M.J.; Bizios, R.; Mikos, A.G. Osteoblast function on synthetic biodegradable polymers. *J. Biomed. Mater. Res.* **1994**, *28*, 1445–1453.
375. Bruder, S.P.; Kraus, K.H.; Goldberg, V.M.; Kadiyala, S. The effect of implants loaded with autologous mesenchymal stem cells on the healing of canine segmental bone defects. *J. Bone Joint Surg. Am.* **1998**, *80*, 985–996.
376. De Kok, I.J.; Drapeau, S.J.; Young, R.; Cooper, L.F. Evaluation of mesenchymal stem cells following implantation in alveolar sockets: A canine safety study. *Int. J. Oral Maxillofac. Implant.* **2005**, *20*, 511–518.