

# Color Atlas of Oral Diseases

George Laskaris, D. D. S., M. D.

Foreword by Gerald Shklar

Second edition, revised and expanded  
555 illustrations

George Laskaris, D.D.S., M.D.  
 Associate Professor in Oral Medicine and Pathology,  
 Dental School, University of Athens.  
 Consultant in Oral Medicine,  
 Dept. of Dermatology, <<A. Syngros> Hospital,  
 University of Athens.  
 20-22 Ipsilandou St.  
 10676 Athens, Greece

*Library of Congress Cataloging-in-Publication Data*

*Laskaris, George.*  
 [Enchromos atlas stomatologias. English]  
 Color atlas of oral diseases / George Laskaris ; foreword  
 by Gerald Shklar. -- 2nd ed., rev. and expanded.  
 p. cm.  
 Includes bibliographical references and index.  
 ISBN 3-13-717002-8 (G. Thieme Verlag). --  
 ISBN 0-86577-537-0 (Thieme Medical Publishers)  
 1. Mouth--Diseases--Atlases. §. Title.  
 [DNLM: 1. Mouth Diseases--atlases. WU 17 L345e  
 1994]  
 RC815.L3713 1994  
 617.5'22'0222--dc20  
 DNLM/DLC  
 for Library of Congress 94-9767  
 CIP

This atlas is based on the Greek edition:  
 Enchromos Atlas Stomatologias-  
 Color Atlas of Stomatology  
 Copyright © 1986 by George Laskaris, Athens, Greece.  
 Published by Litsas Medical Publications,  
 Athens, Greece

Some of the product names, patents and registered  
 designs referred to in this book are in fact registered  
 trademarks or proprietary names even though specific  
 reference to this fact is not always made in the text.  
 Therefore, the appearance of a name without designa-  
 tion as proprietary is not to be construed as a repre-  
 sentation by the publishers that it is in the public  
 domain.

This book, including all parts thereof, is legally protect-  
 ed by copyright. Any use, exploitation or commercial-  
 ization outside the narrow limits set by copyright legisla-  
 tion, without the publisher's consent, is illegal and liable  
 to prosecution. This applies in particular to photostat  
 reproduction, copying, mimeographing or duplication  
 of any kind, translating, preparation of microfilms, and  
 electronic data processing and storage.

Important Note: Medicine is an ever-changing science.  
 Research and clinical experience are continually broad-  
 ening our knowledge, in particular our knowledge of  
 proper treatment and drug therapy. Insofar as this book  
 mentions any dosage or application, readers may rest  
 assured that the authors, editors and publishers have  
 made every effort to ensure that such references are  
 strictly in accordance with **the state of knowledge at the  
 time** of production of the book. Nevertheless, every  
 user is requested to carefully examine the manufac-  
 turers leaflets accompanying each drug to check on his  
 own responsibility whether the dosage schedules recom-  
 mended therein or the contraindications stated by the  
 manufacturers differ from the statements made in the  
 present book. Such examination is particularly impor-  
 tant with drugs which are either rarely used or have  
 been newly released on the market.

Cover drawing: Renate Stockinger

1st Italian edition 1991  
 1st French edition 1989

©1988,1994 Georg Thieme Verlag, RudigerstraBe 14,  
 70469 Stuttgart, Germany  
 Thieme Medical Publishers, Inc.,  
 381 Park Avenue South, New York, N. Y. 10016

Typesetting by Druckhaus Gotz GmbH,  
 71636 Ludwigsburg  
 (System 5, Linotron 202)  
 Printed in Germany by K. Grammlisch, GmbH

ISBN 3-13-717002-8 (Georg Thieme Verlag, Stuttgart)  
 ISBN 0-86577-537-0 (Thieme Medical Publishers, Inc.,  
 New York)

## Foreword

It is a distinct pleasure to see Dr. George Laskaris' excellent Atlas of Oral Diseases come out in an English edition. Dr. Laskaris' knowledge, background, and wealth of experience in the disciplines of oral medicine and oral pathology have been well known to those of us in the field. His highly respected research on autoimmune diseases of the mouth has appeared in many English language journals, and it is fitting that his extensive experience with oral diseases is now made available to the English-speaking world. This Atlas has impressed even those of us who could not read the

original Greek, by the excellence of the color illustrations and the broad range of diseases covered. The English text now offers a brief but authoritative discussion of each condition.

GERALD SHKLAB, D.D.S., M.S.

Charles A. Brackett Professor of Oral Pathology  
and Head of the Department of Oral Medicine  
and Oral Pathology,  
Harvard School of Dental Medicine,  
Boston, Massachusetts

## Preface to the Second Edition

The second edition of the Color Atlas of Oral Diseases is enlarged and revised to keep pace with current concepts and changes in the field of Oral Medicine. New chapters and illustrations have been included and the text of the first edition has been modified on several occasions.

Two new chapters on HIV infections and AIDS and renal diseases have been added.

Sixty-four illustrations of lesions and clinical entities affecting the oral cavity, not published in the first edition, are now included.

Nineteen new illustrations of diseases published in the first edition have been added to broaden the spectrum of clinical presentation of these entities.

Twenty-three illustrations have been replaced by new, higher quality, more representative ones.

Three hundred and eighty-eight references have been added.

I hope that the revised and enlarged second edition of the Atlas is an improvement, and that it will be as useful as the first edition to all of those who are involved in the field of oral medicine.

Athens, 1994      GEORGE LASKARIS, D.D.S., M.D.

## Preface to the First Edition

Oral medicine is a rapidly growing clinical specialty encompassing the diagnosis and treatment of patients with a wide spectrum of disorders involving the oral cavity.

To achieve the optimum goals, oral medical clinicians have to broaden their knowledge bases and practice their clinical skills.

When I first started to work in this field 20 years ago, I could not imagine the variety of disorders that affect the oral cavity, including genetic diseases, infections, cancers, blood diseases, skin diseases, endocrine and metabolic disorders, autoimmune and rheumatologic diseases, local lesions, to name a few. Fortunately, the oral cavity is accessible to visual examination, and I have attempted to record oral lesions in color slides. During my career as a stomatologist, I have collected more than 25,000 clinical color slides that encompass a broad spectrum of common and rare oral diseases. The most representative and educationally useful illustrations have been used in this Atlas. Almost all color slides have been taken by me with a Nikon-Medical camera.

This book is the distillation of my clinical experience and is intended to aid primarily the practicing dentist, the specialist in oral medicine, the

oral pathologist and surgeon, the dermatologist, and otorhinolaryngologist to solve the diagnostic problems posed by oral diseases. It can also be valuable to dental and medical students, general internists, pediatricians, and other medical specialists.

This book is not a complete reference work of oral medicine and should be used in conjunction with current textbooks and articles regarding recommendations on treatment and new diagnostic techniques that are beyond its scope.

The material of the Atlas is divided into 33 chapters. Each entity is accompanied by color plates and a description of the clinical features, differential diagnosis, helpful laboratory tests, and a brief statement on treatment.

Selective bibliography and index are included.

I hope that the Atlas will serve as a comprehensive pictorial guide for diagnostic problems in the mouth and it will find its way in the places where the battle against oral diseases is waged daily, that is dental schools, hospitals, and private practice offices.

Athens, 1988      GEORGE LASKARIS, D.D.S., M.D.

## Acknowledgements

My deep appreciation is due to my patients, who taught me so much, and to all of the Greek dentists and physicians who have contributed by referring their patients to me through the years.

My gratitude is extended to the late Professor of Dermatology, John Capetanakis, and the current Professor of Dermatology and Head of the Department of Dermatology, University of Athens, "A. Syngros" Hospital, John Stratigos, for their constant encouragement in my endeavors.

I am also indebted to Associate Professor of Dermatology Antony Vareltzidis, who has greatly helped me to broaden my knowledge in the field of dermatology.

My sincere thanks are extended to the scientific staff of "A.Syngros" Hospital, Department of Dermatology, University of Athens, for their willing and prompt help during the 23 years of our cooperation.

I am particularly grateful to Stathis S. Papavasiliou, M.D., for his efforts and comments on the translation of the Greek edition of this book into English and text contributions in the chapter of endocrine diseases.

My deepest gratitude is due to Professor Crispian Scully, Department of Oral Medicine and Surgery, University of Bristol, England, and Professor Gerald Shklar, Department of Oral Medicine and Pathology, Harvard School of Den-

tal Medicine, United States, both of whom read the manuscript of the first edition. Their suggestions and criticisms have been gratefully received and indeed improved the text considerably.

Finally, I wish to thank my colleagues at the Department of Oral Medicine and Pathology of the Dental School, University of Athens, with whom I have worked closely for more than 25 years. In particular I wish to thank Dr. Alexandra Sklavounou, Dr. Panagiota Economopoulou, and Dr. Eleana Stufi for their assistance in the preparation of the first edition of the Atlas.

I am especially indebted to Dr. Stathis S. Papavasiliou and Professor Crispian Scully for their critical review of the text of second edition.

I thank the following colleagues for permission to use their color plates: Dr. Robert Gorlin (USA) for Figure 46, Dr. Karpathios (Greece) for Figure 358, Dr. Andreas Katsabas (Greece) for Figure 363, Dr. Nikos Lygidakis (Greece) for Figure 67, Dr. Adeyeni Mosadomi (Nigeria) for Figure 490, Dr. Crispian Scully (England) for Figure 278, Dr. Gerald Shklar (USA) for Figures 277, 400, and Dr. Carl Witkop (USA) for Figure 21.

Last, but by no means least, I can never fully repay all that I owe my wife and three children for their constant patience, support, and encouragement.

# Contents

1. Normal Anatomic Variants .....	2	Gardner's Syndrome .....	30
<b>Linea Alba</b> .....	2	Maffucci's Syndrome .....	30
Normal Oral Pigmentation .....	2	<b>Tuberous Sclerosis</b> .....	32
<b>Leukoedema</b> .....	2	Sturge-Weber Syndrome .....	34
		<b>Klippel-Trenaunay-Weber Syndrome</b> ...	34
		Cowden's Disease .....	36
2. Developmental Anomalies .....	4	<b>Cleidocranial Dysplasia</b> .....	36
Fordyce's Granules .....	4	Oro-Facial Digital Syndrome .....	38
<b>Oral Hair</b> .....	4	Focal Dermal Hypoplasia .....	38
<b>Congenital Lip Pits</b> .....	4	Incontinentia Pigmenti .....	40
<b>Ankyloglossia</b> .....	6	<b>Ehlers-Danlos Syndrome</b> .....	40
Cleft Lip .....	6	Marfan's Syndrome .....	42
Cleft Palate .....	6	Down's Syndrome .....	42
Bifid Tongue .....	8		
<b>Double Lip</b> .....	8	4. Mechanical Injuries .....	44
Torus Palatinus .....	8	Traumatic Ulcer .....	44
Torus Mandibularis .....	10	Traumatic Bulla .....	46
<b>Multiple Exostoses</b> .....	10	<b>Traumatic Hematoma</b> .....	46
Fibrous Developmental Malformation .....	10	Chronic Biting .....	46
Facial Hemiatrophy .....	12	<b>Toothbrush Trauma</b> .....	46
Masseteric Hypertrophy .....	12	Factitious Trauma .....	48
		<b>Fellatio</b> .....	<b>48</b>
3. Genetic Diseases .....	14	Lingual Frenum Ulcer After Cunnilingus ..	48
White Sponge Nevus .....	14	Cotton Roll Stomatitis .....	48
Hereditary Benign Intraepithelial		<b>Denture Stomatitis</b> .....	50
<b>Dyskeratosis</b> .....	<b>14</b>	Epulis Fissuratum .....	50
<b>Gingival Fibromatosis</b> .....	14	Papillary Hyperplasia of the Palate .....	50
<b>Pachyonychia Congenita</b> .....	16	Hyperplasia due to Negative Pressure .....	52
<b>Dyskeratosis Congenita</b> .....	16	Atrophy of the Maxillary Alveolar Ridge ..	52
Hypohidrotic Ectodermal Dysplasia .....	18	Foreign Body Reaction .....	52
Focal Palmoplantar and Oral Mucosa		Palatal Necrosis due to Injection .....	54
Hyperkeratosis Syndrome .....	18	Eosinophilic Ulcer .....	54
Papillon-Lefevre Syndrome .....	20		
Benign Acanthosis Nigricans .....	22	5. Oral Lesions due to Chemical Agents ...	56
Dyskeratosis Follicularis .....	22	Phenol Burn .....	56
Familial Benign Pemphigus .....	24	Trichloroacetic Acid Burn .....	56
Epidermolysis Bullosa .....	24	<b>Eugenol Burn</b> .....	56
<b>Neurofibromatosis</b> .....	<b>26</b>	Aspirin Burn .....	58
Chondroectodermal Dysplasia .....	28	Iodine Burn .....	58
Hereditary Hemorrhagic Telangiectasia .....	28	Alcohol Burn .....	58
Peutz-Jeghers Syndrome .....	28	<b>Acrylic Resin Burn</b> .....	58

<b>Sodium Perborate Burn</b> .....	60	<b>Plasma Cell Gingivitis</b> .....	88
<b>Silver Nitrate Burn</b> .....	60	<b>Desquamative Gingivitis</b> .....	90
Sodium Hypochlorite Burn .....	60		
Paraformaldehyde Burn .....	60	12. Diseases of the Tongue .....	92
Chlorine Compounds Burn .....	62	<b>Median Rhomboid Glossitis</b> .....	92
Agricultural Chemical Agents Burn .....	62	Geographic Tongue .....	92
		Fissured Tongue .....	94
6. Oral Lesions due to Smoking and Heat ..	64	Hairy Tongue .....	94
Nicotinic Stomatitis .....	64	Furred Tongue .....	96
Palatal Erosions due to Smoking .....	64	Plasma Cell Glossitis .....	96
Cigarette Smoker's Lip Lesion .....	66	<b>Glossodynia</b> .....	<b>96</b>
Smoker's Melanosis .....	66	<b>Crenated Tongue</b> .....	98
<b>Thermal Burn</b> .....	66	Hypertrophy of Foliate Papillae .....	98
		Hypertrophy of Circumvallate Papillae ....	98
7. Oral Lesions due to Drugs .....	68	Hypertrophy of the Fungiform Papillae ....	100
Gold-induced Stomatitis .....	68	Sublingual Varices .....	100
<b>Antibiotic-induced Stomatitis</b> .....	68		
<b>Stomatitis Medicamentosa</b> .....	68	13. Diseases of the Lips .....	102
Ulcerations due to Methotrexate .....	70	Median Lip Fissure .....	102
Ulceration due to Azathioprine .....	70	<b>Angular Cheilitis</b> .....	102
Penicillamine-induced Oral Lesions .....	70	<b>Actinic Cheilitis</b> .....	102
Phenytoin-induced Gingival Hyperplasia ...	72	Exfoliative Cheilitis .....	104
Cyclosporine-induced Gingival Hyperplasia .	72	Contact Cheilitis .....	104
Nifedipine-induced Gingival Hyperplasia ..	72	<b>Cheilitis Glandularis</b> .....	104
<b>Angioneurotic Edema</b> .....	74	Cheilitis Granulomatosa .....	106
Pigmentation due to Antimalarials .....	74	<b>Plasma Cell Cheilitis</b> .....	106
Pigmentation due to Azidothymidine ....	74		
<b>Cheilitis due to Retinoids</b> .....	76	14. Soft-Tissue Cysts .....	108
		<b>Mucocele</b> .....	<b>108</b>
8. Metal and Other Deposits .....	77	<b>Ranula</b> .....	<b>108</b>
Amalgam Tattoo .....	77	Lymphoepithelial Cyst .....	110
Bismuth Deposition .....	78	<b>Dermoid Cyst</b> .....	110
<b>Phleboliths</b> .....	<b>78</b>	<b>Eruption Cyst</b> .....	112
Materia Alba of the Attached Gingiva .....	78	<b>Gingival Cyst of the Newborn</b> .....	112
		Gingival Cyst of the Adult .....	112
9. Radiation-Induced Injuries .....	80	<b>Palatine Papilla Cyst</b> .....	114
		<b>Nasolabial Cyst</b> .....	114
		Thyroglossal Duct Cyst .....	114
10. Allergy to Chemical Agents Applied			
<b>Locally</b> .....	<b>83</b>	15. Viral Infections .....	116
Allergic Stomatitis due to Acrylic Resin .....	83	Primary Herpetic Gingivostomatitis .....	116
Allergic Stomatitis due to Eugenol .....	84	Secondary Herpetic Stomatitis .....	116
		<b>Herpes Labialis</b> .....	118
11. Periodontal Diseases .....	85	<b>Herpes Zoster</b> .....	118
<b>Gingivitis</b> .....	<b>85</b>	<b>Varicella</b> .....	<b>120</b>
<b>Periodontitis</b> .....	86	<b>Herpangina</b> .....	<b>120</b>
<b>Juvenile Periodontitis</b> .....	86	Acute Lymphonodular Pharyngitis .....	120
<b>Periodontal Abscess</b> .....	86	<b>Hand-Foot-and-Mouth Disease</b> .....	122
<b>Periodontal Fistula</b> .....	88	<b>Measles</b> .....	<b>122</b>
Gingivitis and Mouth Breathing .....	88	Infectious Mononucleosis .....	124
		<b>Mumps</b> .....	<b>124</b>



Verruca Vulgaris . . . . .	124	20. Diseases with Possible Immunopathogenesis . . . . .	177
<b>Condyloma Acuminatum</b> . . . . .	126	Recurrent Aphthous Ulcers . . . . .	177
<b>Molluscum Contagiosum</b> . . . . .	126	Minor Aphthous Ulcers . . . . .	177
Focal Epithelial Hyperplasia . . . . .	128	Major Aphthous Ulcers . . . . .	178
<b>16. HIV Infection and AIDS</b> . . . . .	129	<b>Herpetiform Ulcers</b> . . . . .	178
<b>Infections</b> . . . . .	<b>130</b>	Behcet's Syndrome . . . . .	180
<b>Neoplasms</b> . . . . .	<b>136</b>	<b>Reiter's Syndrome</b> . . . . .	182
Neurologic Disturbances . . . . .	138	Wegener's Granulomatosis . . . . .	184
Lesions of Unknown Cause . . . . .	140	<b>Lethal Midline Granuloma</b> . . . . .	185
<b>17. Bacterial Infections</b> . . . . .	142	Crohn's Disease . . . . .	186
Necrotizing Ulcerative Gingivitis . . . . .	142	<b>21. Autoimmune Diseases</b> . . . . .	188
Necrotizing Ulcerative Stomatitis . . . . .	142	Discoid Lupus Erythematosus . . . . .	188
<b>Cancrum Oris</b> . . . . .	142	Systemic Lupus Erythematosus . . . . .	190
Streptococcal Gingivostomatitis . . . . .	144	<b>Scleroderma</b> . . . . .	<b>190</b>
<b>Erysipelas</b> . . . . .	<b>144</b>	<b>Dermatomyositis</b> . . . . .	<b>192</b>
Scarlet Fever . . . . .	144	Mixed Connective Tissue Disease . . . . .	194
Oral Soft-Tissue Abscess . . . . .	146	Sjogren's <b>Syndrome</b> . . . . .	194
Peritonsillar Abscess . . . . .	146	Benign Lymphoepithelial Lesion . . . . .	196
Acute Suppurative Parotitis . . . . .	146	<b>Primary Biliary Cirrhosis</b> . . . . .	196
Acute Submandibular Sialadenitis . . . . .	148	Lupoid Hepatitis . . . . .	196
Buccal Cellulitis . . . . .	148	<b>22. Skin Diseases</b> . . . . .	198
<b>Klebsiella Infections</b> . . . . .	148	<b>Erythema Multiforme</b> . . . . .	198
Pseudomonas Infections . . . . .	150	Stevens-Johnson Syndrome . . . . .	199
<b>Syphilis</b> . . . . .	<b>150</b>	Toxic Epidermal Necrolysis . . . . .	200
Primary Syphilis . . . . .	150	<b>Pemphigus</b> . . . . .	<b>202</b>
Secondary Syphilis . . . . .	152	<b>Pemphigus Vulgaris</b> . . . . .	202
Late Syphilis . . . . .	154	Pemphigus Vegetans . . . . .	202
Congenital Syphilis . . . . .	156	Pemphigus Foliaceus . . . . .	204
<b>Chancroid</b> . . . . .	<b>158</b>	Pemphigus Erythematosus . . . . .	204
Gonococcal Stomatitis . . . . .	158	Juvenile Pemphigus Vulgaris . . . . .	204
<b>Tuberculosis</b> . . . . .	<b>158</b>	Paraneoplastic Pemphigus . . . . .	206
Lupus Vulgaris . . . . .	160	Cicatricial Pemphigoid . . . . .	207
<b>Leprosy</b> . . . . .	<b>160</b>	Childhood Cicatricial Pemphigoid . . . . .	210
<b>Actinomycosis</b> . . . . .	<b>162</b>	Linear Immunoglobulin A Disease . . . . .	210
<b>18. Fungal Infections</b> . . . . .	164	<b>Bullous Pemphigoid</b> . . . . .	210
<b>Candidosis</b> . . . . .	<b>164</b>	Dermatitis Herpetiformis . . . . .	212
Primary Oral Candidosis . . . . .	164	Epidermolysis Bullosa Acquisita . . . . .	214
Secondary Oral Candidosis . . . . .	168	<b>Lichen Planus</b> . . . . .	214
<b>Histoplasmosis</b> . . . . .	<b>170</b>	<b>Psoriasis</b> . . . . .	<b>218</b>
North American Blastomycosis . . . . .	170	Mucocutaneous Lymph Node Syndrome . . . . .	220
<b>Paracoccidioidomycosis</b> . . . . .	<b>172</b>	Malignant Acanthosis Nigricans . . . . .	220
<b>Mucormycosis</b> . . . . .	<b>172</b>	Acrodermatitis Enteropathica . . . . .	222
<b>19. Other Infections</b> . . . . .	174	Lip-Licking Dermatitis . . . . .	222
Cutaneous Leishmaniasis . . . . .	174	Perioral Dermatitis . . . . .	222
<b>Sarcoidosis</b> . . . . .	<b>174</b>	<b>Warty Dyskeratoma</b> . . . . .	224
Heerfordt's Syndrome . . . . .	176	<b>Vitiligo</b> . . . . .	<b>224</b>

23. Hematologic Disorders	226	29. Precancerous Lesions	258
Iron Deficiency Anemia	226	<b>Leukoplakia</b>	<b>258</b>
Plummer-Vinson Syndrome	226	<b>Erythroplasia</b>	<b>262</b>
<b>Pernicious Anemia</b>	<b>226</b>	<b>Candidal Leukoplakia</b>	<b>264</b>
<b>Thalassemias</b>	<b>228</b>	30. Precancerous Conditions	265
Congenital Neutropenia	228	Plummer-Vinson Syndrome	265
Cyclic Neutropenia	228	Atrophic Glossitis in Tertiary Syphilis	266
<b>Agranulocytosis</b>	<b>230</b>	Submucous Fibrosis	266
Aplastic Anemia	232	Epidermolysis Bullosa Dystrophica	268
<b>Thrombocytopenic Purpura</b>	<b>232</b>	Xeroderma Pigmentosum	268
<b>Myelodysplastic Syndrome</b>	<b>232</b>	Lichen Planus	268
24. Renal Diseases	234	31. Malignant Neoplasms	270
Uremic Stomatitis	234	<b>Squamous Cell Carcinoma</b>	<b>270</b>
25. Metabolic Diseases	236	<b>Verrucous Carcinoma</b>	<b>274</b>
<b>Amyloidosis</b>	<b>236</b>	Adenoid Squamous Cell Carcinoma	276
Lipoid Proteinosis	238	<b>Spindle Cell Carcinoma</b>	<b>276</b>
Glycogen Storage Disease Type Ib	240	<b>Lymphoepithelial Carcinoma</b>	<b>276</b>
<b>Xanthomas</b>	<b>240</b>	Basal Cell Carcinoma	278
<b>Porphyrias</b>	<b>242</b>	Acinic Cell Carcinoma	278
<b>Hemochromatosis</b>	<b>242</b>	Mucoepidermoid Carcinoma	280
<b>Cystic Fibrosis</b>	<b>244</b>	Adenoid Cystic Carcinoma	280
Histiocytosis X	244	<b>Malignant Pleomorphic Adenoma</b>	<b>282</b>
26. Nutritional Disorders	247	<b>Adenocarcinoma</b>	<b>282</b>
<b>Pellagra</b>	<b>247</b>	Clear Cell Adenocarcinoma	282
Ariboflavinosis	248	Polymorphous Low-Grade Adenocarcinoma	284
<b>Scurvy</b>	<b>248</b>	<b>Fibrosarcoma</b>	<b>284</b>
Protein Deficiency	248	Kaposi's Sarcoma	284
27. Endocrine Diseases	250	Malignant Fibrous Histiocytoma	286
<b>Diabetes Mellitus</b>	<b>250</b>	<b>Hemangioendothelioma</b>	<b>286</b>
Adrenocortical Insufficiency	250	<b>Hemangiopericytoma</b>	<b>286</b>
<b>Hypothyroidism</b>	<b>250</b>	Malignant Melanoma	288
Primary Hyperparathyroidism	252	<b>Chondrosarcoma</b>	<b>288</b>
Sex Hormone Disorders	252	<b>Osteosarcoma</b>	<b>290</b>
<b>Acromegaly</b>	<b>252</b>	<b>Metastatic Tumors</b>	<b>290</b>
28. Diseases of the Peripheral Nervous System	254	32. Malignancies of the Hematopoietic and Lymphatic Tissues	293
Hypoglossal Nerve Paralysis	254	<b>Leukemias</b>	<b>293</b>
Peripheral Facial Nerve Paralysis	254	Acute Leukemias	293
Ipsilateral Masseter's Spasm	256	<b>Chronic Leukemias</b>	<b>293</b>
Melkersson-Rosenthal Syndrome	256	<b>Erythroleukemia</b>	<b>296</b>
		<b>Polycythemia Vera</b>	<b>296</b>
		Hodgkin's Disease	298
		Non-Hodgkin's Lymphomas	298
		Burkitt's Lymphoma	300
		<b>Mycosis Fungoides</b>	<b>300</b>
		<b>Macroglobulinemia</b>	<b>302</b>
		Plasmacytoma of the Oral Mucosa	302
		Multiple Myeloma	302

33. Benign Tumors .....	304	<b>Blue Nevus</b> .....	324
<b>Papilloma</b> .....	<b>304</b>	Nevus of Ota .....	326
Verrucous Hyperplasia .....	304	Lentigo Maligna .....	326
<b>Keratoacanthoma</b> .....	<b>306</b>	Melanotic Neuroectodermal Tumor of	
<b>Fibroma</b> .....	<b>306</b>	<b>Infancy</b> .....	<b>328</b>
Giant Cell Fibroma .....	306	<b>Pleomorphic Adenoma</b> .....	328
Peripheral Ossifying Fibroma .....	308	Papillary Cystadenoma Lymphomatosum ..	330
Soft-Tissue Osteoma .....	308		
<b>Lipoma</b> .....	<b>310</b>	34. Other Salivary Gland Disorders .....	331
<b>Myxoma</b> .....	<b>310</b>	Necrotizing Sialometaplasia .....	331
<b>Neurofibroma</b> .....	<b>310</b>	<b>Sialolithiasis</b> .....	<b>332</b>
<b>Schwannoma</b> .....	<b>312</b>	Mikulicz's Syndrome .....	332
<b>Traumatic Neuroma</b> .....	312	<b>Sialadenosis</b> .....	<b>332</b>
<b>Leiomyoma</b> .....	<b>312</b>	<b>Xerostomia</b> .....	<b>334</b>
Verruciform Xanthoma .....	314		
Granular Cell Tumor .....	314	35. Tumor-like Lesions .....	335
Benign Fibrous Histiocytoma .....	314	Pyogenic Granuloma .....	335
<b>Hemangioma</b> .....	<b>316</b>	Pregnancy Granuloma .....	336
<b>Lymphangioma</b> .....	<b>318</b>	<b>Postextraction Granuloma</b> .....	<b>336</b>
<b>Cystic Hygroma</b> .....	318	<b>Fistula Granuloma</b> .....	338
Papillary Syringadenoma of the Lower Lip ..	320	Peripheral Giant Cell Granuloma .....	338
Sebaceous Adenoma .....	320	Congenital Epulis of the Newborn .....	340
Cutaneous Horn .....	320		
<b>Freckles</b> .....	<b>322</b>	<b>Selected Bibliography</b> .....	<b>341</b>
Lentigo Simplex .....	322		
Intramucosal Nevus .....	322	<b>Index</b> .....	<b>363</b>
Junctional Nevus .....	324		
Compound Nevus .....	324		

This atlas is dedicated  
to the memory of my father  
and  
to my family

# 1. Normal Anatomic Variants

## Linea Alba

Linea alba is a normal linear elevation of the buccal mucosa extending from the corner of the mouth to the third molars at the occlusal line. Clinically, it presents as a bilateral linear elevation with normal or slightly whitish color and normal consistency on palpation (Fig. 1).

It occurs more often in obese persons. The oral mucosa is slightly compressed and adjusts to the shape of the occlusal line of the teeth.

## Normal Oral Pigmentation

Melanin is a normal skin and oral mucosa pigment produced by melanocytes. Increased melanin deposition in the oral mucosa may occur in various diseases. However, areas of dark discoloration may often be a normal finding in black or dark-skinned persons. However, the degree of pigmentation of skin and oral mucosa is not necessarily significant. In healthy persons there may be clinically asymptomatic black or brown areas of varying size and distribution in the oral cavity, usually on the gingiva, buccal mucosa, palate, and less often on the tongue, floor of the mouth, and lips (Fig. 2). The pigmentation is more prominent in areas of pressure or friction and becomes more intense with aging.

The differential diagnosis includes Addison's disease, pigmented nevus, melanoma, smoker's melanosis, heavy metal deposition, lentigo maligna, pigmentation caused by drugs, Peutz-Jeghers syndrome, Albright's syndrome, and von Recklinghausen's disease.

## Leukoedema

Leukoedema is a normal anatomic variant of the oral mucosa due to increased thickness of the epithelium and intracellular edema of the malpighian layer. As a rule, it occurs bilaterally and involves most of the buccal mucosa and rarely the lips and tongue. Clinically, the mucosa has an opalescent or grayish-white color with slight wrinkling, which disappears if the mucosa is distended by pulling or stretching of the cheek (Fig. 3). Leukoedema has normal consistency on palpation, and it should not be confused with leukoplakia or lichen planus.

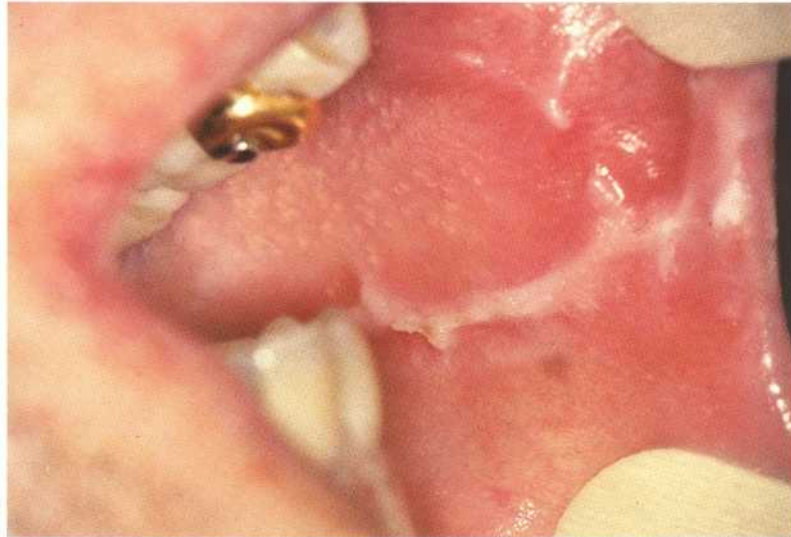

Fig. 1. Linea alba.

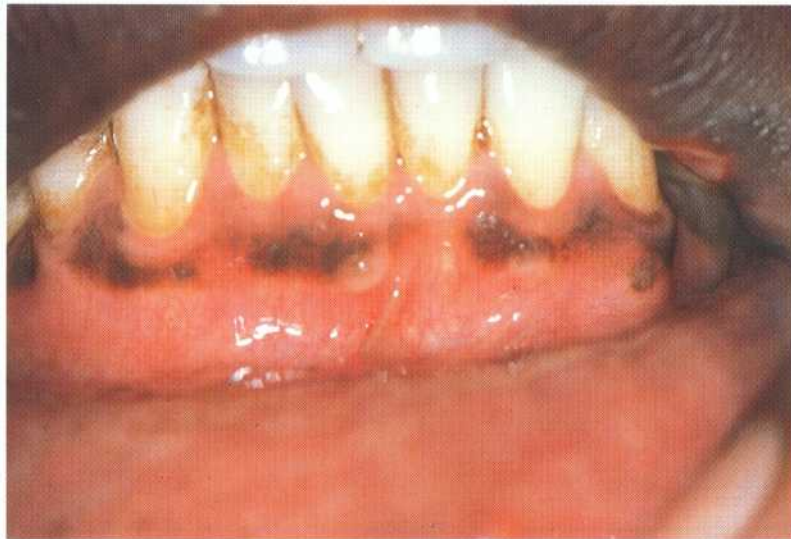

Fig. 2. Normal pigmentation of the gingiva.

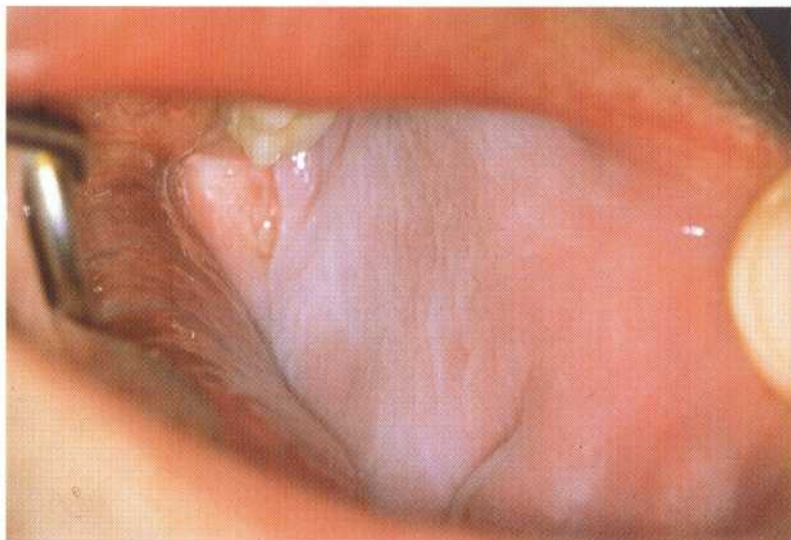


Fig. 3. Leukoedema of the buccal mucosa.

## 2. Developmental Anomalies

### Fordyce's Granules

Fordyce's granules are a developmental anomaly characterized by collections of heterotopic sebaceous glands in the oral mucosa. Clinically, there are many small, slightly raised whitish-yellow spots that are well circumscribed and rarely coalesce, forming plaques (Fig. 4). They occur most often in the mucosal surface of the upper lip, commissures, and the buccal mucosa adjacent to the molar teeth in a symmetrical bilateral pattern.

They are a frequent finding in about 80% of persons of both sexes. These granules are asymptomatic and come to the patient's attention by chance. With advancing age, they may become more prominent but should not be a cause for concern.

The differential diagnosis includes lichen planus, candidosis, and leukoplakia.

Treatment. No treatment is required.

### Oral Hair

Hair and hair follicles are extremely unusual within the oral cavity. Only five cases have been reported so far. There is no satisfactory explanation for the occurrence of oral hair although a developmental anomaly is the most likely possibility. All reported patients have been white males. The buccal mucosa, gingiva, and tongue are the preferred areas of hair growth.

Oral hair presents as an asymptomatic black hair 0.3-3.5 cm in length (Fig. 5). The patients are usually anxious and nervous. The presence of oral hair and hair follicles may offer an explanation for the rare occurrence of keratoacanthoma intraorally.

The differential diagnosis should be made from traumatically implanted hair and the presence of hair in skin grafts after surgical procedures in the oral cavity.

Laboratory test. Histopathologic examination supports the clinical diagnosis.

Treatment. Surgical removal is recommended.

### Congenital Lip Pits

Congenital lip pits represent a rare developmental malformation that may occur alone or in combination with commissural pits, cleft lip, or cleft palate. Clinically, they present as bilateral or unilateral depressions at the vermilion border of the lower lip (Fig. 6). A small amount of mucous secretion may accumulate at the depth of the pit. The lip may be enlarged and swollen.

Treatment of choice is surgical excision, but only for esthetic purposes.

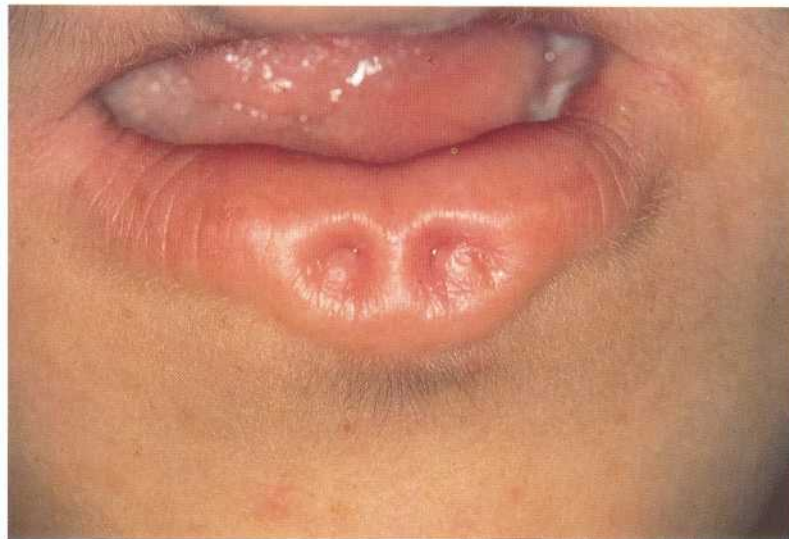
Fig. 4. Fordyce's granules in the buccal mucosa.

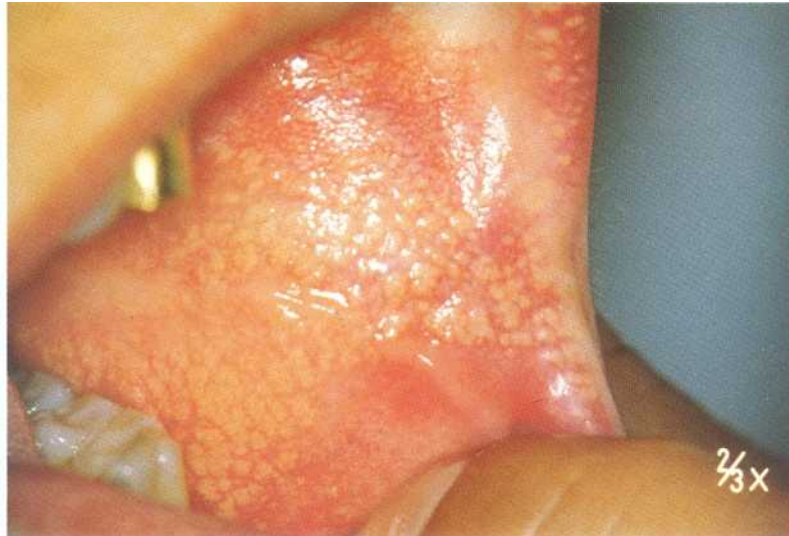

Fig. 5. Black hair on the tip of the tongue (arrow).

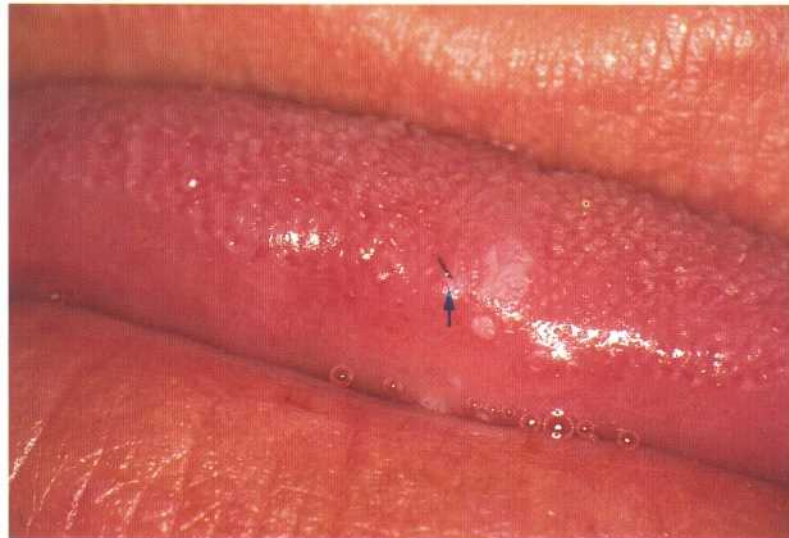

Fig. 6. Congenital lip pits.





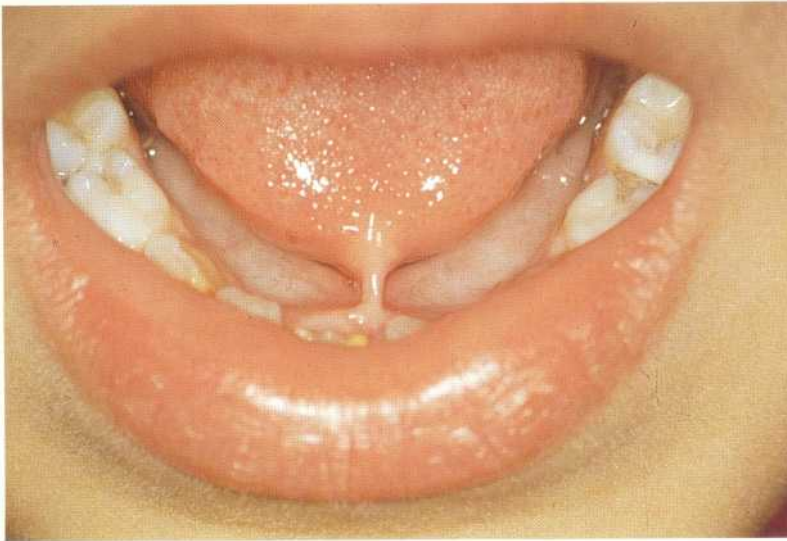


Fig. 7. Ankyloglossia.

### Ankyloglossia

Ankyloglossia, or tongue-tie, is a rare developmental disturbance in which the lingual frenum is short or is attached close to the tip of the tongue (Fig. 7). In these cases the frenum is often thick and fibrous. Rarely, the condition may occur as a result of fusion between the tongue and the floor of the mouth or the alveolar mucosa. The malformation may cause speech difficulties.

**Treatment.** Surgical clipping of the frenum corrects the problem.

### Cleft Lip

Cleft lip is a developmental malformation that usually involves the upper lip and very rarely the lower lip (Fig. 8). It frequently coexists with cleft palate and it rarely occurs alone. The incidence of cleft lip alone or in combination with cleft palate varies from 0.52 to 1.34 per 1000 births.

The disorder may be unilateral or bilateral, complete or incomplete.

**Treatment.** Plastic surgery as early as possible corrects the esthetic and functional problems.

### Cleft Palate

Cleft palate is a developmental malformation due to failure of the two embryonic palatal processes to fuse. The cause remains unknown, although heredity may play a role. Clinically, the patients exhibit a defect at the midline of the palate that may vary in severity (Fig. 9). Bifid uvula represents a minor expression of cleft palate and may be seen alone or in combination with more severe malformations (Fig. 10).

Cleft palate may occur alone or in combination with cleft lip. The incidence of cleft palate alone varies between 0.29 and 0.56 per 1000 births. It may occur in the hard or soft palate or both. Serious speech, feeding, and psychologic problems may occur.

**Treatment.** Early surgical correction is recommended.

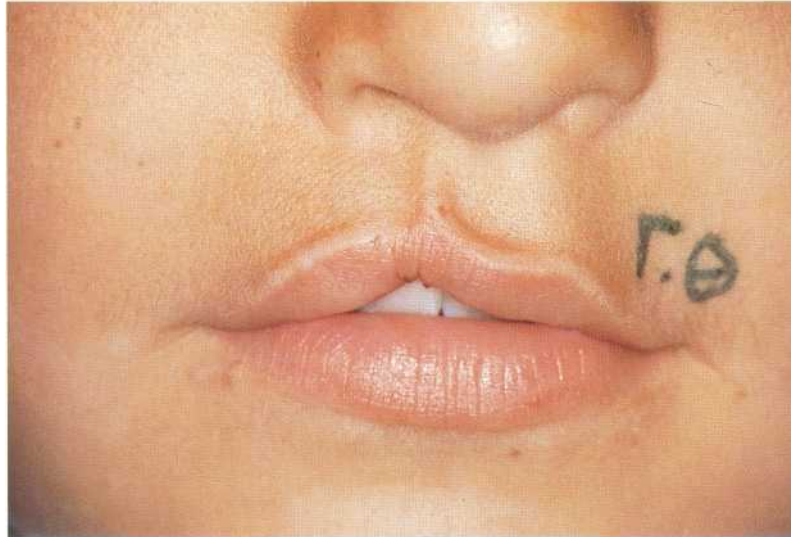

Fig. 8. Cleft lip.

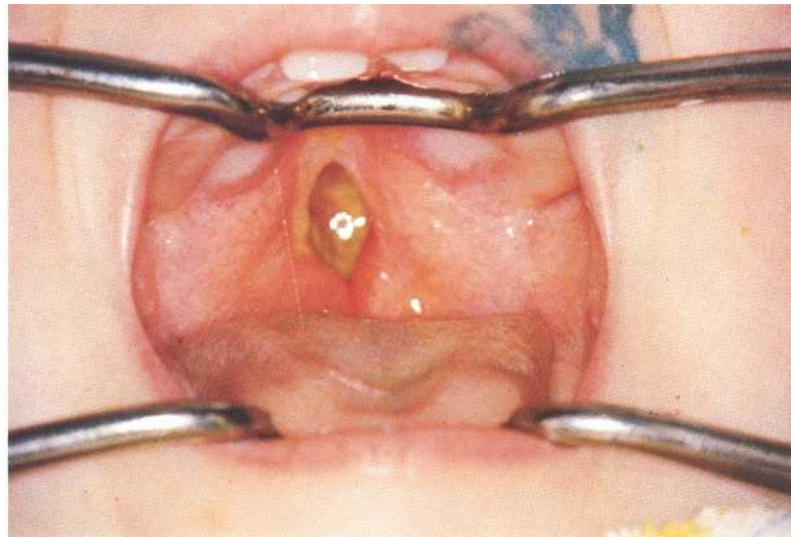

Fig. 9. Cleft palate.

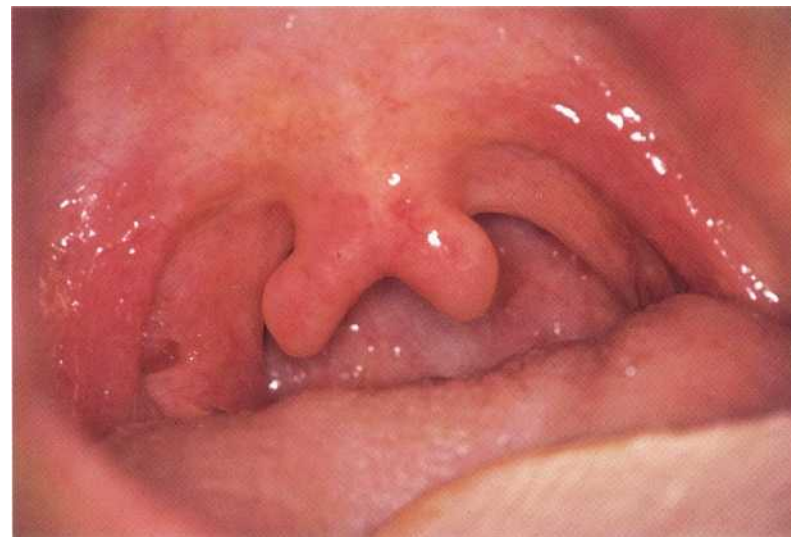

Fig. 10. Bifid uvula.

### **Bifid Tongue**

Bifid tongue is a rare developmental malformation that may appear in complete or incomplete form. The incomplete form is manifested as a deep furrow along the midline of the dorsum of the tongue or as a double ending of the tip of the tongue (Fig. 11). Usually, it is an asymptomatic disorder requiring no therapy. It may coexist with the oro-facial digital syndrome.

### **Double Lip**

Double lip is a malformation characterized by a protruding horizontal fold of the inner surface of the upper lip (Fig. 12). It may be congenital, but it can also occur as a result of trauma. The abnormality becomes prominent during speech or smiling. Frequently, it may be part of Ascher's syndrome.

**Treatment.** Surgical correction may be attempted for esthetic reasons only.

### **Torus Palatinus**

Torus palatinus is a developmental malformation of unknown cause. It is a bony exostosis occurring along the midline of the hard palate. The incidence of torus palatinus is about 20% and appears in the third decade of life, but it also may occur at any age. The size of the exostosis varies, and the shape may be spindlelike, lobular, nodular, or even completely irregular (Fig. 13). The exostosis is benign and consists of bony tissue covered with normal mucosa, although it may become ulcerated if traumatized. Because of its slow growth, the lesion causes no symptoms, and it is usually an incidental finding during physical examination.

**Treatment.** No treatment is needed, but problems may be anticipated if a total or partial denture is required.

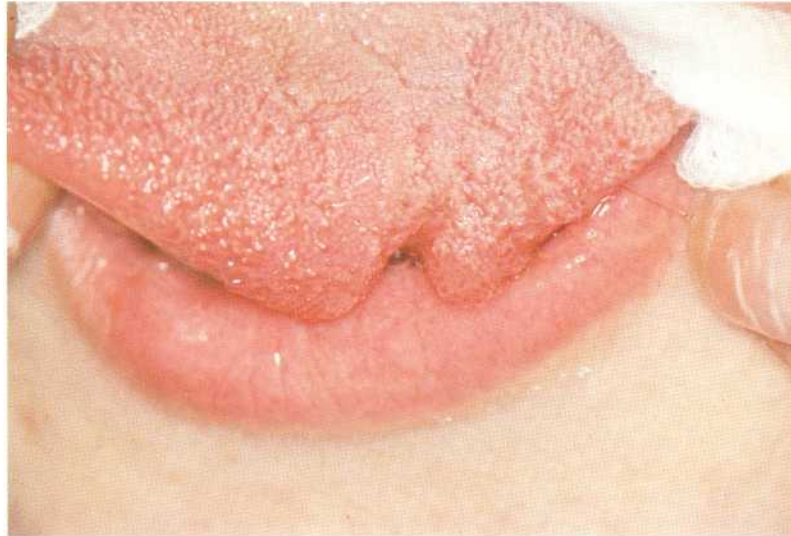

Fig. 11. Bifid tongue.

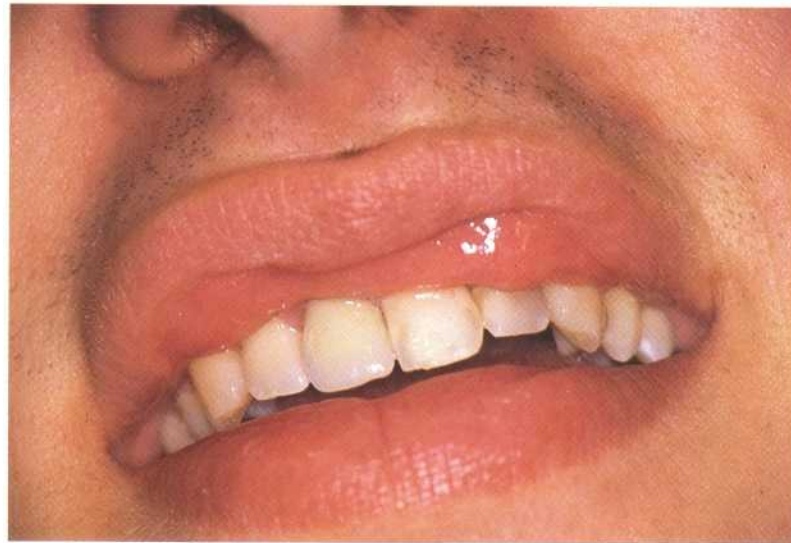


Fig. 12. Double lip.

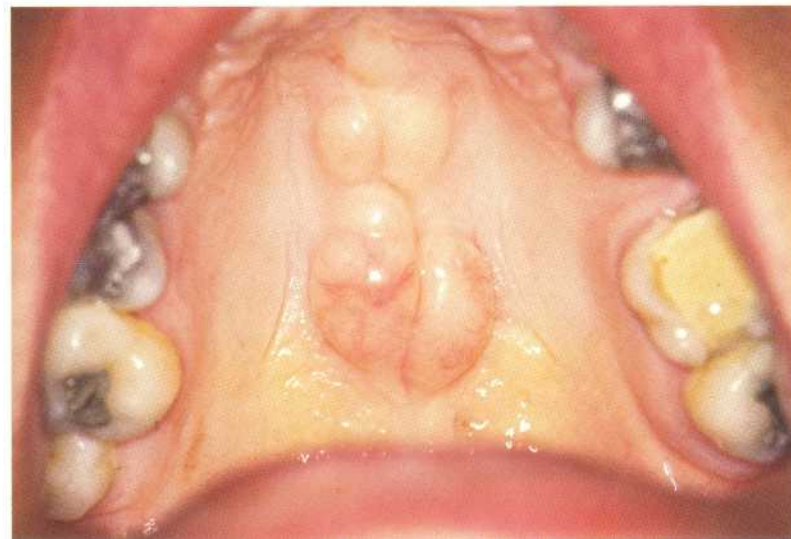

Fig. 13. Torus palatinus.

### **Torus Mandibularis**

Torus mandibularis is an exostosis covered with normal mucosa that appears on the lingual surfaces of the mandible, usually in the area adjacent to the bicuspids (Fig. 14). The incidence of torus mandibularis is about 6%. Bilateral exostoses occur in 80% of the cases.

Clinically, it is an asymptomatic growth that varies in size and shape.

**Treatment.** Surgical removal of torus mandibularis is not indicated, but difficulties may be encountered if a denture has to be constructed.

### **Multiple Exostoses**

Multiple exostoses are rare and may occur on the buccal surface of the maxilla and the mandible. Clinically, they appear as multiple asymptomatic small nodular, bony elevations below the mucoclabial fold covered with normal mucosa (Fig. 15).

The cause is unknown and the lesions are benign, requiring no therapy.

Problems may be encountered during denture preparation.

### **Fibrous Developmental Malformation**

Fibrous developmental malformation is a rare developmental disorder consisting of fibrous overgrowth that usually occurs on the maxillary alveolar tuberosity. It appears as a bilateral symmetrical painless mass with a smooth surface, firm to palpation, and normal or pale color (Fig. 16). Commonly, the malformation develops during the eruption of the teeth and may cover their crowns. The mass is firmly attached to the underlying bone but on occasion may be movable.

The classic sites of development are the maxillary alveolar tuberosity region, but rarely it may also appear in the retromolar region of the mandible and on the entire attached gingiva.

**Treatment.** Surgical excision is required if mechanical problems exist.

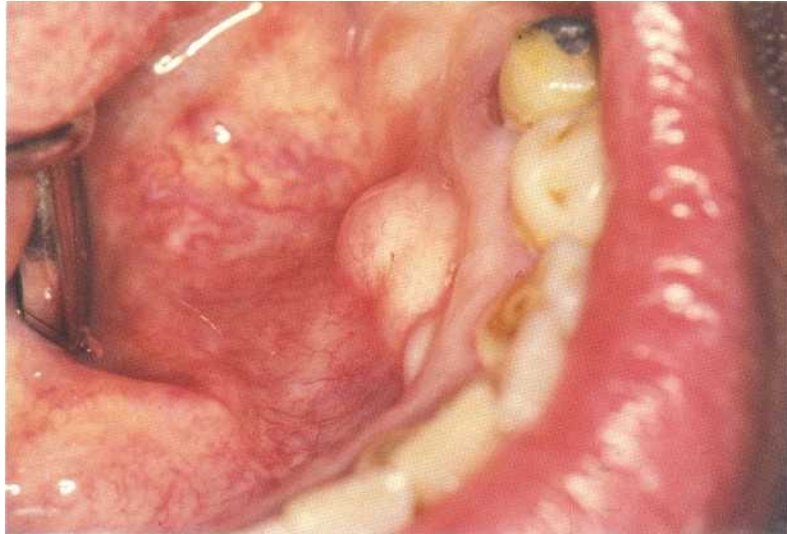

Fig. 14. Torus mandibularis.

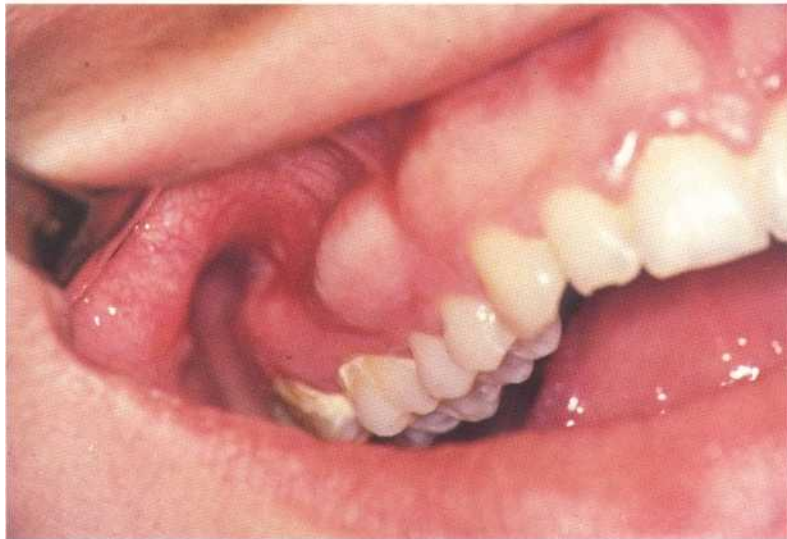

Fig. 15. Multiple exostoses.

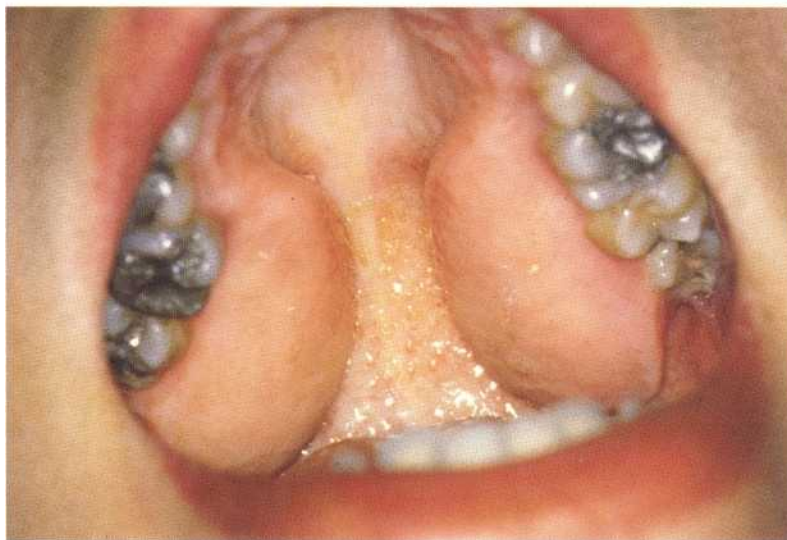


Fig. 16. Fibrous developmental malformation of the maxillary tuberosities.

### Facial Hemiatrophy

Facial hemiatrophy, or Parry-Romberg syndrome, is a developmental disorder of unknown cause characterized by unilateral atrophy of the facial tissues.

Sporadic hereditary cases have been described. The disorder becomes apparent in childhood and girls are affected more frequently than boys in a ratio of 3:2. In addition to facial hemiatrophy, epilepsy, trigeminal neuralgia, eye, hair, and sweat gland disorders may occur. The lipocytes on one side of the face disappear first, followed by skin, muscle, cartilage, and bone atrophy. Clinically, the affected side appears atrophic and the skin is wrinkled and shriveled with hyperpigmentation occasionally (Fig. 17).

Hemiatrophy of the tongue and the lips are the most common oral manifestations (Fig. 18). Jaw and teeth disorders on the affected side may also occur.

The differential diagnosis includes true lipodystrophy, atrophy secondary to facial paralysis, facial hemihypertrophy, unilateral masseteric hypertrophy, and scleroderma.

Treatment is plastic reconstruction.

### Masseteric Hypertrophy

Masseteric hypertrophy may be either congenital or functional as a result of an increased muscle function, bruxism, or habitual overuse of the masseters during mastication. The hypertrophy may be bilateral or unilateral. Clinically, masseteric hypertrophy appears as a swelling over the ascending ramus of the mandible, which characteristically becomes more prominent and firm when the patient clenches the teeth (Fig. 19).

The differential diagnosis includes Sjogren's, Mikulicz's, and Heerfordt's syndromes, cellulitis, facial hemihypertrophy, and neoplasms.

Treatment. No treatment is necessary.

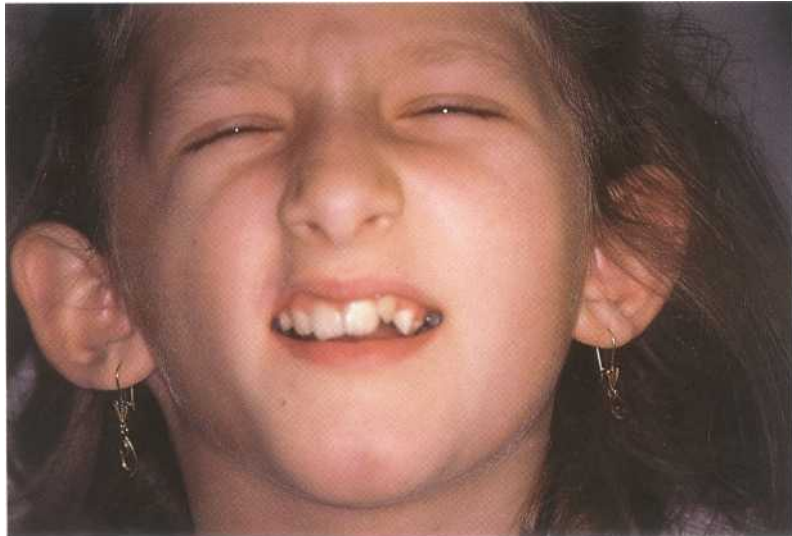

Fig. 17. Hemiatrophy of the right side of the face.

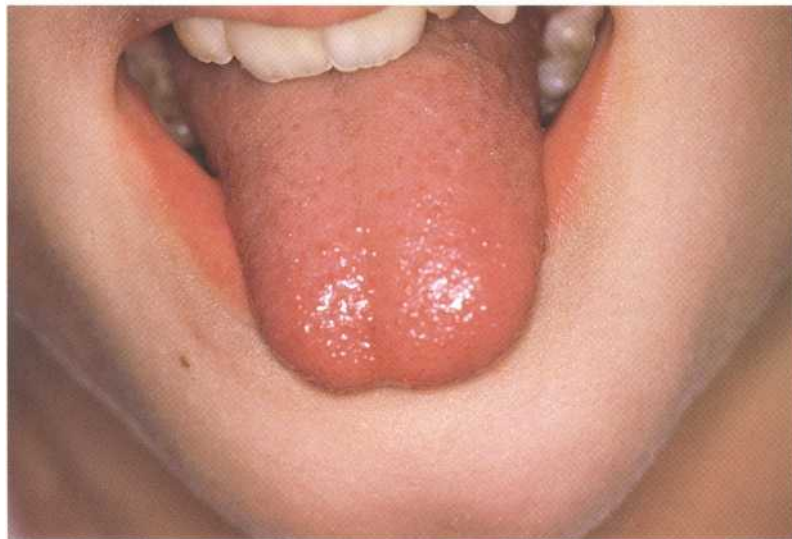

Fig. 18. Atrophy of the right side of the tongue.

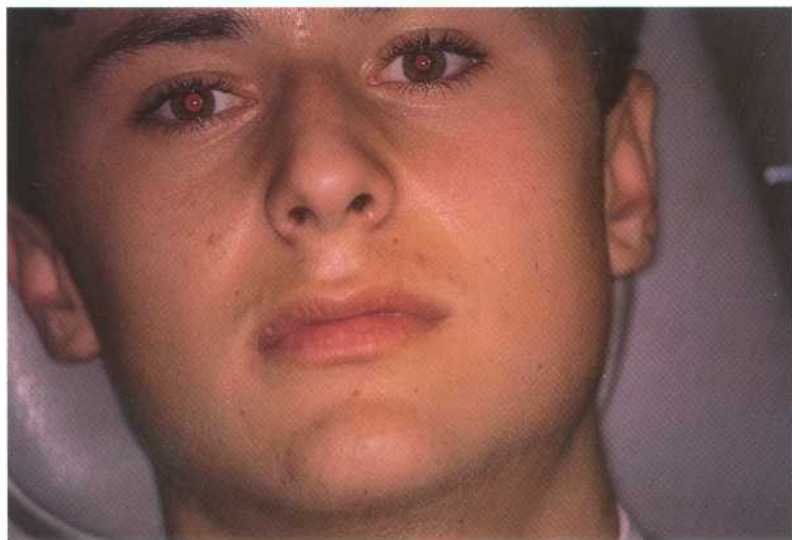


Fig. 19. Hypertrophy of the left masseter.



### 3. Genetic Diseases

#### White Sponge Nevus

White sponge nevus, or Cannon's disease, is an uncommon disorder inherited as an autosomal dominant trait. It may appear at birth or more commonly during childhood. It is progressive until early adulthood, remaining stable thereafter. Clinically, the affected oral mucosa is white or gray-white with multiple furrows and a spongy texture (Fig. 20). The lesions are benign, asymptomatic, and usually bilateral. Most frequently, they are found in the buccal mucosa and the ventral surface of the tongue but may occur anywhere in the mouth.

Some patients have similar lesions in the vaginal or rectal mucosa.

The differential diagnosis includes leukoplakia, lichen planus, leukoedema, pachyonychia congenita, congenital dyskeratosis, hereditary benign intraepithelial dyskeratosis, and mechanical whitish lesions.

Laboratory test. Histopathologic examination is helpful in establishing the diagnosis.

Treatment is not required.

#### Hereditary Benign Intraepithelial Dyskeratosis

Hereditary benign intraepithelial dyskeratosis is a genetic disorder inherited as an autosomal dominant trait with a high degree of penetrance. It affects the oral mucosa and the bulbar conjunctiva. The disease was first found in a triracial population (white, Indian, black) in North Carolina. Clinically, the oral lesions appear as thick, soft, white folds and plaques (Fig. 21). They are firm and asymptomatic and the patient may not be aware of the lesions. Any region of the oral mucosa can be affected. The ocular lesion presents as a gelatinous plaque covering the pupil partially or totally and may cause temporary

blindness. The plaque usually sheds and consequently vision is restored. This periodic appearance of the ocular lesion seems to show a seasonal pattern. The oral and conjunctival lesions appear usually during the first year of life.

The differential diagnosis includes white sponge nevus, dyskeratosis congenita, and rarely other genodermatoses associated with white hyperkeratotic lesions of the oral mucosa.

Laboratory tests. Histopathologic examination establishes the diagnosis.

Treatment. There is no need for treatment.

#### Gingival Fibromatosis

Gingival fibromatosis is transmitted as an autosomal dominant trait. It usually appears by the tenth year of life in both sexes. Clinically, there is generalized enlargement of the gingiva, which is usually firm, smooth, and occasionally nodular with minimal or no inflammation and normal or pale in color (Fig. 22).

The teeth may be partially or completely covered by the overgrown gingiva.

The upper gingiva are more severely affected and may prevent the eruption of the teeth.

The differential diagnosis should include gingival hyperplasia due to phenytoin, nifedipine, and cyclosporine, and gingival fibromatosis, which may occur as part of other genetic syndromes.

Treatment. Surgical excision of the enlarged gingiva.

Fig. 20. White sponge nevus of the buccal mucosa.

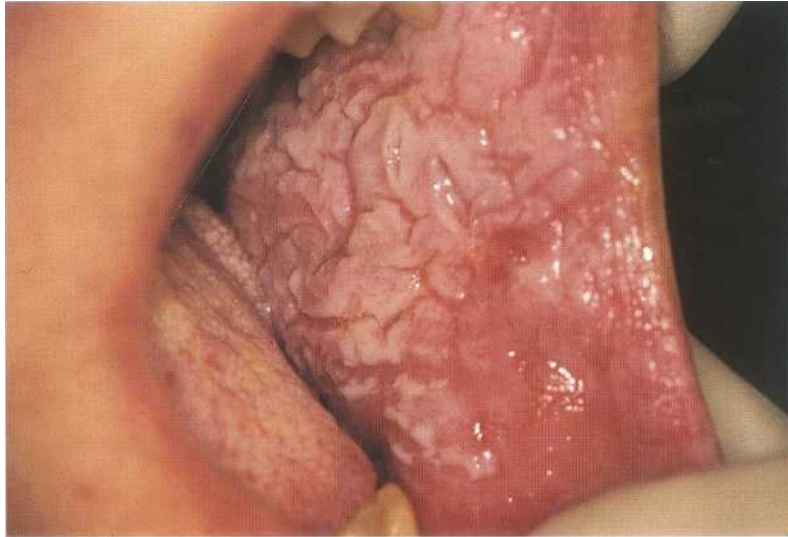

Fig. 21. Hereditary benign intraepithelial dyskeratosis, white lesions on the buccal mucosa.

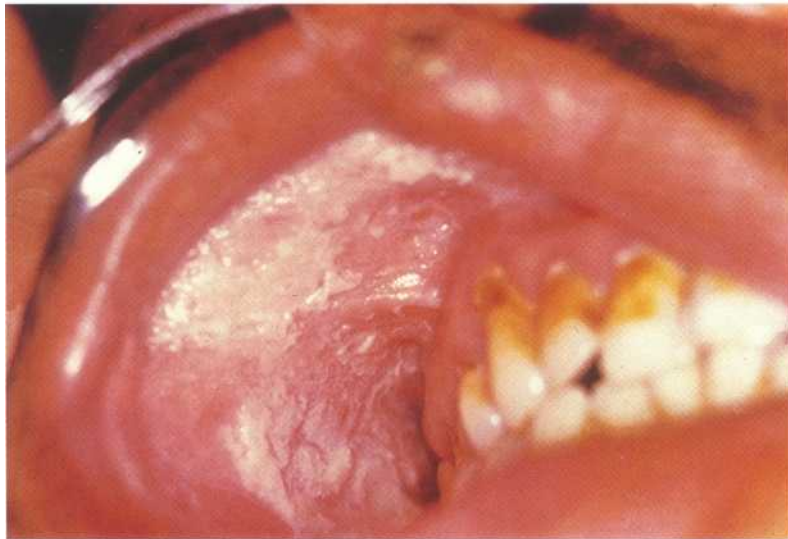
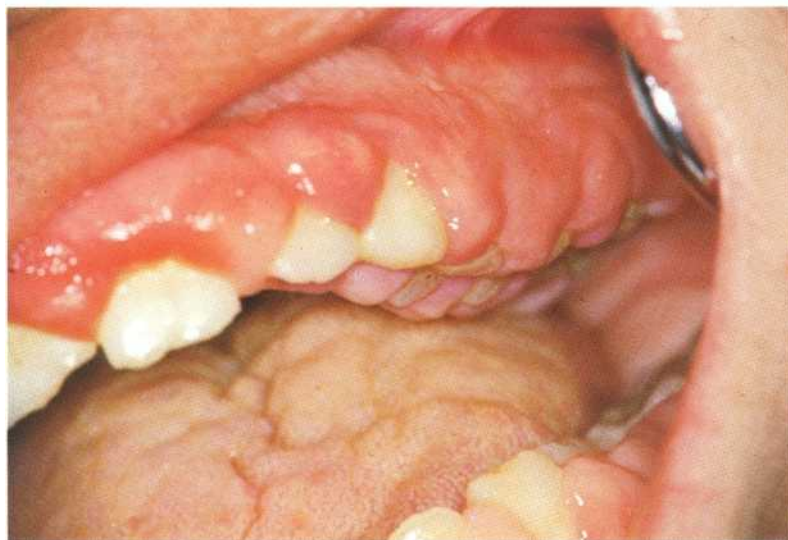
Fig. 22. Gingival fibromatosis.



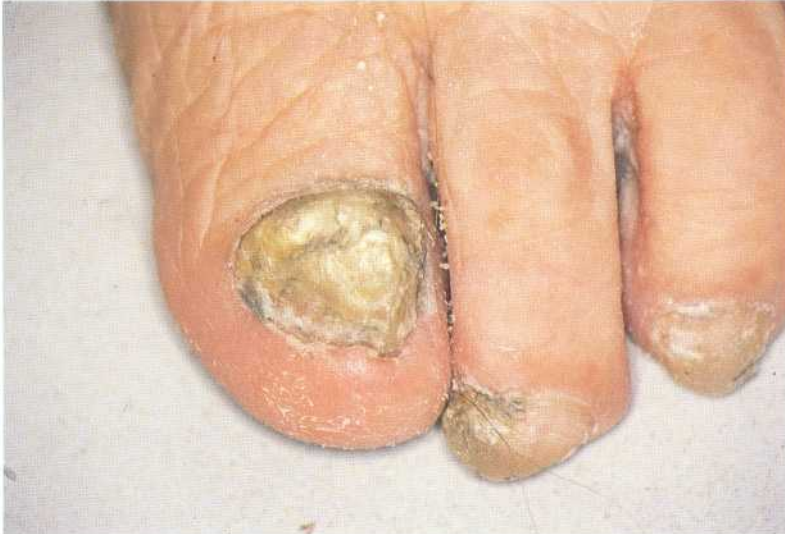

Fig. 23. **Pachyonychia congenita**, thickening of the nails.

### **Pachyonychia Congenita**

Pachyonychia congenita, or Jadassohn-Lewandowsky syndrome, is an autosomal dominant disease. It is characterized by symmetrical thickening of the nails (Fig. 23), palmoplantar hyperkeratosis with hyperhidrosis, blister formation, follicular keratosis, and hyperkeratosis of the oral mucosa. The oral mucosal lesions are almost always present as thick and white or grayish-white areas that usually are located on the palate, dorsum of the tongue, the gingiva, and the buccal mucosa (Fig. 24). These lesions appear at birth or shortly thereafter.

The differential diagnosis should include leukoplakia, lichen planus, white sponge nevus, dyskeratosis congenita, hereditary benign intraepithelial dyskeratosis, and focal palmoplantar and oral mucosa hyperkeratosis syndrome.

Treatment. No treatment is required.

### **Dyskeratosis Congenita**

Dyskeratosis congenita, or Zinsser-Engman-Cole syndrome, is a disorder probably inherited as a recessive autosomal and X-linked trait. It is characterized by hyperpigmentation, telangiectasias, and atrophic areas of the skin (usually on the face, neck, and chest), dystrophic nails (Fig. 25), hyperhidrosis, dermal and mucosal bullae, blepharitis (Fig. 26), ectropion, aplastic anemia, mental handicap, and oral manifestations.

The oral lesions consist of aggregates or recurrent blisters that rupture, leaving a raw ulcerated surface mainly on the tongue and buccal mucosa. Atrophy of the oral mucosa is the result of repeated episodes. Finally, leukoplakia and squamous cell carcinoma may occur (Fig. 27).

The differential diagnosis of the oral lesions should include leukoplakia, lichen planus, pachyonychia congenita, and epidermolysis bullosa.

Laboratory tests somewhat helpful for diagnosis are the blood cell examination and low serum gamma globulin levels.

Treatment is supportive.

Fig. 24. Pachyonychia congenita, grayish-white lesion on the buccal mucosa.

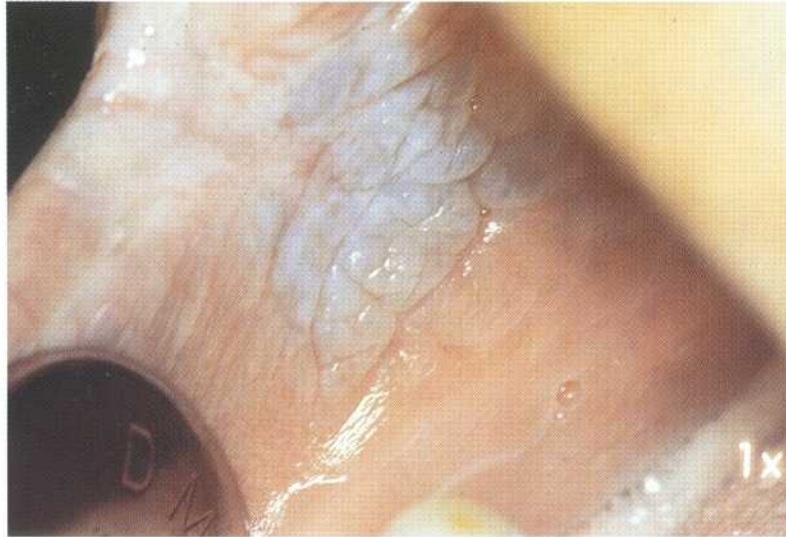

Fig. 25. Dyskeratosis congenita, dystrophic nails.

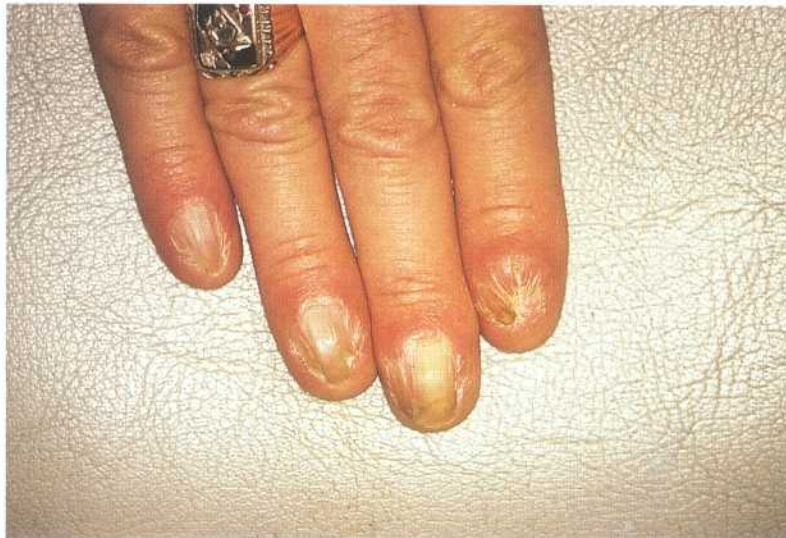
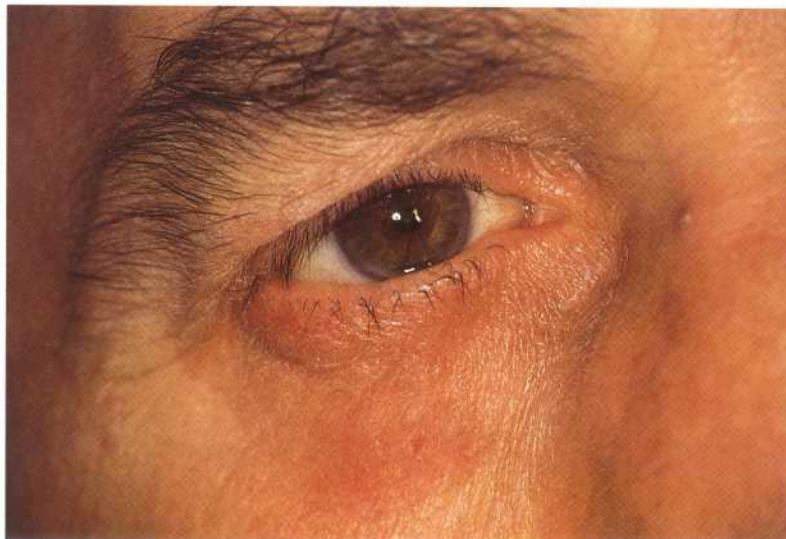
Fig. 26. Dyskeratosis congenita, blepharitis.



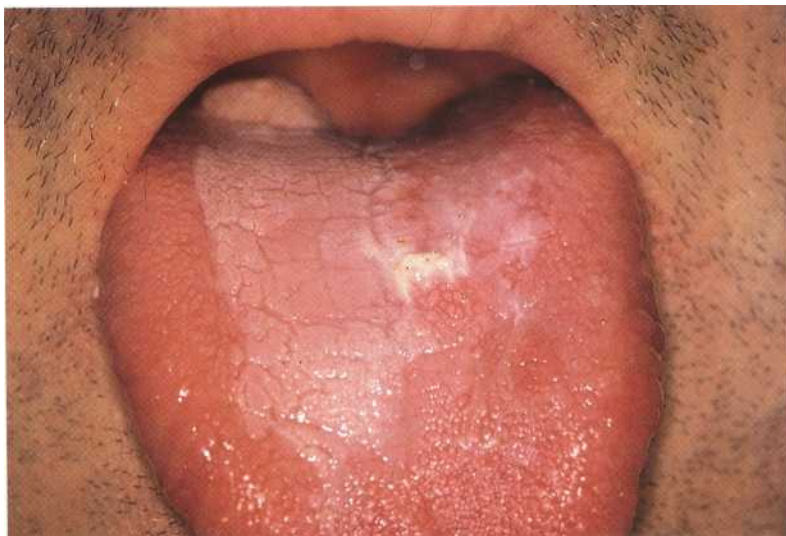

Fig. 27. Dyskeratosis congenita, leukoplakia and verrucous carcinoma of the dorsal surface of the tongue.

### Hypohidrotic Ectodermal Dysplasia

Hypohidrotic ectodermal dysplasia is characterized by dysplastic changes of tissues of ectodermal origin and is usually inherited as an X-linked recessive trait, therefore affecting primarily males. The clinical hallmarks are characteristic facies with frontal bossing, large lips and ears, and a saddle nose (Fig. 28); thin, dry skin and sparse, blond short hair, decreased sweating or complete anhidrosis, due to absence of sweat glands; absence of eyebrows; and oral lesions.

The characteristic finding in the oral cavity is hypodontia or anodontia (Fig. 29). When teeth are present, they are hypoplastic and often have a conical shape. In some cases xerostomia may occur as a result of salivary gland hypoplasia. The disease usually presents during the first year of life, with a fever of unknown cause along with the retarded eruption or absence of the deciduous teeth.

The differential diagnosis includes idiopathic oligodontia, Papillon-Lefevre syndrome, chondroectodermal dysplasia, cleidocranial dysplasia, and focal dermal hypoplasia.

Laboratory tests useful in establishing the diagnosis are dental radiographs and the demonstration of hypohidrosis or anhidrosis.

**Treatment.** There is no specific treatment. However, partial or full dentures must be constructed as early as possible.

### Focal Palmoplantar and Oral Mucosa Hyperkeratosis Syndrome

Focal palmoplantar and oral mucosa hyperkeratosis syndrome is inherited as an autosomal dominant trait. It is also referred as hyperkeratosis palmoplantaris and attached gingival hyperkeratosis and by many other names. The disorder is rare, characterized by focal hyperkeratosis at the weight-bearing and pressure-related areas of the palms, soles, and oral mucosa (Figs. 30, 31). Marked hyperkeratosis of the attached gingiva is a constant finding (Fig. 32). However, other areas bearing mechanical pressure or friction, such as the palate, alveolar mucosa, lateral border of the tongue, retromolar pad mucosa, and the buccal mucosa along the occlusal line may manifest hyperkeratosis, presenting clinically as leukoplakia. The hyperkeratosis appears early in childhood or at the time of puberty. The severity of the hyperkeratotic lesions increases with age and varies among patients, even in the same family. Rarely, hyperhidrosis, hyperkeratosis, and thickening of the nails may be observed.

The differential diagnosis should include pachyonychia congenita, dyskeratosis congenita, Papillon-Lefevre syndrome, and oral leukoplakia and esophageal carcinoma syndrome.

**Treatment.** No reliably successful treatment exists, but aromatic retinoids may occasionally be helpful.

Fig. 28. Hypohidrotic ectodermal dysplasia, characteristic face.

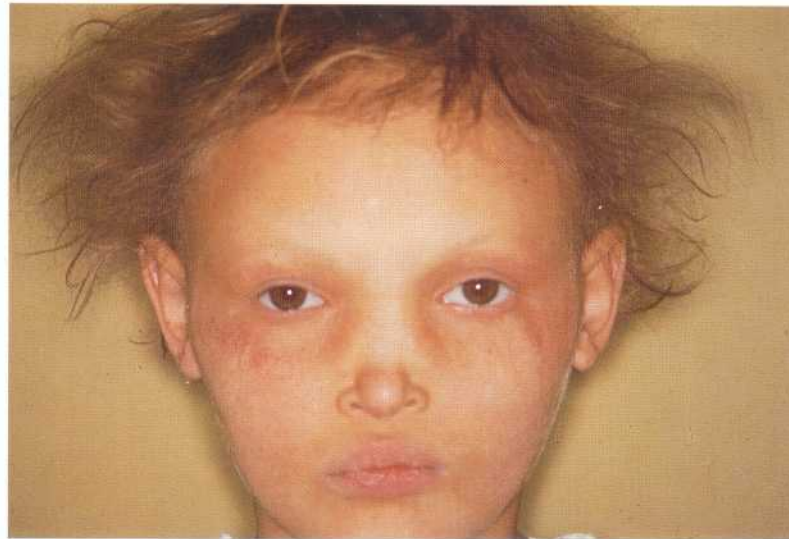

Fig. 29. Hypohidrotic ectodermal dysplasia, anodontia.

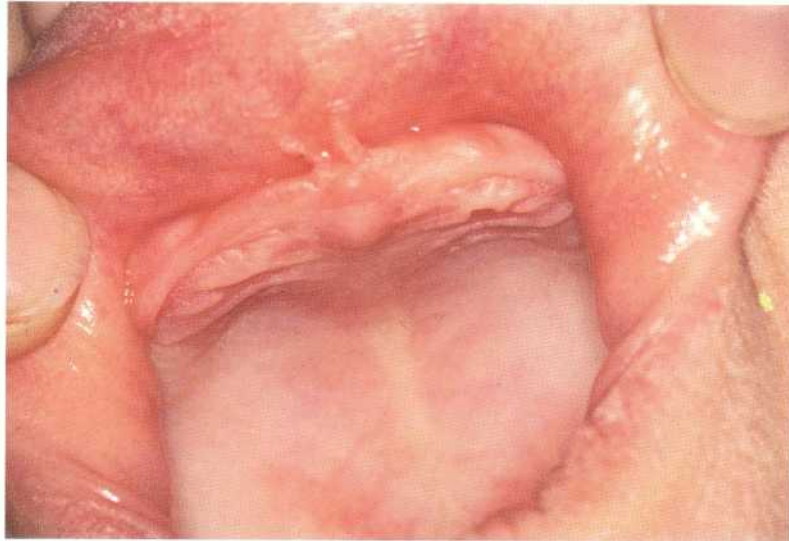
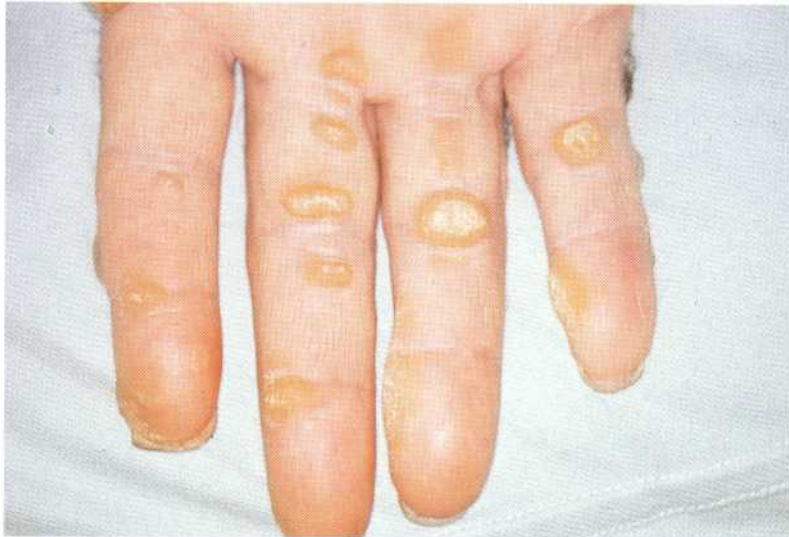

Fig. 30. Focal palmoplantar and oral mucosa hyperkeratosis syndrome, hyperkeratosis of the palm.



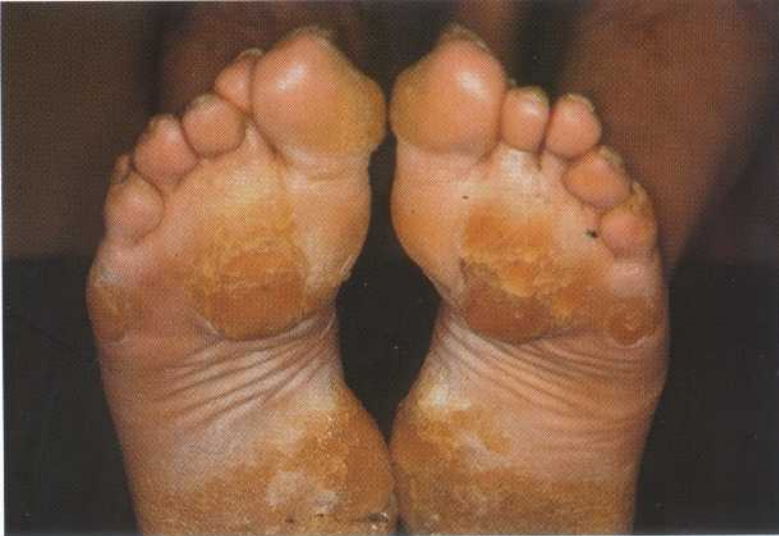

Fig. 31. Focal palmoplantar and oral mucosa hyperkeratosis syndrome, hyperkeratosis of the soles.

### Papillon-Lefevre Syndrome

Papillon-Lefevre syndrome is inherited as an autosomal recessive trait. It is characterized by hyperkeratosis of the palms and soles (Fig. 33), severe destruction of periodontal tissues of both deciduous and permanent dentitions, and meningeal calcifications. Eruption of the deciduous teeth proceeds normally, but inflammation of the periodontal tissues, with periodontal pocket formation and bone destruction, ensues. The severe periodontitis results in premature loss of all the deciduous teeth by about the fourth year of age (Fig. 34). The inflammatory response subsides at this stage and the gingiva resumes its normal appearance. The periodontitis again develops with the eruption of the permanent teeth and results in their loss by the age of 14. The oral mucosa appears normal even during the phase of active periodontal breakdown. The skin lesions usually appear between the second and fourth year of life and consist of well-demarcated, reddened and scaly hyperkeratosis of the palms and soles. Similar scaly red plaques may be seen on the dorsum of the fingers and toes, over the tibial tuberosity, and other areas of the skin.

The differential diagnosis should include juvenile periodontitis, histiocytosis X, acatalasia, hypophosphatasia, hypohidrotic ectodermal dysplasia, focal palmoplantar and oral mucosa hyperkeratosis syndrome, other disorders that are associated with palmoplantar hyperkeratosis, congenital neutropenia, cyclic neutropenia,

agranulocytosis, Chediak-Higashi syndrome, leukemia, and diabetes mellitus.

**Laboratory test.** Panoramic radiography discloses severe periodontal destruction and bone loss. Various immunologic defects have been recorded.

**Treatment.** Keratolytic agents and aromatic retinoids may help in the treatment of skin lesions. Therapy of the periodontal disease is always unsuccessful. However, plaque control, scaling, and oral hygiene instruction are to be recommended.

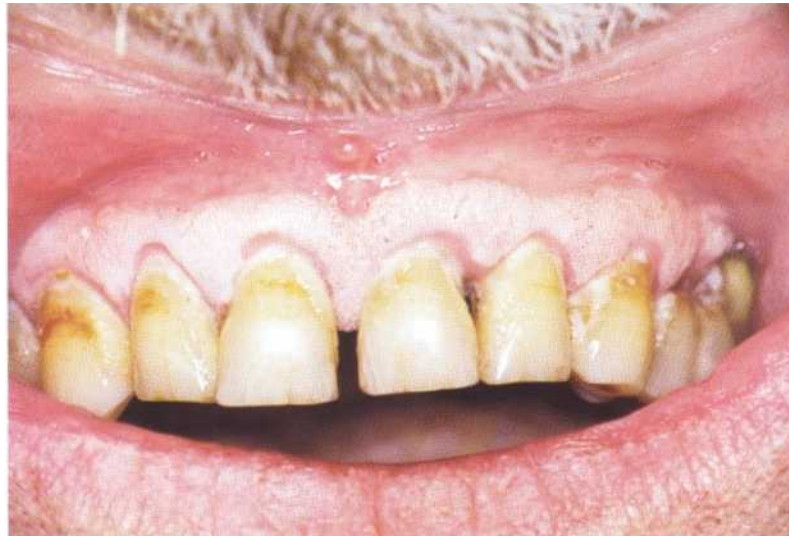

Fig. 32. Focal palmoplantar and oral mucosa hyperkeratosis syndrome, hyperkeratosis of the attached gingiva.

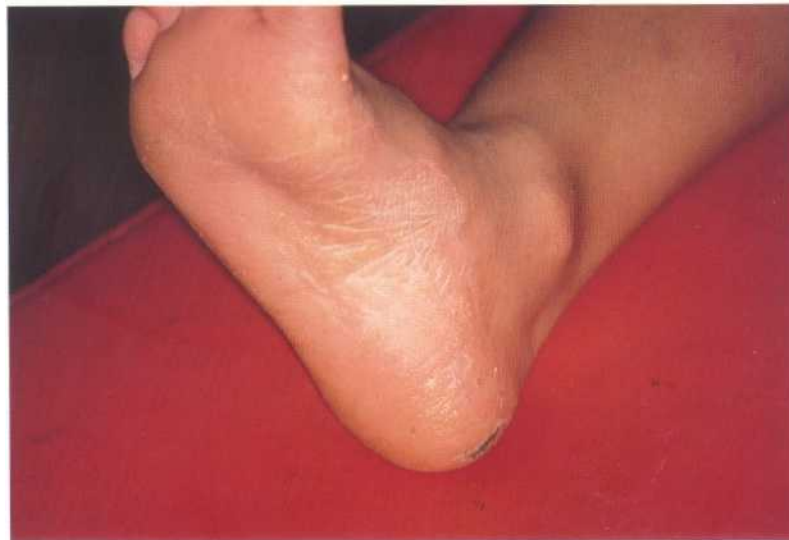

Fig. 33. Papillon-Lefevre syndrome, hyperkeratosis of the sole.

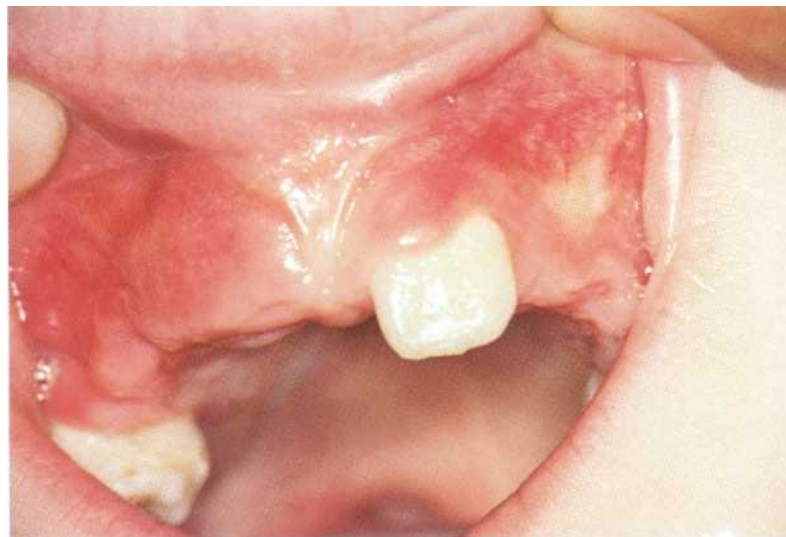

Fig. 34. Papillon-Lefevre syndrome, premature loss of deciduous teeth in a 6-year-old patient.



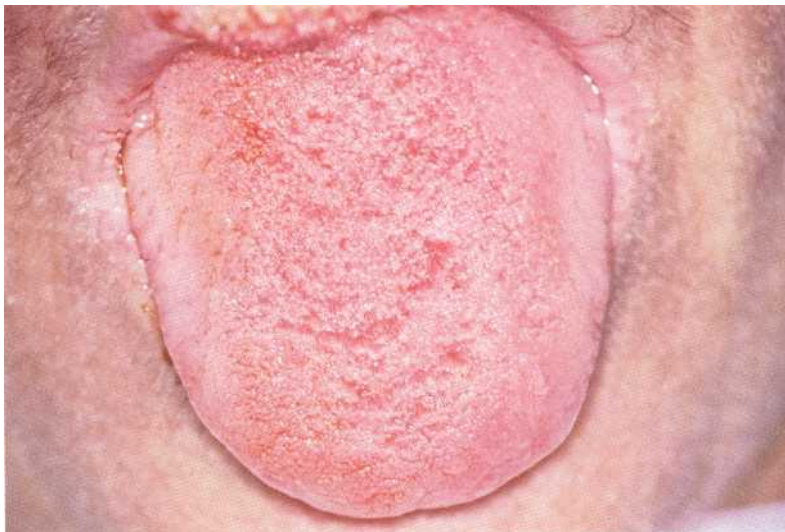

Fig. 35. Benign acanthosis nigricans, hypertrophy and elongation of the filiform papillae of the tongue.

### Benign Acanthosis Nigricans

Acanthosis nigricans is a rare disease involving the skin and mucosae, characterized by dark discoloration and papillary lesions. The disorder is classified into two major types: benign and malignant.

The benign variety is subdivided into: (1) genetic type that is manifested during childhood or early adolescence and rarely affects the oral cavity; (2) acanthosis nigricans that occurs as part of other syndromes, such as Prader-Willi, Crouzon, and Bloom syndromes, insulin-resistant diabetes mellitus, lupoid hepatitis, and hepatic cirrhosis; the syndromal type is manifested during childhood and does not involve the oral mucosa; and (3) pseudoacanthosis, which is an acquired form that affects obese and dark-skinned persons 25 to 60 years of age and involves the skin only.

Malignant acanthosis nigricans is an acquired form that is associated with a malignancy.

The genetic type of benign acanthosis nigricans involves the oral mucosa in about 10 to 15% of the cases. The tongue and lips are very often involved, and rarely the gingiva, buccal mucosa or palate. Clinically, there is hypertrophy and elongation of the filiform papillae, resulting in a shaggy appearance of the tongue (Fig. 35). The lips may be enlarged and covered by papillomatous growths, particularly at the commissures. The skin is thick with small velvety papillary lesions, tags (Fig. 36), and dark pigmentation. The most common sites of involvement are the axillae, neck, groins, umbilicus, perianal area, and the genitalia.

The differential diagnosis includes hairy tongue and malignant acanthosis nigricans.

Laboratory test. Histopathologic findings are indicative but not specific.

Treatment. There is no treatment.

### Dyskeratosis Follicularis

Dyskeratosis follicularis, or Darier-White disease, is an uncommon disorder inherited as an autosomal dominant trait.

It is more frequent in men and is manifested initially during childhood or early adolescence. The disease affects mainly skin and nails, but the mucosae may also be involved (mouth, rectum, genitalia). The scalp, forehead, chest and back, ears, and nasolabial folds are usually affected.

Clinically, multiple skin papules that occasionally may coalesce into large plaques are seen (Fig. 37). They are brownish-red in color and are covered by a yellowish to tan scaly crust. Hypertrophic and ulcerated lesions may also occur. The nails show subungual keratosis and longitudinal ridges and lines. The oral mucosa is affected in 20 to 40% of the cases, but the severity of oral lesions is independent of the activity of the disease in the skin.

The typical oral lesions are small whitish confluent papules, which may coalesce into plaques and become hypertrophic, assuming a cobblestone appearance (Fig. 38). The palate, gingiva, buccal mucosa, and tongue are the most frequent sites of localization. The rectal, vaginal, vulval, and pharyngeal mucosae may also be involved.

Fig. 36. Benign acanthosis nigricans, multiple skin tags.

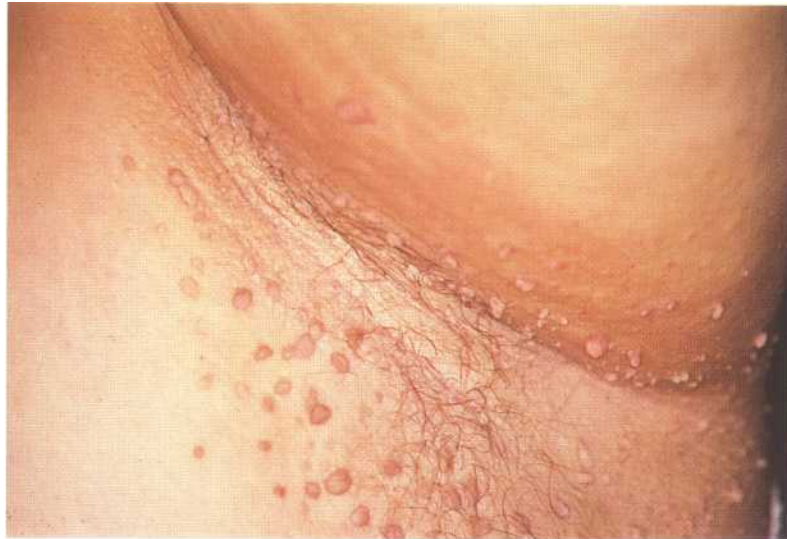

Fig. 37. Dyskeratosis follicularis, multiple skin papules.

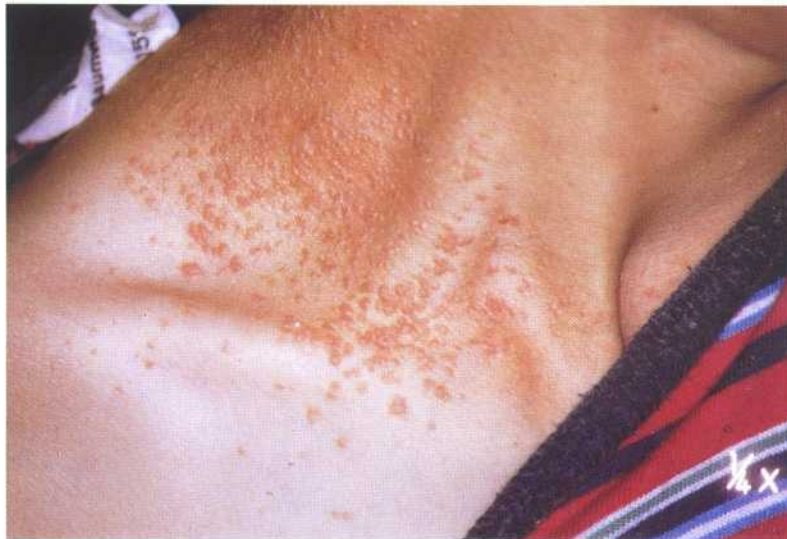
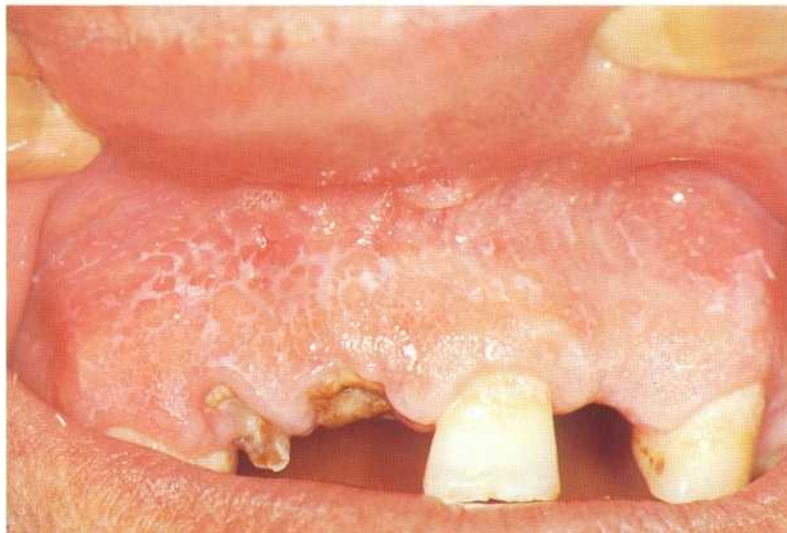
Fig. 38. Dyskeratosis follicularis, multiple whitish confluent papules on the gingiva and alveolar mucosa.



The differential diagnosis includes acanthosis nigricans, papillary hyperplasia of the palate, warty dyskeratoma, and familial benign pemphigus.

**Laboratory test.** Histopathologic examination confirms the diagnosis.

**Treatment.** Vitamin A, retinoid acid, and salicylic acid are helpful.

### Familial Benign Pemphigus

Familial benign pemphigus, or Hailey-Hailey disease, is a rare skin disease inherited as an autosomal dominant trait. Clinically, it is characterized by a recurrent group of small flaccid vesicles arising on an erythematous or normal skin base (Fig. 39). The vesicles rapidly rupture, leaving erosions covered with crusts. The skin lesions are usually localized, with a tendency to spread peripherally, although the center heals with pigmentation or exhibits granular vegetations. Widespread lesions are unusual. The disease appears most frequently on the axillae, the groin, the neck, the perianal region, and the trunk. Nail changes may occur.

The oral mucosa is rarely affected and always after the skin involvement. The oral lesions consist of groups of small vesicles that rupture easily, leaving denuded localized areas covered with pseudomembranes (Fig. 40).

The disease usually begins between the second to third decade and has a good prognosis, although the clinical course is characterized by remissions and exacerbations and shows little tendency for improvement.

The differential diagnosis should include pemphigus, dyskeratosis follicularis, and rarely bullous and cicatricial pemphigoid and transient acantholytic dermatosis.

**Laboratory test.** Histopathologic examination supports the clinical diagnosis.

**Treatment.** Topical application of steroid and antifungal or antibacterial ointments or creams are of value in cases with secondary infection of the oral lesions. Systemic steroids are used only in severe cases.

### Epidermolysis Bullosa

Epidermolysis bullosa is a group of inherited disorders characterized by bullae formation on the skin and mucous membranes spontaneously or after mechanical friction. Based on clinical, his-

topathologic, biochemical, ultrastructural, and genetic criteria the disorder falls into three major groups: nondystrophic, atrophic, and dystrophic.

In the nondystrophic subgroup is epidermolysis bullosa simplex, which includes several varieties. It is inherited as an autosomal dominant trait and begins at birth or early infancy. It is characterized by nonscarring generalized or localized bullae as a result of mechanical friction. The nails are spared. In the oral mucosa a few bullae may rarely occur, leaving erosions that heal without scarring (Fig. 41). The dentition is normal.

In the atrophic subgroup belong junctional epidermolysis bullosa, which is also called epidermolysis bullosa letalis, and generalized atrophic benign epidermolysis bullosa.

Both types are inherited as autosomal recessive traits. Lesions begin at birth or shortly after and consist of generalized bullae formation, which heal without scarring. The nails are involved. The oral mucosa shows bullae, severe ulcerations, and dysplastic teeth in the junctional type and mild lesions in the generalized atrophic benign type.

The prognosis is unfavorable for the first variety and good for the generalized atrophic benign type.

In the dystrophic subgroup belong dominant dystrophic epidermolysis bullosa and recessive dystrophic epidermolysis bullosa. Oral mucosal lesions are more common (about 50%) and severe in the recessive type. Clinically, bullae occur in areas of friction, which rupture leaving ulcers and scarring after the acute eruption. The tongue becomes depapillated and scarred (Fig. 42). Oral mucosal hyperplasia forming vegetating lesions, particularly on the palate, may be seen.

The teeth are usually dysplastic. Finally, leukoplakia, and squamous cell carcinomas may develop on the scars. The pharynx, larynx, esophagus, and anus are commonly affected. Generalized skin bullae leaving ulcerations that heal with scarring and milia formation are common in the recessive dystrophic type. The lesions are more often found on the hands, feet, knees, and elbows.

Dystrophy and loss of the nails are common (Fig. 43). In both types the lesions appear first at birth or infancy.

The prognosis is relatively good.

The differential diagnosis should include pemphigus, bullous pemphigoid, linear IgA disease, bullous erythema multiforme, dermatitis herpetiformis, cicatricial pemphigoid of childhood, and bullous dermatoses of childhood.

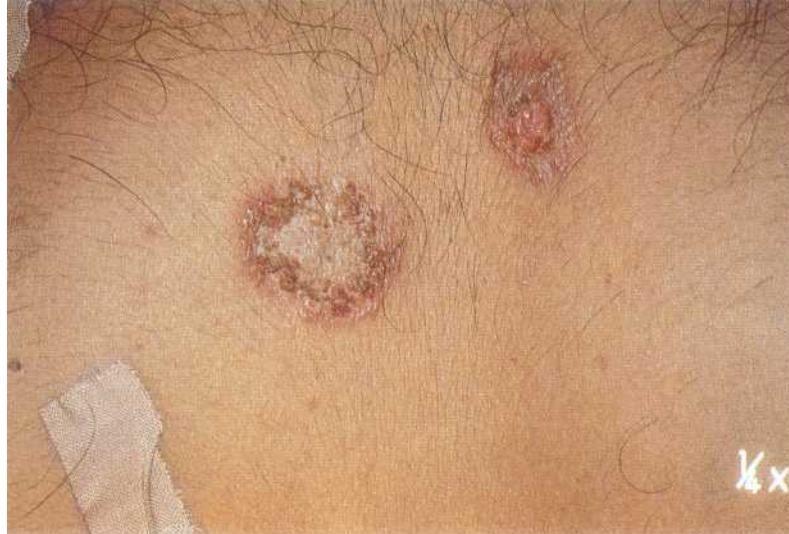

Fig. 39. Familial benign pemphigus, skin lesions.

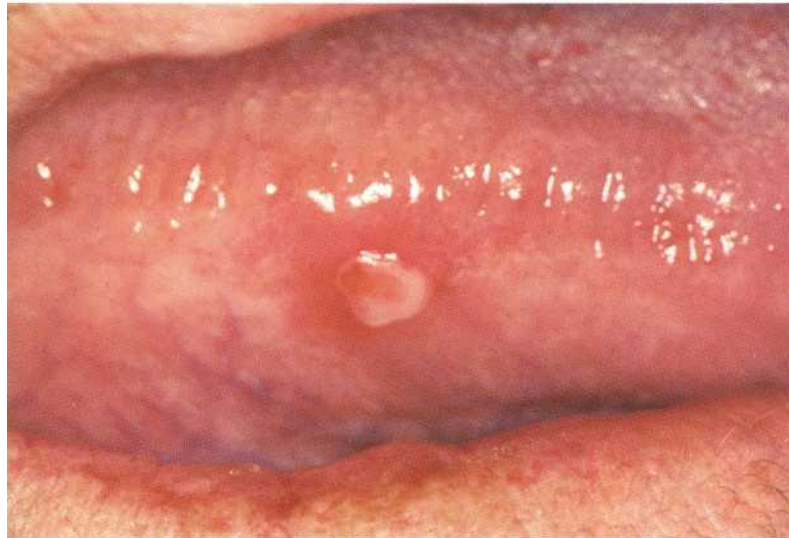

Fig. 40. Familial benign pemphigus, erosion on the tongue.

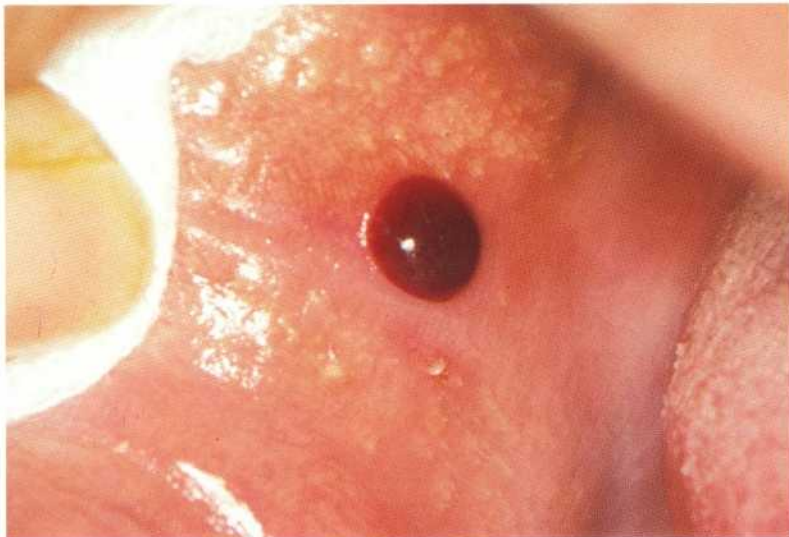

Fig. 41. Epidermolysis bullosa simplex, hemorrhagic bulla on the buccal mucosa.

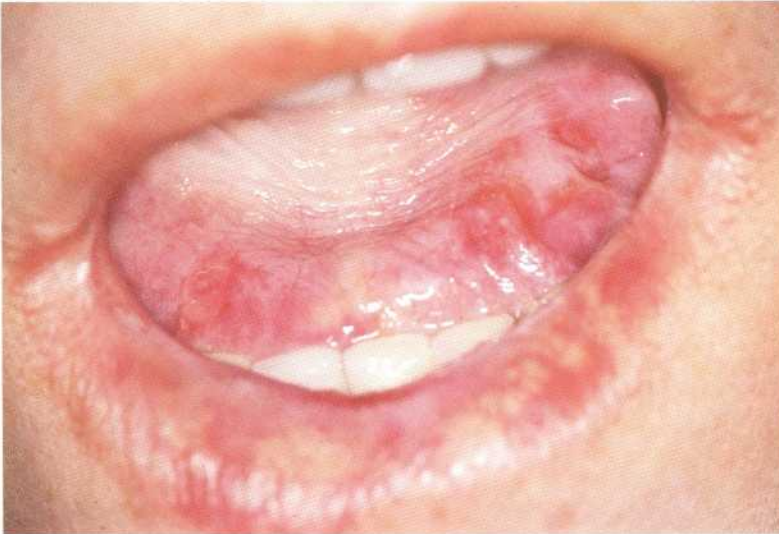

Fig. 42. Epidermolysis bullosa, recessive dystrophic, depapillated and scarred tongue.

Laboratory test. Histopathologic examination is important to establish the final diagnosis of different groups of epidermolysis bullosa.

Treatment. Therapy is nonspecific. Symptomatic topical therapy (antibiotics, steroids), systemic steroids, vitamin E, phenytoin, and retinoids have been used in severe cases.

### Neurofibromatosis

Neurofibromatosis, or von Recklinghausen's disease, is a genetic disorder inherited as an autosomal dominant trait. The disease is characterized by cafe-au-lait spots (more than 6 spots over 1.5 cm in diameter are very suspicious of the disease), central nervous system manifestations, skeletal disorders, multiple neurofibromas, neurosarcomas in 3 to 12% of the cases, and endocrine disorders (such as pheochromocytoma).

The cardinal features of the disease are the cafe-au-lait spots and the skin neurofibromas. They usually appear during or after childhood. The skin neurofibromas are multiple and may be either cutaneous or subcutaneous (Fig. 44). The oral cavity is uncommonly affected but may exhibit multiple or, rarely, isolated nodular neurofibromas, which vary in size (Fig. 45).

The tongue, alveolar mucosa, and palate are the most commonly affected sites. Malignant transformation of oral neurofibromas is very rare. Involvement of the mandible and maxilla is also extremely rare.

The differential diagnosis should include multiple mucosal neuromas, multiple endocrine neoplasia type III syndrome, and the Klippel-Trenaunay-Weber syndrome.

Laboratory test. Histopathologic examination of oral and skin neurofibromas is helpful in establishing the diagnosis.

Treatment. Treatment is supportive and presents many problems for the dermatologist, surgeon, and endocrinologist.

Fig. 43. Epidermolysis bullosa, recessive dystrophic, scarring, dystrophy and loss of the fingernails.

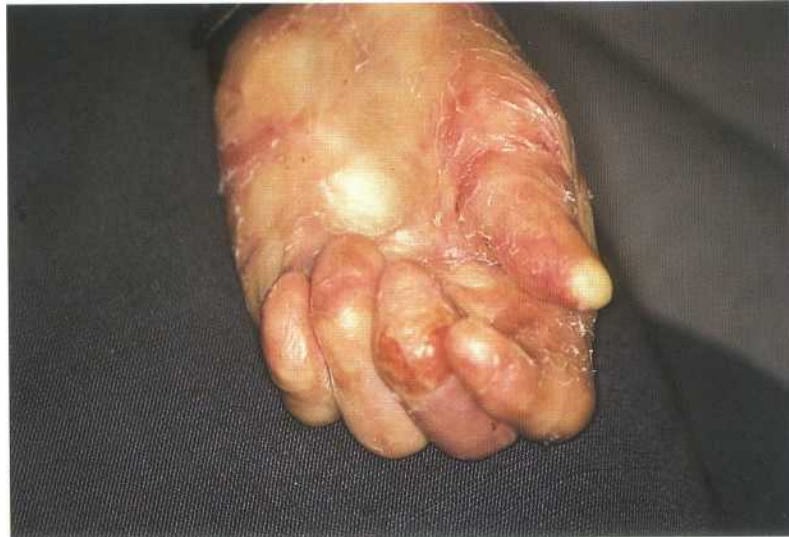

Fig. 44. Neurofibromatosis, multiple cutaneous neurofibromas.

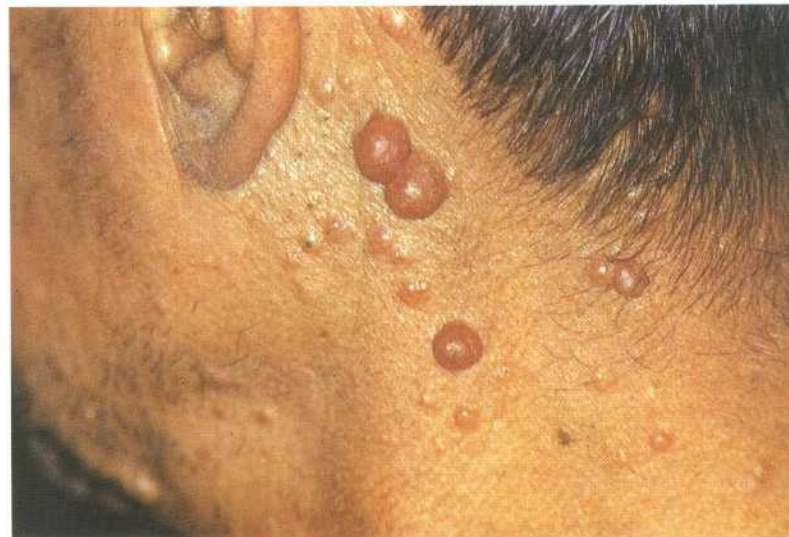
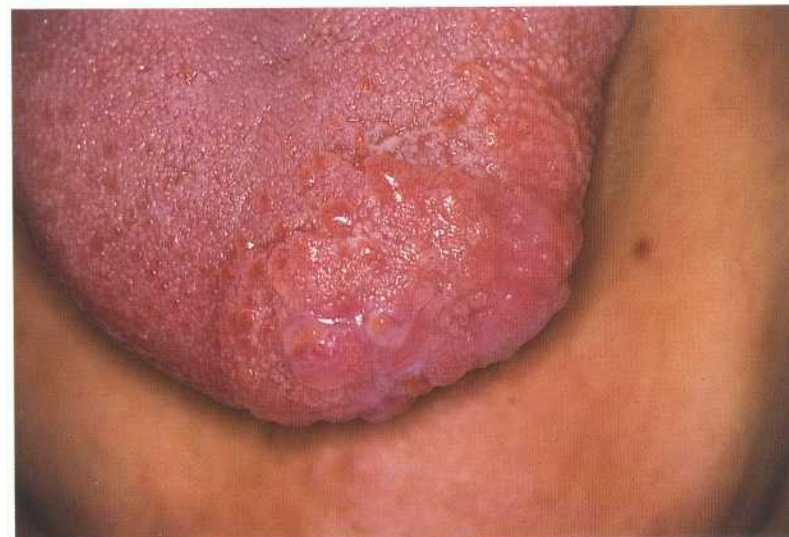
Fig. 45. Neurofibromatosis, multiple neurofibromas of the tongue.



### Chondroectodermal Dysplasia

Chondroectodermal dysplasia, or Ellis-van Creveld syndrome, is inherited as an autosomal recessive trait. The main characteristics are bilateral polydactyly, chondrodysplasia of long bones, involvement of ectodermal tissues (hair, nails, teeth), and, rarely, congenital heart disease.

The most constant oral finding is fusion of the upper or lower lip to the gingiva, resulting in the disappearance of the mucolabial fold or multiple fibrous bands (Fig. 46). Oligodontia and small conical teeth with enamel hypoplasia are also present.

The differential diagnosis includes oro-facial digital syndrome, acrofacial dysostosis of Weyers, other forms of chondrodystrophies.

Treatment is supportive.

### Hereditary Hemorrhagic Telangiectasia

Hereditary hemorrhagic telangiectasia or Osler-Renderu-Weber disease is inherited as an autosomal dominant trait.

Characterized by dysplasia of the capillaries and small vessels, the disease usually develops during adolescence and affects both sexes. The cardinal manifestations are mucosal, cutaneous, and internal organ (liver, spleen, stomach) telangiectases. Morphologically, three varieties of telangiectases have been described: microscopic lesions of less than a millimeter in diameter, nodules, and spiderlike lesions.

These lesions have a bright red, purple, or violet color and disappear on pressure with a glass slide. The oral mucosa is frequently involved with multiple lesions on the lip and the dorsum of the tongue (Fig. 47). The palate, buccal mucosa, and gingiva may be less frequently involved. Hemorrhage from oral lesions is frequent after minimal mechanical damage, such as tooth brushing.

Epistaxis and gastrointestinal bleeding are early, common, and occasionally serious complications.

The differential diagnosis includes varicosities of the tongue, Maffucci's syndrome, CREST syndrome, and Fabry's disease.

Laboratory test. Histopathologic examination confirms the clinical diagnosis.

Treatment. Control of spontaneous hemorrhage. The angiomatous lesions may sometimes be excised surgically, cauterized, or treated with the cryoprobe.

### Peutz-Jeghers Syndrome

Peutz-Jeghers syndrome is transmitted as an autosomal dominant disorder with a high degree of penetrance, characterized by intestinal polyposis and mucocutaneous pigmented spots. The manifestations, which may be apparent at any age, include intestinal polyps (hamartomas) 0.5 to 7 cm in diameter and pigmented spots. About 50% of the patients have numerous dark spots on the perioral skin, the nose, and around the eyes. Similar spots may occur in other regions.

Pigmented spots 1 to 10 mm in diameter are always found in the oral mucosa, particularly on the lower lip and the buccal mucosa, but rarely on the upper lip, the tongue, the palate, and the gingiva (Fig. 48). Oral pigmentation constitutes the most important diagnostic finding and appears in the form of oval, round, or irregular brown or black spots or patches.

The differential diagnosis includes Addison's disease, Albright's syndrome, Gardner's syndrome, simple freckles, and normal pigmentation.

Laboratory test. Radiologic evaluation of the gastrointestinal tract is helpful in establishing the diagnosis.

Treatment. Supportive treatment of gastrointestinal bleeding.

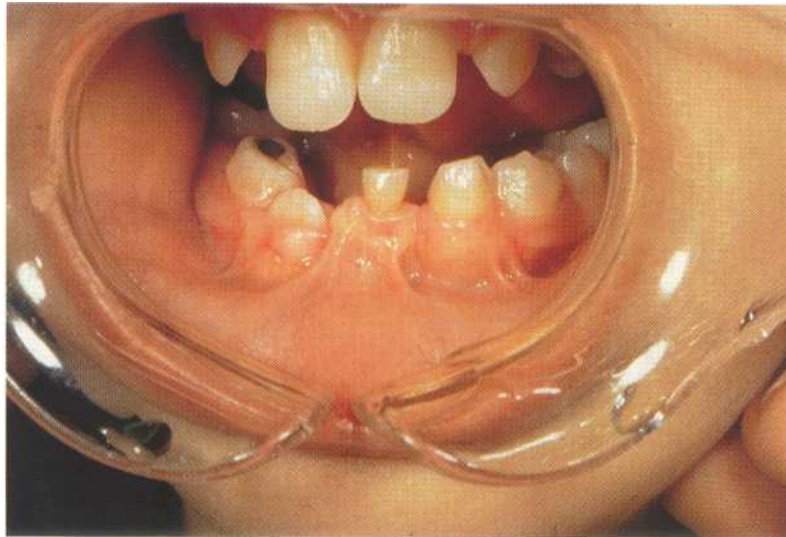


Fig. 46. Chondroectodermal dysplasia, disappearance of the mucolabial sulcus and multiple fibrous bands.

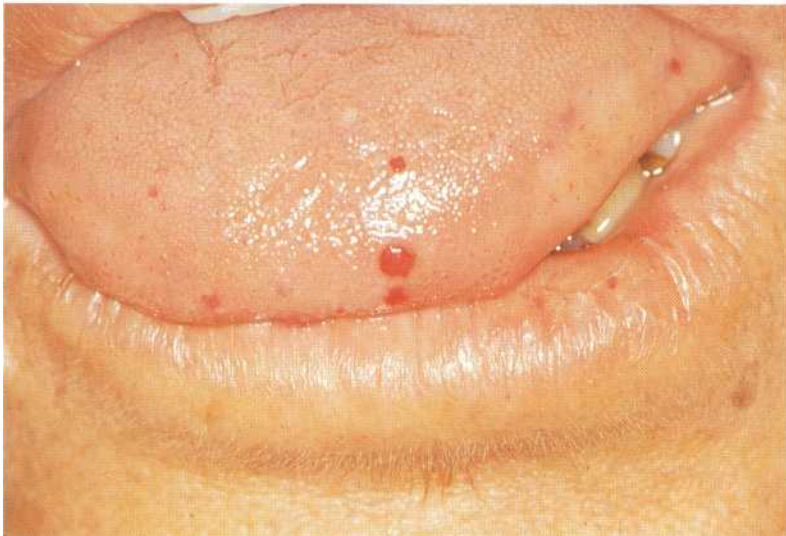

Fig. 47. Hereditary hemorrhagic telangiectasia, multiple lesions on the tongue.

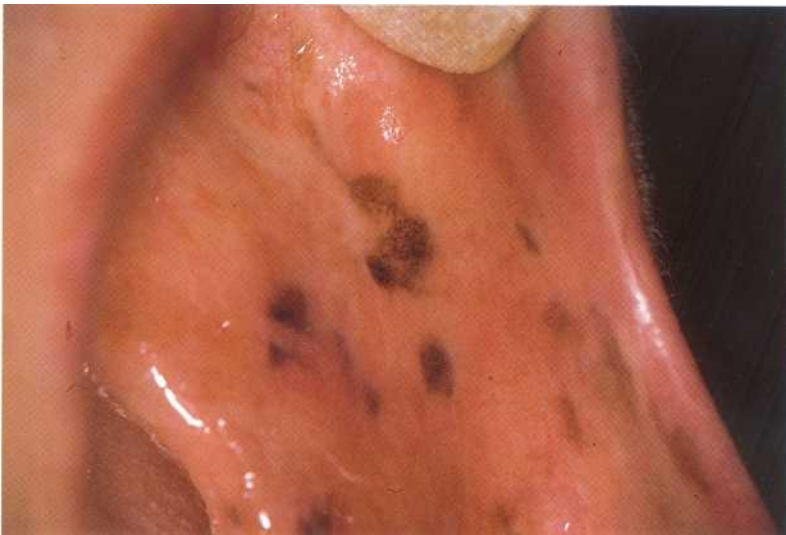

Fig. 48. Peutz-Jeghers syndrome, multiple pigmented spots on the buccal mucosa.



### **Gardner's Syndrome**

Gardner's syndrome is an autosomal dominant disorder characterized by intestinal polyposis, mainly of the colon, multiple osteomas, other bony abnormalities, soft tissue tumors and skin cysts. The skin lesions are epidermal and sebaceous cysts, subcutaneous fibromas and other fibrous tissue disorders, and rarely increased skin pigmentation. Multiple osteomas are a common finding usually located at the facial bones and the calvaria. Oral manifestations include multiple osteomas of the jaws (Fig. 49), supernumerary and impacted teeth, odontomas, and rarely benign fibrous soft tissue tumors (Fig. 50). The oral lesions are innocent but intestinal polyps have a high potential for malignant transformation.

The differential diagnosis includes exostoses, other bone tumors, Peutz-Jeghers syndrome, Cowden's syndrome, and other syndromes associated with multiple intestinal polyposis.

**Laboratory test.** Radiographic or endoscopic examination of the intestinal tract is mandatory. Bone lesions are detected radiographically. Histopathologic examination of soft and hard tissue tumors is also helpful.

**Treatment.** The treatment of osteomas and other soft tissue tumors and cysts is surgical excision.

### **Maffucci's Syndrome**

Maffucci's syndrome is a rare disease of uncertain cause. It is not clear whether it represents an inherited disorder or a dysplasia. Both sexes may be affected. Clinical characteristics include multiple enchondromas, principally in the small bones of the hands and feet, although any bone of cartilaginous origin may be affected; multiple hemangiomas localized on the skin, mucosae, and viscera; phleboliths; and pigmented skin macules. The oral mucosa is rarely affected and the oral lesions usually are multiple hemangiomas. The tongue is the most frequent site of hemangiomas, but the buccal mucosa, lips, soft palate, and other oral regions can also be involved (Fig. 51). In a recent review only 8 of 110 cases were found to have oral hemangiomas.

Chondrosarcomas, hemangiosarcomas, and multiple fractures may be the most severe complications of the disease.

The diagnosis should be based on clinical and histopathologic evidence.

The differential diagnosis includes hemangiomas, Ollier's disease, the blue rubber bleb nevus syndrome, and the Klippel-Trenaunay-Weber syndrome.

**Laboratory tests.** Histopathologic and radiographic examinations confirm the diagnosis.

**Treatment.** Surgical excision of the enchondromas and hemangiomas may be attempted if they are symptomatic.

Fig. 49. Gardner's syndrome, osteoma of the mandible.

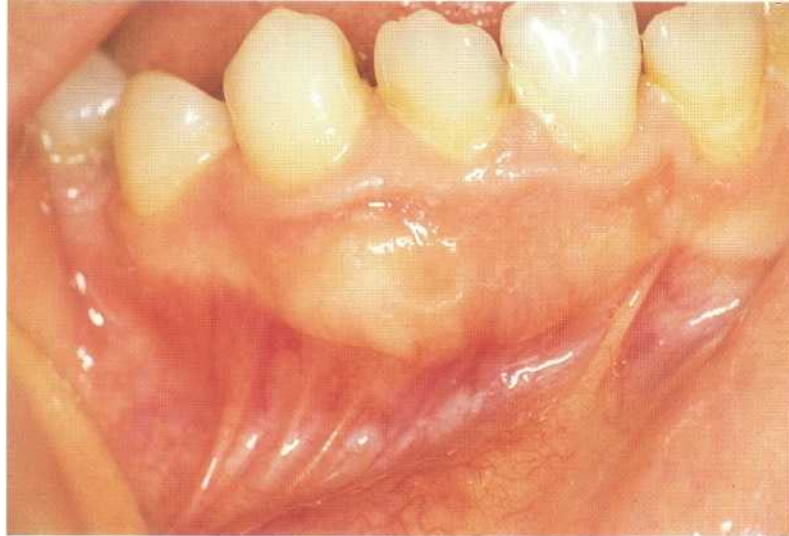

Fig. 50. Gardner's syndrome, multiple fibrous tumors on the tongue.

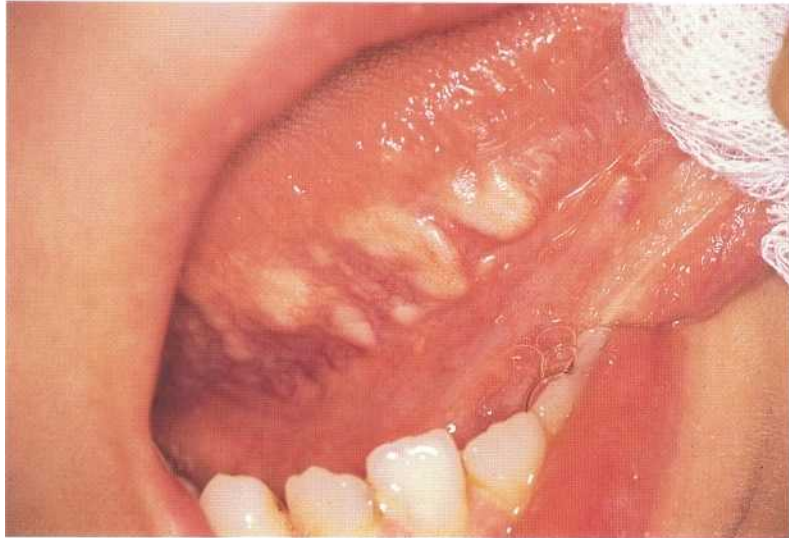
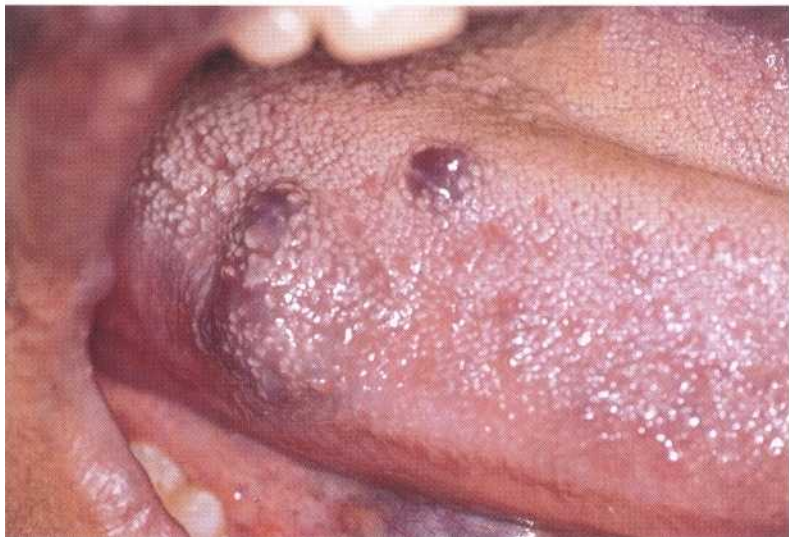

Fig. 51. Maffucci's syndrome, multiple hemangiomas of the tongue.



## Tuberous Sclerosis

Tuberous sclerosis, or Bourneville-Pringle syndrome, is transmitted as an autosomal dominant trait. It is characterized by epilepsy, mental handicap, paraventricular calcifications, multiple small gliomas, mucocutaneous manifestations, skeletal disorders, and, rarely, ophthalmic tumors. The disease affects equally both sexes and usually presents between the ages of 2 and 6 years. Many patients die by the age of 20 years.

Characteristic lesions occur on the face, principally along the nasolabial fold and cheeks. These are numerous small nodules, red to pink in color, which are actually angiofibromas, although the prevailing term is "adenoma sebaceum" (Fig. 52). Other cutaneous changes are white macules (maple leaf or ash leaf), cafe-au-lait spots, skin tags, and multiple periungual fibromas (Fig. 53). The oral mucosa may be involved in about 10% of the cases. The gingiva or other parts of the oral mucosa may exhibit confluent nodules a few millimeters to less than 1 cm in diameter, which are of whitish or normal color (Fig. 54). Enamel pits may also occur.

The differential diagnosis of oral lesions should include multiple fibromas, multiple condylomata acuminata, focal epithelial hyperplasia, and neurofibromatosis.

**Laboratory test.** Histopathologic examination of skin and oral mucosa lesions and skull radiographs are helpful in the diagnosis. The epilepsy should be evaluated by electroencephalography.

**Treatment.** There is no specific therapy, but anti-convulsive drugs may be required.

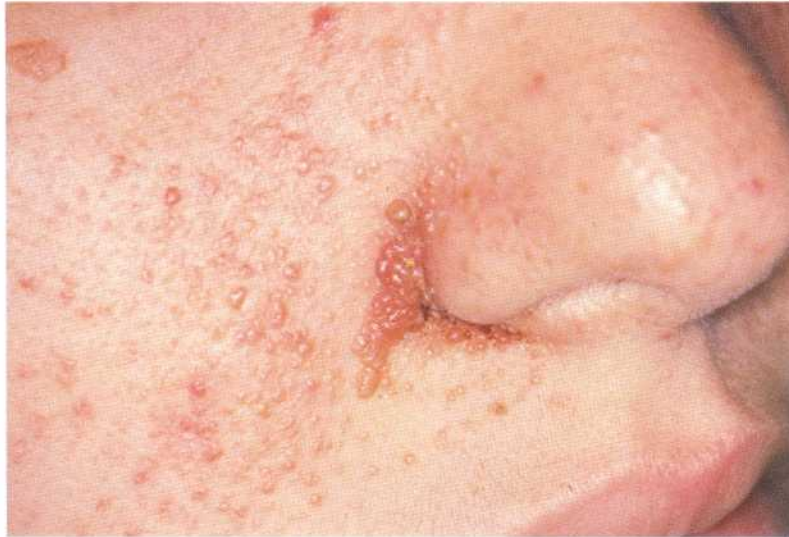

Fig. 52. Tuberous sclerosis, numerous facial angiofibromas (adenoma sebaceum).

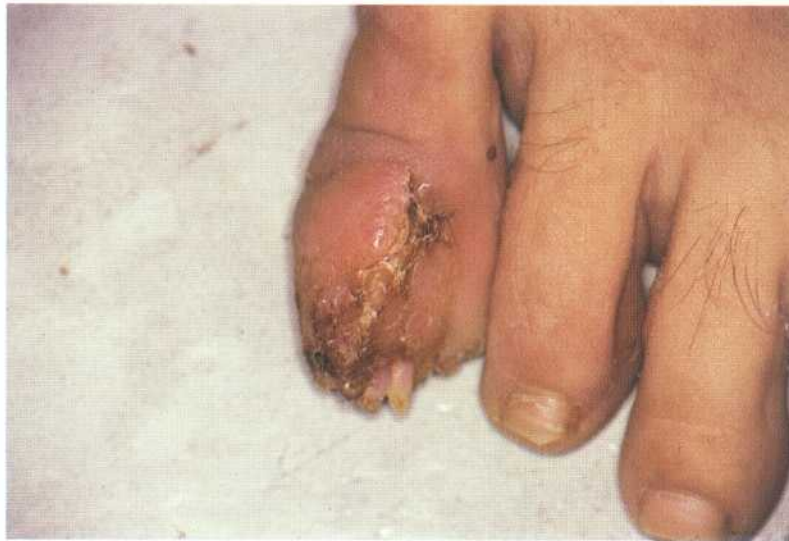

Fig. 53. Tuberous sclerosis, periungual fibromas.

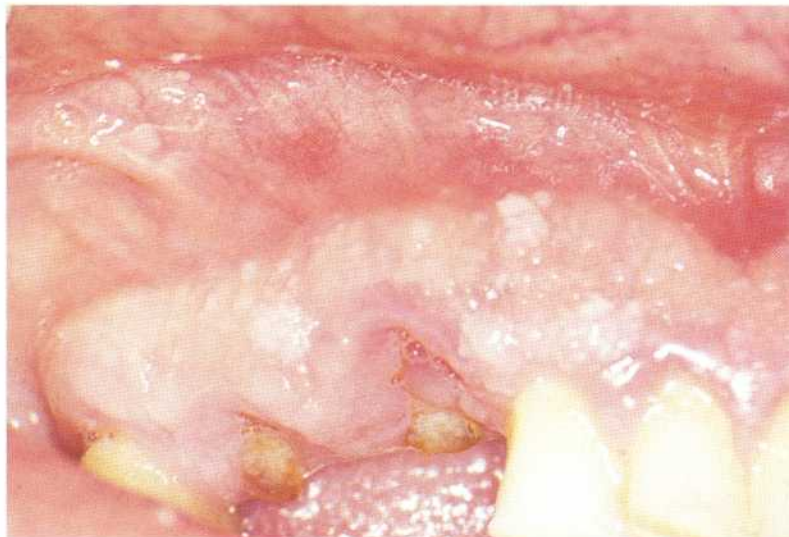

Fig. 54. Tuberous sclerosis, confluent whitish nodules on the gingiva and the alveolar mucosa.

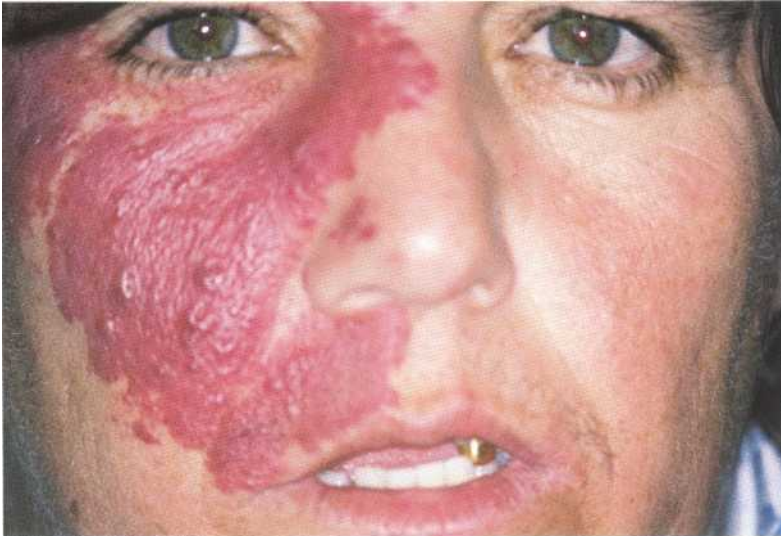

Fig. 55. Sturge-Weber syndrome, facial hemangioma.

### Sturge-Weber Syndrome

Sturge-Weber syndrome is a sporadic congenital dysplasia. Both sexes may be affected. It is characterized by hemangiomas of the face and oral mucosa, and of the leptomeninges, calcification of the brain, ocular disorders, epilepsy, and mild mental handicap.

The facial hemangioma is the most constant finding and is apparent at birth. It is unilateral, has a bright red or purple color, and is confined roughly to the area supplied by the trigeminal nerve (Fig. 55). Hemangiomas of the oral mucosa are unilateral, rarely cross the midline, and may involve the upper gingiva, buccal mucosa, lips, and tongue (Fig. 56). These lesions have a bright red or purple color and a usually flat but may also have a raised irregular surface that causes tissue enlargement. The ipsilateral permanent teeth may erupt early and may be ectopic, although delayed tooth eruption may also occur. Care must be taken during tooth extractions because hemorrhage may be severe. When the classic signs and symptoms are present, the diagnosis of Sturge-Weber syndrome is apparent.

The differential diagnosis includes large disseminated hemangiomas and the Klippel-Trenaunay-Weber syndrome.

Laboratory tests helpful in diagnosis and management are angiography, electroencephalography, skull radiographs, and computed tomography.

**Treatment.** The therapy is guided by the symptoms and is supportive.

### Klippel-Trenaunay-Weber Syndrome

Klippel-Trenaunay-Weber syndrome, or angio-osteohypertrophy, is a rare dysplastic vascular disorder. It is characterized by multiple facial hemangiomas (Fig. 57), vascular masses that involve soft tissues and bone and are accompanied by asymmetric enlargement of the extremities, vascular cutaneous lesions, ocular disorders (scleral pigmentation, cataract, glaucoma, and iris heterochromia) (Fig. 58), hemangiomas in internal organs, and oral hemangiomas. Clinically, the oral hemangiomas are usually located on the soft and hard palates and gingiva, which may be enlarged (Fig. 59). Premature tooth eruption and bony overgrowth may produce malocclusion.

The differential diagnosis includes Sturge-Weber syndrome, Maffucci's syndrome, and large isolated hemangiomas.

Treatment is supportive.

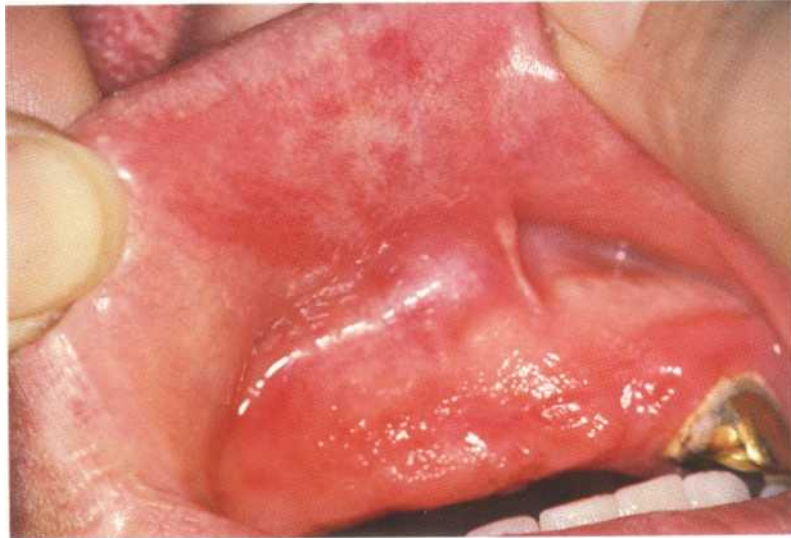

Fig. 56. Sturge-Weber syndrome, oral hemangioma.

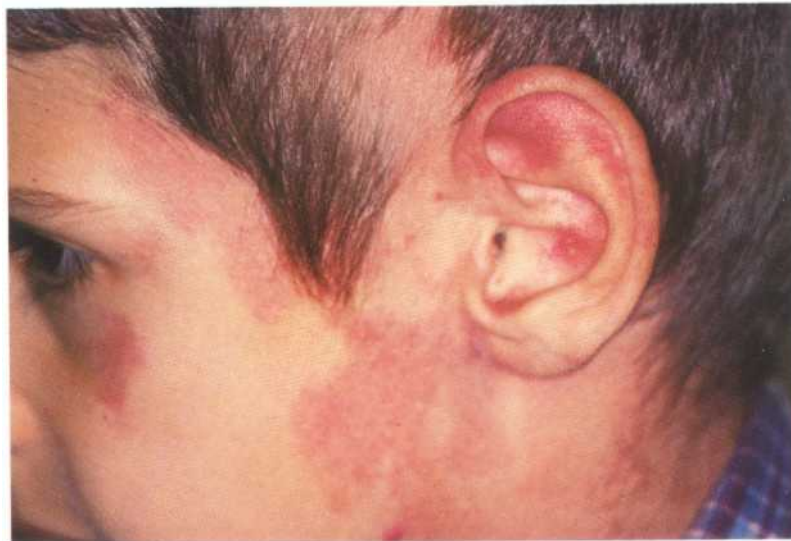

Fig. 57. Klippel-Trenaunay-Weber syndrome, facial hemangiomas.

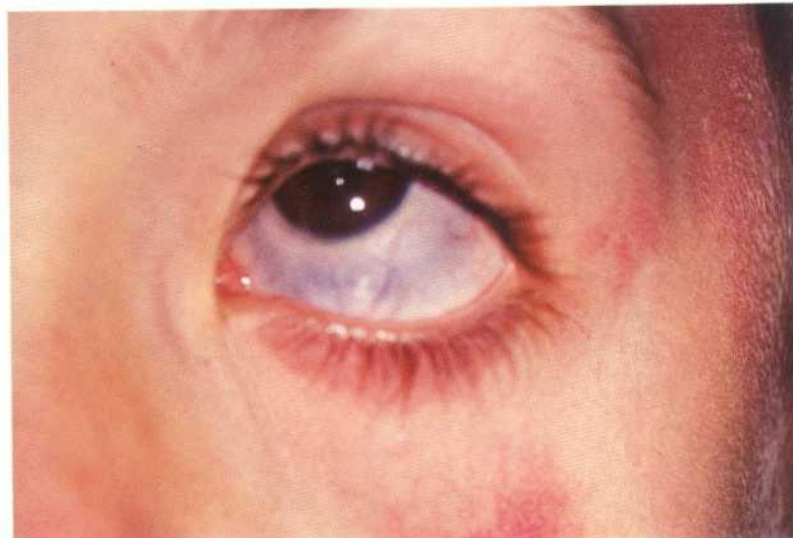

Fig. 58. Klippel-Trenaunay-Weber syndrome, ocular pigmentation.

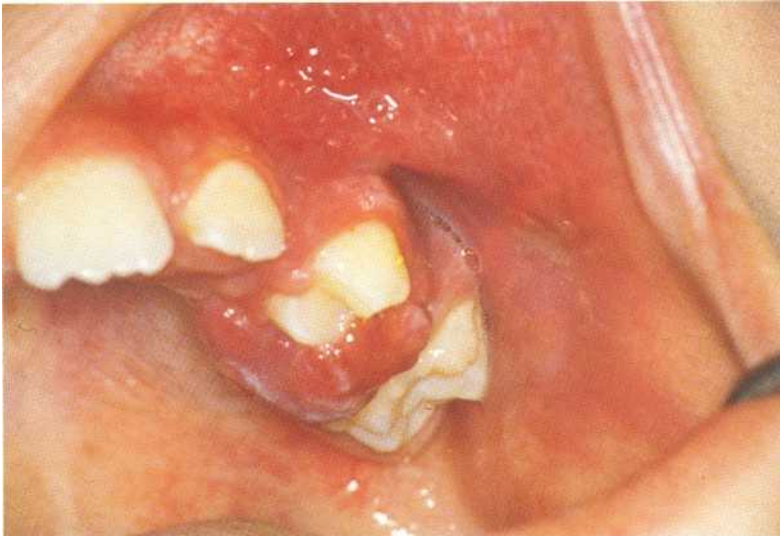

Fig. 59. Klippel-Trenaunay-Weber syndrome, oral hemangiomas.

### Cowden's Disease

Cowden's disease is an autosomal dominant disorder characterized by multiple hamartomas and cancers of the breast, thyroid, and other organs. The cutaneous manifestations are multiple hamartomatous papules, and nodules.

Oral lesions consist of small whitish papules or nodules that may be isolated or coalesce in a cobblestone pattern, usually on the gingiva (Fig. 60).

The differential diagnosis includes tuberous sclerosis, multiple mucosal neuromas, endocrine neoplasia type III syndrome, and malignant acanthosis nigricans.

Laboratory test. Histopathologic examination is helpful in establishing the diagnosis.

Treatment. No treatment is available.

### Cleidocranial Dysplasia

Cleidocranial dysplasia is transmitted as an autosomal dominant trait. It is characterized by unilateral or bilateral hypoplasia or complete absence of the clavicles (as a result the patient has the capability of approximating his or her shoulders) (Fig. 61), skull abnormalities (delayed closure or open fontanelles, open sutures, large skull, broad flat nose), exophthalmos, deafness, and oral lesions. The oral manifestations consist of a high, narrow angulated palate, delayed eruption or noneruption of the deciduous and permanent teeth, and supernumerary unerupted permanent teeth (Fig. 62). The teeth may be malformed. Periodontal disease is commonly found.

The differential diagnosis includes hypohidrotic ectodermal dysplasia, focal dermal hypoplasia, craniofacial dysostosis, and Apert's syndrome.

Laboratory test. Radiographic examination is helpful for the diagnosis.

Treatment. No treatment is available. Dental care is essential.

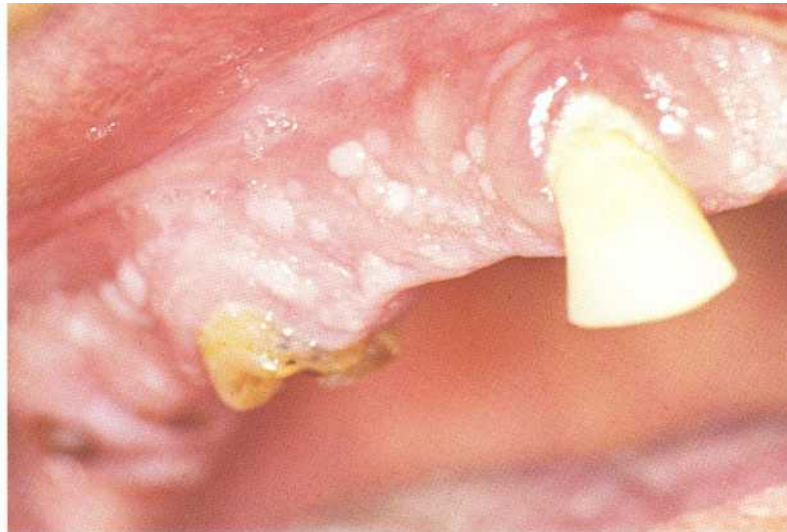


Fig. 60. Cowden's disease, multiple whitish nodules on the alveolar mucosa.

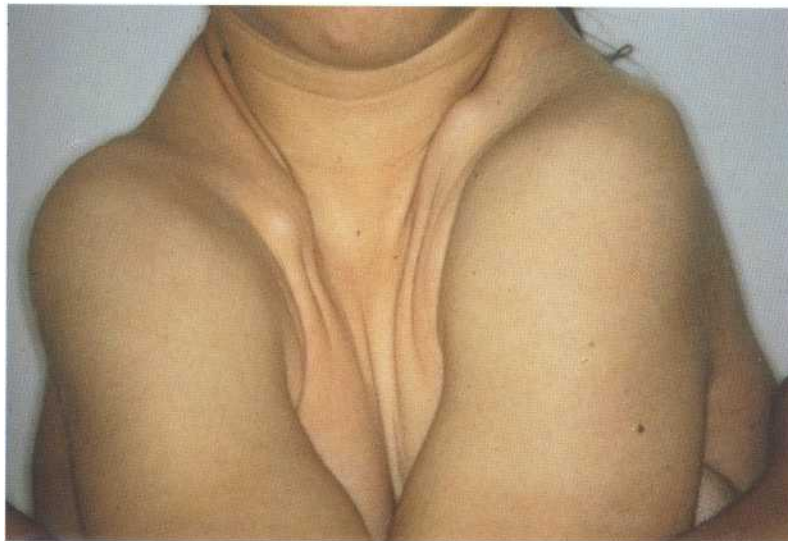

Fig. 61. Cleidocranial dysplasia, hypermobility of the shoulders.

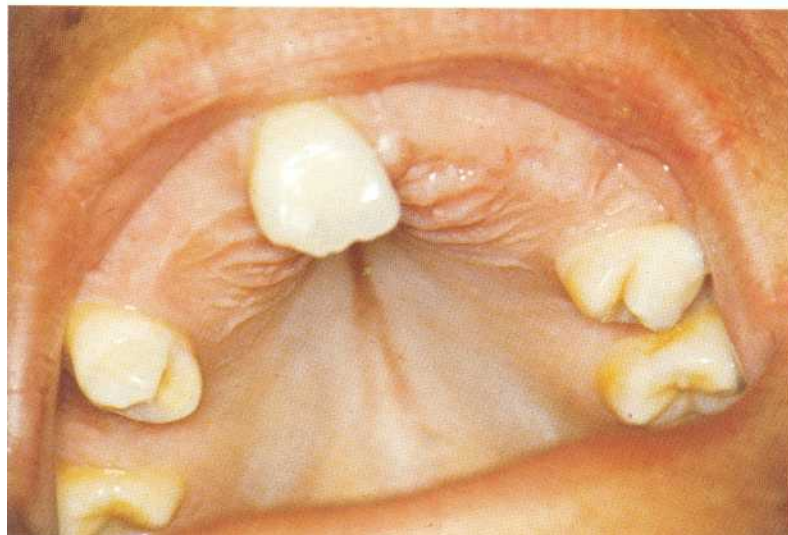


Fig. 62. Cleidocranial dysplasia, high palate and noneruption of some permanent teeth.



### Oro-Facial Digital Syndrome

Oro-facial digital syndrome type I is a rare X-linked dominant inherited disorder lethal to males. The oro-facial digital syndrome type II is inherited as an autosomal recessive trait.

The cardinal clinical manifestations of syndrome type I are digital malformations (brachydactyly, syndactyly, clinodactyly) and other skeletal disorders, cutaneous lesions (milia, xeroderma, alopecia, sparse hair, dermatoglyphic abnormalities), mental handicap, ocular hypertelorism, and oral lesions, which are numerous and variable. Constant oral mucosal findings are the multiple hyperplastic frenula traversing the upper and lower gingivolabial folds (Fig. 63). There is also hypertrophy and shortening of the frenula of upper and lower lips and tongue.

The tongue is multilobed or bifid and often exhibits multiple hamartomas. Clefts of the lips and the soft and hard palate are common. Mandibular lateral incisors are often missing, supernumerary teeth are common, and upper canines are malpositioned.

The differential diagnosis should include oro-facial digital syndrome type II (Mohr syndrome), chondroectodermal dysplasia, and oculodentodigital syndrome.

Treatment. No treatment is available, but the oral problem requires dental care.

### Focal Dermal Hypoplasia

The focal dermal hypoplasia, or Goltz syndrome, is a rare disorder that affects females almost exclusively. The mode of inheritance is not clearly known; probably a single gene mode of inheritance is involved. The syndrome is characterized by irregular linear skin pigmentation, atrophy, and telangiectasia present at birth, localized deposits of subcutaneous fat that present as soft reddish-yellow nodules (Fig. 64), syndactyly, especially between the third and fourth fingers, polydactyly, dystrophic nails, sparse hair, skeletal malformations, occasionally mental handicap, and mucous membrane involvement.

The oral mucosal manifestations are multiple papillomas on the tongue (Fig. 65), buccal mucosa, palate, gingiva, or lips. Similar papillomatous lesions may occur on the vulva, perianal, and perioral areas. Oligodontia, small teeth, dysplastic enamel, and malocclusion are not rare. The diagnosis is made on clinical criteria.

The differential diagnosis of oral lesions should include multiple papillomas and condylomata acuminata, focal epithelial hyperplasia, and incontinentia pigmenti.

Laboratory test. Histopathologic examination is essential to confirm oral papillomas and the fatty collections in the skin nodules.

Treatment is supportive. Surgical excision of oral papillomas.

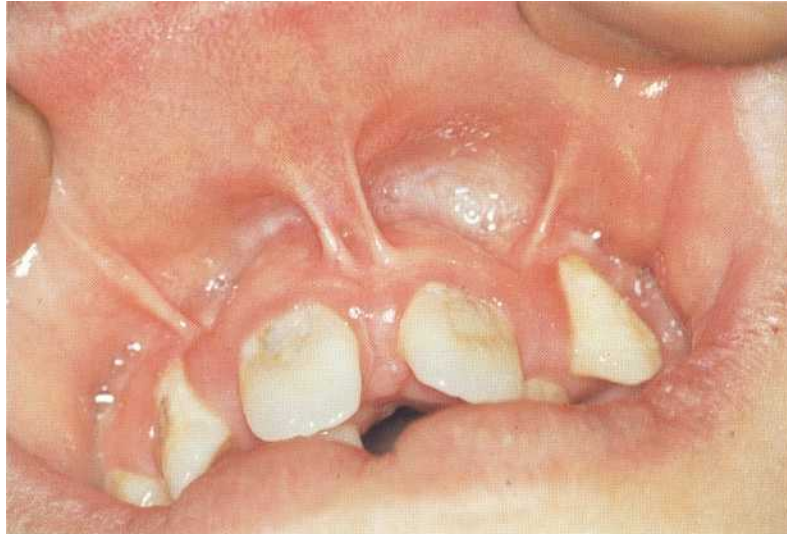

Fig. 63. Oro-facial digital syndrome, multiple hyperplastic frenula.

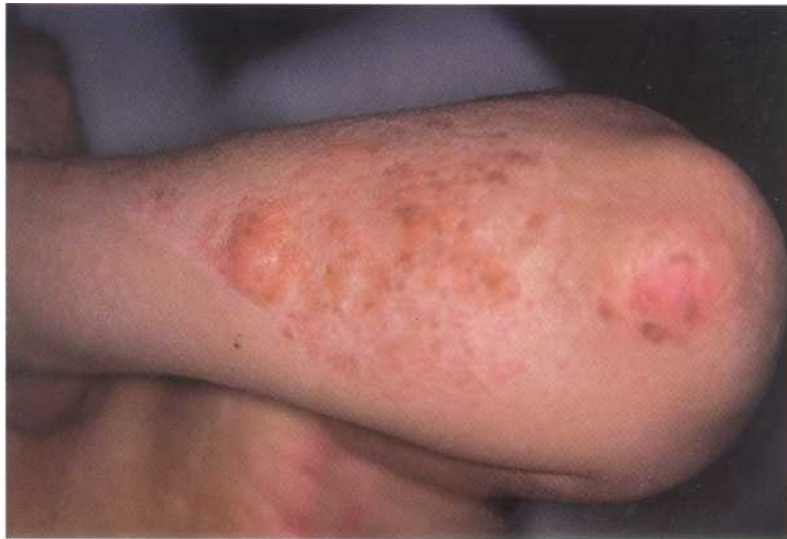

Fig. 64. Focal dermal hypoplasia, multiple localized nodules on the skin.

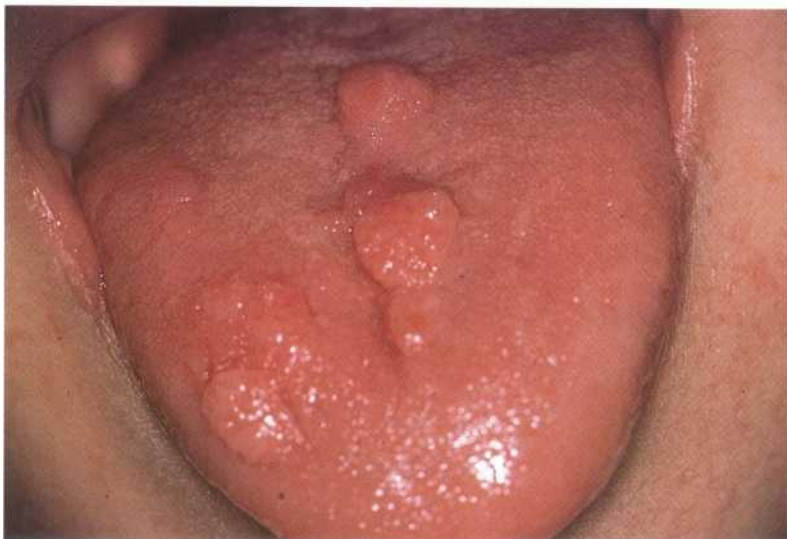

Fig. 65. Focal dermal hypoplasia, multiple papillomas on the tongue.

### Incontinentia Pigmenti

Incontinentia pigmenti is a disease inherited as an X-linked dominant trait that is lethal in males. The lesions usually appear at birth or within the first month as vesiculobullous eruptions in a linear group usually scattered **on the trunk and perimammary regions** or on the extremities, papuloverrucous irregular linear lesions of the skin, characteristic skin pigmentation, which may be the only abnormality (Fig. 66), other disorders (alopecia, dystrophic nails, ocular defects, skeletal and neurologic abnormalities), and dental defects, which include impacted teeth, dysplastic enamel, peg-shaped or conical teeth, delayed dentition, and oligodontia (Fig. 67).

The differential diagnosis should include epidermolysis bullosa, congenital syphilis, hypohidrotic ectodermal dysplasia, and focal dermal hypoplasia.

Laboratory test. Histopathologic examination is useful in establishing the diagnosis.

Treatment. No treatment is available.

### Ehlers-Danios Syndrome

Ehlers-Danlos syndrome is a group of disorders inherited as an autosomal dominant, autosomal recessive, or X-linked recessive trait. In the basis of genetic, clinical, and biochemical criteria, at least 11 types of Ehlers-Danlos syndrome are now recognized. Although the basic defect is not well known, an abnormality in collagen biosynthesis has been recorded in some of the subgroups.

The cardinal clinical features of the syndrome are hyperextensibility of the skin, hyperextensibility of joints, cutaneous fragility, bruisability, and pseudotumors, fragility of blood vessels and delayed wound healing, ocular abnormalities, and oral manifestations.

The oral mucosa is excessively fragile and subject to bruising. Gingival bleeding and periodontitis are common. Wound healing may be only slightly delayed. Tooth mobility is not increased, although a hypermobility of the temporomandibular joint may occur. Approximately 50% of patients have the ability to touch their nose with the tongue tip compared with 10% of normal persons (Fig. 68). Dental abnormalities, such as enamel, dentine, and cementum defects and an increased tendency to develop multiple pulp stones, have been reported.

The differential diagnosis includes cutis laxa, Marfan's syndrome and Marfanoid hypermobility syndrome, and osteogenesis imperfecta.

Laboratory tests, such as histopathologic and blood examinations are suggestive but not diagnostic.

Treatment. There is no definitive treatment for the syndrome. Supportive measures against skin fragility, trauma, etc., should be included in the management of patients.

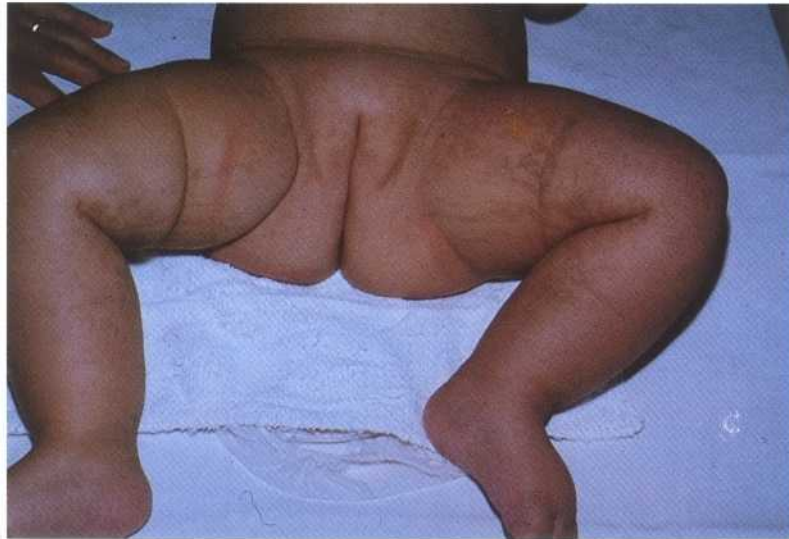

Fig. 66. Incontinentia pigmenti, dirty brown hyperpigmentation of the skin.

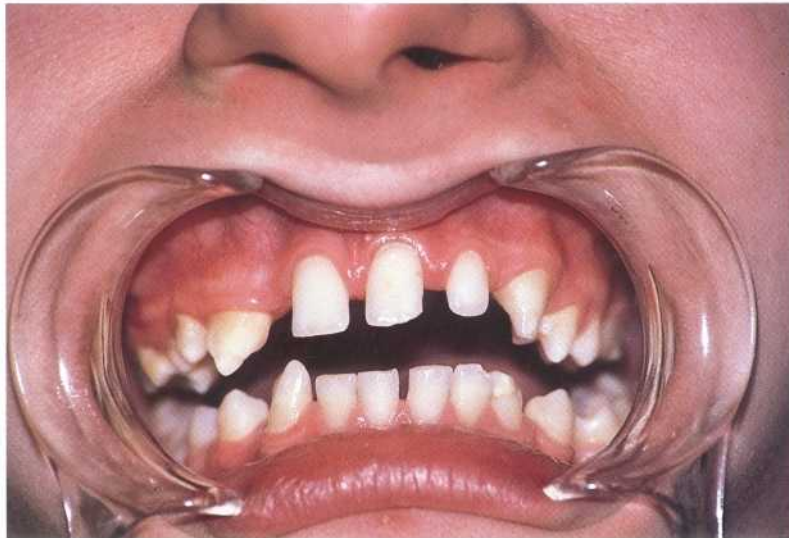

Fig. 67. Incontinentia pigmenti, oligodontia and peg-shaped teeth.

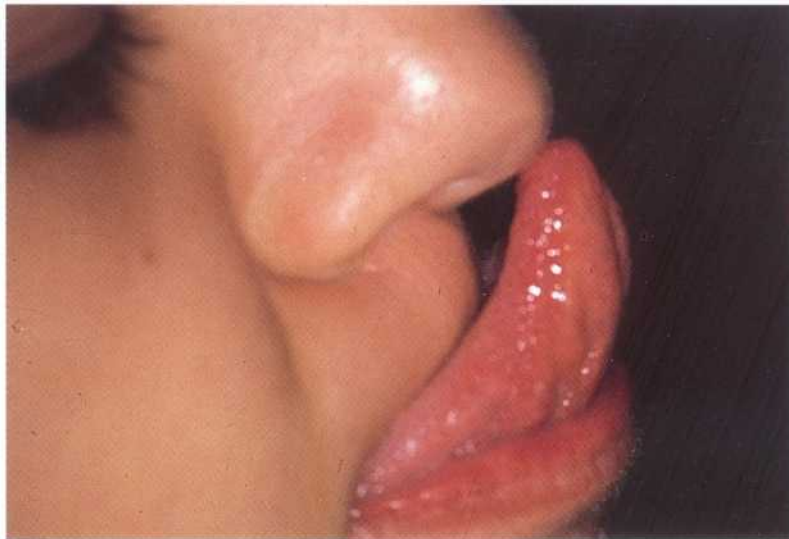

Fig. 68. Ehlers-Danlos syndrome, ability to touch the tip of the nose with the tongue tip.

### Marfan's Syndrome

Marfan's syndrome is inherited as an autosomal dominant trait with a high degree of penetrance and variable expression. It is characterized by changes in the musculoskeletal system, the eyes, and the cardiovascular system. Characteristically the patients are tall with long and slender fingers and toes (arachnodactyly), long arms and legs, chest deformities, scoliosis, and less often kyphosis. Hyperextensibility of joints is also present. The disorders of the eyes are downward lens dislocation (ectopia lentis), myopia, retinal detachment, and glaucoma. Cardiovascular disorders are common and include mitral valve prolapse, aortic dilatation, and aneurysms. The more common and characteristic oral manifestations are a narrow and high-arched palate (Fig. 69) and less commonly cleft palate, bifid uvula, and abnormalities in the shape of the teeth. Skin striae and hyperextensibility may be also seen.

The differential diagnosis includes Ehlers-Danlos syndrome, homocystinuria, multiple endocrine neoplasia type IIb, Marfanoid hypermobility syndrome, and mitral valve prolapse syndromes.

Laboratory test. There is no specific test.

Treatment. There is no specific treatment. Since these patients tend to develop dissecting aneurysms, control of blood pressure is mandatory.

### Down's Syndrome

Down's syndrome or trisomy 21 is a common chromosomal disorder. The prevalence rate is approximately 1 out of 800 live births. There is an association between increasing maternal age at conception and risk of Down's syndrome in the fetus. The most common clinical features are mental retardation, epicanthal folds, mongoloid slanting of the eyes, short ears, flat face with a broad nose bridge, polydactyly-syndactyly-clinodactyly, other skeletal abnormalities, small penis and scrotum, cryptorchidism, dermatoglyphic anomalies, hypotonia, congenital heart disease, oral disorders, and increased risk for leukemia. The most frequent oral lesions are macroglossia, and fissured and geographic tongue; high-arched palate, cleft palate, hypoplastic teeth, and severe periodontitis (Fig. 70).

The differential diagnosis includes trisomies 13, 15, 17, 18 and hypothyroidism.

Laboratory test to confirm the diagnosis is chromosomal analysis. Prenatal diagnosis has become widely available.

Treatment. No definitive treatment exists.

Fig. 69. Marfan's syndrome, narrow and high-arched palate.

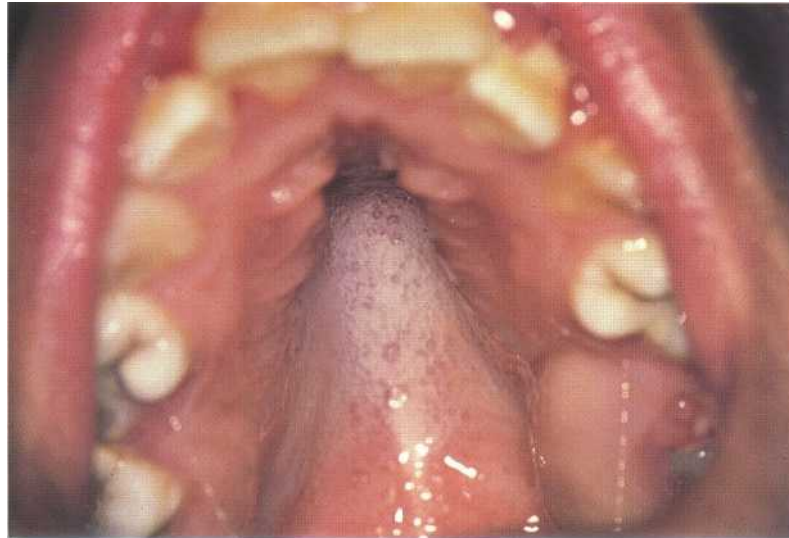
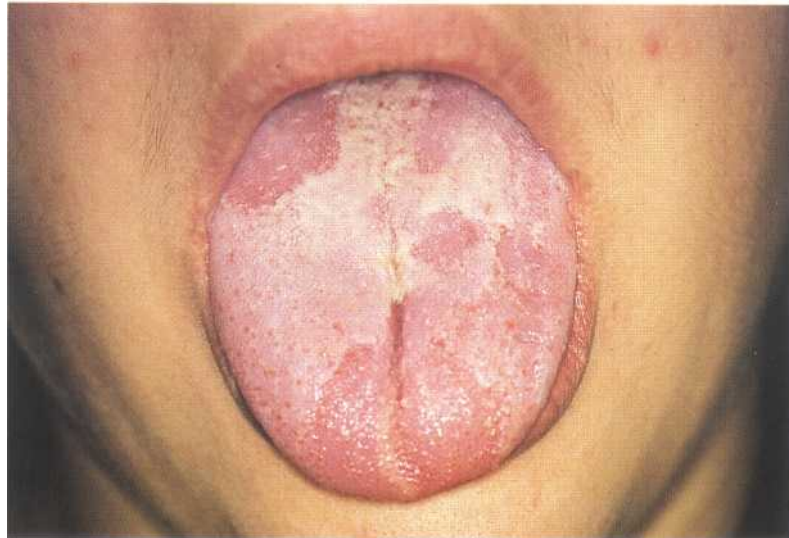

Fig. 70. Down's syndrome, macroglossia and geographic tongue.



## 4. Mechanical Injuries

### Traumatic Ulcer

Traumatic ulcers are common oral lesions. The causes are variable and include a sharp or broken tooth, rough fillings, clumsy use of cutting dental instruments, hard foodstuffs, sharp foreign bodies, biting of the mucosa, and denture irritation. Ulcers of traumatic origin may occur anywhere in the mouth but are most commonly found on the lateral borders of the tongue (Figs. 71, 72), the buccal mucosa, the lips (Fig. 73), the labioalveolar and buccalveolar grooves (Fig. 74).

The size of the ulcer may vary from a few millimeters to several centimeters in diameter and depends on the intensity, duration, and type of the trauma as well as superimposed infection.

The clinical presentation is variable, but usually traumatic ulcers appear as single painful lesions with a smooth red or white-yellow surface and thin erythematous margins. They are usually soft to palpation and heal without scarring within 6 to 10 days, spontaneously or after removal of the cause.

However, when the cause is sustained and intense, the ulcer surface may become irregular with

vegetations, the border may become raised, and the base indurated. In these cases the traumatic ulcer may clinically resemble a carcinoma.

Subjective complaints vary from mild to severe, depending on the depth and location of the ulcer in the mouth. The diagnosis is based on the history and clinical features. Once a relationship has been established between an ulcerogenic factor and an ulcer, removal of the cause is mandatory, with follow-up of the patient for 7 to 10 days to verify complete healing. If the ulcer persists, then revision of the clinical diagnosis and performance of a biopsy to rule out cancer is recommended.

The differential diagnosis should include squamous cell carcinoma and other cancers, syphilis, tuberculosis, aphthae, and eosinophilic and other ulcers.

**Laboratory test.** Histopathologic examination often helps in establishing the diagnosis.

**Treatment.** Removal of the traumatic factors.

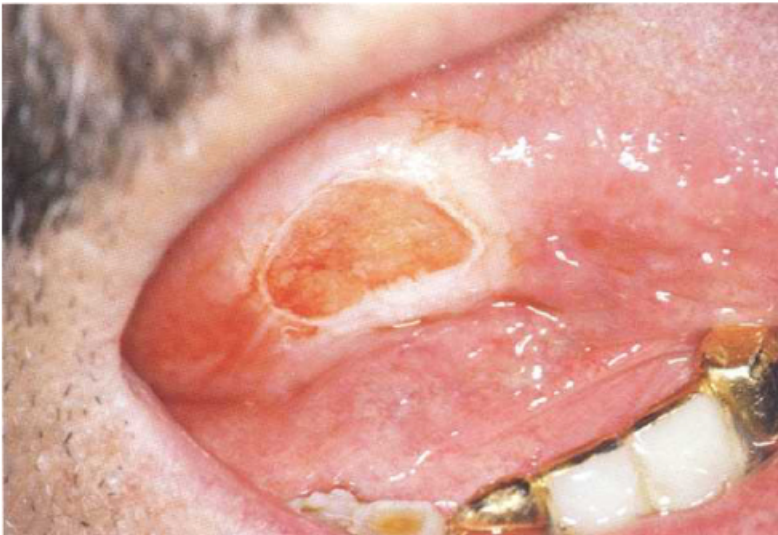

Fig. 71. Traumatic ulcer of the tongue.

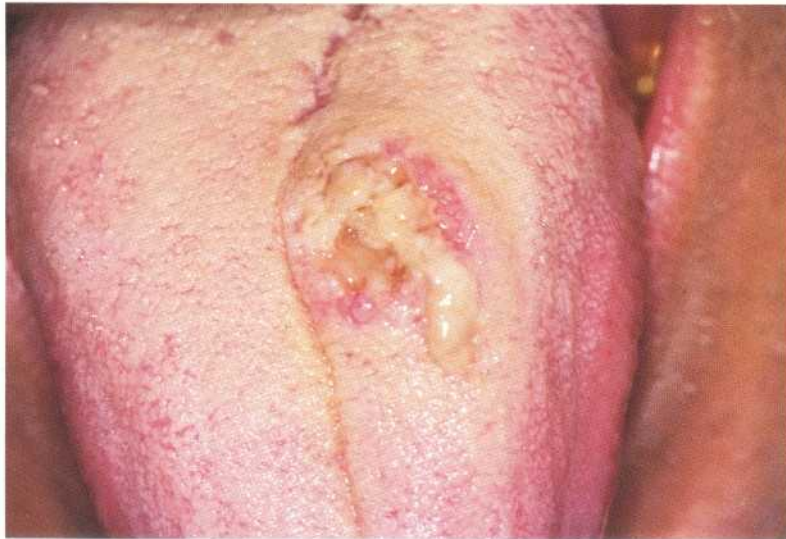

Fig. 72. Traumatic ulcer of the tongue.

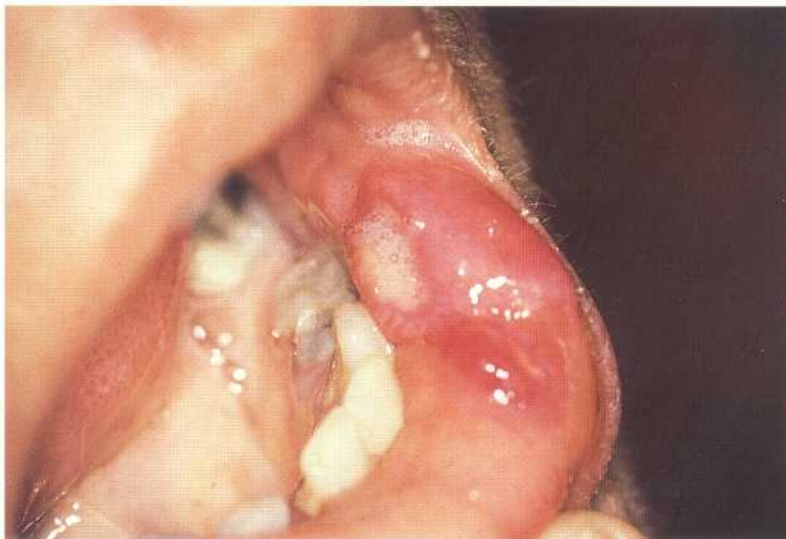

Fig. 73. Traumatic ulcer on the lower lip.

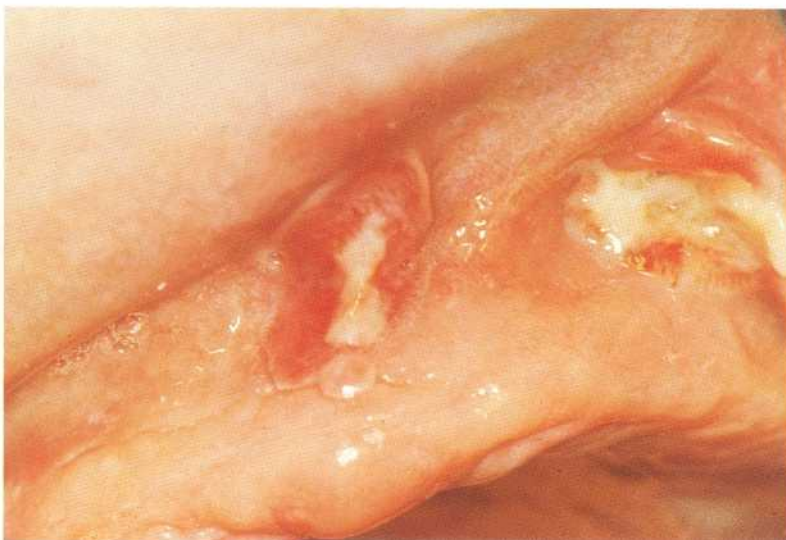

Fig. 74. Traumatic ulcer on the labioalveolar groove caused by dentures.



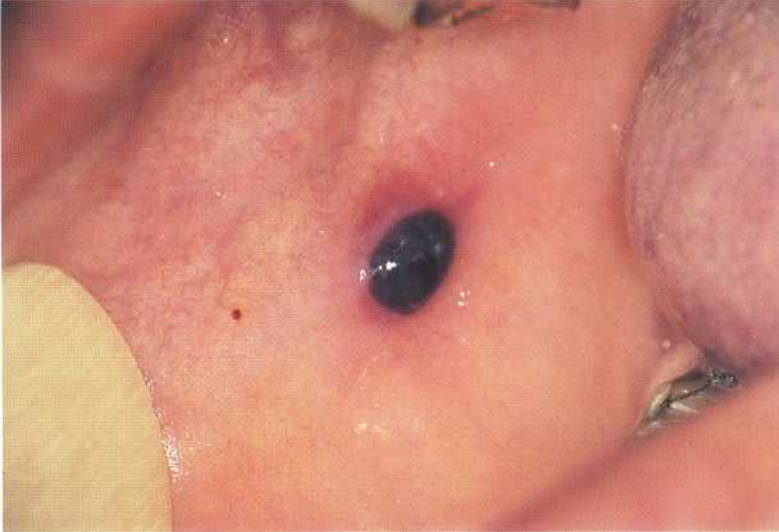


Fig. 75. Traumatic hemorrhagic bulla on the buccal mucosa.

### Traumatic Bulla

Acute traumatic injury of the oral mucosa, usually caused by biting or prosthetic appliances, may produce abrupt subepithelial hemorrhages which sometimes detach the epithelium at the dermoepithelial junction to produce a hemorrhagic bulla formation. The buccal mucosa is the site of predilection, but rarely it may be seen in other oral areas (Fig. 75). The lesion is asymptomatic and usually disappears within 2-3 days without treatment.

The differential diagnosis includes pemphigus, cicatricial pemphigoid, bullous pemphigoid, and epidermolysis bullosa acquisita.

### Traumatic Hematoma

Traumatic hematoma of the oral mucosa occurs under the influence of mild or severe mechanical forces that result in hemorrhage within the oral tissues. Clinically, it appears as an irregular lesion with a deep red hue (Fig. 76). The most common sites of hematoma are the tongue and lips and the most common causes are biting of the oral mucosa or careless use of dental instruments.

### Chronic Biting

Mild chronic biting of the oral mucosa is common in anxious persons. These patients consciously bite the buccal mucosa, tongue, or lips and tear off the superficial epithelial layers. Clinically, this lesion is characterized by a diffuse irregular area characterized by a diffuse irregular area of small furrows, whitish surface, and desquamation of the affected epithelium (Fig. 77). Infrequently, there are surface erosions and petechiae.

The differential diagnosis includes leukoedema, Fordyce's granules, candidosis, leukoplakia, white sponge nevus, and lichen planus.

Treatment includes mild sedatives and warning the patient about the deleterious results of this habit on the oral mucosa.

### Toothbrush Trauma

Toothbrush trauma may occur during aggressive tooth-brushing with a hard brush. The clinical picture consists of small oval, round, or bandlike superficial erosions located on the gingiva and alveolar mucosa (Fig. 78). These lesions cause mild subjective complaints and heal rapidly.

The differential diagnosis includes herpes simplex, aphthous ulcers, and other traumatic lesions.

Fig. 76. Traumatic hematoma on the lower lip.

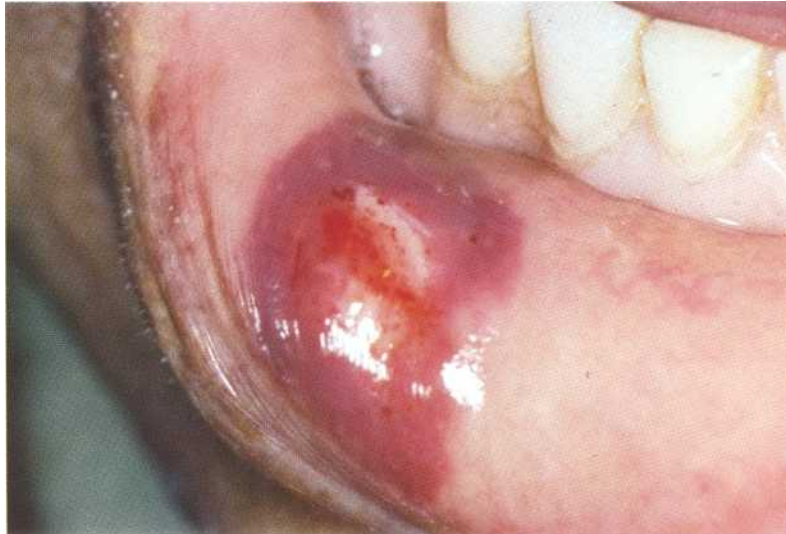

Fig. 77. Chronic biting of the buccal mucosa.

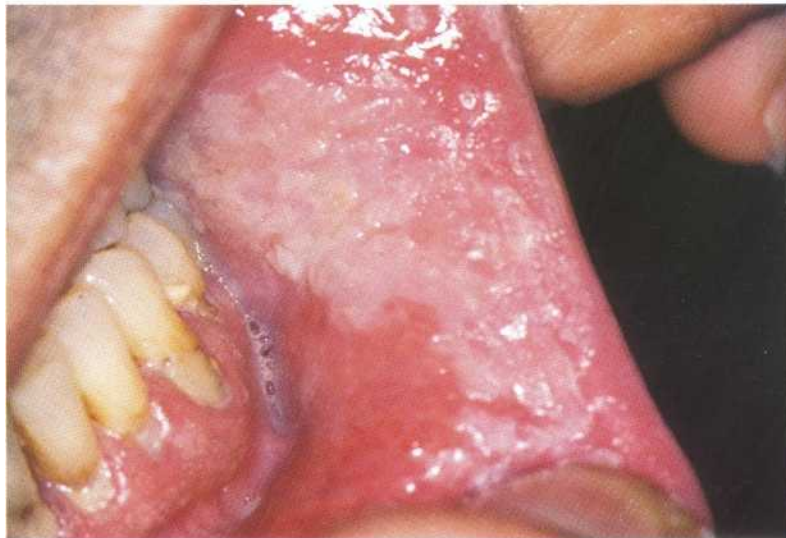
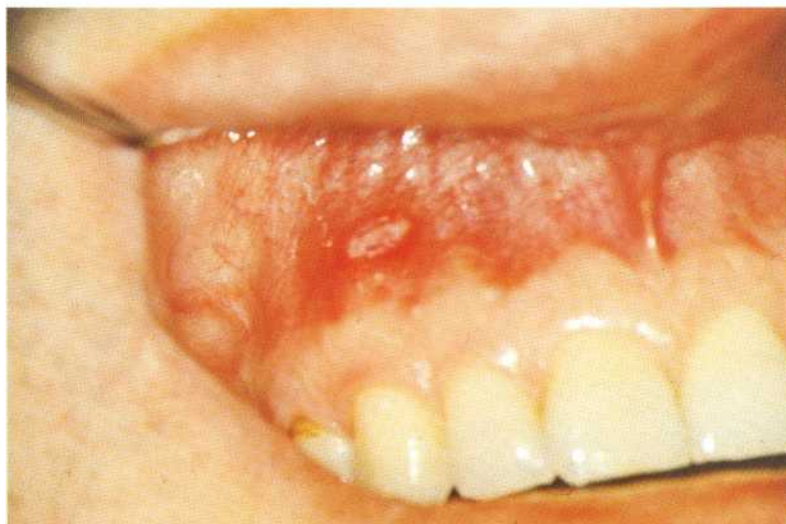
Fig. 78. Erosion caused by tooth-brushing.



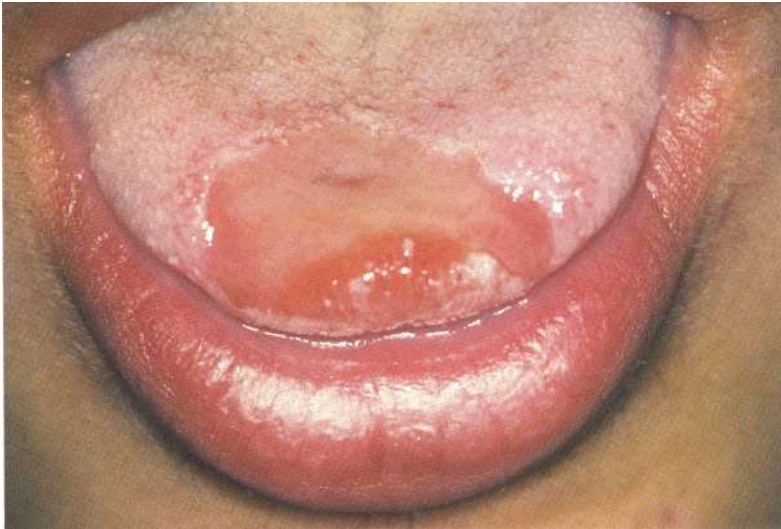

Fig. 79. Factitious ulcer on the tongue.

### Factitious Trauma

Patients mentally handicapped or with serious emotional problems may resort to oral self-inflicted trauma.

The trauma is usually inflicted through biting, fingernails, or through the use of a sharp object.

These lesions are slow to heal due to perpetuation of the injury by the patient. The most frequent locations are the tongue, the lower lip, and the gingiva (Fig. 79).

The diagnosis depends on strong clinical suspicion and the history, although many patients deny that they are responsible for the observed traumatic lesions.

The differential diagnosis includes traumatic ulcer, malignant ulcer, tuberculosis, syphilis, and aphthous ulcer.

Treatment should include local measures and psychiatric therapy, if appropriate.

### Fellatio

Apart from venereal diseases, oral lesions may occur due to negative pressure or mechanical irritation applied during fellatio. Lesions occur at the junction of the soft and hard palate and consist of petechiae, erythema, and ecchymoses (Fig. 80). They disappear spontaneously within a week.

The differential diagnosis includes traumatic injury, infectious mononucleosis, thrombocytopenic purpura, leukemia, and aplastic anemia.

### Lingual Frenum Ulcer After Cunnilingus

Traumatic oral erosion or ulcer may result from practice of orogenital sex. Lingual frenum ulcer secondary to cunnilingus may be seen particularly in males. The lesion develops as the taut lingua frenum is rubbed over the rough incisal edges of the mandibular incisors during the tongue movements in cunnilingus. Clinically, the lesion is characterized by a small nonspecific erosion of ulcer covered by a whitish exudate and surrounded by a red halo (Fig. 81).

The differential diagnosis should include other traumatic erosions or ulcers, primary and secondary syphilis, minor aphthous ulcer, and secondary herpetic lesions.

### Cotton Roll Stomatitis

Cotton rolls are applied in dental practice to keep the dental surfaces dry. Excessive drying of the mucosal surfaces may result in erosions during rough removal of the cotton, which adheres to the mucosa. Clinically, the lesions appear as painful erosions covered with a whitish pseudomembrane, and they heal within 4 to 6 days (Fig. 82).

The differential diagnosis includes other traumatic or chemically induced lesions and aphthous ulcers.

Treatment. No treatment is necessary.

Fig. 80. Erythema on the palate caused by fellatio.

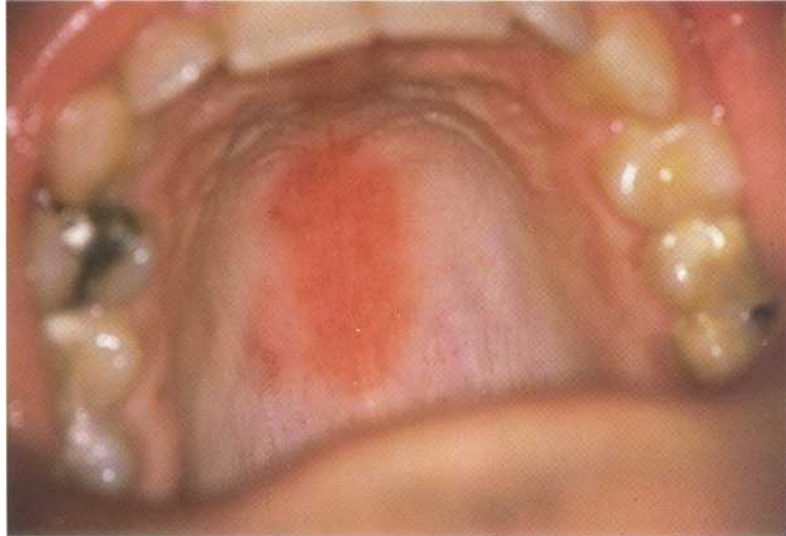

Fig. 81. Lingual frenum ulcer after cunnilingus.

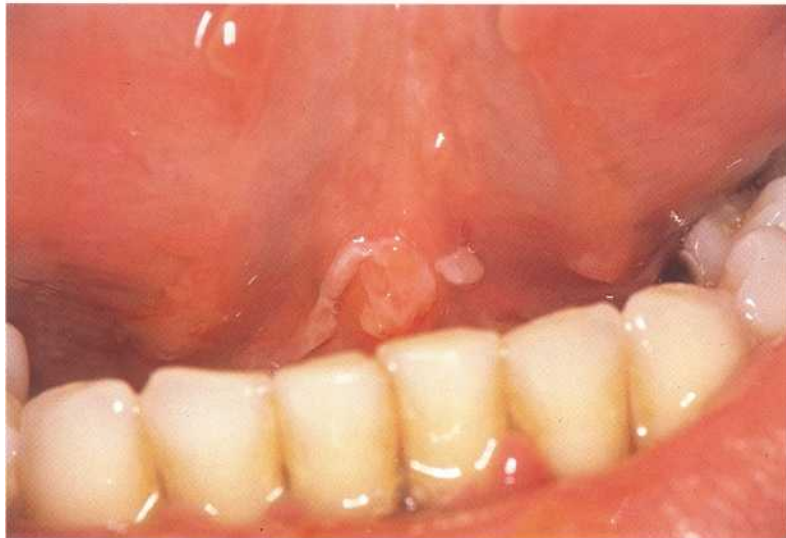
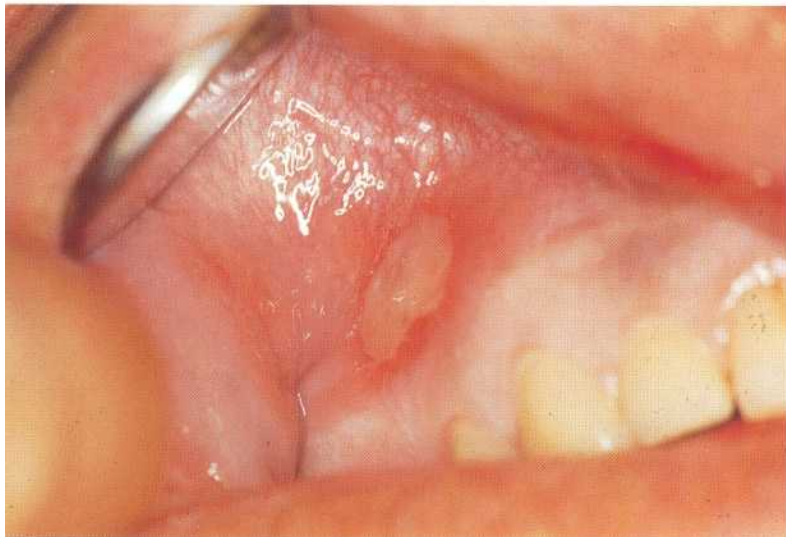
Fig. 82. Erosion caused by cotton roll.



### Denture Stomatitis

Denture stomatitis or denture sore mouth is frequent in patients who wear dentures for long periods of time. Usually, the lesion is confined to the maxilla and only rarely occurs on the mandibular mucosal surface. Clinically, the mucosa beneath the denture is edematous, red with or without whitish spots that represent accumulation of hyphae of *Candida albicans*, or food remnants (Fig. 83). The mucosal surface is smooth or granular.

Most patients are asymptomatic but some complain of a burning sensation or irritation and pain. The lesions are benign and may be localized or generalized. The most important causative factors of denture stomatitis are irritation from the denture, food debris accumulating under the denture surface, and *C. albicans* infection.

The differential diagnosis includes allergic contact stomatitis due to acrylic.

Treatment. Improvement of denture fit, good oral hygiene, and nystatin or clotrimazole if *C. albicans* is present.

### Epulis Fissuratum

Epulis fissuratum, or denture fibrous hyperplasia, is a common tissue reaction caused by poorly fitting dentures in persons who have been wearing dentures for a long period of time. The chronic irritation may be due to a sharp margin of the denture or overextended flanges. The lesion presents as multiple or single inflamed elongated mucosal papillary folds in the mucolabial or mucobuccal grooves (Fig. 84).

These hyperplastic folds are mobile, somewhat firm to palpation, and their continued growth may cause problems in maintaining denture retention. Painful ulceration is common in the base of the fold.

The differential diagnosis includes multiple fibromas, neurofibromatosis, and squamous cell carcinoma.

Treatment. Surgical excision of the hyperplastic folds and new denture construction.

### Papillary Hyperplasia of the Palate

Papillary hyperplasia of the palate is a variety of denture stomatitis occurring in patients who wear ill-fitting dentures for many years.

However, similar lesions may occur in edentulous persons with high-arched palate due to mechanical irritation of foodstuffs on the palate. Clinically, the lesions appear as multiple coalescing small edematous, reddish elevations that usually measure 1 to 2 mm or more in diameter (Fig. 85). The lesions are confluent and occupy part or all of the hard palate, giving it a cauliflower-like appearance. These lesions are asymptomatic as a rule and may be accidentally discovered by the patient, who becomes anxious, fearing a cancer. They are benign and should not be a cause for alarm.

The differential diagnosis includes acanthosis nigricans, multiple condylomata acuminata, dyskeratosis follicularis, and tuberculosis.

Treatment consists of reassurance of the patient regarding the nature of the lesion. These lesions should be removed before the construction of a new denture.

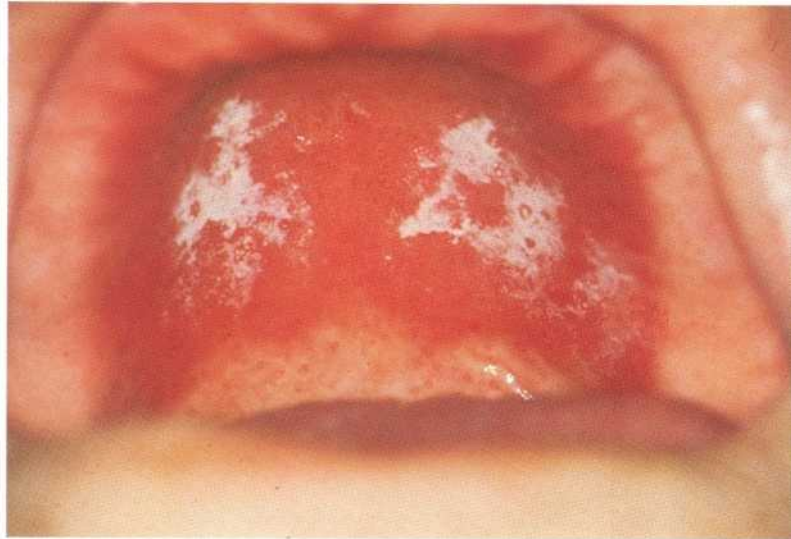


Fig. 83. Denture stomatitis.

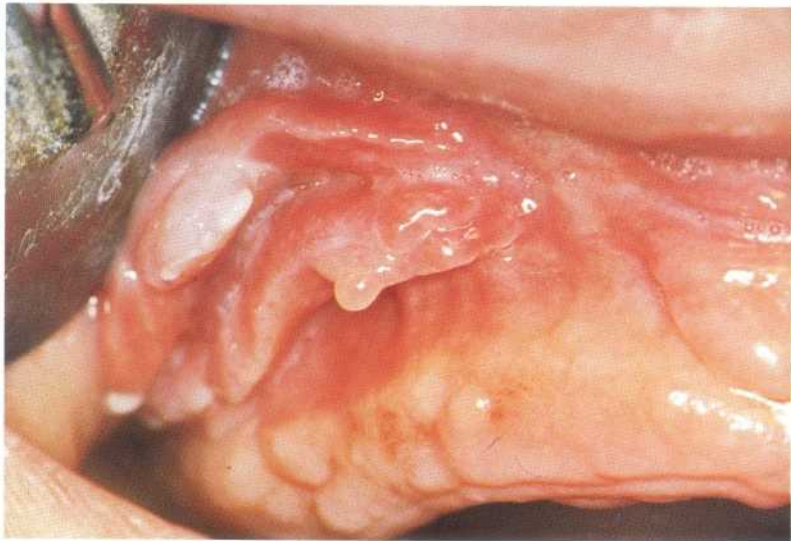

Fig. 84. Epulis fissuratum.

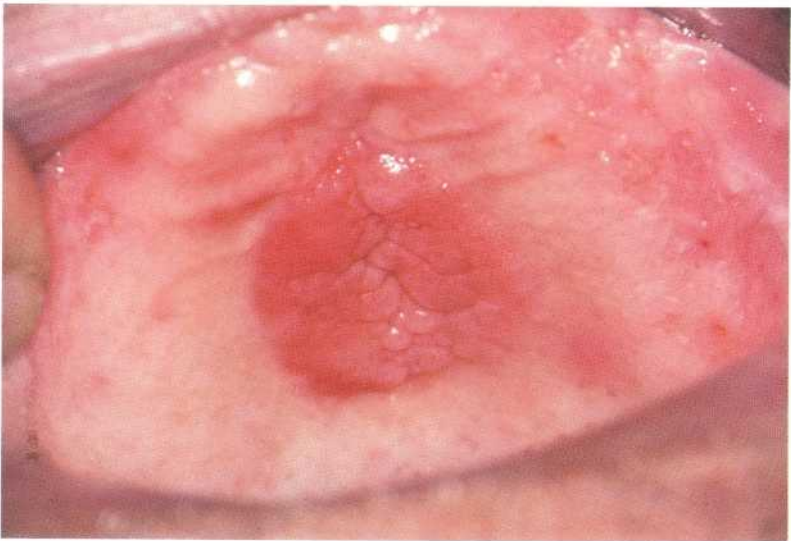

Fig. 85. Papillary hyperplasia of the palate.

### **Hyperplasia due to Negative Pressure**

In patients wearing dentures, a heart-shaped or round area of mucosal hyperplasia may appear on the hard palate. The mucosa may be slightly elevated and appears red with a smooth or papillary surface (Fig. 86). This lesion occurs if a relief chamber exists at the center of the basal plate of the denture. The oral mucosal hyperplasia occurs in response to the negative pressure that develops.

Treatment. No treatment is necessary.

### **Atrophy of the Maxillary Alveolar Ridge**

Atrophy of the maxillary alveolar ridge may be the result of excessive occlusal trauma due to a poor fitting denture. It occurs more frequently in women in the anterior maxilla.

The alveolus becomes flabby and red (Fig. 87).

Epulis fissuratum may coexist.

Treatment. Surgical correction is recommended.

### **Foreign Body Reaction**

Foreign bodies lodged in the oral soft tissues may cause reactive lesions.

The most frequent foreign bodies causing such a reaction are sutures, paraffin, silicon salts, bony fragments, amalgam, metallic fragments from shrapnel, car accidents, etc. The lesions may appear as discolorations, small tumorous enlargements of tissue, abscesses, etc. In peacetime, shrapnel-induced lesions are uncommon. Figure 88 shows a black, well-circumscribed, and asymptomatic nodule caused by shrapnel after a land mine explosion during World War II.

The differential diagnosis includes malignant melanoma, pigmented nevi, and hemangiomas.

Laboratory test. The histopathologic examination is diagnostic, showing reactive granulation tissue and the foreign body fragments. Radiographic examination may be also helpful.

Treatment. Surgical excision.

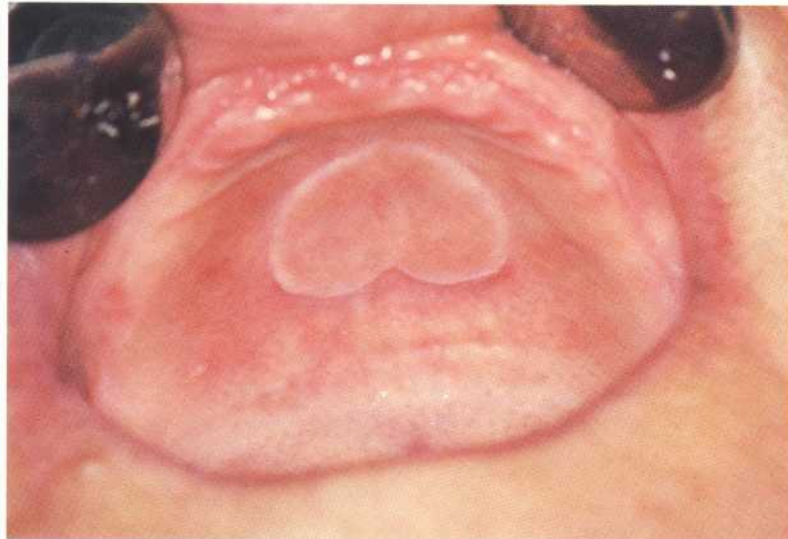


Fig. 86. Palatal hyperplasia caused by negative pressure.

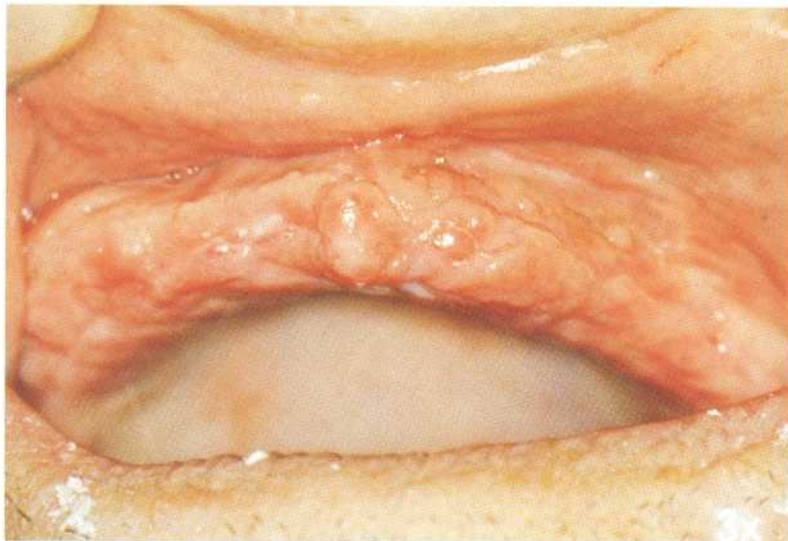


Fig. 87. Atrophy of the maxillary alveolar ridge.

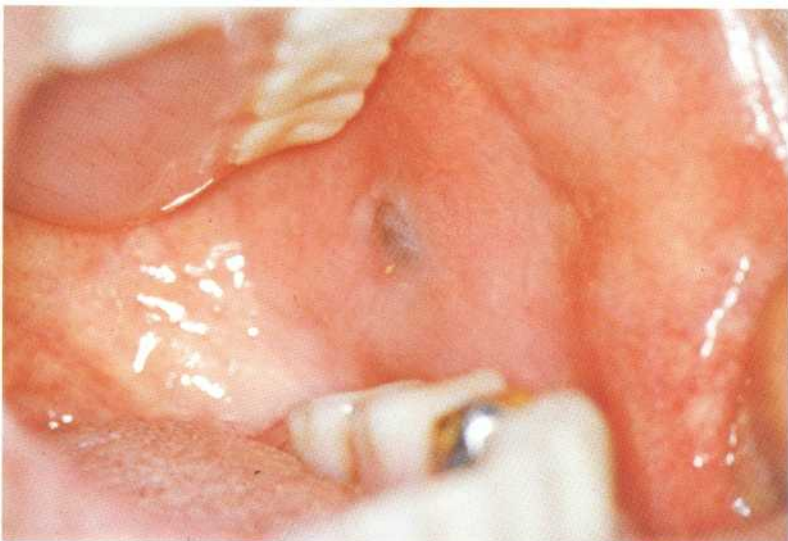

Fig. 88. Nodule on the buccal mucosa caused by shrapnel after a land mine explosion.



### Palatal Necrosis due to Injection

Necrosis of the hard palate may occur after local anesthetic injection. Rapid injection results in local ischemia, which may be followed by necrosis. The hard palate is particularly sensitive to these lesions due to local pressure, because of the firm adherence of mucosa to the bone and the absence of loose connective tissue.

A circular ulcer, a few millimeters in diameter, that heals spontaneously within 2 weeks, is the cardinal manifestation (Fig. 89).

The differential diagnosis includes necrotizing sialometaplasia and lesions of traumatic origin.

**Treatment.** Usually, no therapy is necessary. Mouthwashes with oxygen-releasing substrates are recommended.

### Eosinophilic Ulcer

Eosinophilic ulcer of the oral mucosa, or eosinophilic granuloma of the oral soft tissues, is considered a self-limiting benign lesion unrelated to either facial granuloma or the eosinophilic granuloma of histiocytosis X. The etiology of eosinophilic ulcer remains obscure, although a traumatic background has been suggested. It has been recently proposed that the pathogenesis of eosinophilic ulcer is probably T-cell mediated. In a series of 25 cases reviewed, this disease was more frequent in men than women (5.25: 1), with a mean age of occurrence of 39 years. The tongue was involved in 74% of the cases and less often the lips, buccal mucosa, palate, and gingiva. Clinically, the lesions appear as painful ulcers with irregular surface, covered with a whitish-yellow membrane, and raised indurated margins (Figs. 90,91).

The sudden onset and pain is a cause of concern for the patient. The ulcer may be single or multiple.

The differential diagnosis includes squamous cell carcinoma, major aphthous ulcers, syphilis, tuberculosis, traumatic ulcer, necrotizing sialometaplasia, Wegener's granulomatosis, lethal midline granuloma, lymphoma, and leukemia.

**Laboratory test.** Histopathologic examination is important to establish the diagnosis.

**Treatment.** Low-dose corticosteroids or surgical excision are helpful. Spontaneous healing after biopsy has occurred occasionally.

Fig. 89. Palatal necrosis caused by injection.

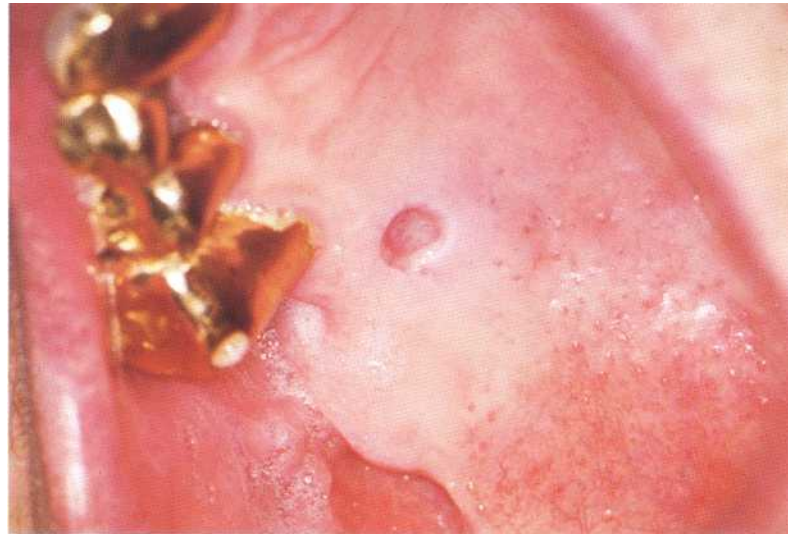

Fig. 90. Eosinophilic ulcer of the tongue.

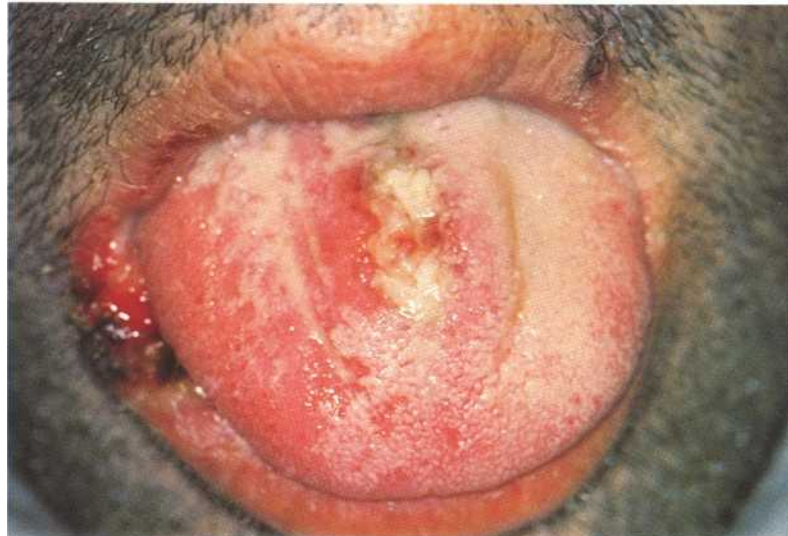
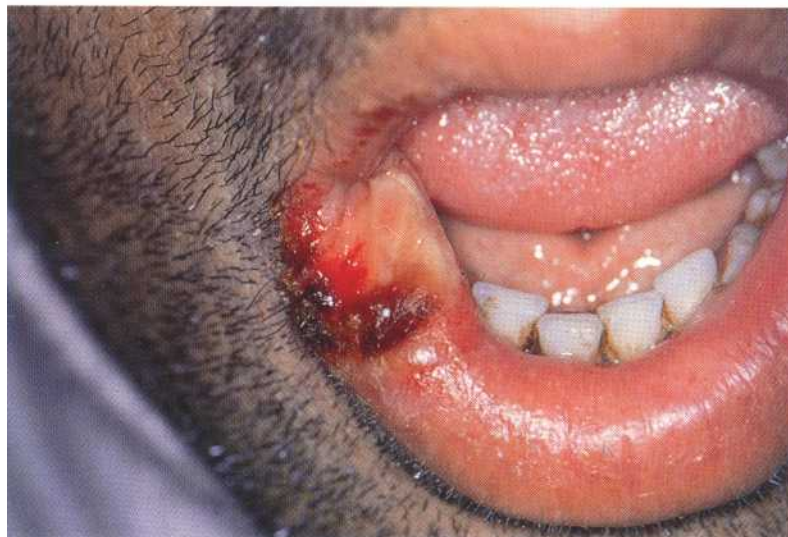
Fig. 91. Eosinophilic ulcer on the lower lip and the commissure.



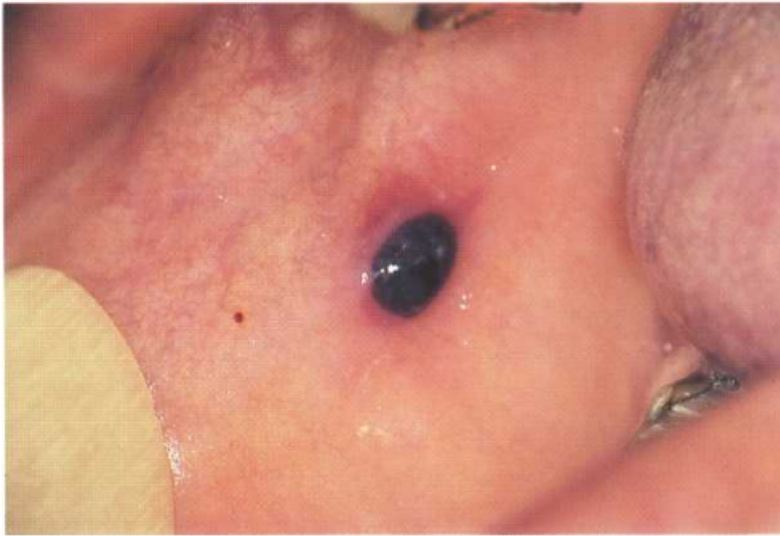


Fig. 75. Traumatic hemorrhagic bulla on the buccal mucosa.

### Traumatic Bulla

Acute traumatic injury of the oral mucosa, usually caused by biting or prosthetic appliances, may produce abrupt subepithelial hemorrhages which sometimes detach the epithelium at the dermoepithelial junction to produce a hemorrhagic bulla formation. The buccal mucosa is the site of predilection, but rarely it may be seen in other oral areas (Fig. 75). The lesion is asymptomatic and usually disappears within 2-3 days without treatment.

The differential diagnosis includes pemphigus, cicatricial pemphigoid, bullous pemphigoid, and epidermolysis bullosa acquisita.

### Traumatic Hematoma

Traumatic hematoma of the oral mucosa occurs under the influence of mild or severe mechanical forces that result in hemorrhage within the oral tissues. Clinically, it appears as an irregular lesion with a deep red hue (Fig. 76). The most common sites of hematoma are the tongue and lips and the most common causes are biting of the oral mucosa or careless use of dental instruments.

### Chronic Biting

Mild chronic biting of the oral mucosa is common in anxious persons. These patients consciously bite the buccal mucosa, tongue, or lips and tear off the superficial epithelial layers. Clinically, this lesion is characterized by a diffuse irregular area of small furrows, whitish surface, and desquamation of the affected epithelium (Fig. 77). Infrequently, there are surface erosions and petechiae.

The differential diagnosis includes leukoedema, Fordyce's granules, candidosis, leukoplakia, white sponge nevus, and lichen planus.

Treatment includes mild sedatives and warning the patient about the deleterious results of this habit on the oral mucosa.

### Toothbrush Trauma

Toothbrush trauma may occur during aggressive tooth-brushing with a hard brush. The clinical picture consists of small oval, round, or bandlike superficial erosions located on the gingiva and alveolar mucosa (Fig. 78). These lesions cause mild subjective complaints and heal rapidly.

The differential diagnosis includes herpes simplex, aphthous ulcers, and other traumatic lesions.

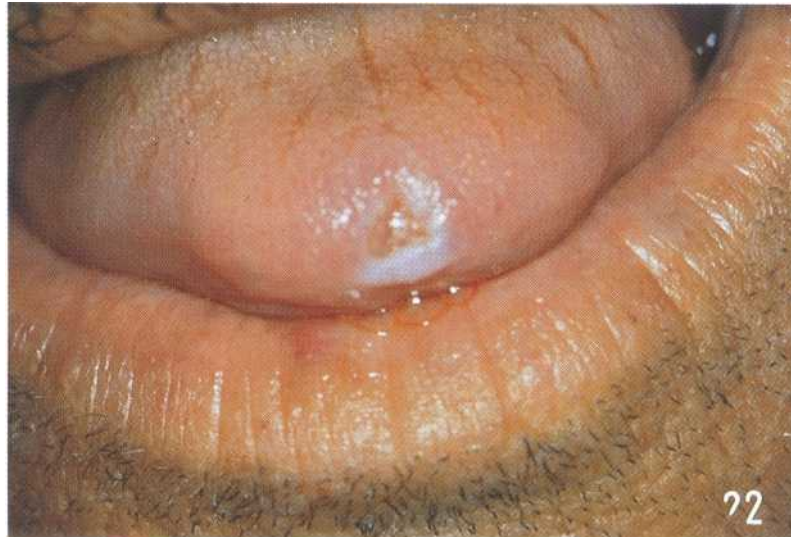

Fig. 92. Phenol burn.

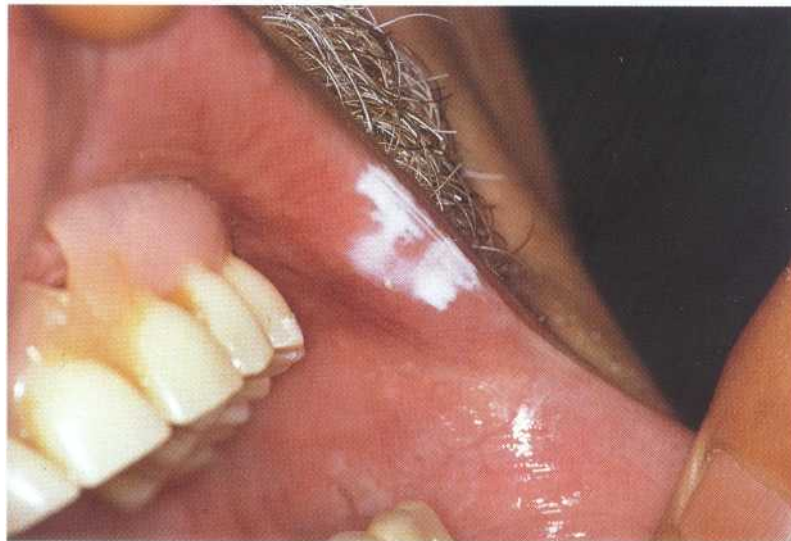

Fig. 93. Trichloroacetic acid burn.

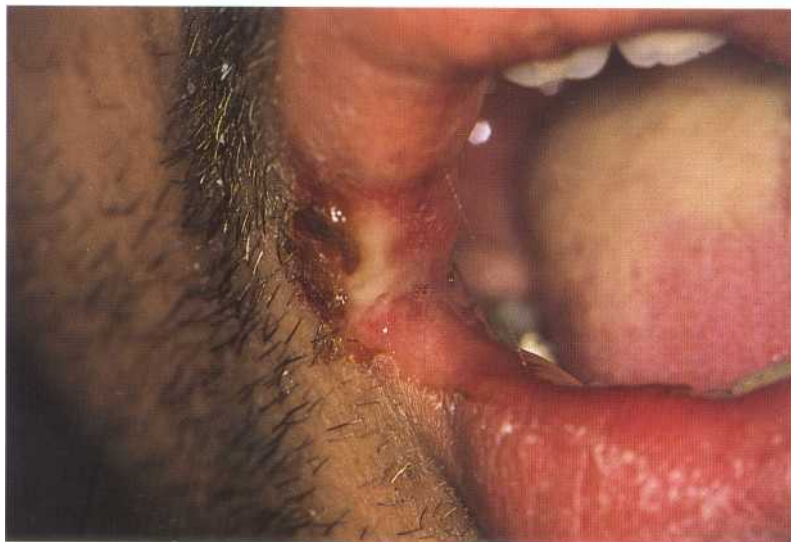

Fig. 94. Eugenol burn.

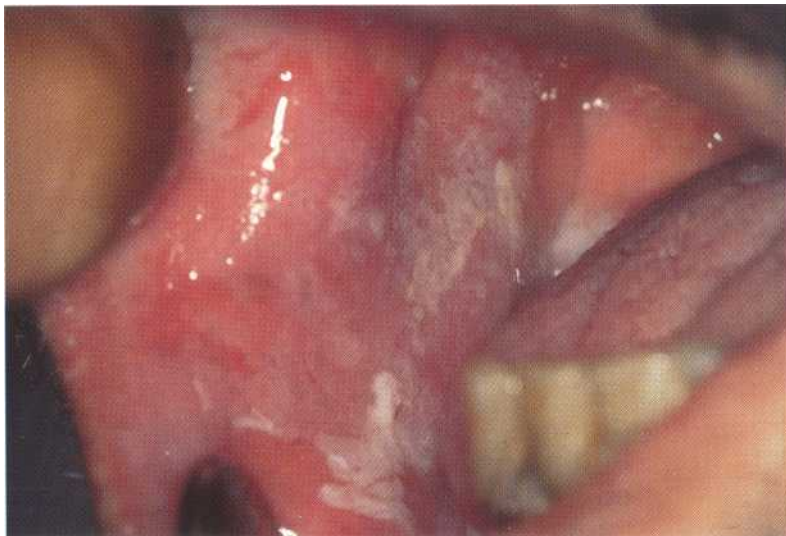

Fig. 95. Aspirin burn.

### **Aspirin Burn**

Aspirin is sometimes used by patients to relieve dental pain. Some patients apply aspirin tablets repeatedly and directly on the painful tooth or on adjacent tissues. In these cases the drug dissolves locally causing necrosis of the tissues. The mucosa is whitish and wrinkled (Fig. 95). Later, the necrotic epithelium desquamates exposing an underlying painful erosion, which heals within a week.

### **Iodine Burn**

Mild burns may occur after repeated application of concentrated alcoholic iodine solutions. The affected mucosa is whitish or red and has a rough surface (Fig. 96). The lesion heals spontaneously within 2 to 4 days.

### **Alcohol Burn**

Concentrated alcohol in the form of absolute alcohol, or spirits with high alcohol content, is used on occasion by patients as a local anesthetic for dental pain. With repeated application, a mild burn may result. The affected mucosa is whitish, wrinkled, and tender (Fig. 97). The lesion heals within 2 to 4 days.

### **Acrylic Resin Burn**

Autopolymerizing acrylic resins are used in dentistry for the construction of temporary prostheses and may cause local burns either due to heat evolving during polymerization or to monomer excess. The mucosa is red with or without erosions (Fig. 98).

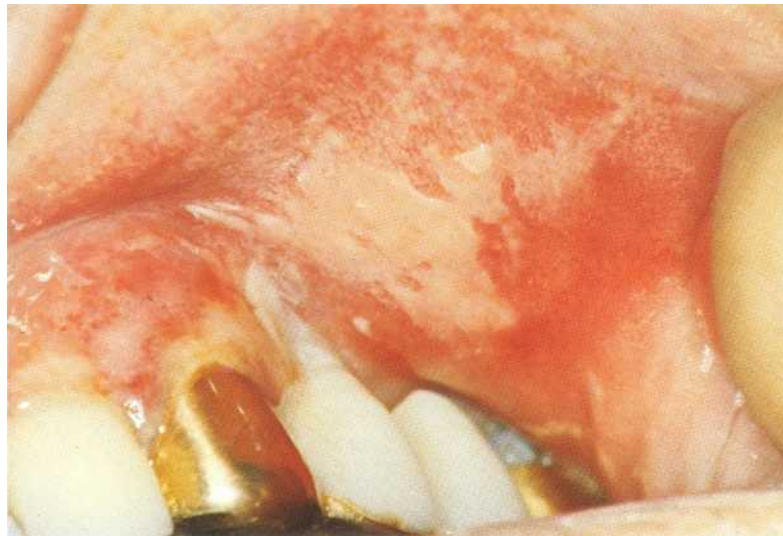

Fig. 96. Iodine burn.

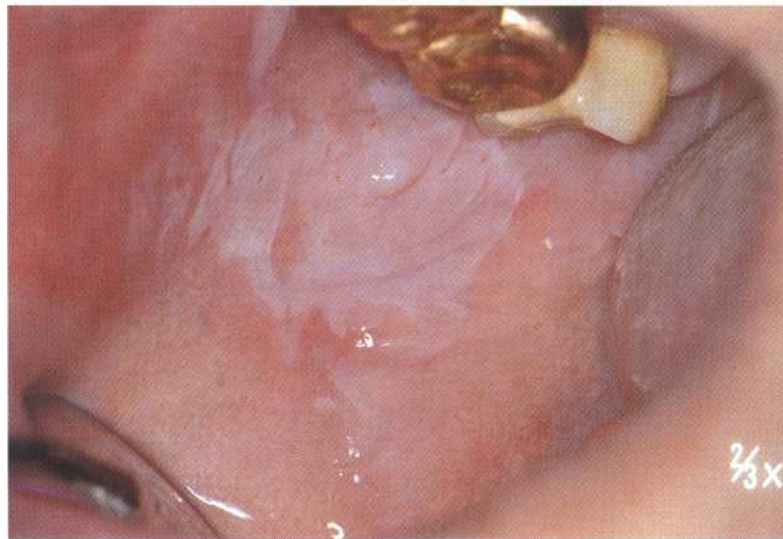


Fig. 97. Alcohol burn.

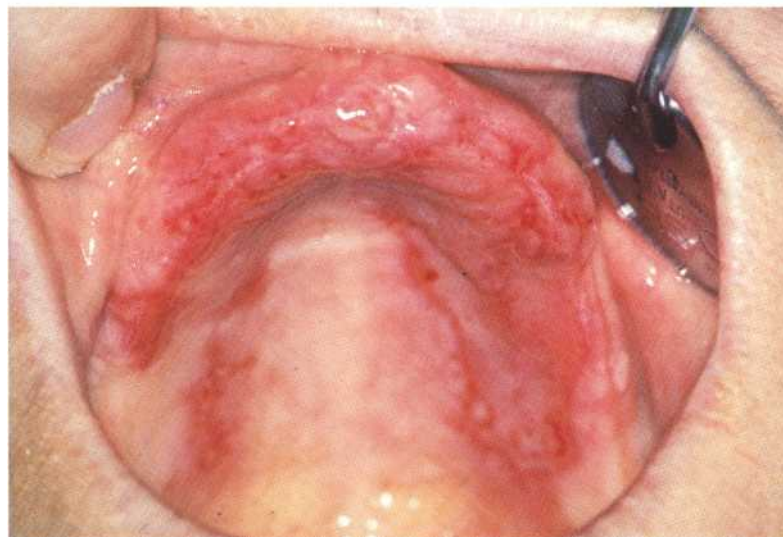


Fig. 98. Acrylic resin burn.

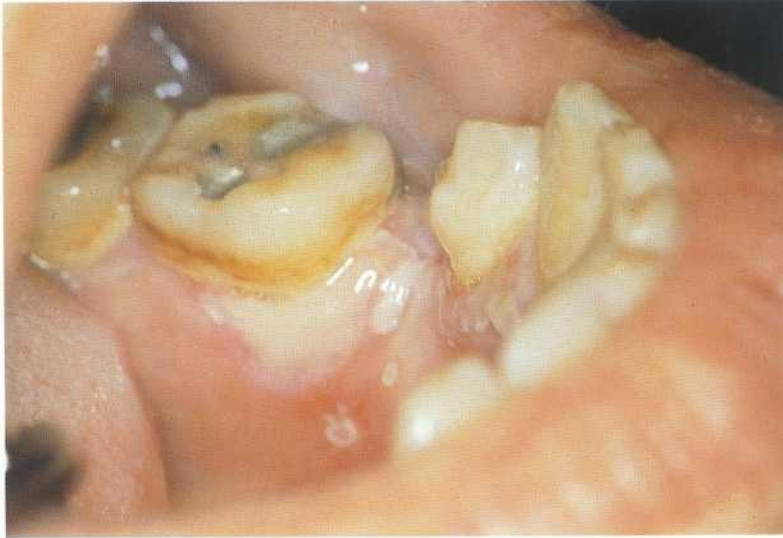

Fig. 99. Sodium perborate burn.

### **Sodium Perborate Burn**

Sodium perborate has been used as an antiseptic and hemostatic mouthwash. With repeated use, however, it can cause a burn on the oral mucosa that is manifested as an erythematous and edematous area or rarely as a superficial erosion that heals spontaneously (Fig. 99).

### **Silver Nitrate Burn**

Silver nitrate was used in the past by dentists and otolaryngologists as a cavity sterilizing agent or for cauterization of various oral lesions. At the site of application, it creates a painful burn with a whitish or brown surface and erosion (Fig. 100). Silver nitrate has no place in modern practice.

### **Sodium Hypochlorite Burn**

Sodium hypochlorite is used in endodontics for mechanical irrigation of root canals and as a mild antiseptic. In contact with the oral mucosa, it may cause a mild burn (Fig. 101). The affected mucosa is red and painful, with superficial erosions that heal spontaneously within 4 to 6 days.

### **Paraformaldehyde Burn**

Paraformaldehyde was used in the past for pulp mummification. It is an extremely caustic chemical agent and in contact with the oral mucosa it may cause severe necrosis of oral tissues (Fig. 102). The lesions heal within 1 to 2 weeks. Paraformaldehyde has no place in modern endodontic practice.

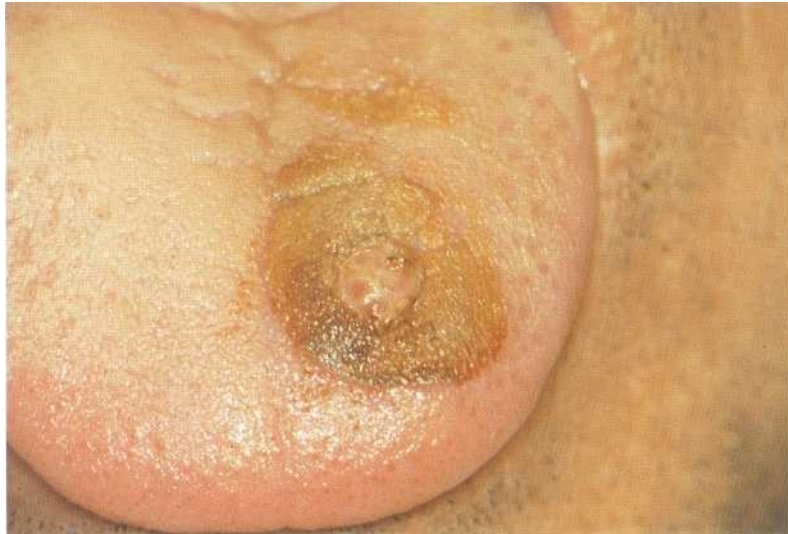

Fig. 100. Silver nitrate burn.

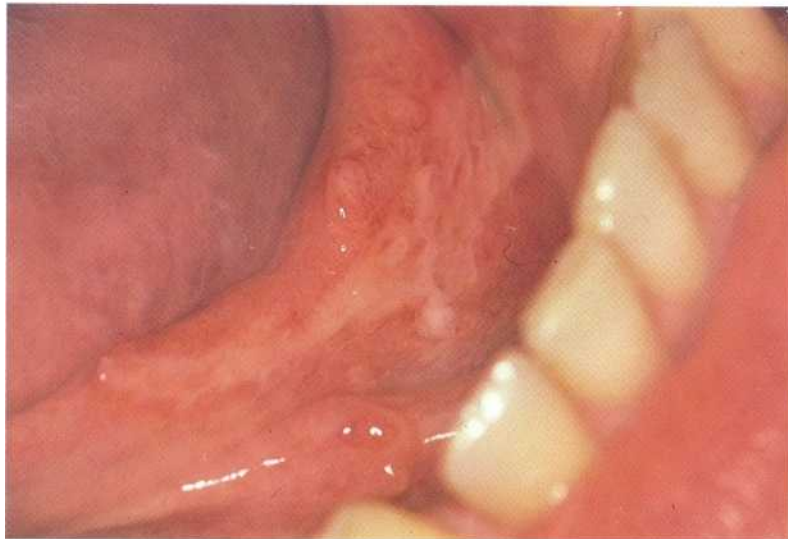


Fig. 101. Sodium hypochlorite burn.

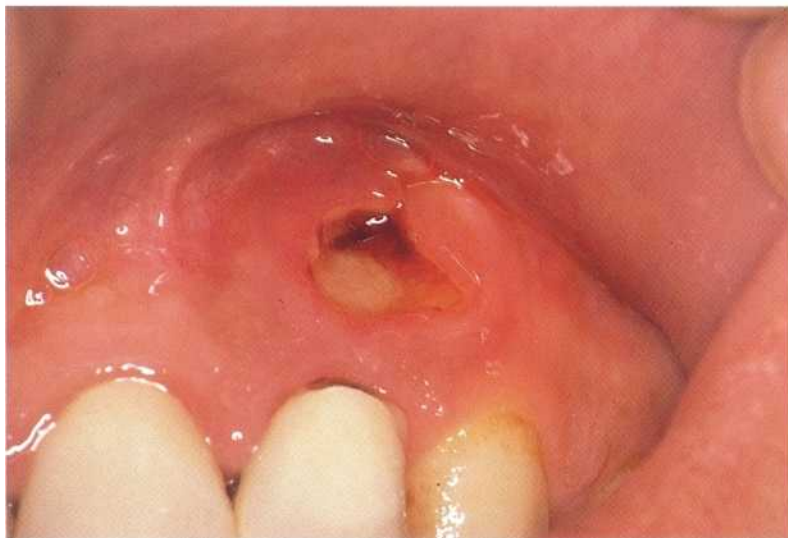

Fig. 102. Paraformaldehyde burn.



**Chlorine Compounds Burn**

Accidental contact of chlorine compounds with the oral mucosa causes burn and necrosis. Clinically, a whitish painful erosion or ulceration of the oral mucosa is detected, covered with a necrotic membrane (Fig. 103). Full recovery can be expected within 1 to 2 weeks.

**Agricultural Chemical Agents Burn**

A wide range of chemical agents is used in agriculture. Accidental contact of agricultural compounds with the oral mucosa may cause chemical burns. The severity and extent of such burns depends on the nature of the particular agent, the duration of contact with the oral tissues, and the concentration and quantity of the compound. Burns due to agricultural compounds present in a variable fashion, ranging from redness all the way to painful extensive erosions covered with whitish necrotic epithelial debris (Fig. 104).

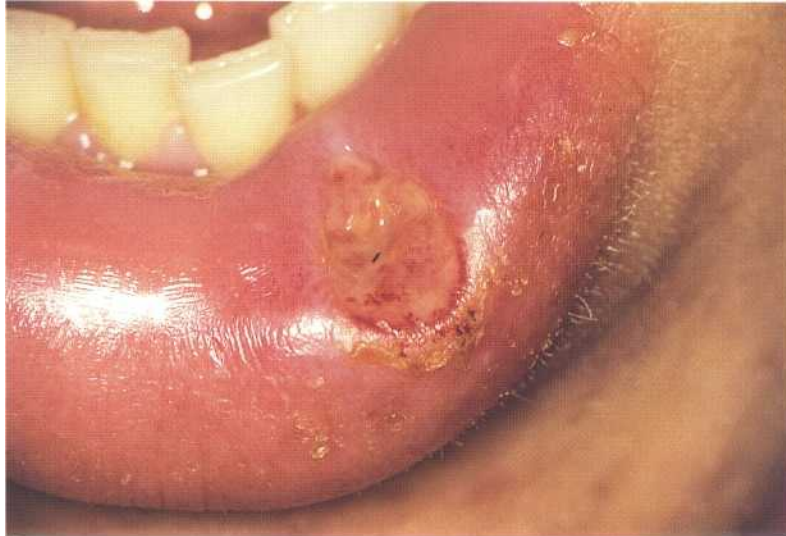


Fig. 103. Chlorine compound burn.

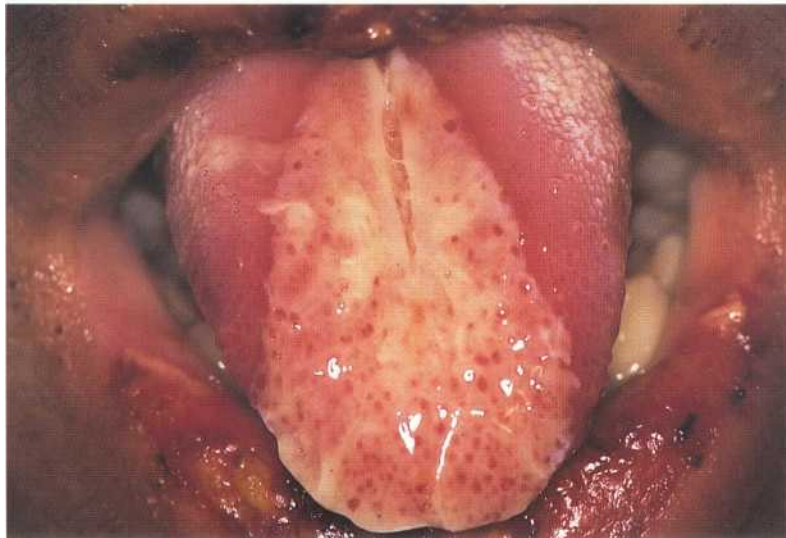


Fig. 104. Severe and extensive erosions on the tongue and lips due to accidental contact with agricultural compound.

## 6. Oral Lesions due to Smoking and Heat

### Nicotinic Stomatitis

Nicotinic stomatitis, or smoker's palate, occurs almost exclusively in heavy pipe smokers and only rarely in cigarette or cigar smokers. Thermal and chemical agents acting locally are responsible for the occurrence of this condition. Clinically, nicotinic stomatitis is manifested with redness on the palate, which later assumes a grayish-white and multinodular appearance due to keratinization of the epithelium.

A characteristic finding is the appearance of multiple red dots, 1 to 5 mm in diameter, which represent the dilated and inflamed orifices of minor salivary gland ducts. In heavy smokers there are fissures, furrows, and elevations forming an irregular wrinkled surface (Figs. 105, 106).

Nicotinic stomatitis is not a precancerous lesion and has a good prognosis. However, it should not be confused with lesions associated with reversed smoking, which have serious consequences and high risk of malignant transformation.

Laboratory test. Histopathologic examination may show a characteristic pattern.

Treatment. Cessation of smoking.

### Palatal Erosions due to Smoking

In heavy smokers consuming more than 60 cigarettes a day, palatal painful erosions may occur in addition to nicotinic stomatitis (Fig. 107). The erosions are due to the elevated temperature in the oral cavity for a long time. Thickening of the epithelium and white lesions may also occur.

The differential diagnosis includes traumatic erosions, chemical burns, erythroplakia, and rarely other specific erosions.

Treatment. Cessation of smoking and biopsy to rule out epithelial dysplasia or carcinoma.

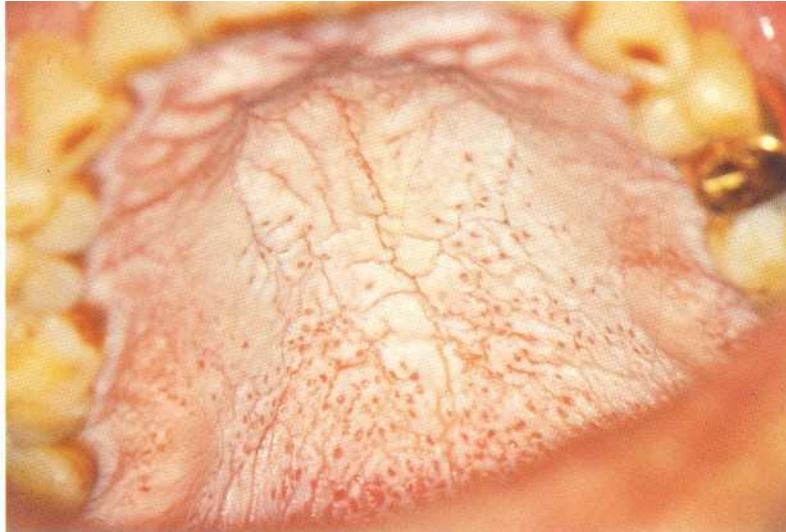


Fig. 105. Nicotinic stomatitis.

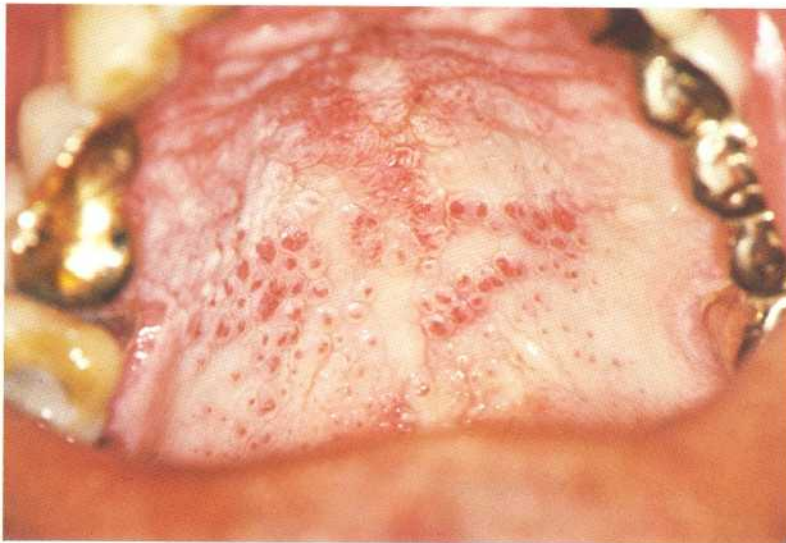

Fig. 106. Nicotinic stomatitis.

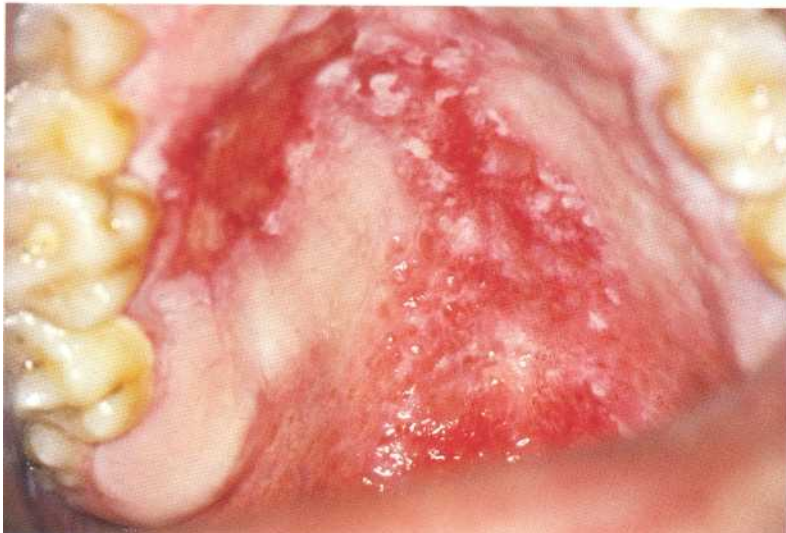

Fig. 107. Palatal erosions caused by smoking.

### **Cigarette Smoker's Lip Lesion**

Cigarette smoker's lip lesion appears commonly in smokers of nonfiltered cigarettes who hold them between the lips for a long time until short cigarette butts remain. The lesions characteristically appear on the mucosal surface of the lower and upper lips. It is a common finding in psychiatric patients.

The lip lesions correspond to the site at which the cigarette is held and are characterized by flat or slightly elevated whitish areas with red striations (Fig. 108).

The differential diagnosis includes leukoplakia, lichen planus, mechanical friction, chemical burn, and candidosis.

Treatment. Cessation or reduction of smoking.

### **Smoker's Melanosis**

Smoker's melanosis is a benign focal pigmentation of the oral mucosa frequently involving the attached mandibular gingiva, particularly on the labial side of the anterior teeth. It is due to melanin deposition within the basal cell layer and the lamina propria. Smoker's melanosis is more common in females usually after the third decade of life and is related to tobacco consumption and not to drugs, systemic diseases, or genetic factors. About 25-31% of tobacco users display smoker's melanosis.

Clinically, the lesions usually present as multiple brown pigmented macules less than 1 cm in diameter, localized mainly at the attached labial anterior gingiva and the interdental papillae of the mandible (Fig. 109). Buccal mucosa and palate pigmentation has been associated with pipe smoking.

The differential diagnosis includes racial melanosis, habit pigmentation, amalgam tattoo, melanosis due to medications, pigmented nevi, lentigo, freckles, Addison's disease, Peutz-Jeghers syndrome, Albright's syndrome, and von Recklinghausen's disease.

Treatment. No treatment is required.

### **Thermal Burn**

Thermal burns of the oral mucosa are rare. However, very hot foods (such as pizzas, melted cheese), liquid, or hot metal objects may produce mild or severe thermal burns. The palate, lips, floor of the mouth, and tongue are most frequently affected. Clinically, the oral mucosa is painful, red, and may undergo desquamation, leaving small or extensive erosions (Fig. 110). Vesicles may also appear. The lesions heal in about one week. The history is very important in order to make the correct diagnosis. The patient usually remembers the incident that caused the burn.

The differential diagnosis includes chemical burns, traumatic ulcers, aphthous ulcers, herpes simplex, stomatitis medicamentosa, and fellatio.

Treatment. Supportive treatment is recommended.

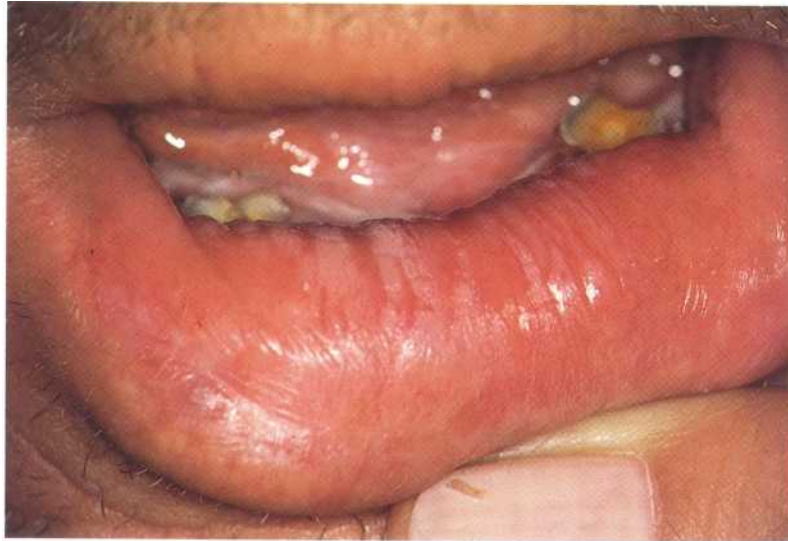

Fig. 108. Cigarette smoker's lip lesions.

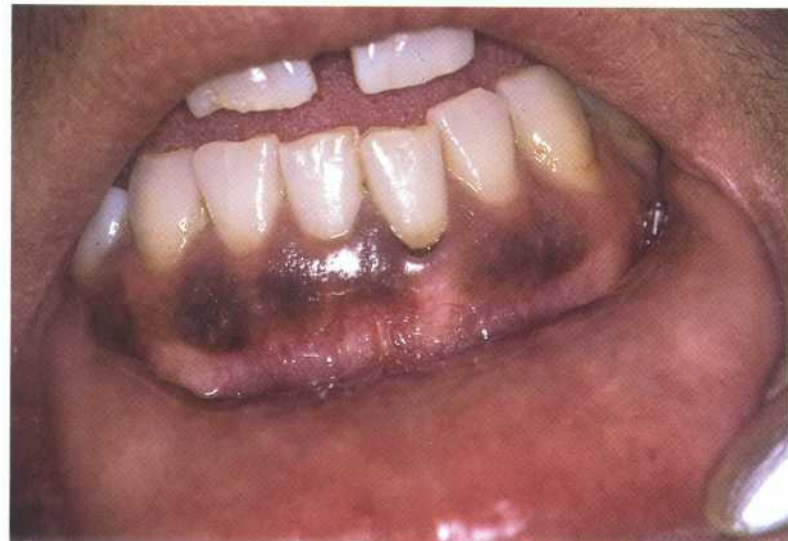

Fig. 109. Smoker's melanosis of the gingiva.

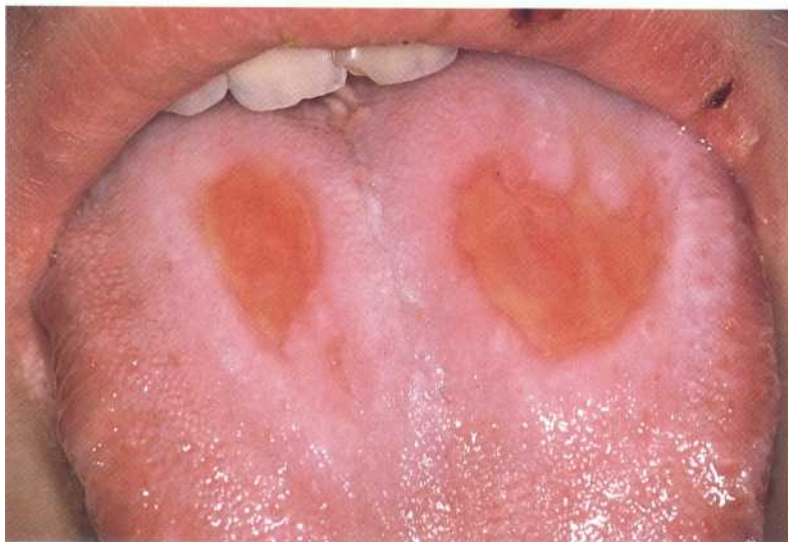

Fig. 110. Erosions on the dorsum of the tongue caused by very hot food.

## 7. Oral Lesions due to Drugs

### Gold-induced Stomatitis

Gold compounds are used selectively in patients with rheumatoid disorders. Gold is stored in the tissues and is excreted slowly through the kidneys. Measurable amounts can be detected in the urine 8 to 10 months after cessation of the drug. Gold toxicity may be manifested with fever, headache, proteinuria, skin rashes, oral lesions, thrombocytopenia, agranulocytosis, or aplastic anemia. The oral mucosa is red, with painful erosions covered with a yellowish membrane (Fig. 111). There is an intense burning sensation and increased salivation. The diagnosis is based on the history and clinical features.

The differential diagnosis includes stomatitis medicamentosa, erythema multiforme, pemphigus vulgaris, cicatricial pemphigoid, bullous pemphigoid, and erosive lichen planus.

Treatment. Cessation of gold therapy. Antihistamines and low-dose steroids may be helpful.

### Antibiotic-induced Stomatitis

Systemic long-term administration of broad-spectrum antibiotics, such as tetracycline, may cause a form of stomatitis. Clinically, it is characterized by a nonspecific diffuse erythema of the oral mucosa. The tongue is extremely red and painful, with desquamation of the filiform papillae (Fig. 112). Hairy tongue and candidosis may also occur as a result of changes in the oral microbial flora.

The differential diagnosis includes stomatitis medicamentosa, erythema multiforme, pellagra, and ariboflavinosis.

Treatment. Interruption or change of antibiotics and B-complex vitamins are recommended. In the case of candidosis, nystatin is indicated.

### Stomatitis Medicamentosa

Systemic administration of medications may induce hypersensitivity reactions in the oral mucosa characterized as stomatitis medicamentosa, or pharmaceutical stomatitis.

A plethora of drugs may cause stomatitis medicamentosa, including antipyretics, non-steroid anti-inflammatory drugs, sulfonamides, antibiotics, and barbiturates. Clinically, the condition is characterized by diffuse erythema of the oral mucosa, purpuric patches, vesicles or bullae, painful erosions, ulcers, etc. (Fig. 113). Any area of the mouth may be involved. The lesions appear during or shortly after administration of a drug and may recur.

The differential diagnosis includes erythema multiforme, pemphigus, bullous pemphigoid, cicatricial pemphigoid, erosive and bullous lichen planus, etc.

Treatment. Cessation of the drug. Antihistamines or steroids in low doses.

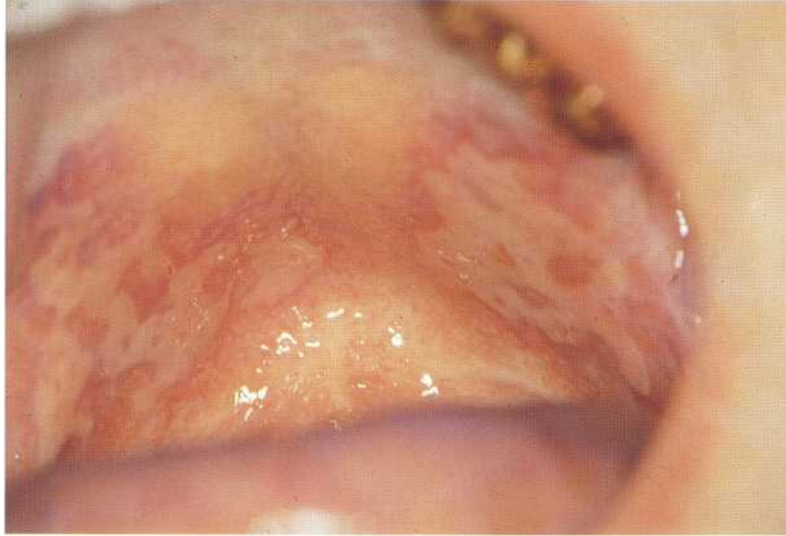

Fig. 111. Gold-induced stomatitis, erosions on the palate.

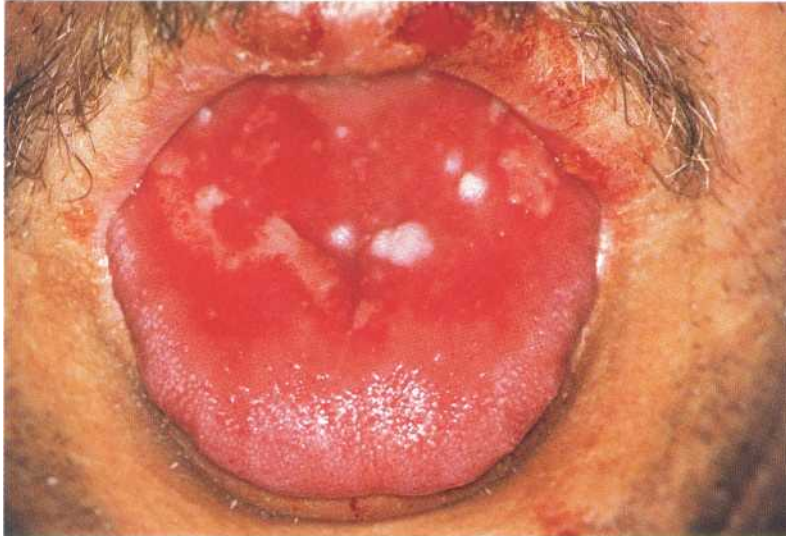

Fig. 112. Antibiotic-induced stomatitis, diffuse erythema and desquamation of the filiform papillae of the tongue.

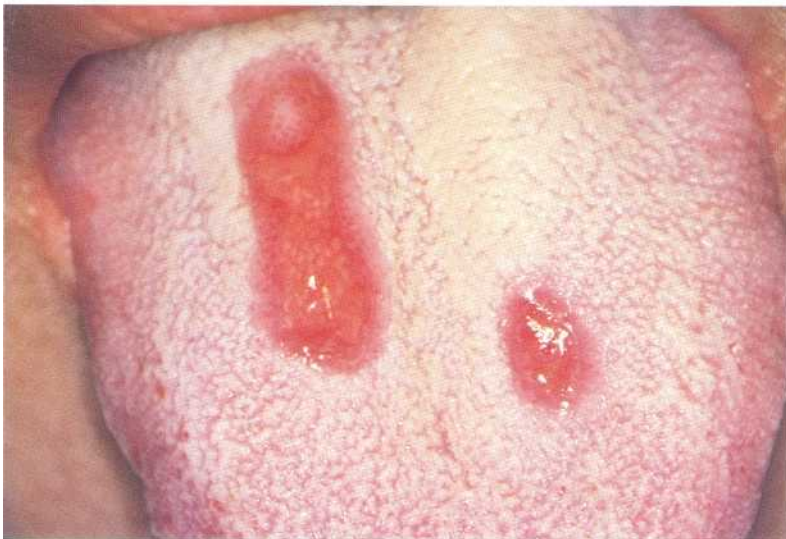

Fig. 113. Stomatitis medicamentosa, erosions on the dorsum of the tongue.



### Ulcerations due to Methotrexate

Methotrexate is a folic acid antimetabolite that is used in the treatment of leukemias, solid cancers, psoriasis, etc. Side effects occur by inhibiting the formation of nucleic acid in both malignant and normal cells. The most common side effects are alopecia, liver and gastrointestinal disorders, etc. Oral mucosal lesions are frequent and are characterized by redness and painful erosions or ulcers (Fig. 114). They commonly involve the tongue, lips, and buccal mucosa, although they may occur anywhere in the oral cavity.

These lesions appear 2 to 3 weeks after initiation of treatment and constitute an indication for cessation of drug or lowering of the dose.

The differential diagnosis includes traumatic ulcer, thermal and chemical burn, and stomatitis medicamentosa.

Treatment. Folic acid replacement and changing the drug, if possible.

### Ulceration due to Azathioprine

Azathioprine is an antimetabolite widely used as an immunosuppressive drug. Alopecia, gastrointestinal disorders, and bone marrow toxicity are the most common side effects. Rarely, limited erosions or ulcers of the oral mucosa may develop after long-term and high-dose administration (Fig. 115).

Treatment. Lowering the dose of the drug, and B-complex vitamin administration.

### Penicillamine-induced Oral Lesions

D-penicillamine, a heavy metal chelator used in the treatment of hepatolenticular degeneration (Wilson's disease) and other diseases (rheumatoid arthritis, primary biliary cirrhosis, scleroderma, cystinuria, and heavy metal intoxication), may be associated with mucocutaneous and noncutaneous side effects. The noncutaneous side effects include hematologic, pulmonary, gastrointestinal, renal, autoimmune, and allergic disorders. The most common cutaneous manifestations are autoimmune disorders (pemphigus group, cicatricial pemphigoid, lupus erythematosus), acute sensitivity reaction, interference with collagen and elastin, etc. The most common oral manifestation is penicillamine-induced pemphigus, which is characterized by vesiculobullous lesions and erosions of the oral mucosa, clinically, histopathologically, and immunologically identical to those seen in classic pemphigus. Commonly, involvement of the oral mucosa may be the first sign of the disease and rarely the only manifestation (Fig. 116). Penicillamine-induced pemphigus usually appears within 6 to 12 months after initiation of the drug and may resolve within several weeks after withdrawal of the drug. Cicatricial pemphigoid lesions, aphthous stomatitis, and taste loss are also oral complications of the drug. Pemphigus and cicatricial pemphigoid lesions are frequently seen in penicillamine-treated patients with rheumatoid arthritis.

The differential diagnosis of oral lesions includes classic pemphigus, cicatricial pemphigoid, bullous pemphigoid, erythema multiforme, and stomatitis medicamentosa.

Treatment is withdrawal of penicillamine and systemic steroids.

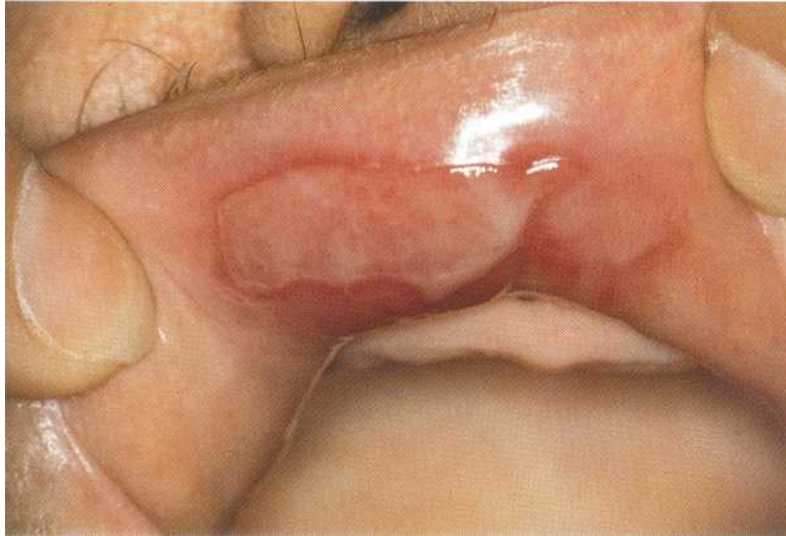

Fig. 114. Ulcer on the upper lip caused by methotrexate.

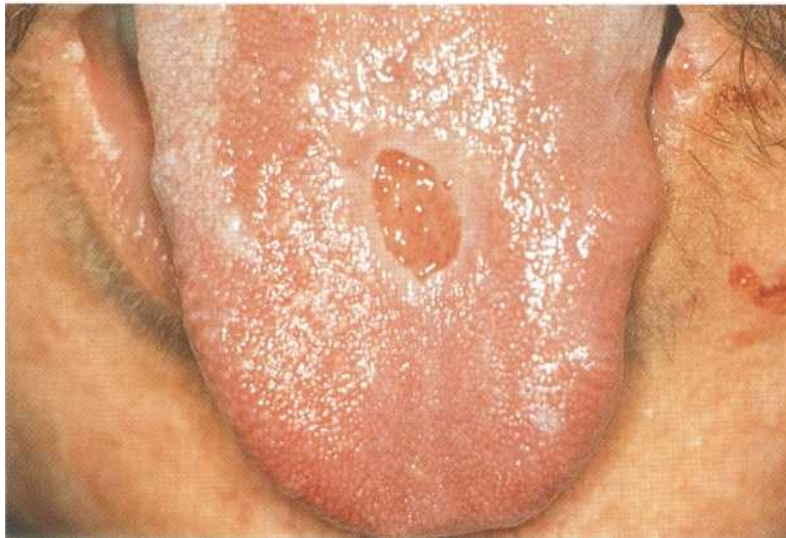

Fig. 115. Ulcer on the tongue caused by azathioprine.

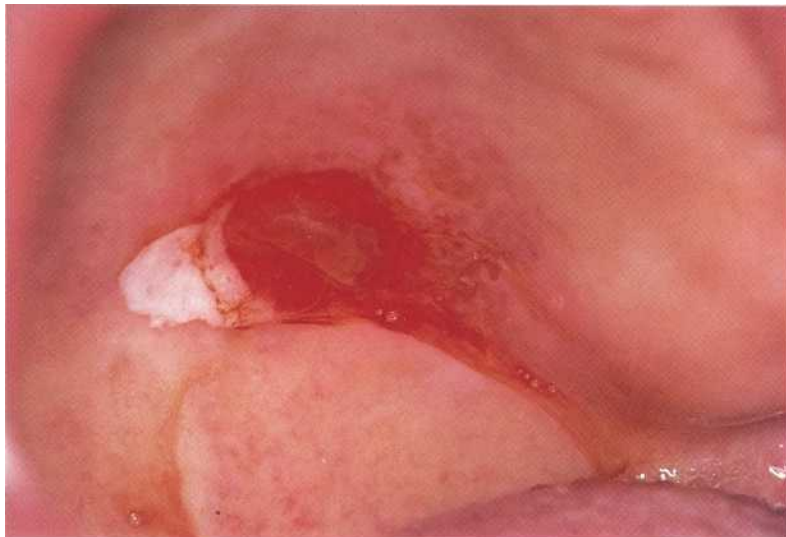

Fig. 116. Penicillamine-induced oral pemphigus, erosion on the palate.

### Phenytoin-induced Gingival Hyperplasia

Phenytoin is an antiepileptic agent widely used in patients with generalized seizures.

A common side effect is fibrous gingival hyperplasia, which occurs in 30 to 60% of the patients taking the drug. Although the exact mechanism of gingival hyperplasia is not clear, the appearance and degree of the hyperplasia depend on the daily dose, the duration of therapy, the state of oral hygiene, and other local and systemic factors. The hyperplasia usually begins in the interdental papillae and gradually involves the marginal and attached gingiva. With gradual progression, the gingiva may cover the crowns of the teeth entirely.

The gingivae are firm, lobulated, slightly red, and painless, with little or no tendency to bleed (Fig. 117). Usually, the enlargement of the gingiva is generalized. Rarely, hyperplasia may occur in edentulous patients.

The differential diagnosis includes cyclosporine and nifedipine-induced hyperplasia, idiopathic fibromatosis of the gingiva, and gingival hypertrophy due to mouth breathing or leukemia.

**Treatment.** Careful oral hygiene, surgical excision. Discontinuation of the drug or change to another antiepileptic agent may result in regression of the hyperplasia.

### Cyclosporine-induced Gingival Hyperplasia

Cyclosporine is a powerful immunosuppressive drug used to prevent organ transplant rejection and to treat lupus erythematosus and many other autoimmune diseases. Several side effects of cyclosporine have been reported, such as hypertension, hepatotoxicity, nephrotoxicity, hirsutism, mild tremor, and predisposition to cancers. Gingival hyperplasia is a common side effect occurring in between 30 to 70% of the patients receiving cyclosporine therapy. Cyclosporine-induced gingival hyperplasia is related to the time of therapy, the serum concentration of the drug, and the presence of dental plaque. It is more common in children and adolescents than adults, and the degree of gingival enlargement may vary from mild or moderate to severe. Clinically, the gingiva is enlarged, firm with focal lobulation, and little inflammation (Fig. 118).

The differential diagnosis includes fibrous gingival hyperplasia due to phenytoin, and nifedipine, gingival fibromatosis, gingivitis, periodontitis, and leukemia.

**Treatment.** Gingivectomy. The lesions are usually reversible after cessation of the drug.

### Nifedipine-induced Gingival Hyperplasia

Nifedipine is a calcium channel-blocking agent widely used in patients with coronary insufficiency and hypertensive disorders. The drug may cause gingival hyperplasia. The exact mechanism of this complication is unknown, although local alterations in calcium metabolism seem to play a role. Recently other calcium ion antagonists such as nitrendipine, felodipine, verapamil, and exodipine have also appeared to cause gingival hyperplasia.

The dose of the drug and the duration of therapy, in association with the dental plaque and other local factors, seem to play a role in the development of gingival hyperplasia. The incidence of gingival hyperplasia is not well known. Recently, gingival hyperplasia has been observed in 51% of nifedipine-treated, renal transplant patients, compared with 8% in patients not on nifedipine.

Clinically, the gingiva is painless, enlarged, firm, lobulated, with no or little inflammation, and usually partly covers the teeth (Fig. 119). The overgrowth is more evident in the interdental papillae and less commonly in the free and attached gingiva. The gingival enlargement may be localized or generalized and is most prominent in the vestibular aspect of the anterior region.

The differential diagnosis includes phenytoin and cyclosporine-induced gingival hyperplasia, hyperplasia due to other calcium-blocking drugs, hereditary gingival fibromatosis, mouth breathing gingival hyperplasia, scurvy, and gingival hyperplasia due to systemic diseases such as leukemia, Wegener's granulomatosis, Crohn's disease, amyloidosis and sarcoidosis, acanthosis nigricans, Zimmermann-Laband syndrome, and Hurler's syndrome.

**Treatment.** Good oral hygiene. Gingivectomy is usually necessary, although hyperplasia may be reduced after cessation of the drug.

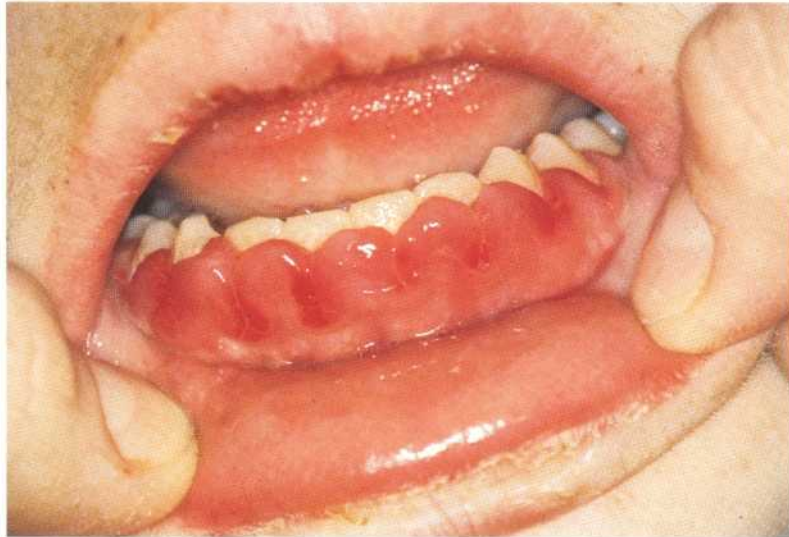

Fig. 117. Fibrous gingival hyperplasia caused by phenytoin.

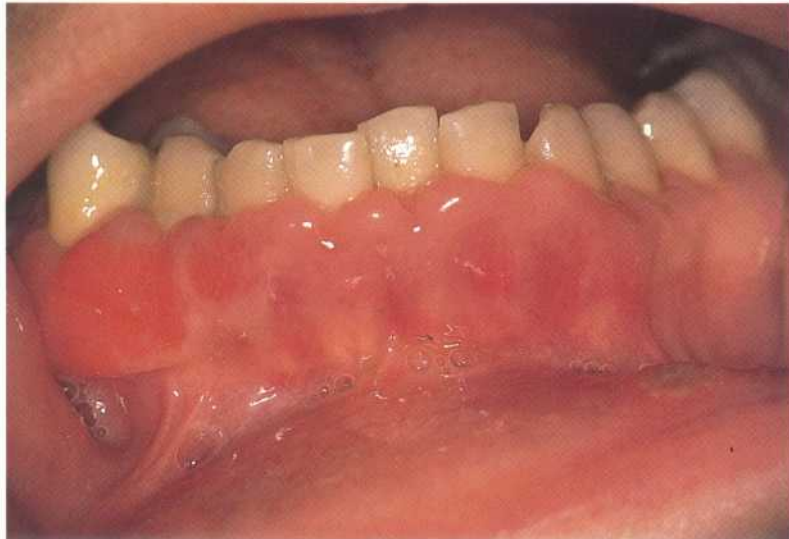

Fig. 118. Gingival hyperplasia caused by cyclosporine.

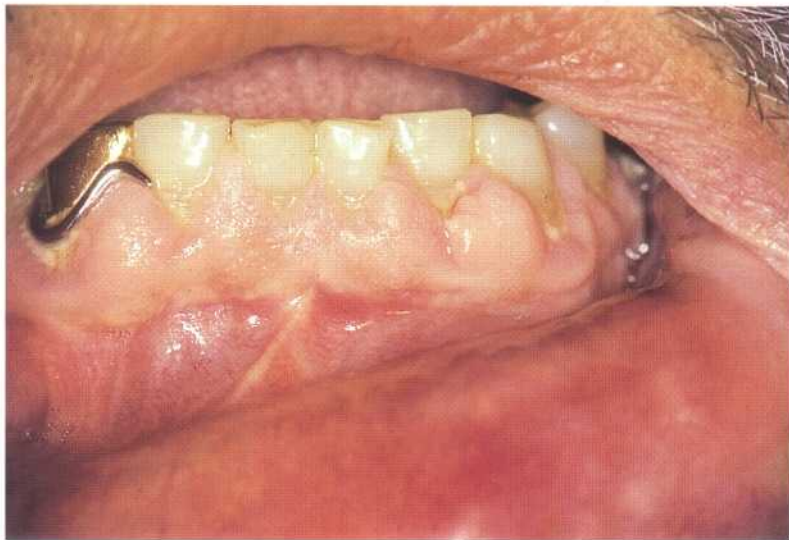

Fig. 119. Gingival hyperplasia caused by nifedipine.

### Angioneurotic Edema

Angioneurotic edema is a common allergic reaction that may be acquired or inherited. The inherited form is associated with C1 esterase inhibitor deficiency and is inherited as an autosomal dominant trait. In addition to sudden facial edema, edema of the larynx and tongue, which involves the gastrointestinal tract, with abdominal pain, nausea, vomiting, and diarrhea, also occur. The acquired form is far more frequent and may be due to food allergy, pharmaceuticals, local anesthetics, infections, and emotional stress. These factors may act either directly on mast cells or through an immunoglobulin E-mediated allergic reaction to cause release of inflammatory mediators, such as histamine, kinins, and leukotrienes. The result is capillary leakage and submucosal or subcutaneous edema.

Angioneurotic edema of either type has a sudden onset, lasts usually for 24 to 48 hours, and may recur at variable time intervals. Clinically, it is characterized by painless, usually nonpruritic and smooth swelling involving the lips (Fig. 120), tongue, soft palate, face, hands, feet, or any other area. Edema of the glottis represents a severe complication that may result in death.

The differential diagnosis should include trauma, surgical emphysema, cellulitis, cheilitis granulomatosa, Melkersson-Rosenthal syndrome, and cheilitis glandularis.

Treatment. Antihistamines, systemic steroids, and in acute severe cases epinephrine subcutaneously.

### Pigmentation due to Antimalarials

Chloroquine and other antimalarials are used in the treatment of malaria and occasionally in patients with rheumatoid arthritis and lupus erythematosus. Long-term use may cause brown or black irregular pigmentation on the soft palate or other areas of the oral cavity (Fig. 121). These discolorations must be differentiated from Addison's disease and usually remit with interruption of the drug.

The differential diagnosis includes other drug-induced pigmentation, Peutz-Jeghers syndrome, Albright's syndrome, and Addison's disease.

### Pigmentation due to Azidothymidine

Azidothymidine (zidovudine, AZT) is the most important drug used in the management of patients with HIV infection. Several side-effects of the drug have been reported, e.g., nausea and bone marrow depression. Recently, nail and skin pigmentation as well as pigmentation of the oral mucosa have been described usually shortly after starting treatment. Clinically, oral pigmentation appears as irregular macules with a brown or dark brown color. The tongue, buccal mucosa, and palate are the most commonly affected sites (Fig. 122). Clinicians should keep in mind that ketoconazole may produce oral pigmentation during antimycotic therapy of HIV-infected patients.

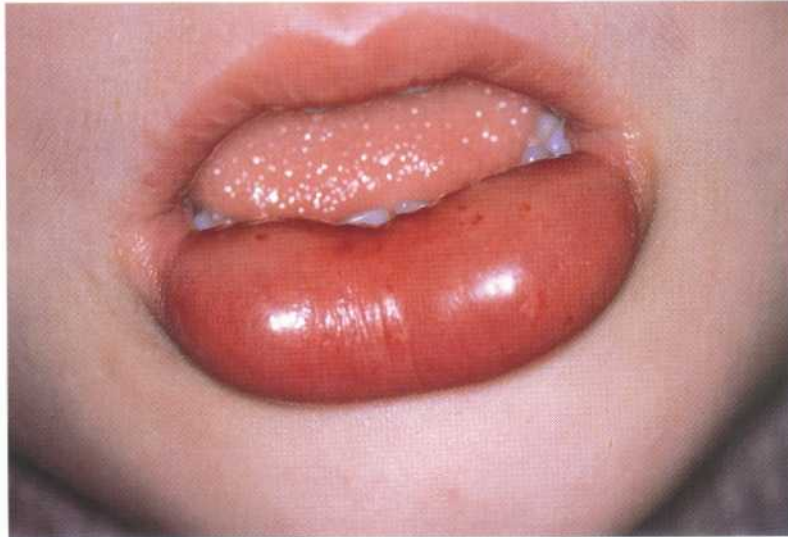

Fig. 120. Angioneurotic edema, swelling of the lower lip.

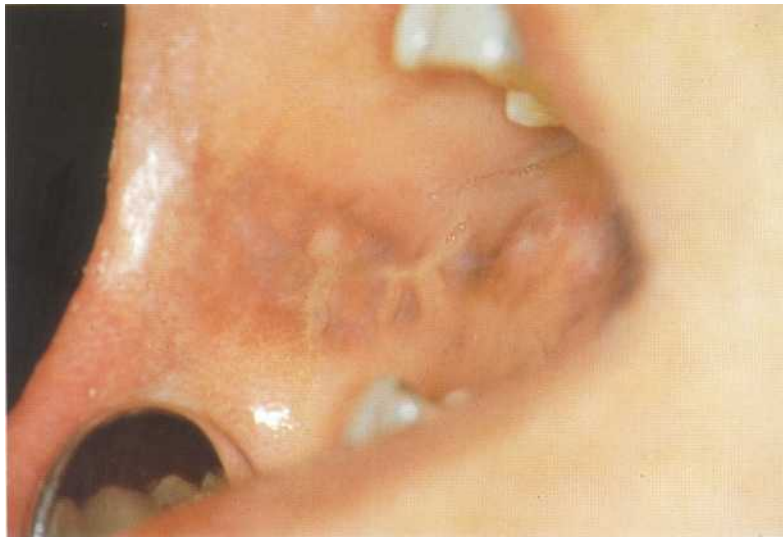

Fig. 121. Pigmentation of the buccal mucosa caused by chloroquine.

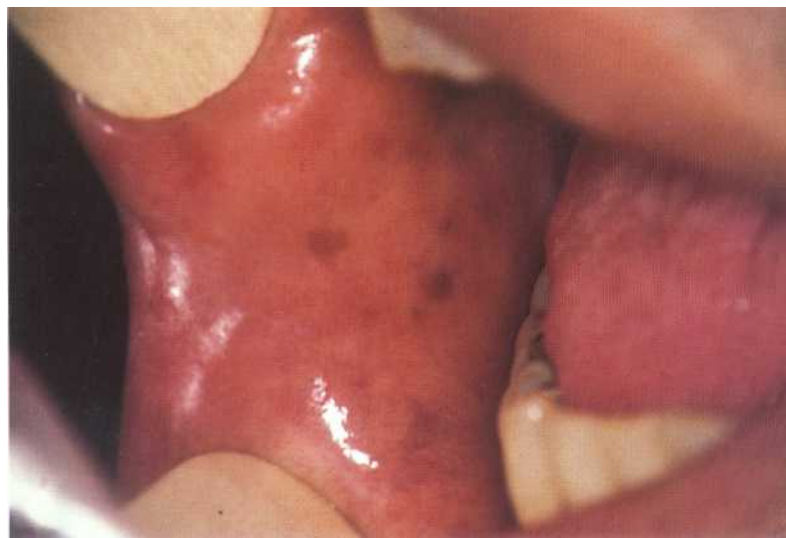
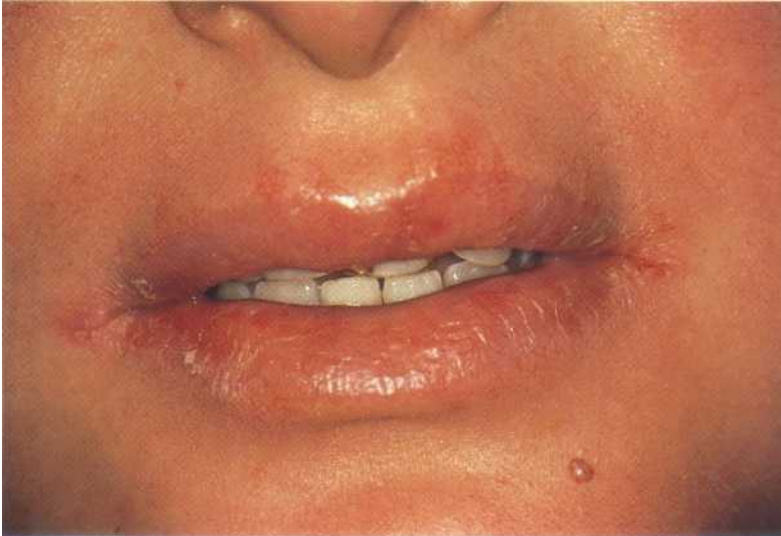

Fig. 122. Melanotic spots on the buccal mucosa caused by azidothymidine.



**Fig. 123. Cheilitis caused by systemic administration of the aromatic retinoid etretinate.**

### **Cheilitis due to Retinoids**

During the last decade, synthetic retinoids (13-cis-retinoic acid and the aromatic analogue of retinoic acid, etretinate) have been introduced as new agents in the modern therapy of skin diseases. They are extremely effective drugs in various disorders of keratinization. In addition, they have anti-inflammatory and immunomodulatory effects. Synthetic retinoids have recently been used in the treatment of psoriasis, acne vulgaris, ichthyosis, lichen planus, parapsoriasis en plaques, mycosis fungoides, Darier's disease, and other keratotic genodermatoses.

Several side effects may appear during retinoid administration. The most common are dryness with scaling of the lips and dryness of the oral mucosa (Fig. 123). Hair loss, palmoplantar scaling, thinning of the skin, pruritus, epistaxis, paronychia, and vomiting may also occur. No severe complications have been observed after retinoid administration in therapeutic dosages. However, pregnancy must be avoided during treatment and one year thereafter because of the teratogenic and embryotoxic action of these drugs.

**Treatment.** Cheilitis and dryness of the mouth remit after discontinuing the drugs.

## 8. Metal and Other Deposits

### Amalgam Tattoo

Amalgam deposition develops either as a result of continuous contact between an amalgam filling and the gingiva or from embedding of amalgam fragments in the oral tissues during dental filling or surgical operations. In addition, during tooth extraction, fragments of amalgam restorations are broken off and may be embedded in the adjacent soft tissues. Amalgam tattoo appears as a well-defined flat area with a bluish-black or brownish discoloration of varying size (Fig. 124). Amalgam deposits usually occur in the gingiva, the alveolar mucosa, and the buccal mucosa.

The differential diagnosis includes pigmented nevi, malignant melanoma, normal pigmentation, and hematoma.

Laboratory test. Histopathologic examination and radiographs are necessary on occasion to differentiate amalgam tattoo from other lesions of the oral mucosa with dark discoloration.

Treatment. No treatment is required.

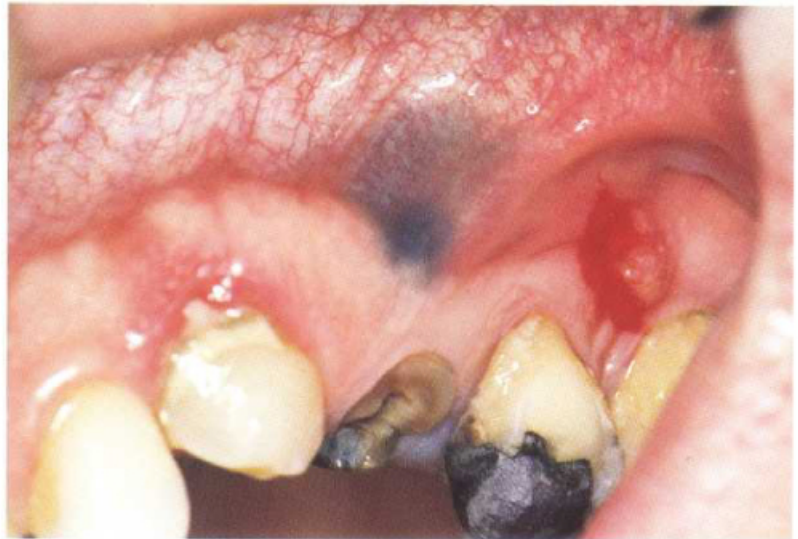

Fig. 124. Amalgam tattoo.



### **Bismuth Deposition**

Bismuth compounds were formerly used in the treatment of syphilis. However, in recent years antibiotics have replaced these compounds in the treatment of syphilis. Oral discolorations due to bismuth are now rarely encountered except in patients who have been treated for syphilis in the preantibiotic era and have poor oral hygiene. Clinically, bismuth deposition forms a characteristic bluish line along the marginal gingiva or black spots within the gingival papillae (Fig. 125). Less frequently, bismuth may be deposited in other areas of the oral mucosa, mainly the periphery of ulcers or in areas of inflammation.

The differential diagnosis includes normal pigmentation, silver deposition, amalgam tattoo, and Addison's disease.

Treatment. No treatment is required.

### **Phleboliths**

Phleboliths are calcified thrombi that occur in veins and blood vessels. The phenomenon is a characteristic feature of cavernous hemangiomas. It is accepted that thrombi are produced by a slowing of the peripheral blood flow, and become secondarily organized and mineralized. Such calcified thrombi constitute the core of the phlebolith. Clinically, it appears as a hard, painless swelling of the oral soft tissues typically associated with hemangiomas, although in some cases there are no signs of hemangiomas (Fig. 126).

The differential diagnosis includes salivary gland calculi, calcified lymph nodes, and soft-tissue tumors.

Laboratory tests. Histopathologic examination confirms the diagnosis. Radiograms, angiography, and computed tomography are also helpful.

Treatment is surgical excision.

### **Materia Alba of the Attached Gingiva**

Materia alba is the result of accumulation of bacteria, dead epithelial cells, and food debris. It is usually found at the dentogingival margins of persons with poor oral hygiene. However, materia alba presenting as a white plaque along the vestibular surface of the gingiva and the alveolar mucosa may be seen in patients who are unable to brush their teeth because of painful oral diseases (Fig. 127). The white plaque is soft and easily detached after slight pressure, leaving a red surface.

The differential diagnosis should include leukoplakia and candidosis.

Treatment is good oral hygiene.

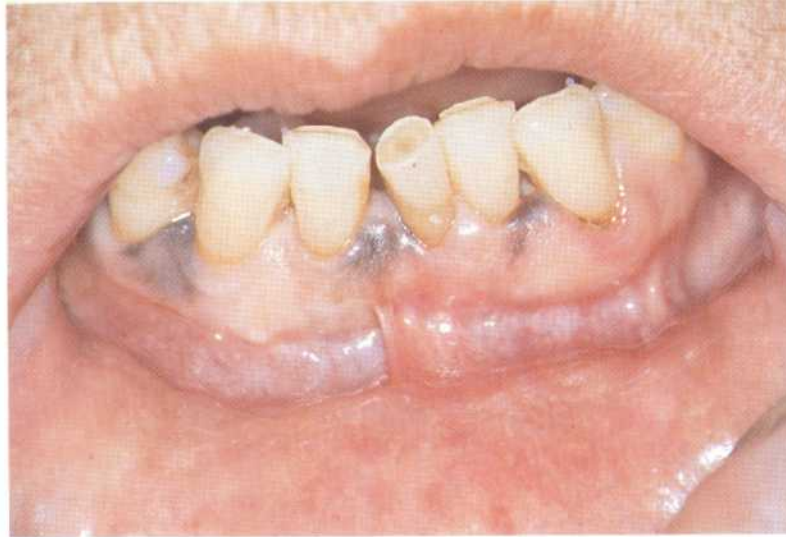

Fig. 125. Bismuth deposition within the gingival papillae.

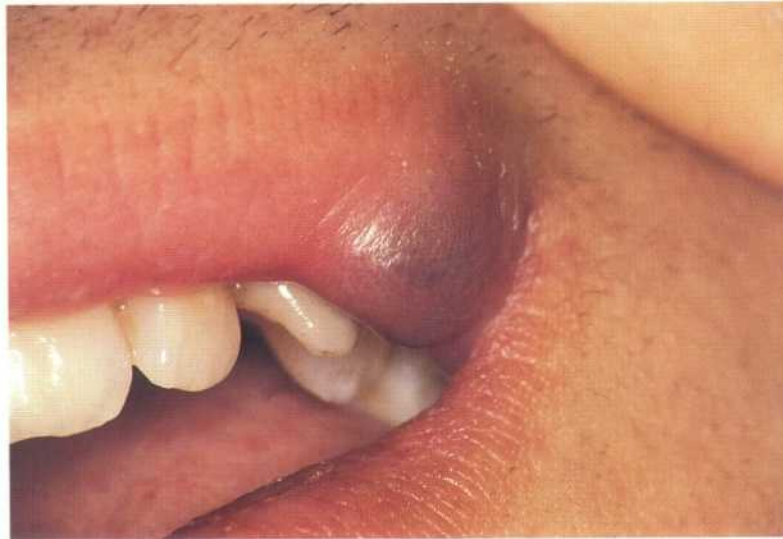

Fig. 126. Hemangioma and phlebolith on the upper lip.

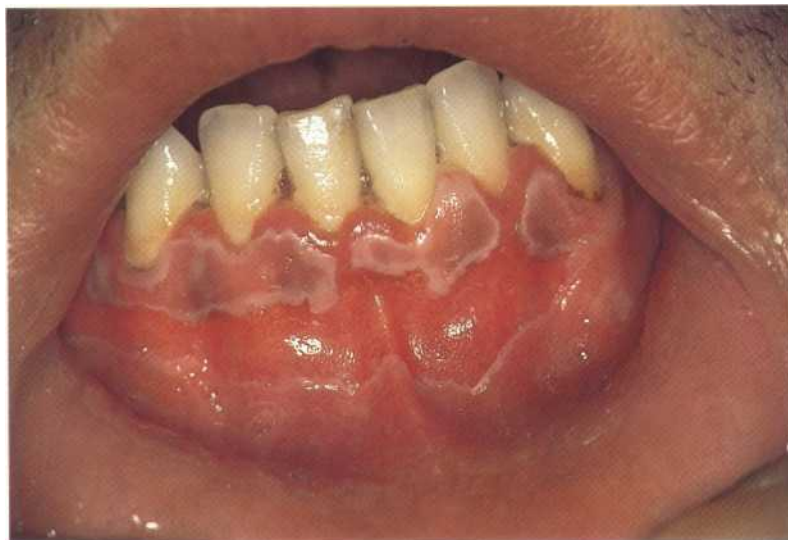

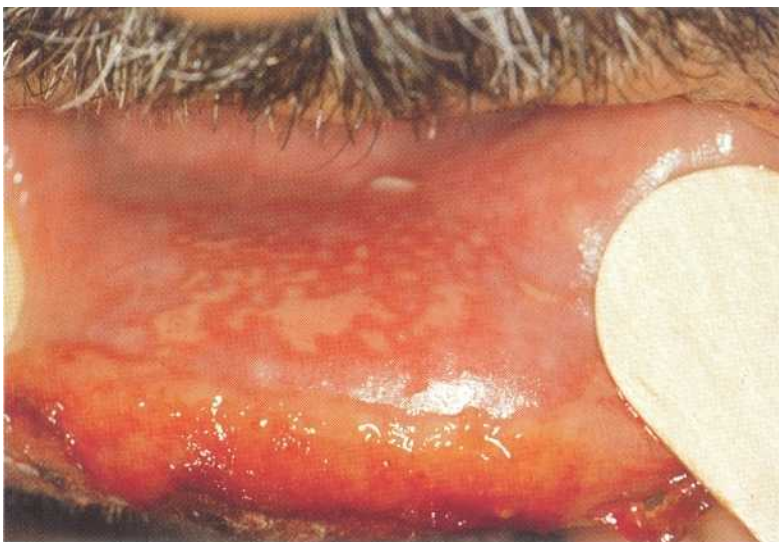
Fig. 127. White plaques on the attached gingiva and the alveolar mucosa caused by materia alba accumulation.

## 9. Radiation-induced Injuries

Radiation therapy has a prominent place in the treatment of oral and other head and neck cancers. The most common form of radiation used is ionizing radiation, delivered by an external source, or radioactive implants (gold, iridium, etc.).

Ionizing radiation, in addition to its therapeutic effect, can also affect normal tissues. The oral mucosal side effects after radiation are mainly dependent on the dose and the duration of treatment. These radiation-induced mucosal reactions may be classified as early and late. Early reactions appear at the end of the first week of therapy and consist of erythema and edema of the oral mucosa. During the second week, erosions and ulcers may appear, which are covered by a whitish-yellow exudate (Figs. 128, 129). Subjective complaints include malaise, xerostomia, loss of taste, burning, and pain during mastication, speech, and swallowing. The lesions persist during the treatment period and for several weeks there-

after. If the salivary glands are irradiated, xerostomia is one of the earliest and most common findings. Spontaneous remission of oral lesions may occur gradually after termination of the radiation treatment. However, secondary infection may delay recovery. Late manifestations are usually irreversible and result in extremely sensitive atrophic oral mucosa. The teeth, in the absence of salivary protection, rapidly develop caries and finally are destroyed (Fig. 130). Osteoradionecrosis is a serious complication and occurs in cases of high-dose radiation, especially if inadequate measures are taken to reduce the radiation dosage delivered to the bones. It is manifested as painful osteomyelitis with bone necrosis and sequestration and, rarely, formation of extraoral fistulas (Fig. 131). The mandible is more frequently affected than the maxilla. The risk of this complication is increased particularly if teeth within the radiation field are extracted after irradiation. Lymphoedema may also occur (Fig. 132).



**Fig. 128.** Erythema and erosions on the lower lip caused by ionizing radiation.

Fig. 129. Erosion of the tongue caused by radioactive iridium.

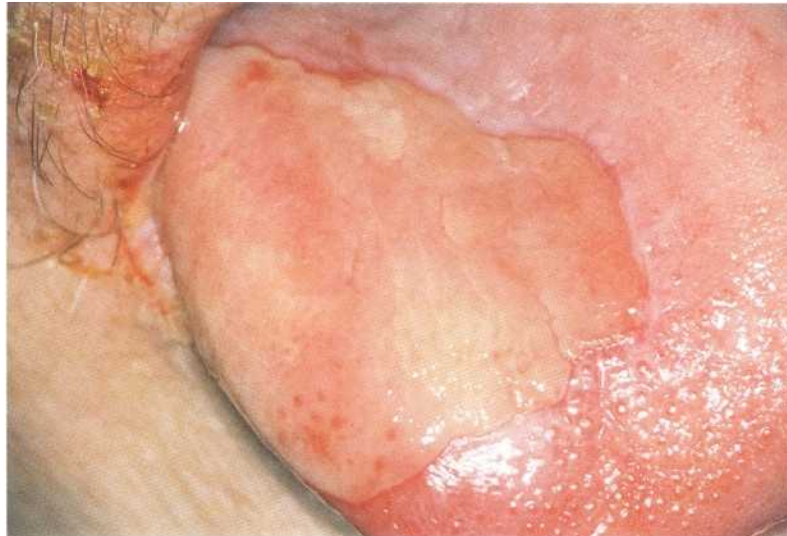


Fig. 130. Dental and gingival lesions caused by ionizing radiation.

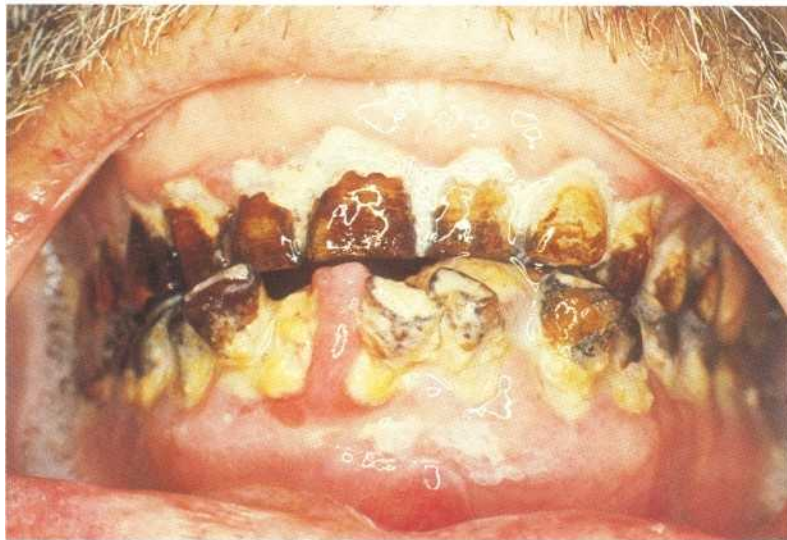
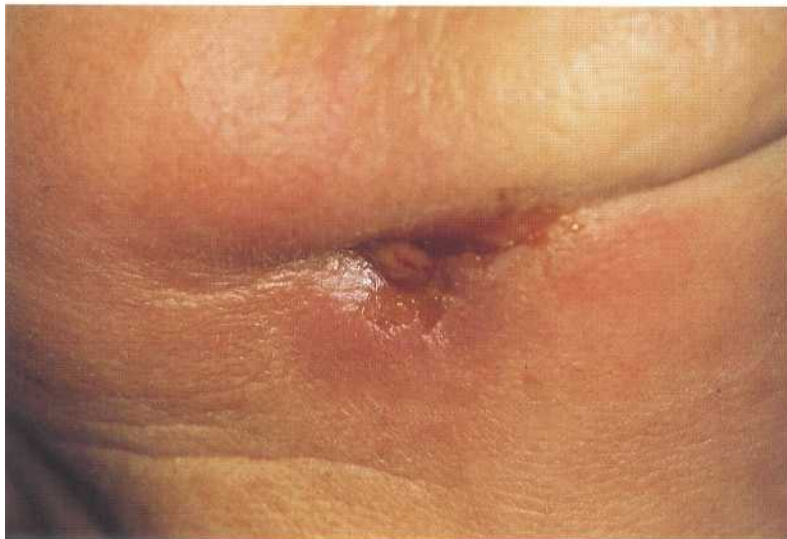
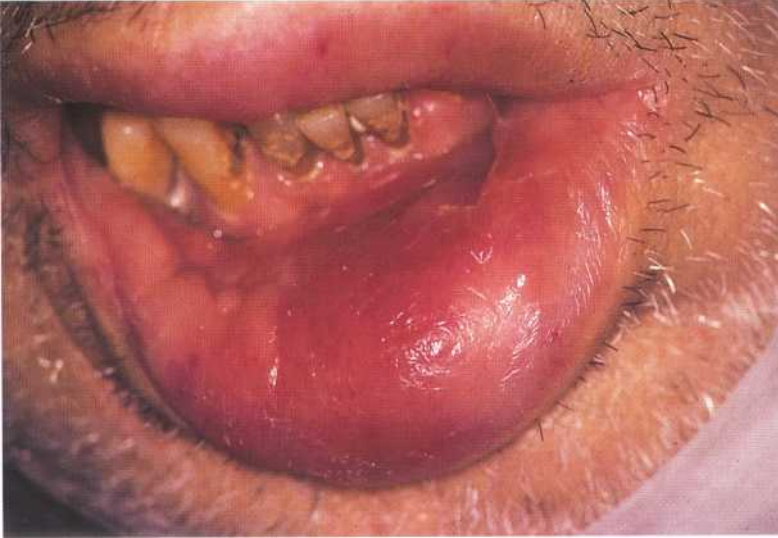Fig. 131. Extraoral fistula after radiation.





**Fig. 132. Lymphoedema of the lower lip after radiation.**

Diagnosis of oral lesions due to radiation depends on the medical history and the clinical features.

**Treatment should** include preventive measures, cessation of the, radiation therapy, analgesics, topical steroids, anti-inflammatory agents, B-complex vitamins, and antibiotics in case of oral mucosa and bone infections.

## 10. Allergy to Chemical Agents Applied Locally

### Allergic Stomatitis due to Acrylic Resin

True allergy of the oral mucosa to denture base material is very rare. The residual acrylic monomer (methyl methacrylate), however, is believed to be responsible for allergic reactions of the oral mucosa in susceptible persons. Alternatively, traces of other allergenic substances absorbed within the denture base may be the cause of the allergic reactions.

Allergic acrylic stomatitis is characterized by diffuse erythema, edema, and occasionally small vesicles and erosions, especially in areas of contact with the dentures (Figs. 133, 134). The patient complains of intense burning of the mouth and this reaction may extend to areas of the oral mucosa that are not in direct contact with the dentures. Removal of the dentures usually results in complete resolution. The skin patch test is usually positive.

The differential diagnosis includes denture stomatitis and reactions to other allergens.

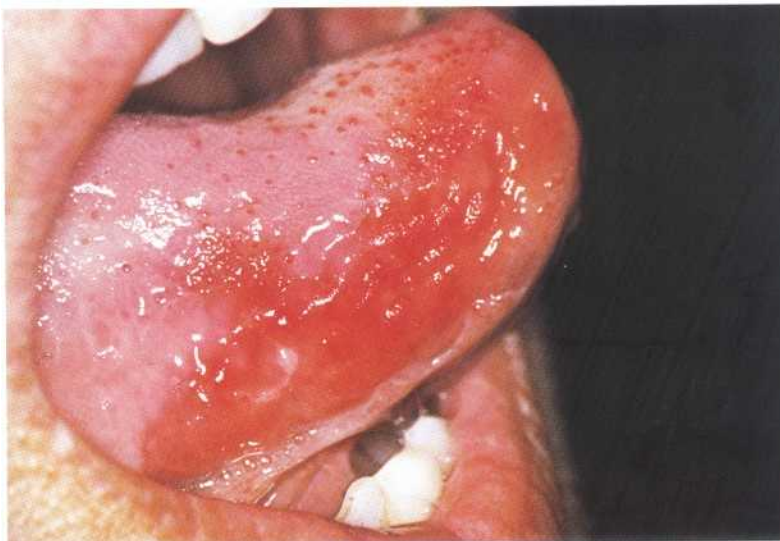
Treatment consists of oral antihistamines and construction of new dentures with fully polymerized monomer.

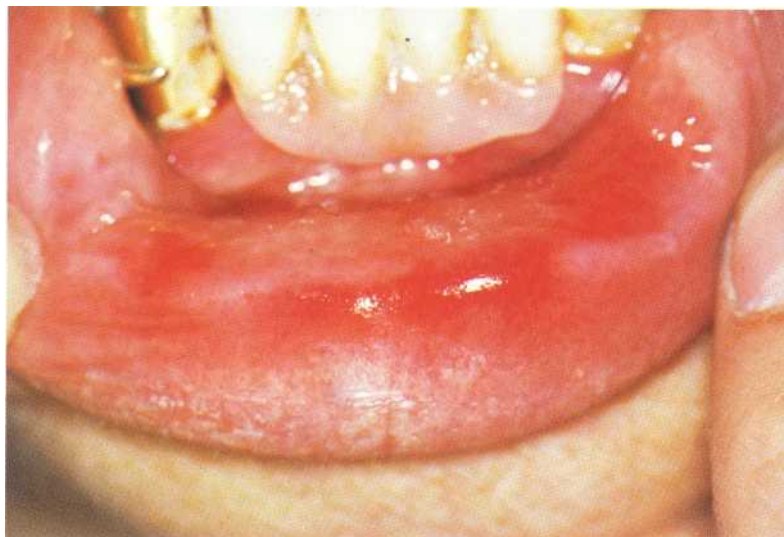
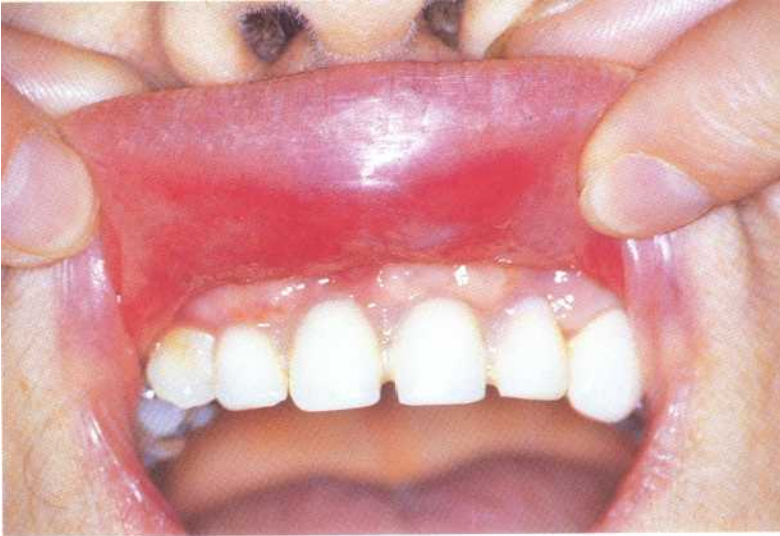
Fig. 133. Allergic stomatitis caused by acrylic resin.



**Fig. 134. Allergic stomatitis caused by acrylic resin.**



**Fig. 135. Allergic stomatitis caused by eugenol.**

### **Allergic Stomatitis due to Eugenol**

Eugenol has many uses in dentistry as an antiseptic, filling material, and periodontal pack. In sensitized patients it may cause generalized allergic reactions after direct contact with the oral mucosa.

In localized reactions there is redness, edema, and erosions that are covered with whitish pseudomembranes (Fig. 135). Subjectively, there is intense pain. The skin patch test is usually positive.

**Treatment consists** of removal of the eugenol and the use of antihistamines.

## 11. Periodontal Diseases

### Gingivitis

Gingivitis is an inflammatory disease of the gingiva caused by dental microbial plaque. Factors that contribute to the accumulation of plaque are poor oral hygiene, faulty restorations, tooth malposition, calculus, food impaction, mouth breathing, etc. In addition, several systemic disorders, such as endocrine diseases, immune deficiencies, nutritional disturbances, and drugs, are known to be modifying factors of host response to the microbial activity of plaque. The severity of gingivitis is related to local factors and the host resistance. Clinically, the gingiva appear red and swollen, with decreased and finally loss of normal stippling.

An early and common feature is gingival bleeding, even after mild local stimulation. Inflammation is mainly located at the marginal gingiva and the interdental papillae without development of periodontal pockets (Fig. 136). However, if gingival hyperplasia is severe, pseudopockets may be formed. Gingivitis is frequently chronic, although occasionally acute or subacute forms may occur. If chronic gingivitis is not treated, it frequently evolves into periodontitis.

**Treatment.** Good oral hygiene, complete removal of calculus from the teeth, and repair of faulty restorations are indicated.

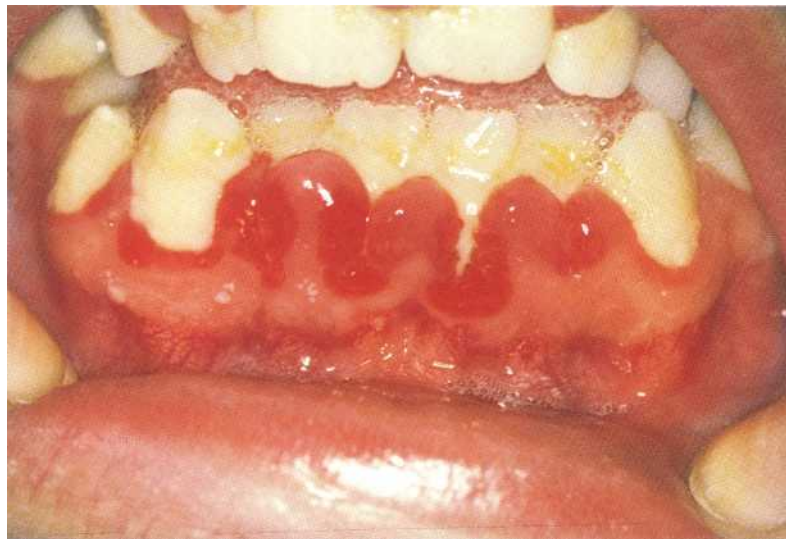


Fig. 136. Gingivitis.



## Periodontitis

Periodontitis is a chronic inflammatory disease that involves all periodontal tissues (gingiva, periodontal ligament, cementum, alveolar bone) and usually follows chronic gingivitis. Local factors also contribute to the development of periodontitis, but the most important factor is host resistance to local infection. Recently, an aggressive form of periodontitis has been recorded in patients with acquired immune deficiency syndrome. The cardinal clinical features of periodontitis are periodontal pocket formation and alveolar bone loss. Other findings include gingival swelling, redness and bleeding, gingival hyperplasia or recession, pyorrhea, varying degree of tooth mobility, and migration (Fig. 137).

Laboratory test. Radiographic examination confirms the diagnosis.

Treatment. The treatment consists of an effective plaque control regimen followed by scaling and root planing, surgical procedures, and, in certain cases, systemic antibiotics.

## Juvenile Periodontitis

Juvenile periodontitis is an inflammatory gingival disease that occurs in otherwise healthy children and young adults. Although the exact cause remains obscure, recent evidence suggests that infection by local specific microorganisms and host response play important roles in the pathogenesis of the disease.

Based on clinical, radiographic, microbiologic, and immunologic criteria, juvenile periodontitis is classified into two forms: localized juvenile periodontitis, which clinically is characterized by severe periodontal pocket formation and alveolar bone loss with mild or moderate inflammation localized mainly in the periodontal tissues of the permanent incisors and first molars, and generalized juvenile periodontitis, which is clinically characterized by generalized periodontal pockets and alveolar bone loss that involves almost all teeth along with gingival inflammation (Fig. 138).

The differential diagnosis includes juvenile periodontitis associated with several systemic diseases, such as Papillon-Lefevre syndrome, hypophosphatasia, acatalasia, histiocytosis X, cyclic neutropenia, agranulocytosis, juvenile diabetes mellitus, glycogen storage disease type 1b, Crohn's disease, and Ehlers-Danlos syndrome.

Laboratory tests to establish the diagnosis are radiographs, bacterial cultures, and immune studies.

Treatment. The treatment consists of plaque control followed by scaling and root planing, surgical procedures, and systemic antibiotics.

## Periodontal Abscess

Periodontal abscess is formed by localized pus accumulation in a preexisting periodontal pocket. When the depth of the periodontal pocket exceeds 5 to 8 mm, the edematous gingival tissues around the cervix of the tooth may approximate the tooth tightly and cause complete obstruction of the opening of the pocket so that a periodontal abscess is formed. Clinically, it appears as a painful soft, red gingival enlargement (Fig. 139). On pressure, pus exudes from the cervical area of the tooth. The teeth involved are tender to percussion and occasionally mobile. When substantial pus accumulation occurs, it diffuses into the surrounding tissues, resulting in cellulitis. Fever, malaise, and mild lymphadenopathy may be present.

The differential diagnosis includes dental abscess, gingival cyst of adults, palatine papilla cyst, nasolabial cyst, and actinomycosis.

Laboratory test. Radiographic examination may be helpful.

Treatment. Antibiotics during the acute phase and periodontal treatment.

Fig. 137. Periodontitis.

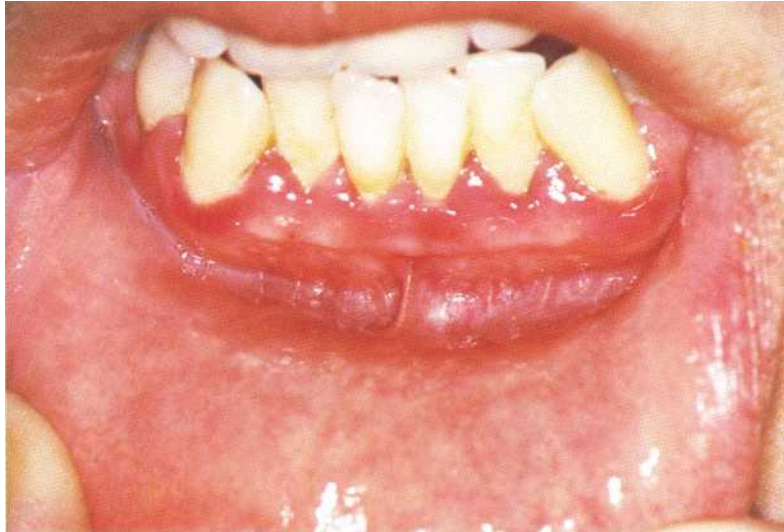

Fig. 138. Generalized juvenile periodontitis.

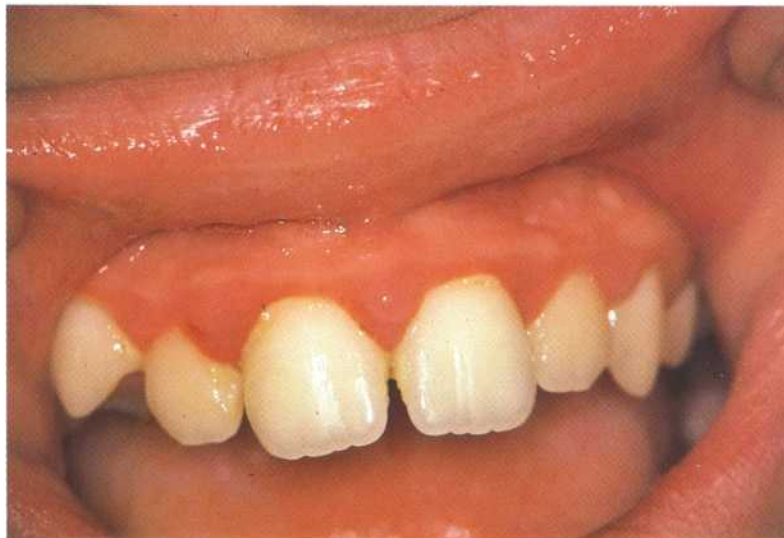
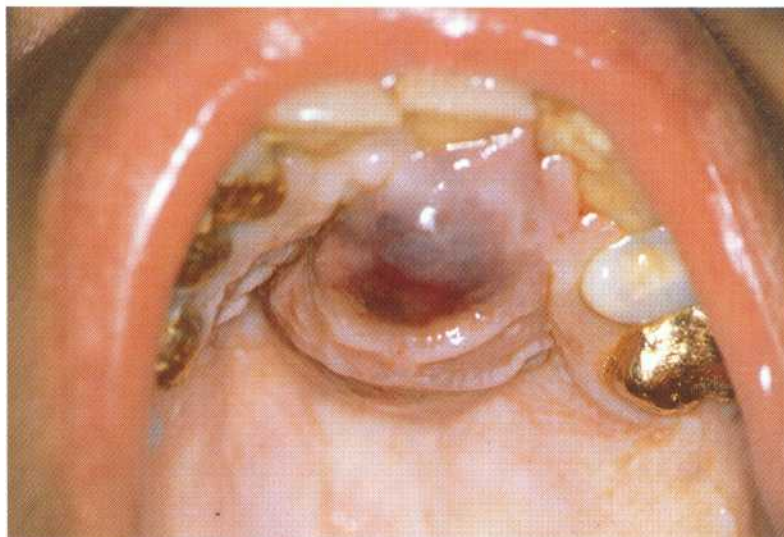
Fig. 139. Periodontal abscess.



### Periodontal Fistula

Periodontal fistula forms when pus bores through the gingival tissues and drains an underlying periodontal abscess. Clinically, the orifice of the fistula appears red, with granulomatous tissue formation (Fig. 140). On pressure, the orifice will release pus. The pulp of the neighboring teeth is vital.

The differential diagnosis includes periapical abscess and fistula, osteomyelitis, actinomycosis, and tuberculosis.

Treatment consists of surgical procedures, scaling, and root planing.

### Gingivitis and Mouth Breathing

Habitual mouth breathing favors the development of gingivitis with some special clinical features. This form of gingivitis affects the vestibular portion of the maxillary anterior gingiva in young persons. Clinically, the gingiva appear swollen, red, dry, and shiny, covering part of the crown of the teeth (Fig. 141).

### Plasma Cell Gingivitis

Plasma cell gingivitis is a unique disorder that histopathologically is characterized by a dense plasma cell infiltration of the gingival connective tissue. The disease shows clinical and histopathologic similarities to plasma cell balanitis or Zoon's balanitis. The precise cause remains obscure, although several factors have been incriminated, such as chronic infections, hormonal disorders, allergy, *Candida albicans*, and hypersensitivity to several components of chewing gum. Plasma cell gingivitis is more common in women between 20 and 50 years of age, and it usually lasts for several months or years. Clinically, both marginal and attached gingiva are bright red and edematous with a faintly stippled surface (Fig. 142). The gingivitis may be localized or widespread and frequently is accompanied by itching and burning. Similar lesions have been described on the tongue and lips.

The differential diagnosis includes desquamative gingivitis, gingivitis, geographic stomatitis, early leukemic gingival lesions, erythroplasia of Queyrat, candidosis, and psoriasis.

**Laboratory test.** Histopathologic examination confirms the diagnosis.

**Treatment.** Specific treatment does not exist. At times, antihistamines and nystatin may be helpful.

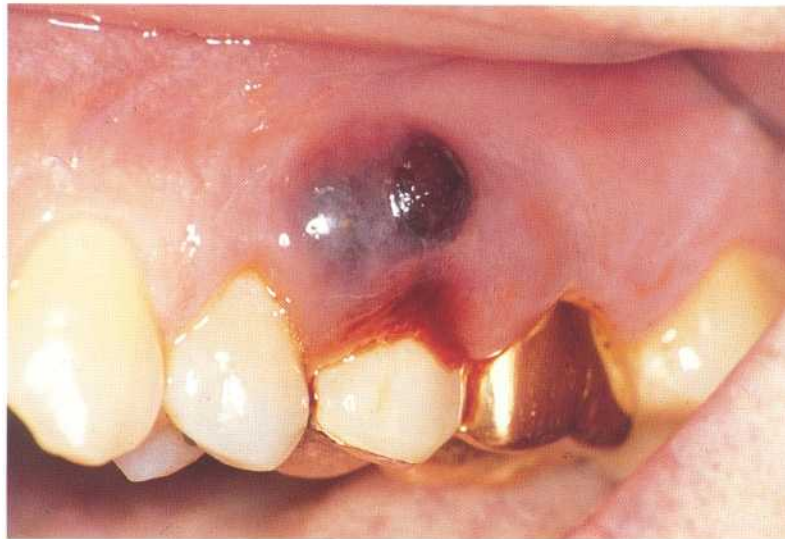

Fig. 140. Periodontal fistula.

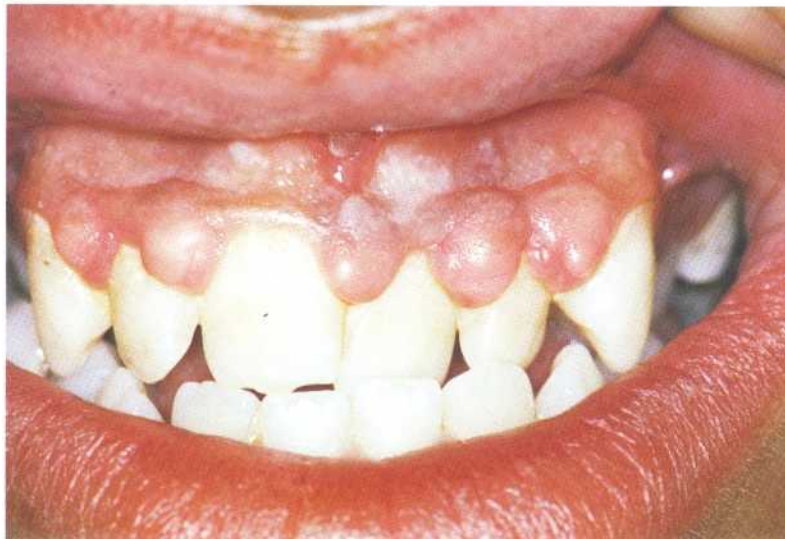

Fig. 141. Gingivitis caused by mouth breathing.

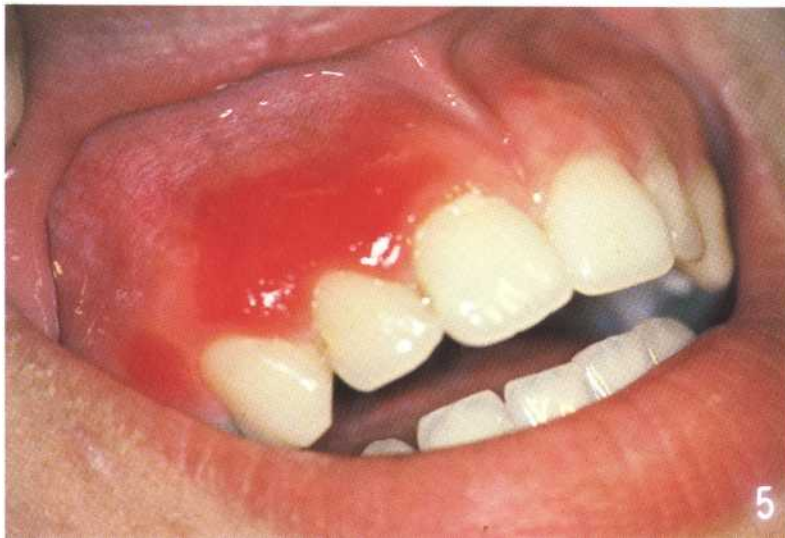

Fig. 142. Plasma cell gingivitis.

### **Desquamative Gingivitis**

Desquamative gingivitis does not represent a specific disease entity, but is a descriptive term used to name a rather nonspecific gingival manifestation of several disease processes. Recent findings suggest that the great majority of cases of desquamative gingivitis represents a manifestation of chronic bullous dermatoses, such as cicatricial pemphigoid, pemphigus vulgaris, bullous pemphigoid, and lichen planus. In a recent study of 453 patients with these disorders we found desquamative gingivitis in 63.6% of the cases with cicatricial pemphigoid, in 25% with lichen planus; in 18.4% with pemphigus vulgaris; and in 3.2% with bullous pemphigoid. Clinically, desquamative gingivitis is characterized by erythema and edema of the marginal and attached gingiva, predominantly labially and buccally (Figs. 143, 144). A characteristic sign is peeling off of the epithelium or elevation with subsequent forma-

tion of a hemorrhagic blister after massage of the gingiva. The gingival lesions may be either localized or diffuse. Desquamative gingivitis may be the only oral manifestation or may be associated with other oral manifestations of a chronic bullous dermatosis. In the presence of desquamative gingivitis the identification of the underlying disease is based on the following criteria: careful clinical observation of all intraoral and extraoral lesions, histopathologic examination of gingival biopsy specimens, direct immunofluorescence of gingival biopsy specimens, indirect immunofluorescent examination for serum epithelial antibodies, and clinical follow-up of the patient.

The differential diagnosis includes plasma cell gingivitis and chronic mechanical gingival trauma.

**Treatment.** The therapy of desquamative gingivitis depends on the identification and treatment of the underlying disease.

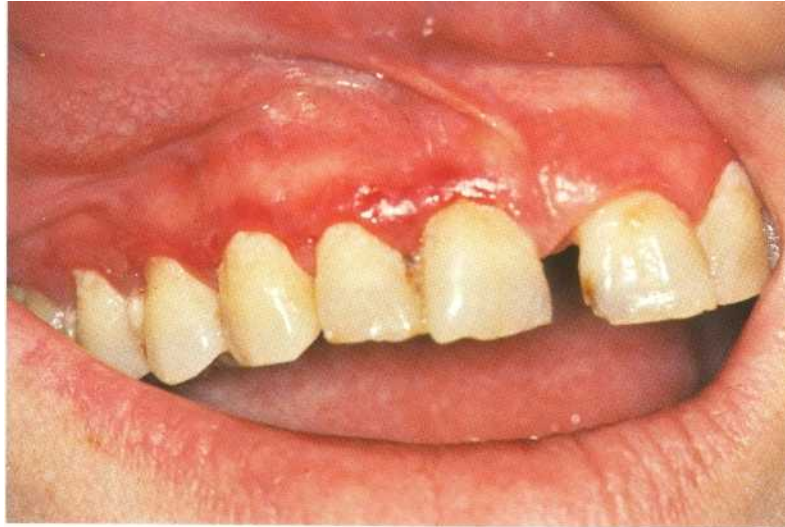

Fig. 143. Desquamative gingivitis as a manifestation of cicatricial pemphigoid.

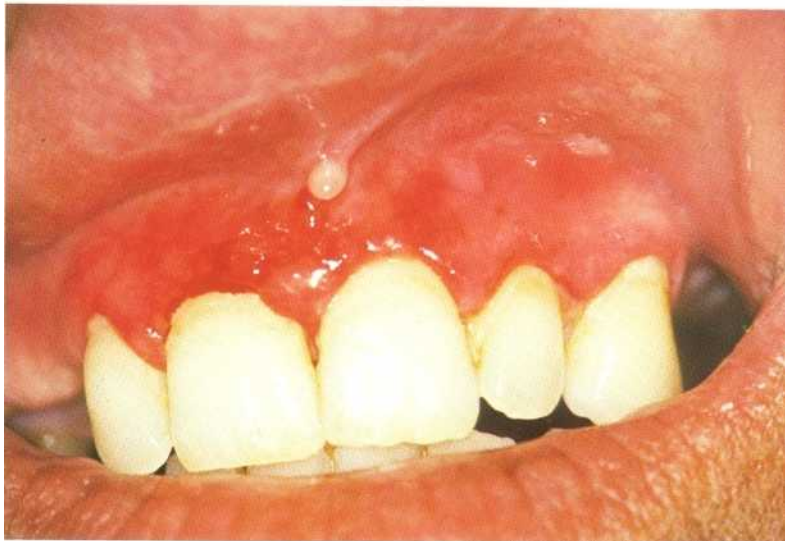

Fig. 144. Desquamative gingivitis as a manifestation of pemphigus vulgaris.

## 12. Diseases of the Tongue

### Median Rhomboid Glossitis

Median rhomboid glossitis is a congenital abnormality of the tongue that is thought to be due to persistence of the tuberculum impar until adulthood. The disorder appears on the dorsal surface of the tongue as an area devoid of papillae. However, recently, it has been suggested that chronic *Candida albicans* infection may play a role in the pathogenesis of median rhomboid glossitis. Clinically, the lesion has a rhomboid or oval shape and is localized along the midline of the dorsum of the tongue immediately anterior to the circumvallate papillae. Two clinical varieties are recognized: a smooth, well-circumscribed red plaque that is devoid of normal papillae, slightly below the level of the surrounding normal mucosa (Fig. 145), and a raised multinodular, firm, reddish mass with a smooth surface without papillae (Fig. 146).

Median rhomboid glossitis is usually asymptomatic, although occasionally secondary *C. albicans* infection may occur with mild inflammation causing subjective symptoms.

The differential diagnosis includes interstitial syphilitic glossitis, erythematous candidosis, geographic tongue, thyroglossal duct cyst, lymphangioma, hemangioma, and other neoplasms.

Laboratory test. Histopathologic examination is occasionally indicated to exclude neoplasia.

Treatment is generally not required. In cases of *C. albicans* infection topical use of nystatin or clotrimazole is helpful.

### Geographic Tongue

Geographic tongue, or benign migratory glossitis, is a disorder of unknown cause and pathogenesis, although an inherited pattern has been suggested. The prevalence ranges from 1 to 2%. It appears in all ages and is slightly more common in females. Geographic tongue frequently coexists with fissured tongue. Clinically, the condition is characterized by multiple, usually painless, circinate erythematous patches surrounded by a thin, raised whitish border (Fig. 147). The lesions vary in size from several millimeters to several centimeters and are due to desquamation of the filiform papillae, whereas the fungiform papillae remain intact and prominent. These lesions persist for a short time in one area and then heal completely and reappear in another area of the tongue.

Geographic tongue is a benign condition persisting for weeks, months, or even years and is usually restricted to the dorsal surface of the tongue. Occasionally, lesions may appear on the ventral surface and the margins. However, similar lesions have also been described in other areas of the oral mucosa (such as lips, buccal mucosa, palate, gingiva) and have been described as geographic stomatitis or migratory stomatitis (Fig. 148). It has been suggested that psoriasis and geographic stomatitis are related lesions.

The differential diagnosis includes oral lesions of psoriasis and Reiter's syndrome, plasma cell glossitis, mucous patches of secondary syphilis, lichen planus, leukoplakia, candidosis, and allergic reactions.

Treatment is not required. However, patients should be reassured.

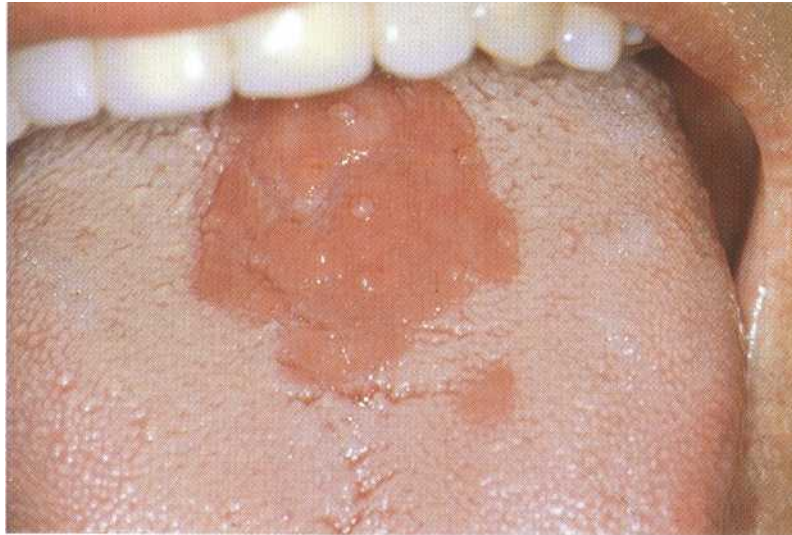

Fig. 145. Median rhomboid glossitis.

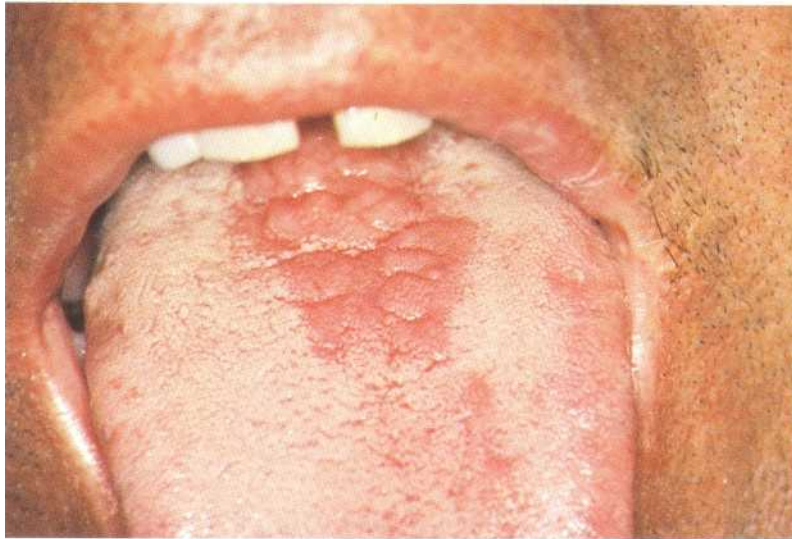

Fig. 146. Median rhomboid glossitis.

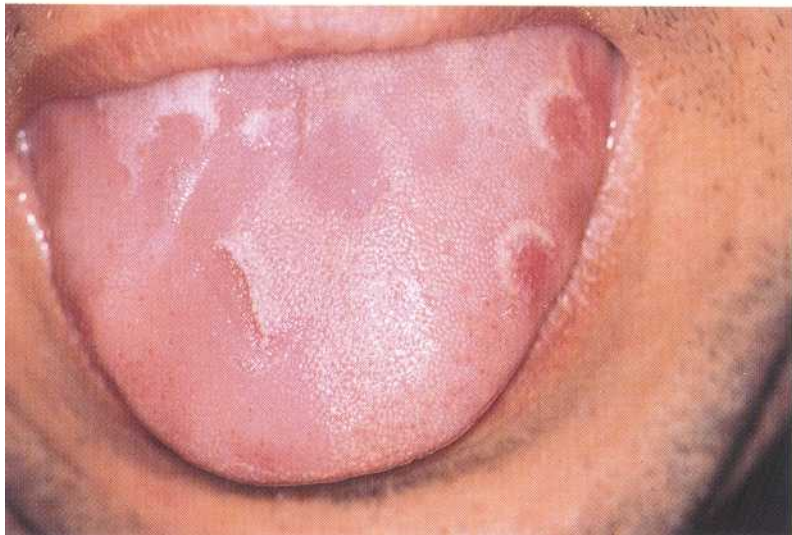
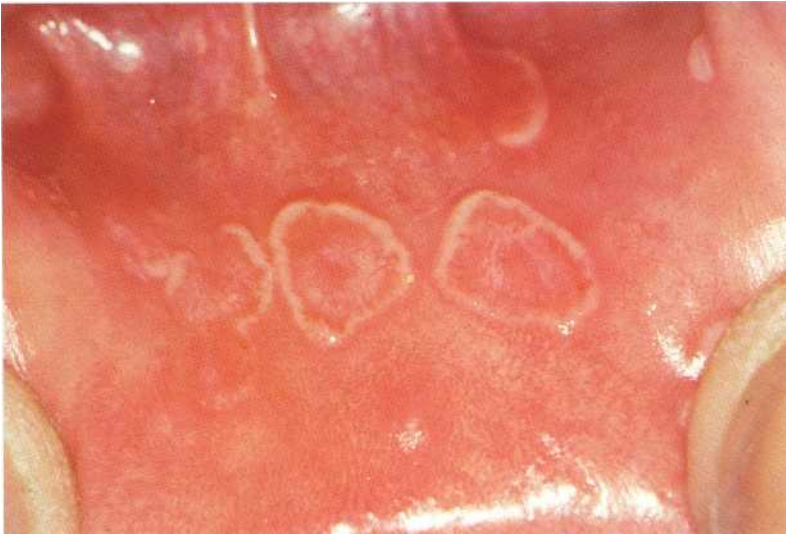
Fig. 147. Geographic tongue.





**Fig. 148. Geographic stomatitis, lesions on lower lip mucosa.**

### Fissured Tongue

Fissured or scrotal tongue is a common developmental malformation of unknown cause and pathogenesis. However, recent evidence supports the concept that fissured and geographic tongues are inherited disorders with a common polygenic mode of transmission. Clinically, fissured tongue is characterized by multiple fissures or grooves on the dorsal surface of the tongue resulting in a scrotal appearance (Fig. 149). The fissures may vary in depth, size, and number and usually have a symmetrical distribution. The condition is asymptomatic, although food debris, microorganisms, and fungi may be retained in the deeper fissures and may cause mild local irritation. The prevalence ranges from 0.5 to 5 %.

Fissured tongue may coexist with geographic tongue and is one of the clinical diagnostic criteria of Melkersson-Rosenthal syndrome. It is also a feature of Down's syndrome.

The differential diagnosis includes tongue appearance in Sjogren's syndrome and interstitial syphilitic glossitis.

Treatment is not required.

### Hairy Tongue

Hairy tongue is a relatively common disorder that is due to hypertrophy and elongation of the filiform papillae. The cause is obscure, although several predisposing factors have been incriminated, such as oral antibiotics oxidizing agents, metronidazole, excessive smoking, radiation, emotional stress, poor oral hygiene, and *C. albicans*. Clinically, the condition is characterized by hypertrophy and elongation of the filiform papillae of the dorsum of the tongue, which take on a hairy appearance. The color of the filiform papillae may be yellowish-white, brown, or black when pigment-producing bacteria colonize the elongated papillae (Figs. 150, 151).

The disorder is usually asymptomatic although the excessive length of the papillae may cause an unpleasant feeling in the mouth, resulting in gagging and discomfort. Although the disorder is benign in nature, it may cause significant distress to the patient for esthetic reasons.

**Treatment.** In mild cases, brushing of the dorsum of the tongue may promote desquamation and reduce the length of the papillae. Nystatin may be helpful in selected cases, when *C. albicans* growth is documented. In cases of extreme papillary elongation, topical use of keratolytic agents (such as salicylic acid in alcohol, podophyllin in alcohol, trichloroacetic acid) may be helpful.

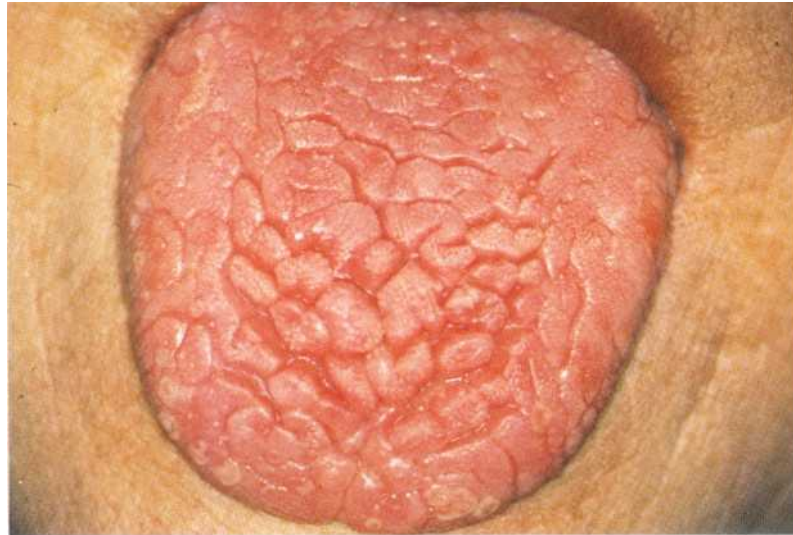


Fig. 149. Fissured tongue.

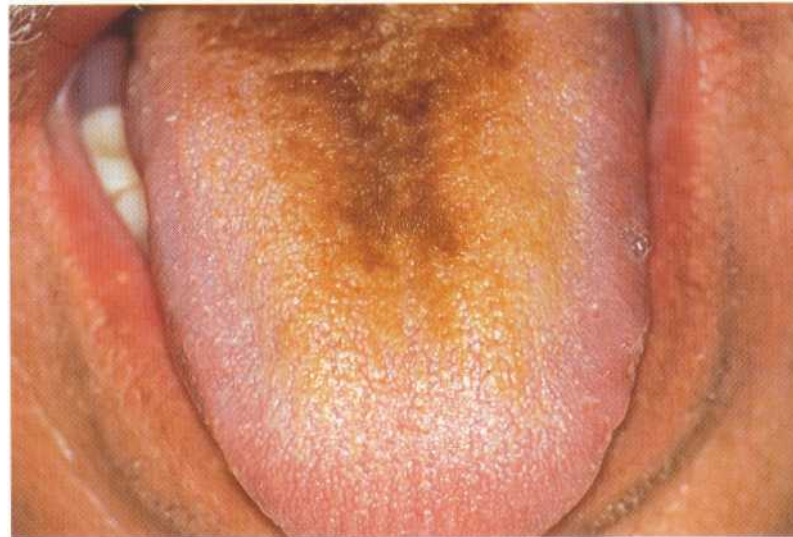


Fig. 150. Hairy tongue.

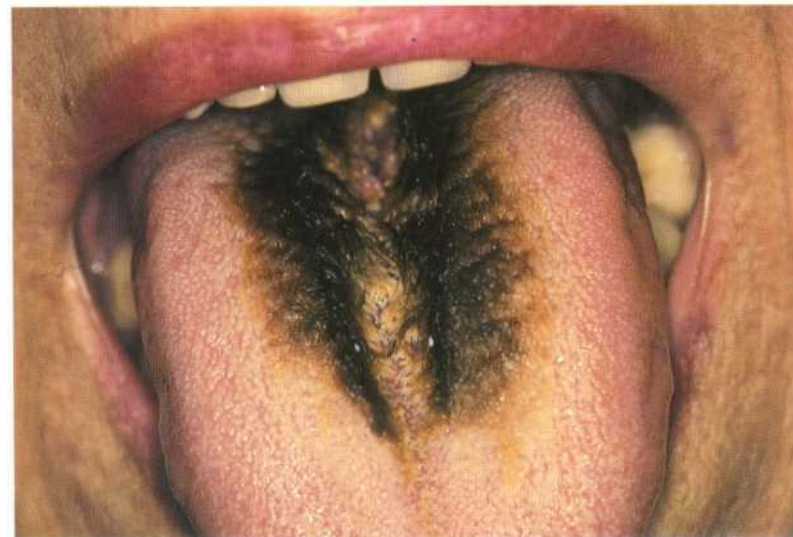

Fig. 151. Black hairy tongue.

## Furred Tongue

Furred tongue is a relatively uncommon disorder of healthy individuals. It is common in febrile illnesses, particularly in cases with oral painful lesions (e. g., scarlet fever, primary herpetic gingivostomatitis, herpes zoster, erythema multiforme, pemphigus vulgaris, etc.). Dehydration and soft diet are also predisposing factors. The cause is not well understood. The most important features of the lesion are the lengthening of the filiform papillae, no more than 3 - 4 mm, and accumulation of debris and bacteria in cases with poor oral hygiene. Clinically, the condition presents as a white or whitish-yellow thick coating on the dorsal surface of the tongue (Fig. 152). Characteristically, furred tongue appears and disappears in a short time.

The differential diagnosis includes hairy tongue, pseudomembranous candidosis, and hairy leukoplakia.

Treatment. Treatment of underlying illnesses and good oral hygiene.

## Plasma Cell Glossitis

Plasma cell glossitis is a rare disorder characterized by diffuse or localized erythema of the tongue, which exhibits plasma cell infiltration on histopathologic examination (Fig. 153).

The cause of the disease is unknown, although several predisposing factors, such as allergic reactions, endocrine disorders, and *C. albicans*, have been incriminated.

Plasma cell glossitis may persist for a prolonged period and may be accompanied by a burning sensation.

Similar lesions may appear on the gingiva, lips, and other areas of the oral mucosa.

The differential diagnosis includes geographic tongue, allergic reactions, and candidosis.

Laboratory test. Histopathologic examination is essential to establish the diagnosis.

Treatment is symptomatic. Antihistamines and nystatin may be helpful.

## Glossodynia

Glossodynia, or glossopyrosis is not a specific disease entity but a symptom of burning sensation of the tongue. During the last decades, it has become a very common condition, particularly in women more than 50 years old. In the vast majority glossodynia represents a manifestation of an underlying psychologic problem with no clinically visible changes. Other common causes are candidosis, iron deficiency anemia, pernicious anemia, geographic tongue, lichen planus, xerostomia, diabetes mellitus, hypertension, allergic reaction, etc. In glossodynia of psychologic origin, the tongue is usually normal, although slight erythema and mild elongation of fungiform papillae at the tip of the tongue may occasionally occur (Fig. 154). The patient complains of a burning sensation or itching, usually at the tip and the lateral borders of the tongue. Similar symptoms may appear at any area of the oral cavity. The condition is, as a rule, associated with cancerophobia, shows remissions and exacerbations, and may persist for years.

Treatment. There is no specific treatment, although various antidepressant drugs have been used successfully. In severe cases the patient must be referred to a psychiatrist.

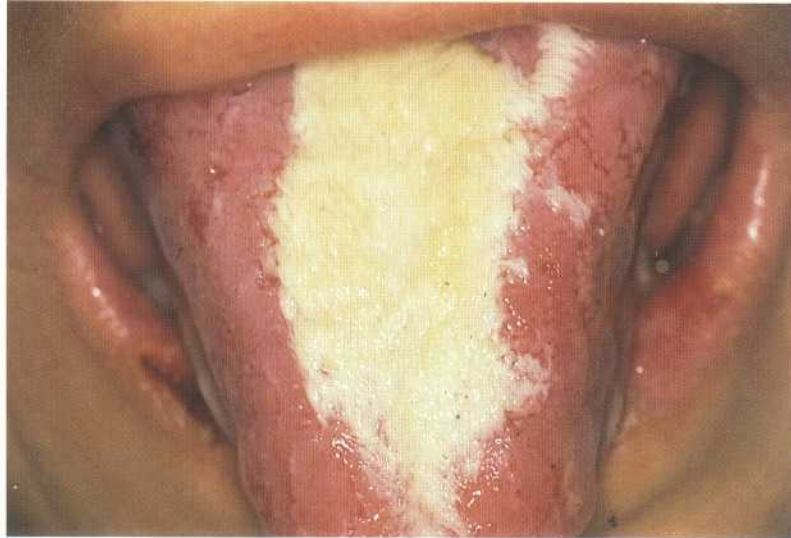


Fig. 152. Furred tongue.

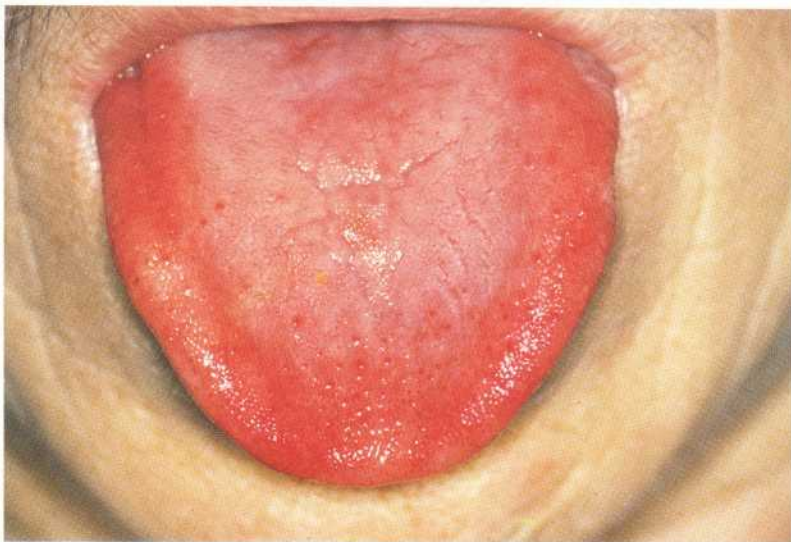

Fig. 153. Plasma cell glossitis.

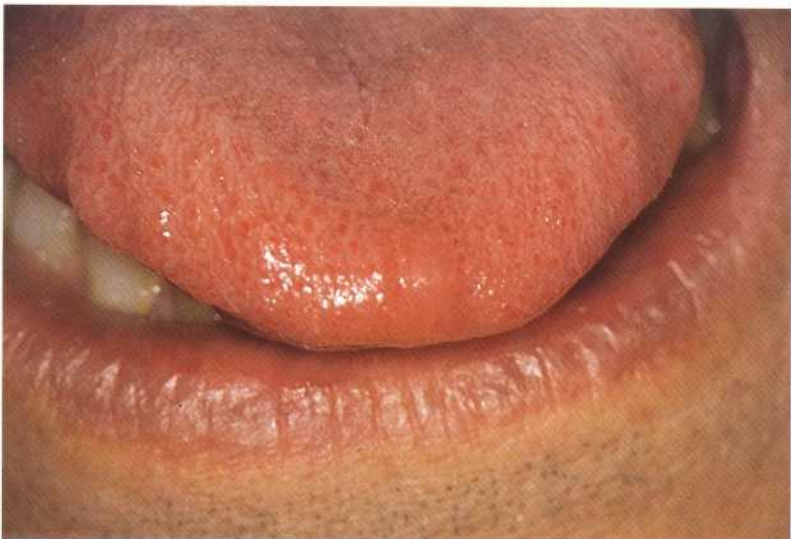

Fig. 154. Glossodynia, slight erythema and mild elongation of fungiform papillae at the tip of the tongue.

### **Crenated Tongue**

Crenated tongue consists of shallow impressions on the lateral margins of the tongue due to the neighboring teeth -(Fig. 155). The mucosa is usually normal in appearance but may occasionally be red if there is intense friction or pressure against the teeth.

It is frequently found in persons who have the habit of pressing the tongue hard against the teeth or when tooth malposition exists.

Myxedema, acromegaly, amyloidosis, and lipoid proteinosis are diseases that may cause macroglossia and subsequently crenated tongue.

### **Hypertrophy of Foliate Papillae**

The foliate papillae are localized in the posterior lateral borders of the tongue and may be rudimentary in size or they may appear as large protruding nodules.

They may become inflamed and enlarged in response to local chronic irritation or infection (Fig. 156).

The patient may complain of a burning sensation and frequently be alarmed by the enlarged papillae, fearing a cancer.

Treatment. Reassurance is indicated.

### **Hypertrophy of Circumvallate Papillae**

The circumvallate papillae are located on the posterior aspect of the dorsum of the tongue. They are 8 to 12 in number arranged in a V-shaped pattern. Hypertrophy of the circumvallate papillae results in red, well-circumscribed raised nodules (Fig. 157), which, when discovered by the patient, may cause fear of a cancer.

Treatment. No treatment is indicated apart from reassurance.

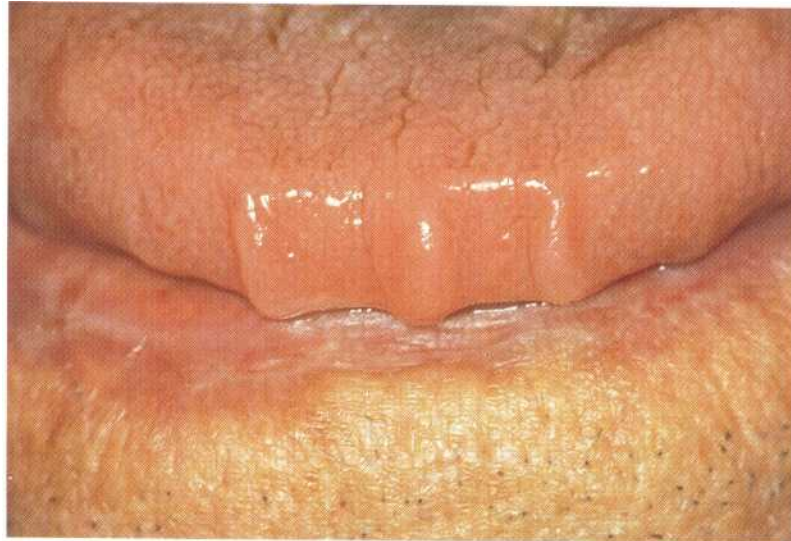


Fig. 155. Crenated tongue.

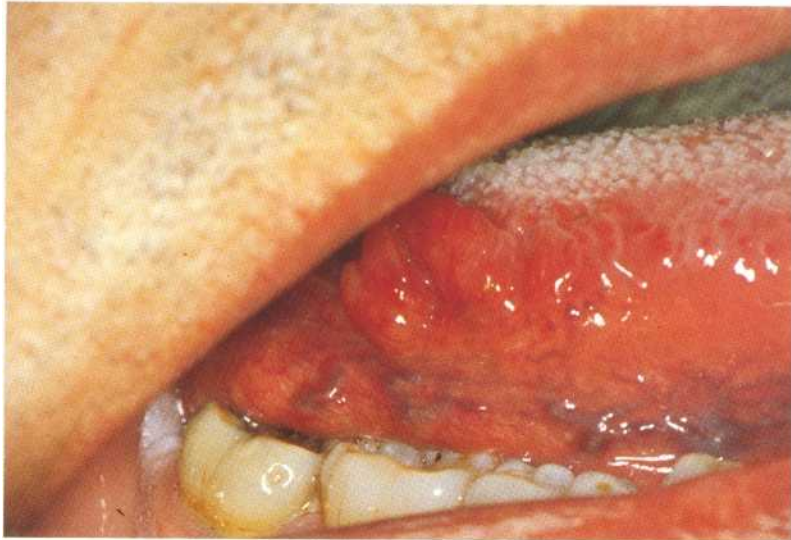

Fig. 156. Hypertrophy of foliate papillae.

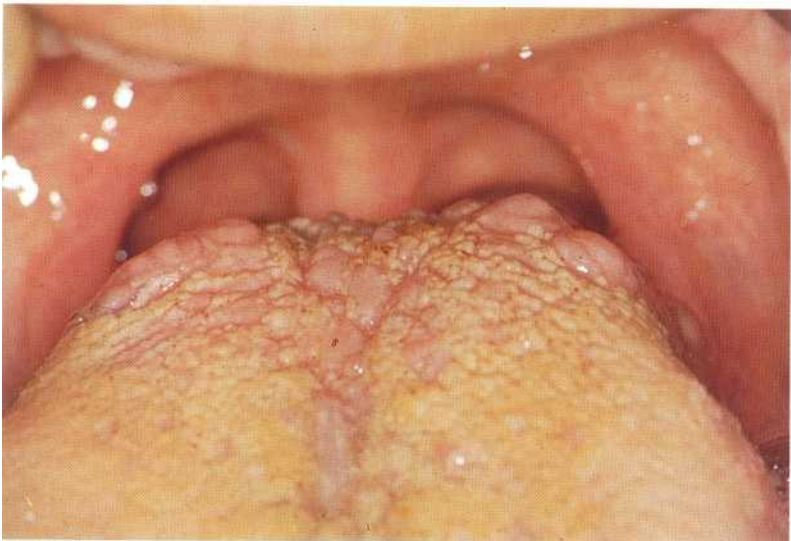

Fig. 157. Hypertrophy of circumvallate papillae.

### **Hypertrophy of the Fungiform Papillae**

The fungiform papillae appear as multiple small round red nodules along the anterior portion of the dorsum of the tongue.

Fungiform papillae sometimes become inflamed and enlarged, causing a burning sensation or mild pain, mainly at the tip of the tongue. Excessive smoking, alcohol consumption, hot foods, mechanical friction, irregular tooth surfaces, spices, etc., may predispose to inflammation and enlargement of the fungiform papillae (Fig. 158). Elimination of these factors is indicated.

### **Sublingual Varices**

In persons more than 60 years of age varicosities of the sublingual veins are common. Clinically, they appear as tortuous, sublingual veins with widened nodule-like areas at the ventral surface and the lateral border of the tongue (Fig. 159). Sublingual varices are benign and they are usually discovered accidentally by the patient.

**Treatment.** No therapy except reassurance is required.

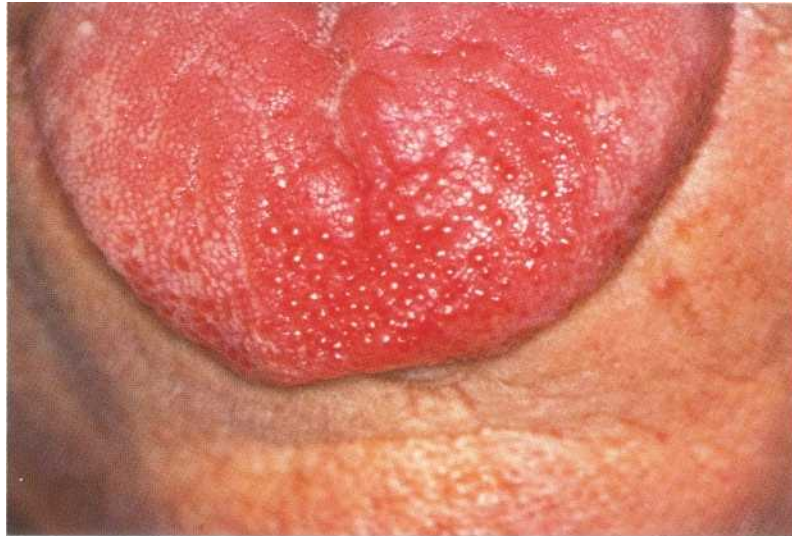

Fig. 158. Hypertrophy of fungiform papillae.

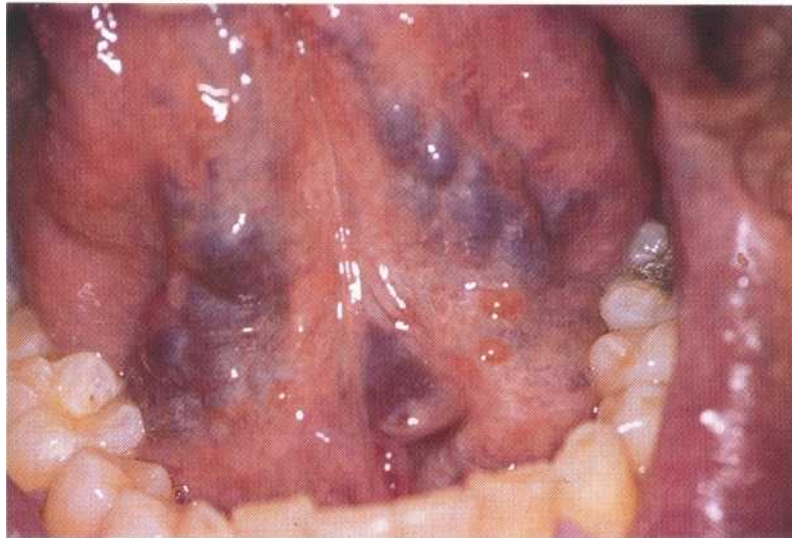

Fig. 159. Sublingual varices.



## 13. Diseases of the Lips

### Median Lip Fissure

Median lip fissure is a relatively rare disorder that may appear in both lower and upper lips and is more common in males than females. The cause of the lesion is not clear although mechanical irritation, maceration, smoking, cold, windy and dry weather, sun exposure, and lipstick have been suggested as predisposing factors. In addition, nutritional disorders, immunosuppressive states and HIV-infection, Crohn's disease, and Down's syndrome may predispose toward lip fissure development. Recently, a hereditary predisposition has been proposed. Clinically, lip fissure presents as a deep inflammatory, persistent vertical fissure at the middle of the lip, usually infected by bacteria and *Candida albicans* (Fig. 160). Spontaneous bleeding, discomfort, and pain are common findings.

**Treatment.** Topical corticosteroid with or without antibiotics and nystatin may be helpful. In persistent severe cases, surgical excision with plastic reconstruction is recommended.

### Angular Cheilitis

Angular cheilitis, or perleche, is a disorder of the lips caused by several factors, such as riboflavin deficiency, iron deficiency anemia, Plummer-Vinson syndrome, and mechanical trauma. However, many cases are due to loss of proper vertical dimension of the teeth, which may occur in patients who wear dentures or in edentulous persons. In such cases, a fold is formed at the angles of the mouth in which saliva continuously moistens the region, producing maceration and fissuring. It has been shown that microorganisms, such as *Candida albicans*, Streptococci, Staphylococci, and others may superimpose or cause angular cheilitis. Clinically, the condition is characterized by maceration, fissuring, erythema with erosions, and crusting at the commissures (Fig. 161).

Characteristically, the lesions do not extend beyond the mucocutaneous border. A burning sensation and feeling of dryness may occur. Untreated, angular cheilitis may last for a long time, showing remissions and exacerbations.

Treatment consists of correction of the occlusal vertical dimension, vitamin administration, and local steroid or antibiotic ointment.

### Actinic Cheilitis

Actinic cheilitis may occur as an acute or chronic process. Chronic actinic cheilitis is observed in older persons as a result of long-standing exposure to sunlight (such as farmers, seamen) and characteristically involves the lower lip.

During the early stage, mild edema and slight erythema of the lower lip are common findings, followed by dryness and fine scaling. Progressively, the epithelium becomes thin, atrophic with small whitish-gray areas intermingled with red regions (Fig. 162). Later, the lip becomes very dry and scaly. Nodules and sometimes erosions may form. There is an increased risk of development of leukoplakia and squamous cell carcinoma.

The differential diagnosis should include lupus erythematosus, lichen planus, contact cheilitis, leukoplakia, and squamous cell carcinoma.

**Laboratory test.** Histopathologic examination is essential to exclude cancer.

Treatment consists of protection from prolonged exposure to the sun, local application of 5-fluorouracil, and, in severe cases, surgical excision of the involved areas of the lip.

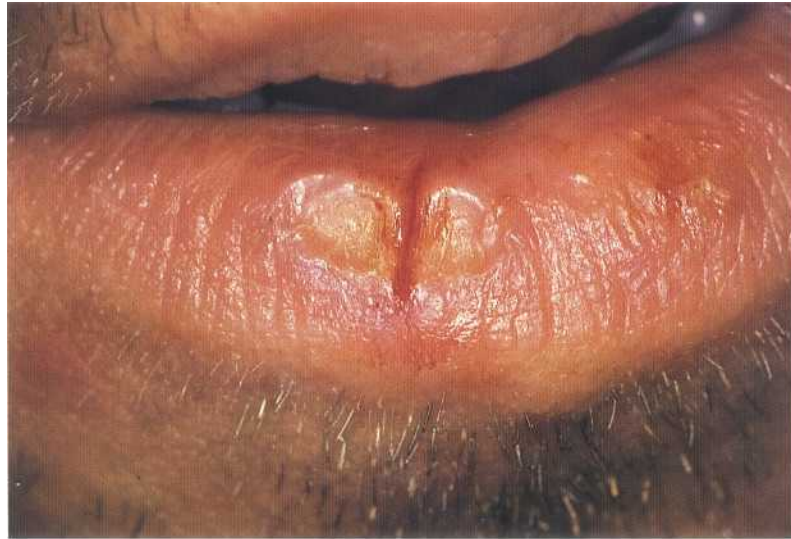

Fig. 160. Median deep vertical fissure of the lower lip.

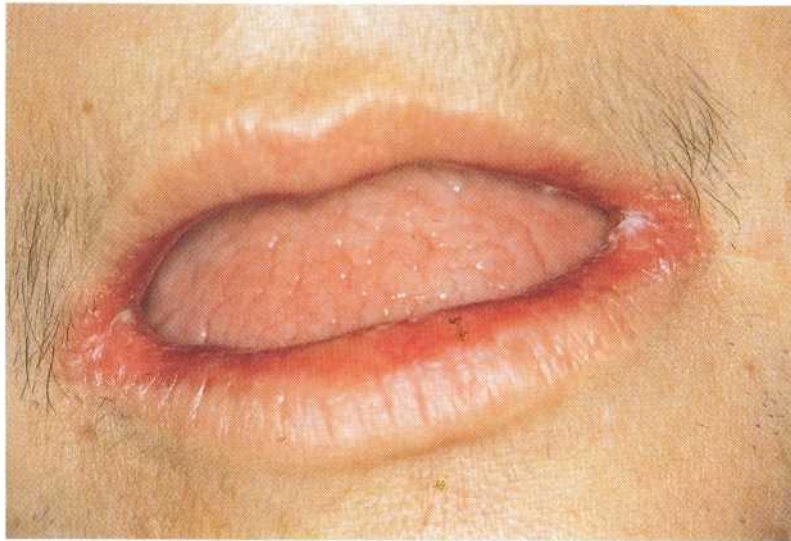

Fig. 161. Angular cheilitis.

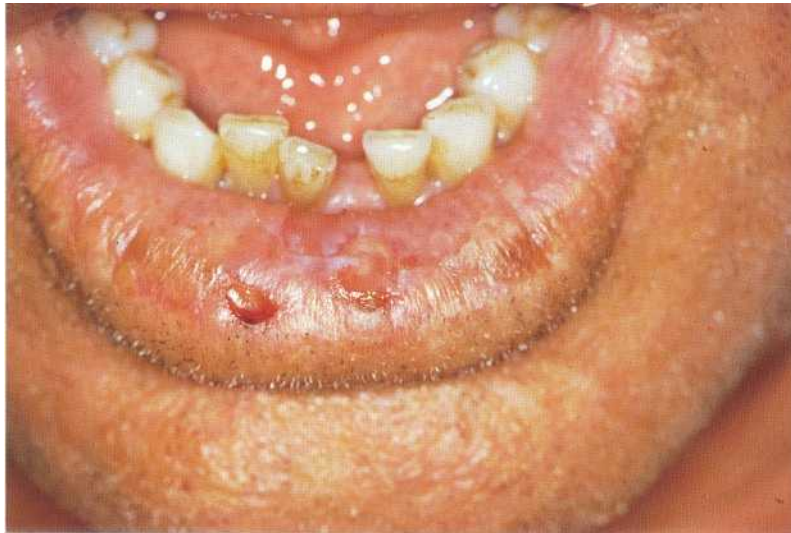

Fig. 162. Actinic cheilitis.

### Exfoliative Cheilitis

Exfoliative cheilitis is a chronic inflammatory disorder of the vermilion border of the lips, which is characterized by the persistent formation of scales and crusts. It is most commonly observed in young women with emotional stress and may coexist with atopy. The cause is unknown, although the lesions may become aggravated by cold or very hot weather. Clinically, exfoliative cheilitis consists of severe exfoliation of the vermilion border of the lips, leaving an erythematous and sensitive surface. This pattern is repetitive, resulting in thickening, scaling, and crusting of one or both lips (Fig. 163). Exfoliative cheilitis may persist with variable severity for months or years, with remissions and exacerbations, and may cause a significant cosmetic problem to the patient.

The differential diagnosis includes contact cheilitis and actinic cheilitis.

Treatment. Topical moistening agents (such as cocoa butter) and topical steroids may be helpful.

### Contact Cheilitis

Contact cheilitis is an inflammatory disorder of the lips that is attributed to allergy to various chemical agents. The most common causes that have been incriminated are lipsticks, lip salves, dentrifices, mouthwashes, foods, etc. Clinically, contact cheilitis is characterized by mild edema and erythema, followed by irritation and scaling (Fig. 164). It is usually confined to the vermilion border of the lips. A careful history is essential to determine the probable cause. In addition, a patch test is necessary to confirm the causative substance.

The differential diagnosis includes exfoliative cheilitis, and plasma cell cheilitis.

Treatment consists of discontinuing all contact with the offending substance and use of topical steroids.

### Cheilitis Glandularis

Cheilitis glandularis is an uncommon chronic inflammatory disorder involving chiefly the lower lip. The cause is unknown, although in some cases a hereditary pattern is observed. Emotional stress and chronic exposure to sunlight have also been incriminated. Clinically, it consists of enlargement of the lip due to minor salivary gland hyperplasia and chronic inflammatory infiltration (Fig. 165). Characteristically, the orifices of the secretory ducts are dilated and appear as numerous pinhead openings from which mucus or mucopustular fluid may be expressed on pressure. Crusting, erosions, and abscesses may also occur.

Three forms of cheilitis glandularis are recognized: a simple form, which is the most common, a superficial suppurative form, and a deep suppurative form. The last two forms are a result of microbial infection and the clinical signs and symptoms are more severe.

The differential diagnosis includes cheilitis granulomatosa, sarcoidosis, Crohn's disease, lymphangioma, and tuberculosis.

Laboratory test. Histopathologic examination is essential in establishing the diagnosis.

Treatment. Topical steroids are of limited value. In advanced cases plastic surgery is indicated.

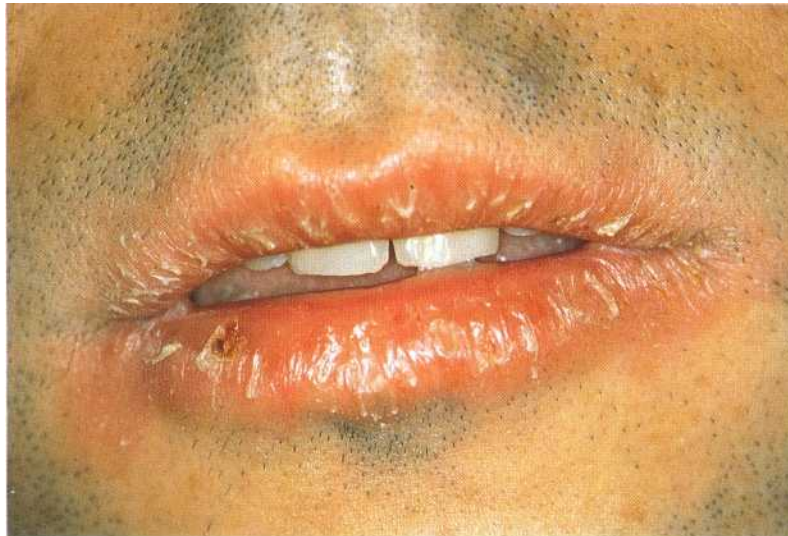

Fig. 163. Exfoliative cheilitis.

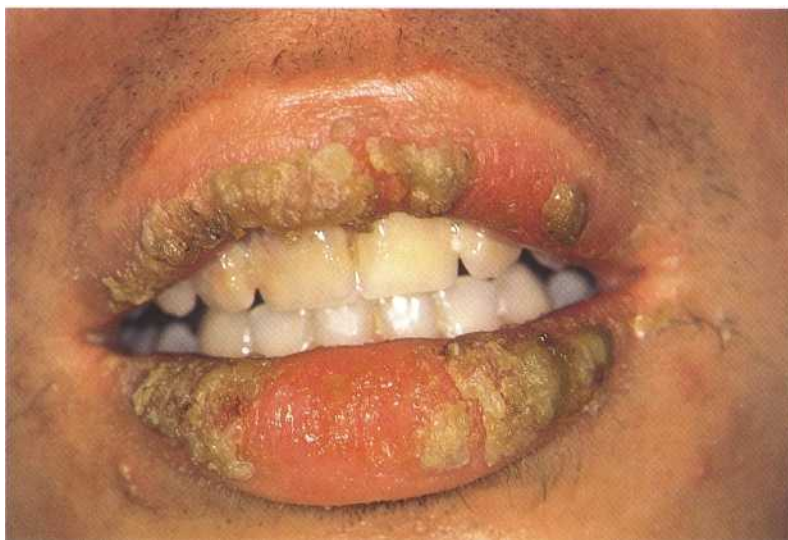

Fig. 164. Contact cheilitis.

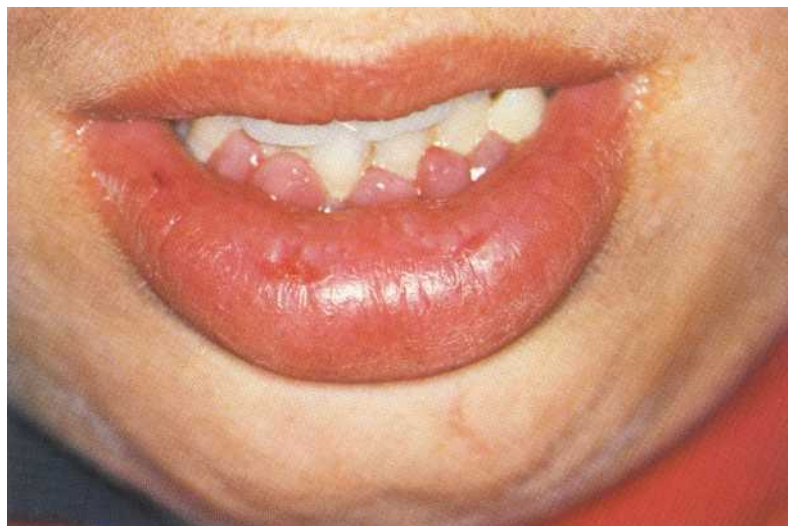

Fig. 165. Cheilitis glandularis.

### Cheilitis Granulomatosa

Cheilitis granulomatosa, or Miescher's cheilitis, is an uncommon chronic disorder of unknown cause. It may occur either as an isolated disorder or as part of several other diseases, such as the Melkersson-Rosenthal syndrome, sarcoidosis, and Crohn's disease. However, the isolated cases are believed to be a monosymptomatic form of the Melkersson-Rosenthal syndrome. Clinically, cheilitis granulomatosa is characterized by painless, diffuse swelling, frequently of the lower lip and rarely the upper lip or both (Fig. 166). The surrounding skin and oral mucosa may be normal or erythematous. Small vesicles, erosions, and scaling may occasionally appear. The disease usually has a sudden onset and a chronic course, with remissions and exacerbations, finally leading to permanent enlargement of the lips.

The differential diagnosis includes cheilitis glandularis, sarcoidosis, Crohn's disease, lymphoedema, lymphangioma, erysipelas, angioneurotic edema, and Kawasaki disease.

**Laboratory test.** Histopathologic examination is essential to establish the diagnosis.

**Treatment.** Topical steroid ointments, intralesional injection of triamcinolone, or systemic steroids may be useful in some cases. However, in advanced cases plastic surgery is indicated.

### Plasma Cell Cheilitis

Plasma cell cheilitis is an uncommon inflammatory disorder of the lips, characterized by a dense infiltration of mature plasma cells.

The cause remains unknown, and the lesion usually occurs in patients more than 60 years of age. Clinically, it is characterized by diffuse redness with slight swelling of the vermilion border of the lower lip (Fig. 167). Similar lesions have been described on the gingiva and the tongue. This group of lesions is identical to plasma cell balanitis (Zoon's disease).

The differential diagnosis includes contact cheilitis, allergic reactions, actinic cheilitis, erythroplakia, candidosis, lichen planus, and lupus erythematosus.

**Laboratory test.** Histopathologic examination is helpful in establishing the diagnosis.

**Treatment** is symptomatic, and topical steroids may be helpful.

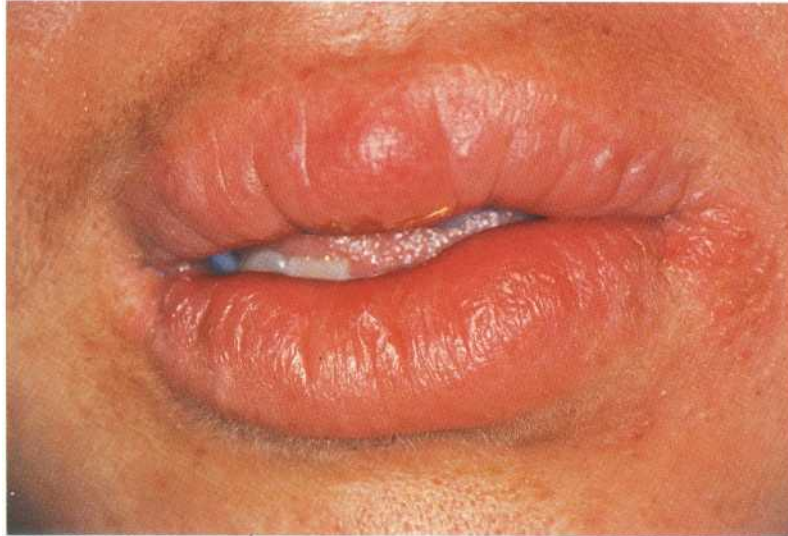

Fig. 166. Cheilitis granulomatosa.

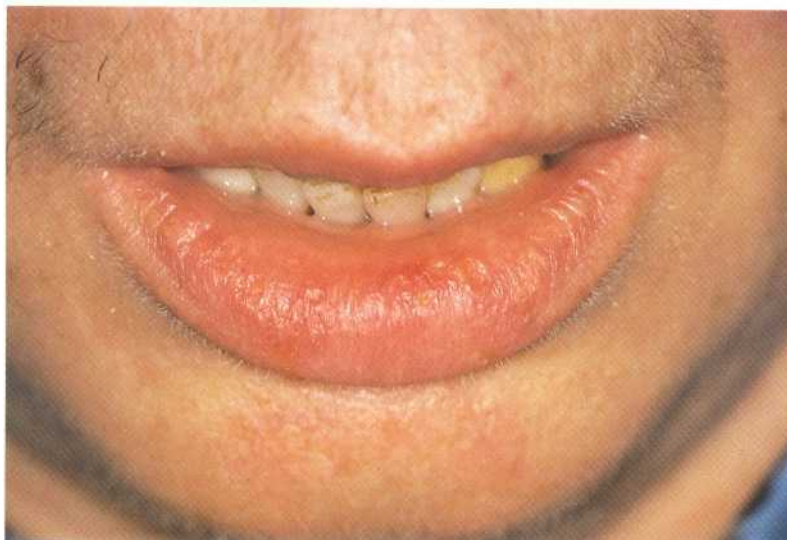

Fig. 167. Plasma cell cheilitis.

## 14. Soft-Tissue Cysts

### Mucocele

Mucocele, or mucous cysts, originate from minor salivary glands or their ducts and are the most common cysts of the oral soft tissues. Two types are recognized: extravasation mucoceles are most common (more than 80%) and their pathogenesis is related to duct rupture from trauma due to biting; retention mucoceles are rare and their pathogenesis is related to partial obstruction of the duct, probably due to infection, calculus, or sialoliths.

Extravasation-type mucoceles display a peak incidence during the second and third decades, whereas the retention-type mucoceles are more common in older age groups. However, there is no sex predilection, and they may occur at all ages. Most frequently, mucoceles occur on the lower lip, usually laterally, at the level of the bicuspid, less commonly on the buccal mucosa, floor of the mouth, palate, tongue, and very seldom on the upper lip.

Clinically, mucoceles are painless, spherical, solitary fluctuant masses that vary in size from a few millimeters to several centimeters in diameter (Figs. 168, 169). Superficial cysts are translucent and bluish, whereas deeper lesions have the color of normal mucosa. Usually, they appear suddenly, rapidly reaching their final size, and may persist for several weeks to several months. Sometimes they empty partially and then reform due to accumulation of fresh fluid.

The differential diagnosis includes hemangioma, lymphangioma, lipoma, papillary cystadenoma lymphomatosum, mucoepidermoid tumor, and Sjogren's syndrome.

Laboratory test. Histopathologic examination is useful in establishing the diagnosis.

Treatment consists of surgical excision or cryosurgery.

### Ranula

Ranula is a variety of mucocele localized exclusively in the floor of the mouth. It arises from the ducts of the submandibular gland, sublingual gland, or the accessory salivary glands of the floor of the mouth, and its pathogenesis is similar to that of mucoceles. Clinically, it presents as a smooth, fluctuant, painless mass in the floor of the mouth, just lateral to the lingual frenum (Fig. 170). The color ranges from normal to translucent bluish.

The average size is 1 to 2 cm, but larger lesions may form, causing speech and swallowing problems.

The differential diagnosis includes dermoid cyst, lymphoepithelial cyst, abscess of the floor of the mouth, hemangioma, lymphangioma, etc.

Laboratory test. Histopathologic examination establishes the diagnosis.

Treatment consists of surgical removal.

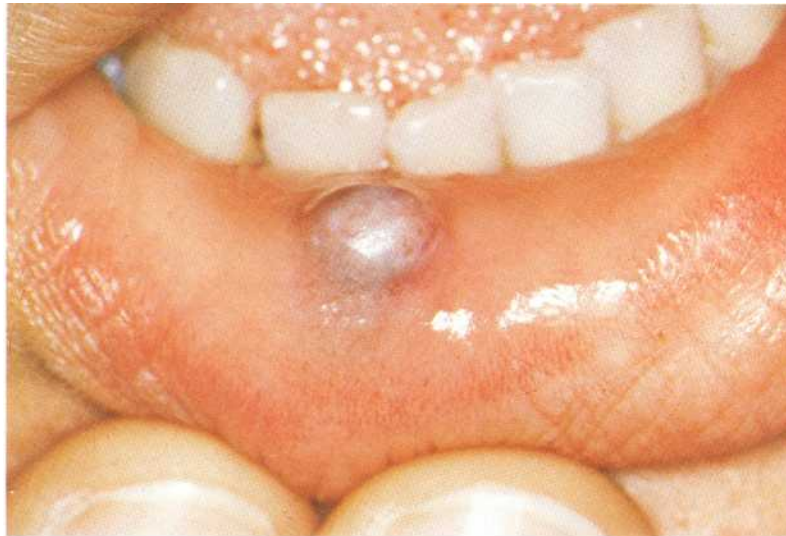

Fig. 168. Mucocele of the lower lip.

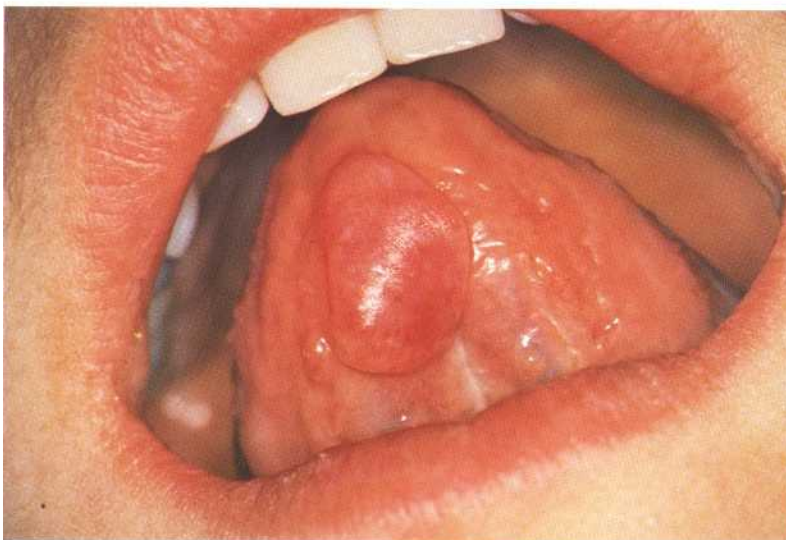

Fig. 169. Mucocele of the tongue.

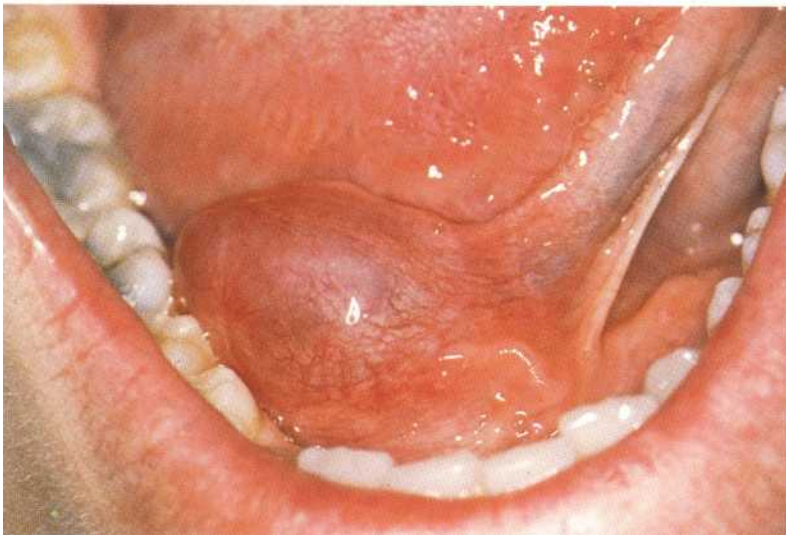

Fig. 170. Ranula.



### Lymphoepithelial Cyst

Lymphoepithelial cyst of the oral mucosa is an uncommon developmental lesion that is probably due to cystic degeneration of glandular epithelium entrapped within oral lymphoid tissue during embryogenesis. It usually becomes apparent between the ages of 20 and 50 years and is slightly more frequent in men than women (ratio 3:2). Intraoral lymphoepithelial cyst is histologically similar to the branchial cleft cyst that develops in the neck (Fig. 171). The intraoral cyst occurs most frequently in the floor of the mouth and the ventral surface of the tongue, although sporadic cases have been described in other sites. Clinically, it is a mobile, painless, well-defined, firm, and elevated nodule with a yellowish or reddish color (Fig. 172). The size ranges from a few millimeters to 2 cm in diameter.

The differential diagnosis includes lymph node, dermoid cyst, mucocele, lipoma, and other benign tumors.

Laboratory test. Histopathologic examination is essential to establish the diagnosis.

Treatment is surgical removal.

### Dermoid Cyst

Dermoid cyst is an uncommon developmental lesion arising from embryonic epithelial remnants. Dermoid cyst of the oral cavity is usually situated in the midline of the floor of the mouth. The cyst frequently appears in early adulthood and both sexes are equally affected. The size is small, but the cyst expands progressively and slowly and finally may reach several centimeters in diameter. Clinically, it is a painless elevated swelling with normal or slightly reddish color and characteristic soft doughlike consistency on palpation (Fig. 173). When the cyst is located above the geniohyoid muscle, it displaces the tongue upward, producing difficulties in mastication, speech, and swallowing. If located between the geniohyoid and mylohyoid muscles, it protrudes submentally.

The differential diagnosis includes lymphoepithelial cyst, ranula, cystic hygroma, and abscess of the floor of the mouth.

Laboratory test. Histopathologic examination is essential for the final diagnosis.

Treatment is surgical removal.

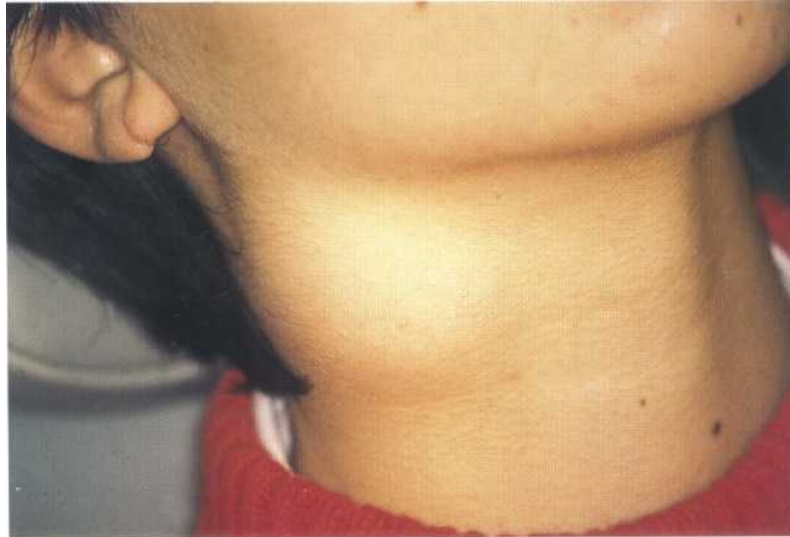

Fig. 171. Branchial cleft cyst on the lateral side of the neck.

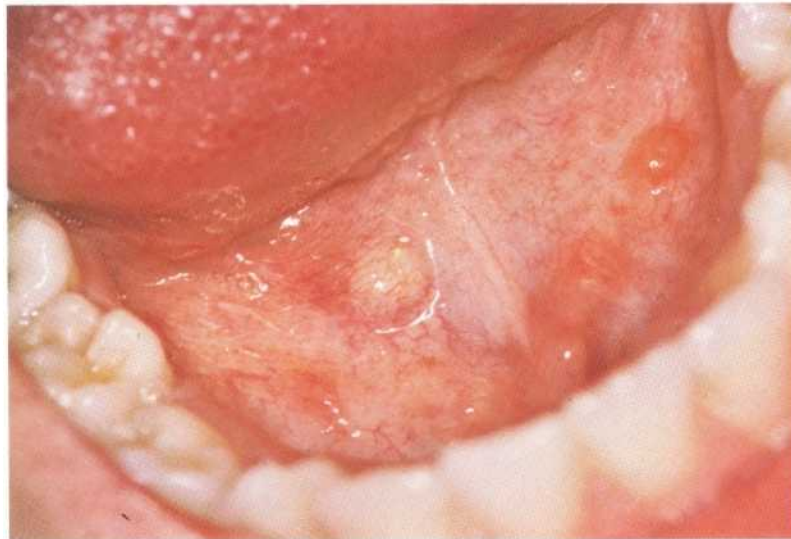

Fig. 172. Lymphoepithelial cyst in the floor of the mouth.

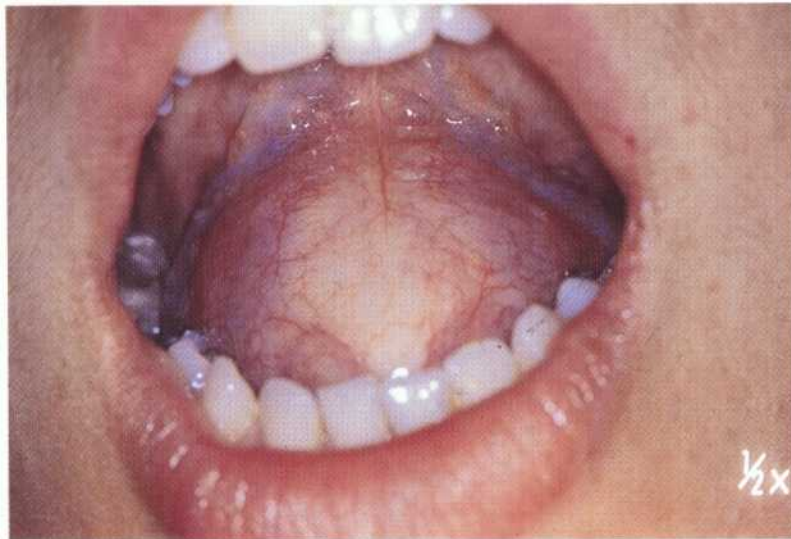


Fig. 173. Dermoid cyst.

### Eruption Cyst

Eruption cyst is a variety of dentigerous cyst that is associated with an erupting deciduous or permanent tooth. It is commonly located at the site of eruption of the canines and molars. Clinically, eruption cyst appears as well-demarcated, fluctuant, and soft swelling directly overlying the alveolus at the site of the erupting tooth. Very often, the color is blue, or dark red when the cyst cavity is filled with blood (Fig. 174). The clinical features are characteristic and the diagnosis is obvious.

The differential diagnosis includes hemangioma, hematoma, amalgam tattoo, oral pigmented nevi, and malignant melanoma.

**Laboratory test.** Histopathologic examination confirms the diagnosis.

Treatment usually is not required. However, the soft tissue cap may be excised.

### Gingival Cyst of the Newborn

Gingival cyst of the newborn, or Epstein's pearls or Bohn's nodules, are small lesions on the alveolar ridge of newborn infants. It arises from remnants of the dental lamina. Clinically, it appears as multiple or solitary asymptomatic whitish nodules 1 to 3 mm in diameter in the alveolar mucosa (Fig. 175). These cysts contain keratin and regress spontaneously within a few months.

The differential diagnosis includes lymphangioma and congenital epulis of the newborn.

**Laboratory test.** Histopathologic examination confirms the diagnosis.

Treatment is not required.

### Gingival Cyst of the Adult

Gingival cyst is rare in adult patients and may be located either in the free or attached gingiva. It originates from epithelial rests (such as dental lamina) in the gingiva. It is more frequent in patients more than 40 years of age and is located most often to the mandibular vestibule between the lateral incisor and first premolar. Clinically, it appears as a small well-circumscribed nodule of the gingiva, covered with normal mucosa with a size varying from few millimeters to 1 cm in diameter (Fig. 176).

The differential diagnosis includes mucocele, periodontal abscess, peripheral ossifying fibroma, and traumatic fibroma.

**Laboratory test.** Histopathologic examination is essential in establishing the diagnosis.

Treatment is surgical excision.

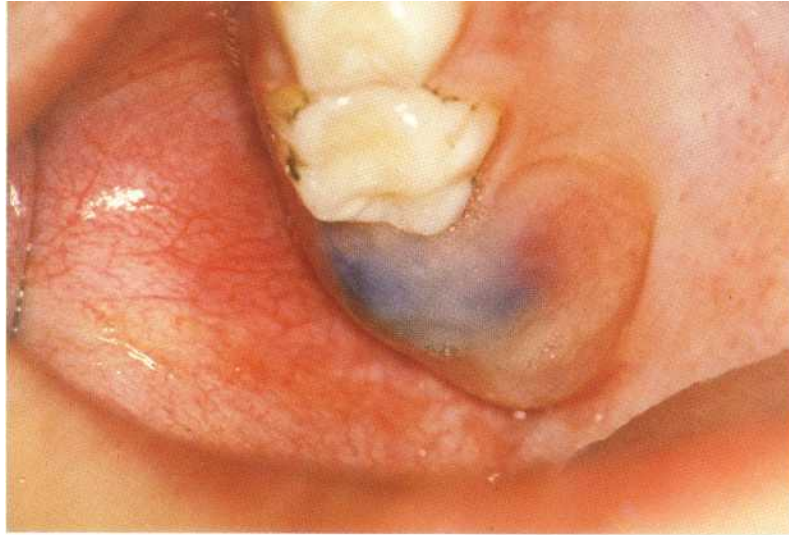


Fig. 174. Eruption cyst.

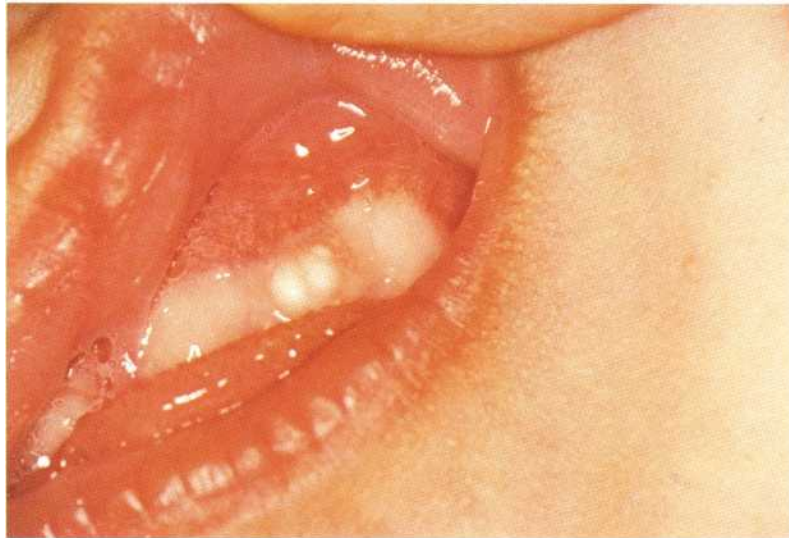

Fig. 175. Gingival cyst of the newborn.

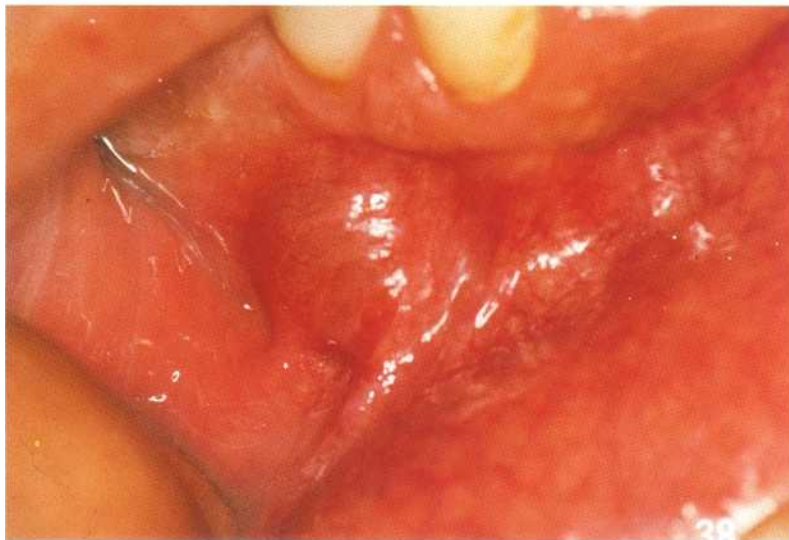


Fig. 176. Gingival cyst of the adult.

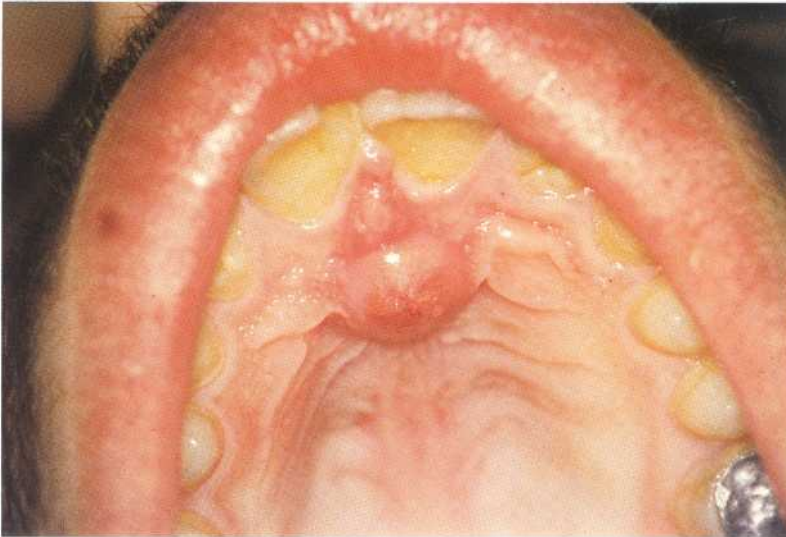

Fig. 177. Palatine papilla cyst.

### Palatine Papilla Cyst

Palatine papilla cyst is a variety of the nasopalatine cyst that arises from epithelial rests in the incisive foramen. Clinically, it appears as a soft swelling of the palatine papilla, covered with normal mucosa (Fig. 177). Often, it may become inflamed and painful due to infection. On radiographic examination, there are no pathologic findings.

The differential diagnosis includes dental and periodontal abscess, trauma of the palatine papilla, fibroma, and other benign tumors of the oral connective tissue.

Laboratory test. Histopathologic examination is necessary to establish the diagnosis.

Treatment is surgical removal.

### Nasolabial Cyst

Nasolabial cyst is a rare soft-tissue cyst with unclear pathogenesis. Recently it has been suggested that the cyst develops from the inferior and anterior part of the nasolacrimal duct. It is more frequent in females usually between 40 - 50 years of age. Clinically, nasolabial cyst appears as a soft tissue swelling in the mucobuccal fold of the maxilla, exactly opposite to the cupid, or in the floor of the nose (Fig. 178). Nasal obstruction and a feeling of pressure may be the patient's main complaints.

The differential diagnosis includes tooth abscess, soft tissue abscess, radicular cyst, mucocele, minor salivary gland neoplasms, and mesenchymal neoplasms.

Laboratory test. Histopathologic examination is necessary to establish the diagnosis.

Treatment. Surgical excision.

### Thyroglossal Duct Cyst

Thyroglossal duct cyst is a rare developmental lesion that may form anywhere along the thyroglossal duct from the foramen caecum of the tongue to the thyroid glands. It is more frequent in younger females and appears as a firm circumscribed midline cystic swelling a few millimeters to several centimeters in diameter. When it is localized in the oral cavity, it is usually found on the dorsum of the tongue close to the foramen caecum (Fig. 179). On rare occasions, it may be found in the floor of the mouth. It grows slowly and, if significantly enlarged, may cause dysphagia. A fistula may form on occasion, opening on the skin or mucosal surface (Fig. 180).

The differential diagnosis includes benign and malignant tumors and median rhomboid glossitis.

Laboratory test. Radioisotope and scintiscanning are useful. Histopathologic examination is sometimes necessary to establish the diagnosis.

Treatment may consist of observation, reassurance, thyroid hormone, isotope suppression, and surgical excision.

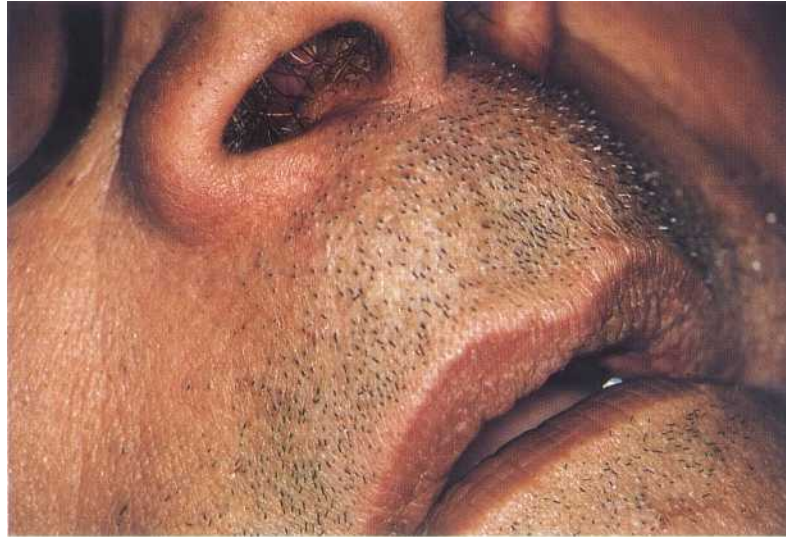

Fig. 178. Nasolabial cyst, swelling at the nasolabial fold.

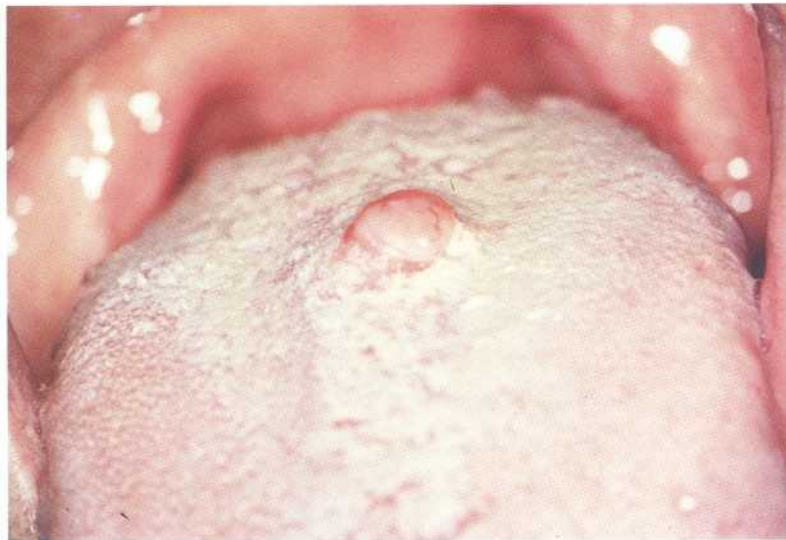

Fig. 179. Thyroglossal duct cyst on the dorsum of the tongue.

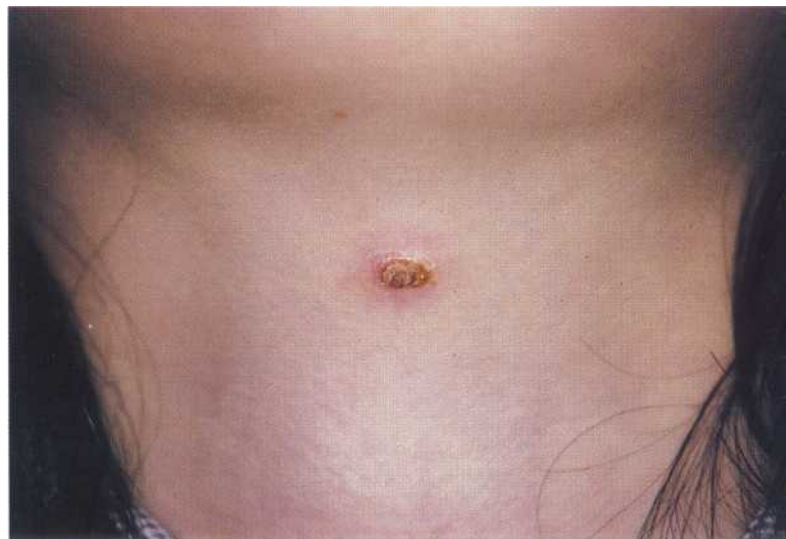

Fig. 180. Thyroglossal duct cyst and fistula in the midline of the neck.

## 15. Viral Infections

### Primary Herpetic Gingivostomatitis

Primary herpetic gingivostomatitis is the most frequent acute viral infection of the oral mucosa. It mainly affects children and young adults. The cause of the disease is the herpes simplex virus, type 1 (HSV-1). Primary contact with the HSV-1 may produce either acute primary disease or a subclinical asymptomatic infection: both lead to immunity. Clinically, primary herpetic gingivostomatitis is characterized by high temperature, malaise, irritability, headache, pain in the mouth, followed within 1 to 3 days by the eruptive phase. The oral mucosa is red and edematous, with numerous coalescing vesicles. Within 24 hours, the vesicles rupture, leaving painful small, round, shallow ulcers covered by a yellowish-gray pseudomembrane and surrounded by an erythematous halo (Fig. 181). New elements continue to appear during the first 3 to 5 days. The ulcers gradually heal in 10 to 14 days without scarring. Bilateral painful regional lymphadenopathy is a constant feature of the disease. Lesions are almost always present on the gingiva, resulting in acute gingivitis, which may be free of vesicles (Fig. 182). Any other area of the oral mucosa may also be affected, that is, the buccal mucosa, tongue, lips, and palate. The oral lesions are usually scattered, although solitary lesions may be seen.

The diagnosis is based on the clinical features and only rarely is laboratory confirmation required.

The differential diagnosis includes herpetiform ulcers, aphthous ulcers, hand-foot-and-mouth disease, herpangina, streptococcal stomatitis, acute necrotizing ulcerative gingivitis, erythema multiforme, and pemphigus vulgaris.

Laboratory test. Cytologic examination is definitive for intranuclear viral infection. Histopathologic studies, monoclonal antibodies, isolation, and culture of the virus (nucleic acid hy-

bridization) confirm the diagnosis in difficult cases. An elevated serum titer of antibodies is also suggestive of the disease.

Treatment. In severe cases acyclovir systemically is indicated, but in most cases treatment is symptomatic.

### Secondary Herpetic Stomatitis

Reactivation of HSV-1 in preinfected persons may cause recurrent intraoral herpes simplex.

Recurrent herpes infection differs from primary infection in that the vesicles are closely grouped, smaller in size, and the constitutional symptoms are absent. Predisposing factors that may precipitate reactivation of the virus include emotional stress, febrile illness, needle trauma after an oral injection, and extraction of a tooth. In addition, recently it has been recorded that recurrent herpetic lesions is a relatively common manifestation in HIV-infected patients.

The clinical features consist of a small number of discrete vesicles arranged in clusters, usually localized on the hard palate and the attached gingiva. The vesicles rupture in a few hours, leaving small, 1 to 3 mm ulcers that heal spontaneously in 6 to 10 days without scarring (Fig. 183).

Because of acquired immunity during the primary infection, the subjective complaints are usually mild and constitutional symptoms are characteristically absent. The diagnosis is made exclusively on clinical criteria.

The differential diagnosis includes herpetiform ulcers, aphthous ulcers, herpes zoster, streptococcal stomatitis, gonococcal stomatitis, primary and secondary syphilis.

Treatment is symptomatic.

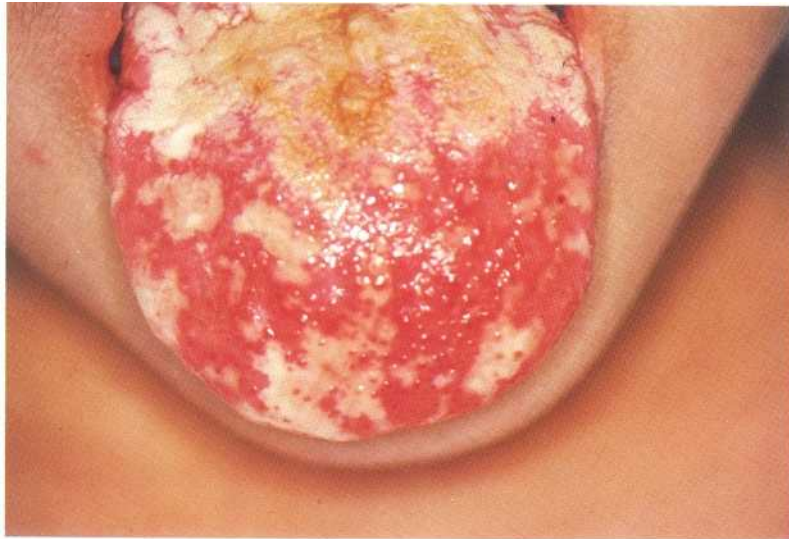

Fig. 181. Primary herpetic gingivostomatitis, multiple ulcers on the tongue.

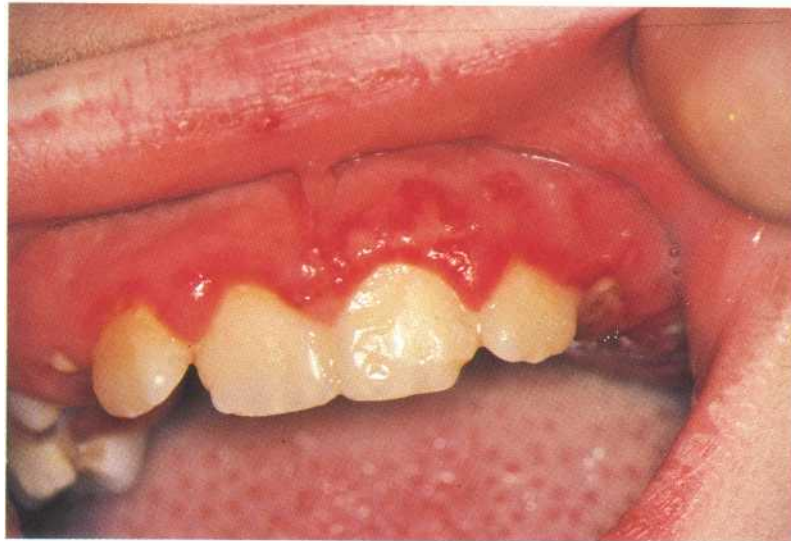

Fig. 182. Primary herpetic gingivostomatitis, erythema and multiple ulcers on the gingiva.

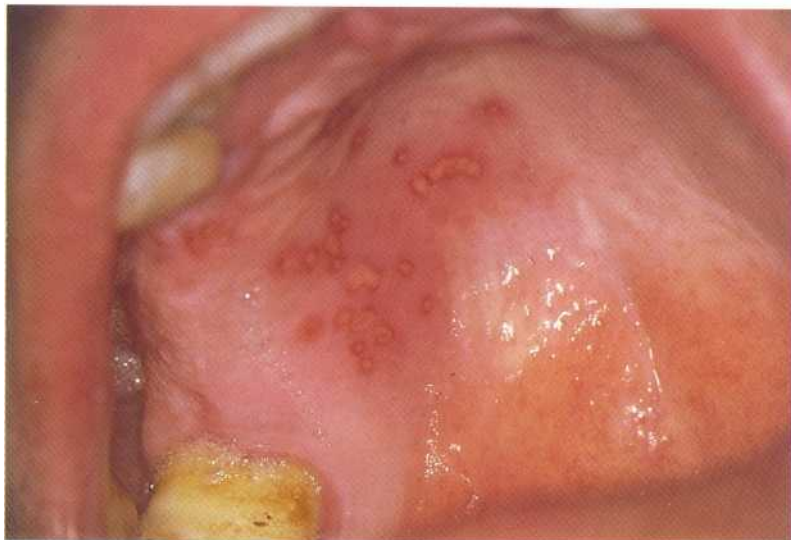

Fig. 183. Secondary herpetic stomatitis, round small ulcers on the palate.



### Herpes Labialis

Herpes labialis is due to reactivation of HSV-1 from its location in nerve ganglia, and it is by far the most common form of recurrent herpetic infection. It affects women more often than men in a ratio of about 2 : 1 and involves the upper or lower lip with equal frequency. Prodromal symptoms, such as burning, mild pain, and itching, usually precede the eruption by a few hours. Clinically, it is characterized by edema and redness on the vermilion border and the adjacent perioral skin, followed by clusters of small vesicles.

The vesicles soon rupture, leaving small ulcers that are covered by crusts and heal spontaneously in 5 to 8 days (Fig. 184).

Frequently, recurrences may be associated with fever, emotional stress, menstruation, light exposure, cold weather, mechanical trauma, etc. The diagnosis is made usually on clinical grounds.

The differential diagnosis includes traumatic lesions, primary and secondary syphilis, and impetigo.

Treatment is symptomatic and is strengthened by topical application of acyclovir.

### Herpes Zoster

Herpes zoster is an acute localized viral disease caused by reactivation of a latent varicella-zoster virus. Herpes zoster affects elderly persons, usually more than 50 years old, and is rare in infants and children. An increased incidence of herpes zoster occurs in Hodgkin's disease, leukemias and other cancers, HIV infection, after administration of corticosteroids and other immunosuppressive drugs, and during radiation therapy. The thoracic, cervical, trigeminal, and lumbosacral dermatomes are most frequently affected. Clinically, the first manifestation of the disease is usually tenderness and pain in the involved dermatome. Constitutional symptoms, such as fever, malaise, and headache may also occur. After 2 to 4 days, the eruptive phase follows, characterized by grouped maculopapules on an erythematous base, which rapidly form vesicles and in 2 to 3 days evolve into pustules. Within 5 to 10 days, the pustules crust and persist for 10 to 20 days. New lesions continue to appear for several days. The regional lymph nodes are usually tender and enlarged. The unilateral location of the lesions is the most characteristic clinical feature of herpes zoster. Oral manifestations may occur when the second and third

branches of the trigeminal nerve are involved. Frequently, intraoral involvement is associated with unilateral skin lesions on the face. Oral mucosal lesions are almost identical to the cutaneous lesions. An itching sensation and pain, which may simulate pulpitis, precede oral lesions. These begin as unilateral clusters of vesicles, which in 2 to 3 days rupture, leaving ulcers surrounded by a broad erythematous zone (Figs. 185, 186). The ulcers heal without scarring in 2 to 3 weeks. Postherpetic trigeminal neuralgia is the most common complication of oral herpes zoster. Rarely, osteomyelitis, necrosis of the jaw bone, or loss of teeth may occur in immunocompromised patients.

The diagnosis of oral herpes zoster is based on clinical criteria.

The differential diagnosis should consider secondary herpetic stomatitis, and erythema multiforme.

Laboratory test. Cytologic examination confirms virally modified epithelial cells.

Treatment is symptomatic. Analgesics and sedatives may help to control the pain. Low-dose corticosteroids (such as 15 to 20 mg prednisolone per day) for a short time during the early stage of the disease may reduce the possibility of postherpetic neuralgia. Corticosteroids are contraindicated in immunosuppressed patients. Acyclovir and other antiviral agents may be helpful in severe cases.

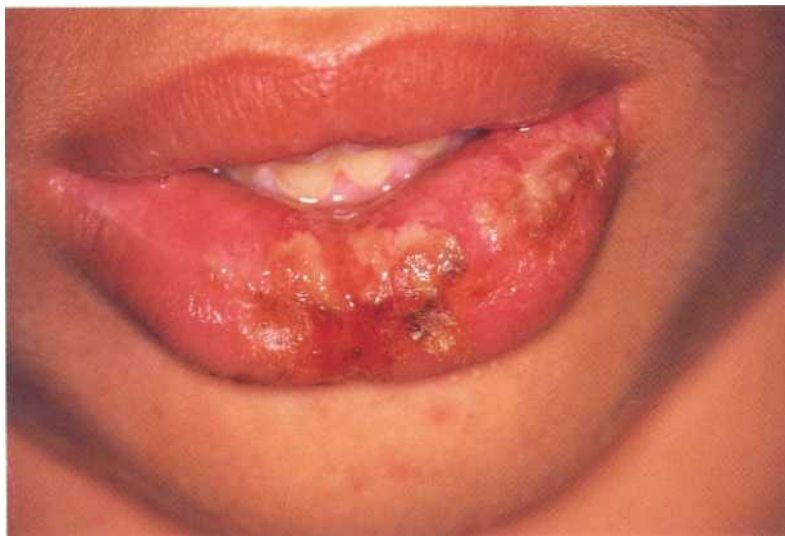

Fig. 184. Herpes labialis.

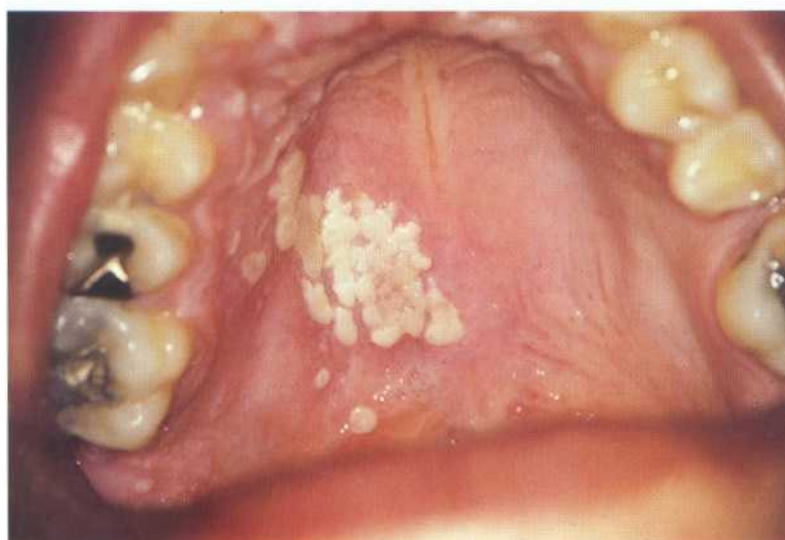


Fig. 185. Herpes zoster, clusters of vesicles on the palate.

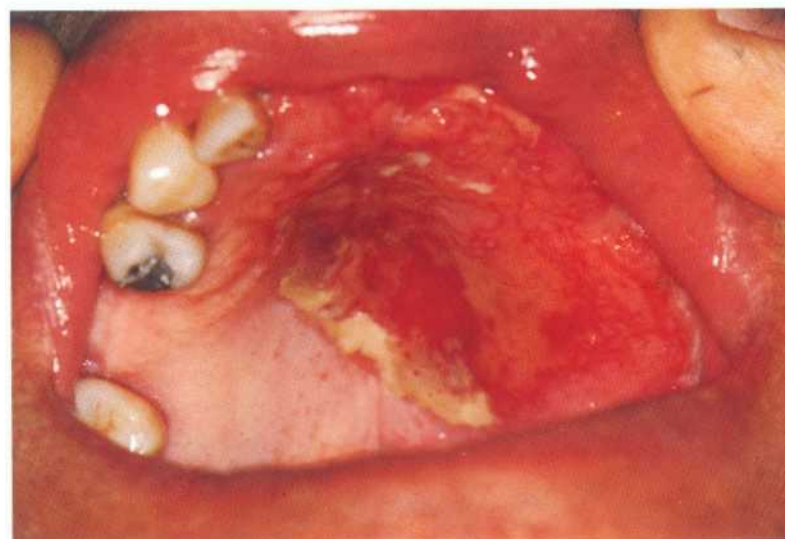


Fig. 186. Herpes zoster, erosions on the left side of the palate.

### Varicella

Varicella (chickenpox) is an acute exanthematous and highly contagious disease of childhood caused by primary infection with the varicella-zoster virus. The disease shows an increased prevalence in winter and spring. An incubation period of 10 to 20 days is common, followed by headache, lowgrade fever, and a maculopapular skin rash that rapidly becomes vesicular, pustular, and finally crusting. New elements appear in successive waves over 2 to 4 days and the presence of lesions at different stages is a characteristic clinical feature. The trunk, face, and scalp are most commonly involved.

In the oral mucosa a few small vesicles appear that soon rupture, leaving erosions with a whitish surface and red halo (Fig. 187). Oral lesions are common and show a predilection for the palate and the lips. Vesicles may also appear on other mucous membranes.

The diagnosis is made on clinical grounds.

The differential diagnosis of oral lesions includes herpetic lesions, aphthous ulcer, and streptococcal stomatitis.

Treatment is symptomatic.

### Herpangina

Herpangina is a specific acute infection caused by Coxsackie virus group A, types 1-6, 8, 10, and 22 and occasionally other types. It has a peak incidence during summer and autumn and frequently affects children and young adults. Clinically, the disease presents with sudden fever (ranging from 38° to 40°C), sore throat, headache, dysphagia, and malaise followed within 24 to 48 hours by diffuse erythema and a vesicular eruption of the posterior oral mucosa and oropharynx.

The vesicles are numerous, small, and soon rupture, leaving painful shallow ulcers that heal in 7 to 10 days (Fig. 188). The lesions characteristically involve the soft palate and uvula, the tonsils, faucial pillars, posterior pharyngeal wall, and rarely the buccal mucosa and the tongue.

The absence of lesions from the lips, gingiva, and the floor of the mouth are characteristic. The disease lasts for 7 to 12 days, and the diagnosis is exclusively based on clinical criteria.

The differential diagnosis includes primary herpetic gingivostomatitis, aphthous ulcers, herpetic ulcers, acute lymphonodular pharyngitis,

streptococcal and gonococcal pharyngitis, and erythema multiforme.

Laboratory tests to confirm the diagnosis are the isolation of the virus and serology, although they are not usually needed.

Treatment is symptomatic.

### Acute Lymphonodular Pharyngitis

Acute lymphonodular pharyngitis is an acute febrile disease caused by Coxsackie virus A10.

The disease frequently affects children and young adults. Clinically, it presents with fever (ranging from 38° to 41°C), a mild headache, anorexia, and sore throat, followed within 2 to 3 days by a characteristic nonvesicular eruption on the uvula, soft palate, anterior tonsillar pillars, and posterior pharynx (Fig. 189). The lesions consist of multiple, raised, discrete papules whitish to yellowish in color surrounded by an erythematous halo. The size of the lesions varies from 3 to 6 mm in diameter and they last 4 to 8 days.

The differential diagnosis includes herpangina and herpes simplex.

Laboratory tests to confirm the diagnosis are the isolation of the virus and serologic examination.

Treatment is symptomatic and the disease is self-limiting.

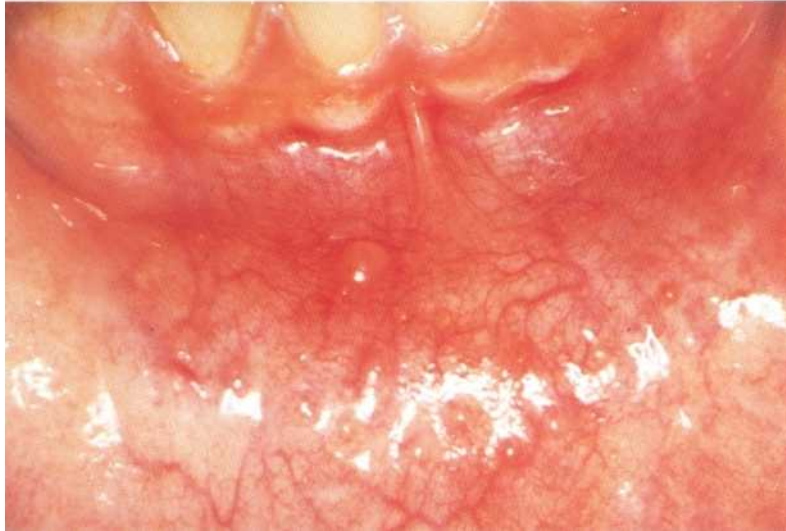

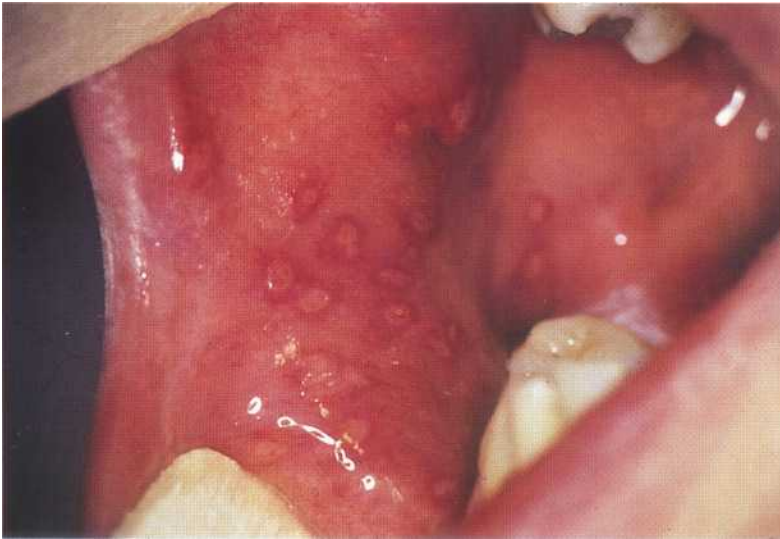
Fig. 187. Varicella, small vesicle on the lower lip mucosa.

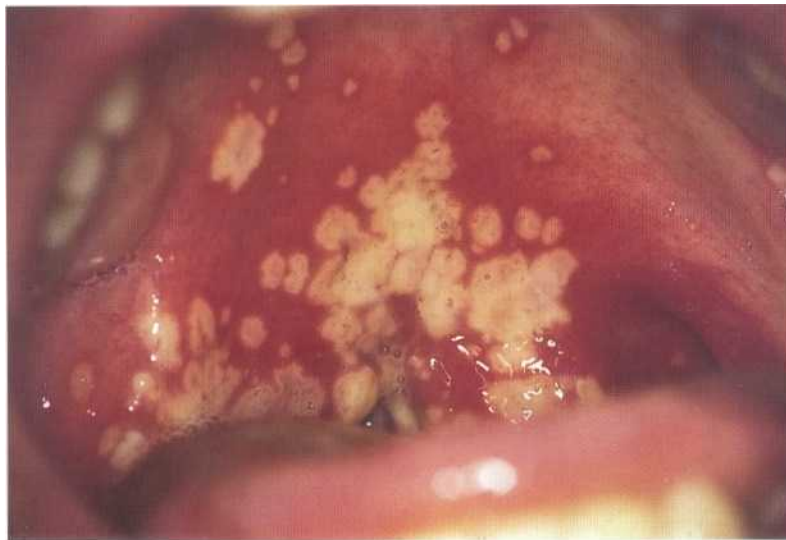

Fig. 188. Herpangina, numerous shallow ulcers on the soft palate.

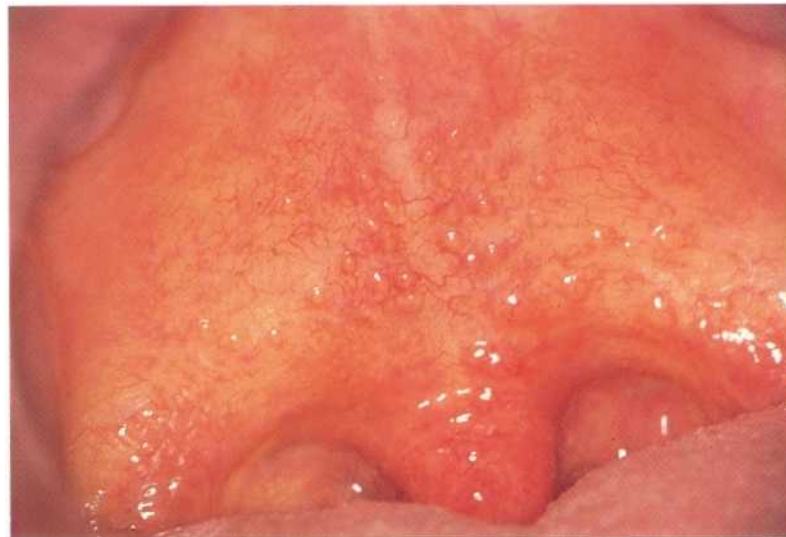

Fig. 189. Acute lymphonodular pharyngitis, multiple discrete papules on the soft palate and uvula.



**Fig. 190. Hand-foot-and-mouth disease, shallow ulcers on the buccal mucosa.**

### Hand-Foot-and-Mouth Disease

Hand-foot-and-mouth disease is usually associated with Coxsackie virus A16, occasionally with A5, A10, and infrequently with other types. It usually affects children and young adults. The disease may occur in epidemics or isolated cases. Clinically, there appear a few (5 to 10 in number) small vesicles that soon rupture, leaving slightly painful, shallow ulcers (2 to 6 mm in diameter) surrounded by a red halo (Fig. 190). The tongue, buccal mucosa, and palate are the usual sites of involvement. Skin lesions are inconstant, and small vesicles surrounded by a narrow red halo are present. The lateral and dorsal surfaces of the fingers and toes are the more frequently involved areas (Figs. 191, 192). However, lesions may occur on the palms, soles, and buttocks. Low-grade fever of short duration and malaise may be present. The disease lasts 5 to 8 days.

The diagnosis is based on clinical criteria.

The differential diagnosis includes aphthous ulcers, herpetiform ulcers, primary and secondary herpetic stomatitis, and herpangina.

Laboratory test. Isolation of the virus and inoculation in newborn mice may be needed to confirm the diagnosis in atypical cases.

Treatment is supportive.

### Measles

Measles is an acute, contagious infection of childhood, caused by a specific paramyxovirus. After an incubation period of 8 to 12 days the patient presents with fever, malaise, chills, cough, and conjunctivitis. Three to 4 days later a characteristic maculopapular rash appears behind the ears and on the forehead and spreads within 24 hours to the rest of the face, the neck, the trunk, and the extremities. The rash fades from the 6th to 10th days. Characteristic bluish-white specks with bright red areola (Koplik's spots) may appear on the buccal mucosa at the level of the first and second molars, 1 to 2 days before onset of the rash. Koplik's spots are transient and usually absent. A diffuse erythema, petechiae, and rarely small round erosions on the oral mucosa may also be observed (Fig. 193). Complications are encephalitis, otitis media, pneumonia, and enteritis.

The differential diagnosis of oral lesions includes acute candidosis, minor aphthous ulcers, herpetic lesions, infectious mononucleosis, and varicella.

Laboratory test. Serologic tests are useful in the diagnosis of atypical cases.

Treatment is symptomatic.

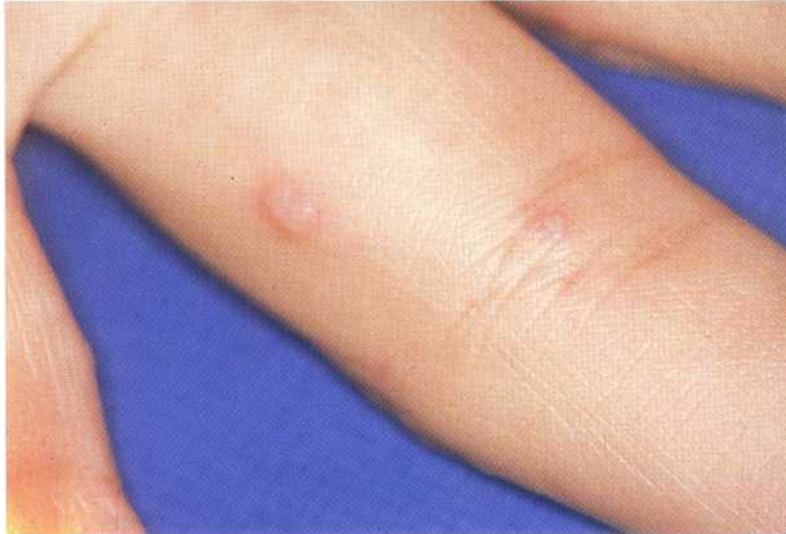

Fig. 191. Hand-foot-and-mouth disease, two small vesicles on the fingers.

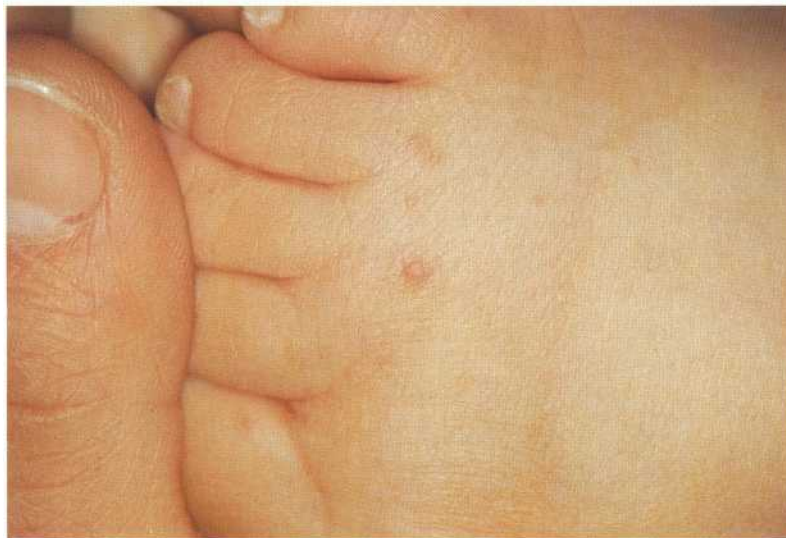

Fig. 192. Hand-foot-and-mouth disease, small vesicles on the foot.

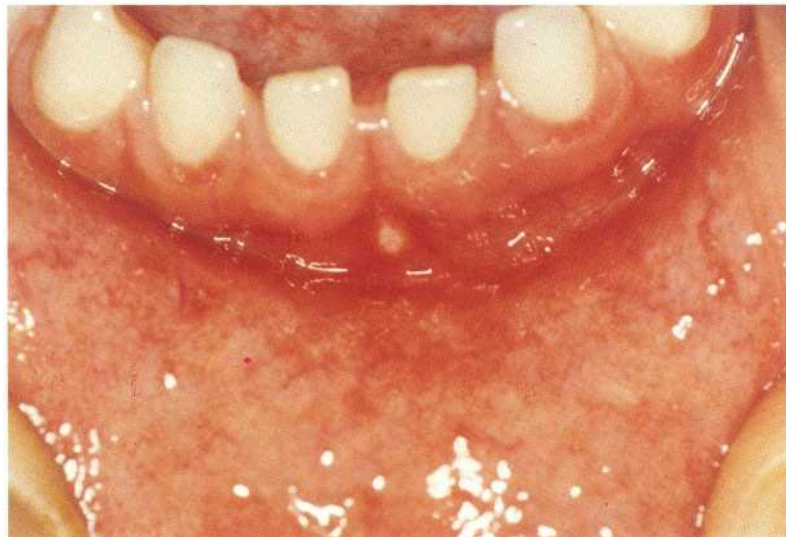

Fig. 193. Measles, small erosion on the mucolabial fold.

### Infectious Mononucleosis

Infectious mononucleosis is an acute self-limited disease caused by the Epstein-Barr virus. The virus is frequently transmitted through salivary transfer. Infectious mononucleosis is more common in children and young adults. The incubation period is about 30 to 50 days, followed by low-grade fever, which persists for 1 to 2 weeks, malaise, mild headache, and fatigue. Generalized lymphadenopathy also begins early and is a common manifestation. Splenomegaly, hepatomegaly, and very rarely central nervous system involvement may also occur. A maculopapular eruption usually on the trunk and arms is present in 5 to 15% of cases. The oral manifestations are early and frequent, and the most constant features are palatal petechiae, uvular edema, tonsillar exudate, diffuse erythema of the oral mucosa, gingivitis, and rarely ulcers (Fig. 194). Sore throat, tonsillitis, and pharyngitis may also occur in association with the oral lesions.

The diagnosis is usually based on the clinical features.

The differential diagnosis of oral lesions includes lesions from fellatio, streptococcal oropharyngitis, diphtheria, leukemia, and secondary syphilis.

Laboratory tests. The diagnosis is confirmed by heterophile antibody tests and other specific antibody tests.

Treatment is symptomatic.

### Mumps

Mumps or epidemic parotitis is an acute viral infection most commonly affecting children between 5 and 15 years of age and rarely older individuals. Transmission is by respiratory droplets. The parotid gland and less often the submandibular and sublingual glands are predominantly affected.

Clinically, after an incubation period of 14 - 21 days, variable fever, chills, headache, and malaise develop, accompanied by pain in the parotid area. Tender, rubbery, and edematous swelling of one or both of the parotids are the presenting signs and last for about 7 days (Fig. 195). The orifice of Stensen's duct may be swollen and red. Orchitis, meningoencephalitis, and pancreatitis are the most common complications.

The differential diagnosis includes acute suppurative parotitis, calculi in the salivary glands, buccal

cellulitis, angioneurotic edema, Sjogren's syndrome, Mikulicz's syndrome, Heerfordt's syndrome, salivary gland neoplasms, and lymph node enlargement.

Laboratory tests. The diagnosis can be confirmed by serologic examination and isolation of the virus from saliva. Elevated serum amylase and relative lymphocytosis may be present.

Treatment is symptomatic. Bed rest during the febrile period, and analgesics.

### Verruca Vulgaris

Verruca vulgaris, or common wart, is a benign skin lesion caused by a specific human papilloma virus (HPV 2 and 4). The most prevalent sites of localization are the backs of the fingers and the hands. From these lesions, the virus may be auto-inoculated to the oral mucosa.

Verruca vulgaris is relatively uncommon in the oral mucosa and is clinically and histologically similar to its cutaneous counterpart. Clinically, it appears as a small sessile, well-defined exophytic growth with a cauliflower surface and whitish or normal color (Fig. 196). The oral lesions may be single or multiple and are frequently located on the lips, palate, and rarely in other oral regions.

The differential diagnosis includes papilloma, condyloma acuminatum, early verrucous carcinoma, verruciform xanthoma, and sialadenoma papilliferum.

Laboratory test. Histopathologic examination confirms the diagnosis.

Treatment consists of surgical excision.

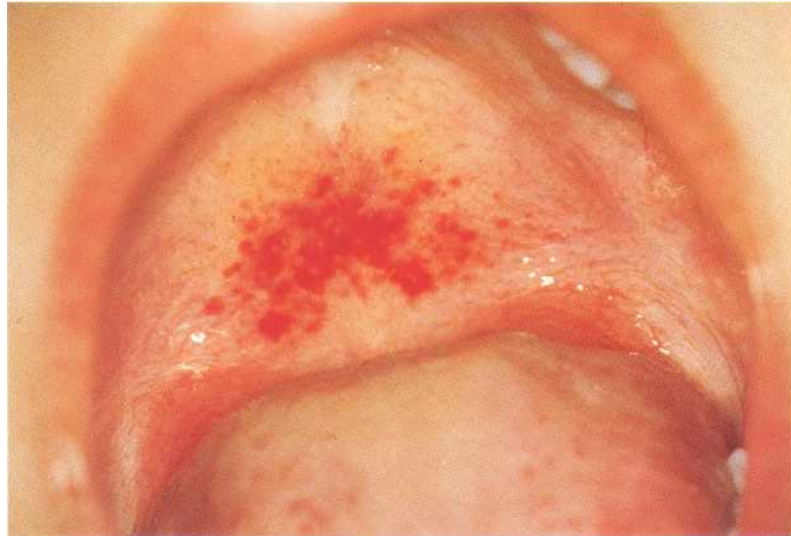

Fig. 194. Infectious mononucleosis, petechiae on the palate.

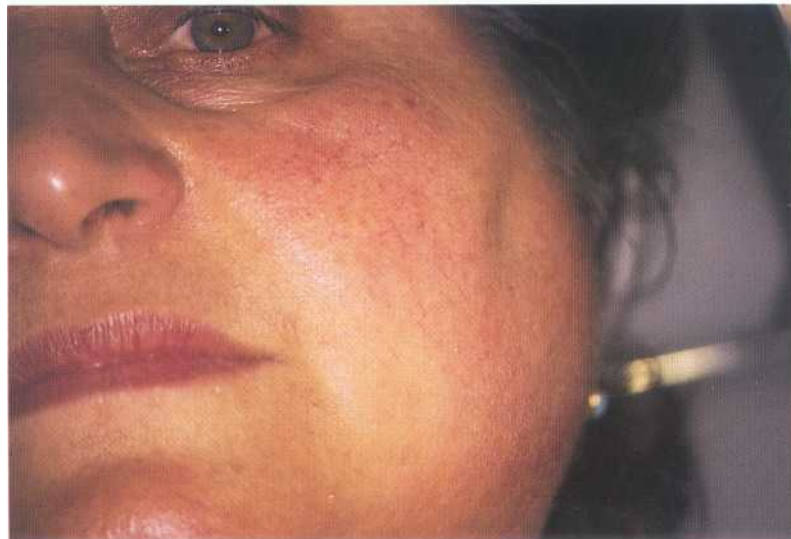

Fig. 195. Mumps, swelling of the left parotid.

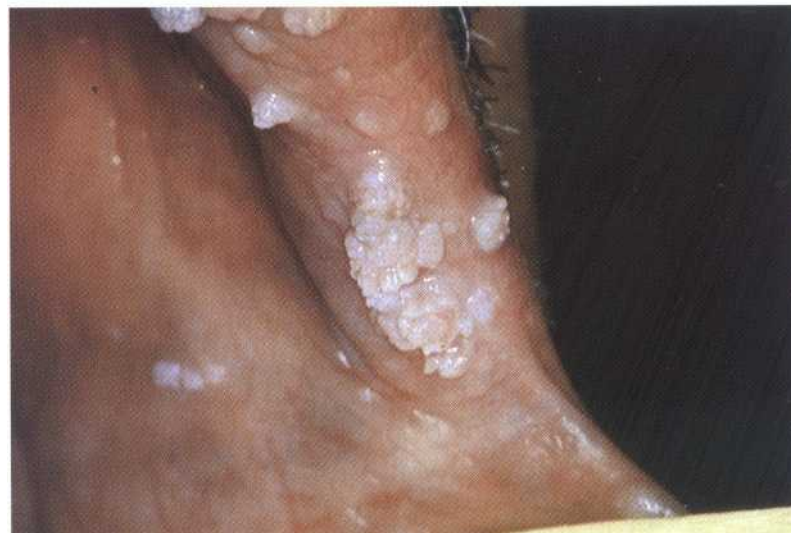

Fig. 196. verruca vulgaris, multiple lesions on the lip mucosa.



### Condyloma Acuminatum

Condyloma acuminatum, or genital wart, is a common benign virus-induced lesion mainly occurring in the anogenital area. The disease is sexually transmitted and is caused by a human papillomavirus.

Condyloma acuminatum of the oral mucosa is rarely encountered and may be due to autoinoculation from genital condyloma acuminatum or during orogenital contact. An increased incidence of the lesions have been reported in HIV-infected patients. Clinically, it appears as single or multiple small sessile or pedunculated nodules that may proliferate and coalesce, forming cauliflower-like growths (Fig. 197). The lesions have whitish or normal color and display a tendency to recur. The dorsum of the tongue, lip mucosa, gingiva, buccal mucosa, especially near the commissure, and the palate are the sites most commonly affected.

The differential diagnosis includes verruca vulgaris, papilloma, verrucous carcinoma, verruciform xanthoma, focal epithelial hyperplasia, sialadenoma papilliferum, molluscum contagiosum, and focal dermal hypoplasia syndrome.

**Laboratory test.** Histopathologic examination is necessary to confirm the diagnosis. DNA hybridization techniques may also be helpful.

**Treatment** consists of surgical excision or electrocautery.

### Molluscum Contagiosum

Molluscum contagiosum is a benign lesion usually seen on the skin and caused by a pox virus. The lesions may develop at any age, but the majority of cases are found in children. Males are affected more frequently than females. An increased incidence of molluscum contagiosum has been observed in patients with HIV infection. Clinically, the lesions are characterized by grouped, minute, dome-shaped papules, often with central umbilication. Small amounts of whitish fluid may exude on pressure from these lesions. Any skin region may be involved, but the head, eyelids, trunk, and genitalia are most often affected. Molluscum contagiosum is extremely rare in the oral cavity. The clinical picture of oral lesions is similar to the skin lesions and is characterized by multiple small hemispheric papules with a central umbilication (Fig. 198). The buccal mucosa, labial mucosa, and palate are the sites of involvement in the reported cases.

The differential diagnosis of oral lesions should include lymphangioma, hemangioma, pyogenic granuloma, and condyloma acuminatum.

**Laboratory test.** Histopathologic examination establishes the final diagnosis.

**Treatment.** Surgical excision or cryotherapy are the preferred modes of treatment of oral lesions.

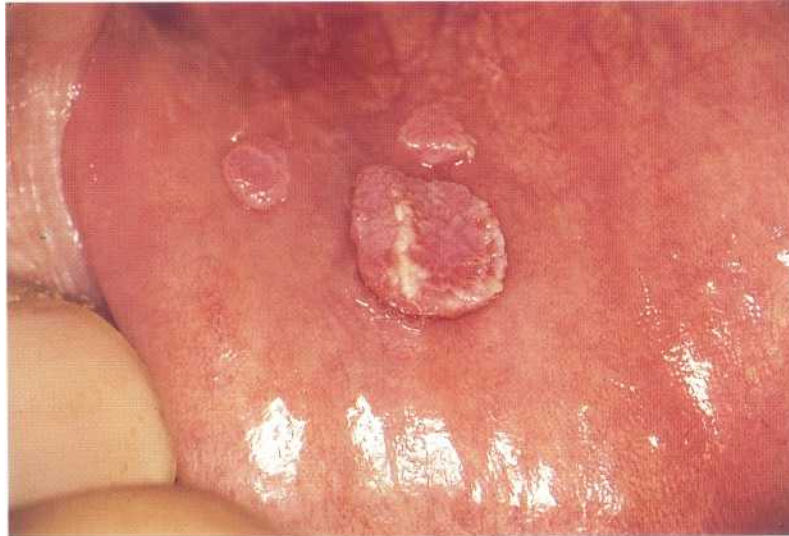


Fig. 197. Multiple condylomata acuminata on the lower lip mucosa.

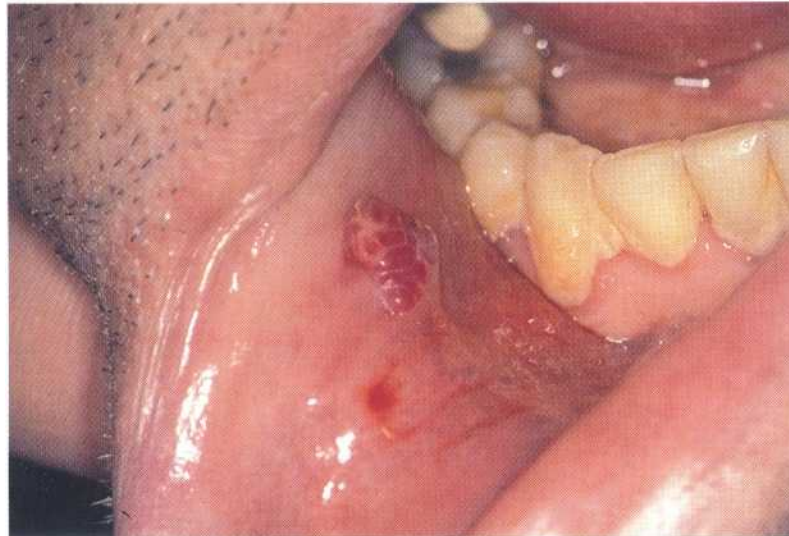
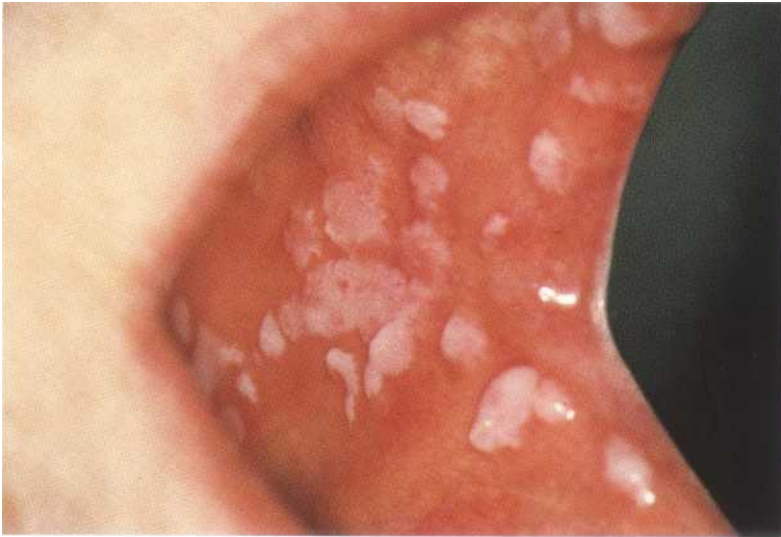
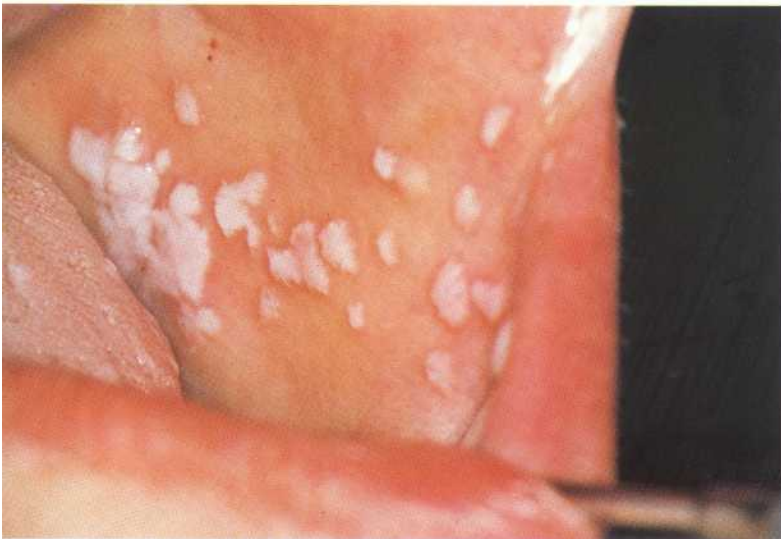

Fig. 198. Molluscum contagiosum of the buccal mucosa.



**Fig. 199. Focal epithelial hyperplasia, multiple lesions on the buccal mucosa.**



**Fig. 200. Focal epithelial hyperplasia, multiple lesions on the buccal mucosa.**

### **Focal Epithelial Hyperplasia**

Focal epithelial hyperplasia is a benign hyperplastic lesion of the oral mucosa. It frequently occurs in Eskimos, North American Indians and South Africans, but it has also been reported in other racial groups. Sporadic cases have also been encountered among Europeans and Asians. The causative agents are human papillomavirus (HPV-13 and 32). However, the familial occurrence and the predilection of the disease for certain age groups suggest that a genetic factor could also contribute to the appearance of the lesions. Clinically, it is characterized by multiple painless, sessile, slightly elevated soft papules or nodules 1 to 10 mm in diameter (Figs. 199, 200). The lesions are whitish or have normal color and smooth

surface. On stretching the mucosa, the lesions tend to disappear. The disease is more common in children and the lesions frequently are located on the lower lip, the buccal mucosa, the tongue, and less often on the upper lip, the gingiva, and the palate.

The differential diagnosis includes multiple condylomata acuminata and verruca vulgaris, multiple papillomas and fibromas, Cowden's disease, and focal dermal hypoplasia syndrome.

**Laboratory test.** Histopathologic examination is essential for diagnosis.

Treatment is nonspecific and should be conservative, since the lesions may disappear within a few months or they may become inactive.

## 16. HIV Infection and AIDS

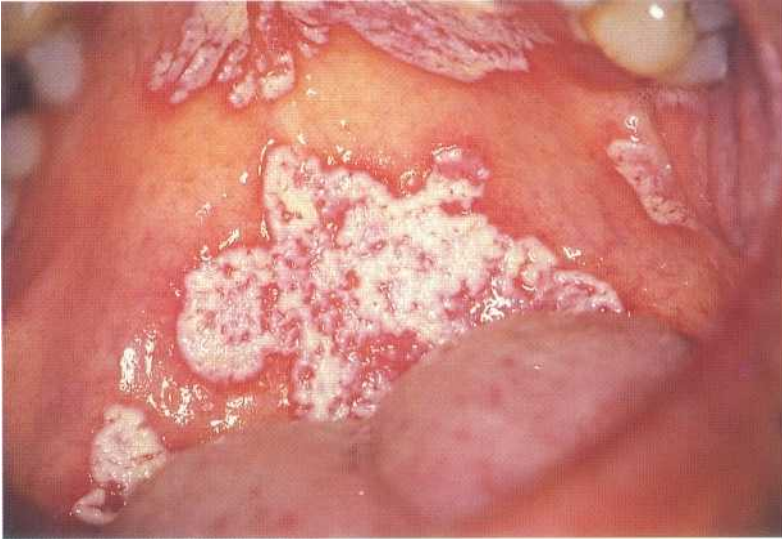
Acquired immune deficiency syndrome (AIDS) was first reported in 1981 in young homosexual men. HIV infection is a disease due to HIV (Human Immunodeficiency Virus). It is mainly transmitted through sexual contact and through blood or blood products. It has been suggested by the World Health Organization and the Centers for Disease Control that AIDS (the more extreme expression of HIV infection) by definition must fulfill the following strict criteria: one or more opportunistic diseases (viral, bacterial, fungal, protozoal, and helminthic infections, neoplasms, such as Kaposi's sarcoma, lymphoma limited to the brain, non-Hodgkin lymphoma and others) diagnosed by reliable methods, which are at least moderately indicative of an underlying cellular immunodeficiency, absence of all known underlying causes of cellular immunodeficiency other than HIV infection, and absence of all other causes of reduced resistance reported to be associated with at least one of those opportunistic infections. However, despite these criteria, the diagnosis of AIDS must be excluded in patients with: negative findings on testing for serum antibodies to HIV, negative culture for HIV, normal or high number of T-helper lymphocytes, and normal or high ratio of T-helper to T-suppressor lymphocytes.

The spectrum of HIV infections is extremely broad. At one end is full-blown AIDS and at the other are clinically healthy persons who carry HIV antigens or antibodies. Between these two extremes are patients who exhibit various clinical and laboratory manifestations of HIV infection, referred to as patients with the AIDS-related complex (ARC) and chronic lymphadenopathy syndrome (LAS). In 1986 the CDC suggested a classification system for the manifestations of HIV infection into four groups: acute infection (group I), asymptomatic infection (group II), persistent generalized lymphadenopathy (group III), and other diseases (group IV); the latter includes five subgroups. In 1993 the CDC suggested a revised

classification system of HIV infection for adolescents and adults. Patients are categorized on the basis of clinical conditions associated with HIV infection and CD4 + T-lymphocyte counts. The main high-risk group for HIV infection comprises, in most areas, homosexual and bisexual men (50-60%), but also drug addicts, hemophiliacs who have received unscreened blood products, heterosexual contacts of high-risk individuals, and transfusion recipients.

The oral manifestations are mainly a result of cellular immunodeficiency induced by HIV infection and may be divided into four major groups: infections, neoplasms, neurologic disturbances, and lesions of unknown cause.

These oral lesions may represent early or later manifestations of the disease although their prevalence as well as the diagnostic and/or prognostic value need further evaluation.



**Fig. 201.** HIV infection, pseudomembranous candidosis on the palate.

## Infections

The infectious oral diseases may be fungal, viral, and bacterial. Of the fungal infections, oral candidosis is an early and common feature occurring in about 50-70% of HIV-infected patients. Pseudomembranous and erythematous candidosis are the most common variants. The pseudomembranous variant is clinically characterized by white or yellow spots of plaques which can be wiped off and may be located anywhere in the mouth (Fig. 201). The erythematous variant is characterized

by a red area without removable white spots or plaques, which is usually located on the dorsum of the tongue (Fig. 202) and the palate (Fig. 203). Both types are almost equally likely to manifest. In addition, angular cheilitis (Fig. 204) is often associated with *Candida albicans*, and may be seen in HIV-infected patients. The different types of candidosis may coexist in the same patient.

Other fungal infections such as histoplasmosis, cryptococcosis, mucormycosis, geotrichosis, and aspergillosis with oral manifestations may rarely be observed.

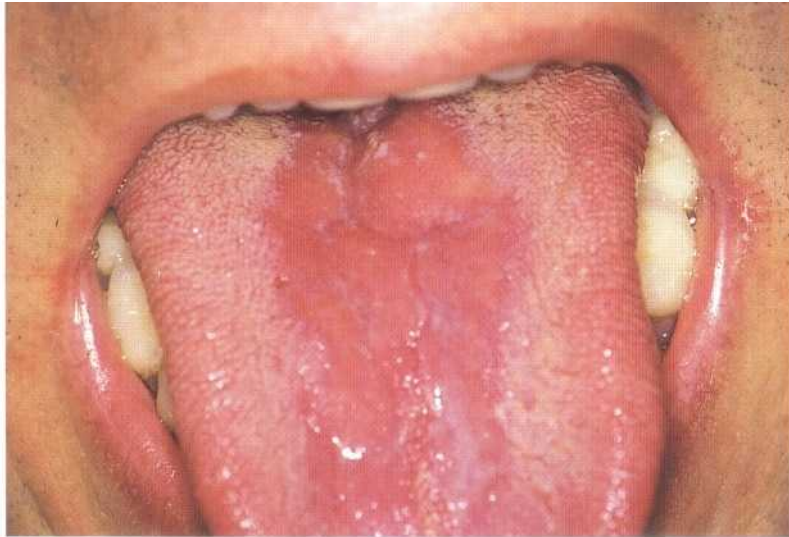


Fig. 202. HIV infection, erythematous candidosis on the dorsum of the tongue.

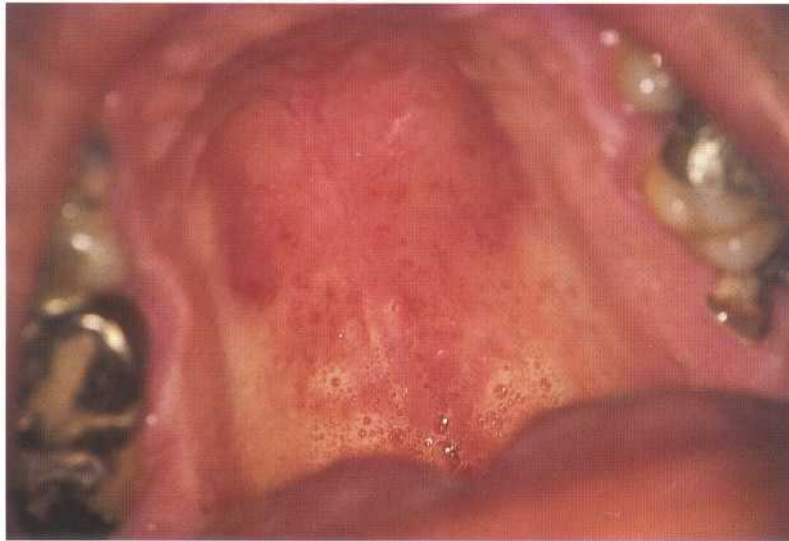
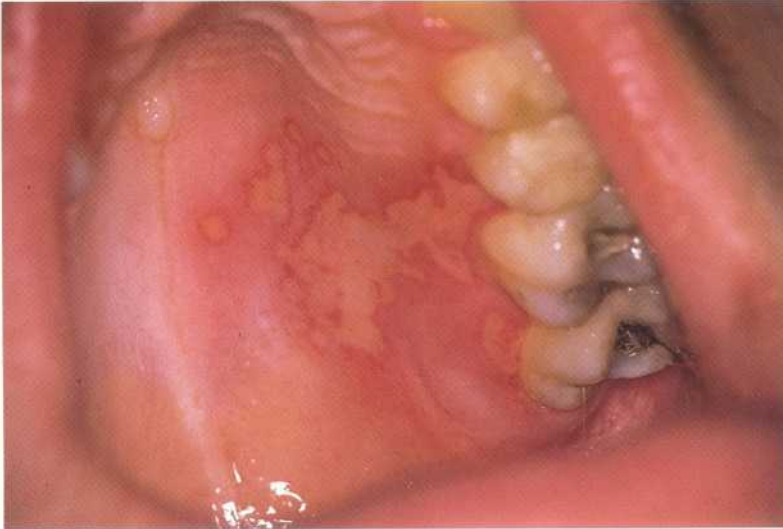


Fig. 203. HIV infection, erythematous candidosis on the palate.

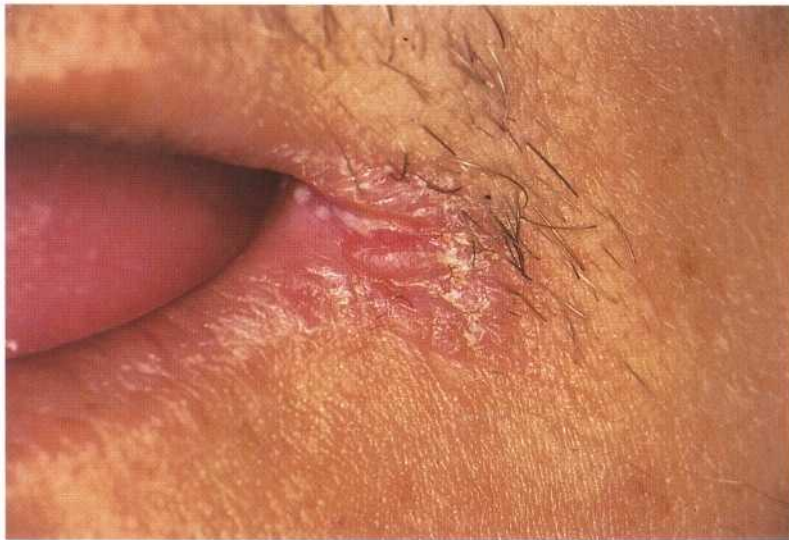

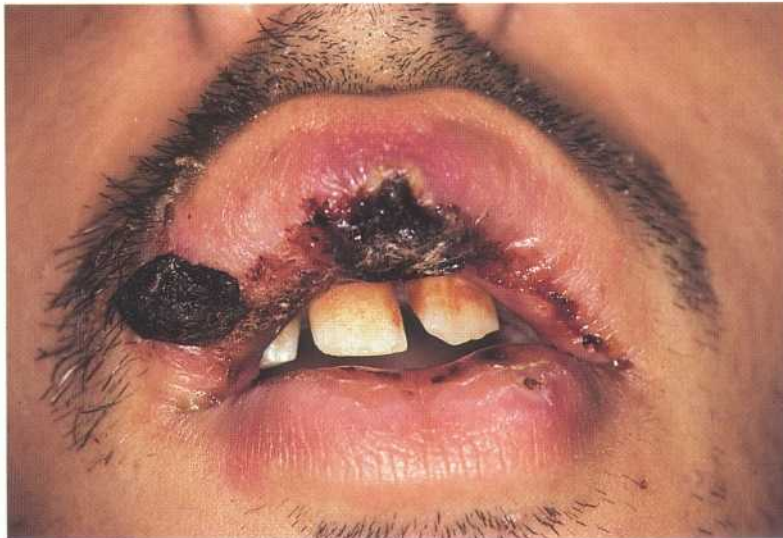Fig. 204. HIV infection, angular cheilitis.



**Fig. 205.** HIV infection, recurrent herpetic lesions on the palate in an 18-year-old homosexual man.



**Fig. 206.** HIV infection, herpes labialis in a 22-year-old hemophiliac.

Intraoral and lip herpes simplex is a relatively frequent oral viral infection (Figs. 205, 206). The prevalence rate is about 5 -10%. Oral herpes zoster is a rare occurrence in HIV-infected patients. Human papillomavirus (HPV)-associated oral lesions such as condyloma acuminatum (Fig. 207), verruca vulgaris, and focal epithelial hyperplasia may also occur. Sporadic cases of oral ulcerations due to cytomegalovirus have also recently reported. Perioral molluscum contagiosum may also occur (Fig. 208). Hairy leukoplakia is a common oral mucosal feature that has been described among all high-risk groups for HIV infection. Hairy leukoplakia may be an early clinical sign and reliable indicator of HIV infection and is a predictor of the subsequent develop-

ment of AIDS. Rarely, cases of hairy leukoplakia have been reported in immunosuppressed subjects after organ transplantation. The prevalence of hairy leukoplakia in HIV-infected patients is not yet fully documented and varies from 20% to 36% or more.

Although the exact etiology and pathogenesis of the lesion remain unclear, the Epstein-Barr virus seems to play an important role.

Clinically, hairy leukoplakia presents as a whitish, slightly elevated, nonremovable lesion of the tongue, often bilaterally.

Characteristically, the surface of the lesion is corrugated with a vertical orientation, but flat and smooth lesions may also be seen (Fig. 209).

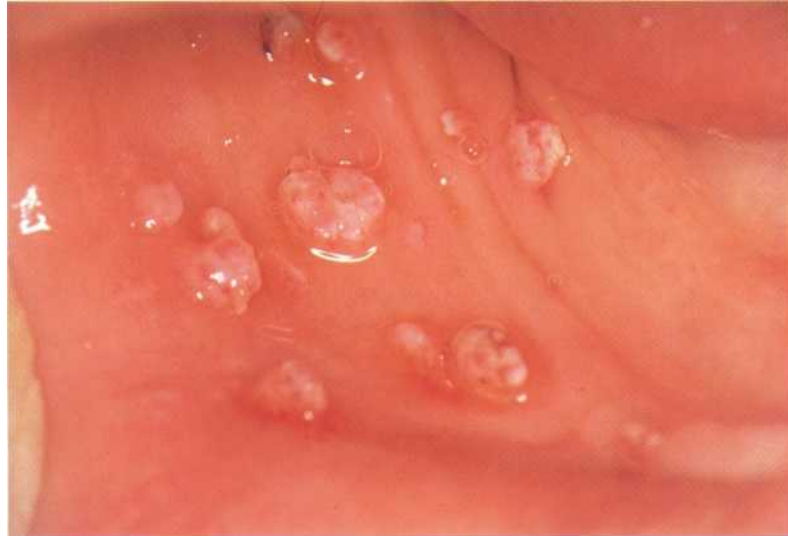

Fig. 207. HIV infection, multiple condylomata acuminata on the buccal mucosa.

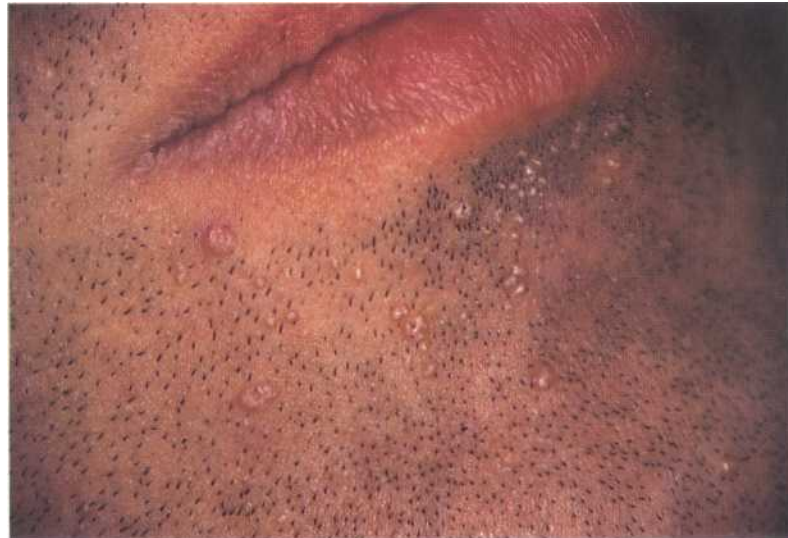

Fig. 208. HIV infection, multiple perioral lesions of molluscum contagiosum in a 35-year-old homosexual man with AIDS.

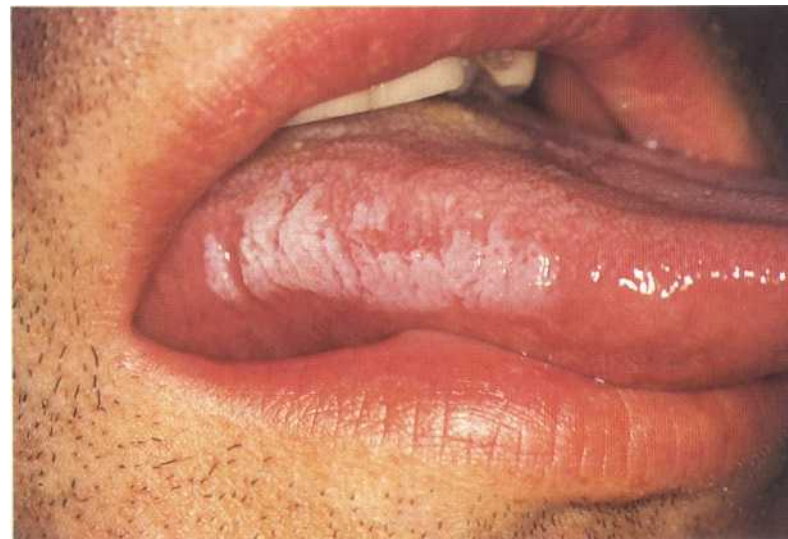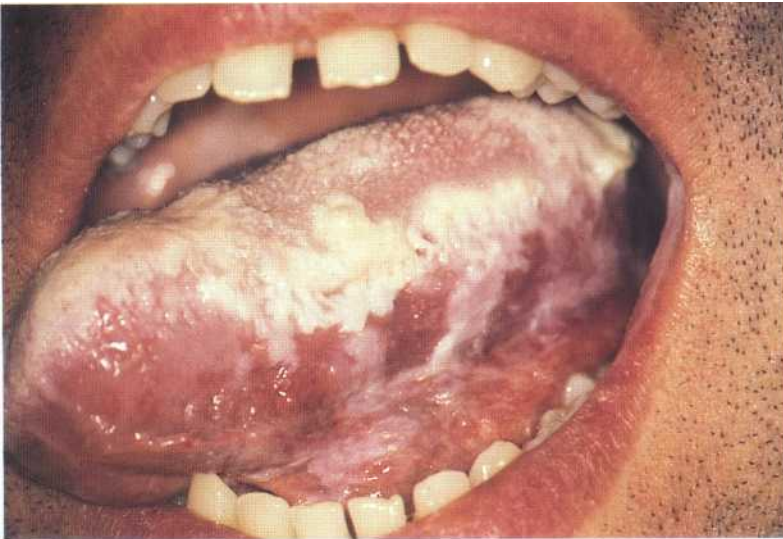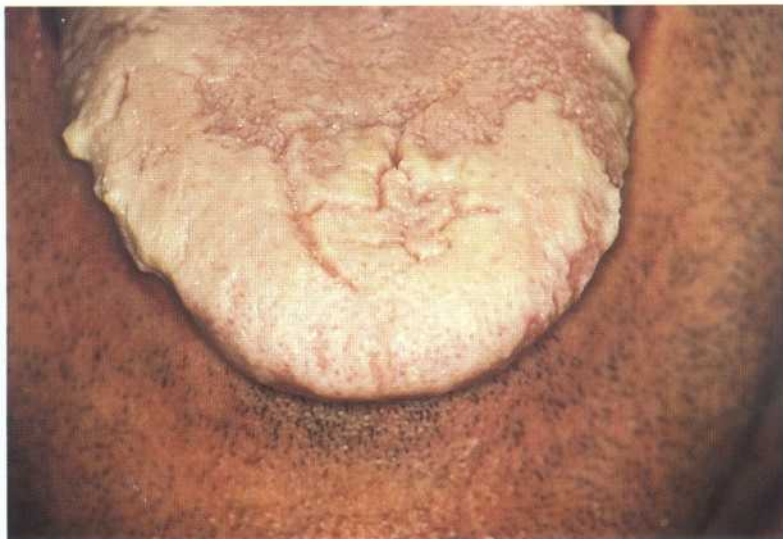


Fig. 209. HIV infection, typical hairy leukoplakia on the lateral border of the tongue in a 31-year-old homosexual man.





**Fig. 210.** HIV infection, moderate hairy leukoplakia on the tongue.



**Fig. 211.** HIV infection, marked hairy leukoplakia involving the dorsum of the tongue in a 28-year-old bisexual man.

Lesions may extend onto the ventral surface and the dorsum of the tongue (Figs. 210, 211). In addition, very rarely lesions may occur at other oral sites. Their size varies from a few millimeters to several centimeters and cannot be used to predict the stage of HIV infection.

Among the bacterial infections, periodontal disease is relatively common in HIV-infected individuals. HIV-related periodontal disease is classified into three forms: HIV-associated gingivitis (linear gingival erythema), HIV-associated periodontitis (necrotizing periodontitis), and necrotizing gingivitis.

Clinically, HIV-associated gingivitis (HIV-G) is characterized by a fiery red band along the margin of the gingiva (Fig. 212). The lesion does not respond to plaque control measures or root planing and scaling. Gingival bleeding may occur spontaneously or on probing.

Clinically, HIV-associated periodontitis (HIV-P) is characterized by soft tissue ulceration and necrosis, and rapid destruction of the periodontal attachment apparatus (Figs. 213, 214). Spontaneous bleeding and severe deep pain are common. The condition does not respond to conventional periodontal treatment. HIV-associated periodontitis is usually localized, although severe cases may be generalized.

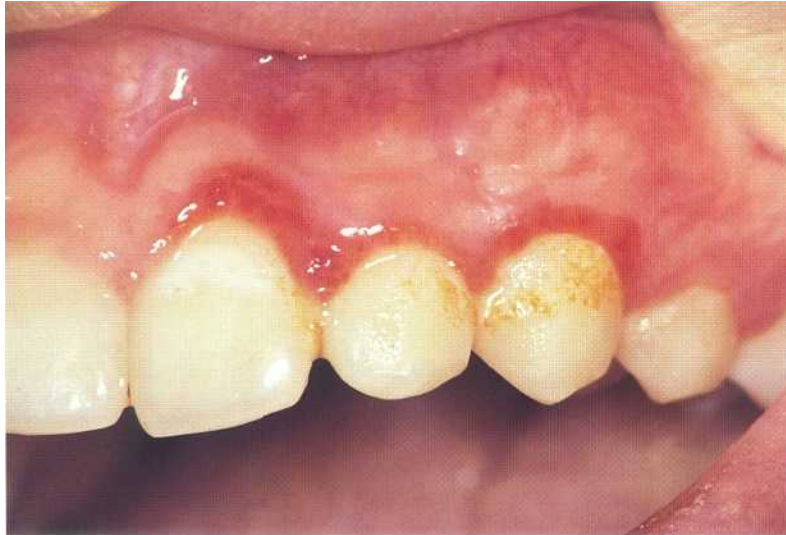

Fig. 212. HIV-gingivitis (linear gingival erythema), fiery red band along the margin of the gingiva.

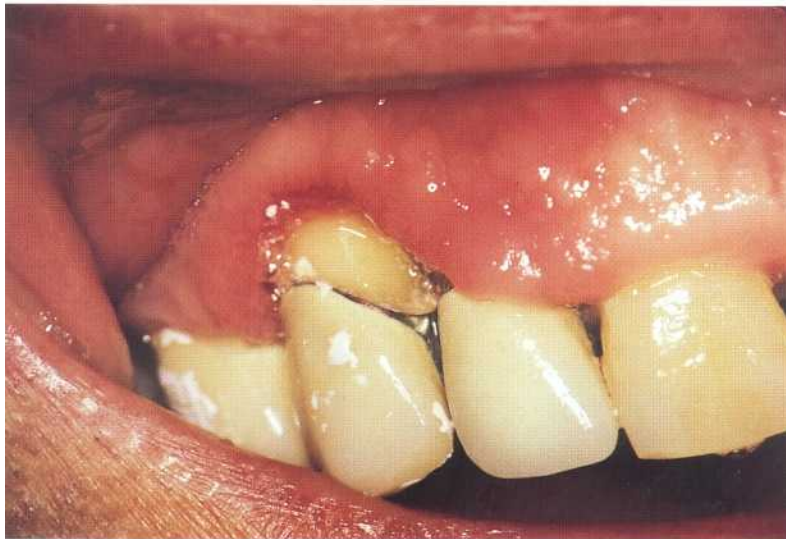

Fig. 213. Localized HIV-periodontitis (necrotizing periodontitis).

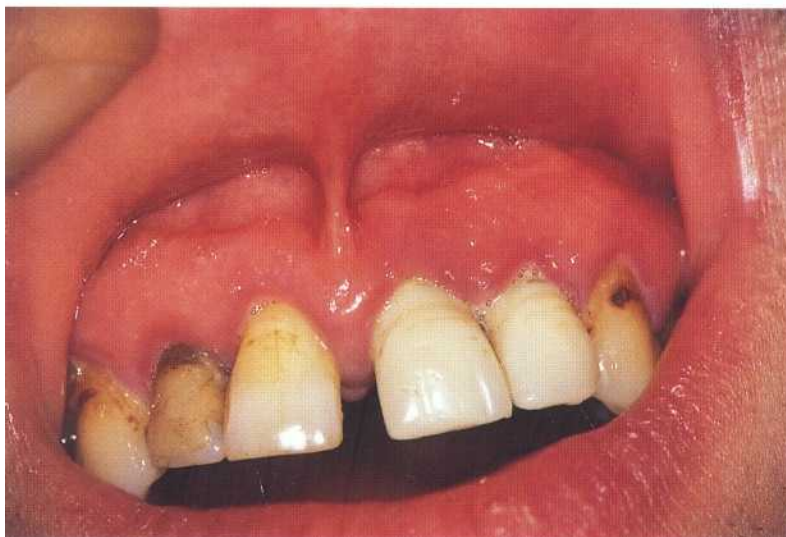
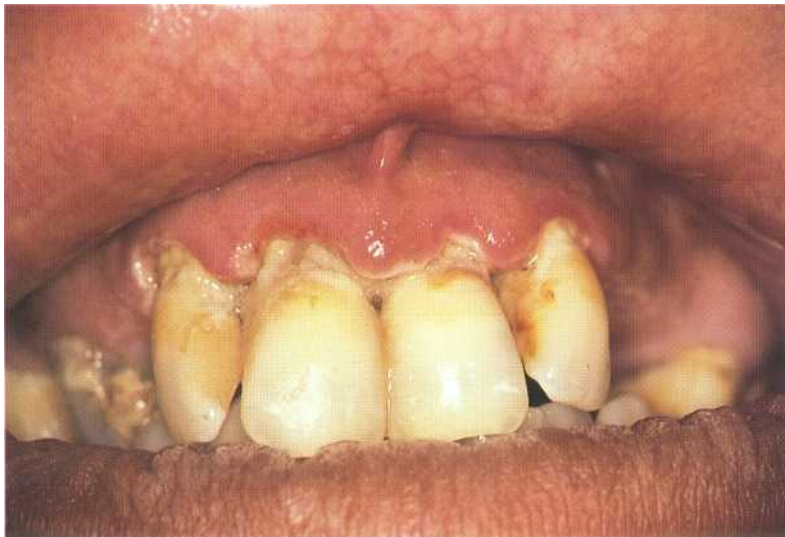
Fig. 214. Severe generalized HIV-periodontitis with rapid destruction of supporting bone in a 35-year-old homosexual man.



**Fig. 215. Severe necrotizing gingivitis in a 32-year-old HIV-seropositive homosexual man.**

Clinically, necrotizing gingivitis exhibits features similar to the necrotizing gingivitis seen in non-HIV-infected patients (Fig. 215).

Necrotizing gingivitis is early and common in HIV-infected patients with a prevalence rate of 4-16%. The possibility of HIV infection must be considered, particularly if high-risk behavior is associated with the necrotizing gingivitis.

Necrotizing gingivitis may in some cases progress to necrotizing stomatitis. The latter is characterized by localized acute, painful ulceronecrotic lesions of the oral mucosa. The underlying bone is exposed or penetrated. The lesion may extend to contiguous tissues (Fig. 216).

Furthermore, oral infections with *Mycobacterium avium intracellulare*, *Mycobacterium tuberculosis*, *Escherichia coli*, *Actinomyces israelii*, and *Klebsiella pneumoniae* have rarely been reported. Recently, bacillary angiomatosis has been also described in the mouth.

## Neoplasms

The AIDS-associated Kaposi's sarcoma is the most common neoplasm, occurring in approximately 20% of patients with AIDS. It usually appears on the skin (trunk, palms, soles, face, head, and neck) (Fig. 217). Up to 50% of AIDS patients with Kaposi's sarcoma have oral lesions, and the palate is the site most commonly involved, followed by the gingiva. Multiple sites of involvement may occur. In some cases, the oral mucosa is the only site of Kaposi's sarcoma. Clinically, the oral lesions in the early phases appear as a red or pigmented macule, papule, or patch (Fig. 218).

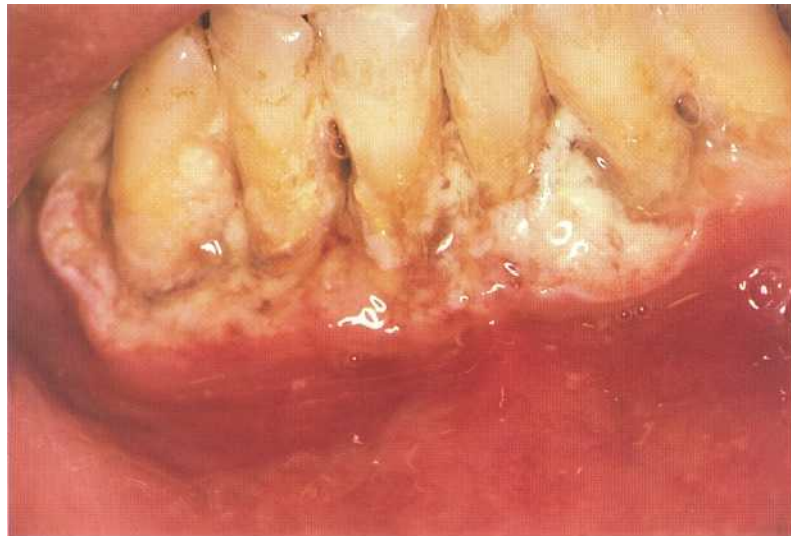


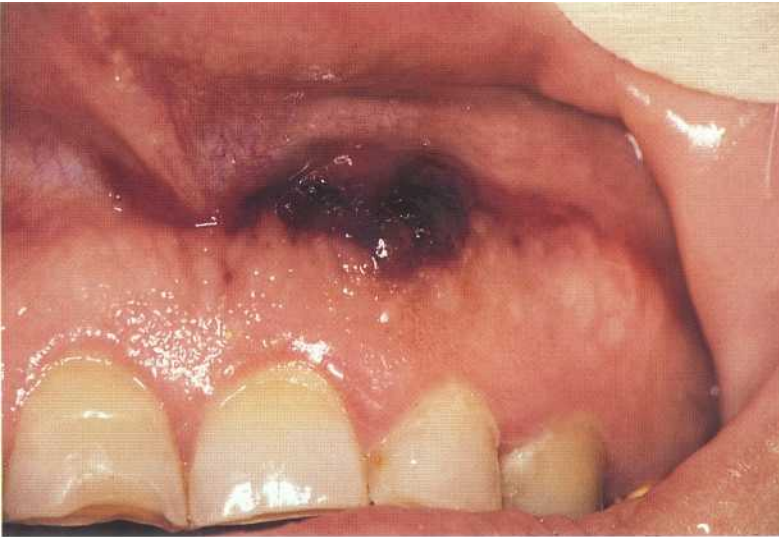
Fig. 216. Necrotizing stomatitis in a 30-year-old man with AIDS. Note extensive soft tissue necrosis beyond the gingiva.

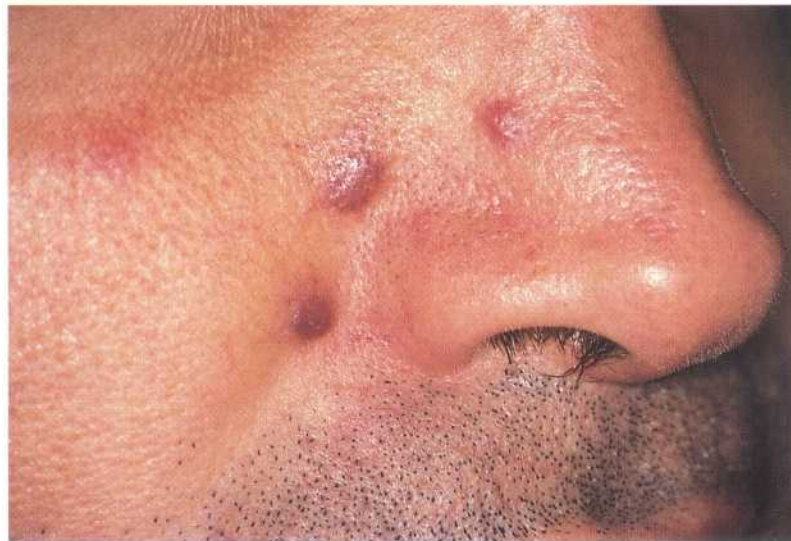

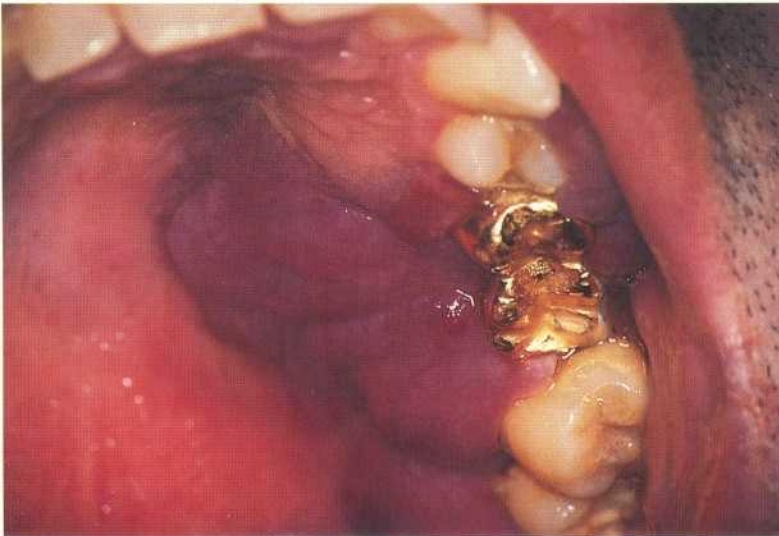
Fig. 217. Kaposi's sarcoma, early lesions on the face in a 42-year-old man with AIDS.

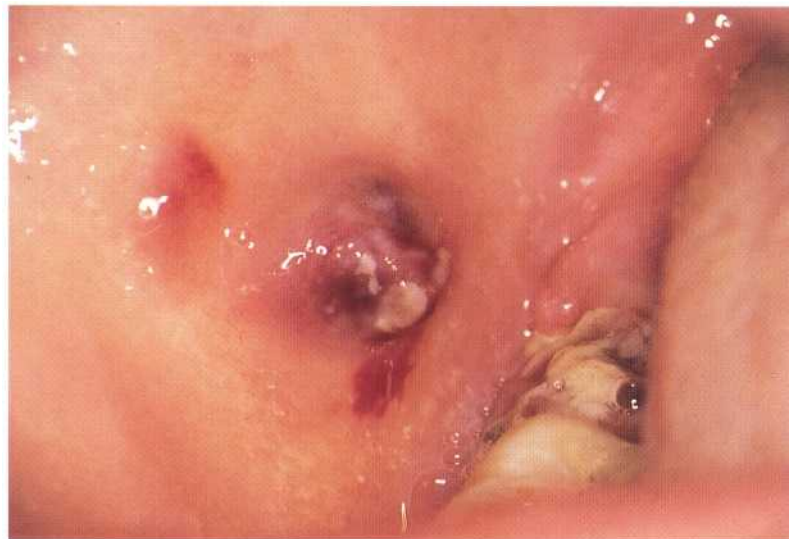

Fig. 218. Kaposi's sarcoma, early lesions on the buccal mucosa in a 33-year-old man with AIDS.



**Fig. 219.** Kaposi's sarcoma on the upper alveolar mucosa presenting as a lobulated tumor in a 48-year-old heterosexual man with AIDS.



**Fig. 220.** Extensive Kaposi's sarcoma on the palate and gingiva in a 42-year-old homosexual man with AIDS.

Later, solitary or multiple lobulated tumors with or without ulceration may be the most prominent clinical feature (Fig. 219, 220). Non-Hodgkin's lymphoma is the second most common malignancy in HIV infection. The incidence of NHL is rapidly increasing and is primarily found in intravenous drug abusers who are HIV-positive. The majority of lymphomas are of B-cell origin. Intraoral non-Hodgkin's lymphoma clinically presents as inflammatory swellings, ulcerative or not, usually involving the gingiva and the palate (Fig. 221). Oral squamous cell carcinomas and Hodgkin's disease with oral lesions (Fig. 222) are occasionally associated with AIDS; however, the prevalence rates and risks have not been established.

### Neurologic Disturbances

Neurologic disturbances are common during the course of HIV infection and may be classified into three groups: opportunistic CNS infections, tumors, and HIV-related diseases. Facial nerve palsy and trigeminal neuropathy are the most frequent neurologic disorders involving the craniofacial nerves in HIV-infected patients (Fig. 223).

Fig. 221. Non-Hodgkin's lymphoma on the retromolar area in a 36-year-old homosexual man with AIDS.

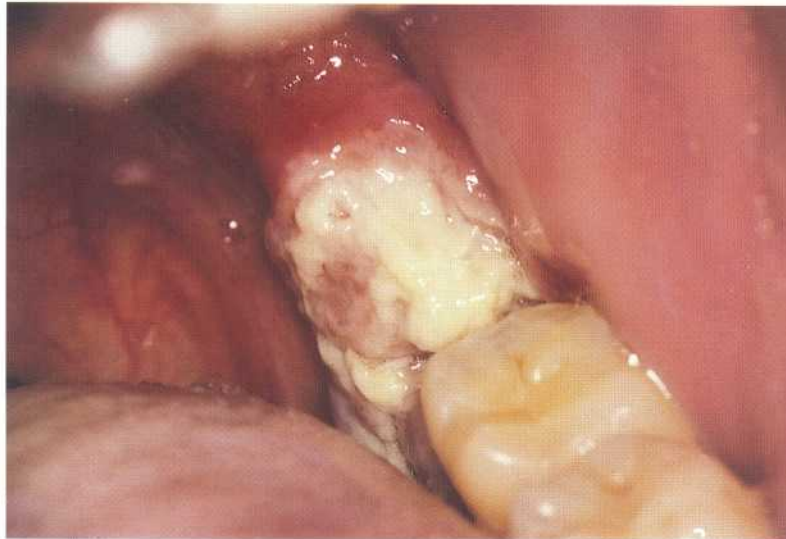


Fig. 222. Hodgkin's disease presenting as an ulcerative inflammatory gingival swelling in a 42-year-old homosexual man with AIDS.

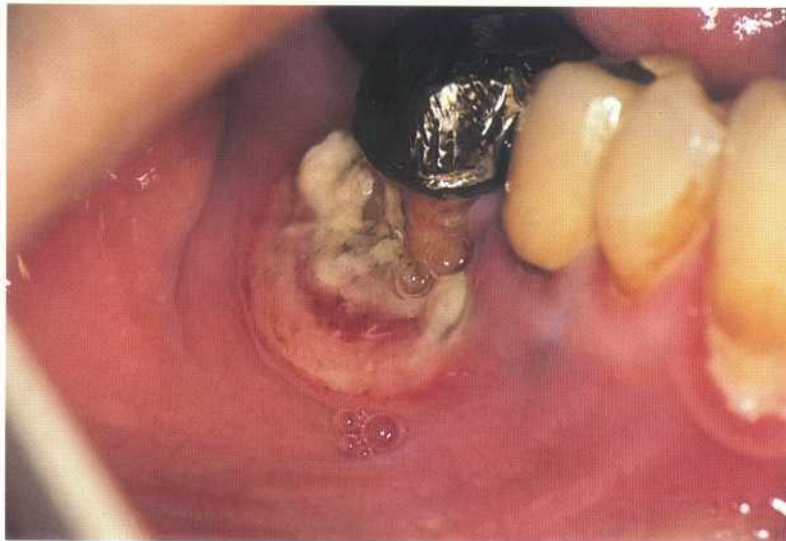
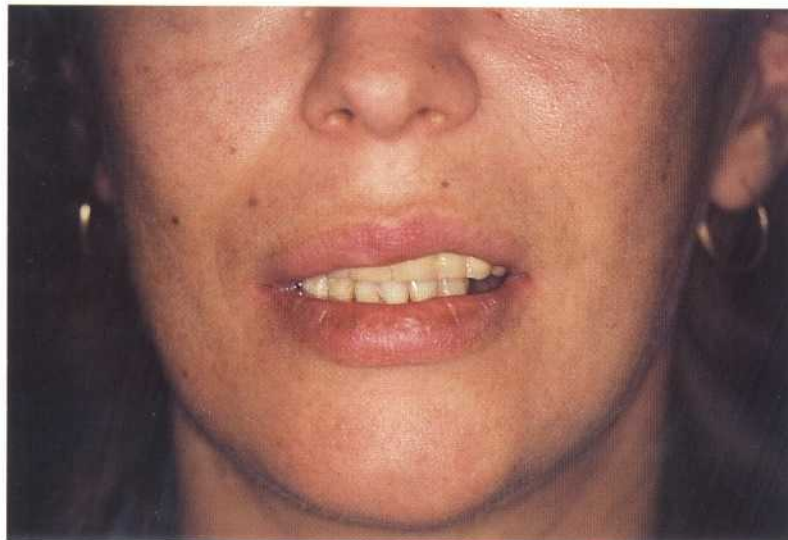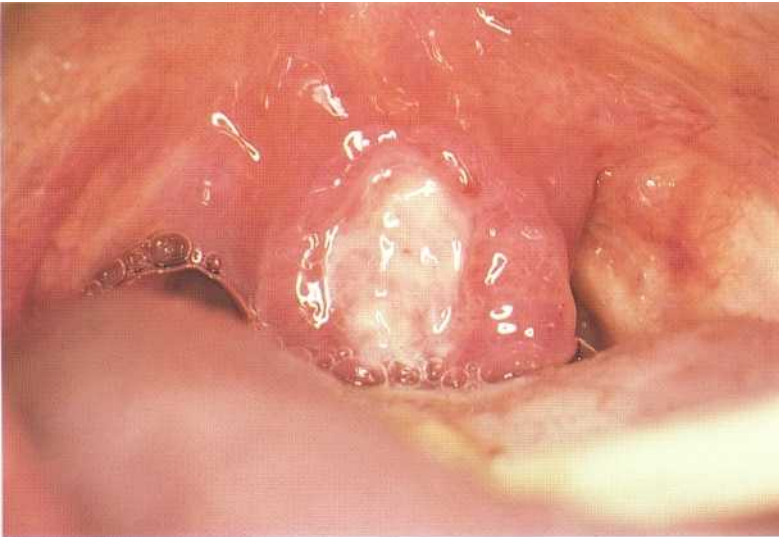


Fig. 223. Facial nerve palsy in a 30-year-old woman with AIDS.





**Fig. 224.** HIV infection, major aphthous ulceration on the uvula.

### Lesions of Unknown Cause

A large number of lesions or diseases are included in this group. The most common of them are: recurrent aphthous ulcers (minor, major, and herpetiform types) (Fig. 224), ulcerations not otherwise specified (Fig. 225), drug reactions (ulcerative, erythema multiforme; lichenoid, toxic epidermolysis) (Fig. 226), thrombocytopenic purpura (Fig. 227), salivary gland disease (bilateral or unilateral swelling of major salivary glands; dry mouth), melanotic hyperpigmentation, Reiter's syndrome, hairy tongue, exfoliative cheilitis, patchy depapillated tongue, and some others.

In 1990 and 1992 an EC-Clearinghouse working group on oral problems related to HIV infection together with the WHO, collaborating center on oral manifestations of the immunodeficiency virus proposed a classification of oral lesions of HIV infection into three main groups: lesions strongly associated with HIV infection, lesions less commonly associated with HIV infection, and lesions possibly associated with HIV infection.

The oral lesions strongly associated with HIV infection are candidosis, hairy leukoplakia, periodontal disease, Kaposi's sarcoma, and non-Hodgkin's lymphoma.

Laboratory tests. The most widely used are the enzyme-linked immunosorbent assay (ELISA), Western blot, and immunofluorescence tests.

Treatment. Current management of HIV infection involves the use of anti-retroviral drugs (AZT, DDI, DDC), and immune modulators. Antibiotics for secondary infections, chemotherapy, and interferon for neoplasms are used. The treatment of oral lesions is symptomatic or etiologic, topical, and/or systemic. Management of HIV infection requires a team approach and collaboration with the appropriate responsible physicians and other health care workers.

Fig. 225. HIV infection, persistent and extensive not otherwise specified ulcerations on the palate in a 35-year-old bisexual man with AIDS.

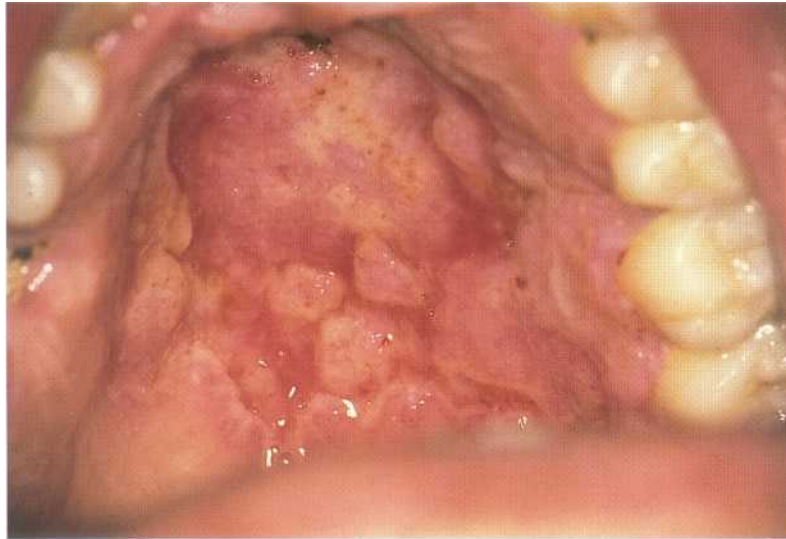
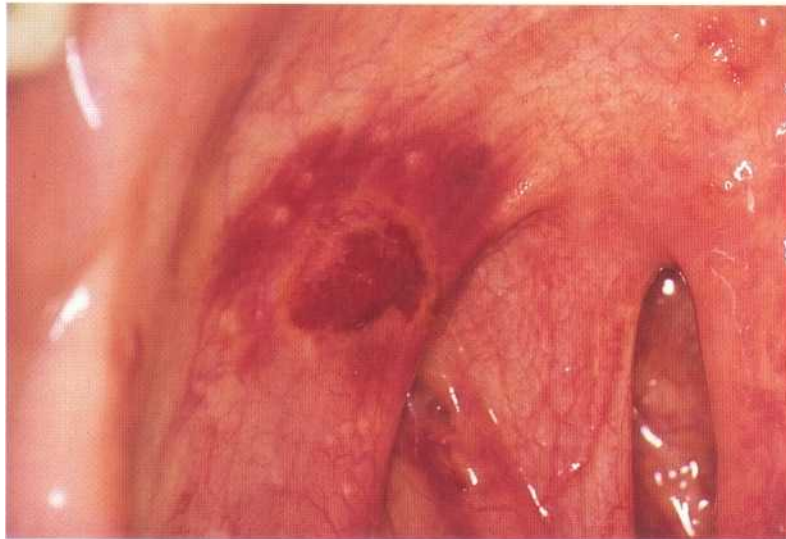


Fig. 226. HIV infection, erythema multiforme, as a drug reaction in a 45-year-old homosexual man with AIDS and pneumocystis carinii pneumonia.

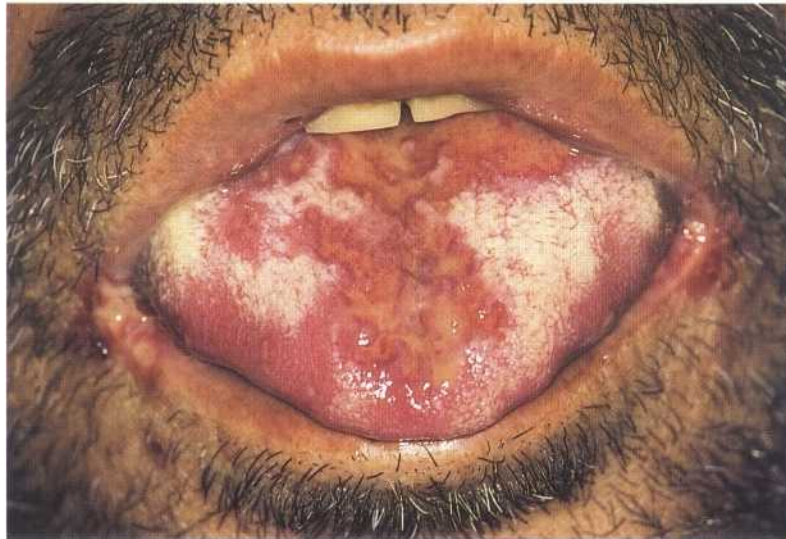

Fig. 227. HIV infection, ecchymosis on the soft palate as a manifestation of thrombocytopenic purpura in a 30-year-old homosexual man.





## 17. Bacterial Infections

### Necrotizing Ulcerative Gingivitis

Necrotizing ulcerative gingivitis chiefly affects young persons. Although the precise causative agents are unknown, *fusiform bacillus*, *Borrelia vincentii*, and other anaerobic microorganisms seem to play an important role. In addition, host factors, such as emotional stress, tobacco use, poor oral hygiene, and local trauma, have been implicated as predisposing factors. Interestingly, necrotizing ulcerative gingivitis has been observed among HIV-infected patients. The onset of the disease is either sudden or insidious, and it is clinically characterized by ulceration and necrosis of the interdental papillae and the free margins of the gingiva, which are covered with a dirty yellow-grayish smear (Fig. 228). The gingiva is fiery red, swollen, and extremely painful. The characteristic clinical feature is necrosis of the gingival margins and interdental papillae and the formation of a crater. Spontaneous hemorrhage, intense salivation, and halitosis are common. The disease is usually accompanied by regional lymphadenopathy, fever, and malaise. The lesions may be localized or generalized. The diagnosis may be established on clinical grounds alone.

The differential diagnosis includes primary herpetic gingivostomatitis, streptococcal gingivostomatitis, scurvy, leukemia, and agranulocytosis.

**Laboratory test.** Smear and histopathologic examination may sometimes be helpful.

**Treatment.** In the acute phase metronidazole or antibiotics active against anaerobic bacteria are beneficial. Mouthwashes with oxygen-releasing compounds may also be used. Management of the underlying gingivitis must follow the acute phase.

### Necrotizing Ulcerative Stomatitis

Necrotizing ulcerative gingivitis may on occasion extend beyond the gingiva and involve other areas of the oral mucosa, usually the buccal mucosa opposite the third molar. Rarely, it may involve the tongue, lips, and palate. Necrotizing ulcerative stomatitis can be a manifestation of HIV infection, but rarely appears in non-HIV-infected patients. Clinically, the oral mucosa is red, ulcerated, with irregular margins, and may be covered with a dirty white-grayish smear (Fig. 229). In these cases the subjective complaints and objective general phenomena may be more intense.

### Cancrum Oris

Cancrum oris, or noma, is a rare but very serious destructive disease usually involving the oral tissues. It more commonly affects children and rarely adults in Africa, Asia, and South America. It is extremely rare in Europe and North America. Vincent's spirochete is always present in the lesions. Predisposing factors include poor oral hygiene, severe protein malnutrition, parasitic diseases, diabetes mellitus, leukemia, and immune defects. Clinically, cancrum oris frequently starts as an ulcerative gingivitis that very soon spreads to the neighboring tissues. Gangrenous necrosis involves the cheeks, lips, and the underlying bone, producing catastrophic lesions of the face (Fig. 230). The gangrenous ulcers are covered with whitish-brown fibrin and debris. Salivation, halitosis, and fever are always present.

The differential diagnosis includes lethal midline granuloma, malignant tumors, leukemia, and agranulocytosis.

**Treatment.** Without treatment, the disease is frequently fatal. Antibiotics and a nutritious diet as soon as possible are important. Surgical removal of the destructed tissues is also indicated.

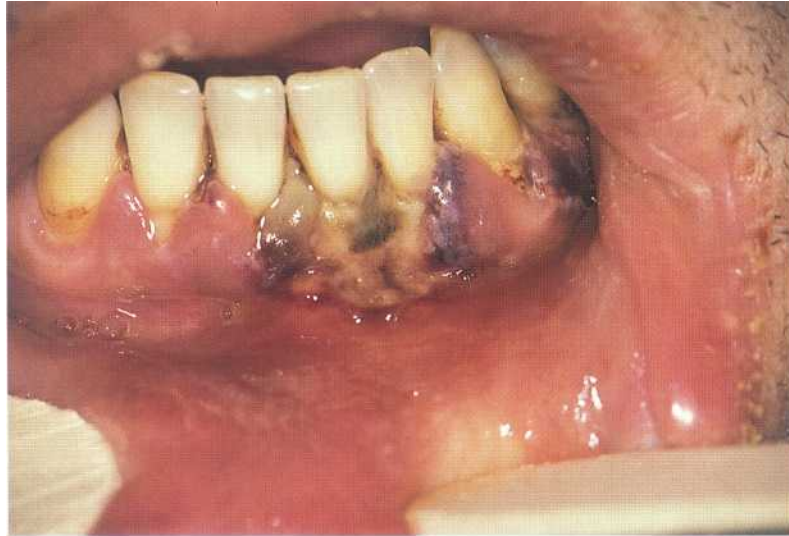

Fig. 228. Necrotizing ulcerative gingivitis.

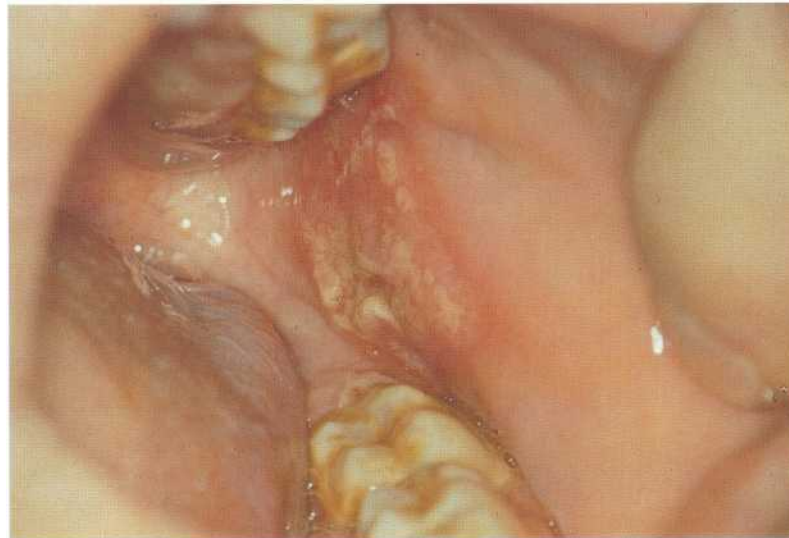


Fig. 229. Necrotizing ulcerative stomatitis, irregular ulcer on the buccal mucosa.

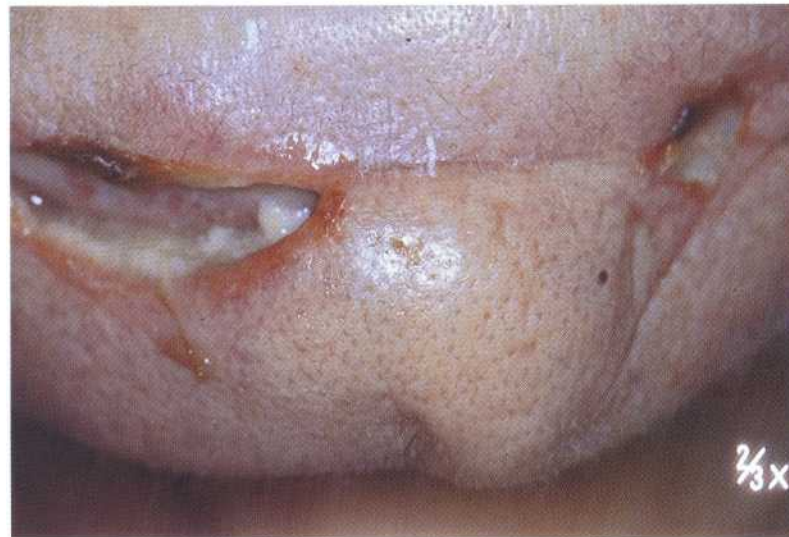

Fig. 230. Cancrum oris (noma), destructive necrosis of oral and facial tissues.

### Streptococcal Gingivostomatitis

Streptococcal gingivostomatitis is a debatable disease caused by B-hemolytic *Streptococcus*. It is a rare entity and the etiologic role of streptococci is controversial because it is not clear whether streptococcal infection is the primary cause or whether it represents a secondary infection of preexisting lesions. The disease is usually localized on the gingiva and rarely in other oral areas (Fig. 231). Frequently, the oral lesions follow a tonsillitis or upper respiratory infection and are manifested by redness, edema of the gingiva, and patchy superficial, round, or linear erosions covered with a white-yellowish smear. The interdental papillae remain intact. The disease is localized and rarely involves the entire gingival tissues. Mild fever and submandibular lymphadenopathy are also present.

The differential diagnosis includes herpetic gingivostomatitis and necrotizing ulcerative gingivitis.

Laboratory test. Gram's stain and isolation of streptococci may confirm the diagnosis.

Treatment consists of oral antibiotics, such as penicillin, ampicillin, and erythromycin.

### Erysipelas

Erysipelas is an acute skin bacterial infection due nearly always to group A streptococci. The sites of predilection are the lower extremities and the face. The oral mucosa is not involved. However, in cases of facial erysipelas the redness and edema may extend to the vermilion border and the lip mucosa (Fig. 232). Clinically, erysipelas is characterized by a shiny, hot, edematous, bright red, and slightly elevated plaque that is sharply demarcated from the surrounding healthy skin and may show small vesicles. The disease may recur and cause permanent edema of the lips. Fever, chills, malaise, and headache may accompany the skin lesions. The diagnosis is made on clinical grounds.

The differential diagnosis includes herpes zoster, angioneurotic edema, and contact dermatitis.

Treatment. Oral antibiotics, especially penicillin or erythromycin, are indicated.

### Scarlet Fever

Scarlet fever, or scarlatina, is an acute infection, caused by group A streptococci, which produce erythrogenic toxin. It is usually a disease of childhood. After an incubation period of 2 to 4 days, there is pharyngitis, fever, chills, headache, malaise, vomiting, nausea, and lymphadenopathy. The rash, which appears 1 to 2 days after the onset of pharyngitis, is characterized by a diffuse punctate erythema giving a rough sandpaper appearance to the skin. It first appears on the upper trunk and quickly spreads within 2 to 3 days. The face is infrequently involved, with few papules and a characteristic perioral pallor. The oral mucosa is red, edematous, and the tongue may be covered by a thick white coating (Fig. 233). Later, hypertrophy of the fungiform papillae follows, giving the tongue a characteristic "strawberry" appearance. The diagnosis is usually made on clinical grounds.

The differential diagnosis includes infectious mononucleosis, drug reactions, scarlatiniform eruption, and Kawasaki's disease.

Laboratory test. The isolation of group A Streptococci confirms the diagnosis.

Treatment. Penicillin or erythromycin is indicated, but therapy is best left to the pediatrician.

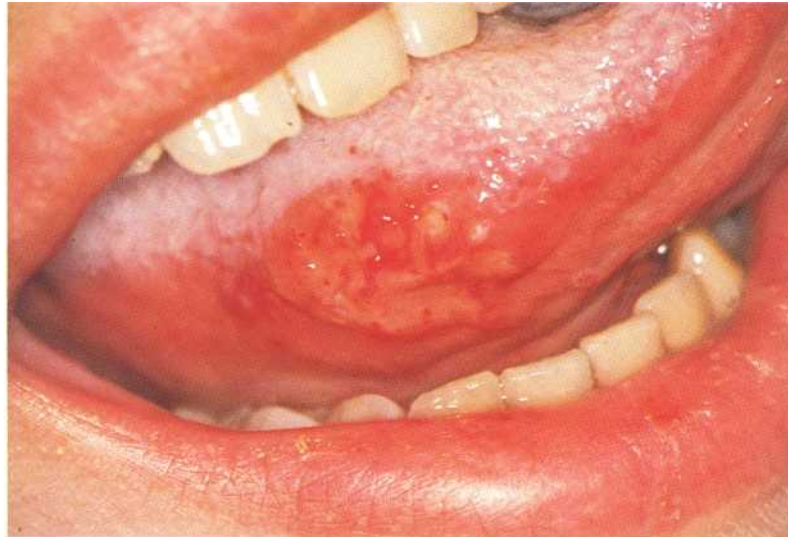

Fig. 231. Streptococcal gingivostomatitis, localized ulcers on the tongue.

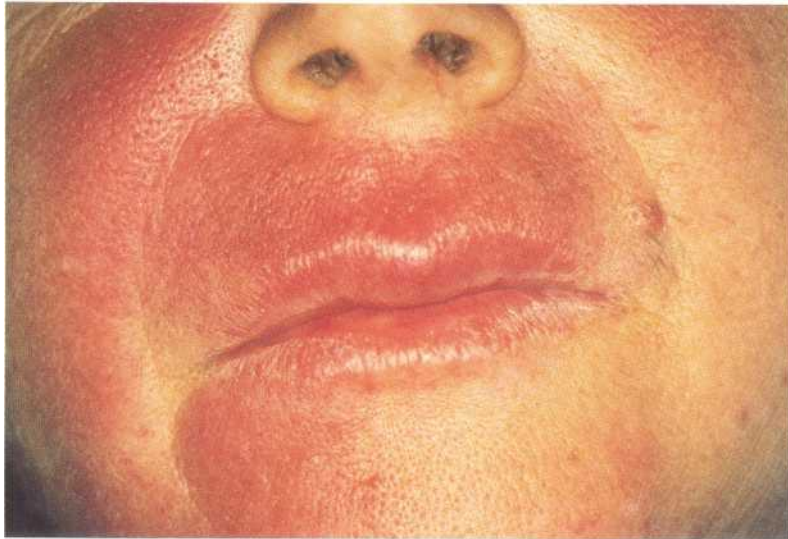

Fig. 232. Erysipelas.

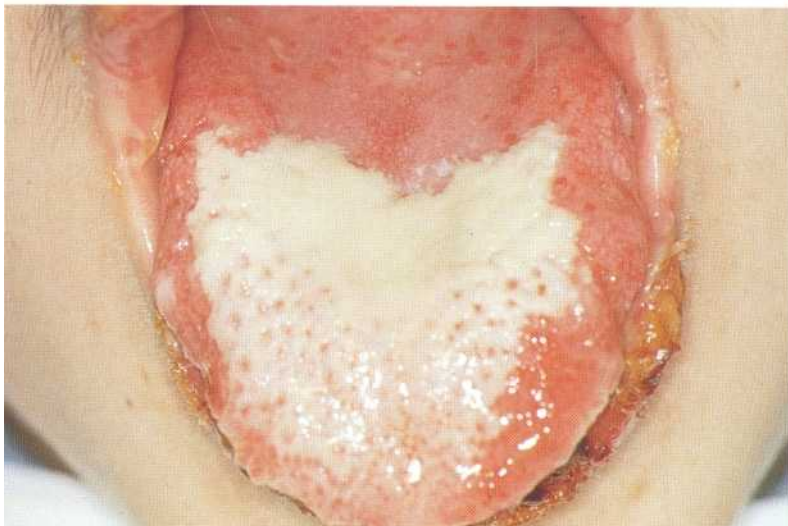

Fig. 233. Scarlet fever, red and edematous tongue, partially covered by a thick white coating.

### Oral Soft-Tissue Abscess

Acute abscess of the oral soft tissues of nondental origin is uncommon. Usually, infectious micro-

organism, such as *Staphylococcus aureus*, *B-hemo-lytic Streptococcus*, and rarely other microorganisms, are responsible.

The origin of the infection is usually difficult to establish. Low local or general resistance to infection is an important predisposing factor. Clinically, oral soft-tissue abscess presents as an acute or subacute, ill-defined, painful swelling usually localized on the tongue and the buccal mucosa (Fig. 234).

The differential diagnosis includes actinomycosis and benign tumors.

Laboratory tests to confirm the diagnosis are bacterial cultures and histopathologic examination.

Treatment with appropriate antibiotics and surgical incision and drainage are indicated.

### Peritonsillar Abscess

Peritonsillar abscess is usually a complication of recurrent tonsillar infection mainly due to *Streptococcus pyogenes* and oral anaerobic bacteria and rarely to other Gram-positive or negative microorganisms. Clinically it appears as a large soft swelling of the tonsil and the adjacent area, with redness and pus draining at the late stage (Fig. 235). Pain, fever, dysphagia, and cervical lymph node enlargement are always present.

The differential diagnosis includes tuberculosis, actinomycosis, systemic mycoses, syphilis, eosinophilic ulcer, lymphomas, and Hodgkin's disease.

Laboratory test. Microbiologic examination confirms the diagnosis.

Treatment. Penicillin and cephalosporins are usually effective. Needle aspiration is also helpful.

### Acute Suppurative Parotitis

Acute suppurative infection of the parotid glands is usually unilateral and most frequently appears in patients more than 60 years of age, although it may also occur during childhood. *Staphylococcus aureus*, *Streptococcus viridans*, and other bacteria of the oral flora are usually responsible for the infection, which may be hematogenous or spread by the bacteria via the ducts.

Clinically, the disease is characterized by induration, tenderness, and painful swelling of the parotid gland. Stenson's papilla is inflamed and pus may be discharged from the duct opening, particularly after pressure on the parotid gland (Fig. 236). Low-grade fever and weakness may be present.

The differential diagnosis includes obstructive parotitis, mumps, chronic specific infections, Sjogren's syndrome, Heerfordt's syndrome, leukemia, lymphomas, and neoplasms of the parotid glands.

Laboratory test helpful in establishing the diagnosis is bacterial culture.

Treatment consists of appropriate antibiotic administration.

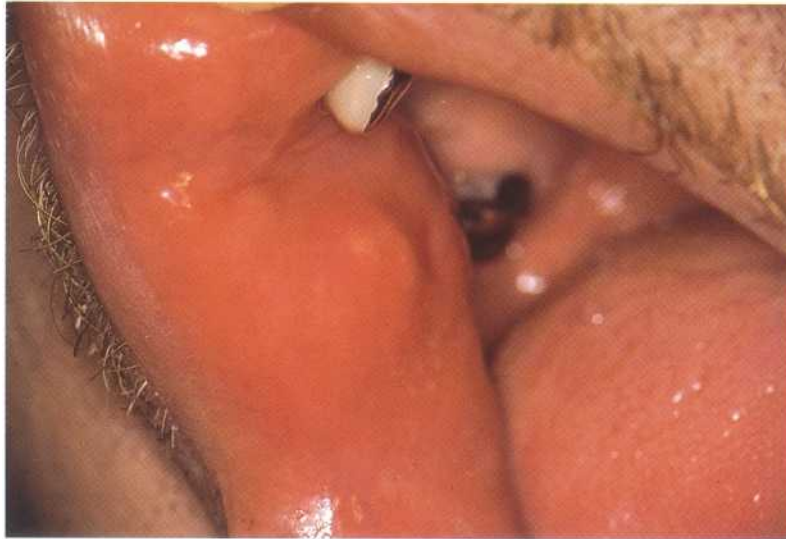

Fig. 234. Acute abscess in the buccal mucosa.

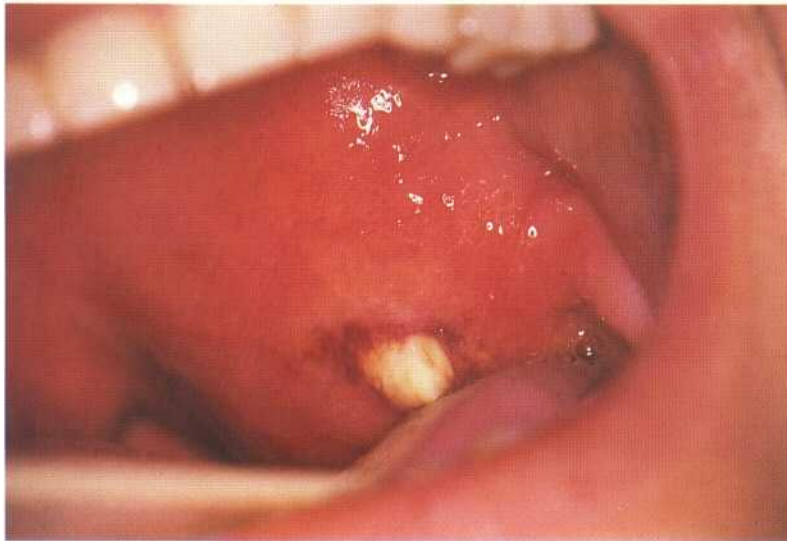


Fig. 235. Peritonsillar abscess, swelling and redness of the tonsillar area.

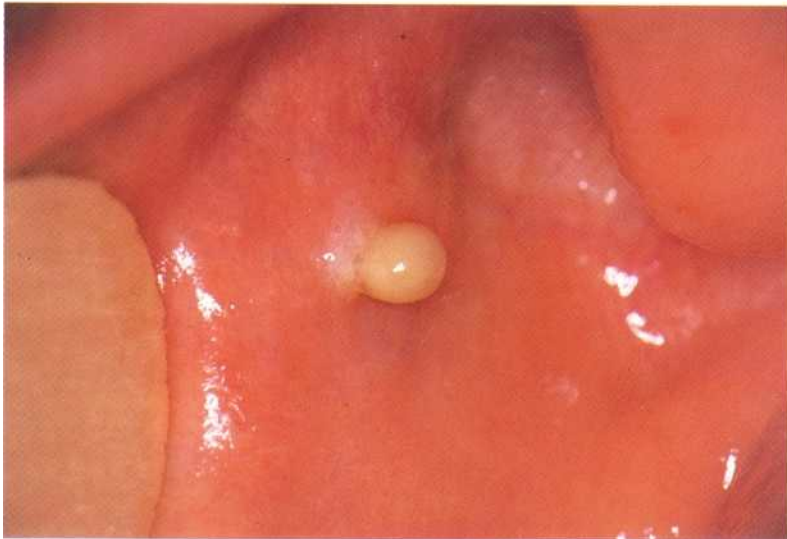

Fig. 236. Acute suppurative parotitis, pus discharge from the parotid duct opening.

**Acute Submandibular Sialadenitis**

Acute suppurative infection of the submandibular gland is relatively rare compared with the frequency of analogous infections of the parotid gland. *Staphylococcus aureus*, *Staphylococcus pyogenes*, *Streptococcus viridans*, and other bacteria of the oral flora are usually responsible. The microorganisms may reach the submandibular gland, either through the gland duct or the bloodstream. Clinically, it presents as a painful swelling, usually unilateral, associated with tenderness and induration of the area under the angle and the body of the mandible (Fig. 237). The skin overlying the swelling may be red and tense. Intraorally, inflammation of the orifice of the duct is a common finding.

The differential diagnosis includes mumps, post-operative sialadenitis, Mikulicz's, Sjogren's, and Heerfordt's syndromes, submandibular lymph node enlargement, Hodgkin's disease, and non-Hodgkin's lymphomas.

Laboratory tests are not particularly helpful.

Treatment with antibiotics is appropriate.

**Buccal Cellulitis**

Cellulitis is a common cutaneous inflammation characterized by diffuse involvement of the soft tissues due to infection. A thin, watery exudate spreads through the cleavage planes of the interstitial tissue spaces. The predominant infectious organisms are *Staphylococcus aureus*, *B-hemolytic Streptococci*, and less frequently *Gram-negative* and anaerobic microorganisms.

Cellulitis due to *Hemophilus influenzae* type B occurs commonly in the buccal soft tissues of infants. Facial cellulitis may result after a dental infection. Clinically, buccal cellulitis has a variable onset and presents as a diffuse, firm, ill-defined erythematous swelling associated with warmth and pain (Fig. 238). The overlying skin shows a deep purplish discoloration. Moderate to severe pyrexia is common.

The differential diagnosis includes erysipelas, acute parotitis, angioneurotic edema, insect bites, and trauma.

Laboratory tests helpful to establish the diagnosis are blood cultures, needle aspiration, or rarely, biopsy.

Treatment. Treatment with antibiotics is necessary. Surgical incision and drainage is indicated if antibiotic therapy is unsuccessful.

**Klebsiella Infections**

*Klebsiella pneumoniae* is a Gram-negative bacillus found among the normal oral flora and gastrointestinal tract. Respiratory and urinary tracts are the systems mainly involved while other anatomic areas are rarely infected. Predisposing factors for the infection are diabetes mellitus, immunosuppression, and treatment with antibiotics to which *Klebsiella* is resistant.

*Klebsiella* infection of the oral cavity is a very rare phenomenon which may occur in patients undergoing cancer chemotherapy and those with diabetes mellitus or HIV infection. Clinically, the oral lesion appears as an abnormally deep ulcer with a necrotic center covered by a thick brown-whitish pseudomembrane (Fig. 239).

The differential diagnosis includes eosinophilic ulcer, ulcerative stomatitis, syphilis, tuberculosis, and systemic mycoses.

Laboratory test. Microbial isolation of the organism establishes the diagnosis.

Treatment. Second- and third-generation cephalosporins and aminoglycosides are effective.

Fig. 237. Acute submandibular sialadenitis, swelling under the angle and the body of the mandible.

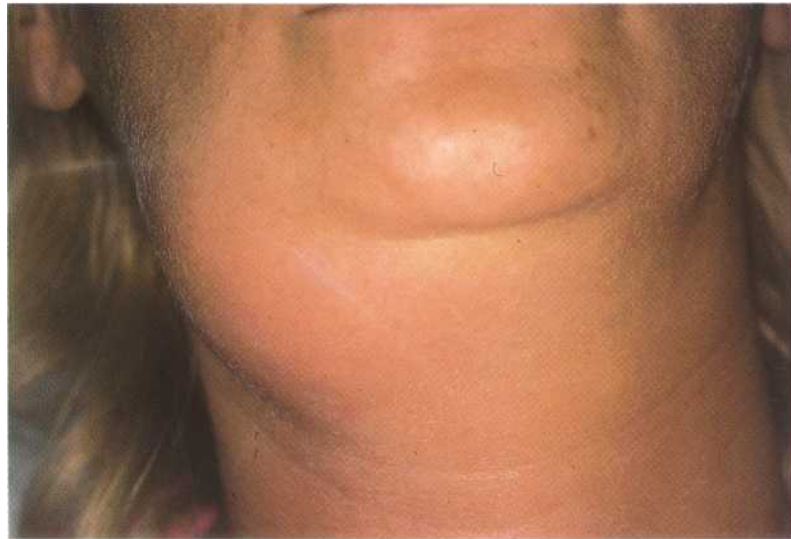
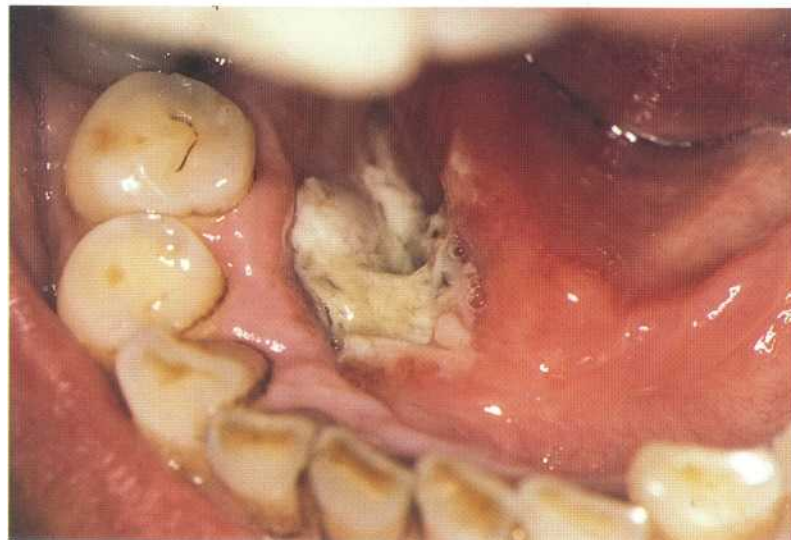


Fig. 238. Buccal cellulitis, ill-defined erythematous swelling on the skin of the face of a 2-year-old girl.

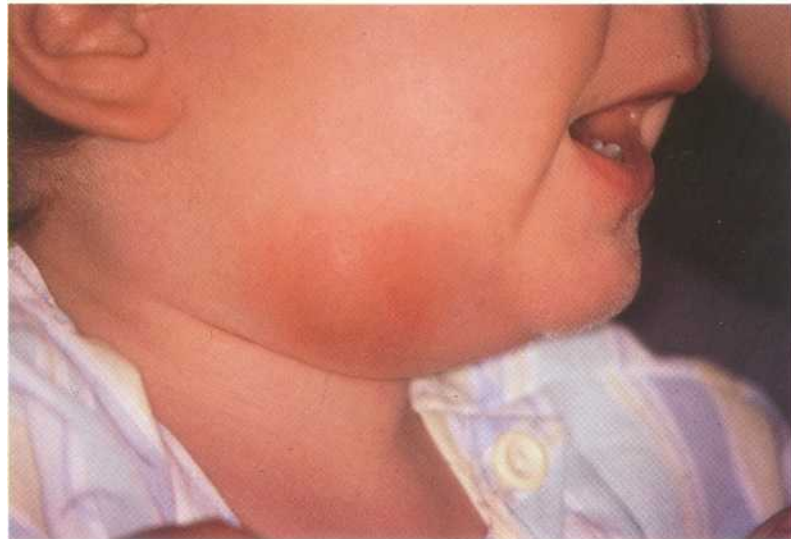

Fig. 239. *Klebsiella* infections, deep ulcer covered by a thick brown-whitish pseudomembrane.





## Pseudomonas Infections

Several strains of *Pseudomonas* have been identified the most common strain being *P. aeruginosa*. *Pseudomonas aeruginosa* is an opportunistic pathogen infecting mostly individuals with defect immunity while rarely causing disease in healthy individuals. Predisposing disorders to *Pseudomonas* infection are cystic fibrosis, glycogen storage disease type Ib, congenital and other types of neutropenias, leukemias, premature infants, and old-age debilitated patients, particularly following antibiotic treatment in the nosocomial environment. The skin and subcutaneous tissues, paranasal sinuses, ear, eye, lung, and urinary tract are usually involved.

Rarely oral, perioral, and lip infection may occur. Clinically it presents as an inflammatory necrotic ulceration with a tendency to expand to surrounding tissue. After healing, scar formation may be seen (Fig. 240).

The differential diagnosis includes tuberculosis and other infections.

Laboratory test. Isolation of microorganism confirms the diagnosis.

Treatment. Polymyxin and colistin for topical use. Systemic specific antibiotics are best left to the specialist.

## Syphilis

Syphilis is a venereal disease caused by *Treponema pallidum*.

Acquired syphilis is most often transmitted through sexual intercourse, but rarely nonvenereal transmission may occur. Placental transmission of *T. pallidum* from an infected mother to fetus causes congenital syphilis.

The modern classification of syphilis is based on epidemiologic, clinical, and therapeutic criteria, as follows: early syphilis, which includes primary and secondary stages and clinical relapses due to incomplete treatment and lasts less than 1 year; latent syphilis, which is subclassified into early stage (lasts less than 2 years) and late stage (lasts 2 years or more); and late syphilis, which includes tertiary syphilis, that is, gumma, central nervous system, and cardiovascular manifestations, and lasts 5 or more years.

## Primary Syphilis

The primary lesion of acquired syphilis is the chancre. It is usually localized on the genitalia, but in about 10 % of the cases the chancre occurs extragenitally (anus, rectum, fingers, nipples, etc.) and especially in the oral cavity. Direct orogenital contact (fellatio or cunnilingus) is the usual mode of transmission of an oral chancre, but kissing may also be responsible if one of the partners has infectious oral lesions.

After an incubation period of 10 to 90 days (average, 21 days), the chancre appears at the site of inoculation.

In males, most chancres tend to appear on the upper lip, and in females, on the lower lip. The tongue is the next most frequent site of involvement, followed by the palate and tonsillar areas. Clinically, the chancre begins as an inflammatory papule that soon erodes. The classic chancre appears as a painless ulcer with a smooth surface, raised border, and indurated base. It is often surrounded by a narrow red border and is covered by a grayish serous exudate teeming with *T. pallidum* (Figs. 241, 242).

The chancre is usually solitary, although multiple lesions may appear simultaneously or in rapid succession. It varies in size from a few millimeters to 3 cm in diameter. A constant finding is the enlargement of the regional lymph nodes, which is usually unilateral, less often bilateral. The enlarged lymph nodes are discrete, mobile, hard, and nontender. Without treatment, the chancre heals spontaneously within 3 to 8 weeks.

The diagnosis of primary syphilis is based on the history, clinical features, and bacteriologic and serologic tests.

The differential diagnosis of oral chancre includes traumatic ulcer, aphthous ulcer, Behcet's disease, chancroid, tuberculous lesions, herpes simplex, infectious mononucleosis, and squamous cell carcinoma.

Laboratory tests include dark-field examination for *T. pallidum*. Serologic tests for syphilis must always be performed, but it should be remembered that, during the early primary phase, these tests may be negative.

Fig. 240. Pseudomonas infections, scar formation on the lower lip and the perioral skin after healing of a large ulceration in a 3-year-old boy with leukemia.

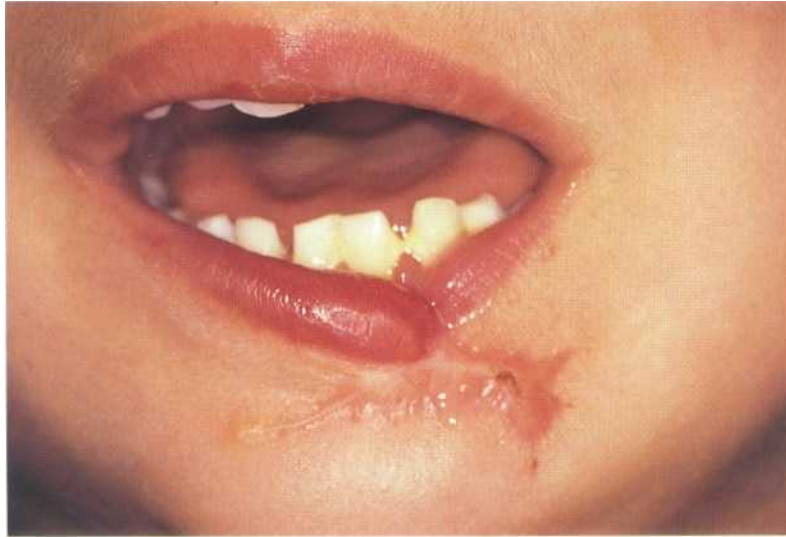

Fig. 241. Solitary chancre on the ventral surface of the tongue.

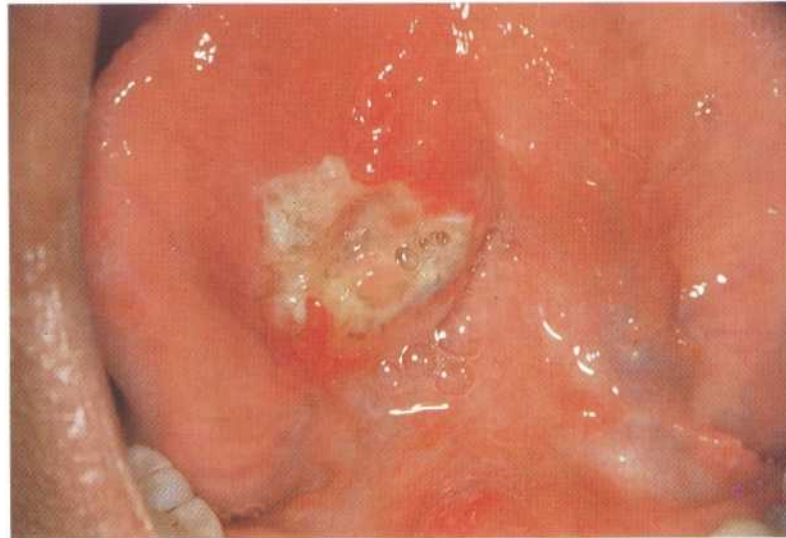
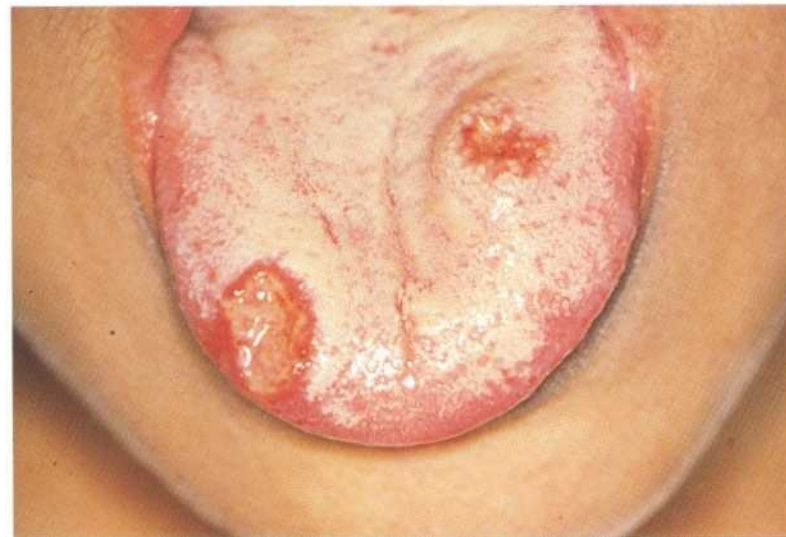
Fig. 242. Two chancres on the tongue.



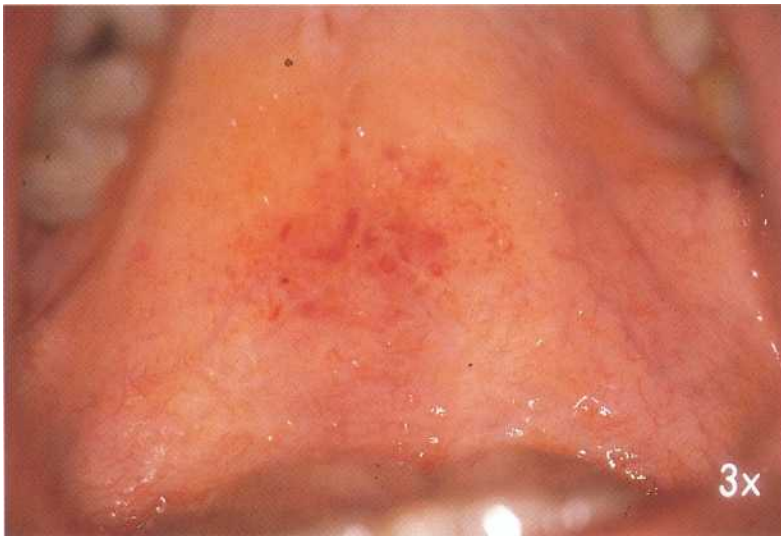

Fig. 243. Macular syphilides on the soft palate.

### Secondary Syphilis

The signs and symptoms of secondary syphilis begin 6 to 8 weeks after the appearance of the chancre, which may still be present at the time of initiation of this stage. The clinical features of secondary syphilis are classified in two major groups: constitutional symptoms and signs, and generalized mucocutaneous manifestations. The former may precede or accompany mucocutaneous lesions and include malaise, low-grade fever, headache, lacrimation, sore throat, loss of appetite, weight loss, polyarthralgias and myalgias, generalized lymphadenopathy, which is a classic and constant finding, along with splenomegaly. (The enlarged lymph nodes are painless, discrete, mobile, and hard-rubbery on palpation.) Generalized mucocutaneous manifestations include pruritus, nail involvement, macular, papular, pustular, nodular, follicular, and other lesions. Mucous membrane lesions are frequent and may appear alone or in association with skin lesions. The mucocutaneous lesions usually last 2 to 10 weeks and disappear without scarring.

### Macular Syphilides

Macular syphilides (roseolas) are the earliest manifestations of secondary syphilis; they remain for a few days and usually go unnoticed. In the oral mucosa macular syphilides are most frequently found in the soft palate (Fig. 243). Clinically, they appear as multiple red oval spots.

### Mucous Patches

Mucous patches are by far the most frequent oral manifestation of secondary syphilis. They are flat or slightly raised, painless, oval or round papules with erosions or superficial ulcers covered by a grayish-white membrane. They are teeming with spirochetes and extremely contagious. The lesions may be surrounded by a red halo and vary in size from 3 to 10 mm or more in diameter. Mucous patches tend to be arranged symmetrically; they are usually multiple and rarely occur as solitary lesions. They occur most frequently on the tongue, palate, tonsils, mucosal surface of the lips, commissures, buccal mucosa, gingiva, and the larynx (Figs. 244-246). On occasion, mucous patches may be the only manifestation of secondary syphilis for a long period of time.

The differential diagnosis includes candidosis, lichen planus, leukoplakia, aphthous ulcers, herpetic gingivostomatitis, erythema multiforme, trauma, and infectious mononucleosis.

**Laboratory test.** Dark-field examination and immunofluorescence for the detection of *T. pallidum* may be a helpful diagnostic tool. In addition serologic tests (VDRL, RPR, FTA-ABS, TPI, TPHA) are positive.

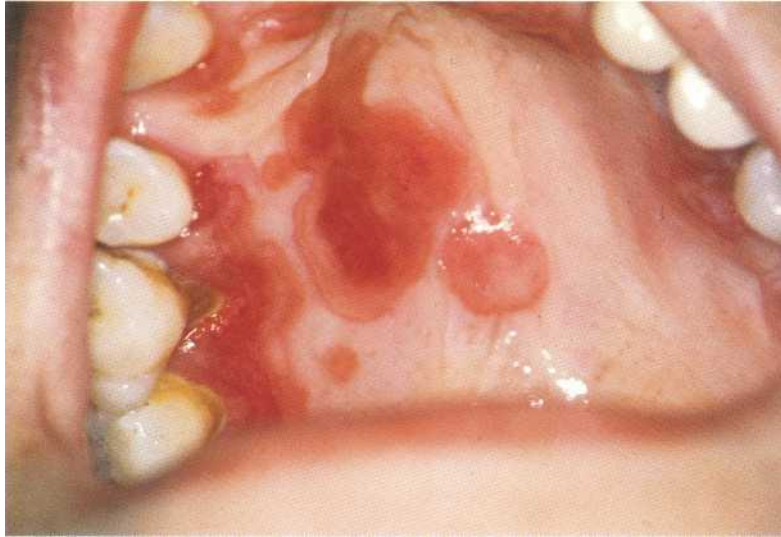


Fig. 244. Mucous patches on the palate and gingiva.

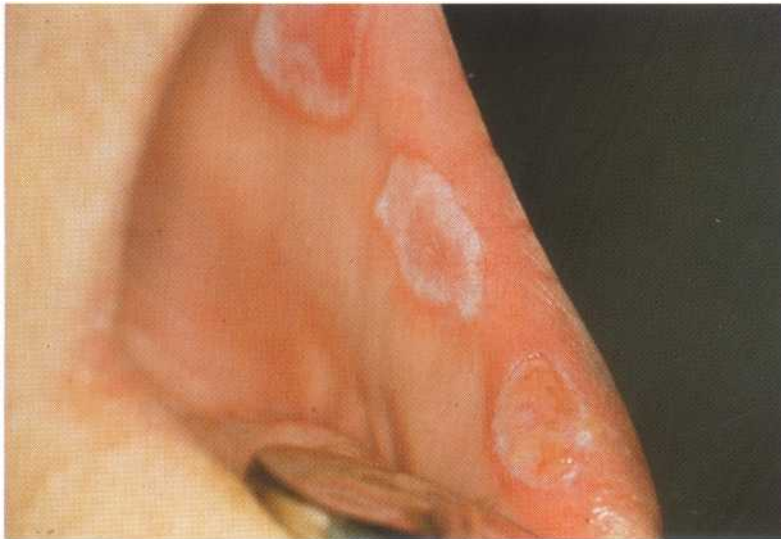

Fig. 245. Mucous patches on the buccal and lip mucosa.

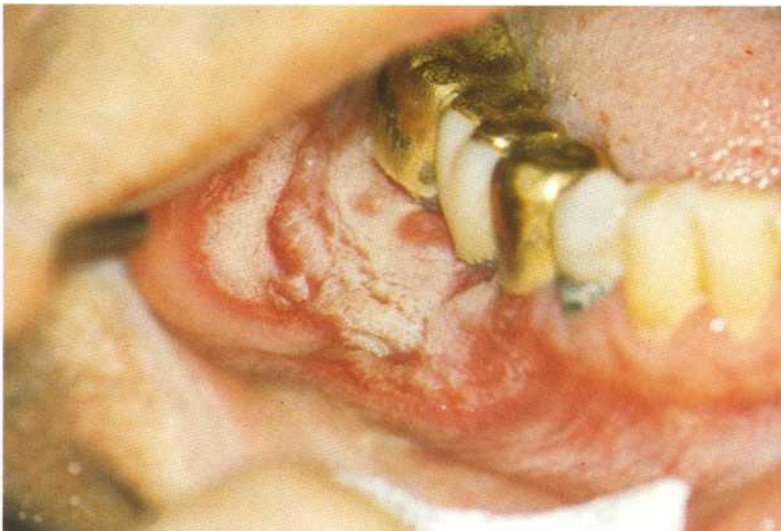
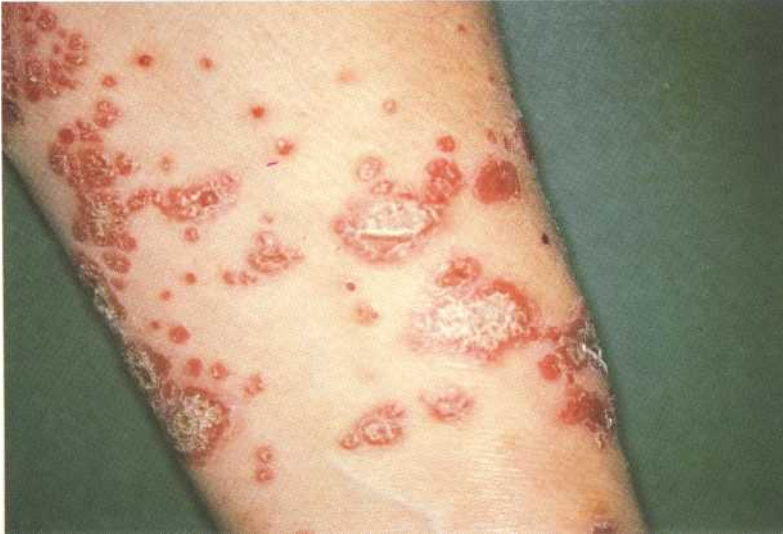
Fig. 246. Mucous patches on the gingiva and alveolar mucosa.



**Fig. 247. Papular syphilides on the skin.**

### **Papular Syphilides**

Papular syphilides are the most characteristic lesions of secondary syphilis, occurring frequently on the skin (Fig. 247) and rarely in the oral mucosa. The oral lesions usually coalesce, forming slightly raised, painless, firm, and round nodules with a grayish-white color (Fig. 248). The lesions have a tendency to ulcerate and are usually located on the commissures and buccal mucosa and rarely in other areas. Papular syphilides and mucous patches are always associated with bilateral regional lymphadenopathy.

### **Condylomata Lata**

In moistened skin areas, the eroded papular syphilides have the tendency to coalesce and to hypertrophy, forming elevated, vegetating, or papillomatous lesions, the condylomata lata. The most frequent localizations of condylomata lata are the perigenital-perianal area, axillae, sub-mammary, and umbilical areas. Condylomata lata rarely appear in the oral cavity, usually at the corners of the mouth and the palate (Fig. 249). They are painless, slightly exophytic, multiple lesions with an irregular surface and are contagious.

### **Late Syphilis**

After a latency period of 4 to 7 years or more, severe clinical manifestations of late syphilis may develop. The main manifestations of late syphilis are mucocutaneous lesions, cardiovascular lesions, and neurosyphilis. Late syphilis is now rare in many western countries. The oral lesions of late syphilis include gummas, atrophic glossitis, and interstitial glossitis.

### **Gumma**

Gumma is a syphilitic granulomatous lesion that originates as a subcutaneous mass secondarily extending both to the epithelium and the deeper tissues. Gumma appears initially as a painless elastic tumor that has a tendency to necrose, forming a characteristic stringy mass. A punched-out ulcer forms and finally heals, leaving a scar. The size varies from 1 to 10 cm. The sites of predilection are the legs, scalp, face, and chest. Gummas are frequently located on the hard palate, which they may destroy and perforate (Fig. 250). They may also involve the soft palate and rarely other oral regions.

The differential diagnosis includes carcinoma or other malignant tumors, leprosy, lethal midline granuloma, and lymphoma.

Fig. 248. Papular syphilides on the buccal mucosa.

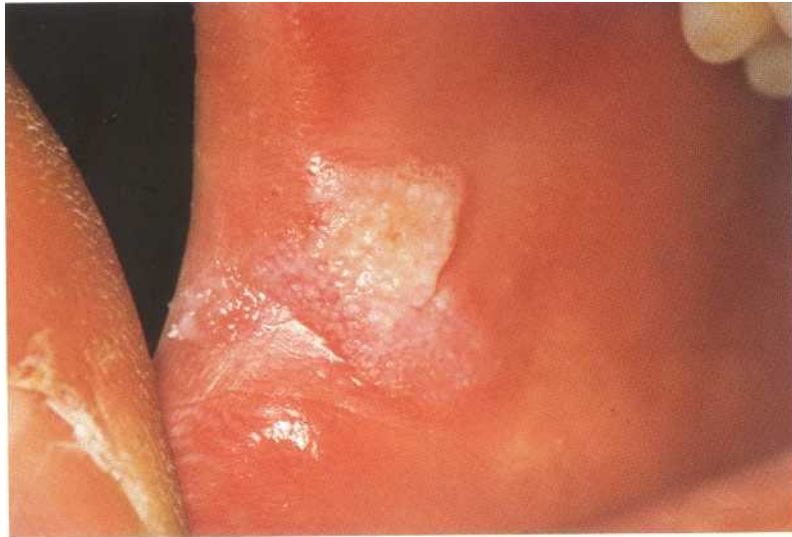

Fig. 249. Condylomata lata on the palate.

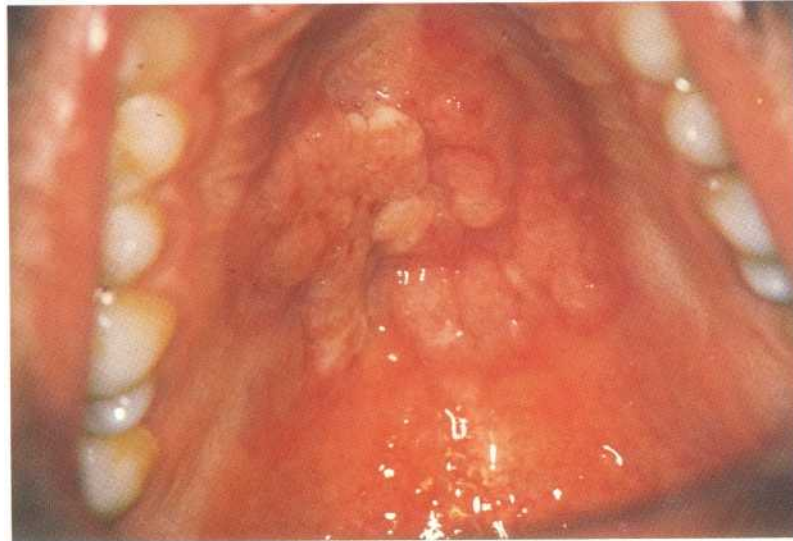
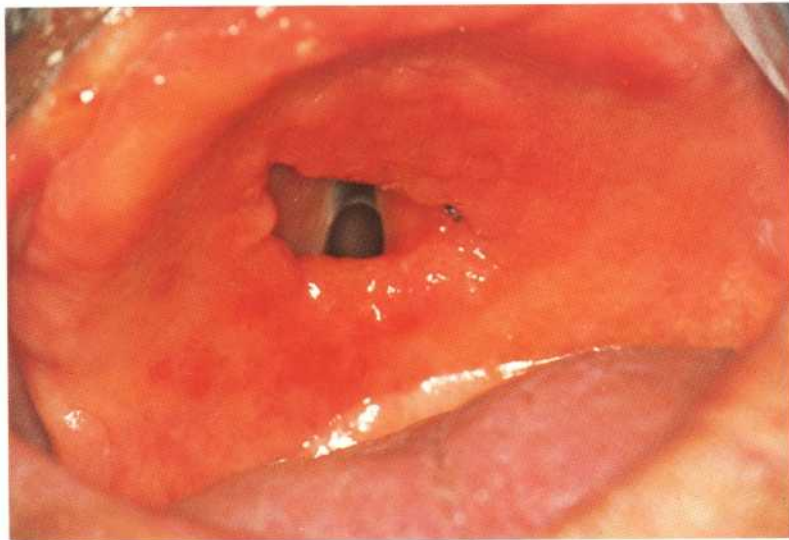


Fig. 250. Gumma, perforation of the hard palate.



### Atrophic Glossitis

The tongue is frequently involved in late syphilis. Clinically, there is atrophy of the filiform and fungiform papillae, and the dorsum becomes smooth and atrophic. Vasculitis finally ending in an obliterative endarteritis is the process underlying these changes.

Atrophic syphilitic glossitis may lead to the development of leukoplakia and squamous cell carcinoma (Fig. 251).

The differential diagnosis includes atrophic lichen planus and Plummer-Vinson syndrome.

### Interstitial Glossitis

Late syphilis of the tongue may occur either as a solitary gumma or most commonly as a diffuse gummatous infiltration, which heals spontaneously, leading to interstitial glossitis. This is the result of contracture of the lingual musculature after the healing of gummas. The tongue appears smoothly lobulated with irregular deep fissures (Fig. 252).

Leukoplakia and squamous cell carcinoma may develop.

**Treatment.** Penicillin is the treatment for all stages of syphilis. The schedules and dosages are internationally established and depend on the stage of the disease. If penicillin allergy exists, erythromycin or cephalosporins may be administered.

### Congenital Syphilis

Congenital (prenatal) syphilis is transmitted by the mother to the fetus in utero. It is classified as early if the disease manifests before age 2 years, late if it becomes apparent after age 2 years, and stigmata, which are developmental changes without active infection.

The most common stigmata are high-arched palate, short mandible, rhagades at the commissures, saddle nose, frontal bossing, Hutchinson's teeth, and dysplastic molars.

The dysplastic permanent incisors comprise, along with interstitial keratitis and eighth nerve deafness, the classic Hutchinson's triad, and they are the most common findings of congenital syphilis. Clinically, the upper central permanent incisors are widely spaced and shorter than the lateral incisors. They are conical or barrel-shaped and at the biting surfaces are usually smaller than at the gingival margins (Fig. 253). Notched biting surfaces may be present as a result of defective enamel. Similar changes may exist in the lateral incisors (although to a lesser degree), and the teeth may be irregularly spaced. The permanent first molars may be dysplastic (Moon's molars, Fournier's molars, mulberry molars). Usually the first lower molars are affected. Affected teeth are narrower on their occlusal surfaces and have supernumerary cusps.

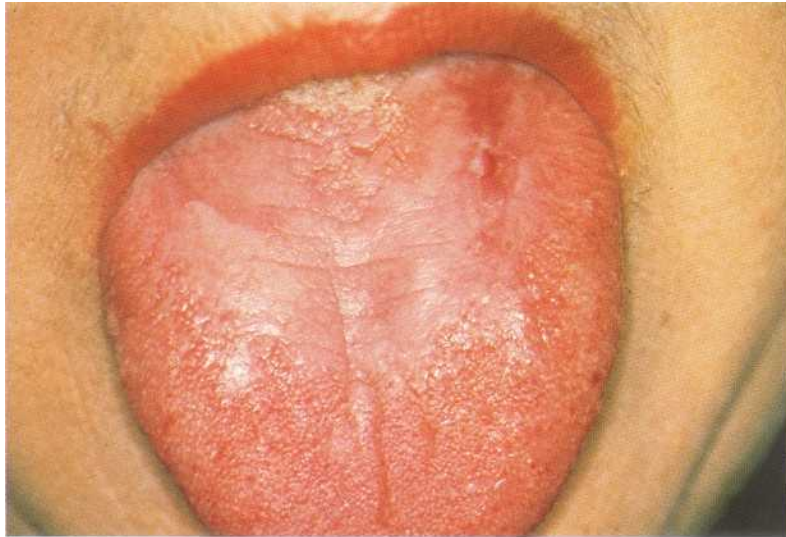

Fig. 251. Atrophic glossitis in late syphilis.

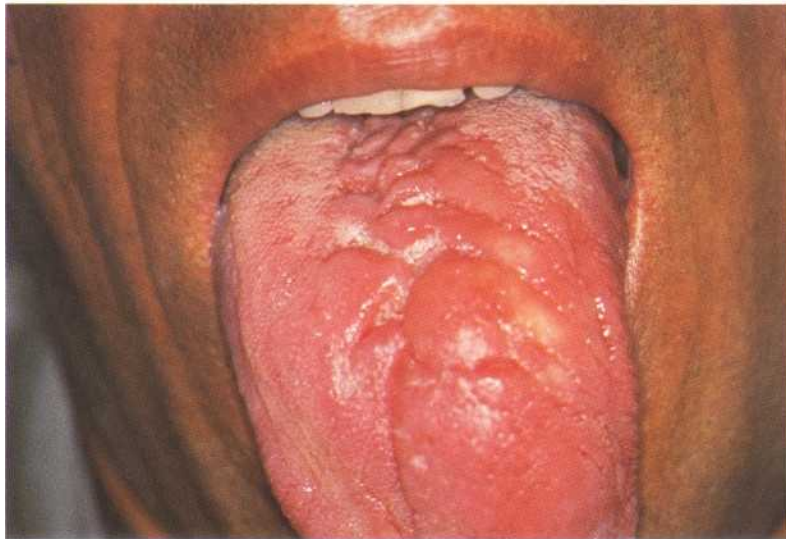

Fig. 252. Interstitial glossitis in late syphilis.

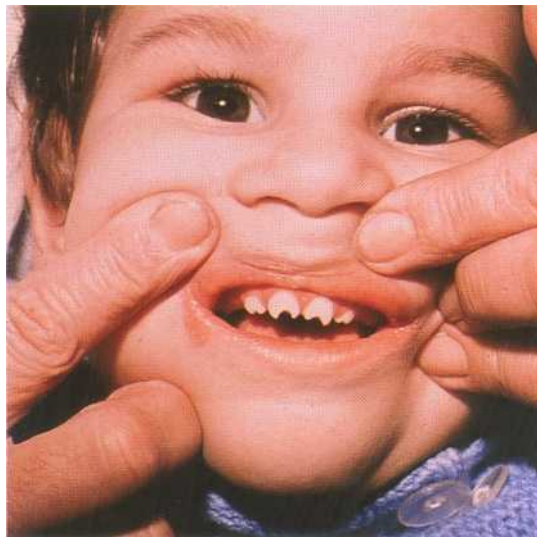

Fig. 253. Congenital syphilis, Hutchinson's teeth.



### Chancroid

Chancroid is an acute venereal disease caused by *Hemophilus ducreyi*, a Gram-negative bacillus. The disease is rare in Europe and the United States and occurs most frequently in underdeveloped countries, especially in communities with poor hygiene. The disease is usually sexually transmitted. Genital and perianal regions are most commonly affected. Oral lesions, which occur after orogenital contact, are extremely rare. After an incubation period of 2 to 5 days, the disease begins as a small red papule or macule that soon becomes pustular and finally ulcerates. The lesions of chancroid are not pathognomonic. The ulcer is round or oval, 1 mm to 2 cm in diameter with slightly raised border and a soft base (Fig. 254). It is covered with a gray-whitish exudate and is surrounded by a red halo. It is painful and usually accompanied by bilateral or unilateral lymphadenopathy.

The differential diagnosis includes aphthous ulcer, traumatic ulcer, primary and secondary syphilis.

Laboratory tests that are helpful in establishing the diagnosis include bacteriologic stains of smears and culture.

Treatment. Erythromycin is the drug of choice. In addition, the combination of sulfamethoxazole and trimethoprim or other antibiotics are effective.

### Gonococcal Stomatitis

Gonorrhea is a common venereal disease caused by the Gram-negative diplococcus *Neisseria gonorrhoeae*. It occurs at all ages and affects both sexes. Gonorrhea is sexually transmitted and involves the genitals, the anal canal, the pharynx, and rarely the oral cavity. Gonococcal stomatitis and pharyngitis are the result of fellatio and are more common in prostitutes and homosexual men. Gonococcal stomatitis is rare without specific clinical signs. The oral mucosa is red, inflamed, and the patient complains of itching and burning. Rarely, erosions and ulcers covered with a whitish pseudomembrane may occur (Fig. 255).

Gonococcal pharyngitis is more frequent and can be manifested as a sore throat or as a diffuse or patchy erythema and edema with or without tiny pustules on the tonsillar pillars and uvula. Notably, oral gonococcal infection may be asymptomatic.

The differential diagnosis includes streptococcal stomatitis, herpetic infection, and candidosis.

Laboratory identification of the organisms by Gram's stain or culture or immunofluorescent antibody techniques establish definitive diagnosis.

Treatment. Oral lesions are self-limited and colonization disappears within 3 months. Penicillin, tetracycline, amoxicillin, and ampicillin in different regimens may eradicate the disease.

### Tuberculosis

The oral mucosa is a rare location of tuberculous infection. The oral infection is usually secondary to pulmonary tuberculosis. The most common secondary lesion of the oral mucosa is the tuberculous ulcer. Clinically, the ulcer is painless and irregular, with a thin undermined border. The surface of the ulcer is vegetating and usually covered by a gray-yellowish exudate. The surrounding tissue is mildly indurated, with inflammation. The size varies from 1 to 5 cm. The dorsal surface of the tongue is most commonly affected, followed by the palate, buccal mucosa, and lips (Figs. 256, 257). Rarely, a tuberculous ulcer of the oral cavity may be the only manifestation of an otherwise silent tuberculosis. Tuberculous osteomyelitis of the jaws and periapical tuberculous granuloma may also occur. Regional lymphadenopathy usually accompanies the oral lesions. Tuberculosis of cervical lymph nodes may lead to

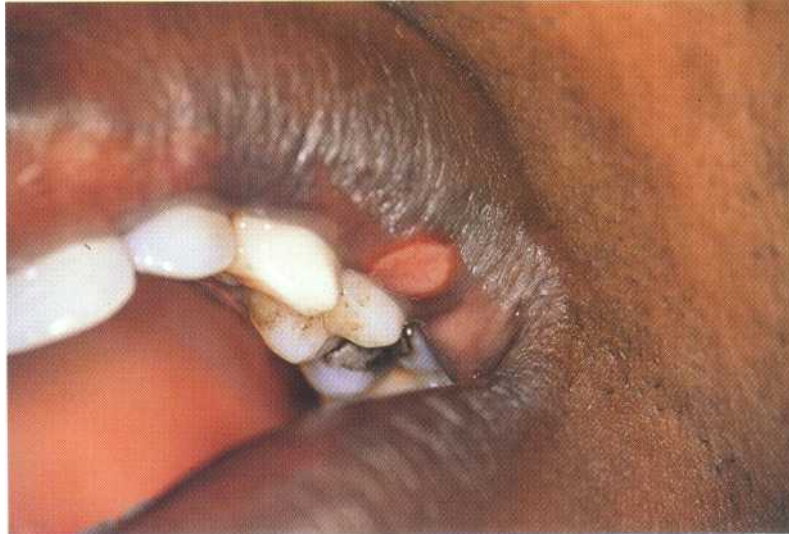

Fig. 254. Chancroid, round ulcer on the upper lip.

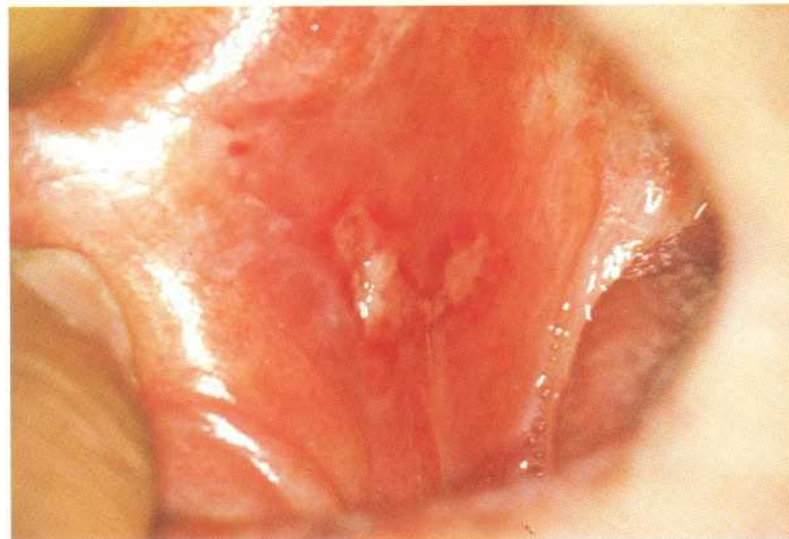

Fig. 255. Gonococcal stomatitis, erythema and erosions on the buccal mucosa.

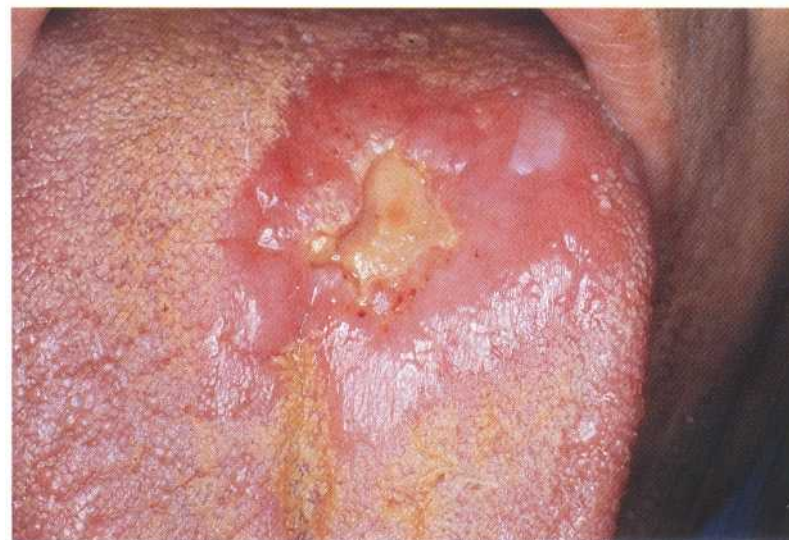

Fig. 256. Tuberculosis, typical ulcer on the dorsal surface of the tongue.

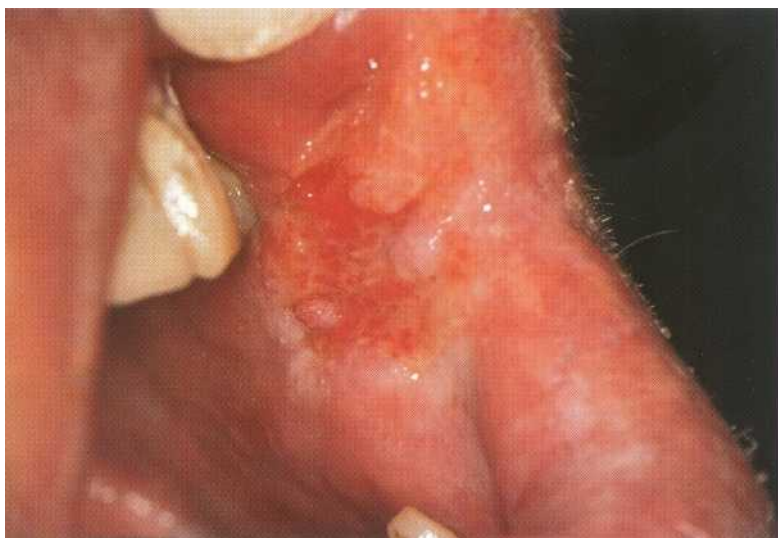

Fig. 257. Tuberculosis, large ulcer on the buccal mucosa.

scrofula, with breakdown of the skin overlying the infected lymph nodes, and multiple fistula formation (Fig. 258).

Clinicians should remember that tuberculosis occurs in an increasing proportion of patients with HIV infection. Almost half of AIDS patients with tuberculosis have extrapulmonary forms of the disease.

The differential diagnosis includes squamous cell carcinoma, syphilis, systemic mycoses, lymphoma, major aphthous ulcer, traumatic ulcer, Wegener's granulomatosis, lethal midline granuloma, actinomycosis and eosinophilic ulcer.

Laboratory tests for the diagnosis of tuberculosis are histopathologic examination, cultures, and a tuberculin skin test. Chest radiographs frequently reveal pulmonary tuberculosis.

Treatment. Therapy consists of systemic anti-tuberculous drugs and is best left to the specialist physician.

### Lupus Vulgaris

Lupus vulgaris is the most common form of secondary tuberculosis of the skin. It is usually observed in persons with a moderate or high degree of tuberculin sensitivity. The skin lesions usually appear most frequently on the head and neck, followed by the extremities. The oral mucosa is rarely affected, either through extension of facial lesions or through lymphatic or hematogenous spread. Clinically, oral lesions begin as a collection of small red nodules that

rapidly coalesce and become necrotic, forming large, irregular vegetating, granulating, or ulcerating lesions (Fig. 259). The lips, buccal mucosa, gingiva, and palate are the sites of predilection.

The differential diagnosis includes squamous cell carcinoma, lymphoma, systemic mycoses, and other granulomatous diseases.

Laboratory tests. Histopathologic examination is essential in establishing the final diagnosis, along with radiographs.

Treatment. Antituberculosis therapy is indicated.

### Leprosy

Leprosy is a chronic, contagious, systemic granulomatous disease, caused by *Mycobacterium leprae*. The disease is transmitted from person to person and has a long incubation period, ranging from 2 to 6 years. Leprosy involves mainly the peripheral nerves, the skin, the mucosa of the upper respiratory tract, and such other tissues as bones and viscera. Leprosy, by clinical, bacteriologic, immunologic, and histopathologic criteria, is classified as tuberculoid, lepromatous, borderline, and indeterminate. Oral manifestations appear usually in lepromatous leprosy and occur in 20 to 60 % of the cases. Clinically, oral lesions are manifested as multiple nodules (lepromas) that progress to necrosis and ulceration. The ulcers heal slowly, forming atrophic scars, or may cause tissue destruction. The lesions are usually found on the soft and hard palate, uvula, dorsum of the tongue, lips, and gingiva (Figs. 260,

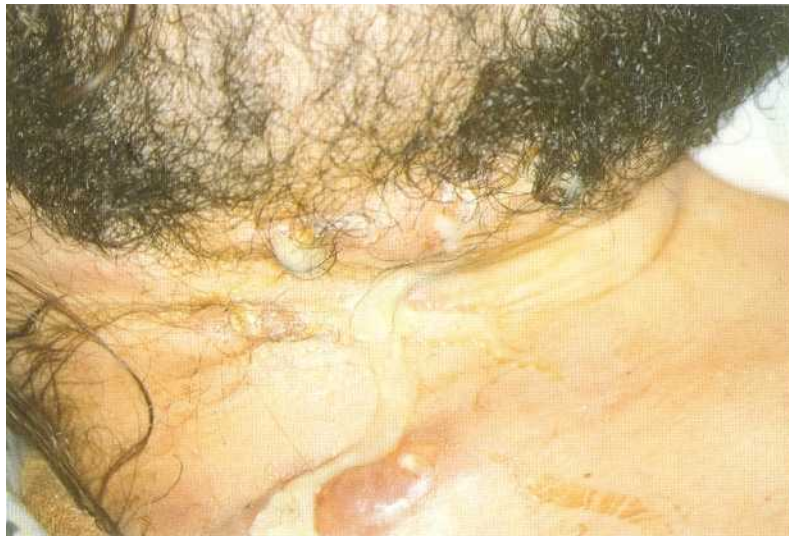

Fig. 258. Scrofula, multiple fistulas on the neck.

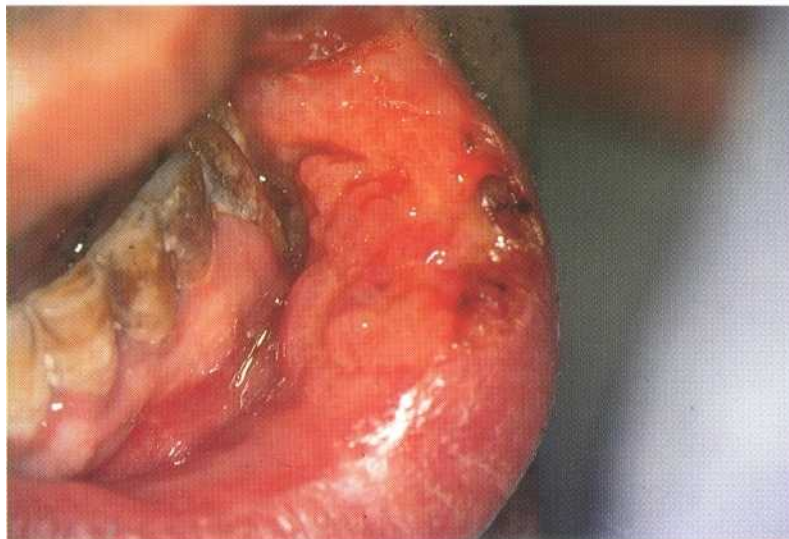


Fig. 259. Lupus vulgaris of the lip mucosa.

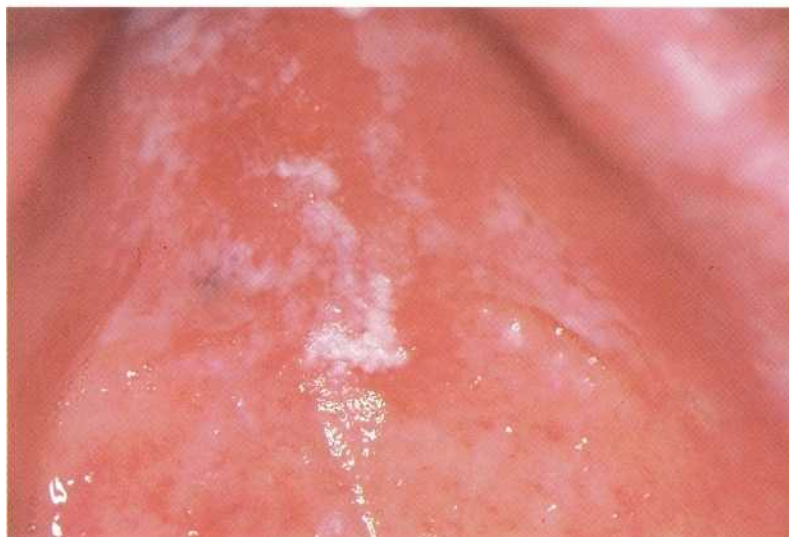
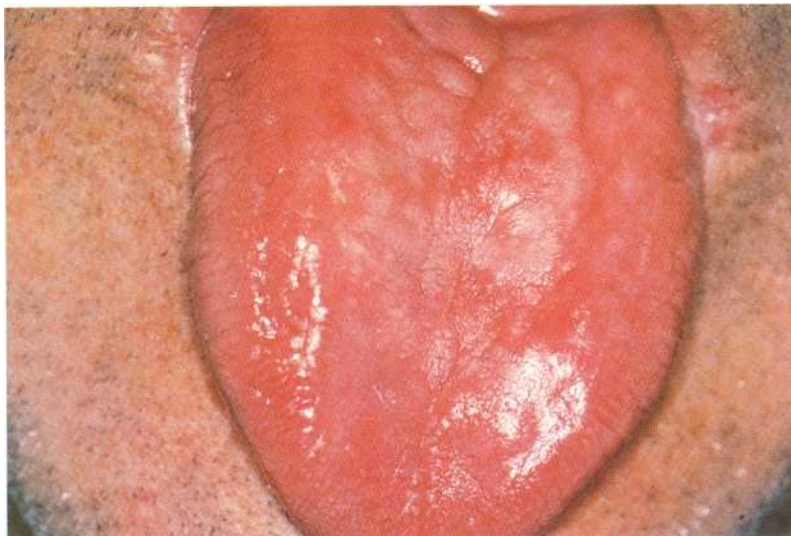
Fig. 260. Leprosy, atrophy and ulcer on the palate.



**Fig. 261. Leprosy, atrophic scars on the dorsum of the tongue.**

and 261). Destruction of the front part of the maxilla and loss of teeth may also occur.

The differential diagnosis of oral lesions includes tertiary syphilis, cicatricial pemphigoid, lethal midline granuloma, lymphomas, systemic mycoses, traumatic lesions, and malignant neoplasms.

Laboratory tests helpful in establishing the diagnosis are bacteriologic and histopathologic examinations, and the lepromin skin test.

**Treatment.** Dapsone is the cornerstone of therapy, but other medications, such as rifampin and clofazimine, are also useful.

### Actinomycosis

Actinomycosis is a chronic granulomatous infectious disease caused by the anaerobic Gram-positive bacterium *Actinomyces israelii*. There are three clinical forms of the disease: cervicofacial, thoracic, and abdominal. Cervicofacial actinomycosis is the most common form of the disease and oral manifestations are part of this form. Although *A. israelii* is a normal inhabitant of the oral cavity, clinical infection from the bacterium is relatively rare. It is assumed that oral actinomycosis occurs as an endogenous infection and that trauma in the oral cavity, such as wounds of the oral mucosa, tooth extraction, and fractures, is necessary to initiate the disease. In addition, open necrotic dental pulp may be the site of entrance of the bacterium. Clinically, at the site of inocula-

tion, there is an inflammatory swelling that grows slowly and is usually painless and characteristically hard on palpation (Fig. 262). As the lesion progresses, multiple abscesses and draining sinuses form, usually on the skin of the face and upper neck (Fig. 263). Yellow purulent material that represents colonies of *Actinomyces* (sulfur granules) may discharge from these sinuses. As the disease becomes chronic, healing of old lesions results in scar formation, but new abscesses and sinuses develop. Mandibular or maxillary involvement may be severe and usually is associated with trismus. Rare locations of actinomycosis are the tongue, lips, and buccal mucosa.

The differential diagnosis includes tuberculosis, systemic mycoses, nocardiosis, dental and periodontal abscess, and other nonspecific infections.

Laboratory tests to establish the diagnosis are direct bacteriologic examination and culture. Histopathologic examination may also be helpful.

**Treatment.** Penicillin is the drug of choice, but erythromycin or tetracycline may be utilized in sensitive patients. In addition, surgery is necessary in most cases.

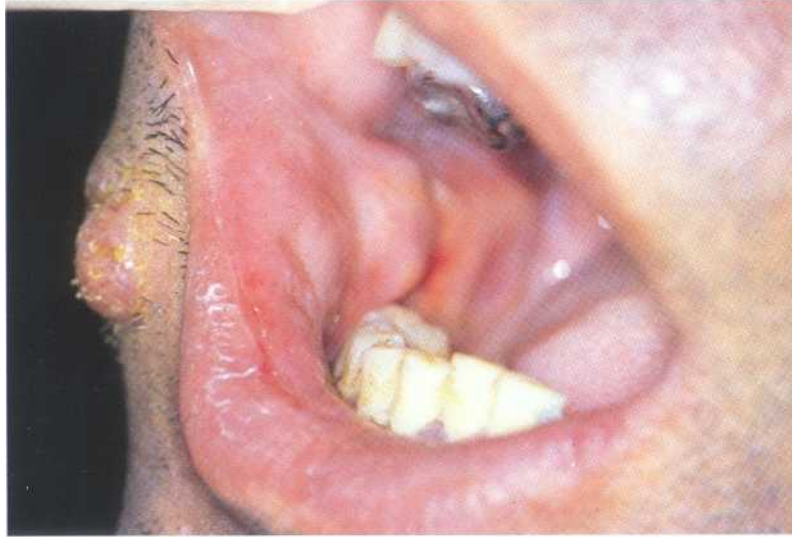

Fig. 262. Actinomycosis, nodules and sinus of the buccal mucosa.

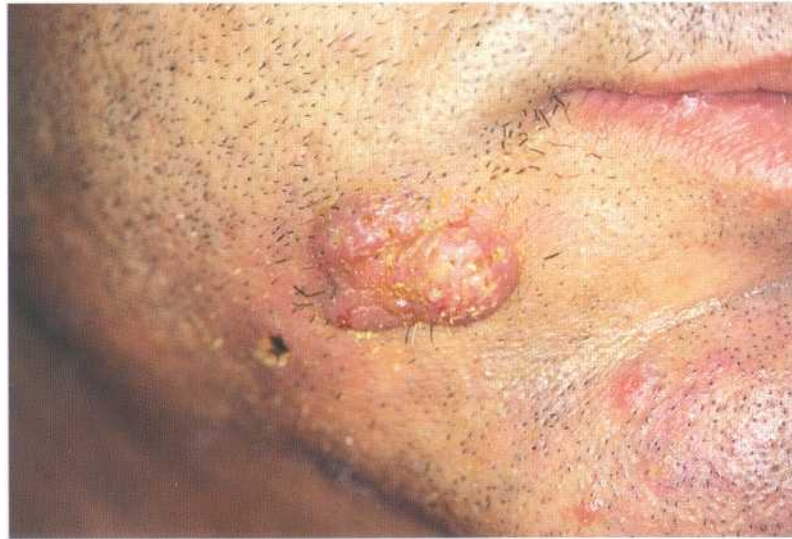

Fig. 263. Actinomycosis, multiple nodules and sinus of the skin.

## 18. Fungal Infections

### Candidosis

Candidosis is the most frequent fungal infection and is caused by *Candida albicans*, a fungus that is part of the normal oral flora in 20% to 50% of healthy persons. Factors predisposing to oral Candidosis include local factors (xerostomia, poor oral hygiene), diabetes mellitus, iron deficiency anemia, chronic diseases, malignancies, antibiotics, corticosteroid and other immunosuppressive drugs, radiation, hypoparathyroidism, Addison's disease, and humoral and cell-mediated immunodeficiency. Recently a novel cofactor implicated in the pathogenesis of oral candidosis has been the host blood group secretor status. In addition, oral candidosis is an early opportunistic infection that occurs in about two-thirds of the patients with or at high risk for HIV infection. Newborns and infants are also particularly susceptible to Candidosis. Oral candidosis has a broad spectrum of clinical manifestations. It has been recently suggested that oral candidosis should be classified as *primary*, comprising infections exclusively localized to the oral and perioral area, and *secondary*, comprising oral lesions of systemic mucocutaneous disease.

### Primary Oral Candidosis

Primary oral candidosis includes the following clinical varieties.

### Pseudomembranous Candidosis

Pseudomembranous candidosis is the most common form of the disease and is usually acute, but the chronic type may also occur. Clinically it is characterized by creamy white or whitish-yellow, slightly elevated spots or plaques, which usually can be easily detached, leaving a raw underlying reddish or normal surface. These lesions may be localized or generalized and may appear at any oral site, but more frequently on the buccal mucosa, the tongue, and the soft and hard palate (Figs. 264, 265, 266). Subjective complaints include xerostomia and a slight burning sensation. This form of candidosis is common in HIV infection.

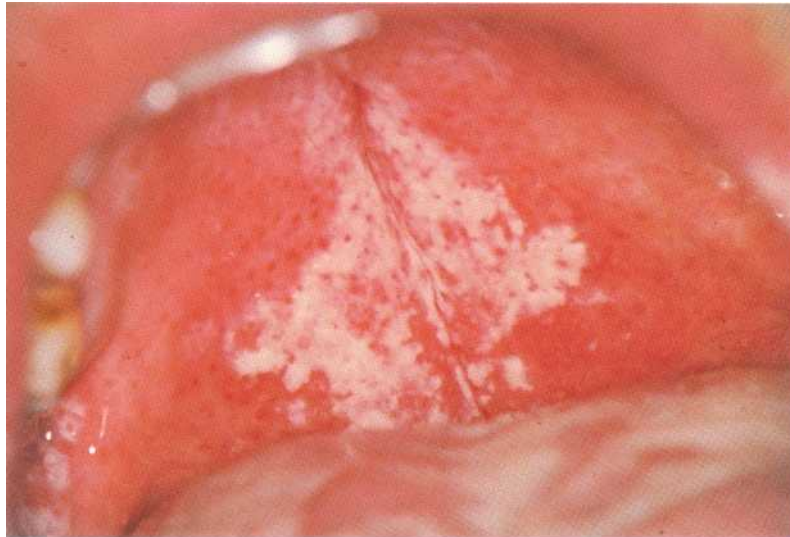

Fig. 264. Acute pseudomembranous candidosis.

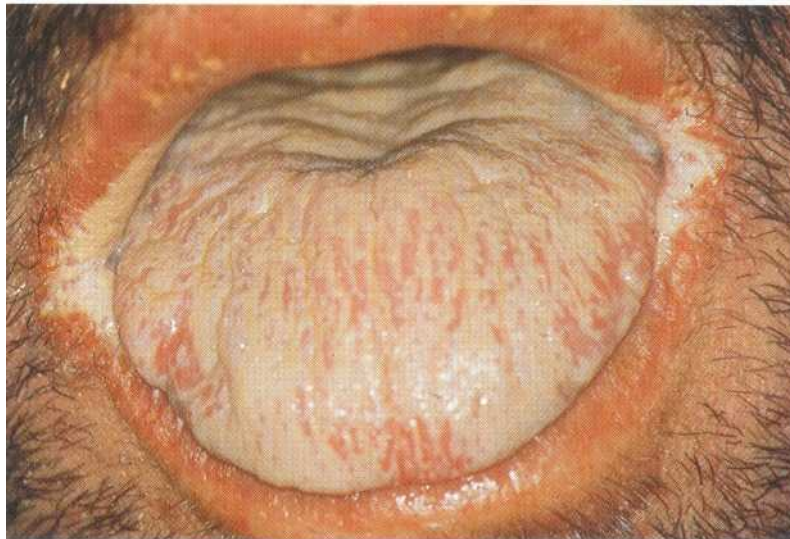


Fig. 265. Acute pseudomembranous candidosis.

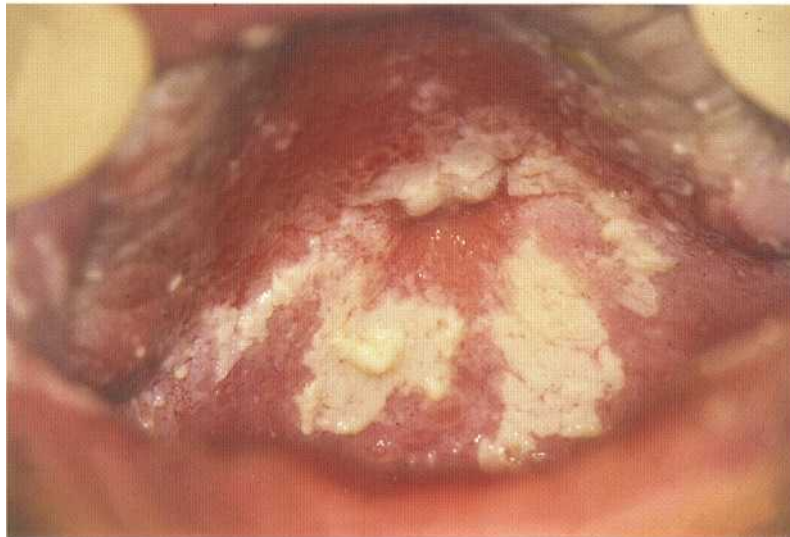
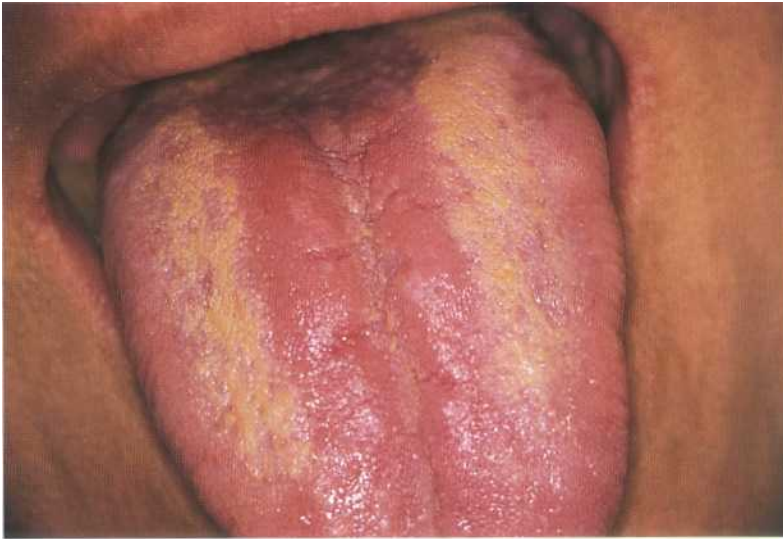

Fig. 266. Chronic pseudomembranous candidosis on the palate.





**Fig. 267. Erythematous candidosis on the dorsal surface of the tongue.**

### Erythematous Candidosis

Erythematous (atrophic) candidosis is also classified as acute or chronic. It is highly prevalent in HIV-infected individuals but may rarely be observed in patients receiving broad-spectrum antibiotics, corticosteroids, or other immunosuppressive agents. Clinically, there are erythematous patches which have a predilection for the dorsal surface of the tongue (Fig. 267) and palate. Erythematous candidosis frequently causes burning.

### Nodular Candidosis

Nodular candidosis (chronic *hyperplastic/Candida* leukoplakia) is a chronic form of candidosis that is characterized by deep infiltration of the oral tissues by fungal hyphae. Clinically, it is characterized by white, firm, and raised plaques occasionally surrounded by erythema (Fig. 268). The lesions may persist for years, do not detach, and are usually located on the retrocommissural area, the dorsum of the tongue, the buccal mucosa, and rarely in other areas. Rarely, lesions of this form of candidosis have been seen in patients with HIV infection. It has been suggested that nodular candidosis predisposes to squamous cell carcinoma and is therefore a precancerous lesion.

### Papillary Hyperplasia of the Palate

Papillary hyperplasia of the palate is a rare chronic form of candidosis that usually affects persons with a high-arched palate who do not wear dentures. Clinically, multiple small spherical nodules appear on the palate, which is usually red (Fig. 269). This lesion should not be confused with denture stomatitis, which appears in persons wearing dentures.

### Candida-associated Lesions

In this category three lesions are included: angular cheilitis, median rhomboid glossitis, and denture stomatitis.

*Angular cheilitis* is a disease of multifactorial etiology, which may be infective or noninfective. *Candida* species play an important role as causative cofactor. Angular cheilitis is often associated with denture stomatitis, which is common among denture wearers. Angular cheilitis is also commonly found among HIV-infected patients, either localized or in association with pseudomembranous candidosis. Clinically, it manifests as red, fissured crusts with or without erosion, occasionally covered by whitish-yellow spots or plaques (Fig. 270).

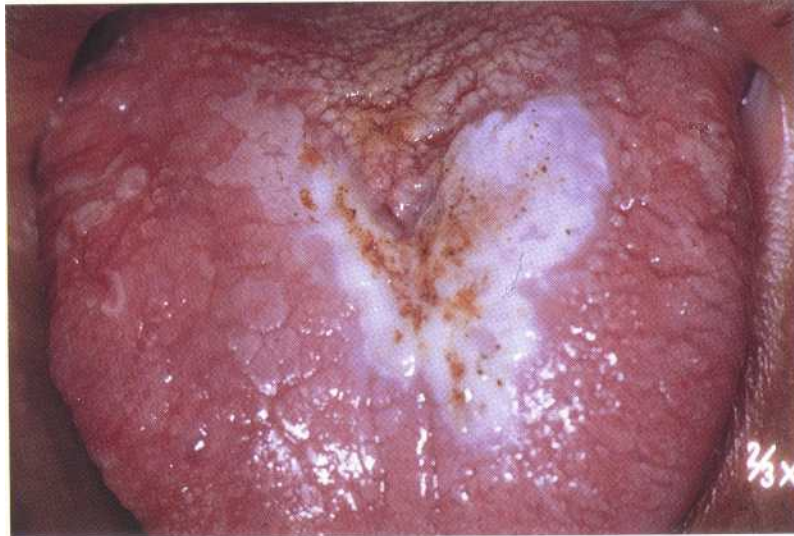

Fig. 268. Nodular candidosis.

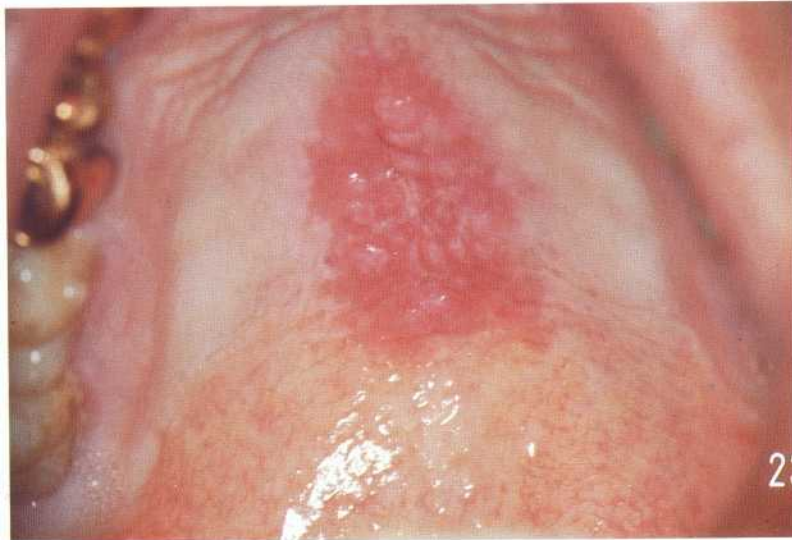

Fig. 269. Papillary hyperplasia of the palate.

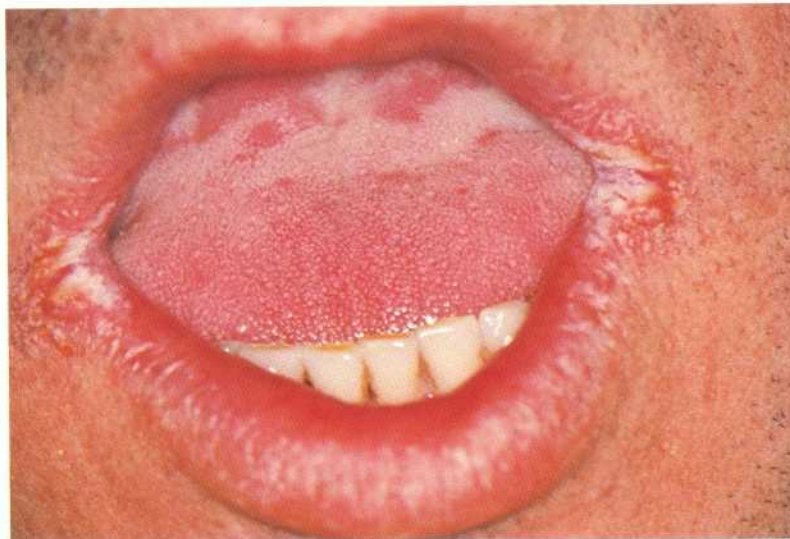
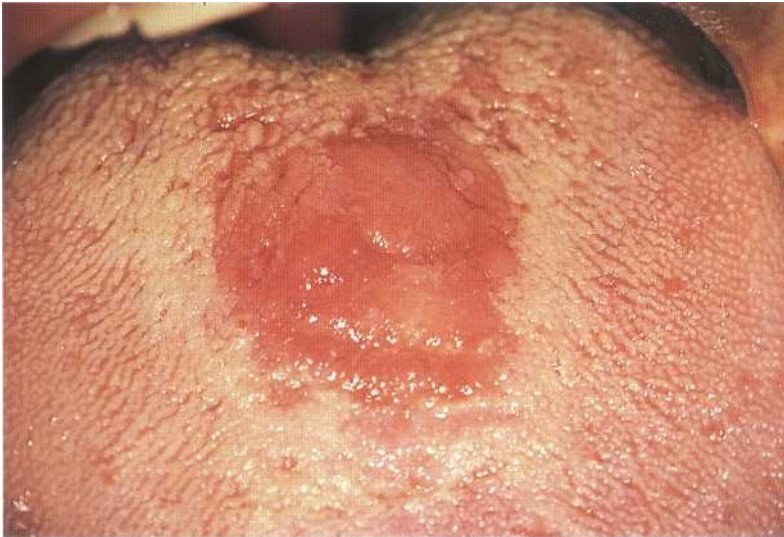
Fig. 270. Angular cheilitis.



**Fig. 271. Median rhomboid glossitis associated with *Candida albicans* infection.**

*Median rhomboid glossitis* may also be associated with *Candida albicans* infection. Clinically, it appears as a reddish smooth or nodular surface located on the midline of the dorsum of the tongue anterior to the circumvallate papillae (Fig. 271).

*Denture stomatitis* is usually associated with *Candida* infection and was referred to in the past as chronic atrophic candidosis. Denture stomatitis is usually common among upper denture wearers. Clinically, it is characterized by a diffuse erythema and slight edema of the mucosa underneath the denture (Fig. 272).

### **Secondary Oral Candidosis**

Secondary oral candidosis includes the following two clinical varieties.

### **Chronic Mucocutaneous Candidosis**

This form of candidosis is a heterogeneous group of clinical syndromes that are characterized by chronic lesions of the skin, nails, and mucosae. It usually appears in childhood and is often associated with numerous immunologic abnormalities, predominantly of cell-mediated immunity and rarely of humoral immunity. Clinically, the early oral lesions are similar to those seen in pseudomembranous candidosis, but later they are similar to the lesions of chronic hyperplastic (nodular) candidosis. Characteristically, the lesions are generalized, with a predilection for the buccal mucosa, commissures, tongue, palate, and lips, and may extend to the oropharynx and esophagus (Fig. 273). Cutaneous and nail involvement in varying degrees of severity are associated with the oral lesions (Fig. 274).

Fig. 272. Denture stomatitis associated with *Candida albicans* infection.

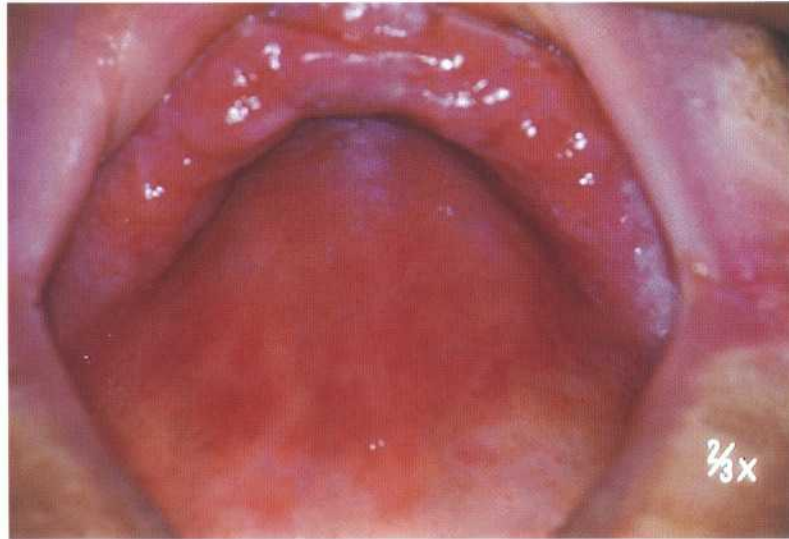

Fig. 273. Chronic mucocutaneous candidosis, multiple lesions on the tongue.

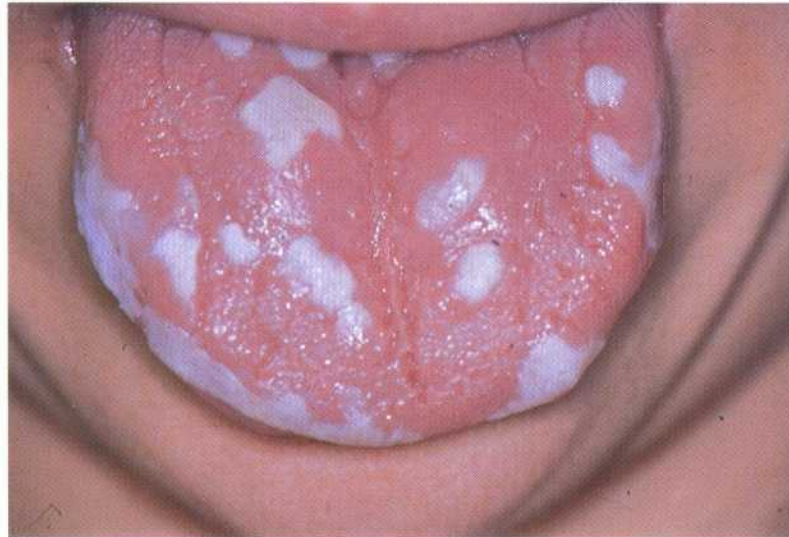
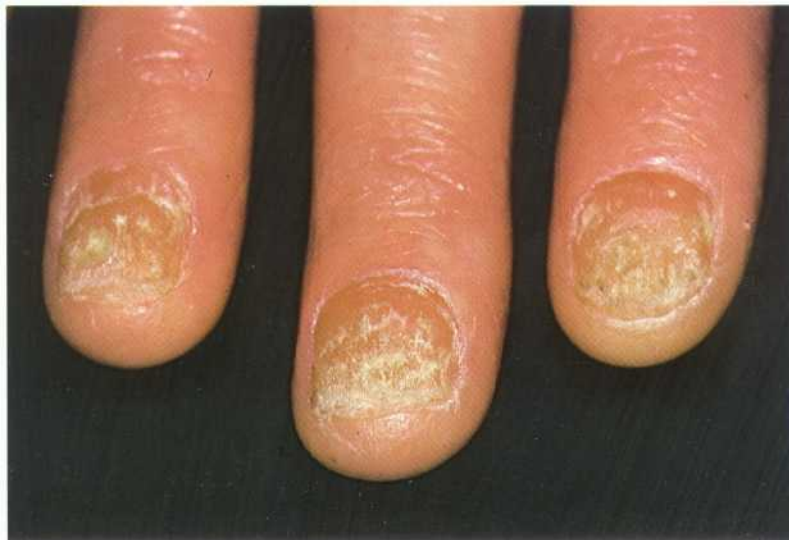
Fig. 274. Chronic mucocutaneous candidosis. nail lesions.



### Candida-Endocrinopathy Syndrome

This syndrome is a unique form of chronic mucocutaneous candidosis that is accompanied by endocrinopathies, such as hypoparathyroidism, hypoadrenalism, hypothyroidism, or pancreatic and ovarian hypofunction. Oral candidosis begins at the age of 4 to 6 years or later, whereas the endocrinopathy may be delayed in onset. Clinically, the oral, skin, and nail lesions are similar to those seen in chronic mucocutaneous candidosis (Fig. 275).

The differential diagnosis of candidosis includes chemical burns, traumatic lesions, white sponge nevus, leukoplakia, hairy leukoplakia, lichen planus, and mucous patches of secondary syphilis.

Laboratory test useful in establishing the diagnosis is direct microscopic examination of smears. Culture and histopathologic examination may also be of use.

Treatment. Nystatin and miconazole are the drugs of choice for topical use. Ketoconazole, amphotericin B, fluconazole, and intraconazole are used systemically with success in generalized forms of the disease.

### Histoplasmosis

Histoplasmosis is a systemic fungal disease caused by the organism *Histoplasma capsulatum*. The disease is endemic in the United States in the Mississippi and Ohio River Valleys, where about 80% of the adult population show positive histoplasmin skin test reaction. However, cases have been reported in other geographic areas, too. Sporadic cases of oral histoplasmosis have also been reported in HIV-infected patients. Three forms of histoplasmosis have been recognized: acute primary, chronic cavitory, and progressive disseminated. The acute primary form, which is more common, is characterized by constitutional symptoms (low-grade fever, malaise, chills, myalgias, etc.), pulmonary symptoms (cough, chest pain), and lymphadenopathy. This form is self-limited and is not associated with oral lesions. The chronic cavitory form is characterized exclusively by pulmonary signs and symptoms. The progressive disseminated form is very rare. Clinically, it is characterized by constitutional symptoms and hepatosplenomegaly, lymphadenopathy, bone marrow involvement, pulmonary radiologic findings, gastrointestinal disorders, adrenal insufficiency, and oral and pharyngeal manifestations.

Oral lesions occur in about 35 to 45% of the cases and are clinically characterized by indurated painful ulceration or verrucous, nodular, or granulomatous lesions (Fig. 276). The palate, tongue, buccal mucosa, gingiva, and lips are the preferred sites of localization. Commonly, oral lesions appear as the initial presenting manifestation.

The differential diagnosis includes squamous cell carcinoma, lymphoma, tuberculosis, Wegener's granulomatous, malignant granuloma, and other systemic fungal infections.

Laboratory tests. Histopathologic examination of biopsy specimens, direct examination of smears and culture are helpful in establishing the diagnosis.

Treatment. Ketoconazole and amphotericin B are effective in the treatment of histoplasmosis.

### North American Blastomycosis

Blastomycosis is a chronic fungal infection caused by *Blastomyces dermatitidis* and usually occurs in North America and Africa. The disease mainly involves the lungs and the skin, rarely the bones, the genital tract, and other organs. In about 25% of the patients oral or nasal mucosal lesions occur. Clinically, oral lesion is usually present as an ulcer with a slightly verrucous surface and thin borders or as a raised vegetating plaque (Fig. 277).

The differential diagnosis includes squamous cell carcinoma, tuberculosis, tertiary syphilis, and other systemic fungal infections.

Laboratory test. Histopathologic examination, direct smear examination, and culture are helpful in establishing the diagnosis.

Treatment. Ketoconazole, fluconazole, intraconazole, and amphotericin B are effective drugs.

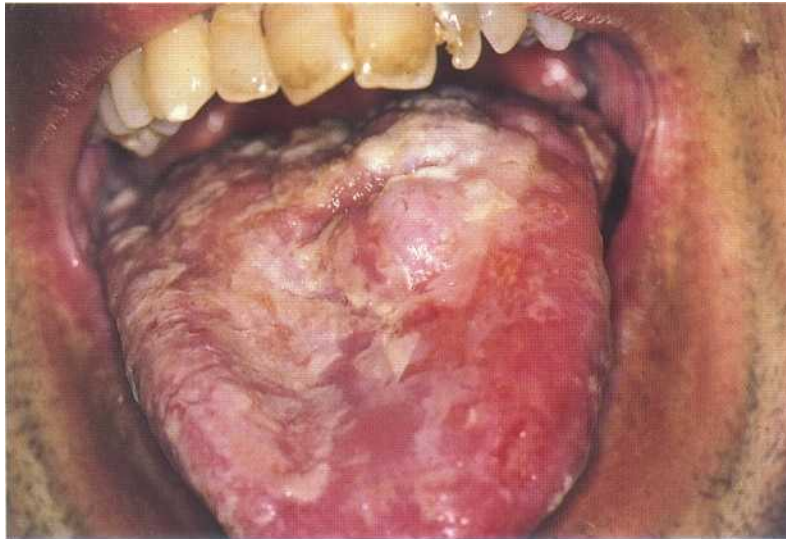


Fig. 275. Candida-endocrinopathy syndrome, severe tongue candidosis.

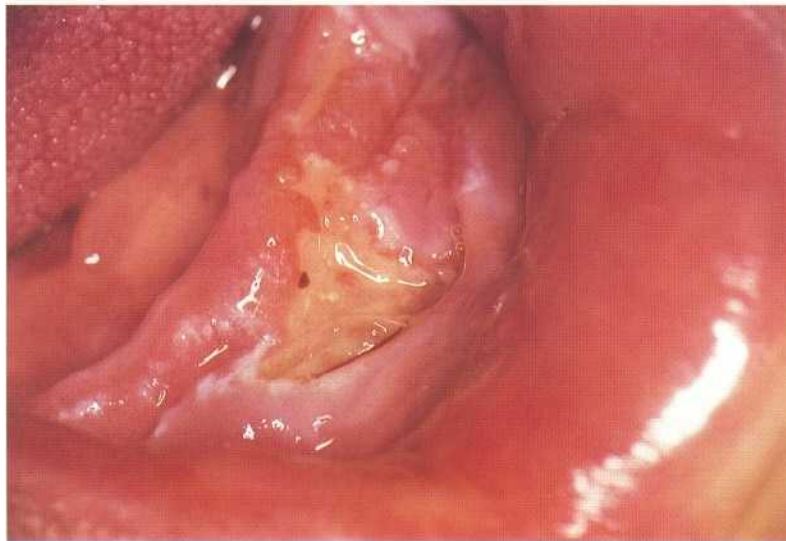


Fig. 276. Histoplasmosis, irregular ulcer on the alveolar mucosa.

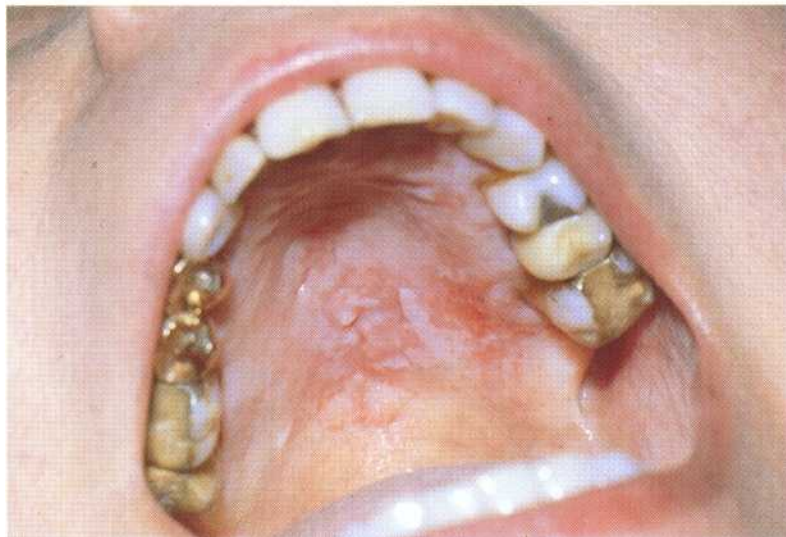

Fig. 277. North American blastomycosis, raised vegetating lesions on the hard palate.

### Paracoccidioidomycosis

Paracoccidioidomycosis (South American blastomycosis) is a chronic granulomatous disease and is caused by *Paracoccidioides brasiliensis*. The disease is particularly restricted to Brazil and other countries of South and Central America. Three forms of the disease are recognized: pulmonary, disseminated, and mucocutaneous.

Clinically, paracoccidioidomycosis is characterized by weight loss, fever, dyspnea, cough, lymph node enlargement, draining lesion of the skin and genital area, and ulcers of the nose, larynx, oropharynx, and oral cavity.

Clinical, oral lesions usually present as a chronic irregular ulcer with a granular surface (Fig. 278). Perforation of the hard palate associated with pain may be seen in severe cases. The soft and hard palate, tongue, and gingiva are frequently involved.

Differential diagnosis includes squamous cell and salivary gland carcinoma, tuberculosis, sarcoidosis, syphilis, malignant granuloma, Wegener's granulomatosis, lymphoma, sialometaplasia, and other systemic mycoses.

Laboratory tests. Histopathologic examination is required for the final diagnosis. Smear and/or culture may also be helpful. Serologic test by immunodiffusion or the complement fixation is useful as well.

Treatment. Intravenous amphotericin B, ketoconazole, and itraconazole are effective drugs.

### Mucormycosis

Mucormycosis (zygomycosis, phycomycosis) is a rare, often fatal, acute opportunistic fungal infection which usually involves debilitated individuals. Fungi of the family *Mucoraceae*, mainly *rhizopus* and *rhizomucor*, and rarely other species are the cause of the disease. The most common predisposing condition is poorly controlled diabetes mellitus with ketoacidosis. Hematologic malignancies, burns, malnutrition, uremia, liver cirrhosis, HIV disease, organ transplantation, cancer chemotherapy, and immunosuppressive therapy also predispose to mucormycosis. The fungus is acquired from the environment and characteristically erodes arteries, causing thrombosis, ischemia, and finally necrosis of the surrounding tissues. Four clinical forms of mucormycosis are recognized: rhinocerebral, pulmonary, gastrointestinal, and disseminated. The rhinocerebral

form is the most common inasmuch as signs and symptoms from oral, cranial, and facial structures account for 40-70 % of all reported cases.

Clinically, the disease is characterized by low-grade fever, headache, malaise, sinus pain, bloody nasal discharge, periorbital or perinasal swelling and edema, ptosis of the eyelid, extraocular muscle paresis, and progressive lethargy. Tissue necrosis of nasal and paranasal sinuses may result in perforation of the palate. Palatal ulceration and necrosis are the most characteristic oral lesions. The ulcer is sharply demarcated with a black necrotic eschar while the bone is exposed (Fig. 279). The mucosa surrounding the ulcer is usually thickened. Orbital and intracranial invasion is a common complication.

The differential diagnosis of oral lesions should include: malignant granuloma, Wegener's granulomatosis, tertiary syphilis, tuberculosis, squamous cell carcinoma, salivary gland adenocarcinoma, and other systemic mycoses.

Laboratory tests useful for diagnosis are histopathologic examination and smear examination. Computerized axial tomography may be useful to demonstrate the extent of bone destruction.

Treatment. Intravenous amphotericin B and surgical debridement are indicated. Correction of underlying predisposing conditions is also important.

Fig. 278. Paracoccidioidomycosis, irregular ulceration on the soft palate.

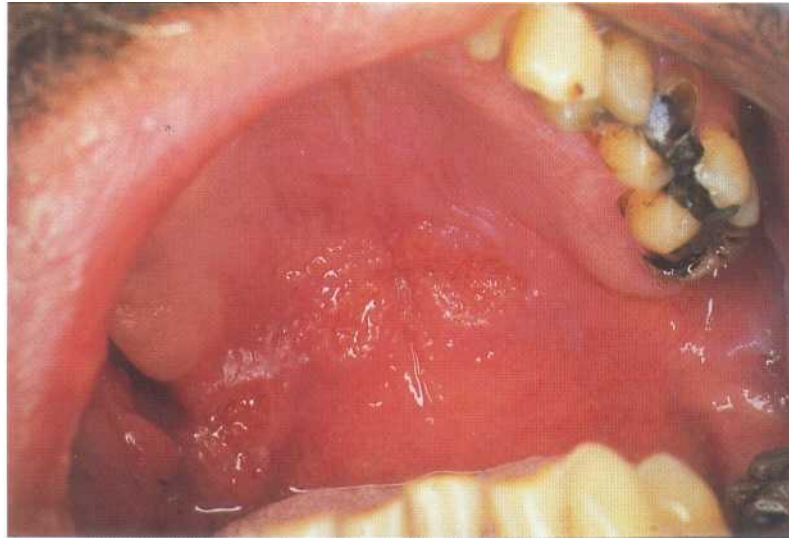
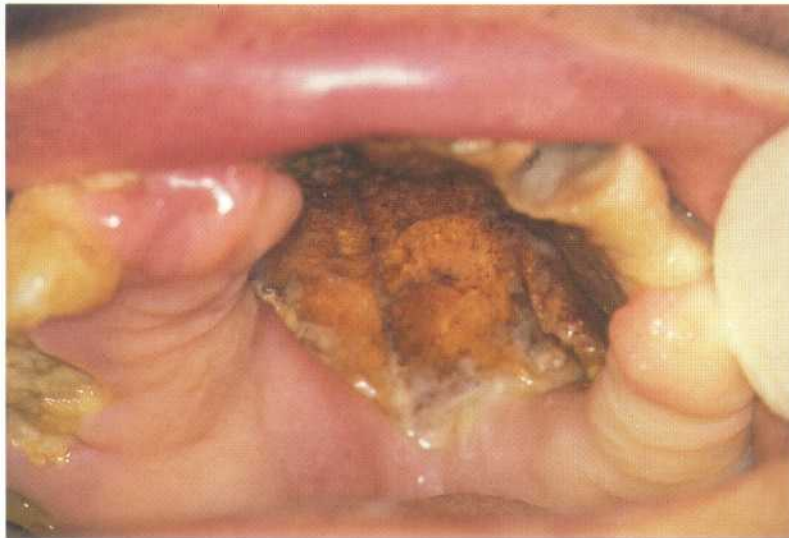

Fig. 279. Mucormycosis, palatal ulceration, necrosis and bone destruction.





## 19. Other Infections

### Cutaneous Leishmaniasis

Leishmaniasis is a parasitic infection caused by organisms of the genus *Leishmania*. Members of the genus *Phlebotomus* transfer the parasite from infected animals to humans. Three distinct clinical entities have been described: Cutaneous leishmaniasis (Oriental sore) caused by *Leishmania tropica*, Mucocutaneous leishmaniasis (American leishmaniasis) caused by *Leishmania brasiliensis*, and Systemic leishmaniasis (Kala-azar) caused by *Leishmania donovani*.

Cutaneous leishmaniasis is endemic in the tropical and subtropical zones and around the Mediterranean.

Skin lesions which may be single or multiple, usually occur on the face or other exposed parts of the skin. The lips may be the site of cutaneous leishmaniasis. Initially, a small papule forms that grows slowly. A red or brownish-red painless nodule with smooth and glistening surface then develops and progresses to ulceration (Fig. 280). A brown-gray crust covers the ulcer, and the surrounding tissues are inflamed.

The differential diagnosis includes basal cell carcinoma, squamous cell carcinoma, keratoacanthoma, syphilitic chancre, and erysipelas.

Laboratory tests useful to confirm the diagnosis are histopathologic examination, isolation and identification of the organism, and the leishmanin skin test.

Treatment includes administration of methylglucamine antimoniate (glucantime), antimalarials, local use of steroids, and rarely surgical excision of the lesion.

### Sarcoidosis

Sarcoidosis is a systemic granulomatous disease affecting the lungs, lymph nodes, spleen, liver, and central nervous system. The salivary glands, bones, and oral mucosa may also be affected. The disease is seen most frequently in women, usually between 20 and 50 years of age. The exact cause of the disease is not known, although evidence exists that a depression of cell-mediated immunity and an overactivity of B cells are associated with sarcoidosis.

The typical skin lesions of sarcoidosis consist of multiple purple-brown macules, papules, or nodules, which may be scattered or confluent (Fig. 281). Lupus pernio, erythema nodosum, scars, and persistent plaques are common skin manifestations. Skin lesions appear in 25 to 30% of patients and may be the only manifestations. The oral mucosa is rarely involved and the lips, tongue, and gingiva are the most commonly affected sites. Clinical manifestations include small or large deep red nodules, which may rarely ulcerate, loosening of the teeth, and temporomandibular dysfunction (Fig. 282). The salivary glands and the jaw bones may also be involved. All lesions are usually associated with lymphadenopathy and splenomegaly.

The differential diagnosis includes amyloidosis, tuberculosis, Crohn's disease, carcinoma, and other granulomatous lesions.

Laboratory tests helpful in establishing the diagnosis include histopathologic examination, Kveim-Siltzbach skin test, and chest radiograph.

Treatment. Steroids, azathioprine, levamisole, oxyphenbutazone, and cyclosporine may be helpful.

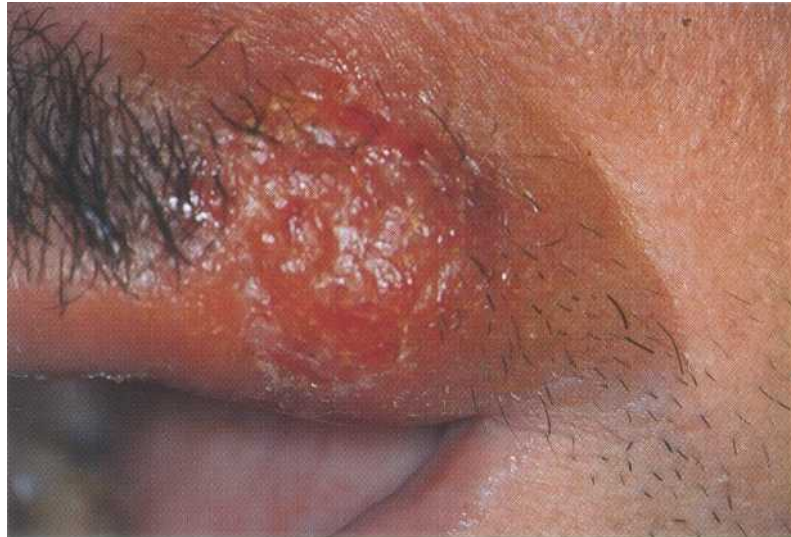

Fig. 280. Cutaneous leishmaniasis of the upper lip.

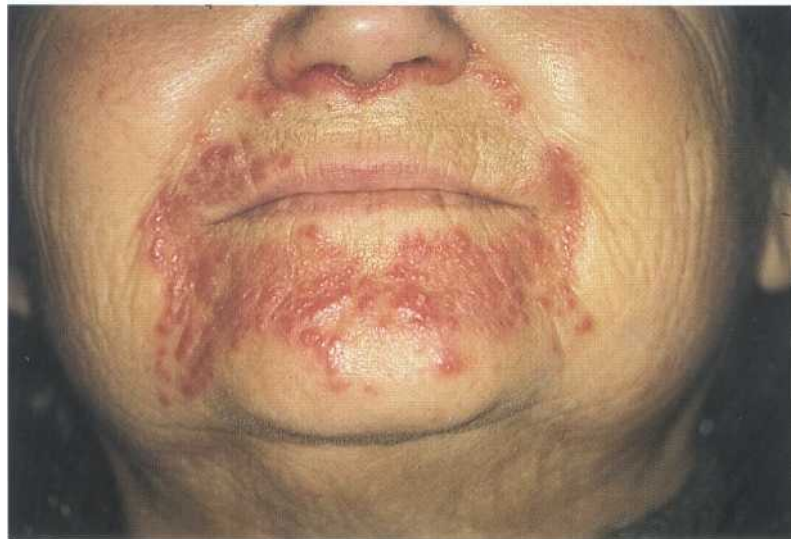

Fig. 281. Sarcoidosis, multiple lesions on the perioral skin.

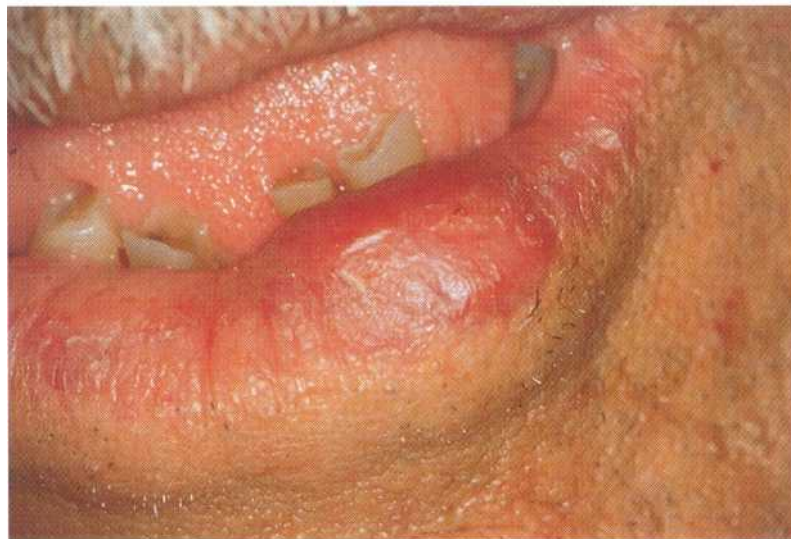
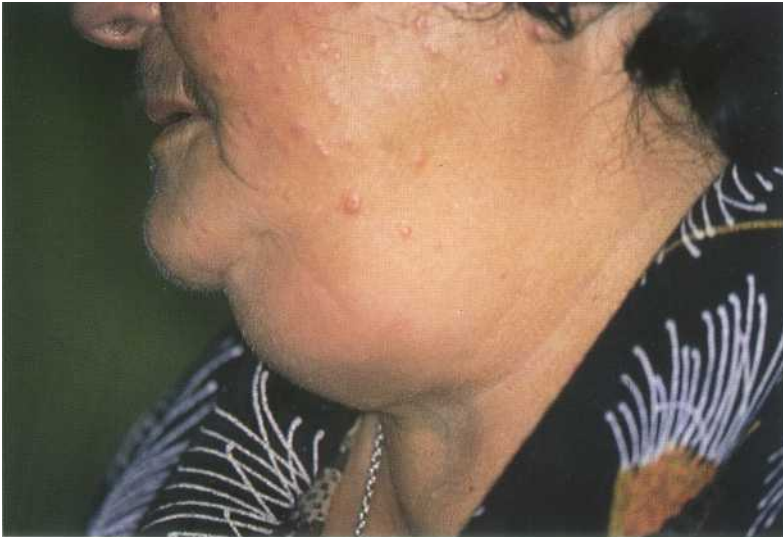
Fig. 282. Sarcoidosis, large red nodule on the lower lip.



**Fig. 283 Heerfordt's syndrome, swelling of the major salivary glands.**

### **Heerfordt's Syndrome**

Heerfordt's syndrome, or uveoparotid fever, is a form of sarcoidosis characterized by bilateral, firm, painless enlargement of the parotid glands, uveitis, facial nerve paralysis and low-grade fever. The sublingual and submandibular salivary glands and the lacrimal glands may also be affected (Fig. 283). Xerostomia is a common subjective symptom. The most frequent ocular lesions are uveitis, conjunctivitis, and keratitis. Lymph node enlargement, erythema nodosum, and cutaneous nodules complete the clinical picture.

The differential diagnosis includes Mikulicz's and Sjogren's syndromes.

**Laboratory test.** Histopathologic examination is helpful in establishing the diagnosis. Kveim-Siltzbach skin test, and chest radiograph may be helpful.

**Treatment.** Steroids.

## 20. Diseases with Possible Immunopathogenesis

### Recurrent Aphthous Ulcers

Recurrent aphthous ulcers are the most common lesions of the oral mucosa and affect 10 to 30% of the population. The exact cause remains unknown, although numerous possible etiologic factors have been suggested, such as iron, vitamin B<sub>12</sub> or folic acid deficiency, and viral or bacterial infection, especially with *Streptococcus* species (*S. sanguis*, *S. mitis*).

Trauma, endocrine disturbances, emotional stress, and allergy are considered the most important predisposing factors. In women the lesions may occur in a cyclic pattern a few days before menstruation. Recent evidence supports the concept that cell-mediated and humoral immunity to oral mucosal antigens play a primary role in the pathogenesis of recurrent aphthous ulcers and Behcet's syndrome. Recurrent aphthous ulcers have been classified into four varieties based on clinical criteria: minor, major, herpetiform ulcers, and aphthae associated with Behcet's syndrome.

### Minor Aphthous Ulcers

Minor aphthous ulcers are the most common form of the disease. They occur somewhat more frequently in females than in males during the second and third decades, although they may appear at any age. A prodromal burning sensation 24 to 48 hours before the appearance of the ulcer is recognized. Clinically, the ulcers are small, 2 to 6 mm in diameter, oval, and very painful, covered by a yellow-white membrane that represents necrotic tissue (Fig. 284). They are well circumscribed and surrounded by a thin erythematous halo. A vesicular stage does not exist.

Ulcers can be single or multiple (2 to 6); they generally persist 5 to 8 days and gradually heal with no evidence of scarring. They recur usually at 1- to 5-month intervals. The most common sites of occurrence are the nonkeratinized (movable) oral mucosa (buccal mucosa, lips, tongue, mucolabial and mucobuccal folds). The lesions are extremely rare on the hard palate and gingiva.

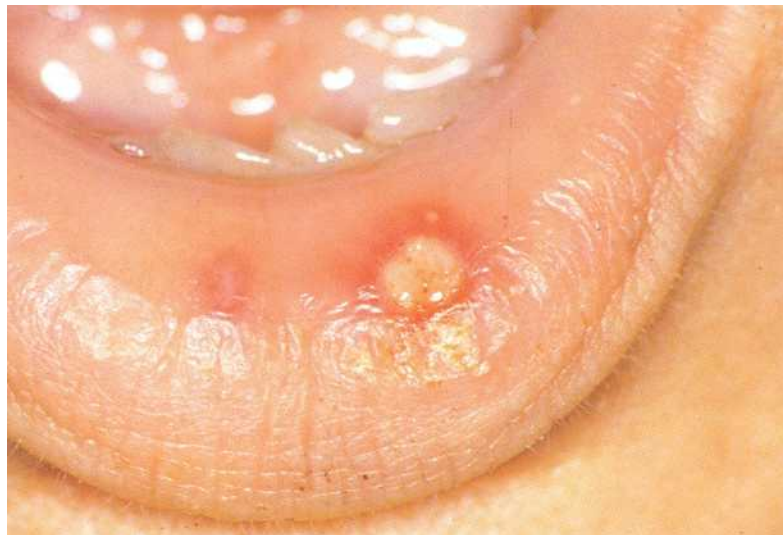

Fig. 284. Minor aphthous ulcer.

### Major Aphthous Ulcers

Major aphthous ulcers are currently believed to be a more severe form of aphthous ulcerations. They were previously thought to represent a separate disease entity known as periadenitis mucosa neerotica recurrens, or Sutton's disease. These ulcers are usually one to five in number and 1 to 2 cm in diameter each, deep, and extremely painful (Figs. 285, 286). The most common sites of occurrence are the lip, buccal mucosa, tongue, and soft palate. They may persist for 3 to 6 weeks, leave a scar on healing in cases of very deep ulcers, and recur, often at 1- to 3-month intervals.

The diagnosis of minor and major aphthous ulcers is based exclusively on clinical criteria. In addition, HLA-1312, A2, AW29, and DR7 antigens are found with slightly increased frequency in patients with aphthous ulcers.

The differential diagnosis of minor and major aphthous ulcers should include herpes simplex, hand-foot-and-mouth disease, syphilitic chancre and mucous patches of secondary syphilis, cyclic neutropenia, erythema multiforme, less frequently stomatitis venenata and medicamentosa, and rarely malignant ulcers.

**Treatment.** Topical application of a steroid ointment reduces discomfort and decreases the duration of the lesions. Topical anesthetics, antibiotics, mouthwashes, cauterizing chemicals, etc., have been used. In severe cases, intralesional steroid injection or systemic steroids in a low dose (10 to 20 mg prednisone) for 5 to 10 days reduce the pain dramatically.

### Herpetiform Ulcers

Herpetiform ulcers, or herpetiform stomatitis, were first described by Cook in 1960, who pointed out the clinical similarities of this disease to the lesions of herpes simplex and the corresponding histologic, microbiologic, and immunologic differences. The disease presents as multiple (10 to 100 in number) small shallow ulcers, 1 to 2 mm in diameter, with a thin red halo, which gradually coalesce to larger irregular lesions (Fig. 287). The lesions are very painful and may occur at any site of the oral mucosa, where they persist for 1 to 2 weeks and recur often over a period of 1 to 3 years.

The most common age of onset is between 20 and 30 years. Although the exact nature of the disease is unknown, it is considered appropriate to include it as a variant of recurrent aphthous ulcers.

The differential diagnosis includes primary herpetic gingivostomatitis, herpangina, and erythema multiforme.

Treatment is symptomatic. Low doses of corticosteroids (15 to 20 mg prednisone) for 5 to 7 days may be useful in severe cases.

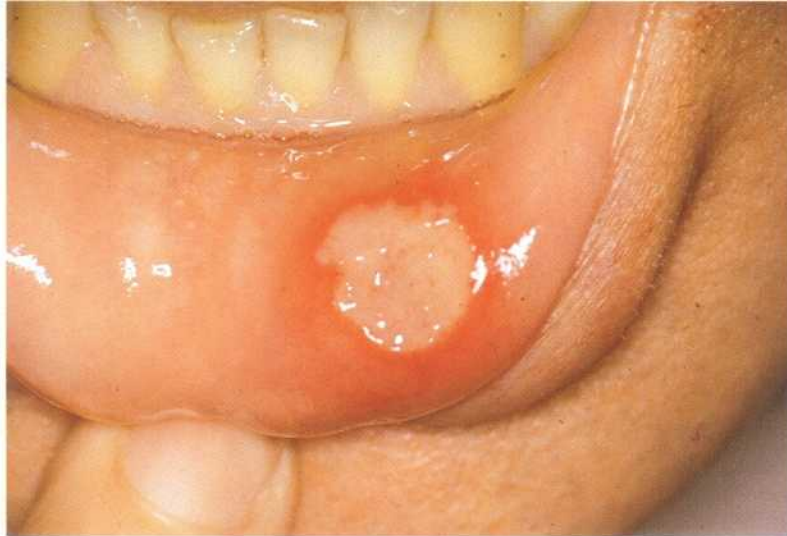

Fig. 285. Major aphthous ulcer on the lower lip.

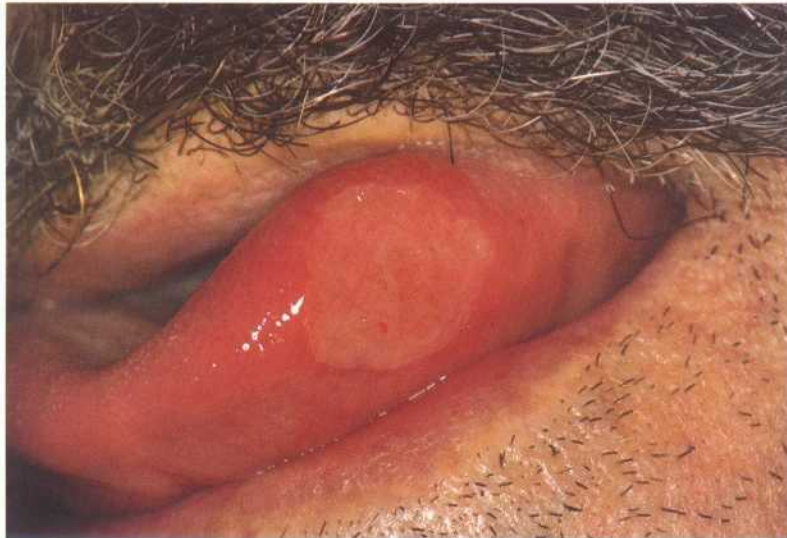


Fig. 286. Major aphthous ulcer on the tongue.

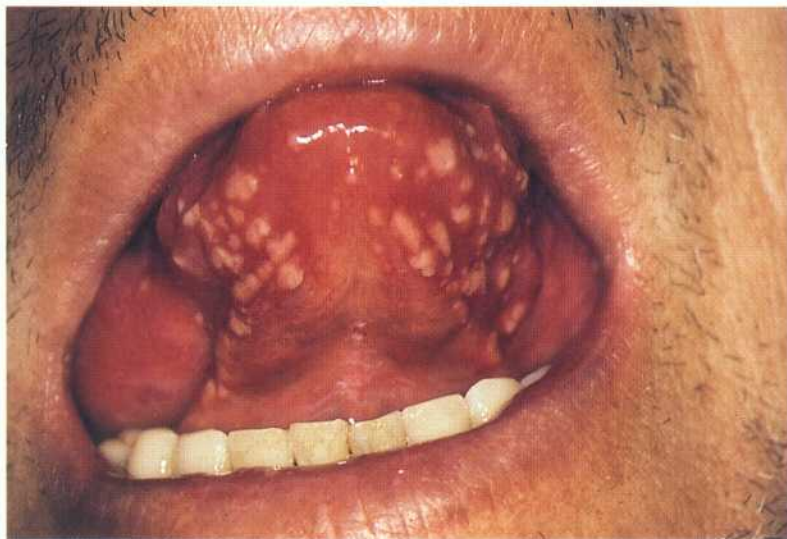
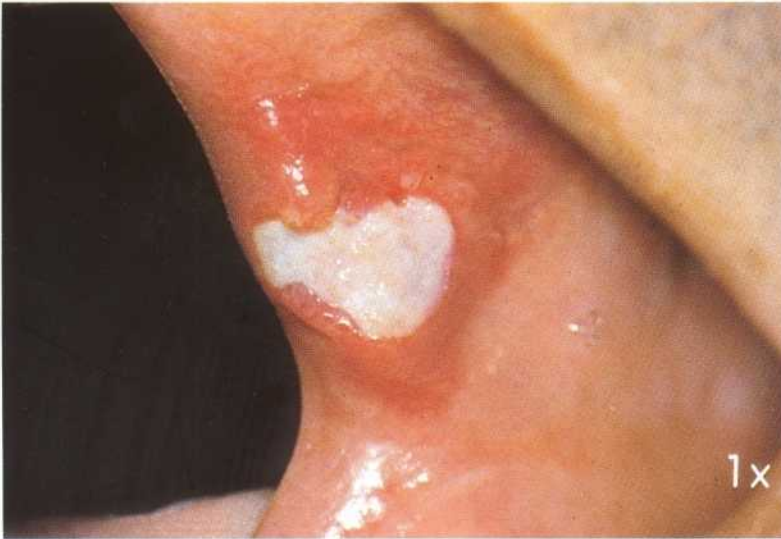
Fig. 287. Multiple herpetiform ulcers on the tongue.



**Fig. 288. Behcet's syndrome, major aphthous ulcer on the buccal mucosa.**

### Behcet's Syndrome

Behcet's syndrome is a chronic multisystemic inflammatory disorder of uncertain cause and prognosis. However, most of the evidence today favors an immunologic nature, which is supported by the association of the disease with complement activation and the formation of immunocomplexes. In addition, an immunogenetic basis is suggested by the increase prevalence of HLA-Bw 51, B5, B27, and B12 in the patients. The disease is five to ten times more common in males, with a mean age at onset of 20 to 30 years. Recently, a new set of five major clinical diagnostic criteria has been proposed by the International Study Group for Behcet's disease. These criteria are: a) recurrent oral ulceration; b) recurrent genital ulceration; c) eye lesions; d) skin lesions, and e) positive pathergy test. However, other minor clinical features such as arthritis, arthralgia, thrombophlebitis, deep vein thrombosis, epididymitis, arterial occlusion and/or aneurysms, CNS involvement, lung and gastrointestinal manifestations, and family history, may be seen. To establish the diagnosis of Behcet's syndrome, recurrent oral ulceration plus any two of the other four major clinical criteria must be present. The oral mucosa is invariably involved and very often oral lesions precede other clinical manifestations. The oral ulcers are present in 90 to 100% of the cases. They vary in size and number, recur quite frequently, and may develop anywhere in the mouth (Figs. 288, 289).

The genital ulcers occur in 60 to 80% of the cases. They are round, sharply demarcated, and occur mainly on the scrotum, glans, or shaft of the penis and labia majora, or even in the inner aspect of the genitocrural flexures (Figs. 290, 291).

Fig. 289. Behget's syndrome, multiple aphthous ulcers on the tongue.

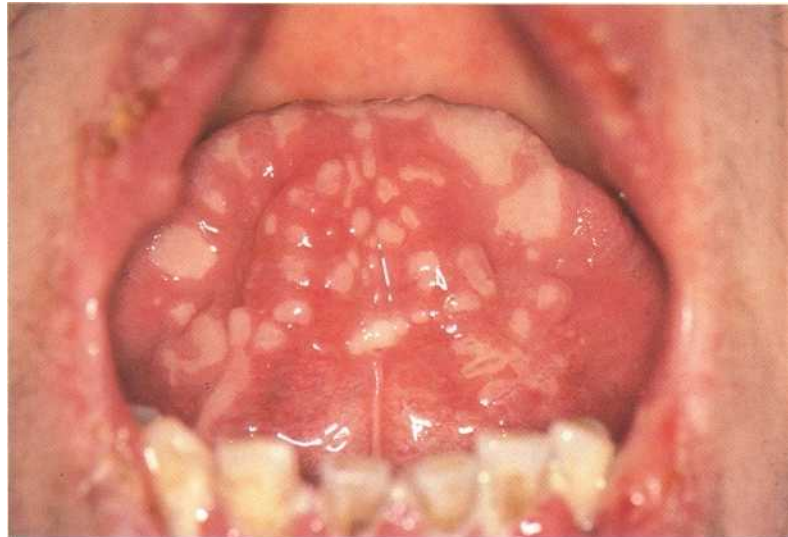

Fig. 290. Behcet's syndrome, two ulcers on the scrotum.

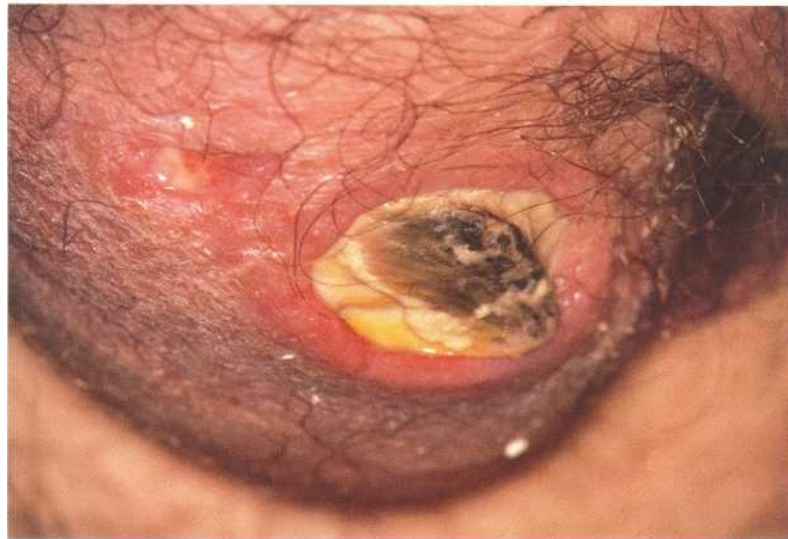
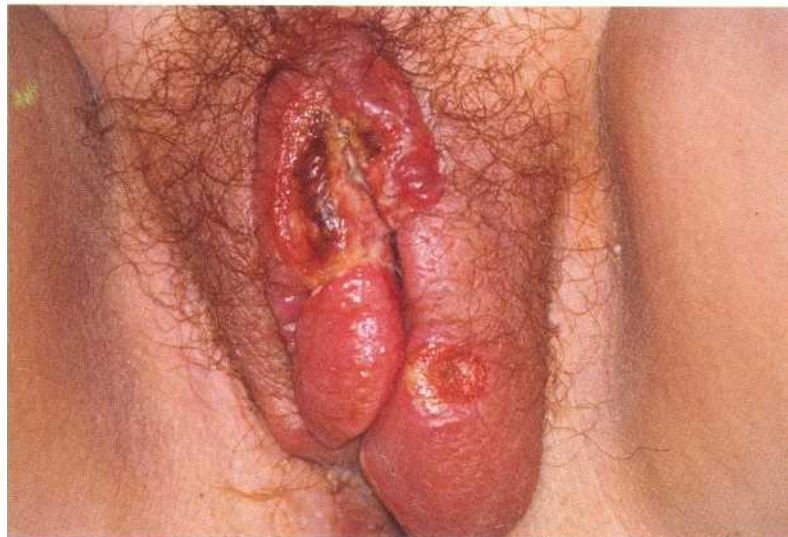
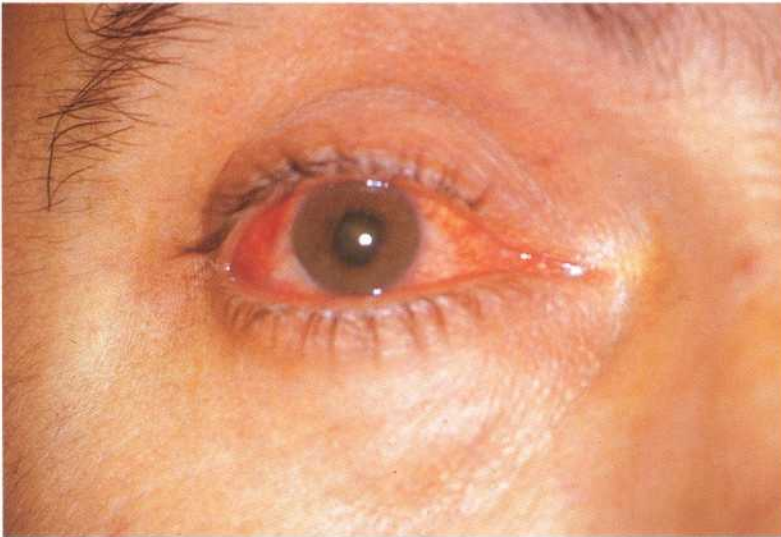Fig. 291. Behcet's syndrome, multiple ulcers on the labia majora.







**Fig. 292. Behcet's syndrome, conjunctivitis and iritis.**

The ocular lesions develop in 30 to 90% of the cases and may vary in severity from simple conjunctivitis to recurrent iritis with hypopyon, uveitis, and retinal vasculitis, which may occasionally lead to blindness (Fig. 292).

The skin lesions are present in 50 to 80% of the cases and consist of papules, pustules, erythema nodosum, ulcers, and rarely necrotic lesions (Fig. 293).

Diagnosis is based exclusively on the history and the clinical evaluation of the lesions, since no pathognomonic laboratory test exists.

The differential diagnosis should include recurrent aphthous ulcers, Reiter's syndrome, erythema multiforme and Stevens-Johnson syndrome, pemphigus, cicatricial pemphigoid, and ulcerative colitis.

**Laboratory tests.** Nonspecific findings of inflammation occur in serologic and routine hematologic studies. Histopathologic examination shows edema and mononuclear infiltration. There is an increased association of HLA-Bw51, B5, B12 and B27 in patients with Behcet's syndrome.

**Treatment.** Symptomatic in mild cases. Systemic steroids, immunosuppressive drugs, colchicine, thalidomide, and dapsone are administered in severe cases.

### Reiter's Syndrome

Reiter's syndrome is a disease of unknown cause that predominantly affects young men, 20 to 30 years of age. Most of the patients with this syndrome are HLA-1327-positive. The syndrome may follow an enteric infection with *Salmonella* or *Yersinia* species, or a nongonococcal urethritis with *Chlamydia* or *Ureaplasma urealyticum*. Clinical characteristics include nongonococcal urethritis, conjunctivitis (Fig. 294), arthritis, and mucocutaneous lesions. Oral lesions occur in 20 to 40% of the patients. They appear as diffuse erythema and slightly painful superficial erosions. Dark red and slightly elevated painless plaques varying from several millimeters to several centimeters in diameter occasionally surrounded by whitish annular lines are common on the buccal mucosa, gingiva, palate, and lips (Fig. 295). When these lesions appear on the tongue, they mimic geographic tongue. The genital lesions include urethritis and circinate balanitis. The cutaneous lesions are characterized by macular or vesicular or pustular lesions (keratoderma blennorrhagicum) usually involving the palms, soles, and other areas of the skin. Keratotic crusts form later in the course of the disease. Psoriasiform rash, scaling papules, plaques with pustular centers, and nail changes may also occur (Fig. 296). Conjunctivitis and acute iridocyclitis may be seen in about 20 to 30% of cases. Although mucocutaneous manifestations appear 4 to 6 weeks after the onset of the disease, they may be important for the diagnosis. Asymmetrical arthritis of the large

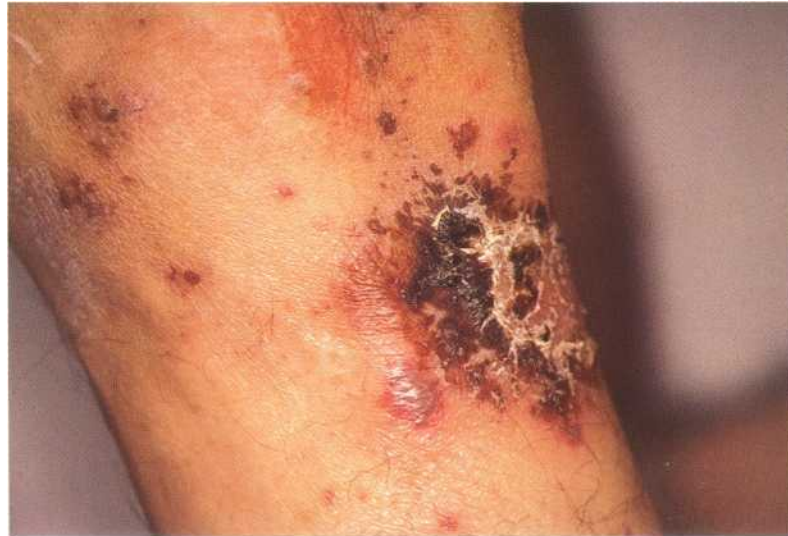

Fig. 293. Behget's syndrome, pustules and necrotic lesions on the skin.

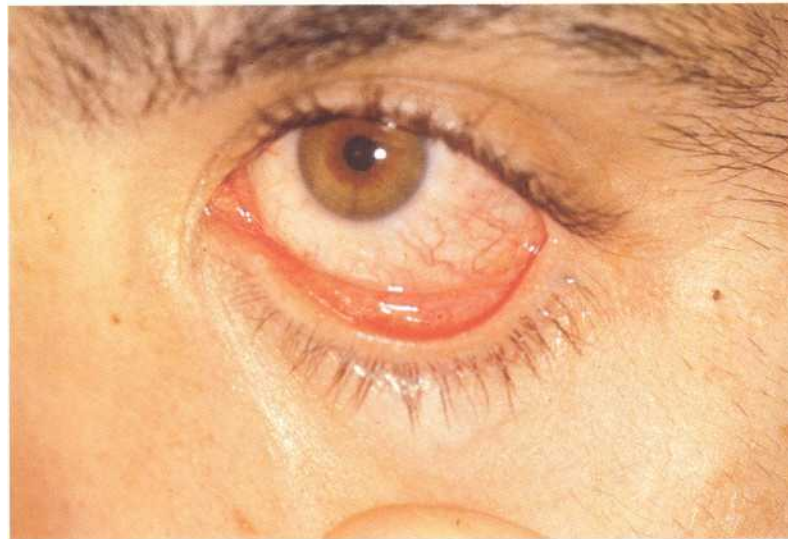

Fig. 294. Reiter's syndrome, conjunctivitis.

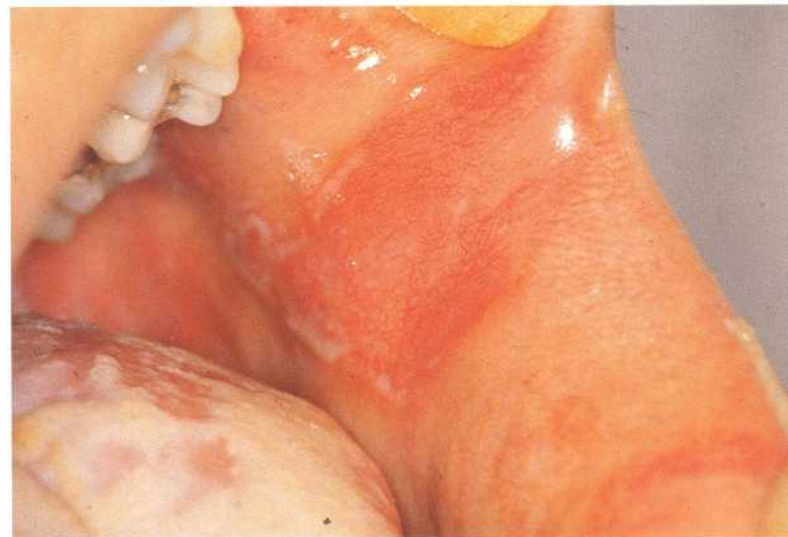
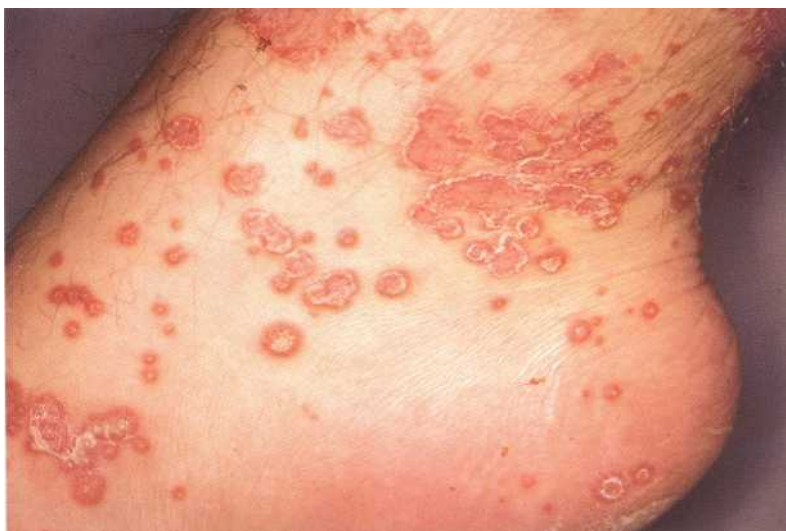

Fig. 295. Reiter's syndrome, red areas surrounded by whitish annular lines on the buccal mucosa.



**Fig. 296. Reiter's syndrome, psoriasiform lesions on the skin.**

joints is the most important and early manifestation and occasionally may produce disability. Cardiovascular and neurologic disorders and amyloidosis may rarely occur.

The differential diagnosis of the oral lesions includes erythema multiforme, Stevens-Johnson syndrome, psoriasis, Behcet's syndrome, geographic tongue, and stomatitis.

Laboratory tests. There is no accurate test. However, histopathologic and radiographic examination are helpful.

Treatment. It is nonspecific and symptomatic. Nonsteroidal anti-inflammatory drugs, salicylates, and tetracyclines may be helpful.

### **Wegener's Granulomatosis**

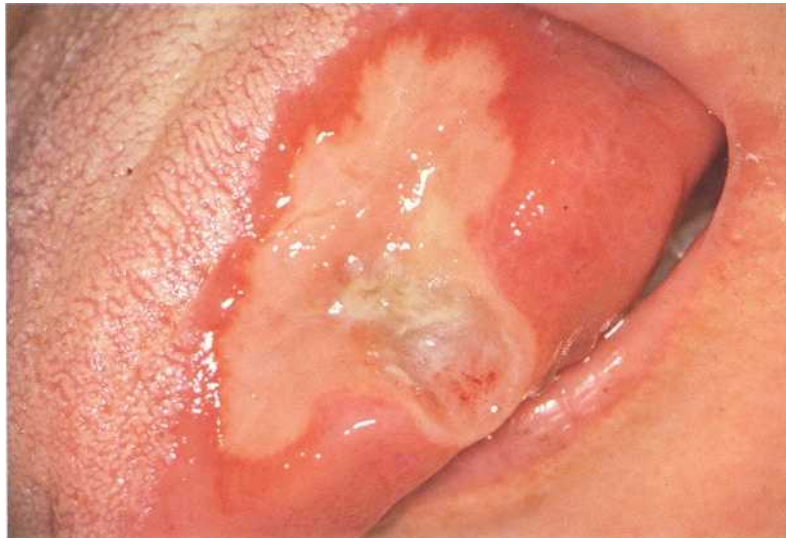Wegener's granulomatosis is a rare chronic granulomatous disease of unknown cause, although an immunologic mechanism is probably related to the pathogenesis. The disease is characterized by necrotizing granulomatous lesions of the upper and lower respiratory tract, generalized focal necrotizing vasculitis involving both veins and arteries, and necrotizing glomerulonephritis. Oral lesions in Wegener's granulomatosis are fairly common, although the true incidence is not known. Clinically, the lesions appear as solitary or multiple ulcer surrounded by an inflammatory zone (Fig. 297). The tongue, palate, and buccal mucosa are commonly affected. Rarely, a peculiar

gingival enlargement may be an early feature of the disease. The gingiva is enlarged with a red, papillary granulomatous surface. Skin lesions occur in half of the patients and are characterized by papules, petechiae, plaques, and ulcers. Ocular, cardiac, joint, and neurologic manifestations may also occur. The pulmonary and renal involvement are the most common and severe manifestations of the disease. The prognosis is usually unfavorable, although recently limited forms of the disease with a better course have been described.

The differential diagnosis includes lethal midline granuloma, tuberculous ulcers, squamous cell carcinoma, leukemia, lymphoma, and systemic mycoses.

Laboratory tests that are helpful in establishing the diagnosis include histopathologic examination, chest radiographs, blood count, and urinalysis. The detection of antineutrophils cytoplasmic autoantibodies (ANCA) in patients' serum is a very important tool for diagnosing Wegener's granulomatosis.

Treatment. A combined therapy with steroids, cyclophosphamide, and azathioprine have improved the prognosis of the disease.

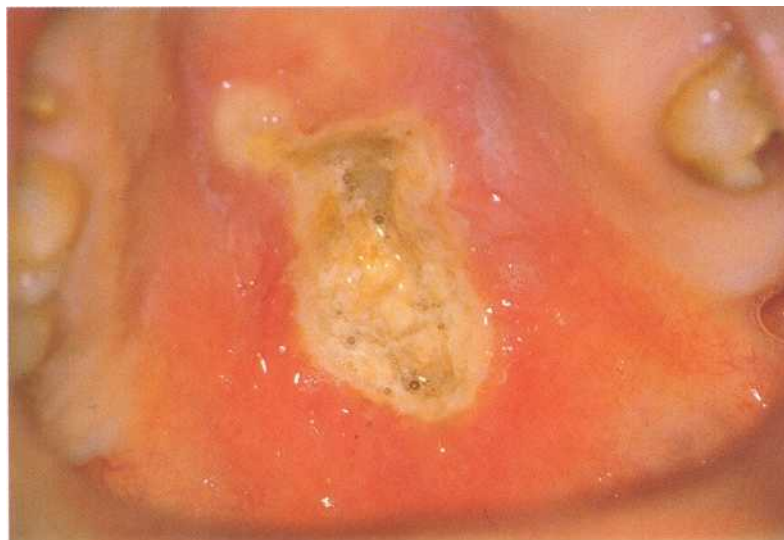

**Fig. 297.** Wegener's granulomatosis, large ulcer surrounded by an erythematous zone on the tongue.

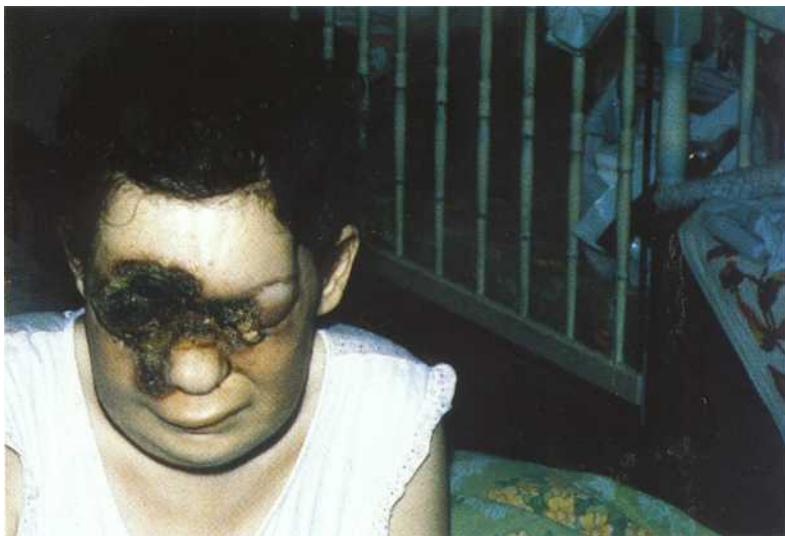### **Lethal Midline Granuloma**

Lethal midline granuloma or malignant granuloma represents a disease spectrum characterized by progressive unrelenting ulceration and necrosis involving the nasal cavity, palate, and the midline segment of the face. The precise pathogenesis remains unknown. Many investigators consider that lethal midline granuloma and Wegener's granulomatosis are extremes of a spectrum. However, recent evidence disputes this view, and under the term "lethal midline granuloma" three varieties may be included: the essentially inflammatory, or idiopathic midline

granuloma; the obviously neoplastic, or polymorphic reticulosis, which is a lymphoproliferative disorder; and a lymphoma with low-grade malignancy. Clinically, the disease is characterized by prodromal signs and symptoms, such as epistaxis, slight pain, nasal stuffiness, foul-smelling secretions, and nasal obstruction with a purulent discharge. Nonhealing ulceration and necrosis of the palate, alveolar processes, retromolar pad, and the nasal cavity occur frequently (Fig. 298). These lesions deteriorate rather rapidly, causing destruction and perforation of the palate, nasal septum and bones, and the neighboring bony structures, resulting in severe disfiguration



**Fig. 298.** Lethal midline granuloma, nonhealing ulcer and necrosis on the palate.



**Fig. 299. Lethal midline granuloma, severe disfiguration of the face.**

(Fig. 299). The prognosis is unfavorable, with an extremely high fatality rate.

The differential diagnosis includes Wegener's granulomatous, leprosy, syphilitic gumma, lymphoma, squamous cell carcinoma, tuberculosis, necrotizing sialometaplasia, mucormycosis, and other systemic mycoses.

Laboratory test. Histopathologic examination is helpful in establishing the diagnosis.

Treatment. Radiation has been reported to have therapeutic value. Steroids and other cytotoxic agents have failed to change the prognosis.

### **Crohn's Disease**

Crohn's disease, or regional enteritis, is a chronic inflammatory disease involving the ileum and other parts of the gastrointestinal tract. The cause remains obscure, although an immune mechanism probably participates in the pathogenesis. The disease usually affects young persons between 20 and 30 years of age, and clinically presents with abdominal pain, diarrhea, weight loss, vomiting, low-grade fever, and rectal bleeding. Extraabdominal manifestations of the disease include spondylitis, arthritis, uveitis, and oral manifestations. Oral lesions have been found in 10 to 20% of patients with Crohn's disease, and they may either precede or follow the intestinal involvement. Clinically, the most frequently affected areas are the buccal mucosa and the mucobuccal fold, where the changes appear as edematous, hypertrophic,

or granulomatous lesions with or without ulcers. Diffuse raised nodules resulting in a "cobblestone" appearance of the buccal mucosa or mucosal tag lesions may also occur (Fig. 300). Granulomatous lip swelling, angular cheilitis, erythema and scaling of perioral skin, diffuse granular erythematous gingival swelling, and palatal ulceration may be seen (Fig. 301). In addition, nonspecific aphthous-like lesions and persistent lymphadenopathy are frequently associated with Crohn's disease. The oral lesions usually regress when intestinal symptoms are in remission.

The differential diagnosis includes pyogenic granuloma, epulis fissuratum, tuberculosis, sarcoidosis, cheilitis granulomatosa, and Melkersson-Rosenthal syndrome.

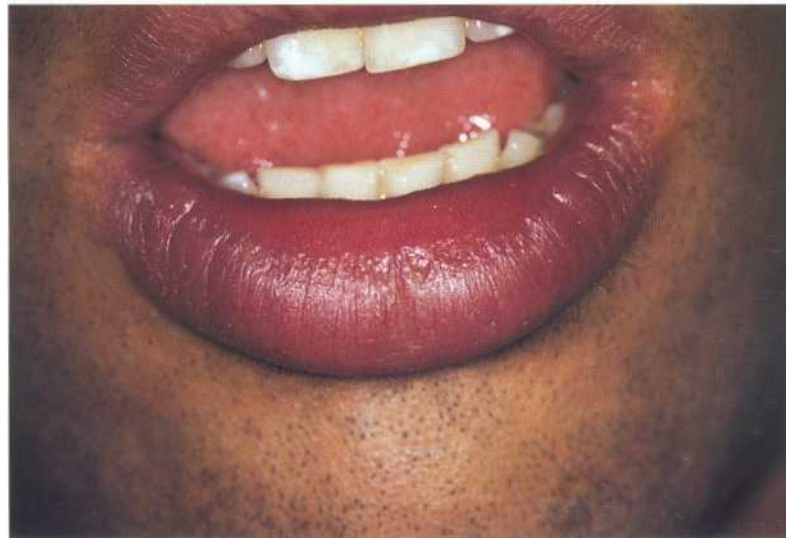
Laboratory test. Histopathologic examination and radiologic studies of the bowel are helpful in establishing the diagnosis.

Treatment. Topical corticosteroids; systemic corticosteroids, sulfonamides, and immunosuppressive agents in severe cases.

Fig. 300. Crohn's disease, "cobblestone" appearance of the buccal mucosa.

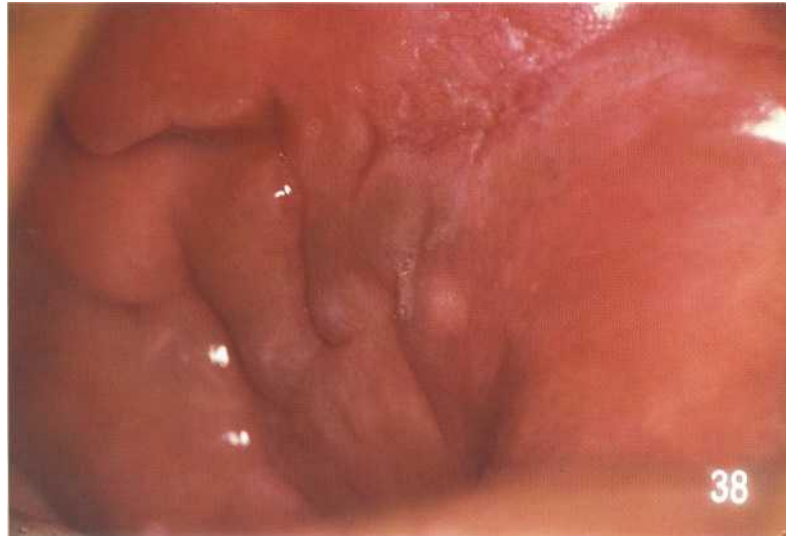

Fig. 301. Crohn's disease, lip swelling.



## 21. Autoimmune Diseases

### Discoid Lupus Erythematosus

Lupus erythematosus is a chronic inflammatory autoimmune disease with a variable spectrum of clinical forms in which mucocutaneous lesions may occur with or without systemic manifestations.

Discoid lupus erythematosus (DLE) is the more common form of the disease. It tends to be confined to the skin and has a benign course in the vast majority of patients. The skin lesions are characterized by violaceous papules and patches, scaling, and prominent follicular hyperkeratosis. These lesions are sharply demarcated from the surrounding healthy skin and progress to scarring with atrophy and telangiectasia. Discoid lupus lesions are very often located above the neck region (face, scalp, and ears) and usually form a characteristic "butterfly" pattern on the face (Fig. 302). If the disease involves areas above and below the neck, it is characterized as generalized DLE. The cutaneous lesions persist for months to years.

The oral mucosa is involved in 15 to 25% of the cases, usually in association with skin lesions. However, on rare occasions, oral lesions may occur alone.

The typical oral lesions are characterized by a well-defined central atrophic red area surrounded by a sharp elevated border of irradiating whitish striae (Fig. 303). Telangiectases and small white dots may be present on the erythematous areas. Ulcers, erosions, or white plaques may also be present and progress to atrophic scarring (Fig. 304).

The buccal mucosa is the most frequently affected site, followed by the lower lip, palate, gingiva, and tongue. Generally, the clinical features of oral lesions are not pathognomonic.

The differential diagnosis should include leukoplakia, erythroplakia, lichen planus, geographic stomatitis, syphilis, and cicatricial pemphigoid.

Laboratory tests. Serum antinuclear antibodies are infrequently present at low titers and anti-double-stranded DNA antibodies are rarely present. Subepidermal immunoglobulins are detected in 75% of biopsy specimens of involved skin or mucosae, using fluorescent techniques. Histopathologic examination of oral lesions is also helpful.

Treatment. The oral lesions of DLE are treated with local steroids if the lesions are small or with systemic steroids or antimalarials in case the disease is more extensive.

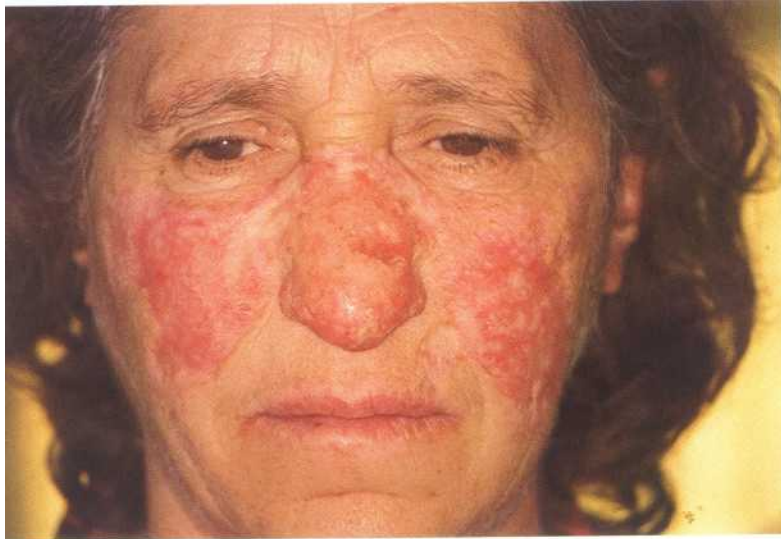

Fig. 302. Discoid lupus erythematosus, characteristic butterfly-like eruption on the face.

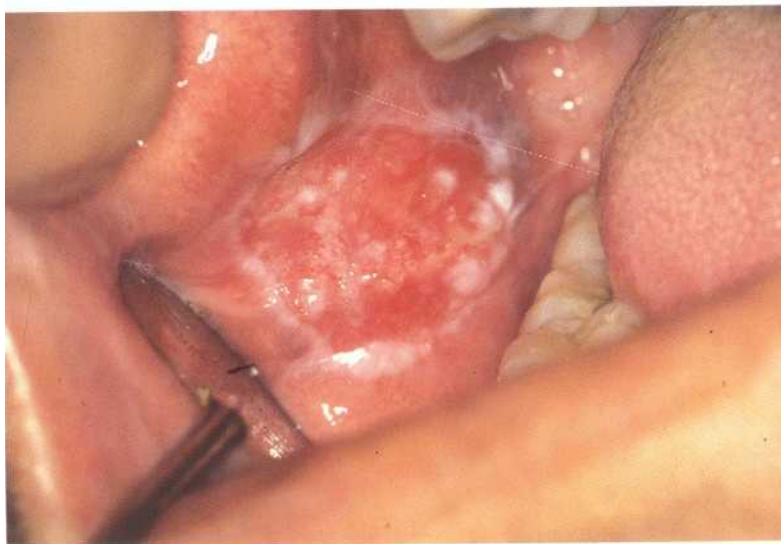


Fig. 303. Discoid lupus erythematosus, typical lesion on the buccal mucosa.

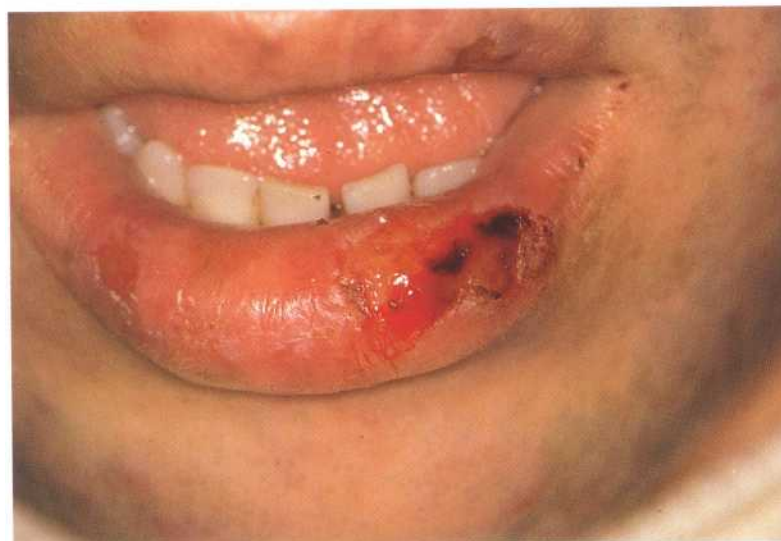
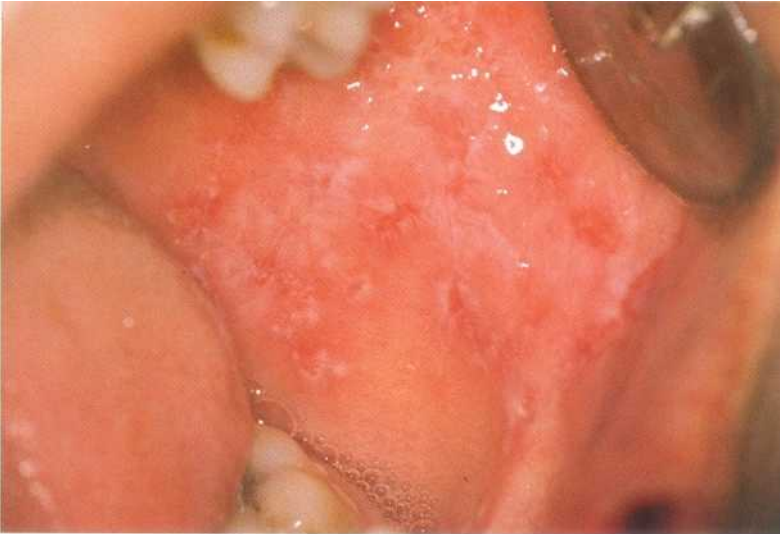
Fig. 304. Discoid lupus erythematosus, ulcer on the lower lip.





**Fig. 305. Systemic lupus erythematosus, multiple erosions surrounded by a whitish or reddish zone.**

### Systemic Lupus Erythematosus

Systemic lupus erythematosus (SLE) is a serious systemic disease involving the skin, mucosae, cardiovascular and gastrointestinal systems, lungs, kidneys, joints, and nervous system. It is accompanied by fever, fatigue, weight loss, lymphadenopathy, and debilitation. The oral mucosa is involved in 30 to 45% of the cases. Clinically, there are extensive painful erosions, or ulcers surrounded by a reddish or whitish zone (Fig. 305). Frequent findings include petechiae, edema, hemorrhages, and xerostomia. White hyperkeratotic lesions are rarely observed.

The palate, lips, and buccal mucosa are the most frequently involved sites.

The oral manifestations of SLE are not pathognomonic.

The differential diagnosis includes cicatricial pemphigoid, erosive lichen planus, pemphigus, bullous pemphigoid, erythema multiforme, and dermatomyositis.

**Laboratory tests.** Histopathologic and immunofluorescent studies of biopsy specimens are essential to make the diagnosis. The presence of anti-double-stranded DNA antibodies in the serum and hematologic abnormalities are also helpful in establishing the diagnosis.

**Treatment.** Depending on the overall clinical severity of the disease, therapy consists of systemic steroids, nonsteroidal anti-inflammatory drugs, antimalarials, immunosuppressants, and plasmapheresis if immune complexes are present.

### Scleroderma

Scleroderma is a chronic connective tissue disorder often classified as an autoimmune disease, although the precise cause is unknown. It primarily affects women between 30 and 40 years of age. Two forms of the disease are distinguished: localized scleroderma (morphea) and progressive systemic sclerosis. The localized form has a favorable prognosis and involves the skin alone, whereas the systemic form of the disease is characterized by multisystem involvement, including the skin and oral mucosa. Initially, the skin is edematous, but, as the disease progresses, it becomes thin, hard, and inelastic, with a pale appearance. Skin necrosis and ulcer occur in severe cases (Fig. 306). Involvement of the facial skin results in a characteristic facies with a small, sharp nose, expressionless stare, and narrow oral aperture (Fig. 307). Raynaud's phenomenon is usually present. The oral mucosa is pale and thin with a smooth dorsal surface of the tongue due to papillary atrophy (Fig. 308). Frequent findings include smoothing out of the palatal folds, and short and hard tongue frenulum, which results in dysarthria. As the disease progresses, there are limitations of mouth opening and induration of the tongue and gingiva. A clinical variant of scleroderma is the CREST syndrome, which is characterized by a combination of calcinosis cutis, Raynaud's phenomenon, esophageal dysfunction, sclerodactyly, and telangiectasia. Telangiectasia can occur on the lips and oral mucosa (Fig. 309).

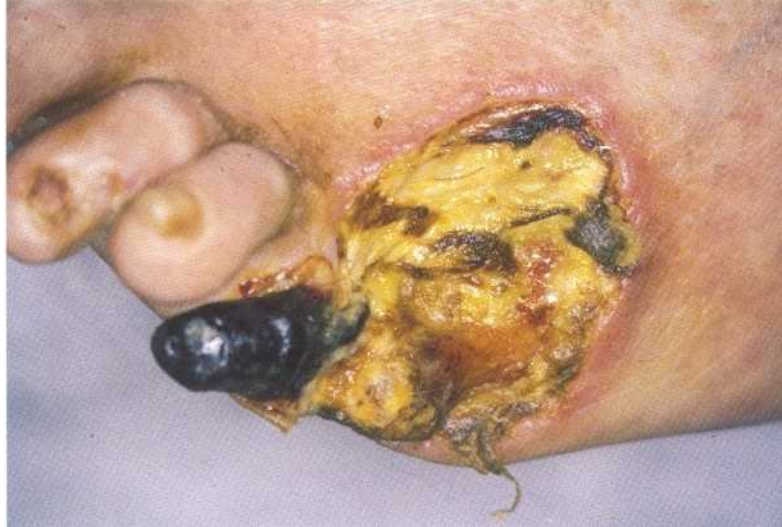

Fig. 306. Progressive systemic sclerosis, ulcer and gangrene of the skin and toe.



Fig. 307. Progressive systemic sclerosis, characteristic facies.

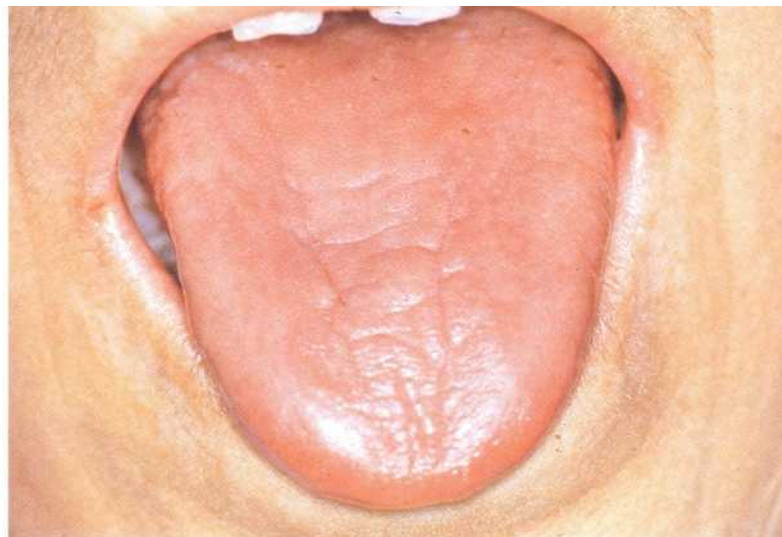
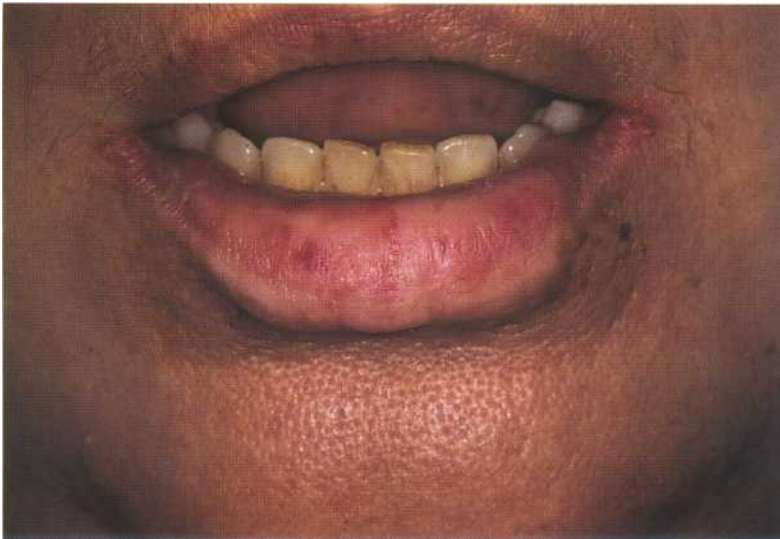
Fig. 308. Progressive systemic sclerosis, pale and atrophic epithelium of the dorsum of the tongue.



**Fig. 309. CREST syndrome, lip telangiectasia.**

The differential diagnosis of the oral lesions includes oral submucous fibrosis, cicatricial pemphigoid, epidermolysis bullosa, and lipoid proteinosis.

**Laboratory tests.** Histopathologic examination of biopsy specimens is indispensable for diagnosis. Radiographs show characteristic widening of the periodontal space in about 20% of the cases of systemic sclerosis. Various serum antibodies are present. Anticentromere antibodies have been reported to characterize the CREST syndrome.

**Treatment.** The treatment of scleroderma remains unsatisfactory. Topical and systemic steroids, anti-malarials, potassium p-aminobenzoate (Potaba), D-penicillamine, azathioprine and other immunosuppressives, nifedipine, and other agents have been tried.

### **Dermatomyositis**

Dermatomyositis is an uncommon inflammatory disease that is characterized by polymyositis and dermatitis. The cause is unknown, although an autoimmune mechanism seems probable. A viral infection of the skeletal muscle is another theory. A classification of dermatomyositis into five groups has been suggested. The disease most frequently affects women, more than 40 years of age. It may be associated with cancers in 10 to 20% of the cases. Progressive symmetrical muscle weakness is usually the first and most important clinical manifestation in the majority of patients with der-

matomyositis. Myalgia and malaise accompanied by fever are prominent early features.

In about 30% of the cases a purplish-red periorbital discoloration and a telangiectatic erythema at the nail margins are the initial manifestations. During its course, the disease is manifested by an erythematous, scaly papulomacular rash, skin discoloration, hyperpigmentation, and atrophy (Fig. 310). The oral cavity is uncommonly involved. The most frequent lesions are redness, painful edema, or ulcers on the tongue, the soft palate, the buccal mucosa, and uvula (Fig. 311).

The differential diagnosis includes SLE, angio-neurotic edema, and stomatitis medicamentosa.

Laboratory tests helpful in the diagnosis are serum enzyme determination (creatinine phosphokinase, aspartate transaminase, alanine transaminase), serum creatinine, electromyography and histopathologic examination of biopsy specimens.

**Treatment.** Steroids are the cornerstone. Cytotoxic drugs should be used when the disease is severe. Plasmapheresis has been used effectively.

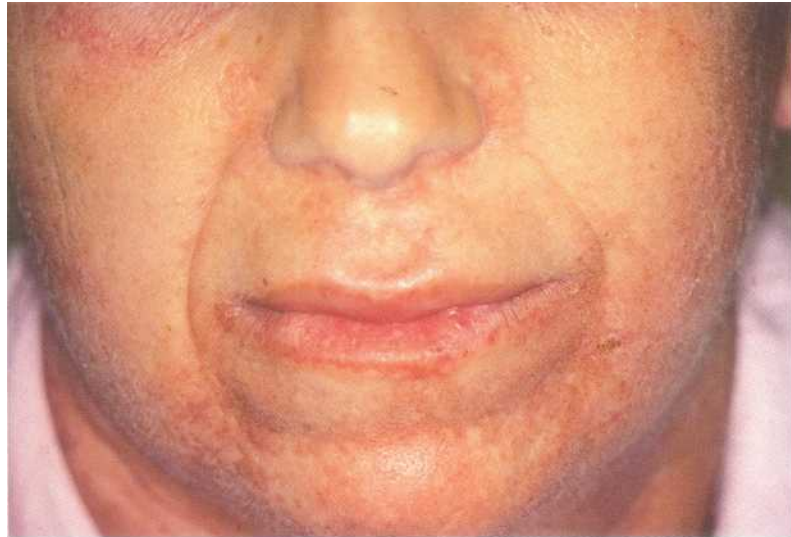

Fig. 310. Dermatomyositis, edema and maculopapular rash on the skin of the face.

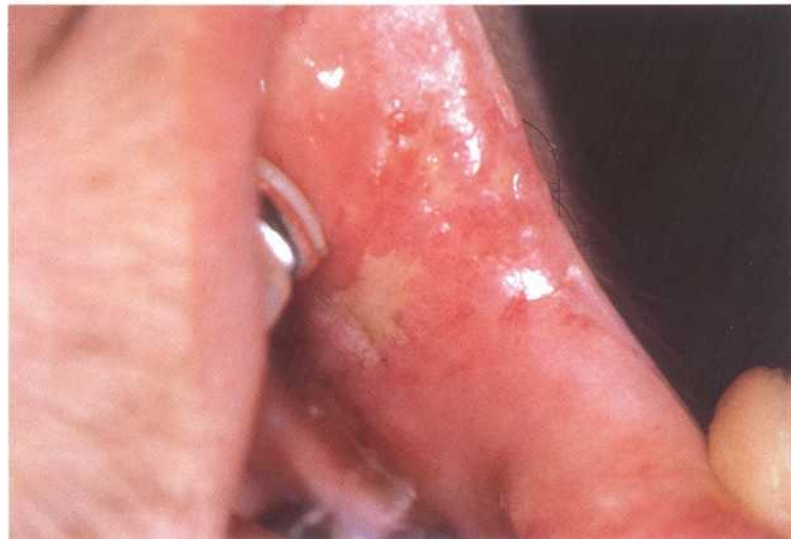

Fig. 311. Dermatomyositis, erythema, edema, and ulcer on the buccal mucosa.

### Mixed Connective Tissue Disease

Mixed connective tissue disease (MCTD) is a multisystemic disorder characterized by a combination of clinical features similar to those observed in systemic lupus erythematosus, scleroderma, polymyositis, and rheumatoid arthritis, which is characteristically associated with high titers of antibody to a nuclear ribonucleoprotein antigen. The cause and pathogenesis of mixed connective tissue disease is unknown. Females are more commonly affected, with a mean of 35 years.

Clinically, the disease is characterized by Raynaud's phenomenon, polyarthralgia or arthritis, sclerodactyly or diffuse swelling of the hands, inflammatory myopathy, pulmonary and esophageal involvement, skin and mucosal lesions, and lymphadenopathy. Less common clinical manifestations are musculoskeletal abnormalities, cardiac and renal disorders, neurologic abnormalities, intestinal involvement, and Sjogren's syndrome. Orofacial manifestations of mixed connective tissue disease include Sjogren's syndrome, trigeminal neuropathy, and peripheral facial paralysis. Rarely telangiectasia and erosions of the oral mucosa may be seen (Fig. 312).

The differential diagnosis includes Sjogren's syndrome and oral manifestations of other connective tissue diseases.

**Laboratory test.** Almost all patients have characteristically high titers of antibody to nuclear ribonucleoprotein (RNP) antigen.

**Treatment.** Systemic corticosteroid, nonsteroidal anti-inflammatory drugs, chloroquine, and, in severe cases, cytotoxic agents have been used.

### Sjogren's Syndrome

Sjogren's syndrome is a chronic autoimmune exocrinopathy that predominantly involves lacrimal, salivary, and other exocrine glands, resulting in a decreased secretion. Most frequently, it affects women in the fourth and fifth decades and is characterized by xerostomia and keratoconjunctivitis sicca. Recent clinical, serologic, and genetic criteria have been used to distinguish two forms of the disease: primary and secondary. Sjogren's syndrome is primary when it is not accompanied by a collagen disease and secondary if it coexists with collagen diseases, such as rheumatoid arthritis, SLE, polymyositis, or with primary biliary cirrhosis, thyroiditis, vasculitides, or cryoglobulinemia. The cardinal clinical manifestations

include a recurrent enlargement of the parotid, submandibular (Fig. 313), and lacrimal glands, lymphadenopathy, purpura, Raynaud's phenomenon, myositis, renal and pulmonary manifestations that occur in varying frequencies, depending on whether the disease is primary or secondary. Xerostomia is the classic finding in the oral cavity. The oral mucosa is reddish, dry, smooth, shiny, and the tongue is smooth with furrowing and appears lobulated (Fig. 314). Frequent findings include dysphagia, candidosis, cheilitis, and dental caries. Oral involvement is usually more severe in primary Sjogren's syndrome. The prognosis remains uncertain, and there is an increased risk of lymphomas in patients with enlarged parotids.

The differential diagnosis of oral lesions should include xerostomia due to other causes (such as drugs, neurologic disorders), iron deficiency anemia, systemic sclerosis, Mikulicz's syndrome, Heerfordt's syndrome, and sialosis.

Laboratory tests useful to establish the diagnosis include Schirmer's lacrimation test, determination of salivary flow rate, histopathologic examination of a biopsy from the lower lip, sialography, and scintigraphy. Many Sjogren's patients have a positive ANA test. Specific antibodies such as anti-SS-A(Ro) and anti-SS-B(La) are found in patients with Sjogren's syndrome.

Treatment is directed toward maintenance of oral hygiene. Artificial saliva and sialagogues may alleviate dryness of the mouth. Artificial tears are indicated. Systemic steroids and other immunosuppressants may be used.

Fig. 312. Mixed connective tissue disease, multiple palatal erosions.

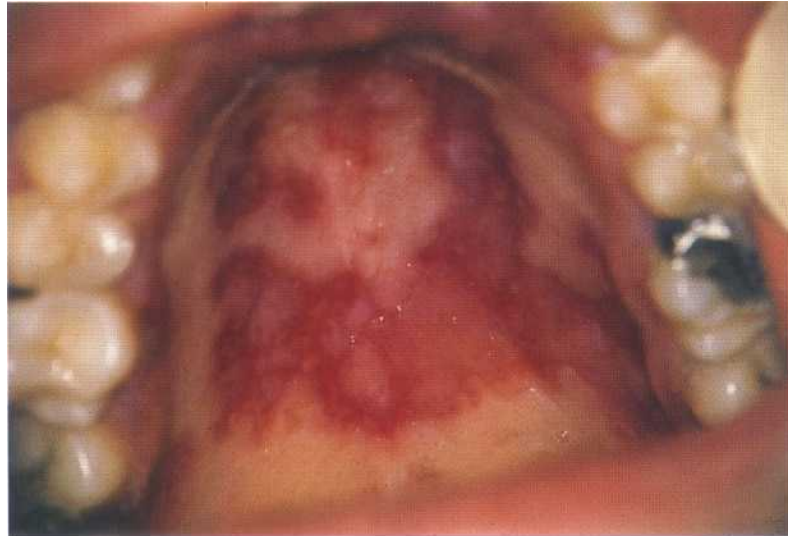


Fig. 313. Sjogren's syndrome, bilateral enlargement of the submandibular glands.

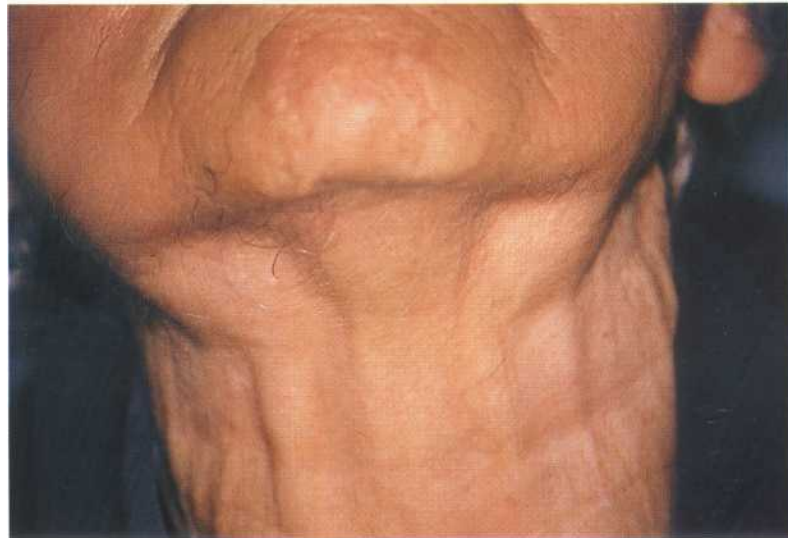
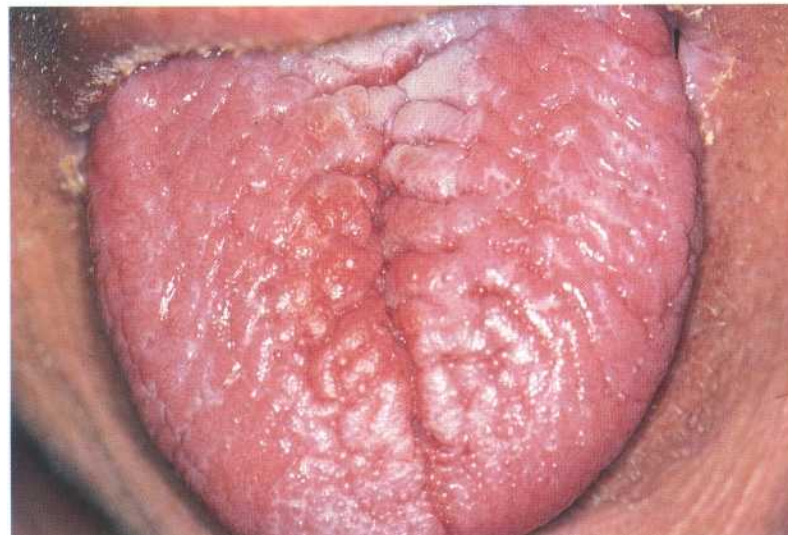
Fig. 314. Sjogren's syndrome, dry and lobulated tongue.



### Benign Lymphoepithelial Lesion

The term "benign lymphoepithelial lesion" is used to define a localized lymphocytic infiltration of the salivary and lacrimal glands. Some investigators classify this lesion as a monosymptomatic form of Sjogren's syndrome. It affects most frequently middle-aged women. Clinically, there are small raised painless nodules of minor salivary glands, usually on the posterior part of palate (Fig. 315).

When the parotids are involved, there is a painless symmetrical enlargement that may cause mild xerostomia and an uncomfortable feeling.

The duration of the disease may extend over months or years, with fluctuations in the size of the lesion.

The differential diagnosis includes necrotizing sialometaplasia and minor salivary gland tumors.

Laboratory test. Histopathologic examination is definitive in establishing the diagnosis.

Treatment. Steroids and nonsteroid anti-inflammatory agents are the usual therapeutic measures.

### Primary Biliary Cirrhosis

Primary biliary cirrhosis is a serious autoimmune disease characterized by intrahepatic cholestasis leading to hepatic cirrhosis. Most frequently, it affects women in the fourth to sixth decades. The cardinal clinical manifestations are jaundice, pruritus, and cutaneous xanthomas. Late manifestations are portal hypertension and the sequelae of cirrhosis (ascites, esophageal varices, encephalopathy, osteomalacia, etc.). During the late stages of the disease, the oral mucosa is red, thin, and atrophic with telangiectasias (Fig. 316).

The differential diagnosis includes mainly lupus erythematosus, scleroderma and CREST syndrome.

Laboratory tests helpful for diagnosis include serologic and immunologic tests and liver biopsy.

Treatment is managed by a team of specialists.

### Lupoid Hepatitis

Lupoid hepatitis is a form of chronic active hepatitis of autoimmune origin, which most frequently affects young women. In addition to liver involvement there are frequently renal, arthritic, lung, and bowel manifestations, hemolytic anemia, and amenorrhea.

Rarely, the oral mucosa is involved. Figure 317 shows a patient with erythematous and edematous gingiva that are tender on palpation. The only difference from desquamative gingivitis is that friction did not cause detachment of the epithelium.

The differential diagnosis includes desquamative gingivitis and plasma cell gingivitis.

Laboratory tests helpful for diagnosis include serologic and immunologic examination and liver biopsy.

Treatment is managed by a team of specialists.

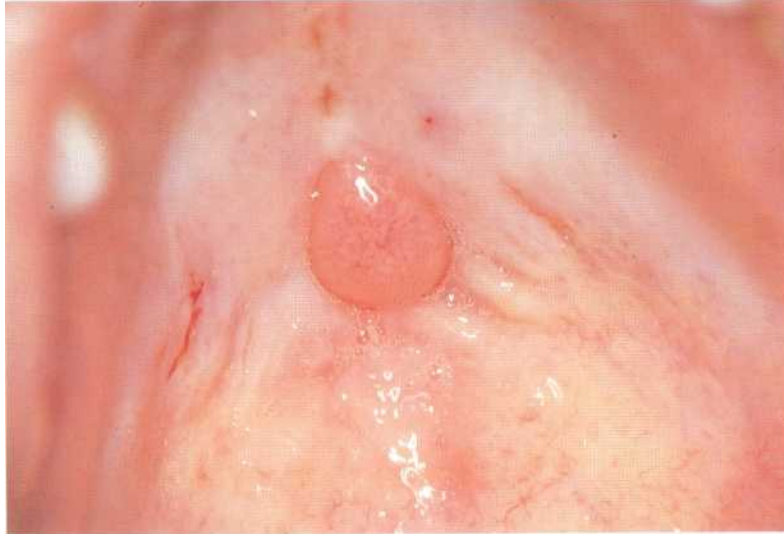

Fig. 315. Benign lymphoepithelial lesion, nodule on the palate.

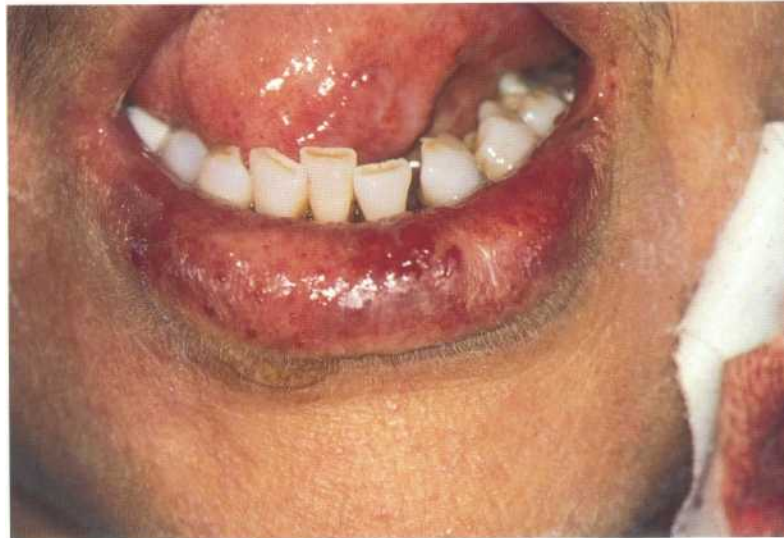

Fig. 316. Primary biliary cirrhosis, telangiectasias of the lower lip.

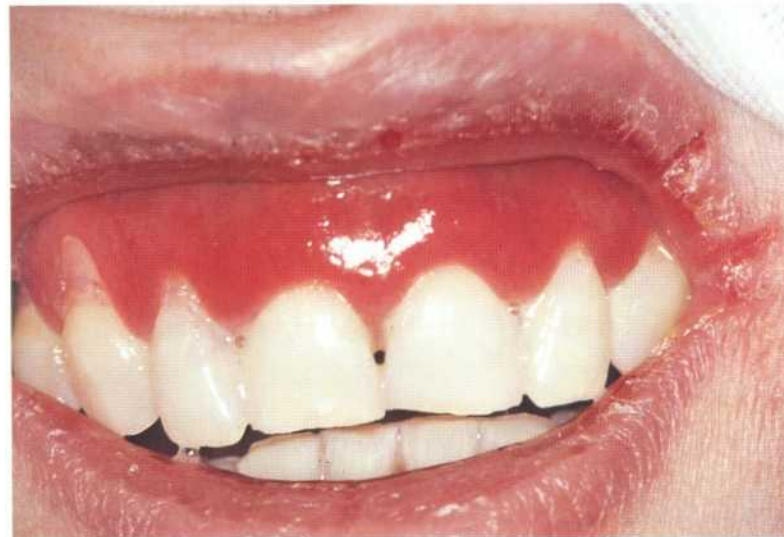

Fig. 317. Lupoid hepatitis, diffuse edema and erythema of the upper gingiva.



## 22. Skin Diseases

### Erythema Multiforme

Erythema multiforme is an acute or subacute self-limiting disease that mainly involves the skin and mucous membranes. Although the exact cause is obscure, a plethora of different agents, such as drugs, infections, radiation, endocrine factors, neoplasia, collagen diseases, and physical factors have been implicated. Immunologic disturbances have also been described. Erythema multiforme occurs chiefly in young adults between 20 and 40 years of age. Men are more frequently affected than women. The disease affects mainly the skin and has a sudden onset with the occurrence of red macules and papules in a symmetrical pattern on the palms and soles and less commonly on the face, neck, and trunk. These lesions are small and may increase in size centrifugally, reaching a diameter of 1 to 2 cm in 24 to 48 hours. The periphery remains erythematous, but the center becomes cyanotic or even purpuric, forming the characteristic target or iris lesion (Fig. 318).

Rarely, bullae develop on preexisting maculopapular lesions, giving rise to the bullous form of the disease. In the oral cavity small vesicles develop that rupture and leave an eroded surface covered by a necrotic pseudomembrane. Lesions may be seen anywhere in the mouth, but the lips and the anterior part of the mouth are most commonly involved (Fig. 319). Conjunctivitis, balanitis, and vaginitis may also be present. Fever, malaise, and arthralgias are also common. The diagnosis is primarily based on clinical criteria.

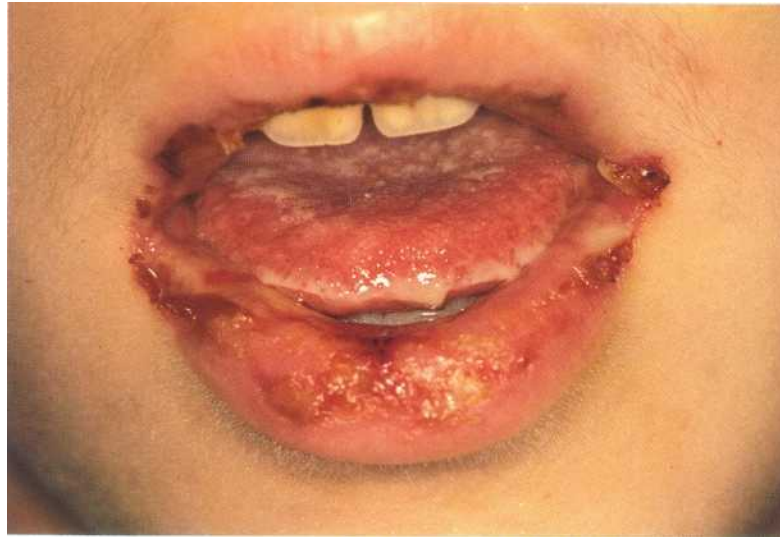
The differential diagnosis includes stomatitis medicamentosa, Stevens-Johnson syndrome, toxic epidermal necrolysis, pemphigus, bullous and erosive lichen planus, cicatricial pemphigoid, bullous pemphigoid, primary herpetic gingivostomatitis, and recurrent aphthous ulcers.

Laboratory findings. A histopathologic examination of the lesions is suggestive of the disease.

Treatment. Systemic steroids.

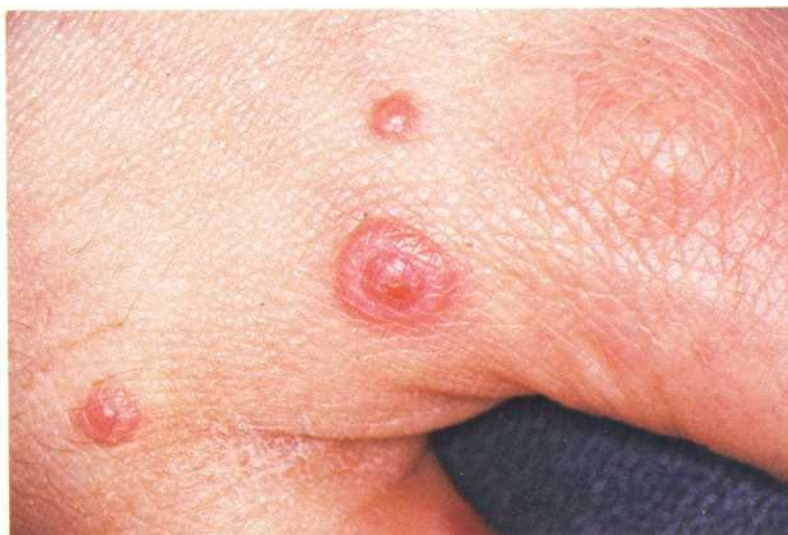

Fig. 318. Erythema multiforme, typical target (iris)-like lesions of the skin.



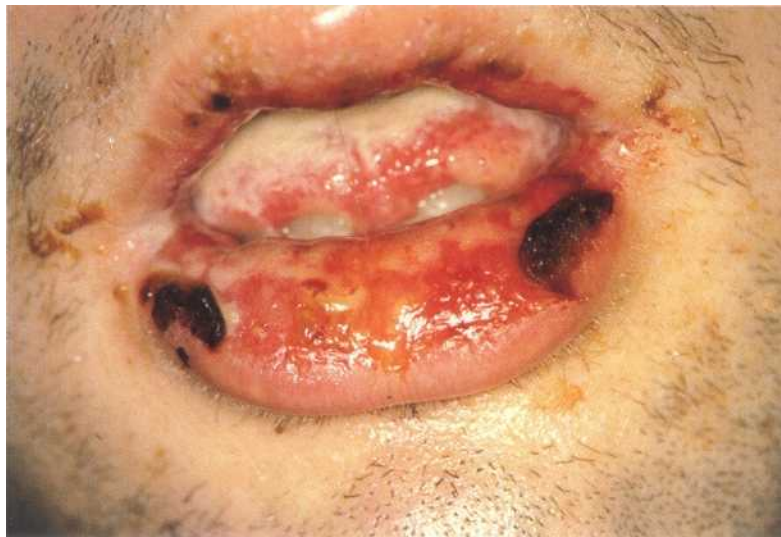**Fig. 319.** Erythema multiforme, multiple erosions on the lips and tongue.

### Stevens-Johnson Syndrome

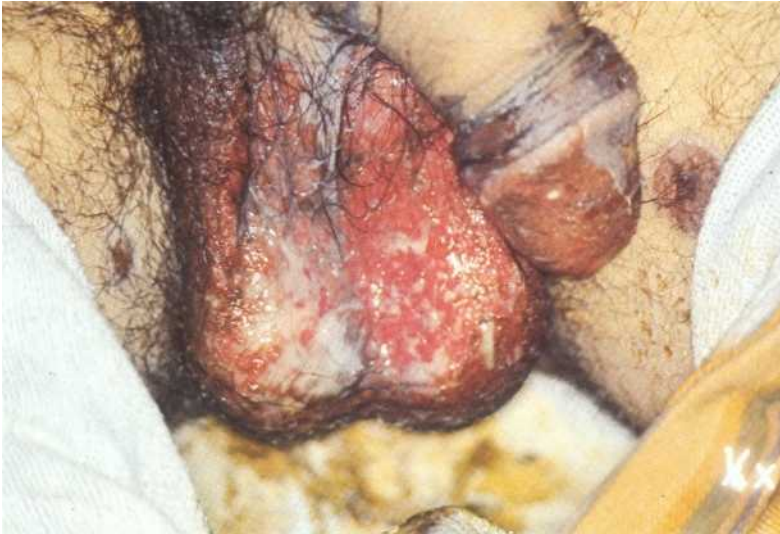Stevens-Johnson syndrome is recognized as a severe form of erythema multiforme that predominantly involves the mucous membranes. Prodromal systemic illness (fever, cough, weakness, malaise, sore throat, arthralgias, myalgias, diarrhea, etc.) usually precedes the appearance of bullae and erosions on the mucous membranes.

The oral mucosa is invariably involved, with extensive formation of bullae followed by

extremely painful erosions covered by grayish-white or hemorrhagic pseudomembranes (Fig. 320). The lips usually show characteristic bloody crusting. Erosions may extend to the pharynx, larynx, esophagus, and respiratory system. The ocular lesions consist of conjunctivitis, but corneal ulceration, anterior uveitis, or panophthalmitis are not rare and sometimes may lead to symblepharon, corneal opacity or even blindness. The genital lesions (Fig. 321) consist of balanitis or vulvovaginitis, which in some cases result in



**Fig. 320.** Stevens-Johnson syndrome, widespread erosions covered by hemorrhagic crusting on the lips and tongue.



**Fig. 321. Stevens-Johnson syndrome, genital lesions.**

phimosis or cicatrization of the vagina. The skin lesions are variable in extent. They may be either the typical maculopapular eruption of erythema multiforme, but more commonly are bullous or ulcerative (Fig. 322).

Pneumonia and renal involvement have been reported in severe cases. The mortality rate of untreated patients ranges from 5 to 15%. Diagnosis is based mainly on clinical criteria.

The differential diagnosis of the oral lesions includes erythema multiforme, Behcet's syndrome, toxic epidermal necrolysis, pemphigus vulgaris, bullous pemphigoid, and cicatricial pemphigoid.

Laboratory findings. Histopathologic examination is supportive of the diagnosis.

Treatment. Large doses of systemic steroids and antibiotics if considered necessary.

### Toxic Epidermal Necrolysis

Toxic epidermal necrolysis, or Lyell's disease, is a severe skin disease with high mortality and is characterized by extensive eruption and detachment of the necrotic epidermis.

A great variety of etiologic factors have been incriminated, but mainly drugs, such as antibiotics, sulfonamides, sulfones, nonopioid analgesics, nonsteroidal anti-inflammatory agents, and anti-epileptic drugs, are thought to be responsible for the disease. Viral, bacterial, and fungal infection, malignant diseases, and radiation have also been

considered as possible causative factors. The pathogenesis of the disease still remains unclear, and an underlying immune mechanism seems most probable. Clinically, the disease usually appears with slight malaise, low-grade fever, arthralgias, skin tenderness, burning sensation of the conjunctivae, and erythema, which begins on the face and extremities and rapidly extends to the whole body surface with the exception of the hairy parts. Within 24 hours, blisters filled with clear fluid appear, and the erythematous skin is lifted up so that the whole body surface appears scalded (Fig. 323). Nikolsky's sign becomes positive early in the course of the disease. In the oral mucosa there is severe inflammation, vesiculation, and painful widespread erosions, primarily on the lips, buccal mucosa, tongue, and soft palate (Fig. 324). Similar lesions may be seen on the eyelids, conjunctivae, genitals, and other mucous membranes. The prognosis is poor. Diagnosis is based on the clinical features.

The differential diagnosis includes erythema multiforme, Stevens-Johnson syndrome, bullous pemphigoid, pemphigus, and generalized bullous fixed-drug eruption.

Treatment. Systemic steroids, antibiotics, fluids and electrolytes.

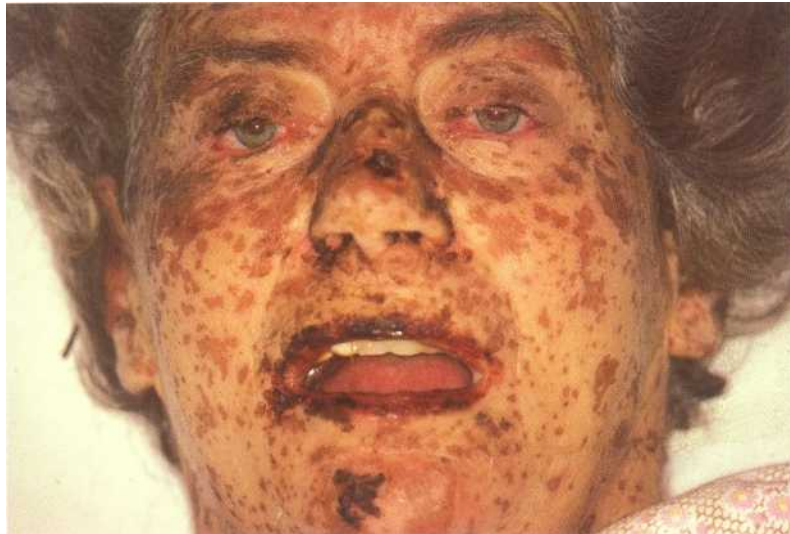

Fig. 322. Stevens-Johnson syndrome, widespread severe lesions on the lips, skin, and eyes.

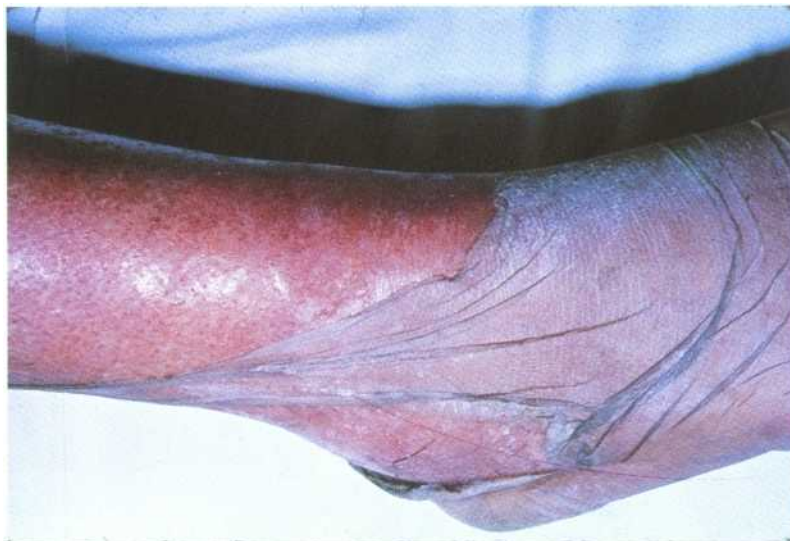

Fig. 323. Toxic epidermal necrolysis, characteristic detachment of epidermis, resembling scalding.

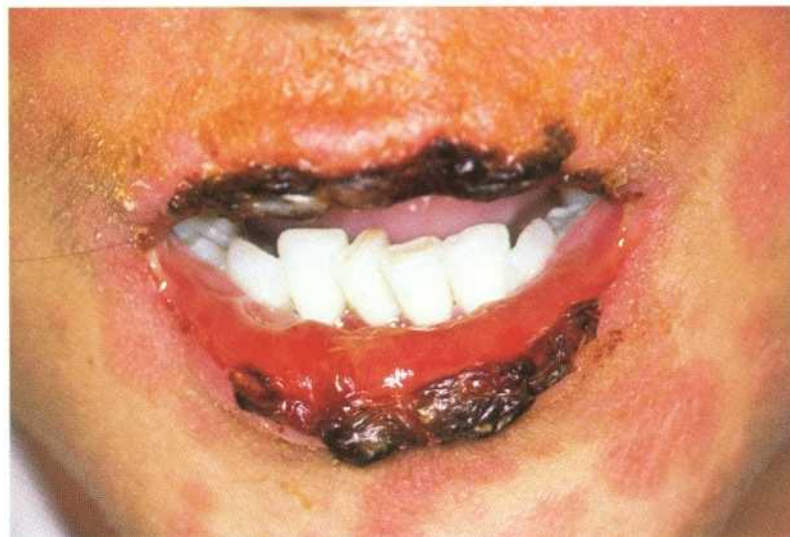
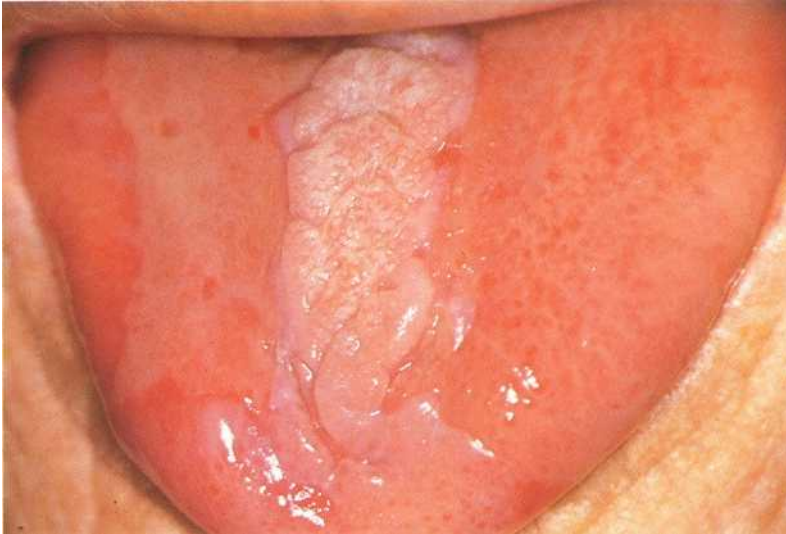
Fig. 324. Toxic epidermal necrolysis, severe erosions covered by hemorrhagic crusting on the lips.



**Fig. 325. Pemphigus vulgaris, erosions on the dorsum of the tongue.**

## Pemphigus

Pemphigus is a chronic autoimmune bullous disease that affects the skin and mucous membranes and has a reasonable prognosis. The disease shows a high incidence in Mediterranean races (Jews, Greeks, Italians) without, however, usually exhibiting any familial distribution. Our own data on 157 patients with pemphigus vulgaris, according to which women were more frequently affected than men (1.6: 1), with ages ranging from 18 to 92 years and a mean age at onset of 54.4 years, are consistent with other reports.

On the basis of clinical, histopathologic, and immunologic criteria, four varieties of pemphigus can be recognized: pemphigus vulgaris, pemphigus vegetans, pemphigus foliaceus, and pemphigus erythematosus, or Senear-Usher syndrome.

### Pemphigus Vulgaris

Pemphigus vulgaris is the most common form of the disease and represents 90 to 95% of the cases. It has been reported that in more than 68% of the cases the disease presents initially in the oral cavity, where it may persist for several weeks, months, or even years before extending to other sites. Clinically, bullae that rapidly rupture leaving painful erosions are seen (Fig. 325). They show little evidence of healing, extend peripherally, and the pain may be so severe that dysphagia can be a serious problem. A characteristic feature of the oral lesions of pemphigus is the presence of small linear discontinuities of the oral epithelium surrounding an active erosion, resulting in epithelial disintegration. Any site in the oral cavity may

be involved, but the soft palate, buccal mucosa, and lower lip predominate. Lesions on other mucosal surfaces (conjunctivae, larynx, nose, pharynx, genitals, anus) may eventually develop in about 13% of the cases (Fig. 326). On the skin, bullae that rupture easily, leaving eroded areas, are seen and exhibit a tendency to enlarge as the epidermis strips off at the edges (Fig. 327). Although any area of skin may be affected, the trunk, scalp, umbilicus, and the intertriginous regions are the most common sites of involvement. Loss of clinically healthy epidermis by rubbing is characteristic both on the skin and oral mucosa (Nikolsky's sign). When the disease is confined to the oral mucosa, diagnosis usually may be delayed for 6 to 11 months due to the nonspecific nature of oral lesions and the low index of suspicion.

The differential diagnosis of oral lesions includes cicatricial pemphigoid, bullous pemphigoid, dermatitis herpetiformis, erythema multiforme, erosive and bullous lichen planus, herpetic gingivostomatitis, aphthous ulcers, and amyloidosis.

### Pemphigus Vegetans

Pemphigus vegetans is a rare variant of pemphigus vulgaris. The skin eruption consists of bullae identical to those of pemphigus vulgaris, but the denuded areas soon develop hypertrophic granulations. They may occur in any part of the body, but are more common in the intertriginous areas. Lesions are rare in the mouth, but vegetating lesions may form at the vermilion border and angles of the lips (Fig. 328). The course and prognosis are similar to those of pemphigus vulgaris.

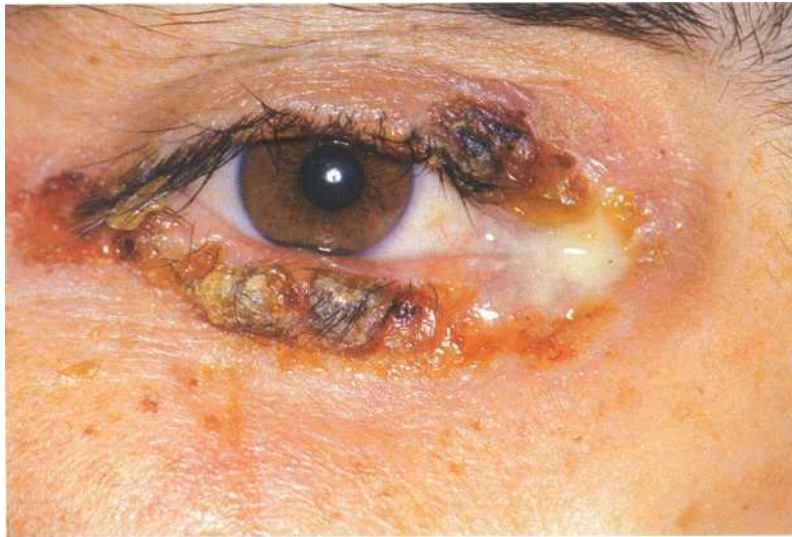

Fig. 326. Pemphigus vulgaris, ocular lesions.

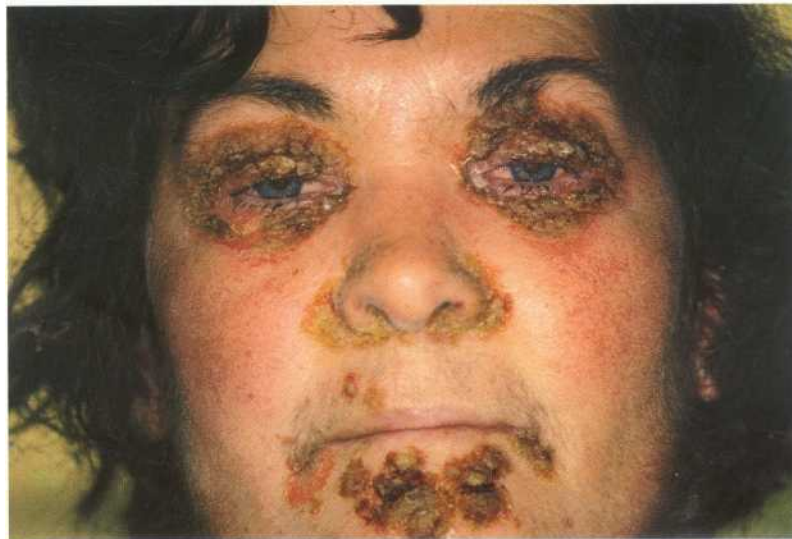

Fig. 327. Pemphigus vulgaris, severe lesions of the skin of the face.

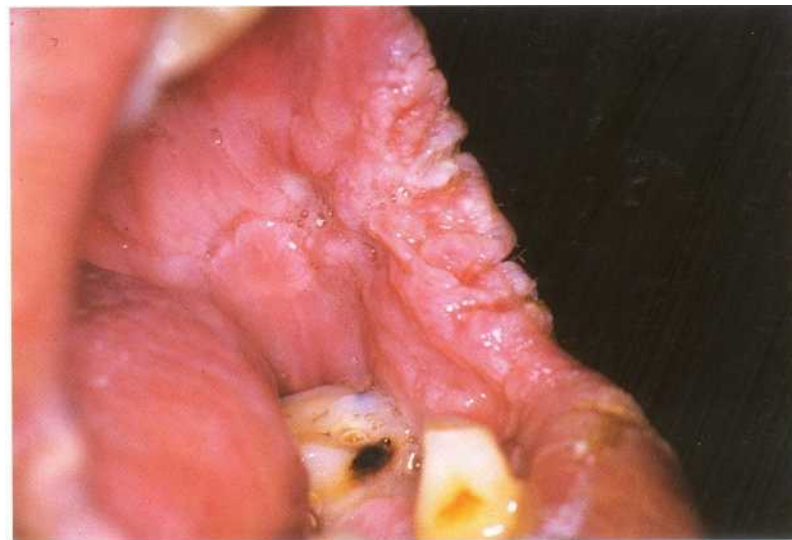
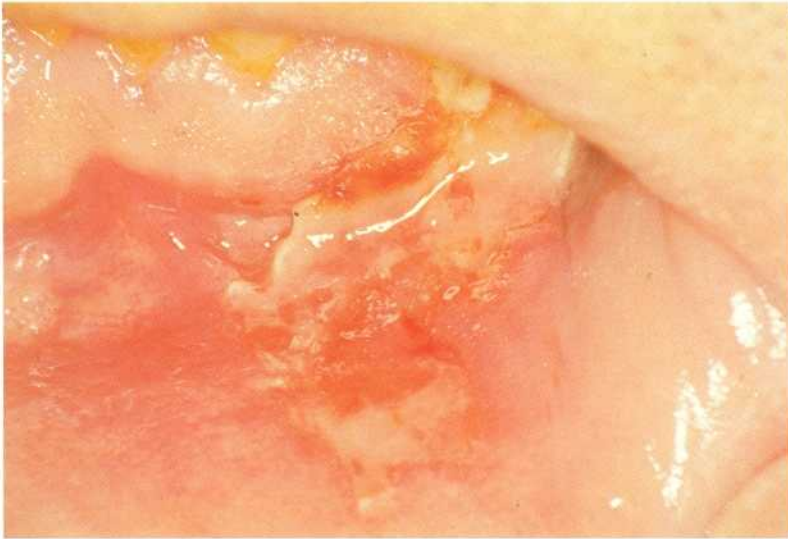

Fig. 328. Pemphigus vegetans, vegetating lesions on the buccal mucosa and commissure.



**Fig. 329. Pemphigus foliaceus, erosions on the mucolabial groove and lip mucosa.**

### **Pemphigus Foliaceus**

Pemphigus foliaceus represents a superficial, less severe but rare variant of pemphigus. The skin lesions are characterized by flaccid bullae on erythematous bases that rapidly rupture, leaving shallow erosions, scales, and crusted patches suggestive of seborrheic dermatitis. They usually develop on the scalp, face, and trunk. The lesions may spread to involve the entire skin, resembling a generalized exfoliative dermatitis. The oral mucosa is rarely affected with small superficial erosions (Fig. 329).

### **Pemphigus Erythematosus**

Pemphigus erythematosus is a rare superficial variety of pemphigus, with a mild course and usually a good prognosis. The disease is clinically characterized by an erythematous eruption similar to that of lupus erythematosus and by superficial bullae concomitant with crusted patches, resembling seborrheic dermatitis (Fig. 330). Sometimes, the disease coexists with lupus erythematosus, myasthenia gravis, and thymoma. The oral mucosa is very rarely affected with small erosions (Fig. 331).

Laboratory tests helpful in establishing the diagnosis in all forms of pemphigus are cytologic, histopathologic, and immunocytologic examinations, as well as direct and indirect immunofluorescence.

**Treatment.** Treatment of all forms of pemphigus includes systemic corticosteroids in high doses, azathioprine, cyclosporine, and cyclophosphamide; in severe cases plasmapheresis.

### **Juvenile Pemphigus Vulgaris**

Pemphigus very rarely affects persons less than 20 years of age. It is now well documented that pemphigus vulgaris, foliaceus, and erythematosus occur in children, too, but the oral mucosa is usually affected by pemphigus vulgaris. It has been reported that in 13 of 14 young patients with pemphigus vulgaris (93%) the disease began in the oral cavity and the female to male ratio was 1.8: 1. Clinically localized or widespread superficial erosions are seen, which may persist and exhibit a tendency to enlarge (Fig. 332). The clinical and laboratory features of juvenile pemphigus are similar to those seen in pemphigus of the adults.

The differential diagnosis includes other bullous diseases affecting children, such as herpetic gingivostomatitis, juvenile bullous pemphigoid, juvenile dermatitis herpetiformis, erythema multiforme, cicatricial pemphigoid of childhood, linear immunoglobulin A (IgA) disease of childhood.

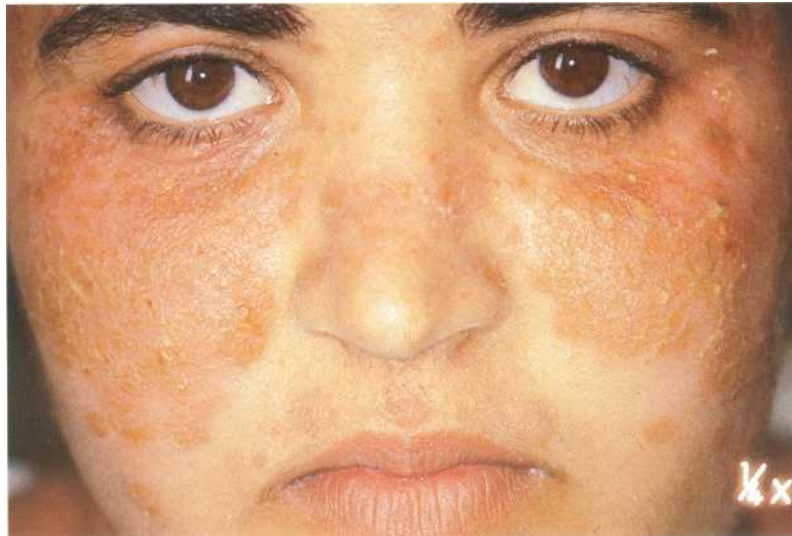

Fig. 330. Pemphigus erythematosus, characteristic erythema and superficial crusting lesions on the "butterfly" area of the face.

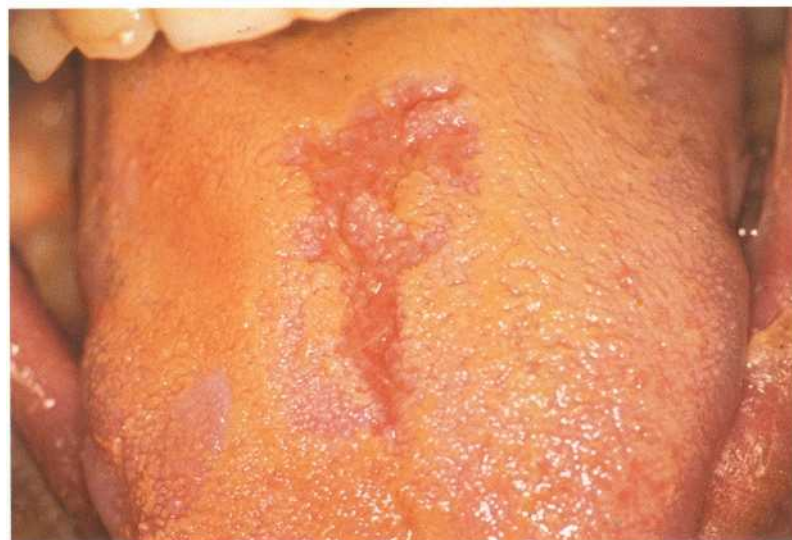

Fig. 331. Pemphigus erythematosus, localized erosion on the dorsum of the tongue.

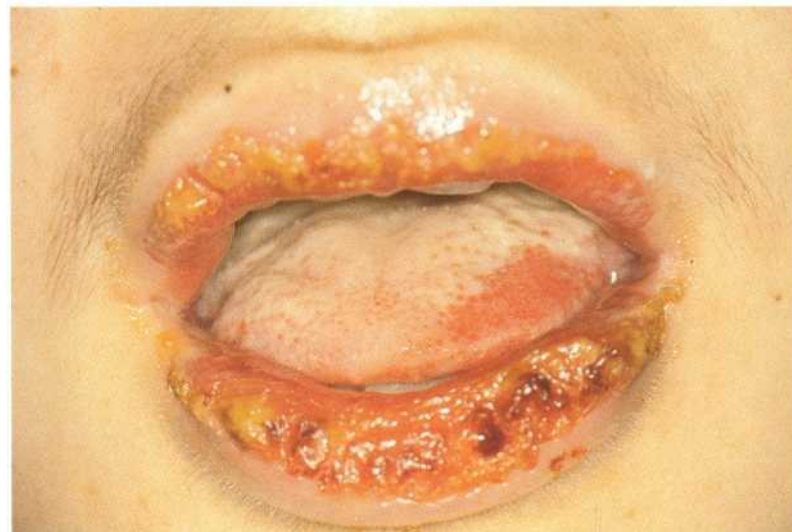
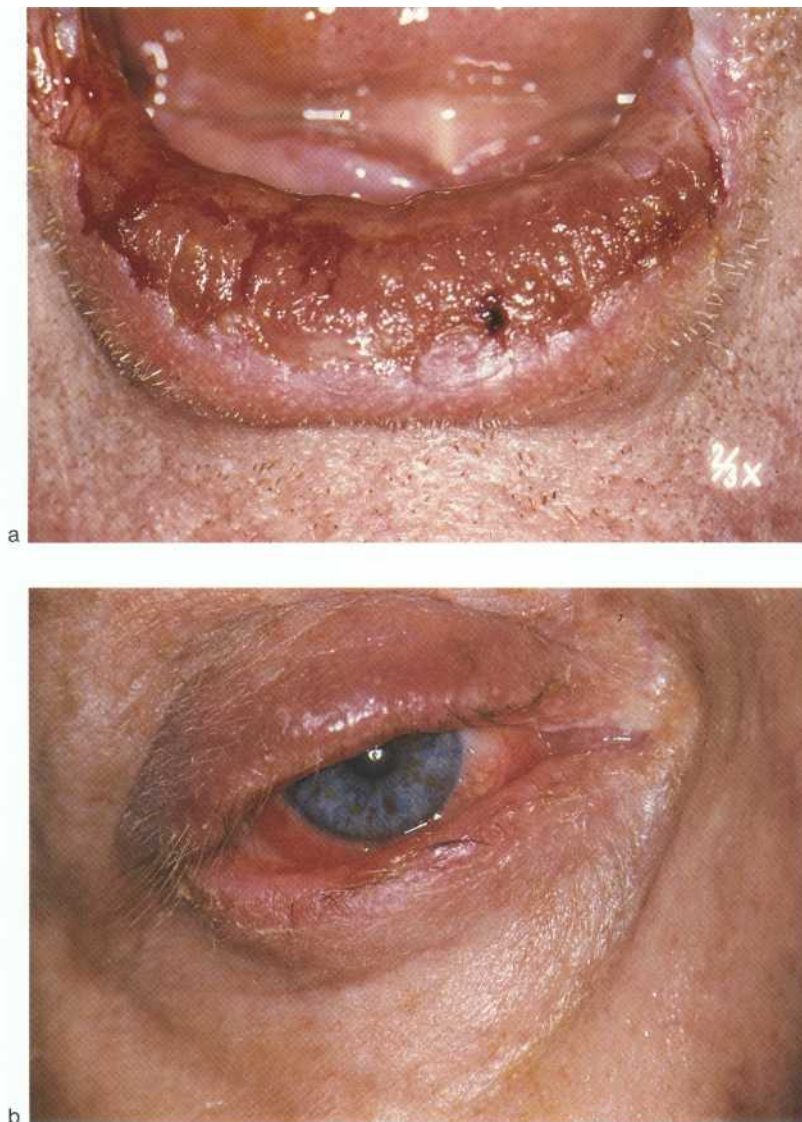
Fig. 332. Juvenile pemphigus vulgaris, severe erosions on the lips.





**Fig. 333. Paraneoplastic pemphigus.**  
**a** Persistent erosions of the lower lip.  
**b** Severe conjunctivitis and edema of the eyelid.

### Paraneoplastic Pemphigus

Paraneoplastic pemphigus is a rare recently described autoimmune variant of pemphigus characterized by skin and mucosal lesions in association with an underlying neoplasm, most frequently lymphoma and leukemia.

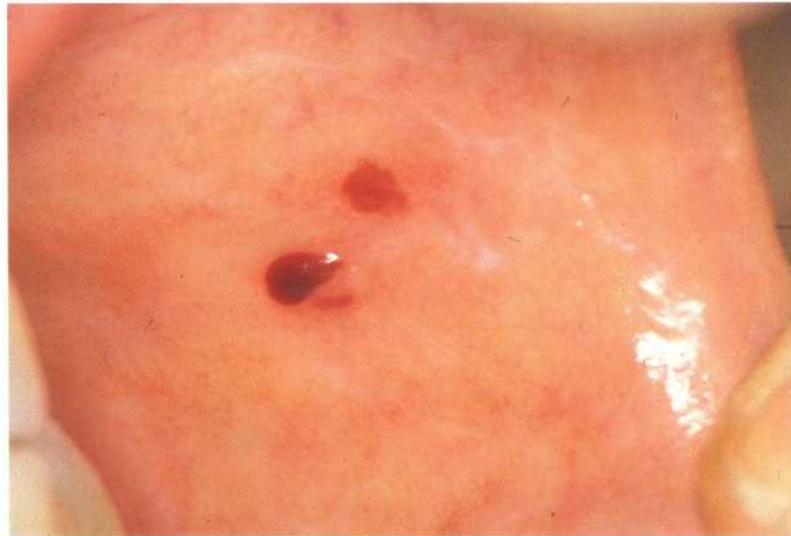The clinical features of the disease are characterized by a) polymorphous skin lesions often presented as papulosquamous eruptions with blister formation mainly on the palms and soles, b) painful, treatment-resistant erosions of the oral mucosa and the vermillion border of the lips (Fig. 333a), and c) persistent conjunctival erosions (Fig. 333b). On direct immunofluorescence IgG and C3 deposition in epidermal intercellular

spaces and along the basement membrane zone are common findings, and circulating "pemphigus-like" antibodies at high titer are also present. All reported patients with paraneoplastic pemphigus have had poor prognoses.

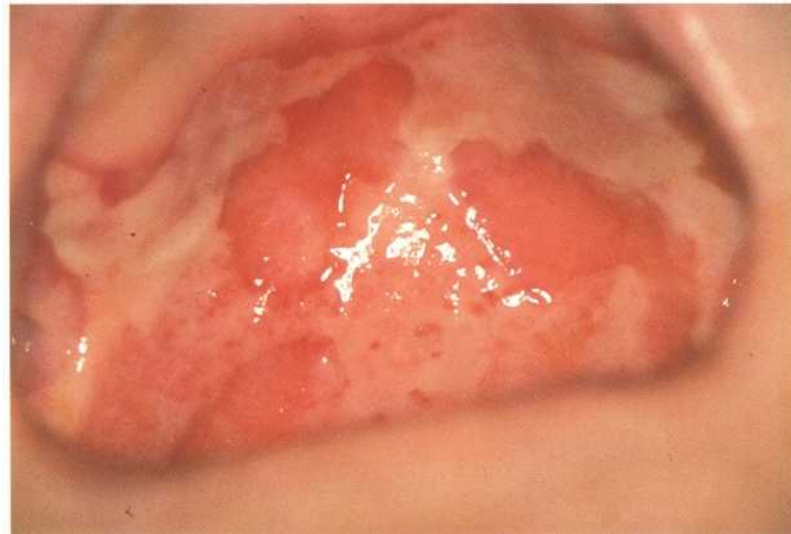The differential diagnosis includes other forms of pemphigus, erythema multiforme, cicatricial and bullous pemphigoid.

Laboratory tests. Helpful laboratory tests include histopathologic examination, direct and indirect immunofluorescence.

Treatment. Systemic corticosteroids in association with the treatment of underlying neoplasm.



**Fig. 334. Cicatricial pemphigoid, intact hemorrhagic bullae on the buccal mucosa.**

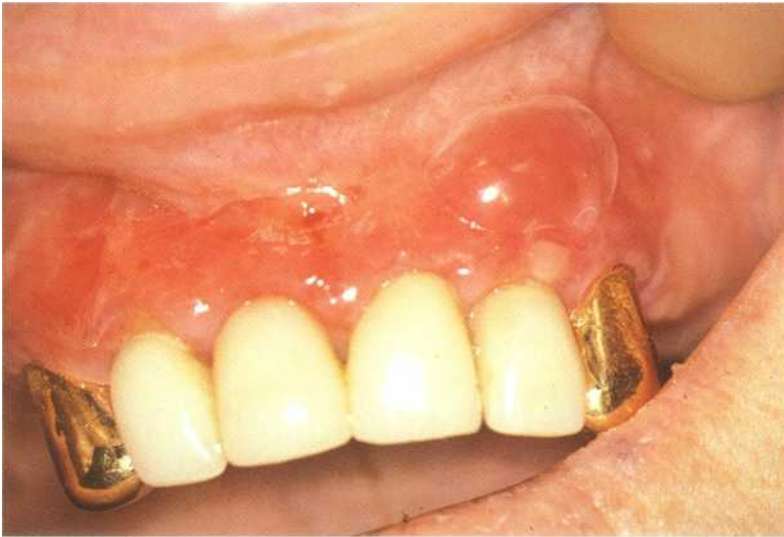

**Fig. 335. Cicatricial pemphigoid, severe erosions on the palate.**

### **Cicatricial Pemphigoid**

Cicatricial pemphigoid, or benign mucous membrane pemphigoid, is a chronic bullous disease of autoimmune origin that preferentially affects mucous membranes and results in atrophy of the epithelium and sometimes in scarring. The disease occurs more frequently in women than in men (1.5: 1), with a mean age of onset of 66 years. The oral mucosa is invariably affected and, in 95% of the cases, the mouth is the initial site of involvement. The most consistent oral lesions are those

involving the gingiva, although ultimately other sites in the oral cavity may be involved. The mucosal lesions are recurrent vesicles or small bullae that rupture, leaving a raw eroded surface that finally heals by scar formation (Fig. 334). Oral lesions are usually localized, and rarely widespread involvement is seen (Fig. 335). Frequently, the disease affects exclusively the gingiva in the form of desquamative gingivitis (Fig. 336). The ocular lesions consist of conjunctivitis, symblepharon, trichiasis, dryness, and opacity of the cornea frequently leading to complete blindness



**Fig. 336. Cicatricial pemphigoid, presenting as desquamative gingivitis.**

(Figs. 337, 338). Less commonly, other mucosae (genitals, anus, nose, pharynx, esophagus, larynx) are involved (Fig. 339). Skin lesions occur in about 10 to 20% of the cases and consist of bullae that usually appear on the scalp, face, and neck and may heal with or without scarring.

The differential diagnosis includes pemphigus vulgaris, bullous pemphigoid, linear IgA disease, bullous and erosive lichen planus, dermatitis herpetiformis, erythema multiforme, Stevens-Johnson syndrome, and lupus erythematosus.

**Laboratory tests.** Helpful laboratory tests include histopathologic examination and direct immunofluorescence of oral mucosa biopsy specimens.

**Treatment.** Systemic corticosteroid and immunosuppressive drugs. In mild cases topical steroids (cream or intralesional injection) may be useful.

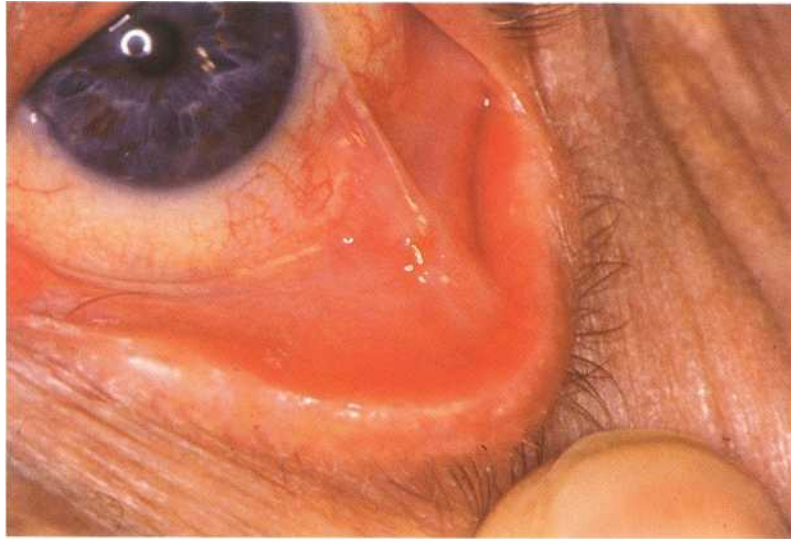


Fig. 337. Cicatricial pemphigoid, conjunctivitis and symblepharon.

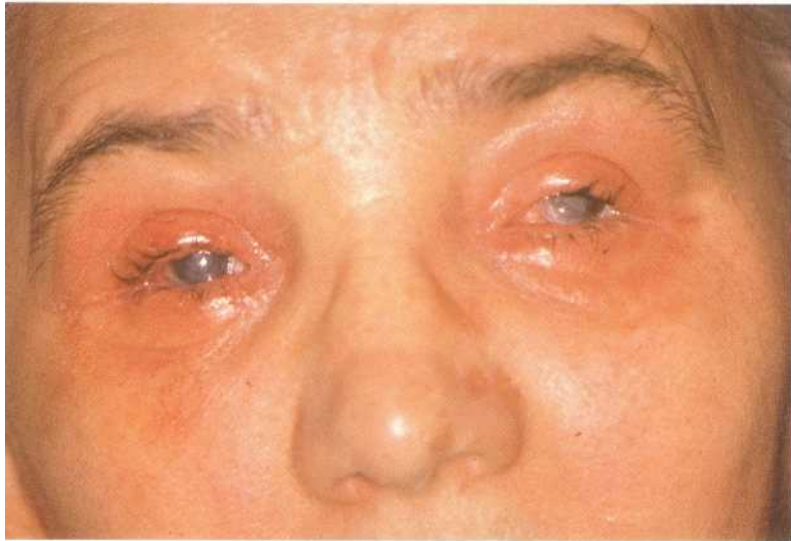

Fig. 338. Cicatricial pemphigoid, severe ocular lesions.

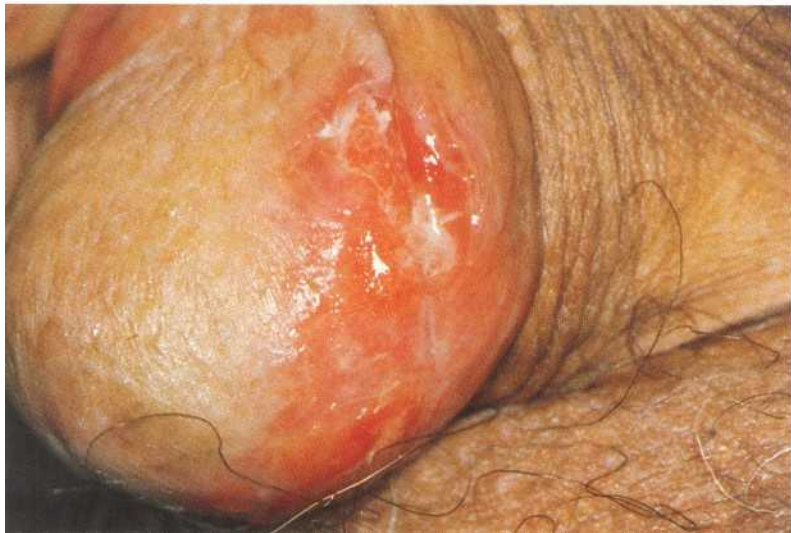

Fig. 339. Cicatricial pemphigoid, erosions and scarring on the penis.

### Childhood Cicatricial Pemphigoid

Cicatricial pemphigoid is a chronic autoimmune bullous disease that affects almost exclusively middle-aged and elderly persons. However, at least eight well-documented cases of cicatricial pemphigoid of childhood have been recorded so far. Five of the patients were girls and three were boys, aged 4 to 18 years. All patients except one had oral lesions, and in four, desquamative gingivitis was the cardinal manifestation of the disease (Fig. 340). The clinical manifestations of oral mucosa, eyes, genitalia, anus, and skin are identical to those seen in cicatricial pemphigoid of adulthood.

The differential diagnosis includes juvenile bullous pemphigoid, juvenile pemphigus, childhood dermatitis herpetiformis, childhood linear IgA disease, childhood chronic bullous disease, and epidermolysis bullosa.

Laboratory tests. Histopathologic examination as well as direct and indirect immunofluorescent tests confirm the diagnosis.

Treatment. Corticosteroids topically or systemically.

### Linear Immunoglobulin A Disease

Linear IgA disease has been recognized as a new nosologic entity in the spectrum of chronic bullous diseases. Linear IgA disease is rare and characterized by spontaneous bullous eruption on the skin and mucous membranes, and homogeneous IgA deposits along the dermoepidermal junction in uninvolved skin. The disease is more common in women than men, with an average age of onset between 40 and 50 years and has been described both in adults and children. Clinically, the rash is characterized by spontaneous blistering without scarring. In about 26% of the patients with linear IgA disease, oral lesions occur. These lesions appear as a bullous eruption that soon ruptures, leaving superficial localized, ulcerations without characteristic features (Fig. 341). Scarring conjunctivitis may also occur. Generally, the clinical manifestations of the disease are indistinguishable from those seen in cicatricial pemphigoid.

The differential diagnosis includes cicatricial pemphigoid, dermatitis herpetiformis, bullous pemphigoid, and chronic bullous disease of childhood.

Laboratory tests to confirm the diagnosis are direct and indirect immunofluorescence and histopathologic examination.

Treatment. Sulfones and systemic corticosteroids.

### Bullous Pemphigoid

Bullous pemphigoid is a chronic autoimmune mucocutaneous bullous disease that affects women more frequently than men (1.7: 1), with a mean age of onset of 65 years. However, well-documented cases have been described in childhood.

Clinically, the cutaneous lesions begin as a nonspecific generalized rash and ultimately large, tense bullae develop that rupture, leaving denuded areas without a tendency to extend peripherally. The eruption appears more commonly on the trunk, arms, and legs and may be localized or widespread (Fig. 342). The oral mucosa is affected in about 40% of the cases, usually after skin involvement.

Initial lesions appear in the oral cavity in only 6% of the cases. Clinically, bullae and ultimately erosions develop more frequently on the buccal mucosa, palate, tongue, and lower lip (Fig. 343). Gingival involvement as desquamative gingivitis is seen in 16% of the cases. Other mucous membranes, such as the conjunctiva, esophagus, vagina, and anus, may also be affected.

The disease has a chronic course with remissions and exacerbations and generally a good prognosis.

The differential diagnosis includes pemphigus vulgaris, cicatricial pemphigoid, dermatitis herpetiformis, linear IgA disease, erosive lichen planus, and discoid lupus erythematosus.

Laboratory tests helpful for the final diagnosis include histopathologic examination, as well as direct and indirect immunofluorescence.

Treatment. Systemic corticosteroids and sometimes immunosuppressive drugs. Sulfones and sulfapyridines have also been used.

Fig. 340. Childhood cicatricial pemphigoid, small hemorrhagic bulla on the gingiva in a 14-year-old girl.

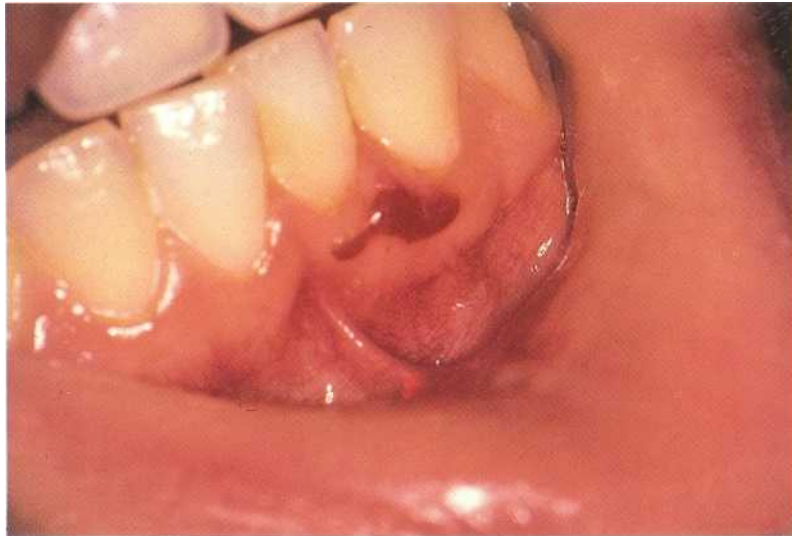

Fig. 341. Linear immunoglobulin A disease, erosion on the tongue covered by a whitish pseudo-membrane.

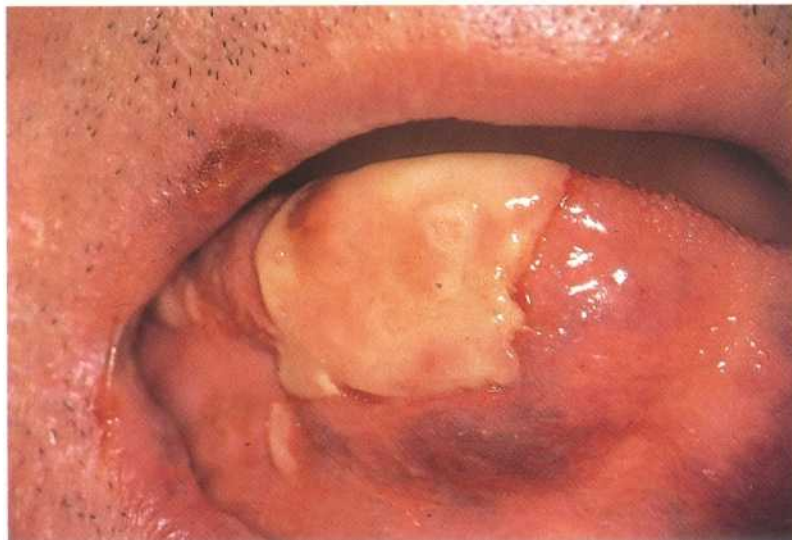
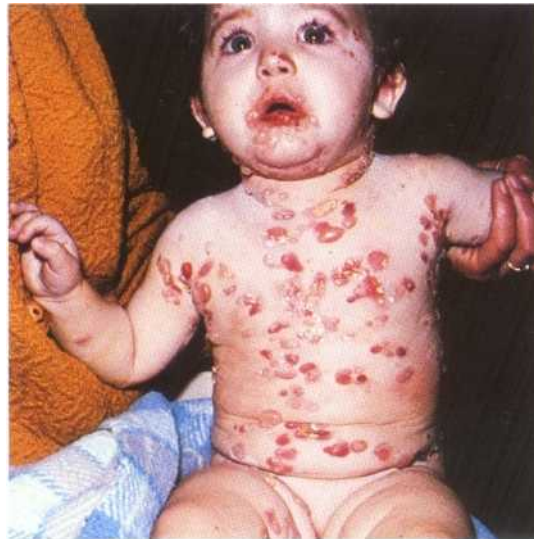
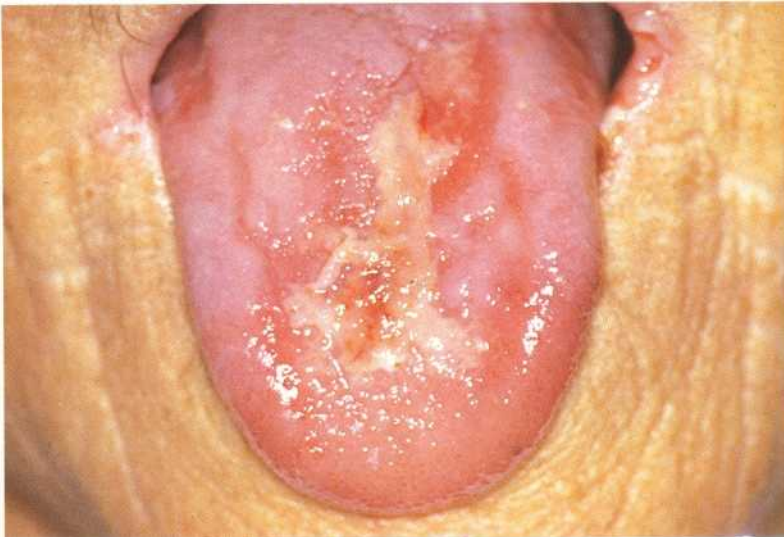Fig. 342. Bullous pemphigoid of childhood, generalized bullous lesions.





**Fig. 343. Bullous pemphigoid, erosions on the dorsum of the tongue.**

### Dermatitis Herpetiformis

Dermatitis herpetiformis, or Duhring-Brocq disease, is a chronic recurrent skin disease characterized by pruritus and a symmetrical papulovesicular eruption on the extensor surfaces of the skin. The disease occurs at any age, including childhood, but is more common between 20 and 50 years of age and males are more frequently affected than females.

The cause remains unknown, although the occurrence of IgA and C3 deposits in the upper dermis and at the dermoepidermal junction suggests that immunologic mechanisms may play a role in the pathogenesis of the disease. In addition, immunogenetic studies have shown an increased frequency of HLA-B8, HLA-A1, HLA-DW3, and DRW3 in patients with dermatitis herpetiformis. Clinically, erythematous papules or plaques first appear on the skin, followed by severe burning and pruritus, and small vesicles, which group in a herpes-like pattern, involving the extensor surfaces symmetrically (Fig. 344). The oral mucosa is affected in 5 to 10% or more of the cases. Oral lesions follow the skin eruption and very rarely precede skin involvement. Clinically, the maculopapular lesions are considered as one of the main types of oral lesions (Fig. 345). In addition, erythematous, purpuric, vesicular, and erosive types have been described (Fig. 346). The vesicles appear in a cyclic pattern, rupture rapidly, leaving superficial painful erosions resembling aphthous ulcers. The palate, tongue, and buccal

mucosa are more frequently involved than the gingiva, lips, and tonsils.

The disease runs a very prolonged course with remissions and exacerbations. In 60 to 70% of the cases gluten-sensitive enteropathy coexists.

The differential diagnosis of the oral lesions includes minor aphthous ulcers, herpetiform ulcers, erythema multiforme, pemphigus vulgaris, cicatricial pemphigoid, linear IgA disease, and herpetic gingivostomatitis.

Laboratory tests supporting the diagnosis are histopathologic examination and direct immunofluorescence. Recently, IgA class endomysial antibodies (IgA-EmA), directed to reticulin components of smooth muscle, have been detected and seem to be a specific marker for the gluten-sensitive enteropathy of dermatitis herpetiformis and coeliac disease.

**Treatment.** Sulfones and sulfapyridines and, in certain cases, corticosteroids. Gluten-free diet may check disease activity.

Fig. 344. Dermatitis herpetiformis, papules and small vesicles on the skin, grouped in a herpeslike pattern.

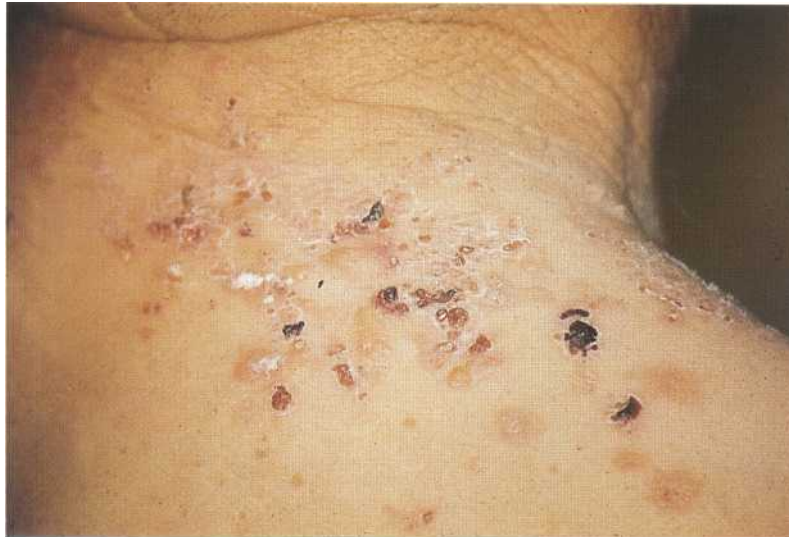

Fig. 345. Dermatitis herpetiformis, maculopapular lesions on the alveolar mucosa.

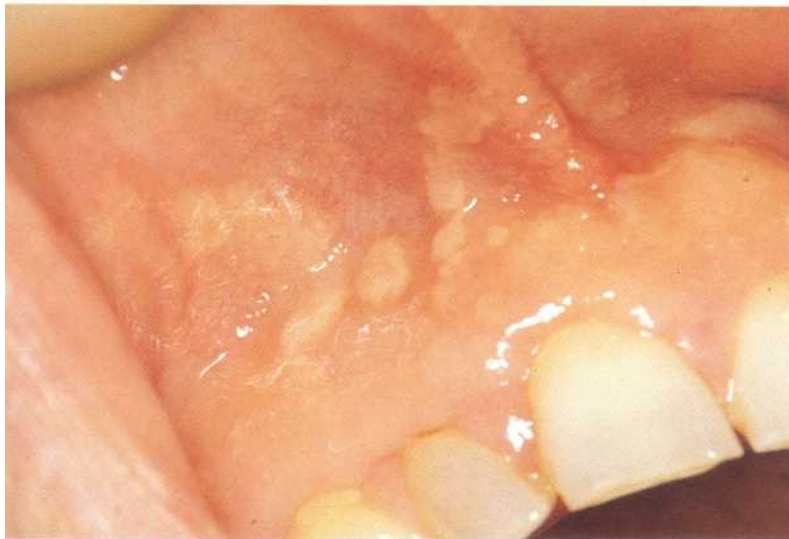
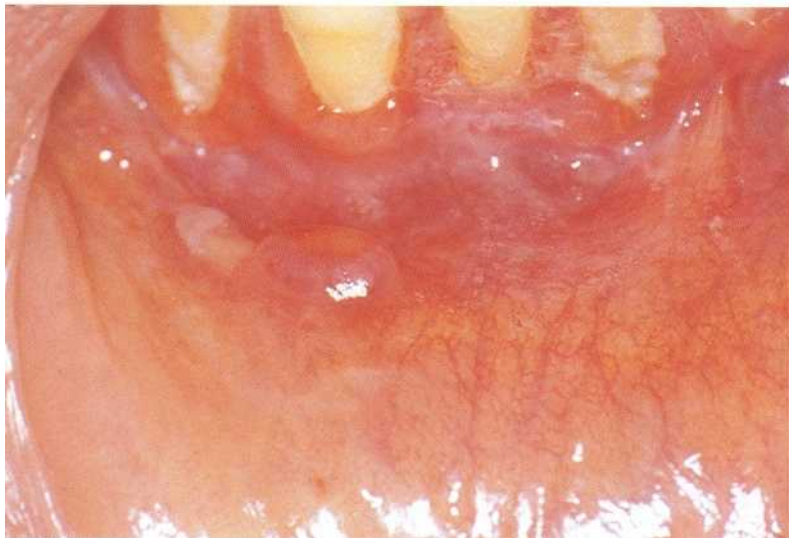
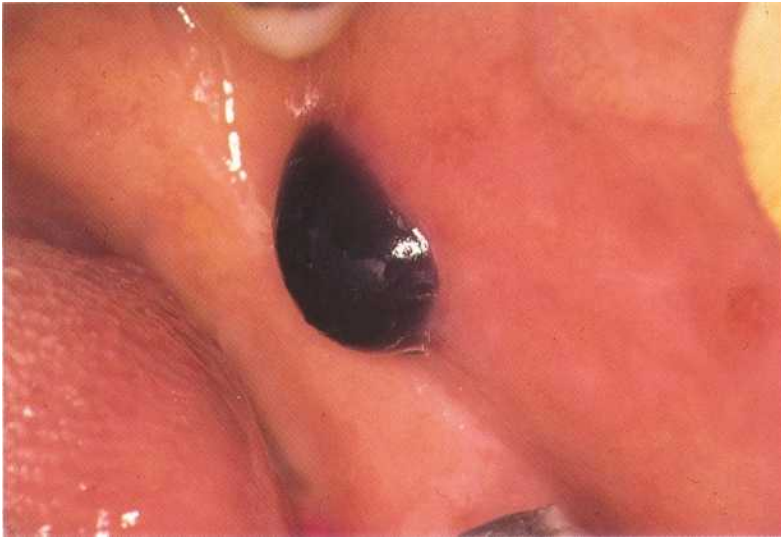Fig. 346. Dermatitis herpetiformis, intact bulla on the lower lip mucosa and small erosions on the gingiva.







**Fig. 347. Epidermolysis bullosa acquisita, hemorrhagic bulla on the buccal mucosa.**

### **Epidermolysis Bullosa Acquisita**

Epidermolysis bullosa acquisita is a rare, non-inherited, chronic mechanobullous disease with autoimmune pathogenesis. Clinically, the disease is characterized by the formation of bullae, mainly on the skin overlying joints, which are frequently induced after mechanical irritation. The bullae are tense, may contain blood, and heal with scarring. The skin over the joints, the extensor surfaces of the lower legs, feet, and hands is usually involved. Milia, atrophic areas, and dystrophic nails may occur. Involvement of the oral mucosa is not frequent. A few hemorrhagic bullae may appear, particularly after mild trauma or spontaneously (Fig. 347). They rupture, leaving ulcers that may heal by scarring. The following diagnostic criteria of epidermolysis bullosa acquisita have been proposed: no family history; adult onset; bullae formation after mechanical trauma, which heal with scarring, milia, and nail dystrophy; exclusion of all other bullous diseases; histopathologic, direct and indirect immunofluorescent examination; and electron microscopy.

The differential diagnosis includes pemphigus, cicatricial pemphigoid, bullous pemphigoid, dermatitis herpetiformis, linear IgA disease, and porphyria cutanea tarda.

**Treatment.** Systemic corticosteroids, immunosuppressive agents, and dapsone.

### **Lichen Planus**

Lichen planus is a common, chronic inflammatory disease of the skin and mucous membranes. The cause of lichen planus remains unknown, although recent evidence suggests that immunologic mechanisms may play a role in the pathogenesis. The association of lichen planus with autoimmune diseases, such as primary biliary cirrhosis, chronic active hepatitis, ulcerative colitis, myasthenia gravis, and thymoma, supports the view of an autoimmune pathogenesis. The disease affects equally members of all races and has a cosmopolitan distribution. An increased frequency of HLA-A3, A28-BS-B7-B8, and DRW9 has been noted in different racial groups. Women are affected somewhat more often than men, and the majority of the patients (about 70%) are between 30 and 60 years of age. Clinically, the cutaneous lesions appear as small, flat, polygonal, shiny papules (Fig. 348). Early papules are red, whereas older lesions display the characteristic violaceous color. Several variants of lichen planus of the skin have been described according to clinical pattern and configuration of lesions. They are distributed in a symmetrical pattern, more frequently over the flexor surfaces of the forearms and wrists, the sacral area, the back, and the lateral sides of the neck, and they are usually accompanied by pruritus. Linear lesions may develop after scratching (Kobner phenomenon). Genitalia, nails, and mucosae are also involved. The oral mucosa may be affected without skin manifestations.

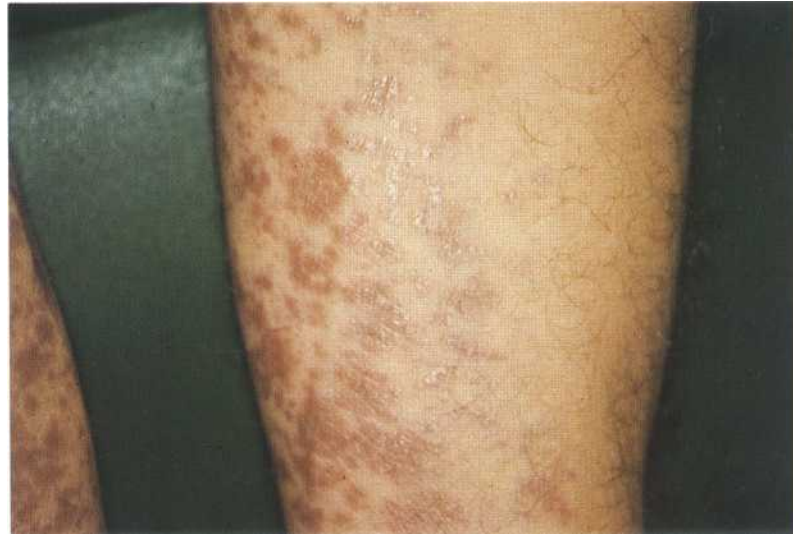

Fig. 348. Lichen planus, skin lesions.

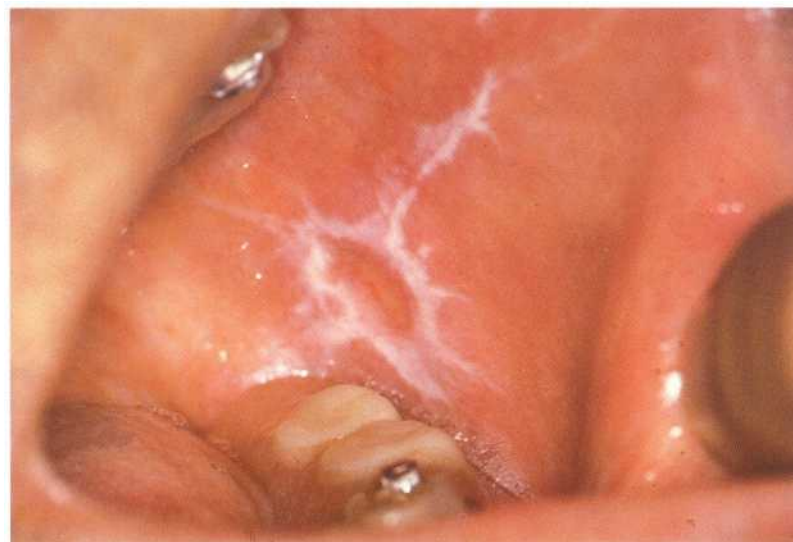

Fig. 349. Lichen planus, reticular form, of the buccal mucosa.

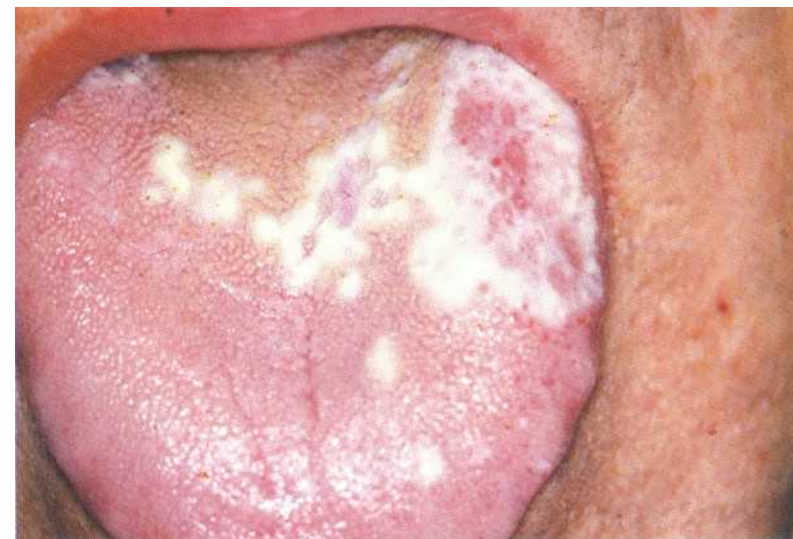
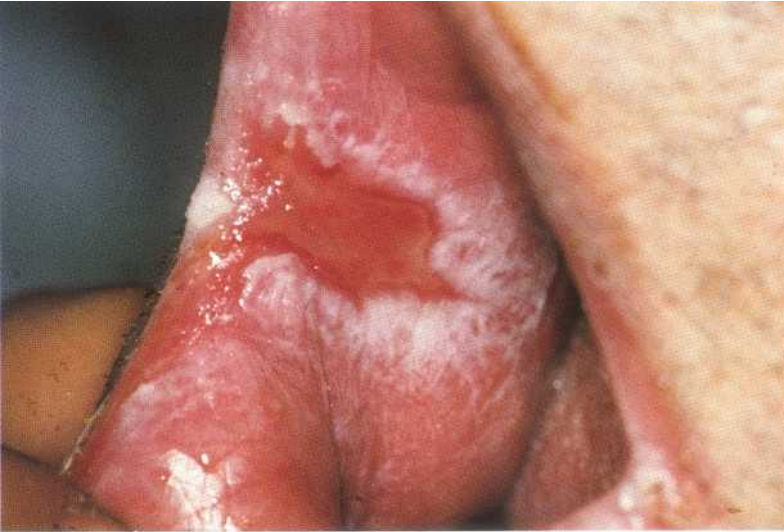
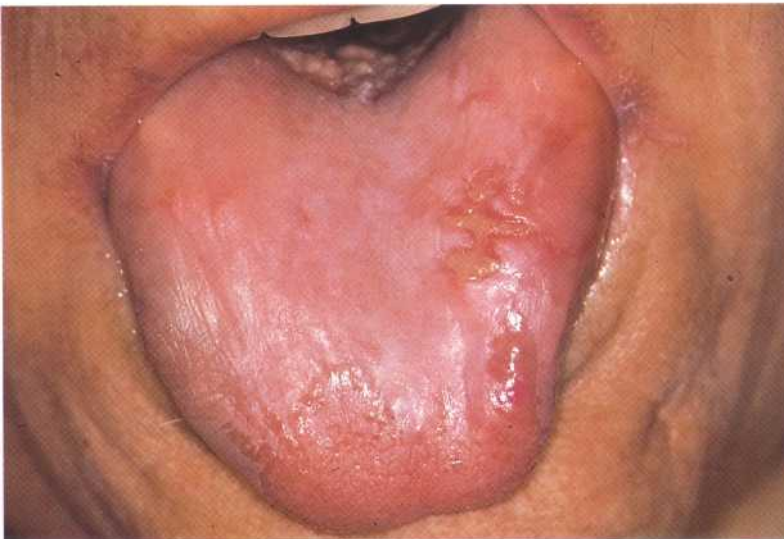Fig. 350. Lichen planus, reticular form, of the tongue.



**Fig. 351.** Lichen planus, erosive form, of the buccal mucosa.



**Fig. 352.** Lichen planus, atrophic form, of the dorsum of the tongue.

Clinically, the following forms of oral lichen planus have been described. The reticular form is the most common variant and is characterized by small white papules, which may be discrete but more often coalesce and form lines (Wickham's striae) and networks of lines (Figs. 349, 350). Linear and annular distribution of the papules may be seen. The erosive or ulcerative form is the second most frequent variant and is characterized by small or extensive painful erosions with isolated papules or lines at the periphery (Fig. 351). The atrophic form is less common and usually the result of the erosive form and is characterized by epithelial atrophy. The lesions have a smooth red surface and poorly defined borders, and, at the

periphery, papules or lines may be seen (Fig. 352). Frequently, the atrophic and erosive forms, when located on the gingiva, may be manifested as desquamative gingivitis (Fig. 353). The hypertrophic form is rare and appears as a well-circumscribed elevated white plaque resembling homogeneous leukoplakia and is the result of coalescing hypertrophic papules (Fig. 354). The bullous form is rare and is characterized by bullae formation of variable size, which rupture rapidly leaving painful ulcerations (Fig. 355). The bullae usually arise on a background of papules or striae. The pigmented form is extremely rare and is characterized by pigmented papules arranged in a reticular pattern interspersed with whitish lesions

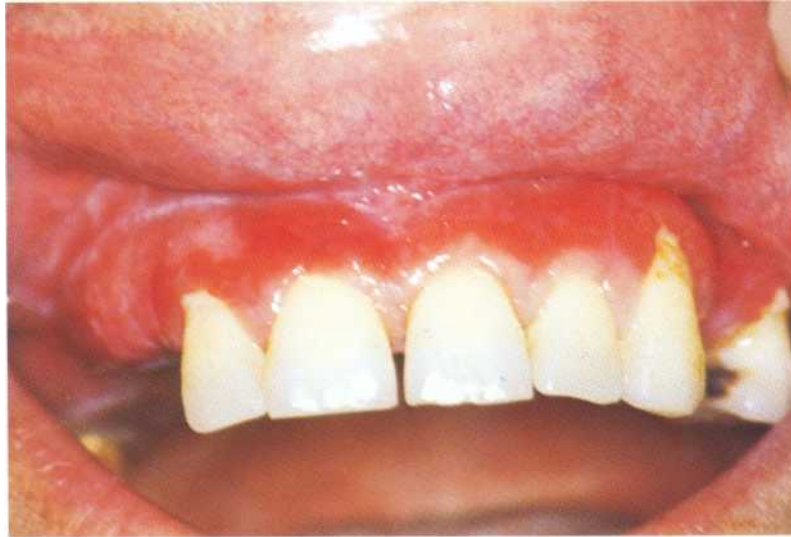

Fig. 353. Lichen planus, presenting as desquamative gingivitis.

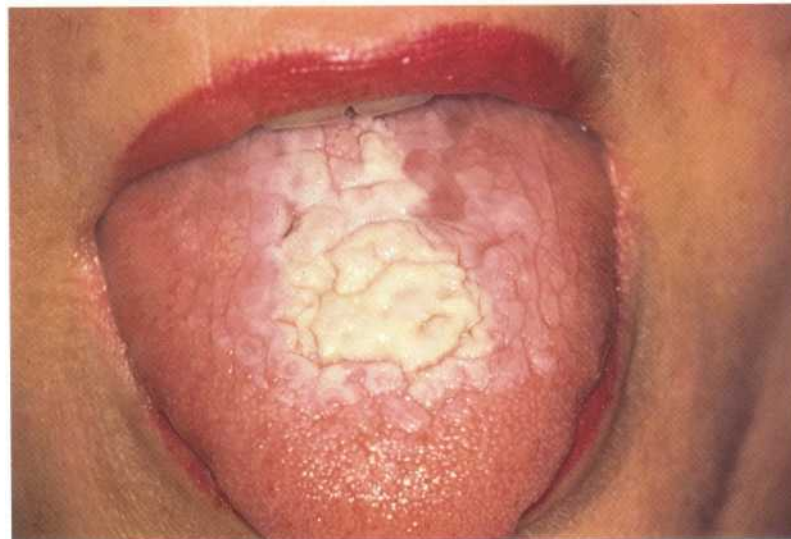

Fig. 354. Lichen planus, hypertrophic form, of the dorsum of the tongue.

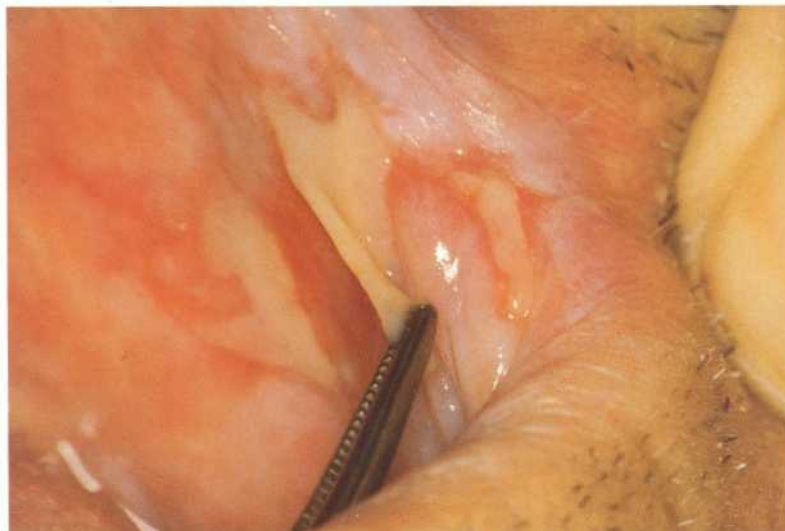


Fig. 355. Lichen planus, bullous form, of the buccal mucosa.

(Fig. 356). This form is due to local melanin overproduction during the acute phase of the disease. It is most frequent on the skin and should not be confused with pigmentation that may develop after healing of lichen planus lesions.

Oral lichen planus may follow a course of remissions and exacerbations. The disease most frequently affects the buccal mucosa, tongue, gingiva, and rarely the lips, palate, and floor of the mouth. The lesions are usually symmetrical and asymptomatic or cause mild discomfort, such as a burning sensation, irritation after contact with certain foods, and an unpleasant feeling of roughness in the mouth. However, erosive and bullous forms tend to be painful. It has been recently suggested that the oral lesions of lichen planus may be associated with *Candida* infection, but this relation remains obscure. The prognosis is good, although it has been suggested that there is a possibility of malignant transformation in the erosive and atrophic forms.

The differential diagnosis includes lupus erythematosus, erythroplakia, erythema multiforme, cicatricial pemphigoid, bullous pemphigoid, pemphigus, dermatitis herpetiformis, secondary syphilis and syphilitic glossitis, candidosis, and leukoplakia.

**Laboratory tests.** Histopathologic examination and direct immunofluorescent examinations help in establishing the diagnosis.

**Treatment.** No therapy is needed when the lesions are asymptomatic. In the erosive form of lichen planus topical, injectable, or systemic steroids are helpful. Aromatic retinoids (etretinate) and cyclosporine mouthwashes have also been used with partial success.

## Psoriasis

Psoriasis is a common, chronic, recurrent skin disease of unknown cause, which is characterized by the presence of erythematous, scaly plaques. There is no sex predilection, and the age of onset is usually beyond 25 years, although the disease may also affect children. Cutaneous lesions are usually located on the extensor surfaces of the extremities, particularly the elbows and knees, the lumbar area, the scalp, and nails (Fig. 357). Depending on the morphology of the skin lesions, certain varieties of psoriasis have been recognized, such as annular, circinate, guttate, nummular, and pustular.

Oral lesions are extremely rare and occur usually in the pustular form of the disease in approximately 2 to 4% of the cases after skin involvement.

Clinically, oral lesions are characterized by erythema, white or grayish plaques, and circular or semicircular lesions similar to geographic tongue (Fig. 358). Rarely, when xerostomia coexists, erythematous and scaly lesions may appear on the dorsal surface of the tongue. The oral lesions are predominantly located on the tongue, followed by the gingiva, buccal mucosa, floor of the mouth, and lips. Generally, oral manifestations are not pathognomonic and pose diagnostic problems that may be solved with histologic examination.

The differential diagnosis of oral psoriasis includes geographic tongue, geographic stomatitis, leukoplakia, lichen planus, Reiter's syndrome, and candidosis.

Laboratory test to confirm the diagnosis is histopathologic examination.

**Treatment.** Topical steroids, coal tar,  $\gamma$ -methoxypsoralen and ultraviolet A irradiation, methotrexate, hydroxyurea, cyclosporine, and aromatic retinoids (etretinate) have been used for treatment of skin lesions. Therapy should be carried out by a dermatologist.

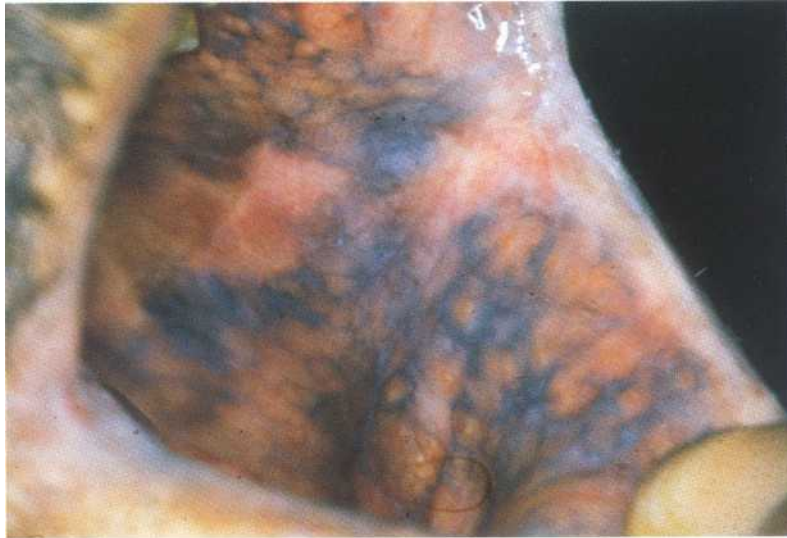

Fig. 356. Lichen planus, pigmented form, of the buccal mucosa.

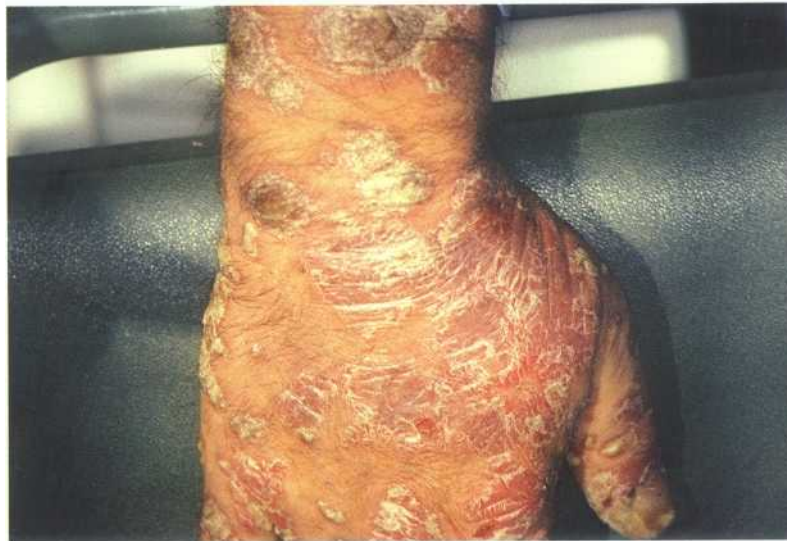

Fig. 357. Psoriasis, typical skin lesions.

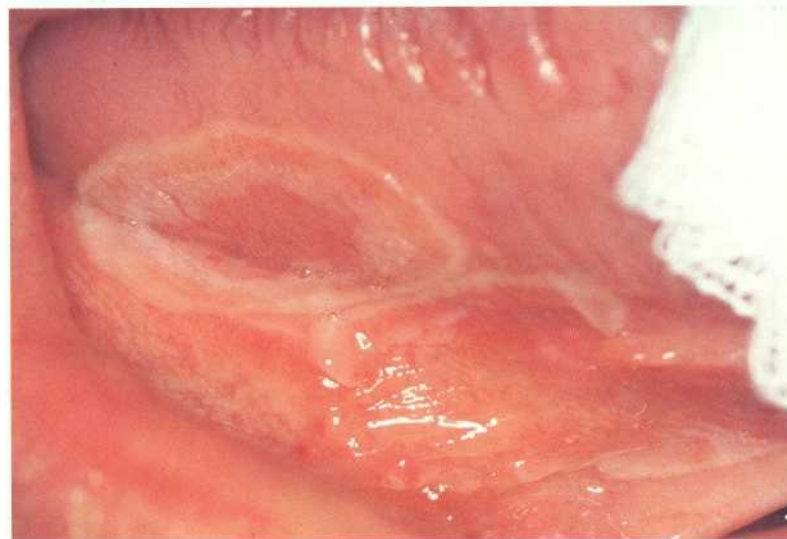


Fig. 358. Psoriasis, circular and semicircular whitish lesions on the tongue similar to geographic tongue.

### **Mucocutaneous Lymph Node Syndrome**

Mucocutaneous lymph node syndrome, or Kawasaki disease, is an acute febrile illness that predominantly affects children and rarely young adults. The disease was initially described in Japan, but cases have been reported in the United States, Hawaii, Canada, and Europe. The disease is associated in Japan with an increased prevalence of HLA-BW22, suggesting a possible immunogenetic predisposition. Although the disorder is known to be a systemic vasculitis, the exact etiology remains obscure. Clinically, it is characterized by the following diagnostic criteria: fever (38.5 to 40°C) lasting for at least 5 days, conjunctival injection and uveitis, erythema and edema of hands and feet followed by peeling, usually of the tips of the fingers and toes, polymorphous nonvesicular skin rash, cervical lymph node enlargement, and oropharyngeal manifestations.

The oral lesions consist of erythema, edema and fissuring of the lips, enlarged and red tongue papillae (strawberry tongue), deep red palate or oropharynx, and rarely ulcers (Fig. 359).

Arthralgia, large joint arthritis, encephalitis, abdominal symptoms, cardiovascular disorders, and renal involvement may be less common associated features. The disease may occasionally be lethal or may cause disability in some patients.

The differential diagnosis includes scarlet fever and erythema multiforme.

Laboratory test. No diagnostic tests are available.

Treatment is nonspecific. Aspirin and corticosteroids may be helpful.

### **Malignant Acanthosis Nigricans**

Malignant acanthosis nigricans is a form of acanthosis nigricans that occurs in adults and is invariably associated with internal cancers, usually adenocarcinoma of the stomach or other internal organs and rarely Hodgkin's disease, squamous cell carcinoma, etc. The mucocutaneous lesions and cancer usually appear simultaneously, whereas less frequently the neoplasia preceds or follows the skin and mucosal lesions. The oral mucosa is involved in about 30 to 40% of the cases. Clinically, multiple verrucous or papillomatous lesions, usually of normal color, are noted, which grow and occupy large areas. The lips and tongue are the most frequently affected sites, followed by the palate, gingiva, and buccal mucosa (Fig. 360). Similar lesions have been described in other mucosae (conjunctiva, anus, vagina, pharynx, esophagus, intestine, etc.). The skin is rough, hyperpigmented, and multiple papillary lesions develop on the axillae, the genitofemoral area, the neck, and rarely on the palms and sole (Fig. 361).

The differential diagnosis includes benign acanthosis nigricans (familial type), lipoid proteinosis, pemphigus vegetans, focal epithelial hyperplasia, multiple papillomas, and verruca vulgaris.

Laboratory test. Histopathologic examination may help to establish the diagnosis.

Treatment. The treatment of the underlying malignancy results in resolution or improvement of skin and mucosal lesions.

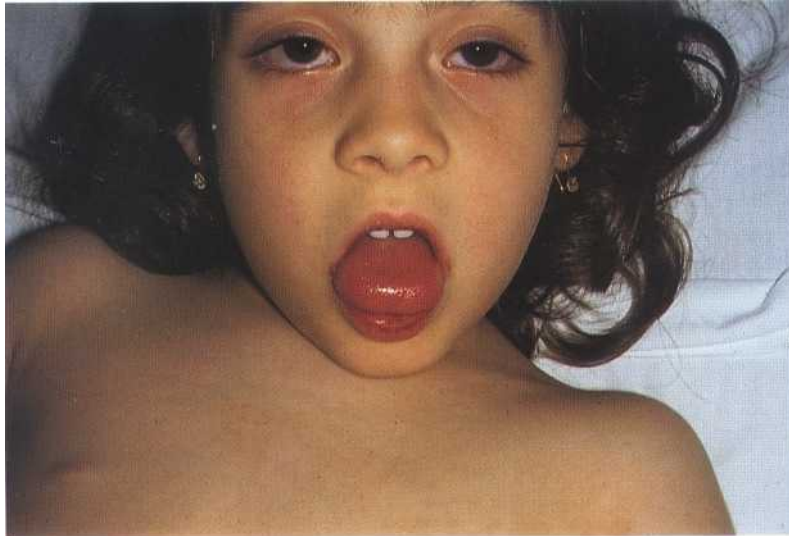

Fig. 359. Mucocutaneous lymph node syndrome, enlarged, red tongue, and conjunctival injection.

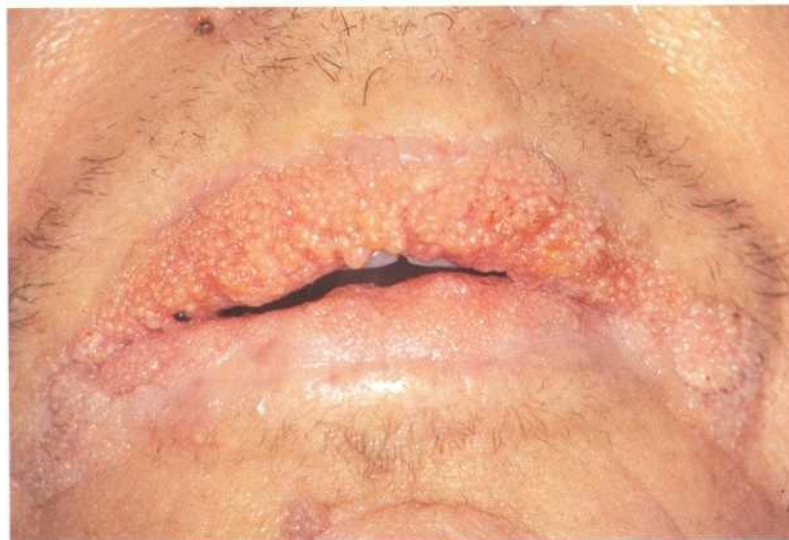

Fig. 360. Malignant acanthosis nigricans, verrucous and papillomatous lesions of the lips.



Fig. 361. Malignant acanthosis nigricans, marked pigmentation and papillary hyperplasia of the skin.



### Acrodermatitis Enteropathica

Acrodermatitis enteropathica is a rare hereditary disease transmitted as an autosomal recessive trait. The disease is related to zinc deficiency due to an inability to absorb dietary zinc from the intestine. It is fatal during infancy or early childhood if left untreated. The disorder starts usually within a few weeks after birth, and it is characterized by: cutaneous lesions, hair loss, nail lesions, and diarrhea. The cutaneous lesions consist of areas of erythema associated with vesicles and pustules in crops that in a few days become crusted and scaly, exhibiting a psoriasiform pattern. Some of these lesions prove to be due to secondary infection, especially by *Candida albicans*. Characteristically, the lesions are located around body orifices, the hands, feet, nails, and the anogenital area. The typical location is the perioral area, where angular cheilitis may appear, but rarely areas of erythema with white macules of edematous lesions with erosions may develop in the oral mucosa (Fig. 362).

The differential diagnosis includes epidermolysis bullosa and bullous diseases of childhood.

Laboratory test confirming the diagnosis is the measurement of serum zinc concentration.

Treatment consists of the administration of zinc salts and a diet rich in zinc salts.

### Lip-Licking Dermatitis

Lip-licking dermatitis is a condition that most commonly occurs in children and is characterized by an inflammation involving the lips and the adjacent skin area.

Clinically, the lips and the perioral skin manifest erythema associated with scaling, crusting, and fissuring of variable severity (Fig. 363). A burning sensation is often the only subjective symptom. Lip-licking dermatitis is an irritant contact dermatitis, secondary to the habit of licking the lips.

The differential diagnosis includes perioral dermatitis and contact dermatitis.

Treatment. The elimination of the habit of licking the lips is often sufficient to cure this condition. In severe cases, topical corticosteroids in medium-low potency for a short time are usually of help.

### Perioral Dermatitis

Perioral dermatitis is a characteristic persistent eruption around the mouth that is composed of micropapular and papulopustular lesions on an inflamed base. The disease is found most frequently in young women who have been using powerful topical corticosteroids for a long time. The extensive use of topical corticosteroids is now considered as the main, if not only, cause of perioral dermatitis. Other factors, like cosmetics, fluorinated toothpastes, and contraceptive pills have also been blamed.

The clinical picture consists of an erythematous region affecting mainly the chin, upper lip, and the sides of the nose, with small papules and papulopustules, usually occurring in clusters. Although in severe cases lesions can occur around the eyelids and in the glabella, there is a typical clear zone between the affected skin and the vermilion border of the lips (Fig. 364).

The differential diagnosis includes acne, seborrheic dermatitis, contact dermatitis, and rosacea.

Treatment. Discontinuation of the use of topical corticosteroids. Oral tetracycline 250 mg 2-3 times daily for 3 weeks and then once a day for another 3-4 weeks is very efficient.

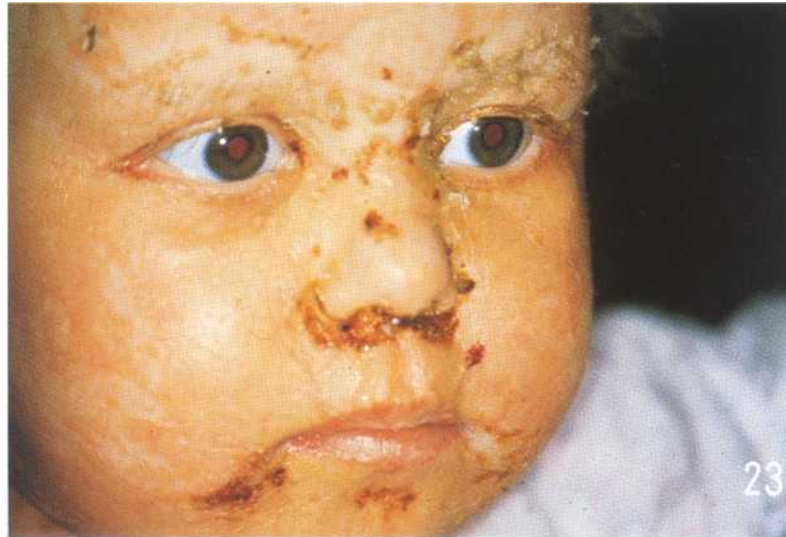

Fig. 362. Acrodermatitis enteropathica, characteristic lesions on the perioral area, commissures, and skin of the face.

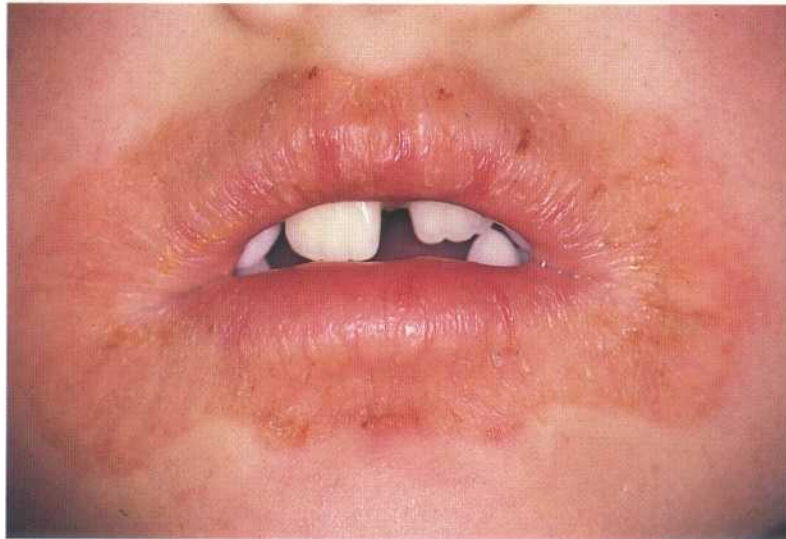

Fig. 363. Lip-licking dermatitis, erythema associated with scaling, crusting and fissuring.

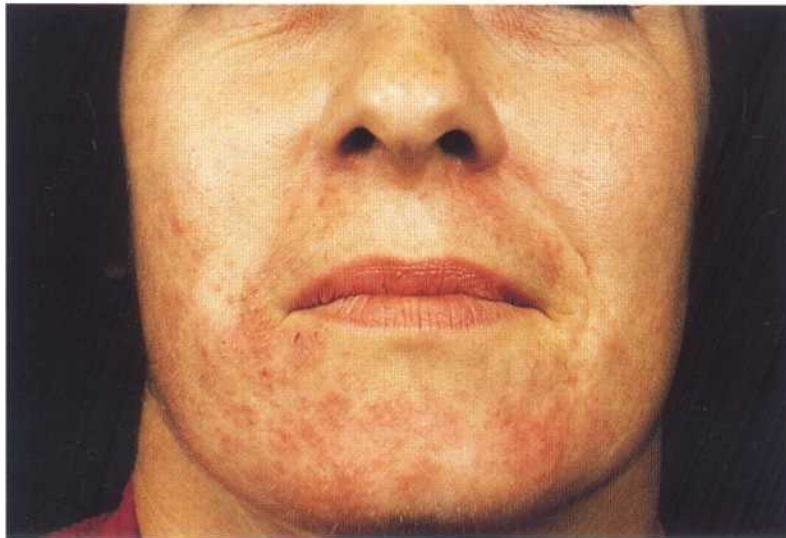

Fig. 364. Perioral dermatitis.

## Warty Dyskeratoma

Warty dyskeratoma is an uncommon solitary cutaneous lesion that microscopically is similar to Darier's disease. The cause remains obscure, although radiation, mechanical and immune factors, and viruses have been implicated in the pathogenesis.

Warty dyskeratoma appears usually in middle-age, and men are more frequently affected than women (ratio 2.5: 1).

The lesion involves the scalp, neck, trunk, and extremities predominantly. The oral mucosa is rarely affected, and only 20 oral dyskeratomas were found in the literature in a review by me in 1985. Clinically, the oral lesions appear as a painless nodular or papular elevation, with a small central crater and smooth or papillomatous surface (Fig. 365). It is sessile with whitish or normal color and a diameter ranging from a few millimeters to 1 cm.

Almost all intraoral lesions occur on keratinized areas (alveolar ridge, hard palate, gingiva) exposed to friction and mechanical irritation. The clinical features are nonpathognomonic.

The differential diagnosis includes Darier's disease, oral keratoacanthoma, periodontal fistula, early pleomorphic adenoma, and benign lymphoepithelial lesion.

Laboratory test important to establish the diagnosis is the histopathologic examination.

Treatment. Surgical excision.

## Vitiligo

Vitiligo is a melanocytopenic disorder of unknown cause, although an autoimmune mechanism is presumably involved in the pathogenesis. Vitiligo usually appears before the age of 20 years and is due to the absence of melanocytes and melanin in the epidermis. Clinically, white asymptomatic macules varying in size from several millimeters to several centimeters in diameter appear, which are surrounded by a zone of normal or hyperpigmented skin. Progressively, the lesions increase in size, forming various, irregular patterns. The lesions are more frequently located on the dorsal aspect of the hands, the neck, periorificial regions and the face. Rarely, lesions may appear on the lips, whereas the oral mucosa usually remains unaffected (Fig. 366).

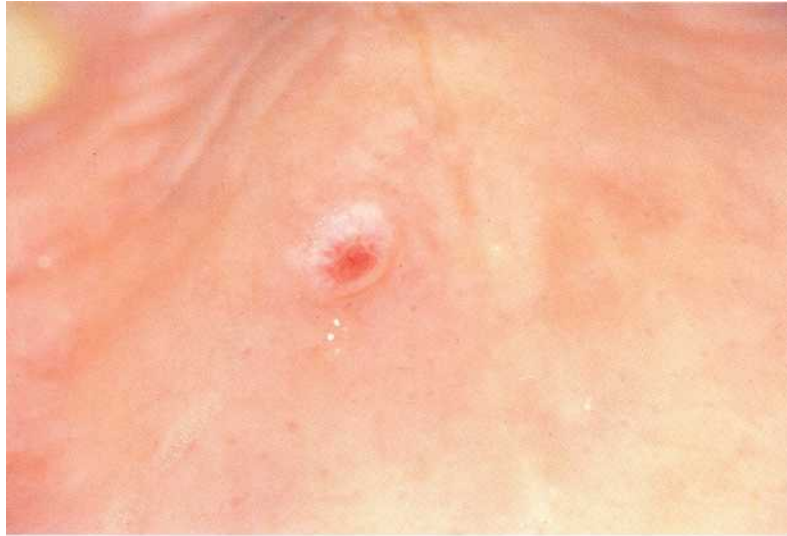

Fig. 365. Warty dyskeratoma of the palate.

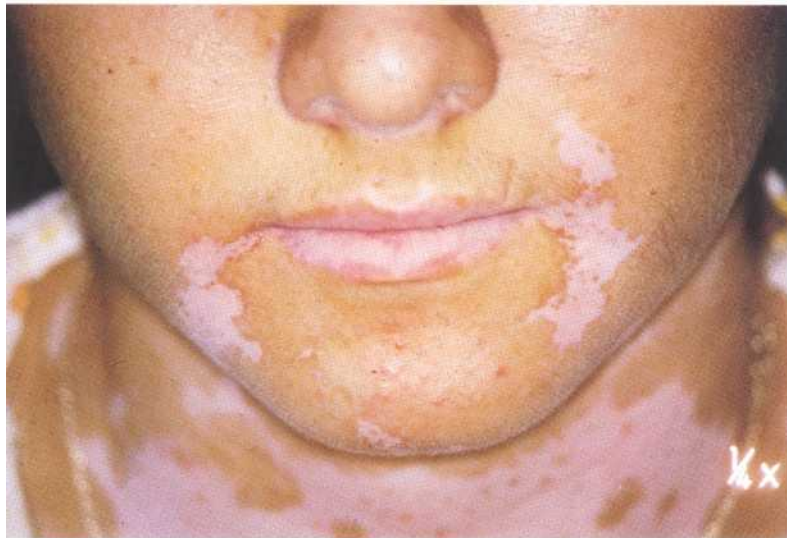

Fig. 366. Vitiligo of the skin and the vermilion border of the lips.

## 23. Hematologic Disorders

### Iron Deficiency Anemia

Iron deficiency anemia represents an advanced stage of iron deficiency. It may result from inadequate dietary iron intake, malabsorption, blood loss, or rarely intravascular hemolysis with hemoglobinuria. Iron deficiency anemia is widespread throughout the world and is more common among children, persons on a poor diet, and women. The symptoms usually reflect the rate of progression of anemia and its severity.

The clinical manifestations of chronic iron deficiency anemia include fatigue, anorexia, headache, lassitude, tachycardia, neurologic disorders, pallor of the skin and mucosae, and koilonychia. The oral manifestations include a burning sensation of the tongue, pallor of the oral mucosa, and gradual atrophy of the filiform and fungiform papillae of the tongue. Progressively, the dorsal surface of the tongue becomes smooth and glistening (Fig. 367). The tongue atrophy may be patchy or generalized.

Rarely, leukoplakia or superficial erosions may develop, and angular cheilitis and oral candidosis are common findings. Delayed wound healing after surgical procedures may also be seen.

The differential diagnosis includes pernicious anemia, geographic tongue, atrophic lichen planus, atrophic glossitis of tertiary syphilis, and malnutrition disorders.

Laboratory tests helpful for the diagnosis include hemoglobin determination, red cell indices, serum iron concentration, serum total iron binding capacity, and plasma ferritin level.

**Treatment.** Before replacement therapy with iron salts, it is imperative that all cases of iron deficiency anemia be thoroughly studied in order to determine the exact cause.

### Plummer-Vinson Syndrome

Plummer-Vinson syndrome is characterized by a combination of iron deficiency anemia, dysphagia, and oral lesions, and it usually appears in middle-aged women. The oral manifestations are identical to those seen in iron deficiency anemia, with a characteristic smooth atrophic and red tongue (Fig. 368). Angular cheilitis and xerostomia are also common.

The dysphagia is due to painful erosions and strictures of the esophagus. Leukoplakia and oral and oropharyngeal squamous cell carcinoma may develop.

### Pernicious Anemia

Pernicious anemia is a megaloblastic anemia due to vitamin B<sub>12</sub> deficiency, usually caused by a gastric mucosal defect that decreases intrinsic factor synthesis.

Other less frequent causes are total gastrectomy, pancreatic dysfunction, parasitic diseases and diseases of the ileum, all of which interfere with vitamin B<sub>12</sub> absorption and antibodies against transcobalamin, etc.

Pernicious anemia affects either sex, usually after the 30th year of age. The clinical features include pallor, malaise, lassitude, weight loss, gastrointestinal upset, and neurologic abnormalities. The oral manifestations are early and common. Burning sensation of the tongue and taste loss are early symptoms. A classic oral feature of pernicious anemia is a painful glossitis. Gradual atrophy of the filiform and fungiform papillae of the tongue eventuates in a smooth, red, and shiny dorsal surface (Fig. 369). The rest of the oral mucosa may be pale, and superficial erosions may develop.

The differential diagnosis includes iron deficiency anemia, Plummer-Vinson syndrome, pellagra, and malnutrition disorders.

Fig. 367. Iron deficiency anemia, smooth dorsal surface of the tongue.

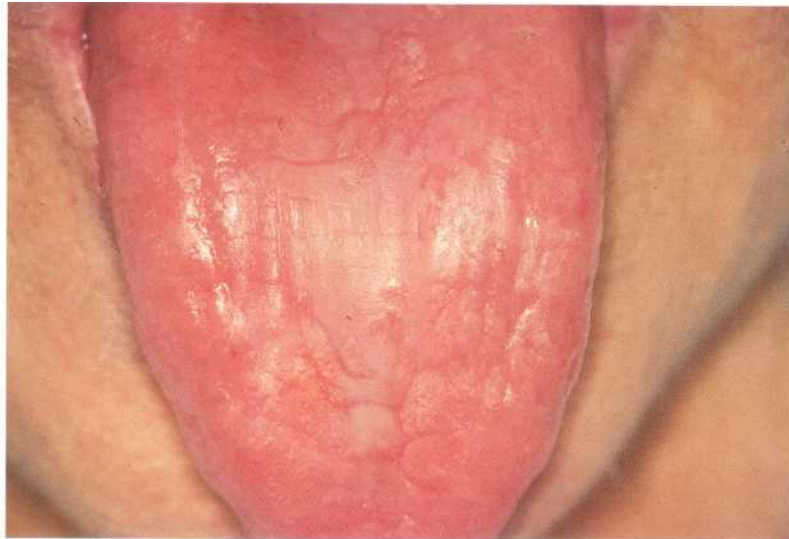

Fig. 368. Plummer-Vinson syndrome, redness and atrophy of tongue papillae associated with angular cheilitis.

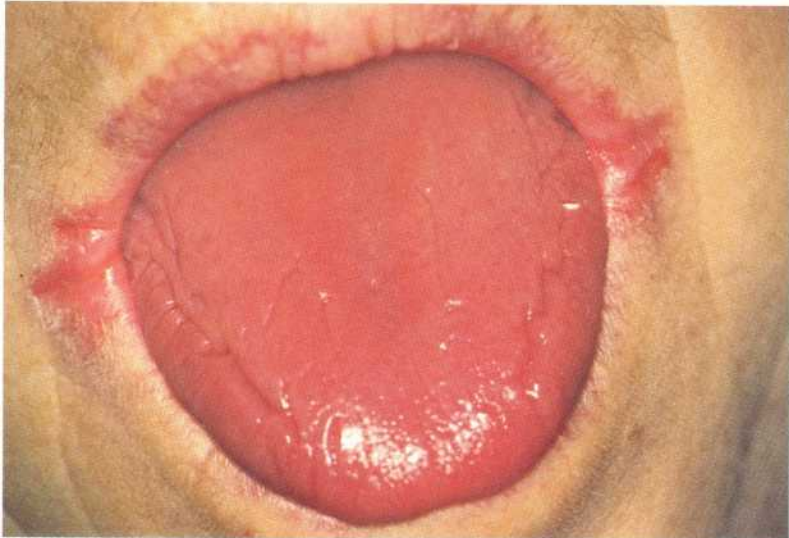
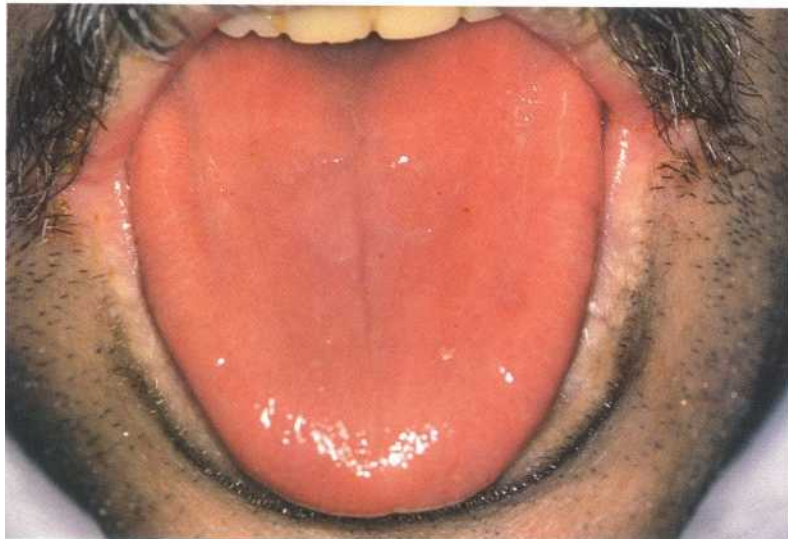


Fig. 369. Pernicious anemia, smooth, red, and shiny dorsum of the tongue.



Laboratory tests helpful in establishing the diagnosis include blood count, hemoglobin determination, vitamin B<sub>12</sub> serum level, the Schilling test, study of bone marrow aspirate, and elevated serum lactic dehydrogenase levels.

Treatment consists of vitamin B<sub>12</sub> replacement.

### Thalassemias

Thalassemias are a group of disorders that result from an inherited abnormality of globin synthesis. They are classified in several types (α, β, δβ, S, and γ) according to which globin chain or chains are affected.

The severe form of the disease (thalassemia major, homozygous type) usually develops during the first few months of life and becomes progressively severe. The course of the disease in childhood depends on whether or not the child is maintained on an adequate transfusion program. The inadequately transfused patient has the typical clinical features, such as skin pallor, low fever, malaise, weakness, and hepatosplenomegaly. Gradually, the face assumes a mongoloid appearance. The oral mucosa is pale; there is protrusion of the upper anterior teeth, open bite, and malocclusion (Fig. 370). Glossodynia, loss of tongue papillae, and swelling of parotid glands may occur.

The diagnosis is based on specialized hematologic tests, including electrophoresis of hemoglobin.

Treatment includes blood transfusion initially.

### Congenital Neutropenia

Congenital neutropenia is also known as infantile genetic agranulocytosis. Other terms have also been used. It is a rare disorder characterized by a marked persistent decrease in circulating neutrophils, associated with severe life-threatening infections. The neutropenia is present at birth. The exact cause is unknown although some patients have a probable autosomal recessive genetic defect. It is assumed that the maturation defect in the granulocyte precursors is due to deficiency of a serum factor.

Multiple bacterial infections characterize the clinical picture of the disease starting early in life. The most common infections involve the skin, lungs, middle ear, and urinary tract. Oral manifestations are common and include persistent and

recurrent ulcerations, bacterial infections, candidosis and periodontal disease. The latter is very common and is characterized by severe gingival inflammation, tooth mobility, and extensive bone loss. The marginal and attached gingiva is fiery red and edematous, and usually the interdental papillae are hyperplastic (Fig. 371).

The differential diagnosis includes agranulocytosis, cyclic neutropenia, aplastic anemia, leukemia, acatalasia, hypophosphatasia, juvenile diabetes mellitus, Papillon-Lefevre syndrome and glycogen storage disease type 1b.

Laboratory tests. Hematologic examination is the key to the diagnosis. Remarkably decreased neutrophils or no neutrophils is a common finding, while eosinophilia may be present. Radiographic examination of the oral cavity shows severe alveolar bone loss.

Treatment. Good plaque control, scaling, and local and systemic prophylaxis are suggested, while periodontal surgery is contraindicated. Antibiotics and supportive treatment based on bacteriologic studies and the patient's response to treatment are to be provided.

### Cyclic Neutropenia

Cyclic neutropenia is a disorder of unknown cause characterized by a cyclic reduction in the number of circulating neutrophil leukocytes. The disease is thought to be transmitted as an autosomal dominant trait with variable expression.

The reduction in neutrophils occurs regularly at 3-week intervals and may last for 1 to 3 days. A recovery phase of 5 to 8 days follows when the number of neutrophils returns to normal. The disease is usually manifested in infancy or childhood, but it may occur at any age. During an episode of profound neutropenia, the patient may complain of low-grade fever, malaise, headache, dysphagia, arthralgias, cervical adenitis, and skin infections.

Painful oral ulcers covered by a whitish membrane and surrounded by slight erythema are usually seen (Fig. 372). The size of ulcers varies from a few millimeters to 1 cm, and they may appear at any area of the oral mucosa for 1 to 2 weeks. Gingivitis is also a common finding of the disease.

The differential diagnosis includes aphthous ulcers, agranulocytosis, congenital neutropenia, acute leukemia, and primary and secondary syphilis.

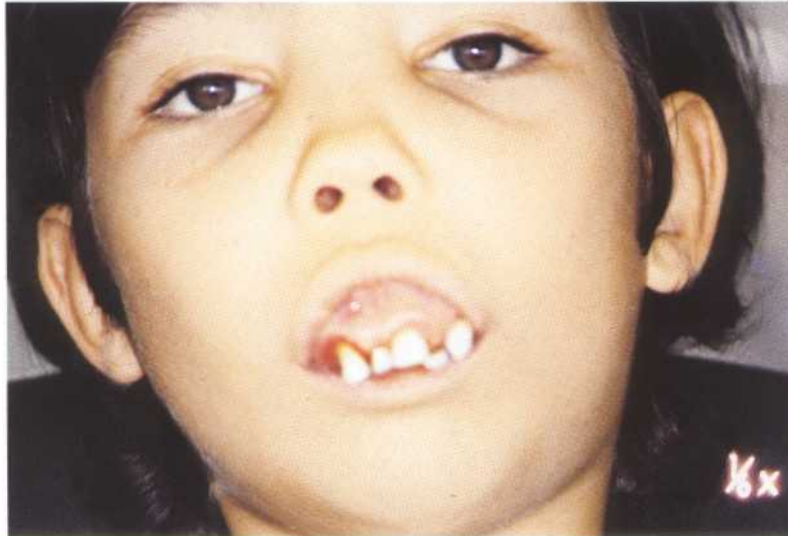

Fig. 370. Thalassemia major, characteristic facies and protrusion of the upper anterior teeth.

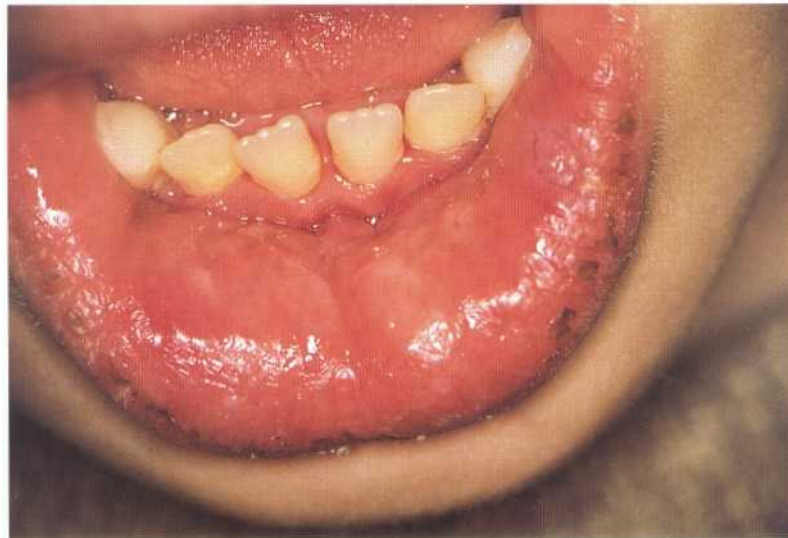

Fig. 371. Congenital neutropenia, lip mucosa ulceration and swelling, and periodontitis.

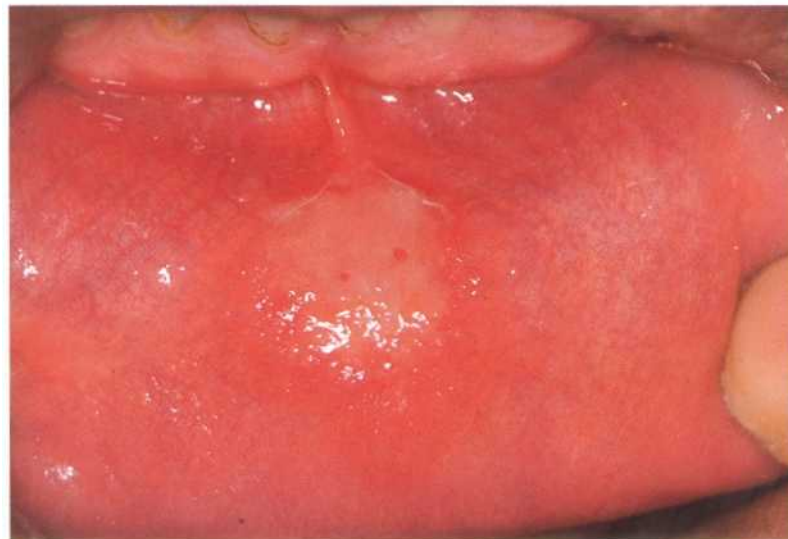

Fig. 372. Cyclic neutropenia, ulcer on the labial mucosa.



Laboratory test helpful in establishing the diagnosis is a repeated determination of neutrophils in the peripheral blood.

Treatment is symptomatic. Corticosteroids and sometimes splenectomy may be helpful.

### **Agranulocytosis**

Agranulocytosis is a serious disorder characterized by a severe reduction of neutrophils or complete absence of all granulocytes. It may be a primary process of unknown cause or secondary due to a definite cause, such as drugs or infection. Drug-induced agranulocytosis has a high mortality rate. The most common drugs that may induce neutropenia are analgesics, antibiotics, antihistamines, anti-inflammatory agents, anticonvulsants, antithyroid drugs, etc. All ages and both sexes may be affected. The important clinical consequence of agranulocytosis is the risk of increased bacterial infection, which is usually correlated with the degree of neutropenia. The onset of agranulocytosis is sudden and is characterized by chills, fever, malaise, and dysphagia. Within

12 to 24 hours, evidence of oral, pharyngeal, respiratory, or gastrointestinal infections usually appear. Oral mucosal lesions are an early sign and consist of necrotic ulcers covered by a gray-white or dark "dirty" pseudomembranes without a red halo (Fig. 373). The ulcers are usually multiple and measure 0.5 cm to several centimeters in diameter. The palate, gingiva, tongue, and tonsils are the most common sites of involvement. Severe necrotizing gingivitis with destruction of periodontal tissues may occur (Figs. 374, 375). The oral lesions are frequently accompanied by increased salivation, painful mastication, and difficulty in swallowing.

The differential diagnosis includes congenital neutropenia, cyclic neutropenia, aplastic anemia, acute leukemia, infectious mononucleosis, and Wegener's granulomatosis.

**Laboratory test.** Bone marrow aspiration and white blood counts in peripheral blood establish the diagnosis.

Treatment includes administration of antibiotics and in selected cases white blood cell transfusions.

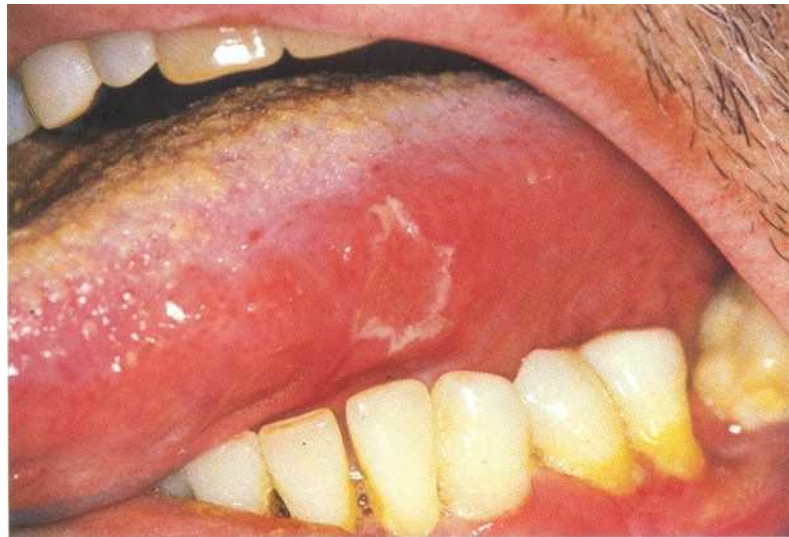

Fig. 373. Agranulocytosis, ulcer on the tongue.

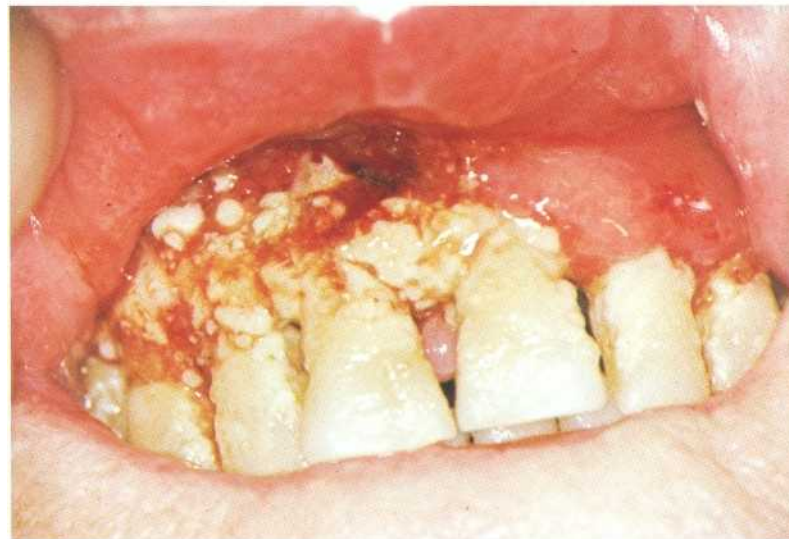

Fig. 374. Agranulocytosis, severe periodontal destruction.

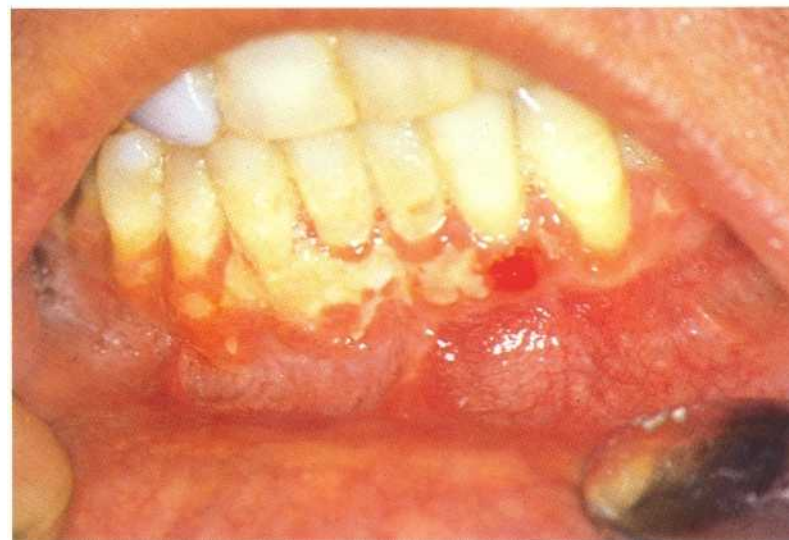

Fig. 375. Agranulocytosis, mild periodontal destruction.

### **Aplastic Anemia**

Aplastic anemia is a stem cell disorder characterized by pancytopenia. The disease may be primary or secondary. The primary form is of unknown cause and may be constitutional (Fanconi's anemia) or acquired. The secondary form may be caused by drugs, radiation, chemicals, infections, and metabolic and immunologic disorders.

The onset of aplastic anemia is usually insidious, and nonspecific signs and symptoms, such as headache, fever, weakness, and fatigue, are early manifestations. Slight pallor and a few petechiae on skin surfaces exposed to pressure are early diagnostic signs. Later, purpuric spots, which may be spontaneous or related to trauma, may appear anywhere.

The oral manifestations are usually related to the degree of coexistent neutropenia and thrombocytopenia. Gingival bleeding is an important early sign. Necrotic ulcers similar to those seen in agranulocytosis may develop, particularly in areas of irritation (buccal mucosa, palate, gingiva) (Fig. 376).

The differential diagnosis includes agranulocytosis, cyclic neutropenia, acute leukemia, thrombocytopenic purpura, and infectious mononucleosis.

Laboratory tests helpful for diagnosis are examination of bone marrow aspiration and biopsy in addition to the standard blood count.

Treatment consists of transfusions and antibiotics. Steroids may be helpful in selected cases, but bone marrow transplantation is the therapy of choice.

### **Thrombocytopenic Purpura**

Thrombocytopenic purpura is characterized by a decrease in platelets in the peripheral blood. The disease may be due to a primary failure of the bone marrow to generate platelets (for example, idiopathic thrombocytopenic purpura) or it may be secondary due to a myelotoxic agent (drugs, radiation, etc.). Clinically, it is characterized by a purpuric rash on the skin and mucosae and a bleeding diathesis. In the oral mucosa, petechiae and ecchymoses usually occur, especially in the palate and buccal mucosa (Fig. 377). Gingival bleeding is a constant early finding. Episodes of bleeding from the gastrointestinal and urinary tracts and epistaxis are likewise frequent findings.

The differential diagnosis includes aplastic anemia, leukemia, polycythemia vera, and agranulocytosis.

Laboratory tests. Bone marrow aspiration and a peripheral platelet count establish the diagnosis. Also, bleeding and clotting times.

Treatment. Corticosteroids are often effective. More complicated or chronic cases require advice from an experienced hematologist.

### **Myelodysplastic Syndrome**

Myelodysplastic syndrome includes a heterogeneous group of refractory anemias often associated with thrombocytopenia, neutropenia, and/or monocytosis. The exact cause of the syndrome is not clear although it may develop secondary to radiotherapy and chemotherapy and is more frequent in older individuals. Myelodysplastic syndrome is classified into five groups depending on hematologic disorders. Multiple bacterial infections and hemorrhage are characteristic disorders due to neutropenia and thrombocytopenia. The oral manifestations include persistent and recurrent ulceration (Fig. 378), hemorrhage, and rarely candidosis and periodontitis.

The differential diagnosis includes leukemia, agranulocytosis, cyclic neutropenia, congenital neutropenia, aplastic anemia, and thrombocytopenia.

Laboratory test. Hematologic examination and bone marrow aspiration and biopsy establish the diagnosis.

Treatment consists of transfusions and antibiotics as indicated. Topical corticosteroid and antiseptic mouthwashes for oral lesions.

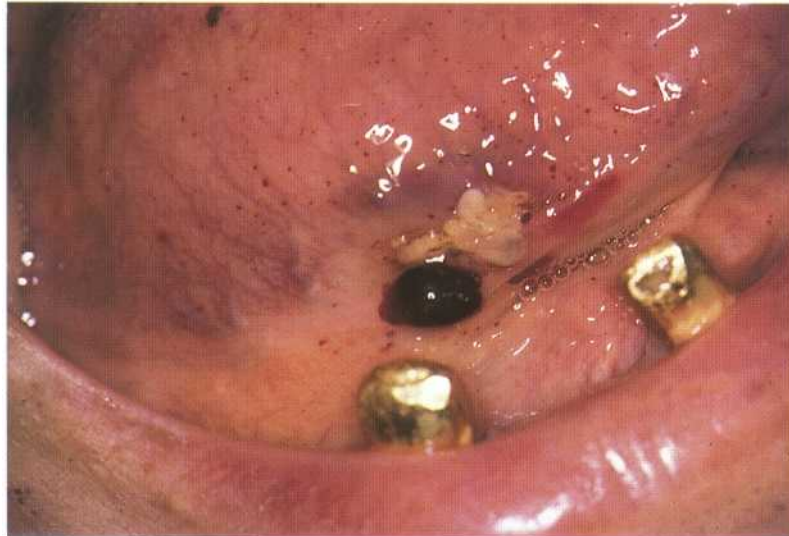

Fig. 376. Aplastic anemia, ecchymoses and ulcers on the tongue.

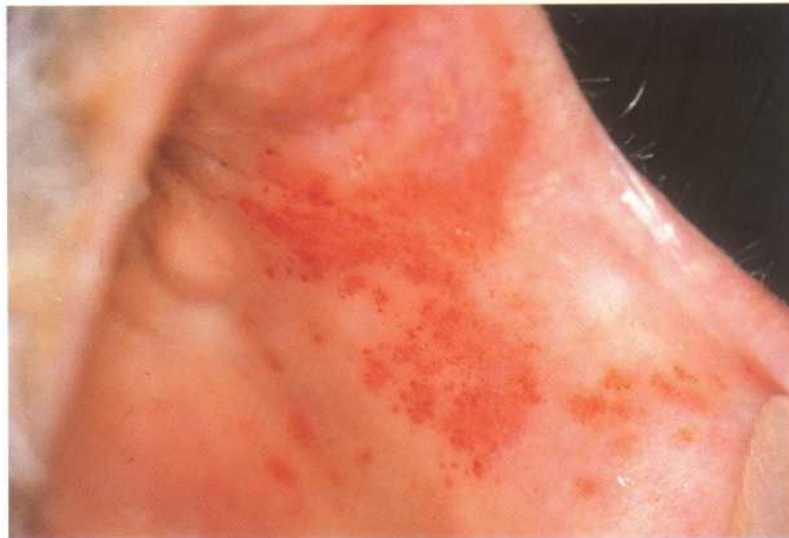

Fig. 377. Idiopathic thrombocytopenic purpura, petechiae and ecchymoses of the buccal mucosa.

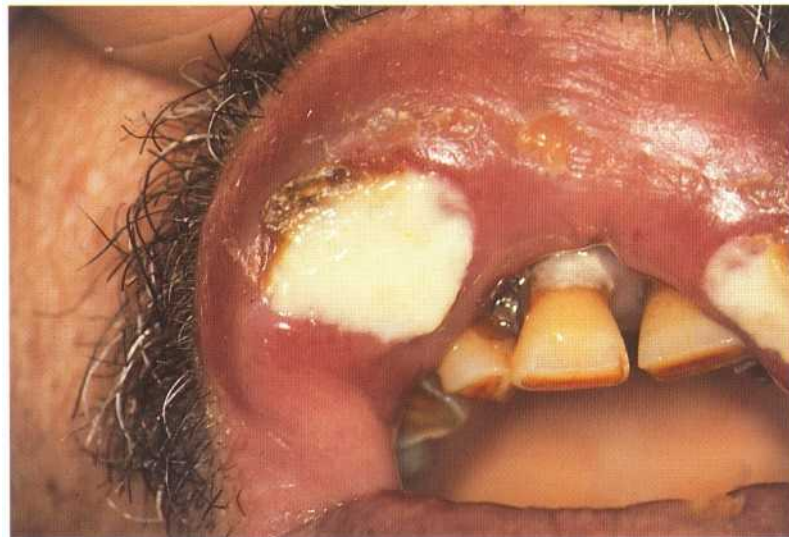

Fig. 378. Myelodysplastic syndrome, persistent ulcerations on the upper lip.

## 24. Renal Diseases

### Uremic Stomatitis

Uremia is a metabolic disorder due to accumulation of nitrogenous waste products in the blood. Uremia may be the result of acute or chronic renal failure. Uremic stomatitis is a relatively rare disorder and occurs usually only when blood urea reaches a level beyond 300 mg/100 ml. Two forms of uremic stomatitis are recognized: a) *ulcerative stomatitis* characterized by painful superficial ulcers varying in size and covered by a pseudomembrane (Fig. 379); and b) *nonulcerative stomatitis*, characterized by a painful diffuse edematous erythema and a thick greyish pseudomembrane on the oral mucosa. Xerostomia, uriniferous breath odor, unpleasant taste, hemorrhagic tendency and oral bleeding, and candidosis and other opportunistic infections (bacterial and viral) may also be seen (Fig. 380).

The differential diagnosis includes candidosis, stomatitis medicamentosa, allergic stomatitis, agranulocytosis, and necrotizing ulcerative stomatitis.

Laboratory tests to confirm the diagnosis include urinalysis and blood urea level determination.

**Treatment.** The oral lesions improve after hemodialysis and improvement of the underlying renal failure. Local treatment consists of improving oral hygiene and antimicrobial agents if necessary.

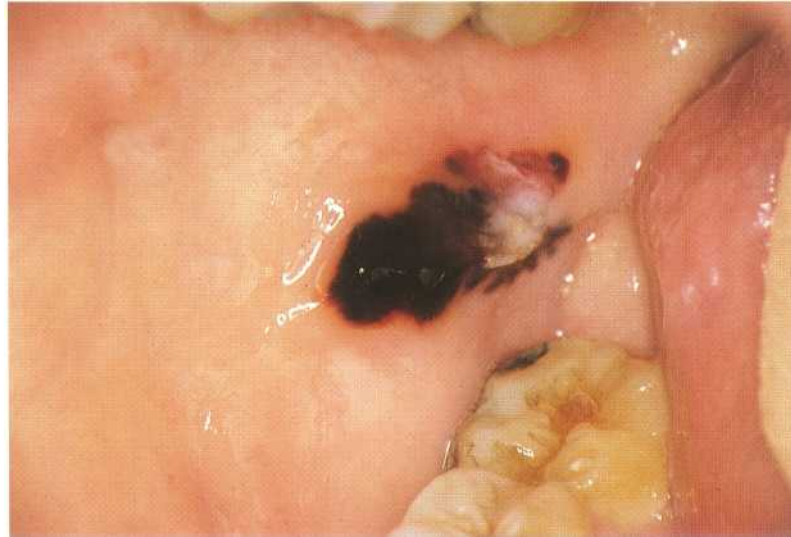


Fig. 379. Uremic stomatitis, ulcerations covered by a necrotic pseudomembrane on the buccal mucosa.

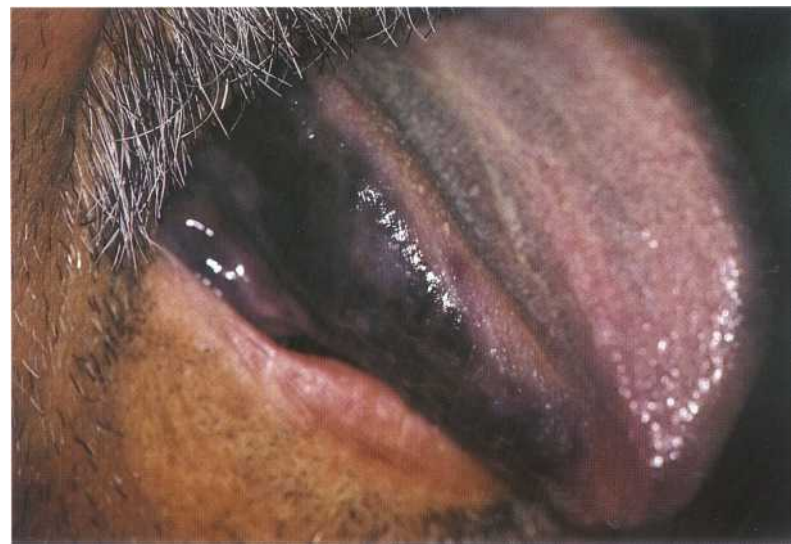

Fig. 380. Uremic stomatitis, extensive hematoma on the tongue.

## 25. Metabolic Diseases

### Amyloidosis

Amyloidosis is a rare metabolic disorder characterized by the extracellular deposition of a fibrillary proteinaceous substance known as amyloid. Deposition in sufficient amounts in vital tissues and organs can induce symptoms and signs or even death.

Amyloidosis is classified into four major forms based on clinical, histochemical, and immunologic criteria; primary, secondary, senile, familial. Primary and secondary forms may be either systemic or localized.

Primary systemic amyloidosis, now referred to as immunoglobulin-related (light chains-AL) amyloidosis, is the most serious form of the disease, affecting mainly men, usually older than the age of 50 years. About 10 to 25% of the cases of primary systemic amyloidosis are associated with multiple myeloma. In this form of the disease amyloid infiltrates predominantly the gastrointestinal tract, joints, skeletal muscles, heart, nervous system, skin, oral mucosa, and rarely other organs.

The most common presenting symptoms are fatigue, weakness, weight loss, edema, dyspnea, hoarseness, bleeding, pain, carpal tunnel syndrome, etc. Cutaneous and oral mucosa manifestations may occur in about 30 to 50% of patients. The most common cutaneous lesions are purpura, petechiae, papules, nodules, and rarely bullous eruptions, ulcers, alopecia, and waxy discoloration of the skin (Fig. 381). The oral mucosa is involved early in the course of the disease, and the most frequent manifestations are petechiae, ecchymoses, papules, nodules, macroglossia, ulcers, minor and major salivary gland-infiltration, xerostomia, regional lymph node enlargement, and rarely hemorrhagic bullae (Figs. 382-384). The tongue is characteristically enlarged, firm, and indurated with red-yellowish nodules along the lateral border. The gingiva is usually clinically normal. The deep red hue of oral lesions is a typical feature of oral amyloidosis. The prognosis is unfavorable, with a mean survival period of about 2 years from the onset of symptoms.

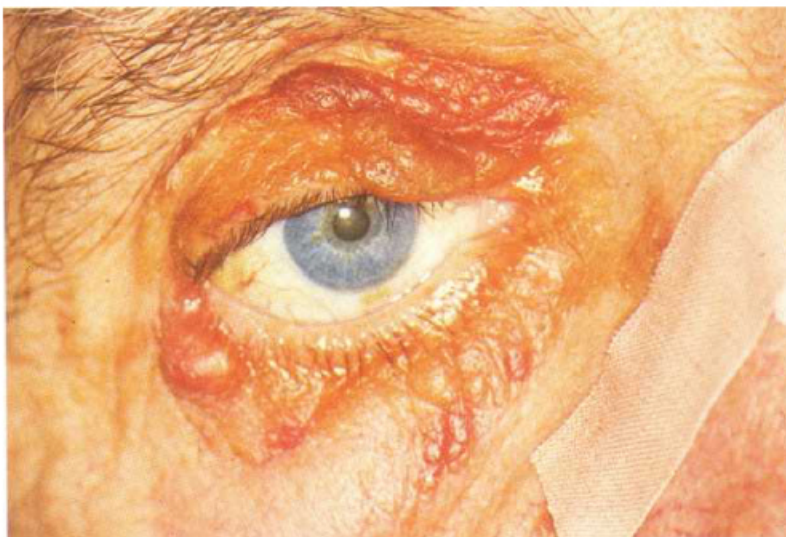

Fig. 381. Primary systemic amyloidosis, multiple papules and nodules on the eyelid.

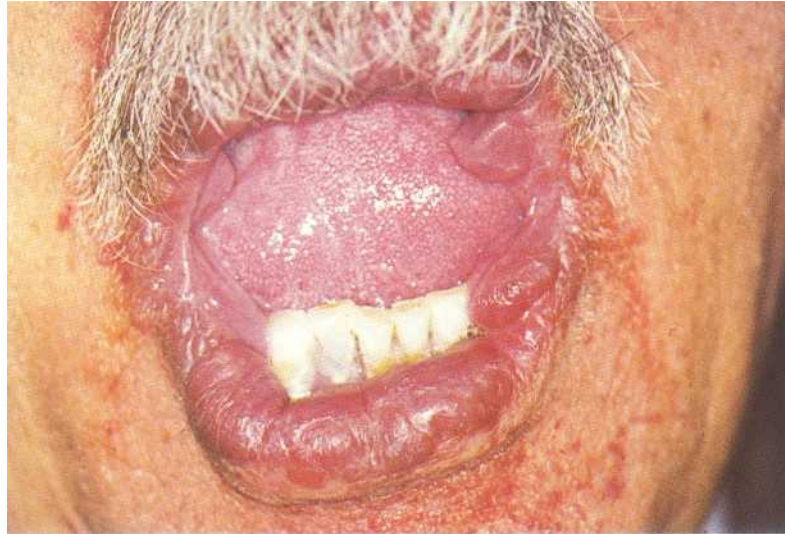

Fig. 382. Primary systemic amyloidosis, deep red nodules on the lips.

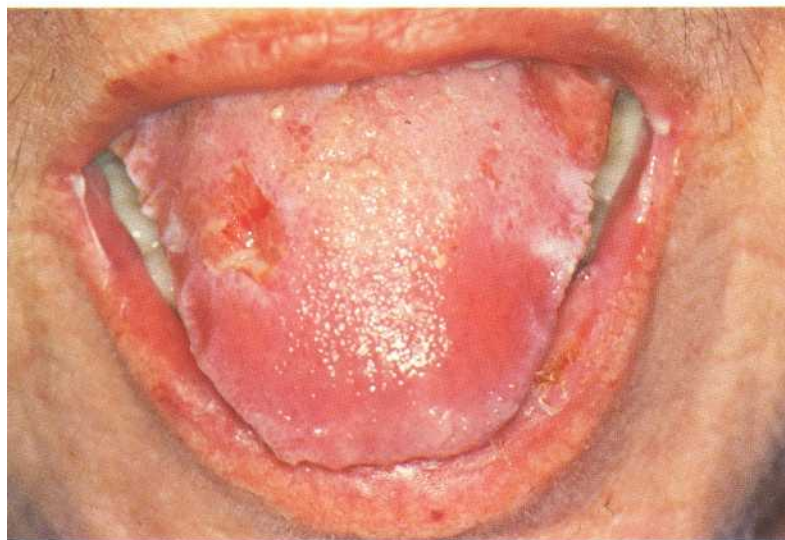

Fig. 383. Primary systemic amyloidosis, macroglossia, ecchymoses, and ulcer on the tongue.

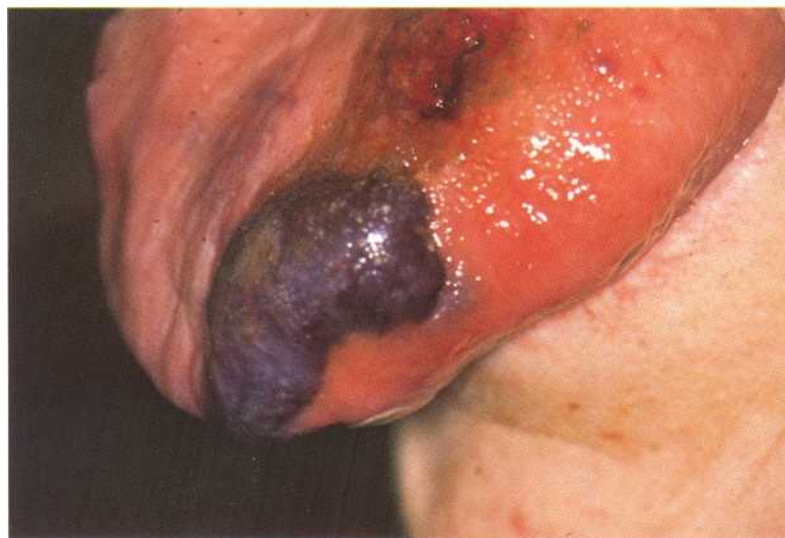

Fig. 384. Primary systemic amyloidosis, hemorrhagic bulla on the tongue.



Secondary amyloidosis (amyloid A protein-AA) is the most common form of amyloidosis and accompanies several chronic illnesses, such as paraplegia and other chronic neurologic diseases, rheumatoid arthritis, leprosy, Hodgkin's disease, tuberculosis, and regional ileitis. Amyloid in secondary amyloidosis infiltrates predominantly the kidneys, spleen, liver, adrenals, and rarely other organs. The oral mucosa and the skin are rarely involved.

The differential diagnosis includes lipoid proteinosis, sarcoidosis, Crohn's disease, multiple neurofibromatosis, Kaposi's sarcoma, macroglossia due to other causes, and, rarely, chronic bulbous diseases.

**Laboratory test.** Histopathologic examination with special stains (Congo red, sirius red, thioflavine T, and methyl violet) are helpful in establishing the diagnosis.

**Treatment.** Treatment is usually symptomatic. Ascorbic acid, colchicine, systemic corticosteroids, melphalan, and dimethyl sulfoxide have been used.

### Lipoid Proteinosis

Lipoid proteinosis, or hyalinosis cutis et mucosae, or Urbach-Wiethe disease, is a rare hereditary metabolic disorder transmitted as an autosomal recessive trait. The disease primarily affects the skin, oral mucosa, larynx, and rarely other organs. It is characterized by the deposition of an amorphous hyaline-like material (glycoprotein) in the mucous membranes and skin. Clinically, the early skin changes are characterized by the presence of papules, nodules, and pustules (Fig. 385). Later, scars are formed that are the typical cutaneous changes. These acnelike scars, although more evident on the face, are also seen on other skin regions. Verrucous hyperkeratotic lesions in areas exposed to pressure or trauma may also occur. The face, eyelid margin, pressure, and exposed areas are the most frequently affected sites. The oral manifestations are early, common, and may become more severe with aging. In young patients the oral changes consist of induration of the lip mucosa and the posterior part of the tongue. By the second decade, granular lesions appear on the lip and papular lesions on the palate and tongue. Progressively, the affected mucosa becomes paler and pitted in structure. The lingual frenulum becomes indurated, thick, and short, resulting in

reduced mobility of the tongue. Finally, the oral mucosa becomes firm and glossy with increased induration, fissures, and scarring (Fig. 386). Oral infections and ulcers may also be seen. Stenosis of the major salivary gland openings, hypodontia, and enamel hypoplasia may also occur. Hoarseness is the most characteristic symptom present from infancy or early childhood and is due to incomplete closure of the vocal cords because of deposition of the proteinaceous material. The posterior wall of the pharynx shows pinpoint lesions, patches, or a network of yellow-white or whitish lines. Dysphagia and difficulty in swallowing may also be encountered due to oral, pharyngeal, or esophageal involvement.

The differential diagnosis includes amyloidosis, porphyria, Hurler's syndrome, and pseudoxanthoma elasticum.

**Laboratory test.** Histopathologic examination of biopsy specimens is necessary to establish the diagnosis.

Treatment is supportive.

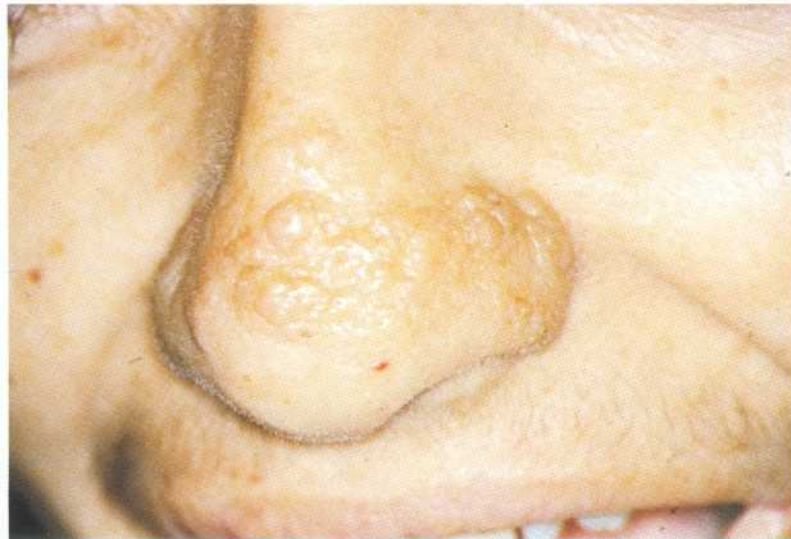

Fig. 385. Lipoid proteinosis, nodules on the nose.

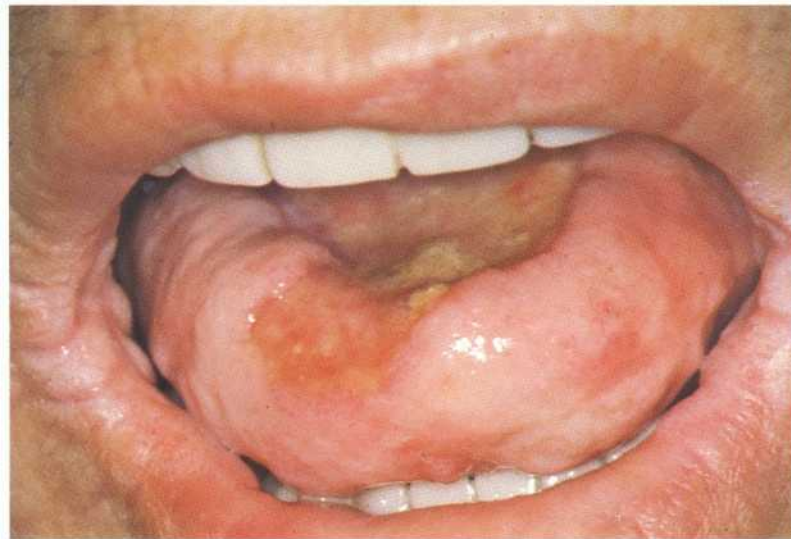

Fig. 386. Lipoid proteinosis, large and glossy tongue.

### **Glycogen Storage Disease Type 1 b**

The glycogen storage diseases are a group of genetic disorders involving the metabolic pathways of glycogen. Glycogen storage disease Ib is a rare severe autosomal recessive metabolic disease caused by a defect in the microsomal translocase for glucose-6-phosphate. The clinical features of the disease are hypoglycemia, hyperlipidemia, hepatomegaly, delayed physical development, bleeding diathesis, short stature, hepatic adenoma, enlarged kidneys, "doll's face" (Fig. 387), neutropenia, and recurrent infection. Oral manifestations are frequent and include rapidly progressive periodontal disease and recurrent ulceration. The oral ulcers appear as discrete, deep, punched-out lesions a few millimeters to several centimeters in size, usually covered by whitish pseudomembranes (Fig. 388).

The differential diagnosis includes cyclic neutropenia, agranulocytosis, congenital neutropenia, Papillon-Lefevre syndrome, acatalasia, hypophosphatasia, Chediak-Higashi syndrome, and diabetes mellitus.

**Laboratory test.** Increased lactate, cholesterol, triglyceride, uric acid, and hematologic examinations are helpful in establishing the diagnosis. Liver biopsy is mandatory.

Treatment is best left to the specialists. Strict oral hygiene program and antibiotics for oral complications.

### **Xanthomas**

Xanthomas are papules, nodules, or plaques of yellowish color that are due to lipid deposits in the skin and mucosae. The major lipid stored is usually cholesterol ester, although in some cases triglycerides are primarily present. Xanthomas are classified into several forms and frequently represent the hallmark of particular syndromes. The clinical importance of xanthomas is the fact that their presence implies an underlying disease. They often localize on the eyelids, the extensor surfaces of the extremities, and in areas of friction and repeated minor trauma. The oral mucosa is a rare location of xanthomas, although they may develop on the lips, gingiva, alveolar mucosa, mucobuccal fold, and buccal mucosa. Clinically, they present as well-circumscribed yellowish plaques that may be widespread or confined to one area (Fig. 389).

The differential diagnosis includes leukoplakia, Fordyce's granules, verruciform xanthoma, focal epithelial hyperplasia, and skin graft.

Laboratory tests to confirm the diagnosis are histopathologic examination and serologic determination of lipids.

**Treatment.** There is no topical treatment.

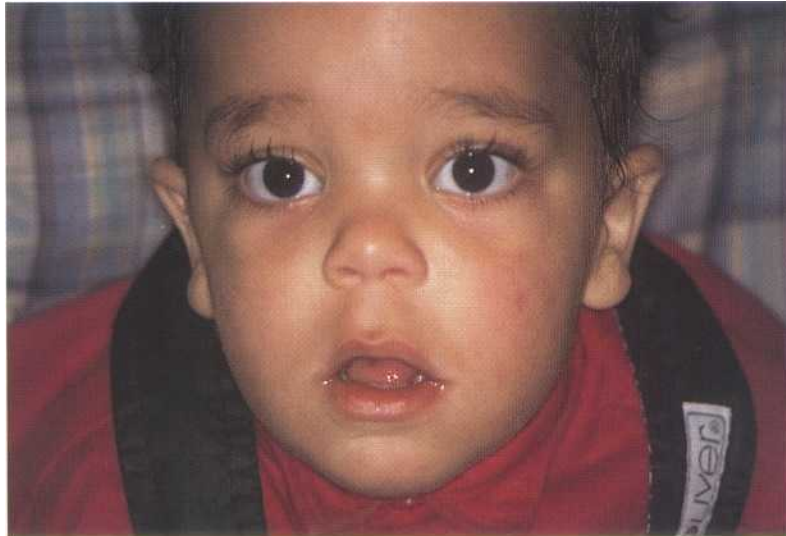

Fig. 387. Glycogen storage disease type 1 b, "doll's face".

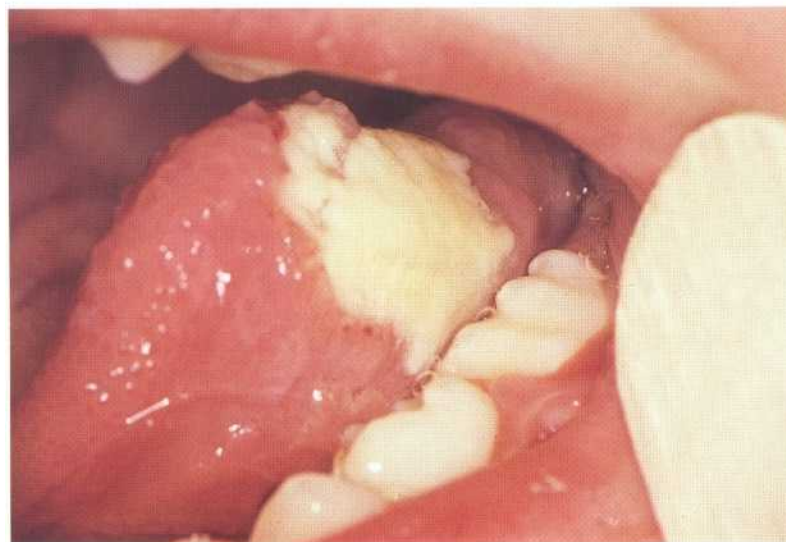


Fig. 388. Glycogen storage disease type 1 b, large ulceration on the tongue.

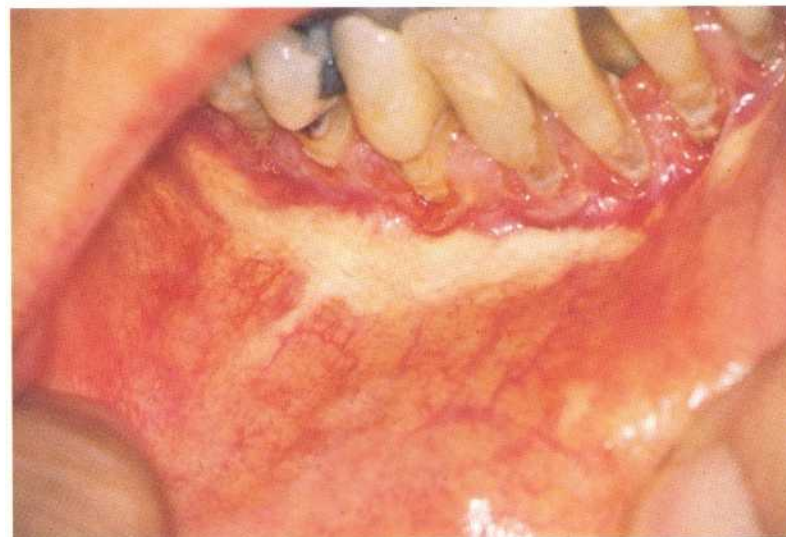

Fig. 389. Xanthomas of the mucolabial fold mucosa.

## Porphyrias

Porphyrias are a rare group of disorders characterized by a defect in porphyrin metabolism, resulting in overproduction of porphyrins and their precursors. Each type is characterized by a deficient activity of specific enzymes in heme synthesis and abnormal porphyrin patterns found either in the urine, feces, or in different tissues. On the basis of the tissue origin of abnormal porphyrin synthesis, the human porphyrias are classified into three major groups with several types: erythropoietic (congenital erythropoietic porphyria, erythropoietic coproporphyrin), hepatic (acute intermittent porphyria, variegate porphyria, Chester porphyria, porphyria cutanea tarda, hereditary coproporphyrin), and erythrohepatic (erythrohepatic protoporphyria, hepatoerythropoietic porphyria). Photosensitivity of the skin is seen in almost all types of porphyria. In addition, skin fragility, erythema, vesicles, bullae, erosions, hyperpigmentation, hypertrichosis, scars, scarring alopecia, milia, etc., are common findings. Light-exposed areas of the skin are primarily affected, along with systemic signs and symptoms.

Congenital porphyria (Gunther's disease) is a rare genetic type characterized by severe cutaneous lesions, hemolytic anemia, and splenomegaly. The presence of red-brown teeth due to incorporation of porphyrins into the developing teeth is an important diagnostic finding in both deciduous and permanent dentition. Under ultraviolet light, the teeth exhibit a characteristic reddish pink fluorescence. The oral mucosa is rarely affected in porphyrias. However, erythema, vesicles, bullae, ulcers, atrophy but no scarring may appear in congenital erythropoietic porphyria and occasionally in porphyria cutanea tarda. The oral lesions usually develop on the vermilion border of the lips, commissures, labial mucosa, anterior vestibular alveolar mucosa, and gingiva (Figs. 390, 391).

The differential diagnosis includes epidermolysis bullosa, chronic bullous diseases, lipid proteinosis, pellagra, and drug-induced photosensitivity.

Laboratory tests to establish the diagnosis are biochemical tests, histopathologic examination, and direct immunofluorescence.

Treatment is best left to the specialist.

## Hemochromatosis

Hemochromatosis is an iron-storage disorder of unknown cause resulting in deposition of large amounts of iron in the internal organs. Hemochromatosis may be either genetic or acquired. Clinically, the disorder is characterized by the coexistence of diabetes mellitus, liver cirrhosis, hyperpigmentation, and less frequently gonadal deficiency, cardiac failure, and joint disorders. Hyperpigmentation may appear both in skin and mucous membranes (oral and conjunctiva). The skin acquires a generalized gray-brown pigmentation in almost all cases. The oral mucosa shows diffuse homogeneous pigmentation of gray-brown or deep brown hue in about 20% of the cases. The buccal mucosa and the attached gingiva are the most frequently involved sites (Fig. 392). In addition, major and minor salivary gland involvement has been reported.

The differential diagnosis includes Addison's disease, drug-induced hyperpigmentation, and normal pigmentation in dark-skinned persons.

Laboratory tests. Routine laboratory tests may reveal evidence of diabetes mellitus and liver dysfunction. In addition, the serum determination of iron, transferrin, and ferritin are helpful in establishing the diagnosis according to standard criteria.

Treatment is best left to the specialist.

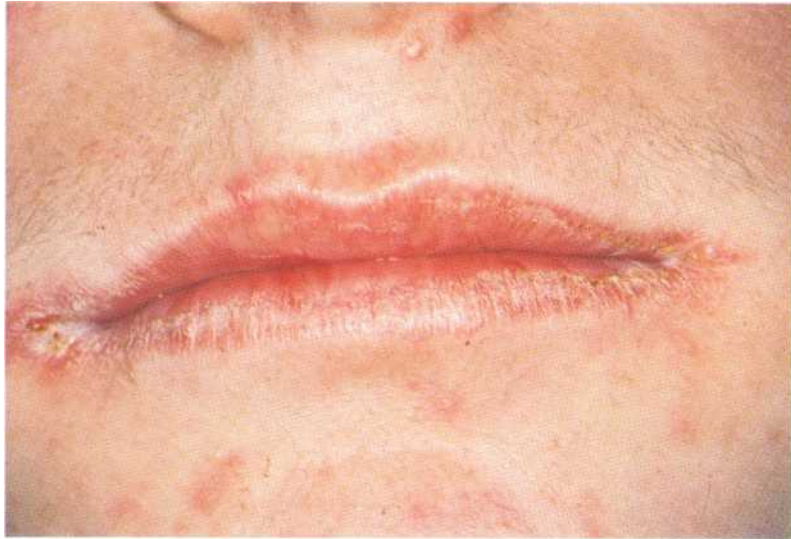

Fig. 390. Porphyria cutanea tarda, erythema of the lips and angular cheilitis.

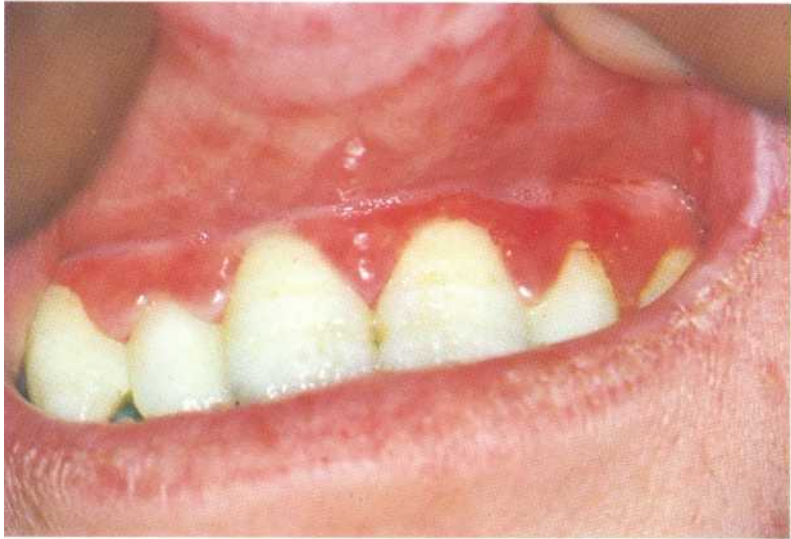

Fig. 391. Porphyria cutanea tarda, diffuse erythema on the gingiva and upper lip mucosa.

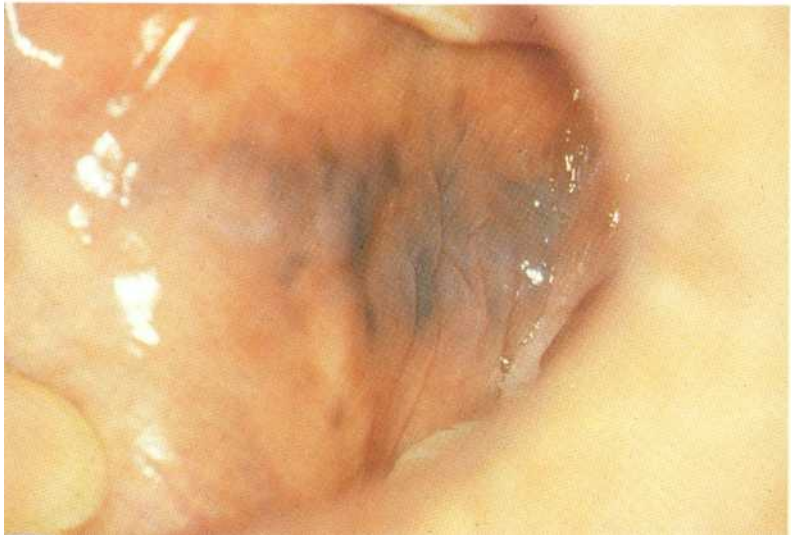
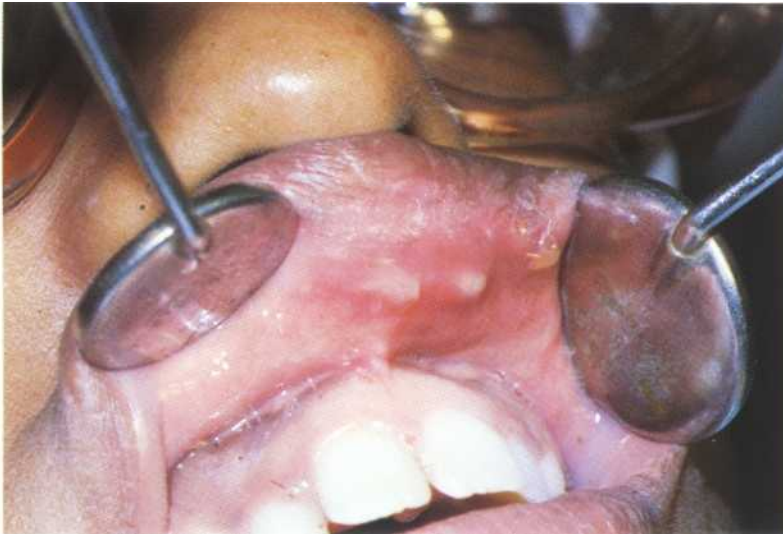
Fig. 392. Hemochromatosis, pigmentation of the buccal mucosa.



**Fig. 393. Cystic fibrosis, localized swelling of the upper lip.**

### Cystic Fibrosis

Cystic fibrosis is a relatively common inherited disorder due to a defective gene on chromosome 7. The disease is characterized by dysfunction of the exocrine glands, particularly the exocrine pancreas, bronchial, tracheal, and gastrointestinal tract glands. The cardinal manifestations are chronic pulmonary infections, pancreatic insufficiency, cirrhosis, skeletal disorders, and skin wrinkling. The salivary glands are affected as part of the generalized exocrine gland involvement. Clinically, the lips may be dry and swollen (Fig. 393).

The differential diagnosis includes cheilitis glandularis, mucopolysaccharidosis, and lipoid proteinosis.

Laboratory test. Histopathologic examination of lip biopsy may confirm the diagnosis. Elevated levels of chloride, potassium and sodium in sweat and lack of pancreatic enzymes in the duodenal fluid are the most reliable diagnostic tests for cystic fibrosis.

Treatment is supportive.

### Histiocytosis X

Histiocytosis X or Langerhans' cell histiocytosis is a proliferative disease of the Langerhans' cells. It is one of the most poorly defined, clinically heterogeneous, diagnostically variable, and prognostically unforeseeable clinical entities. The disease spectrum includes three varieties: Letterer-Siwe disease, Hand-Schuller-Christian disease, and eosinophilic granuloma. Letterer-Siwe disease is the acute disseminated form, which usually appears during the first year of life and has a poor prognosis. Clinically, it is characterized by fever, chills, hepatosplenomegaly, anemia, lymphadenopathy, osteolytic bone lesions, generalized skin rash (petechiae, scaly papules, nodules, vesicles, ulcers), and oral manifestations (Fig. 394). The oral lesions are ulcers, ecchymoses, gingivitis, periodontitis, and loose teeth (Fig. 395).

Hand-Schuller-Christian disease is the chronic disseminated form, which has a more benign course. It usually appears between 3 and 6 years of age and affects predominantly boys (2: 1 ratio). Clinically, there is a classic triad consisting of osteolytic bone lesions (particularly of the skull), exophthalmos, and diabetes insipidus. This triad is present in only 25% of patients. Otitis media, a skin rash, and involvement of internal organs may also occur. The oral cavity is frequently involved in the early stages of the disease, with ulcers, edema, hyperplasia, and necrosis of the gingiva, halitosis, and bad taste (Fig. 396). In cases of involvement of the jaw bones there is loosening of the teeth and severe periodontitis

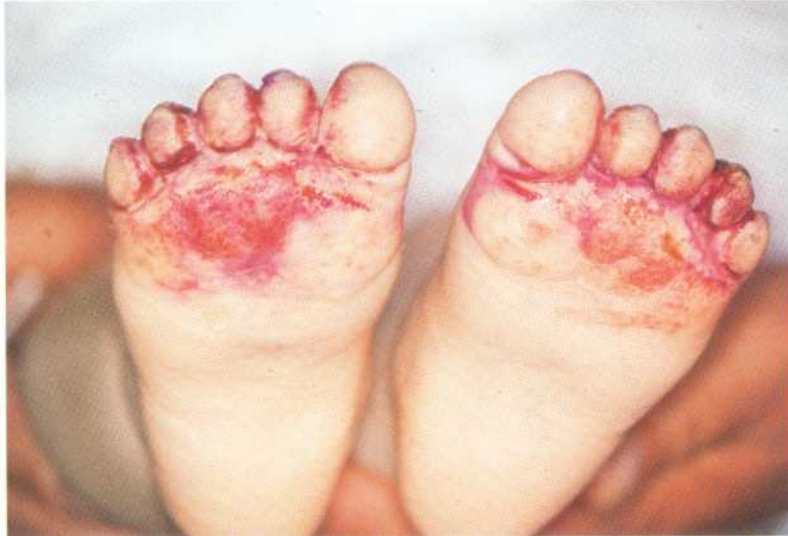

Fig. 394. Letterer-Siwe disease, vesicles and ulcers on the skin in a 1-year-old boy.

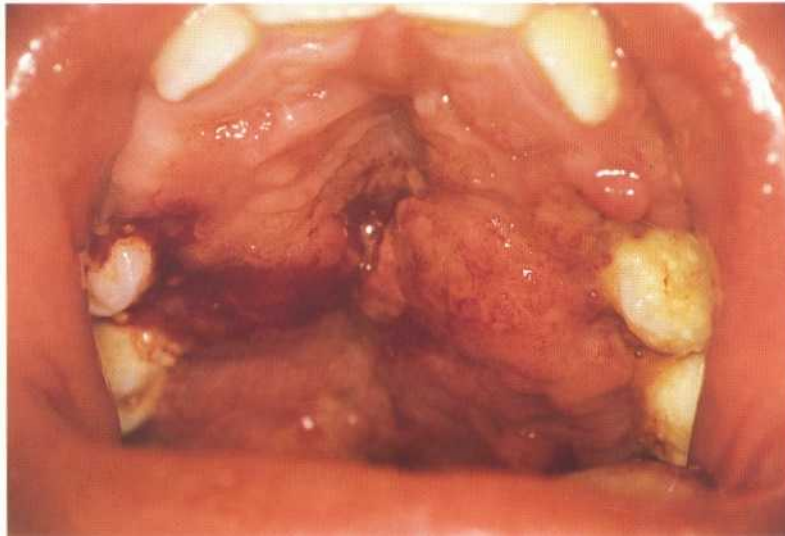


Fig. 395. Letterer-Siwe disease, vegetating ulcer on the palate in a 2-year-old boy.

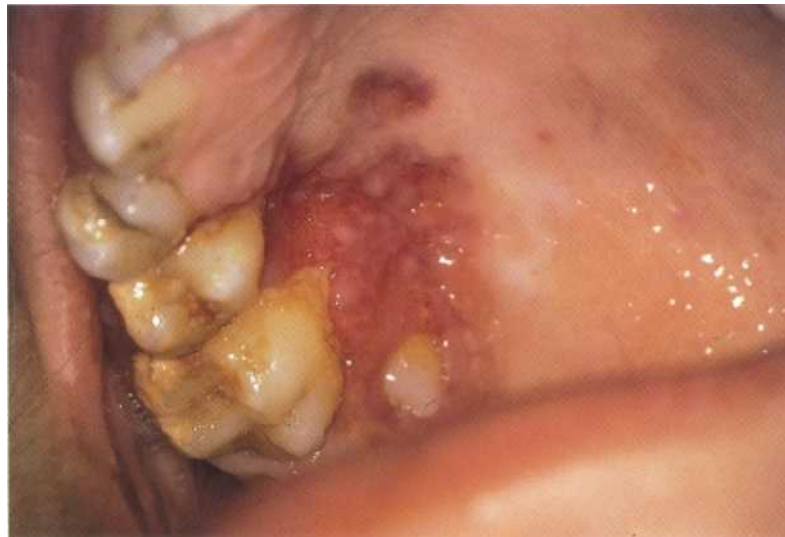
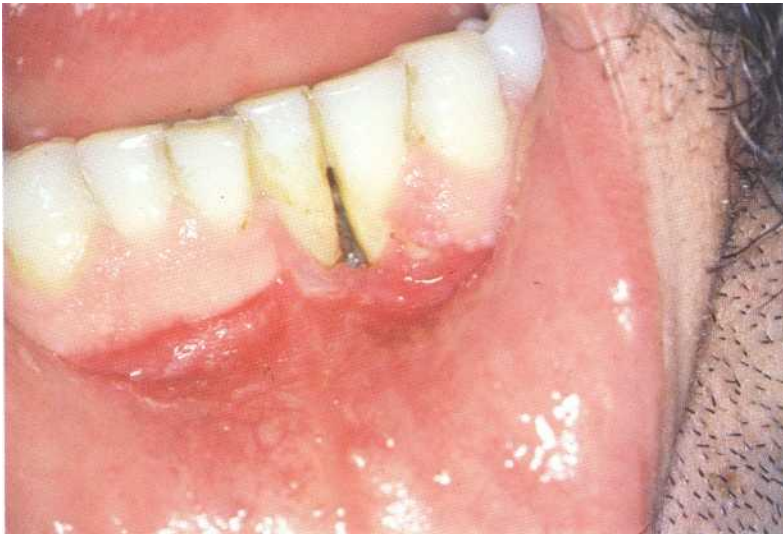
Fig. 396. Hand-Schüller-Christian disease, large ulcer on the gingiva and palatal mucosa.





**Fig. 397. Eosinophilic granuloma, ulcer, and bone destruction of the periodontal tissues between the central and lateral incisor teeth.**

leading to loss of the teeth. Delayed healing of tooth sockets after extraction may be seen.

Eosinophilic granuloma is the localized benign form and usually affects adolescents or young adults. Males are affected more frequently than females. Clinically, the disease is characterized by asymptomatic monostotic or polyostotic osteolytic bone lesions, and on rare occasions there may be local edema and pain.

The jaw bones may be affected and bone destruction may occur, with loosening and loss of teeth. Oral mucosal ulcers, particularly on the gingiva and hard palate, may occur (Fig. 397). The oral lesions of eosinophilic granuloma should not be confused with an eosinophilic ulcer.

The differential diagnosis includes eosinophilic ulcer, acatalasia, hypophosphatasia, juvenile periodontitis, malignant neoplasms with ulcer formation, metastatic carcinoma, and multiple myeloma.

**Laboratory test.** Histopathologic examination and radiographs of the involved areas help to establish the diagnosis.

**Treatment.** Curettage or excision of lesions. Radiotherapy may be helpful. Corticosteroids and cytotoxic agents are used in the generalized forms of histiocytosis X. Immunotherapy may also be helpful.

## 26. Nutritional Disorders

### Pellagra

Pellagra is a deficiency of nicotinic acid. The clinical features of this rare disease are: gastrointestinal manifestations, such as abdominal pain, diarrhea, achlorhydria; nervous system manifestations, such as apathy, restlessness, anxiety, paresthesias, hallucinations, amnesia, loss of orientation; and symmetric dermatitis, particularly on areas exposed to sunlight and friction. This is characterized by sharply outlined erythema with scaling; the surface of the lesions is dry and rough, and vesiculobullous lesions may also occur. With time, the skin becomes hard and pigmented, with a marginated darker edge (Fig. 398). The oral mucosa is involved with edema, redness, and an intense burning sensation. The tongue is smooth because of desquamation of the papillae, and painful ulcers may appear (Fig. 399). Gingivitis, dry and fissured lips, angular cheilitis, and dysphagia are also prominent features.

The differential diagnosis includes stomatitis medicamentosa, erythema multiforme, nutritional deficiencies, and porphyrias.

Treatment is nicotinamide administration.

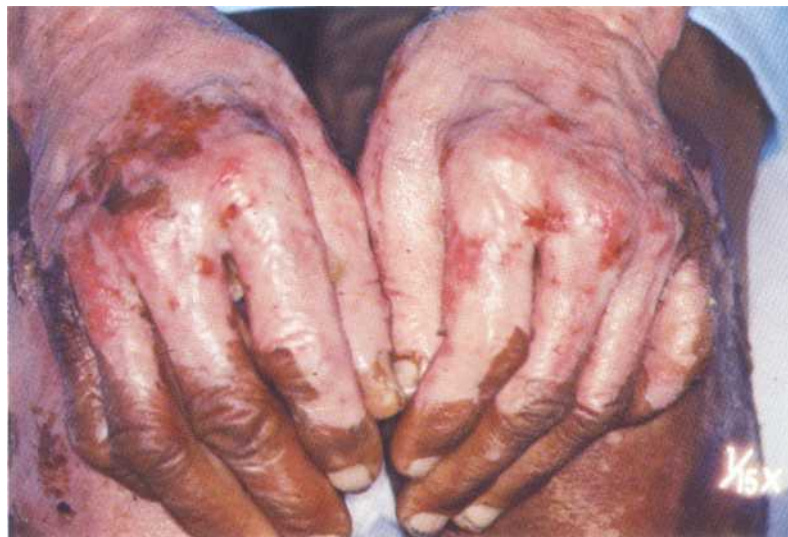
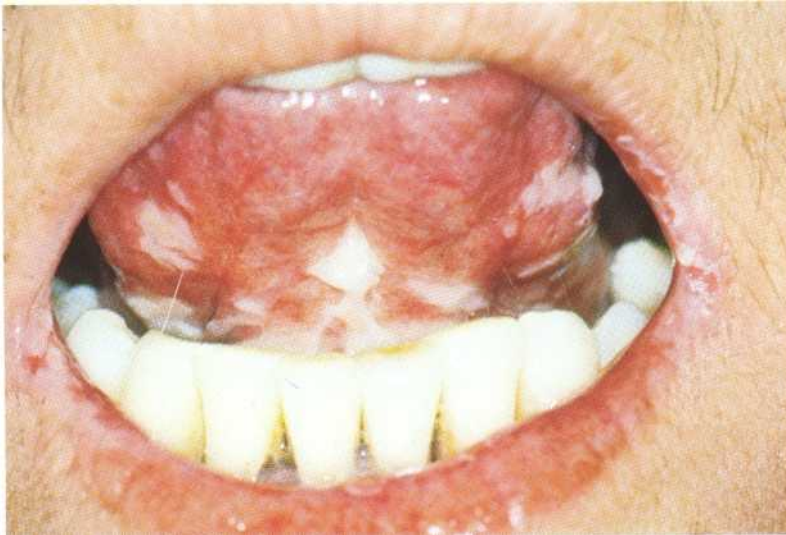
Fig. 398. Pellagra, typical skin lesions.



**Fig. 399. Pellagra, erythema and erosions on the ventral surface of the tongue.**

### **Ariboflavinosis**

Riboflavin, or vitamin B<sub>2</sub>, deficiency may result in seborrheic dermatitis, corneal vascularization, and, in advanced stages, keratitis and oral lesions. The most frequent oral manifestation is angular cheilitis, which may be unilateral or bilateral. The lips are dry and cracked. In most cases atrophy of the filiform papillae results in a smooth red tongue (Fig. 400).

The differential diagnosis includes angular cheilitis and Plummer-Vinson syndrome.

Treatment consists of vitamin B<sub>2</sub> replacement.

### **Scurvy**

Scurvy is caused by vitamin C deficiency. The clinical manifestations include malaise, susceptibility to infections, skin ecchymoses, hematomas and hemorrhages, delayed wound healing, and oral lesions. Early oral manifestations consist of swelling and redness of the interdental and marginal gingiva, and later gingival bleeding and ulcers may develop (Fig. 401). Petechiae, ecchymoses, and hemorrhages are commonly seen, as well as enamel hypoplasia of developing teeth. Mental symptoms, edema of the lower extremities, pain, and anemia may also occur.

The differential diagnosis includes necrotizing gingivitis, herpetic gingivitis, leukemia, and agranulocytosis.

Treatment consists of vitamin C replacement.

### **Protein Deficiency**

Protein deficiency is associated with several severe pathologic conditions, such as malignant diseases, nutritional disorders, metabolic diseases, and diseases with malabsorption and inadequate diet. A specific nutritional disease known as kwashiorkor is a classic protein malnutrition condition mainly affecting children. Clinically, the disorder is characterized by weight loss, edema, muscle wasting, weakness, skin hyperpigmentation, hair loss, anemia, hypoglycemia, hypotension, etc. The oral manifestations are atrophic glossitis with loss of papillae, redness and atrophy of the oral mucosa, angular cheilitis, and burning mouth (Fig. 402).

The differential diagnosis includes mainly vitamin deficiencies with which it frequently coexists.

Treatment requires a complete and balanced diet.

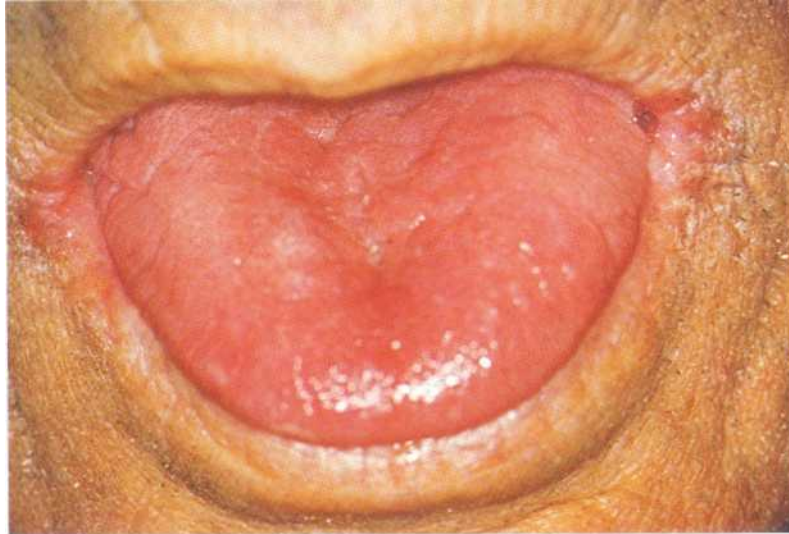

Fig. 400. Ariboflavinosis, angular cheilitis, erythema, and atrophy of tongue papillae.

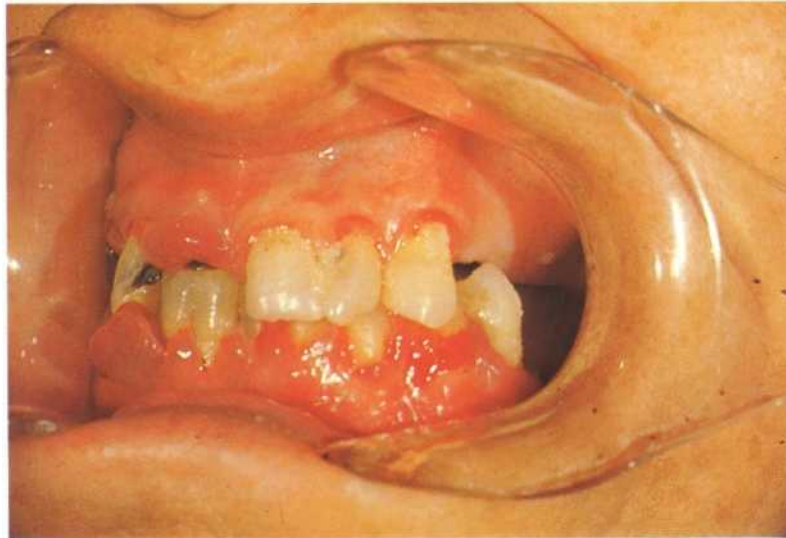

Fig. 401. Scurvy, swelling and redness of the gingiva.

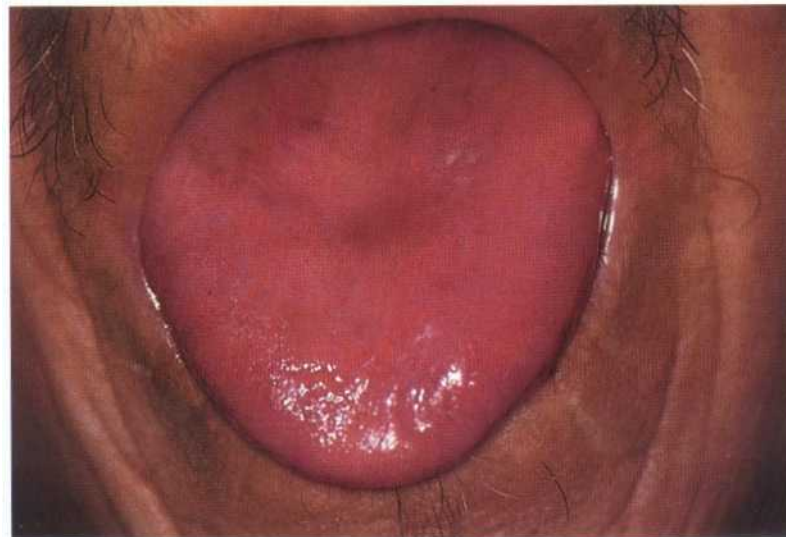


Fig. 402. Protein deficiency, redness and atrophy of the dorsal surface of the tongue.

## 27. Endocrine Diseases

### Diabetes Mellitus

Diabetes mellitus is a chronic metabolic syndrome caused by relative or absolute insulin deficiency. In its complete expression the disease is characterized by fasting hyperglycemia, atherosclerotic and microvascular changes, and neuropathy. In overt diabetes there is prominent polydipsia, polyuria, weight loss, generalized weakness with or without a tendency toward ketosis, depending on the clinical type of the disease. The oral manifestations associated with diabetes mellitus are variable and nonspecific. Gingival tenderness, gingivitis, and periodontitis are common (Fig. 403). Other oral disorders are xerostomia, glossodynia, taste change, fungal and bacterial infections, and delayed wound healing.

**Treatment.** The treatment of the oral lesions includes oral hygiene, periodontal therapy, systemic antibiotics, or antifungal agents. Control of diabetes mellitus by the specialist is very important.

### Adrenocortical Insufficiency

Adrenocortical insufficiency is an endocrine disorder characterized by insufficient secretion of glucocorticoids and mineralocorticoids.

In the primary form of the disease (Addison's disease) there is destruction of the adrenal cortex due to infection, autoimmunity, infiltration by a tumor, amyloid or other substances, hemorrhage, infarction, etc.

The marked increase in circulating adrenocorticotrophic hormone (ACTH) and related peptides causes increased hyperpigmentation of the skin and oral mucosa, especially in areas of friction. Dark brown pigmentation of the oral mucosa is an early and common feature of the disease (Fig. 404). It may be spotty or diffuse and involves the buccal mucosa, the palate, the lips, and the gingiva bilaterally.

Secondary adrenocortical insufficiency occurs when ACTH secretion is deficient because of pituitary or hypothalamic disease. In this case the hyperpigmentation of the skin and mucosae is absent.

In its full expression adrenocortical insufficiency of either type is characterized by cachexia, abdominal pain, orthostatic hypotension, tachycardia, fever, and shock.

The differential diagnosis includes normal pigmentation, pigmentation due to drugs, Peutz-Jegher's syndrome, pigmented nevi, lentigo maligna, and malignant melanoma.

**Laboratory tests.** The diagnosis is established by assay of plasma cortisol, ACTH measurement, and the ACTH stimulation test. In secondary adrenocortical insufficiency, pituitary function tests are also indicated.

Treatment is best left to the endocrinologist.

### Hypothyroidism

Hypothyroidism is a disease caused by insufficient secretion of thyroid hormones.

It may be primary due to failure of the thyroid to secrete sufficient amounts of these hormones, secondary due to insufficient stimulation of the thyroid gland by thyrotropin, or tertiary due to a hypothalamic disorder resulting in insufficient pituitary secretion of thyrotropin.

If the disease occurs at birth, it is termed congenital hypothyroidism and may result in severe mental handicap, delayed skeletal growth, sluggishness, myxedema, protracted neonatal jaundice, and a characteristic hoarse cry. Oral manifestations of congenital hypothyroidism include macroglossia, enamel dysplasia, and delayed eruption of the teeth (Fig. 405). In the adult form of the disease myxedematous changes of the skin, carotenemia, mental slowing, bradycardia, constipation, and susceptibility to the cold

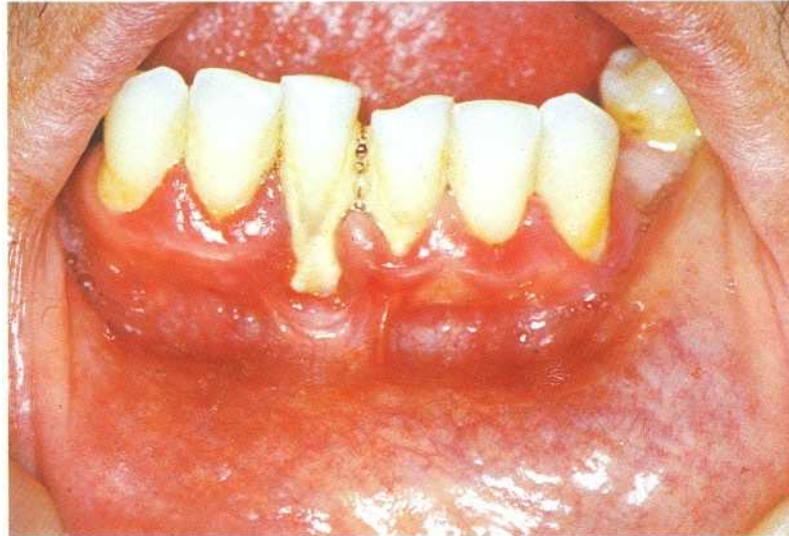

Fig. 403. Diabetes mellitus, severe periodontitis.

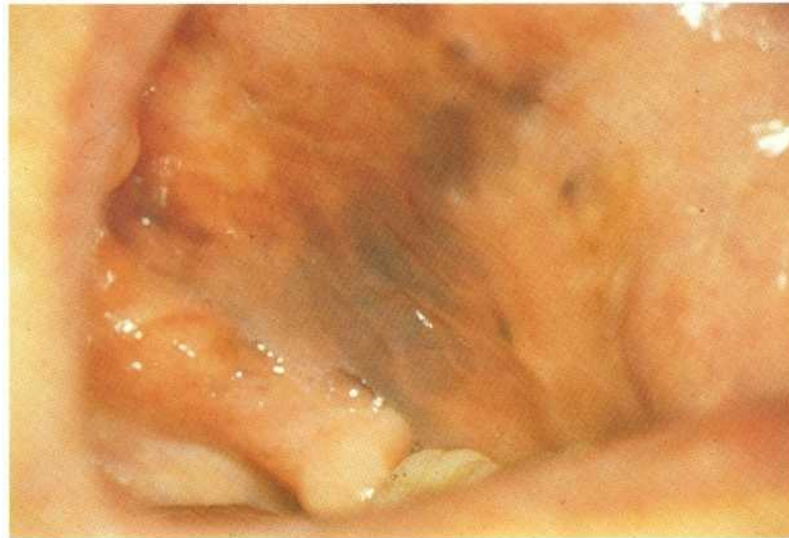

Fig. 404. Addison's disease, pigmentation of the buccal mucosa.

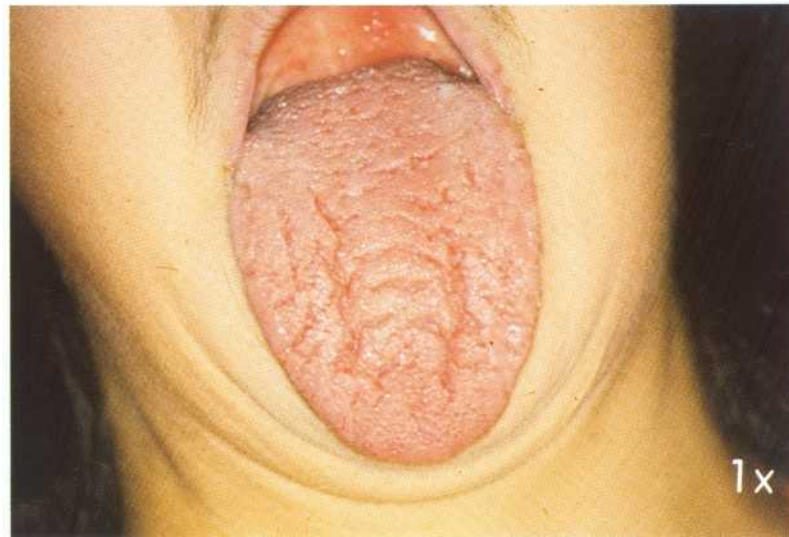

Fig. 405. Primary hypothyroidism, marked macroglossia.

or hypothermia are present. Macroglossia, due to infiltration of the tongue with myxedematous tissue composed of mucopolysaccharides may cause difficulties in speech and mastication.

Laboratory tests. The detection of the disease depends on measurement of TSH and the circulating thyroid hormones in their bound and free form.

Treatment consists of thyroid hormone replacement.

### Primary Hyperparathyroidism

Primary hyperparathyroidism is an endocrine disease due to parathyroid hyperplasia, adenoma, or carcinoma. It may occur alone or as part of multiple endocrine neoplasia, type I.

The disease presents with polydipsia and polyuria, lassitude, mental dysfunction, muscular weakness, osteoporosis, or rarely osteitis fibrosa cystica, renal calculi, and urinary concentration.

"Brown" giant cell tumors may appear in the upper and lower jaws and may be an early sign of the disease, along with loss of lamina dura. Rarely, the tumor may protrude as a soft mass in the oral cavity due to bone destruction (Fig. 406).

The differential diagnosis of oral lesions should include peripheral and central giant cell granuloma, pyogenic granuloma, Kaposi's sarcoma, hemangioendothelioma, and hemangiopericytoma.

Laboratory tests useful for the diagnosis are histopathologic examination, biochemical tests (alkaline phosphatase, calcium, phosphorus, measurement of parathyroid hormone), and skeletal and dental radiographs.

Treatment. Excision of the "brown" tumor is curative only if the underlying disease is treated simultaneously.

### Sex Hormone Disorders

The female sex hormones (estrogens and progesterone) play an important role in the maintenance of oral health. Several disorders can effect the gingiva during the menstrual cycle, puberty, pregnancy, and menopause. The most classic example is gingivitis during pregnancy or exaggeration of gingival inflammation before or during menstruation (Fig. 407). In addition, the so-called pregnancy tumor or granuloma is not an unusual find-

ing during pregnancy. Atrophy and sensitivity of the oral mucosa, glossodynia, and dysgeusia are common during the menopausal and postmenopausal period of life.

### Acromegaly

Acromegaly is an uncommon disease caused by growth hormone excess in adults, usually from a benign pituitary adenoma. The disease may rarely be caused by ectopic GHRH production.

Acromegaly occurs most frequently between the fourth and fifth decade and clinically is characterized by enlarged hands and feet, nasal bone hypertrophy, frontal bossing, coarsening facial features, and laryngeal hypertrophy leading to a hollow-sounding voice.

Neurologic disturbances, decreased vision, musculoskeletal symptoms, cardiorespiratory and genitourinary disorders, myopathy, skin tags and acanthosis nigricans, and general symptoms (fatigue, increased sweating, heat intolerance) are also common.

Oral manifestations include macroglossia, wide spacing of the teeth, jaw overgrowth, mainly of the mandible (prognathism), and enlargement of the lips (Fig. 408).

The differential diagnosis of oral manifestations includes hypothyroidism, Down's syndrome, amyloidosis, and lipoid proteinosis.

Laboratory tests. The diagnosis is confirmed by measurement of the basal serum growth hormone level or after oral administration of glucose. Measurement of somatomedin C is also helpful. Radiologic examination to localize the adenoma is mandatory. On rare occasions measurement of serum GHRH may be indicated.

Treatment is best left to the endocrinologist. In severe cases surgical correction of enlarged jaw and tongue have been suggested.

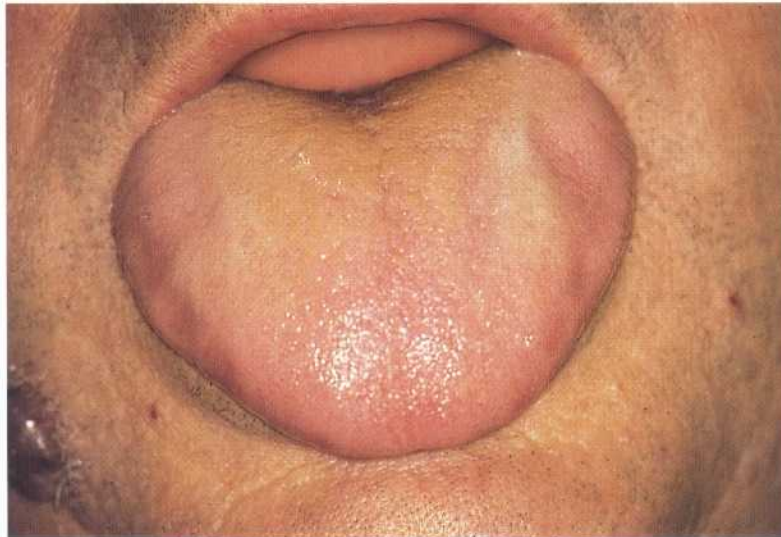
Fig. 406. Primary hyperparathyroidism, "brown" giant cell tumor on the palate.

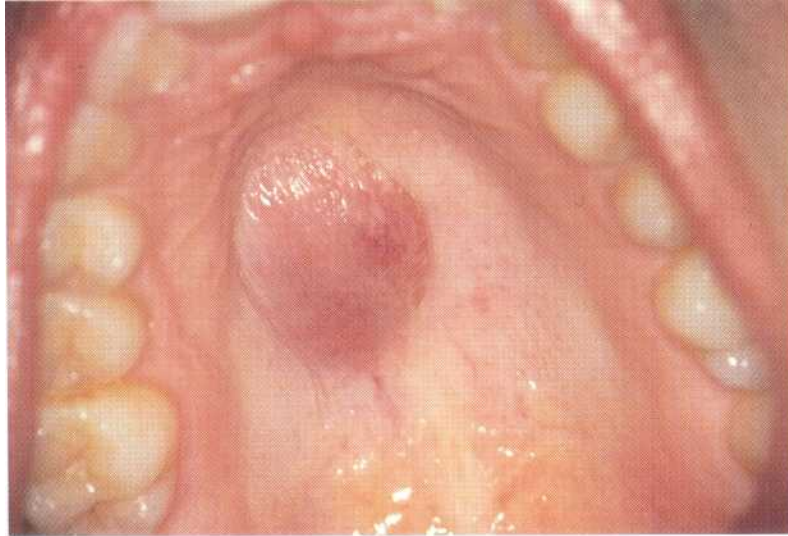

Fig. 407. Severe gingivitis during pregnancy.

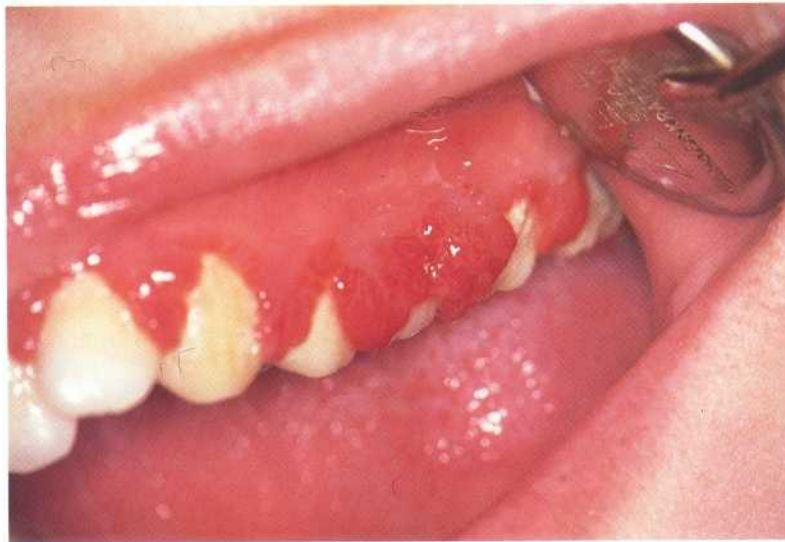

Fig. 408. Acromegaly, macroglossia.





## 28. Diseases of the Peripheral Nervous System

### Hypoglossal Nerve Paralysis

The hypoglossal nerve supplies motor fibers to most of the muscles of the tongue. Unilateral lesions of this nerve cause paralysis of the same side of the tongue. The causes may be central or peripheral and include cerebrovascular accidents, brainstem tumors, multiple sclerosis, syringomyelia, and infectious polyneuritis. In peripheral lesions there is deviation of the tongue toward the affected side, during protrusion (Fig. 409). When the tongue rests on the floor of the mouth, a mild deviation toward the unaffected side may be observed. In central lesions, involvement is often bilateral. The patient cannot protrude the tongue, and attempted movement of the tongue posteriorly is defective and uncoordinated. The tongue is also small and firm.

Treatment is aimed toward the underlying cause of the lesion of the hypoglossal nerve, or the lesion in the brain.

### Peripheral Facial Nerve Paralysis

Peripheral facial nerve paralysis is the most common cause of weakness of the muscles of facial expression. Although the exact cause remains obscure, some predisposing factors, such as viral infections, trauma, systemic diseases, tumors, and exposure to cold, have been incriminated. Malignant tumors of the parotid gland invariably induce facial nerve paralysis by invasion of the nerve. Some cases of facial nerve paralysis have been described to occur after tooth extraction or local anesthesia of the oral tissues or section of the facial nerve during surgical procedures in the parotid gland.

Peripheral facial nerve paralysis may occur at any age, but it is more frequent in young and middle-aged persons and has a seasonal variation, being more frequent during the spring and autumn. The facial paralysis is usually unilateral,

has an acute onset, and is usually associated with pain in the ear, mastoid area, or around the angle of the jaw of the affected side.

Clinically, the disease is characterized by dropping of the angle of the mouth of the involved side, inability to close the eyelid, to grin, to whistle, etc. (Fig. 410). When the patient attempts to smile, the affected side remains motionless, whereas the healthy side shows wrinkling of the skin. On attempts to close the eyes, the eyeball on the affected side is seen to deviate upward (Bell's phenomenon).

Mastication is difficult and taste disorders may be evident. Idiopathic peripheral facial nerve paralysis (Bell's palsy) may resolve within 2 months without any residual phenomena. Alternately, in a small proportion of patients, permanent paralysis may be the end result.

The differential diagnosis includes Melkersson-Rosenthal syndrome, Heerfordt's syndrome, and angioneurotic edema.

Treatment is directed toward the etiologic factor and may be supplemented by a short course of corticosteroids.

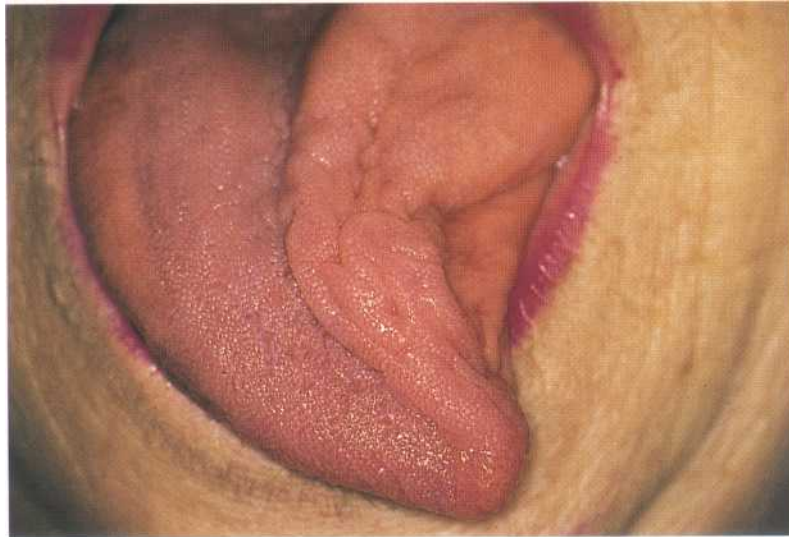


Fig. 409. Peripheral hypoglossal nerve paralysis, deviation of the tongue toward the affected side during protrusion.

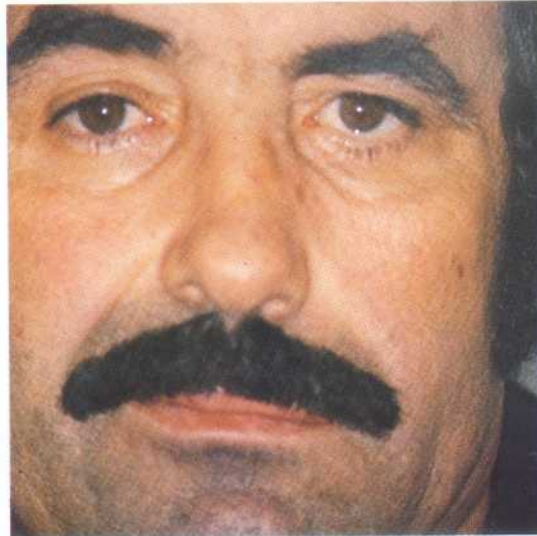


Fig. 410. Peripheral facial nerve paralysis, dropping of the angle of the mouth of the involved side.

### **Ipsilateral Masseter's Spasm**

Muscles subjected to noxious stimulation, i. e., mechanical, emotional, infective, metabolic, thermal, electric, etc., may respond by developing spasms and shortening. They usually lose their capacity to relax, and exhibit an hyperactive stretch reflex with or without the development of trigger areas that refer pain to a distant source. Usually irritation of deeper structures is the causative factor. Infections of the pterygomandibular space resulting from infections with contaminated needles and foreign bodies, and transmission of infection from pulpitis of the lower third molars produce hyperirritable muscles of mastication, usually with limited jaw opening and pain. Temporomandibular joint arthritis, prolonged overstretching of mandibular muscles, prochlorperazine side effects, pterygomandibular space infection, as well as a variety of other physical and metabolic causes are all capable of producing hyperirritable and tender masseter-ptyergoid muscles. Apart from the obvious or referral spasm and tenderness, in more subtle cases, one should apply pressure bilaterally to the mandibular muscles, asking the patient to compare the sensation on the two sides (Fig. 411). Autonomic dysfunction such as transient salivation, unilateral lacrimation, and sweating may accompany muscle spasms or the referral pain from stimulation of trigger areas in hypersensitive muscles of mastication.

The differential diagnosis includes masseteric hypertrophy, facial hemihypertrophy, parotid gland and other tumors, and Sjogren's and Mikulicz's syndromes.

Treatment is best left to the neurologist.

### **Melkersson-Rosenthal Syndrome**

Melkersson-Rosenthal syndrome is a rare disease of unknown cause usually affecting young persons of either sex. It is characterized by recurrent facial swelling, recurrent unilateral facial paralysis, and fissured tongue (Fig. 412). In the complete form of the syndrome all symptoms may appear simultaneously. Cheilitis granulomatosa is considered to represent a monosymptomatic form of the syndrome. The swelling is usually confined to the lips and face (Fig. 413). However, palatal, buccal, and lingual swelling may occur. Gingival involvement appears as small, irregular, bluish-red edematous swellings that may be localized or diffuse.

The differential diagnosis includes idiopathic facial nerve paralysis, cheilitis glandularis, angioneurotic edema, fissured tongue, Crohn's disease, and sarcoidosis.

Laboratory test. Histopathologic examination of biopsy specimen is diagnostic.

Treatment is symptomatic.

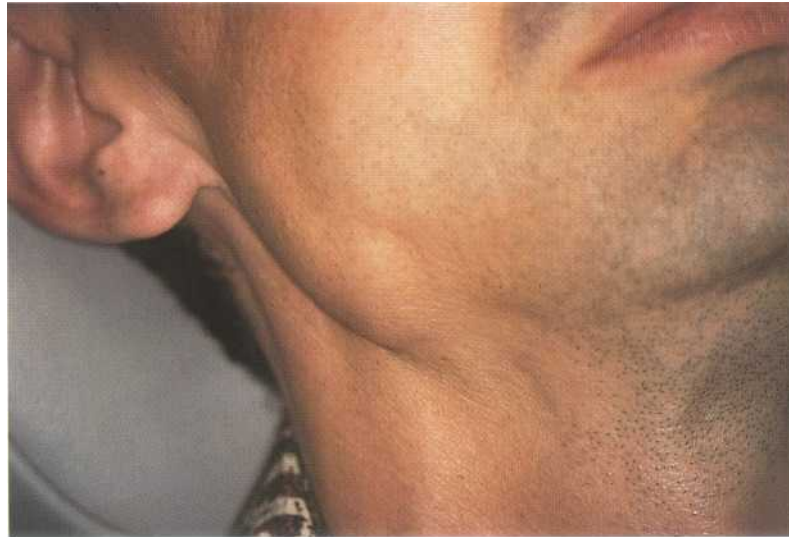

Fig. 411. Ipsilateral masseter's spasm due to hypersensitive mastication muscle's syndrome.

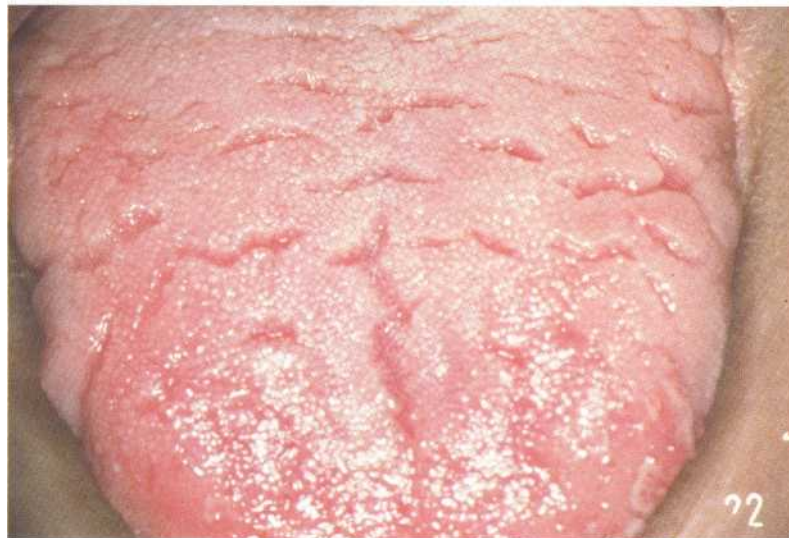

Fig. 412. Melkersson-Rosenthal syndrome, fissured tongue.

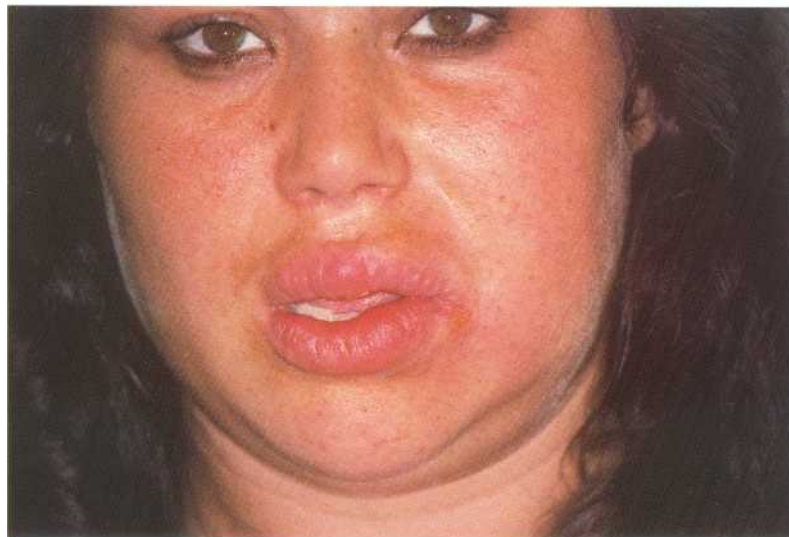

Fig. 413. Melkersson-Rosenthal syndrome, swelling of the lips and face.

## 29. Precancerous Lesions

### Leukoplakia

A precancerous lesion is defined by WHO as "a morphologically altered tissue in which cancer is more likely to occur than in its apparently normal counterpart." Oral leukoplakia is the most common and best studied precancerous lesion. Leukoplakia is a diagnosis by exclusion, and the term is now used in a clinical descriptive sense. It is defined as a white patch or plaque, firmly attached to the oral mucosa, that cannot be classified clinically and pathologically in any other disease entity. The available data show that the prevalence rate of leukoplakia ranges from 0.1 to 5% of the general population. The lesion seems to be more common in men than in women, especially between 40 and 60 years of age. The cause is still obscure. Some of the leukoplakias are tobacco-related, whereas in other cases predisposing factors, such as local irritation, *Candida albicans*, alcohol, industrial products, and possible viruses have been incriminated. However, it must be emphasized that nonsmokers with leukoplakia are

at higher risk than smokers for development of cancer. Clinically, leukoplakia can be divided into two main forms: the homogeneous, which is common and characterized by an asymptomatic white homogeneous plaque with a smooth or wrinkled surface that occasionally may be traversed by fissures or cracks (Fig. 414), and the speckled or nodular form, which is rare and is characterized by a red base with multiple small white nodules or macules on which *C. albicans* infection is often superimposed (Fig. 415). In addition, two other clinical varieties of oral leukoplakia have been described: proliferative verrucous leukoplakia, which is rare and characterized by a white irregular exophytic papillary pattern (Fig. 416), is more common in females than males, shows a relatively prompt extension, and tends to recur after surgical removal, and hairy leukoplakia, which is a unique lesion in patients infected with human immunodeficiency virus. It is characterized initially by a slightly raised, poorly demarcated, and corrugated white patch with late formation of prominent projections, and frequently it appears

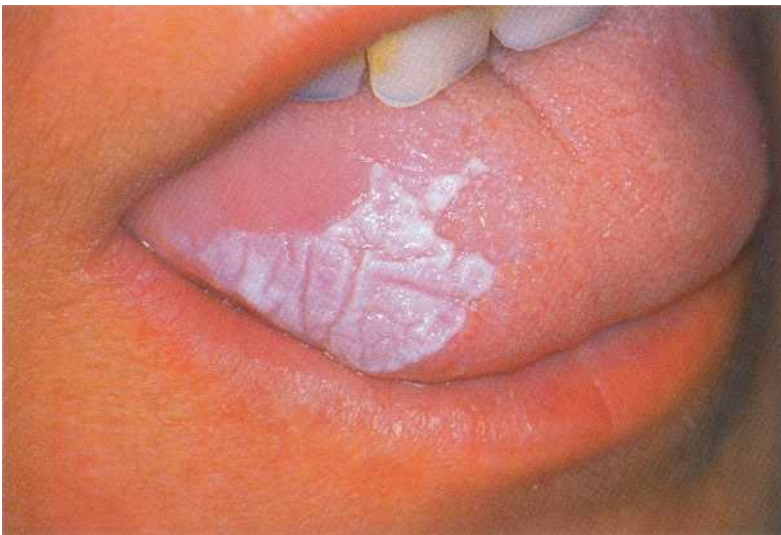

Fig. 414. Homogeneous leukoplakia of the tongue.

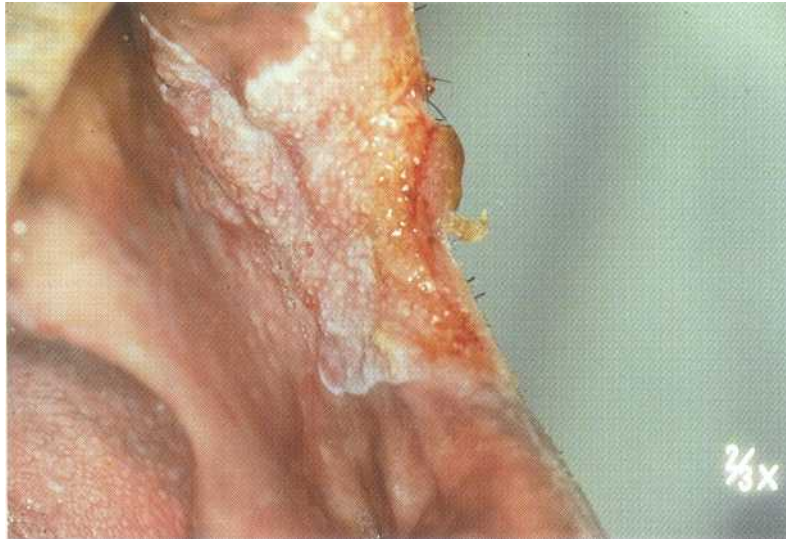

Fig. 415. Speckled leukoplakia of the buccal mucosa.

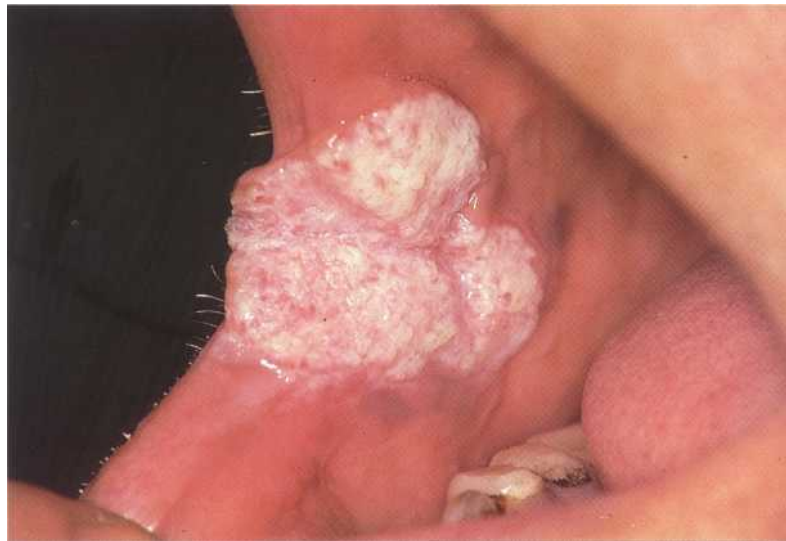

Fig. 416. Proliferative verrucous leukoplakia of the buccal mucosa.

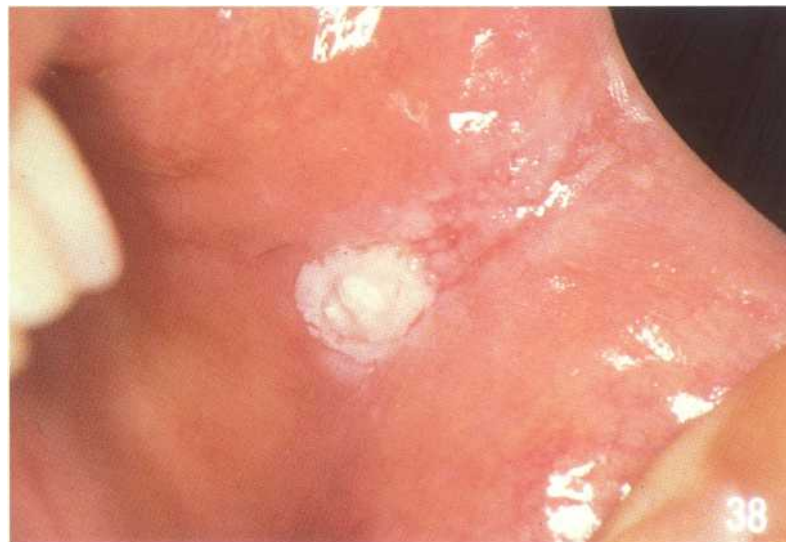
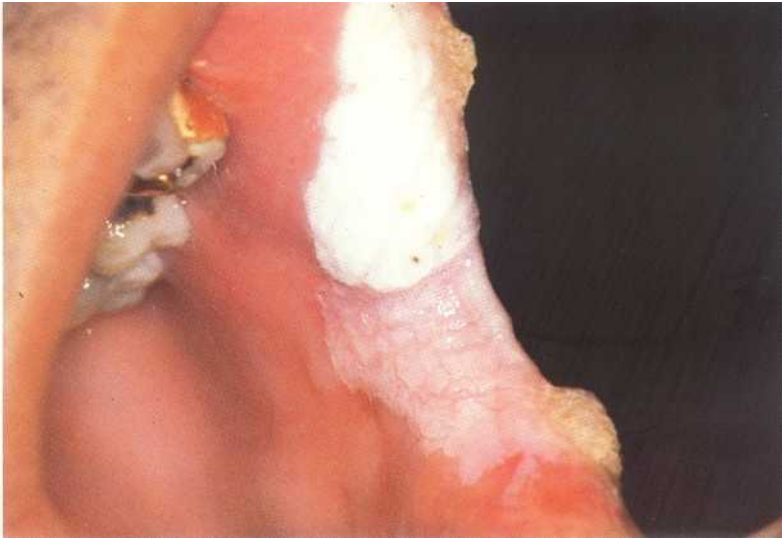
Fig. 417. Leukoplakia of the buccal mucosa.

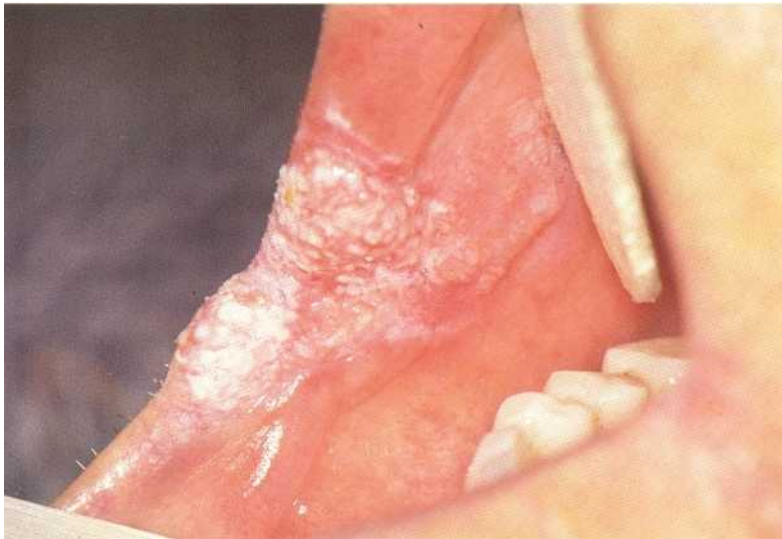on the lateral borders of the tongue. This classification has practical clinical significance, since the speckled leukoplakia is four to five times more likely to result in malignant transformation than homogeneous leukoplakia. Proliferative verrucous leukoplakia also shows an increased risk, whereas the hairy leukoplakia has not been described as progressing to malignancy.

Leukoplakia may occur at any site in the oral cavity. However, the most frequent locations are the buccal mucosa and commissures, followed by the tongue, palate, lip, alveolar mucosa, gingiva, and floor of the mouth (Figs. 417-424). The lesions may be small or large and the sites of highest risk for development of a malignancy are

the floor of the mouth, followed by the tongue and the lip. Clinical signs suggesting a potential malignancy are: speckled surface, erosion or ulceration in the lesion, development of a nodule, induration of the periphery, and the location of the lesion (high-risk sites). However, the aforementioned clinical criteria are not totally reliable and all lesions must be biopsied and subjected to rigorous microscopic examination. About 10 to 20% of clinical oral leukoplakia exhibits histologically epithelial dysplasia, carcinoma in situ, or invasive carcinoma at the time of initial biopsy. Follow-up studies of oral leukoplakia have found a frequency of malignant transformation ranging from 0.13 to 6%.



**Fig. 418. Leukoplakia of the buccal mucosa and commissure.**



**Fig. 419. Speckled leukoplakia of the buccal mucosa and commissure.**

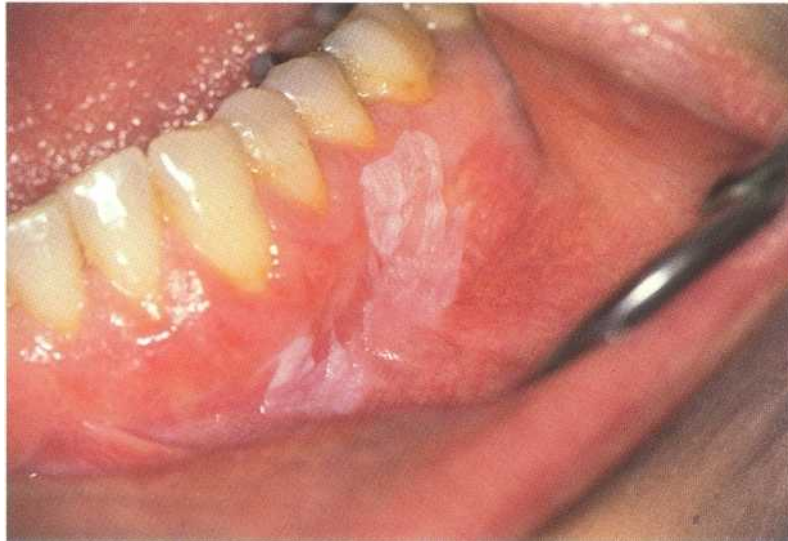

Fig. 420. Leukoplakia of the alveolar mucosa.

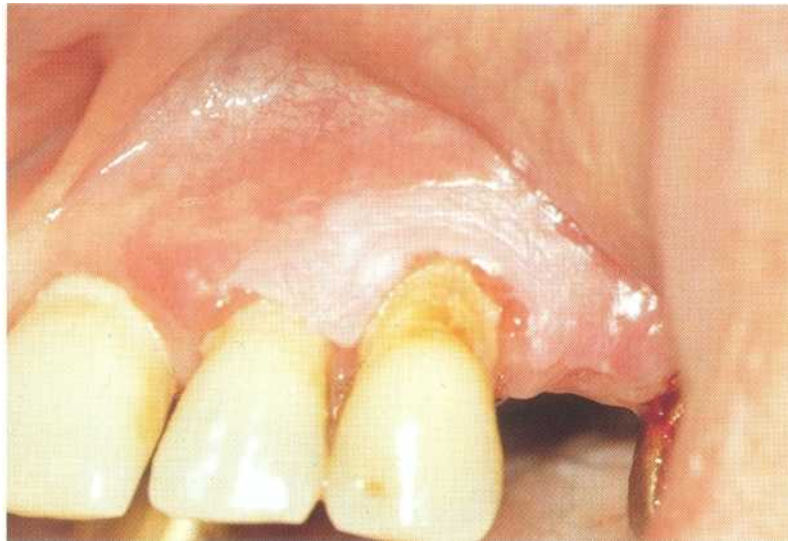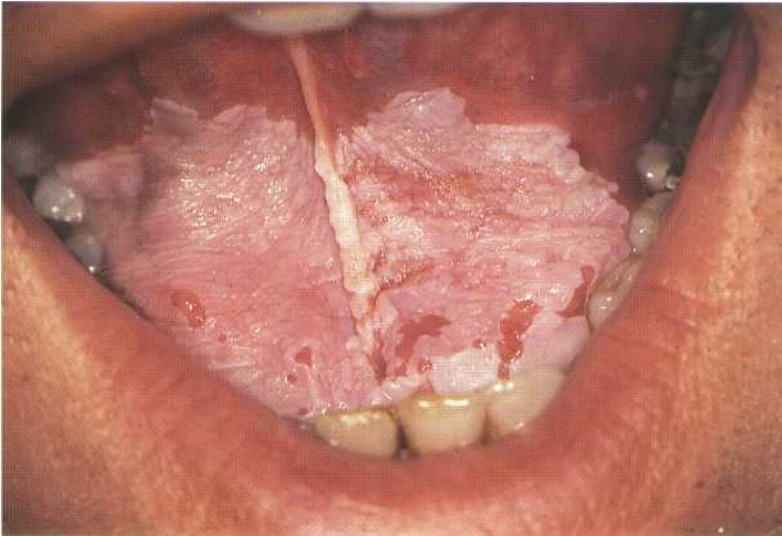


Fig. 421. Leukoplakia of the gingiva

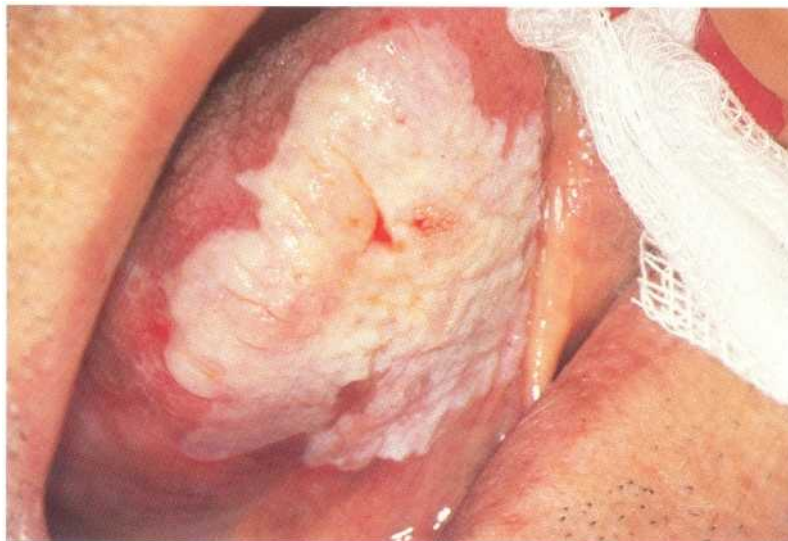

Fig. 422. Leukoplakia of the ventral surface of the tongue.





**Fig. 423. Leukoplakia of the floor of the mouth.**

The differential diagnosis includes hypertrophic lichen planus, chronic hyperplastic candidosis, chemical burn, leukoedema, discoid lupus erythematosus, and several genetic syndromes exhibiting disturbances of keratinization.

**Laboratory test.** Histopathologic examination is the most important test to define the nature and the relative risk of oral leukoplakic lesions. The presence of epithelial dysplasia signifies a precancerous lesion.

**Treatment.** Oral leukoplakia sometimes regresses after discontinuation of tobacco use. In addition, the elimination of any irritating factor is mandatory, and good oral hygiene and follow-up of the patients is indicated. Surgical excision, cryosurgery, and CO<sub>2</sub> laser are the treatment of choice. Retinoic acid has been reported to be effective.

### **Erythroplasia**

Erythroplasia, or erythroplasia of Queyrat, is a lesion frequently occurring on the glans penis and rarely on the oral mucosa. It represents a premalignant process that ultimately leads to carcinoma. The term "oral erythroplasia" is now used in a clinical descriptive sense, and it is clinically characterized by a red nonspecific plaque on the mucosa that cannot be attributed to any other known disease. There is no sex predilection, and it occurs most frequently between 50 and 70 years of age. Clinically, it appears as an asymptomatic,

slightly elevated or flat fiery red plaque of varying size, with a smooth and velvety surface that is well demarcated from the adjacent normal mucosa (homogeneous form). Sometimes, numerous white spots or plaques are noted in or peripheral to the erythematous lesion (speckled form). The floor of the mouth, retromolar area, mandibular alveolar mucosa, and mucobuccal fold are the most common sites of involvement, followed by the soft palate, the buccal mucosa, and the tongue (Figs. 425, 426). More than 91% of cases of erythroplasia exhibit histologically severe epithelial dysplasia, carcinoma in situ, or invasive squamous cell carcinoma at the time of diagnosis. The remaining 9% also shows mild or moderate epithelial dysplasia. It must be emphasized that oral erythroplasia at any site is a high risk of malignant transformation.

The differential diagnosis includes local irritation, lichen planus, discoid lupus erythematosus, erythematous candidosis, tuberculosis, and early squamous cell carcinoma.

**Laboratory test.** Histopathologic examination is essential to establish the accurate diagnosis and to determine the risk for cancer.

Treatment is surgical excision.

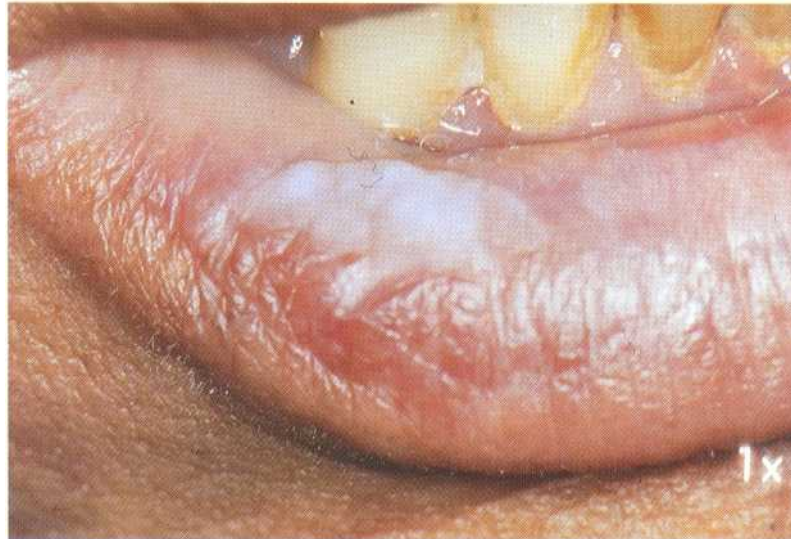

Fig. 424. Leukoplakia of the lower lip.

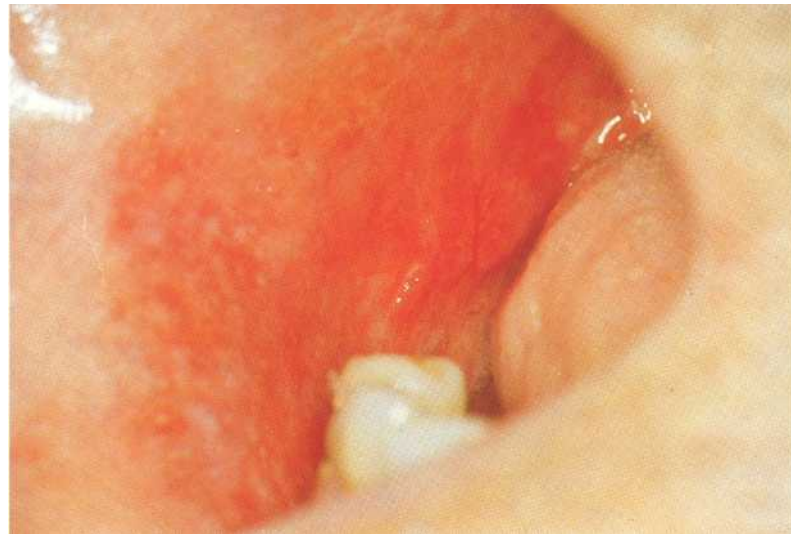

Fig. 425. Erythroplasia of the buccal mucosa.

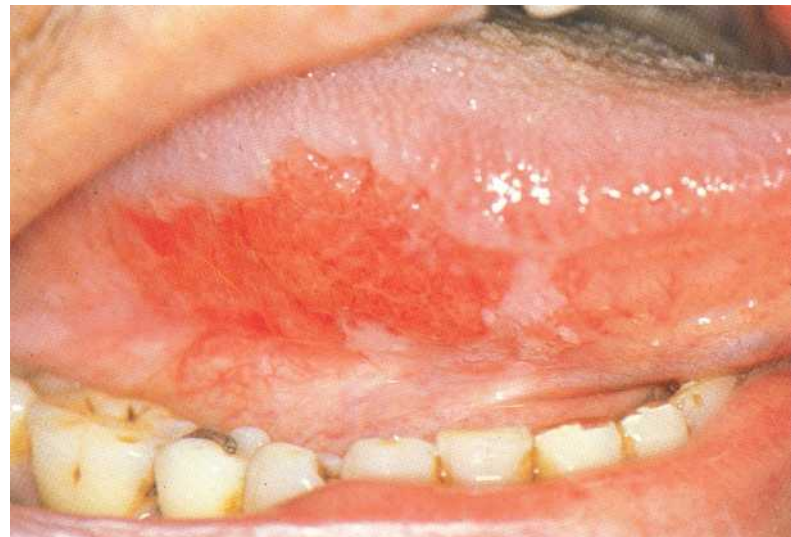
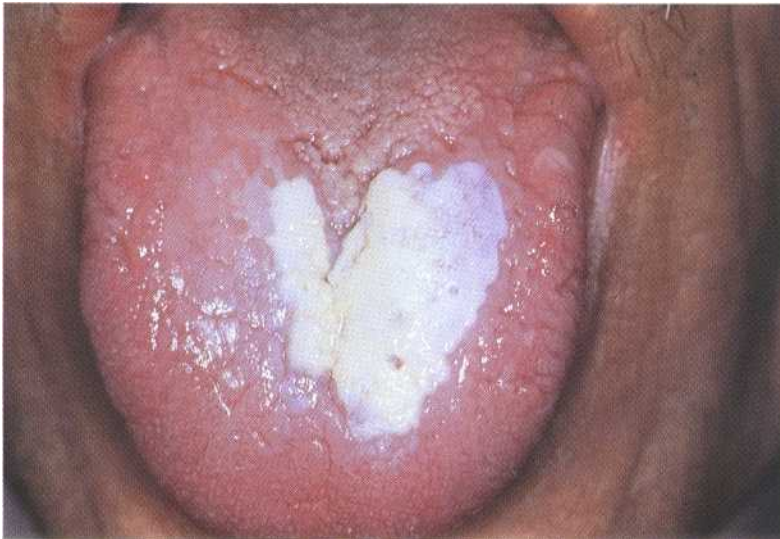
Fig. 426. Erythroplasia of the lateral margin of the tongue.



**Fig. 427.** Candidal leukoplakia of the dorsum of the tongue.

### **Candidal Leukoplakia**

Candidal leukoplakia, or nodular candidosis, is classified by some investigators as a precancerous lesion. However, others believe that *C. albicans* is simply found secondarily and dispute its role in malignant transformation. It has been shown that in 50 to 60% of oral leukoplakia cases with severe epithelial dysplasia or cases in which carcinoma develops, *C. albicans* invasion was present before the malignant transformation. Clinically, candidal leukoplakia is characterized by an intensely white, well-defined plaque not easily detached, which occasionally shows mild erythema or erosions around it (Fig. 427).

The differential diagnosis includes leukoplakia, hypertrophic form of lichen planus, white sponge nevus, and other genodermatoses associated with white oral lesions.

Laboratory test to confirm the diagnosis is histopathologic examination. In addition direct microscopic examination is helpful in establishing the presence of *C. albicans*.

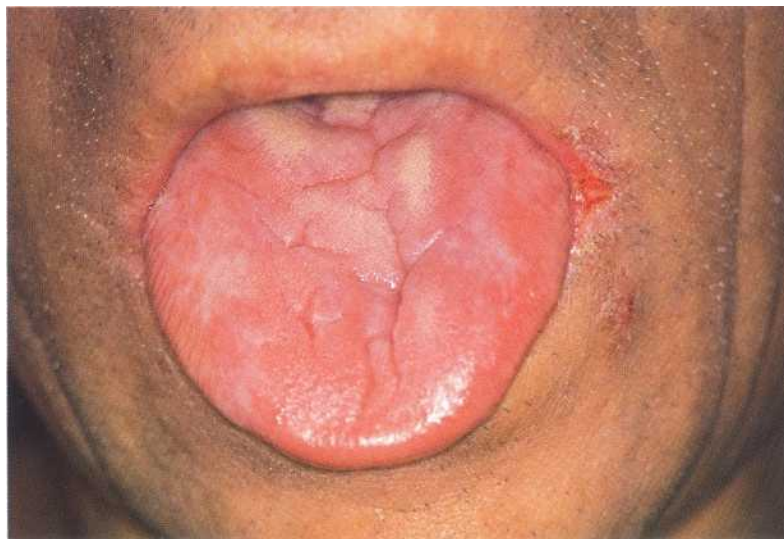**Treatment.** Topical application of nystatin, clotrimazole, miconazole, or in severe cases systemic administration of ketoconazole or fluconazole were found to be beneficial. If the lesion does not regress, surgical excision is recommended.

## 30. Precancerous Conditions

### Plummer-Vinson Syndrome

A precancerous condition is defined by WHO as "a generalized state associated with a significantly increased risk of cancer." The Plummer-Vinson syndrome, or Petterson-Kelly syndrome (iron deficiency dysphagia), involves mainly women between the fourth and sixth decade of life. In Sweden, oral cancer occurs more frequently in

women than in men (1.2: 1), in contrast to most other countries, and 25% of these women have iron deficiency. The Plummer-Vinson syndrome may be associated with oral epithelial atrophy and predisposes to squamous cell carcinoma (Fig. 428). However, this risk of malignant transformation does not seem to be as high in Europe and other countries as in Scandinavia.



**Fig. 428.** Plummer-Vinson syndrome, atrophy of the dorsum of the tongue and early leukoplakia.

### **Atrophic Glossitis in Tertiary Syphilis**

Formerly, syphilis was considered to be an important predisposing factor in the development of oral carcinoma. It is now believed that this relationship has been exaggerated in the past, and the only relationship that exists is between atrophic glossitis and carcinoma of the tongue. It is known that atrophic glossitis is a manifestation of tertiary syphilis, characterized by epithelial atrophy. It has been suggested that the atrophic epithelium is more vulnerable to the action of carcinogenic agents, resulting in leukoplakia and carcinoma (Fig. 429). Atrophic glossitis in tertiary syphilis is now very rare because of early diagnosis and treatment of syphilis.

### **Submucous Fibrosis**

Submucous fibrosis is a chronic disease of unknown cause affecting the oral mucosa and sometimes the pharynx and esophagus. It occurs almost exclusively among Indians and other Asians, although sporadic cases have been reported in other continents. Vitamin B deficiency and the use of chili, betel nut chewing, and tobacco are considered as etiologic agents. The disease is most frequent in patients between 20

and 40 years of age. Clinically, it is characterized by an intense burning sensation and vesicle formation (particularly on the palate), followed by shallow ulcers, excessive salivation, or sometimes xerostomia. Later the oral mucosa becomes smooth, atrophic, and inelastic, simulating scleroderma. The tongue is smooth without papillae, the uvula is destroyed, and multiple fibrotic bands appear on the entire oral mucosa (Fig. 430). The patient develops difficulty in opening the mouth, mastication, and swallowing. The fact that 13 to 14% of all cases histologically show epithelial dysplasia confirms the precancerous nature of the disease. In India 40 to 50% of oral cancer coexist with submucous fibrosis. Furthermore, histologically, squamous cell carcinoma was found in 5 to 6% of submucous fibrosis cases without clinical signs of carcinoma (Fig. 431).

The differential diagnosis includes scleroderma, Plummer-Vinson syndrome, pernicious anemia, atrophic lichen planus, and chronic bullous diseases.

Laboratory test. The diagnosis is confirmed by histopathologic examination.

Treatment. There is no specific therapy. Systemic and local use of corticosteroids have only a temporary effect.

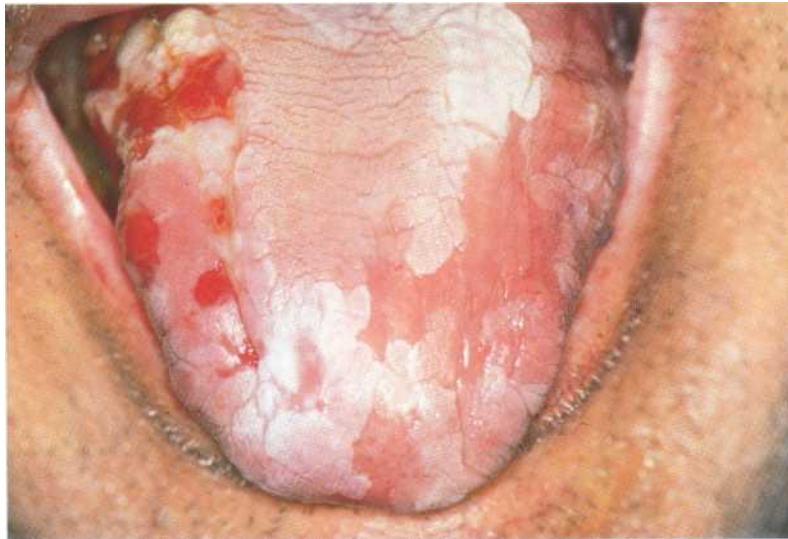

Fig. 429. Atrophic glossitis in tertiary syphilis associated with leukoplakia and early squamous cell carcinoma.

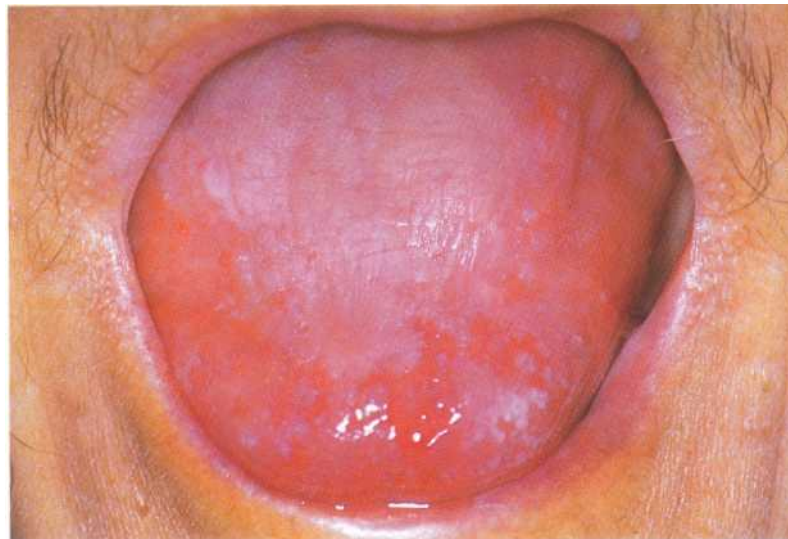

Fig. 430. Submucous fibrosis, atrophy and erosions on the tongue.

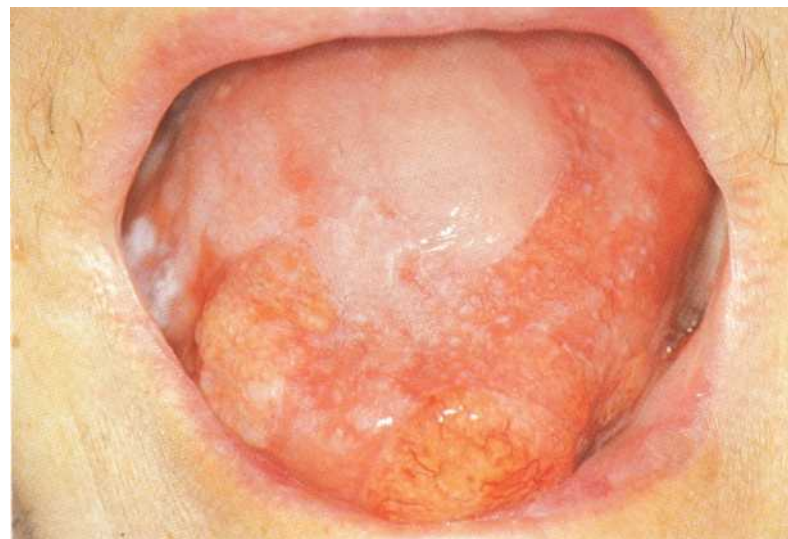

Fig. 431. Submucous fibrosis, squamous-cell carcinoma development on the tongue of patient in Figure 430, 3 years later.

### Epidermolysis Bullosa Dystrophica

Epidermolysis bullosa dystrophica is a rare hereditary disease. Both autosomal dominant and recessive variants of the disease lead to severe atrophy and scarring of the skin and mucous membranes. These patients tend to develop epithelial neoplasms, usually squamous cell carcinoma of the skin and less commonly of the oral mucosa (Fig. 432). It has recently been suggested that skin scar formation in recessive dystrophic epidermolysis bullosa is associated with a persistent growth-activated immunophenotype of epidermal keratinocytes. This chronic growth activation state or failure of cells to differentiate in a normal fashion may be linked to the high incidence of squamous-cell carcinomas.

Oral clinicians should keep in mind the possibility of development of squamous-cell carcinoma in the atrophic oral lesions of epidermolysis bullosa dystrophica, despite the fact that few cases have been reported so far.

### Xeroderma Pigmentosum

Xeroderma pigmentosum is a rare autosomal recessive disease due to a defect in the repair mechanism of DNA after exposure to ultraviolet radiation and some chemicals. It is a systemic disease that usually begins between the first and third year of life, with predominating skin, ocular, and neurologic abnormalities. Clinically, the skin is dry, atrophic, with numerous freckles, erythema, and telangiectasias. Pigmentation, scales, scars, and precancerous actinic keratosis are common manifestations as well. About 50% of the patients with xeroderma pigmentosum develop multiple malignant tumors predominantly on sun-exposed skin (squamous and basal cell carcinoma, melanoma) leading to death, usually before the age of 20 years. Squamous cell carcinoma occasionally develops on the lower lip and rarely intraorally (Fig. 433).

The differential diagnosis includes erythropoietic protoporphyria, porphyria cutanea tarda, polymorphic light eruption, Cockayne syndrome, and Bloom syndrome.

Laboratory test. Several abnormalities of cellular hypersensitivity may be detected.

Treatment. Protection from ultraviolet radiation exposure, and early diagnosis and treatment of neoplasms are suggested.

### Lichen Planus

The precancerous nature of lichen planus (see p. 184) is still debatable. Many investigators deny the premalignant potential of the disease, whereas others have reported malignant transformation varying from 0.4 to 2.5%. It has been suggested that particularly the erosive and atrophic forms of oral lichen planus show an increased risk for cancer (Fig. 434). However, the available data are unreliable and the possible precancerous nature of oral lichen planus needs further clarification.

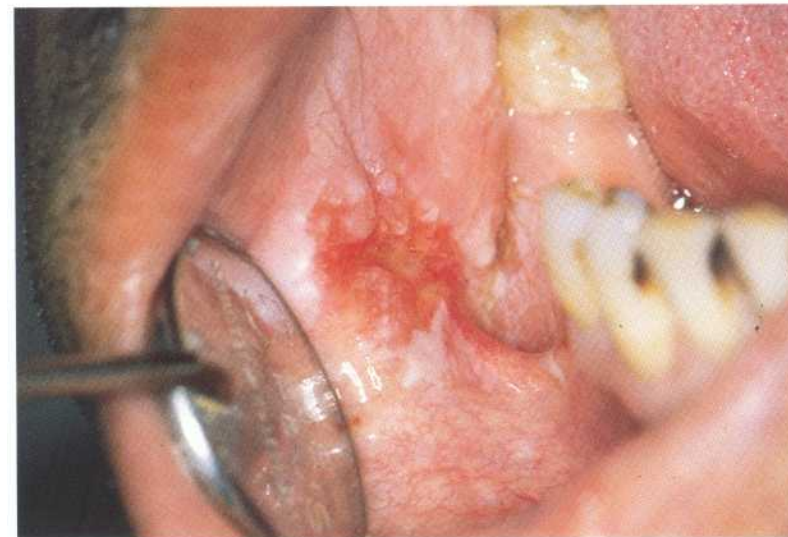
Fig. 432. Epidermolysis bullosa dystrophica, squamous-cell carcinoma on the tongue.

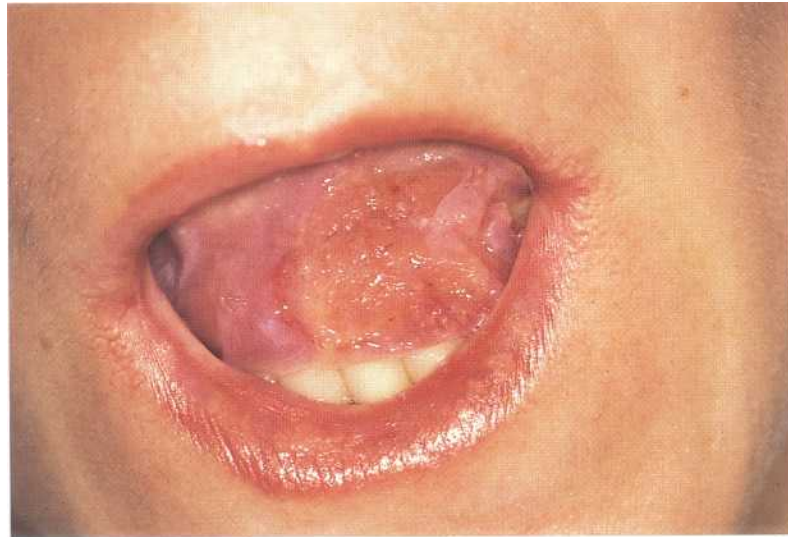

Fig. 433. Xeroderma pigmentosum, typical skin lesions and a squamous cell carcinoma on the lower lip.

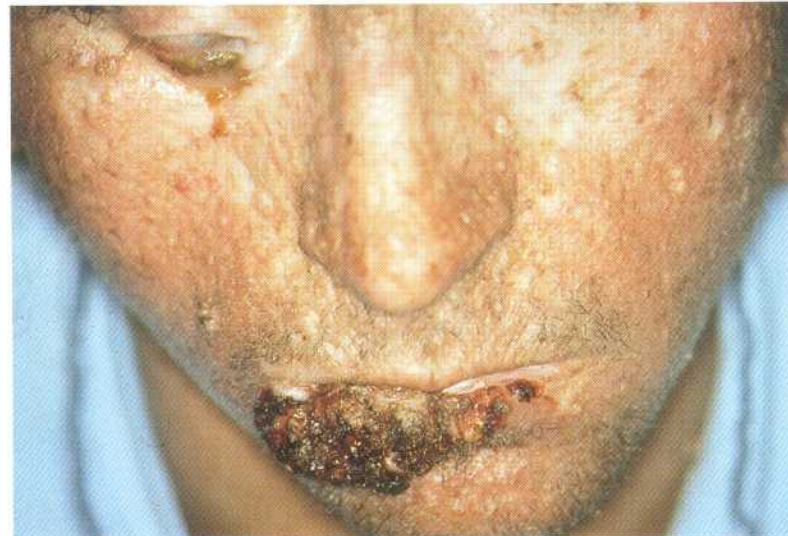

Fig. 434. Lichen planus and carcinoma in situ on the buccal mucosa.





## 31. Malignant Neoplasms

### Squamous Cell Carcinoma

Malignant neoplasms of the oral cavity account for 3 to 5% of all malignancies. Squamous cell carcinoma is the most frequent, accounting for about 90% of all malignant neoplasms of the oral cavity. The cause is unknown, although several predisposing factors have been implicated, the most important being tobacco usage, alcohol, liver cirrhosis, sun exposure, dietary deficiencies, chronic dental injuries, poor oral hygiene, viruses, etc. Squamous cell carcinoma occurs more frequently in men than women (ratio 2:1) who are usually more than 40 years of age. Although the mouth is accessible for visual examination and the patients visit the dentist for routine oral problems, the diagnosis of the disease is frequently delayed. It has been estimated that about 50% of the patients with oral carcinoma have local or distant metastases at the time of diagnosis. Clinically, oral squamous cell carcinoma may mimic a variety of diseases, thus creating diagnostic problems. Early carcinoma may appear as an asymptomatic erythematous or white lesion, or both: it may mimic an erosion, small ulcer, or exophytic mass, periodontal lesion, or even crust formation, as in lip carcinoma. In advanced stages oral carcinoma may present as a deep ulcer with irregular vegetating surface, elevated borders, and hard base; a large exophytic mass with or without ulceration; and an infiltrating hardness of the oral tissues. The chronicity and the presence of induration are important clues at any stage. The lateral borders and the ventral surface of the tongue are the most commonly affected sites. Fifty percent of all intra-oral carcinomas occur on the tongue (Figs. 435-439), followed by the floor of the mouth (Fig. 440), the gingiva, the alveolar mucosa (Figs. 441, 442), the buccal mucosa (Figs. 443, 444), and the palate (Fig. 445). The lower lip is a common site of extraoral involvement (Figs. 446, 447). The prognosis depends on the stage at diagnosis and the histologic pattern.

The differential diagnosis should include traumatic lesions, aphthous ulcer, tuberculous ulcer, primary and secondary syphilis, eosinophilic ulcer, Wegener's granulomatosis, lethal midline granuloma, lymphoma, malignant tumors of minor salivary glands, and necrotizing sialometaplasia.

Laboratory test. Biopsy and histopathologic examination are essential for accurate diagnosis.

Treatment. Surgery, radiotherapy, and chemotherapy are the basic modalities of management.

Fig. 435. Early squamous cell carcinoma of the lateral border of the tongue.

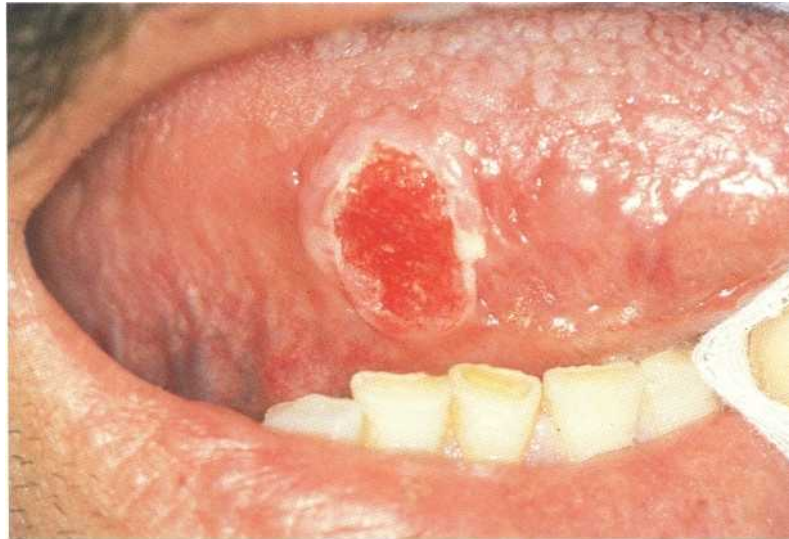

Fig. 436. Early squamous cell carcinoma of the lateral border of the tongue.

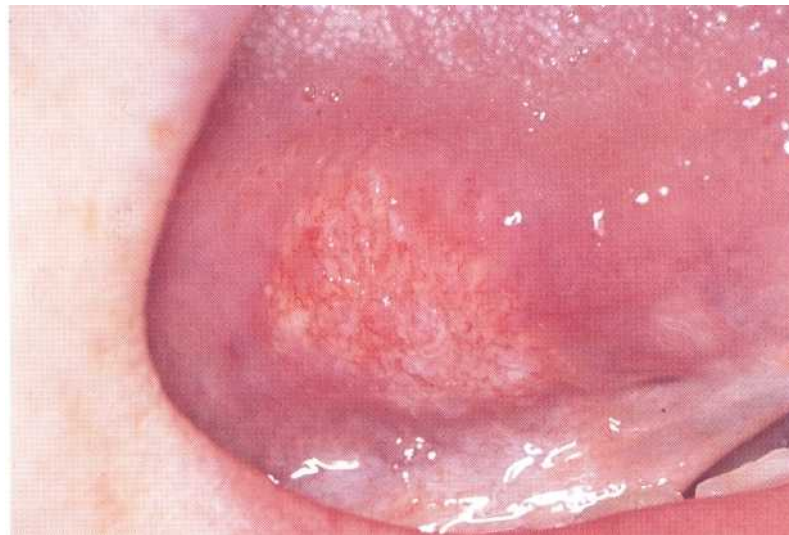

Fig. 437. Squamous cell carcinoma of the lateral border of the tongue presenting as an exophytic mass.

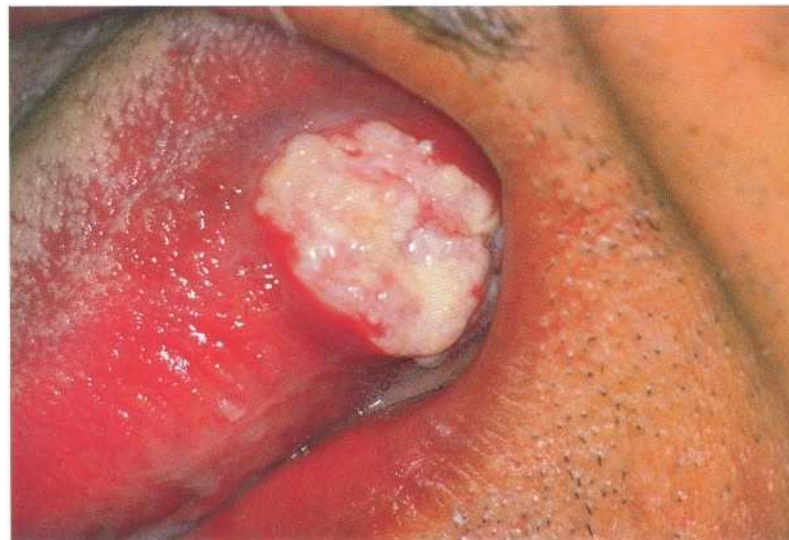

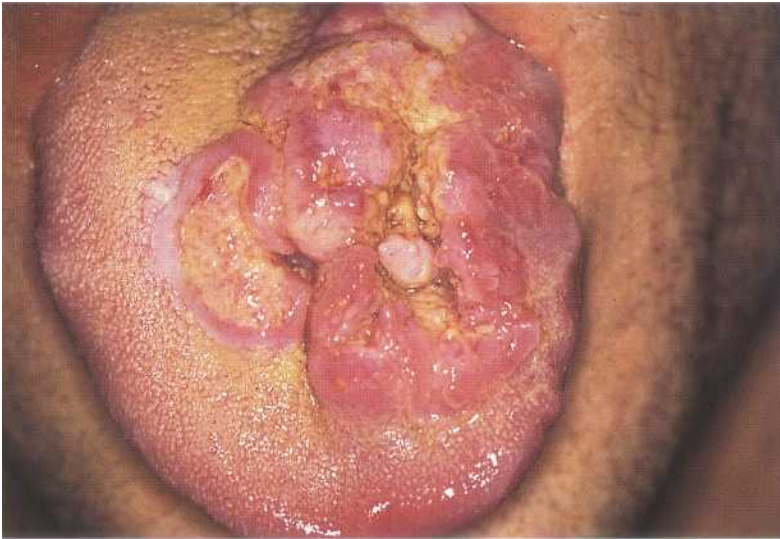


Fig. 438. Late squamous cell carcinoma on the dorsum of the tongue.

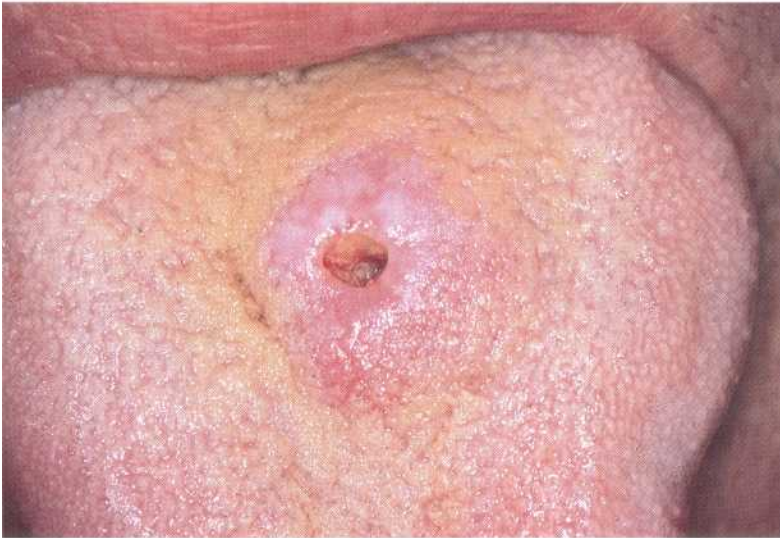

Fig. 439. Unusual location of squamous cell carcinoma on the dorsum of the tongue.

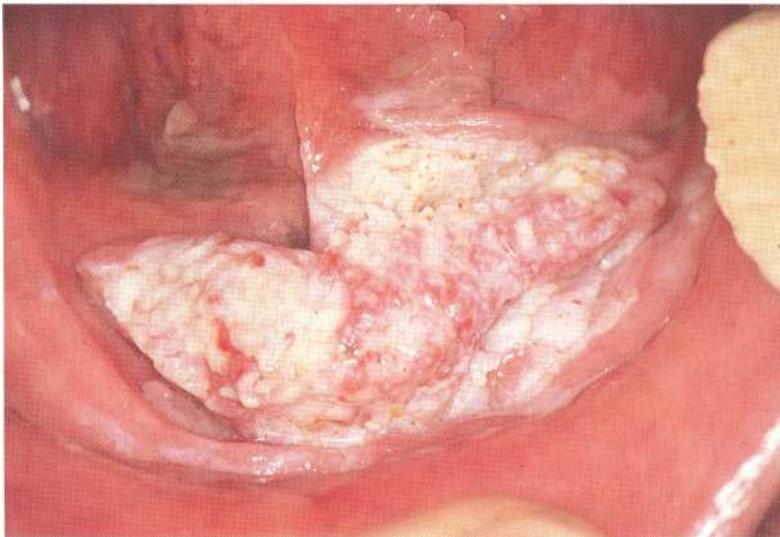


Fig. 440. Late squamous cell carcinoma of the floor of the mouth.

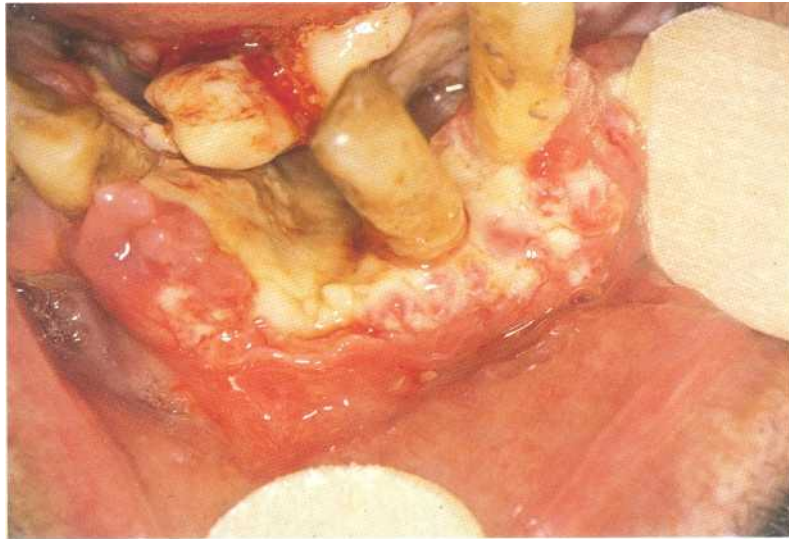


Fig. 441. Late squamous cell carcinoma of the gingiva.

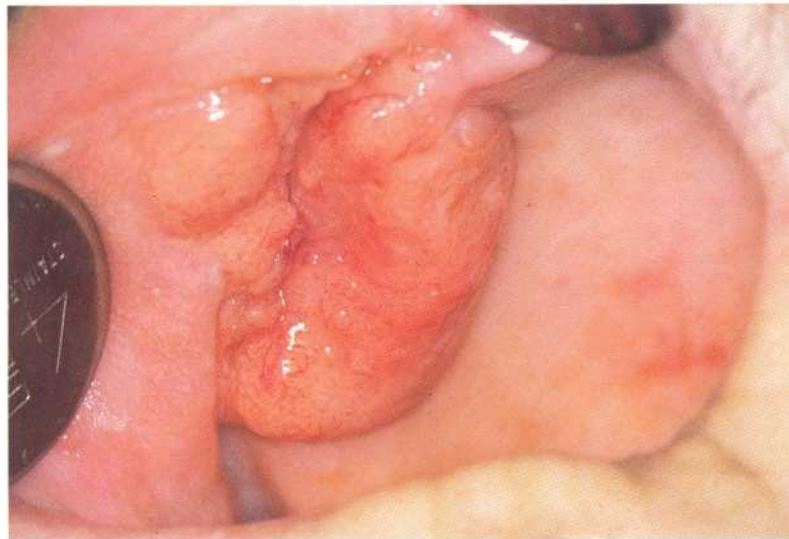


Fig. 442. Squamous cell carcinoma of the alveolar mucosa.

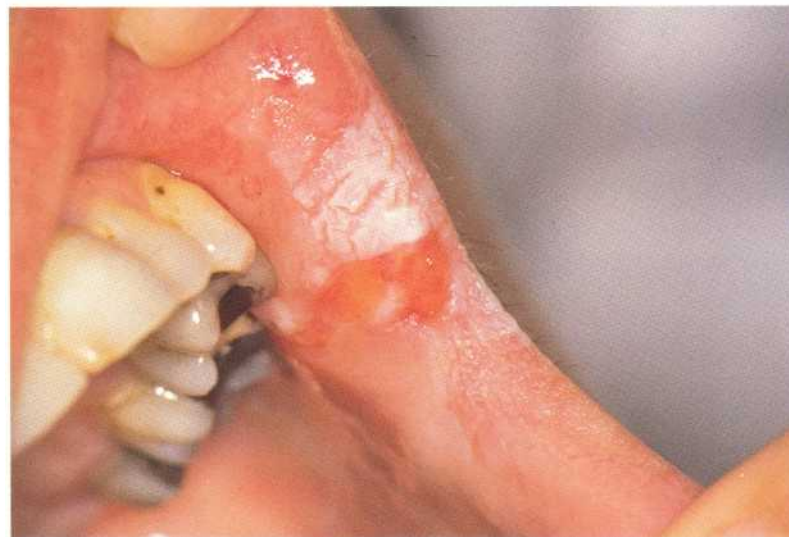
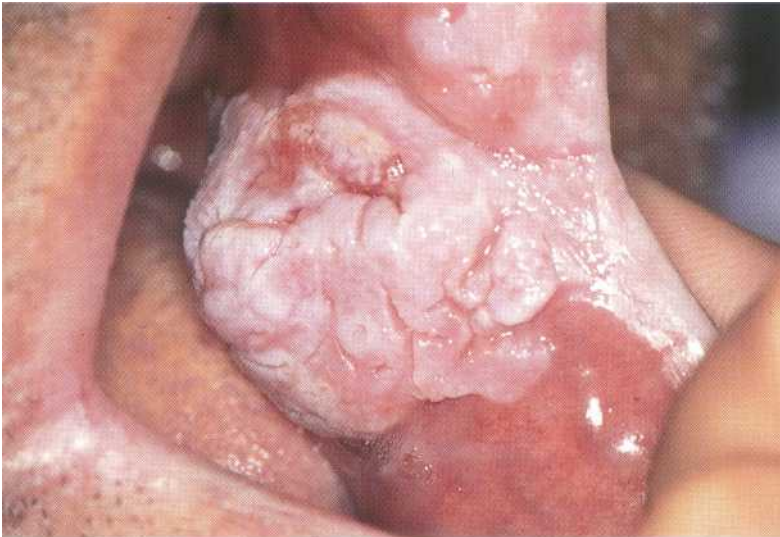
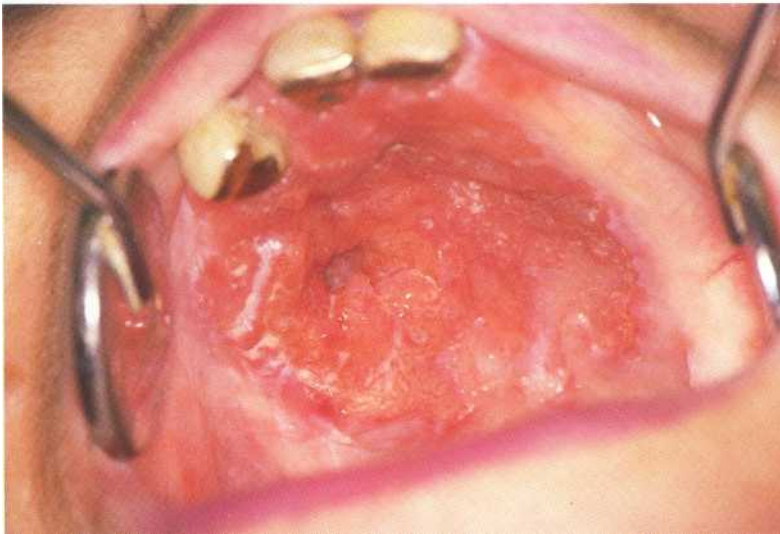Fig. 443. Early squamous cell carcinoma of the buccal mucosa.



**Fig. 444.** Late squamous cell carcinoma of the buccal mucosa.



**Fig. 445.** Late squamous cell carcinoma of the hard palate.

### **Verrucous Carcinoma**

Verrucous carcinoma is a variant of squamous cell carcinoma. It occurs most frequently in the oral cavity, although it can also appear in other mucous membranes and on the skin. Oral verrucous carcinoma differs from oral squamous cell carcinoma in that it is an exophytic superficially spreading and slow-growing mass, has a good biologic behavior, and seldom metastasizes. The neoplasm more frequently affects males more than 60 years of age. The buccal mucosa, gingiva, and alveolar mucosa are involved in 80 to 90% of the cases. The floor of the mouth, palate, tongue,

and lip may also be affected. Clinically, it presents chiefly as an exophytic white mass with a verrucous or pebbly surface (Fig. 448). The size ranges from 1 cm in early stages to quite extensive if it is left untreated (Fig. 449).

The differential diagnosis should include squamous cell carcinoma, proliferating verrucous leukoplakia, verrucous hyperplasia, papilloma, verruciform xanthoma, and white sponge nevus.

Laboratory test helpful for diagnosis is histopathologic examination.

Treatment is surgical excision.

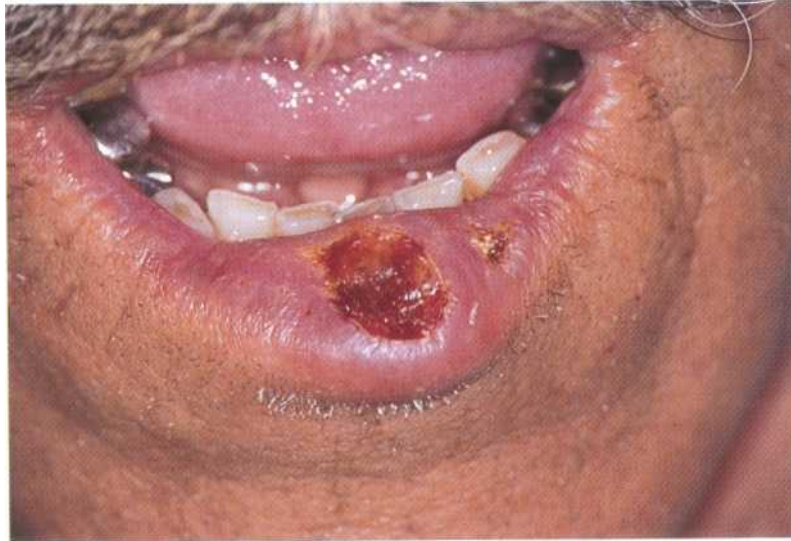

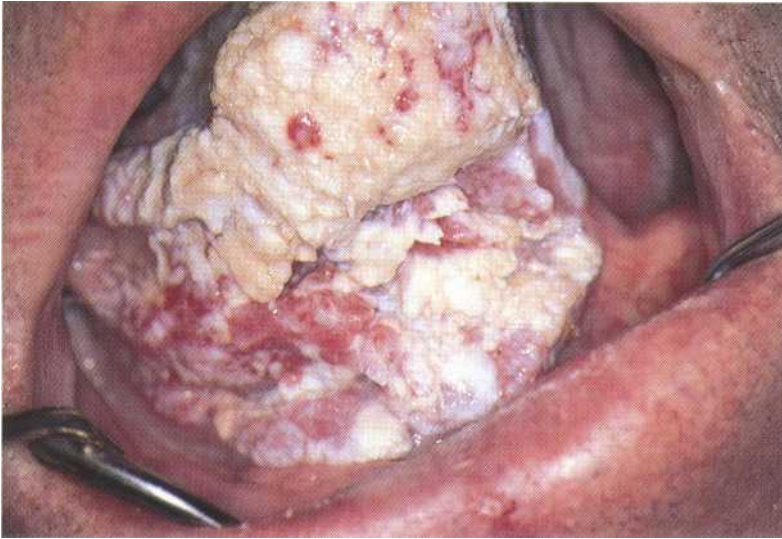
Fig. 446. Early squamous cell carcinoma of the lower lip.

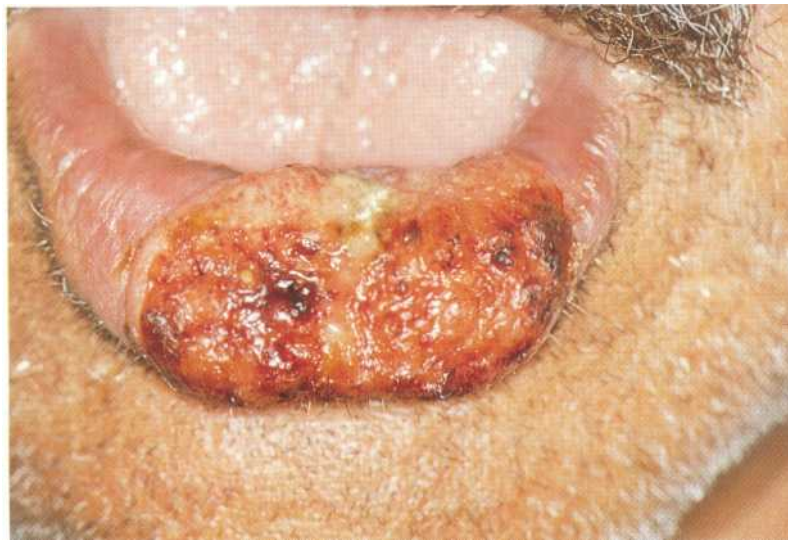

Fig. 447. Late squamous cell carcinoma of the lower lip.

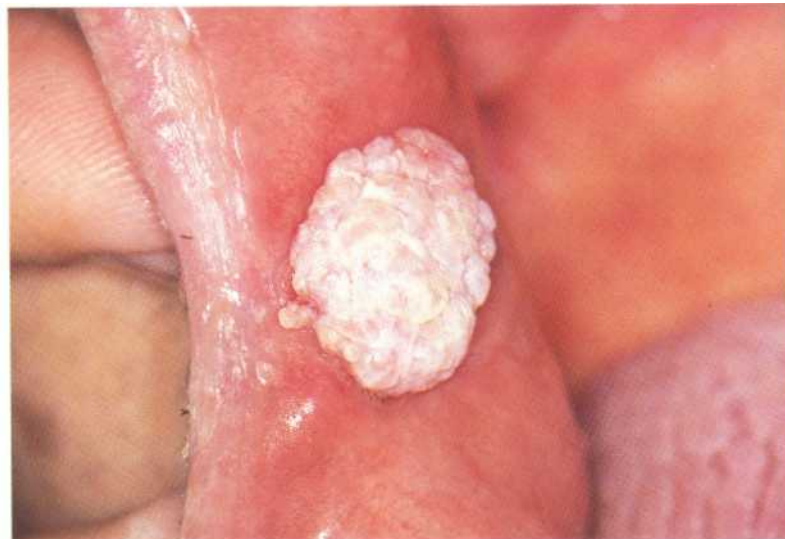

Fig. 448. Early verrucous carcinoma of the buccal mucosa.



**Fig. 449. Extensive verrucous carcinoma of the tongue.**

### Adenoid Squamous Cell Carcinoma

Adenoid squamous cell carcinoma is a rare neoplasm with characteristic histopathologic features. It is mainly seen in men more than 50 years of age, usually on the skin of the head and neck. In the oral cavity it is rare and is usually located on the lower lip. A few cases have been described intra-orally. Clinically, it appears as an ulcerated or exophytic lesion with slightly verrucous surface (Fig. 450).

The differential diagnosis includes all the lesions that should be differentiated from squamous cell carcinoma.

**Laboratory test.** Histopathologic examination establishes the diagnosis.

Treatment is surgical excision.

### Spindle Cell Carcinoma

Spindle cell carcinoma is a rare variety of squamous cell carcinoma with characteristic histopathologic features, involving mainly the upper respiratory and alimentary tracts. It affects males, usually more than 50 years of age, more frequently than females. The lower lip is the most frequent site of involvement, followed by the tongue, gingiva, alveolar mucosa, floor of the mouth, buccal mucosa, etc. Clinically, spindle cell carcinoma appears as an exophytic lesion or ulcer with a size ranging from 0.5 to 5 cm (Fig. 451).

The most common symptoms are swelling, pain, hemorrhage, and loosening of the teeth.

The differential diagnosis should consider other malignant lesions of the oral cavity.

Laboratory test to establish the diagnosis is histopathologic examination.

Treatment is surgical excision or radiation.

### Lymphoepithelial Carcinoma

Lymphoepithelial carcinoma, or lymphoepithelioma, is an extremely rare variety of squamous cell carcinoma. It presents in young persons with a mean age of 26 years, in areas of the mouth rich in lymphatic tissue, such as the posterior lateral margin of the tongue and nasopharynx. Clinically, it appears as a small ulcer or an exophytic lesion with a granular surface (Fig. 452). It metastasizes quickly and has a poor prognosis.

The differential diagnosis includes the lesions that should be differentiated from oral carcinoma.

**Laboratory test.** The diagnosis is based exclusively on histopathologic examination.

Treatment is radiotherapy or surgical excision.

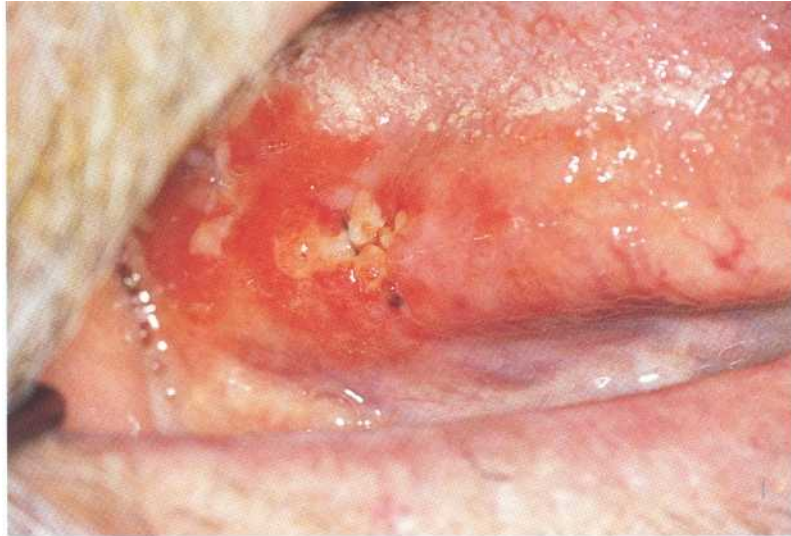

Fig. 450. Adenoid squamous cell carcinoma on lateral border of the tongue.

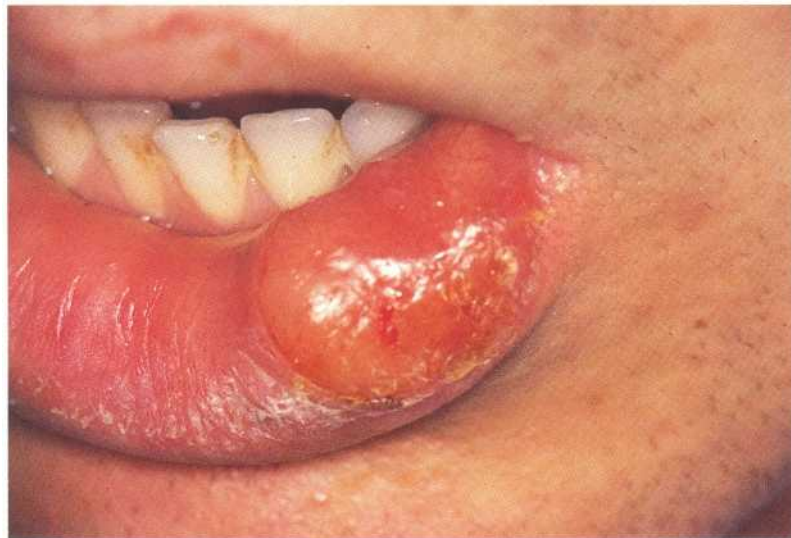

Fig. 451. Spindle cell carcinoma of the lower lip.

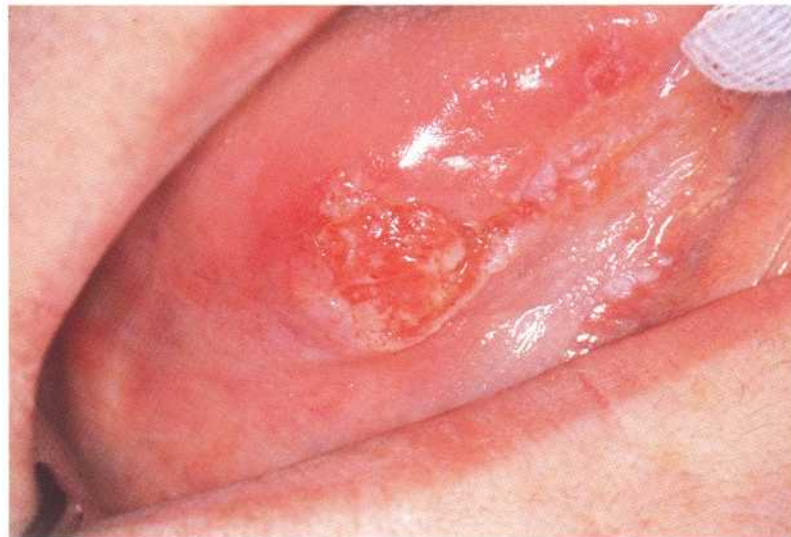

Fig. 452. Lymphoepithelial carcinoma on lateral border of the tongue.



## Basal Cell Carcinoma

Basal cell carcinoma is the most common malignant neoplasm of the skin, arising from the basal cell layer of the epidermis and its appendages. It is usually found in areas exposed to the sun, with a particular predilection for the upper central part of the face. The tumor is more frequent in men than women and usually occurs in patients more than 50 years of age. It is locally invasive, slowly spreading, and rarely metastasizes. Clinically, basal cell carcinoma has a wide variety of forms. The early typical tumor is a slightly elevated papule or nodule with a translucent border and smooth, hyperkeratotic, or crusted surface. It may also present as a plaque or small ulcer. At a later stage, tumors may appear as a large nodule with or without ulceration, an ulcer that does not heal, an atrophic plaque, a pigmented tumor, a morphea-like lesion, etc. Primary basal cell carcinoma does not appear in the oral cavity unless it represents an extension from a lesion of the skin of the face (Figs. 453, 454). However, tumors may be seen on the lips.

The differential diagnosis includes squamous cell carcinoma and keratoacanthoma.

Laboratory test that establishes diagnosis is histopathologic examination.

Treatment consists of radiotherapy or surgical excision.

## Acinic Cell Carcinoma

Acinic cell carcinoma or tumor is a rare malignant neoplasm of the salivary glands, which has a wide spectrum of histopathologic and cellular features. The tumor usually occurs in the parotid, although cases have been described in the sublingual, submandibular, and minor salivary glands. It represents about 2% of all tumors of the salivary glands. The minor salivary gland tumor is slightly more frequent in women than men. The great majority of patients are more than 40 years old.

The most common intraoral locations are the palate and upper lip, and less commonly the buccal mucosa and lower lip. Clinically, it appears as a painless rubbery mass that grows slowly, is slightly mobile, and seldom may be ulcerated (Fig. 455).

The differential diagnosis includes salivary gland tumors and other malignant tumors.

Laboratory test to establish the diagnosis is histopathologic examination.

Treatment is surgical excision.

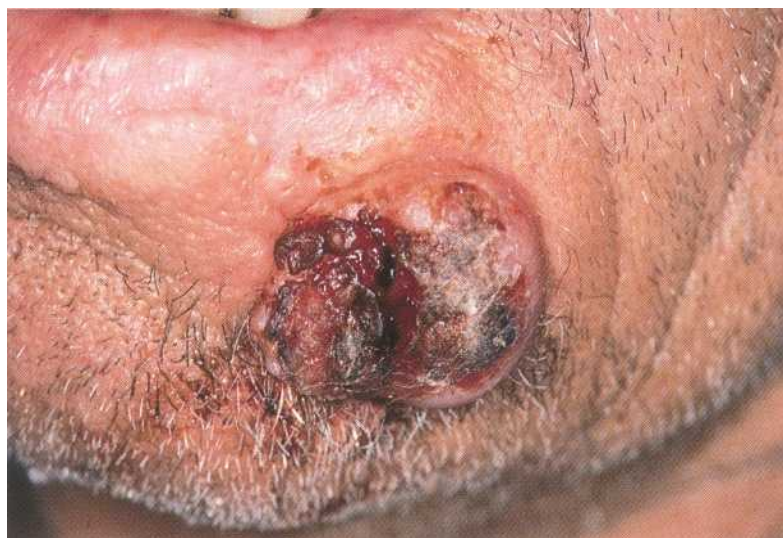

Fig. 453. Basal cell carcinoma of the skin.

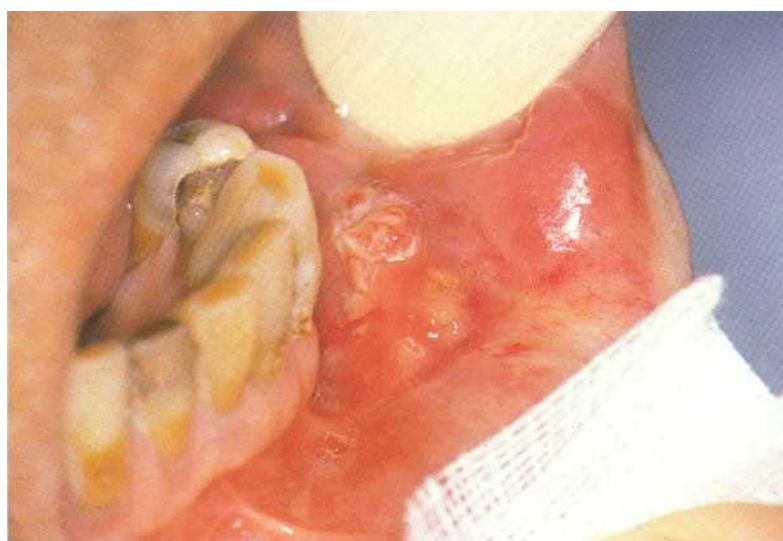

Fig. 454. Basal cell carcinoma on the buccal mucosa originating from the skin of the face.

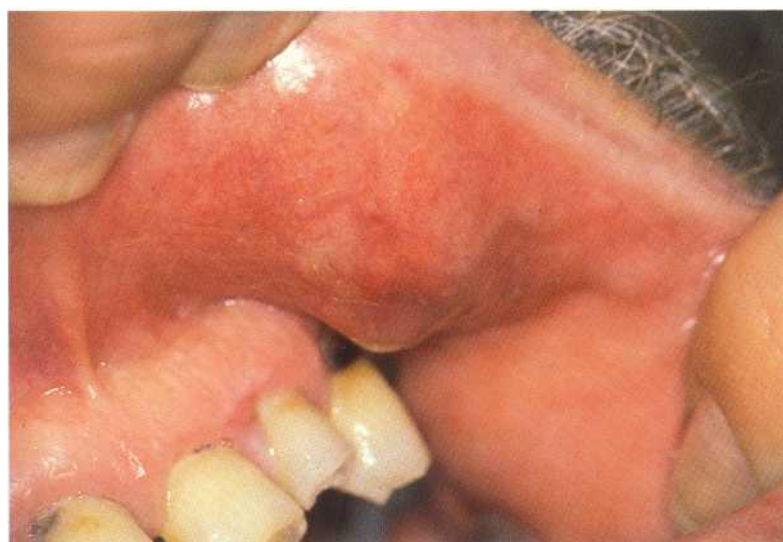

Fig. 455. Acinic cell carcinoma of the upper lip mucosa.

### **Mucoepidermoid Carcinoma**

Mucoepidermoid carcinoma or tumor is a malignant tumor of the salivary glands. It represents about 2 to 3% of the tumors of major salivary glands and 6 to 9% of the minor salivary gland tumors. The biologic behavior of the neoplasm varies from moderate to high-grade malignancy. The tumor affects almost equally men and women, most often between 30 and 50 years of age. Clinically, an intraoral tumor appears as a painless proliferating rubbery swelling that often ulcerates (Fig. 456). A common clinical finding is the development of cysts within the tumor with exudation of mucous material. About 60% of all intraoral tumors are found in the palate, tongue, lips, and retromolar area (Fig. 457).

The differential diagnosis includes pleomorphic adenoma, mucocele, necrotizing sialometaplasia, and other malignant tumors.

Laboratory test. Histopathologic examination is essential for diagnosis.

Treatment is surgical excision or radiotherapy.

### **Adenoid Cystic Carcinoma**

Adenoid cystic carcinoma, or cylindroma, is a malignant neoplasm of the salivary glands with a characteristic histopathologic pattern. It represents about 2 to 6% of all parotid gland tumors, but 15% of all submandibular gland tumors, and 30% of all minor salivary gland tumors. It equally affects men and women and is usually seen in patients more than 50 years of age.

Adenoid cystic carcinoma is the most common malignant tumor of minor salivary glands. It is most frequently located on the palate, followed by the buccal mucosa, lips, and tongue. Clinically, it appears as a slightly painful, enlarging mass that may later ulcerate (Fig. 458). The progression of the tumor is usually slow, and pain is frequent during the late stages. The tumor is prone to infiltrate the perineural spaces and usually has a poor prognosis.

The differential diagnosis includes pleomorphic adenoma and other malignant tumors.

Laboratory test. Histopathologic examination establishes the diagnosis.

Treatment consists of surgical excision and radiation.

Fig. 456. Mucoepidermoid carcinoma of the palate and alveolar mucosa.

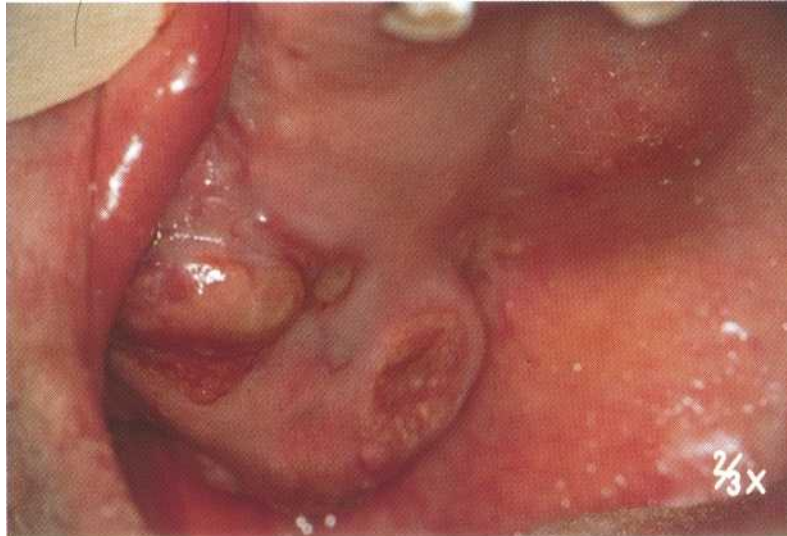


Fig. 457. Mucoepidermoid carcinoma of the retromolar area.

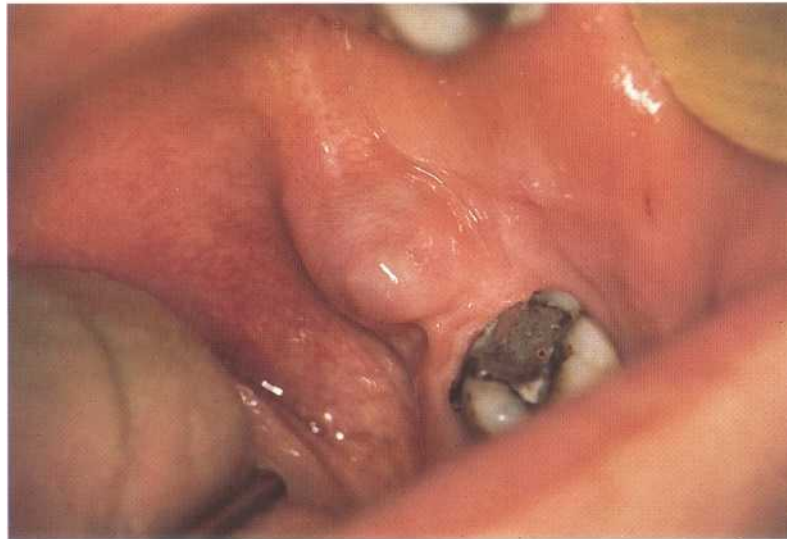
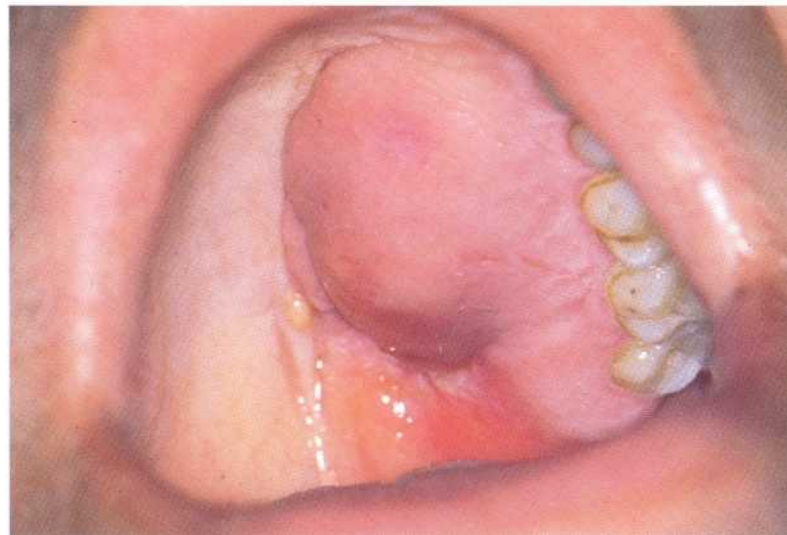
Fig. 458. Adenoid cystic carcinoma of the palate.



### **Malignant Pleomorphic Adenoma**

Malignant pleomorphic adenoma or carcinoma in pleomorphic adenoma is a rare tumor of the salivary glands with a histologic pattern showing areas characteristic of pleomorphic adenoma mixed with areas showing evidence of malignancy. It represents about 2 to 4% of all tumors of the major salivary glands and 3 to 7% of minor salivary glands. Intraoral malignant pleomorphic adenoma is more common in women and has a peak age of onset after 50 years. The palate is the most commonly affected site, followed by the buccal mucosa, lips, and tongue. Clinically, it appears as a painless swelling that slowly increases in size and may later become painful and ulcerated (Fig. 459).

The differential diagnosis includes pleomorphic adenoma and other malignant tumors.

Laboratory test that establishes the diagnosis is histopathologic examination.

Treatment is surgical excision and radiation.

### **Adenocarcinoma**

Adenocarcinoma is a malignant salivary gland tumor with a potential for high-grade malignant behavior, which cannot be placed in any other group of carcinomas. It represents 1 to 3% of all major and 7 to 12% of minor salivary gland tumors. Intraoral tumors are most common in men more than 40 years of age. The palate is the site usually involved, followed by the buccal mucosa, lips, tongue, and other areas. Clinically, it appears as a firm swelling that enlarges and is usually associated with ulceration and pain (Fig. 460).

The differential diagnosis includes other malignant salivary gland tumors and squamous cell carcinoma.

Laboratory test establishing the diagnosis is histopathologic examination.

Treatment is surgical excision.

### **Clear Cell Adenocarcinoma**

Clear cell adenocarcinoma is a very rare variant of adenocarcinoma. It is slightly more frequent in women than men, particularly after 50 years of age. The tumor is usually located in the parotid and is extremely rare in other salivary glands. Clinically, it appears as a painless, firm swelling that increases rapidly in size and soon ulcerates (Fig. 461).

The differential diagnosis of an intraoral lesion should include other malignant neoplasms of minor salivary glands, squamous cell carcinoma, lymphoma, Wegener's granulomatosis, and lethal midline granuloma.

Laboratory test. Histopathologic examination is essential for diagnosis.

Treatment is surgical excision.

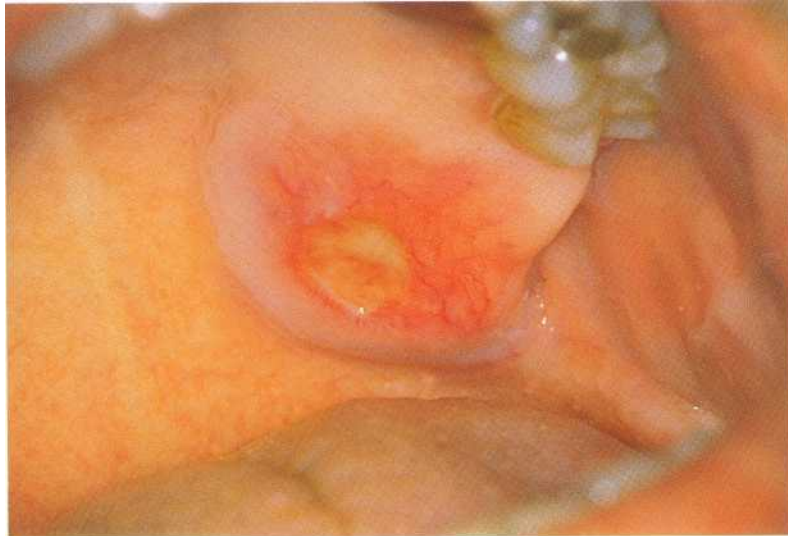


Fig. 459. Malignant pleomorphic adenoma of the palate.

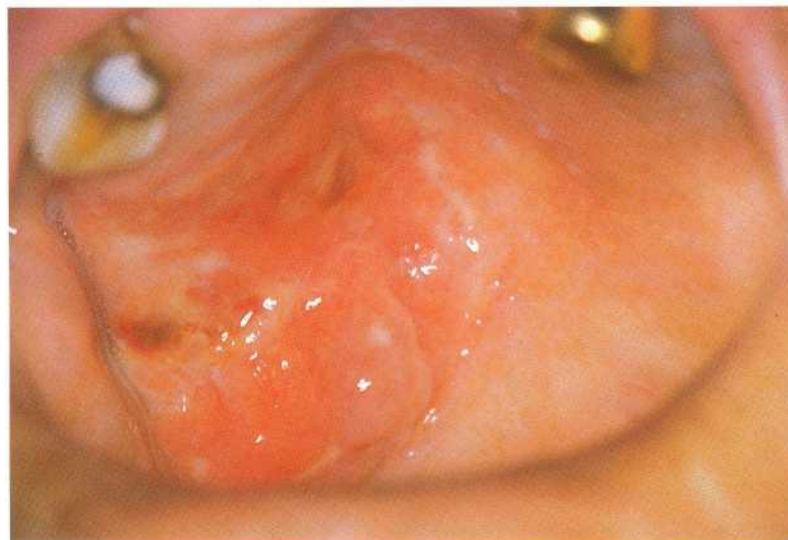

Fig. 460. Adenocarcinoma of the palate.

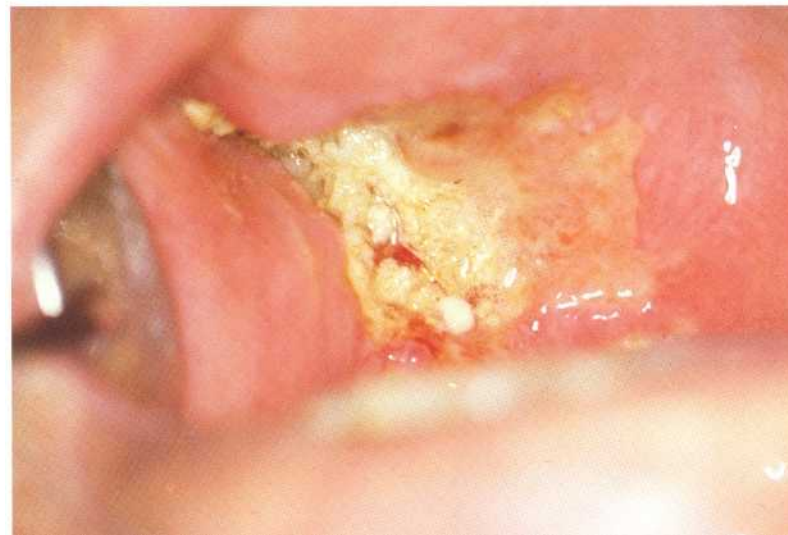

Fig. 461. Clear cell adenocarcinoma of the palate.

### Polymorphous Low-Grade Adenocarcinoma

Polymorphous low-grade adenocarcinoma of minor salivary glands, or terminal duct carcinoma, is a form of adenocarcinoma, locally persistent, with a relatively indolent course. The tumor affects almost exclusively the minor salivary glands. The mean age at onset is 50 years and women are affected more frequently than men. In the great majority of cases the lesion occurs on the palate (frequently at the junction of soft and hard palates), followed by the buccal mucosa, lips, retromolar region, and other areas. Clinically, it appears as a painless, firm swelling or an elevated nodule that is rarely ulcerated (Fig. 462). The size varies from 1 to several centimeters in diameter and the prognosis is favorable.

The differential diagnosis should include pleomorphic adenoma, other malignant minor salivary gland tumors, and lymphomas.

Laboratory test to establish the diagnosis is histopathologic examination.

Treatment is surgical excision.

### Fibrosarcoma

Fibrosarcoma of oral soft tissues is an extremely rare malignant tumor of mesenchymal origin. It usually affects persons before 50 years of age. It has also been described in neonates and older children. It is usually located on the gingiva, buccal mucosa, palate, tongue, and lips. Clinically, the tumor appears as an exophytic mass, soft or semihard on palpation, with or without ulceration (Fig. 463). It grows at a variable rate.

The differential diagnosis should include peripheral ossifying fibroma, fibroma, malignant fibrous histiocytoma, and other malignant connective tissue tumors.

Laboratory test to establish the diagnosis is histopathologic examination.

Treatment is surgical excision.

### Kaposi's Sarcoma

Kaposi's sarcoma, or multiple idiopathic hemorrhagic sarcoma, is a malignant neoplasm of multifocal origin. It probably originates from primitive mesenchymal cells, such as endothelial cells.

Four forms of the neoplasm are recognized.

1) Classic Kaposi's sarcoma is most common in Jewish patients and those of Mediterranean descent, and it involves primarily the skin and occasionally the oral mucosa and has an indolent course. 2) African (endemic) Kaposi's sarcoma is common in Uganda and other African countries, and it involves primarily the skin and lymph nodes, but rarely the oral mucosa and usually has an indolent course. 3) Kaposi's sarcoma is observed in patients with kidney transplantation as well as those having received immunosuppressive drugs for a variety of diseases. The clinical course of this form is indolent, but sometimes can be very aggressive, involving the viscera, but rarely the oral mucosa. 4) Acquired immune deficiency syndrome (AIDS)-related (epidemic) Kaposi's sarcoma, without race predilection and of high incidence among AIDS patients, involves primarily the skin, lymph nodes, viscera, and frequently the oral mucosa. It has a rapid, fatal course. The classic form is frequently located on the skin and seldom in other mucosae and internal organs. It affects men more often than women (ratio about 8: 1) 50 to 70 years of age and progresses slowly. Clinically, the skin lesions are characterized by multiple macules, plaques, nodules, and tumor lesions of purplish or dark blue color (Fig. 464). The feet, hands, nose, and ears are the most common sites of involvement. The oral mucosa is occasionally affected, usually after the skin, but, although rarely, the disease can start from the mouth. Clinically, the oral lesions present as multiple or solitary red, brown-reddish, soft, or ulcerated elevated plaques or tumors (Fig. 465). They most frequently develop on the palate and gingiva, followed by the tongue, lips, and buccal mucosa.

The differential diagnosis includes pyogenic granuloma, peripheral giant cell granuloma, hemangioma, hemangiopericytoma, hemangioendothelioma, pigmented nevi, and malignant melanoma.

Laboratory test. Histopathologic examination confirms the diagnosis.

Treatment. Radiotherapy, interferon-A, and chemotherapy or surgical excision in small localized lesions.

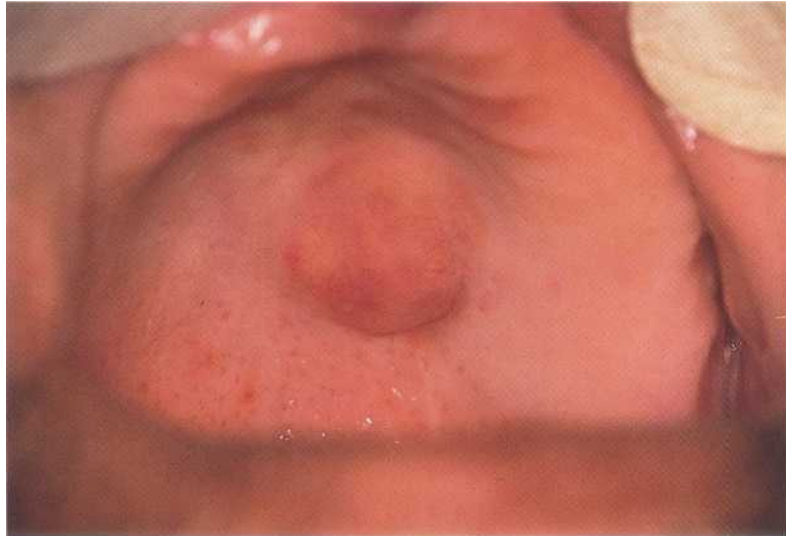

Fig. 462. Polymorphous low-grade adenocarcinoma of minor salivary glands of the palate.

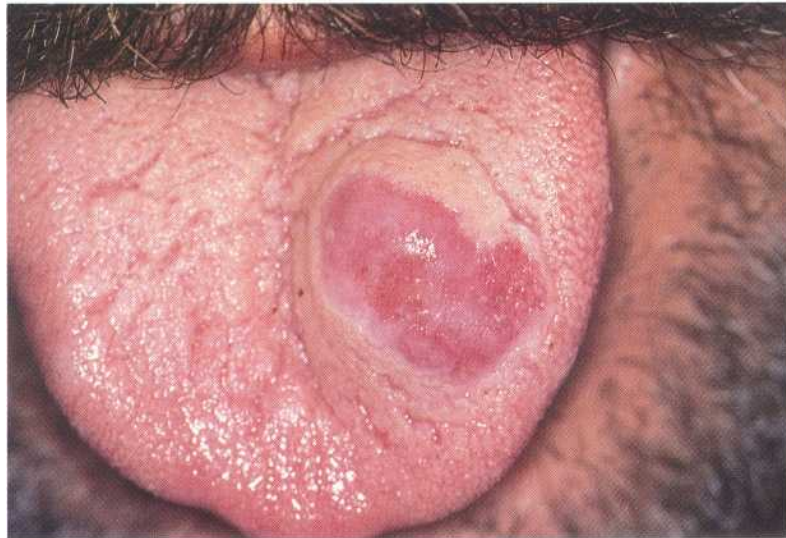

Fig. 463. Fibrosarcoma of the dorsum of the tongue.

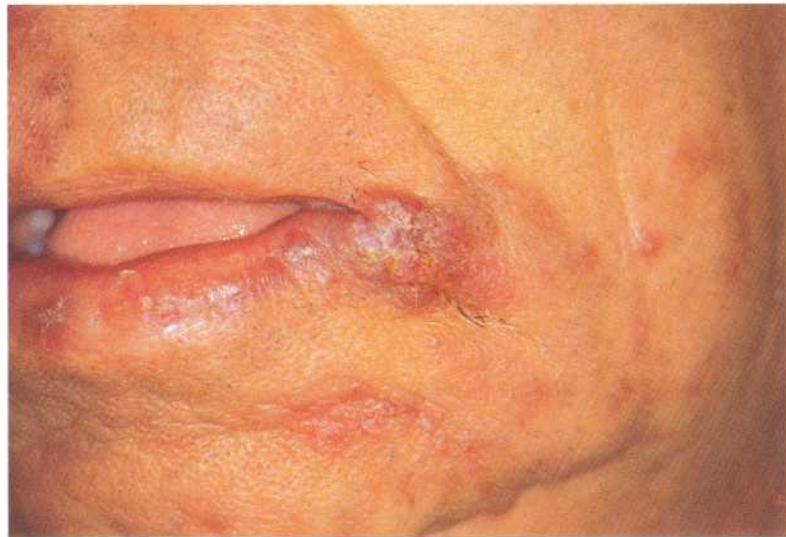
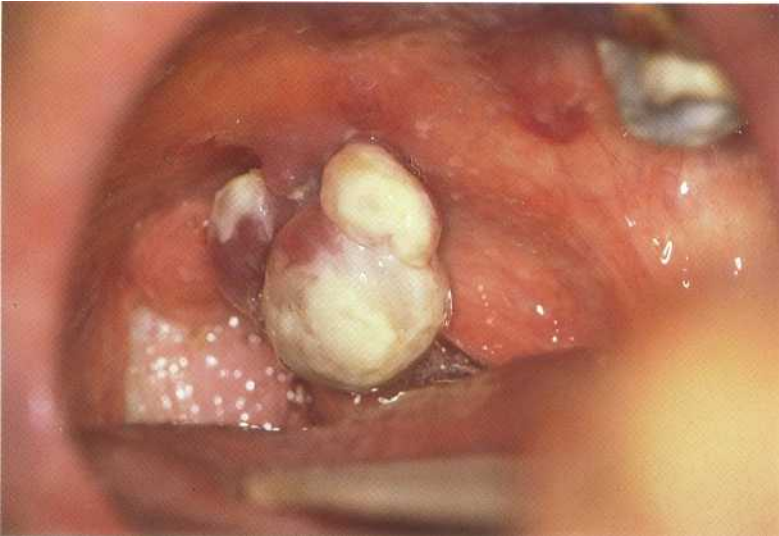
Fig. 464. Kaposi's sarcoma of the perioral skin and lower lip.





**Fig. 465.** Multiple lesions of Kaposi's sarcoma of the soft palate.

### **Malignant Fibrous Histiocytoma**

Malignant fibrous histiocytoma is one of the most common soft tissue sarcomas of late adult life. The tumor rarely involves the oral and maxillofacial region. Approximately 60 cases have been described so far, and the majority appear in the jaw bones. Clinically, the tumor presents as a quickly developing exophytic painless mass, of reddish-brown color, with or without ulceration (Fig. 466).

The differential diagnosis includes postextraction granuloma, peripheral giant cell granuloma, and other malignant tumors of mesenchymal origin.

Laboratory test to establish the diagnosis is histopathologic examination.

Treatment is surgical removal, radiotherapy, and chemotherapy.

### **Hemangioendothelioma**

Hemangioendothelioma is a rare malignant neoplasm that originates from blood vessel endothelial cells. It is more common in females than males and is usually found on the skin. It is rare in the oral cavity, where the tongue, palate, gingiva, and lips may be involved. Clinically, it presents as an elevated firm tumor with characteristic deep red color (Fig. 467). It is usually ulcerated and may bleed.

The differential diagnosis includes hemangioma, pyogenic granuloma, peripheral giant cell

granuloma, leiomyoma, Kaposi's sarcoma, and hemangiopericytoma.

Laboratory test. Histopathologic examination establishes the diagnosis.

Treatment consists of surgical removal and radiotherapy.

### **Hemangiopericytoma**

Hemangiopericytoma is a rare neoplasm originating from blood vessel wall pericytes. Benign and malignant forms exist and are difficult to distinguish. It affects equally both sexes, usually before the age of 50 years, and is extremely rare in the oral mucosa. Clinically, it presents as a well-circumscribed, firm, painless tumor of red or normal color (Fig. 468). It progresses quickly, has a semi-hard consistency, and may become ulcerated.

The differential diagnosis includes hemangioendothelioma, Kaposi's sarcoma, and benign tumors of blood vessel origin.

Laboratory test. Histopathologic examination is helpful in establishing the diagnosis.

Treatment. Surgical removal is the treatment of choice.

Fig. 466. Malignant fibrous histiocytoma of the alveolar mucosa of the mandible.

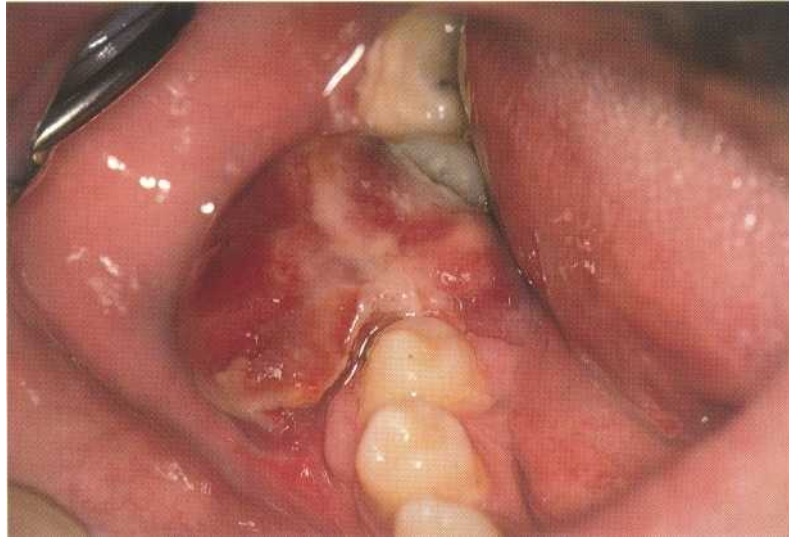


Fig. 467. Hemangioendothelioma of the palate.

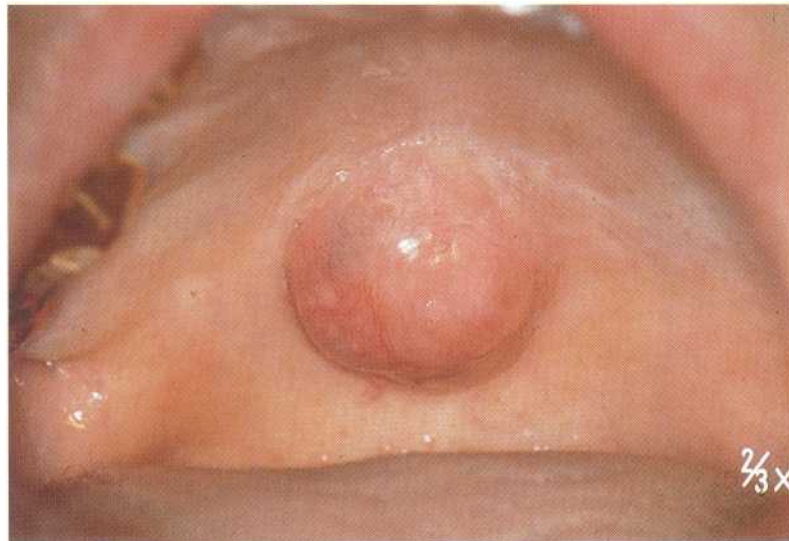
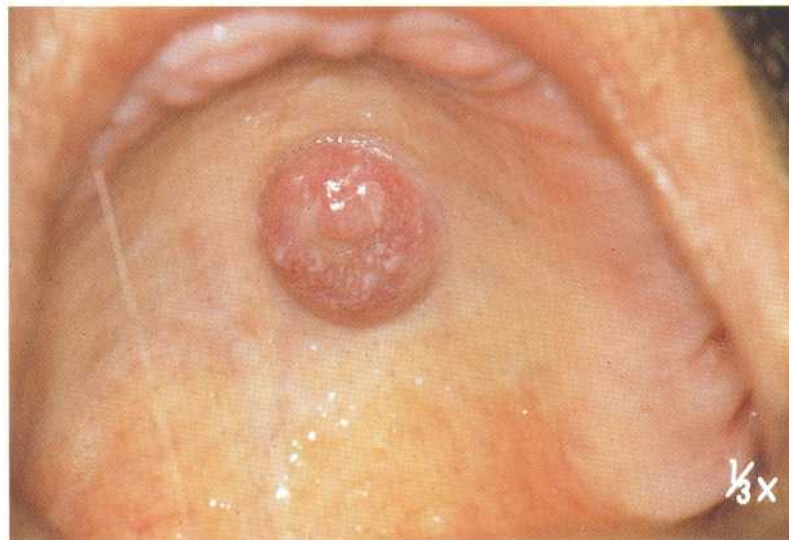
Fig. 468. Hemangiopericytoma of the palate.



### Malignant Melanoma

Malignant melanoma occurs primarily in the skin and originates from melanocytes. It has a very poor prognosis. Cutaneous melanoma represents about 2% of all malignant neoplasms. Primary oral melanoma is uncommon and represents 0.5 to 1.5% of all malignant melanomas in most countries. However, in Japan, oral melanoma makes up 7.5% of all malignant melanomas. The tumor may develop *de novo* or in association with a preexisting melanocytic lesion. Malignant melanoma of the oral mucosa affects equally both sexes, usually after 40 years of age. The great majority of the lesions (about 70 to 80%) occur on the palate, upper gingiva, and alveolar mucosa. The rest appear on the lower gingiva, buccal mucosa, tongue, floor of the mouth, and lips. According to clinical and histopathologic criteria, malignant melanoma is classified in 3 forms: nodular melanoma, which clinically presents as an elevated black or reddish-brown nodule that frequently grows quickly, hemorrhages easily, may become ulcerated, and has a poor prognosis (Fig. 469); superficial spreading melanoma, which clinically presents as a circumscribed flat or slightly elevated brown or black plaque with irregular margins that spreads at the periphery, is relatively rare in the mouth, and has a better prognosis (Fig. 470); and lentigo maligna melanoma, which develops on a preexisting lentigo maligna lesion, is extremely rare in the mouth, but has the best prognosis.

The differential diagnosis of oral malignant melanoma includes amalgam tattoo, oral pigmented nevi, lentigo maligna, lentigo, freckles, normal pigmentation, pyogenic granuloma, and Kaposi's sarcoma.

Laboratory test to establish the diagnosis is histopathologic examination.

Treatment is surgical excision, radiotherapy, immunotherapy, and chemotherapy.

### Chondrosarcoma

Chondrosarcoma is a relatively common malignant neoplasm characterized by the formation of aberrant cartilage tissue. The neoplasm is more common in men than women between 30 and 60 years of age. It is mainly found in the ribs, pelvis, femur, shoulder girdle, and jaws. Chondrosarcoma is subclassified as primary when it arises *de novo* and secondary when it arises from a preexisting benign cartilage tumor. Chondrosarcoma of the jaws is rare and may involve either jaw. Clinically, the tumor presents as a painless, hard swelling that progressively enlarges, causing extensive bone destruction with pain and loosening of the teeth. Occasionally, a large, erythematous, lobulated, and ulcerated mass may present in the oral cavity (Fig. 471). Mesenchymal chondrosarcoma is a rare histologically distinct variant of chondrosarcoma that may also occur in the maxillofacial area.

The differential diagnosis includes osteosarcoma, fibrosarcoma, chondroma, central and peripheral giant cell granuloma.

Laboratory test to confirm the diagnosis is histopathologic examination.

Treatment is surgical removal and radiotherapy.

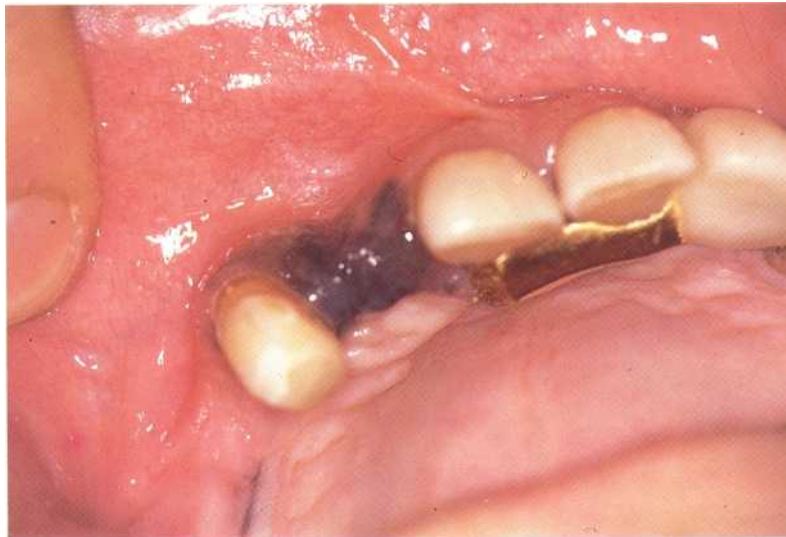

Fig. 469. Early nodular malignant melanoma of the alveolar mucosa.

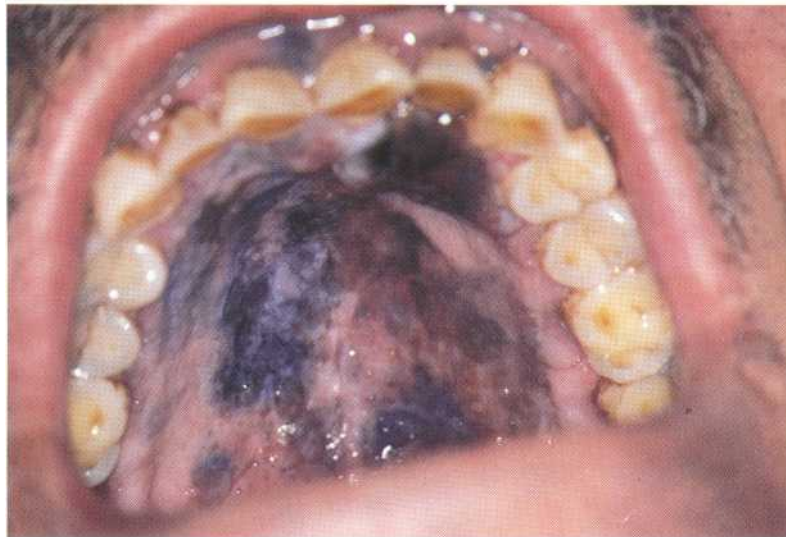


Fig. 470. Extensive superficial spreading melanoma of the palate.

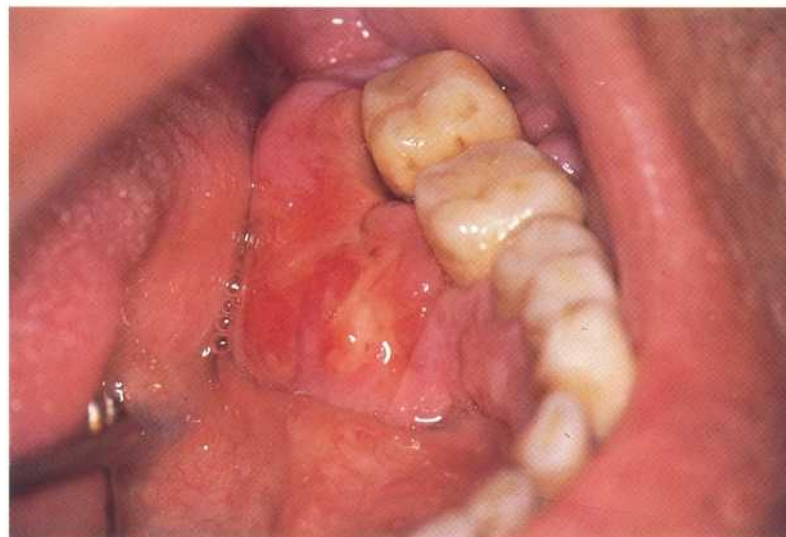
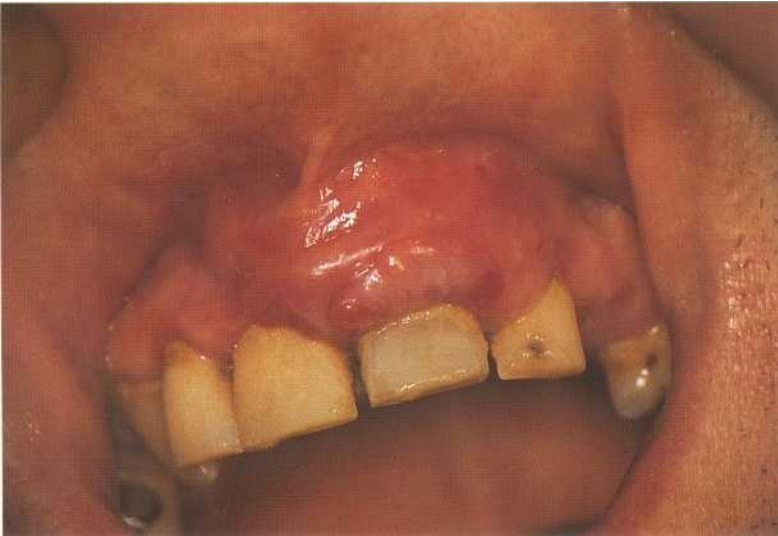
Fig. 471. Chondrosarcoma of the mandible presenting as a lobulated and ulcerated mass.



**Fig. 472.** Osteosarcoma of the upper jaw presenting as a hard swelling.

### Osteosarcoma

Osteosarcoma is the most common primary malignant neoplasm of bone. It affects males more than females and usually occurs between 10 and 20 years of age. The jaws are affected in 6 to 7% of the cases, the mandible and maxilla equally often. The tumor usually appears about 10 years later than a primary tumor elsewhere in the skeleton. Clinically, the lesion presents as a rapidly growing hard swelling of the jaw bone that progressively produces facial deformity (Figs. 472, 473). Pain, paresthesia, loose teeth, and bleeding may also occur.

The differential diagnosis includes mainly chondrosarcoma, fibrosarcoma and rarely odontogenic tumors.

Laboratory test to confirm the diagnosis is histopathologic and X-ray examination.

Treatment consists of surgical excision, radiotherapy, and chemotherapy.

### Metastatic Tumors

Metastases in the jaws or oral mucosa represent approximately 1 to 2% of all oral cancers. Most of them are found in the jaws. Metastases may arise from carcinomas of the gastrointestinal tract, lung, prostate, breast, kidney, etc.

Metastatic tumors of the oral mucosa are usually located on the tongue, gingiva, and palate, where they appear as asymptomatic nodules, frequently ulcerated, without specific clinical features (Figs. 474-477).

The differential diagnosis includes pyogenic granuloma, peripheral giant cell granuloma, fibroma, traumatic ulcer, squamous cell carcinoma, etc.

Laboratory test. The diagnosis is made after histopathologic examination. Investigation for the primary site of involvement may be necessary if not already apparent.

Treatment is related to the type of neoplasia and the therapy of the primary tumor. However, chemotherapy is the usual form of therapy.

Fig. 473. Osteosarcoma of the mandible presenting as a hard swelling at the angle of the mandible.

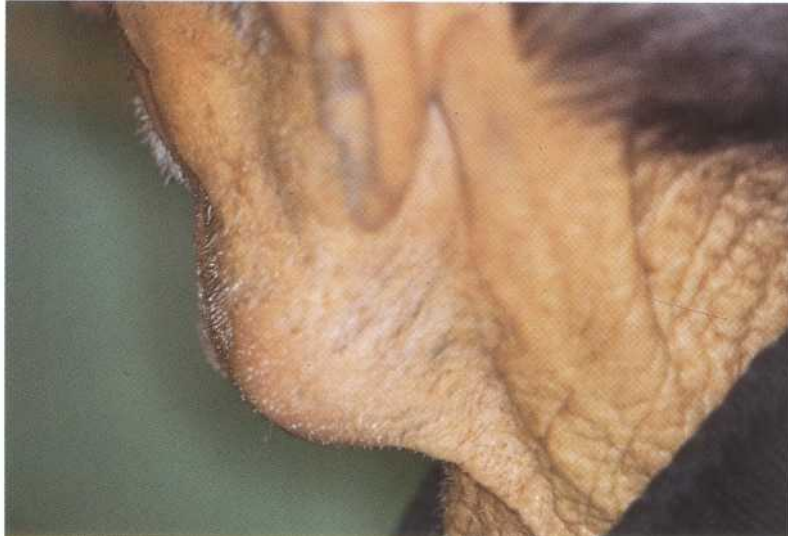

Fig. 474. Metastatic carcinoma of the palate originating from intestinal carcinoma.

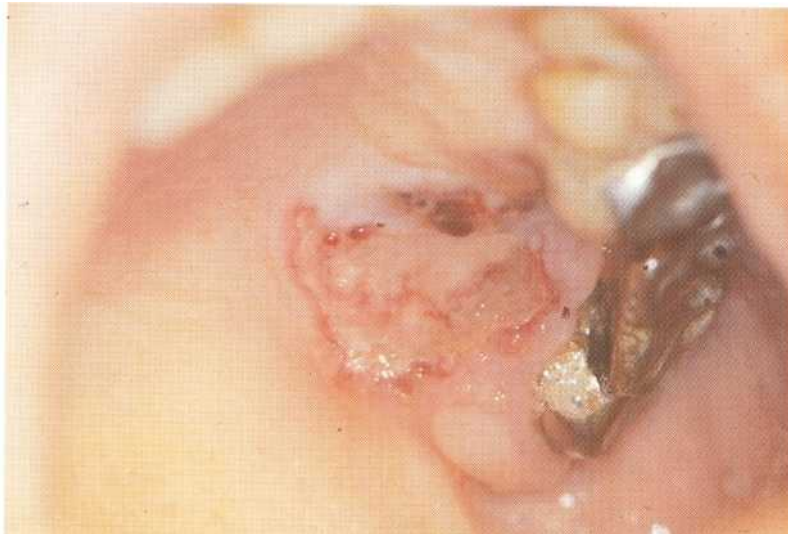
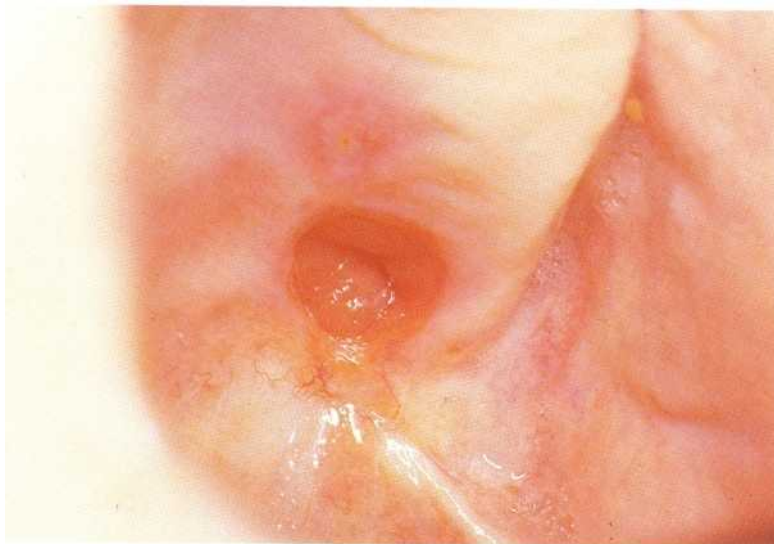

Fig. 475. Metastatic carcinoma of the palate originating from prostate carcinoma.



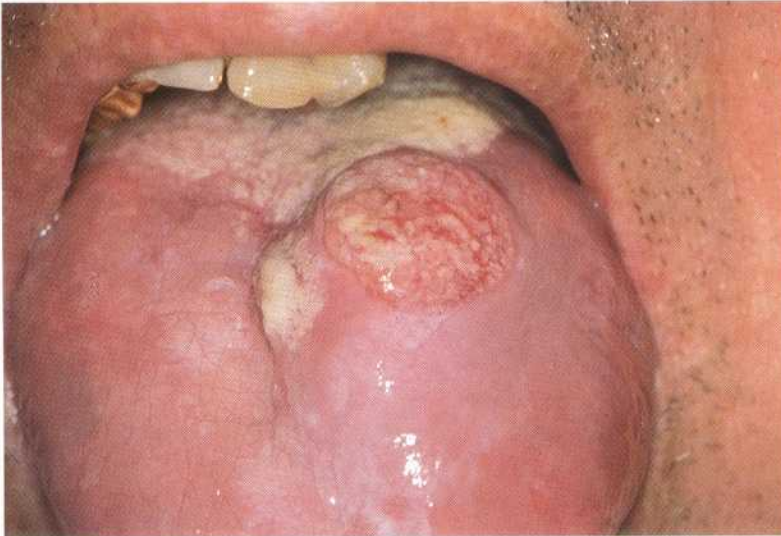

Fig. 476. Metastatic carcinoma of the tongue originating from lung carcinoma.

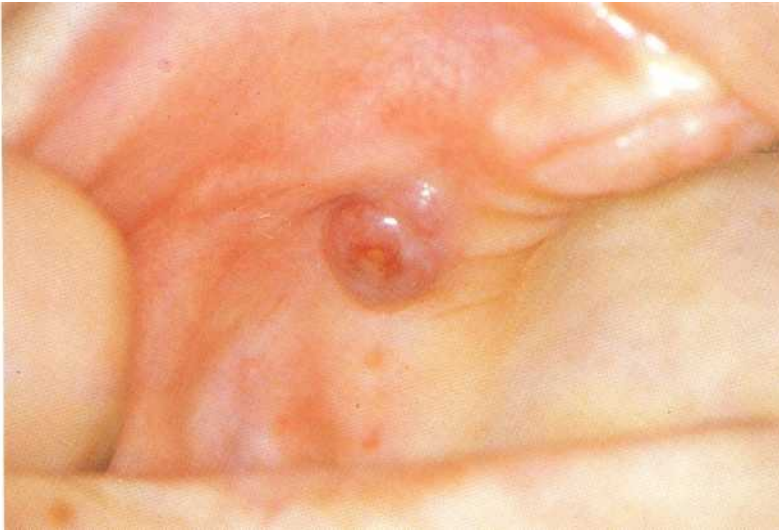

Fig. 477. Metastatic carcinoma of the alveolar mucosa originating from breast carcinoma.

## 32. Malignancies of the Hematopoietic and Lymphatic Tissues

### Leukemias

Leukemias are a heterogeneous group of malignant neoplastic disorder of the blood-forming tissues characterized by defects in the maturation and proliferation of leukocytes. The disorder leads to infiltration of the bone marrow by abnormal white cell clones, abnormalities in the white cell count in peripheral blood, systemic manifestations, infections, anemia, abnormalities in the immune responses, and bleeding disorders.

Depending on the clinical course and the degree of maturation of the cells, the leukemias are subdivided into acute and chronic forms.

Leukemias are also classified according to the abnormal cell clones that predominate and the cell type of origin of these clones, such as lymphocytic leukemia, myelocytic leukemia, myelomonocytic leukemia, eosinophilic leukemia, etc.

All types of leukemia may exhibit oral manifestations during their course, but characteristic alterations of the oral lesions occur more often in acute leukemias, irrespectively of the cell type.

### Acute Leukemias

Acute leukemias originate from the hematopoietic stem cell. On light and electron microscopy and cytochemical criteria, acute leukemias are classified into three major types: myelogenous, lymphocytic, and undifferentiated. The incidence of acute leukemias in Western Europe and the United States is about 3 to 4 cases per 100,000 persons yearly. The disease is slightly more common in males than females and affects children and young adults most frequently. Acute lymphocytic leukemia is the most common type in children, representing 80% of children patients. The main clinical features of the acute leukemias are weakness, fatigue, weight loss, fever, chills, headache, mucous membrane and skin pallor, bleeding, infections, bone tenderness and pain,

hepatosplenomegaly, generalized lymphadenopathy, etc.

The oral mucosa is affected more frequently in the acute leukemias, and up to 80% of patients present oral manifestations during the course of the disease. Oral lesions are more frequent in myelomonocytic leukemia, a variant of acute myelogenous leukemia, and may be an early component of the presenting symptom complex. Petechiae, ecchymoses, gingival hemorrhages, necrosis and ulceration of the oral mucosa, loosening of teeth, delayed wound healing, and submandibular and cervical lymph node enlargement are included in the spectrum of the clinical features of acute leukemia in the oral cavity (Figs. 478, 479).

Oral ulcers may be due to thrombosis of blood vessels by infiltrating leukemic cells or they may reflect a side effect of the treatment with chemotherapeutic agents or finally may be caused by minor trauma.

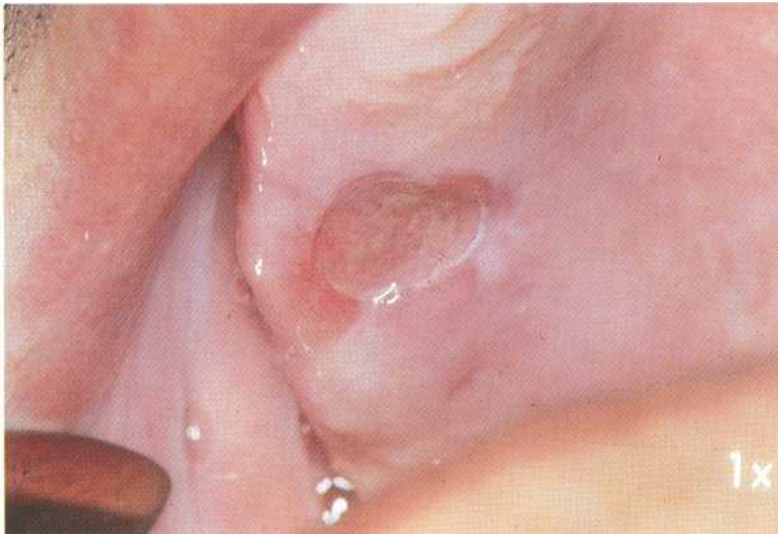Infiltration of the gingival tissues during the course of myelomonocytic or myelocytic leukemia may cause enlargement of the gingiva, which becomes edematous, red, inflamed, and bleeds spontaneously (Figs. 480, 481).

### Chronic Leukemias

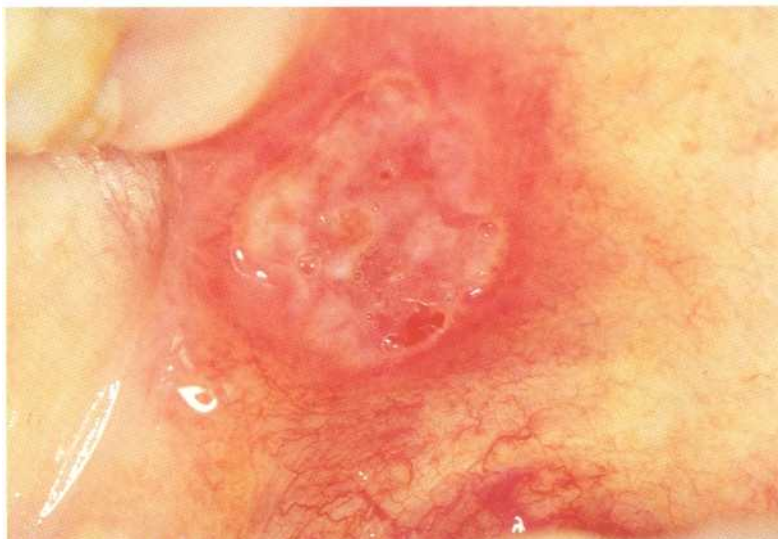Chronic leukemias are classified into myelogenous and lymphocytic forms. They affect most frequently middle-aged persons. Men are more frequently affected than women.

The onset and course are usually insidious and the disease may be discovered accidentally during a routine blood check. Chronic malaise, fatigue, weight loss, night sweats, lymphadenopathy, splenomegaly and hepatomegaly, low-grade fever, and enlargement of the parotid glands are common complaints. Skin manifestations include ecchymoses, petechiae, superficial ulcerations, papules, nodules, pruritus, and dark discoloration





**Fig. 478. Acute myelocytic leukemia, ulcer on the palate.**



**Fig. 479. Acute lymphocytic leukemia, ulcer on the palate.**

of the skin. Rarely, bullous pemphigoid or pemphigus may be associated with chronic leukemia.

The oral mucosa is less frequently affected than in acute leukemia. Clinically, there is pallor of the oral mucosa, petechiae, superficial ulceration, and bleeding episodes after routine oral surgery (Fig. 482). Enlargement of the gingiva may occur in lymphocytic leukemia and less frequently in myelogenous leukemia (Figs. 483, 484). Oral pemphigus and herpes zoster may also be associated with chronic leukemia.

The differential diagnosis includes trauma, agranulocytosis, thrombocytopenic purpura, aplastic anemia, cyclic neutropenia, gingivitis and periodontitis, idiopathic gingival fibromatosis,

and gingival hyperplasia caused by phenytoin, cyclosporine, and nifedipine.

Laboratory tests helpful in establishing the diagnosis in all types of leukemia include peripheral blood count, bone marrow examination, and determination of various markers of the leukemic cells (histochemical, immunologic, etc.).

**Treatment.** A specialized team approach is required in the treatment of these disorders.

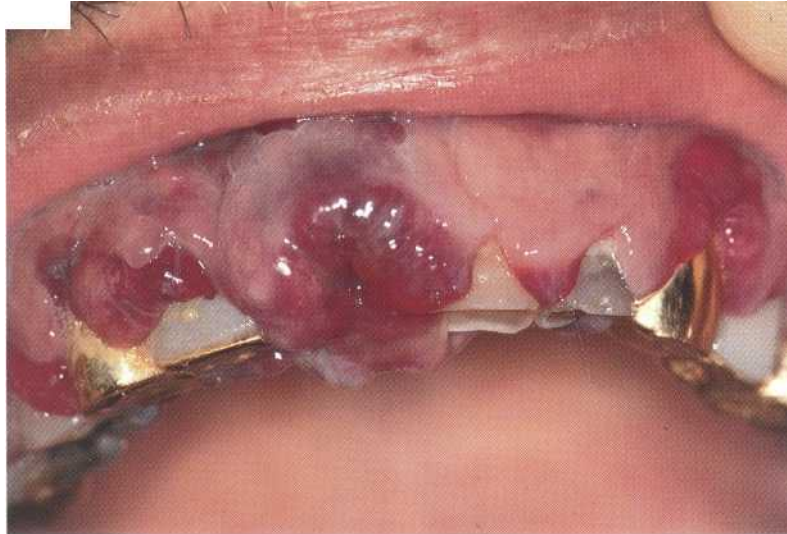

Fig. 480. Acute myelomonocytic leukemia, severe gingival enlargement.

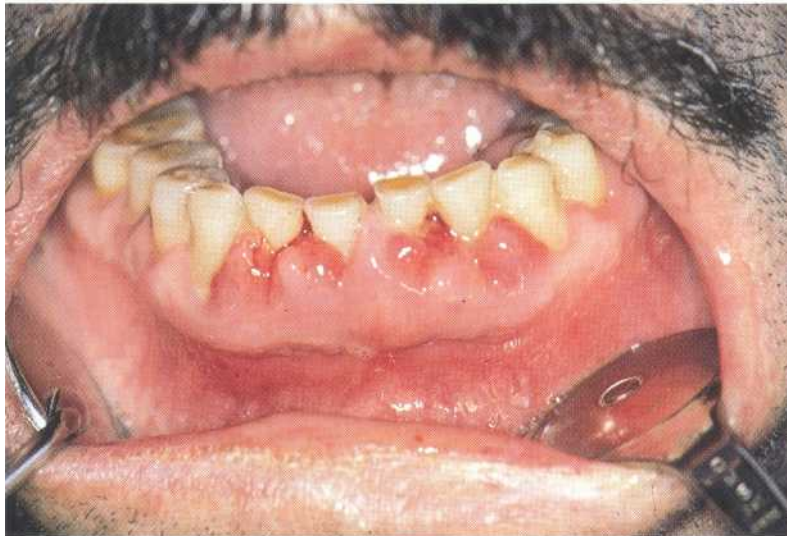

Fig. 481. Acute myelocytic leukemia, marked gingival enlargement.

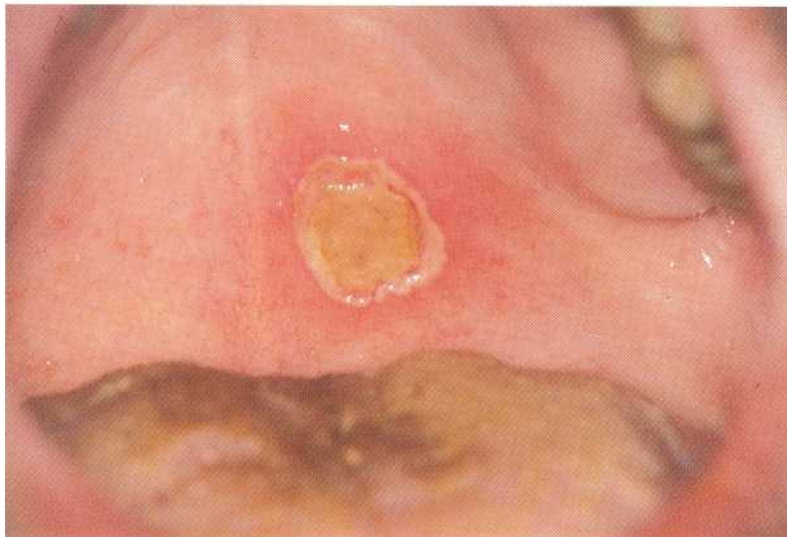
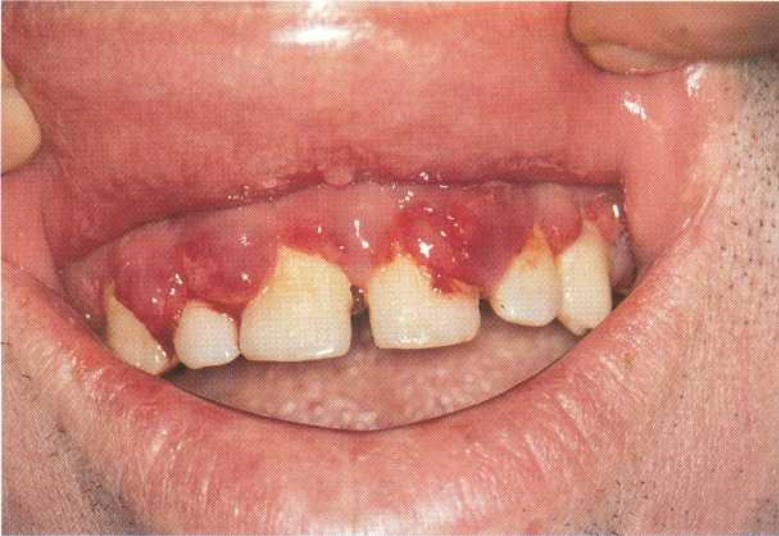
Fig. 482. Chronic lymphocytic leukemia, ulcer on the palate.



**Fig. 483. Chronic lymphocytic leukemia, severe gingival enlargement.**

### Erythroleukemia

Erythroleukemia, or Di Guglielmo's syndrome, is a variant of acute myelogenous leukemia. It represents about 3% of all cases of acute leukemia and is rare in childhood. During the early stages, it is characterized by intense erythroid proliferation in the bone marrow and abnormal red cells in the blood. This erythremic myelosis may evolve to either erythroleukemia or acute myelogenous leukemia. Clinically, there is anemia, fever, hepatosplenomegaly, and hemorrhages. The clinical course is downhill and resembles the course of acute myelogenous leukemia. The oral mucosa may rarely be affected, with gingival hemorrhages and enlargement (Fig. 485).

### Polycythemia Vera

Polycythemia vera is a relatively common myeloproliferative disorder characterized by an increase in the production of red cells and an absolute increase in erythroid mass. The cause remains obscure, and it is more common in men over 50 years of age. The disease usually has an insidious onset and is often discovered after a routine blood count that shows an elevated hemoglobin or hematocrit level. Clinically, it is characterized by headache, dizziness, vertigo, tinnitus, visual disturbances, cardiovascular and gastrointestinal symptoms, pruritus, hemorrhages, venous thromboses, and a ruddy cyanotic skin. The oral mucosa usually acquires a deep purplish red color

(Fig. 486). Gingival bleeding and enlargement, petechiae, and ecchymoses of the oral mucosa may also occur.

The differential diagnosis includes polycythemia secondary to various other causes, idiopathic thrombocythemia, and other platelet disorders.

Laboratory tests helpful in establishing the diagnosis are the standard blood count and bone marrow examination.

Treatment is supportive and is best left on the specialist.

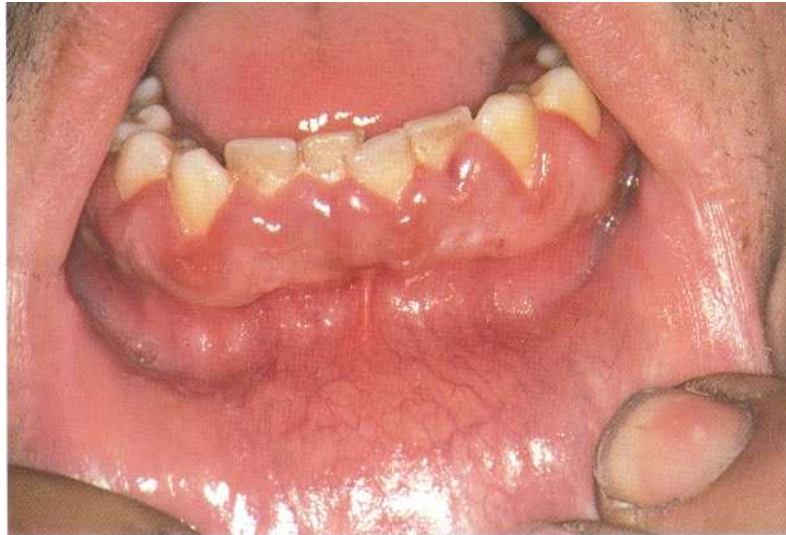

Fig. 484. Chronic myelocytic leukemia, marked gingival enlargement.

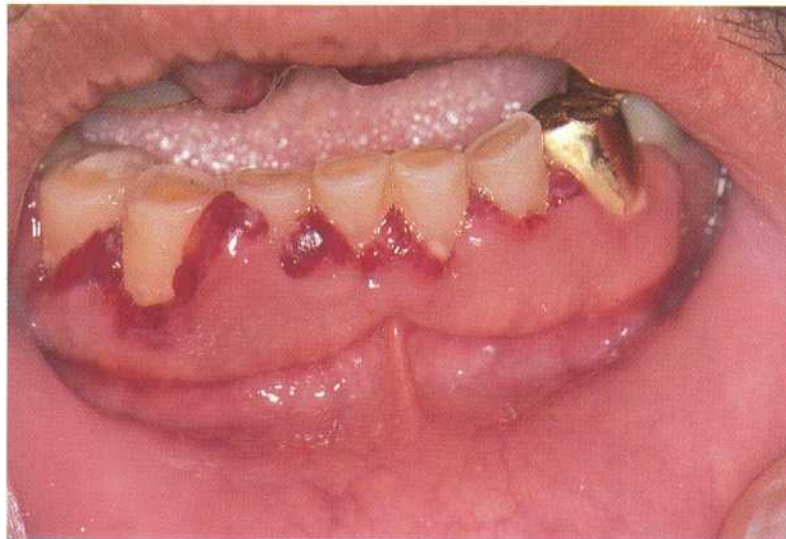

Fig. 485. Erythroleukemia, gingival enlargement.

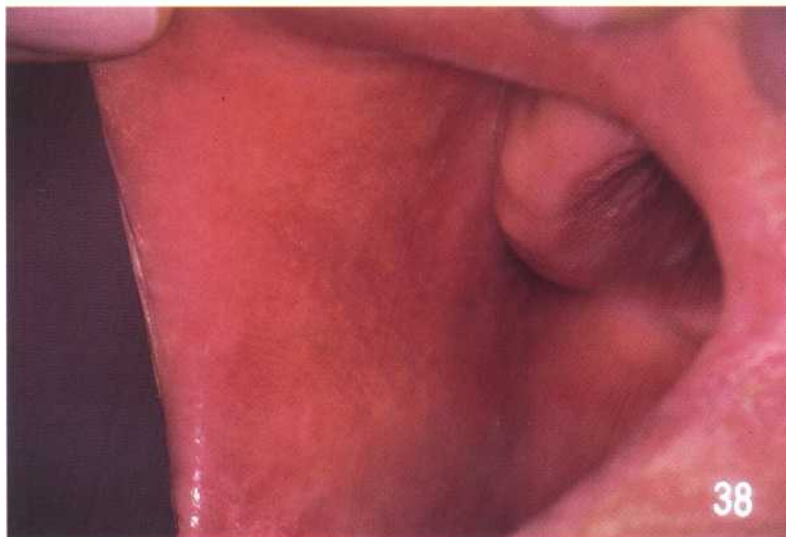

Fig. 486. Polycythemia vera, purplish red color of the buccal mucosa.

## Hodgkin's Disease

Hodgkin's disease is a malignant disease of the mononuclear cell system rather than the lymphoid tissue *per se*. It is a disease of unknown cause that affects more often young males than females. Depending on the extent, Hodgkin's disease is classified as stage I, II, III, or IV and further characterized as A or B, depending on absence or presence of systemic manifestations. This staging along with the histologic typing of the disease determines the treatment and the prognosis. Hodgkin's disease has been recently recorded with increasing frequency in patients with AIDS. Painless enlargement of cervical lymph nodes or other groups of lymph nodes is a common manifestation (Fig. 487). Anorexia, weight loss, fever, night sweats, and pruritus may accompany lymphadenopathy early in the course of the disease, or alternatively these systemic manifestations may appear later. If the disease metastasizes to extra lymphatic tissues, a constellation of symptoms and signs appears, depending on the site of metastasis and the organ involved.

A variety of skin manifestations may be associated with Hodgkin's disease, such as erythema nodosum, exfoliative dermatitis, pemphigus, dermatomyositis.

The oral cavity is an infrequent site of Hodgkin's disease, where ulcers or red swollen areas may appear (Fig. 488). However, submandibular and cervical lymphadenopathy are common initial signs. The involved nodes are multiple or solitary, bilateral or unilateral, and rubbery on palpation.

The differential diagnosis includes non-Hodgkin's lymphomas, necrotizing sialometaplasia, squamous cell carcinoma, Wegener's granulomatosis, lethal midline granuloma, and infectious mononucleosis.

Laboratory tests essential in establishing the diagnosis are histopathologic examination of involved lymph nodes or biopsy of lesions that appear suspicious. Immunologic markers and bone marrow biopsy are very useful for final diagnosis.

**Treatment.** Radiotherapy and chemotherapy. The choice of treatment regimen is dependent on the stage of the disease.

## Non-Hodgkin's Lymphomas

Non-Hodgkin's lymphomas are a heterogeneous group of neoplastic disorders that originate from lymphocytic cell lines. They represent about 70% of all lymphomas and have an unknown cause. Classification of this group depends on pathologic, immunologic, clinical, and therapeutic criteria. The four-stage classification (I, II, III, VI) may be useful for therapeutic and prognostic purposes. Non-Hodgkin's lymphomas occur at any age and affect both sexes equally. The onset may be quiet or fulminant, and painless lymphadenopathy is usually the presenting symptom. Less often, fever, weight loss, or symptoms related to sites of extranodal involvement may occur. Cervical nodes are most frequently involved, followed by axillary, inguinal, and other nodes.

Oral involvement may be part of disseminated disease or the only manifestation. An increased incidence of oral non-Hodgkin's lymphomas has been observed in patients with AIDS.

Usually, an oral lymphoma presents as a diffuse painless swelling, which in advanced cases may ulcerate (Fig. 489). The surface of the ulcer is irregular, with inflammation and induration of the base but not of the surrounding tissues (Fig. 490). The tonsillar area, the palate, the base of the tongue, the posterior gingiva, and the floor of the mouth are the most frequent sites involved.

The differential diagnosis includes Hodgkin's disease, pseudolymphomas, Wegener's granulomatosis, lethal midline granuloma, eosinophilic ulcer, necrotizing sialometaplasia, systemic mycoses and squamous cell carcinoma.

Laboratory tests to establish the diagnosis are designed to determine the histopathologic and immunologic types of the malignant lymphocytes.

**Treatment.** Radiotherapy and chemotherapy.

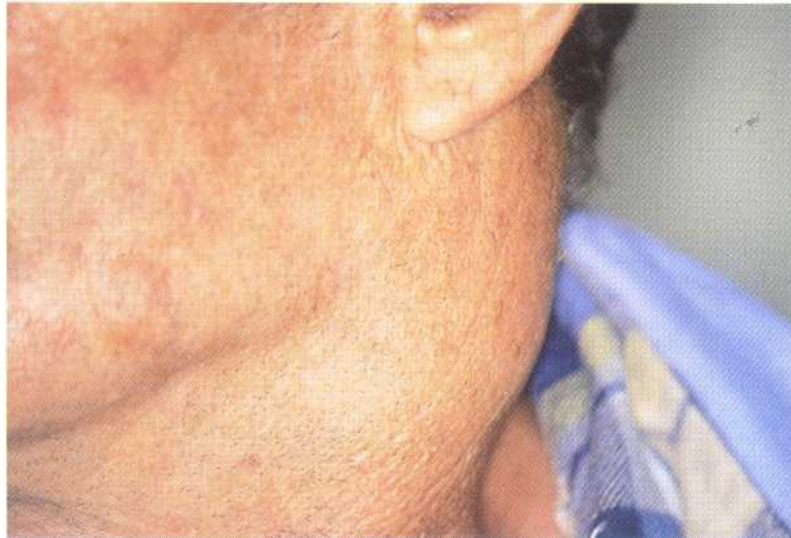

Fig. 487. Hodgkin's disease, swelling of cervical lymph nodes.

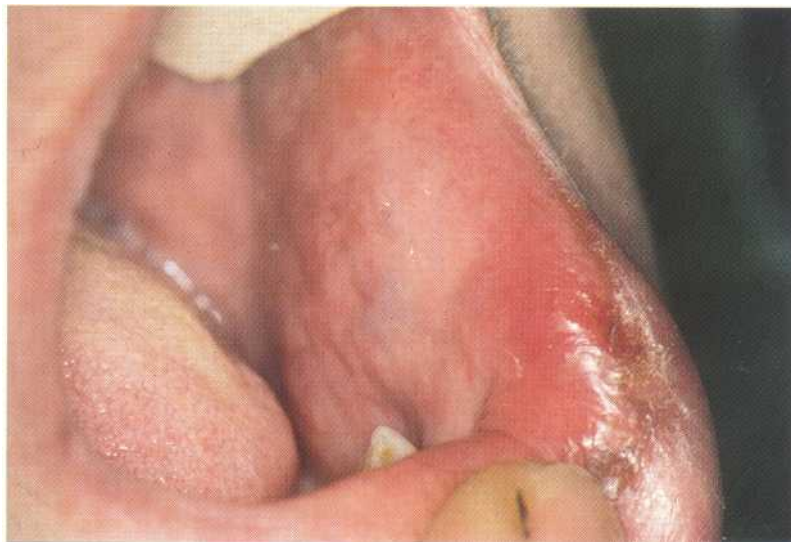

Fig. 488. Hodgkin's disease, swelling of the buccal mucosa.

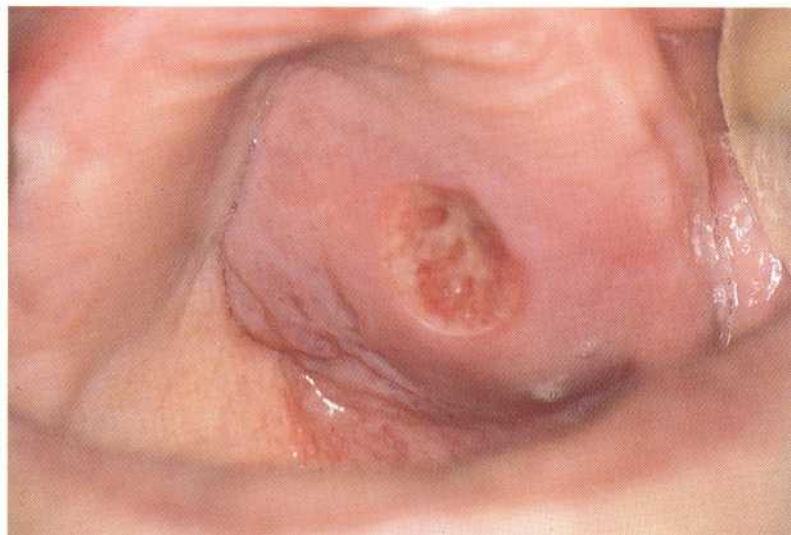
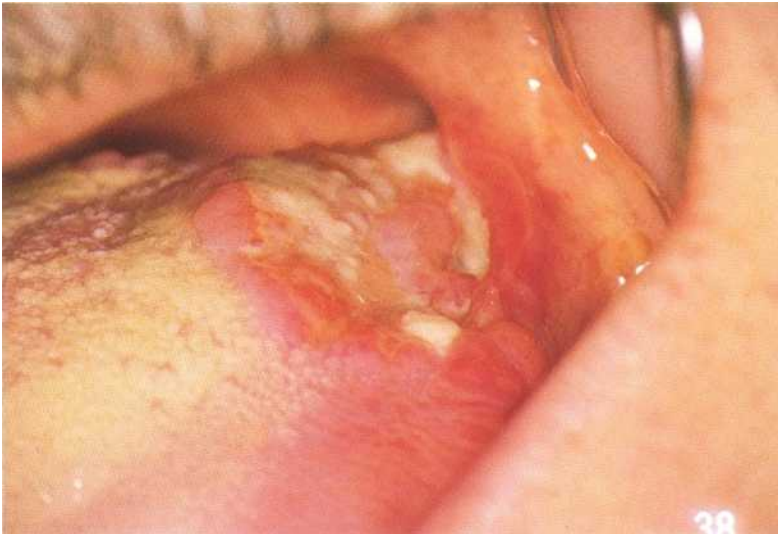
Fig. 489. Non-Hodgkin's lymphoma swelling and ulcer on the palate.



**Fig. 490. Non-Hodgkin's lymphoma ulcer on the tongue.**

### Burkitt's Lymphoma

This is a high-grade malignant B-cell lymphoma arising from germinal cells of lymph nodes. Epstein-Barr virus is related to the development of this lymphoma. It is prevalent in Africa (endemic form) and usually affects children 2 to 12 years of age. Sporadic cases have been described throughout the world (non-endemic form). The prognosis depends on the stage of the disease, and long-term survival ranges from 20 to 70%. The jaws are the most frequent sites of presentation of Burkitt's lymphoma, which grows rapidly and causes bone destruction and tooth loss (Fig. 491). As the disease progresses, large ulcerating masses may be seen in the mouth.

The differential diagnosis includes other cancers of childhood, other subtypes of non-Hodgkin's lymphomas, central giant cell granuloma, ossifying fibroma, and odontogenic tumors.

**Laboratory test.** Histopathologic examination confirms the diagnosis.

Treatment is chemotherapy and radiotherapy.

### Mycosis Fungoides

Mycosis fungoides is a non-Hodgkin's T-cell lymphoma primarily involving the skin. The skin lesions may persist for years, but the disease eventually involves the lymph nodes and other organs, commonly resulting in death. Middle-aged women are more frequently affected than men. The clinical

course progresses in three stages: the premycotic, or erythematous stage, which begins with an intensely pruritic eruption and may resemble psoriasis, parapsoriasis en plaque, or eczema; the plaque stage, which is characterized by the presence of irregularly shaped, well-demarcated, and slightly elevated and indurated plaques (Fig. 492); the tumor stage, in which most of the plaques develop into raised tumors that often ulcerate, or tumors that may arise de novo. Involvement of the oral mucosa is rare and usually occurs during the plaque and tumor stages of the disease. Clinically, the oral mucosa shows an extensive erythema, which later progresses into indurated plaques or ulcerated tumors. Nonspecific superficial ulcers on a red surface may be seen (Fig. 493). The most frequent sites of involvement are the vermillion border of the lips, the buccal mucosa, palate, and the tongue.

The differential diagnosis includes other non-Hodgkin's lymphomas, dermatomyositis, and lupus erythematosus.

Laboratory test to establish the diagnosis is histopathologic examination and monoclonal antibody markers.

Treatment is chemotherapy and radiation.

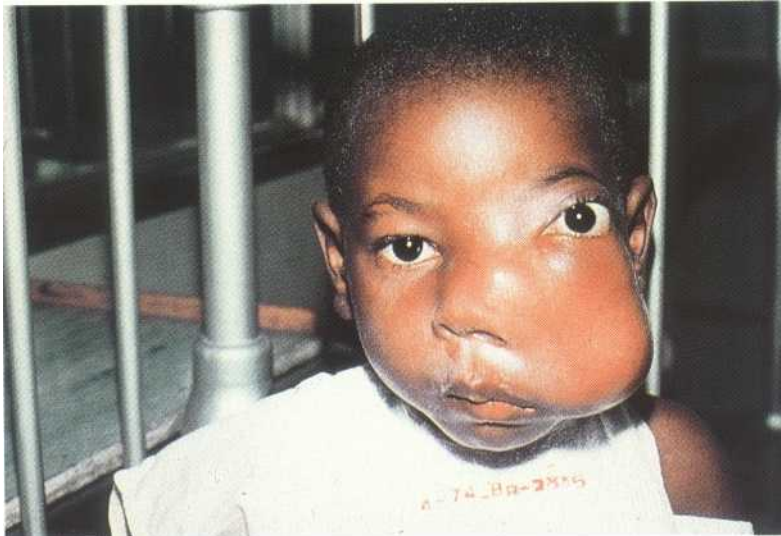

Fig. 491. Burkitt's lymphoma.

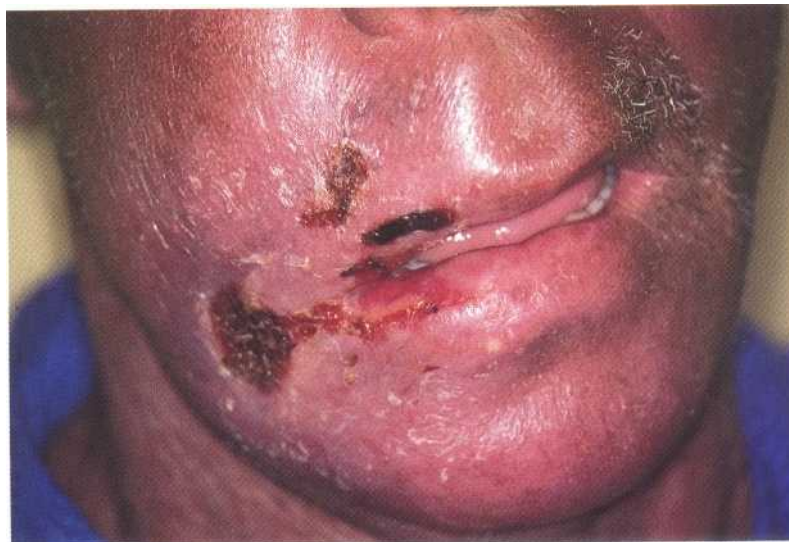

Fig. 492. Mycosis fungoides, plaque stage.

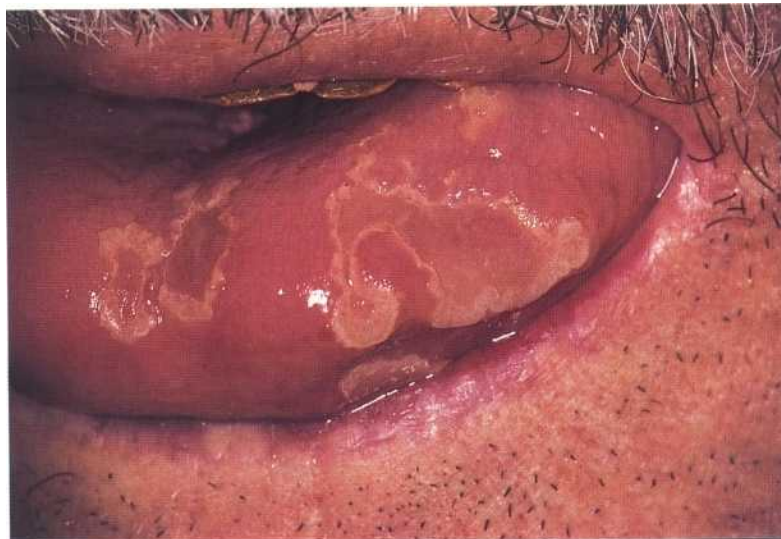


Fig. 493. Mycosis fungoides, multiple ulcers on the tongue.



### Macroglobulinemia

Macroglobulinemia, or Waldenström's disease, is a relatively uncommon plasma cell disorder, resulting in anomalous development of plasma B-cell clones that produce large amounts of immunoglobulin M. The disease more commonly affects men more than 50 years of age. The prognosis varies from a protracted course to fulminant short illness. The most common symptoms are fatigue, weakness, pallor, weight loss, malaise, lymphadenopathy, neurologic disorders, and hepatosplenomegaly. Ocular, nasal, and oral mucosa hemorrhages are characteristic. Gingival hemorrhages that persist and petechiae, ecchymoses, and ulcers are also characteristic findings (Fig. 494).

The differential diagnosis includes thrombocytopenic purpura and leukemia.

Laboratory tests useful for diagnosis are bone marrow biopsy and serum protein electrophoresis.

Treatment. Alkylating agents and systemic corticosteroids are the drugs of choice. Plasmapheresis is also useful.

### Plasmacytoma of the Oral Mucosa

Primary soft tissue plasmacytoma is an unusual neoplasm that consists of plasma cells indistinguishable from those seen in multiple myeloma. It is considered to be a solitary extramedullary form of multiple myeloma that affects more often males over 50 years of age. Primary soft tissue plasmacytoma usually arises in submucous tissues of the upper respiratory tract and oral cavity and rarely in other areas. The oral mucosa is rarely affected. The great majority of the lesions involve the palate and the gingiva and more rarely the buccal mucosa, the floor of the mouth, and the tongue. Clinically, the disease has no characteristic features and presents as a painless soft swelling with a smooth normal surface that may ultimately ulcerate (Fig. 495). The size at the time of diagnosis varies from 1 to several centimeters in diameter.

A number of patients with primary soft tissue plasmacytoma will ultimately develop generalized multiple myeloma; some die because of local invasion and others exhibit no evidence of neoplasm after treatment.

The differential diagnosis includes non-Hodgkin's lymphoma, pleomorphic adenoma, malignant neoplasms of the minor salivary glands, and other tumors.

Laboratory test. Histopathologic examination and serum immunologic studies are necessary to establish the diagnosis.

Treatment. Radiation or chemotherapy or surgery.

### Multiple Myeloma

Multiple myeloma is a generalized malignant plasma cell disorder of unknown cause. The disease originates in the bone marrow, but extramedullary lesions may also develop during the course of the disease. Abnormal proliferation of plasma cells, bone marrow dysfunction, and abnormal immunoglobulin production are the basic disorders. About 10 to 25% of multiple myeloma cases are associated with primary systemic amyloidosis. The disease is more common in men over 50 years of age. The skull, sternum, pelvis, ribs, and clavicles are common sites of bone involvement. Involvement of the jaws, particularly the mandible, is frequent and may be the presenting manifestation. Pain, paresthesia, bone swelling, and teeth mobility are the most common symptoms. A painless, soft, nonspecific swelling, usually on the gingiva and alveolar mucosa, may develop as part of the whole spectrum (Fig. 496).

The differential diagnosis includes non-Hodgkin's lymphoma, gingival cyst of adults, and benign and malignant oral tumors.

Laboratory test confirming the diagnosis is bone marrow biopsy. Serum and urine protein electrophoresis and roentgenographic bone examination are also helpful.

Treatment. Chemotherapy and radiation.

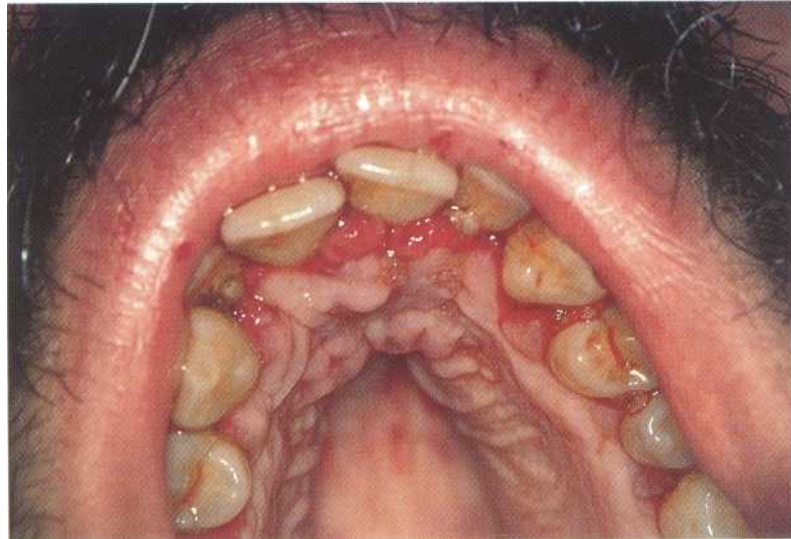


Fig. 494. Macroglobulinemia, gingival hemorrhage and ulcers.

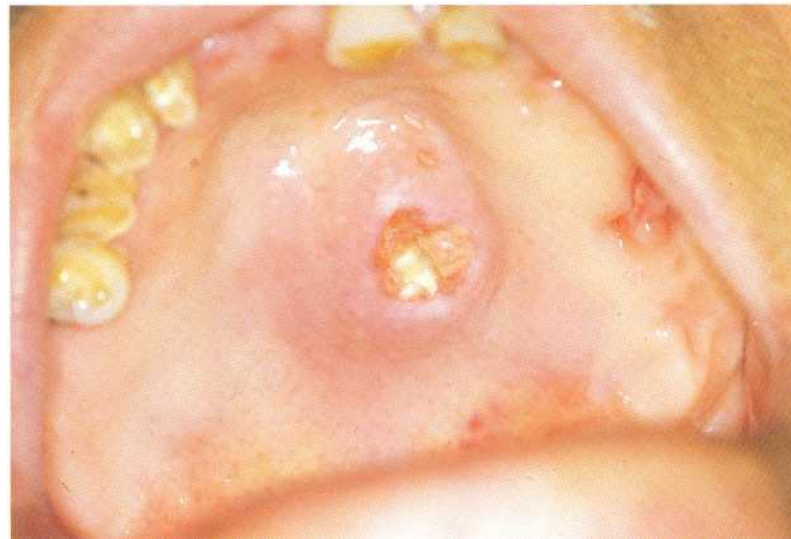

Fig. 495. Solitary plasmacytoma of the palate.

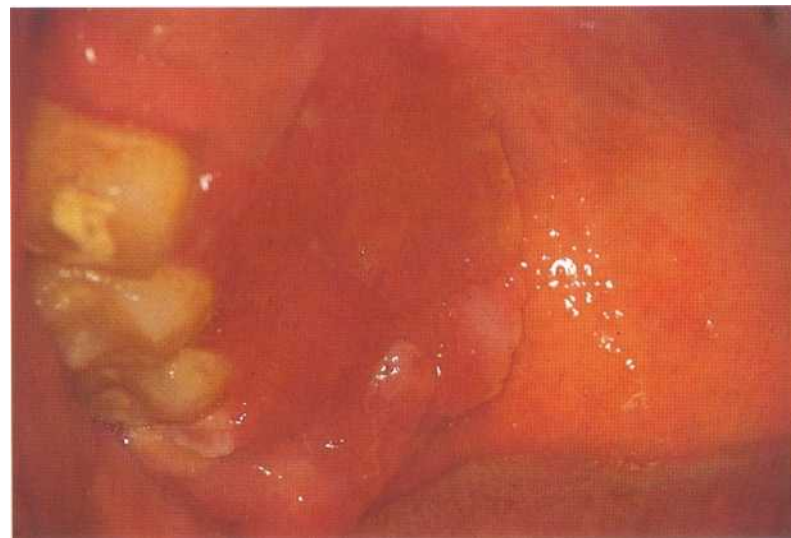


Fig. 496. Multiple myeloma, soft red swelling on the gingiva and palate.

## 33. Benign Tumors

### Papilloma

Papilloma is a common benign neoplasm, originating from the surface epithelium. It occurs at any age and in either sex. Clinically, the papilloma is an exophytic well-circumscribed pedunculated, or sessile growth that usually occurs as a solitary lesion, although multiple lesions may also develop. It consists of numerous small projections, which give the tumor a cauliflower surface (Figs. 497, 498). The tumor has a white or grayish color and varies in size from several millimeters to 1 or 2 cm in diameter. It occurs most frequently on the palate and the tongue and less often on the buccal mucosa, gingiva, and lips.

The differential diagnosis includes verruca vulgaris, condyloma acuminatum, verruciform xanthoma, sialadenoma papilliferum, verrucous carcinoma, and focal dermal hypoplasia syndrome.

Laboratory test. The diagnosis is confirmed by histopathologic examination.

Treatment is surgical excision.

### Verrucous Hyperplasia

Verrucous hyperplasia is a potentially precancerous lesion of the oral mucosa that may have clinical and histologic features similar to those of verrucous carcinoma. It is more common in smokers and patients older than 60 years of age. The gingiva and alveolar mucosa are most frequently involved, followed by buccal mucosa and tongue. Two clinical varieties have been described. The first, which is referred to as the "sharp" variety, consists of long, narrow, and white verrucous processes. The second, which is referred to as the "blunt" variety, consists of white verrucous processes that are broader and flatter (Fig. 499). Verrucous hyperplasia is frequently associated with leukoplakia (53%), as well as verrucous carcinoma (29%), and rarely squamous cell carcinoma (10%), whereas in 60% of the cases epithelial dysplasia may occur.

The differential diagnosis should include proliferating verrucous leukoplakia, verrucous carcinoma, squamous cell carcinoma, and white sponge nevus.

Laboratory test. The diagnosis is based on histopathologic examination.

Treatment is surgical excision.

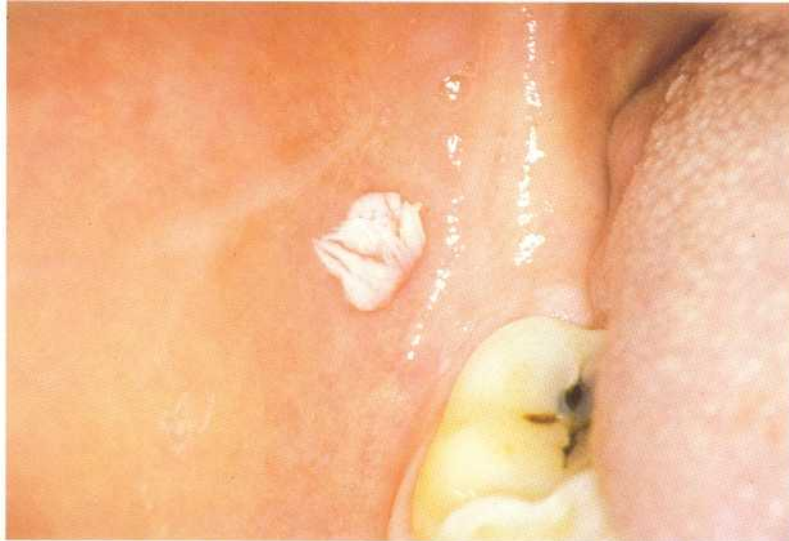

Fig. 497. Papilloma of the buccal mucosa.

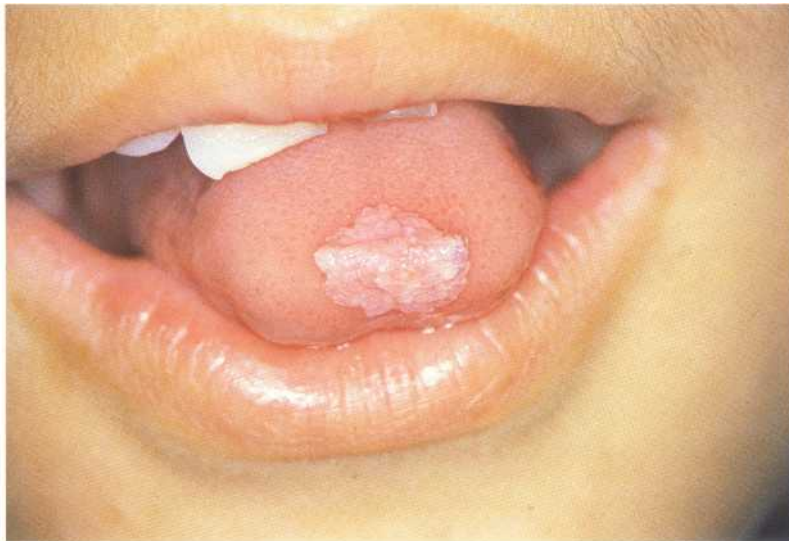

Fig. 498. Papilloma of the tongue.

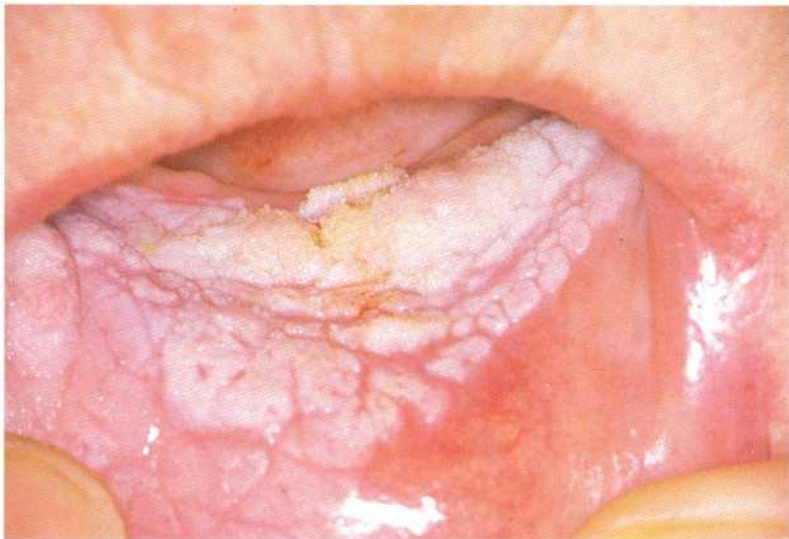

Fig. 499. Verrucous hyperplasia of the alveolar and lip mucosa.

### Keratoacanthoma

Keratoacanthoma is a fairly common benign skin tumor that probably arises from the hair follicles. The tumor occurs on exposed skin, especially the face. It is more common in men than women (ratio 1.8:1) and is usually seen in persons more than 50 years of age. Clinically, it appears as a painless well-circumscribed dome or bud-shaped tumor of 1 to 2 cm diameter, with a keratin crater at the center. The tumor begins as a small nodule that grows rapidly and, within 4 to 8 weeks, reaches its full size. For a period of 1 to 2 months, it persists without change, and then it may undergo spontaneous regression over the next 5 to 10 weeks. About 10% of keratoacanthomas are located on the lips (Fig. 500), whereas very few cases have been reported intraorally.

Based on the histogenesis and the biologic behavior, two types of keratoacanthoma are now recognized. Type I (bud-shaped) arises as a result of thickening and elongation of the walls of the superficial parts of hair follicles. Type II (dome-shaped) arises from the deeper part of the hair follicles or hair germ.

The differential diagnosis should include basal and squamous cell carcinomas and warty dyskeratoma.

Laboratory test. The diagnosis is based on histopathologic examination.

Treatment. Although some keratoacanthomas may regress spontaneously, the treatment of choice is surgical excision, or radiation in small doses.

### Fibroma

Fibroma is the most common benign tumor of the oral cavity and originates from the connective tissue. It is believed that the true fibroma is very rare and that most cases represent fibrous hyperplasia caused by chronic irritation. It occurs in both sexes, most often between the ages of 30 and 50 years. Clinically, the fibroma is a well-defined, firm, sessile or pedunculated tumor with a smooth surface of normal epithelium (Fig. 501). It appears as an asymptomatic, single lesion usually under 1 cm in diameter, although in rare cases it may reach several centimeters. It often occurs on the gingiva, buccal mucosa, lips, tongue, and palate.

The differential diagnosis includes giant cell fibroma, lipoma, myxoma, peripheral ossifying fibroma, neurofibroma, schwannoma, fibrous histiocytoma, fibrous hyperplasia of the tuberosity, and pleomorphic adenoma.

Laboratory test. Histopathologic examination is essential for the diagnosis.

Treatment is surgical excision.

### Giant Cell Fibroma

Giant cell fibroma is a fibrous lesion of the oral mucosa that is histologically characterized by the presence of numerous stellate and multinucleated cells. Clinically, it presents as a painless well-circumscribed and pedunculated tumor with a normal color and slightly nodular surface (Fig. 502). The lesion varies in size from a few millimeters to 1 cm.

The giant cell fibroma is more common during the first three decades of life and displays a marked predilection for the gingiva, followed by the tongue, palate, buccal mucosa, and lip.

The differential diagnosis should include fibroma, neurofibroma, papilloma, peripheral ossifying fibroma, and pyogenic granuloma.

Laboratory test. The diagnosis is made on histopathologic criteria.

Treatment is surgical excision.

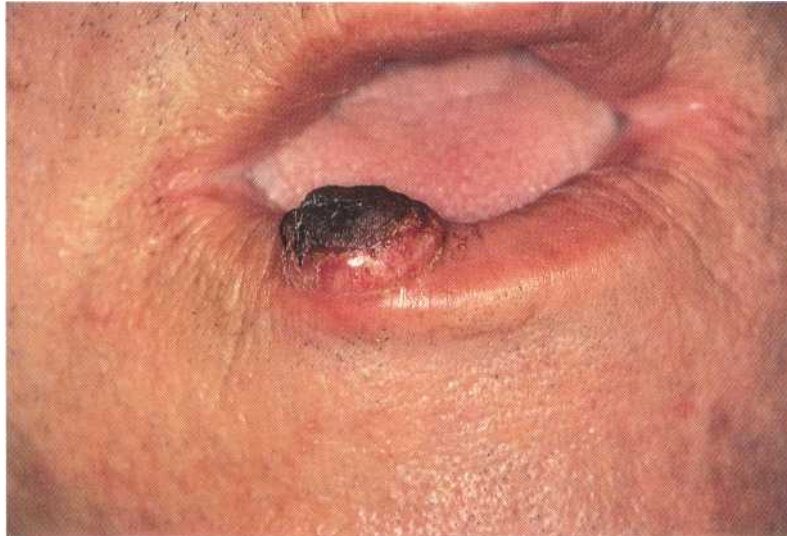

Fig. 500. Keratoacanthoma of the vermilion border of the lower lip.

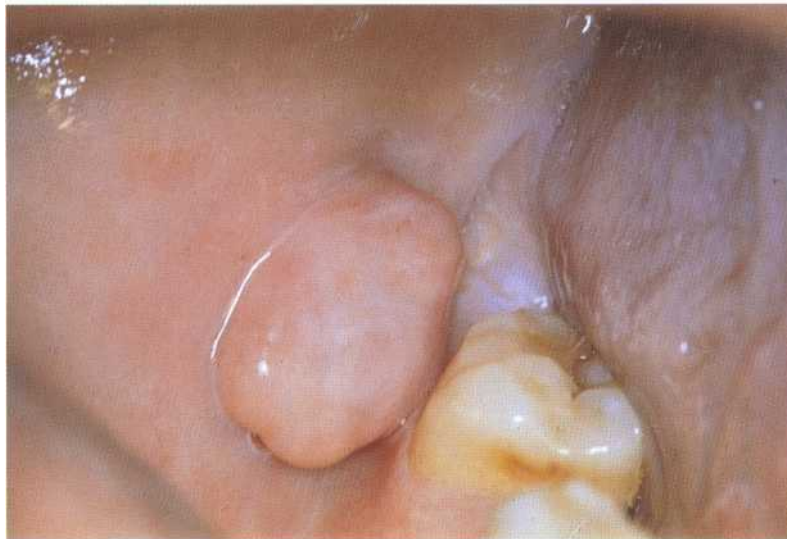


Fig. 501. Fibroma of the buccal mucosa.

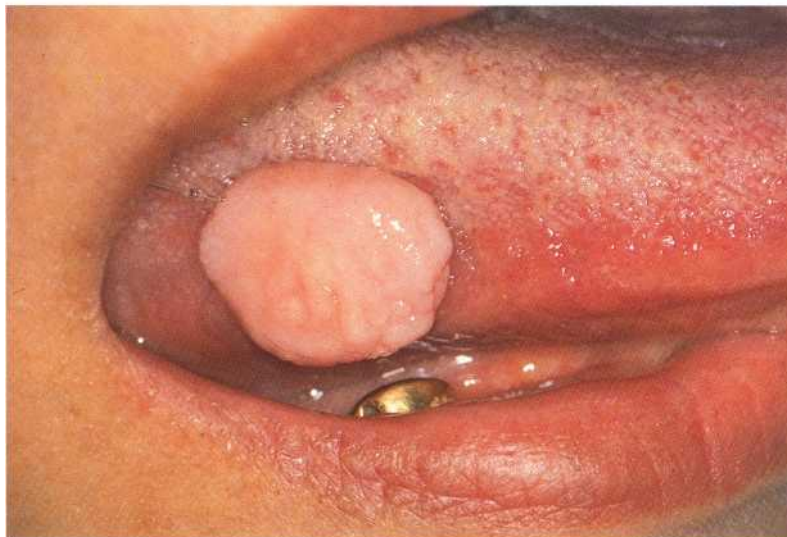

Fig. 502. Giant cell fibroma of the tongue.

### Peripheral Ossifying Fibroma

Peripheral ossifying fibroma, or peripheral odontogenic fibroma, is a benign tumor that is located exclusively on the gingiva and has characteristic histomorphologic features. The exact origin is unknown, although it is believed that it derives from the periodontal ligament. It is more common in children and young adults and has a predilection for females (ratio 1.7:1). Clinically, it is a well-defined firm tumor, sessile or pedunculated, covered by smooth normal epithelium (Figs. 503, 504). Usually the surface is ulcerated due to mechanical trauma. The size varies from a few millimeters to 1 to 2 cm, and more than 50% of the lesions occur in the incisor-cuspid region in both jaws.

The differential diagnosis should include fibroma, giant cell fibroma, peripheral giant cell granuloma, pyogenic granuloma, pregnancy granuloma, and peripheral odontogenic tumors.

Laboratory test. The diagnosis is based on histopathologic criteria.

Treatment is surgical excision.

### Soft-Tissue Osteoma

Osteomas are benign tumors that represent a proliferation of mature cancellous or compact bone. They may develop anywhere in the bone and rarely in the jaws. Osteomas are more common between 30 and 50 years of age and have a predilection for males. Multiple osteomas of the jaws are a common manifestation of Gardner's syndrome, oral soft tissue osteomas are, however, rare. Lesions have been described in the palate, buccal mucosa, tongue, and alveolar process.

Clinically, soft-tissue osteoma appears as a well-defined, asymptomatic hard tumor covered by thin and smooth normal epithelium (Fig. 505). The size ranges from 0.5 to 2 cm in diameter.

The differential diagnosis of soft tissue osteoma includes torus palatinus, exostoses, and fibroma.

Laboratory test. The diagnosis is established by histopathologic examination.

Treatment is surgical excision.

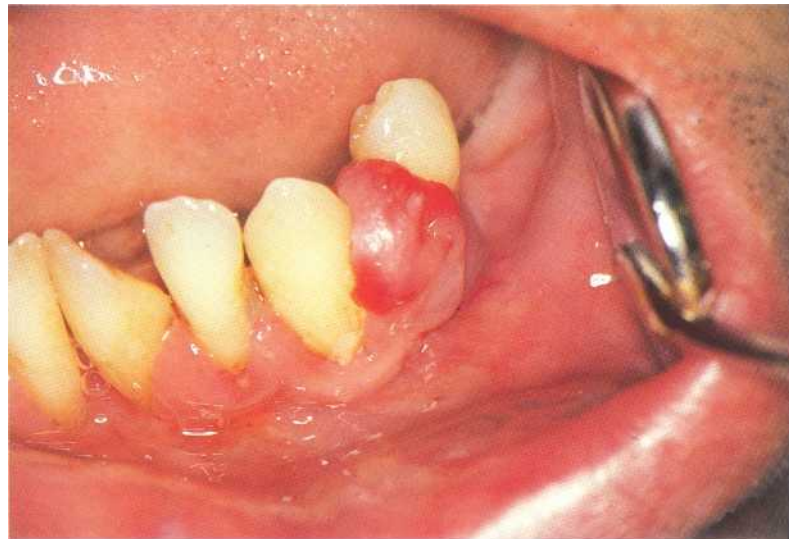

Fig. 503. Peripheral ossifying fibroma.

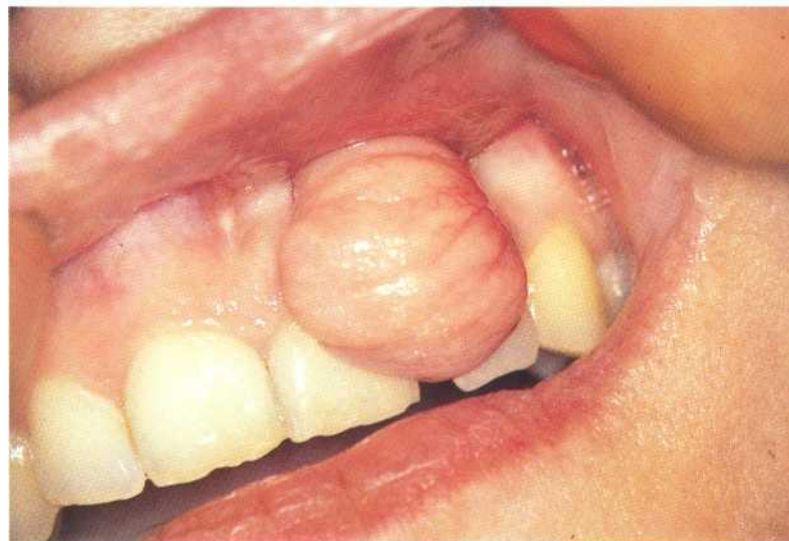

Fig. 504. Peripheral ossifying fibroma.

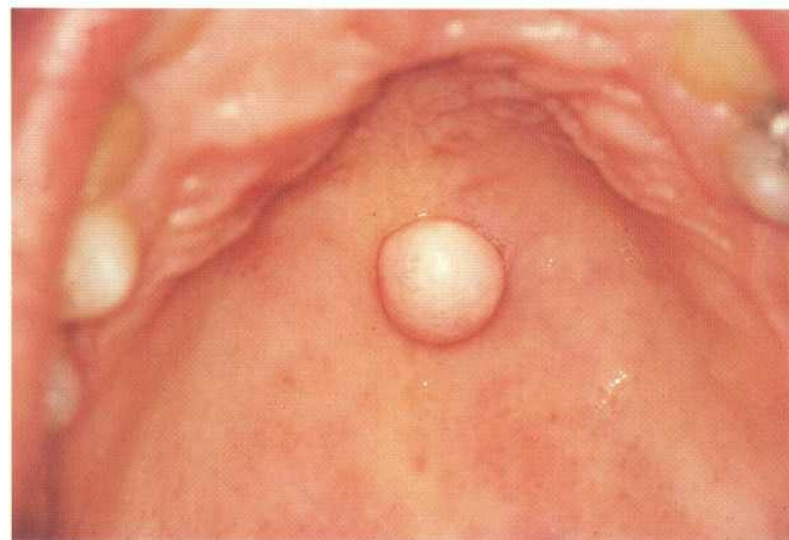


Fig. 505. Soft-tissue osteoma on the palate.



### Lipoma

Lipoma is a benign tumor of adipose tissue relatively rare in the oral cavity. It is more common between 40 and 60 years of age and is usually located on the buccal mucosa, tongue, mucobuccal fold, floor of the mouth, lips, and gingiva. Clinically, it appears as a painless, well-defined tumor, pedunculated or sessile, varying in size from a few millimeters to several centimeters of yellowish or pink color (Fig. 506). The covering epithelium is thin, with visible blood vessels. It is soft on palpation and occasionally fluctuant and may be misdiagnosed as a cyst, especially when it is located in the deeper submucosal tissues.

The differential diagnosis includes myxoma, fibroma, mucocele, and small dermoid cyst.

Laboratory test. The diagnosis is established by histopathologic examination.

Treatment is surgical excision.

### Myxoma

Myxoma is a benign tumor of mesenchymal origin. It is extremely rare in the oral mucosa and most of the lesions represent myxoid degeneration of the connective tissue and not a true neoplasm. Clinically, the myxoma is a well-defined mobile tumor covered by normal epithelium and soft on palpation (Fig. 507). It may appear at any age and is most frequent on the buccal mucosa, floor of the mouth, and palate.

The differential diagnosis includes fibroma, lipoma, mucoceles, and focal mucinosis.

Laboratory test. The diagnosis is established by histopathologic examination. Immunohistochemical markers are useful to distinguish nerve sheath myxomas from other oral myxoid lesions.

Treatment is surgical excision.

### Neurofibroma

Neurofibroma is a benign overgrowth of nerve tissue origin (Schwann cells, perineural cells, endoneurium). It is relatively rare in the mouth and may occur as a solitary or as multiple lesions representing part of neurofibromatosis or von Recklinghausen's disease. Clinically, it usually appears as a painless well-defined pedunculated firm tumor, covered by normal epithelium (Fig. 508). Neurofibromas vary in size from several millimeters to several centimeters. The lesion is usually located on the buccal mucosa and palate, followed by the alveolar ridge, floor of the mouth, and tongue.

The differential diagnosis includes schwannoma, fibroma, granular cell tumor, traumatic neuroma, and other benign mesenchymal tumors.

Laboratory test. Histopathologic examination is necessary to establish the diagnosis.

Treatment is surgical excision.

Fig. 506. Lipoma of the buccal mucosa.

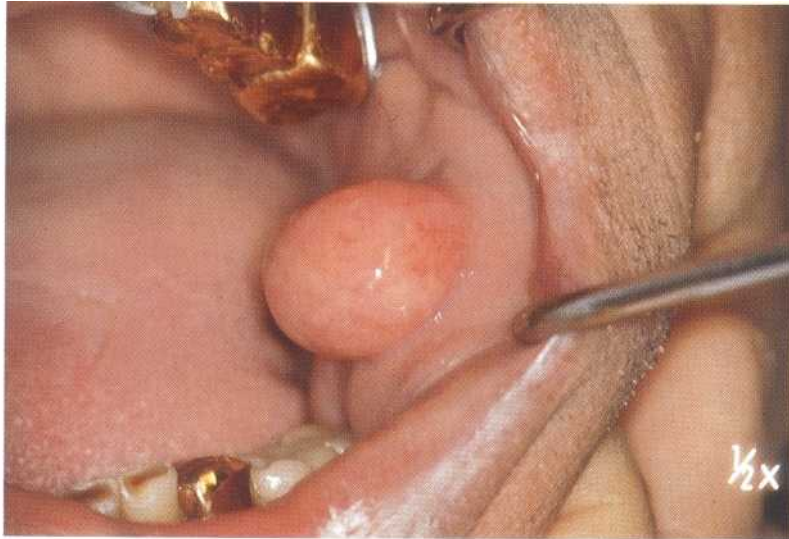


Fig. 507. Myxoma of the buccal mucosa.

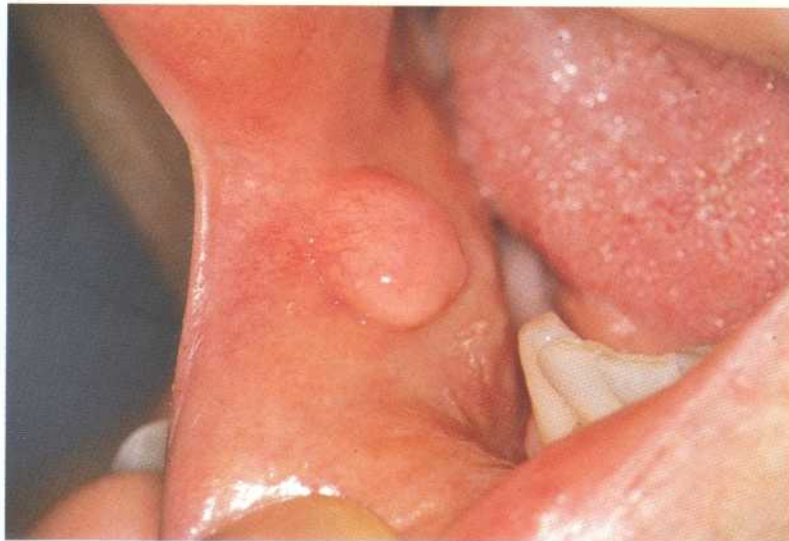
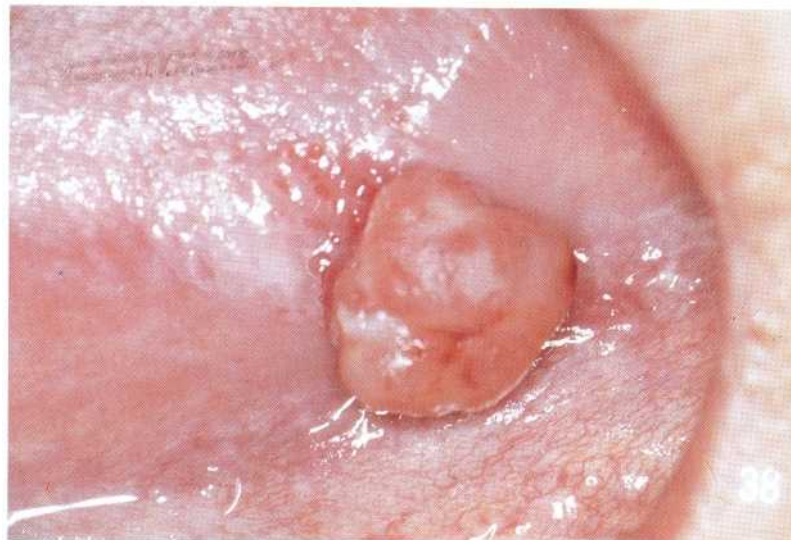
Fig. 508. Neurofibroma on the margin of the tongue.



### Schwannoma

Schwannoma, or neurilemoma, is a rare benign tumor derived from the Schwann cells of the nerve sheath. Clinically, it appears as a solitary well-circumscribed firm and sessile nodule, usually covered by normal epithelium (Fig. 509). It is painless, fairly firm on palpation, and varies in size. The Schwannoma may occur at any age and is most commonly located on the tongue, followed by the palate, floor of the mouth, buccal mucosa, gingiva, and lips.

The differential diagnosis includes neurofibroma, fibroma, granular cell tumor, lipoma, leiomyoma, traumatic neuroma, pleomorphic adenoma, and other salivary gland tumors.

Laboratory test. Histopathologic examination is essential to establish the diagnosis.

Treatment is surgical excision.

### Traumatic Neuroma

Traumatic neuroma or amputation neuroma is not a true neoplasm, but a hyperplasia of nerve fibers and surrounding tissues, after injury or transection of a nerve. Clinically, it appears as a small, usually movable tumor or nodule covered by normal mucosa. It is very slow growing and rarely exceeds 1 cm in size. Traumatic neuroma is characterized by pain, particularly on palpation, and is often located close to the mental foramen, on the alveolar mucosa of edentulous areas, the lips, and the tongue (Fig. 510).

The differential diagnosis includes neurofibroma, schwannoma, foreign-body reaction, and salivary gland tumor.

Laboratory test. The diagnosis is established by histopathologic examination.

Treatment is surgical excision.

### Leiomyoma

Leiomyoma is a rare benign tumor derived from smooth muscles. In the mouth it derives from the smooth muscles of blood vessel walls and from the circumvallate papillae of the tongue. Oral leiomyoma affects both sexes equally and usually persons more than 30 years of age. Clinically, it appears as a slow-growing, painless, firm, and well-defined tumor with normal or reddish color (Fig. 511). The tumor is movable and fairly soft on palpation. Most frequently, it occurs on the tongue, followed by the buccal mucosa, palate, and lower lip.

The differential diagnosis includes other benign tumors of connective tissue origin and blood vessels.

Laboratory test. The diagnosis is established by histopathologic examination.

The treatment of choice is surgical excision.

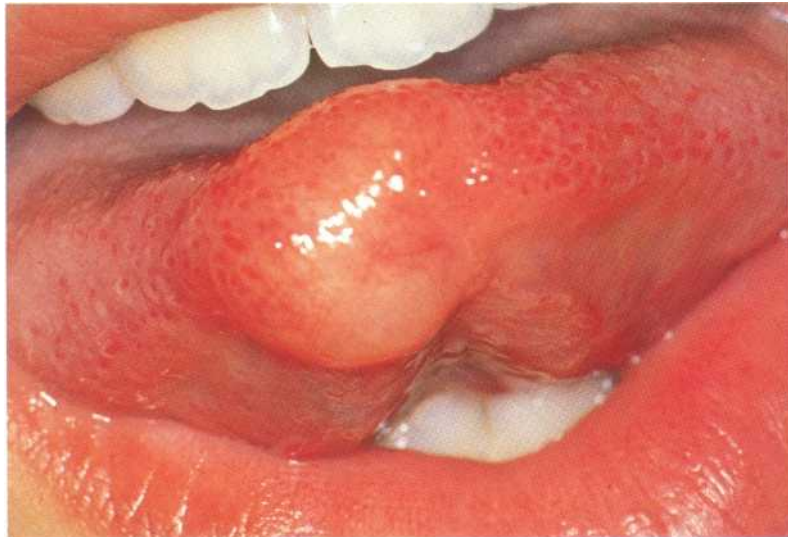

Fig. 509. Schwannoma on the tip of the tongue.

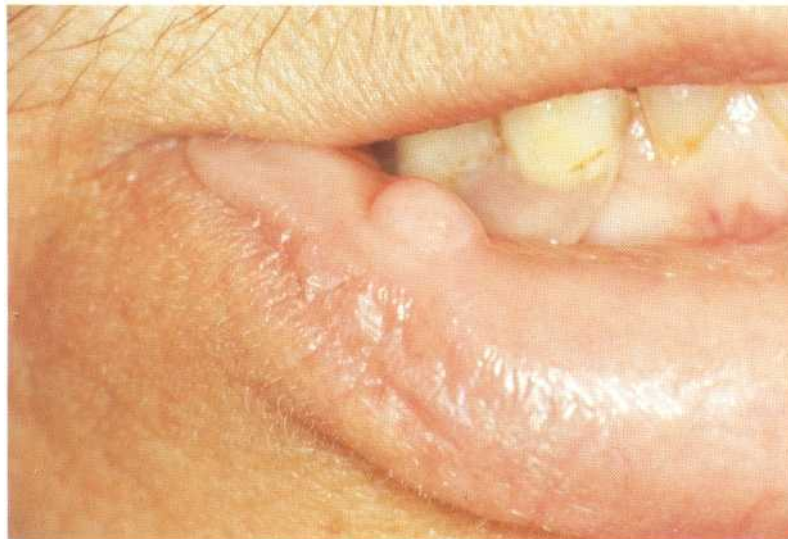

Fig. 510. Traumatic neuroma of the lower lip.

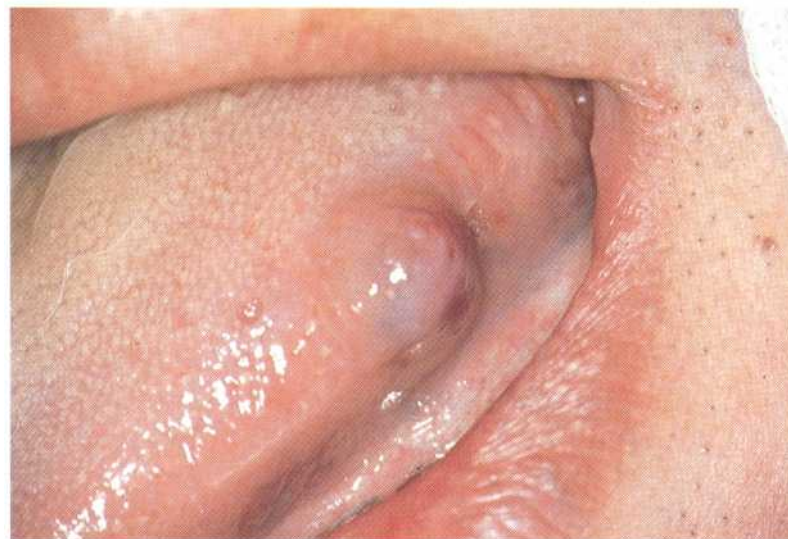

Fig. 511. Leiomyoma on the margin of the tongue.

### Verruciform Xanthoma

Verruciform xanthoma is a rare benign tumor of the oral cavity, of unknown cause and histogenesis, first described by Shafer in 1971. The outstanding microscopic feature is the presence of large xanthoma or foam cells in the connective tissue papillae, which do not extend beyond the epithelial rete peg extensions. It is more common between the 5th and 7th decades of life and seems to have a slight predilection for females (female: male ratio 1.4:1); The size ranges between 0.2 and 2 cm in diameter, and it is frequently located on the alveolar ridge and the gingiva (65%). Less often, it may be seen on the mucobuccal fold, palate, floor of the mouth, tongue, lips, and buccal mucosa. Clinically, it appears as a sessile, slightly elevated, and well-defined lesion. It has a cauliflower-like surface with normal or red-yellowish color (Fig. 512).

The differential diagnosis includes papilloma, verruca vulgaris, condyloma acuminatum, sialadenoma papilliferum, and verrucous carcinoma.

Laboratory test. The diagnosis is established by histopathologic examination.

Treatment is surgical excision.

### Granular Cell Tumor

Granular cell tumor, or granular cell myoblastoma or Abrikossoff's tumor, is a benign tumor of uncertain histogenesis. Recent evidence indicates that the origin of the tumor may be the perineural Schwann cells rather than muscles. The tumor may occur at any age and has a slight predilection for females. Clinically, it is a small, firm, well-defined asymptomatic nodule with whitish or normal color, which may be slightly elevated (Fig. 513). Usually, it is a single lesion, although multiple lesions may occur. In the oral cavity it is usually located on the dorsum and the lateral border of the tongue. It may also be found on the skin, breast, and very rarely in the intestine.

The differential diagnosis should include rhabdomyoma, fibroma, neurofibroma, schwannoma, traumatic neuroma, congenital epulis of the newborn, and other benign mesenchymal tumors.

Laboratory test. The diagnosis is established by histopathologic examination.

Treatment is surgical excision.

### Benign Fibrous Histiocytoma

Benign fibrous histiocytoma is a cellular tumor primarily composed of histiocytes and fibroblasts producing reticulum fibers. It represents a localized reactive lesion rather than a true neoplasm. The tumor occurs more often on the skin of the neck region and very rarely on the oral mucosa. Both sexes are affected, between 8 and 70 years old, and the size of the tumor ranges between 0.5 and 2 cm. The buccal mucosa is the most common site on involvement, followed by the tongue, the lower lip, and the gingiva. Clinically, it appears as a painless, mobile, and firm tumor, covered by normal epithelium, which may be ulcerated (Fig. 514).

The differential diagnosis includes fibroma, neurofibroma, schwannoma, lipoma, and granular cell tumor.

Laboratory test. The diagnosis is established by histopathologic criteria.

Treatment is surgical excision.

Fig. 512. Verruciform xanthoma of the tongue.

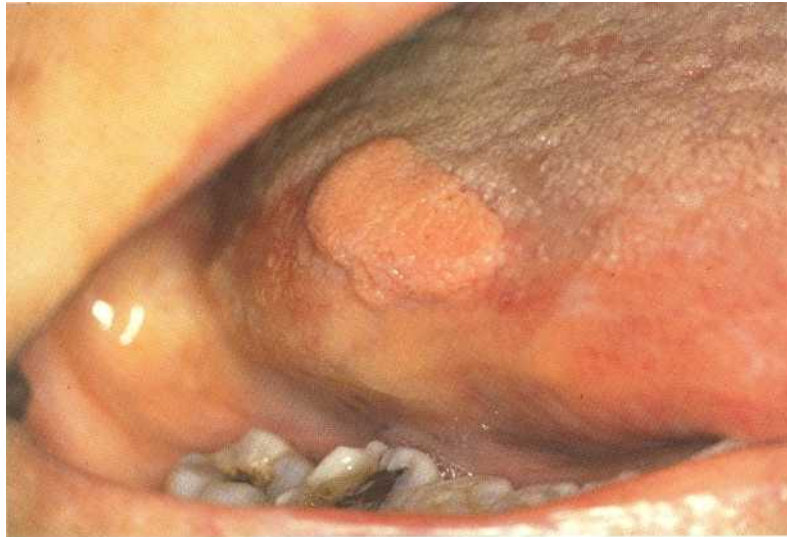

Fig. 513. Granular cell tumor on the margin of the tongue.

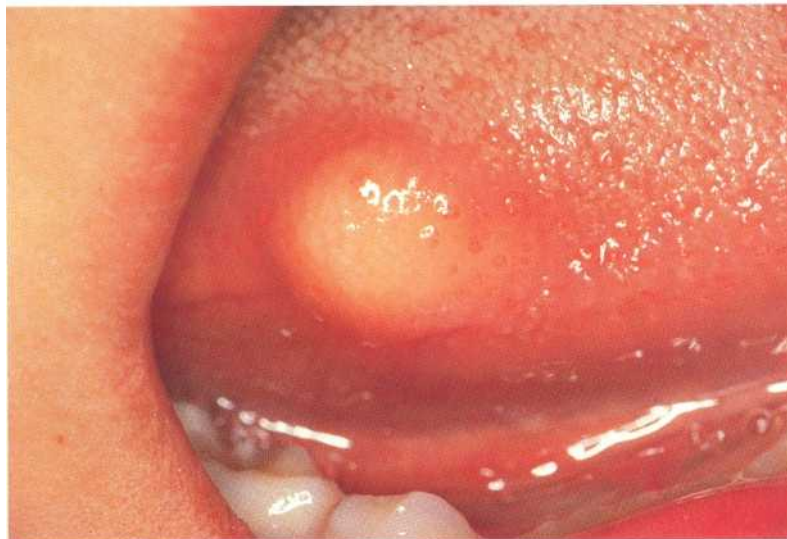
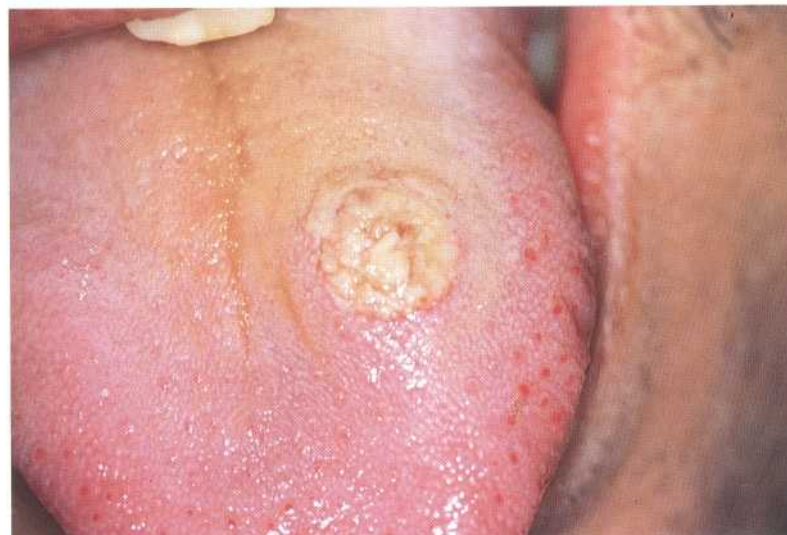
Fig. 514. Benign fibrous histiocytoma on the dorsum of the tongue.



## Hemangioma

Hemangioma is a common benign lesion of the oral cavity, characterized by the proliferation of blood vessels. It is not a true neoplasm, but rather a developmental abnormality. This concept is supported by the frequent presence of hemangiomas at birth or shortly after. On histologic criteria, two main types of hemangiomas are recognized: capillary hemangioma, which consists of numerous small capillaries and clinically appears as a flat red surface (Fig. 515), and cavernous hemangioma, which consists of large dilated sinuses filled with blood and clinically appears as an elevated lesion of deep red or reddish color (Fig. 516). A characteristic clinical sign of the lesions is that on pressure with the finger the red color disappears and returns when the pressure is released. The lips, tongue, and buccal mucosa are the most common sites on involvement. The size ranges from a few millimeters to extensive lesions (Fig. 517), which may cause organ deformities (such as macroglossia, macrocheilia). Rarely, hemangiomas may develop in the jaw bones.

The differential diagnosis includes pyogenic granuloma, hemangioendothelioma, hemangiopericytoma, Kaposi's sarcoma and several syndromes with oral vascular lesions, such as the Sturge-Weber syndrome, Maffucci's syndrome, Klippel-Trenaunay-Weber syndrome, and the Rendu-Osler-Weber syndrome.

Laboratory test useful for the diagnosis is histopathologic examination. The biopsy has to be taken very cautiously because of the danger of hemorrhage.

The treatment is surgical excision, cryotherapy, laser, or the injection of sclerosing agents into the lesion. Some congenital hemangiomas have been found to undergo spontaneous regression.

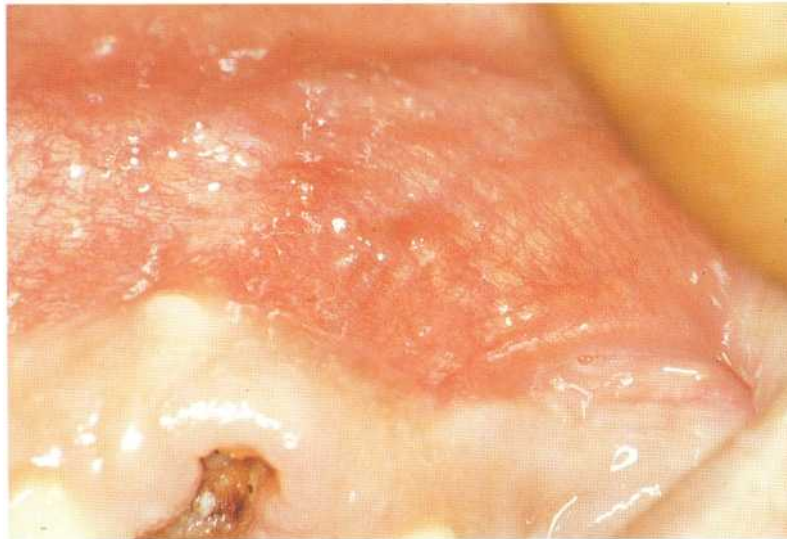

Fig. 515. Capillary hemangioma.

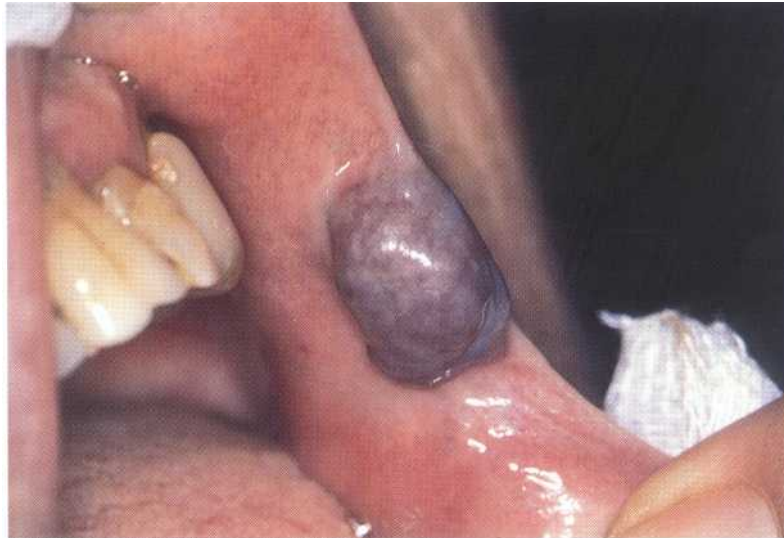

Fig. 516. Cavernous hemangioma.

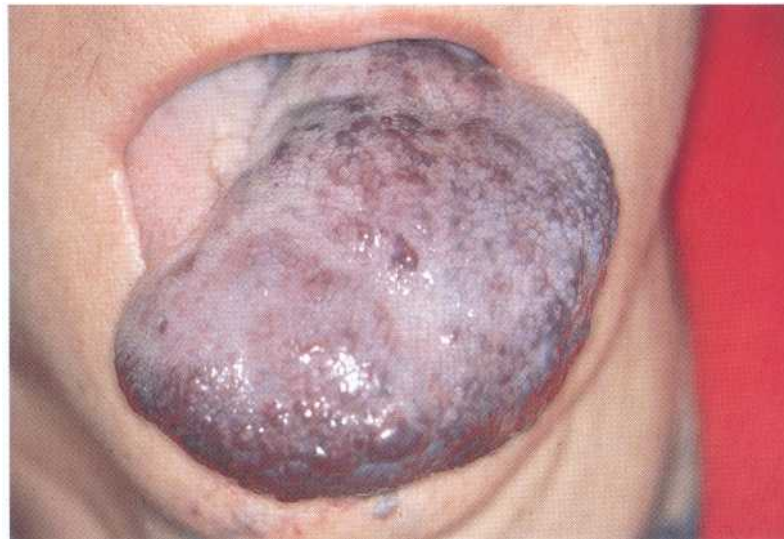
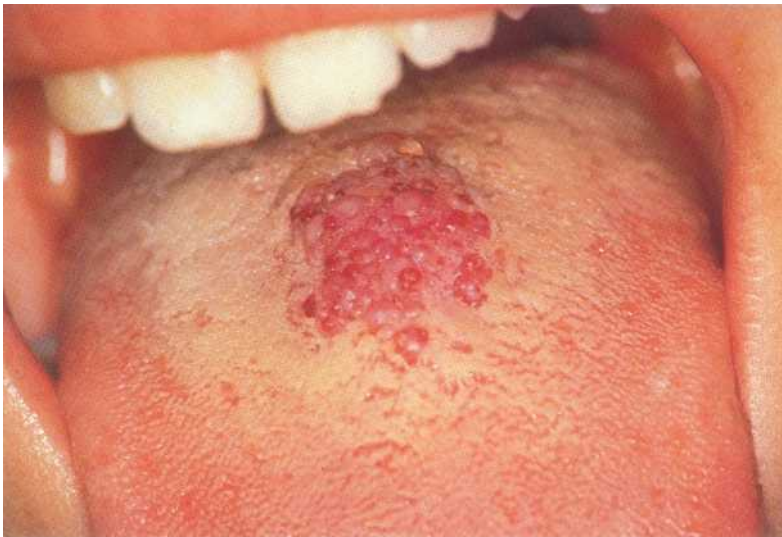
Fig. 517. Extensive hemangioma of the tongue.





**Fig. 518.** Lymphangioma of the tongue.

### Lymphangioma

Lymphangioma is a relatively common benign tumor of the oral cavity and, like hemangioma, it is a developmental abnormality rather than a true neoplasm. The great majority of the lesions appear during the first 3 years of life and show a marked predilection for the head and neck region. Clinically, oral lymphangiomas are characterized by small soft elevated nodules that resemble small cysts and have normal, or yellow-grayish, or red color (Figs. 518, 519). If the lesion is located deeper in the oral tissues, it appears as a diffuse mass without change of color. The size ranges from a few millimeters to extremely large lesions that cause organ deformities (Fig. 520). The dorsum of the tongue is the most frequent site of involvement. Less often, it may be found on the lips, buccal mucosa, floor of the mouth and soft palate, but it is extremely rare on the gingiva. It is usually asymptomatic, but when it gets larger, it may cause pain and discomfort during speech, chewing, and swallowing, or macroglossia. Recurrent infection of the lesion is common and constitutes a serious problem.

The differential diagnosis includes hemangioma, median rhomboid glossitis, lingual thyroid, and papillary hyperplasia of the palate. Deep lymphangiomas may be confused with other mesenchymal neoplasms.

**Laboratory test.** Histopathologic examination is essential for diagnosis.

Treatment is surgical excision.

### Cystic Hygroma

Cystic hygroma is a variety of lymphangioma that consists of large lymphatic sinuses and appears in infancy or early childhood. Clinically, it is a large diffuse soft swelling of the neck, extending to the submandibular or sublingual area and occasionally to the buccal mucosa and the parotid area (Fig. 521). It may cause esthetic or respiratory problems. The lesion may be unilateral or bilateral.

The differential diagnosis includes branchial cysts and diffuse lymphadenopathy.

**Laboratory test.** Histopathologic examination establishes the diagnosis.

Treatment is surgical excision.

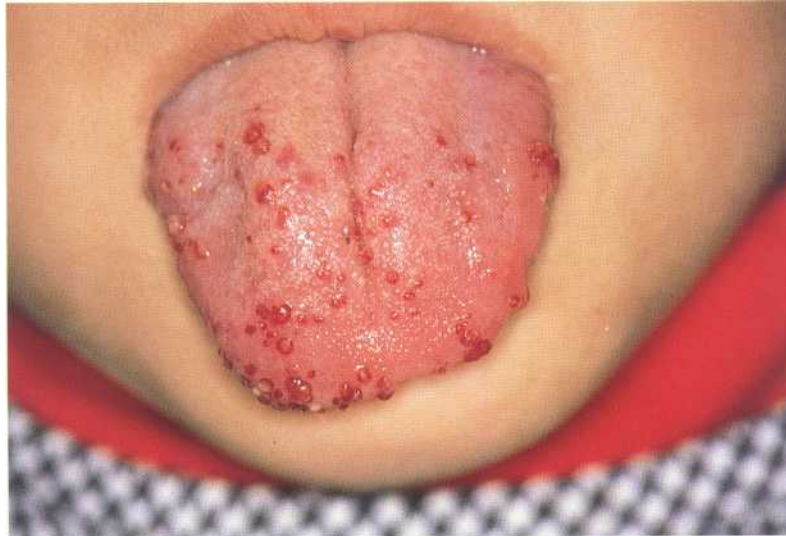

Fig. 519. Lymphangioma of the tongue.

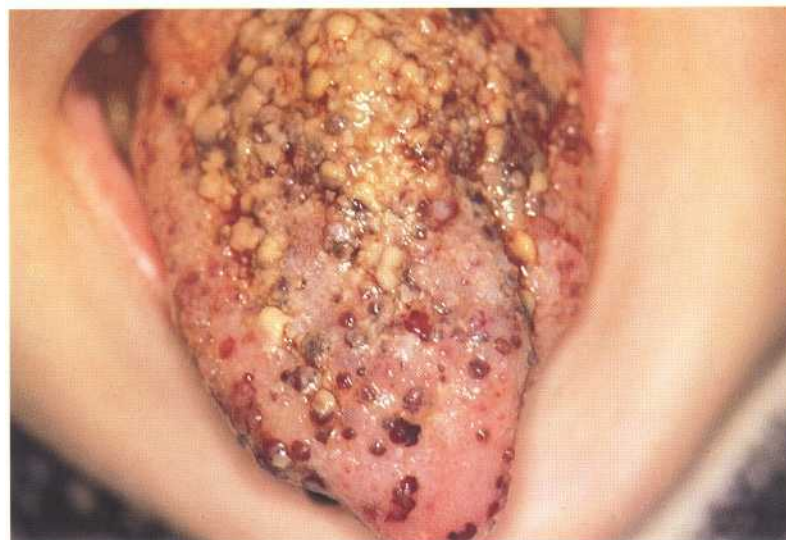


Fig. 520. Extensive lymphangioma of the tongue.

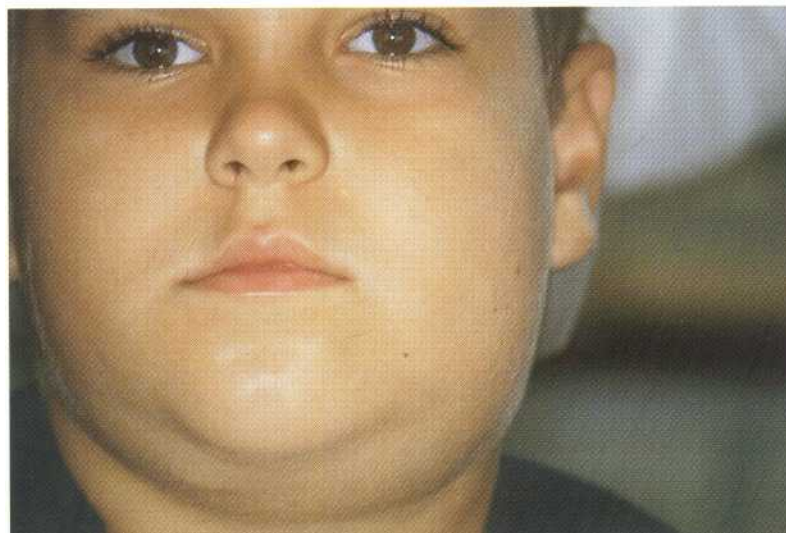
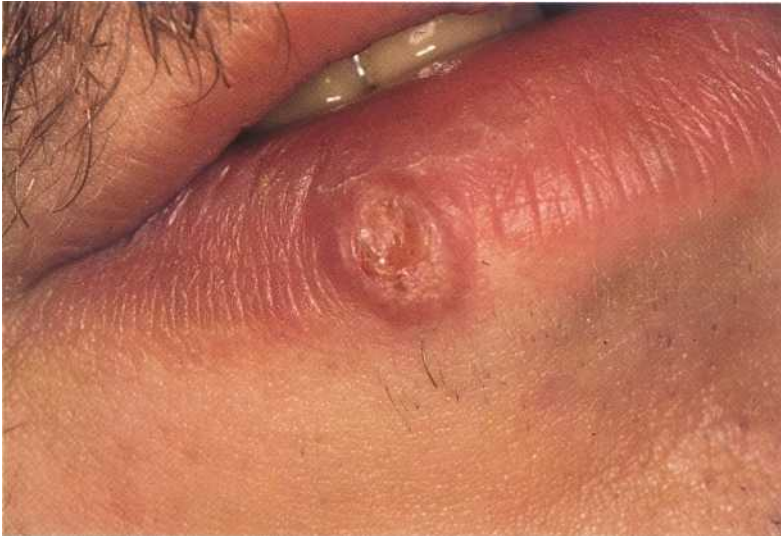
Fig. 521. Cystic hygroma, diffuse swelling of the neck.



**Fig. 522. Papillary syringadenoma of the lower lip.**

### **Papillary Syringadenoma of the Lower Lip**

Papillary syringadenoma, or syringocystadenoma papilliferum, is a benign tumor of sweat glands. The tumor usually appears at birth or in early life and is more frequently located on the scalp and neck and occasionally on the face. Clinically, it is characterized by a solitary well-defined plaque or nodule with a corrugated, slightly depressed surface. The size varies from 0.5 to 1.5 cm. The lips are an uncommon location of papillary syringadenoma, and sporadic cases have been recorded (Fig. 522).

The differential diagnosis includes basal cell carcinoma, squamous cell carcinoma, keratoacanthoma, and other skin tumors.

**Laboratory test.** Histopathologic examination establishes the diagnosis.

Treatment is surgical excision.

### **Sebaceous Adenoma**

Sebaceous adenoma is a rare benign tumor of skin originating from the sebaceous glands. The tumor usually occurs as a solitary lesion on the face or scalp of elderly patients. Sebaceous adenoma of the oral mucosa is extremely rare and it is believed to originate from Fordyce's granules. Clinically, the lesion appears as a solitary, well-defined, round, firm mass 0.5 to 1 cm in diameter (Fig. 523). The color is yellowish and the surface smooth or slightly granular.

The differential diagnosis includes lipoma, verruciform xanthoma, myxoma, and fibroma.

**Laboratory test.** Histopathologic examination establishes the diagnosis.

Treatment is surgical excision.

### **Cutaneous Horn**

Cutaneous horn is a clinical descriptive term representing a prominent conical projection of cohesive keratinized material, which usually occurs in elderly patients. The lesion forms from cutaneous keratotic changes, such as seborrhoeic keratosis, actinic keratosis, actinic cheilitis, warts, basal cell carcinoma, keratoacanthoma, squamous cell carcinoma, lupus erythematosus, etc.

Clinically, cutaneous horns present as hard yellowish or whitish-brown straight or curved horn projections varying in size from a few millimeters to several centimeters. The upper part of the face is the most common site of involvement, although rarely cutaneous horns may be seen on the lower lip (Fig. 524). Hyperkeratotic hornlike overgrowth (mucosal horn) whitish in color may very rarely occur on the glans penis and intraorally (Fig. 525).

The differential diagnosis includes verruca vulgaris, papilloma, and squamous cell carcinoma.

**Laboratory test** to confirm the diagnosis is histopathologic examination.

Treatment is surgical removal.

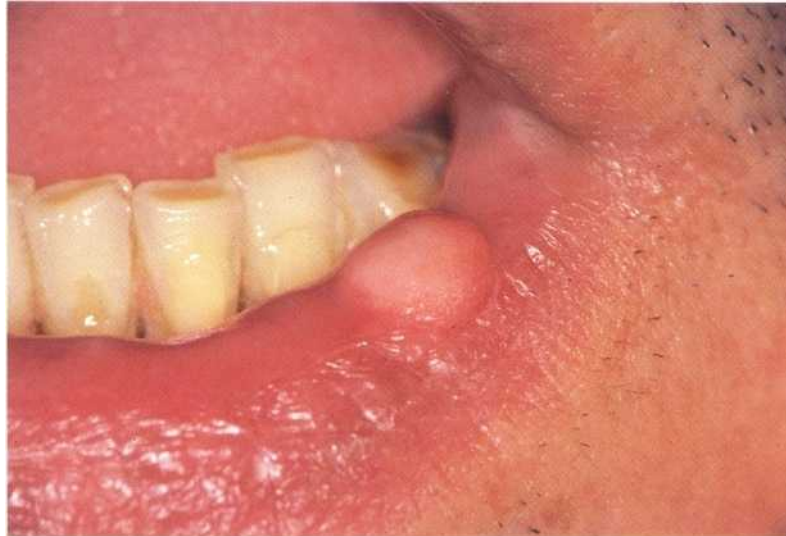

Fig. 523. Sebaceous adenoma of the lower lip.

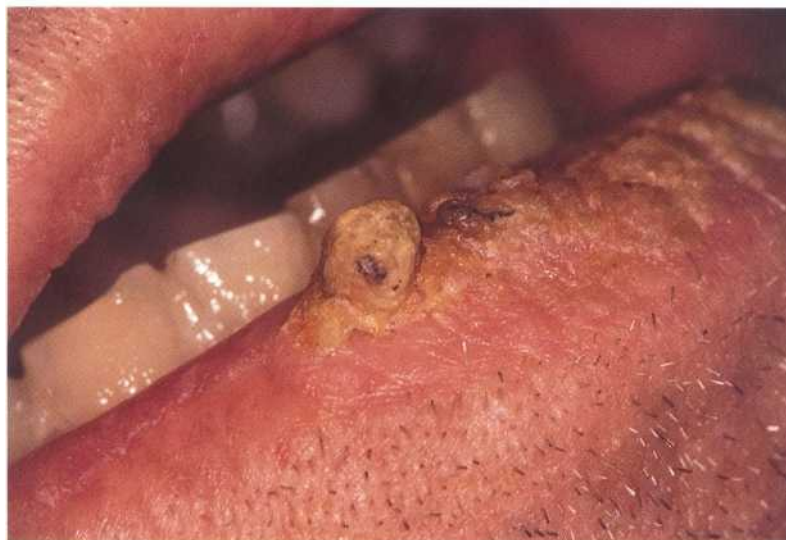

Fig. 524. Cutaneous horn of the lower lip.

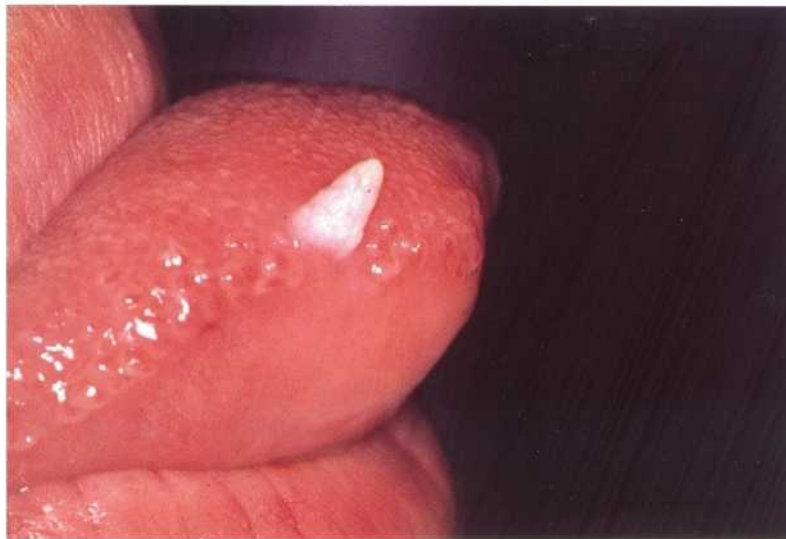

Fig. 525. Mucosal horn on the tongue.

### Freckles

Freckles are discrete brown macules, less than 0.5 cm in diameter, which are due to increased melanin production, whereas the number of epidermal melanocytes is usually normal. They appear during the first 3 years of life exclusively on sun-exposed skin. Rarely, freckles may appear on the vermilion border of the lips (Fig. 526), but the oral mucosa is not affected.

The differential diagnosis includes cellular nevi, lentigo, Peutz-Jeghers syndrome, neurofibromatosis, Albright's syndrome, and other genodermatoses associated with pigmentation.

**Laboratory test.** Histopathologic examination establishes the diagnosis.

**Treatment.** No treatment is required.

### Lentigo Simplex

Lentigo is a circumscribed brown spot of unknown cause that is due to an increased number of epidermal melanocytes. Lentigo is classified into three varieties: lentigo simplex, lentigo solar, and lentigo maligna. Lentigo simplex mainly appears on the skin, nail beds, and rarely on the oral mucosa. It is not related to sun exposure and it appears usually during childhood. Clinically, it presents as small (less than 0.5 cm in diameter), round flat spots of brown or dark brown color (Fig. 527).

The differential diagnosis includes cellular nevi, Peutz-Jeghers syndrome, and freckles.

**Laboratory test.** The diagnosis is established by histopathologic examination.

**Treatment.** No treatment is required.

### Intramucosal Nevus

Pigmented cellular nevi are developmental malformations originating from defective melanoblasts of the neural crest. They usually occur in the skin and rarely in the oral mucosa. They are collections of nevus cells in the epidermis, dermis, or both. There are two main varieties of nevi: congenital and acquired. Based on histologic criteria (location of nevus cells and the presence or absence of junctional activity), acquired nevi may be divided into many categories. In the oral mucosa four types have been described: the intramucosal, junctional, compound, and blue. The intramucosal nevus is more common, representing 55% of the oral nevi. It consists of a number of nevus cells that are embedded in the connective tissue and are separated from the epithelium by a band of collagen. It is more common in females and may be found at any age. Clinically, it is an asymptomatic, flat, or slightly elevated spot or plaque of brown or brown-black color (Fig. 528). It is usually located on the palate and buccal mucosa and rarely on the gingiva and the lips. Intramucosal nevi have little capacity for malignant transformation.

The differential diagnosis includes other types of oral nevi, freckles, lentigo simplex, amalgam tattoo, hematoma, lentigo maligna, and malignant melanoma.

**Laboratory test.** The diagnosis is established by histopathologic examination.

**Treatment.** Usually no treatment is required. However, surgical excision is recommended when the nevus is located at a site of chronic irritation or exhibits any change in its appearance.

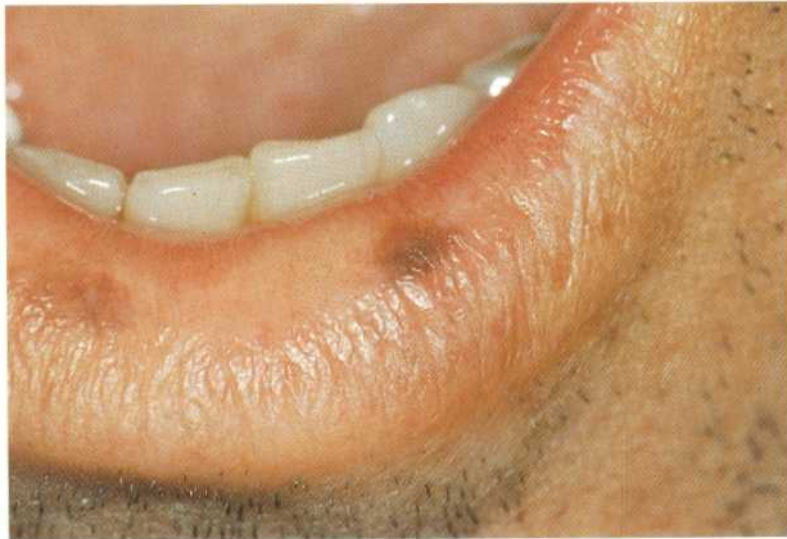


Fig. 526. Freckles on the vermilion border of the lower lip.

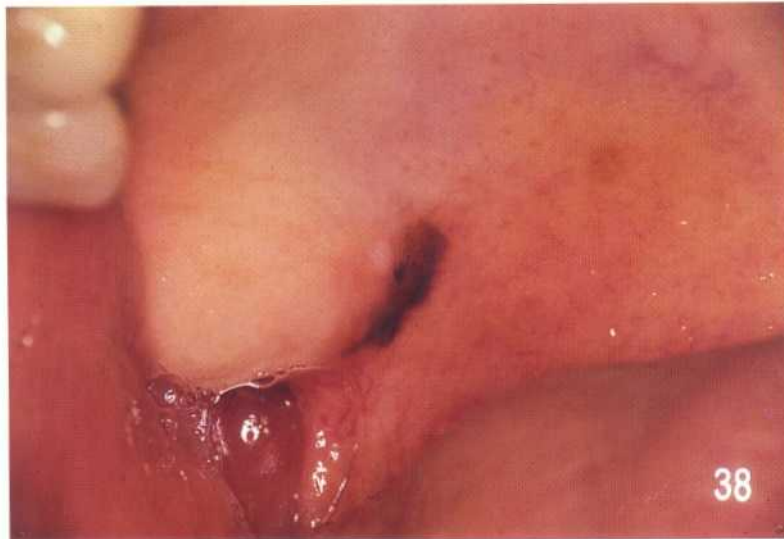

Fig. 527. Lentigo of the palate.

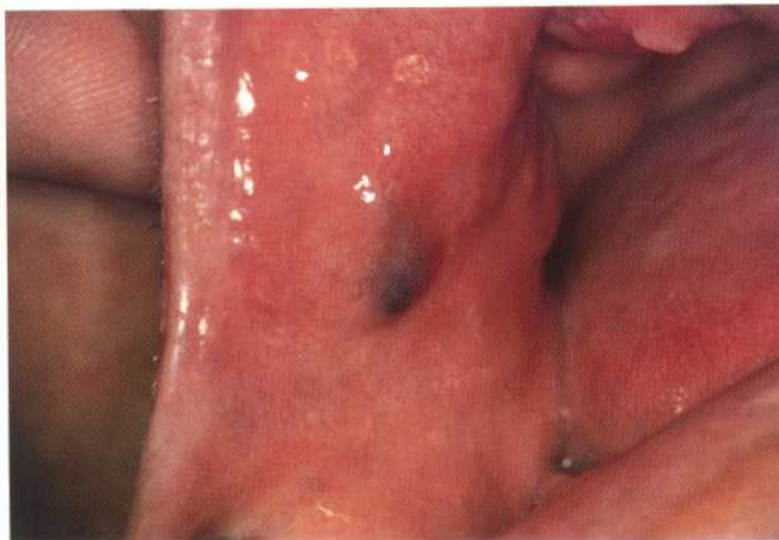

Fig. 528. Intramucosal nevus of the buccal mucosa.

### Junctional Nevus

Junctional nevus is the least frequent of oral nevi, accounting for about 3 to 5.5% of the cases. Histologically, it is characterized by nests of nevus cells along the basal layer of the epithelium. Some of these cells drop off into the underlying connective tissue, showing junctional activity. The clinical features of junctional nevus are not pathognomonic. They appear typically as asymptomatic black or brown flat or slightly elevated spots, which have a diameter of 0.1 to 0.5 cm (Fig. 529). It is found more often on the palate, buccal mucosa, and alveolar mucosa. The junctional nevus has a significant capacity to undergo malignant transformation into melanoma. Clinically, any change in color, size, and texture of an oral nevus should be regarded with suspicion and the possibility of malignant melanoma should not be excluded.

The differential diagnosis includes the other types of oral nevi, freckles, lentigo simplex, amalgam tattoo, normal pigmentation, lentigo maligna, and malignant melanoma.

Laboratory test. The diagnosis is made exclusively on histologic criteria.

Treatment is surgical excision.

### Compound Nevus

Compound nevus is characterized by clusters of nevus cells located both in the epithelium and in the underlying connective tissue; therefore it has the characteristics of both intramucosal and junctional nevus. Compound nevus is rare in the oral cavity, representing about 6 to 8.5% of all oral nevi. There is no sex or age predilection. Clinically, it appears as an asymptomatic slightly elevated or flat spot that has red-brown or black-brown color, and the size varies from a few millimeters to 1 cm in diameter (Fig. 530). It is more often located on the buccal mucosa, the palate, and the gingiva. Compound nevi may be transformed into malignant melanoma.

The differential diagnosis should include other oral nevi, lentigo simplex, freckles, lentigo maligna, amalgam tattoo, and malignant melanoma.

Laboratory test. The diagnosis is exclusively made by histologic examination.

Treatment is the same as for intramucosal nevus.

### Blue Nevus

Blue nevus is the second most frequent nevus of the oral mucosa, accounting for 30.5 to 36% of oral nevi. Histologically, it is characterized by the presence of large numbers of elongated, slender, and melanin-containing melanocytes arranged in a pattern parallel to the epithelium, in the middle and lower parts of the lamina propria. Junctional activity is absent. Two types of blue nevus are recognized: the common type, which appears in the oral mucosa and skin, and the cellular type, which occurs only on the skin. There is no sex predilection, and it is found at any age. Clinically, it appears as an asymptomatic, slightly elevated or flat spot or plaque, of oval or irregular shape brown or blue in color (Fig. 531). It is frequently located on the hard palate (60%) and rarely in other areas. Malignant transformation of oral common blue nevus has not been recorded.

The differential diagnosis should include other oral nevi, lentigo simplex, lentigo maligna, freckles, amalgam tattoo, hemangioma, pyogenic granuloma, and malignant melanoma.

Laboratory test. The diagnosis is established by histologic examination.

Treatment is the same as for intramucosal nevus.

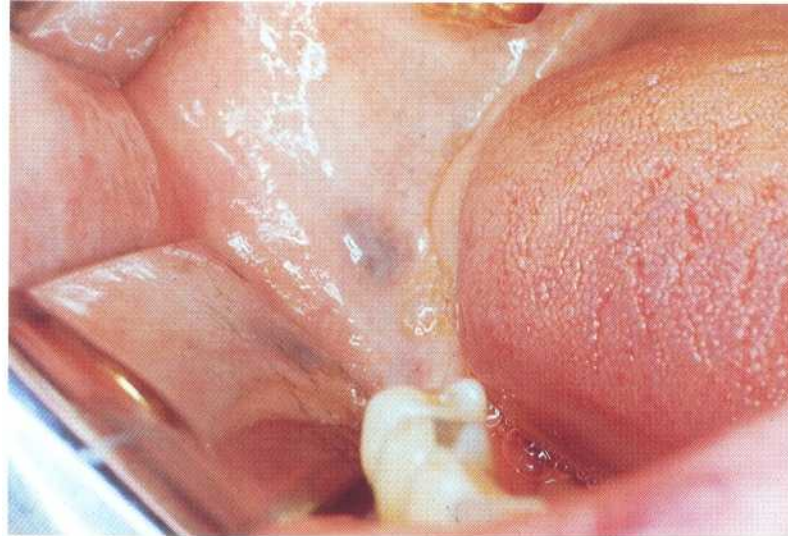


Fig. 529. Junctional nevus of the retromolar area.

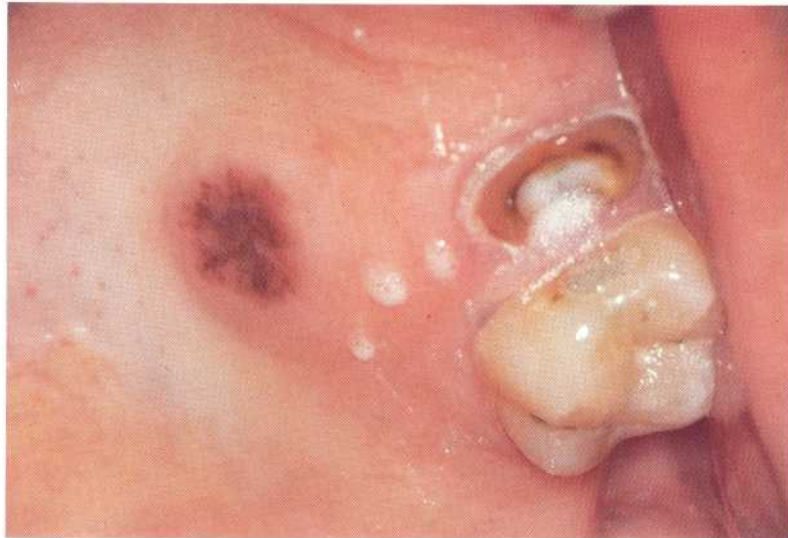

Fig. 530. Compound nevus of the palate.

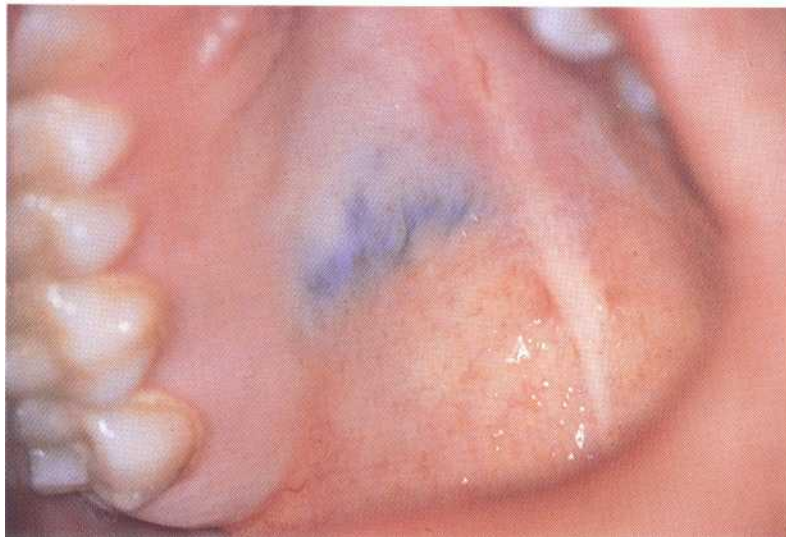
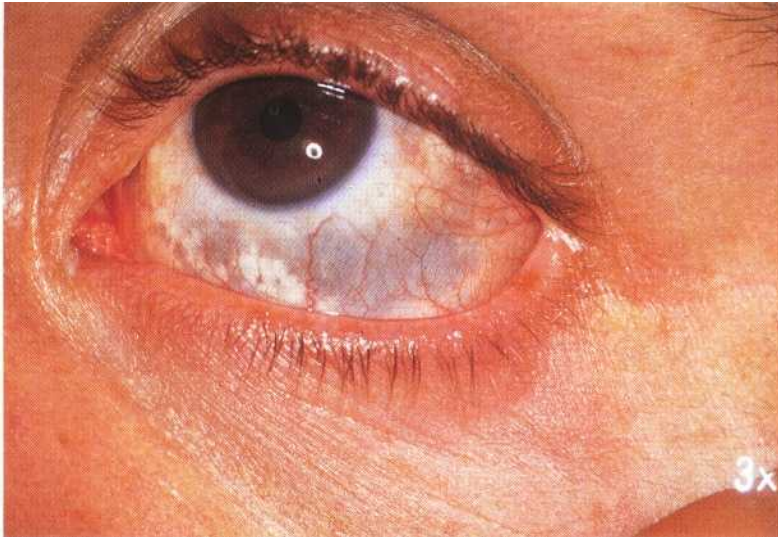
Fig. 531. Blue nevus of the palate.





**Fig. 532. Nevus of Ota, ocular melanosis.**

### Nevus of Ota

Nevus of Ota, or oculodermal melanocytosis, is an acquired blue or brown-gray macule characteristically involving the skin of the face, eyes, and mucous membranes, which are innervated by the first and second branches of the trigeminal nerve. The pathogenesis and the histologic pattern is the same as in blue nevus. It is very common in Japanese and rare in other races. Usually, it appears in early childhood or in young adults and is more frequent in females than males (ratio 5:1). The hyperpigmentation is typically located on the skin of the face and the eyes (cornea, iris, optic nerve, and fundus) (Fig. 532). Other areas of involvement are the hard palate, buccal mucosa, nasal mucosa, and pharynx (Fig. 533). The lesions are usually unilateral although bilateral involvement may also occur. Clinically, the pigmentation appears as mottled macules of blue, blue-black, brown or brownish gray color. The nevus of Ota rarely undergoes malignant transformation.

The differential diagnosis of oral lesions includes blue nevus and other oral nevi, amalgam tattoo, hematoma, lentigo maligna, and malignant melanoma.

**Laboratory test.** The diagnosis is established by the histologic examination.

**Treatment.** No treatment is needed.

### Lentigo Maligna

Lentigo maligna, or melanotic freckle of Hutchinson, is a premalignant lesion of melanocytes. It is thought to be a unique variety of intraepidermal melanocytic dysplasia, which has the capacity to progress to melanoma in situ or invasive melanoma after 5 to 20 years. Lentigo maligna usually occurs on sun-damaged skin (frequently the face) of patients older than 50 years and has no sex predilection. Clinically, it begins as a small, well-defined brown, smooth macule that increases slowly in size and becomes more pigmented and irregularly outlined. The size varies from 0.5 to 3 cm or more.

Lentigo maligna is extremely rare in the oral mucosa, but it may appear as a pigmented plaque with irregular periphery and a very slowly growing margin on the buccal mucosa, palate, floor of the mouth, and lower lip (Figs. 534, 535).

The differential diagnosis should include oral nevi, amalgam tattoo, and malignant melanoma.

**Laboratory test.** The diagnosis is established by histologic examination.

**Treatment.** Surgical excision or radiation is the most reliable method. However, topical 5-fluorouracil, cryotherapy, dermabrasion, and laser have also been used.

Fig. 533. Nevus of Ota, pigmented spots on the palate.

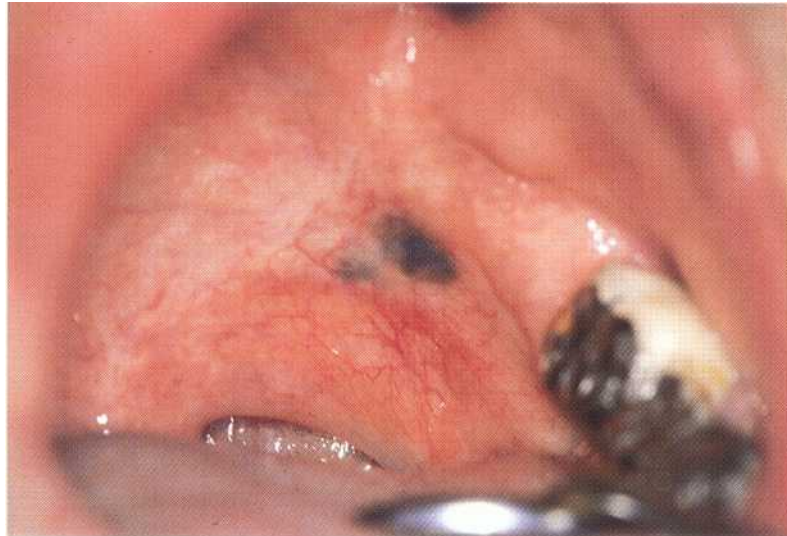

Fig. 534. Lentigo maligna on the buccal mucosa, commissure, and lower lip.

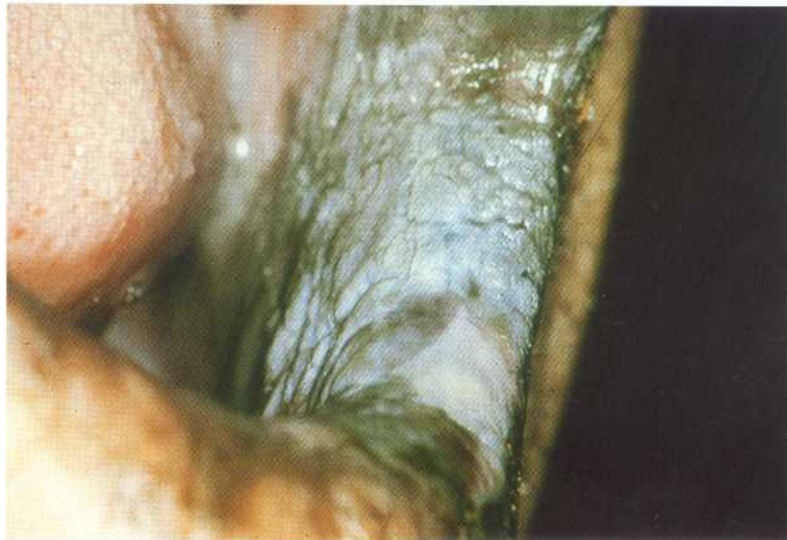
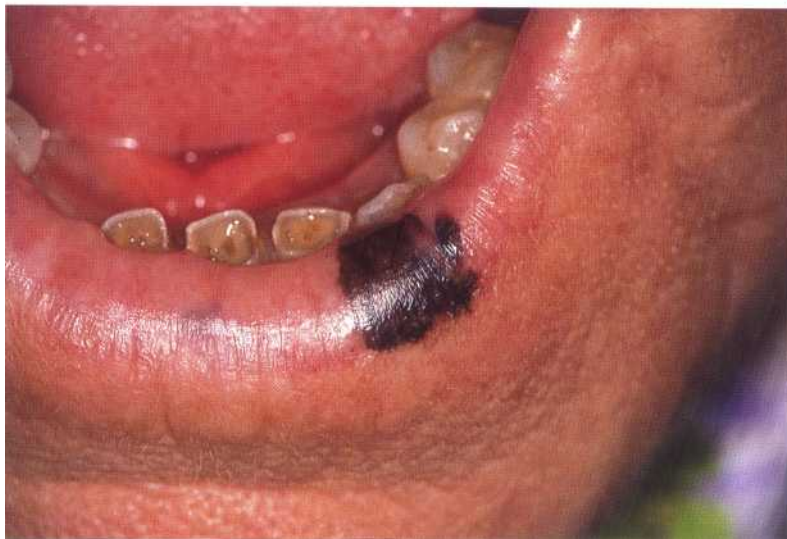
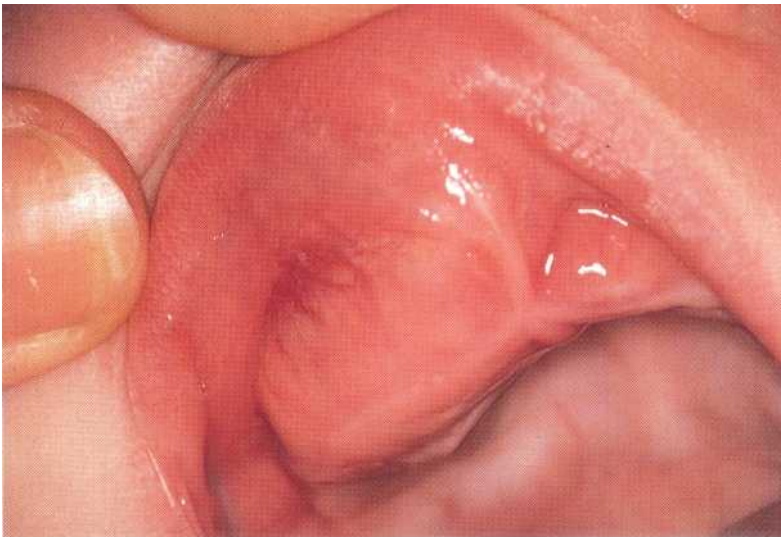
Fig. 535. Lentigo maligna on the vermillion border of the lower lip.





**Fig. 536.** Melanotic neuroectodermal tumor of infancy in the maxilla.

### Melanotic Neuroectodermal Tumor of Infancy

Melanotic neuroectodermal tumor of infancy is a rare benign tumor of neural crest origin with a propensity to appear in tooth-bearing areas. It appears only in infants less than 6 months of age and shows no sex predilection. It occurs mostly in the maxilla (79.1%), but a few cases have also been reported in the skull, mandible, shoulder region, skin, mediastinum, brain, epididymis, uterus, etc. Clinically, it is a rapidly growing, painless tumor covered by normal epithelium of redbrown or normal color, and of elastic consistency (Fig. 536). The tumor may cause bone resorption and this, together with the rapid development, mimics a malignant tumor.

The differential diagnosis includes congenital epulis of the newborn, malignant melanoma, schwannoma, neuroblastoma, odontogenic tumors, and sarcomas.

Laboratory tests. The diagnosis is established by histologic examination, but radiographs and the detection of vanillylmandelic acid in the urine are also helpful.

Treatment is surgical excision.

### Pleomorphic Adenoma

Pleomorphic adenoma is the most common benign neoplasm of the major and minor salivary glands. It represents 62.6 to 75.6% of all tumors of major salivary glands and 42.6 to 70% of all minor salivary gland tumors. The posterior part of the palate is the usual intraoral site of involvement, followed by the upper lip, retromolar area, buccal mucosa, and tongue (Figs. 537, 538). About 90% of the cases of major salivary gland tumors occur in the parotid gland (Fig. 539). Pleomorphic adenoma has no significant sex predilection and occurs more often between 40 and 70 years of age. When located in the minor salivary glands, it is an asymptomatic slow-growing firm swelling, with a size of 2 to 3 cm in diameter. The tumor is covered by normal epithelium and is rarely ulcerated. It may cause difficulties in chewing, speech, and fitting a denture.

The differential diagnosis includes other salivary gland tumors, lipoma, and necrotizing sialometaplasia.

Laboratory test. The diagnosis is made by histologic examination.

Treatment is surgical excision.

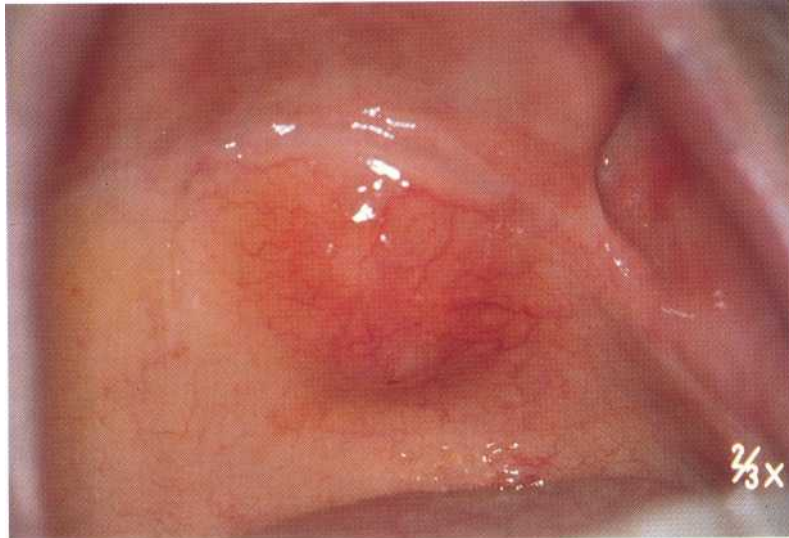

Fig. 537. Pleomorphic adenoma of the palate.

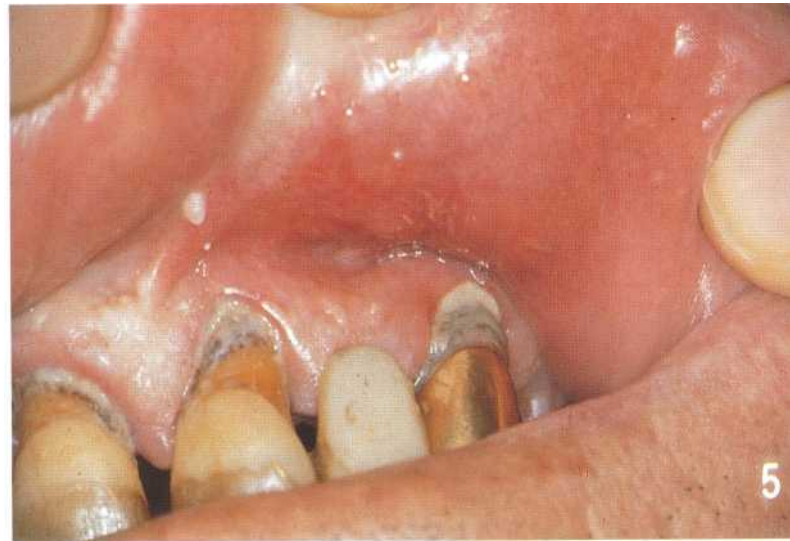

Fig. 538. Pleomorphic adenoma of the upper labial mucosa.

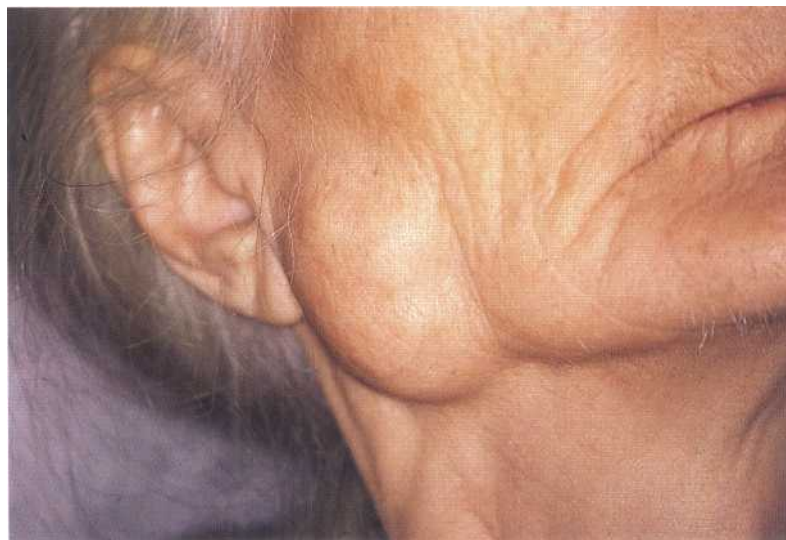
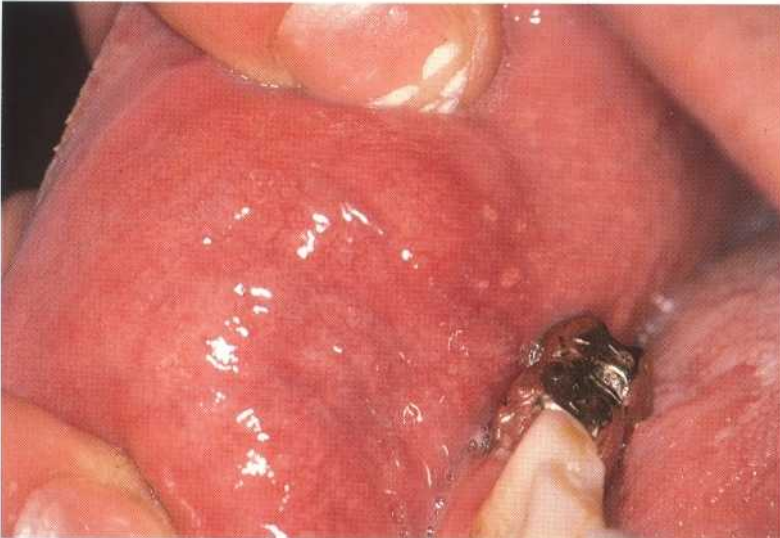
Fig. 539. Pleomorphic adenoma of the parotid gland.



**Fig. 540. Papillary cystadenoma lymphomatosum of the buccal mucosa.**

### **Papillary Cystadenoma Lymphomatosum**

Papillary cystadenoma lymphomatosum, or adenolymphoma or Warthin's tumor, is a rare benign tumor of the salivary glands, almost always located in the parotid gland. However, it is occasionally observed in the submandibular gland and the intraoral minor salivary glands. The tumor is more frequent in men than women of 40 to 70 years of age, and the most common intraoral location is the palate and the lips. Clinically, it is a painless, slow-growing, firm, superficial swelling, with size that varies from 1 to 4 cm in diameter (Fig. 540).

The differential diagnosis includes other benign and malignant salivary gland tumors, mucocele, branchial cyst, and tuberculous lymphadenopathy.

**Laboratory test.** The diagnosis is made by histologic examination.

**Treatment** is surgical excision.

## 34. Other Salivary Gland Disorders

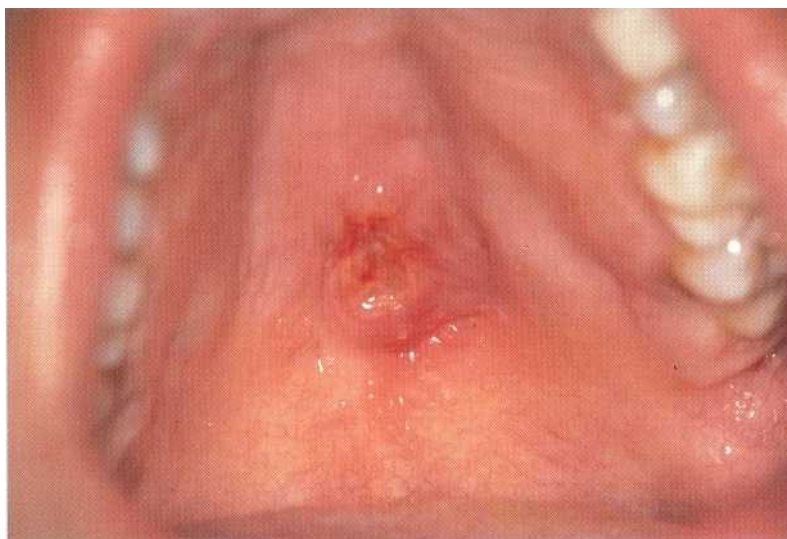
### Necrotizing Sialometaplasia

Necrotizing sialometaplasia is an inflammatory benign, usually self-limiting, lesion of the salivary glands. It is more common in men than women and is usually seen in the fourth to fifth decades of life. In the great majority of the cases the lesion is located on the posterior part of the hard palate, but isolated cases have been described on the lower lip, buccal mucosa, retromolar pad, parotid gland, and extraorally. The cause of the lesion is unknown, although the theory of ischemic necrosis after vascular infarction seems acceptable. The lesion has a sudden onset and clinically may present as a nodular swelling that later leads to a painful craterlike ulcer with irregular and ragged border (Fig. 541).

The differential diagnosis includes mucoepidermoid carcinoma, other malignant salivary gland tumors, squamous cell carcinoma, lethal midline granuloma, traumatic ulcer, and pleomorphic adenoma.

Laboratory test to establish the diagnosis is histopathologic examination.

Treatment. The lesion generally heals spontaneously without treatment within 4 to 10 weeks.



**Fig. 541.** Necrotizing sialometaplasia on the palate.

### Sialolithiasis

Sialoliths are calcareous deposits in the ducts or the parenchyma of salivary glands. The submandibular gland sialoliths are the most common (about 80%), followed by parotid gland, sublingual glands, and minor salivary glands.

When sialoliths increase in size, they may produce partial or complete obstruction of the duct, leading to a sialadenitis. Clinically, it presents as a painful swelling of the gland, especially during a meal. When the sialolith is located at the peripheral part of the duct, inflammation occurs. If the calculus is large, it is palpable and occasionally can be seen at the duct orifice (Fig. 542).

The differential diagnosis includes infectious sialadenitis.

**Laboratory test.** Radiographic examination is important for the diagnosis.

**Treatment.** In the acute phase antibiotics and then surgical removal.

### Mikulicz's Syndrome

Mikulicz's syndrome is characterized by symmetrical painless swelling of the major salivary glands, frequently followed by swelling of the lymph nodes (Fig. 543). It is usually present in association with systemic diseases, such as tuberculosis, sarcoidosis, lymphoma, and leukemia. Therefore the meaning of the syndrome is theoretical and the diagnosis of the underlying disease has to be established.

The differential diagnosis includes Sjogren's syndrome, Heerfordt's syndrome, salivary gland swelling due to drugs, and nutritional and metabolic disorders.

**Treatment.** The treatment consists of cure of the underlying disease.

### Sialadenosis

Sialadenosis is a rare noninflammatory, nonneoplastic enlargement of the parotid and rarely the submandibular glands. The exact etiology remains unknown but the disorder has been found in association with liver cirrhosis, diabetes mellitus, chronic alcoholism, malnutrition, and thyroid and ovarian insufficiencies. Clinically, it presents as a bilateral painless swelling of the parotids that usually recurs (Fig. 544). The swelling is relatively soft, and diminishing salivary secretion may occur.

The differential diagnosis includes Sjogren's, Mikulicz's and Heerfordt's syndromes, recurrent infectious sialadenitis, and salivary gland tumors.

Laboratory test to establish the diagnosis is histopathologic examination.

Treatment is symptomatic. The therapy of the related disease may improve the salivary gland enlargement.

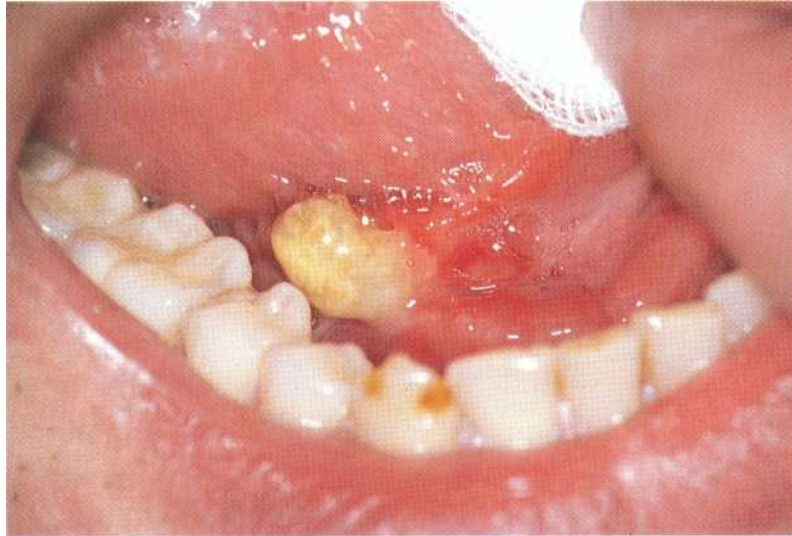

Fig. 542. Sialolith at the duct orifice of the submandibular gland.

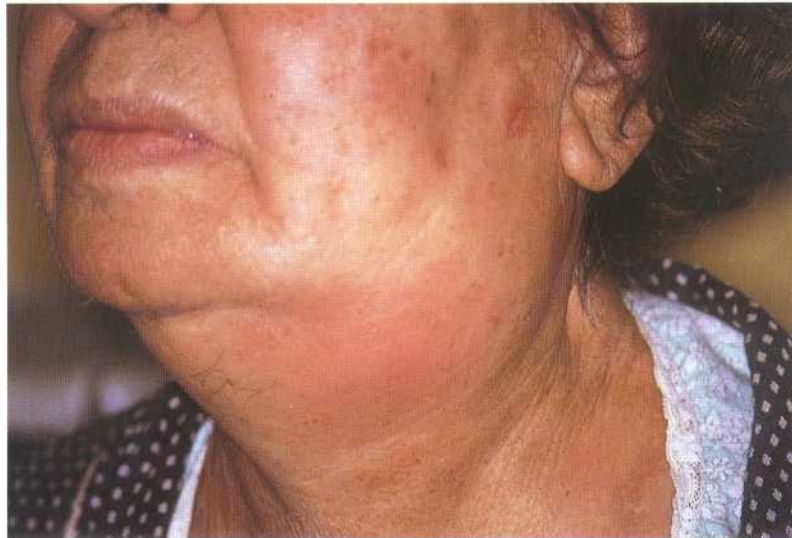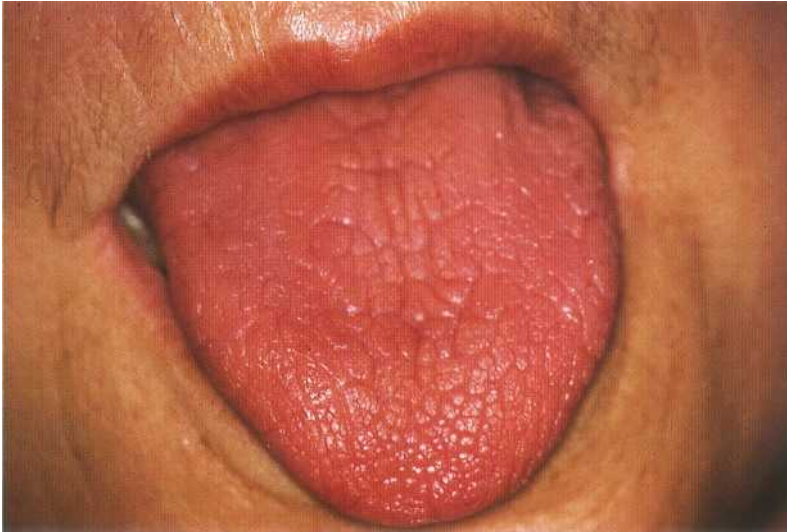


Fig. 543. Mikulicz's syndrome, swelling of the major salivary glands.

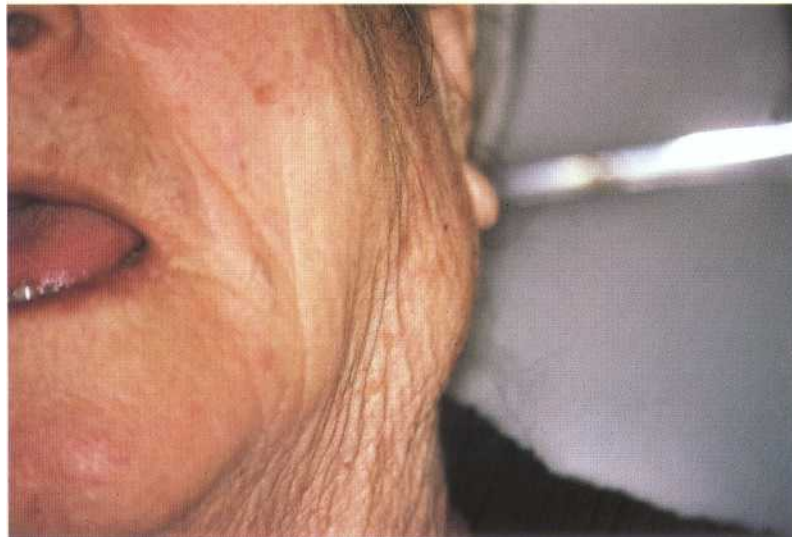

Fig. 544. Sialadenosis, swelling of the parotid gland.





**Fig. 545. Dry and red tongue in a woman with severe xerostomia.**

### Xerostomia

Xerostomia is not a nosologic entity, but a symptom caused by a decreased or total absence of salivary secretions. Xerostomia has a multifactorial cause and may be transient or permanent. The most common causes of xerostomia are drugs (such as anxiolytic, antihypertensive, sympathomimetic, parasympathetic blocking), congenital anomalies of salivary glands, systemic diseases (such as Sjogren's syndrome, diabetes mellitus and diabetes insipidus, dehydration, iron-deficiency anemia, protein deficiency), radiation, decreased peripheral stimulus, emotional stress and neurologic diseases, menopause, and aging. Clinically, the oral mucosa is dry, red, cracked, and the epithelium becomes atrophic (Fig. 545). The patients usually complain of glossopyrosis and change of taste. Oral candidosis and increased caries are common complications. In addition, difficulties of mastication, swallowing, and speech may also occur.

Laboratory test to determine xerostomia are the salivary flow rate, sialography, histopathologic examination, scanning, and serologic tests.

Treatment depends on the cause of xerostomia. Synthetic saliva may be helpful. Pilocarpine and an etholetrithione have been used to stimulate salivary gland secretion.

## 35. Tumor-like Lesions

### Pyogenic Granuloma

Pyogenic granuloma is a common granulation tissue overgrowth in reaction to mild irritation. It has a higher incidence in females (ratio 2:1) and occurs at any age, although about 60% of the patients are between 11 and 40 years of age. Clinically, pyogenic granuloma appears as a painless exophytic, nodular mass that is pedunculated or sessile with a deep red color. The surface may be smooth or lobulated, often ulcerated, and it is covered by a white-yellowish membrane. The lesion is soft and has a tendency to hemorrhage spontaneously or after slight irritation. It grows rapidly and its size usually ranges between 0.5 and 1 cm. The gingiva is the most common site of involvement (about 70%), followed by the tongue, lips, buccal mucosa, palate, etc. (Figs. 546-548).

The differential diagnosis includes peripheral giant cell granuloma, peripheral ossifying fibroma, leiomyoma, hemangioma, hemangioendothelioma, hemangiopericytoma, bacillary angiomatosis, Kaposi's sarcoma, and metastatic tumors.

Laboratory test. Histopathologic examination is helpful.

Treatment. Surgical excision.

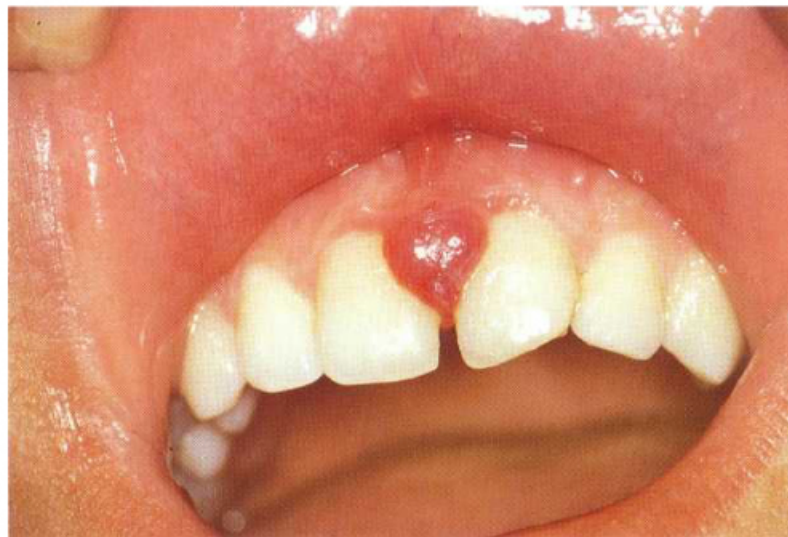
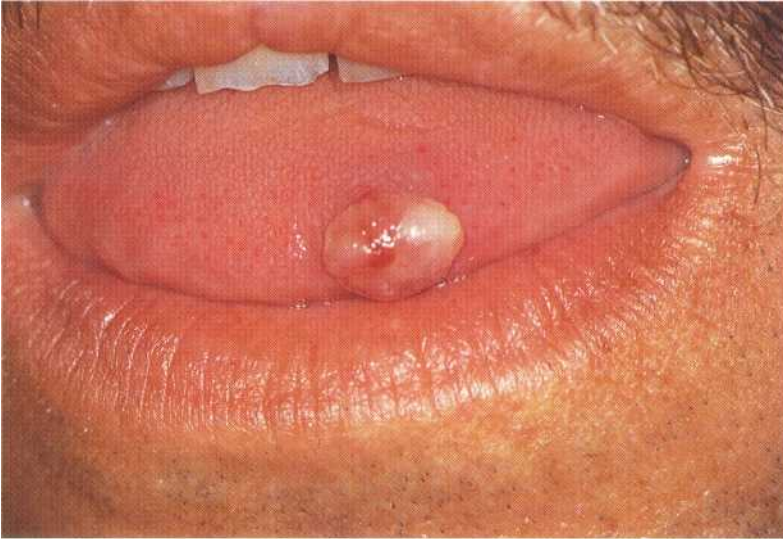
Fig. 546. Pyogenic granuloma of the gingiva.



**Fig. 547. Pyogenic granuloma on the tip of the tongue.**

### **Pregnancy Granuloma**

Pregnancy granuloma occurs during pregnancy and is clinically and histopathologically identical to pyogenic granuloma. It is usually located on the gingiva and appears after the first trimester. Clinically, it appears as a single pedunculated mass with a smooth surface and red color (Fig. 549). Rarely, there is more than one lesion on the gingiva. After delivery, the tumor may regress and sometimes it disappears.

The differential diagnosis includes pyogenic granuloma and peripheral giant cell granuloma.

**Laboratory test.** Histopathologic examination helps to establish the diagnosis.

**Treatment.** Surgical excision preferably postpartum if the granuloma persists. During pregnancy, it can be removed under local anesthesia if it causes discomfort.

### **Postextraction Granuloma**

Postextraction granuloma, or epulis granulomatosa, is a pyogenic granuloma that characteristically appears in the tooth socket after tooth extraction (Fig. 550). The cause is usually the presence of a foreign body, such as bone sequestrum, amalgam remnants, with subsequent reactive inflammatory tissue formation.

**Treatment.** Surgical removal.

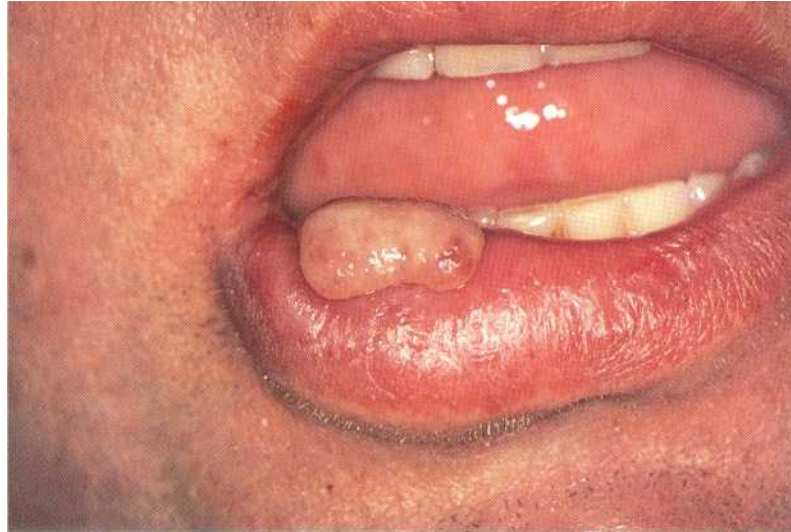

Fig. 548. Pyogenic granuloma on the vermillion border of the lip.

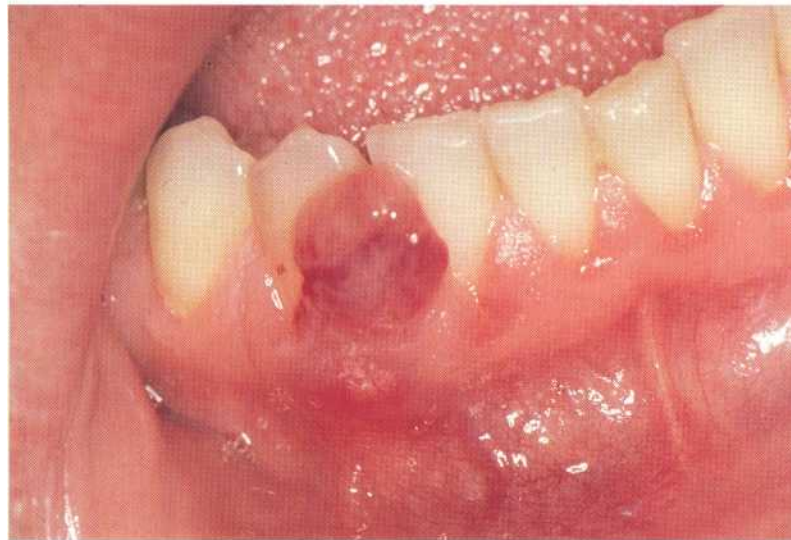


Fig. 549. Pregnancy granuloma of the gingiva.

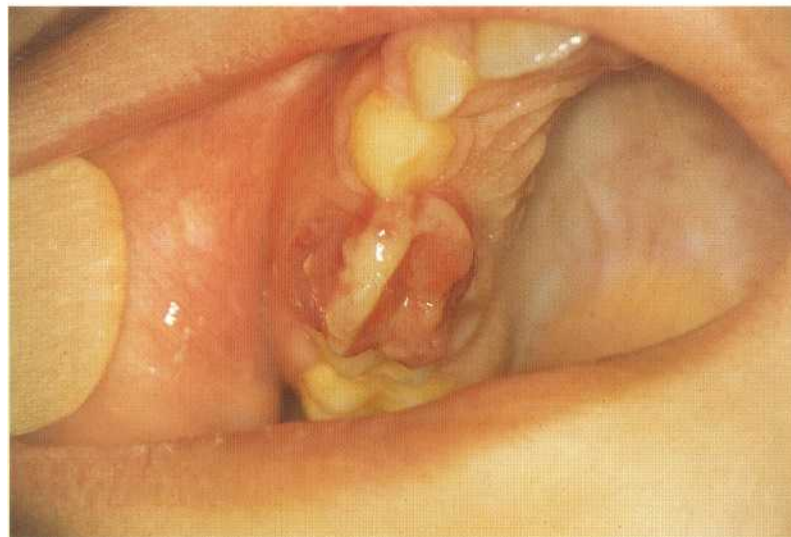
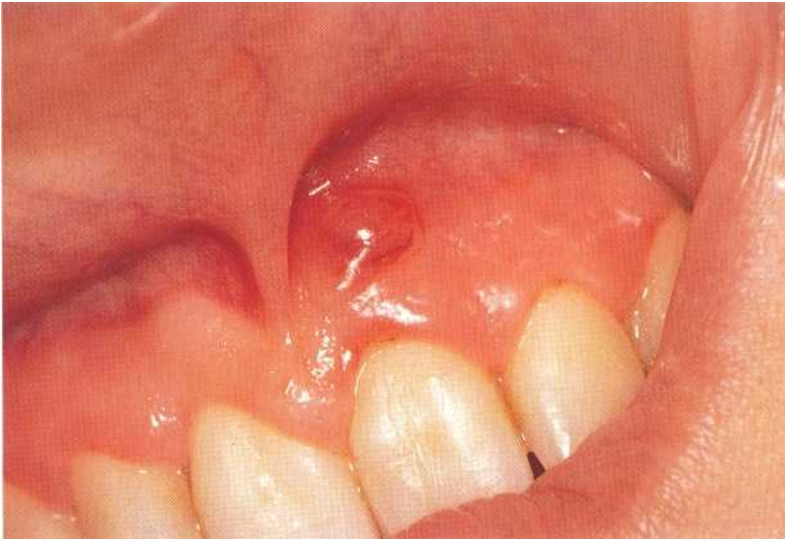
Fig. 550. Postextraction granuloma in the tooth socket after tooth extraction.



**Fig. 551.** Fistula granuloma at the opening of the duct of a dental fistula.

### **Fistula Granuloma**

Fistula granuloma is a pyogenic granuloma that is characteristically found at the opening of the duct of a dental or periodontal fistula (Figs. 551, 552).

### **Peripheral Giant Cell Granuloma**

Peripheral giant cell granuloma is a tumor with characteristic clinical and histopathologic features, which is exclusively found on the gingival region of both jaws. It is not a true neoplasm, but a tissue reaction to local irritation occurring during mixed dentition. Before the 16th year of age, it is more common in males, although after the 16th year of age, it is twice as common in females.

Clinically, it appears as a well-circumscribed pedunculated or sessile tumor of dark red color that is hemorrhagic and often ulcerated (Fig. 553). Its consistency is elastic and the size ranges between 0.5 and 2 cm in diameter. It usually appears on the gingiva, but it can also be found at an edentulous area (Fig. 554).

The differential diagnosis includes pyogenic granuloma, postextraction granuloma, peripheral ossifying fibroma, hemangiopericytoma, hemangioendothelioma, and Kaposi's sarcoma.

Laboratory test helpful for diagnosis is histopathologic examination.

Treatment. Surgical excision.

Fig. 552. Fistula granuloma at the opening of the duct of a periodontal fistula.

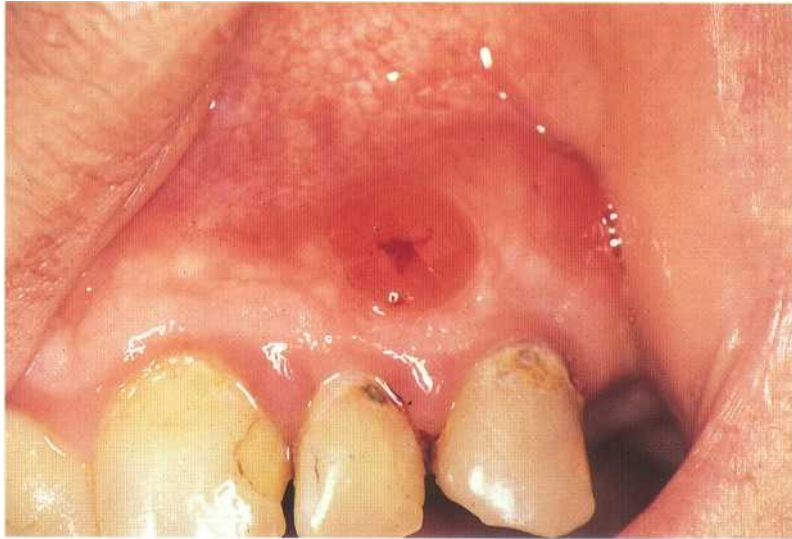

Fig. 553. Peripheral giant cell granuloma of the maxilla.

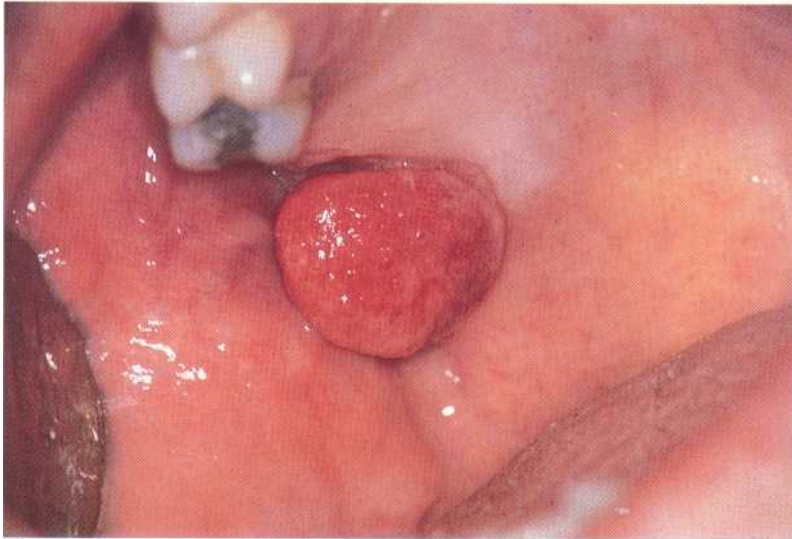
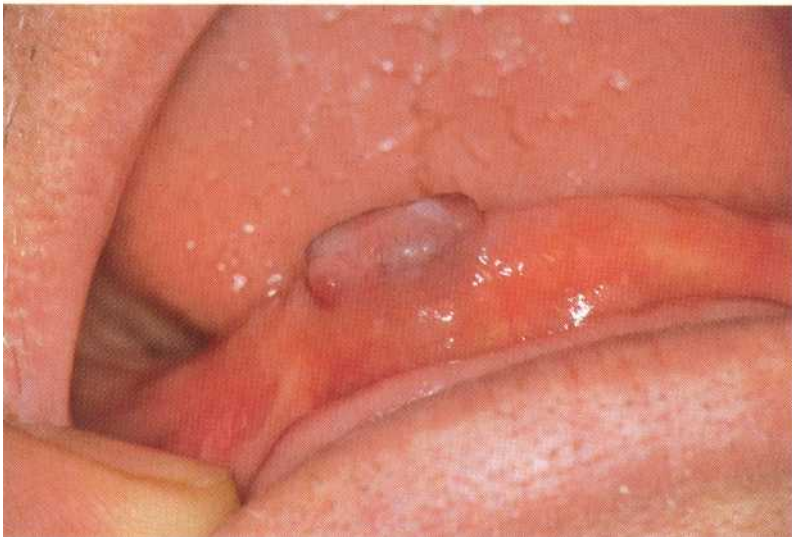
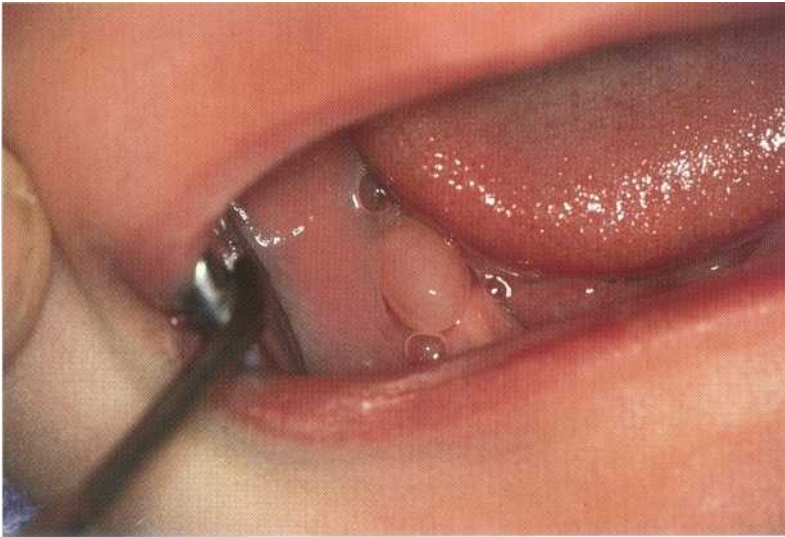
Fig. 554. Peripheral giant cell granuloma of the mandible.





**Fig. 555. Congenital epulis of the newborn.**

### **Congenital Epulis of the Newborn**

Congenital epulis of the newborn is a rare non-neoplastic reactive or degenerative lesion probably arising from mesenchymal cells. It appears in newborn infants, exclusively on the alveolar ridges of the maxilla and mandible. The lesion develops commonly on the maxilla and occurs about ten times more frequently in female than male babies. Clinically, it is present at birth, and it appears as an asymptomatic solitary pedunculated tumor of red or normal color, which ranges from a few millimeters to a few centimeters in diameter (Fig. 555).

The differential diagnosis includes the melanotic neuroectodermal tumor of infancy, pyogenic granuloma, and fibroma.

**Laboratory test.** Histopathologic examination is essential for the diagnosis.

**Treatment.** Surgical excision, although spontaneous regression has been reported.

## Selected Bibliography

### 1. Normal Anatomic Variants

- Bouquot JE, Gorlin RJ: Leukoplakia, lichen planus, and other oral keratoses in 23,616 white Americans over the age of 35 years. *Oral Surg* 61:373, 1986.
- Buchner A, Hansen LS: Melanotic macule of the oral mucosa. A clinicopathologic study of 105 cases. *Oral Surg* 48:244, 1979.
- Dummett CO, Barends G: Pigmentation of the oral tissues: a review of the literature. *J. Periodontol* 38:360, 1967.
- Kaugars GE, Heise AP, Riley WT, et al: Oral melanotic macules: a review of 353 cases. *Oral Surg* 76:59, 1993.
- Patsakas A, Demetriou N, Angelopoulos A: Melanin pigmentation and inflammation in human gingiva. *J. Periodontol* 52:701, 1981.
- Roed-Petersen B, Pindborg JJ: Prevalence of oral leukoedema in Uganda. *Arch. Oral Biol.* 18:1191, 1972.
- WHO: Definition of leukoplakia and related lesions: An aid to studies on oral precancer. *Oral Surg* 45:518, 1978.

### 2. Developmental Anomalies

- Bhatia SN: Genetics of cleft lip and palate. *Br Dent J* 132:95, 1972.
- Bloem JJ, Van Hoof RF: Hypertrophy of the masseter muscle. *Plast Reconstr Surg* 47:138, 1971.
- Daley TD: Pathology of intraoral sebaceous glands. *J Oral Pathol Med* 22:241, 1993.
- Dedo MDD: Hemifacial atrophy: A review of an unusual craniofacial deformity with a report of a case. *Arch Otolaryngol* 104:538, 1978.
- Foster TD: The effects of hemifacial atrophy on dental growth. *Br Dent J* 146:148, 1979.
- Fraser F, Warburton D: No association of emotional stress or vitamin supplement during pregnancy to cleft lip or palate in man. *Plast Reconstr Surg.* 33:395, 1964.
- Guiducci, AA, Hyman AB: Ectopic sebaceous glands. *Dermatologica* 125:44, 1962.
- Gould AR, Escobar VH: Symmetrical gingival fibromatosis. *Oral Surg* 51:62, 1981.
- Humeniuk HM, Burns RA, Shelley ED, Weaver JR: Oral mucosal hair: An ectodermal anomaly. *J Am Acad Dermatol* 15:1301, 1986.
- King DR, Moore GE: An analysis of torus palatinus in a transatlantic study. *J Oral med* 31:44, 1976.
- Kolas S, Halperin V, Jefferis K, et al: The occurrence of torus palatinus and torus mandibularis in 2,478 dental patients. *Oral Surg* 6:1134, 1953.
- Laskaris G, Hatzidou E, Varelzidis A: Rear **hair on the tip of the tongue.** *J Fur Acad Dermatol Venereol* 3: 1994 (in press).
- Mathewson RJ, Siegel MJ, Me Canna DL: Ankyloglossia: A review of the literature and a case report. *J Dent Child* 33:328, 1966.

- Miles AEW: A hair follicle in human cheek mucosa. *Proc R Soc Med* 53:527, 1960.
- Miles AEW: Sebaceous glands in the lip and cheek mucosa in man. *Br Dent J* 105:235, 1958.
- Natsume, N, Suzuki T, Kawai T: The prevalence of cleft lip and palate in the Japanese: Their birth prevalence in 40,304 infants born during 1982. *Oral Surg* 63:421, 1987.
- Rintala AE: Congenital double lip and Ascher syndrome: 11. Relationship to the lower lip sinus syndrome. *Br J Plast Surg* 34:31, 1981.
- Rintala AE, Lahti AY, Gylling US: Congenital sinuses of **the lower lip in connection with cleft lip and palate.** *Cleft Palate J* 7:336, 1970.
- Rintala AE, Ranta R: Lower lip sinuses: Epidemiology, microforms and transverse sulci. *Br J Plast Surg* 34:26, 1981.
- Roncevic R: Masseter muscle hypertrophy. Aetiology and therapy. *J. Maxillofac Surg* 14:344, 1986.
- Schwartz RA, Tedesco AS, Stern LZ, et al: Myopathy associated with sclerodermal facial hemiatrophy. *Arch Neurol* 38:592, 1981.
- Sewerin I: The sebaceous glands in the vermilion border of the lip and in the oral mucosa of man. *Acta Odontol Scand* 33 (Suppl 68):1, 1975.
- Suzuki M, Sakai T: A familial study of torus palatinus and torus mandibularis. *Am J Phys Anthropol* 18:263, 1960.

### 3. Genetic Diseases

- Alper JC: The genodermatoses and their significance in pediatric dermatology. *Dermatol Clin* 4:45, 1986.
- Anneroth G, Isacson G, Lagerholm B, et al: Pachyonychia congenita. A clinical, histological and microradiographic study with special reference to oral manifestations. *Acta Derm Venereol (Stockh)* 55:387, 1975.
- Austin GB, Novak B: Hereditary hemorrhagic telangiectasia with oral manifestations. *Oral Surg* 51:245, 1981.
- Banoczy J, Sugar L, Frithiof L: White sponge nevus: Leukoedema exfoliativum mucosae oris. A report of forty-five cases. *Swed Dent J* 66:481, 1973.
- Barabas GM: The Ehlers-Danlos syndrome. Abnormalities of the enamel, dentine, cementum and the dental pulp: Histological examination of 13 teeth from 6 patients. *Br Dent J* 126:509, 1969.
- Barabas GM, Barabas AP: The Ehlers-Danlos syndrome. A report of the oral and haematological findings in nine cases. *Br Dent J* 123:473, 1967.
- Bazopoulou E, Laskaris G, Katsabas A, Papanicolaou S: Familial benign acanthosis nigricans with predominant, early oral manifestations. *Clinical Genetics* 40:160, 1991.
- Bergman R, Friedman-Birnbaum R: Papillon-Lefevre syndrome: A study of the long-term clinical course, recurrent pyogenic infections and the effects of etretinate treatment. *Br J Dermatol* 119:731, 1988.



- Biggerstaff RH, Mazaheri M: Oral manifestations of the Ellis-van Greveland syndrome. *J Am Dent Assoc* 77:1090, 1968.
- Botvinick I: Familial benign pemphigus with oral mucous membrane lesions. *Cutis* 12:371, 1973.
- Burdick D, Prior JT: Peutz-Jeghers syndrome: A clinicopathologic study of a large family with a 27-year follow-up. *Cancer* 50:2139, 1982.
- Burge SM: Hailey-Hailey diseases: The clinical features, response to treatment and prognosis. *Br J Dermatol* 126:275, 1992.
- Carney RG Jr: Incontinentia pigmenti: A world statistical analysis. *Arch Dermatol* 112:535, 1976.
- Chapple ILC, Thorpe GHG, Smith JM, et al.: Hypophosphatasia: A family study involving a case diagnosed from gingival crevicular fluid. *J Oral Pathol Med* 21:426, 1992.
- Cohen MM Sr, Cohen MM Jr: The oral manifestations of trisomy G (Down's syndrome). *Birth Defects* 7:241, 1971.
- Dormandy TL: Gastrointestinal polyposis with mucocutaneous pigmentation: Peutz-Jeghers syndrome. *N Engl J Med* 256:1093, 1956.
- Everett FG, Hahn CR: Hereditary hemorrhagic telangiectasia with gingival lesions. Review and case reports. *J Periodontol* 47:295, 1976.
- Fenerly A, Laskaris G: Oral manifestations in Darier's disease. *Hell Stomatol Rev* 28:40, 1984.
- Fine JD, Bauer EA, Briggaman RA, et al: Revised clinical and laboratory criteria for subtypes of inherited epidermolysis bullosa. *J Am Acad Dermatol* 24:119, 1991.
- Freedus MS, Doyle PK: Multiple neurofibromatosis with oral manifestations. *J Oral Surg* 33:360, 1975.
- Gedde-Dahl T: Sixteen types of epidermolysis bullosa. *Acta Derm Venereol [Suppl] (Stockh)* 95:74, 1985.
- Gertzman RG, Clark M, Gaston G: Multiple hamartoma and neoplasia syndrome (Cowden's syndrome). *Oral Surg* 49:314, 1980.
- Gorlin RJ: The oral-facial-digital syndrome, *Cutis* 4:1345, 1968.
- Gorlin R, Cohen M, Levin S: *Syndromes of the Head and Neck*: Oxford University Press, New York-Oxford, 1990.
- Gorlin RJ, Pindborg JJ, Cohen MM: *Syndromes of the Head and Neck*, 2nd ed. McGraw-Hill, New York, 1976.
- Haneke E: The Papillon-Lefevre syndrome: Keratosis palmoplantaris with periodontopathy. *Hum Genet* 15:1, 1979.
- Heinze R: Pemphigus chronicus benignus familiaris (Gougerot-Hailey-Hiley) mit Schleimhautbeteiligung bei einer Diabetikerin. *Dermatol Monatsschr* 165:862, 1979.
- Ida M, Nakamura T, Utsunomiya J: Osteomatous changes and tooth abnormalities found in the jaws of patients with adenomatosis coli. *Oral Surg* 52:2, 1981.
- Jessen RT, van Epps DE, Goodwin JS, Bowerman J: Incontinentia pigmenti and defective neutrophil chemotaxis. *Arch Dermatol* 114:182, 1978.
- Jorgenson RJ, Cocker ME: Variation in the inheritance and expression of gingival fibromatosis. *J Periodontol* 45:472, 1974.
- Kratz CL, Morin CK: Hereditary gingival fibromatosis: A child affected with concurrent abnormalities. *J Pedodontics* 11:187, 1987.
- Laskaris G, Drikos G, Rigopoulos A: Oral-facial-digital syndrome: Report of a case. *Hell Stomatol Rev* 19:35, 1975.
- Laskaris G, Varelzidis A, Avgerinou G: Focal palmoplantar and oral mucosa hyperkeratosis syndrome. *Oral Surg* 50:250, 1980.
- Laskaris G, Skouteris C: Maffucci's syndrome. Report of a case with oral hemangiomas. *Oral Surg* 57:263, 1984.
- Lewis RJ, Ketcham AS: Maffucci's syndrome: Functional and neoplastic significance. *J Bone Joint Surg* 55A:1465, 1973.
- Lygidakis NA, Lindenbaum RH: Oral fibromatosis in tuberous sclerosis. *Oral Surg* 68:725, 1989.
- Lymas MA: Marfan's syndrome in Northern Ireland. *Ann Hum Genet* 22:289, 1958.
- Miescher G: Uber plane Angiome (Naevi Hyperaemici). *Dermatologica* 106:176, 1958.
- Milan PE, Griffin TJ, Shapiro RD: A dentofacial deformity associated with incontinentia pigmenti: Report of a case. *Oral Surg* 70:420, 1990.
- Mlymarczyk G: Enamel pitting: A common symptom of tuberous sclerosis. *Oral Surg* 71:63, 1991.
- Nelson DL, King RA: Ehlers-Danlos syndrome type VIII. *J Am Acad Dermatol* 15:297, 1981.
- Neville BW, Hann J, Narang R, Garen P: Oral neurofibrosarcoma associated with neurofibromatosis type I. *Oral Surg* 72:456, 1991.
- Ogden GR, Chisholm DM, Leigh IM, Lane EB: Cytokeratin profiles in dyskeratosis congenita: An immunocytochemical investigation of lingual hyperkeratosis. *J Oral Pathol Med* 21:353, 1992.
- Orfanos CE, Kurka M, Strunk V: Oral treatment of keratosis follicularis with a new aromatic retinoid. *Arch Dermatol* 114:1211, 1978.
- Paller AS, Fine JD, Kaplan S, Pearson RW: The generalized atrophic benign form of junctional epidermolysis bullosa. *Arch Dermatol* 122:704, 1986.
- Person JR: Incontinentia pigmenti: A failure of immunotolerance? *J Am Acad Dermatol* 113:120, 1985.
- Pindborg JJ, Gorlin RJ: Oral changes in acanthosis nigricans (juvenile type). Survey of the literature and report of a case. *Acta Derm Venereol (Stockh)* 42:63, 1962.
- Pope FM, Komorowska A, Lee KW, et al: Ehlers-Danlos syndrome type I with novel dental features. *J Oral Pathol Med* 21:418, 1992.
- Pyeritz RE: The Marfan syndrome. *Am Fam Physician* 34:83, 1986.
- Rasi HB, Herr BS, Sperer AV: Neurofibromatosis of the tongue. *Plast Reconstr Surg* 35:657, 1965.
- Riccardi VM: Von Recklinghausen's neurofibromatosis. *N Engl J Med* 305:1617, 1981.
- Rodu B, Martinez MG: Peutz-Jeghers syndrome and cancer. *Oral Surg* 58:584, 1984.
- Sadeghi EM, Witkop CJ: Ultrastructural study of hereditary benign intraepithelial dyskeratosis. *Oral Surg* 44:567, 1977.
- Sasaki, T, Arai K, Ono M, et al: Ehlers-Danlos syndrome. A variant characterized by the deficiency of pro- $\alpha$ 2 chain of type I procollagen. *Arch Dermatol* 1123:76, 1987.
- Saxen L., Aula S, Westermark T: Periodontal disease associated with Downs syndrome: an orthopantomographic evaluation. *J Periodontol* 48:337, 1977.
- Schonfeld PHIR: The pachyonychia congenita syndrome. *Acta Derm Venereol (Stockh)* 60:45, 1980.
- Schuch, P, Fleischer-Peters A.: Zur Klinik der Dysostosis cleidocranialis. *Z. Kinderheilkd* 98:107, 1967.
- Sciubba JJ, Niebloom T: Juvenile hyaline fibromatosis (Murray-Puetic-Drescher syndrome): Oral and systemic findings in siblings. *Oral Surg* 62:397, 1986.
- Scully C: Orofacial manifestations in tuberous sclerosis. *Oral Surg* 44:706, 1977.
- Steiner M, Gould AR, Graves SM, Kuerschner TW: Klippel-Trenaunay-Weber syndrome. *Oral Surg* 63:208, 1987.
- Stirrups DR, Inglis J: Tuberous sclerosis with nonhydatoid gingival hyperplasia. *Oral Surg* 49:211, 1980.
- Swart JGN, Lekkas C, Allard RHB: Oral manifestations in Cowden's syndrome. *Oral Surg* 59:264, 1985.
- Tagami Y, Akutsu Y, Suzuki M, Takahashi M: Familial benign chronic pemphigus generalized by pseudomonas infection. *J Dermatol* 13:474, 1986.

- Thormann J, Kobayasi T: Pachyonychia congenita Jadassohn-Lewandowsky: A disorder of keratinization. *Acta Derm Venereol*(Stockh)57:63,1977.
- Vassilopoulou A, Laskaris G: Papillon-Lefèvre syndrome: Report of two brothers. *J Dent Child*, September-October:388, 1989.
- Wald C, Diner H: Dyskeratosis congenita with associated periodontal disease. *Oral Surg* 37:736, 1974.
- Wannenmacher MF, Forck G: Mundschleimhautveränderungen beim Sturge-Weber Syndrom. *Dtsch Zahnartzl* 25:1030,1970.
- Witkin JK: Chronic benign familial pemphigus. *Arch Dermatol* 114:136, 1968.
- Witkop CJ, Shenkle CH, Graham JB, et al: Hereditary benign intraepithelial dyskeratosis. 11 Oral manifestations and hereditary transmission. *Arch Pathol*170:696, 1960.
- Wright JT, Fine JD, Johnson LB: Oral soft tissues in hereditary epidermolysis bullosa. *Oral Surg* 71:440, 1991.
- Young NG: Familial white folded dysplasia of the oral mucous membranes. *Br J Oral Surg* 5:93, 1967.
- Zachariades N: Gardner's syndrome: report of a family. *J Maxillofac Surg* 45:438, 1987.

#### 4. Mechanical Injuries

- Bergendal T, Isaccson G: Effect of nystatin in the treatment of denture stomatitis. *Scand J Dent Res*. 88:446, 1980.
- Bergendal T, Isaccson G: A combined clinical, mycological and histological study of denture stomatitis. *Acta Odontol Scand* 41:33,1983.
- Bhaskar SN, Beasley JD, Cutright DE: Inflammatory papillary hyperplasia of the oral mucosa: Report of 341 cases. *J Am Dent Assoc* 81:989, 1970.
- Budtz-Jtbrgensen E.: Oral mucosal lesions associated with the wearing of removable dentures. *J Oral Pathol*110:65,1981.
- Budtz-Jorgensen, E Bertram U: Denture stomatitis. I. The etiology in relation to trauma and infection. *Acta Odontol Scand* 28:71,1970.
- Cutright DE: The histopathologic findings of 583 cases of epulis fissuratum. *Oral Surg* 37:410, 1974.
- Damm DD, White DK, Brinker CM: Variations of palatal erythema secondary to fellatio. *Oral Surg* 52:417, 1981.
- El Mofly SK, Swanson PE, Wick MR, Miller HS: Eosinophilic ulcer of the oral mucosa. *Oral Surg* 75:716, 1993.
- Elzay RP: Traumatic ulcerative granuloma with stromal eosinophilia (Riga-Fede's disease and traumatic eosinophilic granuloma). *Oral Surg* 55:497,1983.
- Giunta J, Tsamsouris A, Cataldo E, et al: Postanesthetic necrotic defect. *Oral Surg* 40:590,1975.
- Guermsey LH: Reactive inflammatory papillary hyperplasia of the palate. *Oral Surg* 26:814, 1965.
- Hartenian KM, Stenger TG: Postanesthetic palatal ulceration. *Oral Surg* 42:447, 1976.
- Iacopino AM, Wathen WF: Oral candidal infection and denture stomatitis: A comprehensive review. *DADA* 123:46, 1992.
- Mader CL: Lingual frenum ulcer resulting from orogenital sex. *J Am Dent Assoc* 103:888, 1981.
- Nordenram A, Landt H: Hyperplasia of the oral tissues in denture cases. *Acta Odontol Scand* 27:481,1969.
- Reichart P, Althoff J: Granular type of denture stomatitis. *Oral Surg* 54:66, 1982.
- Renner, RP, Lee M, Andors L, Me Namara TF: The role of *Candida albicans* in denture stomatitis. *Oral Surg* 47:323, 1979.
- Schlesinger SL, Borbotsina J, O'Neill L: Petechial hemorrhages of the soft palate secondary to fellatio. *Oral Surg* 40:376, 1975.

- Sewerin I: A clinical and epidemiologic study of morsicatio buccarum-labiorum. *Scand J Dent Res* 79:73, 1971.
- Sklavounou A, Laskaris G: Eosinophilic ulcer of the oral mucosa. *Oral Surg*. 58:431, 1984.
- Triantafyllou A, Laskaris G: Unusual foreign body reaction of the oral soft tissues. *Odontostomatol Prog* 37:159, 1983.
- Weathers DR, Fine RM: Thrombosed varix of the oral cavity. *Arch Dermatol* 104:427, 1971.
- Worsaae N, Wanscher B: Oral injury caused by fellatio. *Acta Derm Venereol* (Stockh) 58:187, 1978.

#### 5. Oral Lesions due to Chemical Agents

- Alford B, Harris H: Chemical burns of the mouth, pharynx and esophagus. *Ann Otol* 68:122, 1959.
- Glick GL, Chafee RB, Salkin LM: Oral mucosal lesions associated with acetyl salicylic acid: Two case reports. *NY State Dent J* 40:475, 1975.
- Kawashima Z, Flagg RH, Cox DE: Aspirin induced oral lesion: Report of a case. *J. Am Dent. Assoc* 91:130, 1975.
- Kozam G, Mantell FM: The effect of eugenol on oral mucous membranes. *J Dent Res* 57:954, 1978.
- Murrin JR, Abrams SH, Barkmeier WW: Chemical burn of oral tissue caused by dental cavity varnish: Report of a case. *I Dent J* 47 47:580, 1978.
- Touzy LZ, Hile JJ: A fruit-mouthwash chemical burn. *Oral Surg*. 58:290, 1984.

#### 6. Oral Lesions due to Smoking and Heat

- Axell T: A prevalence study of oral mucosal lesions in an adult Swedish population. Thesis. *Odontol Revy* 27 (suppl. 36):1, 1967.
- Berry HH, Landwerlen JR: Cigarette smoker's lip lesions in psychiatric patients. *J Am Dent Assoc* 86:657, 1973.
- Brown FH, Houston GD: Smoker's melanosis: A case report. *J. Periodonto*162:524, 1991.
- Farman A, VanVyk CW: Leukokeratosis nicotina glossi smoker's tongue. *Int J Oral Surg* 6:340, 1977.
- Hedin CA: Smoker's melanosis. *Arch Dermatol*. 133:1533, 1977.
- Hedin CA, Pindborg JJ, Axell T: Disappearance of smoker's melanosis after reducing smoking. *J Oral Pathol Med* 22:228,1993.
- Mehta FS, Jalnawalla PN, Daftary DK, et al: Reverse smoking in Andhra Pradesh, India: Variability of clinical and histologic appearances of palatal changes. *Int J Oral Surg* 6:75, 1977.
- Pindborg JJ, Reibel J, R6ed-Petersen B, Mehta FS: Tobacco-induced changes in oral leukoplakic epithelium. *Cancer* 45:2330,1980.
- Van Vyk CW: Nicotinic stomatitis of the palate: A clinicohistological study. *J Dent Ass SAfr* 22.1, 1967.

#### 7. Oral Lesions due to Drugs

- Aas E: Hyperplasia gingivae diphenylhydantoinea. A clinical, histological and biochemical study. *Acta Odontol Scand* 32 (Suppl. 34):1, 1963.
- Albright BW, Taylor CG: Hereditary angioneurotic edema: Report of a case. *J Oral Surg* 37:888, 1979.
- Angelopoulos AP: Diphenylhydantoin gingival hyperplasia. A clinicopathological review. I. Incidence, clinical feature and histopathology. *J. Can Dent Assoc* 41:103, 1975.
- Bakaen G, Scully C: Hereditary gingival fibromatosis in a family with the Zimmermann-Laband syndrome. *J Oral Pathol Med* 20:457,1991.

- Barak S, Engelberg IS, Hiss J: Gingival hyperplasia caused by nifedipine. Histopathologic findings. *J Periodontol* 58:639, 1987.
- Barrett AP: **Clinical characteristics and mechanisms involved in chemotherapy-induced oral ulceration.** *Oral Surg* 63:424, 1987.
- Bickley HC: A concept of allergy with reference to oral disease. *J Periodontol* 41:302, 1970.
- Brown RS, Sein P, Corio R, Bottomley WK: Nitrendipine-induced gingival hyperplasia. *Oral Surg* 70:593, 1990.
- Brown RS, Beaver WT, Bottomley WK: **On the mechanism of drug-induced gingival hyperplasia.** *J Oral Pathol Med* 20:201, 1991.
- Cline PW: Acute angioneurotic edema of the lip and tongue due to emotional stress. *Oral Surg* 41:734, 1976.
- Daley TD, Wysocki GP, Day C: Clinical and pharmacologic correlations in cyclosporine-induced gingival hyperplasia. *Oral Surg* 62:417, 1986.
- Dongari A, McDonnell HT, Langlais RP: Drug-induced gingival overgrowth. *Oral Surg* 76:543, 1993.
- Dreizen S: Stomatotoxic manifestations of cancer chemotherapy. *J Prosthet Dent* 40:650, 1978.
- Dreizen S, Me Credie KB, Keating MJ: Chemotherapy-associated oral hemorrhages in adults with acute leukemia. *Oral Surg* 57:494, 1984.
- Eisenberg E, Ballow M, Wolfe SIT, et al: Pemphigus-like mucosal lesions: A side effect of penicillamine therapy. *Oral Surg* 51:409, 1981.
- Fendrich, P, Brooke RI: An unusual case of oral pigmentation. *Oral Surg* 58:288, 1984.
- Giansanti IS, Tillery DE, Olansky S: Oral mucosal pigmentation resulting from antimalarial therapy. *Oral Surg* 31:66, 1971.
- Glenert U: Drug stomatitis due to gold therapy. *Oral Surg* 58:52, 1984.
- Gupta AK, Brown MD, Ellis CN, et al: Cyclosporine in dermatology. *J Am Acad Dermatol* 21:1245, 1989.
- Ho VC, Lui H, Mckean DI: Cyclosporine in nonpsoriatic dermatoses. *J Am Acad Dermatol* 123:1248, 1990.
- Lambardi T, Fiore-Donno G, Belser U, Di Felice R: Felodipine-induced gingival hyperplasia: a clinical and histologic study. *J Oral Pathol Med* 20:89, 1991.
- Laskaris G, Satriano R: Drug-induced blistering oral lesions. *Clin Dermatol* 11:545, 1993.
- Levy RS, Fisher M, Alter JN: Penicillamine: Review and cutaneous manifestations. *J Am Acad Dermatol* 8:548, 1983.
- Lynas RF: A suspected allergic reaction to lidocaine. *Anesthesiology* 31:380, 1969.
- Mason G, Grisius R, Mckean P: Stomatitis medicamentosa associated with gold therapy for rheumatoid arthritis. *US Navy Med* 69:23, 1978.
- Orfanos CE: Oral retinoids-Present status. *Br J Dermatol* 103:473, 1980.
- Orfanos, CE, Braun-Falco O, Farber EM, et al: Retinoids. *Advances in Basic Research and Therapy.* Springer-Verlag, Berlin, 1981.
- Rateitschak-Pluss, EM, Hefti A, L6rtscher R, Thiel G: Initial observation that cyclosporin-A induces gingival enlargement in man. *J. Clin Periodontol* 10:237, 1983.
- Savage NW, Barker MT, Adkins KF: Pigmentary changes in rat mucosa following antimalarial therapy. *J Oral Pathol* 15:468, 1986.
- Schincaglia GP, Forniti F, Cavallini R, et al: Cyclosporine-A increases type-I procollagen production and mRNA level in human gingival fibroblasts in vitro. *J Oral Pathol Med* 21:181, 1992.
- Seymour RA, Heasman PA: Drugs and the periodontium. *J Clin Periodontol* 15:1, 1988.
- Slavin J, Taylor J: Cyclosporin, nifedipine and gingival hyperplasia. *Lancet* ii:739:, 1987.
- Smith N: Acute stomatitis medicamentosa. Two case reports. *Aust Dent* 123:305, 1978.
- Tadini G, D'Orso M, Cusini M, et al: Oral mucosa pigmentation: A new side-effect of azidothymidine therapy in patients with Acquired Immunodeficiency Syndrome. *Arch Dermatol* 127:267, 1991.
- Troy JL, Silvers DN, Grossman ME, Jaffe IA: Penicillamine-associated pemphigus: Is it really pemphigus? *J Am Acad Dermatol* 4:547, 1981.
- Veraldi S, Schianchi-Veraldi, R, Scarabelli G: Pigmentation of the gums following hydroxychloroquine therapy. *Cutis* 49:281, 1992.

## 8. Metal and Other Deposits

- Barr EB: Amalgam tattoo: Report of a case. *J Ind Dent Assoc* 55:13, 1976.
- Buchner A, Hansen LS: Melanotic macule of the oral mucosa: A clinicopathologic study of 105 cases. *Oral Surg* 48:244, 1979.
- Buchner, A, Hansen LS: Amalgam pigmentation (amalgam tattoo) of the oral mucosa. *Oral Surg* 49:139, 1980.
- Cruikshank LG: Dental disease and its relation to antisiphilitic treatment. *Br J Vener Dis* 14:280, 1938.
- Freden H, Hellden L, Milleding P: Mercury content in gingival tissues adjacent to amalgam fillings. *Odonto Revy* 25:207, 1974.
- Lockhart PB: Gingival pigmentation as the sole presenting sign of chronic lead poisoning in a mentally retarded adult. *Oral Surg* 52:142, 1981.
- Sano K, Ogawa A, Inokuchi T, et al: Buccal hemangioma with phleboliths. *Oral Surg* 65:151, 1988.
- Wood NK, Goaz PW: *Differential Diagnosis of Oral Lesions.* 3rd ed C. V. Mosby, St Louis, 1985, p 100.
- Zachariades N, Rallis G, Papademetriou J, et al: Phleboliths: A report of three unusual cases. *Br J Oral Maxillofac Surg* 29:117, 1991.

## 9. Radiation-Induced Injuries

- Dreizen S, Daly TE, Drane JB, Brown LR: Oral complication of cancer radiotherapy. *Postgrad Med* 61:85, 1977.
- Mossman KL, Scheer AC: Complications of radiotherapy of head and neck cancer. *Ear Nose, Throat J* 56:90, 1977.
- Murray CG, Daly TE, Zimmerman SO: The relationship between dental disease and radiation necrosis of the mandible. *Oral Surg* 49:99, 1980.
- Schofield IDF, Abbot W, Popowich L: Osteoradionecrosis of maxillae. *Oral Surg* 45:692, 1978.

## 10. Allergy to Chemical Agents Applied Locally

- Barkin, ME, Boyd JP, Cohen S: Acute allergic reaction to eugenol. *Oral Surg* 57:441, 1984.
- Dahl BL: Tissue hypersensitivity to dental materials. *J Oral Rehabil* 5:117, 1978.
- Eversole LR: Allergic stomatitides. *J Oral Med* 34:93, 1979.
- Gill C, Michaelides P: Dental drugs and anaphylactic reactions. *Oral Surg* 50:30, 1980.
- Giunta J, Zablotsky N: Allergic stomatitis caused by selfpolymerizing resin. *Oral Surg* 41:631, 1976.
- Giunta J, Grauer I, Zablotsky N: Allergic contact stomatitis caused by acrylic resin. *J Prosth Dent* 42:188, 1976.
- McCabe JF, Barker RM: **Tissue sensitivity to acrylic resin.** *Br Dent* 1140:347, 1976.

Nathanson D, Lockhart P: Delayed extraoral hypersensitivity to dental composite material. *Oral Surg* 47:329, 1979.

Turrell, AJW: Allergy to denture-base materials-fallay or reality. *Br Dent J* 120:415, 1966.

### 11. Periodontal Diseases

Carranza FA: *Glickman's Clinical Periodontology*, 6th ed. W. B. Saunders, Philadelphia, 1984.

Genco RJ, Christersson LA, Zambon JJ: Juvenile periodontitis. *Int Dent J* 36:168, 1986.

Genco RJ, Slots J: Host responses in periodontal diseases. *J Dent Res* 63:441, 1984.

Jacobson L: Mouthbreathing and gingivitis. *J Periodont* 8:269, 1973.

Laskaris G, Dimitriou N, Angelopoulos A: Immunofluorescent studies in desquamative gingivitis. *J Oral Pathol* 10:398, 1981.

Lindhe J: *Textbook of Clinical Periodontology*: Munksgaard, Copenhagen, 1983.

Nisengard RJ, Neiders M: Desquamative lesions of the gingiva. *J Periodontol* 52:500, 1981.

Palmer RM, Eveson JW: Plasma-cell gingivitis. *Oral Surg* 51:187, 1981.

Riar DS, Nanda TS, Kamlesh: Mouthbreathing and gingival health. *J Ind Dent Assoc* 42:13, 1970.

Rogers RS III, Sheridan PH, Nightingale SH: Desquamative gingivitis: Clinical, histopathologic, immunopathologic, and therapeutic observations. *J Am Acad Dermatol* 17:729, 1982.

Saxen L, Mutomma H: Age-related expression of juvenile periodontitis. *J Clin Periodontol* 12:21, 1985.

Silverman S Jr, Lozada F: An epilogue to plasma-cell gingivostomatitis (allergic gingivostomatitis). *Oral Surg* 43:211, 1977.

Silverman S Jr, Mighorati CA, Lozada-Nur F. et al: Oral findings in people with or at high risk for AIDS: A study of 375 homosexual males. *J Am Dent Assoc* 112:187, 1986.

Sklavounou A, Laskaris G: Frequency of desquamative gingivitis in skin diseases. *Oral Surg* 56:141, 1983.

Souteyrand P, Wong E, MacDonald DM: Zoon's balanitis (balanitis circumscripta plasmacellularis). *Br J Dermatol* 105:195, 1981.

### 12. Diseases of the Tongue

Banoczy J, Szabo L, Csiba A: Migratory glossitis. A clinical histologic review of seventy cases. *Oral Surg* 39: 113, 1975.

Browning S, Hislop S, Scully C, et al: The association between burning mouth syndrome and psychological disorders. *Oral Surg* 64:171, 1987.

Celis A, Little JW: Clinical study of hairy tongue in hospital patients. *J Oral med* 21:139, 1966.

Cooke B: Median rhomboid glossitis. *Br J Dermatol* 93:399, 1975.

Dupre A, Christol B, Lassere J: Geographic lip: A variant of geographic tongue. *Cutis* 17:263, 1976.

Eidelman E, Chosack A, Cohen T: Scrotal tongue and geographic tongue: Polygenic and associated traits. *Oral Surg* 42:591, 1976.

Espelid M, Bang G, Johannessen AC, et al: Geographic stomatitis: report of 6 cases. *J Oral Pathol Med* 20:425, 1991.

Ettlinger RL, Manderson RD: A clinical study of sublingual varices. *Oral Surg* 38:540, 1974.

Fenerli A, Papanikolaou S, Papanikolaou M, Laskaris G: Histocompatibility antigens and geographic tongue. *Oral Surg* 76:476, 1993.

Gorsky M, Silverman S Jr, Chinn H: Burning mouth syndrome: A review of 98 cases. *J Oral Med* 42:7, 1987.

Grushka M: Clinical features of burning mouth syndrome. *Oral Surg* 63:30, 1987.

Holmstrup P, Axel T: Classification and clinical manifestations of oral yeast infections. *Acta Odont Scand* 48:57, 1990.

Hume WJ: Geographic stomatitis: A critical review. *J Dent* 3:25, 1975.

Katz, J, Benoliel R, Leviner E: Burning mouth sensation associated with fusospirochetal infection in edentulous patients. *Oral Surg* 62:152, 1986.

Kleinman H: Lingual varicosities. *Oral Surg* 23:546, 1967.

Lamey PJ, Lamb AB: Aetiological factors in burning mouth syndrome: A prospective study. *Br Med J* 296:1243, 1988.

Litner MM, Daysn D, Gorsky M, et al: Migratory stomatitis. *Oral Surg* 63:555, 1987.

Marks R, Simons M: Geographic tongue - a manifestation of atopy. *Br J Dermatol* 101:159, 1979.

Maragou P, Ivanyi L: Serum zinc levels in patients with burning mouth syndrome. *Oral Surg* 71:447, 1991.

Marks, R, Czarny D: Geographic tongue: Sensitivity to the environment. *Oral Surg*. 58:156, 1984.

Matthews JB, Basu MK: Plasma cell lesions within the oral tissues: Immunoperoxidase staining of routinely fixed and processed tissue. *Oral Surg* 54:414, 1982.

Muscaro JM, Ferranolo J, Palou J, Bombi JA: Histopathology of the saburral tongue. *Dermatologica* 163:52, 1981.

Regezi JA, Zarbo RJ, Keren DF: Plasma cell lesions of the head and neck: Immunofluorescent determination of clonality from formalin-fixed paraffin-embedded tissue. *Oral Surg* 56:616, 1983.

Simpson HE: Lymphoid hyperplasia in foliate papillitis. *J Oral Surg* 22:209, 1964.

Van der Waal I: The burning mouth syndrome. Munksgaard, Copenhagen 1990.

Van der Waal N, van der Kwast WAM, van Dijk E, van der Waal I: Geographic stomatitis and psoriasis. *Int J Oral Maxillofac Surg* 17:106, 1988.

Walsh LJ, Cleveland DB, Cumming CG: Quantitative evaluation of Langerhans cells in median rhomboid glossitis. *J Oral Pathol Med* 21:28, 1992.

Wright BA: Median rhomboid glossitis: Not a misnomer. *Oral Surg* 46:806, 1978.

Zegarelli DJ: Burning mouth: An analysis of 57 patients. *Oral Surg* 58:34, 1984.

### 13. Diseases of the Lips

Axell T, Skoglund A: Chronic lip fissures. *Int J Oral Surg* 10:354, 1981.

Baughman RD, Berger P, Pringle WM: Plasma cell cheilitis. *Arch. Dermatol.* 110:725, 1974.

Brook IM, King DJ, Miller ID: Chronic granulomatous cheilitis and its relationship to Crohn's disease. *Oral Surg* 56:405, 1983.

Brooke RI: Exfoliative cheilitis. *Oral Surg.* 45:52, 1978.

Chernovsky ME: Relationship between vertical facial dimension and perleche. *Arch Dermatol* 93:332, 1966.

Fisher AA: Allergic contact cheilitis. *Dermatology* 3:10, 1980.

Kruckhoff D, James R: Cheilitis granulomatosa. Successful treatment with combined local triamcinolone injections and surgery. *Arch Dermatol.* 114:1203, 1978.

Luger A: Cheilitis plasmacellularis. *Hautarzt* 17:244, 1966.

Mac Farlane GE, et al: Actinic cheilitis. Diagnosis, prevention and treatment. *US Navy Med* 73:22, 1982.

Morton ME, Ead GA: Granulomatous cheilitis. A report of three cases. *Br Dent J* 156:247, 1984.

- Oliver ID, Pickett AB: Cheilitis glandularis. *Oral Surg* 49:526, 1980.
- Parries E, Neto C, Silva Y: Midline cleft of the lower lip and mandible: report of case. *J Oral Surg* 39:958, 1981.
- Rose AJ: Aetiology of angular cheilosis. *Br Dent J* 125:67, 1968.
- Rosenquist B: Median lip fissure: Etiology and suggested treatment. *Oral Surg* 72:10, 1991.
- Stuller CB, Schaberg SJ, Stokes J, Pierce GL: Cheilitis glandularis. *Oral Surg* 53:602, 1982.
- Swerlick RA, Cooper PH: Cheilitis glandularis: A reevaluation. *J Am Acad Dermatol* 10:466, 1984.
- Williams PM, Greenberg MS: Management of Cheilitis granulomatosa. *Oral Surg* 72:436, 1991.
- Worsaae N, Pindborg JJ: Granulomatous gingival manifestations of Melkersson-Rosenthal syndrome. *Oral Surg* 49:131, 1980.
- #### 14. Soft-Tissue Cysts
- Allard RHB: Nasolabial cyst: review of the literature and report of 7 cases. *Int J Oral Surg* 11:351, 1982.
- Allard RHB: The thyroglossal cyst. *Head Neck Surg* 5:134, 1982.
- Allard RHB, Van der Kwast WAM, Van der Wall I: Nasopalatine duct cyst. Review of the literature and report of 22 cases. *Int J Oral Surg* 10:447, 1981.
- Blenkinsopp PT, Rowe NL: Recurrent dermoid cyst of the floor of the mouth. *Br J Oral Surg* 18:34, 1980.
- Buchner A, Hansen LS: The histomorphologic spectrum of the gingival cyst in the adult. *Oral Surg* 48:532, 1979.
- Buchner A, Hansen LS: Lymphoepithelial cysts of the oral cavity. *Oral Surg* 50:441, 1980.
- Cataldo E, Berkman MD: Cysts of the oral mucosa of newborns. *Am J Dis Child* 116:44, 1968.
- Fogarty D: Lingual thyroid and difficult intubation. *Anaesthesia* 45:251, 1990.
- Fromm A: Epstein's pearls, Bohn's nodules and inclusion-cysts of the oral cavity. *J Dent Child* 34:275, 1967.
- Harrison JD: Sowray JH, Smith NJ: Recurrent ranula. *Br Dent J* 140:180, 1976.
- Laskaris G: Gingival cysts of adult: Report of 3 cases. *Hell Stomatol Rev* 28:175, 1984.
- Mathur SK, Menon PR: Dermoid cyst of the tongue. *Oral Surg* 50:217, 1980.
- Oatis GW, Hartman GL, Robertson GR, Sugg WE: Dermoid cyst of the floor of the mouth. *Oral Surg* 39:192, 1975.
- Ramanathan K, Ganesan TJ, Raghavan KV: Salivary mucoceles-racial and histological variations. *Med J Malaysia* 4:302, 1977.
- Sadeghi EM, Bell WA: Development cyst of floor of mouth: Soft tissue variety of median mandibular cyst. *J Oral Surg* 38:841, 1980.
- Seifert G: Lymphoid lesions of the oral cavity. *Pathol Res Pract* 167:179, 1980.
- Seifert G, Donath K, Gumberg C: Mucozelen der Speicheldrüsen. Extravasation-Mucozelen (Schleimgranulome) und Retentions-Mucozelen (Schleim-Retentionscysten). *HNO* 29:179, 1981.
- Seward MH: Eruption cyst: An analysis of its clinical features. *J Oral Surg* 31:31, 1973.
- Shear M: Cysts of the Oral Regions. Wright PSG, Bristol, 1983.
- Toto PD, Wortel JP, Joseph G: Lymphoepithelial cysts and associated globulins. *Oral Surg* 54:59, 1982.
- Wampler HW, Krolls SO, Johnson RP: Thyroglossal tract cyst. *Oral Surg* 45:32, 1978.
- Warnakulasuriya KAAS, Herath KB: Investigating a lingual thyroid. *Int J Oral Maxillofac Surg* 21:227, 1992.
- Wesley RK, Scannel T, Nathan LE: Nasolabial cyst: Presentation of a case with a review of the literature. *J Oral Maxillofac Surg* 42:188, 1984.
- WHO: Histological typing of odontogenic tumours, jaw cysts and allied lesions. Geneva, 1971.
- #### 15. Viral Infections
- Axell T, Hammarström L, Larson A: Focal epithelial hyperplasia in Sweden. *Acta Odontol Scand* 39:201, 1981.
- Badger GR: Oral signs of chickenpox (varicella): Report of two cases. *J Dent Child* 47:349, 1980.
- Banks, P: Infectious mononucleosis: A problem of differential diagnosis to the oral surgeon. *Br J Oral Surg* 4:227, 1967.
- Barsh, LI: Molluscum contagiosum of the oral mucosa. Report of a case. *Oral Surg* 22:42, 1966.
- Beaudenon S, Praetorius F, Kremsdorf D, et al: A new type of human papillomavirus associated with oral focal epithelial hyperplasia. *J Invest Dermatol* 88:130, 1987.
- Centers for Disease Control: Public health considerations of infectious diseases in child day care centers. *J Pediatr* 105:683, 1984.
- Chang F, Syrjanen S, Kellokoski, J, Syrjanen K: Human papillomavirus (HPV) infections and their associations with oral disease. *J Oral Pathol Med* 20:305, 1991.
- Cohen SG, Greenberg MS: Chronic oral herpes simplex virus infection in immunocompromised patients. *Oral Surg* 59:465, 1985.
- Cotton DWK, Cooper C, Barrett DF, Leppard BJ: Severe atypical molluscum contagiosum infection in an immunocompromised host. *Br J Dermatol* 116:871, 1987.
- Courant P, Sobkov T: Oral manifestation in infectious mononucleosis. *J Periodontol* 40:279, 1969.
- Dreizen S, Me Credie KB, Keating MJ, Bodey GP: Oral infections associated with chemotherapy in adults with acute leukemia. *Postgrad Med* 71:133, 1982.
- Eisenberg E: Intraoral isolated herpes zoster. *Oral Surg* 45:214, 1978.
- Eversole LR, Laipis PJ, Merrell P, Choi E: Demonstration of human papillomavirus DNA in oral condyloma acuminatum. *J Oral Pathol Med* 16:266, 1987.
- Garlick JA, Taichman LB: Human papillomavirus infection of the oral mucosa. *Am J Dermatol* 13:386, 1991.
- George DI, Farman AG: Ultrastructural features of oral condyloma acuminatum. *J Oral Med* 39:169, 1984.
- Green TL, Eversole LR, Leider AS: Oral and labial verruca vulgaris: Clinical, histologic and immunohistochemical evaluation. *Oral Surg* 62:410, 1986.
- Henke, RP, Langosch KM, Loning T, Koppang HS: Human papillomavirus type 13 and focal epithelial hyperplasia of the oral mucosa. *Virch Arch A* 411:193, 1987.
- Katsabas A, Laskaris G, Capetanakis J: Herpes zoster. A clinical study of 227 cases. *Odontostomatol Prog* 32:68, 1978.
- Laskaris G, Papanicolaou S, Angelopoulos A: Focal epithelial hyperplasia: The first reported case from Greece. *Dermatologica* 162:254, 1981.
- Laskaris G, Sklavounou A: Molluscum contagiosum of the oral mucosa. *Oral Surg* 58:688, 1984.
- McKinney RV: Hand, foot and mouth disease: A viral disease of importance to dentists. *J Am Dent Assoc* 91:122, 1975.
- Rosell B, Stenman G, Magnusson B, et al: Disturbed expression of ribonucleotide reductase and cytokeratin polypeptides in focal epithelial hyperplasia. *J Oral Pathol* 15:261, 1986.

- Schiff BL: Molluscum contagiosum of the buccal mucosa. *Arch Dermatol* 178:90, 1958.
- Spruance SL, Wenerstrom RW: Pathogenesis of recurrent herpes simplex labialis. IV. Maturation of lesions within 8 hours after onset and implications for antiviral treatment. *Oral Surg* 58:667, 1984.
- Steigman AJ, Lipton MM, Braspenicky H: Acute lymphonodular pharyngitis: A newly described condition due to Coxsackie A virus. *J Pediatr* 61:331, 1963.
- Svirsky JA, Sawyer DR, Page DG: Molluscum contagiosum of the lower lip. *Int J Dermatol* 24:668, 1985.
- Swan RH, Mc Daniel RK, Dreiman BB, Rome WC: Condyloma acuminatum involving the oral mucosa. *Oral Surg* 51:503, 1981.
- Syrjanen S, Syrjanen K, Ikenberg H, et al: A human papillomavirus closely related to HPV 13 found in a focal epithelial hyperplasia lesion (Heck disease). *Arch Dermatol Res* 276:199, 1984.
- Whitaker SB, Wiegand SE, Budnick SD: Intraoral molluscum contagiosum. *Oral Surg* 72:334, 1991.
- Zeuss MS, Miller CS, White DK: In situ hybridization analysis of human papillomavirus DNA in oral mucosal lesions. *Oral Surg* 71:714, 1991.
- 16. HIV infection and AIDS**
- Adler-Storhthz K, Ficarra G, Woods KV, et al: Prevalence of Epstein-Barr virus and human papillomavirus in oral mucosa of HIV-infected patients. *J Oral Pathol Med* 21:164, 1992.
- Andersen L, Philipsen HP, Reichart PA: Macro- and microanatomy of the lateral border of the tongue with special reference to oral hairy leukoplakia. *J Oral Pathol Med* 19:77, 1990.
- Angrit P, Tuur SM, Macher AM, et al: Epithelioid angiomatosis in HIV infection: neoplasms or cat scratch disease. *Lancet* 1:996, 1988.
- Bach MC, Howell DA, Valenti AJ, et al: Aphthous ulceration of the gastrointestinal tract in patients with the acquired immunodeficiency syndrome (AIDS). *Ann Intern Med* 112:465, 1990.
- Barone R, Ficcarra G, Gaglioti D, et al: Prevalence of oral lesions among HIV-infected intravenous drug abusers and other risk groups. *Oral Surg* 69:169, 1990.
- Beral V, Peterman T, Berkelman RL, Jaffe HW: Kaposi's sarcoma among persons with AIDS: a sexually transmitted infection? *Lancet* 335:123, 1990.
- Biggar RJ, Burnett W, Mikl J, Nasca P: Cancer among New York men at risk of acquired immunodeficiency syndrome. *Int J Cancer* 43:979, 1989.
- Brahim JS, Katz RW, Roberts MW: Non-Hodgkin's lymphoma of the hard palate mucosa and buccal gingiva associated with AIDS. *J Oral Maxillofac Surg* 46:328, 1988.
- Centers for Disease Control. *MMWR* 35:334, 1986.
- Centers for Disease Control: 1993 Revised Classification System for HIV Infection and Expanded Surveillance Case Definition for AIDS Among Adolescents and Adults. *MMWR* 41:1, 1993.
- De Souza YG, Greenspan D, Felton JR, et al: Localization of Epstein-Barr virus DNA in the epithelial cells of oral hairy leukoplakia by in situ hybridization of tissue sections. *N Engl J. Med.* 320:1559, 1989.
- Dodd, CL, Greenspan D, Katz MH, et al: Oral candidiasis in HIV infection: **Pseudomembranous and erythematous candidiasis show similar rates of progression to AIDS.** *AIDS* 5:1339, 1991.
- Dodd, CL, Greenspan D, Schiodt M, et al: Unusual oral presentation of non-Hodgkin's lymphoma in association with HIV infection. *Oral Surg* 73:630, 1992.
- EC-Clearinghouse on oral problems related to HIV-infection: An update of the classification and diagnostic criteria of oral lesions in HIV-infection. *J Oral Pathol Med* 20:97, 1991.
- EC-Clearinghouse on oral problems related to HIV-infection: Classification and diagnostic criteria for oral lesions in HIV-infection. *J Oral Pathol Med* 22:289, 1993.
- Epstein J, Scully C: Cytomegalovirus: a virus of increasing relevance to oral medicine and pathology. *J Oral Pathol Med* 22:348, 1993.
- Epstein JB, Sherlock CH, Greenspan JS: Hairy leukoplakia-like lesions following bone-marrow transplantation. *AIDS* 5:101, 1991.
- Epstein JB, Sherlock CH, Wolber RA: Hairy leukoplakia after **bone marrow transplantation.** *Oral Surg* 75:690, 1993.
- Epstein JB, Silverman S Jr: Head and neck malignancies associated with HIV infection. *Oral Surg* 73:193, 1992.
- Eversole LR: Viral infections of the head and neck among HIV-seropositive patients. *Oral Surg* 73:155, 1992.
- Ficarra G: Oral lesions of iatrogenic and undefined etiology and neurologic disorders associated with HIV infection. *Oral Surg* 73:201, 1992.
- Ficarra G, Berson AM, Silverman S Jr, et al: Kaposi's sarcoma of the oral cavity: A study of 134 patients with a review of the pathogenesis, epidemiology, clinical aspects and treatment. *Oral Surg* 66:543, 1988.
- Glick M, Cleveland DB: Oral mucosal bacillary epithelioid angiomatosis in a patient with AIDS associated with rapid alveolar bone loss: case report. *J Oral Pathol Med* 22:235, 1993.
- Greenspan D, Greenspan JS: Significance of oral hairy leukoplakia. *Oral Surg* 73:151, 1992.
- Greenspan D, Greenspan JS, Conant M, et al: Oral "hairy" leukoplakia in male homosexuals: Evidence of association with both papillomavirus and a herpes-group virus. *Lancet* 2:831, 1984.
- Greenspan JS, Barr CE, Sciubba JJ et al: Oral manifestations of HIV infection. *Oral Surg* 73:142, 1992.
- Greenspan JS, Greenspan D: Oral hairy leukoplakia: Diagnosis and management. *Oral Surg* 67:396, 1989.
- Heinic GS, Greenspan D, Mac Phail LA, et al: Oral histoplasma capsulatum infection in association with HIV infection: A case report. *J. Oral Pathol Med* 21:85, 1992.
- Herbst JS, Morgan J, Raab-Traub N, et al: Comparison of the efficacy of surgery and acyclovir in the treatment of oral hairy leukoplakia. *J Am Acad Dermatol* 21:753, 1989.
- Kaugars GE, Burns JC: Non-Hodgkin's lymphoma of the oral cavity associated with AIDS. *Oral Surg* 67:433, 1989.
- Klein RS, Quart AM, Small CB: Periodontal disease in heterosexuals with acquired immunodeficiency syndrome. *J Periodontol* 62:535, 1991.
- Langford-Kunzz A, Reichart P, Pohle HD: Impairment of craniofacial nerves due to AIDS: Report of two cases. *Int J Oral Maxillofac Surg* 17:227, 1988.
- Langford A, Kunze R, Timm H, et al: Cytomegalovirus-associated oral ulcerations in HIV-infected patients. *J Oral Pathol Med* 19:71, 1990.
- Laskaris G, Agrogiannis B: Oral hairy leukoplakia of the tongue in a patient with simultaneous immunosuppression following renal transplantation and HIV infection. *Hell Stomatol Rev* 34:285, 1990.
- Laskaris G, Anastasiadis P, Kittas C: Oral Kaposi's sarcoma as the first sign of AIDS. *Stomatologia* 47:201, 1990.

- Laskaris G, Hadjivassiliou M, Stratigos J: Oral signs and symptoms in 160 Greek HIV-infected patients. *J Oral Pathol Med* 21:120, 1992.
- Laskaris G, Potouridou I, Laskaris M, Stratigos J: Gingival lesions of HIV infection in 178 Greek patients. *Oral Surg* 74:168, 1992.
- Laskaris G, Stergiou G, Kittas C, Scully C: Hodgkin's disease involving the gingiva in AIDS. *Oral Oncol, Eur J Cancer* 28:13:39, 1992.
- Lozada F, Silverman S, Magliorati CA, et al: Oral manifestations of tumor and opportunistic infections in the acquired immunodeficiency syndrome (AIDS): Findings in 53 homosexual men with Kaposi's sarcoma. *Oral Surg* 56:491, 1983.
- Lucartorto FM, Franker CK, Maza J: Postscaling bacteremia in HIV-associated gingivitis and periodontitis. *Oral Surg* 73:550, 1992.
- Lucht E, Heimdahl A, Nord CE: Periodontal disease in HIV-infected patients in relation to lymphocyte subsets and specific microorganisms. *J Clin Periodontol* 18:252, 1991.
- Mac Phail LA, Greenspan D, Greenspan JS: Recurrent aphthous ulcers in association with HIV infection. *Oral Surg* 73:283, 1992.
- Mindel A: Herpes simplex virus. Springer-Verlag, London-Berlin, 1989.
- Murray PA, Grassi M, Winkler JR: The microbiology of HIV-associated periodontal lesions. *J Clin Periodontol* 16:636, 1989.
- Oda D, Me Dougal L, Fritsche T, Worthington P: Oral histoplasmosis as a presenting disease in acquired immunodeficiency syndrome. *Oral Surg* 70:631, 1990.
- Pindborg JJ: Classification of oral lesions associated with HIV infection. *Oral Surg* 67:292, 1989.
- Ramirez V, Gonzalez A, de la Rosa E, et al: Oral lesions in Mexican HIV-infected patients. *J Oral Pathol Med* 19:482, 1990.
- Rams TE, Andriolo M Jr, Feik D, et al: Microbiological study of HIV-related periodontitis. *J Periodontol* 68:74, 1991.
- Reichart PA: Oral ulceration and iatrogenic disease in HIV infection. *Oral Surg* 73:212, 1992.
- Reichart PA, Langford A, Gelderblom HR, et al: Oral hairy leukoplakia: Observations in 95 cases and review of the literature. *J Oral Pathol Med* 18:410, 1989.
- Reyes-Teran G, Ramirez-Amador V, De la Rosa E, et al: Major recurrent oral ulcers in AIDS: Report of three cases. *J Oral Pathol Med* 21:409, 1992.
- Riley C, London JP, Burmeister JA: Periodontal health in 200 HIV-positive patients. *J Oral Pathol Med* 21:124, 1992.
- Robinson P: Periodontal disease and HIV infection: A review of the literature. *J Clin Periodontol* 19:609, 1992.
- Samaramayake LP: Oral mycoses in HIV infection. *Oral Surg* 73:171, 1992.
- SanGiacomo TR, Tan PM, Loggi DK, Itkin AB: Progressive osseous destruction as a complication of HIV-periodontitis. *Oral Surg* 70:476, 1990.
- Schiodt M, Dodd CL, Greenspan D, et al: Natural history of HIV-associated salivary gland disease. *Oral Surg* 74:326, 1992.
- Schmidt WA, Greenspan D, Felton JR, et al: Oral hairy leukoplakia in an HIV-seronegative heart transplant patient. *J Oral Pathol Med* 19:192, 1990.
- Schulten EA, ten Kate RW, van der Waal I: Oral manifestations of HIV infection in 75 Dutch patients. *J Oral Pathol Med* 18:42, 1989.
- Scully C, Laskaris G, Pindborg J, Porter S, Reichart P: Oral manifestations of HIV infection and their management. I. More common lesions. II. Less common lesions. *Oral Surg* 71:158 and 167, 1991.
- Serraino D, Zaccarelli M, Franceschi S, Greco D: **The epidemiology of AIDS-associated Kaposi's sarcoma in Italy.** *AIDS* 6:1015, 1992.
- Silverman S, Magliorati CA, Lozada F, et al: Oral findings in people with or at high risk for AIDS: A study of 375 homosexual males. *JADA* 112:187, 1986.
- Tadini G, D'orso M, Cusini M, et al: Oral mucosa pigmentation: A new side-effect of azidothymidine therapy in patients with Acquired Immunodeficiency Syndrome. *Arch Dermatol* 127:267, 1991.
- Thompson SH, Charles GA, Craig DB: Correlation of oral disease with the Walter-Reed staging scheme for HIV-1-seropositive patients. *Oral Surg* 73:289, 1992.
- Tirelli U, Carbone A, Monfardini S, et al: Malignant tumors in patients with human immunodeficiency virus infection: A report of 580 cases. *J Clin Oncol* 7:1582, 1989.
- Tukutuku K, Muyembe-Tamfum L, Kajembe K, et al: Oral manifestations of AIDS in a heterosexual population in a Zaire hospital. *J Oral Pathol Med* 19:232, 1990.
- WHO: *Wkly Epidem Rec* 61:69, 1986.
- Williams CA, Winkler JR, Grassi M, Murray PA: HIV-associated periodontitis complicated by necrotizing stomatitis. *Oral Surg* 69:351, 1990.
- Winkler JR, Robertson PB: Periodontal disease associated with HIV infection. *Oral Surg* 73:145, 1992.

### 17. Bacterial Infections

- Abell E, Marks R, Wilson J: Secondary syphilis: A clinicopathological review. *Br J Dermatol* 93:53, 1975.
- Alfieri N, Fleury RN, Opromolla DV, et al: Oral lesions in borderline and reactional tuberculoid leprosy. *Oral Surg* 55:52, 1983.
- Armstrong EA, Ziola B, Habbick BF, Komiyama K: Role of cations and IgA in saliva-mediated aggregation of *Pseudomonas aeruginosa* in cystic fibrosis patients. *J Oral Pathol Med* 22:207, 1993.
- Borssen E, Sundqvist G: Actinomyces of infected dental root canals. *Oral Surg* 51:643, 1981.
- Chapel TA: The variability of syphilitic chancres. *Sex Transm Dis* 5:68, 1978.
- Chapel TA: The signs and symptoms of secondary syphilis. *Sex Transm Dis* 7:161, 1980.
- Dimitrakopoulos J, Zouloumis L, Lazaridis N, et al: Primary tuberculosis of the oral cavity. *Oral Surg* 72:712, 1991.
- Epker B, Via WF: Oral and perioral manifestations of leprosy. *Oral Surg* 28:342, 1969.
- Escobar V, Farman AG, Arm RN: Oral gonococcal infection. *Int J Oral Surg* 13:549, 1984.
- Fitch HB, Alling GC: Leprosy, oral manifestations. *J Periodontol* 33:40, 1962.
- Fiumara NJ: Oral lesions of gonorrhea and syphilis. *Cutis* 17:689, 1976.
- Fiumara NJ: Venereal diseases of the oral cavity. *J Oral Med* 31:36, 1976.
- Fiumara NJ, Grande DJ, Giunta JL: Papular secondary syphilis of the tongue. *Oral Surg* 45:540, 1978.
- Fiumara NJ, Lessell S: Manifestations of late congenital syphilis - analysis of 271 patients. *Arch Dermatol* 102:78, 1970.
- Fleisher G, Ludwig S, Campos J: Cellulitis: Bacterial etiology, clinical features and laboratory findings. *J Pediatr* 97:591, 1980.
- Girdhar BK, Desikan KV: A clinical study of the mouth in untreated lepromatous patients. *Lepr Revy* 50:25, 1979.
- Giunta JL, Fiumara NJ: Facts about gonorrhea and dentistry. *Oral Surg* 62:529, 1986.

- Gould IM, Rise R: *Pseudomonas aeruginosa*: clinical manifestations and management. *Lancet* 2:1224, 1985.
- Griffin JM, Bach DE, Nespeca JA, Marshall KJ: Noma: Report of two cases. *Oral Surg* 56:605, 1983.
- Gustafson JR: Acute parotitis. *Surgery* 29:786, 1951.
- Happonen RP, Viander M: Comparison of fluorescent antibody technique and conventional staining methods in diagnosis of cervico-facial actinomycosis. *J Oral Pathol* 11:417, 1982.
- Holmes KK, Per-Anders M, Sparling PF, Wiesner PF: Sexually Transmitted Diseases. McGraw-Hill, New York, 1984.
- Holst E, Lund P: Cervico-facial actinomycosis. *Int J Oral Surg* 8:194, 1979.
- Hook EW: Acute cellulitis. *Arch Dermatol* 123:460, 1987.
- Jamsky RT: Gonococcal tonsillitis. *Oral Surg* 44:197, 1977.
- Krippachne W, Hunt TK, Dunphy J: Acute suppurative parotitis: Study of 161 cases. *Ann Surg* 156:251, 1962.
- Laskaris G, Nicolis G: Lupus vulgaris of the oral mucosa. *Dermatologica* 162:183, 1981.
- Lerner PI, et al: Group B Streptococcus bacteremia in adults: Analysis of 32 case and review of the literature. *Medicine (Baltimore)* 56:457, 1977.
- Lighterman I, Watanabe Y, Hidaha I: Leprosy of the oral cavity and adnexa. *Oral Surg* 15:1178, 1962.
- Littner MM, Dayan D, Kaffe I, et al: Acute streptococcal gingivostomatitis. *Oral Surg* 53:144, 1982.
- Malden N: An interesting case of adult facial gangrene (from Papua, New Guinea). *Oral Surg* 59:279, 1985.
- Mayer I, Shklar G: The oral manifestations of acquired syphilis. *Oral Surg* 34:45, 1967.
- Michaud M, Blanchette G, Tomich CE: Chronic ulceration of the hard palate: First clinical sign of undiagnosed pulmonary tuberculosis. *Oral Surg* 57:63, 1984.
- Nitzan DW, Shteyer A: Acute facial cellulitis and trismus originatin in the external auditory meatus. *Oral Surg* 62:262, 1986.
- Pindborg JJ, Thorn JJ, Schidtt M, et al: Acute necrotizing gingivitis in an AIDS patient. *Dan Dent J* 90:450, 1986.
- Purohit SD, Mathur BB, Gupta PR, et al: Tuberculous fistula of cheek. *Oral Surg* 60:41, 1985.
- Rao TV: Satyanarayana CV, Sundareshwar B, et al: Unusual form of tuberculosis of the lips. *J Oral Surg* 35:595, 1977.
- Rauch DM, Friedman E: Systemic tuberculosis initially seen as an oral ulceration: Report of a case. *J Oral Surg* 36:387, 1978.
- Reichart P: Facial and oral manifestations in leprosy: An evaluation of seventy cases. *Oral Surg* 41:385, 1976.
- Rennie RP, Duncan IBR: Emergence of gentamicin-resistant *Klebsiella* in a general hospital. *Antimicrob Agents Chemother* 11:179, 1978.
- Saunders PR, Macpherson DW: Acute suppurative parotitis: A forgotten cause of upper airway obstruction. *Oral Surg* 72:412, 1991.
- Sawyer D, Nwoku AJ: Cancrum oris (noma): Past and present. *J Dent Child* 48:138, 1981.
- Shields WD: Acute necrotizing ulcerative gingivitis. A study of some of the contributing factors and their validity in an army population. *J Periodontol* 48:346, 1977.
- Taylor CO, Carter JB: Buccal cellulitis in a infant due to ampicillin-resistant *Hemophilus influenzae*. *J Oral Maxillofac Surg* 44:234, 1986.
- Tempest MN: Cancrum oris. *Br J Surg* 53:949, 1966.
- Tumber-Saini SK, Habbick BE, Oles AM, et al: The role of saliva in aggregation and adherence of *Pseudomonas aeruginosa* in patients with cystic fibrosis. *J Oral Pathol Med* 21:299, 1992.
- Winchell SA, Tschen JA, Mc Gavran MH: Follicular secondary syphilis. *Cutis* 35:259, 1985.
- Wingard JR, Dick J, Charache P, Saral R: Antibiotic-resistant bacteria in surveillance stool cultures of patients with prolonged neutropenia. *Antimicrob Agents Chemother* 30:435, 1986.
- Wingard JR, Niehaus CS, Peterson DE, et al: Oral mucositis after bone marrow transplantation. *Oral Surg* 72:419, 1991.
- Winkler JR, Robertson PB: Periodontal disease associated with HIV infection. *Oral Surg* 73:145, 1992.
- Zachariades N, Papanikolaou S, Koundouris J: Scrofula: A report of two cases. *Int J Oral Surg* 11:127, 1982.
- Zhao-ju Z, Song-ling W, Jia-rui Z, et al: Chronic obstructive parotitis: report on ninety-two cases. *Oral Surg* 73:434, 1992.

#### 18. Fungal Infections

- Allen CM: Oral candidiasis: diagnosis and managing. *JADA* 123:77, 1992.
- Almeida O, Jorge J, Scully C, Bozzo L: Oral manifestations of paracoccidioidomycosis (South American blastomycosis). *Oral Surg* 72:430, 1991.
- Almeida O, Scully C: Oral lesions in the systemic mucoses. *Current Opinion in Dentistry*, 1:423, 1991.
- Aronson K, Soltani K: Chronic mucocutaneous candidosis: A review. *Mycopathologia* 60:17, 1976.
- Bastiaan RJ, Reade PC: The prevalence of *Candida albicans* in the mouths of tobacco smokers with and without oral mucous membrane keratoses. *Oral Surg* 53:148, 1982.
- Bennet DE: Histoplasmosis of the oral cavity and larynx. A clinicopathologic study. *Arch Intern Med* 120:417, 1967.
- Berdicevsky I, Ben-Aryeh H, Szargel R, Gutman D: Oral *Candida* in children. *Oral Surg* 57:37, 1984.
- Budtz-Jorgensen E: The significance of *Candida albicans* in denture stomatitis. *Scand J Dent Res* 82:151, 1974.
- Cohen PR, Held JL, Grossman ME, et al: Disseminated histoplasmosis presenting as an ulcerated verrucous plaque in a human immunodeficiency virus-infected man. *Int J Dermatol* 30:104, 1991.
- Crockett DN, O'Grady JF, Reade PC: *Candida* species and *Candida albicans* morphotypes in erythematous candidiasis. *Oral Surg* 73:559, 1992.
- Darwazeh AMG, Lamey PJ, Samaranayake LP, et al: The relationship between colonisation, secretor status and in vitro adhesion of *Candida albicans* to buccal epithelial cells from diabetics. *J Med Microbiol* 33:43, 1990.
- Eyre J, Nally FF: Oral candidosis and carcinoma. *Br J Dermatol* 85:73, 1971.
- Franco M, Mendes RP, Moscardi-Bacchi M, et al: Paracoccidioidomycosis. *Clin Trop Med Commun Dis* 4:185, 1989.
- Hauman CHJ, Raubenheimer EJ: Orofacial mucormycosis. *Oral Surg* 68:624, 1989.
- Higgs JM, Wells RS: Chronic mucocutaneous candidiasis: Associated abnormalities of iron metabolism. *Br J Dermatol* 86 (Suppl. 8):88, 1972.
- Holbrook WP, Rodgers GD: Candidal infections: Experience in a British dental hospital. *Oral Surg* 49:122, 1980.
- Holmstrup P, Axell T: Classification and clinical manifestations of oral yeast infections. *Acta Odontol Scand* 48:57, 1990.
- Iacopino AM, Wathen WF: Oral candidal infection and denture stomatitis: a comprehensive review. *JADA* 123:46, 1992.
- Jones AC, Bentsen TY, Freedman PD: Mucormycosis of the oral cavity. *Oral Surg* 75:455, 1993.



- Kirkpatrick CH, Sohnle PG: Chronic mucocutaneous candidiasis. In: Safai B, Good RA, (ed): Immunodermatology. Plenum Press, New York, 1981, p. 495.
- Klein RS, Harris CA, Small CB, et al: Oral candidiasis in highrisk patients as the initial manifestation of the acquired immunodeficiency syndrome. *N Engl J Med* 311:354, 1984.
- Kolnick JR: Oral candidosis. *Oral Surg* 50:411, 1980.
- Lakshman P, Samaranyake LP: Superficial oral fungal infections. *Current Opinion in Dentistry* 1:415, 1991.
- Lamey PJ, Darwazeh AMG, Muirhead J, et al: Chronic hyperplastic candidosis and secretor status. *J Oral Pathol Med* 20:64,1991.
- Loh FC, Yeo JF, Tan WC, Kumarisinghe G: Histoplasmosis presenting as hyperplastic gingival lesion. *J Oral Pathol Med* 18:533,1989.
- Lucatorto FM, Franker C, Hardy WD, Chafey S: Treatment of refractory oral candidiasis with fluconazole. *Oral Surg* 71:42, 1991.
- Mac Farlane TW, Helnarska SJ: The microbiology of angular cheilitis. *Br Dent J* 140:403, 1976.
- Miller RL, Gould AR, Skolnick JL, Epstein WM: Localized oral histoplasmosis. *Oral Surg* 53:367, 1982.
- Mylbarniemi S, Perheentura J: Oral findings in the autoimmune polyendocrinopathy-candidosis syndrome and other forms of hypoparathyroidism. *Oral Surg* 45:721, 1978.
- Nagai Y, Takeshita N, Saku T: Histopathologic and ultrastructural studies of oral mucosa with *Candida* infection. *J Oral Pathol Med* 21:171, 1992.
- Oda D, McDougal L, Fritsche T, Worthington P: Oral histoplasmosis as a presenting disease in acquired immunodeficiency syndrome. *Oral Surg* 70:631, 1990.
- Page LR, Drummond JR, Daniels HT, et al: Blastomycosis with oral lesions. *Oral Surg* 47:157, 1979.
- Parfrey NA: Improved diagnosis and prognosis of mucormycosis: a dinicopathologic study of 33 cases. *Medicine* 65:113, 1986.
- Renner RP, Lee M, Andors L, Me Namara TF: The role of *Candida albicans* in denture stomatitis. *Oral Surg* 47:323, 1979.
- Rockoff AS: Chronic mucocutaneous candidiasis. *Arch Dermatol* 115:322,1979.
- Samaranyake LP: Oral candidosis: an old disease in new guises. *Dent Update* 17:36, 1990.
- Samaranyake LP: Oral mucoses in HIV infection. *Oral Surg* 73:171, 1992.
- Samaranyake LP, MacFarlane TW, eds: *Oral Candidosis*. Wright, 1990.
- Scully C, Almeida O: Orofacial manifestations of the systemic mycoses. *J Oral Pathol Med* 21:289, 1992.
- Tavitian A, Raufman J-P, Rosenthal LE: Oral candidiasis as a marker for esophageal candidiasis in the acquired immunodeficiency syndrome. *Ann Intern Med* 104:54, 1986.
- Toth BB, Frame RR: Oral histoplasmosis: Diagnostic complication and treatment. *Oral Surg* 55:97, 1983.
- Warnakulasuriya KAAS, Samaranyake LP, Peiris JSM: Angular cheilitis in a group of Sri Lankan adults: a clinical and microbiologic study. *J Oral Pathol Med* 20:172,1991.
- Witorsch P, Utz JP: North American blastomycosis: A study of 40 patients. *Medicine (Baltimore)* 47:169, 1968.
- Wright BA, Fenwick F: Candidiasis and atrophic tongue lesions. *Oral Surg* 51:55, 1981.
- Yusuf H, Craig GT, Allan D: Disseminated histoplasmosis presenting with oral lesions. *Br J Oral Surg* 16:234, 1978-79.
- 19. Other Infections**
- Abbas K, El Toum IA, El Hassan AM: Oral leishmaniasis associated with Kala-azar: a case report. *Oral Surg* 73:583, 1992.
- DeLuke DM, Sciubba JJ: Oral manifestations of sarcoidosis: Report of a case masquerading as a neoplasm. *Oral Surg* 59:184,1985.
- Farah FS: Protozoan and helminth infections, in: Fitzpatrick TB, Eisen AZ, Wolff K, et al (eds): *Dermatology in General Medicine*, 3rd ed. Me Graw-Hill, New York, 1987, p 2480.
- Gold RS, Flanders NJ, Sager E: Oral sarcoidosis: Review of the literature. *J Oral Surg* 34:237, 1976.
- Greer RO, Sanger RG: Primary intraoral sarcoidosis. *J Oral Surg* 35:507,1977.
- Hamner JE, Scofield HH: Cervical lymphadenopathy and parotid gland swelling in sarcoidosis. *J Am Dent Assoc* 74:1224,1967.
- James DG, Jones WW: Immunology of sarcoidosis. *Am J Med* 72:5, 1982.
- Orlian AI, Birnbaum M: Intraoral localized sarcoid lesion. *Oral Surg* 49:341, 1980.
- Sloan PJM, O'Neil TCA, Smith CJ, Holdsworth CD: Multisystem sarcoid presenting with gingival hyperplasia. *Br J Oral Surg* 21:31,1983.
- Verheijen-Breemhaar L, De Man K, Zondervan PE, Hilvering C: Sarcoidosis with maxillary involvement. *Int J Oral Maxillofac Surg* 16:104, 1987
- 20. Diseases with Possible Immunopathogenesis**
- Arbesfeld SJ, Kurban AK: Behget's disease: new prospectives on an enigmatic syndrome. *J Am Acad Dermatol* 19:767, 1988.
- Bernstein ML, McDonald JS: Oral lesions in Crohn's disease: Report of two cases and update of the literature. *Oral Surg* 46:234,1978.
- Borradori L, Saada V, Rybojad M, et al: Oral intraepidermal IgA pustulosis and Crohn's disease. *Br J Dermatol* 126:383, 1992.
- Brook IM, King DJ, Miller ID: Chronic granulomatous cheilitis and its relationship to Crohn's disease. *Oral Surg* 56:405, 1983.
- Brooke RI, Sapp JP: Herpetiform ulceration. *Oral Surg* 42:182,1976.
- Butler DJ, Thompson H: Malignant granuloma. *Br J Oral Surg* 9:208,1972.
- Catterall RD: Clinical aspects of Reiter's disease. *Br J Rheumat* 22:151, 1983.
- Challacombe SJ, Barkhan P, Lehner T: Haematological features and differentiation of recurrent oral ulceration. *Br J Oral Surg* 15:37, 1977-78.
- Cohen PS, Meltzer JA: Strawberry gums: A sign of Wegener's granulomatosis. *JAMA* 246:2610,1981.
- Crama-Bohbouth G, Bosman FT, Vermeer BJ, et al: Immunohistological findings in lip biopsy specimens from patients with Crohn's disease and healthy subjects. *Gut* 24:202,1983.
- Edwards MB, Buckerfield JP: Wegener's granulomatosis: A case with primary mucocutaneous lesions. *Oral Surg* 46:53, 1978.
- Field EA, Tyldesley WR: Oral Crohn's disease revisited - A 10-year review. *Br J Oral Maxillofac Surg* 27:114, 1989.
- Frankel DH, Mostofi RS, Lorincz AL: Oral Crohn's disease: Report of two cases in brothers with metallic dysgeusia and a review of the literature. *J Am Acad Dermatol* 12:260, 1985.

- Freiberger HF, Fudenberg HH: Behçet's disease: Pitfalls in therapy and diagnosis. *Hosp Pract* 15:49g, 1980.
- Friedman-Birnbaum R, Bergman R, Aizen E: **Sensitivity and specificity of pathergy test results in Israeli patients with Behçet's disease.** *Cutis* 45:261, 1990.
- Gallina G, Cumbo V, Messina P, Caruso C: HLA-A, B, C, DR, MT and MB antigens in recurrent aphthous stomatitis. *Oral Surg* 59:364, 1985.
- Ghandour K, Issa M: Oral Crohn's disease with late intestinal manifestations. *Oral Surg* 72:565, 1991.
- Greenspan JS, Gadol N, Olson JA, et al: Lymphocyte function in recurrent aphthous ulceration. *J Oral Pathol* 114:592, 1985.
- Helm TN, Camisa C, Allen C, Lowder C: Clinical features of Behçet's disease: report of four cases. *Oral Surg* 72:30, 1991.
- International Study Group for Behçet's Disease: Criteria for diagnosis of Behçet's disease. *Lancet* 335:1078, 1990.
- Ishii Y, Yamanaka N, Ogawa K, et al: Nasal T-cell lymphoma as a type of so-called "lethal midline granuloma." *Cancer* 50:2336, 1982.
- Jorizzo JL, Rogers RS: Behçet's disease. *J Am Acad Dermatol* 23:738, 1990.
- Keczkes K: Wegener's granulomatosis. Combined therapy with low-dose systemic corticosteroids, azathioprine and cyclophosphamide in three patients. *Br J Dermatol* 94:391, 1976.
- Kousa M: Clinical observations on Reiter's disease with special reference to the venereal and non-venereal aetiology. *Acta Derm Venereol [Suppl] (Stockh)* 58:18, 1978.
- Lehner T: Fine structural findings in recurrent oral ulceration. *Br Dent J* 121:454, 1966.
- Lehner T: Pathology of recurrent oral ulceration and oral ulceration in Behçet syndrome: Light, electron and fluorescence microscopy. *J Pathol* 197:481, 1969.
- Lehner T: Immunologic aspects of recurrent oral ulcers. *Oral Surg* 33:80, 1972.
- Lehner T: Progress report. Oral ulceration and Behçet's syndrome. *Gut* 18:491, 1977.
- Lennette HE, Magoffin R: Virologic and immunologic aspects of major oral ulceration. *J Am Dent Assoc* 87:1055, 1973.
- Miller MF, Garfunkel AA, Ram CA, Ship 11: The inheritance of recurrent aphthous stomatitis. *Oral Surg* 49:409, 1980.
- Nolle B, Specks U, Luderman J, et al: Anticytoplasmic autoantibodies. Their immunodiagnostic value in Wegener's granulomatosis. *Ann Intern Med* 111:28, 1989.
- Nelson JF, Finkelstein MW, Acevedo A, et al: Midline "nonhealing" granuloma. *Oral Surg* 58:554, 1984.
- Peterson A, Hougen HP, Kenrad B: T-lymphocyte subsets in oral mucosa of patients with recurrent aphthous ulceration. *J Oral Pathol Med* 21:176, 1992.
- Pindborg JJ, Gorlin RJ, Asboe-Hansen G: Reiter's syndrome. Review of the literature and report of a case. *Oral Surg* 16:551, 1963.
- Porter SR, Scully C, Bowden J: Immunoglobulin G subclasses in recurrent aphthous stomatitis. *J Oral Pathol Med* 21:26, 1992.
- Poulter LW, Lehner T: Immunohistology of oral lesions from patients with recurrent oral ulcers and Behçet's syndrome. *Clin Exp Immunol* 78:189, 1989.
- Savage NW, Seymour GJ, Kruger BJ: Expression of class I and class II major histocompatibility complex antigens on epithelial cells in recurrent aphthous stomatitis. *J Oral Pathol* 15:191, 1986.
- Sharp JT: Reiter's syndrome: A review of current status and a hypothesis regarding its pathogenesis. *Curr Probl Dermatol* 5:157, 1973.
- Specks U, Wheatley CL, McDonald TJ, et al: Anticytoplasmic autoantibodies in the diagnosis and follow-up of Wegener's granulomatosis. *Mayo Clin Proc* 64:28, 1989.
- Stratigos A, Laskaris G, Stratigos J: Behçet's Disease. *Seminars in Neurology* 12:346, 1992.
- Sun A, Wu Y-C, Liang L-C, Kwan H-W: Circulating immune complexes in recurrent oral ulcers. *J Dermatol* 13:170, 1986.
- Taylor VE, Smith CJ: Oral manifestations of Crohn's disease without demonstrable gastrointestinal lesions. *Oral Surg* 39:58, 1975.
- Tsokos M, Fauci AS, Costa J: Idiopathic midline destructive disease (IMDD): A subgroup of patients with the "midline granuloma" syndrome. *Am J Clin Pathol* 77:162, 1982.
- Yazici H, Pazarli H, Barnes CG, et al: A controlled trial of azathioprine in Behçet's syndrome. *N Engl J Med* 322:281, 1990.

## 21. Autoimmune Diseases

- Alfaro-Giner A, Penarrocha-Diago M, Bagan-Sebastian JV: Orofacial manifestations of mixed connective tissue disease with an uncommon serologic evolution. *Oral Surg* 73:441, 1992.
- Andonopoulos AP, Skopouli F, Dimou GS, et al: Sjögren's syndrome in systemic lupus erythematosus. *J Rheumatol* 17:201, 1990.
- Berdon JK, Girasole RV: Oral manifestations of lupoid hepatitis. *Oral Surg* 33:900, 1972.
- Bohan A et al: A computer-assisted analysis of 153 patients with polymyositis and dermatomyositis. *Medicine* 56:255, 1977.
- Calln JP: The value of malignancy evaluation in patients with dermatomyositis. *J Am Acad Dermatol* 16:253, 1982.
- Duncan AG, Richardson JB, Klein JB, et al: Clinical, serologic and immunogenetic studies in patients with dermatomyositis. *Acta Derm Venereol (Stockh)* 71:312, 1990.
- Fox RI, Robinson CA, Curd JG, et al: Sjögren's syndrome: proposed criteria for classification. *Arthritis Rheum* 29:577, 1986.
- Green D: Scleroderma and its oral manifestations. Report of three cases of progressive systemic sclerosis (diffuse scleroderma). *Oral Surg* 15:1312, 1962.
- Hahn BH: Systemic lupus erythematosus. In *Harrison's Principles of Internal Medicine*, 12th ed McGraw-Hill, Inc, New York 1991, pp 1432-1437.
- Hausmann G, Herrero C, Cinta M, et al: Immunopathologic study of skin lesions in dermatomyositis. *J Am Acad Dermatol* 25:225, 1991.
- Herrmann K, Heckmann M, Kulozik M, et al: Steady-State mRNA levels of collagens I, III, fibronectin and collagenase in skin biopsies of systemic sclerosis patients. *J Invest Dermatol* 97:219, 1991.
- Hidano A, Kaneko K, Arai Y, Kikuchi R: Survey of the prognosis for dermatomyositis, with special reference to its association with malignancy and pulmonary fibrosis. *J Dermatol* 13:233, 1986.
- Jonsson R, Heyden G, Westberg NG, Nyberg G: Oral mucosal lesions in systemic lupus erythematosus. A clinical, histopathological and immunopathological study. *J Rheumatol* 11:38, 1984.
- Marmary Y, Glaiss A, Pisanty S: Scleroderma: Oral manifestations. *Oral Surg* 52:32, 1981.
- Moutsopoulos HM, et al: **Sjögren's syndrome (sicca syndrome): Current issues.** *Ann Intern Med* 92:212, 1980.
- Moutsopoulos HM, Webber BL, Vlgopoulos TP, et al: **Differences in the clinical manifestations of sicca syndrome in the presence and absence of rheumatoid arthritis.** *Am J Med* 66:733, 1979.
- Naylor WP: Oral management of the scleroderma patients. *J Am Dent Assoc* 105:814, 1982.

- Podolsky DK, Isselbacher KJ: Cirrhosis of the liver. In Harrison's Principles of Internal Medicine, 12th ed, McGraw-Hill, Inc, New York 1991, pp 1340-1350.
- Rhodus NL, Schuh MJ: Effects of pilocarpine on salivary flow in patients with Sjögren's syndrome. *Oral Surg* 72:545, 1991.
- Richardson JB, Callen JP: Dermatomyositis and malignancy. *Med Clin North Am* 73:1211, 1989.
- Rowell N, Hopper F: The periodontal membrane in systemic sclerosis. *Br J Dermatol* 96:15, 1977.
- Saito T, Fukuda H, Arisue M, et al: Relationship between sialographic findings of parotid glands and histopathologic finding of labial gland in Sjogren's syndrome. *Oral Surg* 72:675, 1991.
- Sanger RG, Kith JW: The oral and facial manifestations of dermatomyositis with calcinosis. *Oral Surg* 35:476, 1973.
- Schiødt M: Oral manifestations of lupus erythematosus. *Int J Oral Surg* 13:101, 1984.
- Schiødt M, Pindborg JJ: Oral discoid lupus erythematosus. I. The validity of previous histopathologic diagnostic criteria. *Oral Surg* 57:46, 1984.
- Scully C: Sjogren's syndrome: Clinical and laboratory features, immunophogenesis and management. *Oral Surg* 62:510, 1986.
- Sharp GC: Mixed connective tissue disease. *Bull Rheum Dis* 25:828, 1975.
- Skopouli F, Siouna-Fatourou H, Dimon GS, et al: Histologic lesion in labial salivary glands of patients with systemic lupus erythematosus. *Oral Surg* 72:208, 1991.
- Takahashi H, Cheng J, Fujita S, et al: Primary malignant lymphoma of the salivary gland: a tumor of mucous-associated lymphoid tissue. *J Oral Pathol Med* 21:318, 1992.
- Tarpley TM Jr, Anderson LG, White CL: Minor salivary gland involvement in Sjogren's syndrome. *Oral Surg* 37:64, 1974.
- Varga E, Field EA, Tyldesley WR: Orofacial manifestations of mixed connective tissue disease. *Br Dent* 1168:330, 1990.
- Weisman RA, Calcaterra TC: Head and neck manifestations of scleroderma. *Ann Otol* 87:332, 1978.
- Wright JM, Dunsworth AR: Follicular lymphoid hyperplasia of the hard palate: A benign lymphoproliferative process. *Oral Surg* 55:162, 1983.
22. Skin Diseases
- Aboobaker J, Bhogal B, Wojnarowska F, et al: The localization of the binding site of circulating IgA antibodies in linear IgA disease of adults, chronic bullous disease of childhood and childhood cicatricial pemphigoid. *Br J Dermatol* 116:293, 1987.
- Aine L, Maki M, Reunala T: Coeliac-type dental enamel defects in patients with dermatitis herpetiformis. *Acta Derm Venereol (Stockh)* 72:25, 1992.
- Albrecht M, Banoczy, Dinya E, Tamas G Jr: Occurrence of oral leukoplakia and lichen planus in diabetes mellitus. *J Oral Pathol Med* 21:364, 1992.
- Anhalt GJ, Kim SC, Stanley JR, et al: Paraneoplastic pemphigus: An autoimmune mucocutaneous disease associated with neoplasia. *N Engl J Med* 323:1729, 1990.
- Barnett ML, Wittwer JW, Miller RL: Desquamative gingivitis in a 13-year-old male: Case report. *J Periodontol* 52:270, 1981.
- Bernard P, Prost C, Aucouturier P, et al: The subclass distribution of IgG autoantibodies in cicatricial pemphigoid and epidermolysis bullosa acquisita. *J Invest Dermatol* 97:259, 1991.
- Bernard P, Prost C, Lecerf V, et al: Studies of cicatricial pemphigoid autoantibodies using direct immunoelectron microscopy and immunoblot analysis. *J Invest Dermatol* 94:630, 1990.
- Brown J, Winkelmann RK: Acanthosis nigricans: A study of 90 cases. *Medicine (Baltimore)* 47:33, 1968.
- Buchner A, Begleiter A: Oral lesions in psoriatic patients. *Oral Surg* 41:327, 1976.
- Buchner A, Lozada F, Silverman S: Histopathologic spectrum of oral erythema multiforme. *Oral Surg* 49:221, 1980.
- Buckley DB, English J, Molloy W, et al: Dermatitis herpetiformis. A review of 119 cases. *Clin Exp Dermatol* 18:477, 1983.
- Bystryn JC: Adjuvant therapy of pemphigus. *Arch Dermatol* 120:941, 1984.
- Cataldo E, Me Carthy P, Yaffee H: Psoriasis with oral manifestations. *Cutis* 20:705, 1977.
- Camisa C, Helm TN, Liu Y-C, et al: Paraneoplastic pemphigus: A report of three cases including one long-term survivor. *J Am Acad Dermatol* 127:547, 1992.
- Caughman SW: Epidermolysis bullosa acquisita. *Arch Dermatol* 122:159, 1986.
- Chan MNY, Radden BG: Oral warty dyskeratoma. *J Oral Pathol* 13:546, 1984.
- Chorzelsky T, Jablonska S: Evolving concept of IgA linear dermatosis. *Semin Dermatol* 7:225, 1988.
- Cohen HJ: Perioral dermatitis. *J Am Acad Dermatol* 4:739, 1981.
- Curth HO: The necessity of distinguishing four types of acanthosis nigricans. Proceedings of the XIII International Congress of Dermatology, vol I, p 577, 1968.
- Dean AG, Melish ME, Hicks R, Palumbo NE: An epidemic of Kawasaki syndrome in Hawaii. *J Pediatr* 100:552, 1982.
- Economopoulou P, Laskaris G: Dermatitis herpetiformis: Oral lesions as an early manifestation. *Oral Surg* 62:77, 1986.
- Epstein O: Lichen planus and liver disease. *Br J Dermatol* 111:473, 1984.
- Eisen D, Ellis CN, Duell EA, et al: Effect of topical cyclosporine rinse on oral lichen planus. *N Engl J Med* 323:290, 1990.
- Esterly NB, Wortmann DW: Kawasaki syndrome. *Austr J Dermatol* 131:61, 1990.
- Farber EM, Nall ML: The natural history of psoriasis in 5,600 patients. *Dermatologica* 148:1, 1974.
- Farthing PM, Matear P, Cruchley AT: The activation of Langerhans cells in oral lichen planus. *J Oral Pathol Med* 19:81, 1990.
- Fine JD, Appell ML, Green LK, Sams WM Jr: Pemphigus vulgaris: combined treatment with intravenous corticosteroid pulse therapy, plasmapheresis and azathioprine. *Arch Dermatol* 124:236, 1988.
- Fraser NG, Kerr NW, Donald D: Oral lesions in dermatitis herpetiformis. *Br J Dermatol* 89:439, 1973.
- Furusawa M, Iwata M, Tamaki K, Ishibashi Y: **Anatomical distribution and immunological characteristics of epidermolysis bullosa acquisita antigen and buttons pemphigoid antigen.** *Br J Dermatol* 114:651, 1986.
- Gallgher G, Shklar G: Oral involvement in mucous membrane pemphigoid. *Clin Dermatol* 15:18, 1987.
- Giallorenzi A, Goldstein B: Acute (toxic) epidermal necrolysis. *Oral Surg* 40:611, 1975.
- Hatchuel DA, Peters E, Lemmer J, et al: **Candidal infection in oral lichen planus.** *Oral Surg* 70:172, 1990.
- Ho VC, Lui H, McLean DI: Cyclosporine in nonpsoriatic dermatoses. *J Am Acad Dermatol* 123:1248, 1990.
- Imamura S, Yanase K, Taniguchi S, et al: Erythema multiforme: Demonstration of immune complexes in the sera and skin lesions. *Br J Dermatol* 102:161, 1980.
- Jablonska S, Chorzelski TP, Blaszczyk M, Maciejowska E: Buttons diseases and malignancy. *Semin Dermatol* 3:316, 1984.

- Jordon RE, Kawana S, Fritz KA: Immunopathologic mechanisms in pemphigus and bullous pemphigoid. *J Invest Dermatol* 85:72s, 1985.
- Kadunce DP, McMurry MP, Avotins AA, et al. The effect of an elemental diet with and without gluten on disease activity in dermatitis herpetiformis. *J Invest Dermatol* 97:175, 1991.
- Kanerva L, Hietanen J: Ultrastructure of oral mucous membrane lesions in psoriasis. *Acta Derm Venereol (Stockh)* 64:191, 1984.
- Kanwar AJ, Handa S, Ghosh S, Kaur S: Lichen planus in childhood: a report of 17 patients. *Pediatr Dermatol* 8:288, 1991.
- Kato S, Kimura M, Tsuji K, et al: HLA antigens in Kawasaki disease. *Pediatrics* 61:252, 1978.
- Katz SI, Strober W: The pathogenesis of dermatitis herpetiformis. *J Invest Dermatol* 70:63, 1978.
- Kawasaki T, Kosaki F, Okawa S, et al: A new infantile acute febrile mucocutaneous lymph node syndrome (MLNS) prevailing in Japan. *Pediatrics* 54:271, 1974.
- Kazmierowski J, Wuepper K: Erythema multiforme: Immune complex vasculitis of the superficial cutaneous microvasculature. *J Invest Dermatol* 171:366, 1978
- Kelly S, Frith PA, Millard PR et al: A clinicopathological study of mucosal involvement in linear IgA disease. *Br J Dermatol* 119:161, 1988.
- Lagrain V, Taieb A, Surleve-Bazeille J-E, Bernard P, Maleville J: Linear IgA dermatosis of childhood: case report with an immunoelectron microscopic study. *Pediatric Dermatol* 8:310, 1991.
- Langeland T: Childhood cicatricial pemphigoid with linear IgA deposits: A case report. *Acta Derm Venereol (Stockh)* 65:354, 1985.
- Laskaris G: Oral pemphigus vulgaris: An immunofluorescent study of 58 cases. *Oral Surg* 51:626, 1981.
- Laskaris G, Papavasiliou S, Bovopoulou O, Nicolis G: Association of oral pemphigus vulgaris: An immunofluorescent study of 58 cases. *Oral Surg* 51:626, 1981.
- Laskaris G, Angelopoulos A: Cicatricial pemphigoid: Direct and indirect immunofluorescent studies. *Oral Surg* 51:48, 1981.
- Laskaris G, Papanicolaou S, Angelopoulos A: Immunofluorescent study of cytologic smears in oral pemphigus: A simple diagnostic technique. *Oral Surg* 51:531, 1981.
- Laskaris G, Papavasiliou S, Bovopoulou O, Nicolis G: Association of oral pemphigus with chronic lymphocytic leukemia. *Oral Surg* 50:244, 1980.
- Laskaris G, Papavasiliou S, Bovopoulou O, Nicolis G: Lichen planus pigmentosus of the oral mucosa: A rare clinical variety. *Dermatologica* 162:61, 1981.
- Laskaris G, Sklavounou A: Warty dyskeratoma of the oral mucosa. *Br J Oral Maxillofac Surg* 23:371, 1985.
- Laskaris G, Sklavounou A, Angelopoulos A: Direct immunofluorescence in oral lichen planus. *Oral Surg* 53:483, 1982.
- Laskaris G, Sklavounou A, Bovopoulou O: Juvenile pemphigus vulgaris. *Oral Surg* 51:415, 1981.
- Laskaris G, Sklavounou A, Stratigos J: Bullous pemphigoid, cicatricial pemphigoid and pemphigus vulgaris. A comparative clinical study of 278 cases. *Oral Surg* 54:656, 1982.
- Laskaris G, Stufi E: Pemphigus vulgaris in a 6-year-old girl. *Oral Surg* 69:609, 1990.
- Laskaris G, Triantafyllou A, Economopoulou P: Gingival manifestations of childhood cicatricial pemphigoid. *Oral Surg* 66:349, 1988.
- Leonard JN, Haffenden GP, Ring NP, et al: Linear IgA disease in adults. *Br J Dermatol* 107:301, 1982.
- Leonard JN, Wright P, Williams DM, et al: The relationship between linear IgA disease and benign mucous membrane pemphigoid. *Br J Dermatol* 110:307, 1984.
- Lim RT, Bystryn JC: Effect of plasmapheresis therapy on circulating levels of pemphigus antibodies. *J Am Acad Dermatol* 22:35, 1990.
- Mahrle G, Hamme SM, Ippen H: Oral treatment of keratinizing disorders of skin and mucous membranes with etretinate. *Arch Dermatol* 118:97, 1982.
- Melish ME, Hicks RM, Larson EJ: Mucocutaneous lymph node syndrome in the United States. *Am J Dis Child* 130:599, 1976.
- Meyer JR, Migliorati CA, Daniels TE, Greenspan JS:** Localization of basement membrane components in mucous membrane pemphigoid. *J Invest Dermatol* 84:105, 1985.
- Milgrom H, Palmer EL, Slovin SF, et al: Kawasaki disease in a healthy young adult. *Ann Intern Med* 92:467, 1980.
- Mobacken H, Nilsson LA, Olsson R, Sloberg K: Incidence of liver disease in chronic lichen planus of the mouth. *Acta Derm Venereol (Stockh)* 64:70, 1984.
- Mockli G, Kabra PM, Kurtz TW: Laboratory monitoring of cyclosporine levels: Guidelines for the dermatologist. *J Am Acad Dermatol* 23:1275, 1990.
- Mooney E, Falk RJ, Gammon R: Studies on complement deposits in epidermolysis bullosa acquisita and bullous pemphigoid. *Arch Dermatol* 128:58, 1992.
- Mostofi RS, Hayden NP, Soltani K: Oral malignant acanthosis nigricans. *Oral Surg* 56:372, 1983.
- Moy W, Kumar V, Friedman RP, et al: Cicatricial pemphigoid: A case of onset at age 5. *J Periodontol* 57:39, 1986.
- Moynahan EJ, Barnes PM: Zinc deficiency and a synthetic diet for lactose intolerance. *Lancet* 1:676, 1973.
- Murti PK, Bhonsle RB, Deftany DC, Mehta FS: Oral lichen planus associated with pigmentation. *J Oral Med* 34:23, 1979.
- Nazif MM, Ranalli DN: Stevens-Johnson syndrome: A report of fourteen cases. *Oral Surg* 53:263, 1982.
- Newland JR, Leventon G: Warty dyskeratoma of the oral mucosa. *Oral Surg* 58:176, 1984.
- Niimi Y, Jun Zhu ZX, Bystryn JC: Identification of basement membrane zone antigens defined by antibodies that react to both the epidermal and dermal size of 1M sodium chloride split skin. *J Invest Dermatol* 97:312, 1991.
- Nisengard RJ, Chorzelski T, Maciejowska E, Kryst L: Dermatitis herpetiformis: IgA deposits in gingiva, buccal mucosa and skin. *Oral Surg* 54:22, 1982.
- Olbricht SM, Flotte TJ, Collins AB, et al: Dermatitis herpetiformis. Cutaneous deposition of polyclonal IgA1. *Arch Dermatol* 122:418, 1986.
- Porter SR, Scully C, Midda M, Eveson JW: Adult linear immunoglobulin A disease manifesting as desquamative gingivitis. *Oral Surg* 70:450, 1990.
- Prost C, Colonna De Leca A, Combemale P, et al: Diagnosis of adult linear IgA dermatosis by immunoelectromicroscopy in 16 patients with linear IgA deposits. *J Invest Dermatol* 92:39, 1989.
- R6enick HH, Pearson RW: Epidermolysis bullosa acquisita. *Arch Dermatol* 117:383, 1981.
- Rogers RS III, Van Hale HM: Immunopathologic diagnosis of oral mucosal inflammatory diseases. *Australian J Dermatol* 27:51, 1986.
- Rosenbaum MM, Esterly NB, Creenwal MJ, Gerson CR: Cicatricial pemphigoid in a 6-year-old child: Report of a case and review of the literature. *Pediatr Dermatol* 2:13, 1984.
- Sananmuang K, Pankhurst CL, Gilkes JHH, et al: In vitro lymphocyte stimulation by simonsiella in patients with oral lichen planus. *Micro Ecol Health Diss* 3:59, 1990.
- Sammarine MA, Loffredo A, Cecio A, et al: Stevens-Johnson syndrome: A clinical and histological study. *Ophthalmologica* 1183:122, 1981.

- Schioldt M, Permin H, Wilk A, et al: Oral lupus erythematosus, lichen planus and leukoplakia. An aid in diagnosis. *Acta Pathol Microbiol Scand [C]* 91:59, 1982.
- Scully C, El-Kom M: Lichen planus: **Review and update on pathogenesis.** *J Oral Pathol* 114:431, 1985.
- Sedano HO, Gorlin RJ: Acanthosis nigricans. *Oral Surg* 63:462, 1987.
- Seghal VN: A clinical evaluation of 202 cases of vitiligo. *Cutis* 14:439, 1974.
- Siegel M, Balciunas A, Kelly M, Serio F: Diagnosis and management of commonly occurring oral vesiculoerosive disorders. *Cutis* 47:39, 1991.
- Silverman S Jr, Gorsky M, Lozada-Nur F, Giannotti K: A prospective study of findings and management in 214 patients with oral lichen planus. **Oral Surg** 72:665, 1991.
- Simon M, Djawari D, Schoenberger A: HLA antigens associated with lichen planus. *Clin Exp Dermatol* 9:435, 1984.
- Sklavounou A, Laskaris G: Frequency of desquamative gingivitis in skin diseases. *Oral Surg* 56:141, 1983.
- Sklavounou A, Laskaris G: Oral psoriasis: report of a case and review of the literature. *Dermatologica* 180:157, 1990.
- Sklavounou A, Laskaris G: Childhood cicatricial pemphigoid with exclusive gingival involvement. *J Oral Maxillofac Surg* 19:197, 1990.
- Tanay A, Mehregan AH: Warty dyskeratoma. *Dermatologica* 138:155, 1969.
- Thomopoulou-Doukoudakis A, Squier C, Hill MW: Distribution of ABO blood group substances in various types of oral lichen planus. *J Oral Pathol* 112:47, 1983.
- Valaes T: Mucocutaneous lymph node syndrome in Athens, Greece. *Pediatrics* 55:295, 1975.
- Vincent SD, Lilly GE, Baker KA: Clinical, historic and therapeutic features of cicatricial pemphigoid. *Oral Surg* 76:453, 1993.
- Voute ABE, de Jong WFB, Schulten EAJM, et al: Possible premalignant character of oral lichen planus. *J Oral Pathol Med* 21:326, 1992.
- Younger JR, Harris DWS, Colver GB: Azathioprine in dermatology. *J Am Acad Dermatol* 125:281, 1991.
- Watanabe T, Ohishi M, Tanaka K, Sato H: Analysis of HLA antigens in Japanese with oral lichen plasma. *J Oral Pathol* 15:529, 1986.
- Wells BT, Winkelmann RK: Acrodermatitis enteropathica: Report of 6 cases. *Arch Dermatol* 184:40, 1961.
- Williams DM: Vesiculo-bullous mucocutaneous disease: Benign mucous membrane and buttons pemphigoid. *J Oral Pathol Med* 19:16, 1990.
- Wojnarowska, F, Marsden RA, Bhogal B, Black MM: Childhood cicatricial pemphigoid with linear IgA deposits. *Clin Exp Dermatol* 9:407, 1984.
- Woodley DT, Briggaman RA, O'Keefe EJ, et al: Identification of the skin basement membrane autoantigen in epidermolysis bullosa acquisita. *N Engl J Med* 310:1007, 1984.
- Wuepper KD, Watson PA, Kazmierowski JA: Immune complexes in erythema multiforme and the Stevens-Johnson syndrome. *J Invest Dermatol* 74:368, 1980.
- Zegarelli, DJ: Multimodality steroid therapy of erosive and ulcerative oral lichen planus. *J Oral Med* 38:127, 1983.
- Baird IM, Dodge OG, Palmer FJ, Wawman RJ: The **tongue and oesophagus in iron deficiency anemia and effect of iron therapy.** *J Clin Pathol* 14:603, 1961.
- Berlin NJ: Diagnosis and classification of the polycythemias. *Semin Hematol* 12:339, 1976.
- Beveridge BR, Bannerman RM, Evanson JM, Witts LJ: Hypochromic anaemia: A retrospective study and follow-up of 378 patients. *Q J Med* 34:145, 1965.
- Deasy MJ, Vogel RI, Macedo-Sobrinho B, et al: Familial benign chronic neutropenia associated with periodontal disease. *J Periodontol* 151:206, 1980.
- Drummond JF, White DK, Damm DD: Megaloblastic anemia with oral lesions: A consequence of gastric bypass surgery. *Oral Surg* 59:149, 1985.
- Fotos PG, Graham WL, Bowers DC, Perfetto SP: Chronic autoimmune thrombocytopenic purpura. *Oral Surg* 56:564, 1983.
- Goldfarb A, Nitzan DW, Marmary Y: Changes in the parotid salivary gland of R-thalassemia patients due to hemosiderin deposits. *Int J Oral Surg* 12:115, 1983.
- Gorlin RJ, Chaudhry AP: The oral manifestations of cyclic (periodic) neutropenia. *Arch Dermatol* 82:344, 1960.
- Greenberg MS: Clinical and histologic changes of the oral mucosa in pernicious anemia. *Oral Surg* 52:38, 1981.
- Griffin JD: Myelodysplastic syndromes. *Clin Haematol* 15:909, 1986.
- Jacobs A, Cavill T: The oral lesions of iron deficiency anemia. Pyridoxin and riboflavin status. *Br J Haematol* 114:291, 1968.
- James WD, Guiry C, Grote W: Acute idiopathic thrombocytopenic purpura. *Oral Surg* 57:149, 1984.
- Koller AZ: Immune thrombocytopenic purpura. *Med Clin North Am* 64:761, 1980.
- Kostmann R: Infantile genetic agranulocytosis: A review with presentation of ten new cases. **Acta Paediatr Scand** 64:362, 1975.
- Logothetis J, Economidou J, Costantoulakis M, et al: Cephalofacial deformities in thalassemia major (Cooley's anemia). *Am J Dis Child* 121:300, 1971.
- Millard HD, Gobetti JP: Nonspecific stomatitis: A presenting sign in pernicious anemia. *Oral Surg* 39:562, 1975.
- Mishkin DJ, Akers JO, Darby CP: Congenital neutropenia: Report of a case and a rationale for dental management. *Oral Surg* 42:738, 1976.
- Ranasinghe AW, Warnakulasuriya KA, Tennekoon GE, et al: Oral mucosal changes in iron deficiency anemia in a Sri Lankan female population. *Oral Surg* 55:29, 1983.
- Scully C, McFadyen E, Campbell A: Oral manifestations in cyclic neutropenia. *Br J Oral Surg* 230:96, 1982.
- Sickles EA, Greece WH, Wiernik PH: Clinical presentation of infection in granulocytopenic patients. *Arch Intern Med* 135:715, 1975.
- Van Dis ML, Langlais RP: The thalassemias: Oral manifestations and complications. *Oral Surg* 62:229, 1986.
- Weatherall DJ, Clegg JB: *The Thalassemia Syndromes*, 3rd ed. Blackwell Scientific, Oxford, 1981.
- Wood MM, Elwood PC: Symptoms of iron deficiency anaemia: A community survey. *Br J Prev Sec. Med* 20:117, 1966.

### 23. Hematologic Disorders

- Alexander WN, Ferguson RL: Beta thalassemia minor and cleidocranial dysplasia: A rare combination of genetic abnormalities in one family. *Oral Surg* 49:413, 1980.
- Baehni PC, Payot P, Tsai C-C, Cimasoni G: Periodontal status associated with chronic neutropenia. *J Clin Periodontol* 10:222, 1983.

### 24. Renal Diseases

- Halazonitis J, Harley A: Uremic stomatitis. *Oral Surg* 23:573, 1967.
- Herman LT, Friedman JM: Management of orofacial infection in patients with chronic renal disease. *J Oral Surg* 33:942, 1975.

- Jaspers MT: Unusual oral lesions in a uremic patient. *Oral Surg* 39:934, 1975.
- Stufi ED, Sonis ST, Shklar G: Significance of the head and neck in late infection in renal transplant recipients. *Oral Surg* 62:524, 1986.
- 25. Metabolic Diseases**
- Ambruso DR, McCabe ERB, Anderson D, et al: Infectious and bleeding complications in patients with glycogenosis Ib. *AJDC* 139:691, 1985.
- Barrett AP: Neutropenic ulceration: A distinctive clinical entity. *J Periodontol* 58:51, 1987.
- Barrett AP, Backley DJ, Katelaris CH: Oral complications in type Ib glycogen storage disease. *Oral Surg* 69:174, 1990.
- Bashan N, Potashnik R, Peleg N, et al: Uptake and transport of hexoses into polymorphonuclear leukocytes of patients with glycogen storage disease type Ib. *J Inher Metab Dis* 13:252, 1990.
- Bonkovsky HL: Porphyria: Practical advice for the clinical gastroenterologist and hepatologist. *Dig Dis* 5:179, 1987.
- Breathnach SM: Amyloid and amyloidosis. *J Am Acad Dermatol* 118:1, 1988.
- Buluham JF, Johnson SC, Norback DH: Bullous amyloidosis. *Arch Dermatol* 116:1164, 1980.
- Calkins E: Amyloidosis of the skin. In: Fitzpatrick T, Eisen AZ, Wolff K, et al (eds): *Dermatology in General Medicine*. McGraw Hill, New York, 1987, pp 1656-1657.
- Chevrand-Breton J, Simon M, Bourel M, Ferrand B: Cutaneous manifestations of idiopathic hemochromatosis. *Arch Dermatol* 113:161, 1977.
- Crosby WH: Hemochromatosis: the unsolved problems. *Semin Hematol* 14:135, 1977.
- Dean DH, Hiramoto RN: Submandibular salivary gland involvement in hemochromatosis. *J Oral Med* 39:197, 1984.
- Di Sant' Agnese PA, Davis PB: Cystic fibrosis in adults. *Am J Med* 66:121, 1979.
- Emsley A, Paster L: Lipoid proteinosis presenting with neuropsychiatric manifestations. *J Neurol Neurosurg Psychiatr* 48:1290, 1985.
- Finkelstein MW, Hammond HL, Jones RB: Hyalinosis cutis et mucosae. *Oral Surg* 54:49, 1982.
- Franklin EC: Amyloid and amyloidosis of the skin. *J Invest Dermatol* 67:451, 1976.
- Gilhuus-Moc O, Koppang H: Oral manifestations of porphyria. *Oral Surg* 33:926, 1972.
- Goette DK, Carpenter WM: The mucocutaneous marker of pseudoxanthoma elasticum. *Oral Surg* 51:68, 1981.
- Gorsky M, Silverman S, Lozada F, Kushner J: Histiocytosis-X: Occurrence and oral involvement in six adolescent and adult patients. *Oral Surg* 55:24, 1983.
- Granda FM, Me Daniel RK: Multiple progressive eosinophilic granuloma of the jaws. *J Oral Maxillofac Surg* 40:174, 1982.
- Greenberger JS, Crocker AC, Vawter G, et al: Results of treatment of 127 patients with systemic histiocytosis (Letterer-Siwe syndrome, Schiiller-Christian syndrome and multifocal eosinophilic granuloma). *Medicine (Baltimore)* 60:311, 1981.
- Hansen RC, Lenten R, Revsin B: Cystic fibrosis manifesting with acrodermatitis enteropathica-like eruption. *Arch Dermatol* 119:51, 1983.
- Harper JI, Duance VC, Sims TJ, Light ND: Lipoid proteinosis: An inherited disorder of collagen metabolism? *Br J Dermatol* 113:145, 1985.
- Hartman KS: Histiocytosis-X: A review of 114 cases with oral involvement. *Oral Surg* 49:38, 1980.
- Hofer, PA, Bergenholtz A: Oral manifestations in Urbach-Wiethe disease (lipoglycoproteinosis; lipoid proteinosis; hyalinosis cutis et mucosae). *Odont Revy* 26:39, 1975.
- Kerem B, et al: Identification of the cystic fibrosis gene: Genetic analysis. *Science* 245:1073, 1989.
- Meenan FO, Bowe SD, Dion JJ, et al: Lipoid proteinosis: A clinical, pathological and genetic study. *Q J Med* 47:549, 1978.
- Moschella SL: Cutaneous xanthomas: A review and their relationship with the current classification of the hyperlipoproteinemias. *Lahey Clin Found Bull* 19:106, 1970.
- Murphy GM, Hawk JLM, Nicholson DS, Magnus IA: Congenital erythropoietic porphyria (Gunther's disease). *Clin Exp Dermatol* 12:61, 1987.
- Osband ME, Pochedly C: Histiocytosis-X. *Hematology/Oncology Clinics of North America*, 1:1, 1987, Saunders WB Co.
- Raffle EJ, Hall DC: Xanthomatosis presenting with oral lesions. *Br Dent J* 125:62, 1968.
- Rayne J: Porphyria erythropoietica. *Br J Oral Surg* 5:68, 1967.
- Rook A: Lipoid proteinosis: Urbach-Wiethe disease. *Br J Dermatol* 94:341, 1976.
- Salisbury PL, Jacoway JR: Oral amyloidosis: A late complication of multiple myeloma. *Oral Surg* 56:48, 1983.
- Schaub J, Heyne K: Glycogen storage disease type Ib. *Eur J Pediatr* 140:283, 1983.
- Schwartz HC, Olson DJ: Amyloidosis: A rational approach to diagnosis by intraoral biopsy. *Oral Surg* 39:837, 1975.
- Stanbury JB, Wyngaarden JB, Fredrickson DS, et al: *The Metabolic Basis of Inherited Diseases*, 5th ed. McGraw-Hill, New York, 1983.
- Smit GPA, Fernandes J, Leonard JV, et al: The long-term outcome of patients with glycogen storage diseases. *J Inher Metab Dis* 13:441, 1990.
- Tumber-Saini SK, Habbick BF, Oles AM, et al: The role of saliva in aggregation and adherence of *Pseudomonas aeruginosa* in patients with cystic fibrosis. *J Oral Pathol Med* 21:299, 1992.
- Tygstrup I, Haase E, Flensborg EW: The diagnostic value of lip biopsy in mucoviscidosis. *Acta Paediatr Scand* 58:208, 1969.
- Ward-Booth P, Ferguson MM, McDonald DG: Salivary gland involvement in hemochromatosis. *Oral Surg* 51:487, 1981.
- Wong CK: Mucocutaneous manifestations in systemic amyloidosis. *Clin Dermatol* 2:7, 1990.
- Zuendel MT, Bowers DF, Kramer RN: Recurrent histiocytosis-X with mandibular lesions. *Oral Surg* 58:420, 1984.
- 26. Nutritional Disorders**
- Afonsky D: Stomatitis in nutritional deficiencies. *Int Dent J* 5:59, 1955.
- Barthelemy H, Chouvet B, Cambazard F: Skin and mucosal manifestations in vitamin deficiency. *J Am Acad Dermatol* 15:1263, 1986.
- El Zawahry N: Pellagra: Notes and comments. *Int J Dermatol* 12:158, 1973.
- Heyl T: Chronic protein malnutrition. *Trans St Johns Hosp Dermatol Soc* 61:87, 1975.
- Jillson OF: Nutrition. *Cutis* 27:379, 1981.
- Price NM: Vitamin C deficiency. *Cutis* 26:375, 1980.
- Stratigos J, Katsambas A: Pellagra: A still existing disease. *Br J Dermatol* 96:99, 1977.
- Stratigos J, Katsambas A: Pellagra: „Reappraisal.“ *Acta Vitaminol Enzymol (Milano)* 4:115, 1982.
- Tillman HT: Oral and systemic changes in acute adult scurvy. *Oral Surg* 14:877, 1961.

## 27. Endocrine Diseases

- Bartolucci EG, Parkes RB: Accelerated periodontal breakdown in uncontrolled diabetes. *Oral Surg* 52:387, 1981.
- Bernick SM, Cohen DW, Baker L, Laster L: Dental disease in children with diabetes mellitus. *J Periodontol* 46:241, 1975.
- Cohen WD, Friedman LA, Shapiro J, et al: Diabetes mellitus and periodontal disease: Two years longitudinal observations. Part 1. *J Periodontol* 41:709, 1970.
- Farman AG: Atrophic lesions of the tongue among diabetic outpatients: Their incidence and regression. *J Oral Pathol* 6:396, 1977.
- Frohman LA, Janssen J-O: Growth hormone-releasing hormone. *Endocrinol Rev* 7:223, 1986.
- Nabarro JDN: Acromegaly. *Clin Endocrinol* 126:481, 1987.
- Nerup J: Addison's disease - clinical studies: A report of 180 cases. *Acta Endocrinol (Copenh)* 76:127, 1974.
- Ross JW: Mandibular osteotomy in an acromegalic. *Int J Oral Surg* 3:256, 1974.
- Russotto SB: Asymptomatic parotid gland enlargement in diabetes mellitus. *Oral Surg* 52:594, 1981.
- Silverman S Jr, Ware WH, Gillooly C: Dental aspects of hyperparathyroidism. *Oral Surg* 26:184, 1968.
- Warnakulasuriya S, Markwell RD, Williams DM: Familial hyperparathyroidism associated with cementifying fibromas of the jaws in two siblings. *Oral Surg* 59:269, 1985.
- Wilson JB, Foster DW: *William's Textbook of Endocrinology*, 7th ed. W. B. Saunders: Philadelphia, 1985.
- Wittmann AL: Macroglossia in acromegaly and hypothyroidism. *Virchows Arch [A]* 373:353, 1977.

## 28. Diseases of the Peripheral Nervous System

- Bannister R: *Brain's Clinical Neurology*, 6th ed. Oxford University Press, Oxford, 1985.
- Burzynski NH, Weisskopf B: Familial occurrence of Bell's palsy. *Oral Surg* 36:504, 1973.
- Fisher AA: Chronic lip edema with particular reference to the Melkersson-Rosenthal syndrome. *Cutis* 44:144, 1990.
- Greene RM, Rogers RS: Melkersson-Rosenthal syndrome: A review of 36 patients. *J Am Acad Dermatol* 21:1263, 1989.
- Hilton J: *Rest and Pain*, 2nd edition. P. W. Garfield, Cincinnati, 1981.
- Hornstein OP: Melkersson-Rosenthal syndrome: A neuromucocutaneous disease of complex origin. *Curr Probl Dermatol* 5:117, 1973.
- Kime CE: Bell's palsy: A new syndrome associated with treatment by nicotinic acid. *Arch Otolaryngo* 168:28, 1958.
- Kreutziger KL, Mahan PE: Temporomandibular degenerative joint disease. Part 1. Anatomy, pathophysiology and clinical description. *Oral Surg* 40:165, 1975.
- Kreutziger KL, Mahan PE: Temporomandibular degenerative joint disease. Part 11. Diagnostic procedure and comprehensive management. *Oral Surg* 40:297, 1975.
- Travell J: Temporomandibular joint pain referral from muscles of the head and neck. *J Prosth Dent* 10:745, 1960.
- Williams PM, Greenberg MS: Management of cheilitis granulomatosa. *Oral Surg* 72:436, 1991.
- Worsaae N, Pindborg JJ: Granulomatous gingival manifestations of Melkersson-Rosenthal syndrome. *Oral Surg* 49:131, 1980.
- Worsaae N, Christensen KC, Schiodt M, Reibel J: Melkersson-Rosenthal syndrome and cheilitis granulomatosa. *Oral Surg* 54:404, 1982.

## 29. Precancerous Lesions

- Axell T, Gupta PC, Hansen L, et al: Diagnostic and therapeutic problems of oral precancerous lesions. *Int J Oral Maxillofac Surg* 15:790, 1986.
- Ban6czy J: Follow-up studies in oral leukoplakia. *J Maxillofac Surg* 5:69, 1977.
- Banozy J, R6ed-Petersen B, Pindborg JJ, Inovay J: Clinical and histologic studies on electrogalvanically induced oral white lesions. *Oral Surg* 48:319, 1979.
- Baric JM, Alman JE, Feldman RS, Chauncey HH: Influence of cigarette, pipe, and cigar smoking, removable partial dentures and age on oral leukoplakia. *Oral Surg* 54:424, 1982.
- Bouguot JE, Gorlin RJ: Leukoplakia, lichen planus, and other oral keratoses in 23,616 white Americans over the age of 35 years. *Oral Surg* 61:373, 1986.
- Bovopoulou O, Sklavounou A, Laskaris G: Loss of intercellular substance antigens in oral hyperkeratosis, epithelial dysplasia and squamous cell carcinoma. *Oral Surg* 60:648, 1985.
- Chu FWK, Silverman S, Dedo HH: CO<sub>2</sub>-laser treatment of oral leukoplakia. *Laryngoscope* 98:125, 1988.
- Creath CJ, Cutter G, Bradley DH, Wright JT: Oral Leukoplakia and adolescent smokeless tobacco use. *Oral Surg* 72:35, 1991.
- Eyre J, Nally FF: Oral candidosis and carcinoma. *Br J Dermatol* 85:73, 1971.
- Garewal HS, Meyskens FL, Killen D, et al: Response of oral leukoplakia to beta-carotene. *J Clin Oncol* 8:1715, 1990.
- Gupta PC, Bhonsle RB, Murti RP, et al: An epidemiologic assessment of cancer risk in oral precancerous lesions in India with special reference to nodular leukoplakia. *Cancer* 63:2247, 1989.
- Hong WK, Endicott J, Itri LM, et al: 13-Cis-retinoid acid in the treatment of oral leukoplakia. *N Engl J Med* 315:1501, 1986.
- Jones JH, Russel C: Candidal infection and Leukoplakia. *Br J Oral Surg* 11:177, 1973.
- Kaugars GE, Brandt RB, Chan W, Carcaise-Edinboro P: Evaluation of risk factors in smokeless tobacco-associated oral lesions. *Oral Surg* 72:326, 1991.
- Knapp MJ: Oral disease in 181,338 consecutive oral examinations. *J Am Dent Assoc* 83:1288, 1971.
- Kramer IRH, El-Labban N, Lee KW: The clinical features and risk of malignant transformation in sublingual keratosis. *Br Dent J* 144:171, 1978.
- Laskaris G, Nicolis G: Erythroplakia of Queyrat of the oral mucosa. *Dermatologica*, 162:395, 1981.
- Mehta FS, Pindborg JJ, Gupta PC, Daftary DK: Epidemiologic and histologic study of oral cancer and leukoplakia among 50,915 villagers in India. *Cancer* 24:832, 1969.
- Reichart PA, Althoff J: Oral leukoplakia: A scanning electron microscopic study of epithelial surface patterns. *Int J Oral Surg* 12:159, 1983.
- Roodenburg JLN, Panders AK, Vermey A: Carbon dioxide laser surgery of oral leukoplakia. *Oral Surg* 71:670, 1991.
- Shafer WG, Waldron CA: Erythroplakia of the oral cavity. *Cancer* 36:1021, 1975.
- Shroyer KR, Greer RO: Detection of human papillomavirus DNA by in situ DNA hybridization and polymerase chain reaction in premalignant and malignant oral lesions. *Oral Surg* 71:708, 1991.
- Silverman S Jr: *Oral Cancer*, 2nd ed. American Cancer Society, New York, 1985.
- Silverman S Jr, Gorsky M, Lozada F: Oral Leukoplakia and malignant transformation: A follow-up study of 257 patients. *Cancer* 53:563, 1984.

- Waldron CA, Shafer WG: Leukoplakia revisited. A clinicopathologic study of 3256 oral leukoplakias. *Cancer* 36:1386,1975.
- WGO Collaborating Centre for Oral Precancerous Lesions: Definition of leukoplakia and related lesions. An aid to studies on oral precancer. *Oral Surg* 46:518, 1978.
- 30. Precancerous Conditions**
- Barnard NA, Scully C, Eveson JW, et al: Oral cancer development in patients with oral lichen planus. *J Oral Pathol Med* 22:421,1993.
- Carapeto FJ, Pastor JA, Martin J, Agurruza J: Recessive dystrophic epidermolysis bullosa and multiple squamous cell carcinomas. *Dermatologica* 165:39, 1982.
- Chierci G, Silverman S Jr, Forsythe B: A tumor registry study of oral squamous carcinoma. *J Oral Med* 23:91, 1968.
- Fulling HJ: Cancer development in oral lichen planus. *Arch Dermatol* 108:667, 1973.
- Holmstrup P, Pindborg JJ: Erythroplakia lesions in relation to oral lichen planus. *Acta Derm Venereol [Suppl] (Stockh)* 85:77,1979.
- Kraemer KH, Lee MM, Scotto J: Xeroderma pigmentosum: Cutaneous, ocular and neurologic abnormalities in 830 published cases. *Arch Dermatol* 123:241, 1987.
- Krutchkoff DJ, Cutler L, Laskowski S: Oral lichen planus. The evidence regarding potential malignant transformation. *J Oral Pathol* 7:1, 1978.
- Larsson LG, Sandström A, Estling P: Relationship of Plummer-Vinson disease to cancer of the upper alimentary tract in Sweden. *Cancer Res* 35:3308, 1975.
- Laskaris G, Bovopoulou O, Nicolis G: Oral submucous fibrosis in a Greek female. *Br J Oral Surg* 19:197, 1981.
- Lentz SR, Raish RJ, Orłowski EP, Marion JM: Squamous cell carcinoma in epidermolysis bullosa. *Cancer* 66:1276, 1990.
- Lovas JGL, Harsanyi BB, Elgeneidy AK: Oral lichenoid dysplasia: A clinicopathologic analysis. *Oral Surg* 68:57, 1989.
- Mackenzie IC, Dabelsteen E, Squier CA: *Oral Premalignancy*. University of Iowa Press, Iowa City, 1980.
- Mayer I, Abbey LM: The relationship of syphilis to primary carcinoma of the tongue. *Oral Surg* 30:678, 1970.
- Marti PR, Daftary DK, Gupta PC, et al: Malignant potential of oral lichen planus: Observations in 72 patients from India. *J Oral Pathol* 115:71,1986.
- Pindborg JJ: Is submucous fibrosis a precancerous condition in the oral cavity? *Int Dent J* 22:474, 1972.
- Pindborg JJ, Bhonsle RB, Marti PR, et al: Incidence and early forms of oral submucous fibrosis. *Oral Surg* 50:40, 1980.
- Pogrel MA, Weldon LL: Carcinoma arising in erosive lichen planus in the midline of the dorsum of the tongue. *Oral Surg* 55:62,1983.
- Reed WB, College J Jr, Francis MJO, et al: Epidermolysis bullosa dystrophica with epidermal neoplasma. *Arch Dermatol* 110:894, 1974.
- Schwartz RA, Birnkrant AP, Rubenstein DJ, et al: Squamous cell carcinoma in dominant type epidermolysis bullosa dystrophica. *Cancer* 47:615, 1981.
- Silverman S Jr: *Oral Cancer*, 2nd ed. American Cancer Society, New York, 1985.
- Silverman S Jr, Griffith M: Studies on oral lichen planus. II. Follow-up on 200 patients, clinical characteristics and associated malignant. *Oral Surg* 37:705,1974.
- Smeller BA, McNutt NS, Carter DM, et al: Recessive dystrophic epidermolysis bullosa skin displays a chronic growth-activated immunophenotype. *Arch Dermatol* 126:78, 1990.
- Voute ABE, de Jong WFB, Schulten EAJM, et al: Possible premalignant character of oral lichen planus. *J Oral Pathol Med* 21:326, 1992.
- Yagi KI, El-Casim A, Abbas KED, Prabhu SR: Carcinoma of the tongue in a patient with xeroderma pigmentosum. *Int J Oral Surg* 10:73, 1981.
- Yagi KI, Prabhu SR: Carcinoma of the lip in xeroderma pigmentosum. *J Oral Med* 38:97, 1983.
- Wynder EL, Bross IJ, Feldman RM: A study of the etiological factors in cancer of the mouth. *Cancer* 10:1300, 1957.
- 31. Malignant Neoplasms**
- Aberle AM, Abrams AM, Bowe R, et al: Lobular (polymorphous low-grade) carcinoma of minor salivary glands. *Oral Surg* 60:387, 1985.
- Ackerman LV: Verrucous carcinoma of the oral cavity. *Surgery* 23:670,1948.
- Ajagbe HA, Daramola JO, Junaid TA: Chondrosarcoma of the jaws: Review of fourteen cases. *J Oral Maxillofac Surg* 43:763,1985.
- Anderson C, Krutchkoff D, Pedersen C, et al: Polymorphous low-grade adenocarcinoma of minor salivary glands: A clinicopathologic and comparative immunohistochemical study. *Mod Pathol* 13:76, 1990.
- Baker DL, Oda D, Myall RW: Intraoral infantile hemangiopericytoma: Literature review and addition of a case. *Oral Surg* 73:596, 1992.
- Batsakis JG, Pinkston GR, Byers RM, et al: Adenocarcinomas of the oral cavity: A clinicopathologic study of terminal duct carcinomas. *J Laryngol Otol* 197:825, 1983.
- Bras J, Batsakis JG, Luna MA: Malignant fibrous histiocytoma of the oral soft tissues. *Oral Surg* 64:57, 1987.
- Batsakis JG, Luna MA: Histopathologic grading of salivary gland neoplasms: I. Mucoepidermoid carcinomas. *Ann Otol Rhinol Laryngol* 199:835, 1990.
- Brocheriou C, Creyp C, Guilbert F, et al: Tumeurs des glandes salivaires accessoires de la cavité buccale: Etude de 296 cas. *Bull Cancer (Paris)* 67:29, 1980.
- Brodsky G, Rabson AB: Metastasis to the submandibular gland as the initial presentation of small cell ("oat cell") lung carcinoma. *Oral Surg* 58:76, 1984.
- Carr RJ, Green DM: Oral presentation of disseminated angiosarcoma. *Br J Oral Maxillofac Surg* 24:277, 1986.
- Chau MNY, Radden BG: Intra-oral salivary gland neoplasms: A retrospective study of 98 cases. *J Oral Pathol* 15:339, 1986.
- Chaudhry AP, Hampel A, Gorlin RJ: Primary malignant melanoma of the oral cavity: A review of 105 cases. *Cancer* 11:923,1958.
- Chaudhry AP, Ribinovitch MR, Mitchell DF: Chondrogenic tumors of the jaws. *Am J Surg* 102:403, 1961.
- Chaudhry AP, Vickers RA, Gorlin RJ: Intraoral minor salivary gland tumors. *Oral Surg* 14:1194, 1961.
- Chen KTK: Clear cell carcinoma of the salivary gland. *Hum Pathol* 14:91, 1983.
- Chomette G, Auriol M, Labrousse F, Vaillant JM: Mucoepidermoid tumors of salivary glands: Histoprognotic value of NORs stained with AgNOR technique. *J Oral Pathol Med* 20:130, 1991.
- Clark L, Unni KK, Dahlin DC: Osteosarcoma of the jaws. *Cancer* 51:2311, 1983.
- Clark WH Jr, From L, Bernardino E, Mihm MC: The histogenesis and biologic behavior of primary human malignant melanomas of the skin. *Cancer Res* 29:705, 1969.
- Cooke BED: Recognition of oral cancer. Causes of delay. *Br Dent J* 142:96, 1977.



- Dahlin DC, Unni KK: Osteosarcoma of bone and its important recognizable varieties. *Am J Surg. Pathol* 1:61, 1977.
- de Vries N, Gluckman JL: Multiple primary tumors in the head and neck. Georg Thieme Verlag, Stuttgart-New York, 1990.
- Douglass CW, Gammon MD: Reassessing the epidemiology of lip cancer. *Oral Surg* 57:63 t, 1984.
- Eckardt A, Nommels R: Breast carcinoma metastatic to the gingiva. *J Oral Maxillofac Surg* 44:902, 1986.
- Eisenberg E, Rosenberg B, Krutchkoff D: Verrucous carcinoma: A possible viral pathogenesis. *Oral Surg* 59:52, 1985.
- Ellis GL, Corio RL: Spindle cell carcinoma of the oral cavity. *Oral Surg* 50:523, 1980.
- Ellis GL, Corio RL: Acinic cell adenocarcinoma: a clinicopathologic analysis of 294 cases. *Cancer* 52:542, 1988.
- Eneroth CM: Salivary gland tumors in the parotid gland, submandibular gland and the palate region. *Cancer* 27:1415, 1971.
- Evans HL, Batsakis JG: Polymorphous low-grade adenocarcinomas of minor salivary glands: A study of fourteen cases of a distinctive neoplasm. *Cancer* 53:935, 1984.
- Eveson JW, Cawson RA: Tumours of the minor (oropharyngeal) salivary glands: A demographic study of 336 cases. *J Oral Pathol* 14:500, 1985.
- Farman AG, Uys PB: Oral Kaposi's sarcoma. *Oral Surg* 39:288, 1975.
- Ficarra G, Berson AM, Silverman S Jr, et al: Kaposi's sarcoma of the oral cavity: A study of 134 patients with a review of the pathogenesis, epidemiology, clinical aspects and treatment. *Oral Surg* 66:543, 1988.
- Fonseca I, Martins AG, Soares J: Epithelial salivary gland tumors of children and adolescents in southern Portugal. *Oral Surg* 72:696, 1991.
- Forteza G, Colmenero B, López-Barea F: Osteogenic sarcoma of the maxilla and mandible. *Oral Surg* 62:179, 1986.
- Gardner DG, Bell MA, Wesley RK, Wysocki GP: Acinic cell tumors of minor salivary glands. *Oral Surg* 50:545, 1980.
- Harris M: Spindle cell squamous carcinoma: ultrastructural observations. *Histopathology* 6:197, 1982.
- Harwood AR, Osoba D, Hofstader SL, et al: Kaposi's sarcoma in recipients of renal transplants. *Am J Med* 67:759, 1979.
- Hatziotis J, Constantinidis H, Papanayotou PH: Metastatic tumors of the oral soft tissues. *Oral Surg* 36:544, 1973.
- Hirshberg A, Leibovich P, Buchner A: Metastases to the oral mucosa: analysis of 157 cases. *J Oral Pathol Med* 22:385, 1993.
- Hui KK, Luna MA, Batsakis JG, et al: Undifferentiated carcinomas of the major salivary glands. *Oral Surg* 69:76, 1990.
- Huvos AG, Rosen G, Dabska M, Marcove RC: Mesenchymal chondrosarcoma: A clinicopathologic analysis of 35 patients with emphasis on treatment. *Cancer* 51:1230, 1983.
- Isacson G, Shear M: Intraoral salivary gland tumors: A retrospective study of 201 cases. *J Oral Pathol.* 12:57, 1983.
- Jacoway JR, Nelson JF, Boyers RC: Adenoid squamous cell carcinoma (adenocanthoma) of the oral labial mucosa. A clinicopathologic study of fifteen cases. *Oral Surg* 32:444, 1971.
- Kato T, Takematsu H, Tomita Y, et al: Malignant melanoma of mucous membranes: A clinicopathologic study of 13 cases in Japanese patients. *Arch Dermatol* 113:216, 1987.
- Kaugars GE, Svirsky JA: Lung malignancies metastatic to the oral cavity. *Oral Surg* 51:179, 1981.
- La Riviere W, Pickett AB: Clinical criteria in diagnosis of early squamous cell carcinoma of the lower lip. *J Am Dent Assoc* 99:972, 1979.
- Lewis JE, Olsen KD, Weiland LH: Acinic cell carcinoma. Clinicopathologic review. *Cancer* 67:172, 1991.
- Lindqvist C, Teppo L, Sane J, et al: Osteosarcoma of the mandible: Analysis of nine cases. *J. Oral Maxillofac Surg* 44:759, 1986.
- Luna MA, Ordonez NG, Mackay B, et al: Salivary epithelial-myoeplithelial carcinomas of intercalated ducts: A clinical, electron microscopic, and immunocytochemical study. *Oral Surg* 59:482, 1985.
- Macht SD: Current concepts in melanoma. *Otolaryngol Clin North Am* 15:241, 1982.
- Mackie RM: The immune response in human malignant melanoma. *Clin Exp Dermatol* 1:23, 1976.
- Makepeace AR, Cannon SR: Malignant fibrous histiocytoma: The most common soft-tissue sarcoma. *Br J Hosp Med* 39:122, 1988.
- Mashberg A, Meyers H: Anatomical site and size of 222 early asymptomatic oral squamous cell carcinomas. *Cancer* 37:2149, 1976.
- Me Coy JM, Waldron CA: Verrucous carcinoma of the oral cavity. *Oral Surg* 52:623, 1981.
- Me Millan MD, Smillie AC, Ferguson JW: Malignant fibrous histiocytoma of the tongue: Report of a case and ultrastructural observations. *J Oral Pathol* 15:255, 1986.
- Milton GW: Malignant Melanoma of the Skin and Mucous Membranes. Churchill-Livingstone, London, 1977.
- Mitchell DA, Eveson JW, Ord RA: Polymorphous low-grade adenocarcinoma of minor salivary glands - A report of three cases. *Br J Oral Maxillofac Surg* 27:494, 1989.
- Modlin RL, Hofman FM, Kempf R, et al: Kaposi's sarcoma in homosexual men: An immunohistochemical study. *J Am Acad Dermatol* 8:620, 1983.
- Molnar L., Ronay P, Tapolcsanyi L: Carcinoma of the lip: Analysis of the material of 25 years. *Oncology* 29:101, 1974.
- Neiders ME: Early clinical diagnosis of oral cancer. *Int Dent J* 22:441, 1972.
- Nunnery EW, Kahn LB, Reddick RL, Lipper S: Heman-giopericytoma. *Cancer* 47:906, 1981.
- O'Day RA, Soule EH, Gores RJ: Soft tissue sarcomas of the oral cavity. *Mayo Clin Proc* 39:169, 1964.
- Ogus HD, Bennet MH: Carcinoma of the dorsum of the tongue: A rarity of misdiagnosis. *Br J Oral Surg* 16:115, 1978.
- Oikarinen VJ, Calonius PE, Sainio P: Metastatic tumors to the oral region. 1. An analysis of cases in the literature. *Proc Finn Dent Soc* 71:58, 1975.
- Pizer ME, Dubois DD: Adenoid cystic carcinoma of the upper lip. *Oral Surg* 59:70, 1985.
- Saw D: Fibrosarcoma of maxilla. *Oral Surg* 47:164, 1979.
- Sawyer DR, Nwoku AI, Kekere-Ekun AT: Chondrosarcoma of the jaws: Report of two cases. *J Oral Med* 42:30, 1987.
- Scully C: Viruses and cancer: Herpes viruses and tumors in the head and neck. *Oral Surg* 56:285, 1983.
- Seifert G: Histological classification of salivary gland tumours. WHO International Histological Classification of Tumours. Berlin, Springer, 1991.
- Seifert G: Histopathology of malignant salivary gland tumours. *Oral Oncol, Ear J Cancer* 2813:49, 1992.
- Shroyer KR, Creer RO: Detection of human papillomavirus DNA by in situ DNA hybridization and polymerase chain reaction in premalignant and malignant oral lesions. *Oral Surg* 71:708, 1991.
- Silverman S Jr.: *Oral Cancer*, 2nd ed. American Cancer Society, New York 1985.
- Slotweg PJ, Muller H: Verrucous hyperplasia or verrucous carcinoma: An analysis of 27 patients. *J Maxillofac Surg* 11:13, 1983.

- Solomon MP, Sutton AL: Malignant fibrous histiocytoma of the soft tissues of the mandible. *Oral Surg* 35:653, 1973.
- Spiro RH, Koss LG, Hajdu SI, Strong EW: Tumors of minor salivary origin. A clinicopathologic study of 492 cases. *Cancer* 31:117, 1973.
- Spiro RH, Alfonso AE, Farr HW, et al: Cervical node metastasis from epidermoid carcinoma of the oral cavity and oropharynx. *Am J Surg* 128:562, 1974.
- Tagagi M, Ishikawa G, Mori W: Primary malignant melanoma of the oral cavity in Japan with special reference to mucosal melanosis. *Cancer* 34:358, 1974.
- Tanzawa H, Uchiyama S, Sato K: Statistical observation of osteosarcoma of the maxillofacial region in Japan. *Oral Surg* 72:444, 1991.
- Thompson SH, Shear M: Fibrous histiocytomas of the oral and maxillofacial regions. *J Oral Pathol* 113:282, 1984.
- Tomich CE, Hutton CE: Adenoid squamous cell carcinoma of the lip: Report of cases. *J Oral Surg* 30:592, 1972.
- Triantafyllou A, Laskaris G: Clear cell adenocarcinoma of the oral cavity. *Iatriki* 43:331, 1983.
- Tsianos E, Barris C, Stefanaki-Nikou S, Drosos A: Mandibular gingival metastasis from a rectal adenocarcinoma. *J Oral Maxillofac Surg* 43:133, 1985.
- Van Hale HM, Handlers JP, Abrams AM, Strahs G: Malignant fibrous histiocytoma, myxoid variant metastatic to the oral cavity. Report of a case and review of the literature. *Oral Surg* 51:156, 1981.
- Watts SL, Brewer EE, Fry TL: Human papillomavirus DNA types in squamous cell carcinomas of the head and neck. *Oral Surg* 71:701, 1991.
- Welch RD, Hirsch SA, Davis RG: Melanoma with metastasis to an apical periodontal cyst. *Oral Surg* 59:189, 1985.
- Wesley RK, Mintz SM, Wertheimer FW: Primary malignant hemangioendothelioma of the gingiva. *Oral Surg* 39:103, 1975.
- Williams HK, Edwards MB, Adekeye EO: Mesenchymal chondrosarcoma. *Int J Oral Maxillofac Surg* 16:119, 1987.
- Zachariades N: Neoplasms metastatic to the mouth, jaws and surrounding tissues. *J Cranio Maxillofac Surg* 17:283, 1989.
- Zachariadis N, Papadakou A, Koundouris J, et al: Primary hemangioendotheliosarcoma of the mandible: Review of the literature and report of a case. *J Oral Surg* 38:288, 1980.
- 32. Malignancies of the Hematopoietic and Lymphatic Tissues**
- Ambrus JL, Ambrus M: Burkitt's lymphoma. *J. Med.* 12:385, 1981.
- Adatia AK: Significance of jaw lesions in Burkitt's lymphoma. *Br Dent J* 145:263, 1978.
- Barrett AP: A long-term prospective clinical study of oral complications during conventional chemotherapy for acute leukemia. *Oral Surg* 63:313, 1987.
- Barrett AP: Gingival lesions in leukemia. *J Periodontol* 55:585, 1984.
- Barrett AP: Long-term prospective clinical study of neutropenic ulceration in acute leukemia. *J Oral Med* 42:102, 1987.
- Barnett ML, Cole RJ: Mycosis fungoides with multiple oral mucosal lesions. *J Periodontol* 56:690, 1985.
- Bathard-Smith PJ, Coonar HS, Markus AF: Hodgkin's disease presenting intraorally. *Br J Oral Surg* 16:64, 1978-79.
- Bennett JH, Shankar S: Gingival bleeding as the presenting feature of multiple myeloma. *Br Dent J* 157:101, 1984.
- Biggar RJ, Barnett W, Mikl J, Nasca P: Cancer among New York men at risk of acquired immunodeficiency syndrome. *Int J Cancer* 43:979, 1989.
- Block P, Delden L, Van der Waal I: Non-Hodgkin's lymphoma of the hard palate. *Oral Surg* 47:445, 1979.
- Bressman E, Decter JA, Chasens AI, Sackler RS: Acute myeloblastic leukemia with oral manifestations. *Oral Surg* 54:401, 1982.
- Burkitt DP: The discovery of Burkitt's lymphoma. *Cancer* 51:1777, 1983.
- Canellos GP: Advances in chemotherapy for Hodgkin's and non-Hodgkin's lymphomas. *Semin Hematol* 25:1, 1988.
- Champlin R, Gale RP: Acute myelogenous leukemia: Recent advances in therapy. *Blood* 69:1551, 1987.
- Champlin R, Gale RP: Acute lymphoblastic leukemia: Recent advances in biology and therapy. *Blood* 73:2051, 1989.
- Curtis AB: Childhood leukemias: Initial oral manifestations. *J Am Dent Ass.* 81:159, 1971.
- Damm DD, White DK, Cibull ML, et al: Mycosis fungoides: Initial diagnosis via palatal biopsy with discussion of diagnostic advantages of plastic embedding. *Oral Surg* 58:413, 1984.
- De-The, G, Geser A, Day NE: Epidemiological evidence for causal relationship between Epstein-Barr virus and Burkitt's lymphoma from Uganda prospective study. *Nature* 274:756, 1978.
- Dolin S, Dewar JP: Extramedullary, plasmacytoma. *Am J Pathol* 32:83, 1956.
- Dreizen S, McCredie KB, Kreating MJ, Luna MA: Malignant gingival and skin » infiltrates << in adult leukemia. *Oral Surg* 55:572, 1983.
- Dreizen S, McCredie KB, Kreating MJ: Chemotherapy associated oral hemorrhages in adults with acute leukemia. *Oral Surg* 57:494, 1984.
- Edelson RL: Cutaneous T-cell lymphoma: Mycosis fungoides. Sezary syndrome and other variants. *J Am Acad Dermatol* 2:89, 1980.
- Eisenbud L, Sciubba J, Mir R, Sachs SA: Oral presentations in non-Hodgkin's lymphoma: A review of thirty-one cases. Part I. Data analysis. *Oral Surg* 56:151, 1983.
- Eisenbud I, Sciubba J, Mir R, Sachs SA: Oral presentations in non-Hodgkin's lymphoma: A review of thirty-one cases. Part II. Fourteen cases arising in bone. *Oral Surg* 57:272, 1984.
- Eisenbud L, Mir R, Sciubba J, Sachs SA: Oral presentations in non-Hodgkin's lymphoma: A review of thirty-one cases. Part III. Six cases in children. *Oral Surg* 59:44, 1985.
- Epstein JB, Voss NJS, Stevenson-Moore P: Maxillofacial manifestations of multiple myeloma. *Oral Surg* 57:267, 1984.
- Foon K, Gale RP: Staging and therapy of chronic lymphocytic leukemia. *Semin Hematol* 24:264, 1987.
- Freedman AS, Nadler LM: Cell surface markers in hematologic malignancies. *Semin Oncol* 14:193, 1987.
- Fucuda Y, Ishida T, Fujimoto M, et al: Malignant lymphoma of the oral cavity: Clinicopathologic analysis of 20 cases. *J Oral Pathol* 116:8, 1987.
- Gamble JW, Driscoll EJ: Oral manifestation of macroglobulinemia of Waldenström. *Oral Surg* 13:104, 1960.
- Glover GR, Nesbitt JA, North AF: Maxillary plasmacytoma (plasma cell myeloma). *Oral Surg* 64:680, 1987.
- Haidar Z: A review of non-Hodgkin's lymphoma of the oral cavity 1950-1980. *J Oral Med* 41:197, 1986.
- Hashimoto N, Kurihara K, Sakai H: Extramedullary plasmacytoma with crystal inclusions arising from the palatal tonsil. *J Oral Pathol* 12:309, 1983.
- Hockin WG, Golde DW: Polycythemia: evaluation and management. *Blood Rev.* 3:57, 1989.
- Howell RE, Handlers JP, Abrams AM, Melrose RJ: Extranodal oral lymphoma. Part 11. **Relationships between clinical features and the Lukes-Collins classification of 34 cases.** *Oral Surg* 64:597, 1987.

- Kabani S, Gataldo E, Folkerth R, et al: Atypical lymphohistiocytic infiltrate (pseudolymphoma) of the oral cavity. *Oral Surg* 66:587, 1988.
- Kurihara K, Sakai H, Hashimoto N: Russel body-like inclusions in oral B-lymphomas. *J Oral Pathol* 13:640, 1984.
- Laskaris G, Nicolis G, Capetanakis J: Mycosis fungoides with oral manifestations. *Oral Surg* 46:40, 1978.
- Laskaris G, Papavasiliou S, Bovopoulou O, Nicolis G: Association of oral pemphigus with lymphocytic leukemia. *Oral Surg* 50:244, 1980.
- Laskaris G, Stergiou G, Kittas C, Scully C: Hodgkin's disease involving the gingiva in AIDS. *Oral Oncol, Eur J Cancer* 2813:39, 1992.
- Laskaris G, Triantafyllou A, Bazopoulou E: Solitary plasmacytoma of oral soft tissues: Report of a case and review of literature. *Iatriki* 39:452, 1981.
- Lehrer S, Roswit B, Federman O: The presentation of malignant lymphoma in the oral cavity and pharynx. *Oral Surg* 41:441, 1976.
- Loh HS: A retrospective evaluation of 23 reported cases of solitary plasmacytoma of the mandible, with an additional case report. *Br J Oral Maxillofac Surg* 22:216, 1984.
- Lynch MA, Ship 11: Initial oral manifestations of leukemia. *J Am Dent Assoc* 75:932, 1967.
- Matthews JB, Basu MK: Plasma cell lesions within the oral tissues: Immunoperoxidase staining of routinely fixed and processed tissue. *Oral Surg* 54:414, 1982.
- Poole AG, Marchetta FC: Extramedullary plasmacytoma of the head and neck. *Cancer* 22:14, 1968.
- Raubenheimer EJ, Dauth J, De Coning JP: Multiple myeloma presenting with extensive oral and perioral amyloidosis. *Oral Surg* 61:492, 1986.
- Regezi JA, Zarbo RJ, Keren OF: Plasma cell lesions of the head and neck: Immunofluorescent determination of clonality from formalin-fixed, paraffin-embedded tissue. *Oral Surg* 56:616, 1983.
- Rog RP: Beware of malignant lymphoma masquerading as facial inflammatory processes. *Oral Surg* 71:415, 1991.
- Rosenberg SA, Diamond HD, Jaslowitz B, Craver LF: Lymphosarcoma: A review of 1269 cases. *Medicine (Baltimore)* 40:31, 1961.
- Sariban E, Donahue A, Magrath IT: Jaw involvement in American Burkitt's lymphoma. *Cancer* 53:1777, 1984.
- Smith JL, Butler JJ: Skin involvement in Hodgkin's disease. *Arch Dermatol* 114:1832, 1978.
- Stafford R, Sonis S, Lockhart P, Sonis A: Oral pathoses as diagnostic indicators in leukemia. *Oral Surg* 50:134, 1980.
- Tabachnick TT, Levine B: Multiple myeloma involving the jaws and oral soft tissues. *J Oral Surg* 34:931, 1976.
- Takahashi H, Cheng J, Fujita S, et al: Primary malignant lymphoma of the salivary gland: a tumor of mucosa-associated lymphoid tissue. *J Oral Pathol Med.* 21:318, 1992.
- Tirelli U, Carbone A, Monfardini S, et al: Malignant tumors in patients with human immunodeficiency virus infection: A report of 580 cases. *J Clin Oncol* 7:1582, 1989.
- Tomich CM, Shafer WG: Lymphoproliferative disease of the hard palate: Clinicopathologic entity. *Oral Surg* 39:754, 1975.
- Wahlin YB: Salivary secretion rate, yeast cells, and oral candidiasis in patients with acute leukemia. *Oral Surg* 71:689, 1991.
- Wahlin YB, Matsson L: Oral mucosal lesions in patients with acute leukemia and related disorders during cytotoxic therapy. *Scand J Dent Res* 96:128, 1988.
- Waldenström J: Macroglobulinemia. *Adv Metab. Disord* 2:115, 1965.
- Waldenström JG: Macroglobulinemia - A review. *Haematologica* 71:437, 1986.
- Webb HE: Harrison EG, Masson JK, ReMine WH: Solitary extramedullary myeloma (plasmacytoma) of the upper part of respiratory and oropharynx. *Cancer* 15:1142, 1962.
- White GE: Oral manifestations of leukemia in children. *Oral Surg* 29:420, 1970.
- Wong DS, Fuller LM, Butler JJ, Shullenberger CC: Extranodal non-Hodgkin's lymphoma of the head and neck. *Am J Roentgenol Radium Ther Nucl Med* 123:471, 1975.
- Wright JM, Balciunas BA, Huus JH: Mycosis fungoides with oral manifestations. *Oral Surg* 51:24, 1981.
- Yoshimura Y, Takada K, Kawai N, et al: Two cases of plasmacytoma in the oral cavity. *Int J Oral Surg* 5:82, 1976.

### 33. Benign Tumors

- Abbey LM, Page DG, Sawyer DR: The clinical and histopathologic features of a series of 464 oral squamous cell papillomas. *Oral Surg* 49:419, 1980.
- Artzi Z, Taicher S, Nass D: Neurilemmoma of the mental nerve. *J Oral Maxillofac Surg* 49:196, 1991.
- Baden E, Pierce M, Selman AJ, et al: Intra-oral papillary cystadenoma lymphomatosum. *J Oral Surg* 34:533, 1976.
- Bayer RA, Harman FG: Intra-oral surgical management of cystic hygroma. *Br J Oral Surg* 14:36, 1976.
- Buchner A: Peripheral odontogenic fibroma. *J Craniomaxillofac Surg* 17:134, 1989.
- Buchner A, Hansen LS: Melanotic macule of the oral mucosa. *Oral Surg* 48:244, 1979.
- Buchner A, Hansen LS: Pigmented nevi of the oral mucosa: A clinicopathologic study of 32 new cases and review of 75 cases from the literature. *Oral Surg* 49:55, 1980.
- Buchner A, Hansen LS: The histomorphologic spectrum of peripheral ossifying fibroma. *Oral Surg* 63:452, 1987.
- Buchner A, Hansen LS: Pigmented nevi of the oral mucosa: A clinicopathologic study of 36 new cases and review of 155 cases from the literature. *Oral Surg* 63:566, 1987.
- Chau MNY, Radden BG: Intra-oral salivary gland neoplasms: A retrospective study of 98 cases. *J Oral Pathol* 15:339, 1986.
- Chen SY, Fantasia JE, Miller AS: Myxoid lipoma of oral soft tissue. *Oral Surg* 57:300, 1984.
- Chen SY, Miller AS: Neurofibroma and schwannoma of the oral cavity. *Oral Surg* 47:522, 1979.
- Cherrick HM, Dunlap CL, King OH: Leiomyomas of the oral cavity: Review of the literature and clinicopathologic study of seven new cases. *Oral Surg* 35:54, 1973.
- Chou L, Hansen LS, Daniels TE: Choristomas of the oral cavity: A review. *Oral Surg* 72:584, 1991.
- Damm DD, Neville BW: Oral leiomyomas. *Oral Surg* 47:343, 1979.
- Elzay RP, Dutz W: Myxomas of the paraoral-oral soft tissues. *Oral Surg* 45:246, 1978.
- Eneroth CM, Blanck C, Jacobsson PA: Carcinoma in pleomorphic adenoma of the parotid gland. *Acta Otolaryngol* 66:477, 1968.
- Enzinger FM, Weiss SW: *Soft-Tissue Tumors*. C. V. Mosby, St. Louis, 1983.
- Eveson JW, Cawson RA: Tumours of the minor (oropharyngeal) salivary glands: A demographic study of 336 cases. *J Oral Pathol* 14:500, 1985.
- Epker BN, Henny FA: Intraoral sebaceous gland adenoma. *Cancer* 27:987, 1971.
- Erlandson RA, Cardon CC, Higgins PJ: Histogenesis of benign pleomorphic adenoma (mixed tumor) of the major salivary glands: An ultrastructural and immunohistochemical study. *Am J Surg Pathol* 8:803, 1984.

- Fantasia JE, Miller AS: Papillary cystadenoma lymphomatosum arising in minor salivary glands. *Oral Surg* 52:411,1981.
- Feenstra K, Hadders HN, Rittersma H: Een benign choristoom (osteoom) in de weke delen van het palatum. *Ned Tijdschr Tandheelkd* 84:200, 1977.
- Fonsesa I, Martins AG, Soares J: Epithelial salivary gland tumors of children and adolescents in southern Portugal. *Oral Surg* 72:696, 1991.
- Freedman DJ, Luzzi A, Pellegrino P, et al: Benign and malignant fibrohistiocytic tumors. *J Am Pediatr Med Assoc* 77:544,1987.
- Green TL, Leighty SM, Waltes R: Immunohistochemical evaluation of oral myxoid lesions. *Oral Surg* 73:469, 1992.
- Hatziotis J: Lipoma of the oral cavity. *Oral Surg* 36:511, 1971.
- Helwing EB, Hackney VC: Syringadenoma papilliferum. Lesions with and without naevus sebaceous and basal cell carcinoma. *Arch Dermatol* 171:361, 1955.
- Hidano A: Natural history of nevus of Ota. *Arch Dermatol* 95:187,1967.
- Hoffman S, Martinez MG: Fibrous histiocytomas of the oral mucosa. *Oral Surg* 52:277, 1981.
- Houston GD: The giant cell fibroma. A review of 464 cases. *Oral Surg* 53:582, 1982.
- Ide F, Umemura S: A microscopic focus of traumatic neuroma with intralésional glandular structures: An incidental finding. *Oral Surg* 57:68, 1984.
- Isacson G, Shear M: Intraoral salivary gland tumors: A retrospective study of 201 cases. *J Oral Pathol* 12:57,1983.
- Judd PL, Pedod D, Harrop K, Becker J: Melanotic neuroectodermal tumor of infancy. *Oral Surg* 69:723, 1990.
- Kakarantza-Angelopouou E, Nicolatou O, Anagnostopoulou S: Verruciform xanthoma of the palate: Case report with electron microscopy. *J Oral Maxillofac Surg* 49:409, 1991.
- Kerpel MA, Freedman PD, Lumerman H: The papillary cystadenoma of minor salivary gland origin. *Oral Surg* 46:820, 1978.
- Krolls SO, Jacoway JR, Alexander WA: Osseous choristomas (osteomas) of intraoral soft tissues. *J Oral Surg* 32:588, 1971.
- Laskaris G, Giannouloupoulos A, Kariaba E, Arsenopoulos A:** Melanotic neuroectodermal tumor of infancy. *Mat Med Greca* 8:226, 1980.
- Laskaris G, Patsakas A, Papadakou A, Angelopoulos A: Melanotic freckle of Hutchinson's of the oral mucosa. *Mat Med Greca* 6:211, 1978.
- Laskaris G, Skouteris C, Angelopoulos A: Compound nevus of the oral mucosa. *Iatriki* 34:457, 1978.
- Lea PJ, Pawlowski A: Human melanocytic naevi. *Acta Derm Venereol [Suppl] (Stockh)* 127:5, 1986.
- Levine J, Krutchkoff DJ, Eisenberg E: Monomorphic adenoma of minor salivary glands: A reappraisal and report of nine new cases. *J Oral Surg* 39:101, 1981.
- Lovas GL, Wysocki GP, Daley TD: The oral blue nevus: Histogenetic implications of its ultrastructural features. *Oral Surg* 55:145, 1983.
- Louridis O, Markopoulos A, Laskaris G: Junctional nevus of the oral mucosa. Report of a case. *Odontostomatol Progr* 24:195,1970.
- Luna MA, Stimson PG, Bardwill JM: Minor salivary gland tumors of the oral cavity. *Oral Surg* 25:71, 1968.
- Mammino JJ, Vidmar DA: Syringocystadenoma papilliferum. *Int J Dermatol* 30:763, 1991.
- Martis C: Parotid benign tumors: Comments on surgical treatment of 263 cases. *Int J Oral Surg* 12:211, 1983.
- Mc Coy JM, Mincer HH, Turner JE: Intraoral ancient neurilemoma (ancient schwannoma). *Oral Surg* 56:174, 1983.
- Mesa ML, Sohneider LC, Northington L: Osteoma of the buccal mucosa. *J Oral Maxillofac Surg* 40:684,1982.
- Nakahata A, Deguchi H, Yanagawa T, et al: Co-expression of intermediate-sized filaments in sialadenoma papilliferum and other salivary gland neoplasms. *J Oral Pathol Med* 19:313,1990.
- Niizuma K: Syringocystadenoma papilliferum: Light and electron microscopic studies. *Acta Derm Venerol (Stockh)* 56:327, 1976.
- Nowparast B, Howell FV, Rick GM: Verruciform xanthoma. *Oral Surg* 51:619, 1981.
- Orlian A, Salman L, Reddi T, et al: Sebaceous adenoma of the oral mucosa. *J Oral Med* 42:38, 1987.
- Papanicolaou S, Eversole LR: Glandular structures in neural sheath neoplasms. *Oral Surg* 53:69, 1982.
- Papanicolaou S, Pierrakou E, Patsakas A: Intraoral blue nevus. *J Oral Med* 40:32, 1985.
- Papanicolaou SJ, Triantafyllou AG: Sialadenoma papilliferum of the oral cavity: A case report and review of the literature. *J Oral Med* 42:57, 1987.
- Pettinato G, Manivel JC, D'Amore ESG, et al: Melanotic neuroectodermal tumor of infancy. A reexamination of a histogenetic problem based on immunohistochemical, flow cytometric and ultrastructural study of 10 cases. *Am J Surg Pathol* 15:233, 1991.
- Pollack RP: Neurofibroma of the palatal mucosa: a case report. *J Periodontol* 61:456, 1990.
- Pulitzer DR, Beed RJ: Nerve-sheath myxoma (perineural myxoma). *Am J Dermatopathol* 7:409, 1985.
- Rapidis A: Lipoma of the oral cavity. *Int J Oral Surg* 11:30, 1982.
- Rapidis A, Triantafyllou A: Myxoma of the oral soft tissue. *J Oral Maxillofac Surg* 41:188,1983.
- Rennie JS, McDonald DG, Critchlow HA: Sialadenoma papilliferum. A case report and review of the literature. *Int J Oral Surg* 13:452, 1984.
- Richards D: Neurofibroma of the oral cavity. *Br J Oral Surg* 21:36,1983.
- Richards H, Strider JW, Short SG, et al: Large peripheral osteoma arising from the genial tubercle area. *Oral Surg* 61:268, 1986.
- Seifert G, Miehke A, Haubrich J, Chilla R: Diseases of the Salivary Glands. Georg Thieme Verlag, Stuttgart, 1986.
- Shapiro L, Zegarelli DJ: The solitary labial lentigo: A clinicopathologic study of 20 cases. *Oral Surg* 31:87, 1971.
- Sist TC, Greene GW: Traumatic neuroma of the oral cavity. *Oral Surg* 51:394, 1981.
- Sklavounou A, Laskaris G, Angelopoulos A: Verruciform xanthoma of the oral mucosa. *Dermatologica* 164:41,1982.
- Slabbert HV, Altini M: Peripheral odontogenic fibroma: A clinicopathologic study. *Oral Surg* 72:86, 1991.
- Slootweg PJ: Heterologous tissue elements in melanotic neuroectodermal tumor of infancy. *J Oral Pathol. Med* 21:90,1992.
- Slootweg PJ, Muller H: Verrucous hyperplasia or verrucous carcinoma. *J Maxillofac Surg* 11:13, 1983.
- Sohneider LC, Dolinsky HB, Grodjesk JE: Solitary peripheral osteoma of the jaw: Report of case and review of the literature. *J Oral Surg* 38:452, 1980.
- Spiro RH: Salivary neoplasms: Overview of 35-year experience with 2807 patients. *Head Neck Surg* 8:177, 1986.
- Stewart CM, Watson RE, Eversole LR, et al: Oral granular tumors: A clinicopathologic and immunocytochemical study. *Oral Surg* 65:427, 1988.
- Thompson SH, Shear M: Fibrous histiocytomas of the oral and maxillofacial regions. *J Oral Pathol* 13:284,1984.

- Tosios K, Laskaris G, Eveson J, Scully C: Benign cartilaginous tumor of the gingiva: a case report. *Int J Oral Maxillofac Surg* 22:231, 1993.
- Triantafyllou A, Laskaris G: Papillary syringadenoma of the lower lip: Report of a case. *J Oral Maxillofac Surg* 45:884, 1987.
- Triantafyllou A, Sklavounou A, Laskaris G: Benign fibrous histiocytoma of the oral mucosa. *J Oral Med* 40:36, 1985.
- Waldron CA, El-Mofty SK, Gnepp DR: Tumors of the intra-oral salivary glands: A demographic and histologic study of 426 cases. *Oral Surg* 66:323, 1988.
- Weathers DR, Callihan MD: Giant cell fibroma. *Oral Surg* 37:374, 1974.
- Weathers DR, Corio RL, Grawford BE, et al: The labial melanotic macule. *Oral Surg* 42:196, 1976.
- Weber A, van Heerden WFP, Ligthelm AJ, Raubenheimer EJ: Diffuse peripheral odontogenic fibroma: Report of 3 cases. *J Oral Pathol Med* 21:82, 1992.
- Wesley RK, Zielinski RJ: Osteocartilaginous choristoma of the tongue: Clinical and histopathologic considerations. *J Oral Surg* 36:59, 1978.
- Zachariades N: Schwannoma of the oral cavity: Review of the literature and report of a case. *J Oral Med* 39:41, 1984.
- Zachariades N, Mezitis M, Vairaktaris E, et al.: Benign neurogenic tumors of the oral cavity. *Int J Oral Maxillofac Surg* 16:70, 1987.
- Zain RB, Fei YJ: Fibrous lesions of the gingiva: A histopathologic analysis of 204 cases. *Oral Surg* 70:466, 1990.
- 34. Other Salivary Gland Disorders**
- Abrams AM, Melrose RJ, Howell FV: Necrotizing sialometaplasia: A disease simulating malignancy. *Cancer* 32:130, 1973.
- Anneroth G, Hansen LS: Necrotizing sialometaplasia: The relationship of its pathogenesis to its clinical characteristics. *Int J Oral Surg* 11:283, 1982.
- Bertram U: Xerostomia. *Acta Odontol Scand (Suppl)* 49:1, 1967.
- Chaudhry AP, Yamane GM, Salman L, et al: Necrotizing sialometaplasia of palatal minor salivary glands: A report on 2 cases. *J Oral med* 40:2, 1985.
- Epivatianos A, Harrison JD: The presence of microcalculi in normal human submandibular and parotid salivary glands. *Arch Oral Bio* 134:261, 1989.
- Epstein J, Schubert M: Synergistic effect of sialogogues in management of xerostomia after radiation therapy. *Oral Surg* 64:179, 1987.
- Harrison JD, Epivatianos A: Production of microliths and sialadenitis in rats by a short combined course of isoprenaline and calcium gluconate. *Oral Surg* 73:585, 1992.
- Kinney RB, Burton CS, Vollmer RT: Necrotizing sialometaplasia: A sheep in Wolf's clothing. *Arch Dermatol* 122:208, 1986.
- Lancaster JE, Hughes KW: Mikulicz's disease involving multiple salivary glands. *Oral Surg* 16:1266, 1963.
- Mesa ML, Gertler RS, Schneider LC: Necrotizing sialometaplasia: Frequency of histologic misdiagnosis. *Oral Surg* 57:71, 1984.
- Patton DW: Recurrent calculus formation following removal of the submandibular salivary gland. *Br J Oral Maxillofac Surg* 25:15, 1987.
- Pullen PA, Miller AS: Sialolithiasis of accessory salivary glands. Review of 55 cases. *J Oral Surg* 30:832, 1972.
- Rauch, S.: Die Speicheldrüsen des Menschen. Georg Thieme, Stuttgart, 1959.
- Seifert G, Miehlke A, Haubrich J, Chilla R: Diseases of the salivary glands. Pathology-diagnosis-treatment-facial surgery. Georg Thieme Verlag, Stuttgart-New York, 1986.
- 35. Tumorlike Lesions**
- Angelopoulos AP: Pyogenic granuloma of the oral cavity: Statistical analysis of its clinical features. *J Oral Surg* 29:840, 1971.
- Apisanthanarax P: Granular cell tumor. An analysis of 16 cases and review of the literature. *J Am Acad Dermatol* 5:171, 1981.
- Damm DD, Cibull ML, Geissler RH, et al: Investigation into the histogenesis of congenital epulis of the newborn. *Oral Surg* 76:205, 1993.
- Darski K, Stoll HL Jr: Cutaneous horn arising in chronic discoid lupus erythematosus. *Arch Dermatol* 121:837, 1985.
- De la Monte SM, Radowsky M, Hood AF: Congenital granular-cell neoplasms: An unusual case report with ultrastructural findings and a review of the literature. *Am J Dermatopathol* 18:57, 1986.
- Eversole LR, Rovin S: Reactive lesions of the gingiva. *J Oral Pathol* 1:30, 1972.
- Fuhr AA, Krogh PHJ: Congenital epulis in the newborn. *J Oral Surg* 26:61, 1972.
- Giansanti JS, Waldron CA: Peripheral giant cell granuloma: Review of 720 cases. *J Oral Surg* 27:787, 1969.
- Henefer EP, Abaza NA, Anderson SP: Congenital granular-cell epulis. *Oral Surg* 57:515, 1979.
- Katsikeris N, Kakarantza E, Angelopoulos A: Peripheral giant cell granuloma. Clinicopathologic study of 224 new cases and review of 956 reported cases. *Int J Oral Maxillofac Surg* 17:94, 1988.
- Lack EE, Worsham GF, Callihan MD, et al: Gingival granular cell tumors of the newborn (congenital » epulis«). A clinical and pathology study of 21 patients. *Am J Surg Pathol* 5:37, 1981.
- Lifshitz MS, Flotte TJ, Greco MA: Congenital granular cell epulis. Immunohistochemical and ultrastructural observations. *Cancer* 53:1845, 1984.
- Reis LT, Perini MO, Do Rosario M, et al: Cutaneous horn on the glans. *Int J Dermatol* 17:410, 1978.
- Rohrer MD, Young SK: Congenital epulis (gingival granular cell tumor): Ultrastructural evidence of origin from pericytes. *Oral Surg* 53:56, 1982.
- Samant A, Mallick CP, Chabra S, et al: Gingivitis and periodontal disease in pregnancy. *J. Periodontol* 47:419, 1976.
- Schwartz RA, Stoll HL Jr: Cutaneous horn. In: Fitzpatrick TB, Eisen AZ, Wolff K, et al (eds): *Dermatology in General Medicine*, 3rd ed McGraw-Hill, 1987, p. 736.
- Vilmann A, Vilmann P, Vilmann H: Pyogenic granuloma: Evaluation of oral conditions. *Br J Oral Maxillofac Surg* 24:376, 1986.
- Welbury RR: Congenital epulis of the newborn. *Br J Oral Surg* 18:238, 1980.

# Index

Page numbers in bold refer to illustrations.

- A**
- abscess
    - oral soft tissue, 146, 147
    - periodontal, 86, 87
    - peritonsillar, 146, 147
  - acanthosis nigricans
    - benign, 22, 22, 23
    - malignant, 22, 220, 221
  - acinic cell carcinoma, 278, 279
  - acquired immune deficiency syndrome (AIDS), 129, 132, 136, 137, 139, 141, 286
    - see also* HIV infection
  - acrodermatitis enteropathica, 222, 223
  - acromegaly, 252, 253
  - acrylic resin
    - allergic stomatitis, 83, 83
    - burn, 58, 59
  - Actinomyces israelii*, 162
  - actinomycosis, 162, 163
  - Addison's disease, 250, 251
  - adenocarcinoma, 282, 283
    - clear cell, 282, 283
    - polymorphous low-grade, 284, 285
  - adenoid cystic carcinoma, 280, 281
  - adenoma
    - pleomorphic, 328, 329
    - malignant, 282, 283
    - sebaceous, 320, 321
  - adenoma sebaceum, 32, 33
  - adrenocortical insufficiency, 250
  - adrenocorticotrophic hormone (ACTH), 250
  - agranulocytosis, 230, 231
    - infantile genetic, 228
  - agricultural chemical burn, 62, 63
  - AIDS, 129, 132, 136, 137, 139, 141, 286
    - see also* HIV infection
  - AIDS-related complex (ARC), 129
  - alcohol burn, 58, 59
  - allergic stomatitis
    - due to acrylic resin, 83, 83, 84
    - due to eugenol, 84, 84
  - allergy to locally applied chemical agents, 83-4
  - alveolar mucosa
    - adenoid cystic carcinoma, 281
    - in Cowden's disease, 37
    - dermatitis herpetiformis lesions, 213
    - in dyskeratosis follicularis, 23
    - leukoplakia, 261
    - malignant fibrous histiocytoma, 287
    - malignant melanoma, 289
    - and materia alba, 79
    - metastatic carcinoma, 292
    - mucous patches in secondary syphilis, 153
    - squamous cell carcinoma, 273
    - in tuberous sclerosis, 33
    - ulcer, in histoplasmosis, 171
    - verrucous hyperplasia, 305
  - alveolar ridge, maxillary, atrophy, 52, 53
  - amalgam tattoo, 77, 77
  - amyloidosis, 236-8
    - primary systemic, 236, 236, 237
    - secondary, 238
  - anatomic variants, normal, 2, 3
  - anemia
    - aplastic, 232, 233
    - iron deficiency, 226, 227
    - pernicious, 226-8, 227
  - angiofibroma, facial, in tuberous sclerosis, 33
  - angiomas, epithelial, in HIV infection, 136
  - angioneurotic edema, 74, 75
  - angio-osteohypertrophy, 34
  - angular cheilitis, 102, 103, 166, 167
    - in ariboflavinosis, 249
    - in HIV infection, 130, 131
    - in Plummer-Vinson syndrome, 226, 227
    - in porphyria cutanea tarda, 243
  - ankyloglossia, 6, 6
  - anodontia, in hypohidrotic ectodermal dysplasia, 19
  - anomalies, developmental, 4-13
  - antibiotic-induced stomatitis, 68, 69
  - antimalarial drugs, and pigmentation, 74, 75
  - aphthous ulcer
    - in HIV infection, 140, 140
    - major, 178, 179
    - minor, 177, 177
    - recurrent, 177
  - aplastic anemia, 232, 233
  - arachnodactyly, 42
  - ariboflavinosis, 248, 249
  - aspirin burn, 58, 58
  - atrophic glossitis, 156, 157
    - in tertiary syphilis, 266, 267
  - autoimmune diseases, 188-97
  - azathioprine, ulcerations due to, 70, 71
  - azidothymidine (AZT), 140
    - and pigmentation, 74, 75
- B**
- bacterial infections, 142-63
  - basal cell carcinoma, 278, 279
  - Behget's syndrome, 180-2, 180-2
  - benign fibrous histiocytoma, 314, 315
  - benign lymphoepithelial lesion, 196, 197
  - benign tumors, 304-30
  - bifid tongue, 8, 9
  - bifid uvula, 6, 7
  - biliary cirrhosis, primary, 196, 197
  - bismuth deposition, 78, 79
  - biting, chronic, oral mucosa, 46, 47
  - Blastomyces dermatidis*, 170
  - blastomycosis
    - North American, 170, 171
    - South American, 172, 173
  - blepharitis, in dyskeratosis congenita, 17
  - Bloom syndrome, and benign acanthosis nigricans, 22
  - blue nevus, 324, 325
  - Bohn's nodules, 112
  - Bourneville-Pringle syndrome, 32
  - brown giant cell tumor, in primary hyperparathyroidism, 252, 253
  - buccal cellulitis, 148, 149
  - buccal mucosa
    - in actinomycosis, 163
    - acute abscess, 147
    - in Addison's disease, 251
    - basal cell carcinoma, 279
    - in bullous lichen planus, 227

- buccal mucosa (*cont.*)  
 cobblestone appearance, in  
   Crohn's disease, 187  
 condyloma acuminatum, in HIV  
   infection, 133  
 in dermatomyositis, 193  
 in discoid lupus erythematosus, 189  
 in epidermolysis bullosa  
   acquisita, 214  
   simplex, 25  
 in erosive lichen planus, 216  
 erythroplasia, 263  
 fibroma, 307  
 Fordyce's granules, 5  
 in gonococcal stomatitis, 159  
 hemorrhagic bullae, in cicatricial  
   pemphigoid, 207  
 hereditary benign intraepithelial  
   dyskeratosis, 15  
 in Hodgkin's disease, 299  
 in idiopathic thrombocytopenic  
   purpura, 233  
 intramucosal nevus, 323  
 lentigo maligna, 327  
 lesions, in focal epithelial hyper-  
   plasia, 128  
 leukoedema, 3  
 leukoplakia, 259, 260  
 lichen planus and carcinoma  
   in situ, 269  
 lipoma, 311  
 melanotic spots, due to azidothy-  
   midine, 75  
 molluscum contagiosum, 127  
 mucous patches in secondary  
   syphilis, 153  
 myxoma, 311  
 necrotic pseudomembrane, in  
   uremic stomatitis, 235  
 papilloma, 305  
 in Peutz-Jeghers syndrome, 29  
 pigmentation  
   due to chloroquine, 75  
   in hemochromatosis, 243  
   in pigmented lichen planus, 219  
   polycythemia vera, 296, 297  
   in Reiter's syndrome, 183  
   in reticular lichen planus, 215  
   shrapnel-induced nodule, 53  
   squamous cell carcinoma, 273, 274  
   tuberculous ulcer, 160  
   vegetating lesions, in pemphigus  
     vegetans, 203  
   verrucous carcinoma, 275  
   white sponge nevus, 15
- bullae**  
 epidermolysis bullosa, 24-6, 25,  
 26,27  
 traumatic, 46, 46
- bullous pemphigoid**, 210, 211, 212  
 and desquamative gingivitis, 90
- Burkitt's lymphoma**, 300, 301
- burns**  
 acrylic resin, 58, 59  
 agricultural chemicals, 62, 63  
 alcohol, 58, 59  
 aspirin, 58, 58  
 chlorine compounds, 62, 63  
 eugenol, 56, 57  
 iodine, 58, 59  
 paraformaldehyde, 60, 61  
 phenol, 56, 57  
 silver nitrate, 60, 61  
 sodium hypochlorite, 60, 61  
 sodium perborate, 60, 60  
 thermal, 66, 67  
 trichloroacetic acid, 56, 57
- butterfly appearance**, in discoid lupus  
 erythematosus, 188, 189
- C**
- cancer**, *see* adenocarcinoma; carci-  
 noma; malignant neoplasms;  
 tumors
- cancerum oris**, 142, 143
- Candida**  
 endocrinopathy syndrome, 170, 171  
 infection, and lichen planus, 218
- Candida albicans**, 164  
 and acrodermatitis enteropathica,  
 222  
 and angular cheilitis, 102  
 and denture stomatitis, 50, 168, 169  
 and hairy tongue, 94  
 in HIV infection, 130  
 and leukoplakia, 258, 264, 264  
 and median lip fissure, 102  
 and median rhomboid glossitis, 92  
 and plasma cell gingivitis, 88
- candidosis**, 164-70  
 in antibiotic-induced stomatitis, 68  
 chronic mucocutaneous, 168, 169  
 erythematous, 131, 166,166  
 in HIV infection, 130, 130, 131  
 nodular, 166, 167  
 primary oral, 164-8  
 pseudomembranous, 164, 165  
   in HIV infection, 130  
 secondary oral, 168-70
- Cannon's disease**, 14
- capillary hemangioma**, 317
- carcinoma**  
 acinic cell, 278, 279  
 adenoid cystic, 280, 281  
 basal cell, 278, 279  
 buccal mucosa, 269  
 and lichen planus, 268, 269  
 lymphoepithelial, 276, 277  
 metastatic, 290, 291-2  
 mucoepidermoid, 280, 281  
 spindle cell, 276, 277  
 squamous cell, 270, 271-5  
   adenoid, 276, 277  
   lip, 269  
   and submucous fibrosis, 266,  
     267  
   tongue, 267, 269  
 verrucous, 274, 275, 276  
   in dyskeratosis congenita, 18  
*see also* adenocarcinoma; malig-  
 nant neoplasms; precancerous  
 conditions; tumors
- cavernous hemangioma**, 317  
 and phleboliths, 78, 79
- cellulitis**, buccal, 148, 149
- chancroid**, 158, 159
- cheilitis**  
 actinic, 102, 103  
 angular, 102, 103, 166, 167  
   in ariboflavinosis, 249  
   in HIV infection, 130, 131  
   in Plummer-Vinson syndrome,  
     226,227  
   in porphyria cutanea tarda, 243
- contact**, 104, 105  
 due to retinoids, 76, 76  
 exfoliative, 104, 105  
 glandularis, 104, 105  
 granulomatosa, 106, 107, 256  
 plasma cell, 106, 107
- chemical agents**  
 and allergy, 83-4  
 and oral lesions, 56-63
- chickenpox**, 120, 121
- childhood**, *see* infantile; juvenile;  
 newborns
- childhood cicatricial pemphigoid**, 211
- chlorine compound burn**, 62, 63
- chloroquine**, and pigmentation, 74, 75
- chondroectodermal dysplasia**, 28, 28
- chondrosarcoma**, 288, 289
- chronic biting**, oral mucosa, 46, 47
- cicatricial pemphigoid**, 207-9,  
 207-10,211  
 childhood, 210, 211  
 and desquamative gingivitis, 90,  
 91
- cigarette smoker's lip lesion**, 66, 67
- circumvallate papillae**, hypertrophy,  
 98,99
- cirrhosis**, primary biliary, 196, 197
- clear cell adenocarcinoma**, 282, 283
- cleft lip**, 6, 7  
 in oro-facial digital syndrome, 38
- cleft palate**, 6, 7  
 in oro-facial digital syndrome, 38
- cleidocranial dysplasia**, 36, 37
- cobblestone appearance**, buccal  
 mucosa, in Crohn's disease,  
 187
- compound nevus**, 324, 325
- condyloma acuminatum**, 126, 127  
 in HIV infection, 132, 133
- condylomata lata**, 154, 155
- congenital epulis of newborn**, 340,  
 340
- congenital lip pits**, 4, 5

- congenital neutropenia, 228, 229  
 congenital porphyria, 242  
 congenital syphilis, 156, 157  
 conjunctivitis  
   in Behçet's syndrome, 182  
   in cicatricial pemphigoid, 209  
   in paraneoplastic pemphigus, 206  
   in Reiter's syndrome, 183  
 connective tissue disease, mixed,  
   194, 195  
 cotton roll stomatitis, 48, 49  
 Cowden's disease, 36, 37  
 Coxsackie virus  
   and acute lymphonodular pharyngitis, 120  
   and hand-foot-and-mouth disease, 122  
   and herpangina, 120  
 crenated tongue, 98, 99  
 CREST syndrome, 190, 193  
 Crohn's disease, 186, 187  
   and cheilitis granulomatosa, 106  
   and median lip fissure, 102  
 Crouzon syndrome, and benign acanthosis nigricans, 22  
 cunnilingus, and lingual frenum ulcer, 48, 49  
 cutaneous horn, 320, 321  
 cutaneous leishmaniasis, 174, 175  
 cyclic neutropenia, 228-30, 229  
 cyclosporine, and gingival hyperplasia, 72, 73  
 cyst  
   branchial cleft, 110, 111  
   dermoid, 110, 111  
   eruption, 112, 113  
   gingival  
     of adult, 112, 113  
     of newborn, 112, 113  
   lymphoepithelial, 110, 111  
   nasolabial, 114, 115  
   palatine papilla, 114, 114  
   soft-tissue, 108-15  
   thyroglossal duct, 114, 115  
 cystadenoma lymphomatous, papillary, 330, 330  
 cystic fibrosis, 244, 244  
 cystic hygroma, 318, 319
- D
- Darier-White disease, 22  
 dentures  
   and epulis fissuratum, 50  
   and fibrous hyperplasia, 50  
   and maxillary alveolar ridge atrophy, 52  
   and negative pressure hyperplasia, 52  
   and papillary hyperplasia of the palate, 50  
   stomatitis, 50, 51, 168, 169
- dermatitis  
   herpetiformis, 212, 213  
   lip-licking, 222, 223  
   perioral, 222, 223  
 dermatomyositis, 192, 193  
 dermoid cyst, 110, 111  
 desquamative gingivitis, 90, 91  
   in cicatricial pemphigoid, 208  
   and lichen planus, 217  
 developmental anomalies, 4-13  
 developmental malformation, fibrous,  
   10, 11  
 diabetes mellitus, 250, 251  
 discoid lupus erythematosus, 188, 189  
 doll's face, in glycogen storage disease type Ib, 240, 241  
 double lip, 8, 9  
 Down's syndrome, 42, 43  
   and fissured tongue, 94  
   and median lip fissure, 102  
 drugs, oral lesions, 68-76  
 Dühring-Brocq disease, 212  
 dyskeratoma, warty, 224, 225  
 dyskeratosis  
   congenita, 16, 17, 18  
   follicularis, 22-4, 23  
   hereditary benign intraepithelial,  
     14, 15  
 dysplasia  
   chondroectodermal, 28, 29  
   cleidocranial, 36, 37  
   hypohidrotic ectodermal, 18, 19
- E
- ecchymosis, on soft palate, in HIV infection, 141  
 ectodermal dysplasia, hypohidrotic,  
   18, 19  
 ectopia lentis, 42  
 edema, angioneurotic, 74, 75  
 Ehlers-Danlos syndrome, 40, 41  
 Ellis-van Creveld syndrome, 28  
 endocrine diseases, 250-3  
 eosinophilic granuloma, 244, 246,  
   246  
   oral mucosa, 54  
 eosinophilic ulcer  
   lower lip, 55  
   oral mucosa, 54  
   tongue, 55  
 epidermal necrolysis, toxic, 200, 201  
 epidermolysis bullosa, 24-6, 25, 26,  
   27  
   acquisita, 214, 214  
   dystrophica, 268, 269  
 Epstein-Barr virus  
   and Burkitt's lymphoma, 300  
   and hairy leukoplakia, in HIV infection, 132  
   and infectious mononucleosis, 124  
 Epstein's pearls, 112
- epulis  
   congenital, of newborn, 340, 340  
   fissuratum, 50, 51  
   granulomatosa, 336  
 eruption cyst, 112, 113  
 erysipelas, 144, 145  
 erythema, tongue, 97  
 erythema multiforme, 198, 198, 199  
   in AIDS, 141  
 erythematous candidosis, 166, 166  
 erythroleukemia, 296, 297  
 erythroplasia, 262, 263  
 etretinate, and cheilitis, 76, 76  
 eugenol  
   and allergic stomatitis, 84, 84  
   burn, 56, 57  
 exodipine, 72  
 exostosis, multiple, 10, 11  
 extraoral fistula, radiation-induced, 81  
 eye  
   melanosis, nevus of Ota, 326  
   pigmentation, in Klippel-Trenaunay-Weber syndrome, 35  
   *see also* ocular  
 eyelid  
   papules and nodules, in primary systemic amyloidosis, 236  
   in paraneoplastic pemphigus, 206
- F
- face  
   angiofibroma, in tuberous sclerosis, 33  
   characteristic  
     in hypohidrotic ectodermal dysplasia, 19  
     in progressive systemic sclerosis, 191  
   doll's, in glycogen storage disease type I b, 240, 241  
   hemangioma  
     in Klippel-Trenaunay-Weber syndrome, 35  
     in Sturge-Weber syndrome, 34  
   swelling, in Melkersson-Rosenthal syndrome, 257  
   in thalassemia major, 229  
 facial hemiatrophy, 12, 13  
 facial nerve palsy, in HIV infection,  
   138, 139  
 factitious trauma, 48, 48  
 familial benign pemphigus, 24, 25  
 fellatio, oral lesions, 48, 49  
 felodipine, 72  
 fibroma, 306, 307  
   giant cell, 306, 307  
   peripheral ossifying, 308, 309  
   periungual, in tuberous sclerosis,  
     32, 33  
 fibromatosis, gingiva, 14, 15



- fibrosarcoma, 284, 285  
 fibrosis  
   cystic, 244, 244  
   submucous, 266, 267  
 fibrous developmental malformation, 10, 11  
 fibrous gingival hyperplasia, phenytoin-induced, 72, 73  
 fibrous histiocytoma  
   benign, 314, 315  
   malignant, 286, 287  
 fibrous tumors, in Gardner's syndrome, 31  
 fingers, small vesicles, in hand-foot-and-mouth disease, 123  
 fistula  
   extraoral, radiation-induced, 81  
   granuloma, 338, 338, 339  
   periodontal, 88, 89  
 focal dermal hyperplasia, 38, 39  
 focal epithelial hyperplasia, 128, 128  
 focal palmoplantar and oral mucosa hyperkeratosis syndrome, 18, 19, 20, 21  
 foliate papillae, hypertrophy, 98, 99  
 foot, small vesicles, in hand-foot-and-mouth disease, 123  
 Fordyce's granules, 4, 5  
   and sebaceous adenoma, 320  
 foreign body reaction, 52  
 Fournier's molars, 156  
 freckle, 322, 323  
   melanotic, of Hutchinson, 326  
 frenula, multiple hyperplastic, in orofacial digital syndrome, 39  
 frenum, lingual, ulcer after cunnilingus, 48, 49  
 fungal infections, 164-73  
 fungiform papillae, hypertrophy, 100, 101  
 furred tongue, 96, 97
- G**
- Gardner's syndrome, 30, 31  
 genetic diseases, 14-43  
 genital lesions, in Stevens-Johnson syndrome, 200  
 geographic stomatitis, 92, 94  
 geographic tongue, 92, 93  
 giant cell fibroma, 306, 307  
 giant cell granuloma, peripheral, 338, 339  
 giant cell tumor, brown, 252, 253  
 gingiva  
   attached, materia alba, 78, 79  
   bismuth deposition, 79  
   in childhood cicatricial pemphigoid, 211  
   in dyskeratosis follicularis, 23  
   erosions, in dermatitis herpetiformis, 213  
   erythema  
     in porphyria cutanea tarda, 243  
     in primary herpetic gingivostomatitis, 117  
   erythroleukemia, 297  
   HIV gingivitis, 135  
   hyperkeratosis, 18, 21  
   leukemia, 295, 296, 297  
   leukoplakia, 261  
   in lupoid hepatitis, 197  
   mucous patches, in secondary syphilis, 153  
   multiple myeloma, 303  
   normal pigmentation, 3  
   pregnancy granuloma, 337  
   pyogenic granuloma, 335  
   radiation-induced lesions, 81  
   in scurvy, 249  
   squamous cell carcinoma, 273  
   in tuberosus sclerosis, 33  
   ulcer  
     in Hand-Schuller-Christian disease, 245  
     in primary herpetic gingivostomatitis, 117  
 gingival cyst  
   of adult, 112, 113  
   of newborn, 112, 113  
 gingival fibromatosis, 14, 15  
 gingival hyperplasia  
   cyclosporine-induced, 72, 73  
   nifedipine-induced, 72, 73  
   phenytoin-induced, 72, 73  
 gingivitis, 85, 85  
   desquamative, 90, 91  
     in cicatricial pemphigoid, 208  
     and lichen planus, 217  
   HIV-associated, 134, 135  
   and mouth breathing, 88, 89  
   necrotizing  
     HIV-related, 134, 136, 136  
     ulcerative, 142, 143  
   plasma cell, 88, 89  
   in pregnancy, 252, 253  
 gingivostomatitis, streptococcal, 144, 145  
 gingivostomatitis, primary herpetic, 116, 117  
 glossitis  
   atrophic, 156, 157  
     in tertiary syphilis, 266, 267  
   benign migratory, 92  
   interstitial, 156, 157  
   median rhomboid, 92, 93, 168, 168  
   plasma cell, 96, 97  
 glossodynia, 96, 97  
 glycogen storage disease type I b, 240, 241  
 gold-induced stomatitis, 68, 69  
 Goltz syndrome, 38  
 gonococcal stomatitis, 158, 159  
 granular cell tumor, 314, 315  
 granuloma  
   eosinophilic, 244, 246, 246  
   oral mucosa, 54  
   fistula, 338, 338, 339  
   lethal midline, 185, 185-6, 187  
   peripheral giant cell, 338, 339  
   postextraction, 336, 337  
   pyogenic, 335, 335-7  
 granulomatosis, Wegener's, 184, 185  
 groove, labioalveolar, traumatic ulcer, 45  
 gumma, 154, 155  
 Gunther's disease, 242
- H**
- Haemophilus ducreyi*, 158  
 Hailey-Hailey disease, 24  
 hair, oral, 4, 5  
 hairy leukoplakia, in HIV infection, 132, 133, 134  
 hairy tongue, 94, 95  
 hand-foot-and-mouth disease, 122, 122, 123  
 Hand-Schuller-Christian disease, 244, 245  
 heat, oral lesions, 64-7  
 Heerfordt's syndrome, 176, 176  
 hemangioendothelioma, 286, 287  
 hemangioma, 316, 317  
   cavernous, and phleboliths, 78, 79  
 facial  
   in Klippel-Trenaunay-Weber syndrome, 35  
   in Sturge-Weber syndrome, 34  
 oral  
   in Klippel-Trenaunay-Weber syndrome, 36  
   in Sturge-Weber syndrome, 35  
 hemangiopericytoma, 286, 287  
 hematologic disorders, 226-33  
 hematoma, traumatic, 46, 47  
 hematopoietic tissue malignancy, 293-303  
 hemiatrophy  
   facial, 12, 13  
   tongue, 13  
 hemochromatosis, 242, 243  
*Hemophilus influenzae*, and cellulitis, 148  
 hemorrhagic telangiectasia, hereditary, 28, 29  
 hepatitis, lupoid, 196, 197  
 hereditary benign intraepithelial dyskeratosis, 14, 15  
 hereditary hemorrhagic telangiectasia, 28, 29  
 herpangina, 120, 121  
 herpes labialis, 118, 119  
 herpes simplex virus (HSV-1), 176, 118  
   in HIV infection, 132

- herpes zoster, 118, 119**  
 oral, and HIV infection, 132
- herpetic gingivostomatitis, primary, 116, 117**
- herpetic stomatitis, secondary, 116, 117
- herpetiform ulcer, 178, 179
- histiocytoma  
 benign fibrous, 314, 315  
 malignant fibrous, 286, 287
- histiocytosis X, 244-6
- Histoplasma capsulatum*, 170
- histoplasmosis, 170, 171
- HIV infection, 129-41  
 and azidothymidine pigmentation, 74  
 and condyloma acuminatum, 126  
 and median lip fissure, 102  
 and molluscum contagiosum, 126  
 and necrotizing ulcerative gingivitis, 142  
 and necrotizing ulcerative stomatitis, 142  
 and recurrent herpetic lesions, 116  
 and tuberculosis, 160  
*see also* AIDS
- Hodgkin's disease, 298, 299**  
 in HIV infection, 138, 139
- horn  
 cutaneous, 320, 321  
 mucosal, tongue, 321
- HPV, *see* human papillomavirus
- HSV-1, *see* herpes simplex virus
- human papillomavirus (HPV)  
 and condyloma acuminatum, 126  
 and focal epithelial hyperplasia, 128  
 in HIV infection, 132  
 and verruca vulgaris, 124
- Hutchinson's melanotic freckle, 326
- Hutchinson's teeth, 157
- hyalinosis cutis et mucosae, 238
- hygroma, cystic, 318, 319
- hyperkeratosis  
 gingiva, 21  
 palm, 19  
 soles, 20  
 syndrome, focal palmoplantar and oral mucosa, 18, 19
- hyperparathyroidism, primary, 252, 253
- hyperpigmentation, in incontinentia pigmenti, 41
- hyperplasia  
 fibrous, denture, 50  
 focal dermal, 38, 39  
 focal epithelial, 128, 128  
 gingival  
 cyclosporine-induced, 72, 73  
 nifedipine-induced, 72, 73  
 phenytoin-induced, 72, 73  
 negative pressure, 52, 53  
 papillary, palate, 50, 51, 166, 167  
 verrucous, 304, 305
- hypertrophy  
 circumvallate papillae, 98, 99  
 foliate papillae, 98, 99  
 fungiform papillae, 100, 101  
 masseteric, 12, 13
- hypoglossal nerve paralysis, 254, 255
- hypothyroidism, 250-2, 251
- immunoglobulin A disease, linear, 210, 211
- immunopathogenetic diseases, 177-87
- incontinentia pigmenti, 40, 41
- infantile genetic agranulocytosis, 228
- infections  
 bacterial, 142-63  
 fungal, 164-73  
 other, 174-6  
 streptococcal, 144, 146, 148  
 viral, 116-28
- injuries, mechanical, 44-55
- interstitial glossitis, 156, 157
- intramucosal nevus, 322, 323
- iodine burn, 58, 59
- ipsilateral masseter spasm, 256, 257
- iritis, in Behyet's syndrome, 182
- iron deficiency anemia, 226, 227
- iron deficiency dysphagia, 265
- jaw, osteosarcoma, 290
- junctional nevus, 324, 325
- juvenile pemphigus vulgaris, 204, 205
- juvenile periodontitis, 86, 87
- K**
- kala-azar, 174
- Kaposi's sarcoma, 284, 285, 286  
 in AIDS, 136, 137, 138
- Kawasaki disease, 220
- keratoacanthoma, 306, 307
- kidney disease, 234, 235
- Klebsiella* infection, 148, 149
- Klippel-Trenaunay-Weber syndrome, 34, 35
- Köbner phenomenon, 214
- kwashiorkor, 248
- L**
- labial, *see* lips
- labia majora, ulcers, in Behget's syndrome, 181
- labioalveolar groove, traumatic ulcer, 45
- Langerhans cell histiocytosis, 244
- leiomyoma, 312, 313
- leishmaniasis, cutaneous, 174, 175  
*Leishmania tropica*, 174
- lentigo maligna, 326, 327
- lentigo simplex, 322, 323
- leprosy, 160, 161, 162, 162
- lesions, tumor-like, 335-40
- lethal midline granuloma, 185, 185-6, 187
- Letterer-Siwe disease, 244, 245
- leukemia, 293-6, 294-7  
 acute, 293, 294  
 chronic, 293-4
- leukoedema, 2, 3
- leukoplakia, 258-62, 258-63  
 candidal, 264, 264  
 in dyskeratosis congenita, 18  
 hairy, in HIV infection, 132  
 and hyperkeratosis, 18
- lichen planus, 214-18, 215-17, 219  
 and carcinoma, 268, 269
- linea alba, 2, 3
- linear immunoglobulin A disease, 210, 211
- lingual frenum, ulcer after cunnilingus, 48, 49
- lip-licking dermatitis, 222, 223
- lipoid proteinosis, 238, 239
- lipoma, 310, 311
- lips  
 agricultural chemical burn, 63  
 chancroid, 159  
 cigarette smoker's, lesion, 66, 67  
 cleft, 6, 7  
 in oro-facial digital syndrome, 38  
 condyloma acuminatum, 127  
 congenital pits, 4, 5  
 cutaneous horn, 321  
 cutaneous leishmaniasis, 175  
 diseases, 102-7  
 double, 8, 9  
 eosinophilic ulcer, 55  
 erythema, in porphyria cutanea tarda, 243  
**in erythema multiforme, 199**  
**fissure, median, 102, 103**  
**hemangioma, 79**  
**herpes labialis, 118, 119**  
**Kaposi's sarcoma, 284, 285**  
**keratoacanthoma, 307**  
**leukoplakia, 262**  
 lupus vulgaris, 161  
 major aphthous ulcer, 179  
 in malignant acanthosis nigricans, 221  
 methotrexate ulcer, 71  
 mucocele, 109  
 mucosa  
 acinic cell carcinoma, 279

- lips, mucosa (*coat.*)  
 in congenital neutropenia, 229  
 dermatitis herpetiformis bulla, 213  
 mucous patches in secondary syphilis, 153  
 pleomorphic adenoma, 329  
 ulcer, in cyclic neutropenia, 229  
 verruca vulgaris, 125  
 verrucous hyperplasia, 305  
 nodules, in primary systemic amyloidosis, 237  
 papillary syringadenoma, 320, 320  
 in paraneoplastic pemphigus, 206  
 pemphigus foliaceus, 204  
 phlebolith, 79  
*Pseudomonas* infection, 151  
 pyogenic granuloma, 337  
 radiation-induced injuries, 80  
 radiation-induced lymphoedema, 82  
 sarcoidosis, 175  
 sebaceous adenoma, 321  
 spindle cell carcinoma, 277  
 squamous cell carcinoma, 275  
 swelling  
 in angioneurotic edema, 75  
 in Crohn's disease, 187  
 in cystic fibrosis, 244  
 in Melkersson-Rosenthal syndrome, 257  
 telangiectasia, in primary biliary cirrhosis, 197  
 in toxic epidermal necrolysis, 201  
 traumatic neuroma, 313  
 ulcer  
 in discoid lupus erythematosus, 189  
 traumatic, 45  
 ulceration, in myelodysplastic syndrome, 233  
 varicella, 121  
 vermilion border  
 freckles, 323  
 lentigo maligna, 327  
 vitiligo, 225  
 lupoid hepatitis, 196, 197  
 lupus **erythematosus**  
**discoid, 188, 189**  
**systemic, 190, 190**  
 lupus **vulgaris, 160, 161**  
**Lyell's disease, 200**  
 lymphadenopathy syndrome (LAS), 129  
**lymphangioma, 318, 318, 319**  
**lymphatic** tissue malignancy, 293-303  
 lymph nodes, cervical, in Hodgkin's disease, 299  
 lymph node syndrome, mucocutaneous, 220, 221  
 lymphoepithelial carcinoma, 276, 277  
 lymphoepithelial cyst, 110, 111  
 lymphoepithelial lesion, benign, 196, 197
- M**
- macroglobulinemia, 302, 303  
 macroglossia  
 in acromegaly, 253  
 in Down's syndrome, 43  
 in primary hypothyroidism, 251  
 in primary systemic amyloidosis, 237  
 macular syphilides, 152, 152  
 Maffucci's syndrome, 30, 31  
 malformation, fibrous developmental, 10, 11  
 malignancy, hematopoietic and lymphatic tissue, 293-303  
 malignant acanthosis nigricans, 220, 221  
 malignant fibrous histiocytoma, 286, 287  
 malignant melanoma, 288, 289  
 malignant neoplasms, 270-92  
 mandible  
 in acute submandibular sialadenitis, 149  
 chondrosarcoma, 289  
 malignant fibrous histiocytoma, 287  
 osteoma, in Gardner's syndrome, 31  
 osteosarcoma, 291  
 peripheral giant cell granuloma, 339  
 radiation-induced injuries, 80  
 torus mandibularis, 10, 11  
 Marfan's syndrome, 42, 43  
 masseteric hypertrophy, 12, 13  
 materia alba, and attached gingiva, 78, 79  
 maxilla  
 alveolar ridge, atrophy, 52, 53  
 fibrous developmental malformation, 11  
 peripheral giant cell granuloma, 339  
 radiation-induced injuries, 80  
 measles, 122, 123  
 mechanical injuries, 44-55  
 median rhomboid glossitis, 168, 168  
 melanoma, malignant, 288, 289  
 melanosis, smoker's, 66, 67  
 melanotic freckle of Hutchinson, 326  
 melanotic neurectodermal tumor of infancy, 328, 328  
 Melkersson-Rosenthal syndrome, 94, 256, 257  
 and cheilitis granulomatosa, 106  
 metabolic diseases, 236-46  
 metal and other deposits, 77-9  
 methotrexate, ulcerations due to, 70, 71  
 midline granuloma, lethal, 185, 185-6, 187  
 Mikulicz's syndrome, 332, 333  
 mixed connective tissue disease, 194, 195  
 molluscum contagiosum, 126, 127  
 in HIV infection, 132, 133  
 mononucleosis, infectious, 124, 125  
 Moon's molars, 156  
 mouth, floor  
 leukoplakia, 262  
 squamous cell carcinoma, 272  
*see also* oral  
 mouth breathing, and gingivitis, 88, 89  
 mucocele, 108, 109  
 mucocutaneous candidosis, chronic, 168, 169  
 mucocutaneous lymph node syndrome, 220, 221  
 mucoepidermoid carcinoma, 280, 281  
 mucolabial fold, erosion, in measles, 123  
 mucormycosis, 172, 173  
 mucous patches, in secondary syphilis, 152, 153  
 mulberry molars, 156  
 multiple exostoses, 10, 11  
 multiple myeloma, 302, 303  
 mumps, 124, 125  
*Mycobacterium leprae*, 160  
 mycosis fungoides, 300, 301  
 myelodysplastic syndrome, 232, 233  
 myeloma, multiple, 302, 303  
 myxoma, 310, 311
- N**
- nails  
 in chronic mucocutaneous candidosis, 169  
 dystrophic, in dyskeratosis congenita, 17  
 and pachyonychia congenita, 16  
 and recessive dystrophic epidermolysis bullosa, 27  
 nasolabial cyst, 114, 115  
 neck  
 swelling, in cystic hygroma, 319  
 thyroglossal duct cyst, 115  
 necrolysis, toxic epidermal, 200, 201  
 necrosis, palate, due to injection, 54, 55  
 necrotizing sialometaplasia, 331, 331  
 necrotizing ulcerative gingivitis, 142, 143  
 necrotizing ulcerative stomatitis, 142, 143  
 negative pressure hyperplasia, 52, 53  
*Neisseria gonorrhoeae*, 158

- neoplasms  
 in HIV infection, 136-8  
 malignant, 270-92
- nerves  
 facial, palsy, in HIV infection, 138, 139  
 hypoglossal, paralysis, 254, 255  
 peripheral facial, paralysis, 254, 255
- neuroectodermal tumor, melanotic, of infancy, 328, 328
- neurilemoma, 312
- neurofibroma, 310, 311
- neurofibromatosis, 26, 27
- neurologic disturbance, in HIV infection, 138, 139
- neuroma, traumatic, 312, 313
- neutropenia  
 congenital, 228, 229  
 cyclic, 228-30, 229
- nevus  
 blue, 324, 325  
 compound, 324, 325  
 intramucosal, 322, 323  
 junctional, 324, 325  
 of Ota, 326, 326. 327  
 white sponge, 14, 15
- newborns  
 congenital epulis, 340, 340  
 gingival cyst, 112, 113
- nicotinic stomatitis, 64, 65
- nifedipine, and gingival hyperplasia, 72, 73
- Nikolsky's sign, 202
- nitrendipine, 72
- nodular candidosis, 166, 167
- noma, 142, 143
- non-Hodgkin's lymphoma (NHL), 298, 299  
 in HIV infection, 138, 139
- North American blastomycosis, 170, 171
- nose, nodules, in lipoid proteinosis, 239
- nutritional disorders, 247-9
- O
- ocular lesions  
 in cicatricial pemphigoid, 209  
 in pemphigus vulgaris, 203
- ocular melanosis, nevus of Ota, 326
- oligodontia, in incontinentia pigmenti, 41
- oral hemangioma  
 in Klippel-Trenaunay-Weber syndrome, 36  
 in Sturge-Weber syndrome, 35
- oral lesions  
 and chemical agents, 56-63  
 and drugs, 68-76  
 penicillamine-induced, 70, 71
- from smoking and heat, 64-7
- oral mucosa, plasmacytoma, 302, 303
- oriental sore, 174
- oro-facial digital syndrome, 38, 39
- Osler-Rendu-Weber disease, 28
- ossifying fibroma, peripheral, 308, 309
- osteoradionecrosis, 80
- osteosarcoma, 290, 290, 291
- Ota's nevus, 326, 326. 327
- P
- pachyonychia congenita, 16, 16, 17
- palate  
 adenocarcinoma, 283  
 adenoid cystic carcinoma, 281  
 benign lymphoepithelial lesion, 197  
 blue nevus, 325  
 chronic pseudo membranous candidosis, 165  
 clear cell adenocarcinoma, 283  
 cleft, 6, 7  
 in oro-facial digital syndrome, 38  
 compound nevus, 325  
 ecchymosis, and thrombocytopenic purpura, 141
- erosion  
 in cicatricial pemphigoid, 207  
 due to smoking, 64, 65  
 penicillamine-induced, 71
- erythema caused by fellatio, 49
- hemangioendothelioma, 287
- hemangiopericytoma, 287
- herpes zoster, 119
- high, in cleidocranial dysplasia, 37
- Kaposi's sarcoma, 286
- lentigo, 323
- lesions, in North American blastomycosis, 171
- in lethal midline granuloma, 185
- leukemia, 294, 295
- macular syphilides, 152, 152
- malignant pleomorphic adenoma, 283
- in Marfan's syndrome, 43
- melanoma, 289
- metastatic carcinoma, 291
- in mixed connective tissue disease, 195
- mucoepidermoid carcinoma, 281
- mucous patches in secondary syphilis, 153
- multiple myeloma, 303
- necrosis, due to injection, 54, 55
- necrotizing sialometaplasia, 331, 331
- negative pressure hyperplasia, 53
- nevus of Ota, 327
- in non-Hodgkin's lymphoma, 299
- papillary hyperplasia, 50, 51, 166, 167
- papules, in acute lymphonodular pharyngitis, 121
- petechiae, in infectious mononucleosis, 125
- plasmacytoma, 303
- pleomorphic adenoma, 329
- polymorphous low-grade adenocarcinoma, 285
- pseudomembranous candidosis, in HIV infection, 130
- smoker's, 64
- smoker's melanosis, 67
- soft-tissue osteoma, 309
- squamous cell carcinoma, 274
- torus palatinus, 8, 9
- ulcer  
 in Hand-Schieller-Christian disease, 245  
 in herpangina, 121  
 in Letterer-Siwe disease, 245  
 in secondary herpetic stomatitis, 117
- ulceration  
 in HIV infection, 141  
 in mucormycosis, 173  
 in paracoccidioidomycosis, 173
- warty dyskeratoma, 225
- palatine papilla cyst, 114, 114
- palm, hyperkeratosis, 19
- papillary cystadenoma lymphomatosum, 330, 330
- papillary hyperplasia, palate, 50, 51, 166, 167
- papillary syringadenoma, lower lip, 320, 320
- papilloma, 304, 305
- Papillon-Lefevre syndrome, 20, 21
- papular syphilides, 154, 154, 155
- Paracoccidioides brasiliensis*, 172
- paracoccidioidomycosis, 172, 173
- paraformaldehyde burn, 60, 61
- paraneoplastic pemphigus, 206, 206
- parotid duct, acute suppurative parotitis, 147
- parotid gland  
 pleomorphic adenoma, 329  
 sialadenosis, 333  
 swelling, in mumps, 125
- parotitis, acute suppurative, 146, 147
- pellagra, 247, 247, 248
- pemphigoid  
 bullous, 210, 211, 212  
 and desquamative gingivitis, 90  
 cicatricial, 207-9, 207-10, 211  
 and desquamative gingivitis, 90, 91
- pemphigus, 202-6  
 erythematous, 204, 205  
 familial benign, 24, 25  
 foliaceous, 204, 204  
 paraneoplastic, 206, 206

- pemphigus (*cont.*)  
 penicillamine-induced, 70, 71  
 vegetans, 202, 203  
 vulgaris, 202, 202  
   juvenile, 204, 205  
 vulgaris, and desquamative gingivitis, 90, 91  
*see also* juvenile pemphigus vulgaris
- penicillamine, oral lesions due to, 70, 71
- penis, erosions and scarring, in cicatricial pemphigoid, 209
- periodontal diseases, 85-91  
 abscess, 86, 87  
 fistula, 88, 89
- periodontitis, 86, 87  
 in congenital neutropenia, 229  
 in diabetes mellitus, 251  
 HIV-associated, 134, 135  
 juvenile, 86, 87  
 necrotizing, 135
- perioral dermatitis, 222, 223
- peripheral facial nerve paralysis, 254, 255
- peripheral giant cell granuloma, 338, 339
- peripheral nervous system disease, 254-7
- peripheral ossifying fibroma, 308, 309
- peritonsillar abscess, 146, 147
- periungual fibroma, in tuberous sclerosis, 32, 33
- perleche, 102
- pernicious anemia, 226-8, 227
- Petterson-Kelly syndrome, 265
- Peutz-Jeghers syndrome, 28, 29
- pharyngitis, acute lymphonodular, 120, 121
- phenol burn, 56, 57
- phenytoin, and gingival hyperplasia, 72, 73
- phleboliths, 78, 79
- pigmentation  
 and antimalarial drugs, 74, 75  
 incontinentia pigmenti, 40, 41  
 ocular, in Klippel-Trenaunay-Weber syndrome, 35  
 oral, normal, 2, 3
- plasma cell cheilitis, 106, 107
- plasma cell gingivitis, 88, 89
- plasma cell glossitis, 96, 97
- plasmacytoma of the oral mucosa, 302, 303
- pleomorphic adenoma, 328, 329**  
 malignant, 282, 283
- Plummer-Vinson syndrome, 226, 227**  
 as precancerous condition, 265, 265
- Pneumocystis carinii* pneumonia, in AIDS, 141
- polycythemia vera, 296, 297
- polymorphous low-grade adenocarcinoma, 284, 285
- porphyria, 242, 243  
 congenital, 242  
 cutanea tarda, 243
- postextraction granuloma, 336, 337**
- Prader-Willi syndrome, and benign acanthosis nigricans, 22**
- precancerous conditions, 265-9**
- precancerous lesions, 258-64**
- pregnancy granuloma, 336, 337**
- primary biliary cirrhosis, 196, 197**
- primary hyperparathyroidism, 252, 253**
- primary systemic amyloidosis, 236, 236, 237
- progressive systemic sclerosis, 190-2, 191, 193
- protein deficiency, 248, 249
- proteinosis, lipoid, 238, 239**
- pseudomembranous candidosis, 164, 165**
- Pseudomonas* infection, 150, 151
- psoriasis, 218, 219**
- purpura, thrombocytopenic, 232, 233**  
 in HIV infection, 140, 141
- pyogenic granuloma, 335, 335-7**
- R
- radiation-induced injuries, 80-2
- radiation therapy, 80
- radioactive implants, 80
- ranula, 108, 109
- Raynaud's phenomenon, 190
- Recklinghausen's disease, 26
- regional enteritis, 186
- Reiter's syndrome, 182-4, 183, 184
- renal disease, 234, 235**
- retinoids, and cheilitis, 76, 76**
- retromolar area  
 junctional nevus, 325  
 mucoepidermoid carcinoma, 281
- rhomboid glossitis, median, 92, 93, 168, 168
- S
- salivary glands  
 disorders, 331-4  
 in Heerfordt's syndrome, 176, 176  
 in Mikulicz's syndrome, 333
- sarcoidosis, 174, 175**  
 and cheilitis granulomatosa, 106
- scarlatina, 144
- scarlet fever, 144, 145**
- schwannoma, 312, 313**
- scleroderma, 190-2, 191, 193**
- sclerosis**  
 progressive systemic, 190-2, 191, 193  
 tuberous, 32, 33
- scrotal tongue, 94
- scrotum, ulcers, in Behcet's syndrome, 181
- scurvy, 248, 249**
- sebaceous adenoma, 320, 321
- sex hormone disorders, 252
- shoulder, hypermobility, in cleidocranial dysplasia, 37
- sialadenitis, acute submandibular, 148, 149
- sialadenosis, 332, 333
- sialolithiasis, 332, 333
- sialometaplasia, necrotizing, 331, 331
- silver nitrate burn, 60, 61
- Sjögren's syndrome, 194, 195
- skin diseases, 198-225
- smoking, oral lesions, 64-7
- sodium hypochlorite burn, 60, 61
- sodium perborate burn, 60, 60
- soft-tissue abscess, oral, 146, 147**
- soft-tissue cysts, 108-15**
- soft-tissue osteoma, 308, 309**
- sole, hyperkeratosis, 20, 21**
- South American blastomycosis, 172, 173
- spasm, ipsilateral masseter, 256, 257
- spindle cell carcinoma, 276, 277
- squamous cell carcinoma, 270, 271-5  
 adenoid, 276, 277
- lip, 269**  
 and submucous fibrosis, 266, 267  
 tongue, 267, 269
- Staphylococcus aureus*  
 and acute submandibular sialadenitis, 148  
 and acute suppurative parotitis, 146  
 and buccal cellulitis, 148  
 and oral soft-tissue abscess, 146
- Staphylococcus pyogenes*, and acute submandibular sialadenitis, 148
- Stevens-Johnson syndrome, 199, 199-200, 200, 201**
- stomatitis**  
 allergic  
 due to acrylic resin, 83, 83, 84  
 due to eugenol, 84, 84  
 antibiotic-induced, 68, 69  
 cotton roll, 48, 49  
 denture, 50, 51, 168, 169  
 geographic, 92, 94  
 gold-induced, 68, 69  
 gonococcal, 158, 159  
 medicamentosa, 68, 69  
 migratory, 92  
 necrotizing, in HIV infection, 136, 137  
 necrotizing ulcerative, 142, 143  
 nicotinic, 64, 65  
 secondary herpetic, 116, 117  
 uremic, 234, 235
- strawberry tongue, 220
- streptococcal gingivostomatitis, 144, 145

- streptococcal infections, 144, 146, 148  
*Streptococcus mitis*, 177  
***Streptococcus pyogenes*, and peritonsillar abscess, 146**  
***Streptococcus sanguis*, 177**  
***Streptococcus viridans***  
 and acute submandibular sialadenitis, 148  
 and acute suppurative parotitis, 146  
 Sturge-Weber syndrome, 34, 34, 35  
 submandibular glands  
 enlargement, in Sjögren's syndrome, 195  
 sialolith, 333  
 submandibular sialadenitis, acute, 148, 149  
 submucous fibrosis, 266, 267  
 suppurative parotitis, acute, 146, 147  
 symblepharon, in cicatricial pemphigoid, 209  
 syphilides  
 macular, 152, 152  
 papular, 154, 154, 155  
 syphilis, 150, **151**  
**congenital, 156, 157**  
 late, 154-6  
 primary, 150  
 secondary, 152-4  
 tertiary, atrophic glossitis, 266, 267  
 syringadenoma of the lower lip, papillary, 320, 320  
 syringocystadenoma papilliferum, 320  
 systemic amyloidosis, primary, 236, 236, 237  
 systemic sclerosis, progressive, **190-2, 191, 193**  
 systemic lupus erythematosus, 190, 190
- T**
- target lesions, in erythema multiforme, 198
- teeth  
 in congenital syphilis, 156, 157  
 loss, in Papillon-Lefevre syndrome, 21  
 migration, in periodontitis, 86, 87  
 noneruption, in cleidocranial dysplasia, 37  
 peg-shaped, in incontinentia pigmenti, 41  
 postextraction granuloma, 337  
 radiation-induced lesions, 81  
 telangiectasia  
 hereditary hemorrhagic, 28, 29  
 in primary biliary cirrhosis, 196, 197  
 in progressive systemic sclerosis, 190, 193  
 tetracycline, and antibiotic-induced stomatitis, 68
- thalassemia, 228, 229  
 thermal **burn, 66, 67**  
**thrombocytopenic purpura, 232, 233**  
**in HIV infection, 140, 141**  
**thyroglossal duct cyst, 114, 115**  
 toe, gangrene, in progressive systemic sclerosis, 191
- tongue (cont.)  
 hematoma, in uremic stomatitis, 235  
 hemiatrophy, 11  
 in hereditary hemorrhagic telangiectasia, 29  
 herpetiform ulcers, 179  
 in hypertrophic lichen planus, 227  
 in late syphilis, 156, 157  
 leiomyoma, 313  
**lesions, in psoriasis, 219**  
**leukoplakia, 258, 261**  
 lingual frenum ulcer after cunnilingus, 48, 49  
 in lipoid proteinosis, 239  
 lymphangioma, 318, 319  
 lymphoepithelial carcinoma, 277  
 major aphthous ulcer, 179  
 metastatic carcinoma, 292  
 mucocele, 109  
 in mucocutaneous lymph node syndrome, 221  
 mucosal horn, 321  
 multiple papillomas, in focal dermal hyperplasia, 39  
 mycosis fungoides, 301  
 neurofibroma, 311  
 in neurofibromatosis, 27  
 non-Hodgkin's lymphoma ulcer, 300  
 papilloma, 305  
 in pellagra, 248  
 pemphigus erythematosus, 205  
 pemphigus vulgaris erosions, 202  
 in pernicious anemia, 227  
 in Plummer-Vinson syndrome, 265  
 in primary systemic amyloidosis, 237  
 in progressive systemic sclerosis, 191  
 in protein deficiency, 249  
 pyogenic granuloma, 336  
 radiation-induced erosion, 81  
 in recessive dystrophic epidermolysis bullosa, 26  
 in reticular lichen planus, 215  
 scarlet fever, 145  
 schwannoma, 313  
 scrotal, 94  
 in Sjögren's syndrome, 195  
 squamous cell carcinoma, 267, 269, 271-2  
 strawberry, 220  
 submucous fibrosis, 267  
 syphilitic chancre, 151  
 thyroglossal duct cyst, 115  
 traumatic ulcer, 44, 45  
 tuberculous ulcer, 159  
 ulcer  
 in agranulocytosis, 231  
 in aplastic anemia, 233  
 in glycogen storage disease type 1b, 241

tongue, ulcer (cont.)  
 in primary herpetic gingivostomatitis, 117  
 verruciform xanthoma, 315  
 verrucous carcinoma, 276  
 in dyskeratosis congenita, 18  
 in Wegener's granulomatosis, 185  
 in xerostomia, 334  
 see also lingual; macroglossia

tongue-tie, 6, 6

tonsillar area, abscess, 147

toothbrush trauma, 46, 47

torus mandibularis, 10, 11

torus palatinus, 8, 9

toxic epidermal necrolysis, 200, 201

trauma, self-inflicted, 48

traumatic neuroma, 312, 313

traumatic ulcer, 44, 44, 45

*Treponema pallidum*, 150

trichloroacetic acid burn, 56, 57

tuberculosis, 158, 159, 160, 160  
 and HIV infection, 160

tuberous sclerosis, 32, 33

tumor-like lesions, 335-40

tumors  
 benign, 304-30  
 fibrous, in Gardner's syndrome, 31  
 giant cell, brown, 252, 253  
 granular cell, 314, 315  
 melanotic neurectodermal, of  
 infancy, 328, 328, 328, 328  
 metastatic, 290, 291-2  
 see also adenocarcinoma; carcinoma; malignant neoplasms

## U

ulcer  
 aphthous  
 in HIV infection, 140, 140  
 major, 178, 179

minor, 177, 177  
 recurrent, 177  
 eosinophilic, oral mucosa, 54  
 herpetiform, 178, 179  
 traumatic, 44, 45

ulceration  
 due to azathioprine, 70, 71  
 due to methotrexate, 70, 71

ulcerative gingivitis, necrotizing, 142, 143

ulcerative stomatitis, necrotizing, 142, 143

Urbach-Wiethe disease, 238

*Ureaplasma urealyticum*, 182

uremic stomatitis, 234, 235

uvula  
 aphthous ulcer, in HIV infection, 140  
 bifid, 6, 7  
 papules, in acute lymphonodular pharyngitis, 121

## V

varicella, 120, 121

varices, sublingual, 100, 101

verapamil, 72

vermillion border, lips  
 freckles, 323  
 lentigo maligna, 327

verruca vulgaris, 124, 125

verruciform xanthoma, 314, 315

verrucous carcinoma, 274, 275, 276  
 tongue, in dyskeratosis congenita, 18

**verrucous hyperplasia, 304, 305**

**Vincent's spirochete, and cancrum oris, 142**

viral infections, 116-28

vittiligo, 224, 225

## W

Waldenström's disease, 302

wart  
 common, see verruca vulgaris  
 genital, see condyloma acuminatum

warty dyskeratoma, 224, 225

Wegener's granulomatosis, 184, 185

white sponge nevus, 14, 15

Wickham's striae, 216

Wilson's disease, 70

## X

xanthoma, 240, 241  
 verruciform, 314, 315

xeroderma pigmentosum, 268, 269

xerostomia, 334, 334  
 in Plummer-Vinson syndrome, 226

## Z

zidovudine, and pigmentation, 74, 75

Zinsser-Engman-Cole syndrome, 16